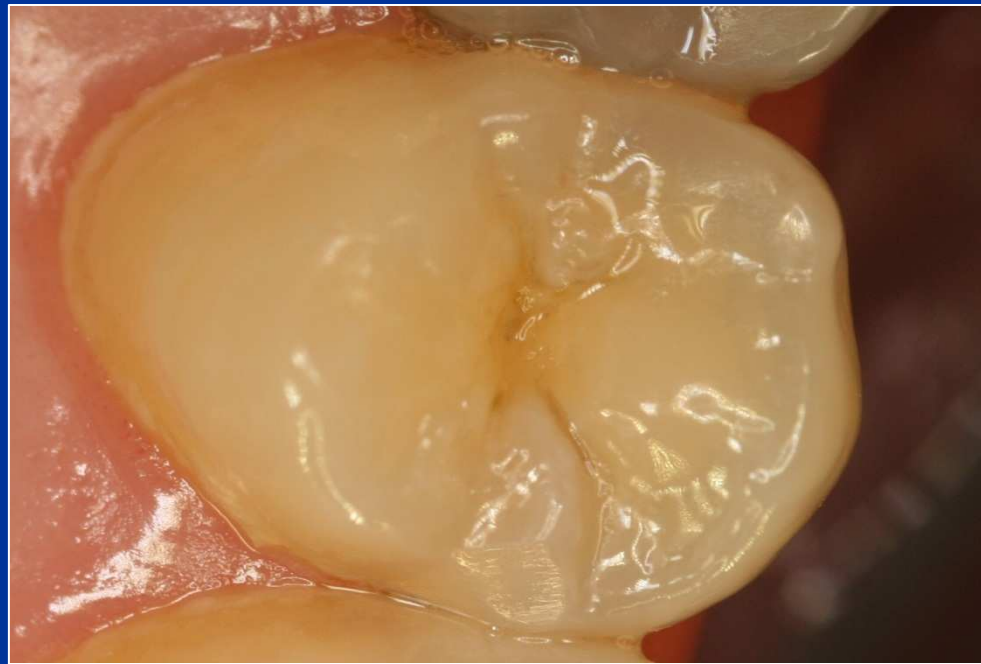

Class II. cavity preparation

Defects affecting one or both proximal surfaces of posterior teeth.

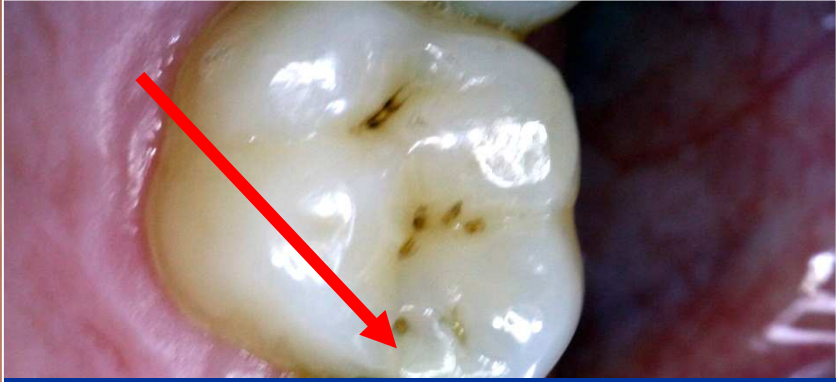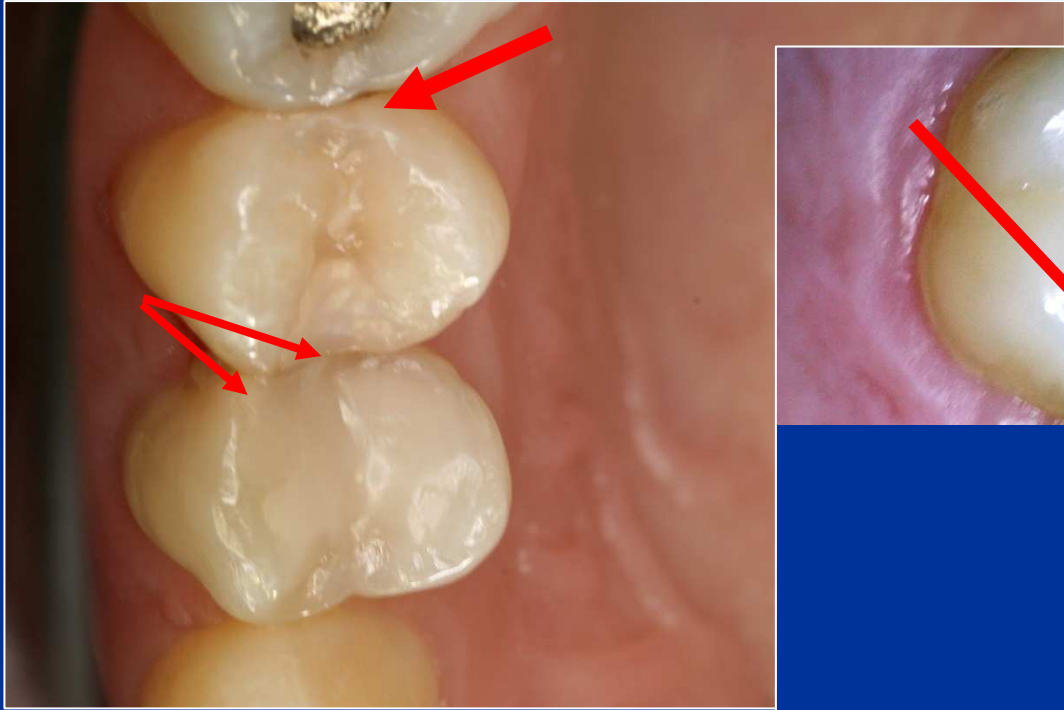


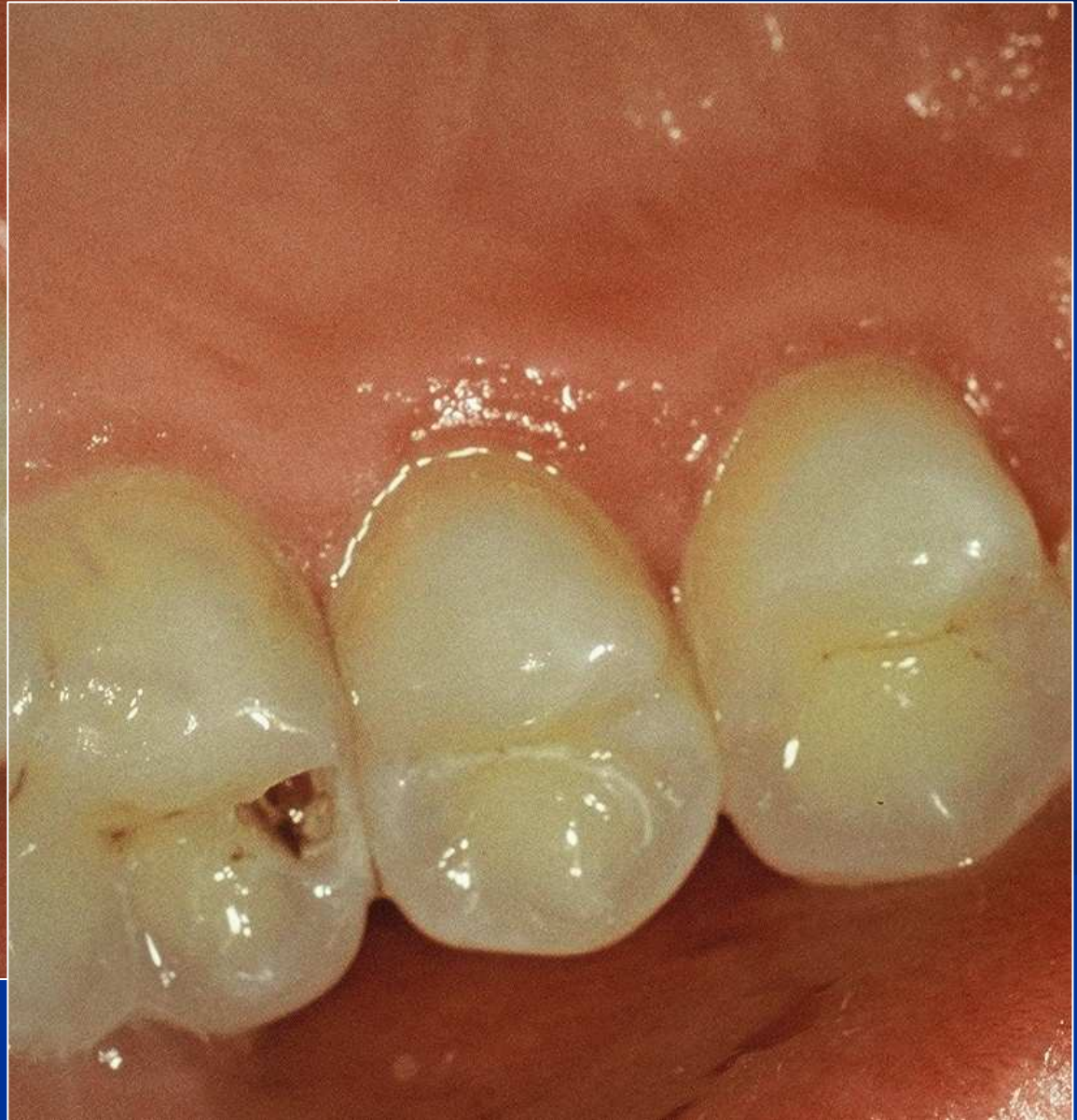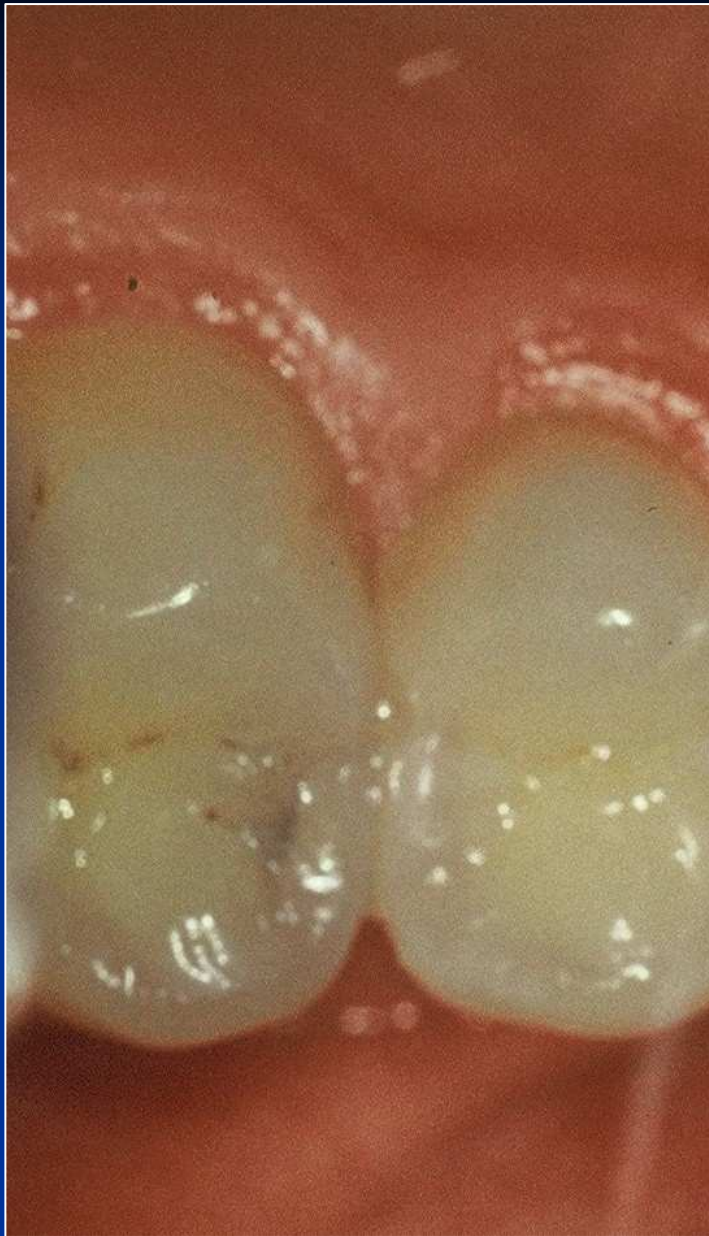Symptoms

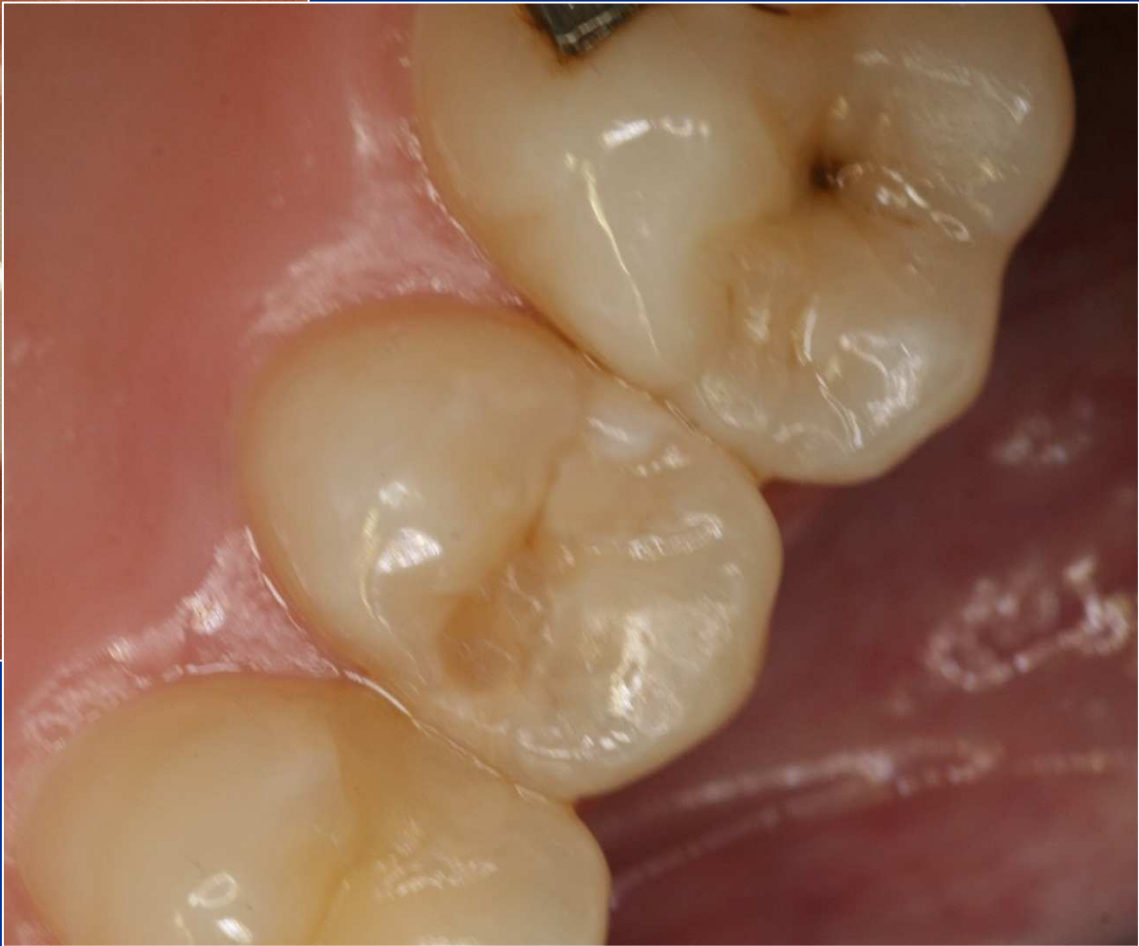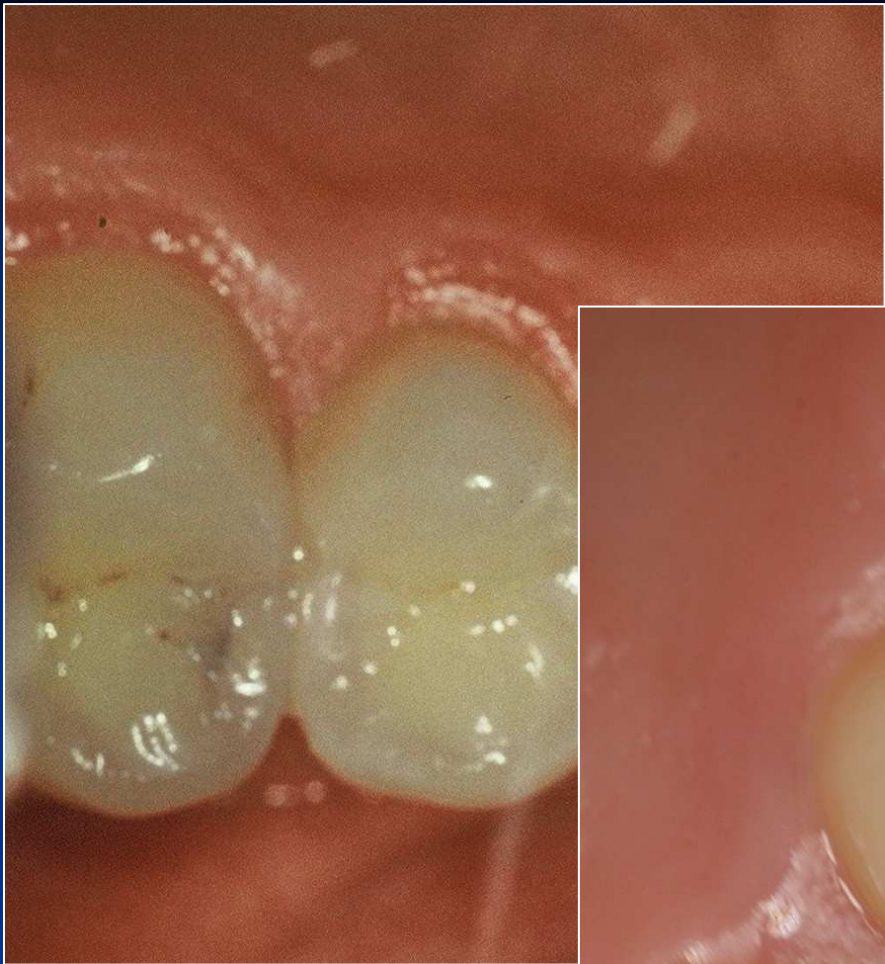- No symptoms
- Increased sensitivity (cold, sweet)
- Retention of food
- Defect (cariious lesion is open – the enamel is broken)
- Bite sensitivity (when cariious lesion is open)

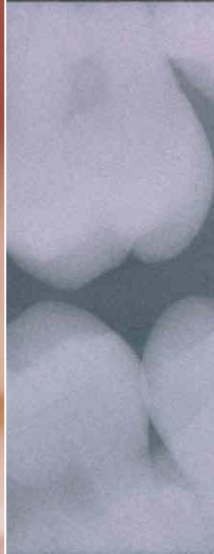
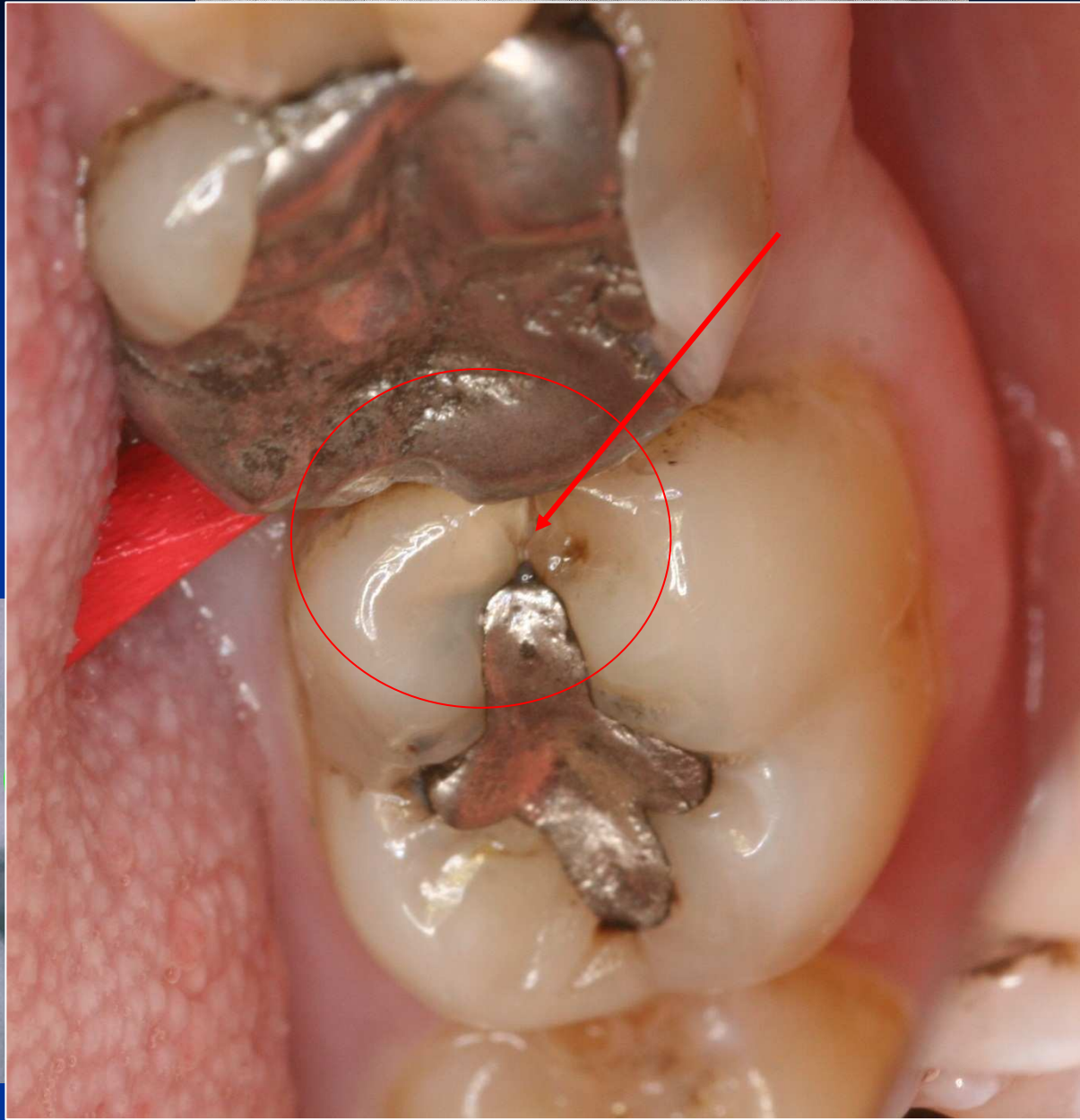
Diagnosis

- Visual changes of tooth structure
- Transillumination
- Radiography









KTG vyšetření = Bite wing

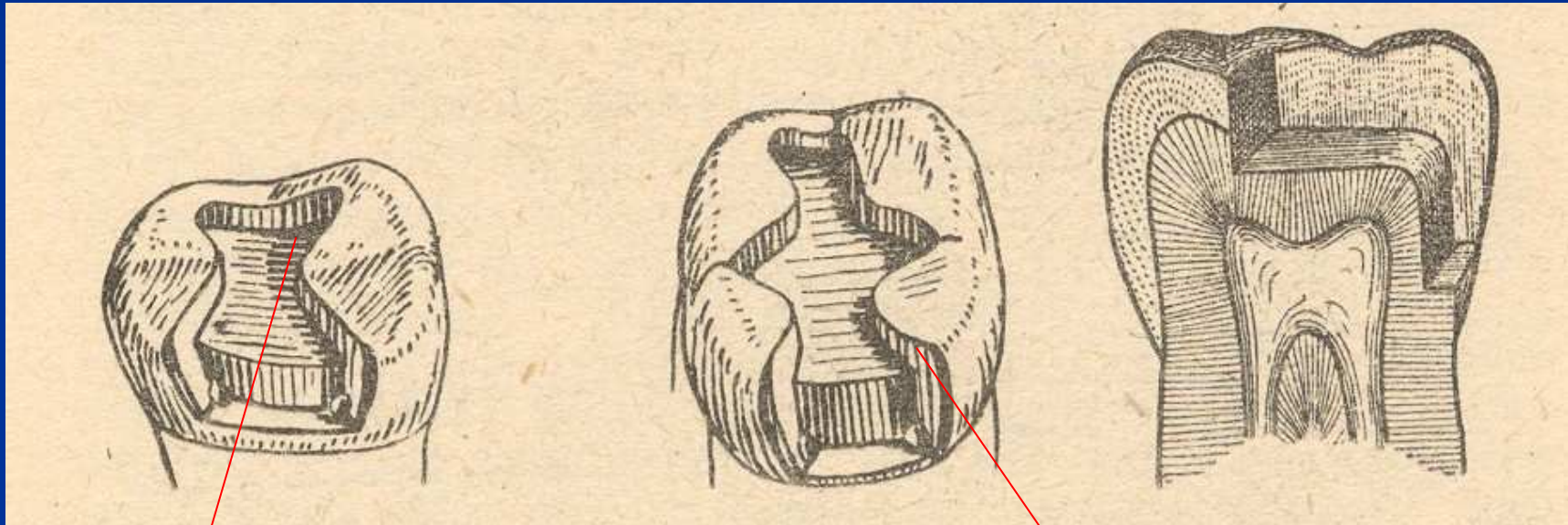
Preparation - amalgam

- Conventional preparation acc. to the Black's rules
- Slot preparation
- Large preparation – cusp(s) involved

Preparation - adhesive materials

- Conventional preparation for composites
- Adhesive slot
- Tunnel preparation

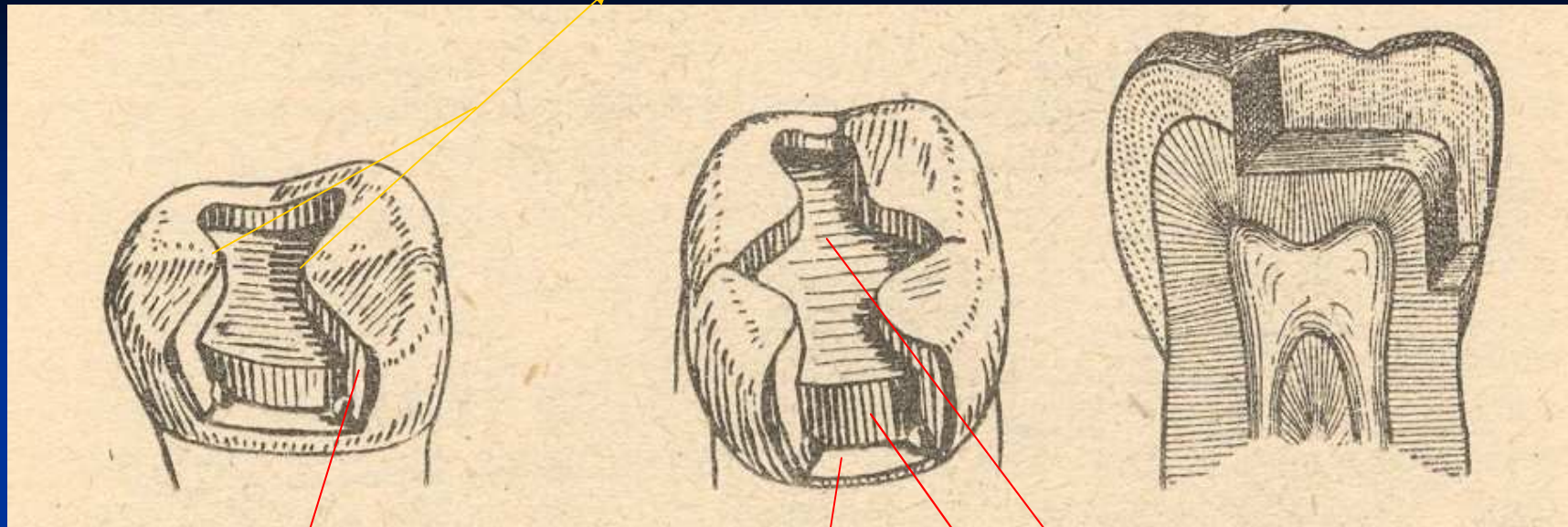
Conventional preparation



Occlusal cavity

Proximal cavity - box

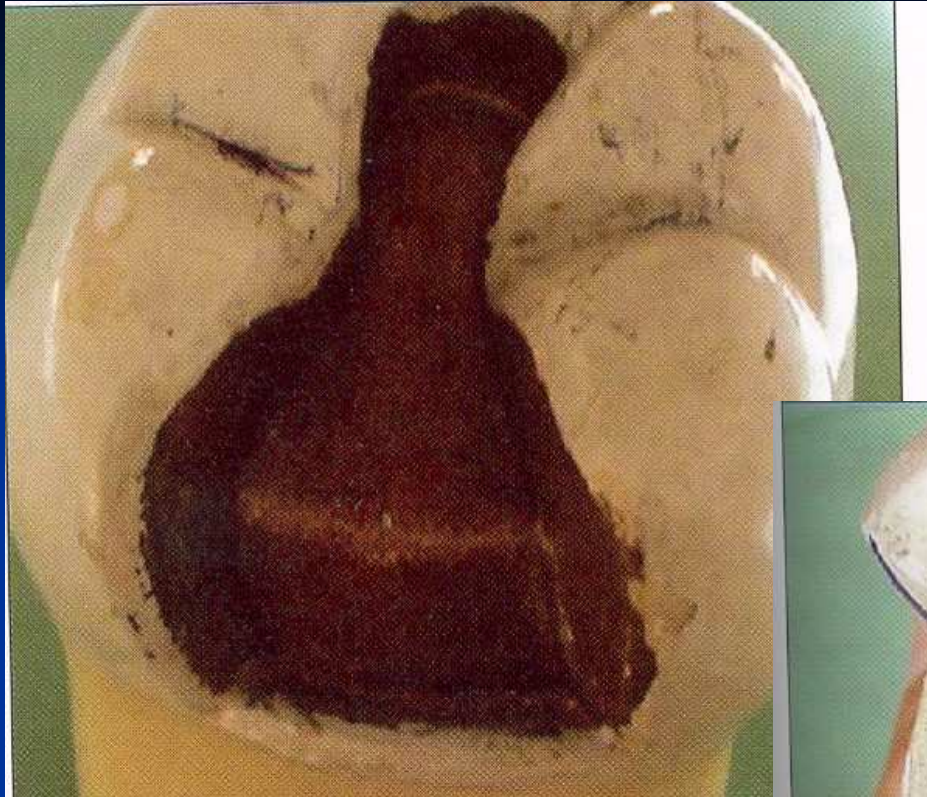Isthmus



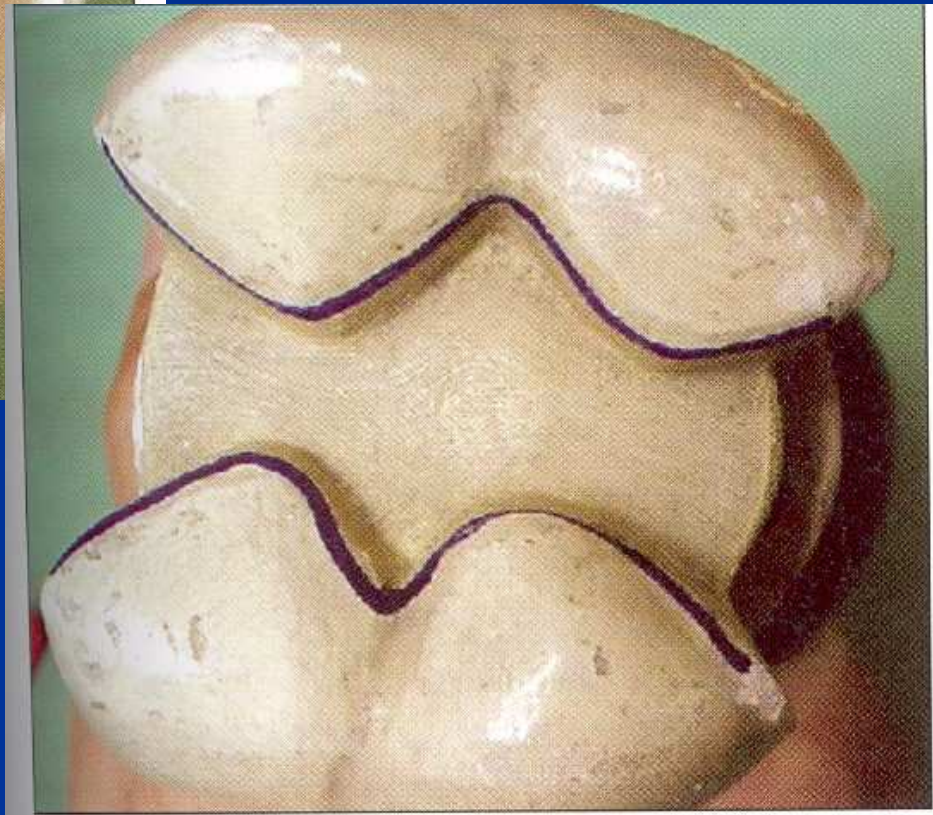
Axial wall

Pulpal walls

Gingival wall



MO – mesioocclusal
OD occlusal – distal
MOD



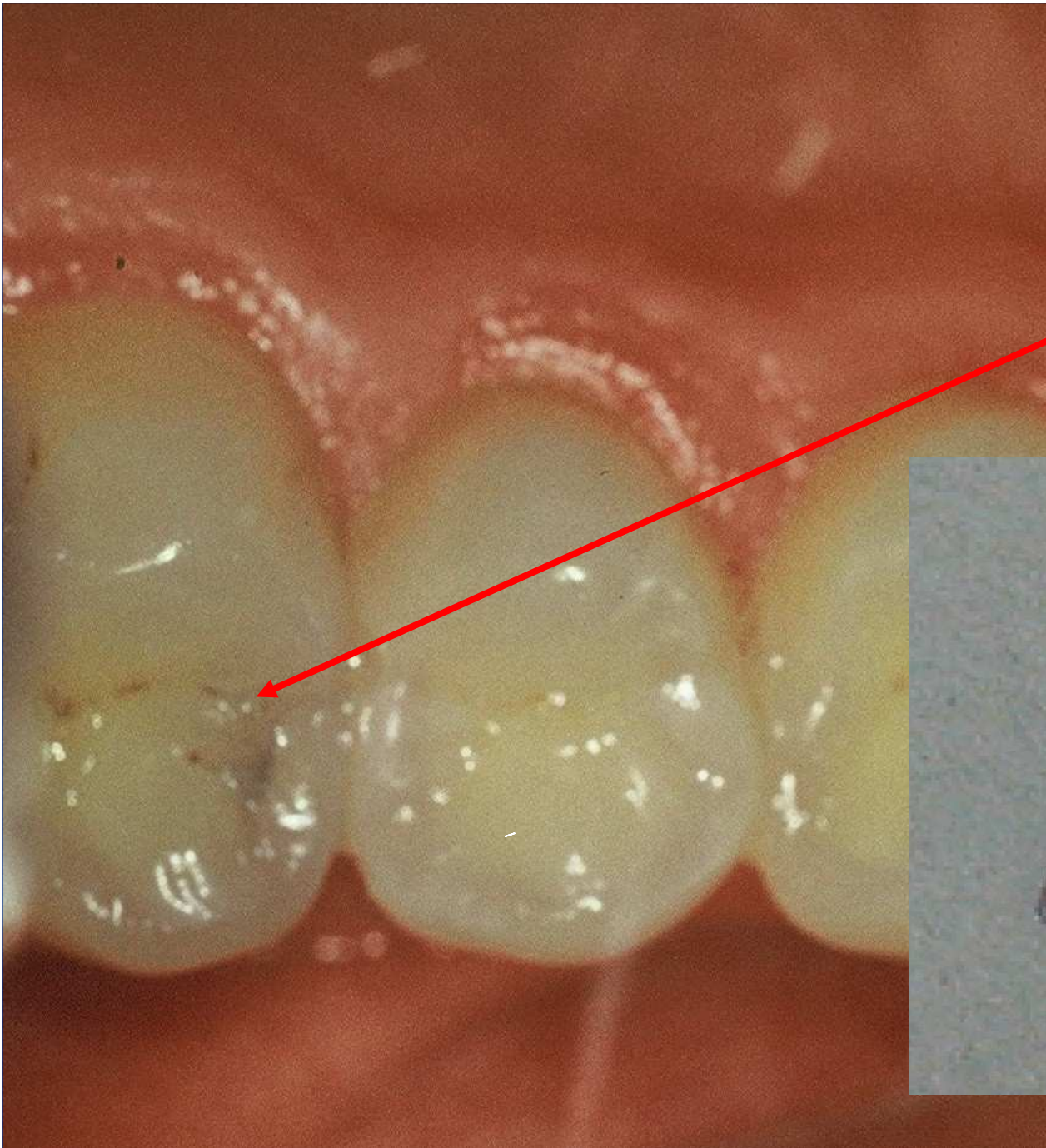
Access to the cavity

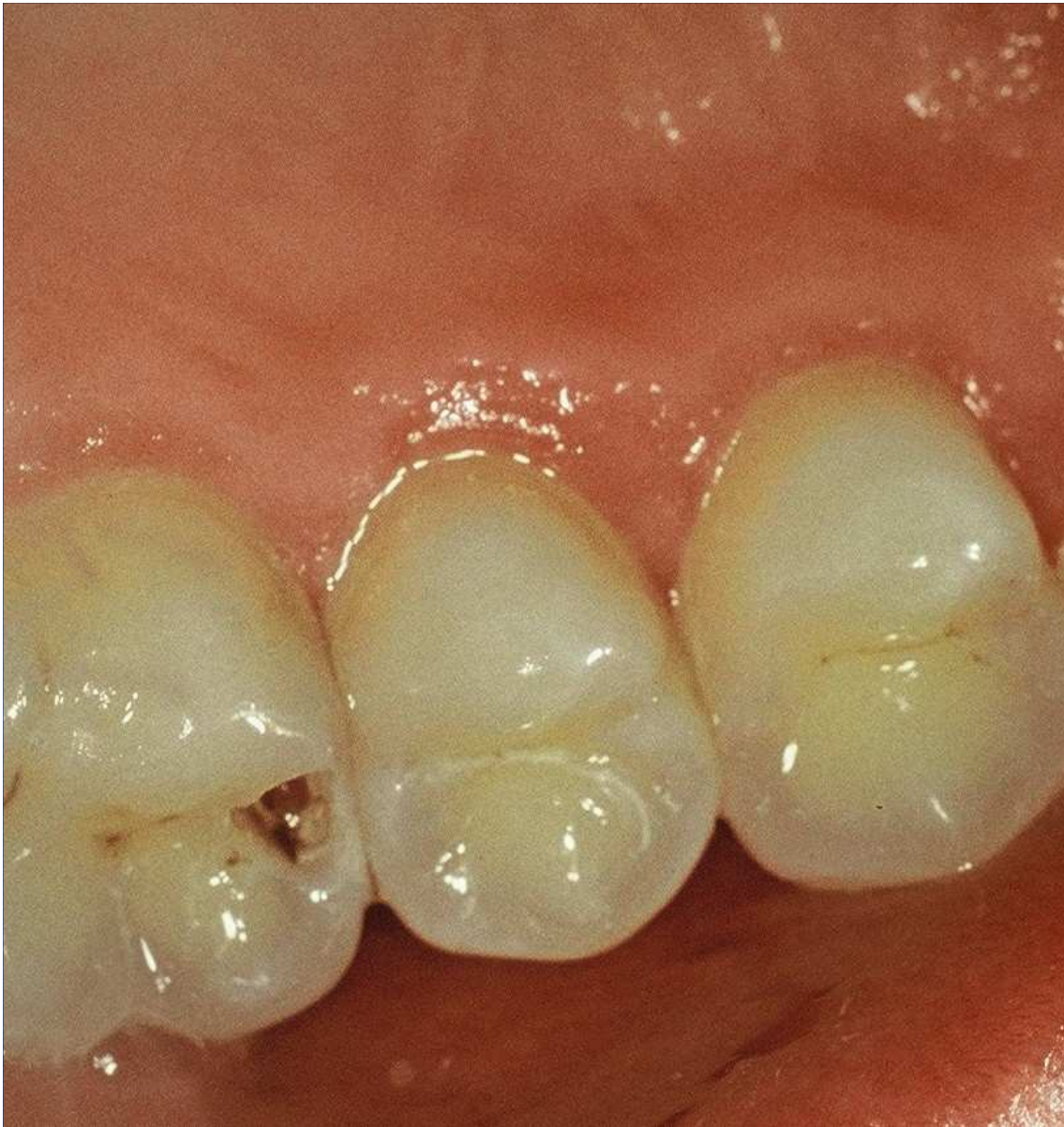From the occlusal surface

Through the undermined enamel

Separation using wooden wedges is useful

Pre op

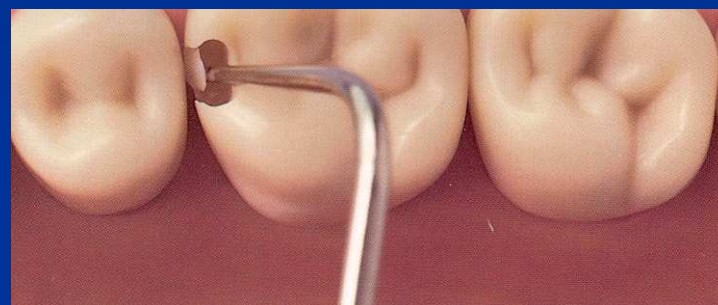
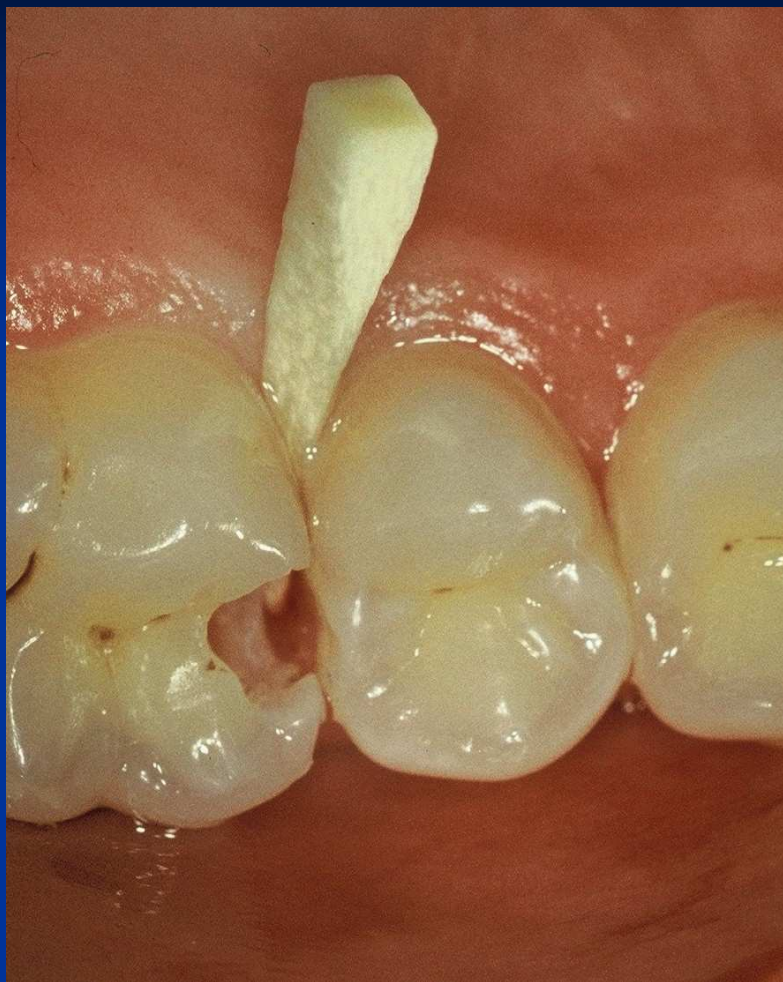

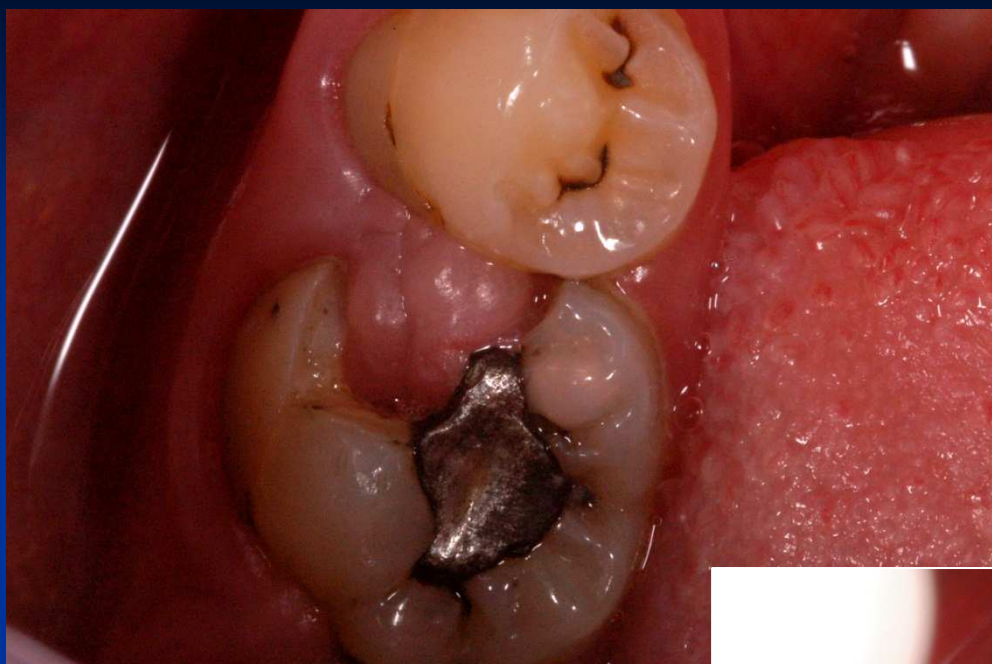


Access to the cavity

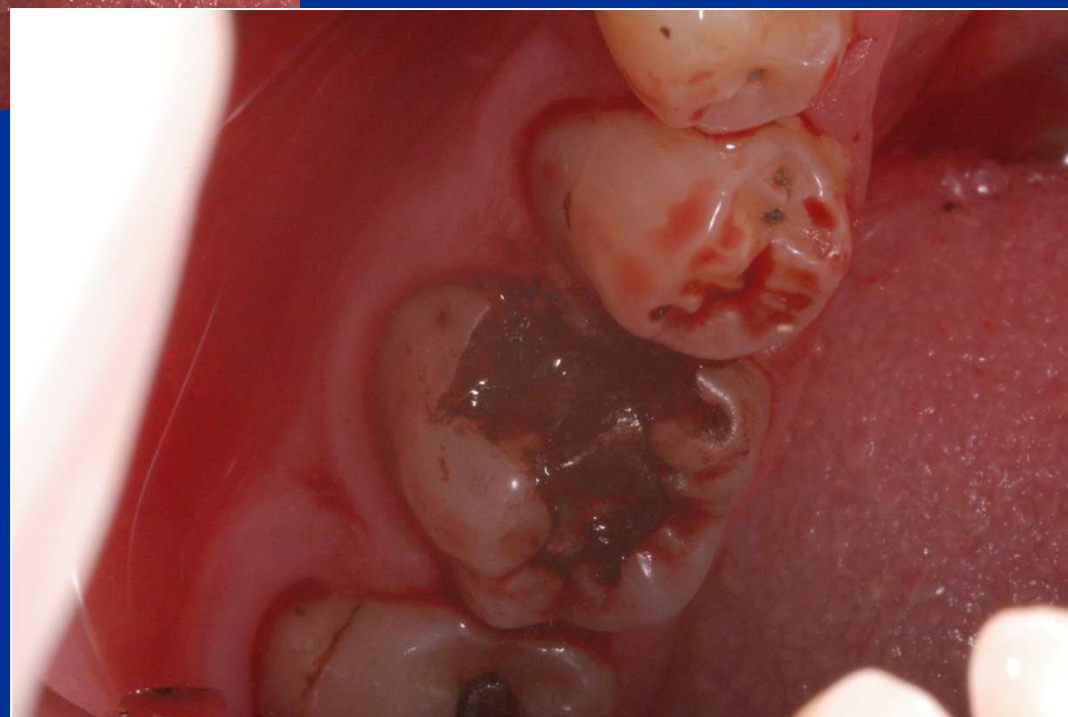lroubal@med.muni.cz







- Skalpel
- Kauter
- Laser
- Temporary filling



Cavosurface margin

Proximal box:


Axial wedges

Under the free gingiva

Occlusal

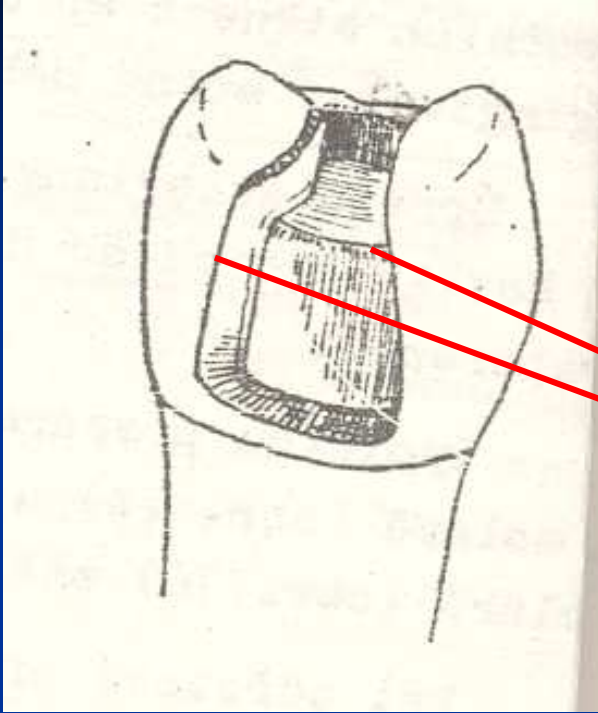
Class I. cavity preparation

American rule

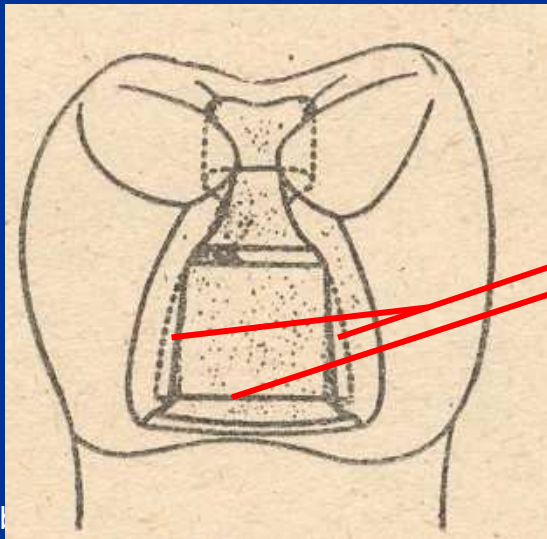


Retention

- Occlusal cavity – auxiliary cavity on occlusal surface
- Undercuts
- Grooves



Axial walls
are divergent
in the gingival direction

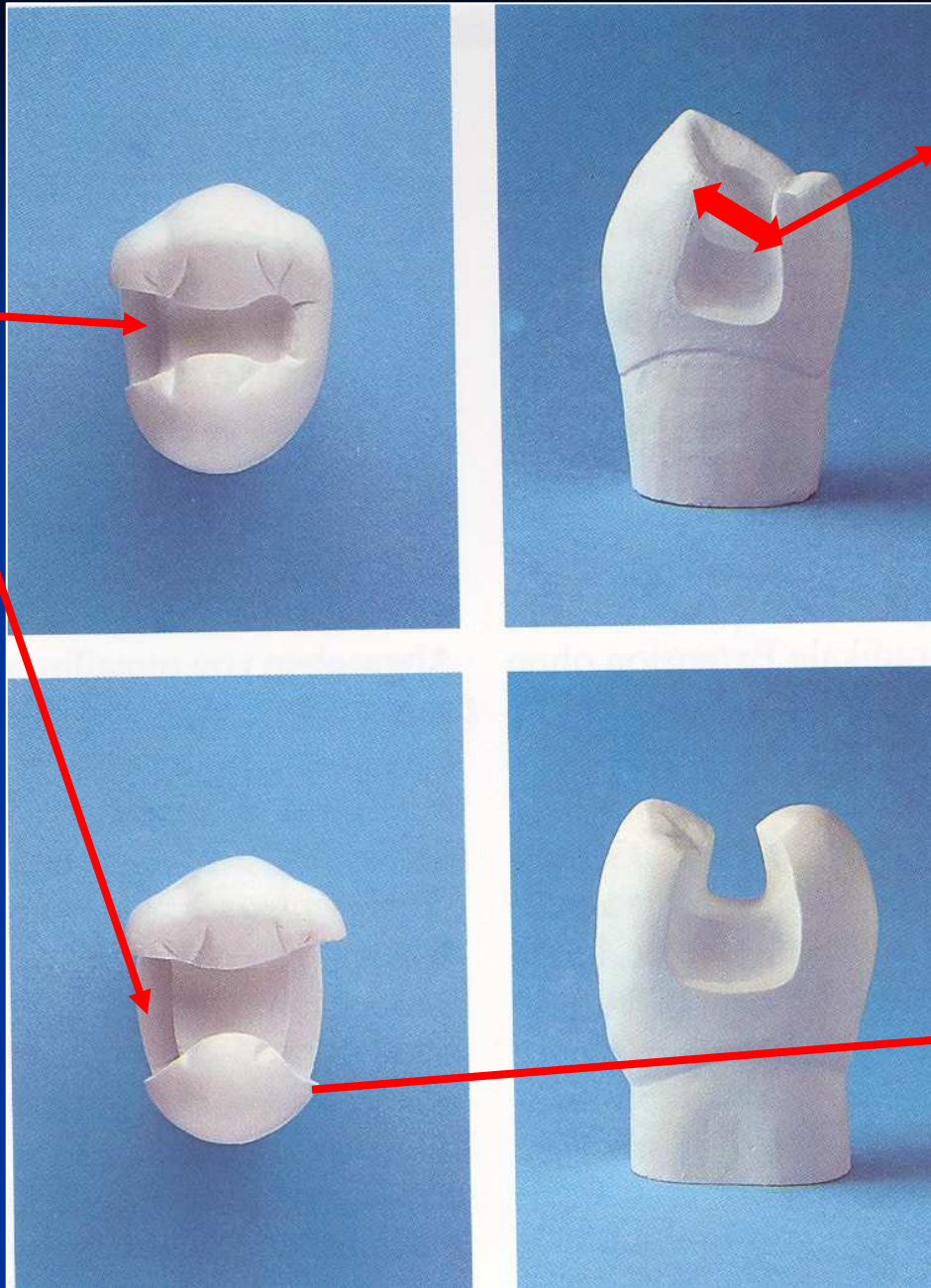


Verical and horizontal
grooves

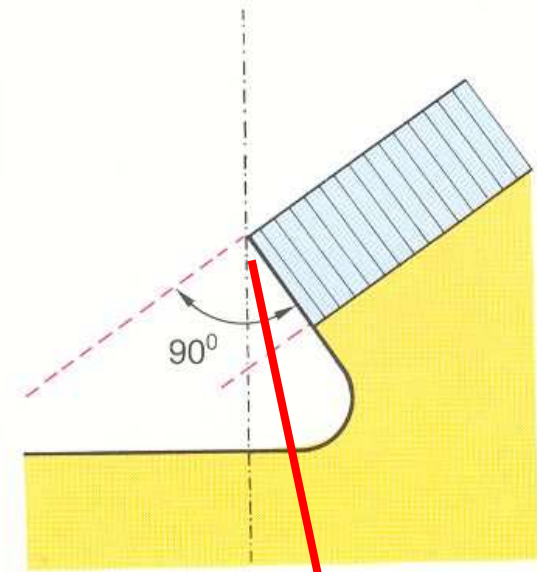
Resistance

- No undermined enamel
- No sharp wedges
- Isthmus is $1/3 - 1/4$ intercuspal distance
- Angle between axial and gingival wall: 90° , or 85°
- Width of gingival wall is 1 mm at least
- Thickness of the filling 2 – 4 mm (4mm cusp replacing)

G. wall



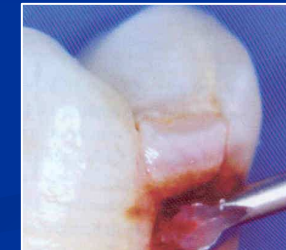
Isthmus



Cavosurface angle

Excavation of carious dentin


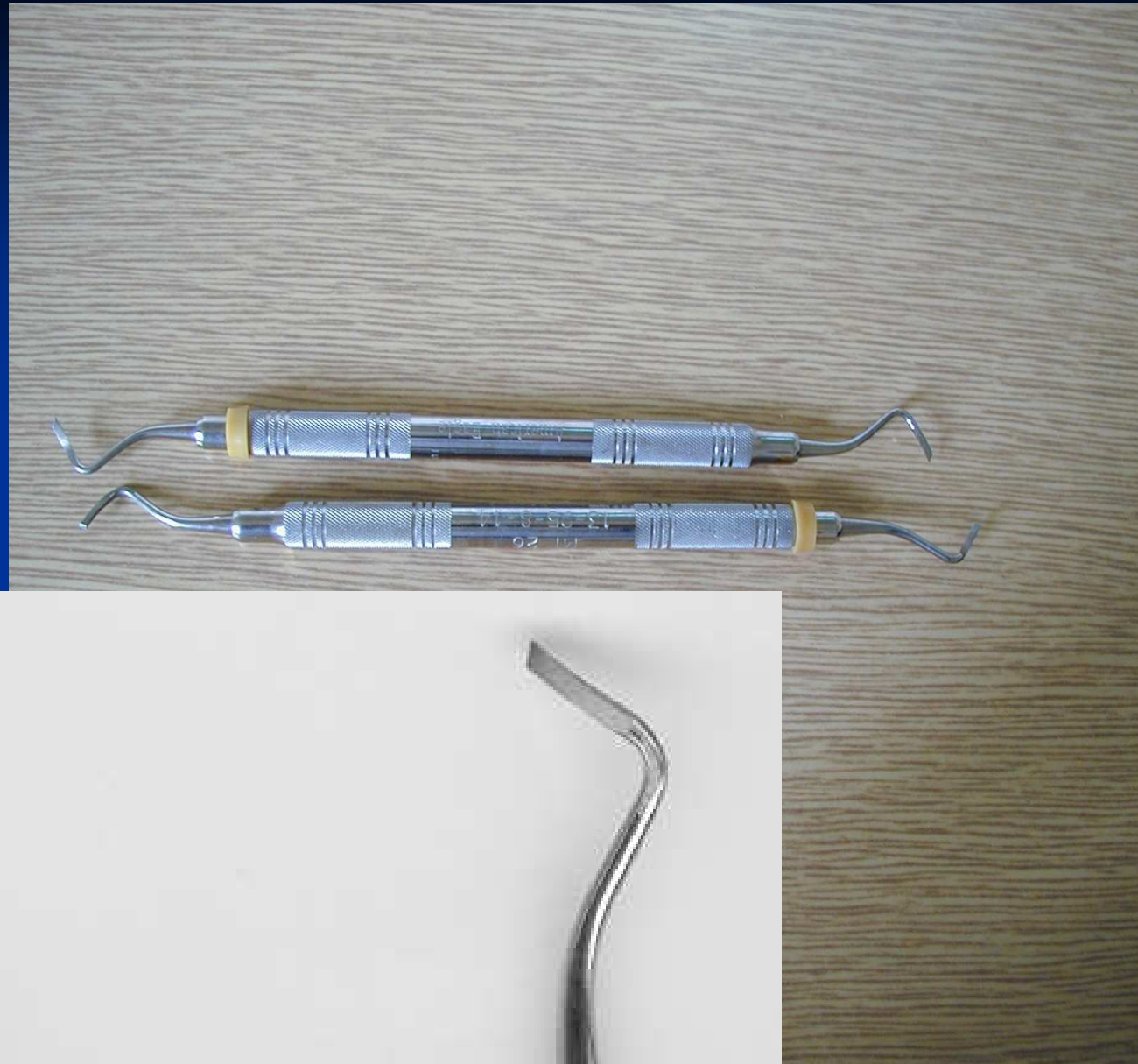
Round bur (ball) or excavator

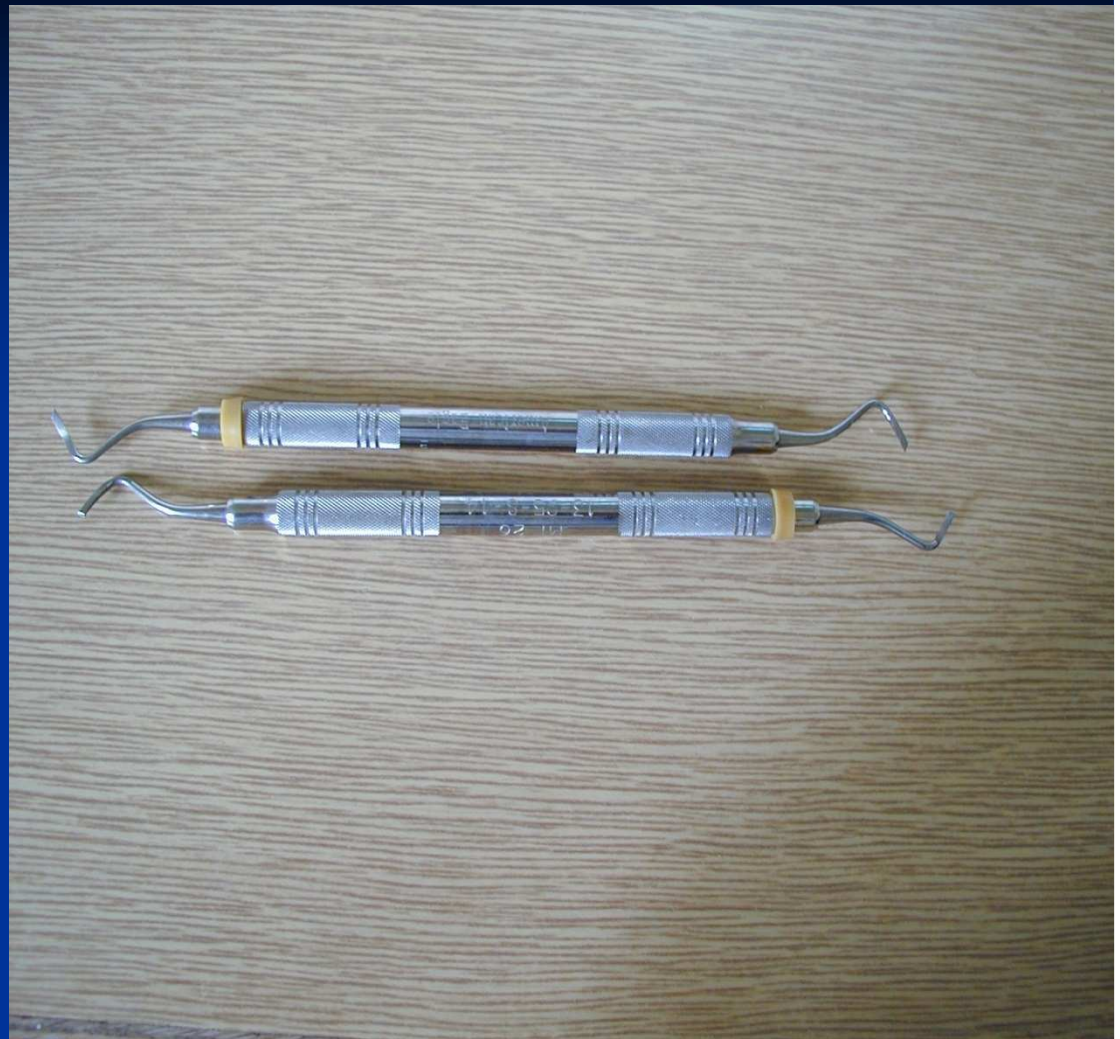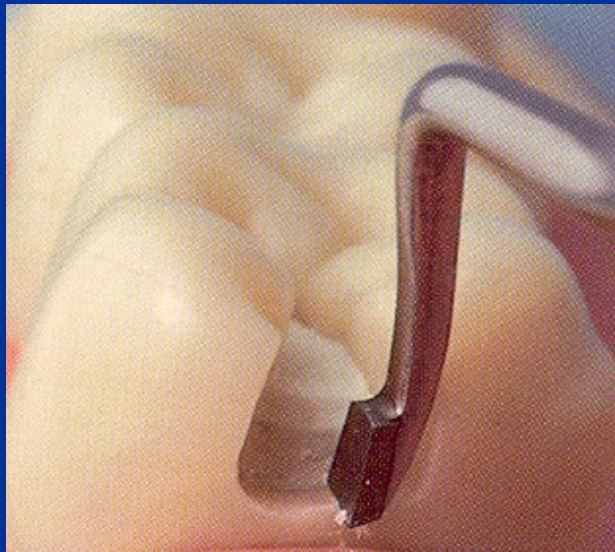
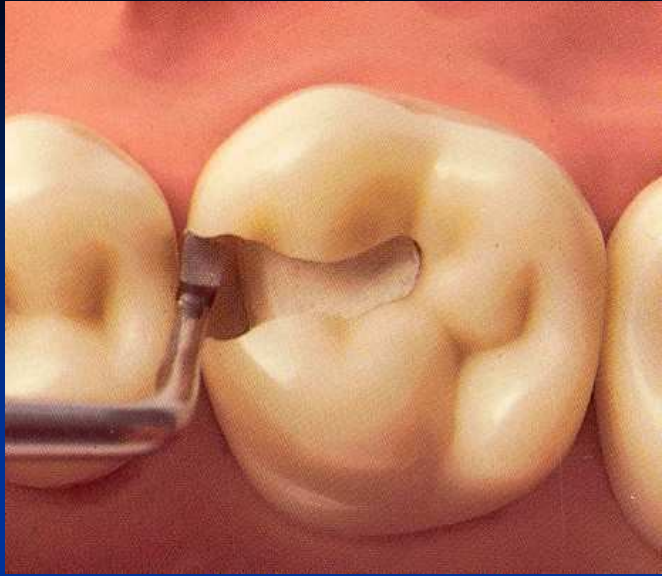


*(Caries Detector, Kuraray,
Japonsko; Caries Marker,
VOCO, Německo)*

Finishing of cavity walls

- Red coded diamond bur
- Chisel on the gingival wall (if in enamel)



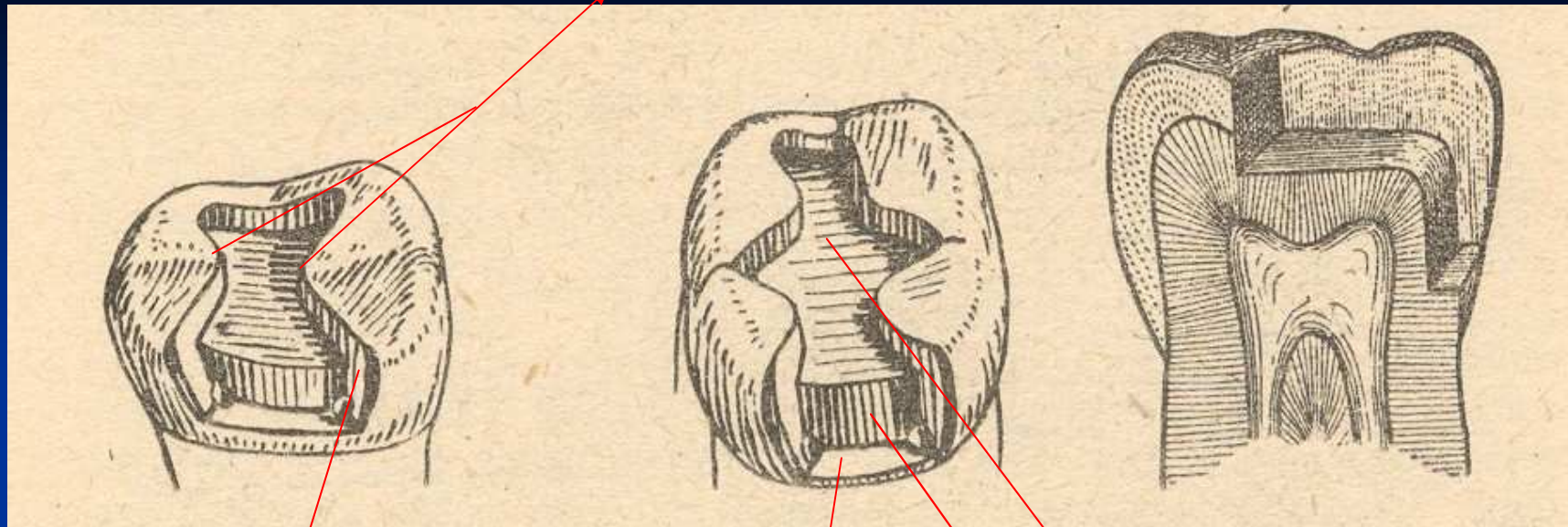




Cavity control

➤ Goog light, mirror

Isthmus



Axial wall

Gingival wall

Pulpal wall

Matrix placement

- Matrix primarily is used when a proximal surface is to be restored

The objectives:

- Provide proper contact
- Provide proper contour
- Confine the restorative material
- Reduce the amount of excess material


Matrices – matrix band, matrix retainer

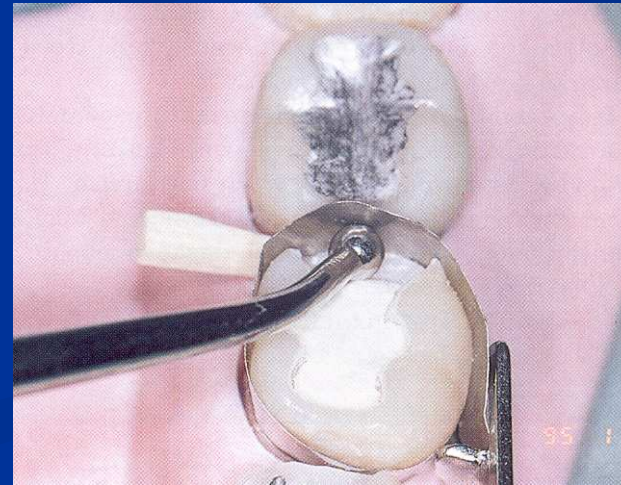
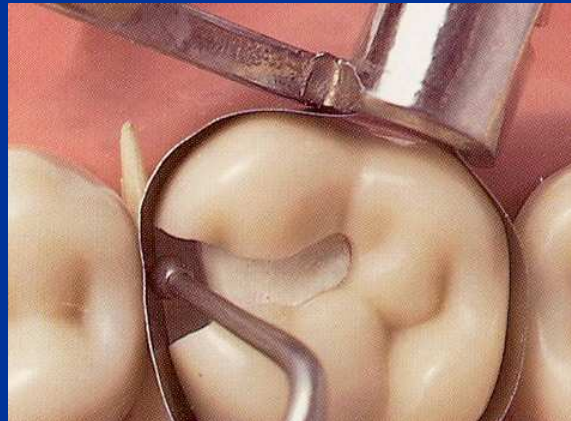

- Ivory I retainer Ivory 1
- Hawe Neos retainer Ivory 8
- Tofelmire matix and retainer

Wedges

➤ Wooden wedges

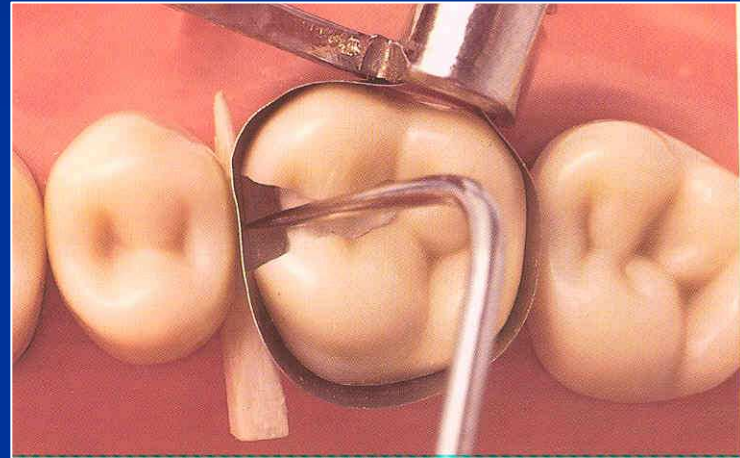
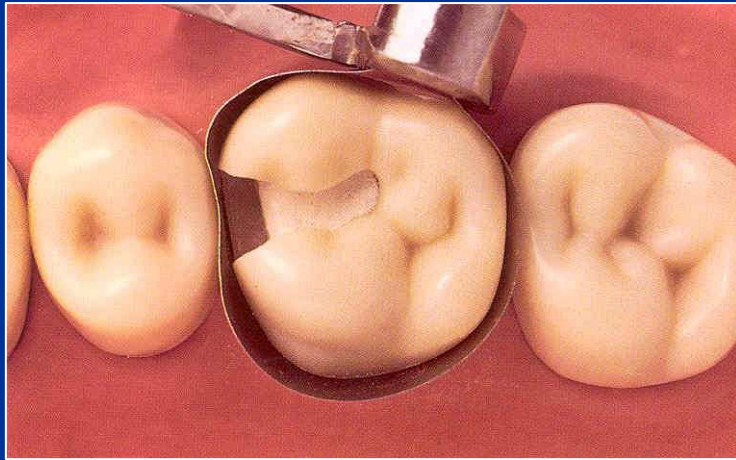

- tighten the matrix band
- do the compression of the gingiva
- separate the teeth






Wedging

- Slip the matrix band over the tooth (apical to the gingival margin – 0,5, - 1 mm)
- Tighten the matrix, check it with probe
- Place a wedge
- Turn the retainer $\frac{1}{4}$ counterclockwise
- Contour the band

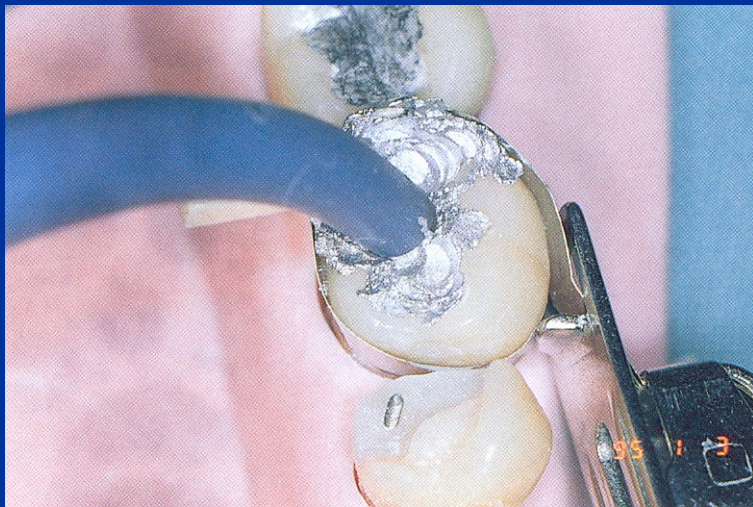
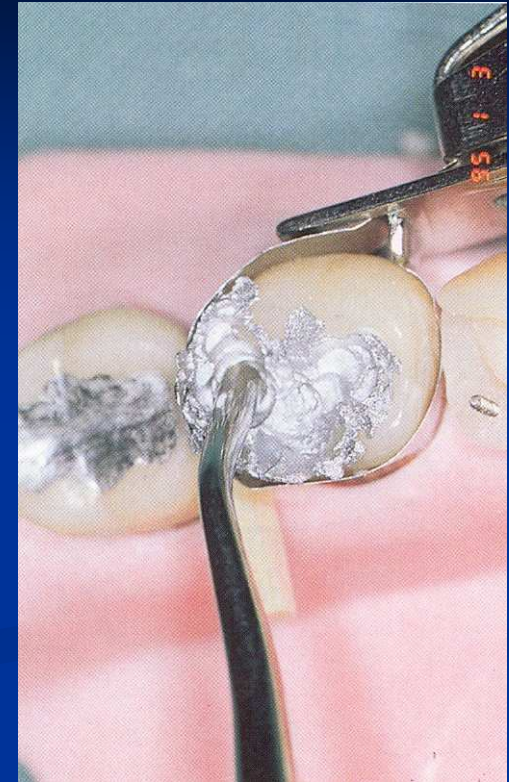


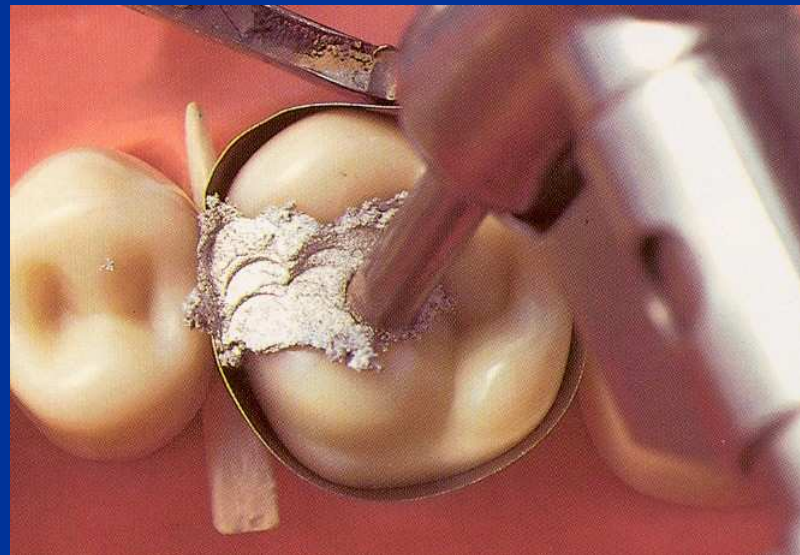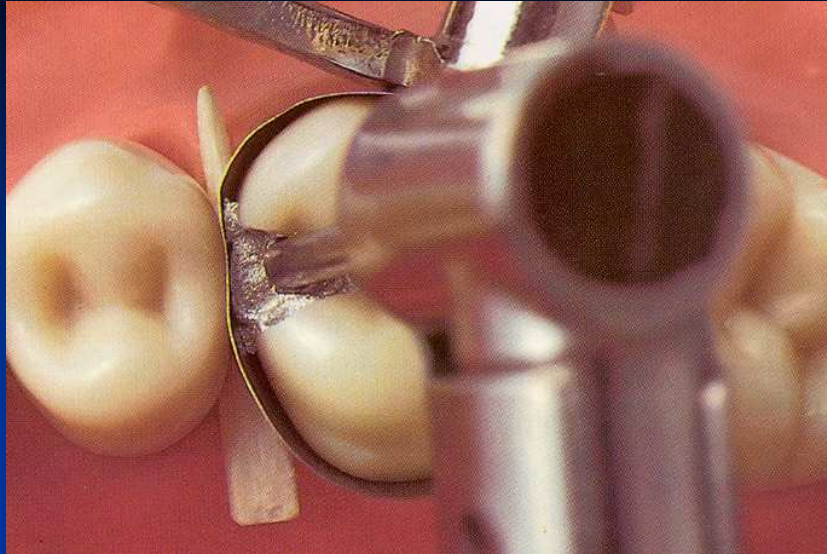


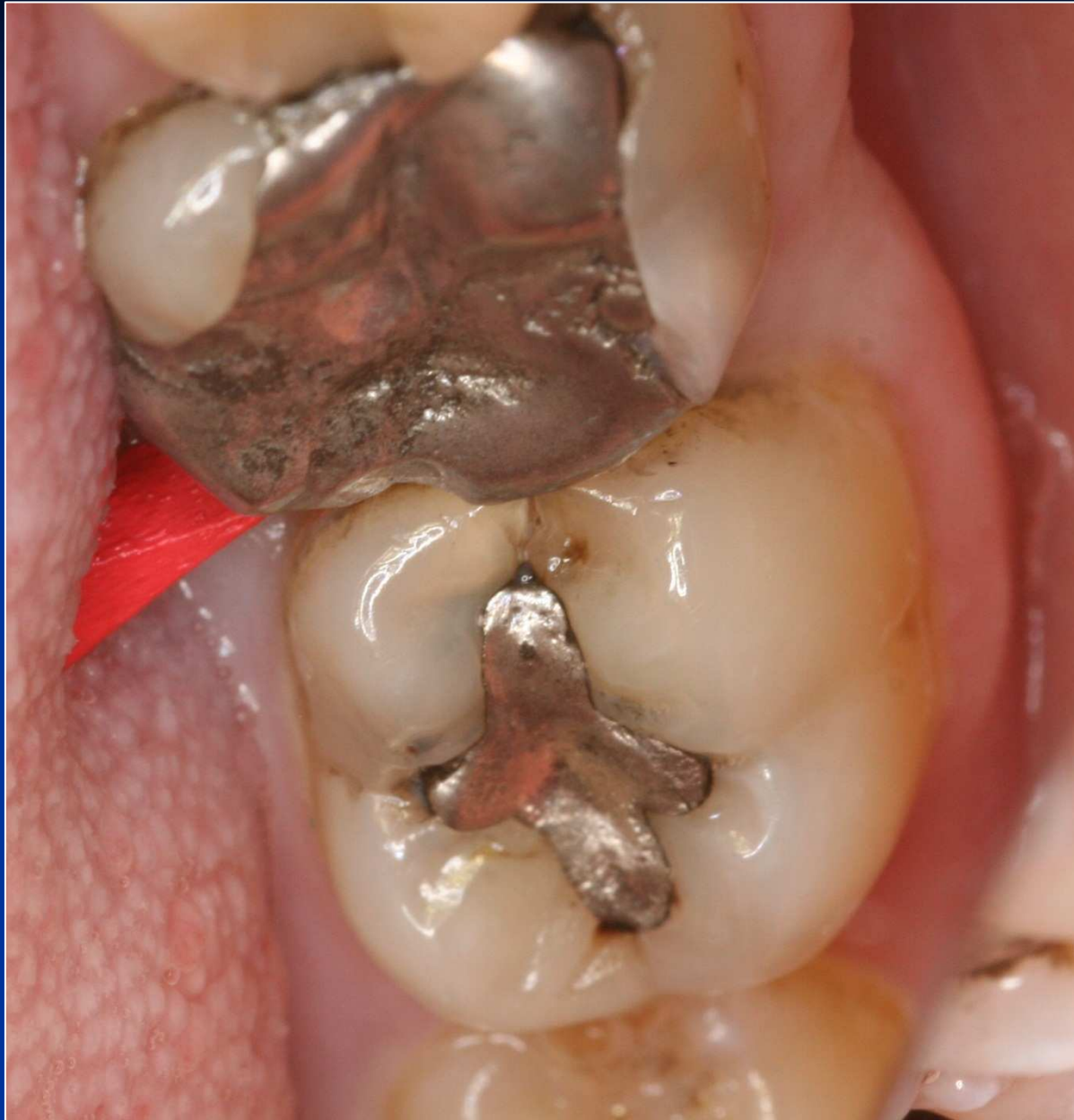Trituration!

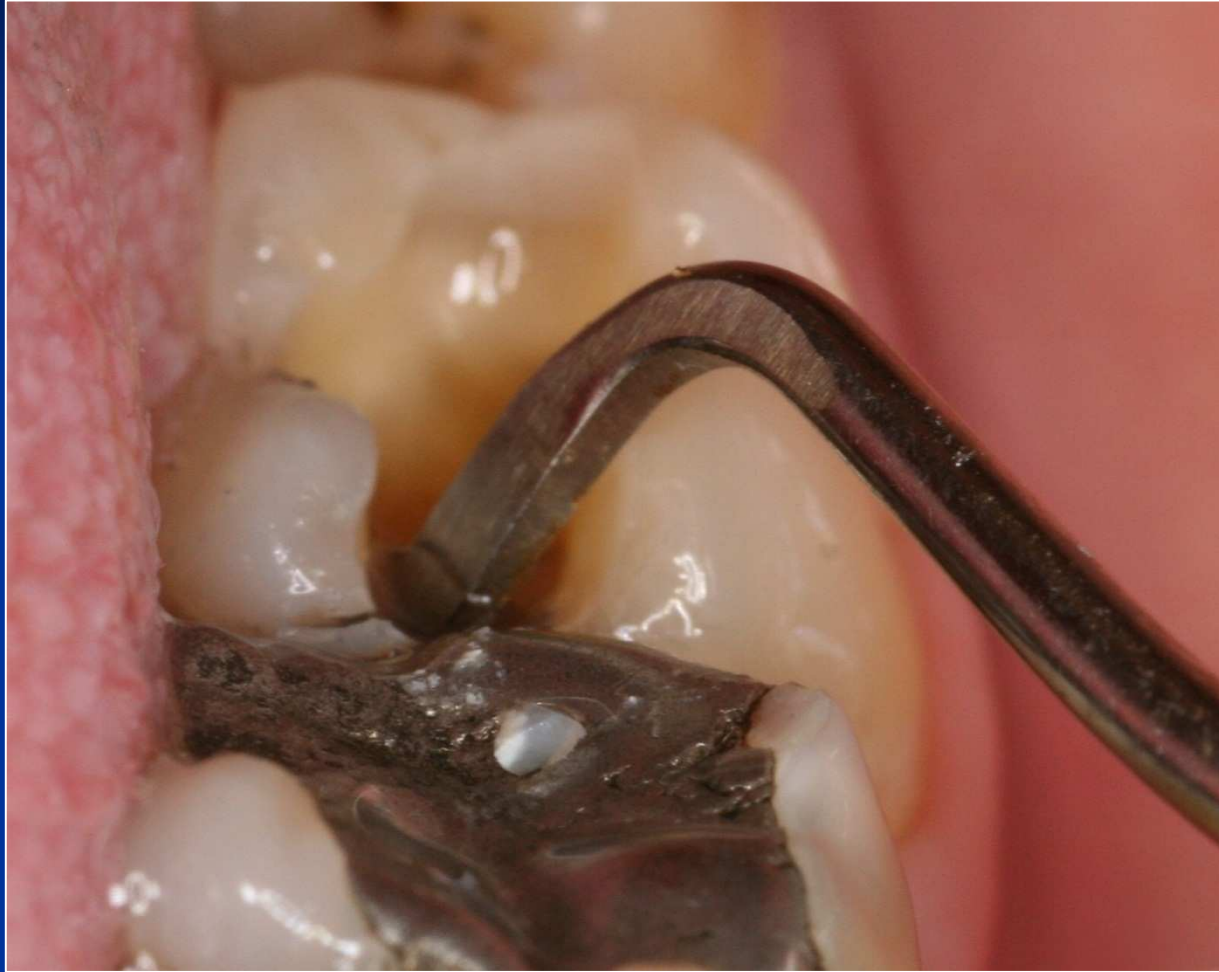Condensation of amalgam

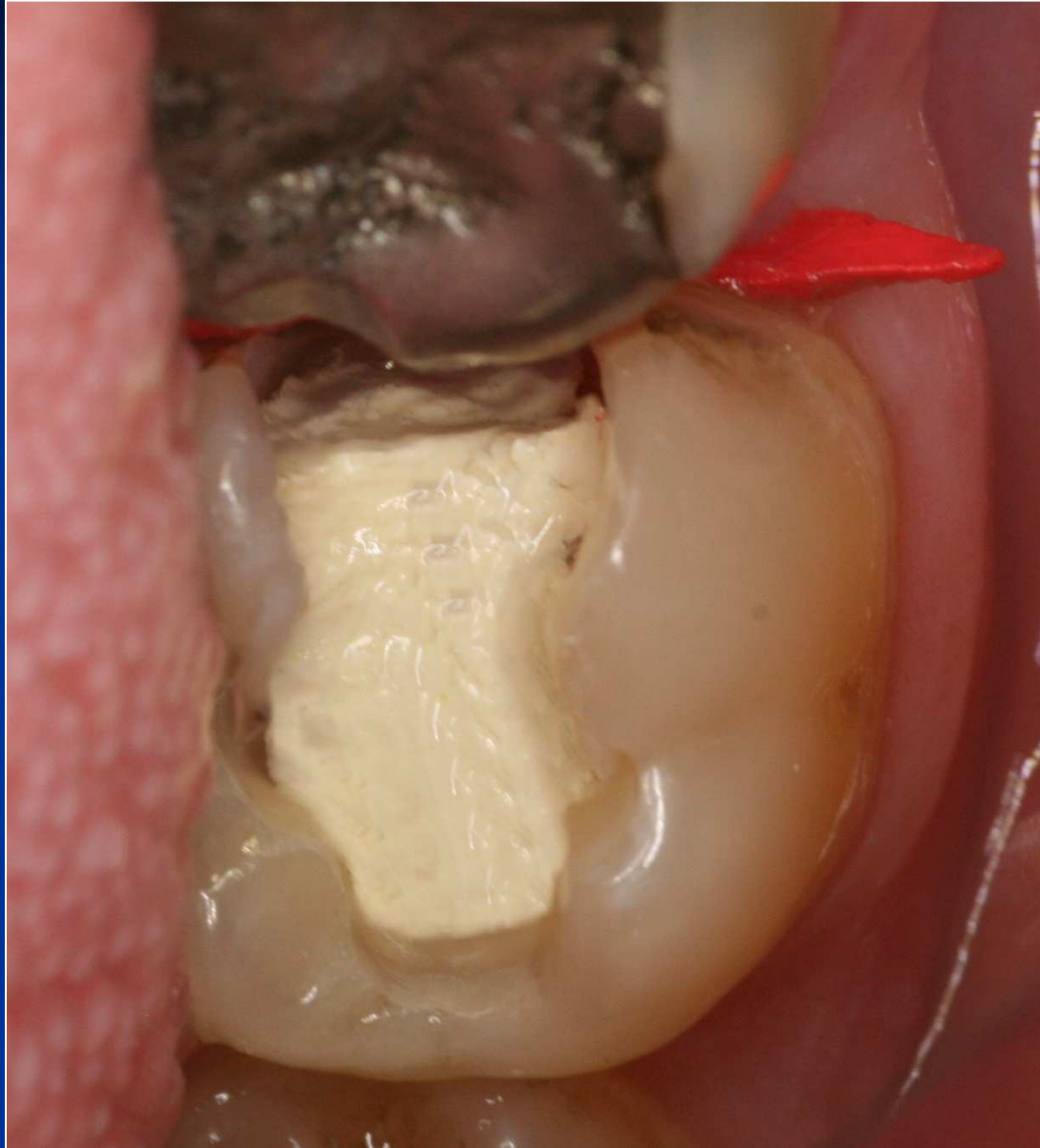- Condensor – straight front
- Power driven condensation

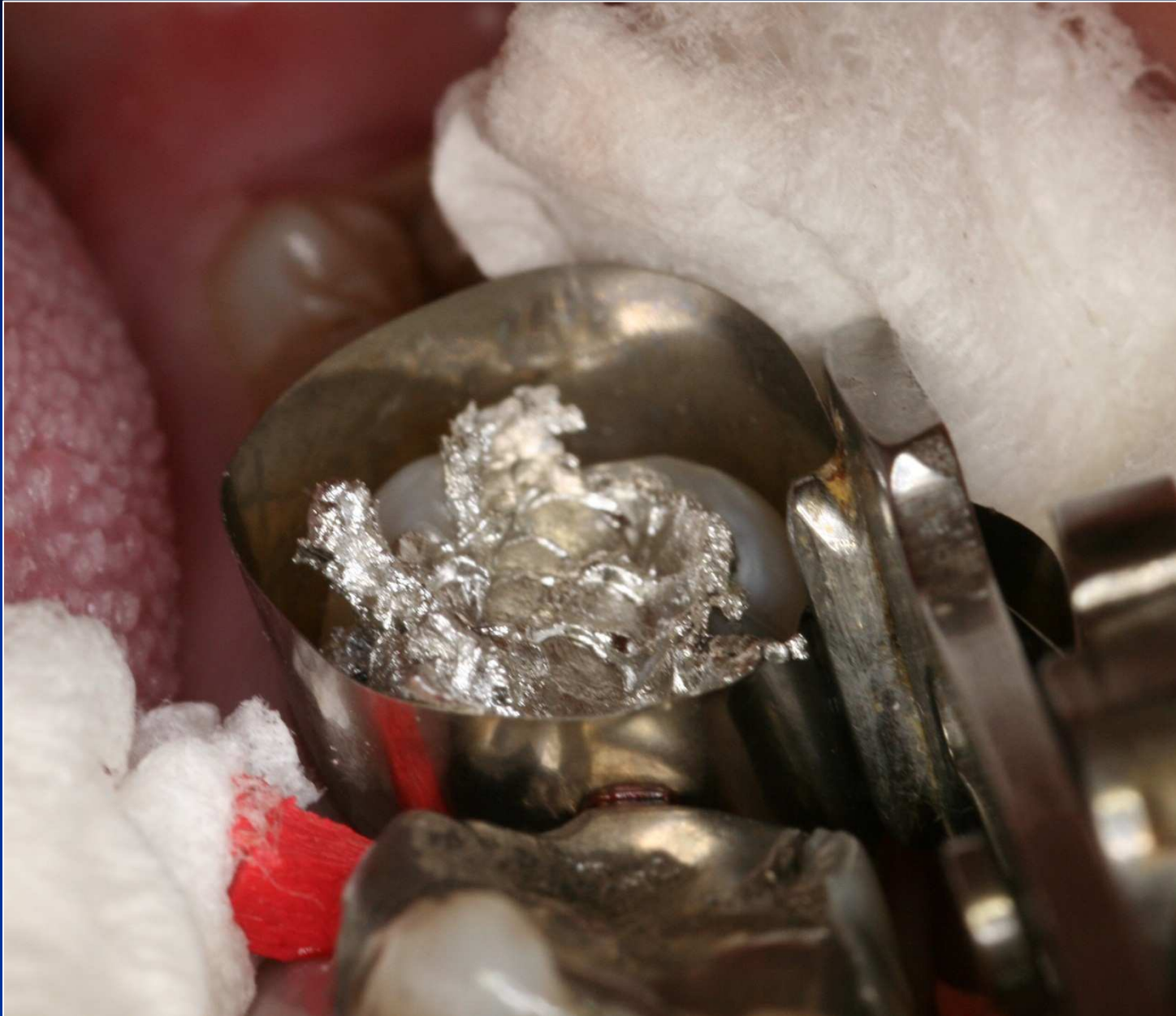


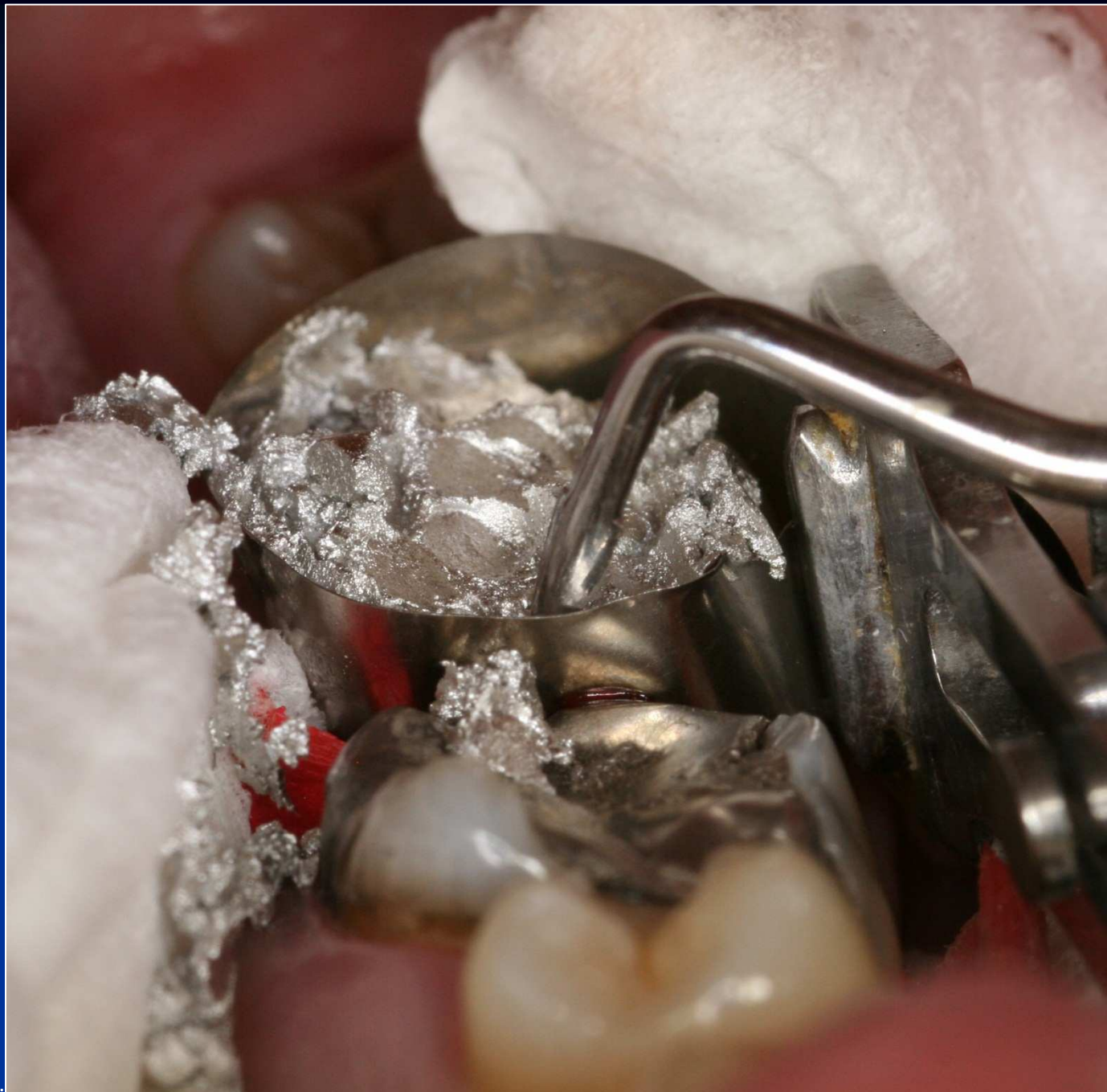


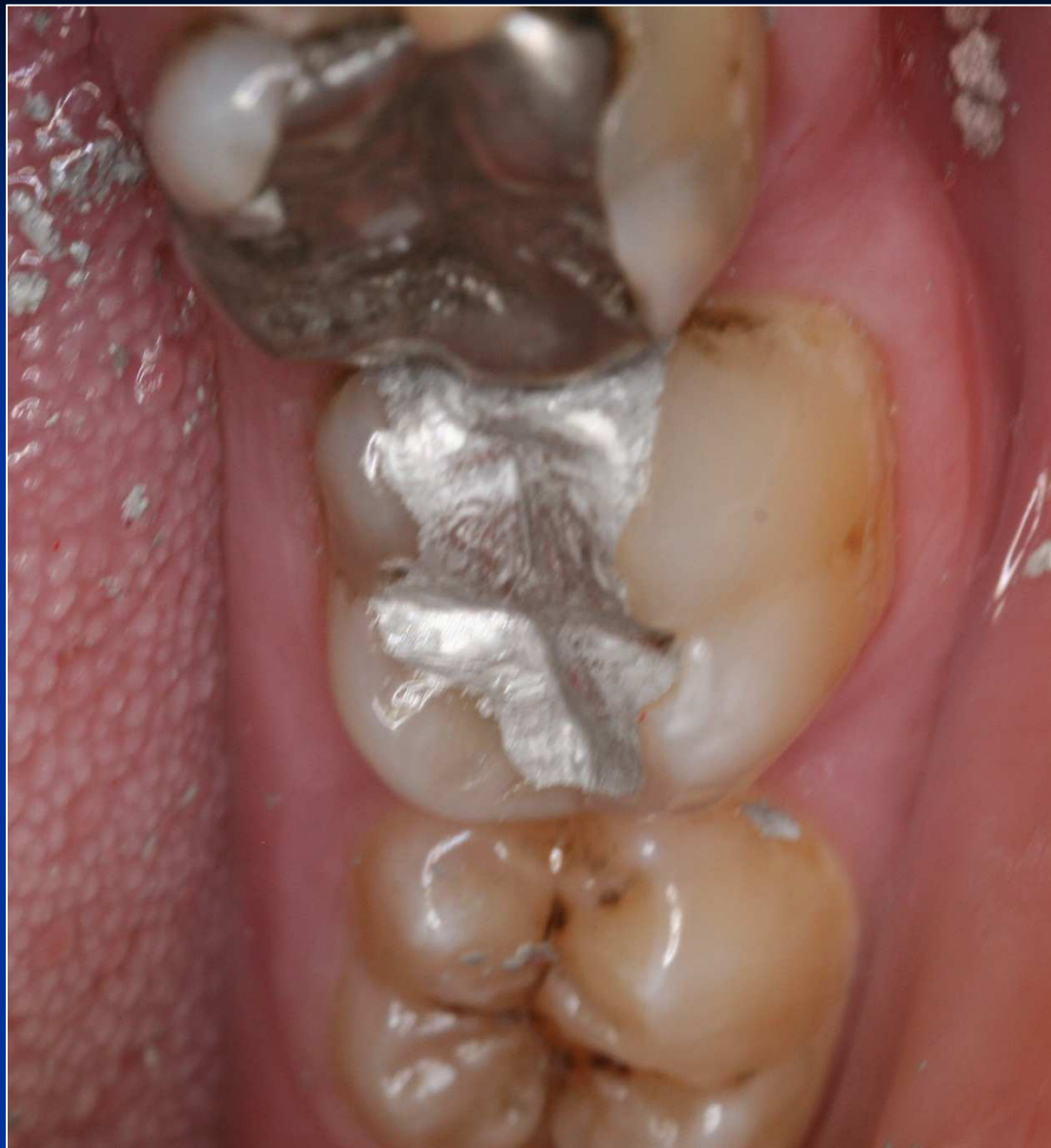





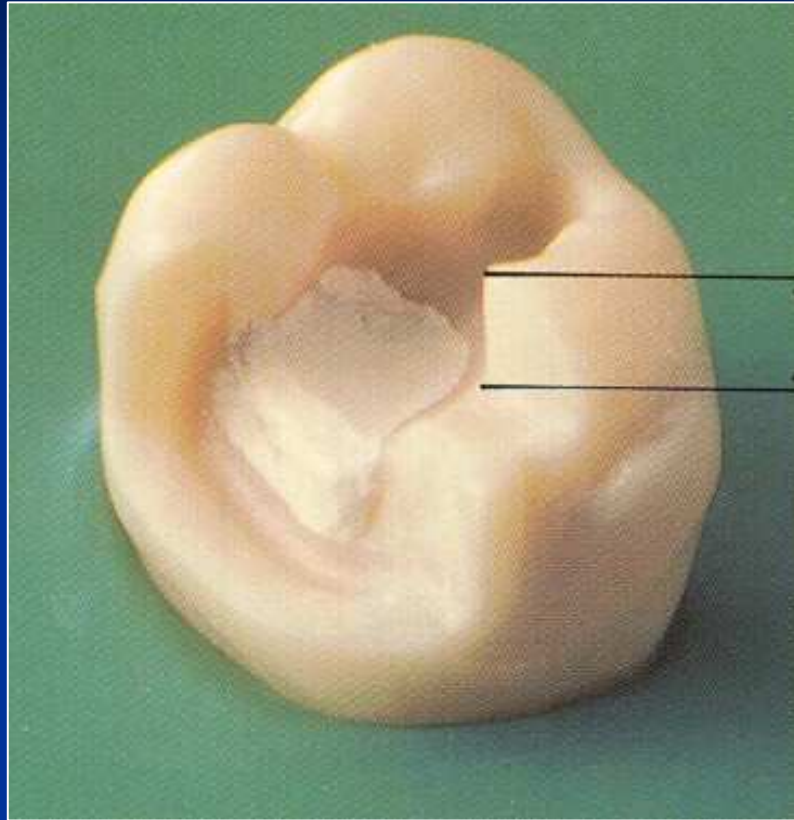


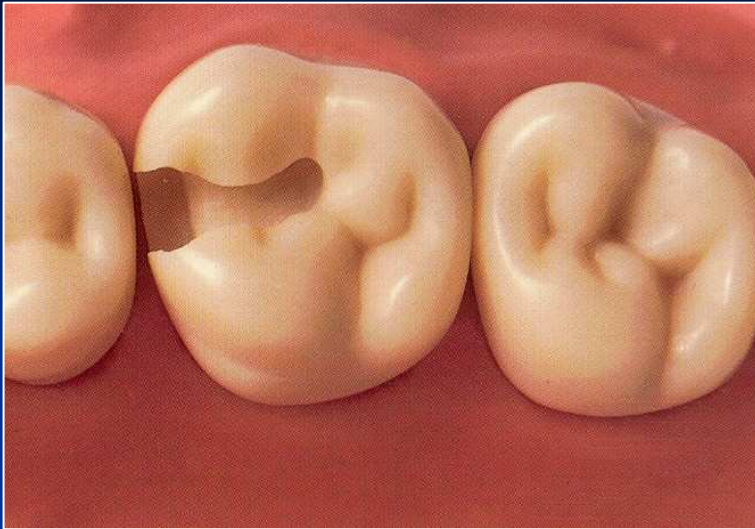


Base

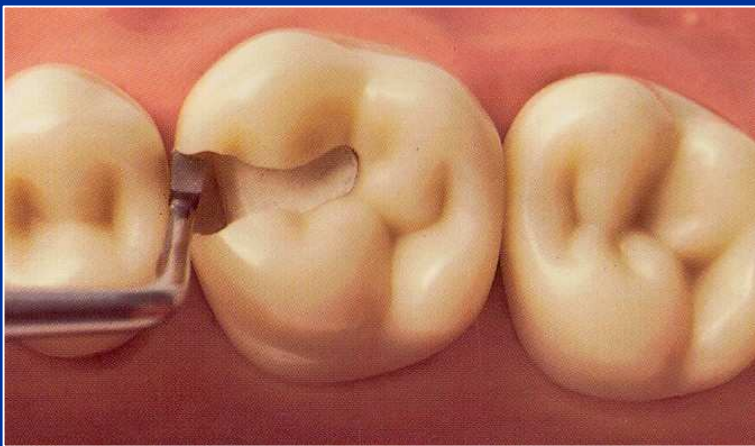
- Zinkoxidphosphate cement

On pulpal walls only!



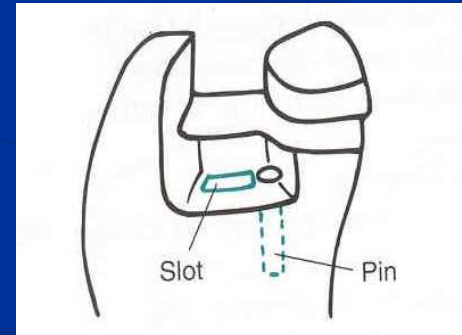
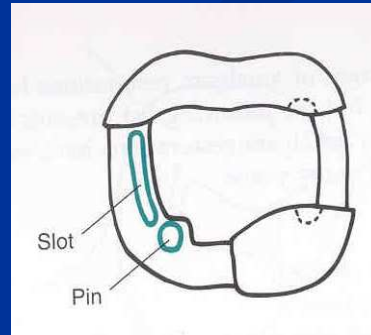
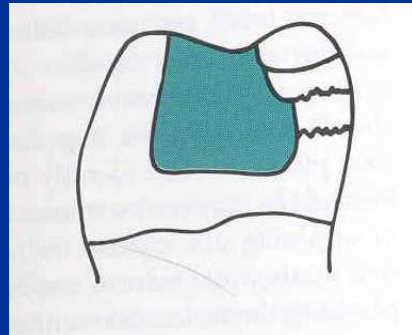
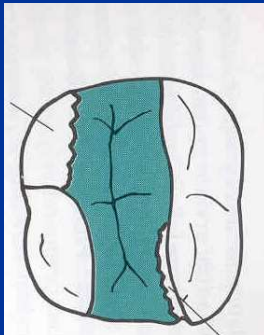


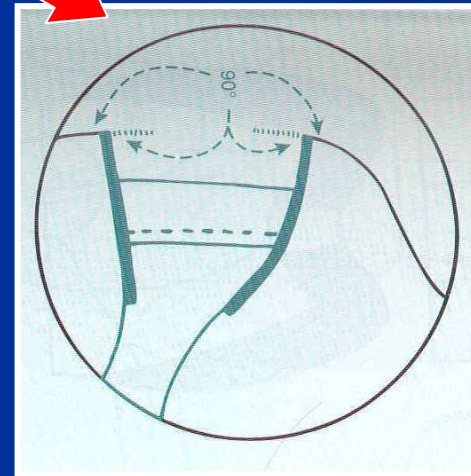
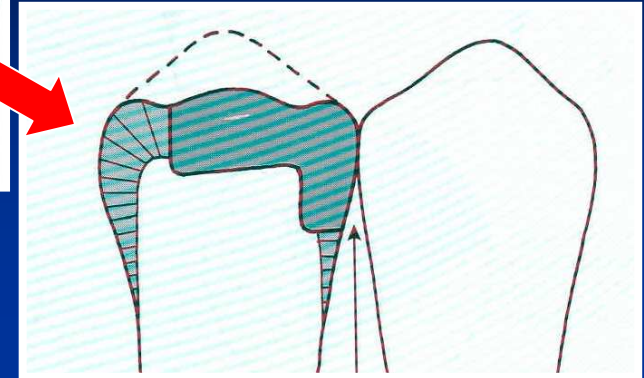
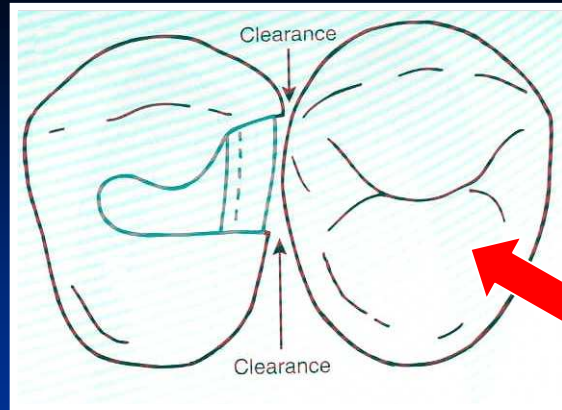
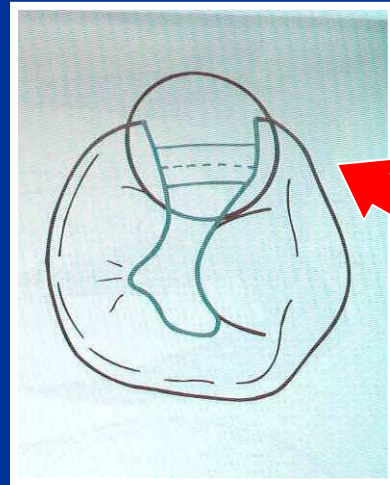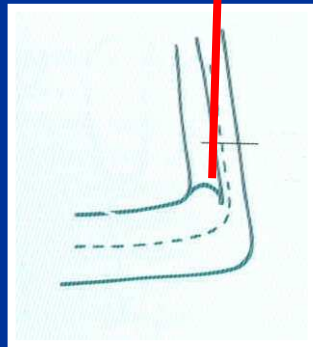
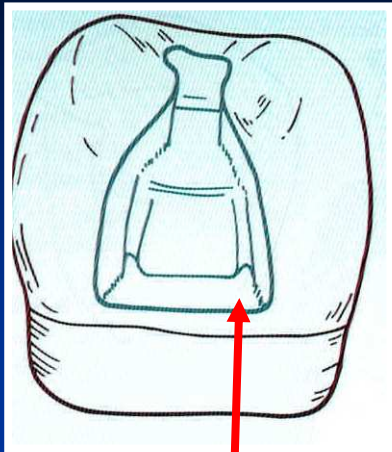
The base must be hardened


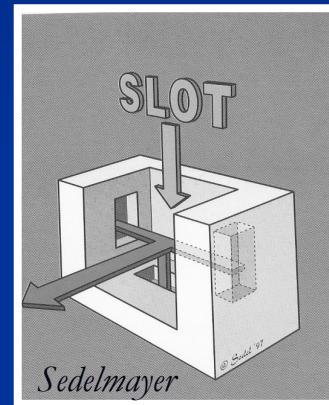
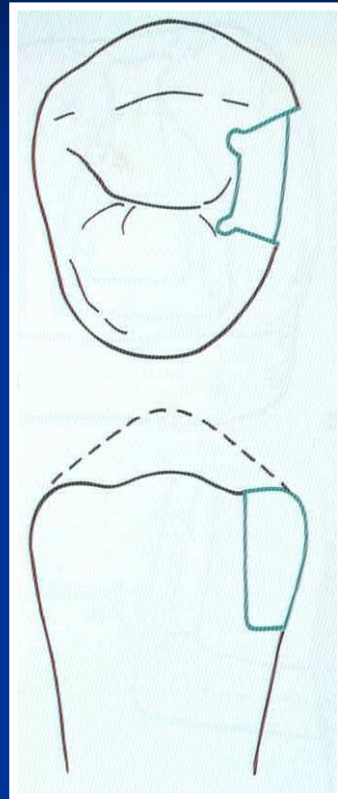
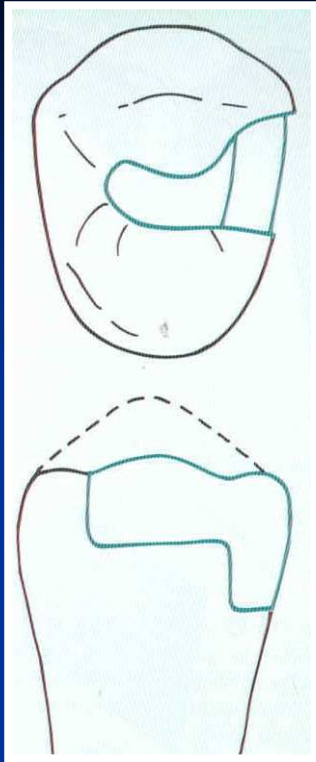


Amalgam

Retention








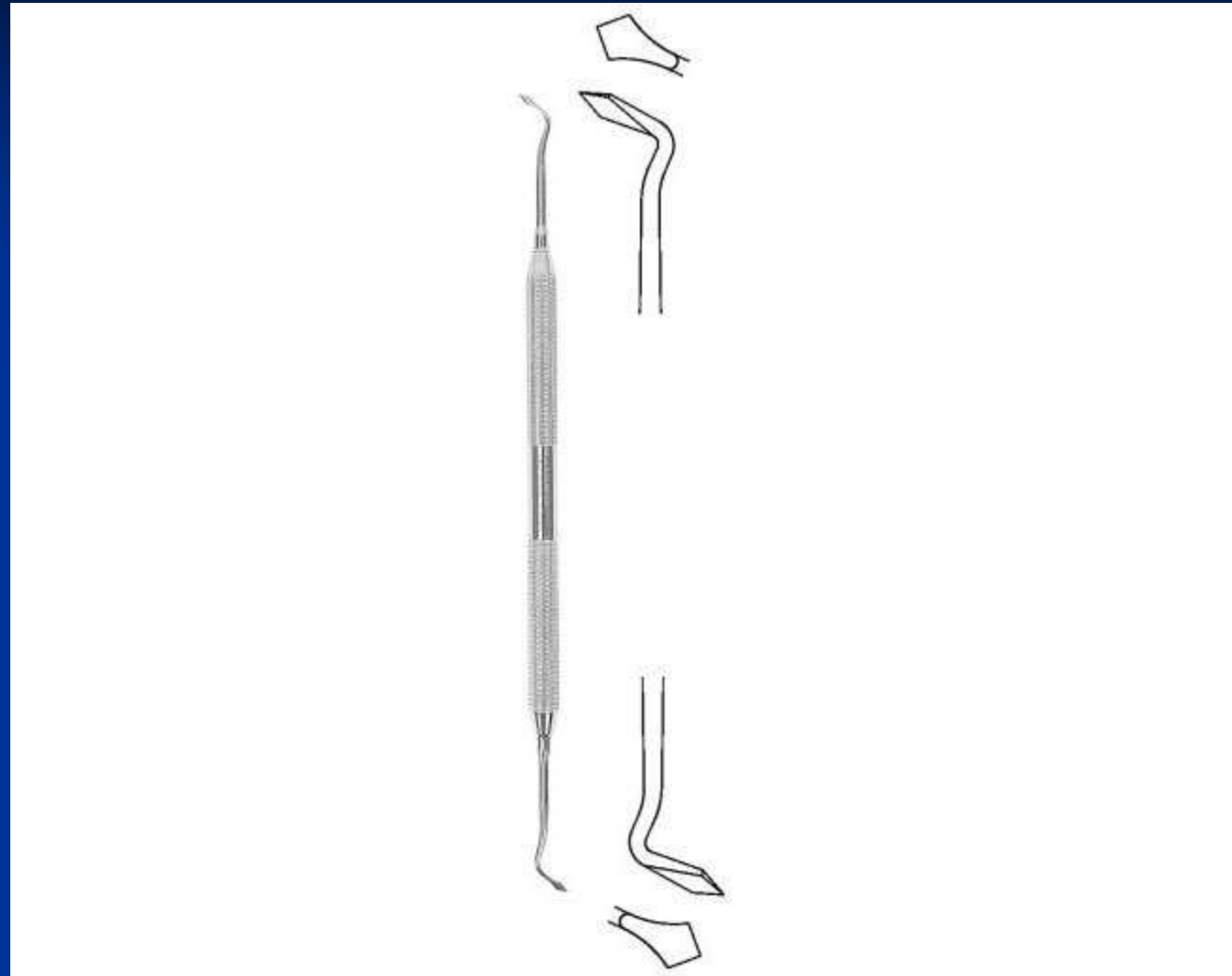
Instruments

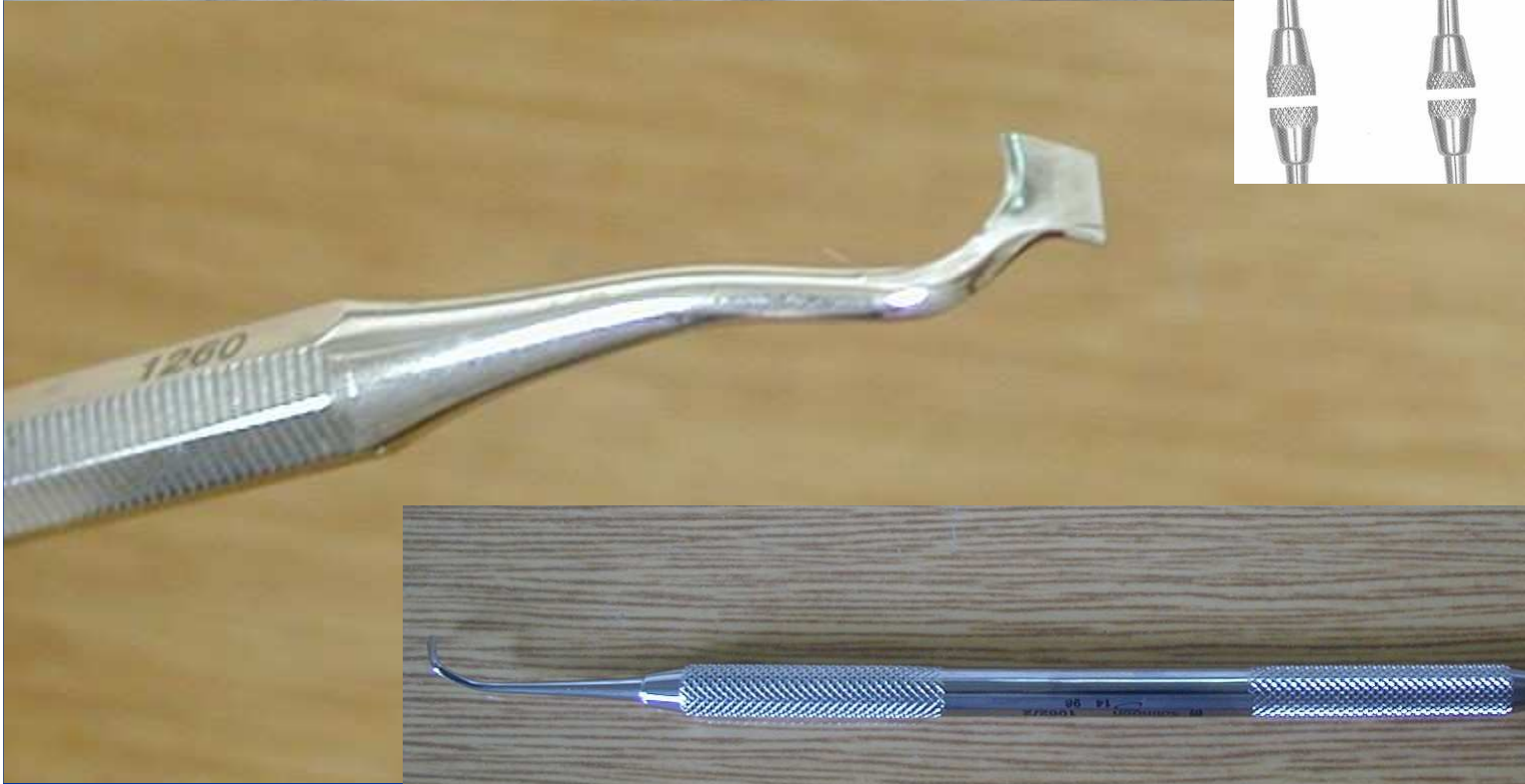
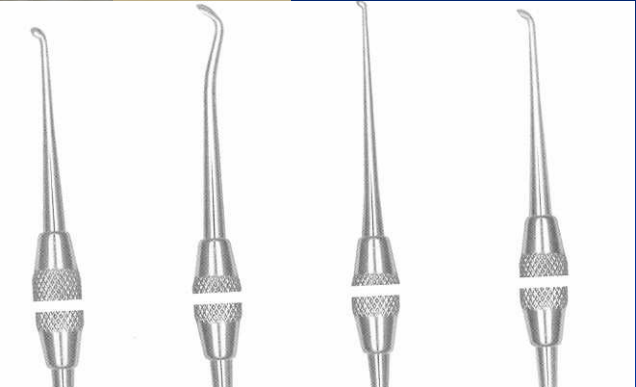- Preparation
- Filling
- Finishing and polishing

Cpátko tyčinkové

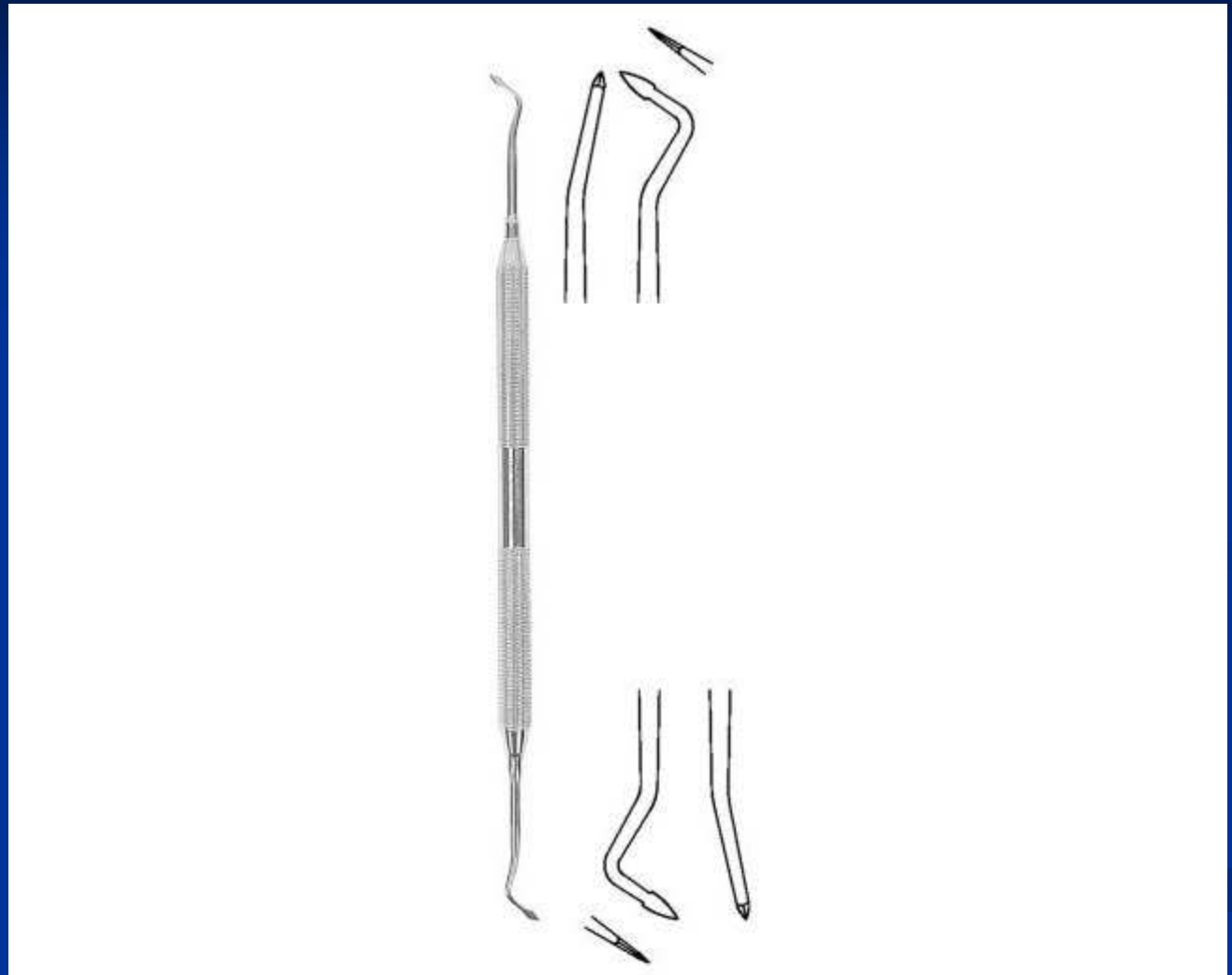


Ořezávač -Frahm






Ořezávač - Sapin



Ořezávač discoid-cleoid



Nosič amalgámu



