

POHYBY DOLNÍCH KONČETIN



POHYBY KYČELNÍHO KLOUBU

FLEXE - PŘEDNOŽENÍ

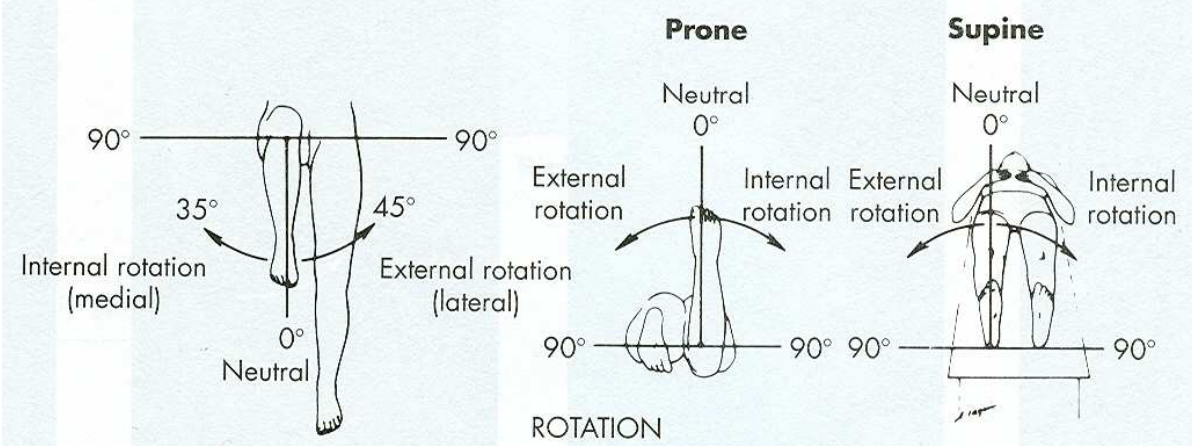
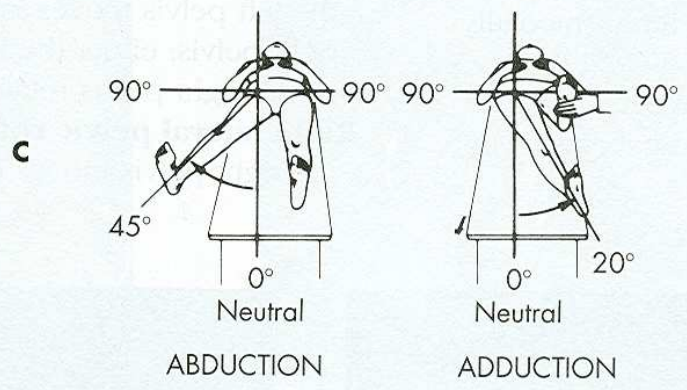
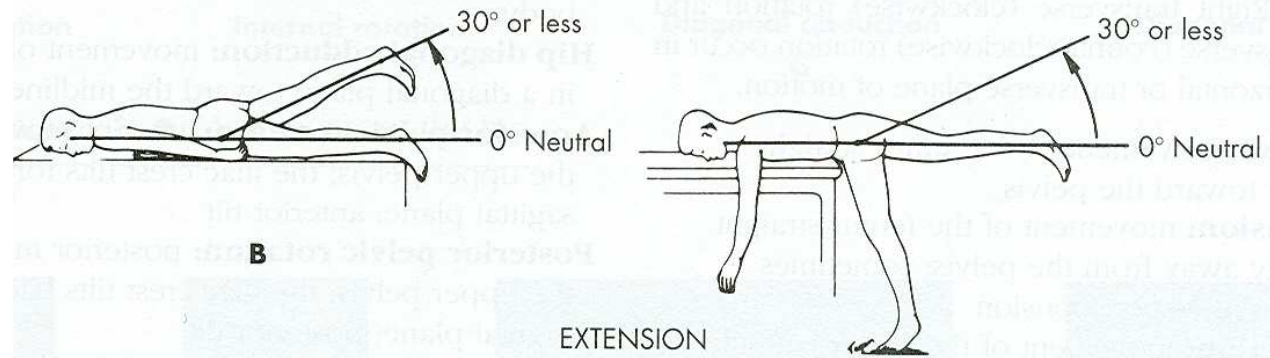
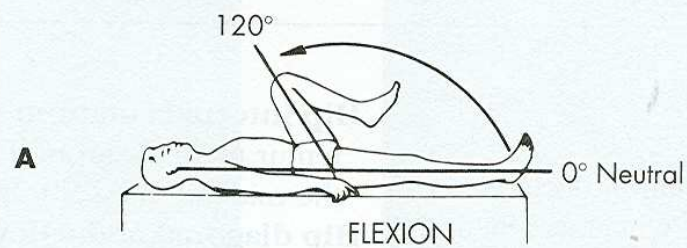
EXTENZE - ZANOŽENÍ

ABDUKCE - UNOŽENÍ

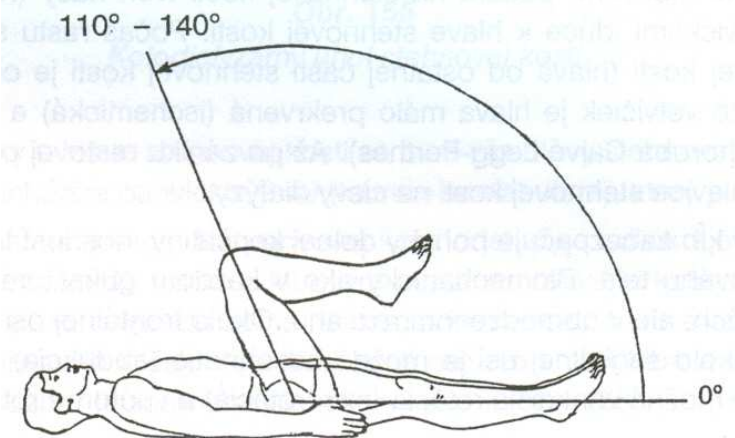
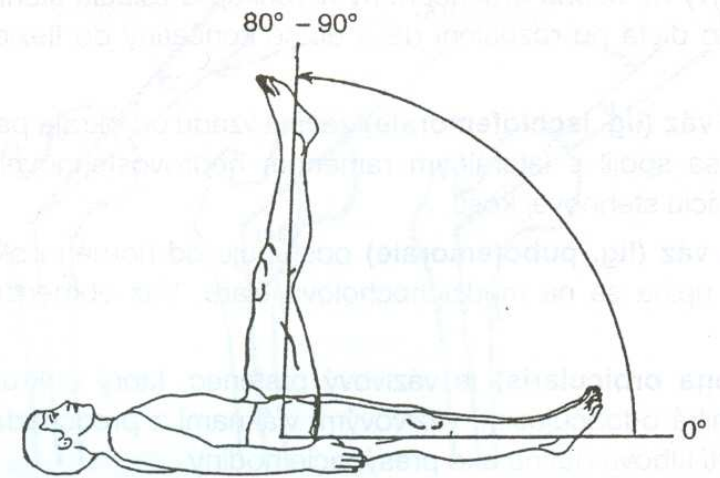
ADDUKCE - PŘINOŽENÍ

VNĚJŠÍ ROTACE

VNITŘNÍ ROTACE



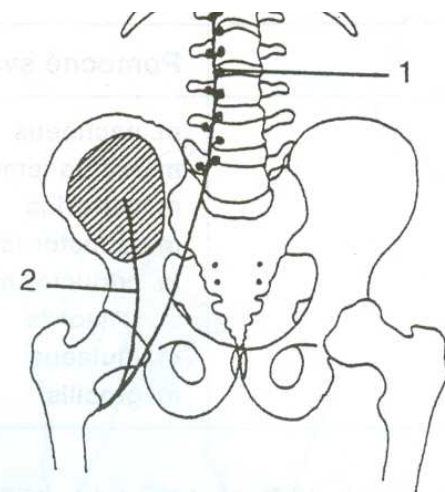
FLEXE - PŘEDNOŽENÍ



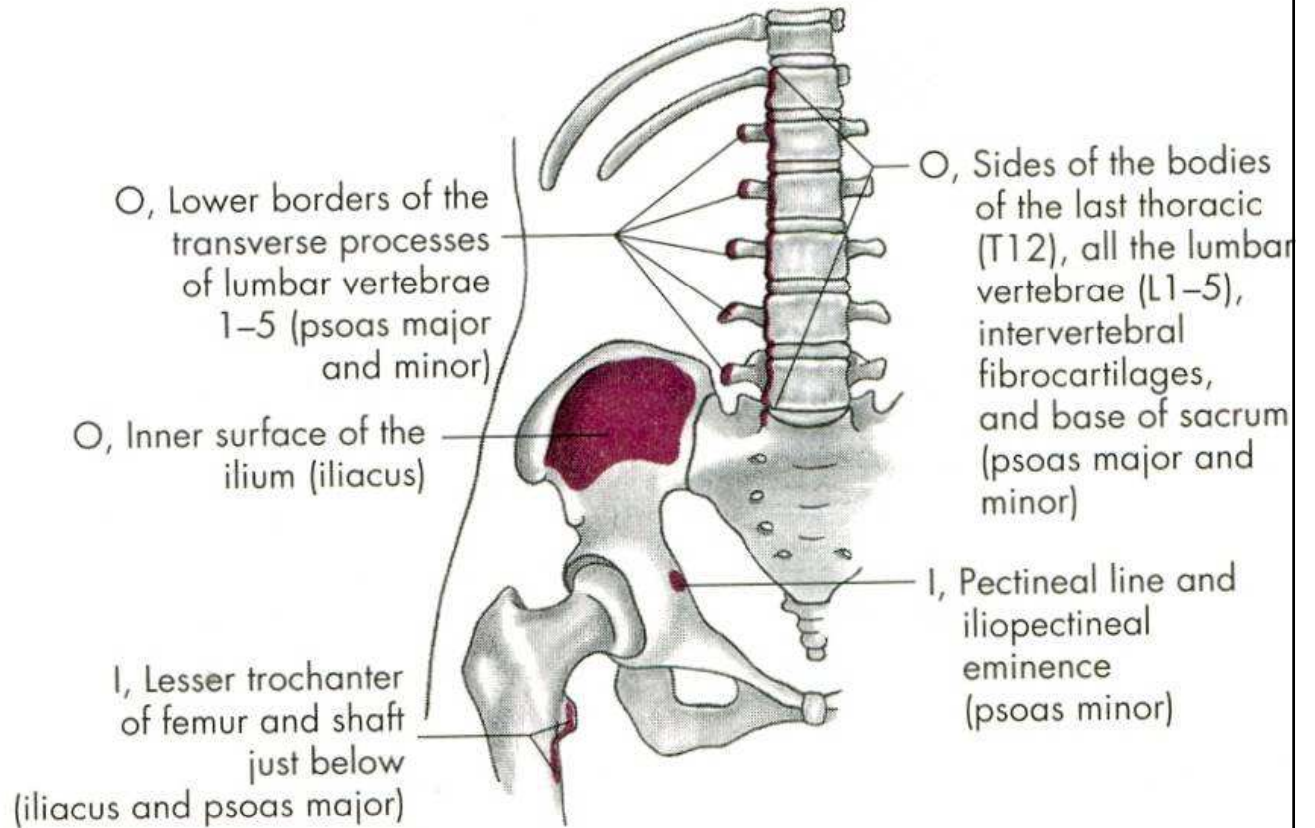
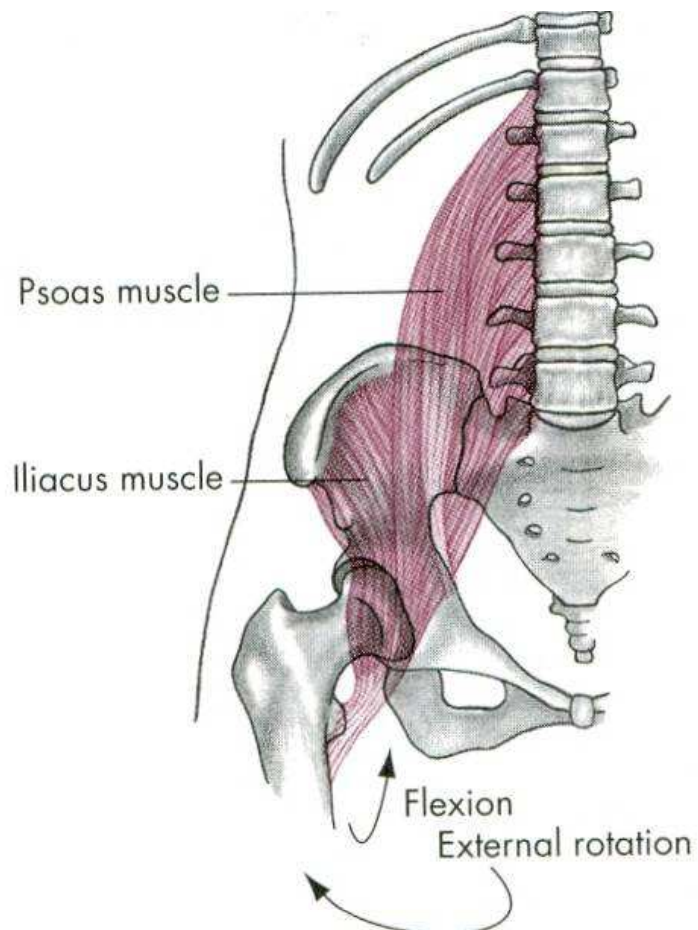
m. iliopsoas

m. psoas major

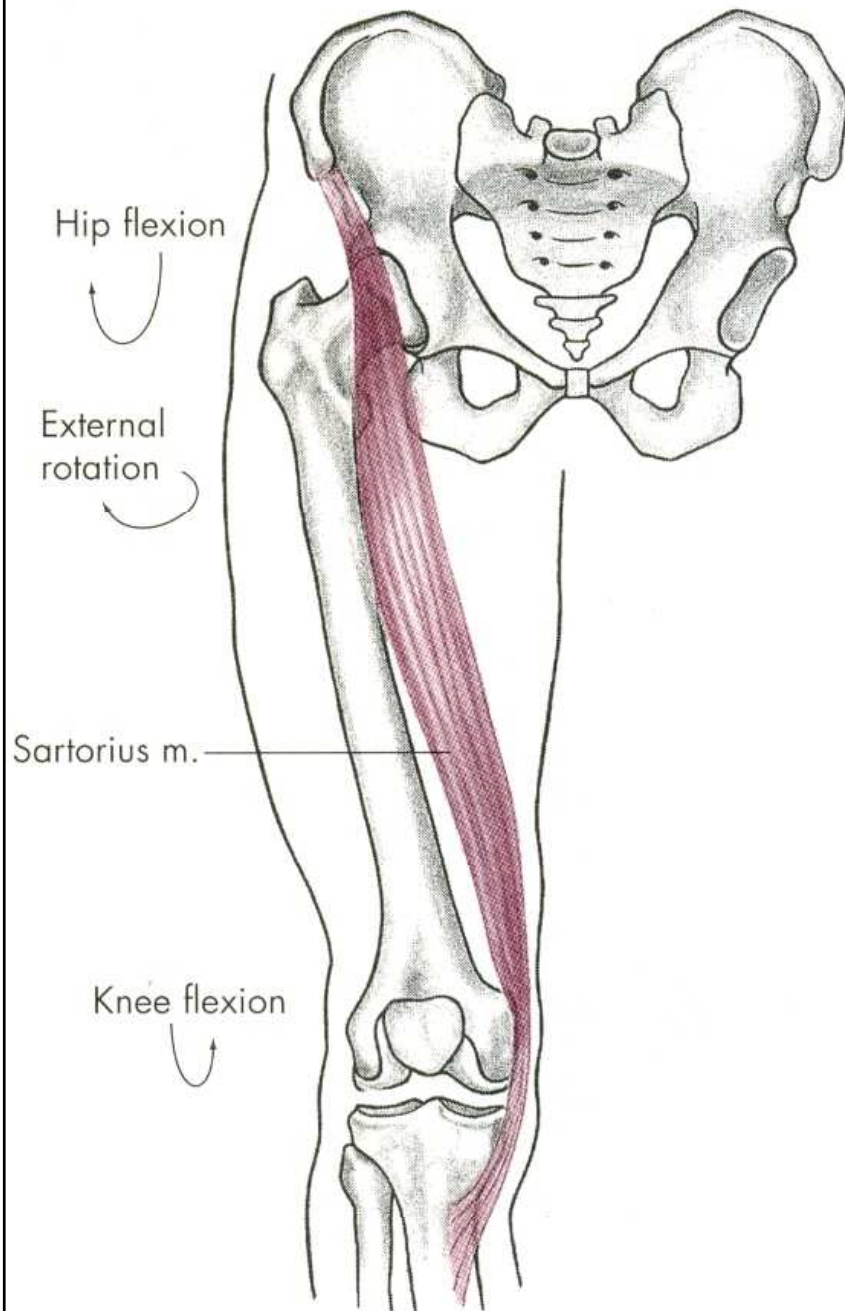
m. iliacus



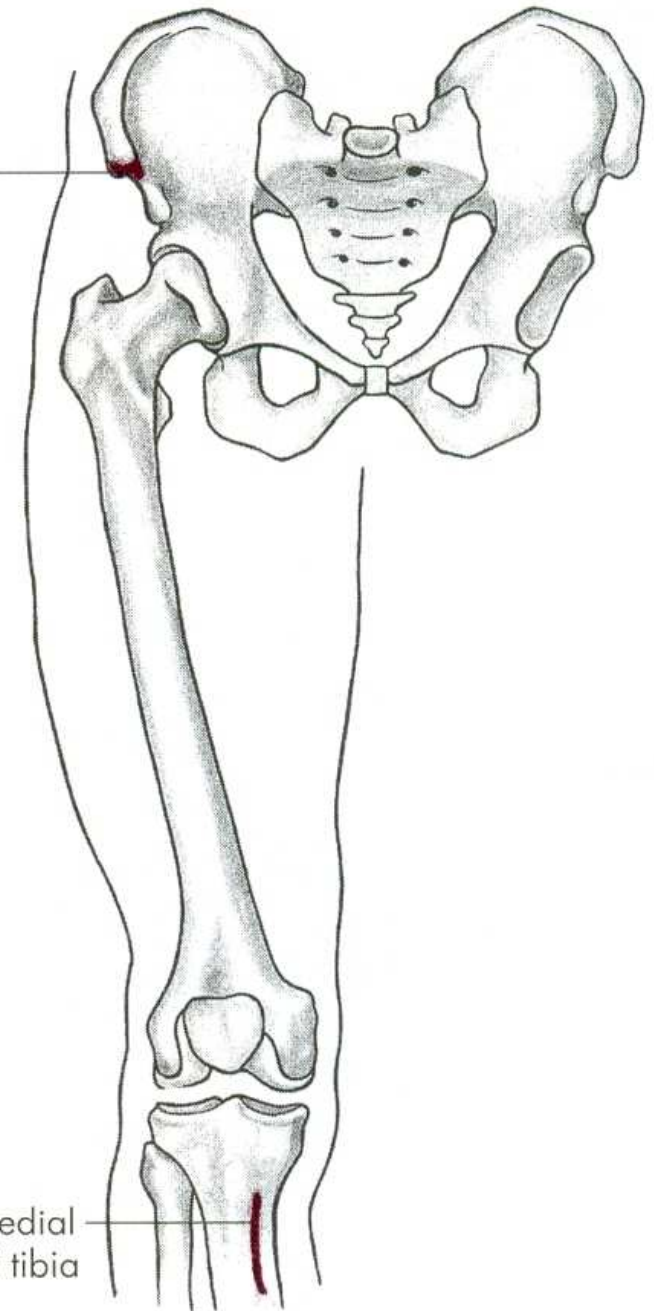
m. iliopsoas

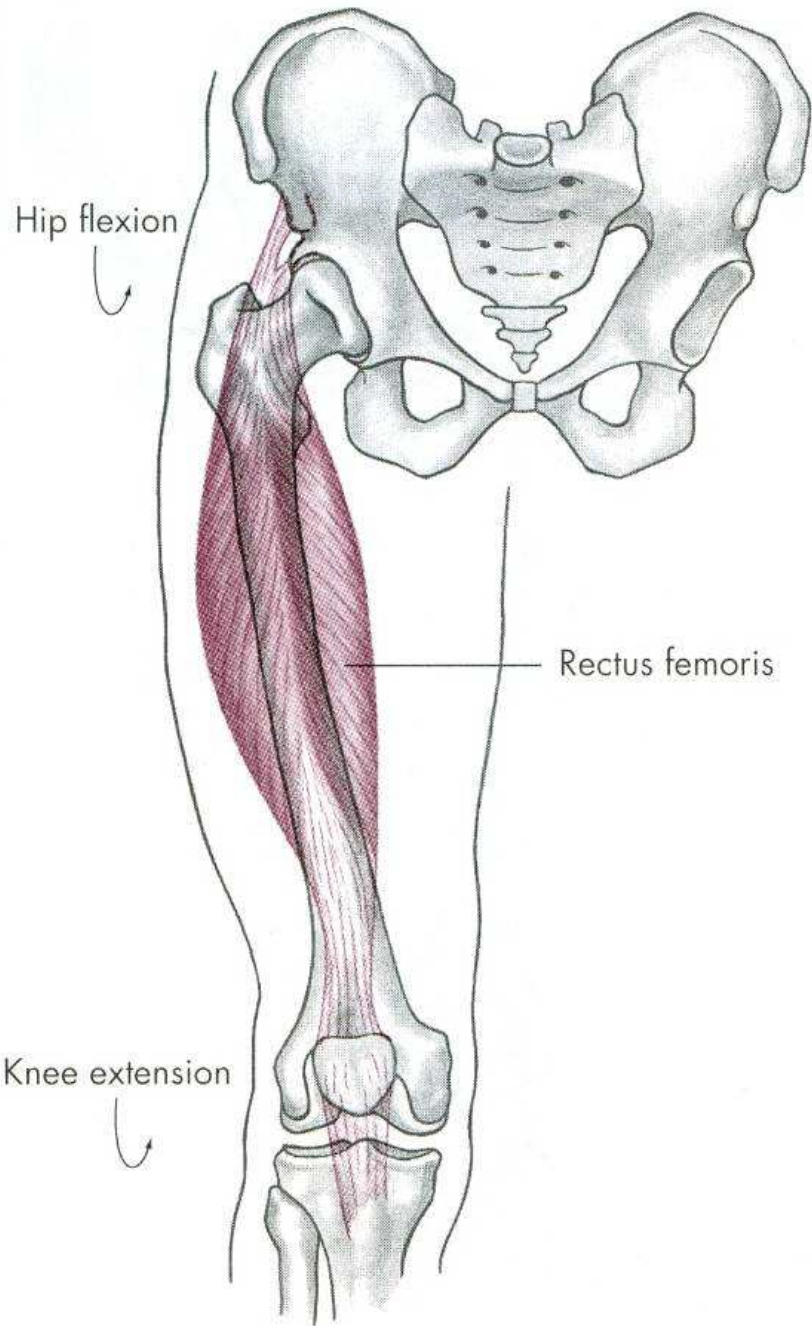


m. sartorius



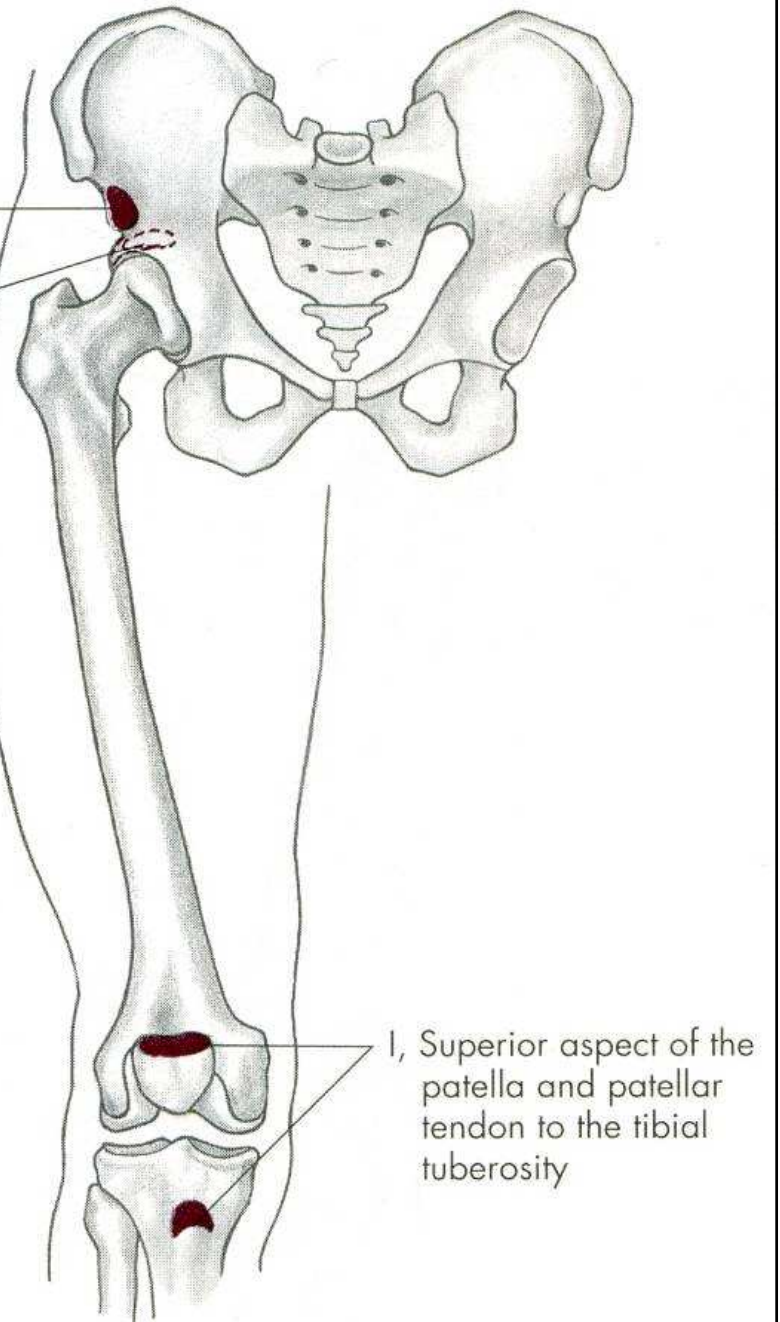
O, Anterior superior iliac spine and notch just below spine of ilium

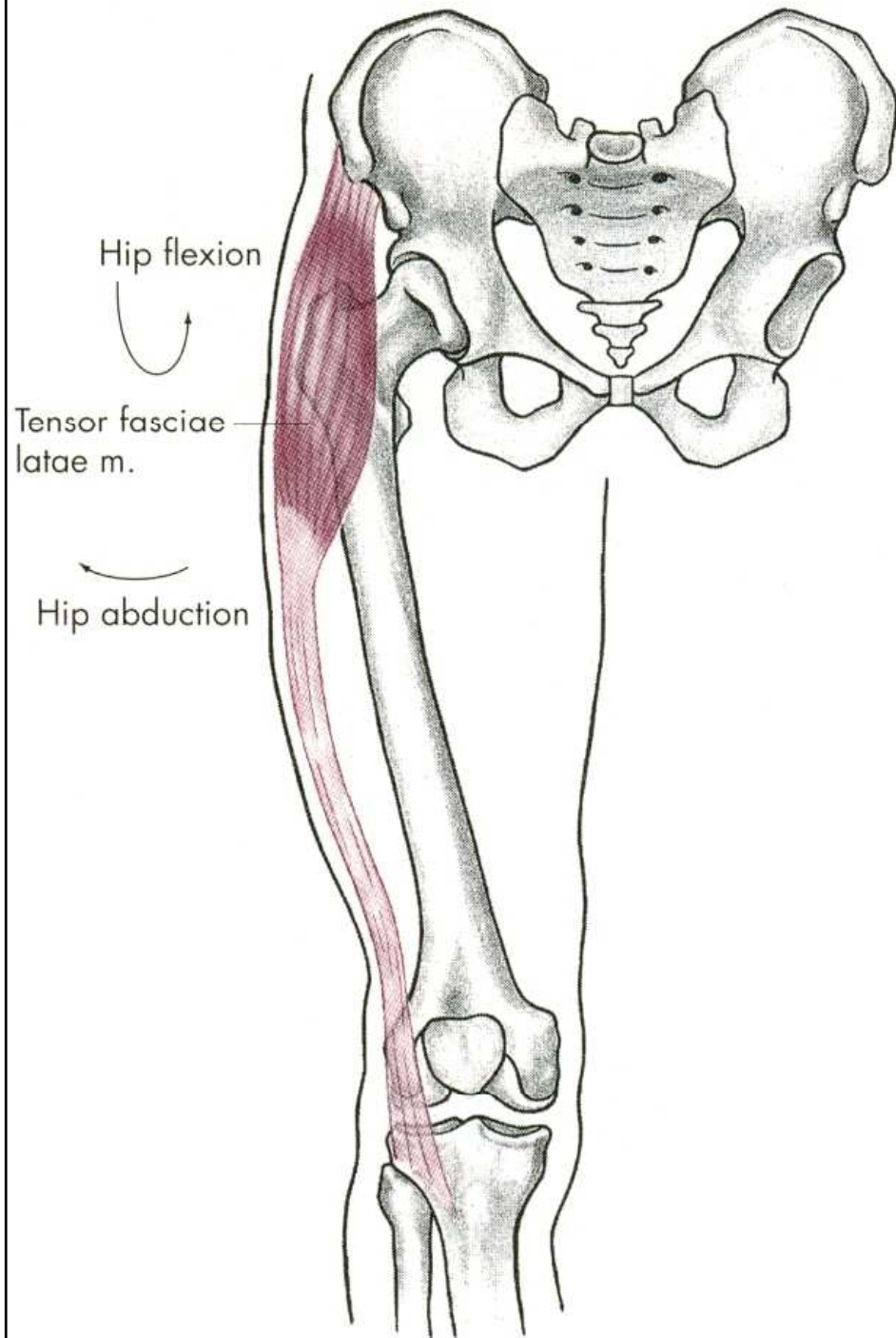




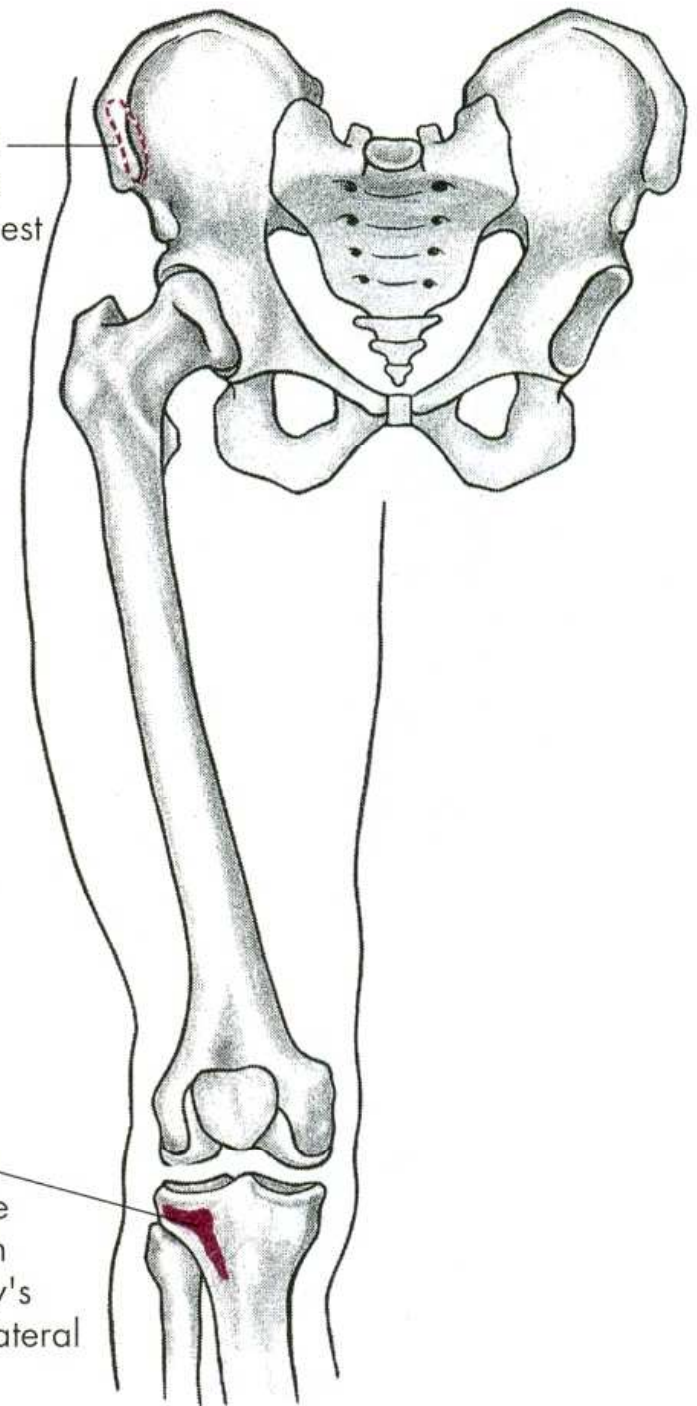
O, Anterior inferior iliac spine

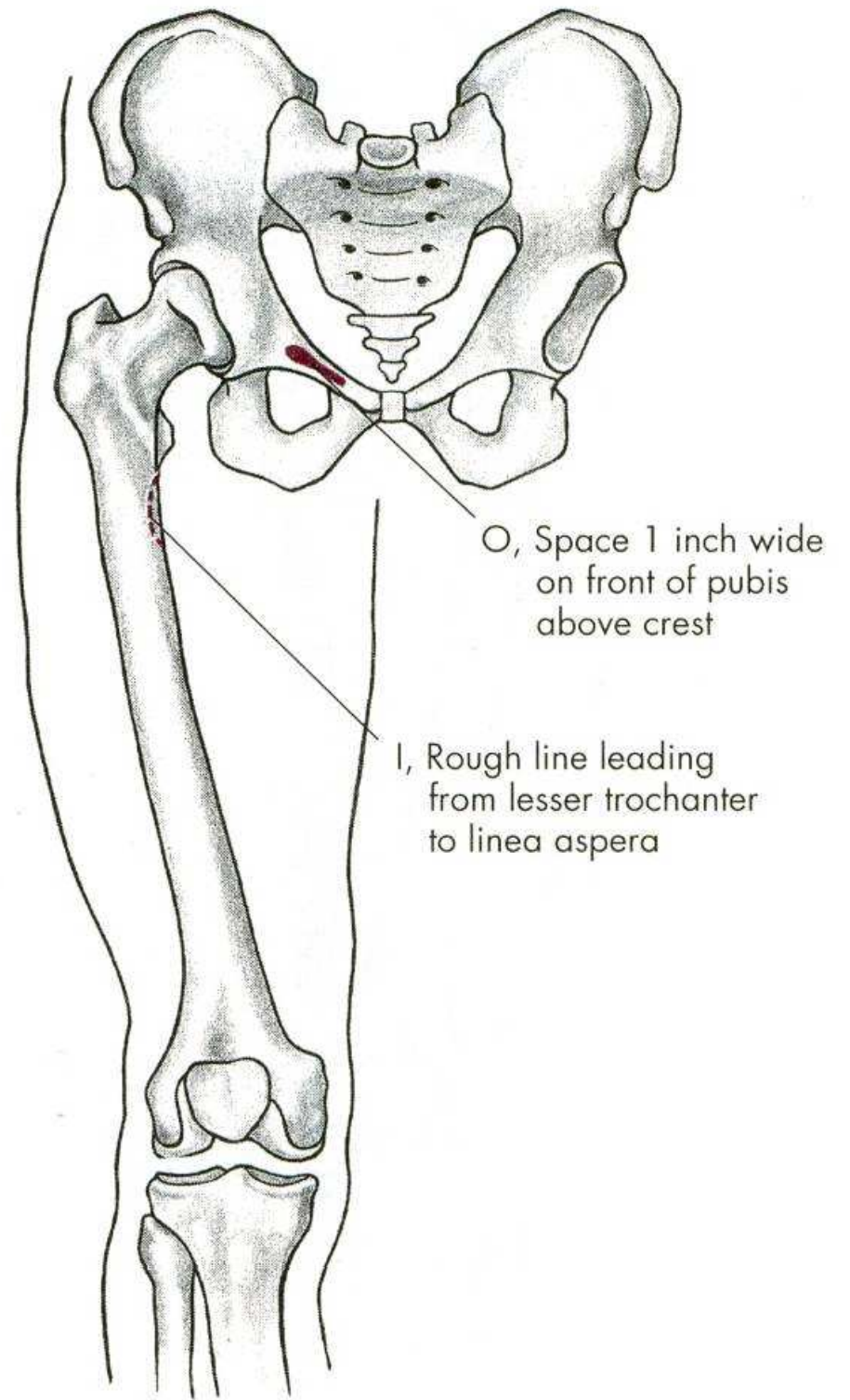
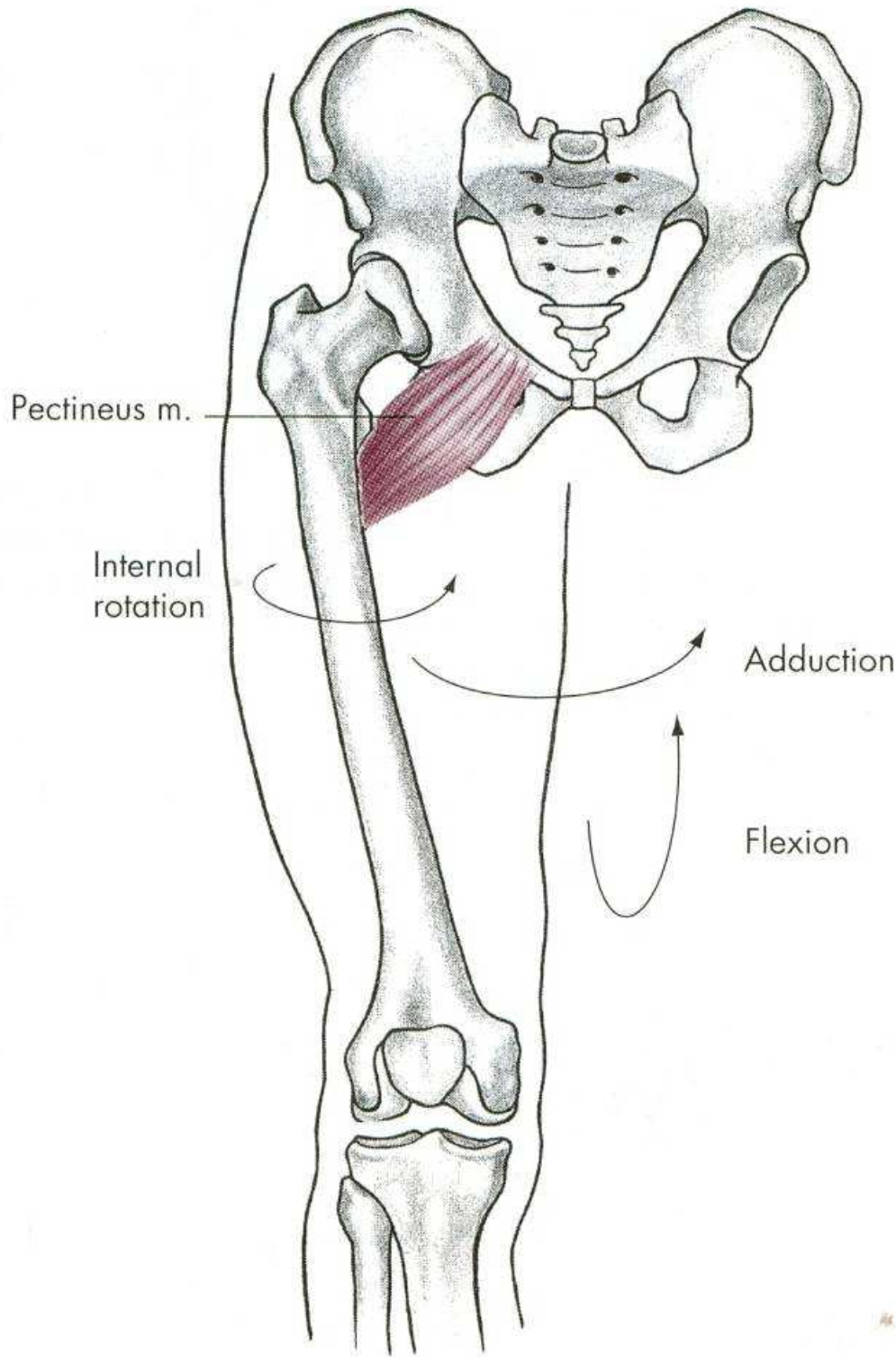
O, Groove (posterior) above the acetabulum





O, Anterior iliac crest and surface of the ilium just below crest





FLEXE

m. iliopsoas – sval bedrokyčlostehenní

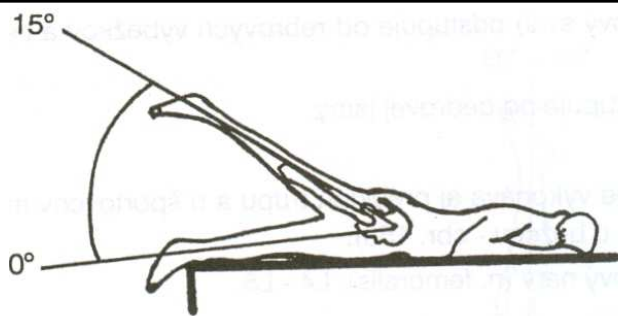
m. rectus femoris –
přímá hlava čtyřhlavého svalu stehenního

m. pectineus – sval hřebenový

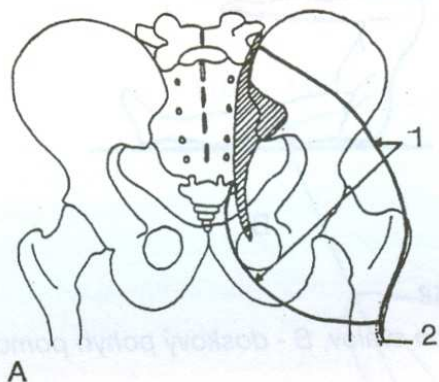
m. sartorius – sval krejčovský

m. gracilis – štíhlý sval stehenní

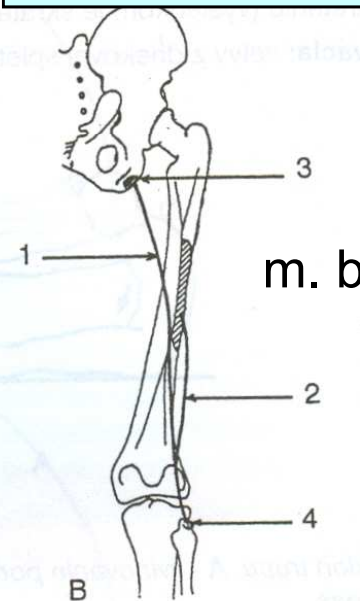
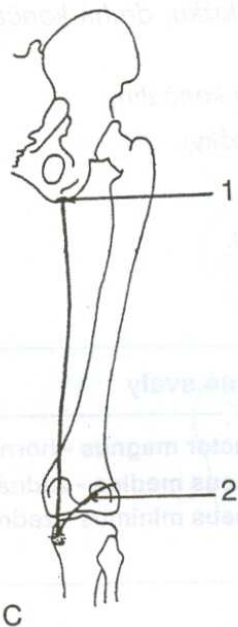
EXTENZE - ZANOŽENÍ



m. gluteus maximus

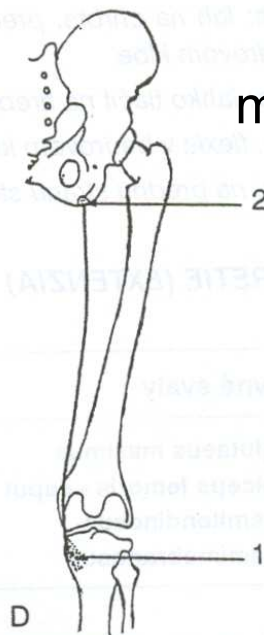


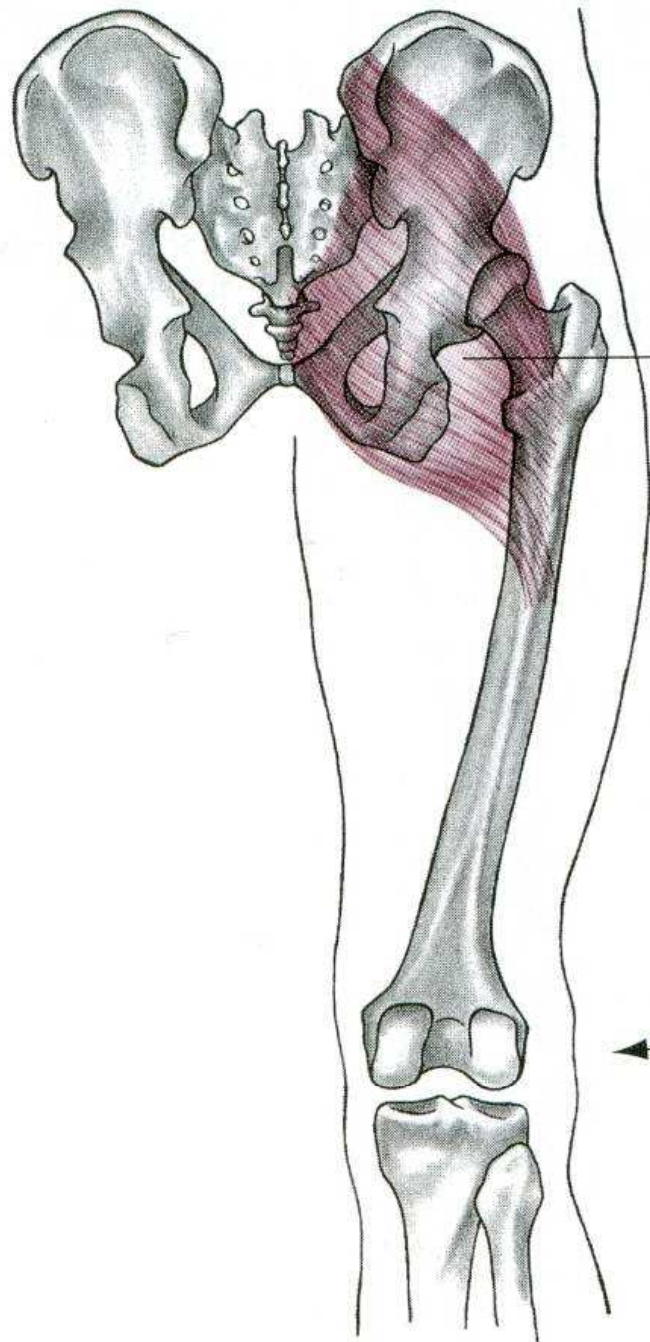
m. semimembranosus



m. biceps femoris

m. semitendinosus

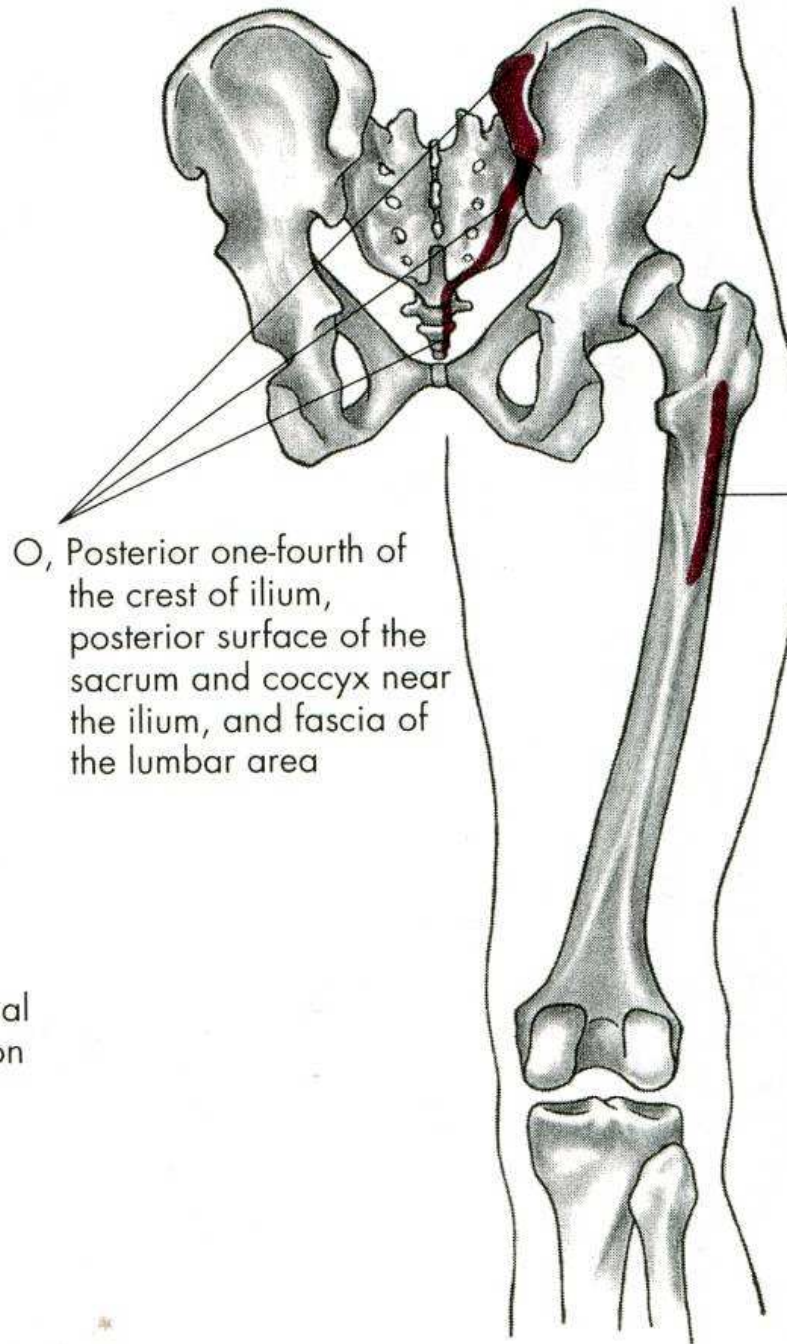




Gluteus maximus

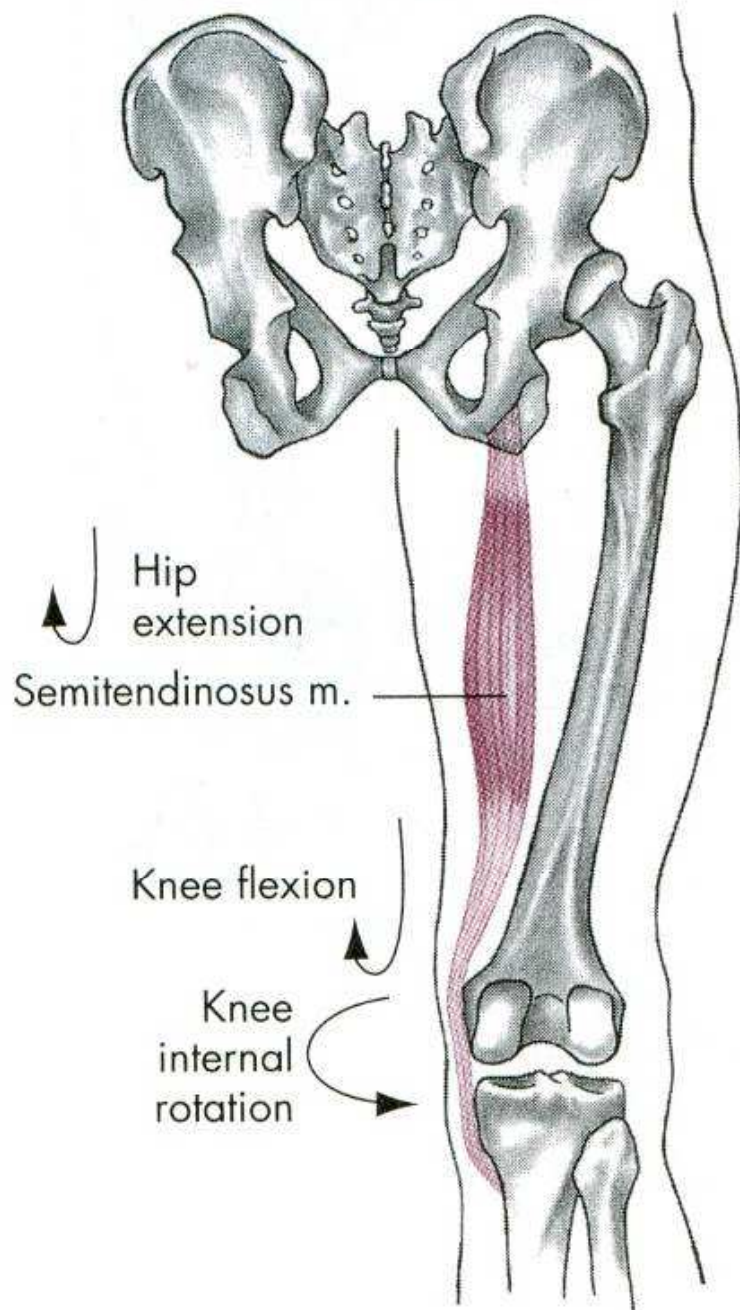
Extension

External rotation

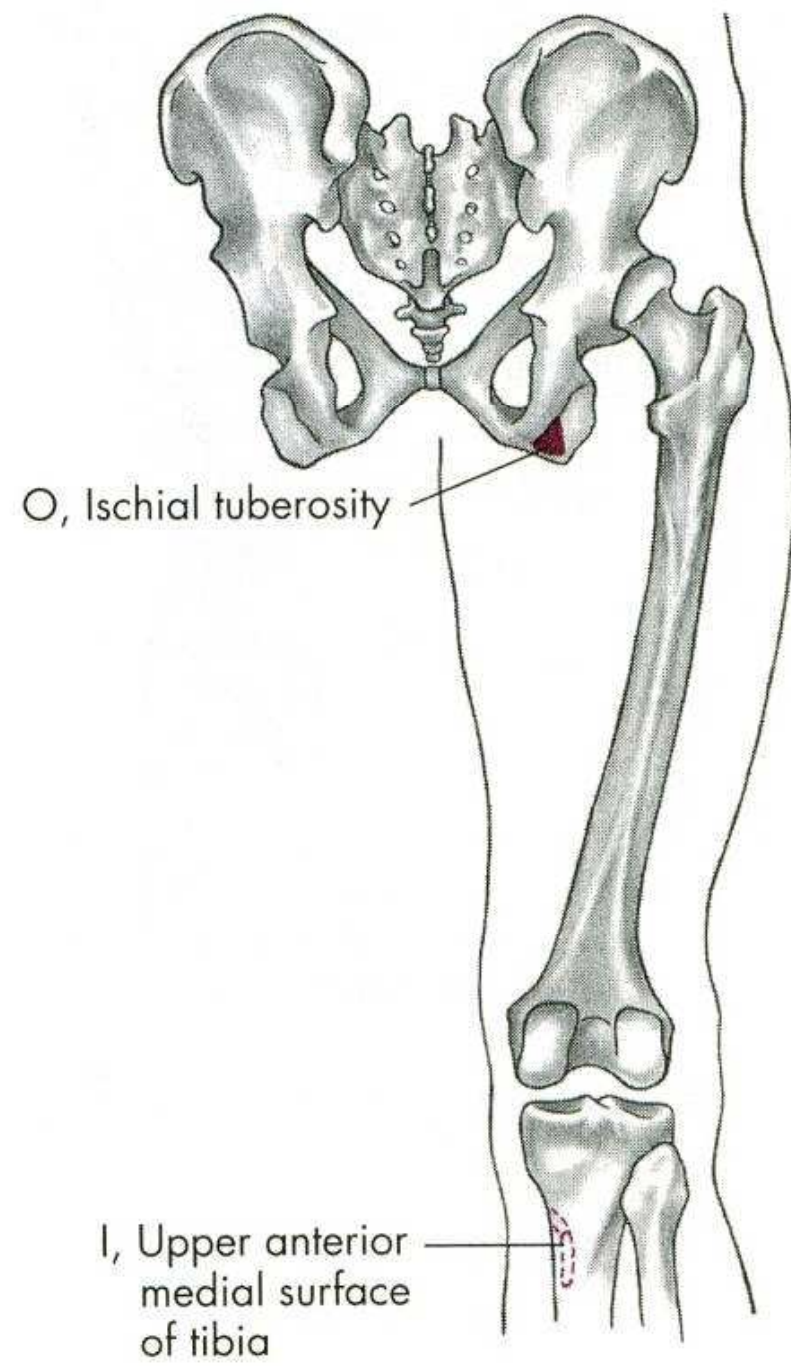


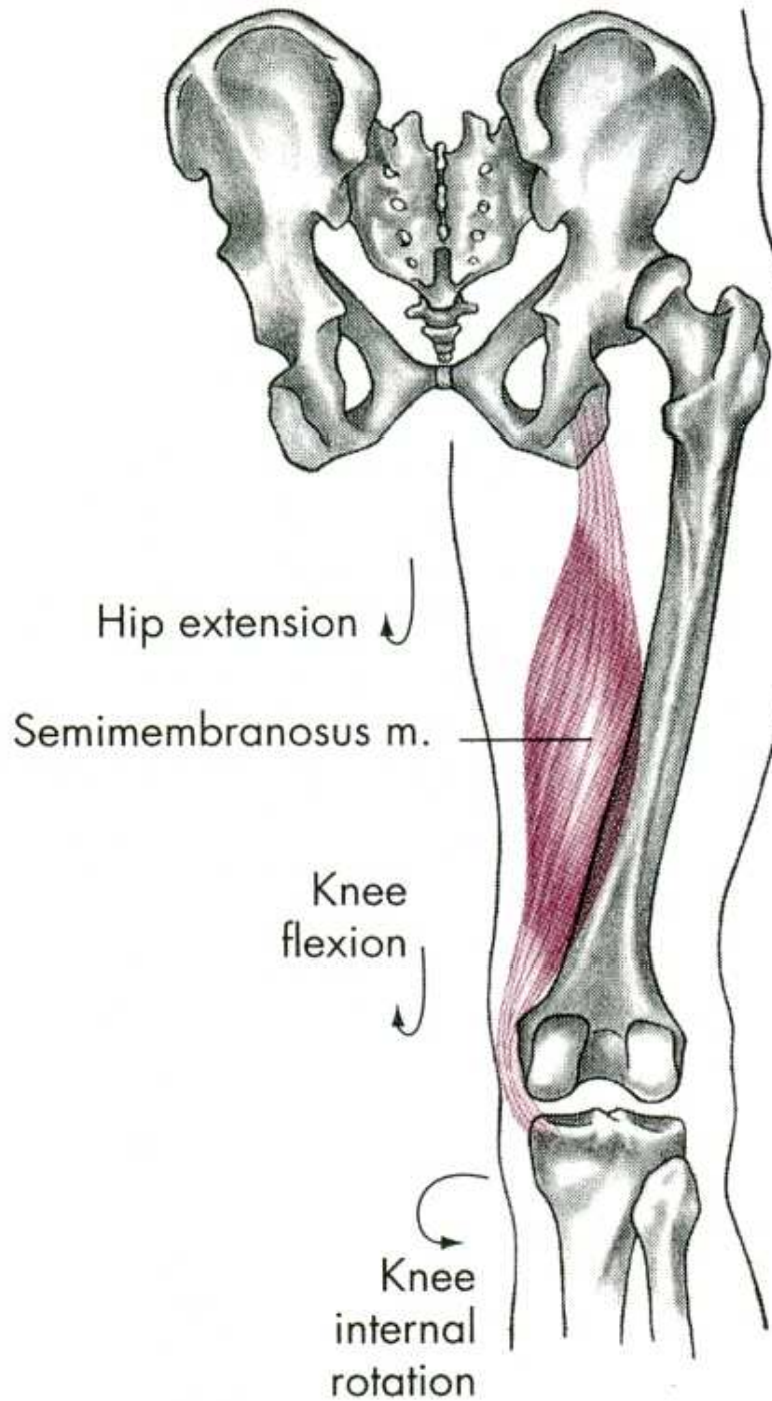
O, Posterior one-fourth of the crest of ilium, posterior surface of the sacrum and coccyx near the ilium, and fascia of the lumbar area

I, Oblique ridge on lateral surface of the greater trochanter and iliotibial band of fascia latae

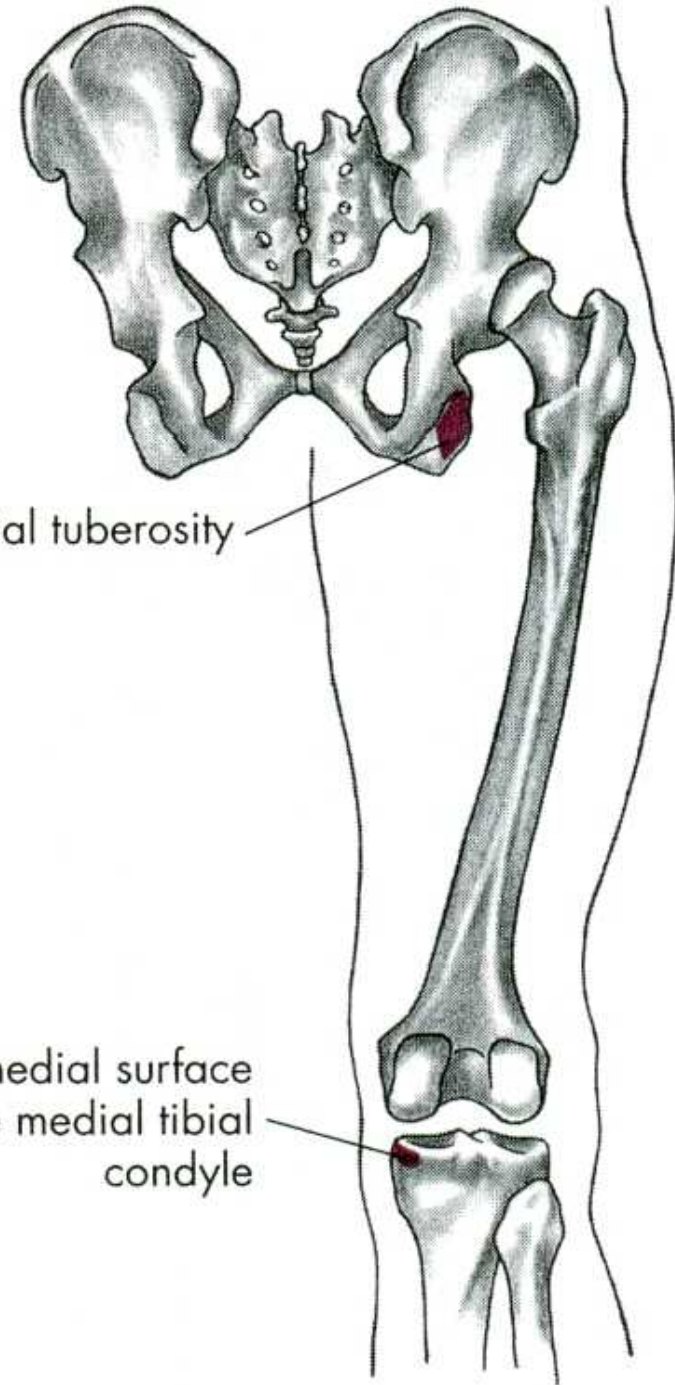


Hip internal rotation



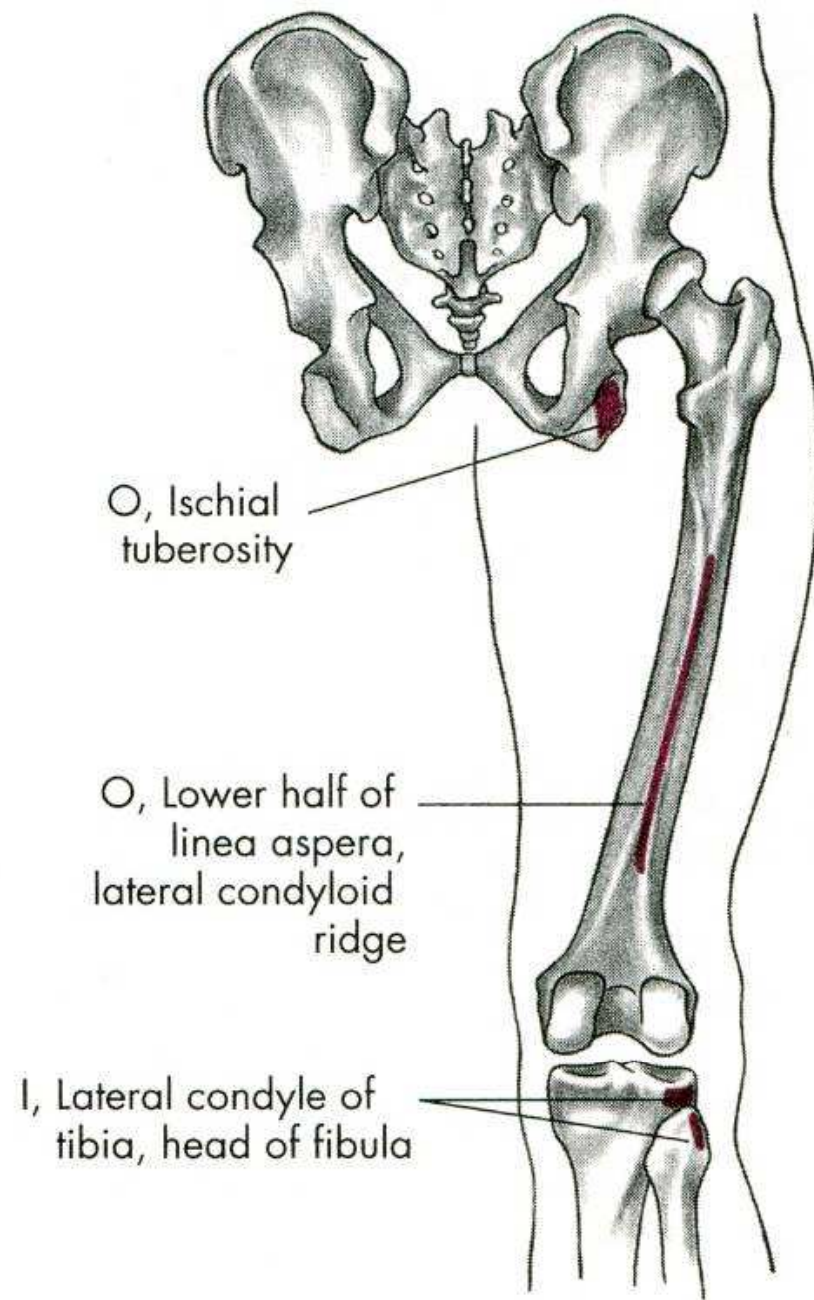
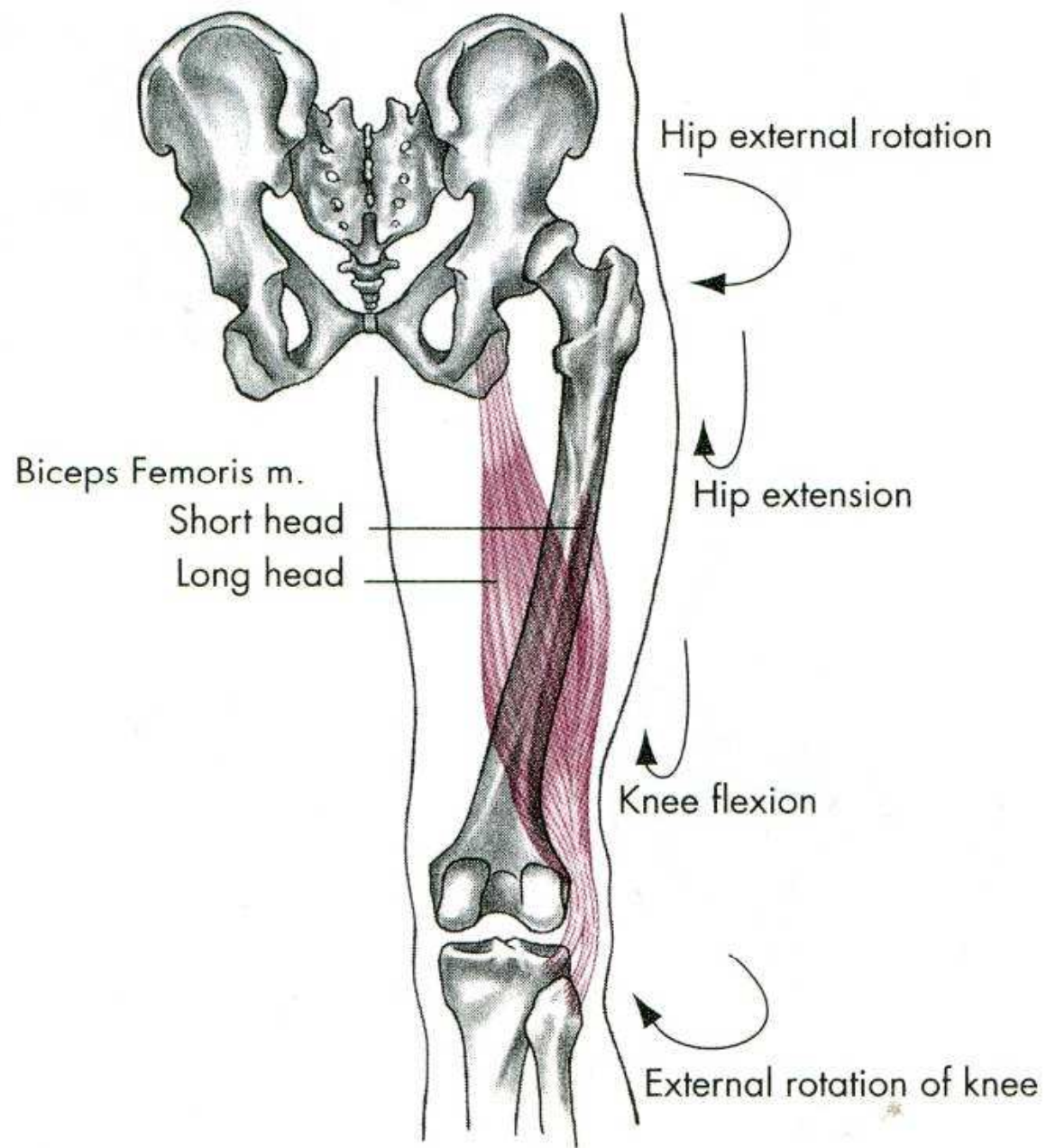


Hip internal rotation



O, Ischial tuberosity

I, Posteromedial surface of the medial tibial condyle



EXTENZE

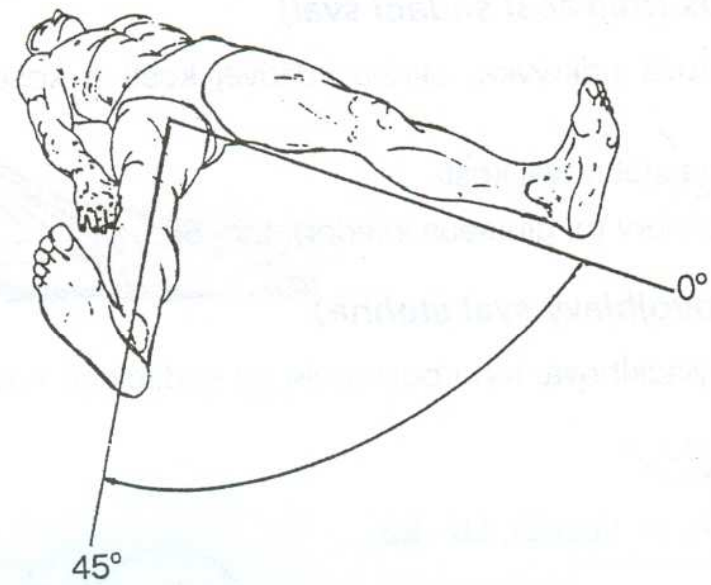
m. gluteus maximus – velký sval hýžďový

m. biceps femoris – dvojhlavý sval stehenní

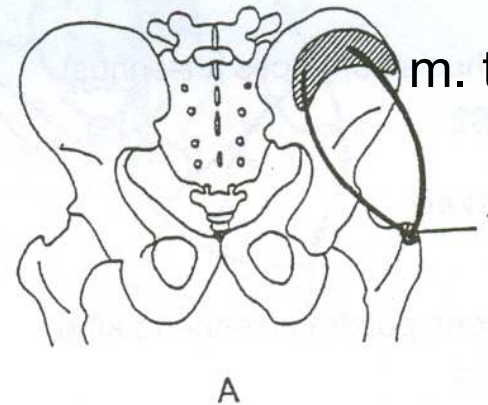
m. semitendinosus – sval pološlašitý

m. semimembranosus – sval poloblanitý

ABDUKCE - UNOŽENÍ

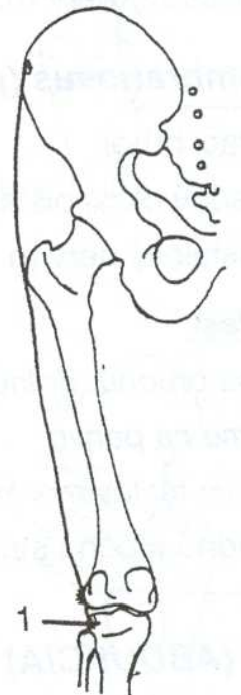
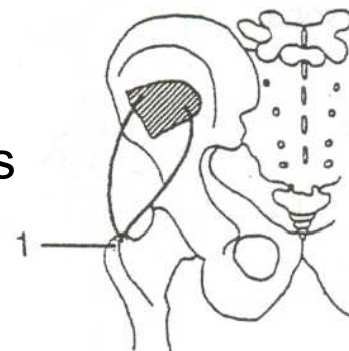


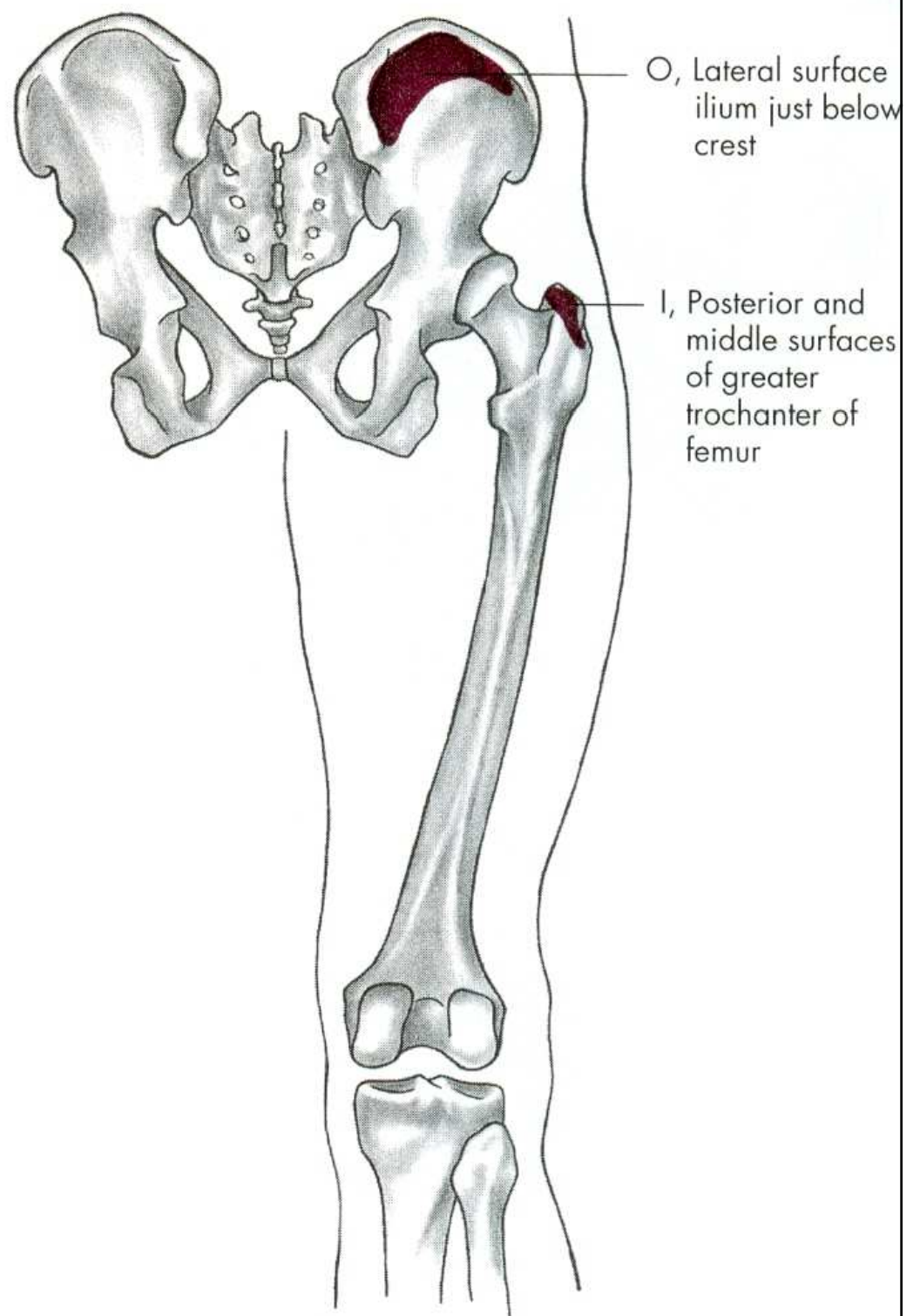
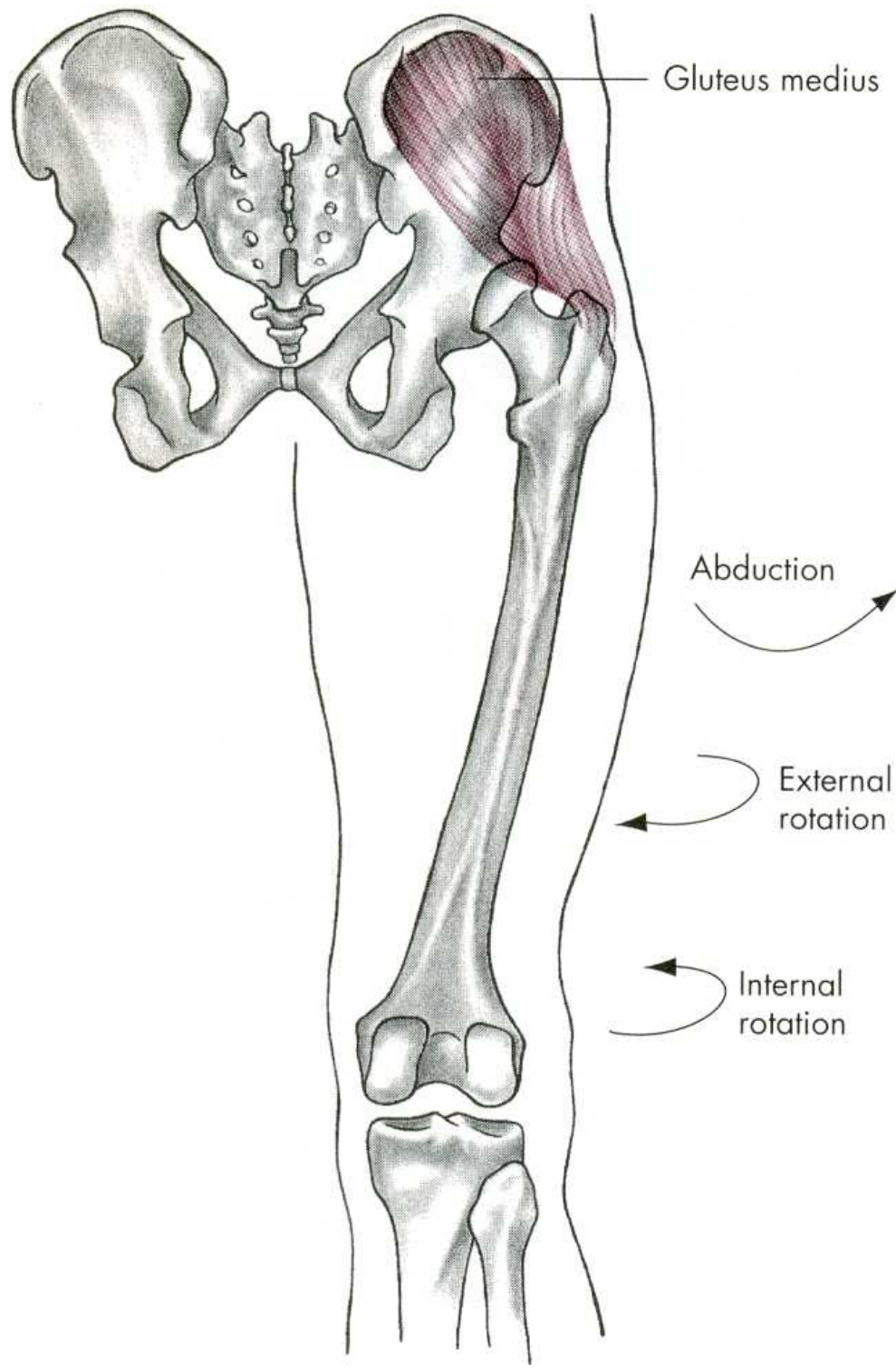
m. gluteus medius



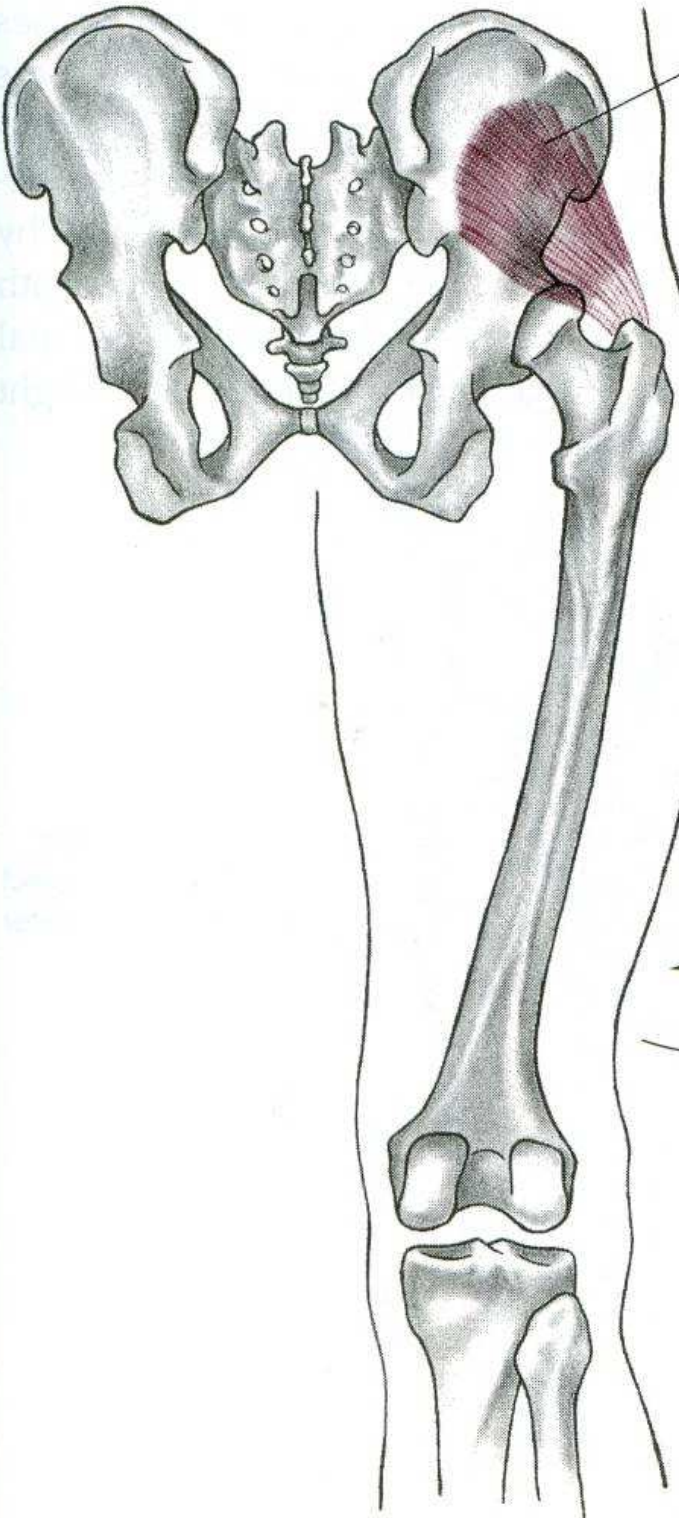
m. tensor fasciae latae

m. gluteus minimus





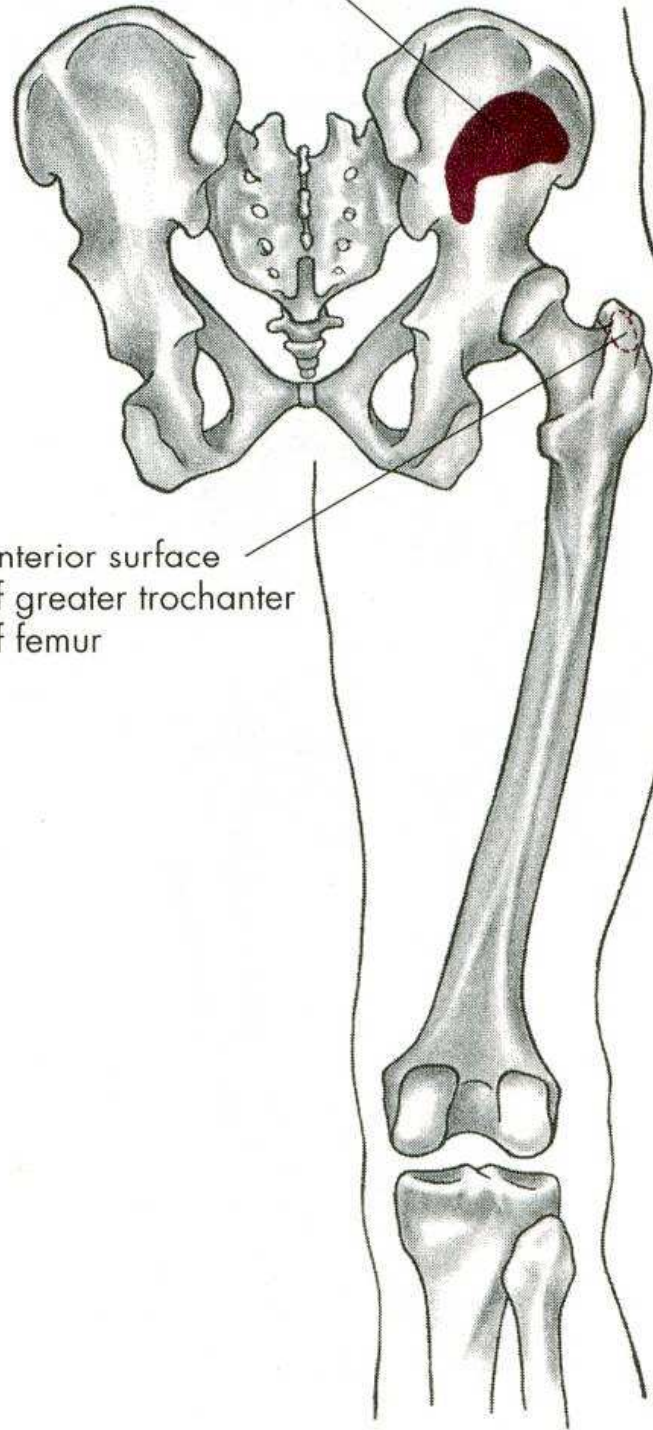
Gluteus minimus



Abduction

Internal rotation

O, Lateral surface of ilium below the origin of gluteus medius



I, Anterior surface of greater trochanter of femur

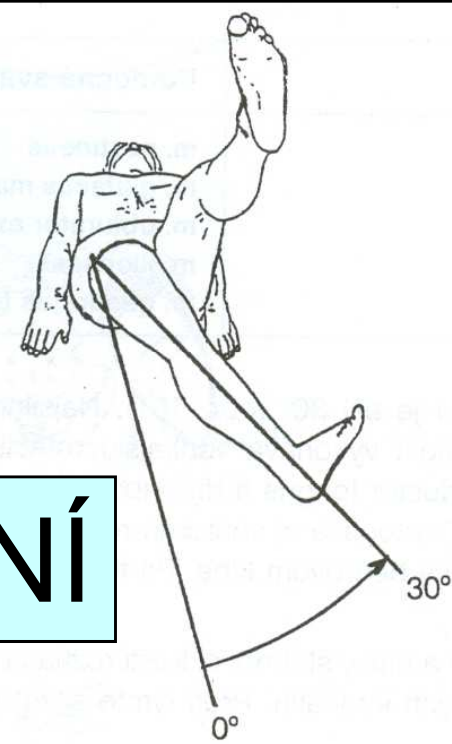
ABDUKCE

m. gluteus medius – střední sval hýžd'ový

m. gluteus minimus – malý sval hýžd'ový

m. tensor fasciae latae –
napínač stehenní povázky

ADDUKCE - PŘINOŽENÍ

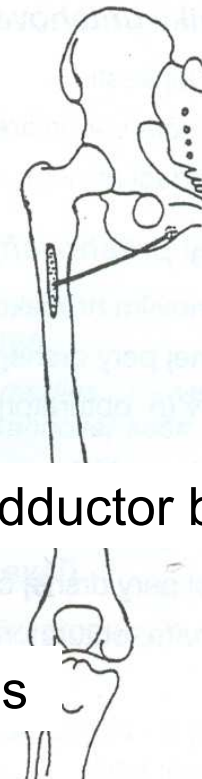


m. gracilis


m. adductor magnus

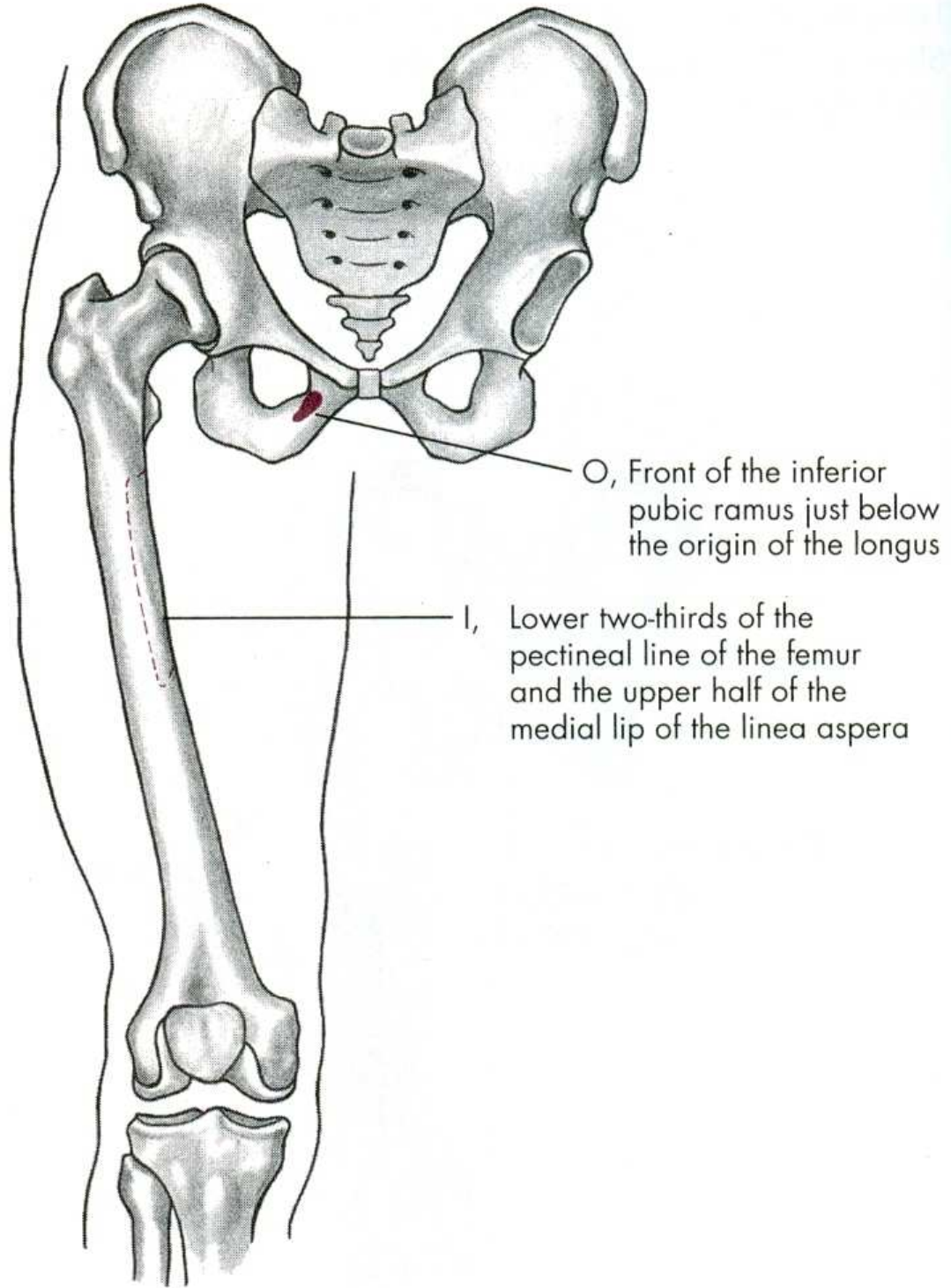
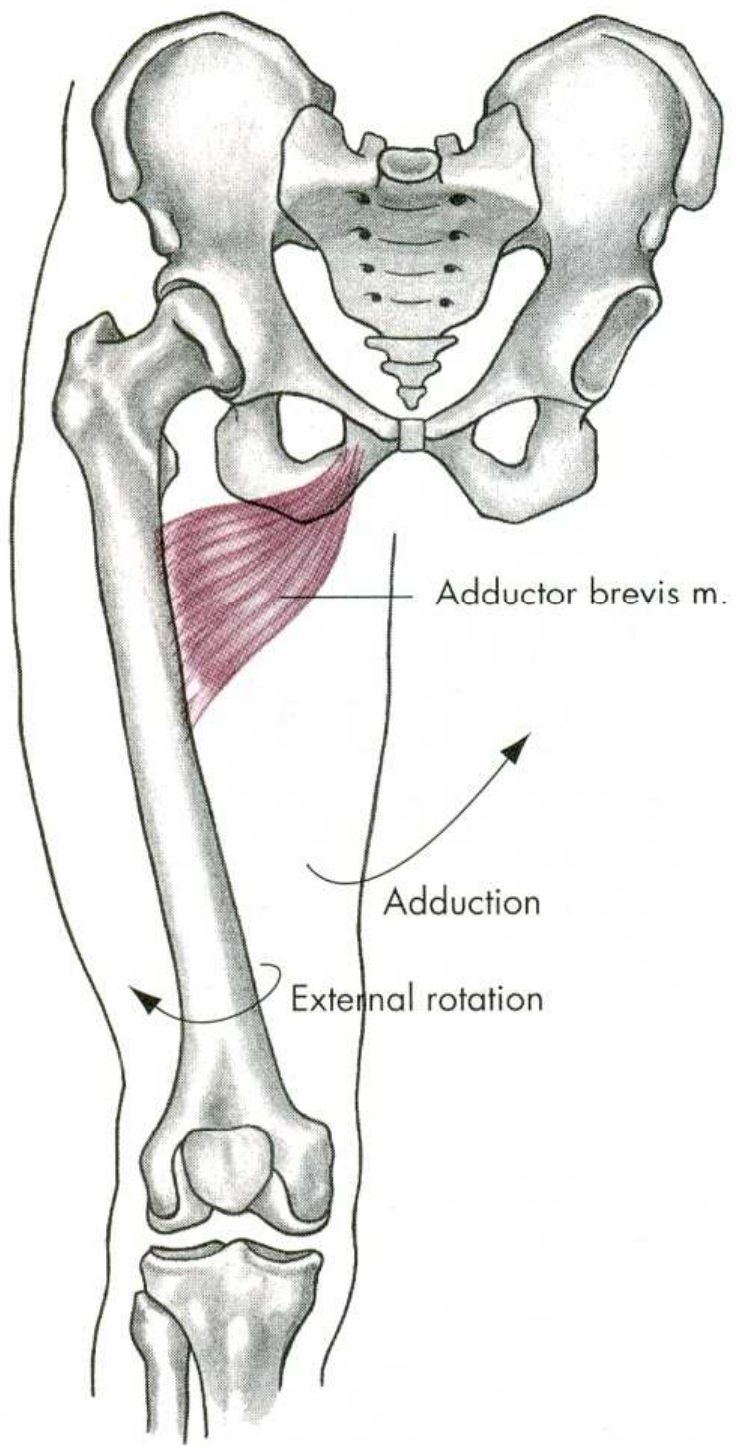


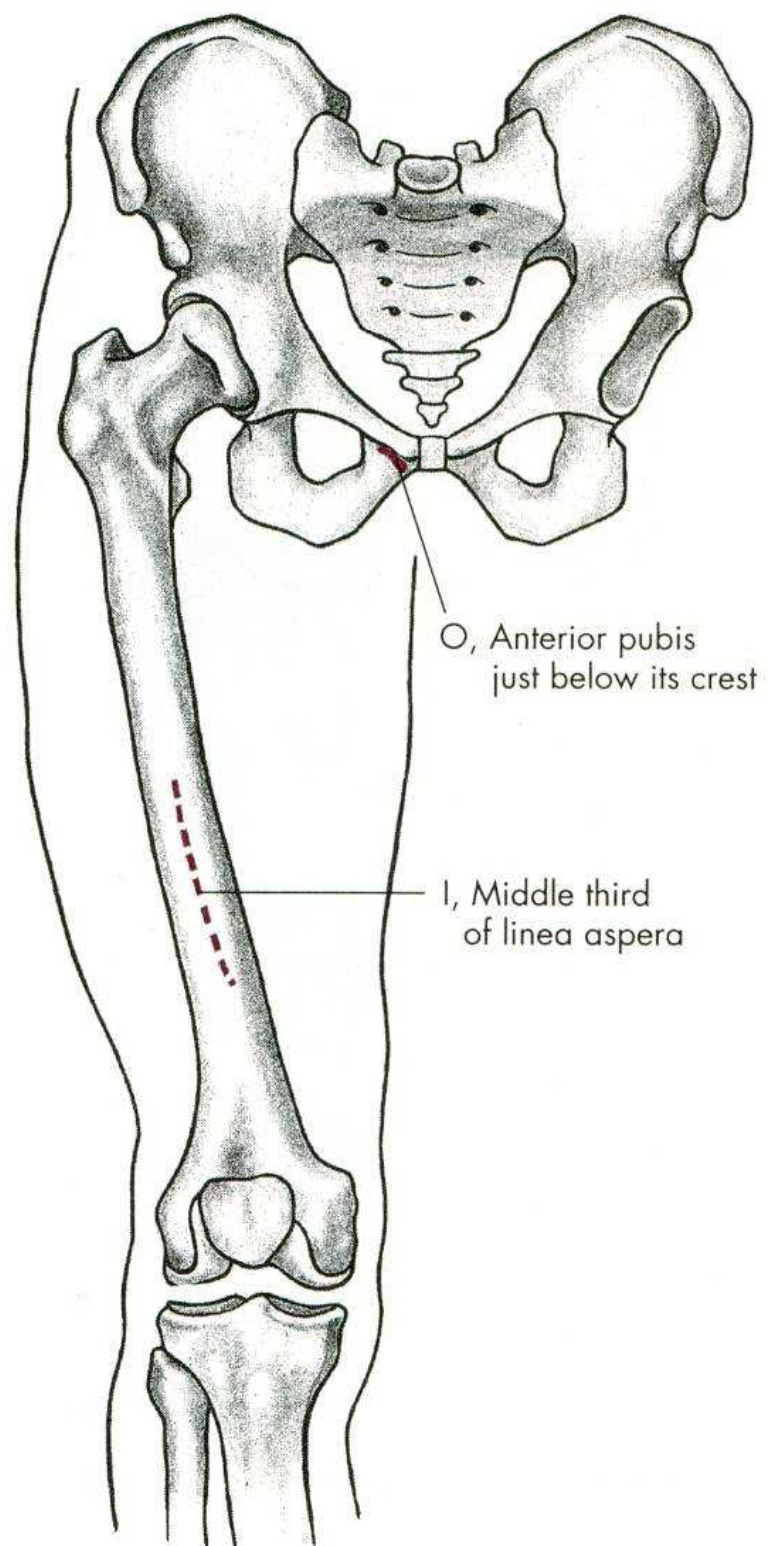
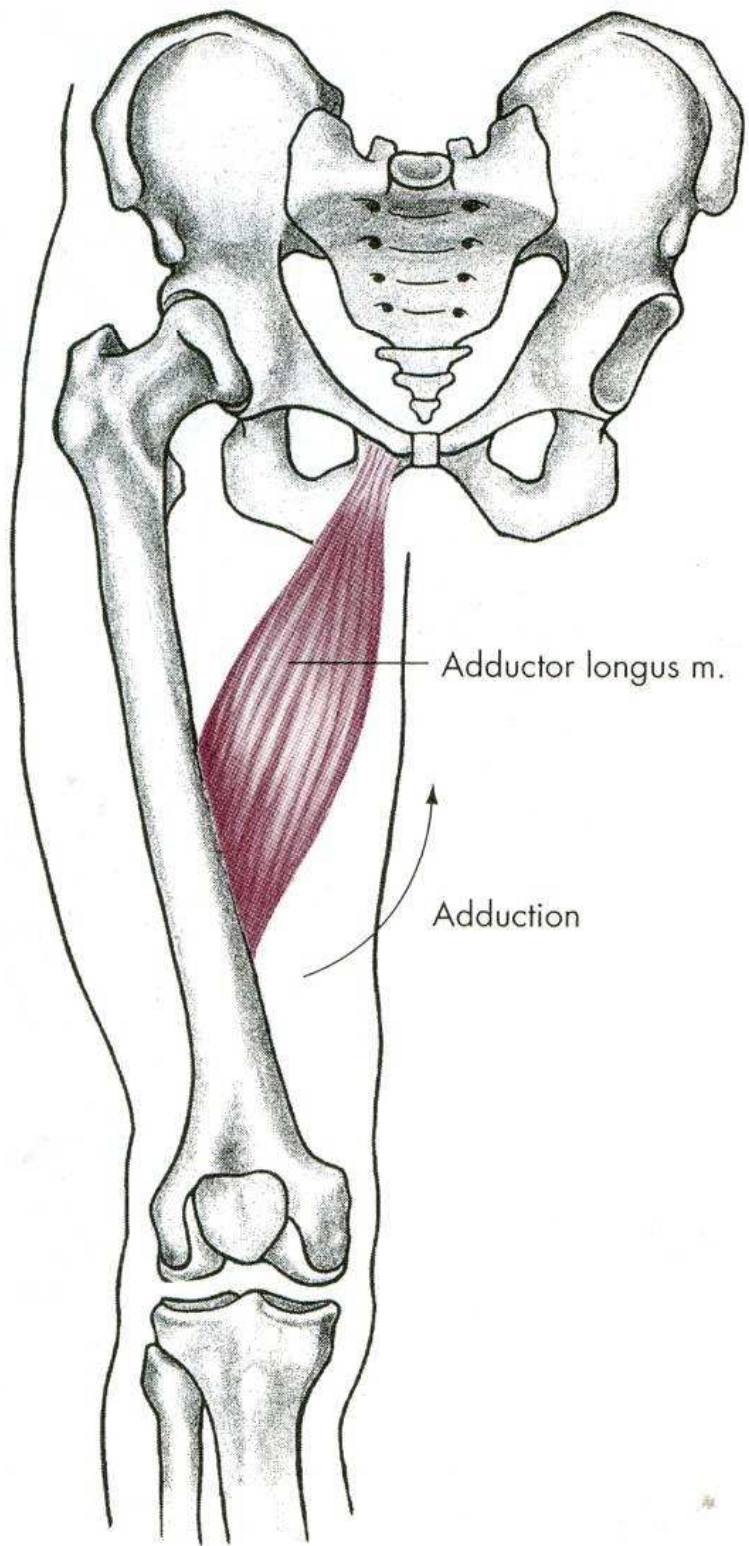
m. adductor longus

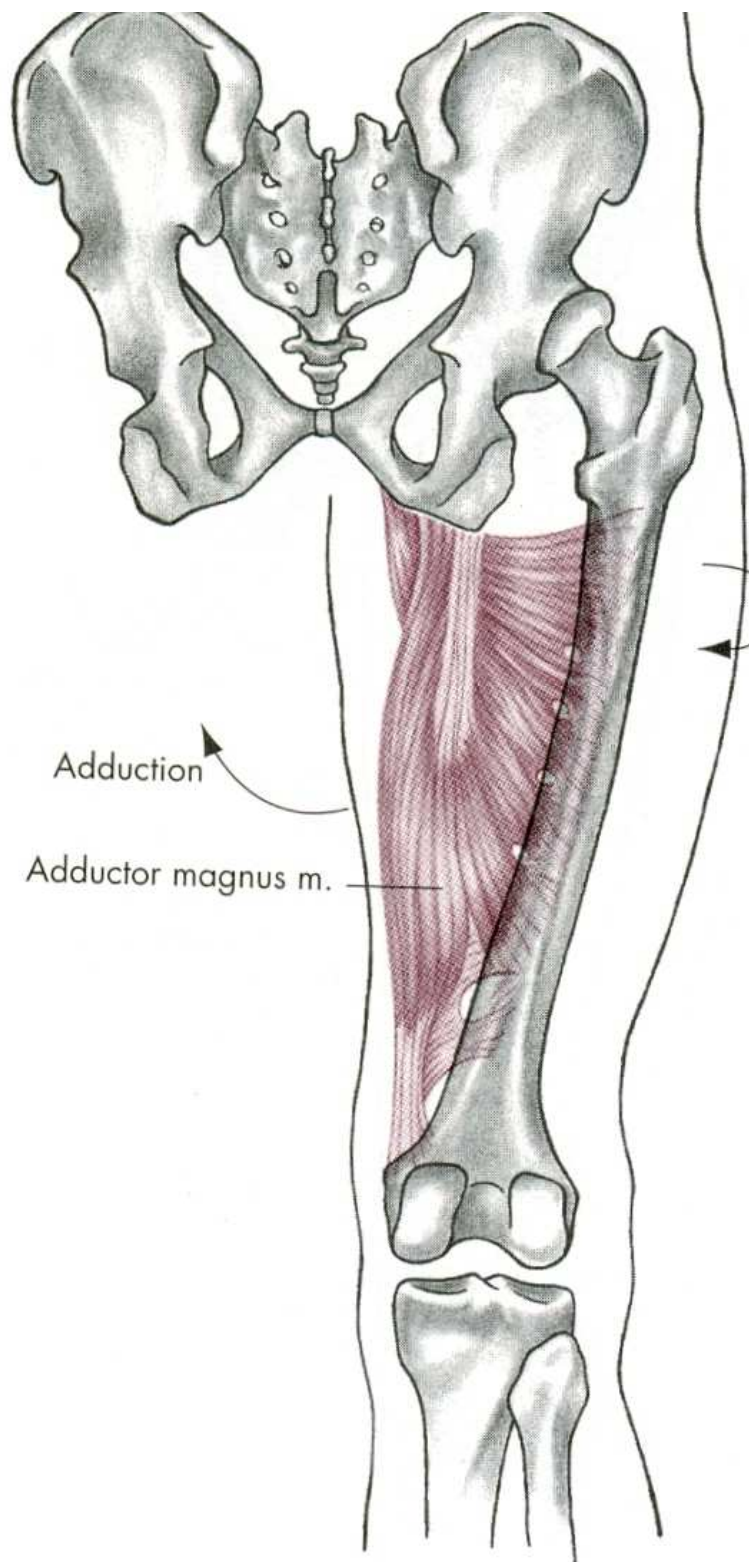


m. adductor brevis





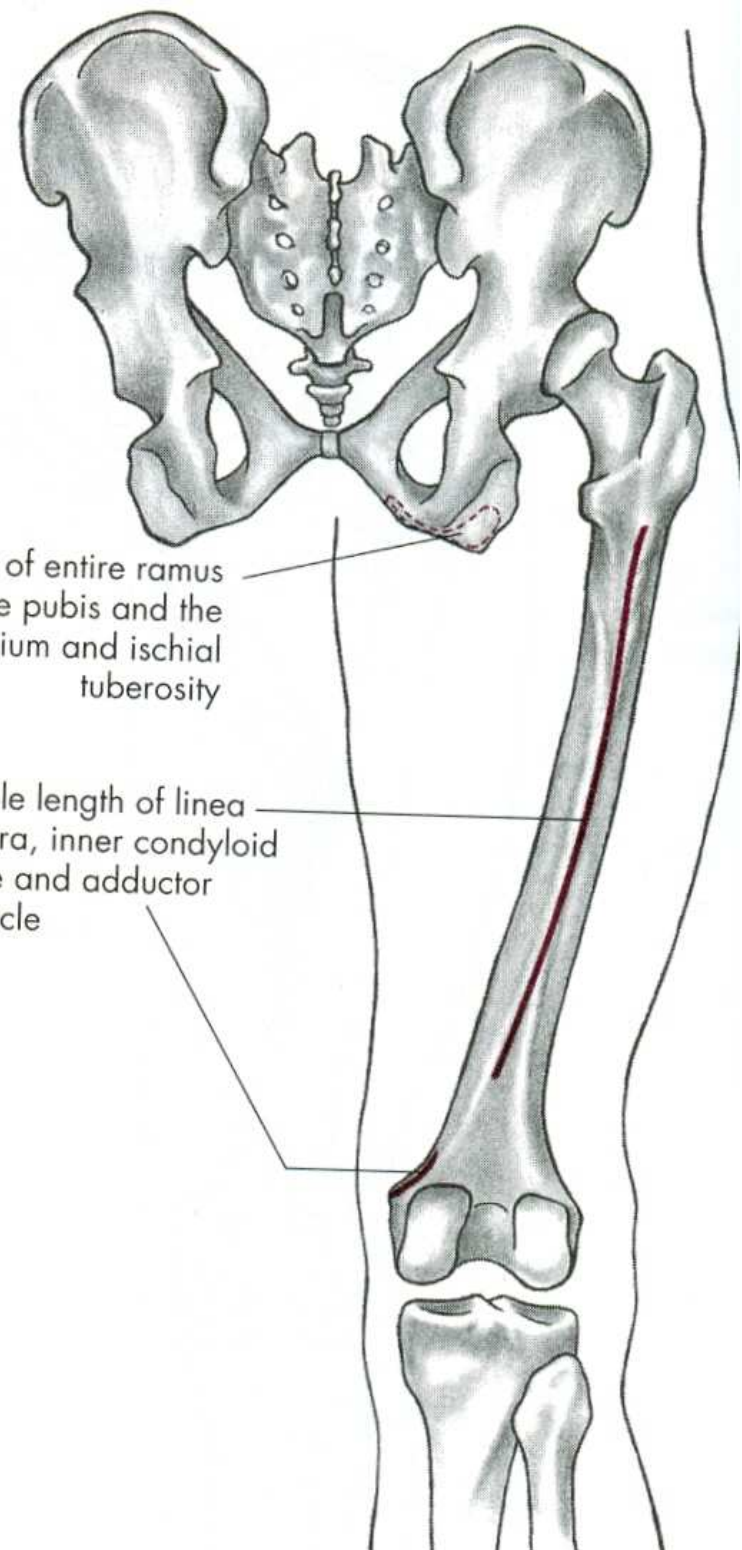




Adduction

Adductor magnus m.

External rotation



O, Edge of entire ramus of the pubis and the ischium and ischial tuberosity

I, Whole length of linea aspera, inner condyloid ridge and adductor tubercle

Hip internal rotation

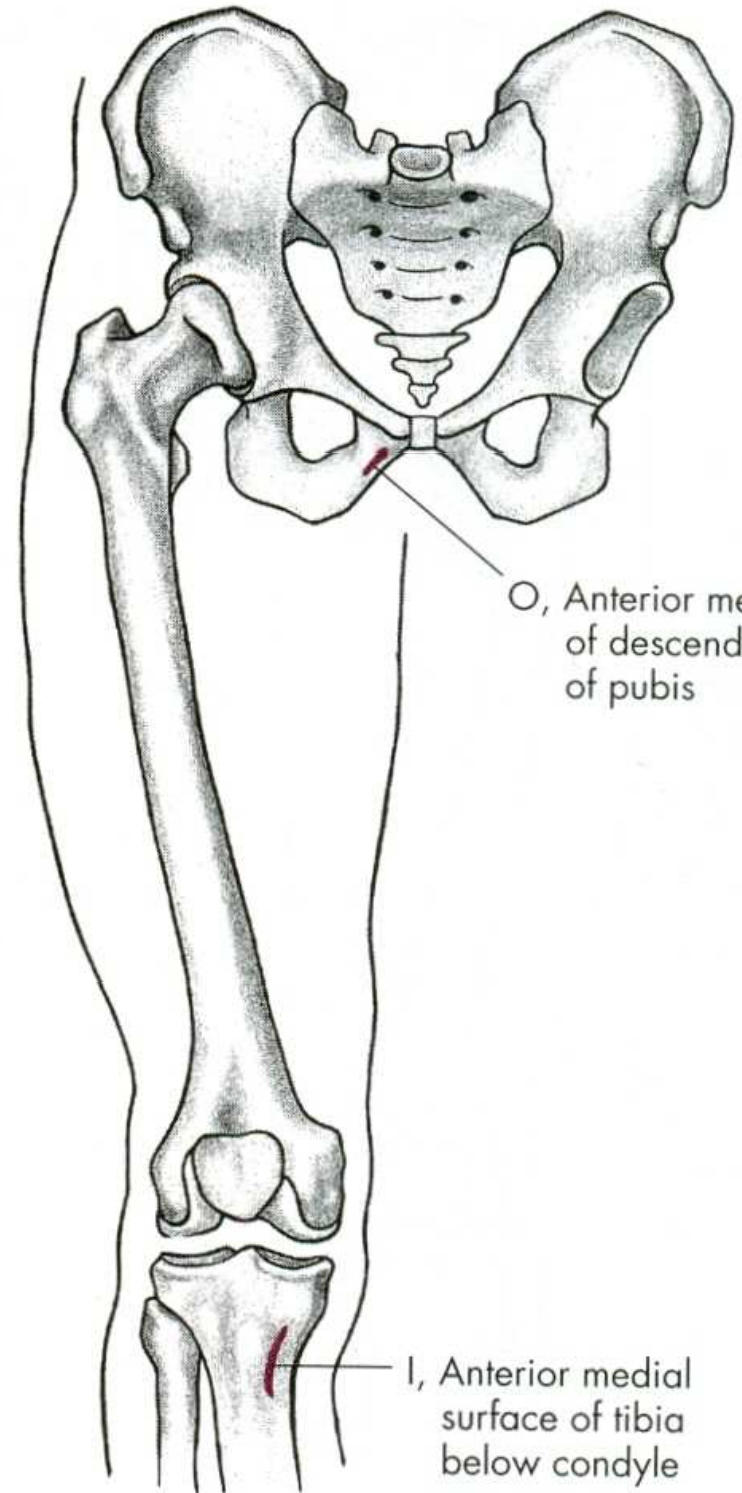
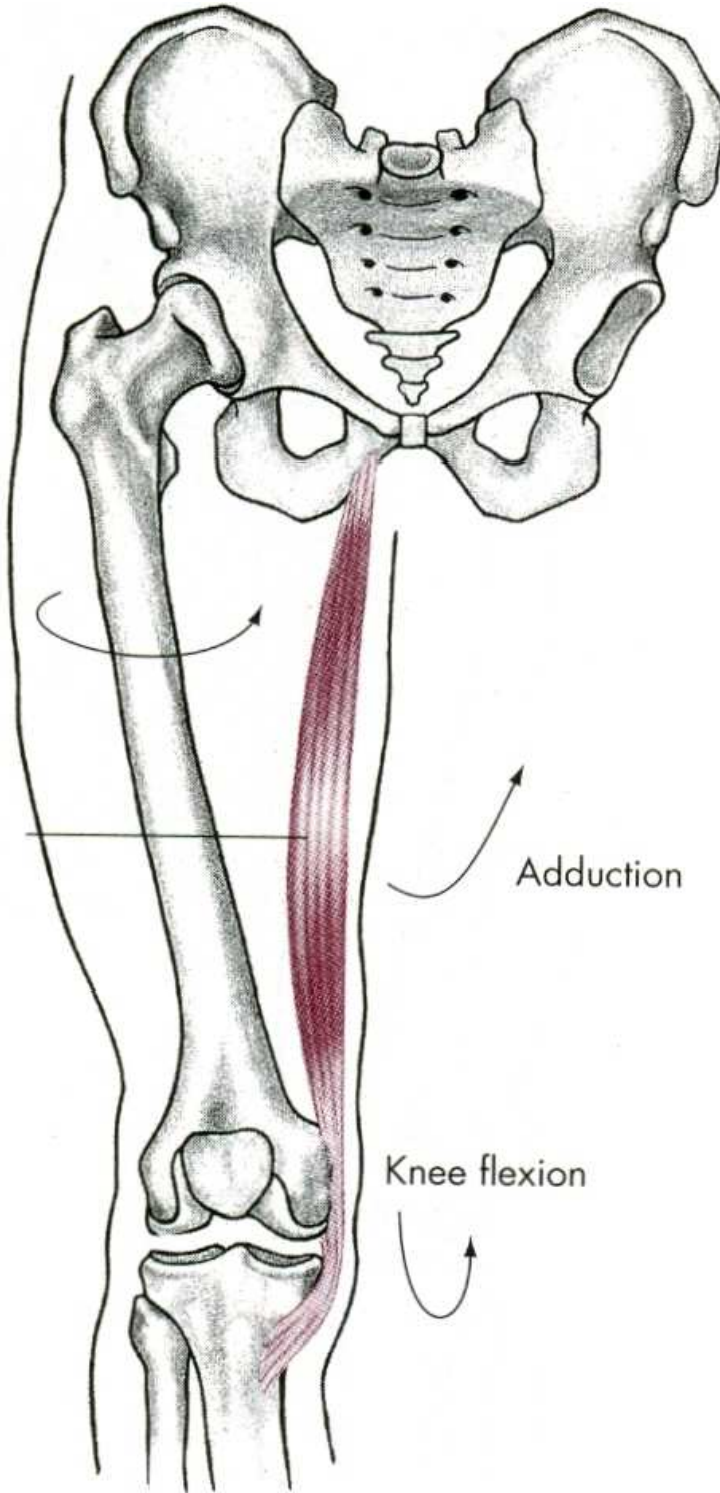
Gracilis m.

Adduction

Knee flexion

O, Anterior medial edge of descending ramus of pubis

I, Anterior medial surface of tibia below condyle



ADDUKCE

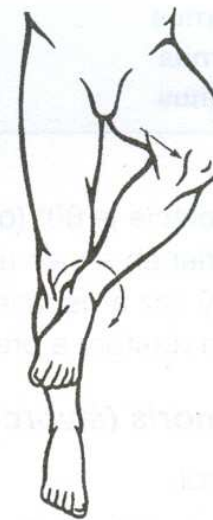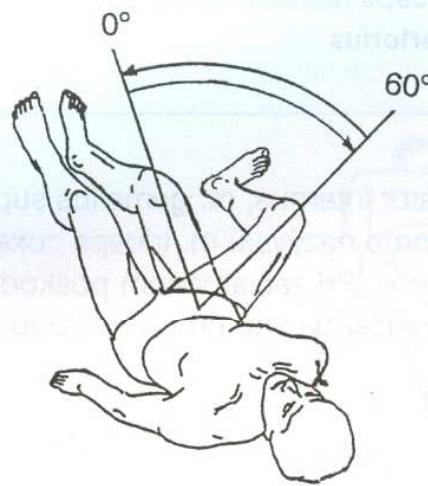
m. adductor magnus – velký přitahovač

m. adductor longus – dlouhý přitahovač

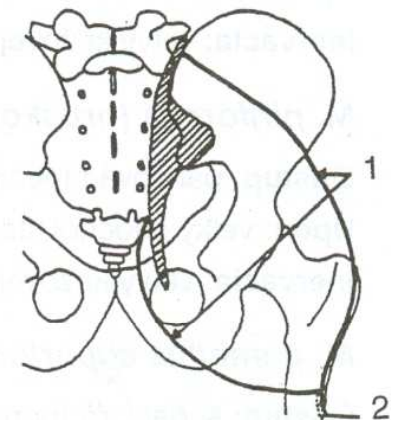
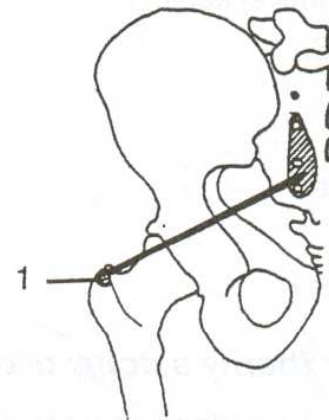
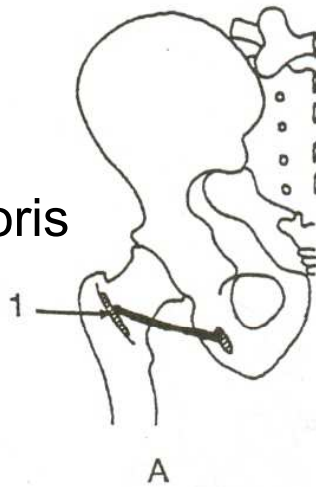
m. adductor brevis – krátký přitahovač

m. gracilis – štíhlý sval stehenní

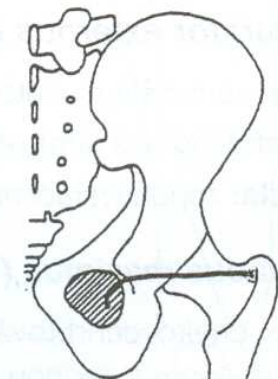
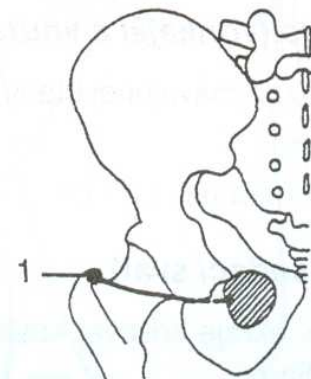
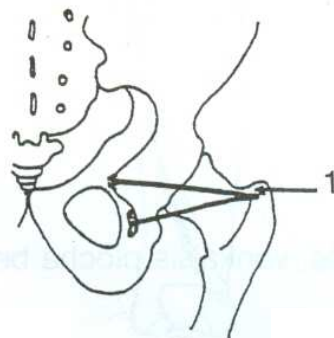
VNĚJŠÍ ROTACE



m. quadratus femoris



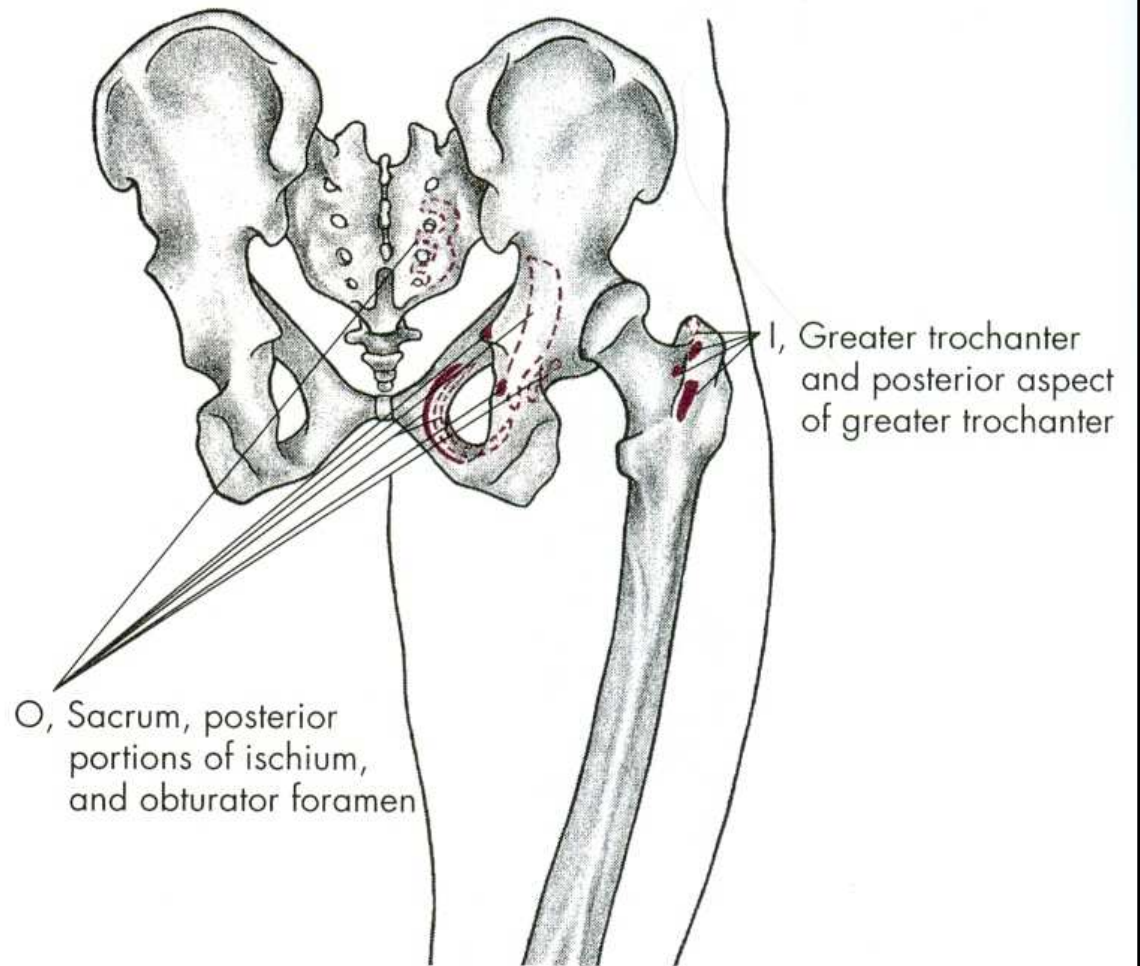
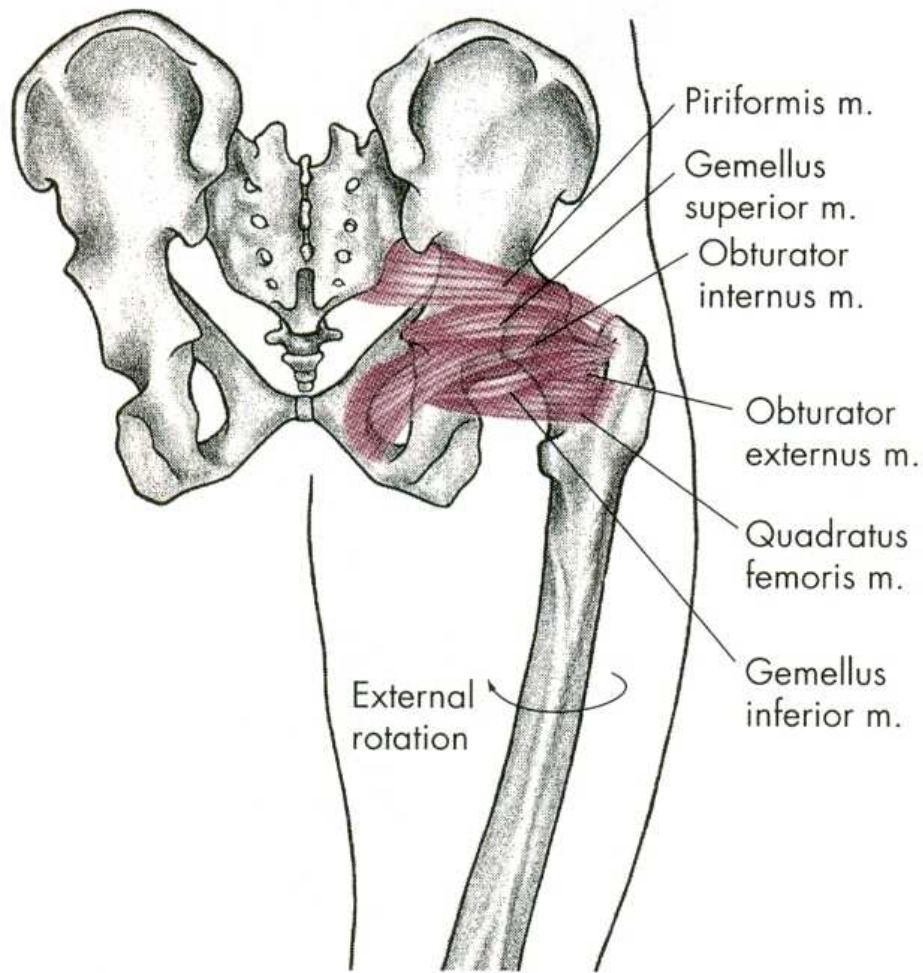
m. piriformis m. gluteus maximus



m. gemellus superior

m. obturator externus

m. obturator internus



ZEVNÍ ROTACE

m. quadratus femoris – čtyřhlavý sval stehenní

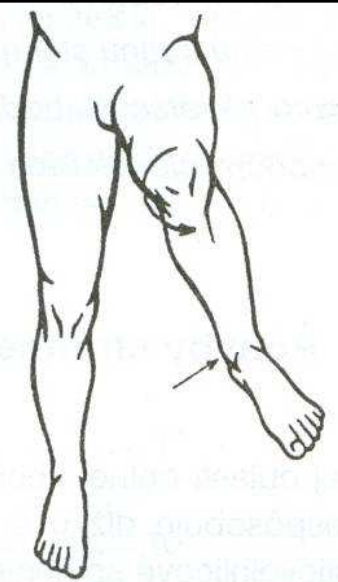
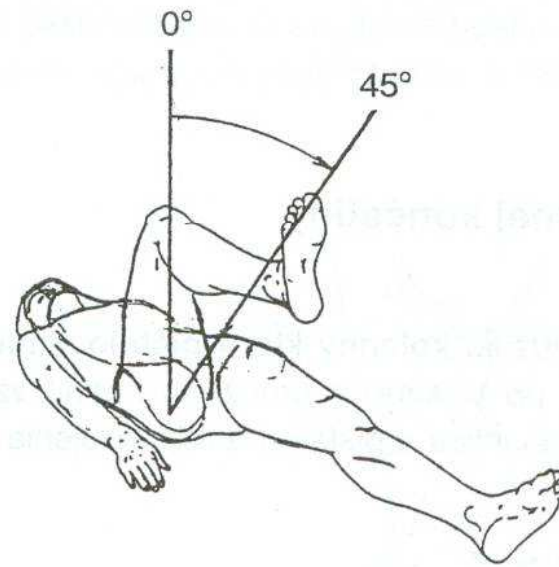
m. piriformis – hruškovitý sval

mm. gemeli

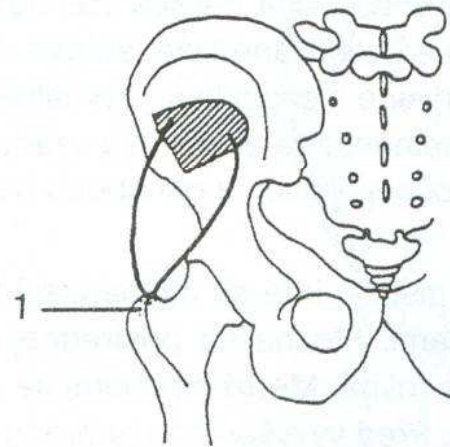
mm. obturatorii – ucpávače

m. gluteus maximus – velký sval hýžd'ový

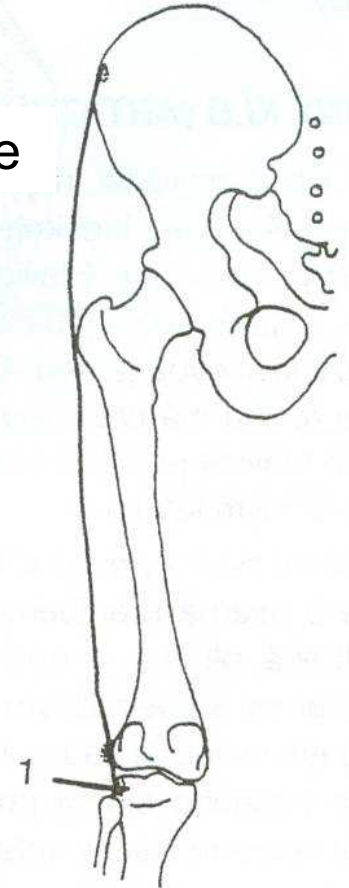
VNITŘNÍ ROTACE



m. tensor fasciae latae



m. gluteus minimus



VNITŘNÍ ROTACE

m. gluteus minimus –
malý sval hýžd'ový-přední snopce

m. tensor fasciae latae –
napínač stehenní povázky

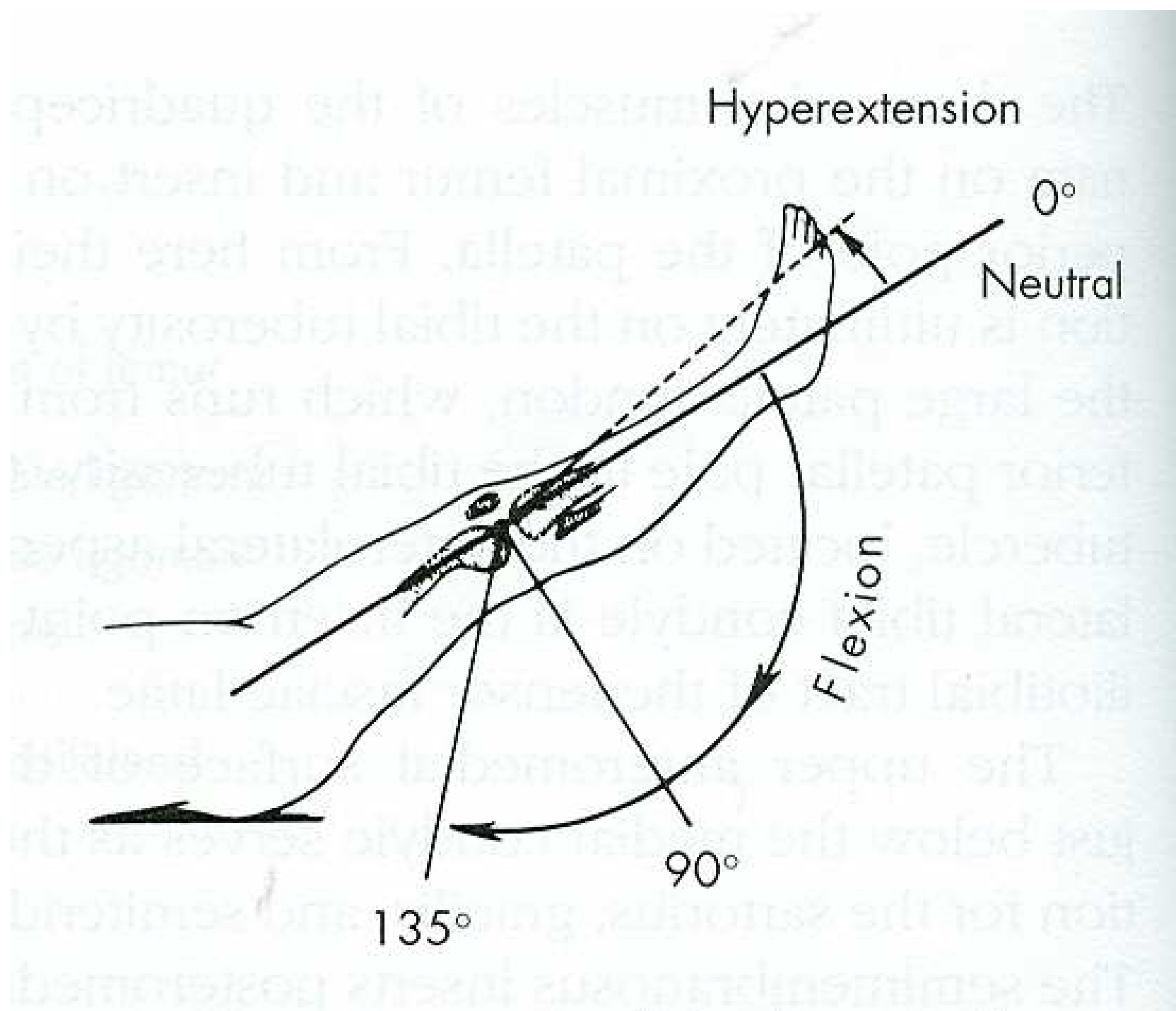
POHYBY KOLENNÍHO KLOUBU

FLEXE

EXTENZE

ZEVNÍ ROTACE

VNITŘNÍ ROTACE



FLEXO

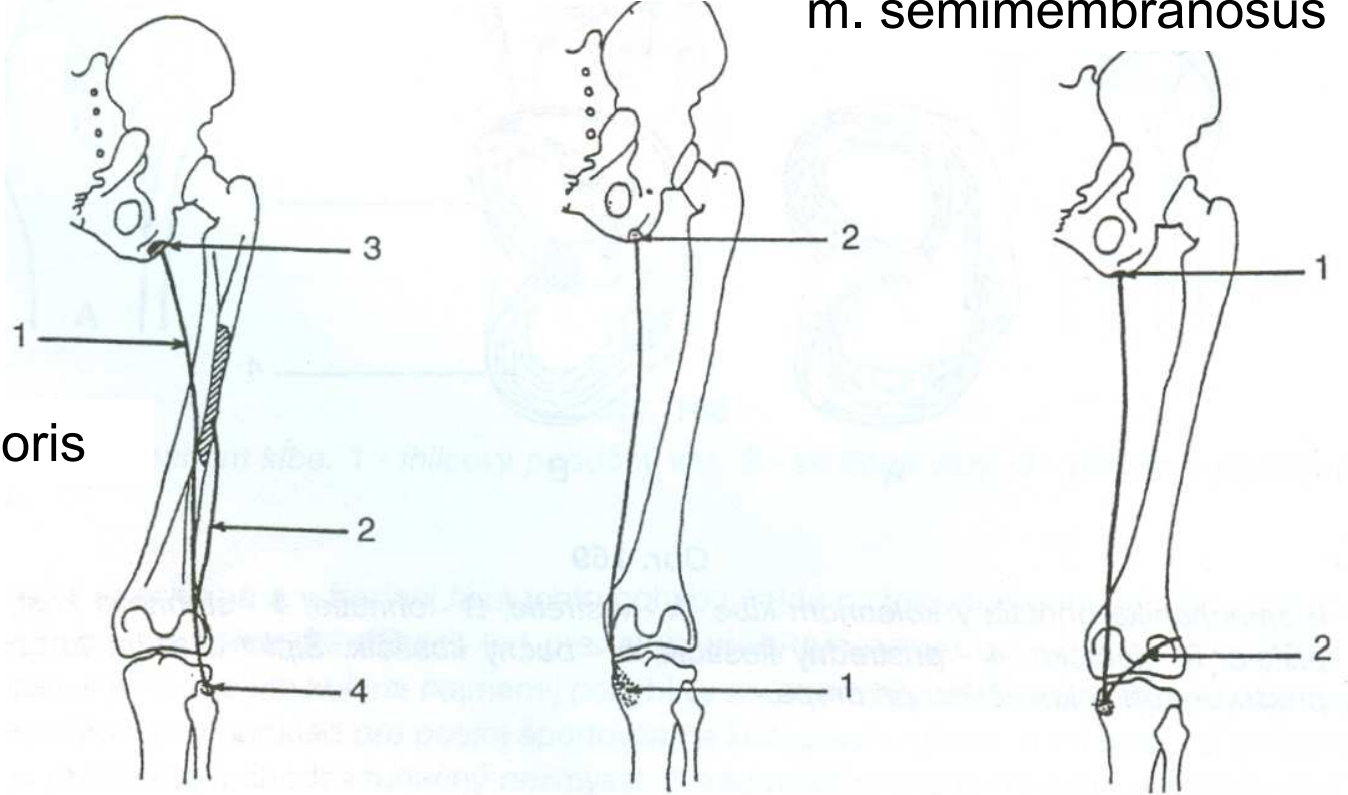
- 140°

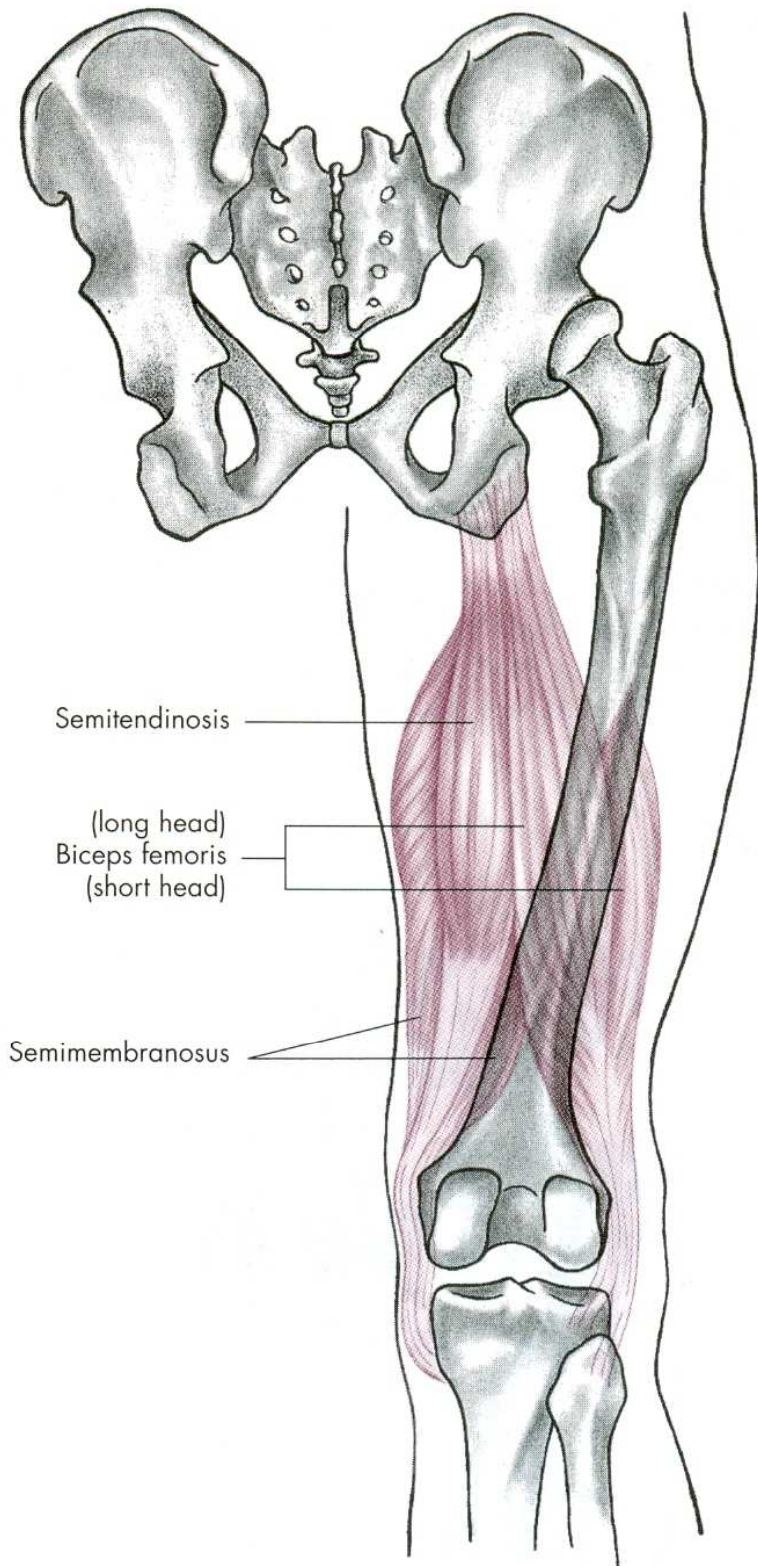
0°

m. semitendinosus

m. semimembranosus

m. biceps femoris

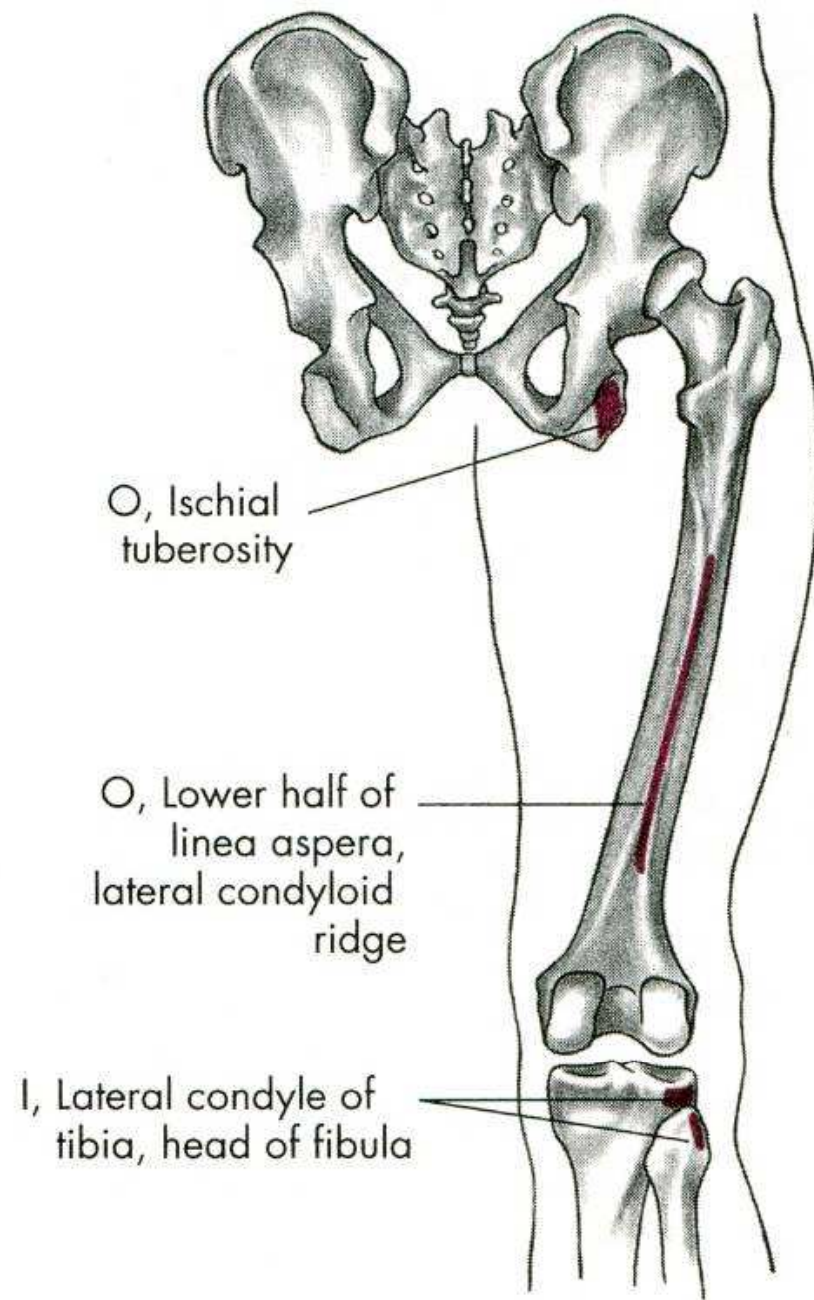
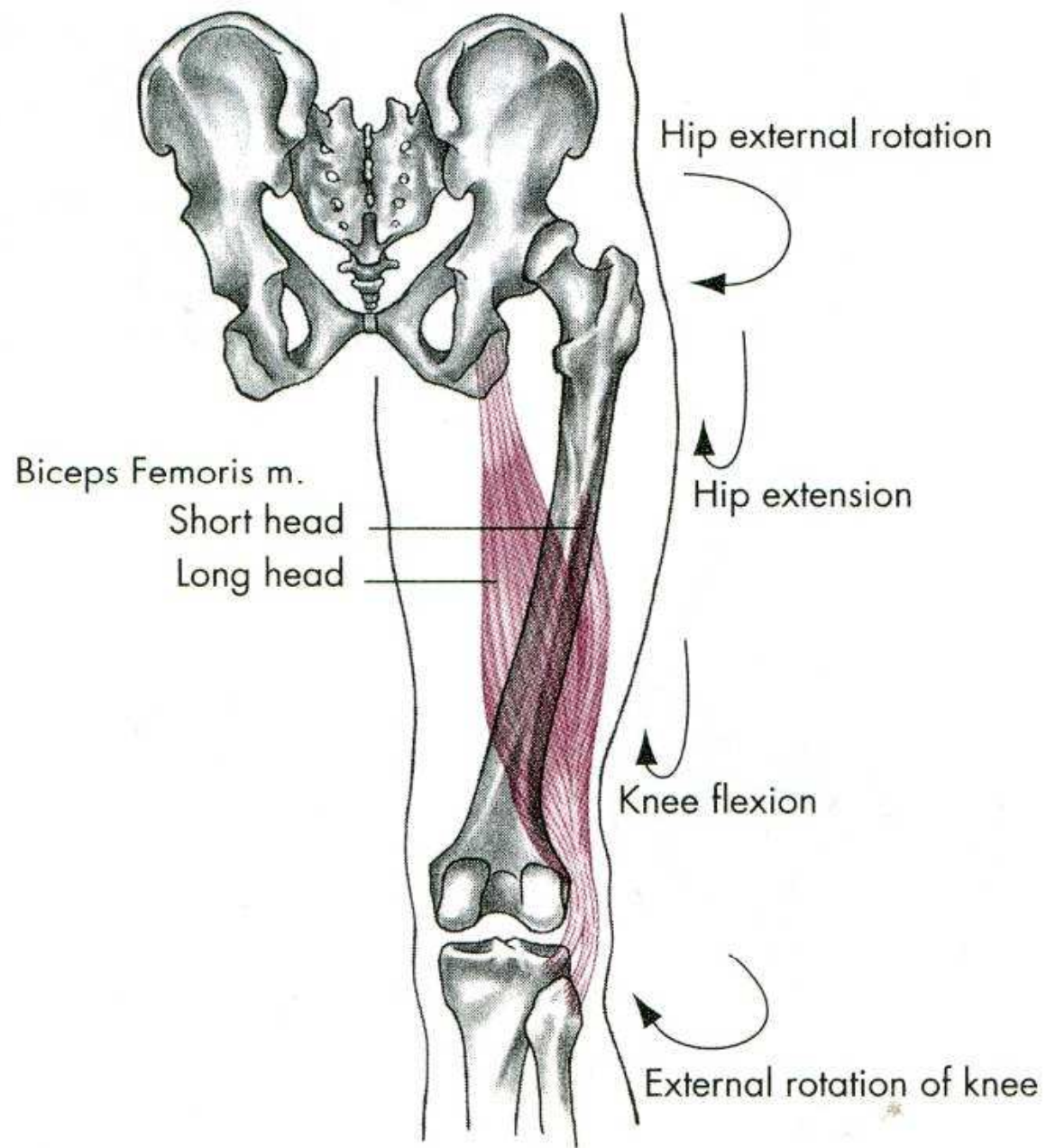


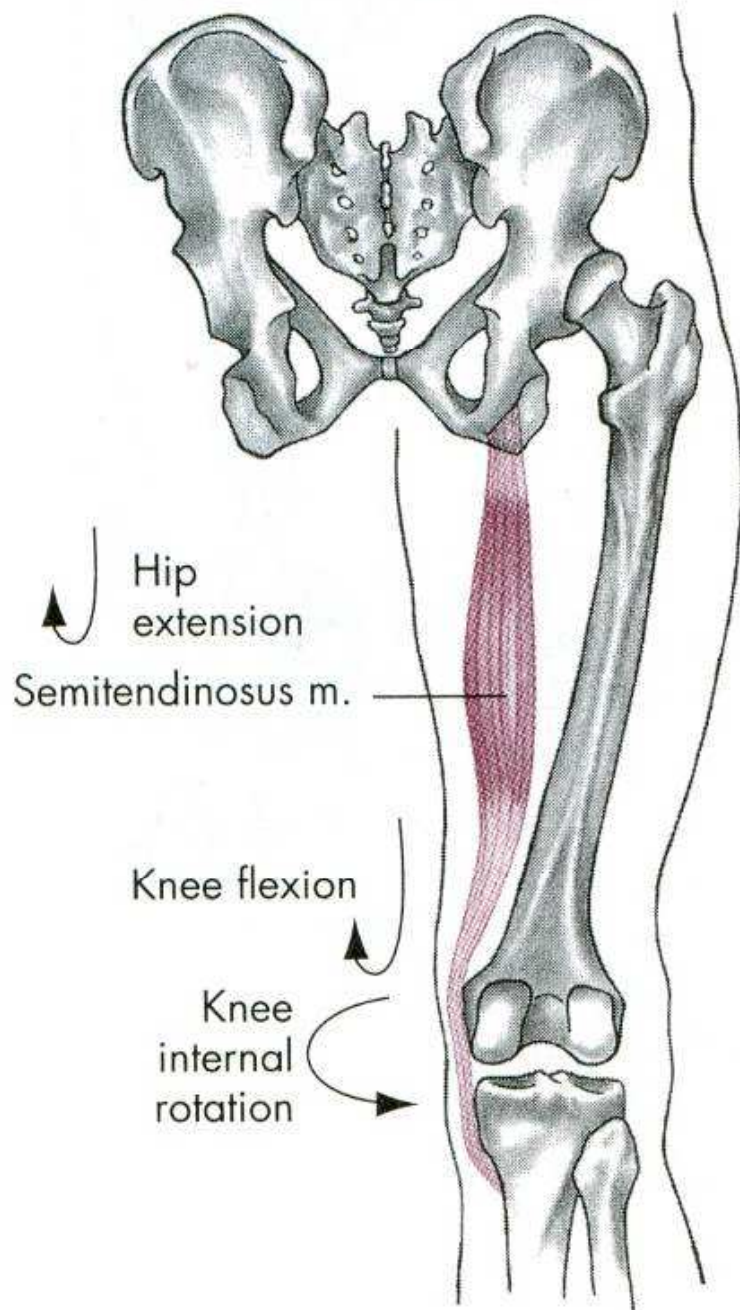


Semitendinosus

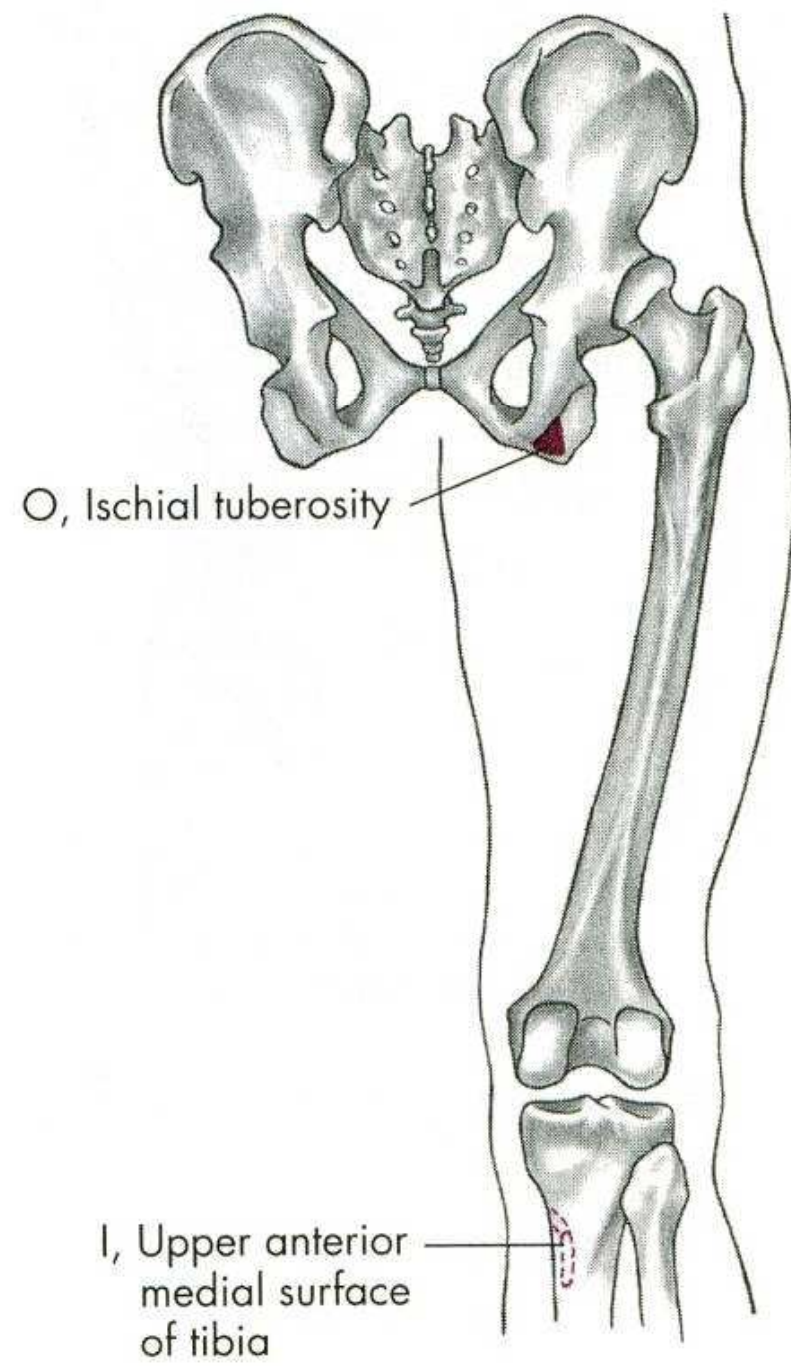
(long head)
Biceps femoris
(short head)

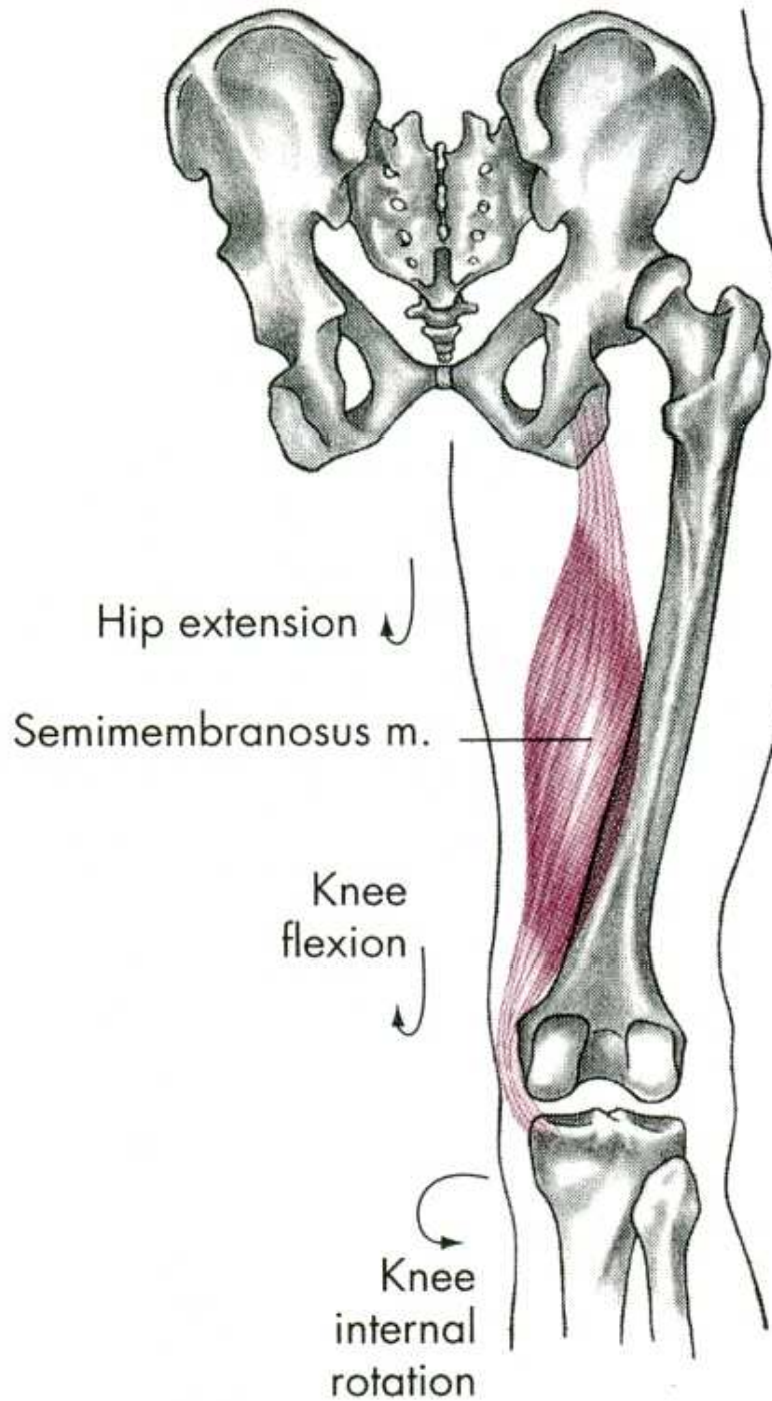
Semimembranosus



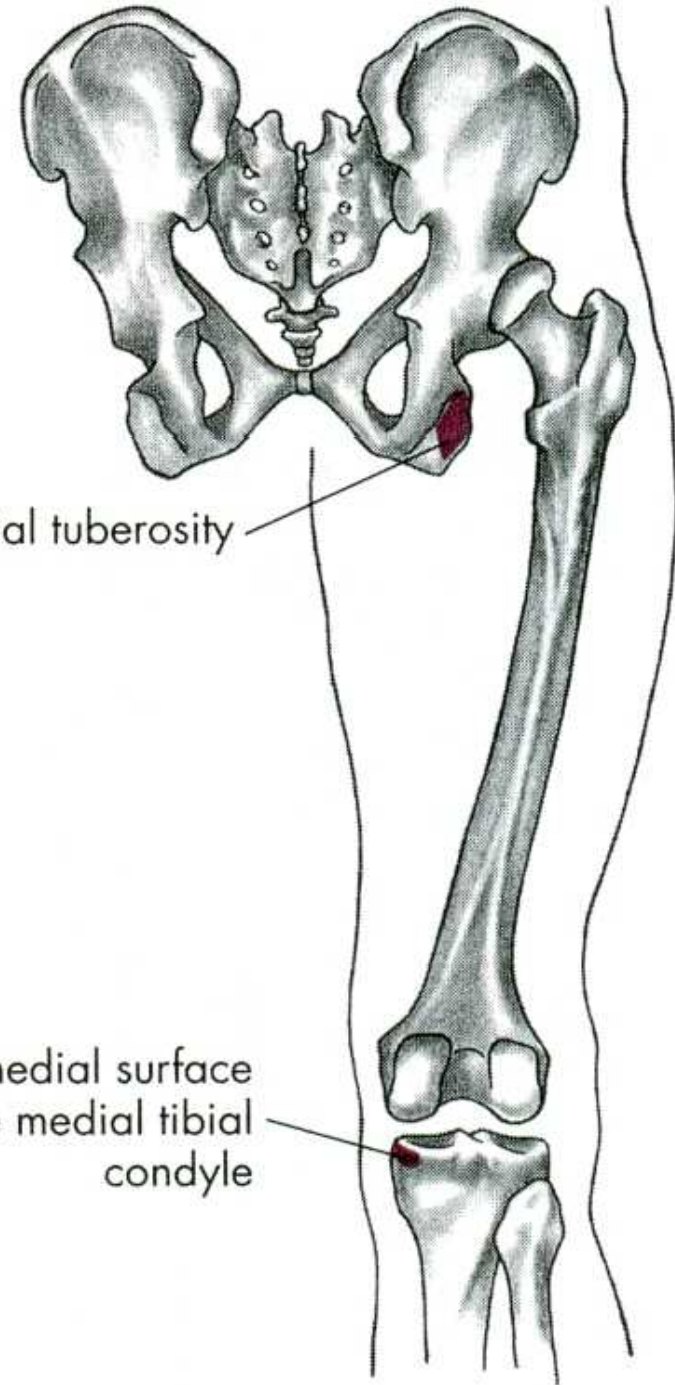


←
Hip internal rotation



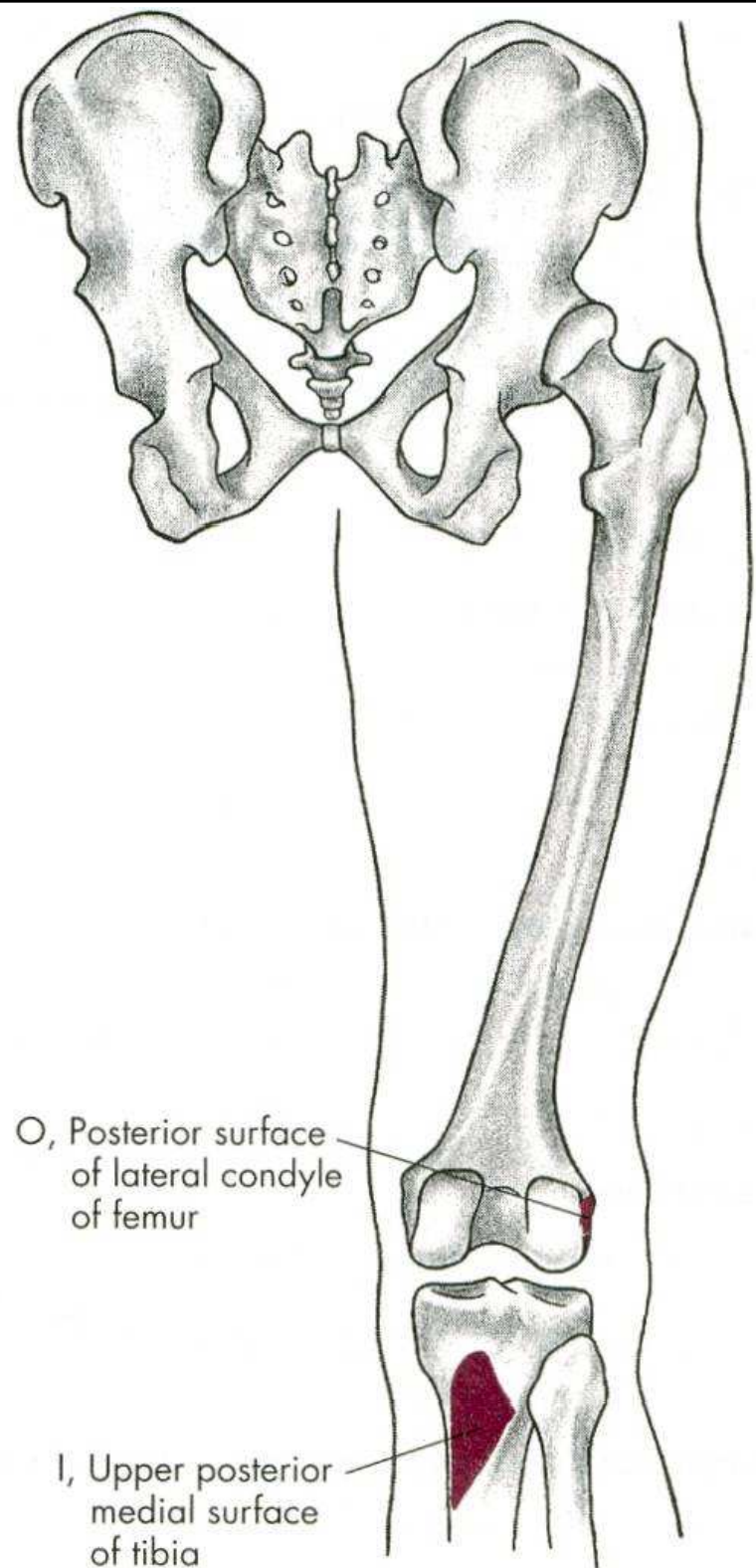
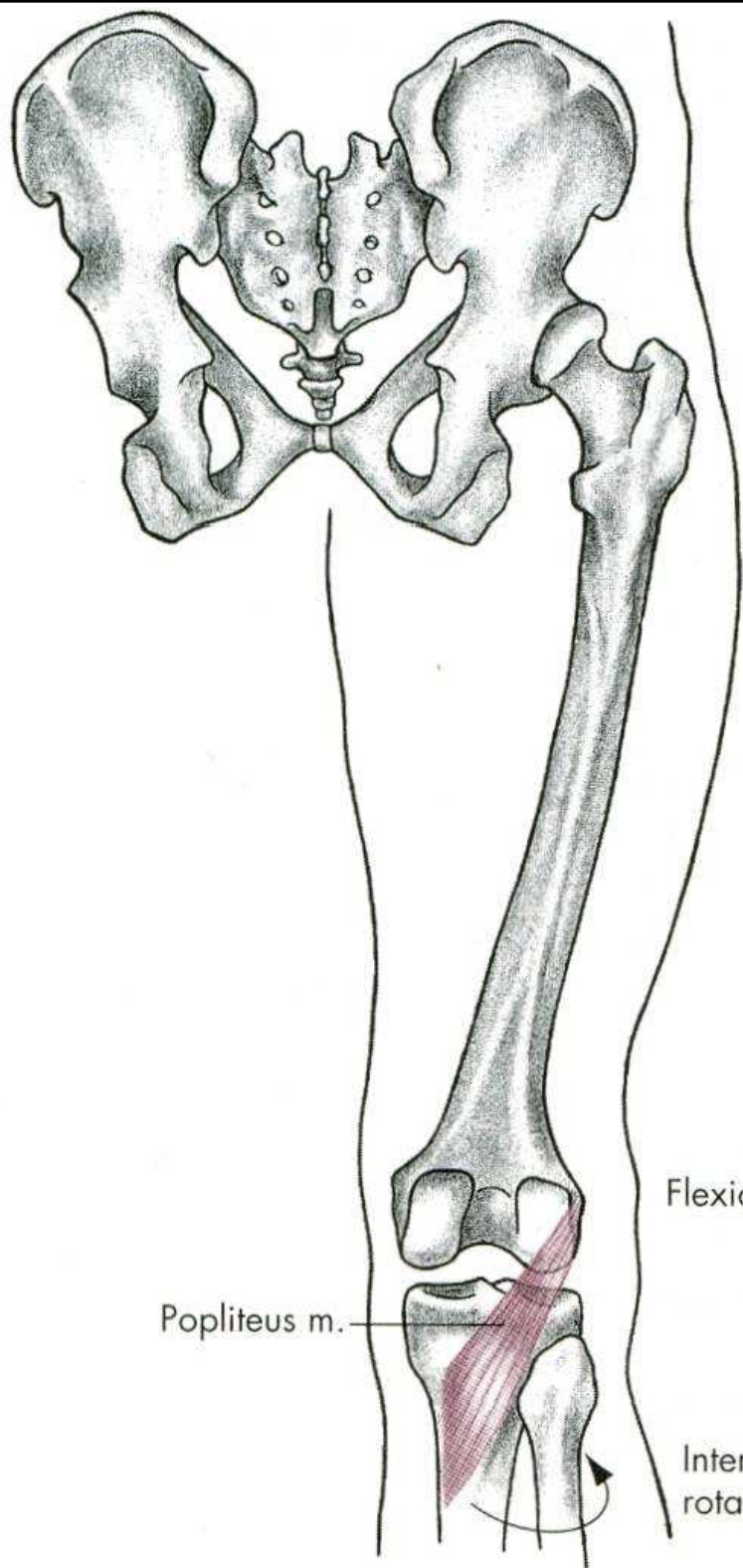


Hip internal rotation



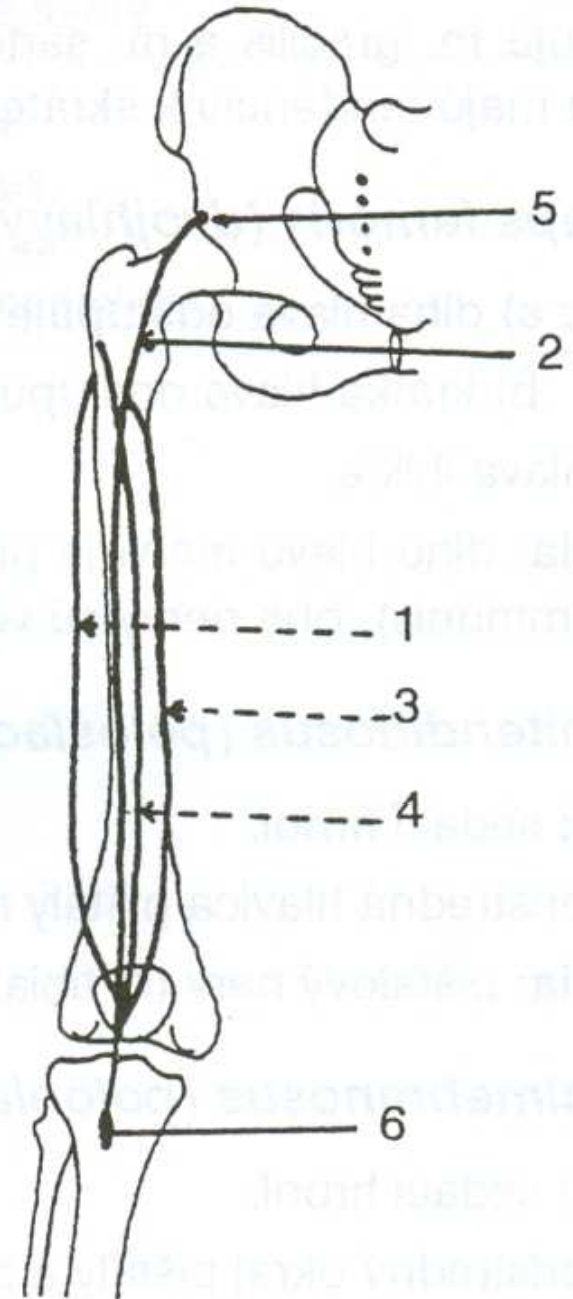
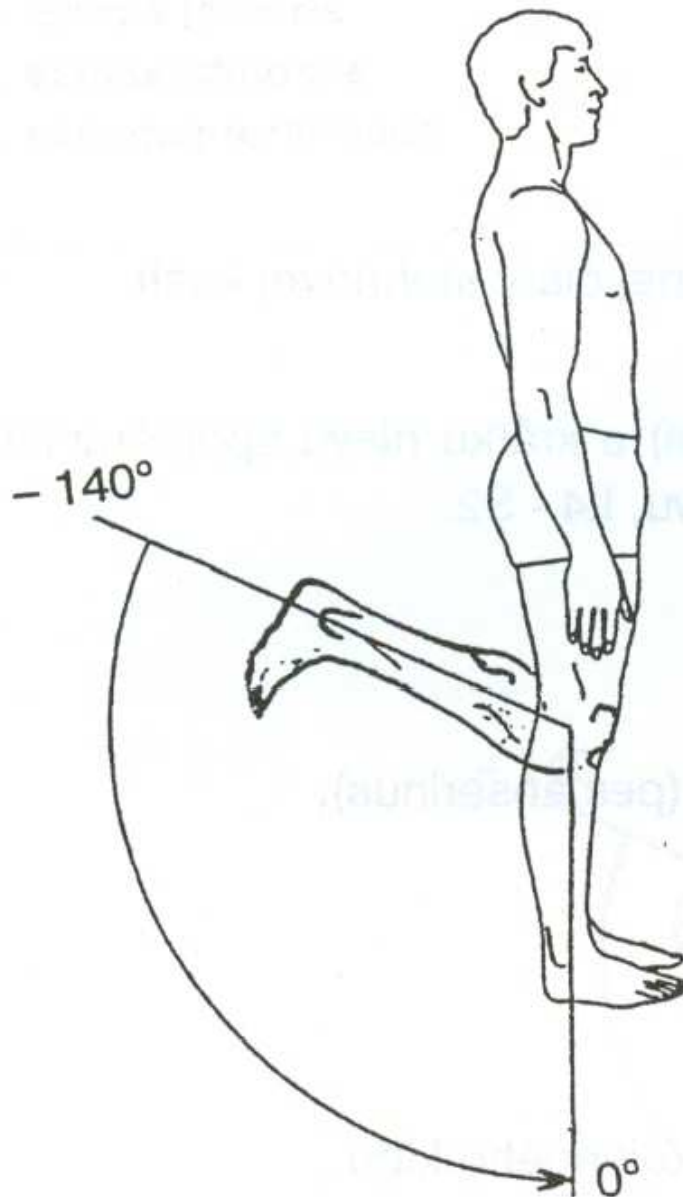
O, Ischial tuberosity

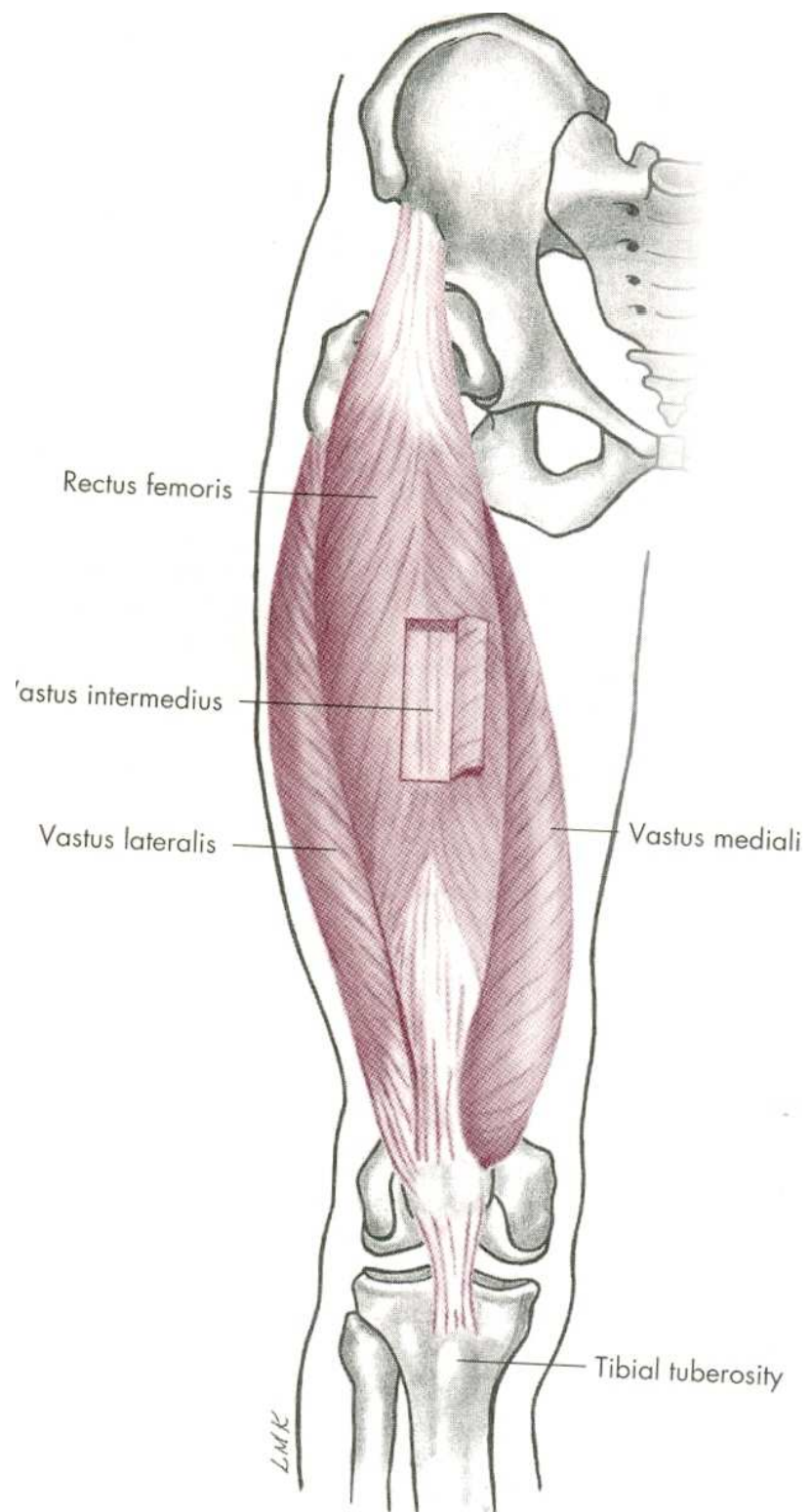
I, Posteromedial surface of the medial tibial condyle

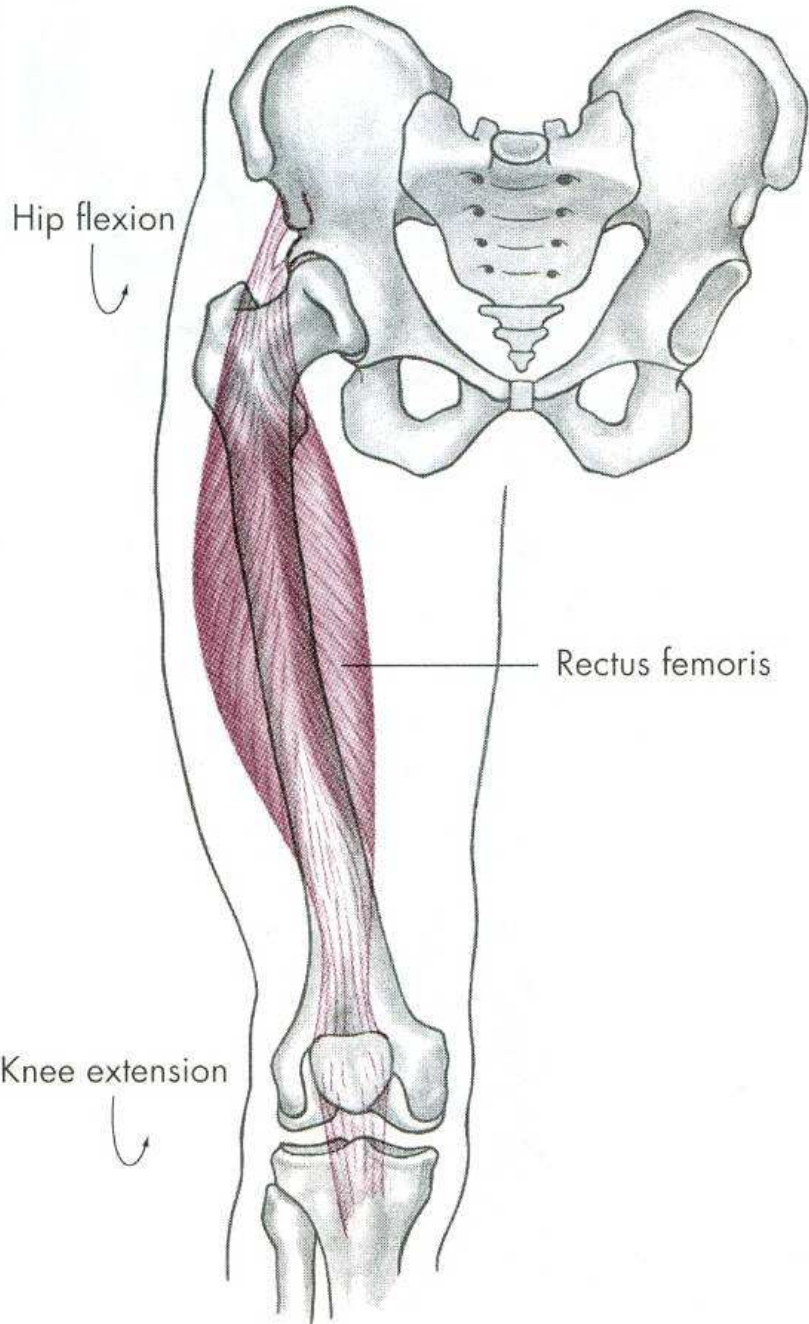


EXTENZE

m. quadriceps femoris

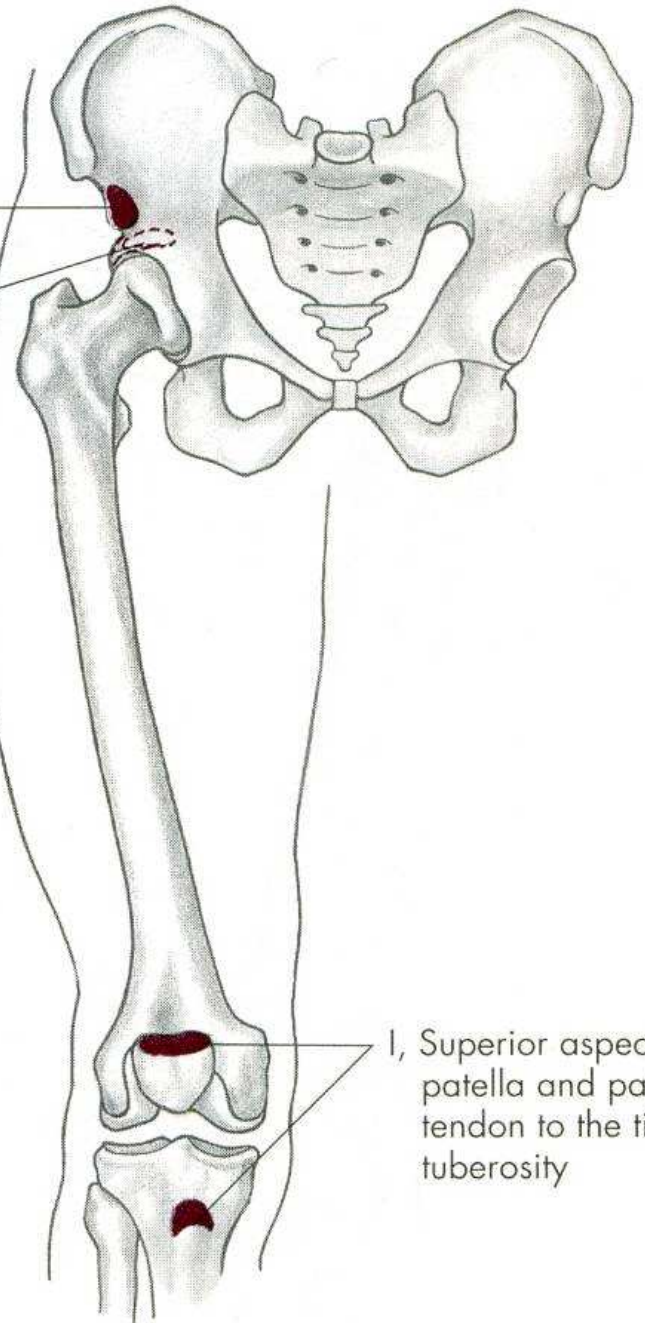


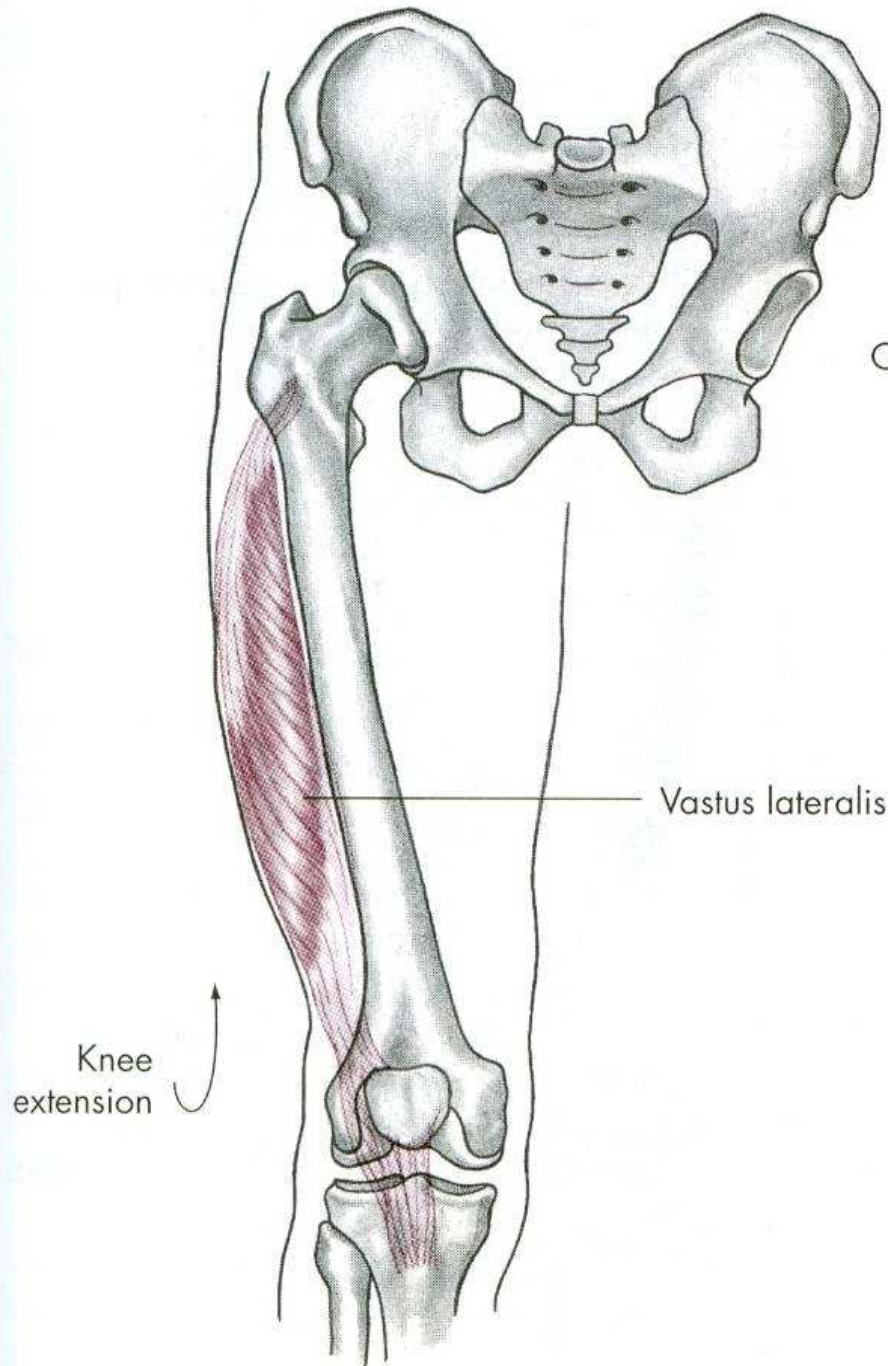




O, Anterior inferior iliac spine

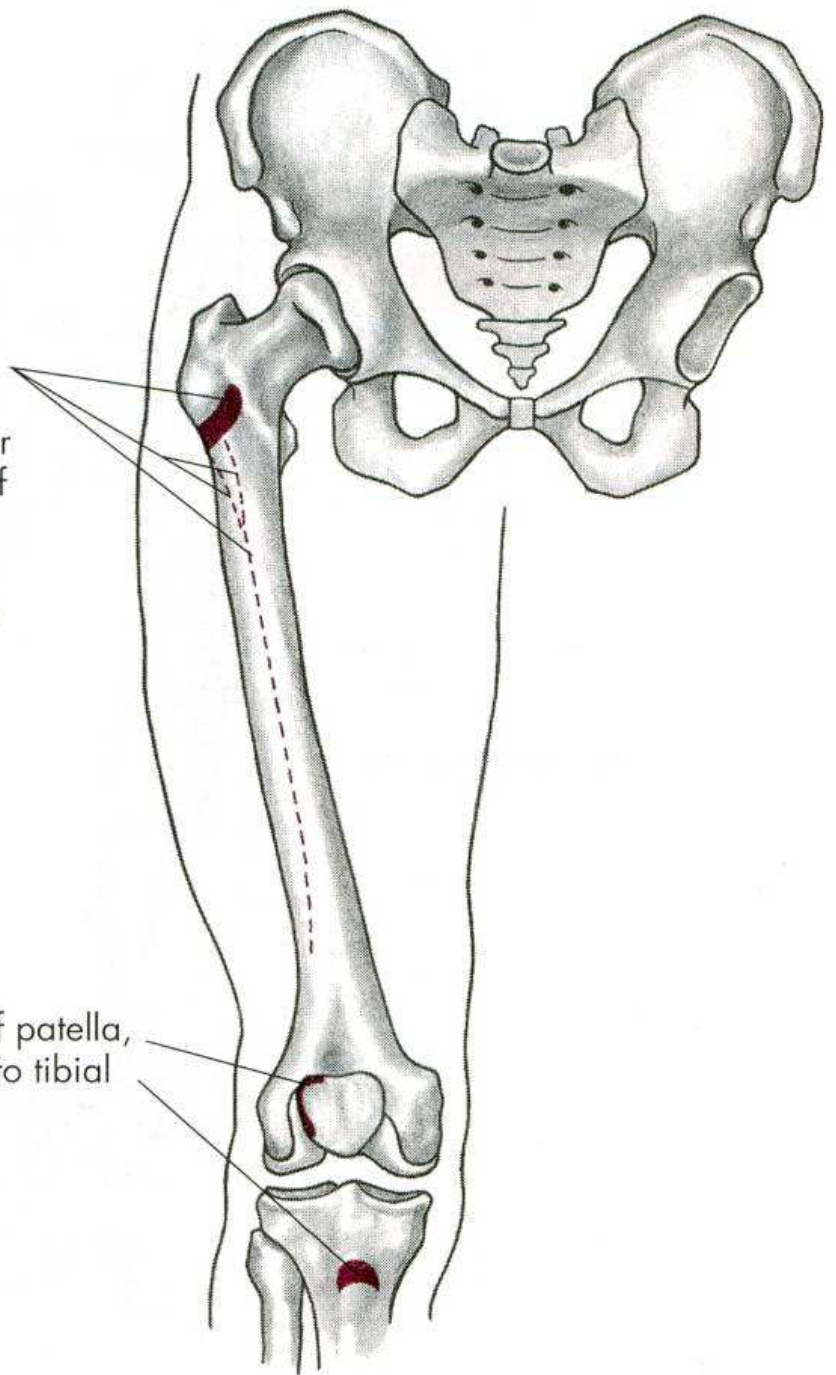
O, Groove (posterior) above the acetabulum

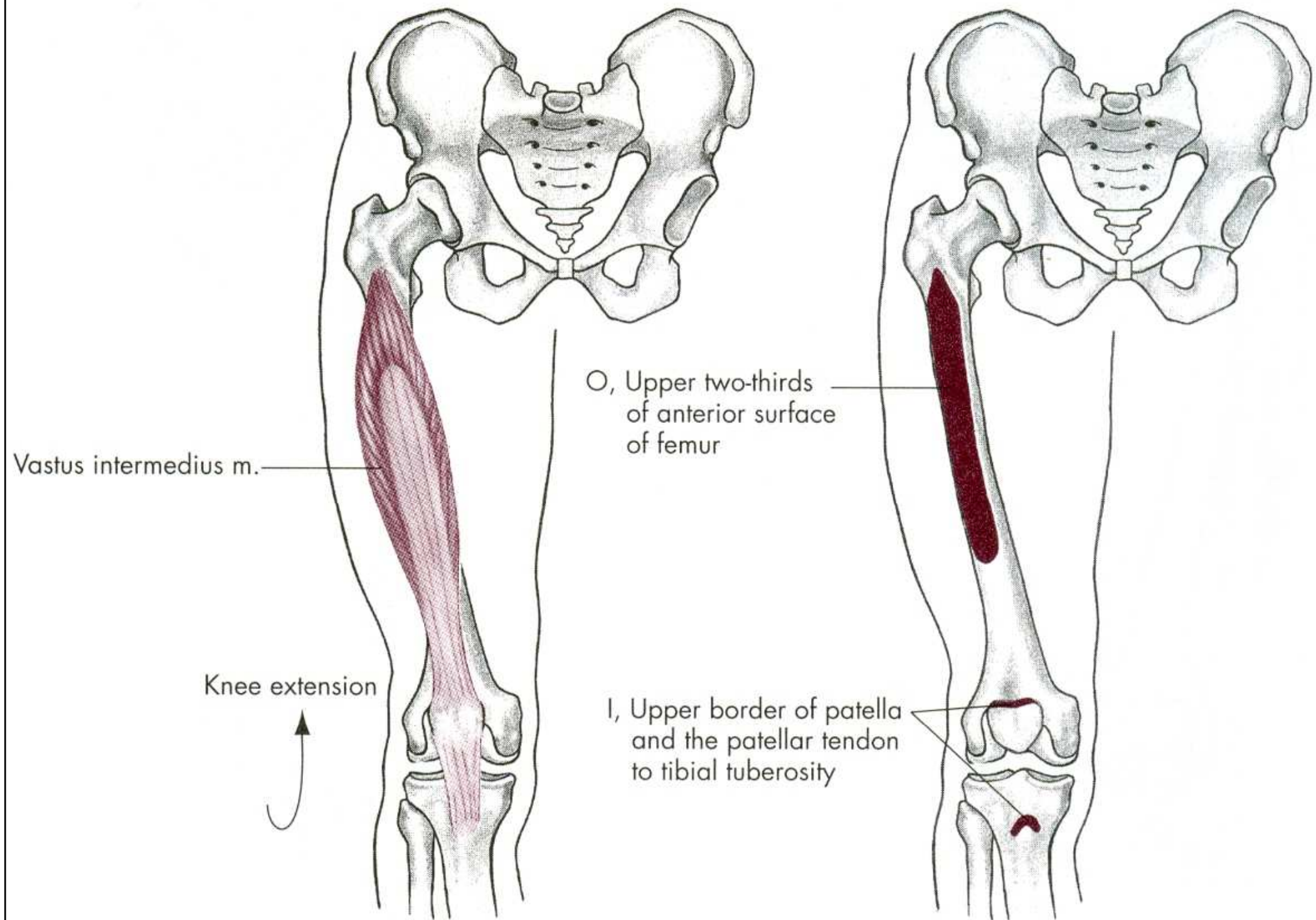


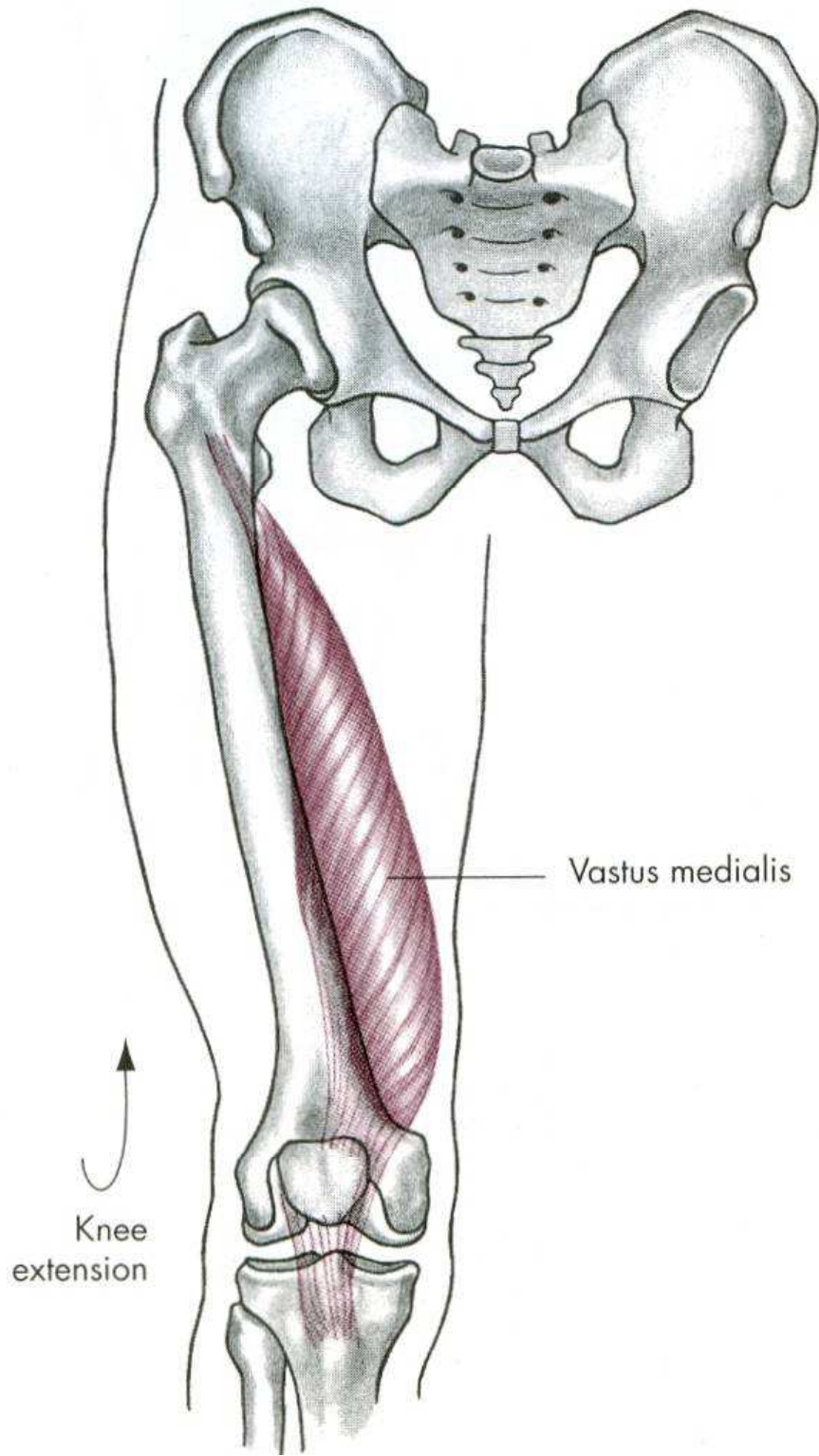


O, Intertrochanteric line, anterior and inferior borders of the greater trochanter, upper half of the linea aspera and the entire lateral intermuscular septum

I, Lateral border of patella, patellar tendon to tibial tuberosity

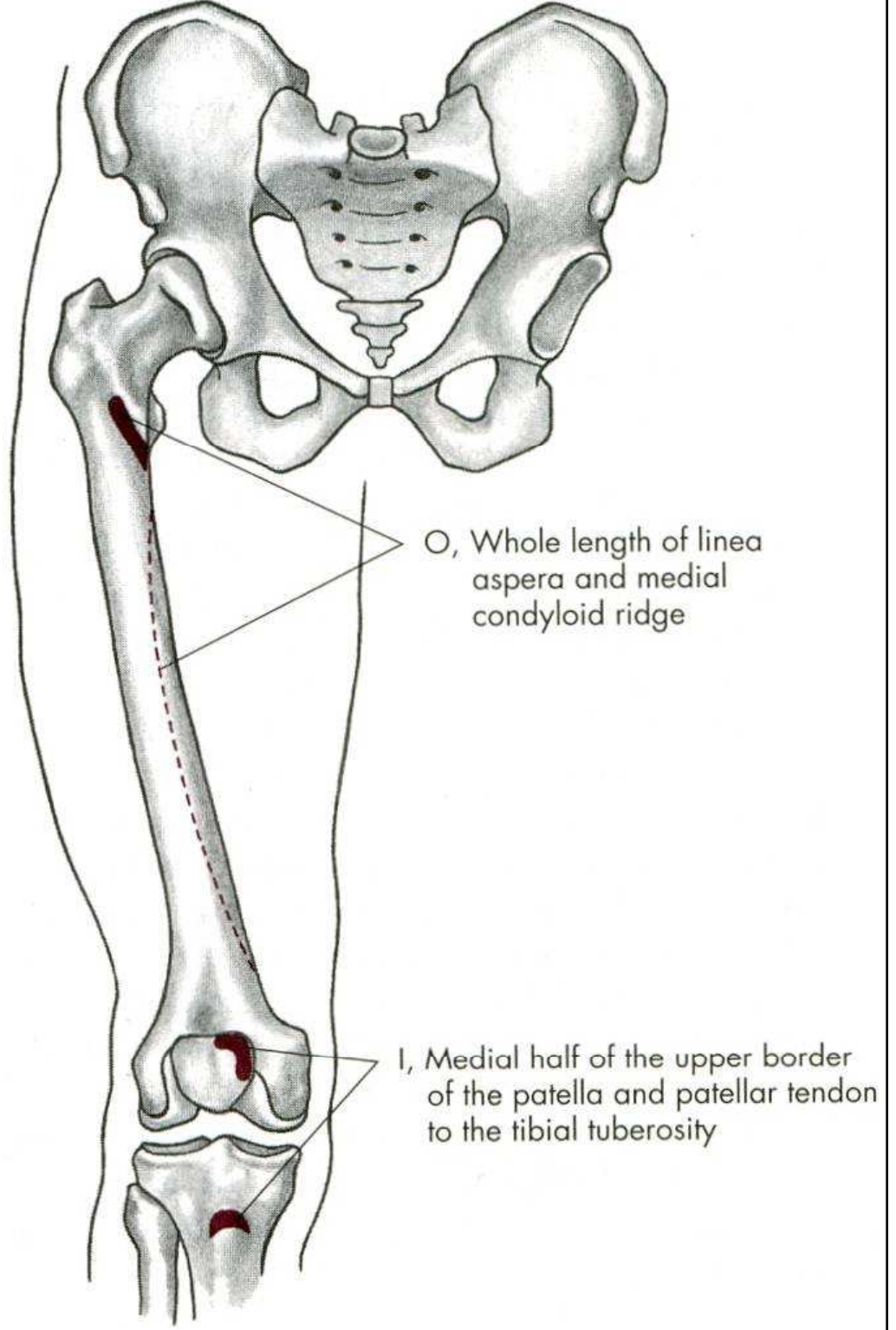






Vastus medialis

Knee extension



O, Whole length of linea aspera and medial condyloid ridge

I, Medial half of the upper border of the patella and patellar tendon to the tibial tuberosity

FLEXE

m. biceps femoris – dvojhlavý sval stehenní

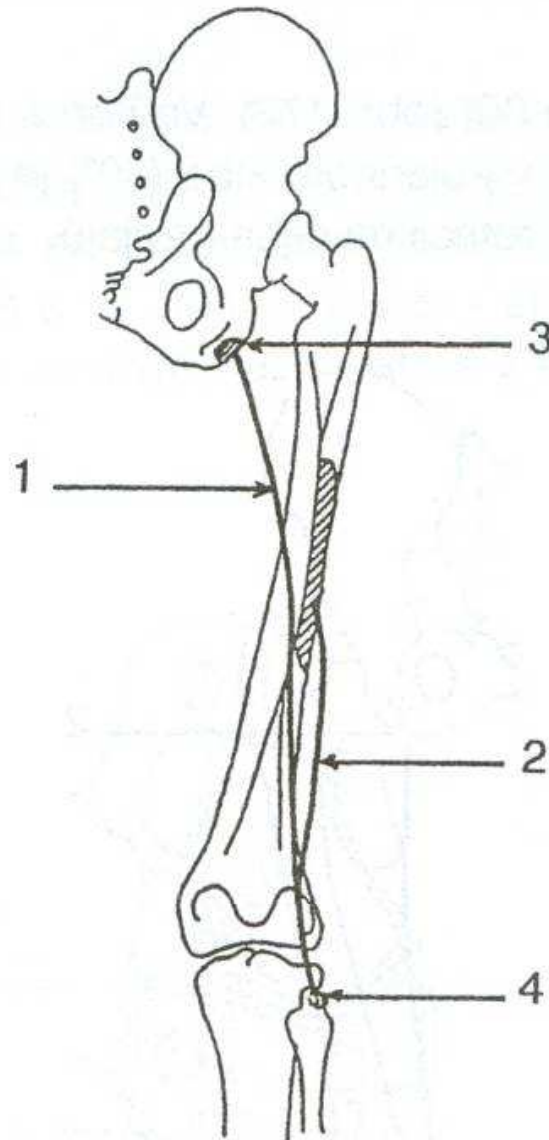
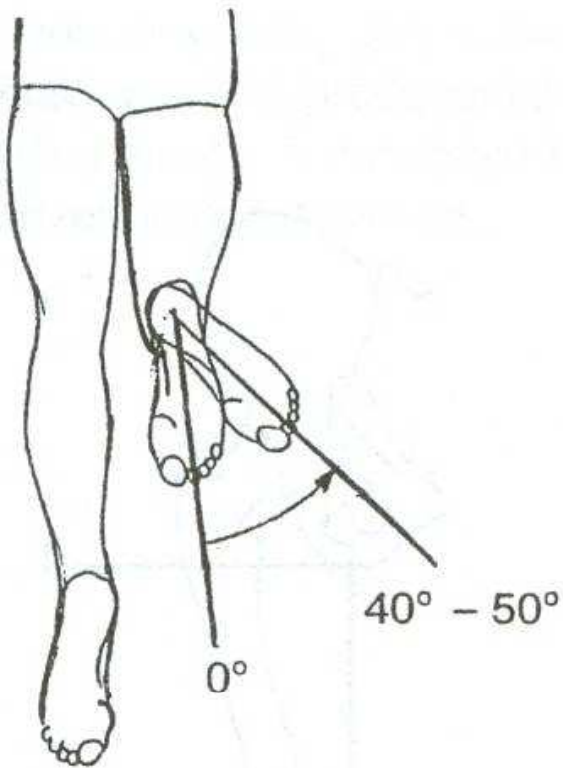
m. semitendinosus – sval pološlašitý

m. semimembranosus – sval poloblanitý

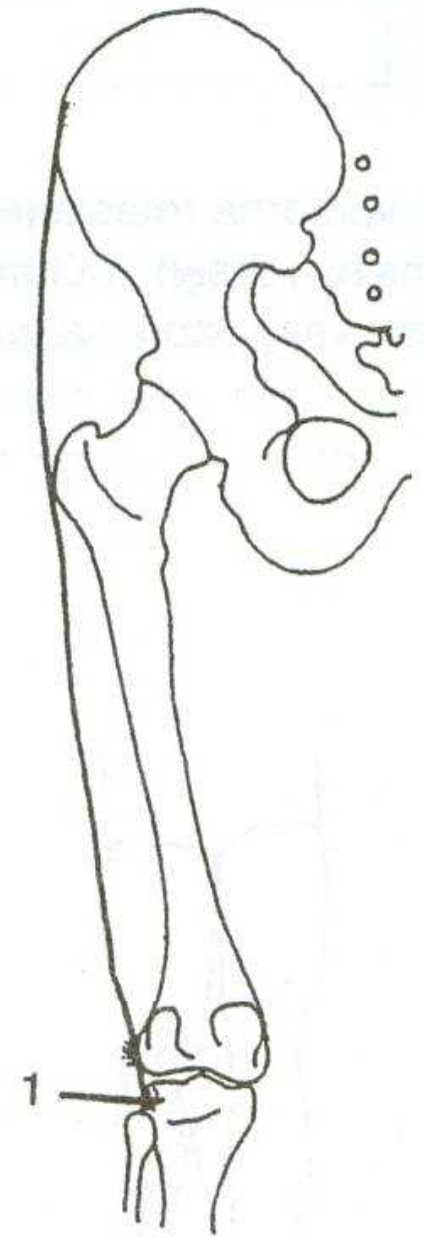
EXTENZE

m. quadriceps femoris – čtyřhlavý sval stehenní

ZEVNÍ ROTACE

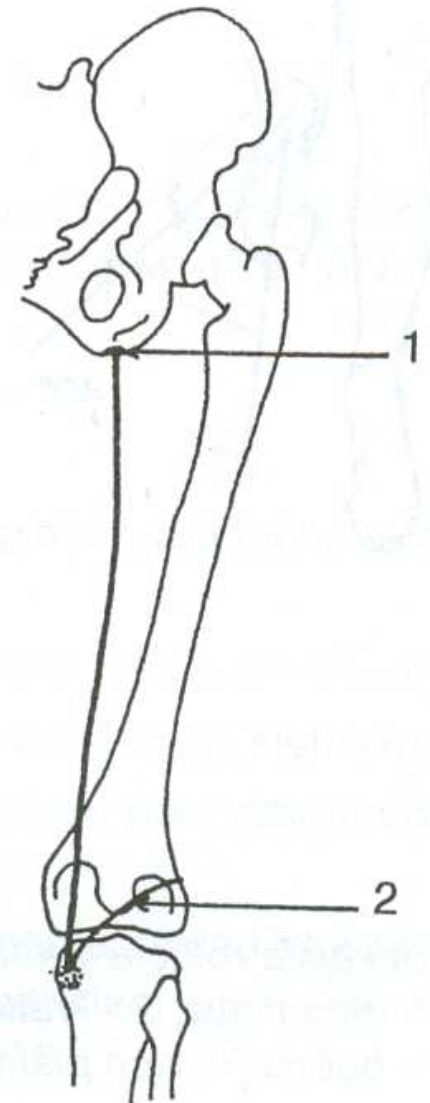
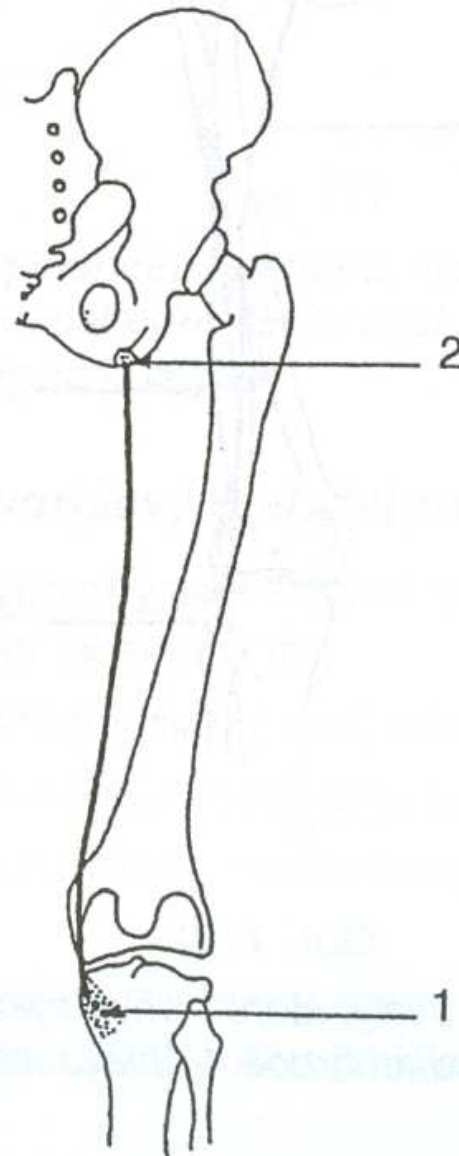
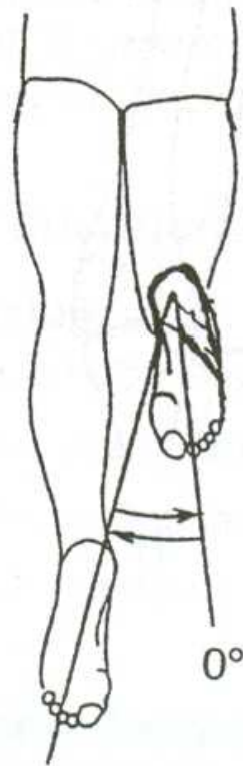


m. biceps femoris



m. tensor fasciae latae

VNITŘNÍ ROTACE



m. semitendinosus

m. semimembranosus

ZEVNÍ ROTACE

m. biceps femoris – dvojhlavý sval stehenní

m. tensor fasciae latae –
napínač stehenní povázky

VNITŘNÍ ROTACE

m. semitendinosus – sval pološlašitý

m. semimembranosus – sval poloblanitý

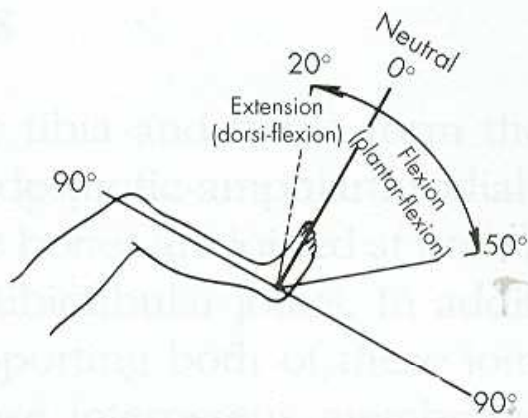
POHYBY HLEZENNÍHO KLOUBU

PLANTÁRNÍ FLEXE –
PROPnutí ŠPIČEK

DORZÁLNÍ FLEXE - FAJFKY

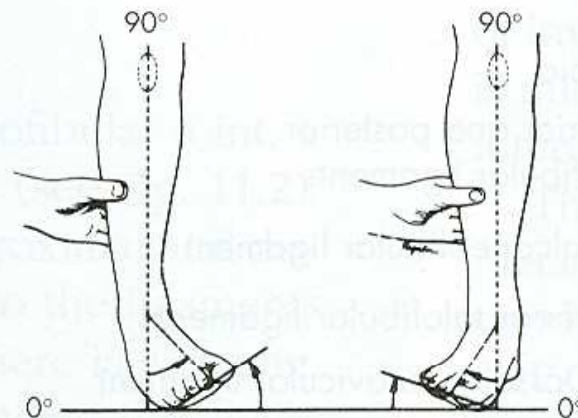
PRONACE

SUPINACE



Ankle joint

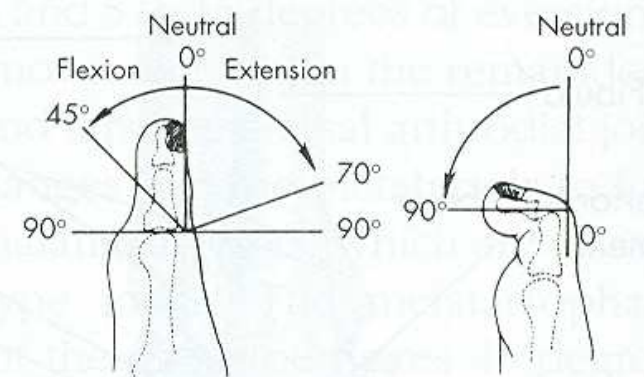
A



Inversion

Eversion

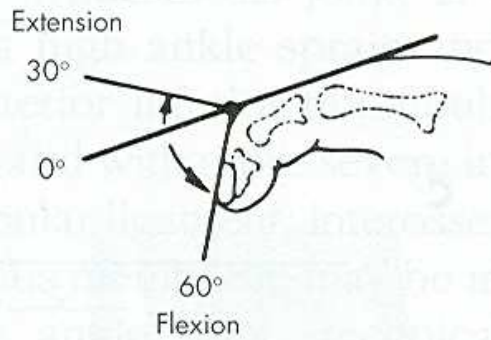
B



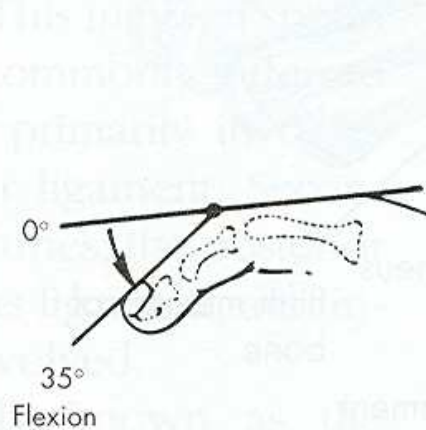
Metatarsophalangeal joint

Interphalangeal joint

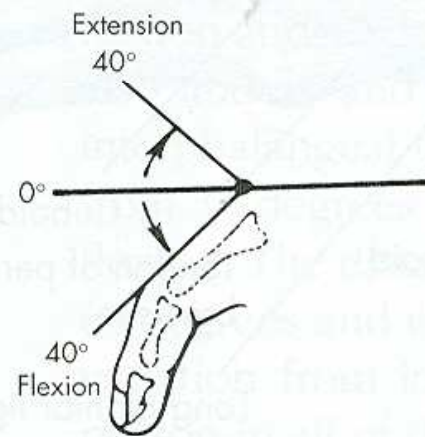
C



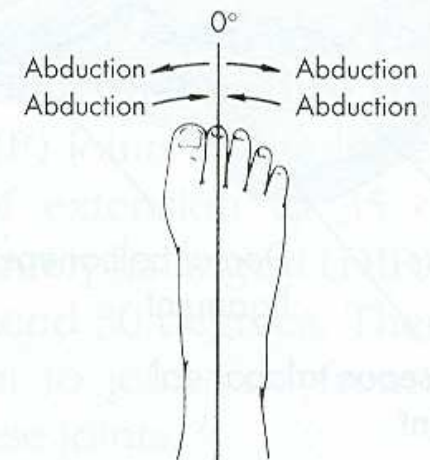
Distal interphalangeal joint



Proximal interphalangeal joint




Metatarsophalangeal joint



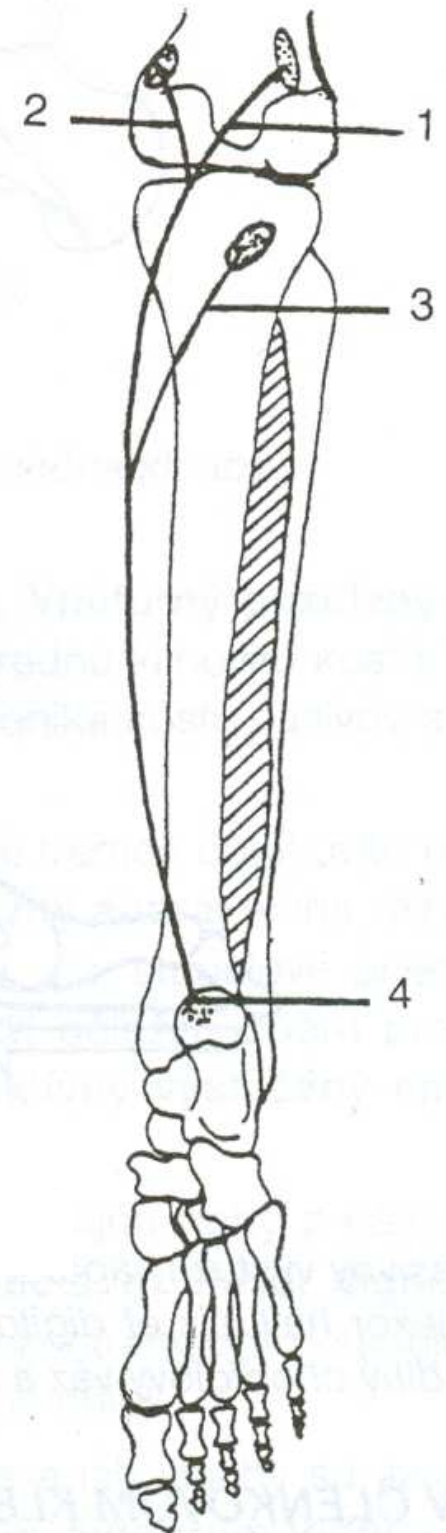
Toe spread

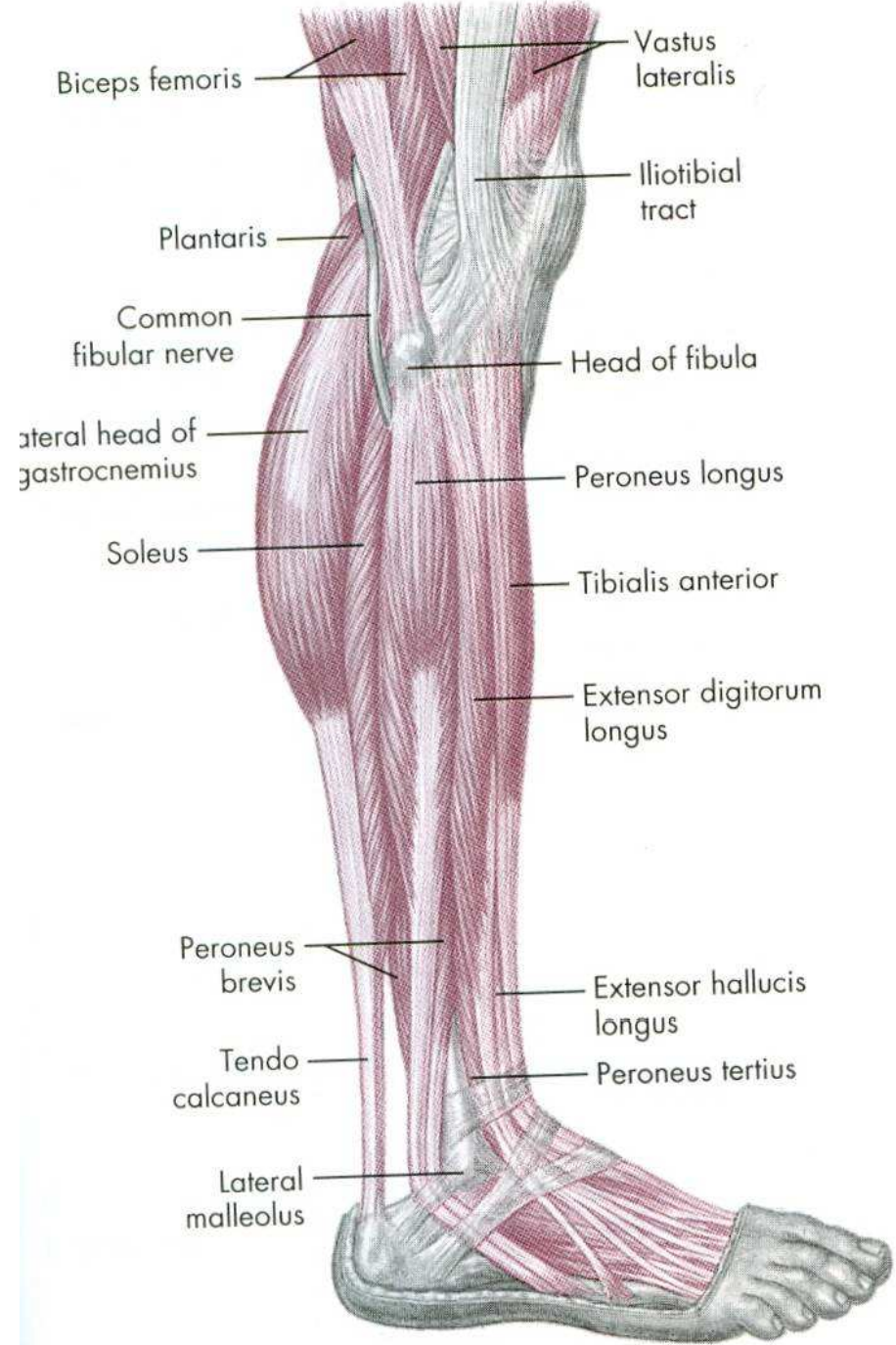
D

PLANTÁRNÍ FLEXE – PROPNUŤÍ ŠPIČEK

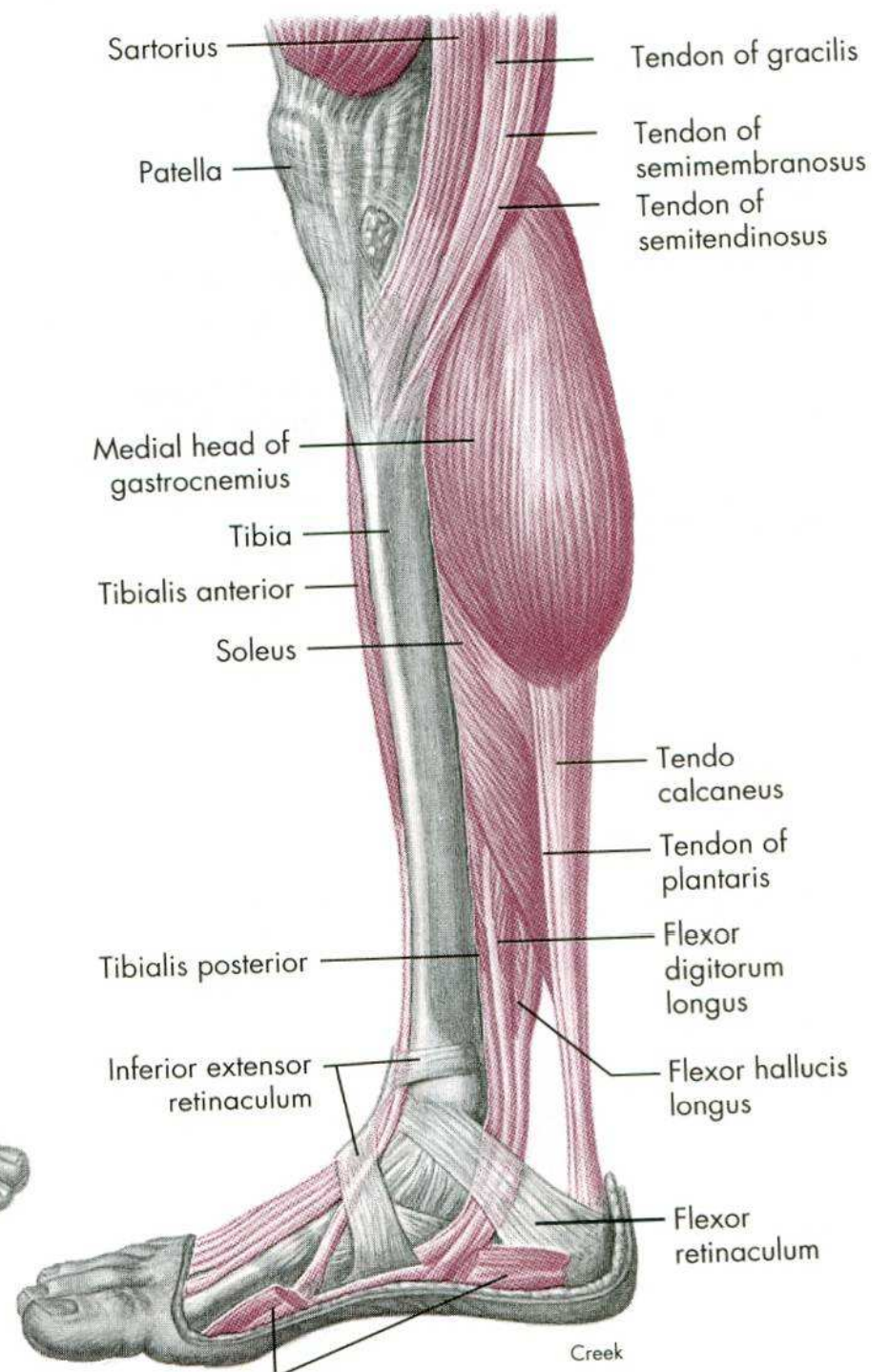


m. triceps surae



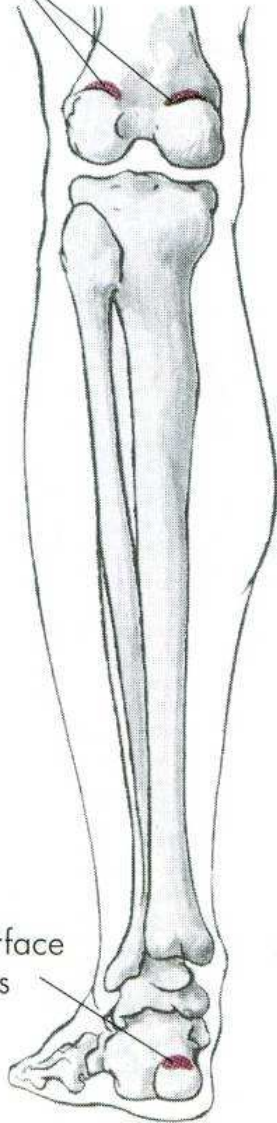


A



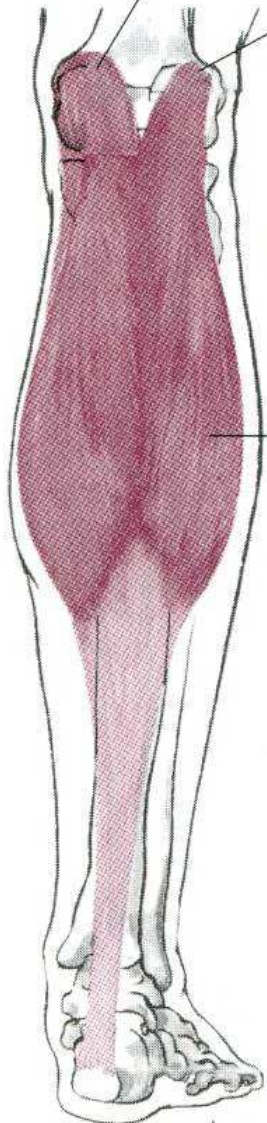
Creek

O, Posterior surfaces of two condyles of femur



I, Posterior surface of calcaneus

Medial head
Lateral head



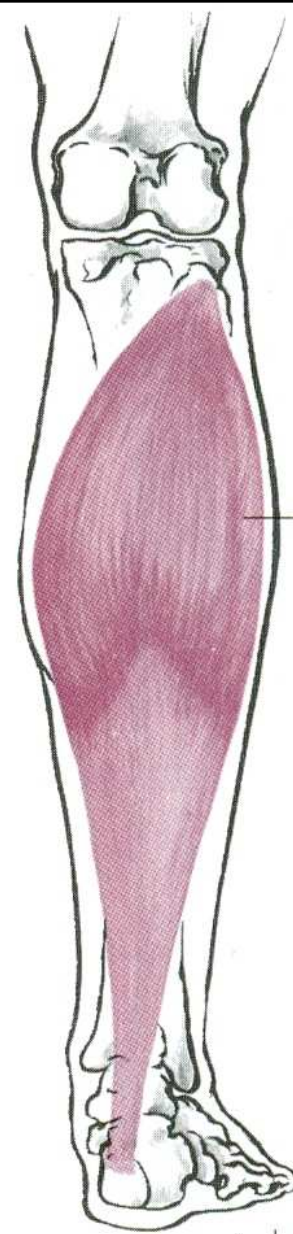

Gastrocnemius m

Knee flexion

Plantar flexion

Proximal two-thirds of posterior surfaces of tibia and fibula

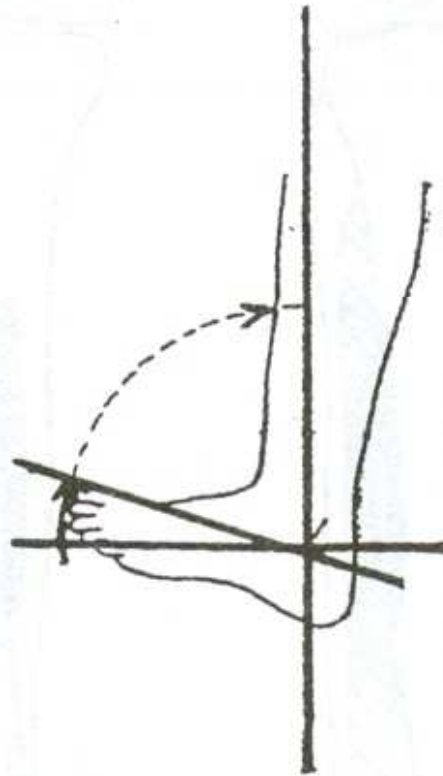
Posterior surface of calcaneus



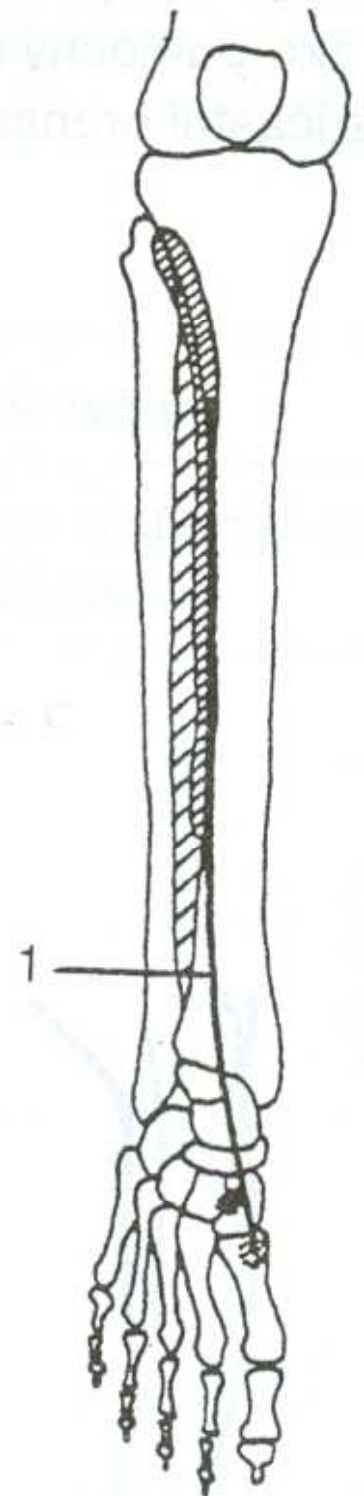
Soleus m.

Plantar flexion

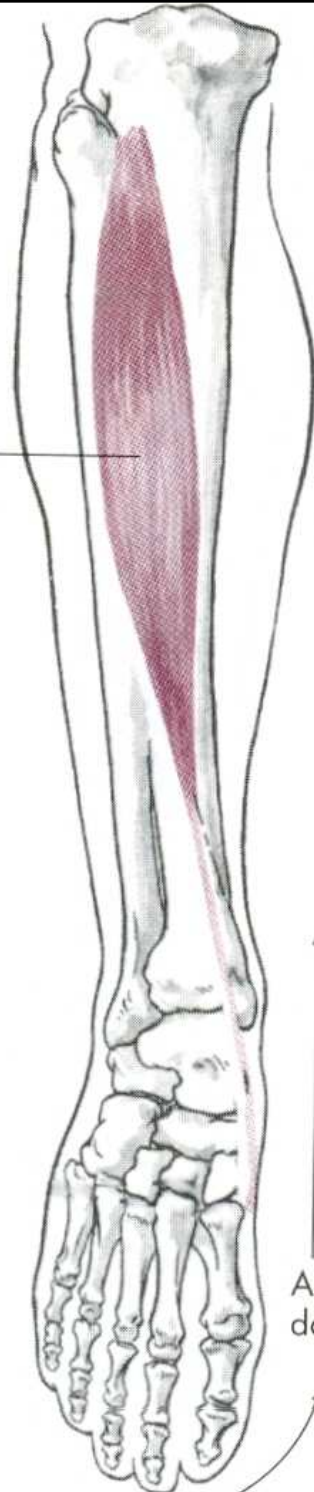
DORZÁLNÍ FLEXE - FAJFKY



m. tibialis anterior



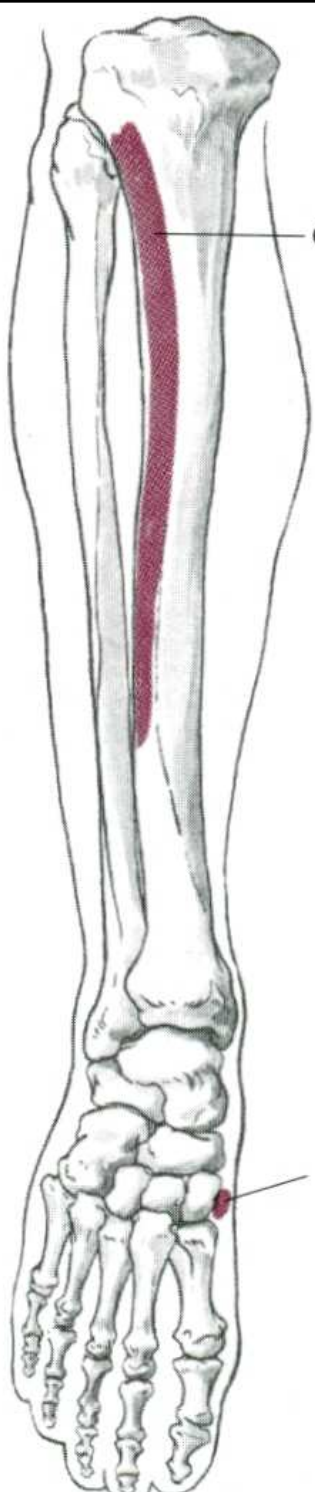
Tibialis anterior m.



Ankle dorsal flexion

Foot inversion

O, Upper two-thirds of lateral surface of tibia



I, Inner surface of medial cuneiform, base of the first metatarsal bones

PLANTÁRNÍ FLEXE

m. triceps surae – trojhlavý sval lýtkový

DORZÁLNÍ FLEXE

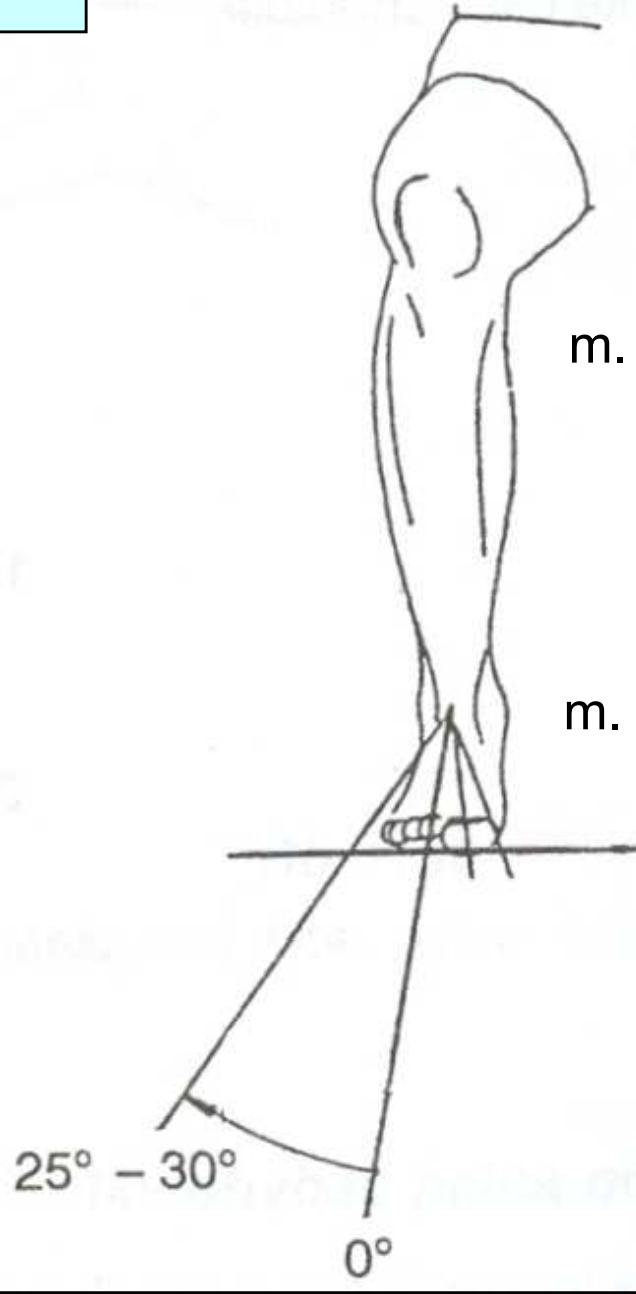
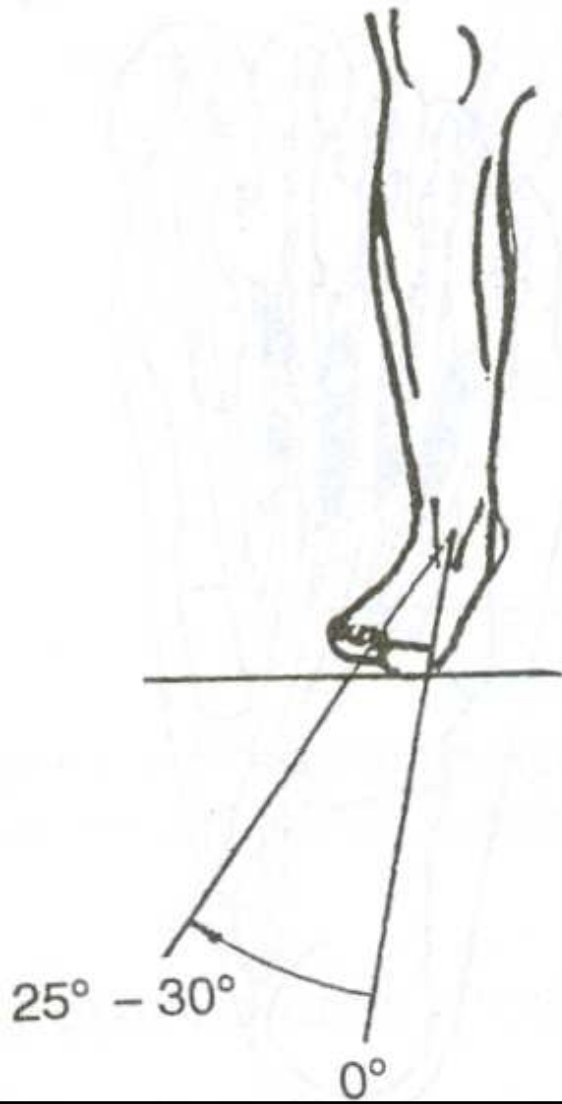
m. tibialis anterior – přední sval holenní

POHYBY DOLNÍHO KLOUBU ZÁNÁRTNÍHO

EVERZE

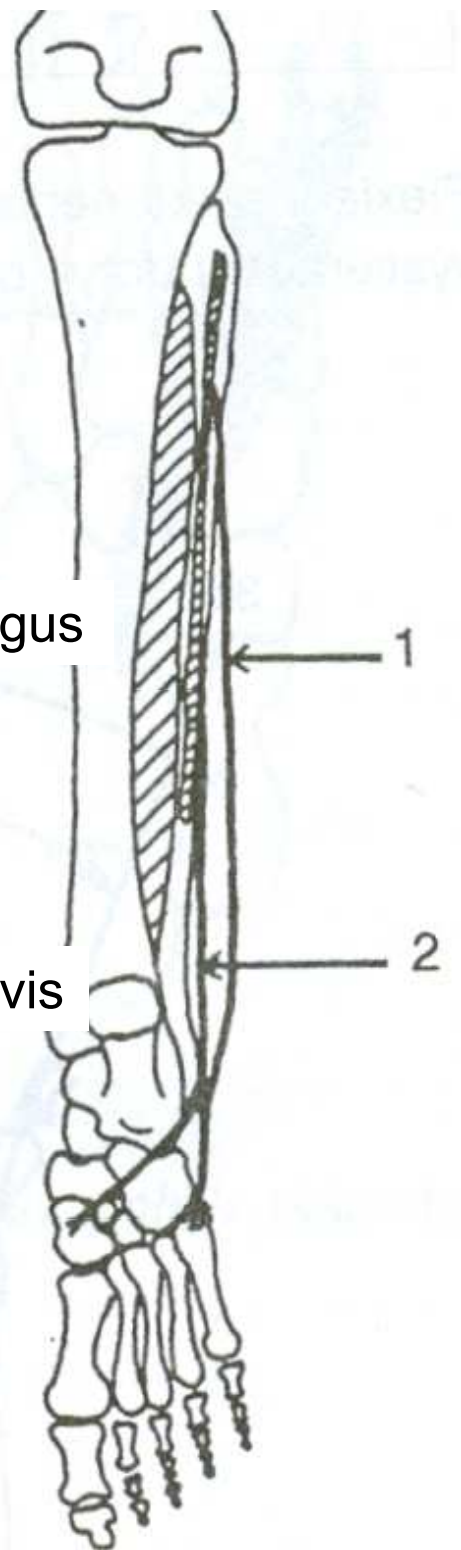
INVERSE

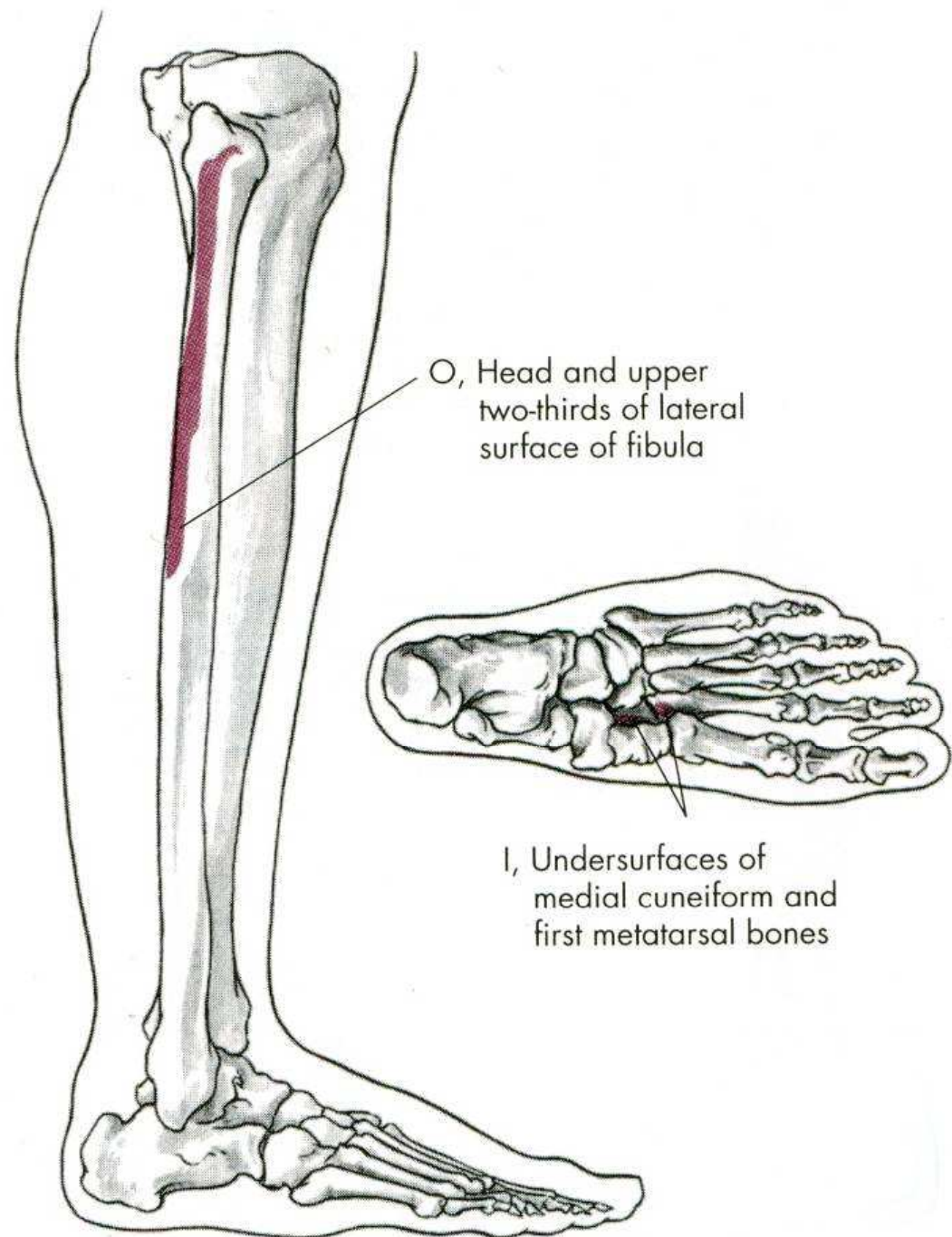
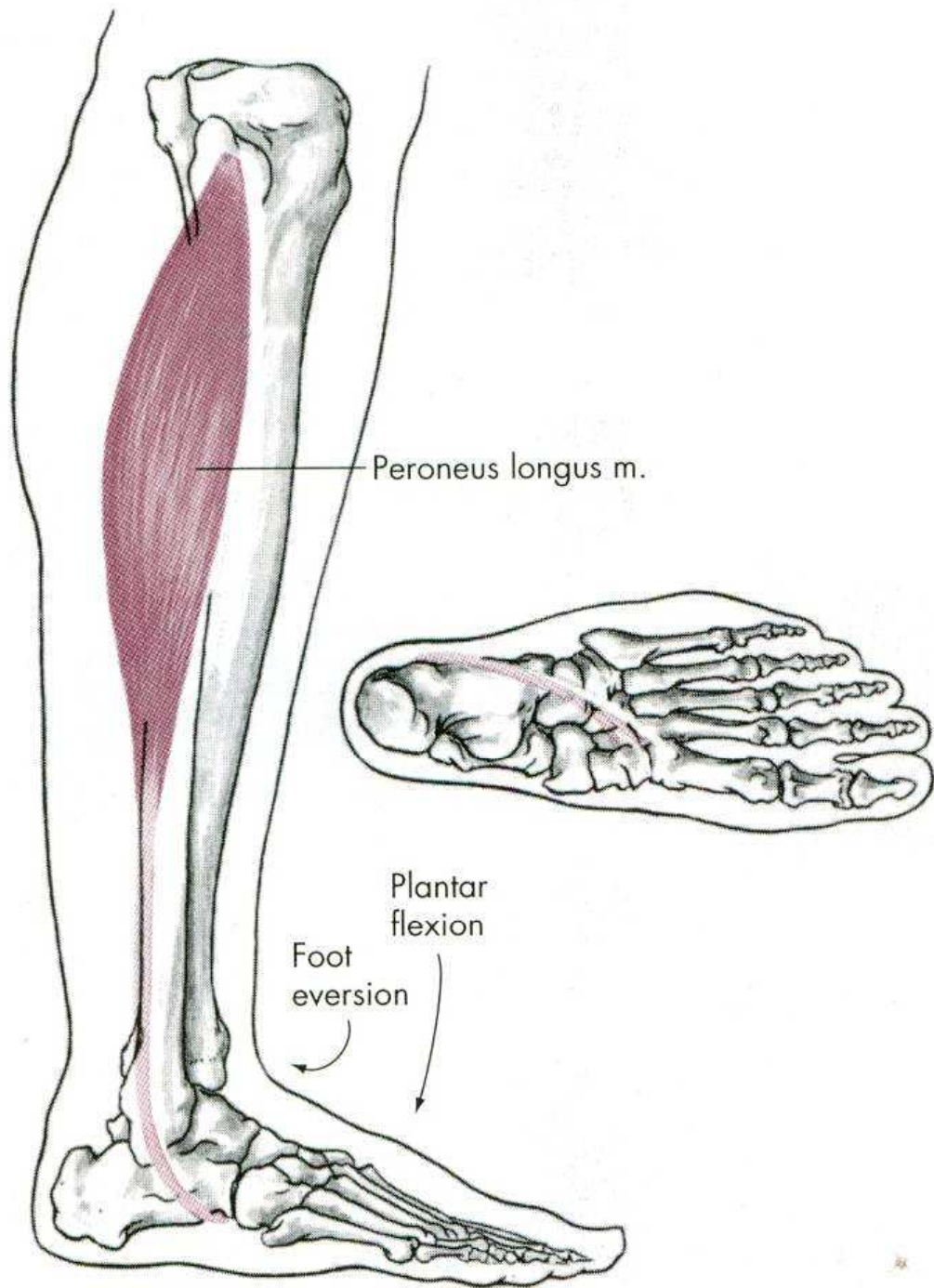
EVERZE

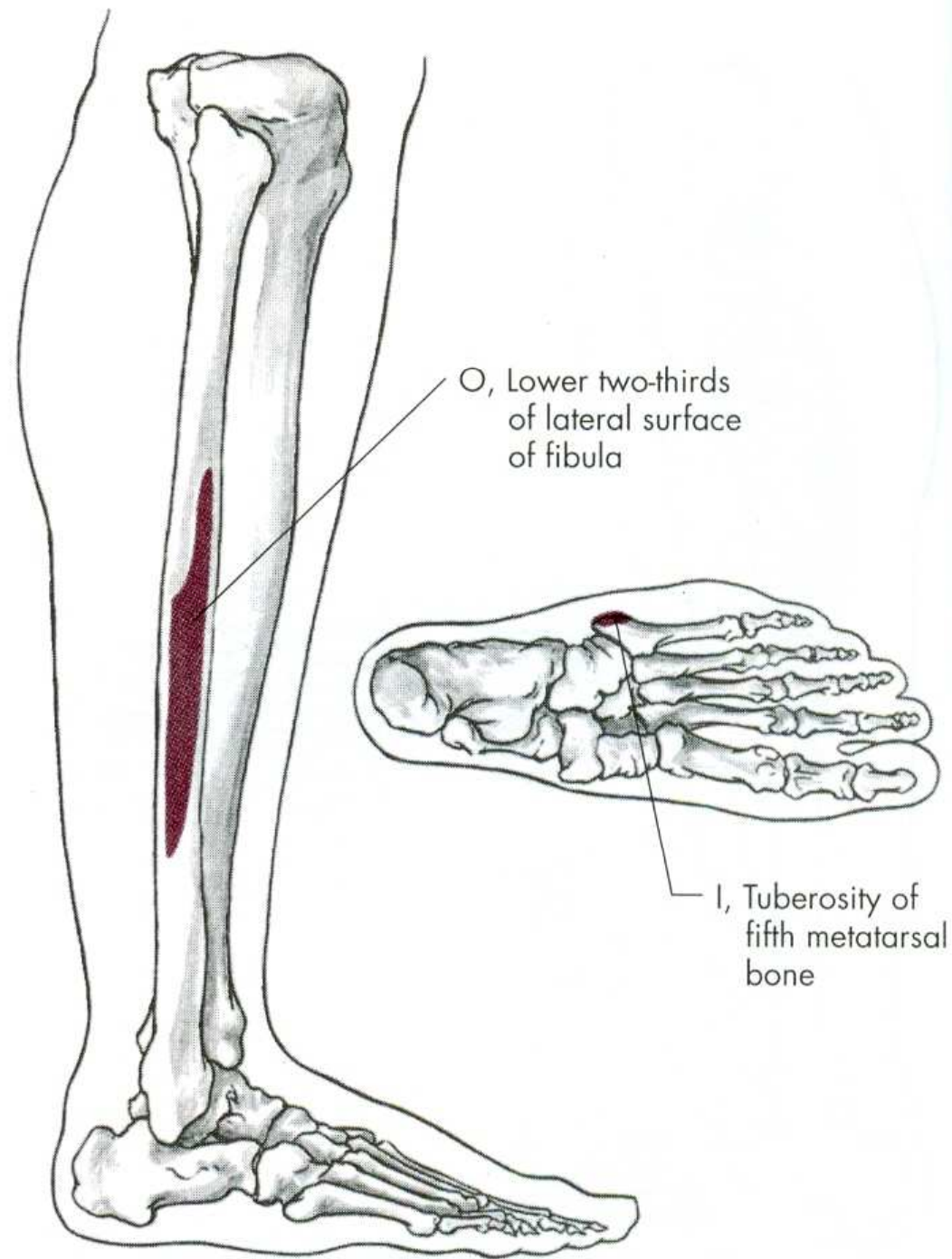
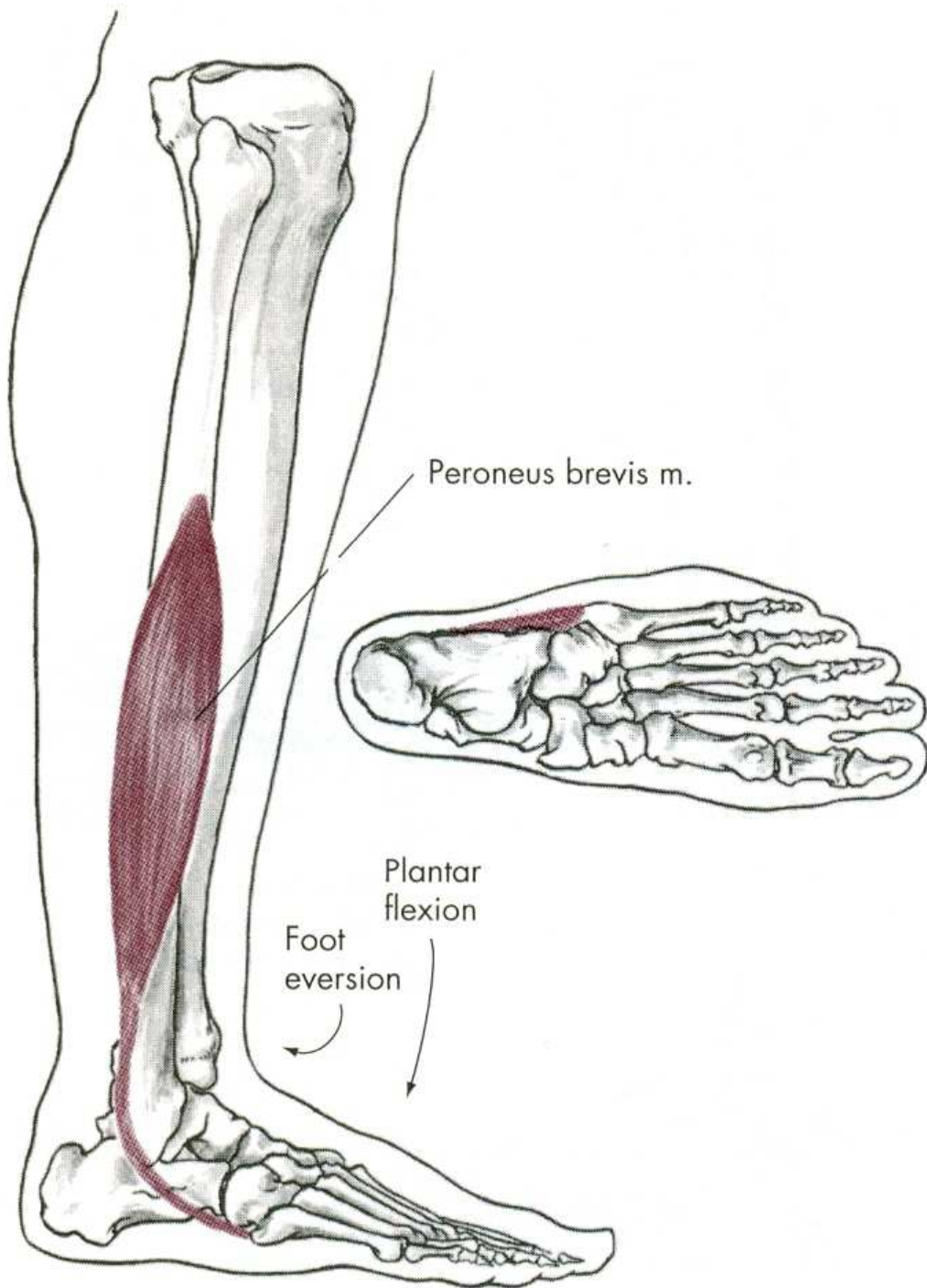


m. peroneus longus

m. peroneus brevis

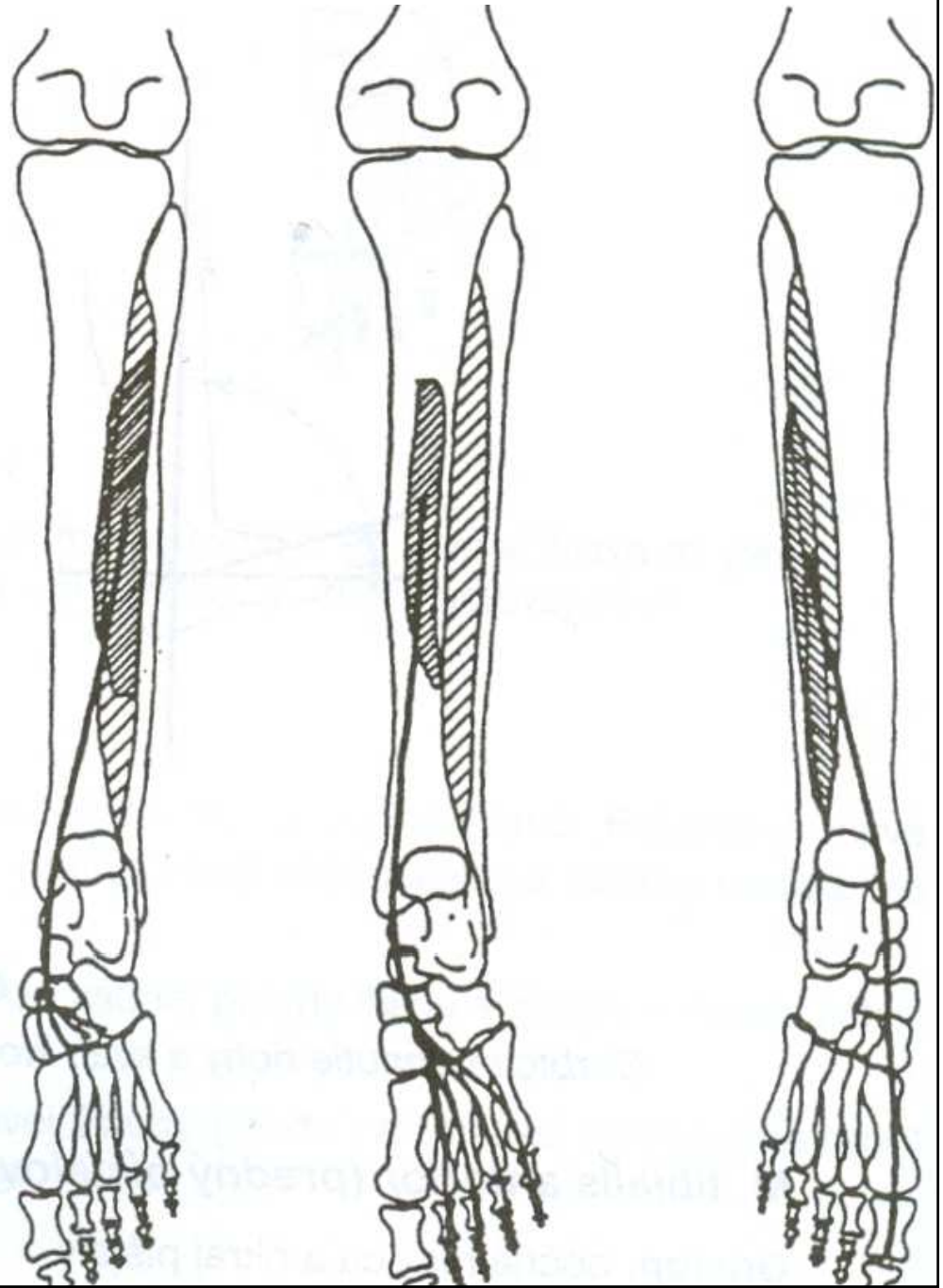
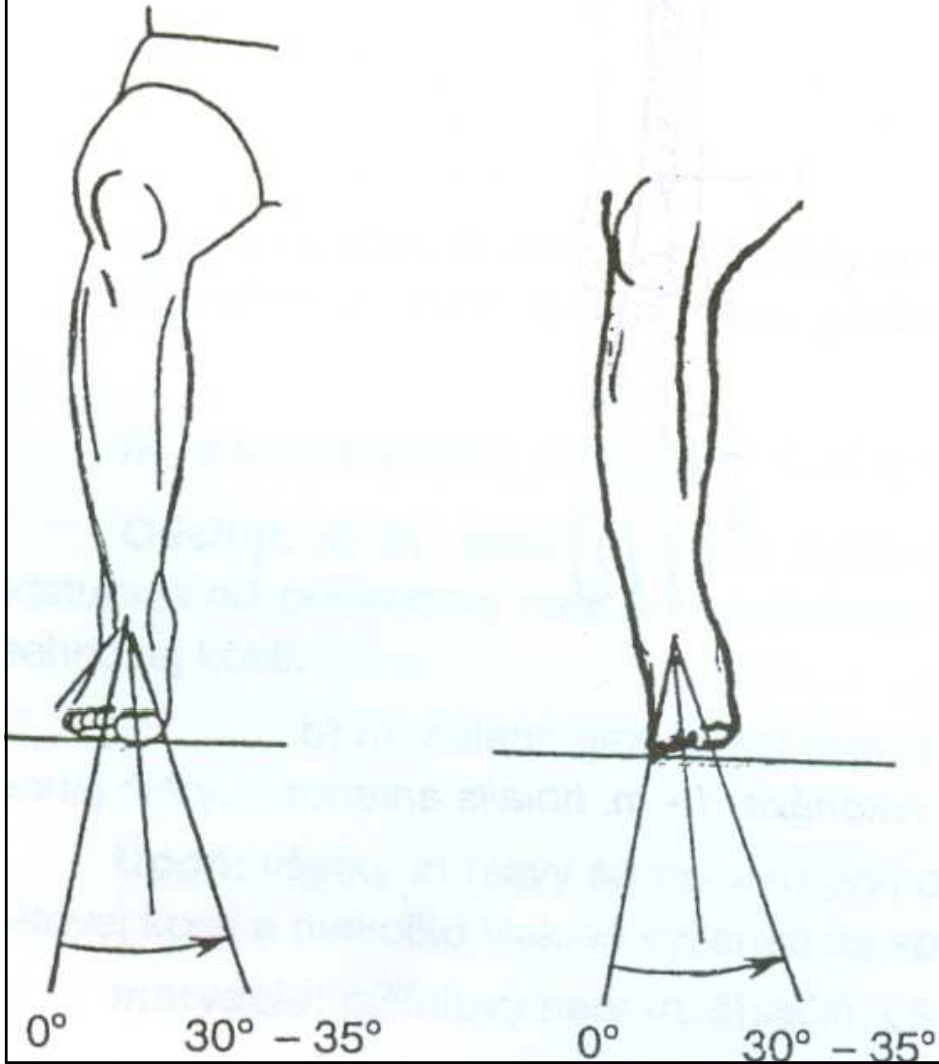






INVERSE

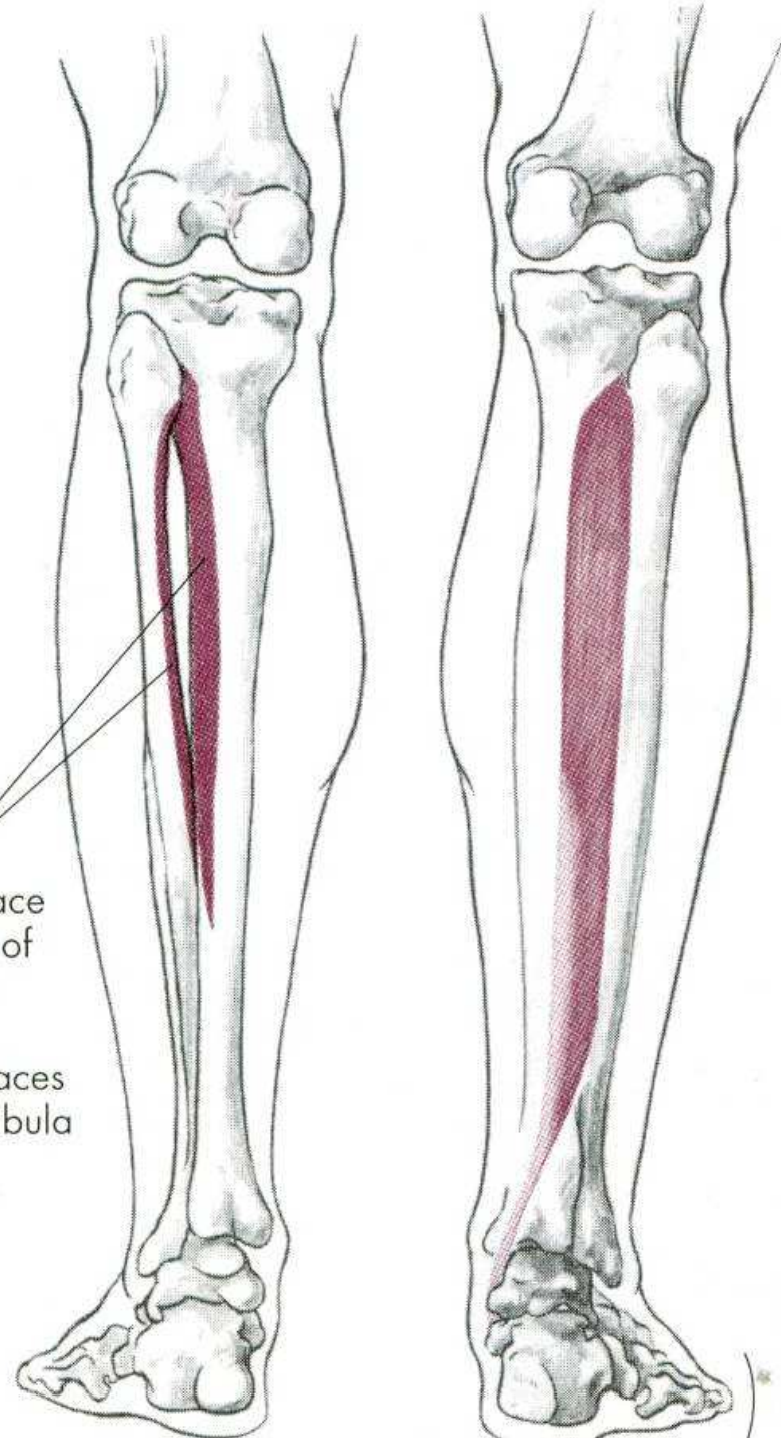
m. tibialis posterior m. flexor digitorum longus m. flexor hallucis longus



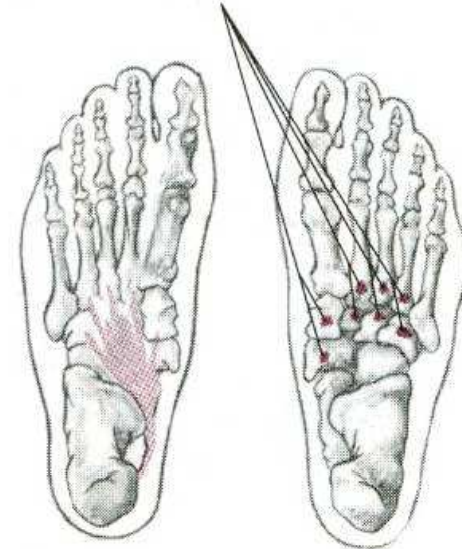
m. tibialis posterior

O, Posterior surface of upper half of interosseous membrane, adjacent surfaces of tibia and fibula

I, Lower inner surfaces of navicular and cuneiform bones, bases of second, third, fourth, and fifth metatarsal bones



Foot inversion
Plantar flexion



EVERSE NOHY

m. peroneus longus

m. peroneus brevis

INVERSE NOHY

m. tibialis posterior – zadní sval holenní

m. flexor digitorum longus

m. flexor hallucis longus

POHYBY PRSTŮ

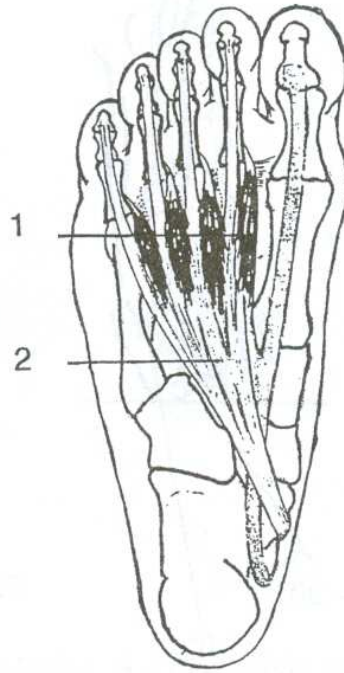

FLEXE - OHNUTÍ

EXTENZE - NATAŽENÍ

ABDUKCE - ODTAŽENÍ

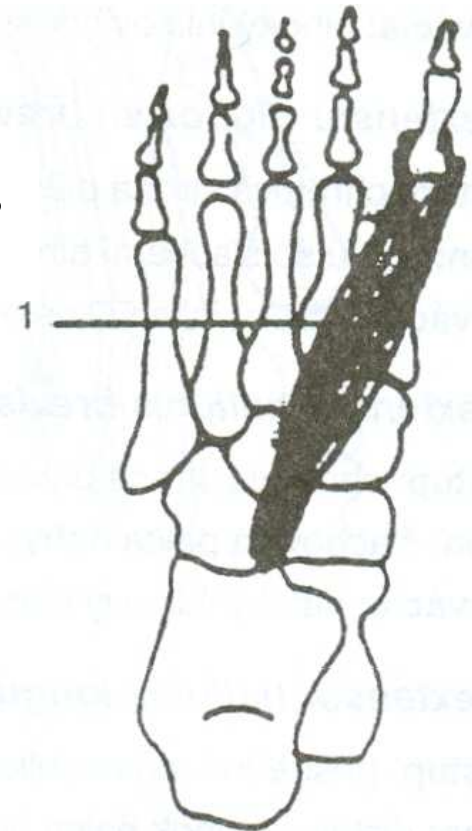
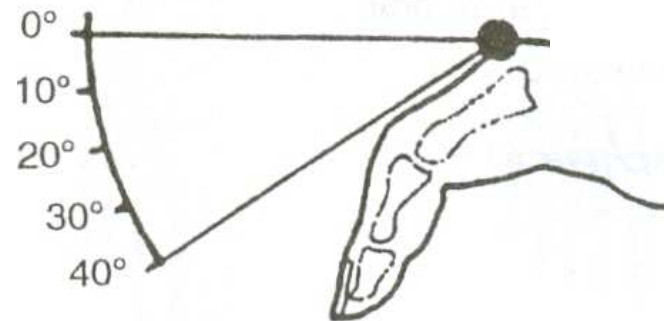
ADDUKCE - PŘITAŽENÍ

mm. lumbricales



FLEXE

m. flexor hallucis
brevis



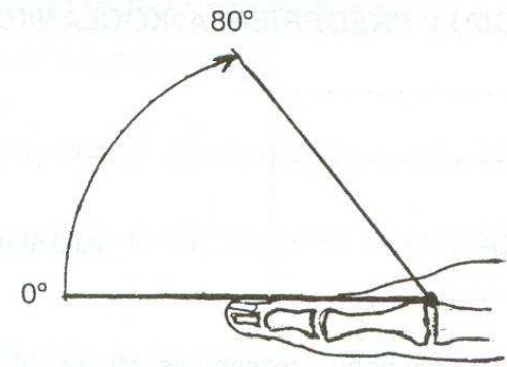
FLEXE PRSTŮ a PALCE

mm. lumbricales

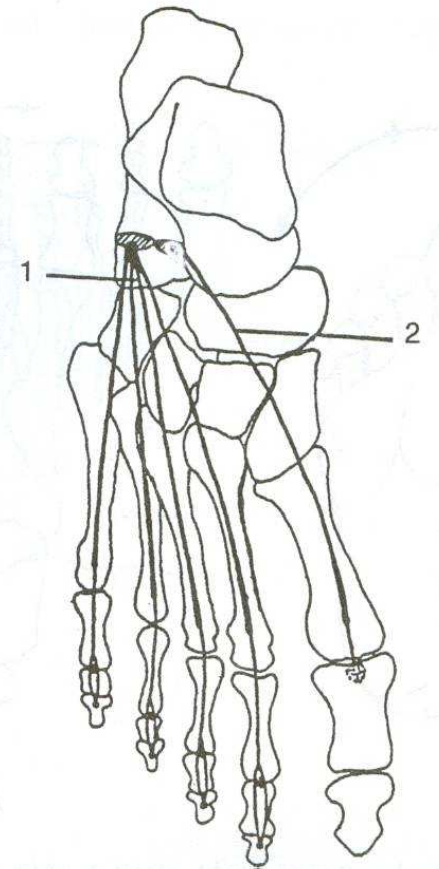
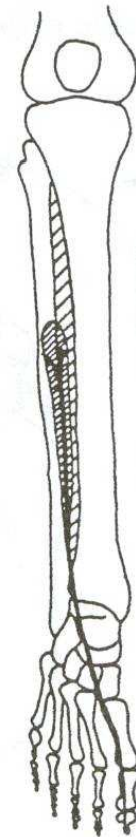
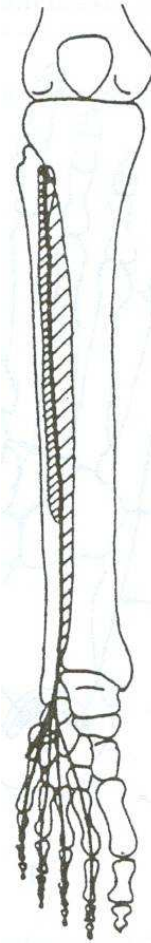
m. flexor digitorum brevis et longus –
krátký a dlouhý ohybač prstů

m. flexor hallucis brevis et longus –
krátký a dlouhý ohybač palce

EXTENZE



m. extensor digitorum longus



m. extensor hallucis longus

m. extensor hallucis brevis