

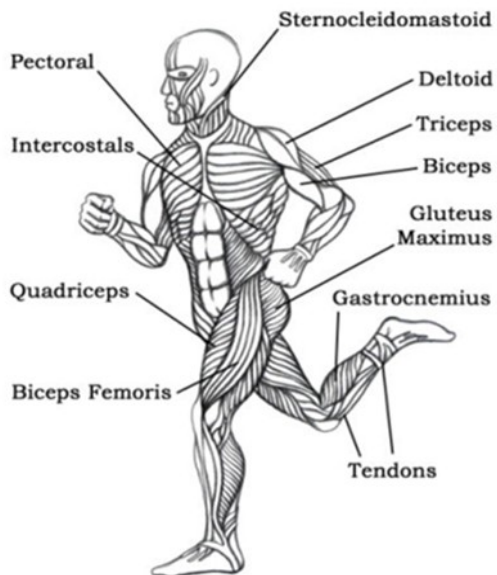
Morphology of the Locomotor System

Look at the diagram and study the main muscles of the body.

Define which muscles have the following functions:

- lowers the arm.
- turn the upper half of the body and are between the ribs.
- straighten the knees.
- extend the thigh or bend the knee.
- rotates the head.
- raises the upper arm.
- raise and lower arms.
- straightens the hip joint and holds the body upright.
- helps to stand on toes.

Some Important Skeletal Muscles



http://www.youtube.com/watch?v=gTQ5PdF_YR8

Lee Smith, a physical therapist from the NeuroRecovery Network at the Frazier Rehab institute in Louisville, Kentucky explains the basic idea behind how locomotor training works.

Watch the video and explain how you understand locomotor training. What does it involve?

Text

Human Skeleton

(From Wikipedia, the free encyclopedia)

The human skeleton consists of both fused and individual bones supported and supplemented by ligaments, tendons, muscles and cartilage. It serves as a scaffold which supports organs, anchors muscles, and protects organs such as the brain, lungs and heart. The biggest bone in the body is the femur in the thigh and the smallest is the stirrup bone in the middle ear. In an adult, the skeleton comprises around 30-40% of the total body weight and half of this weight is water.

Fused bones include those of the pelvis and the cranium. Not all bones are interconnected directly: there are three bones in each middle ear called the ossicles that articulate only with each other. The hyoid bone, which is located in the neck and serves as the point of attachment for the tongue, does not articulate with any other bones in the body, being supported by muscles and ligaments.

There are over 206 bones in the adult human skeleton, a number which varies between individuals and with age - newborn babies have over 270 bones, some of which fuse together into a longitudinal axis, the axial skeleton, to which the appendicular skeleton is attached.

The axial skeleton (80 bones) is formed by the vertebral column, the rib cage (12 pairs of ribs and the sternum), and the skull (22 bones and 7 associated bones). The axial skeleton transmits the weight from the head, the trunk, and the upper extremities down to the lower extremities at the hip joints, and is therefore responsible for the upright position of the human body. The 366 skeletal muscles acting on the axial skeleton position the spine, allowing for big movements in the thoracic cage for breathing, and the head.

The appendicular skeleton (126 bones) is formed by the pectoral girdles, the upper limbs, the pelvic girdle, and the lower limbs. Their functions are to make locomotion possible and to protect the major organs of locomotion, digestion, excretion, and reproduction.

There are many differences between the male and female human skeletons. Most prominent is the difference in the pelvis, owing to characteristics required for the processes of childbirth. The shape of a female pelvis is flatter, more rounded and proportionally larger to allow the head of a fetus to pass. Also, the coccyx of a female's pelvis is oriented more inferiorly whereas the man's coccyx is usually oriented more anteriorly. This difference allows more room for a developing fetus. Men tend to have slightly thicker and longer limbs and digit bones (phalanges), while women tend to have narrower rib cages, smaller teeth, less angular mandibles, less pronounced cranial features such as the brow ridges and external occipital protuberance (the small bump at the back of the skull), and the carrying angle of the forearm is more pronounced in females. Females also tend to have more rounded shoulder blades.

Tasks:

1. Choose an appropriate headline for each of the paragraphs.
2. Find in the text:
 - three names of bones
 - three names of components of the human skeleton
 - two functions of the appendicular skeleton
3. three differences between the male and the female skeleton
4. How many bones does the skeleton have? What can you say about its organization? What is the axial skeleton? What is the appendicular skeleton?

Task: Label the bones in the following diagram:

Skull, maxilla, rib, humerus, radius, ulna, pelvis, sacrum, femur, patella, tibia, fibula, scapula, phalanges, mandible, clavicle

