

Svaly horní končetiny

Mm. membri superioris

DÚ pro studenty, kteří se nemohou zúčastnit semináře ze svalů HK (jedná se pouze o dva studenty).

Prosím napište **jen** č. obrázku a u jednotlivých svalů číslo a název.

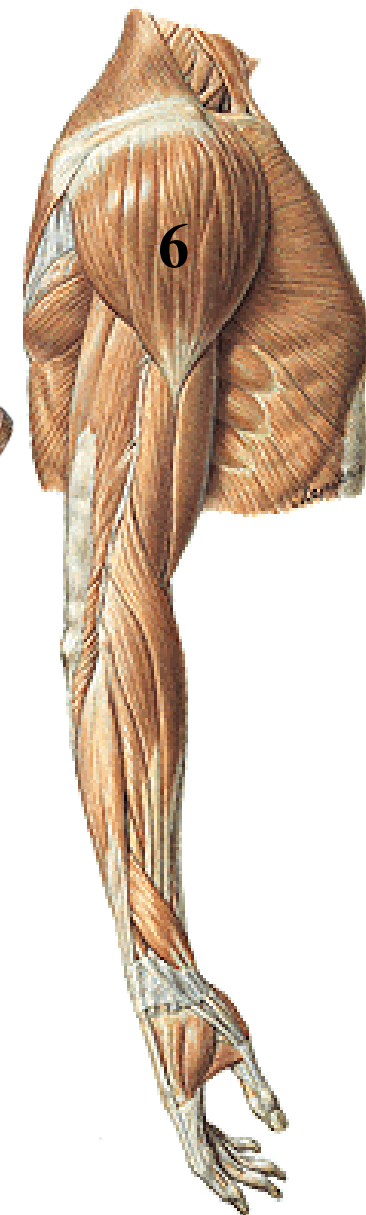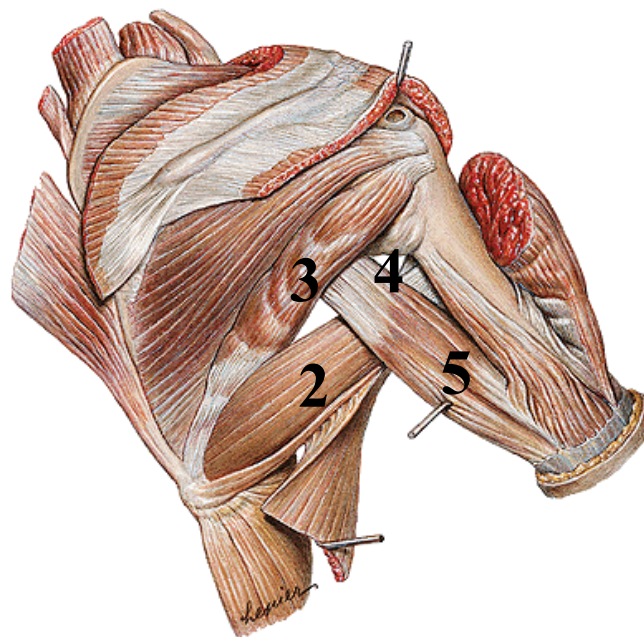
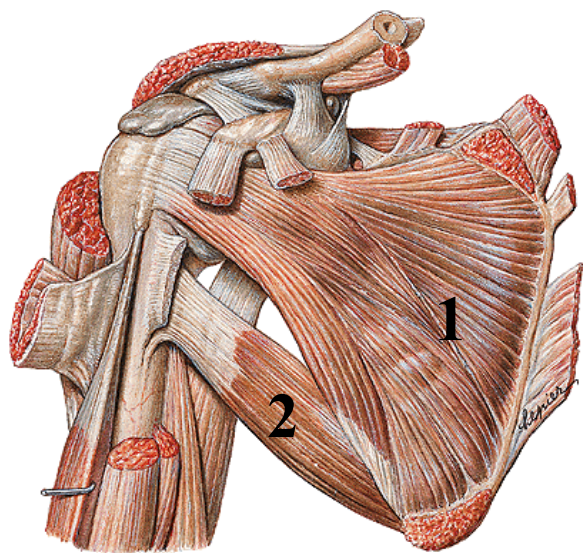
DÚ zašlete na moji adresu **lhorac@fsps.muni.cz**

Ostatní studenti si mohou samozřejmě také vyřešit DÚ, ale výsledky si srovnajte s obrázky v anatomickém atlase, neposílejte mi je.

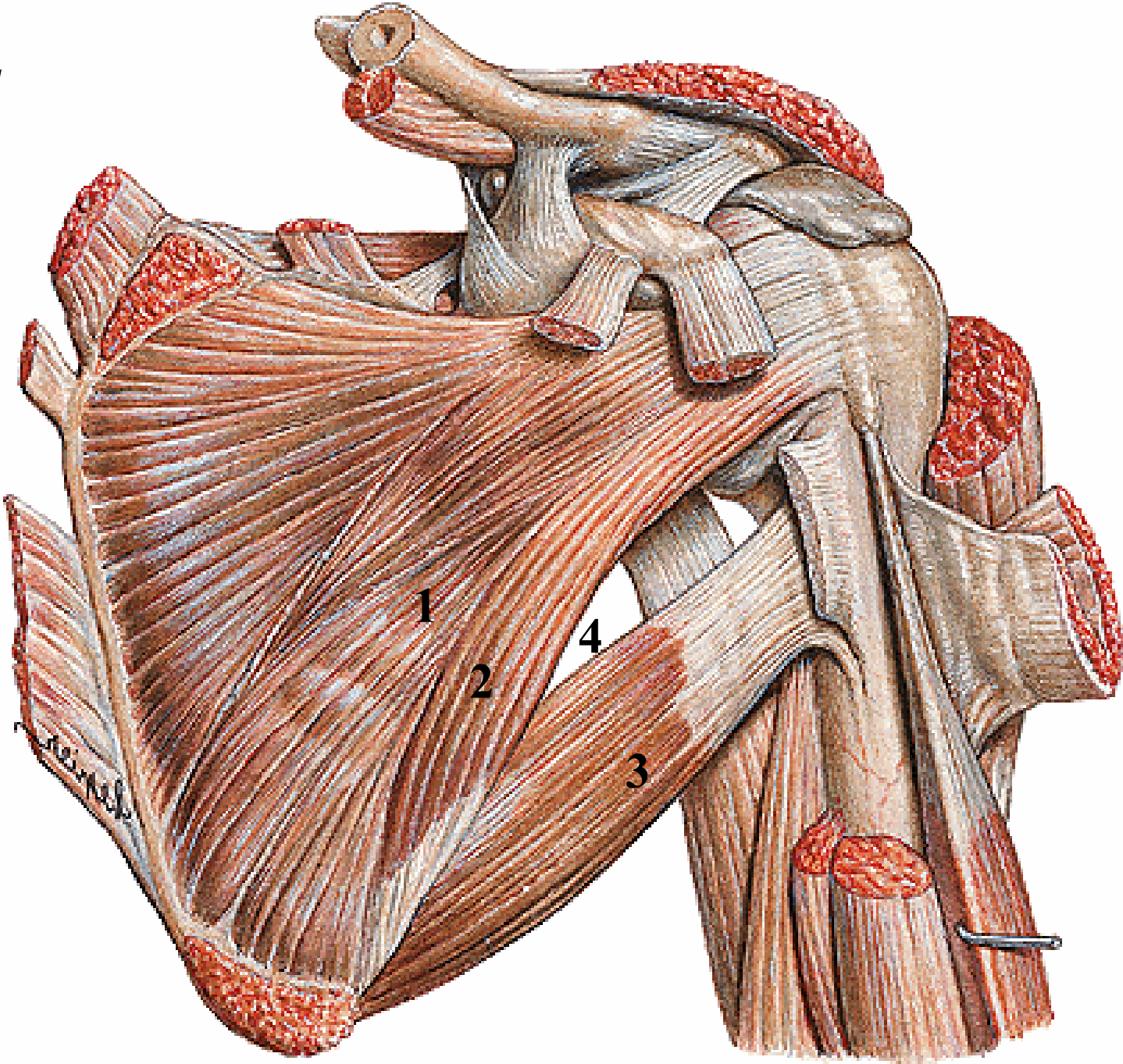
L. Horáčková

Obr. 1

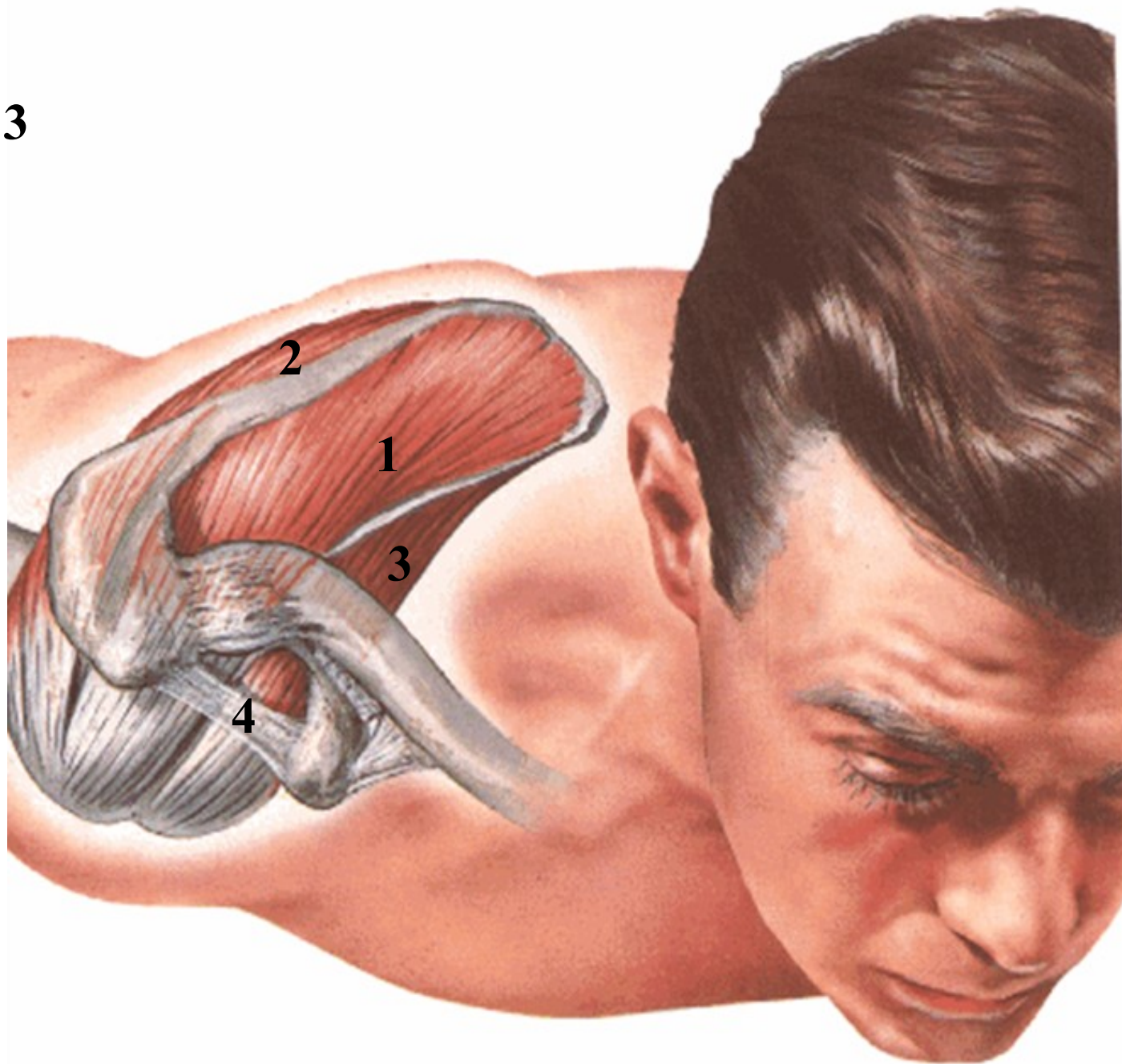
Svaly pletence pažního (*musculi humeri*)



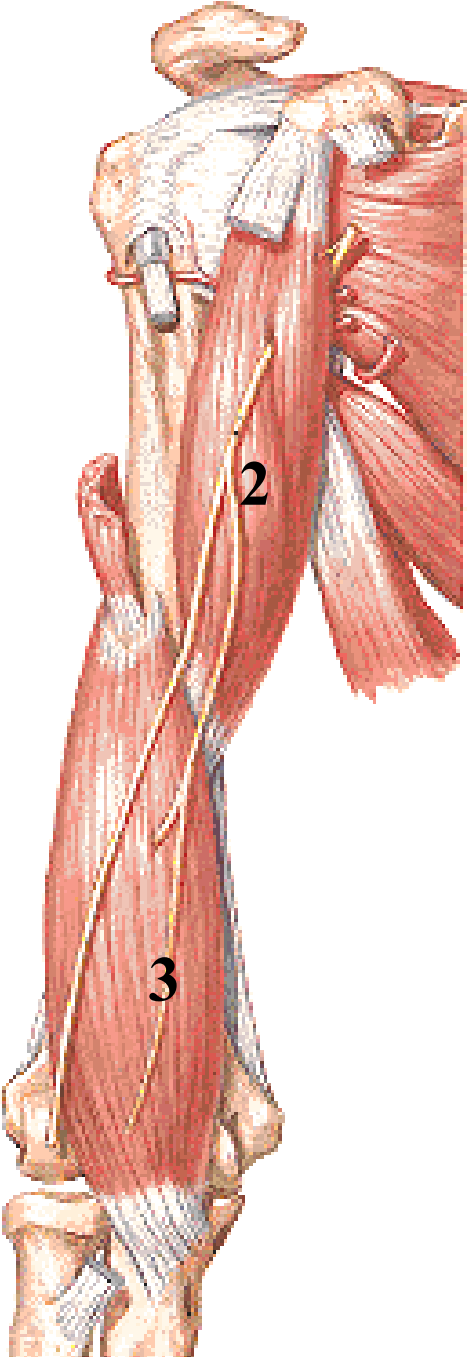
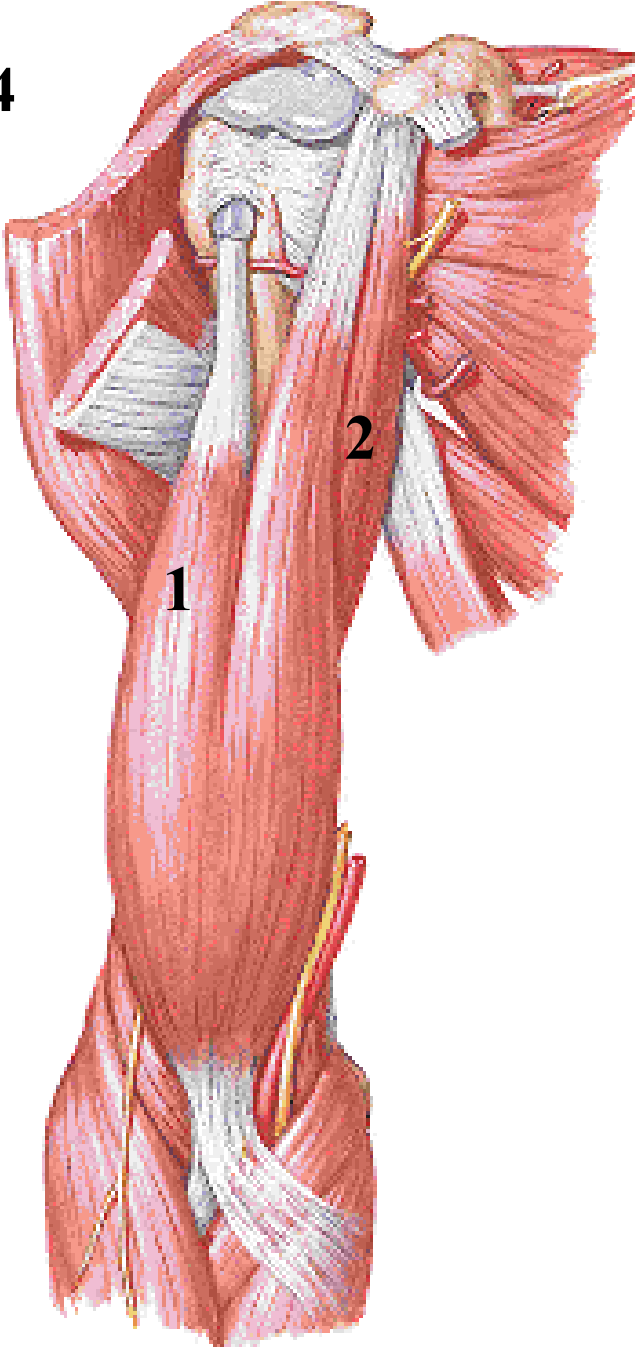
Obr. 2



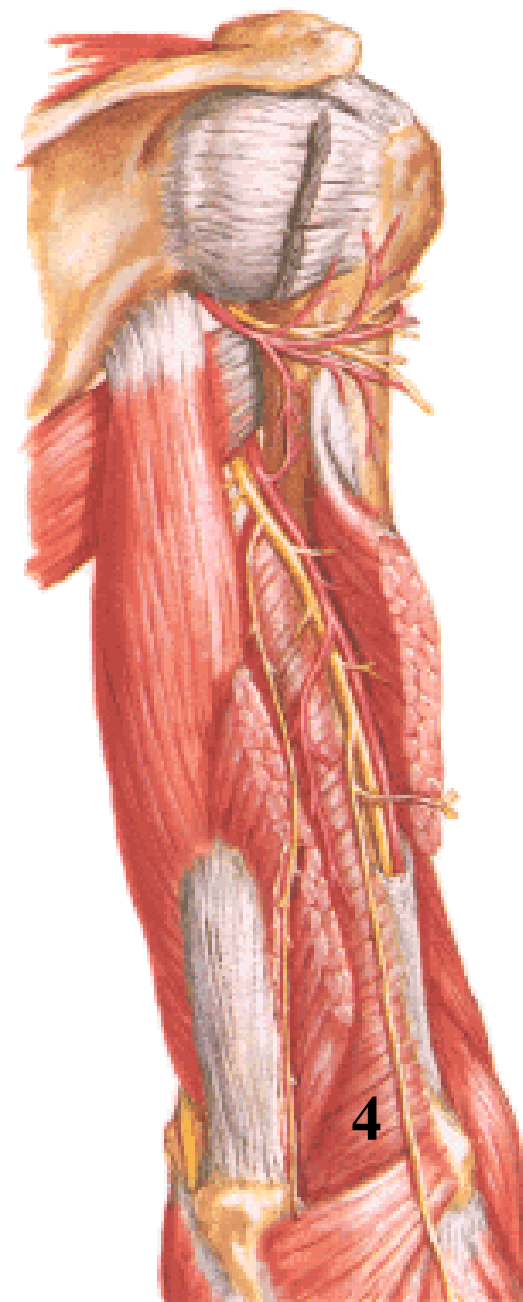
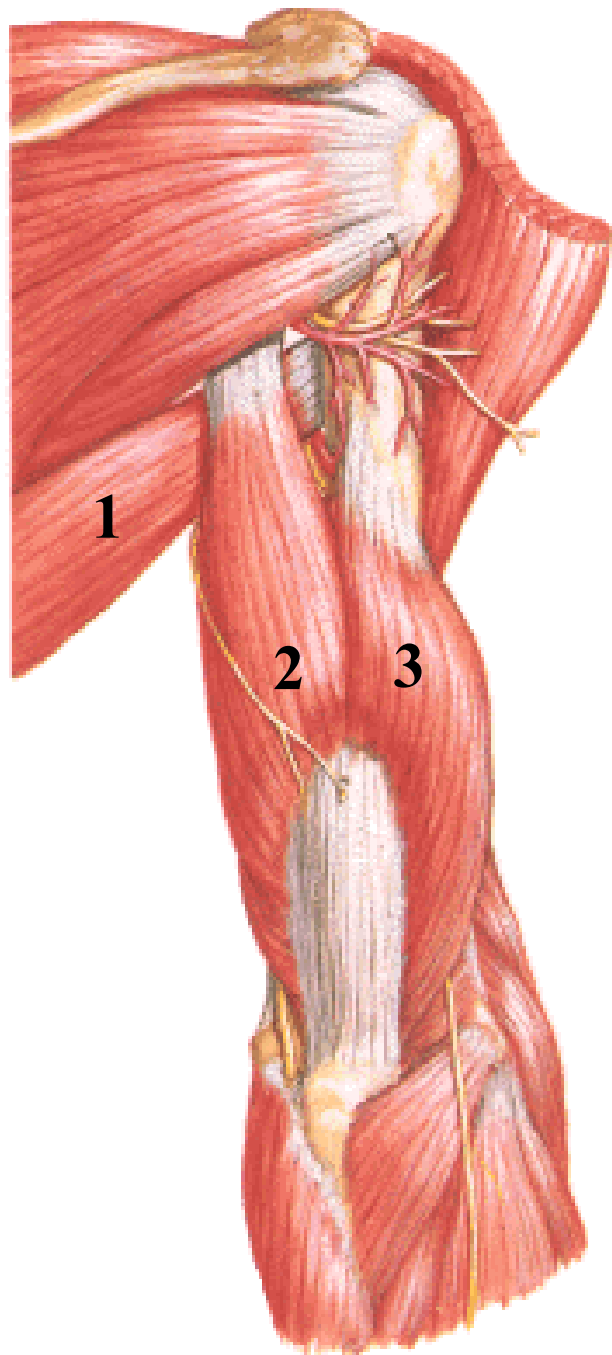
Obr. 3



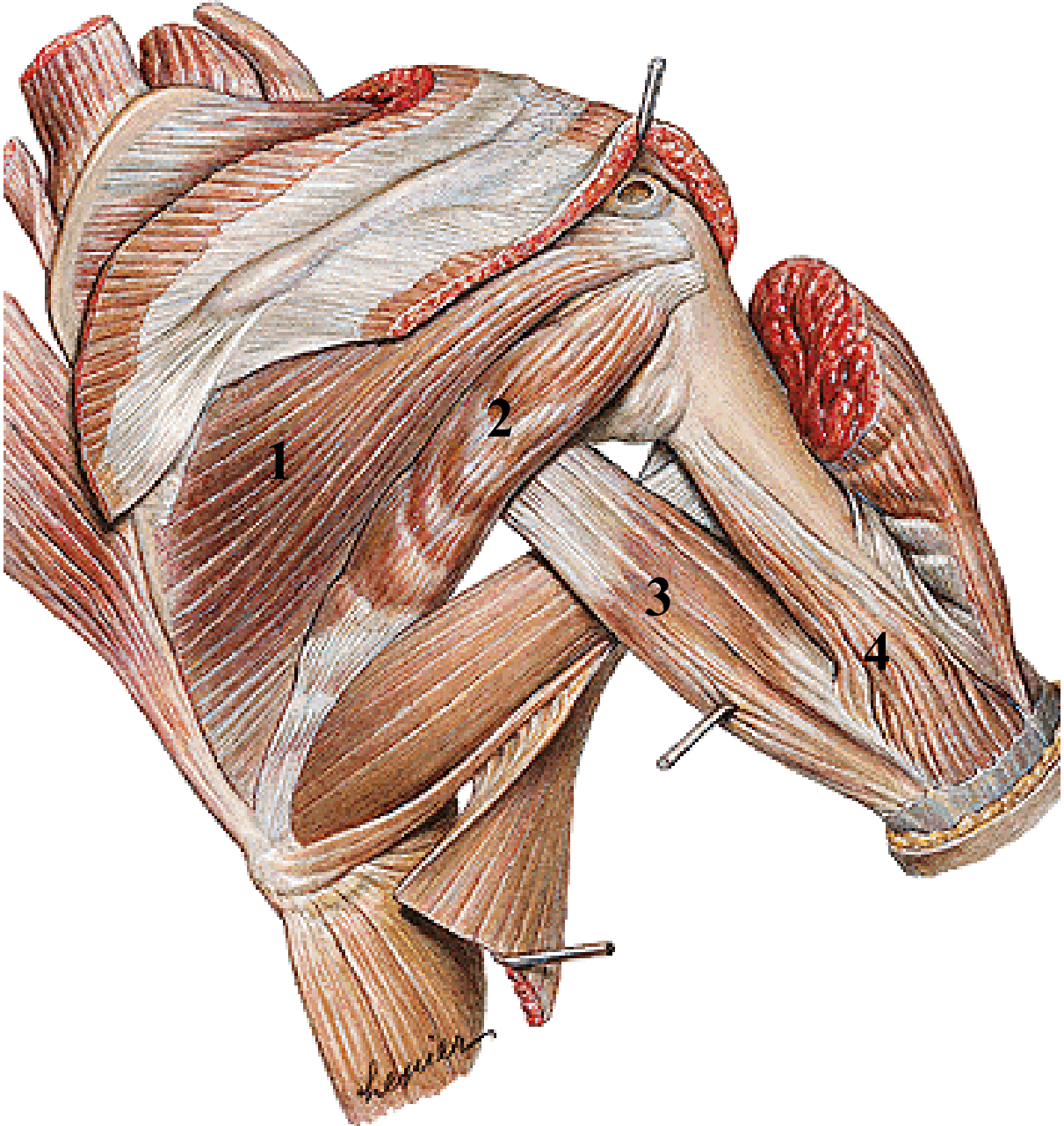
Obr. 4



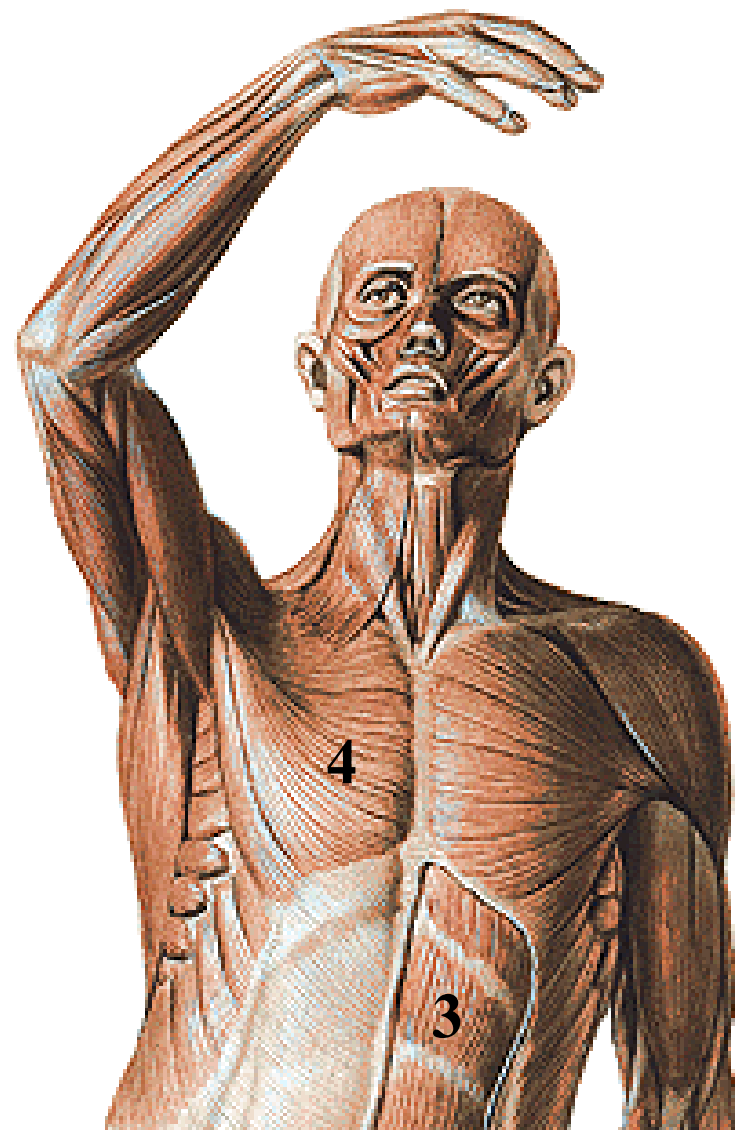
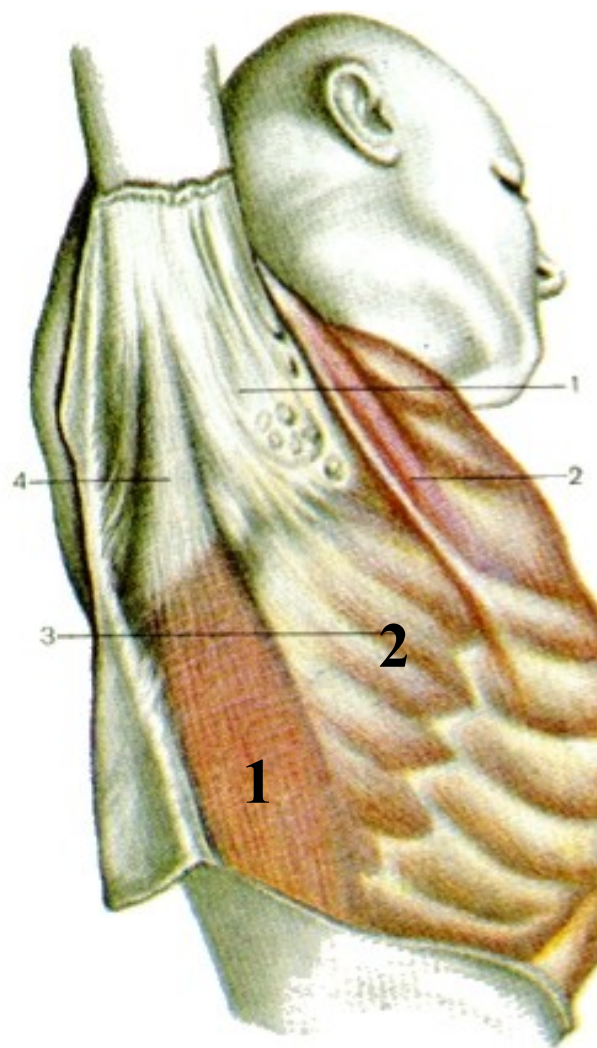
Obr. 5



Obr. 6

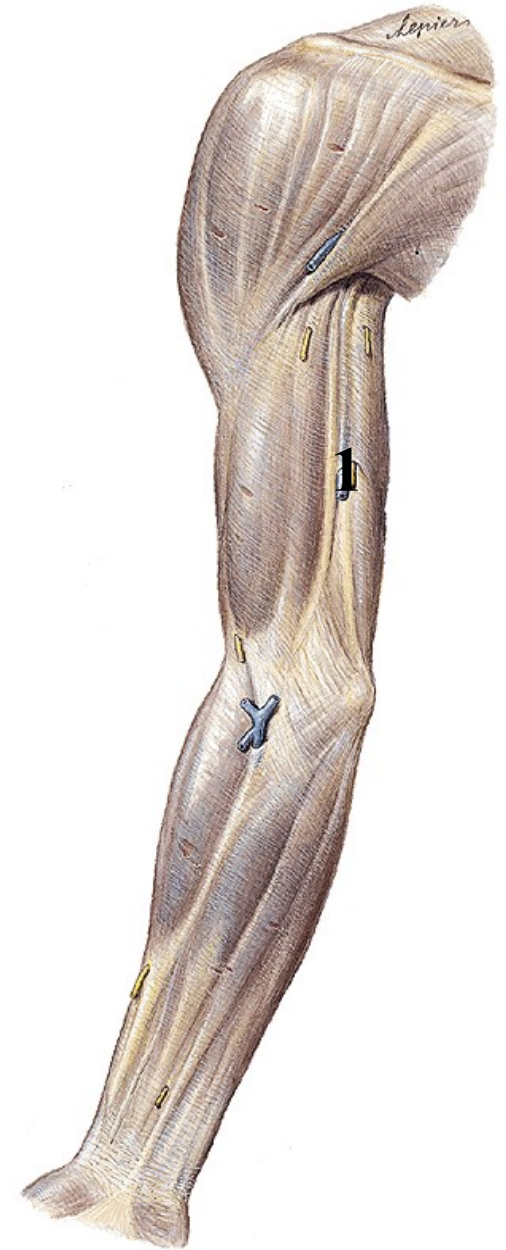
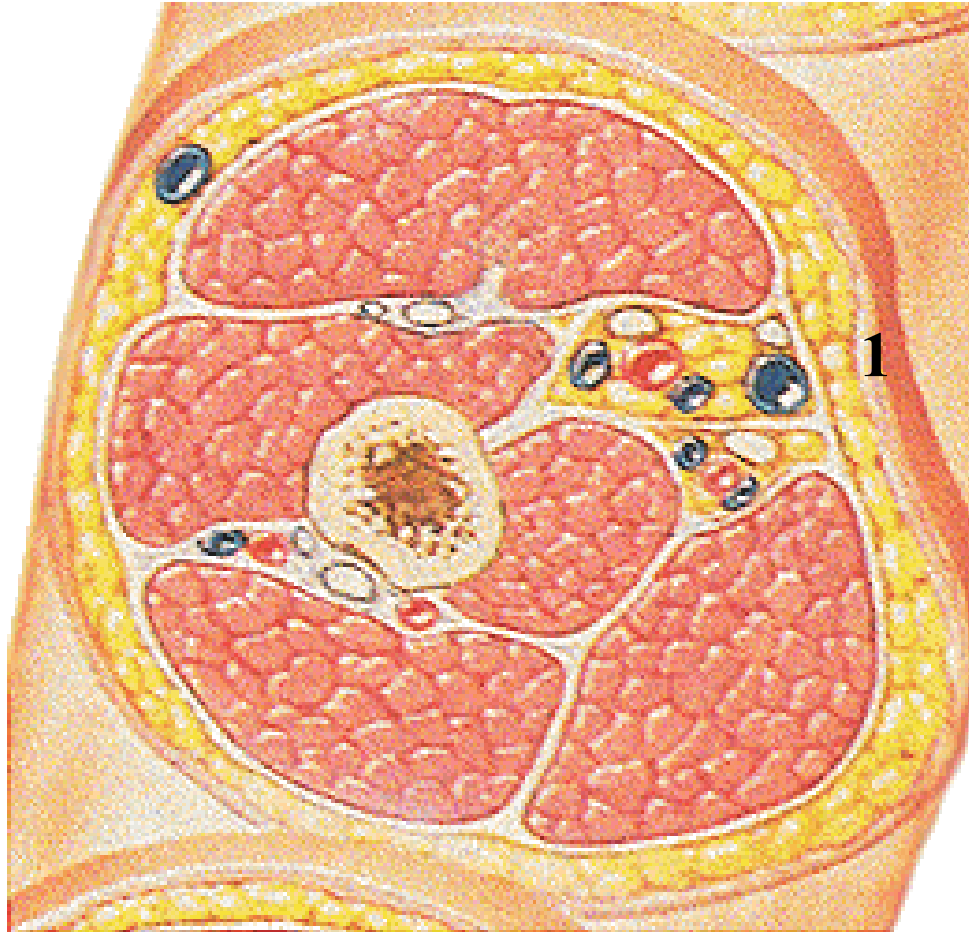


Obr. 7



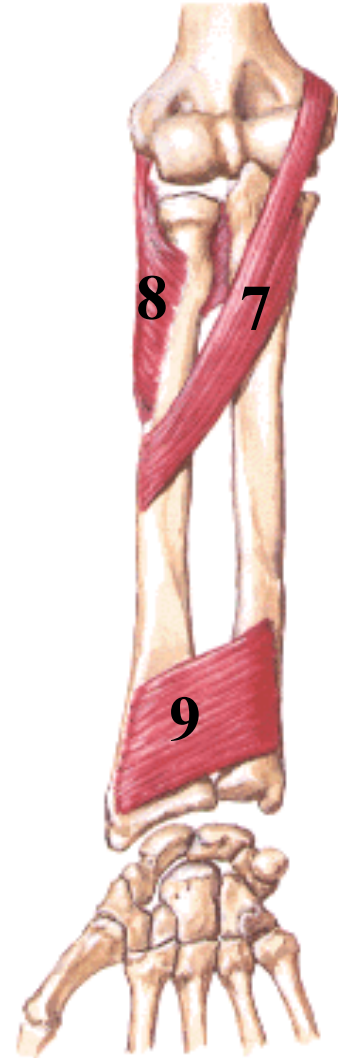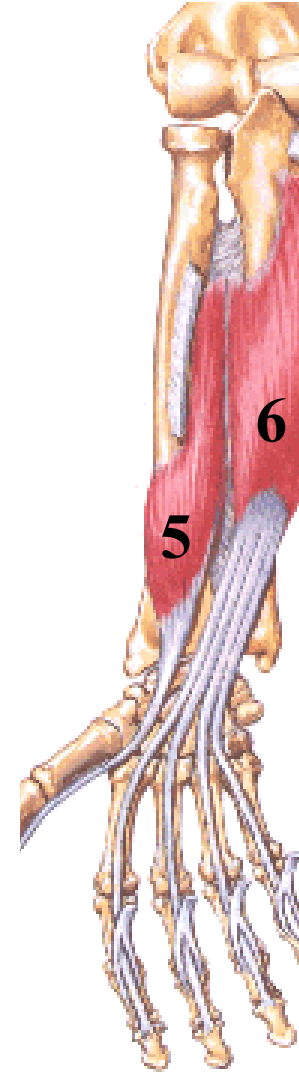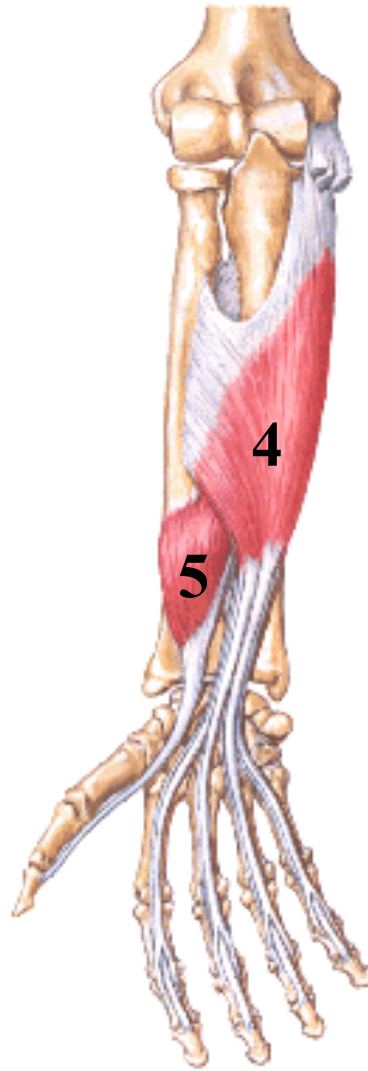
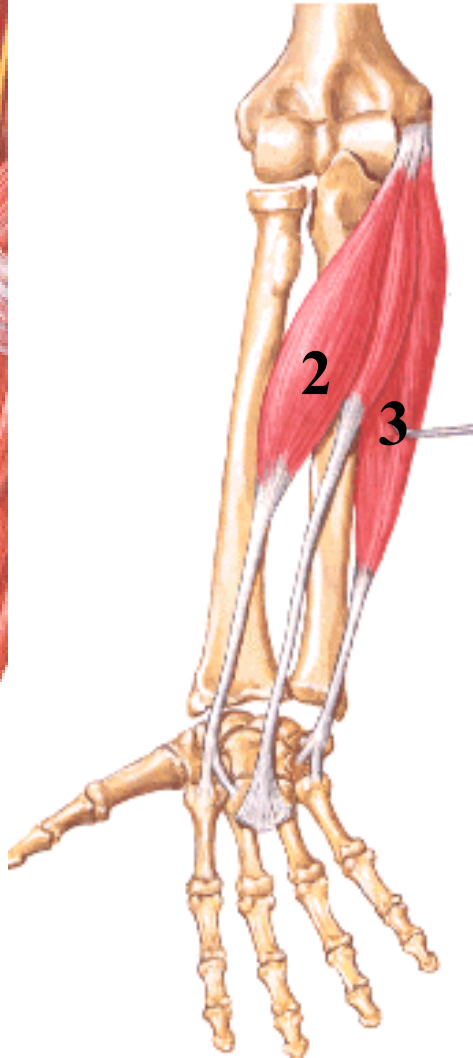
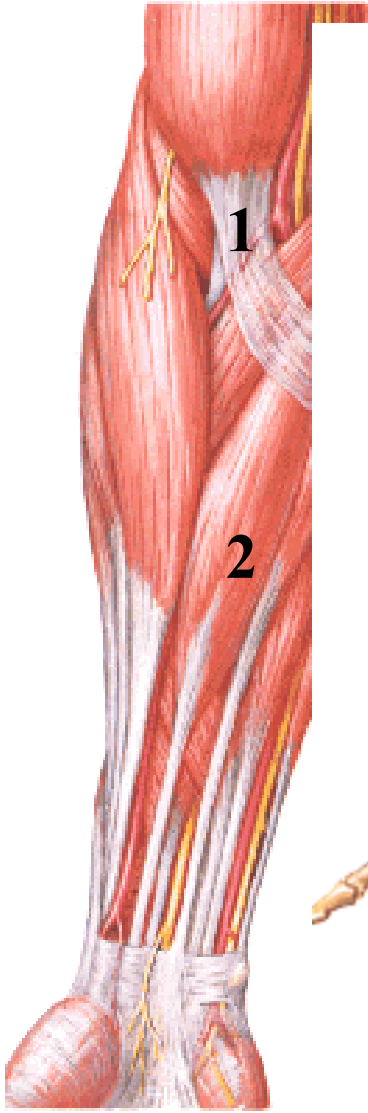
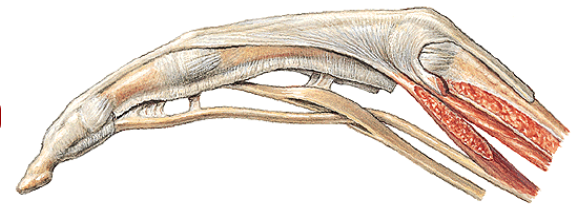
Obr. 8

Fascia brachii

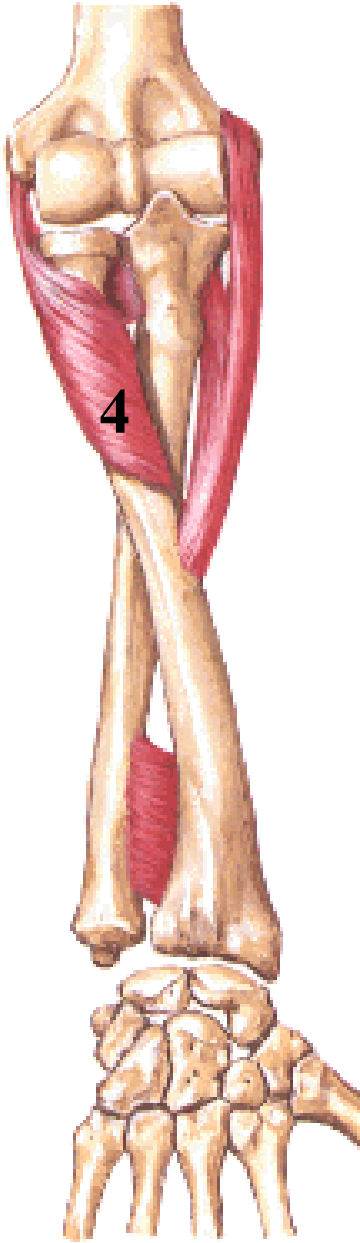
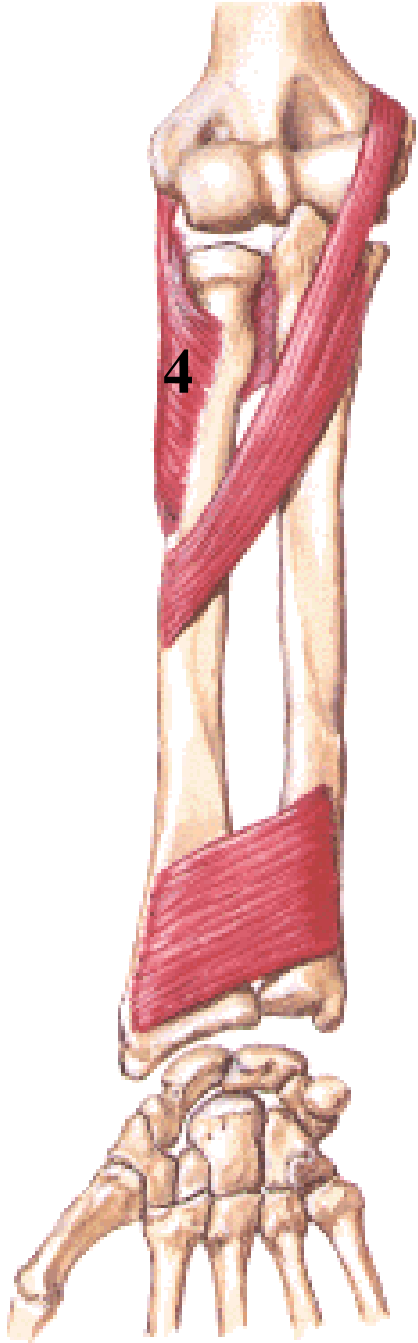
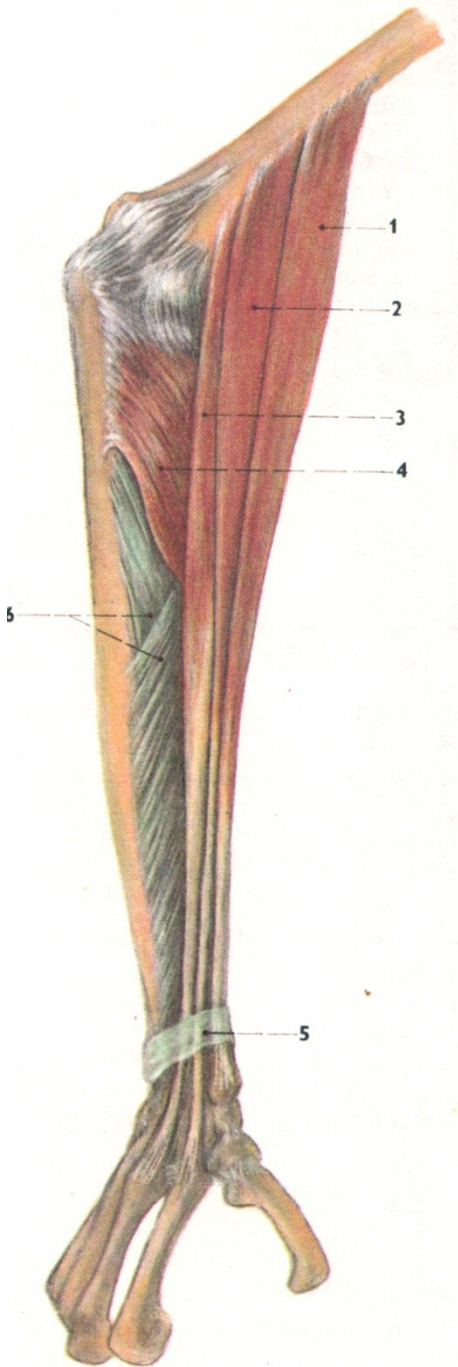


Obr. 9

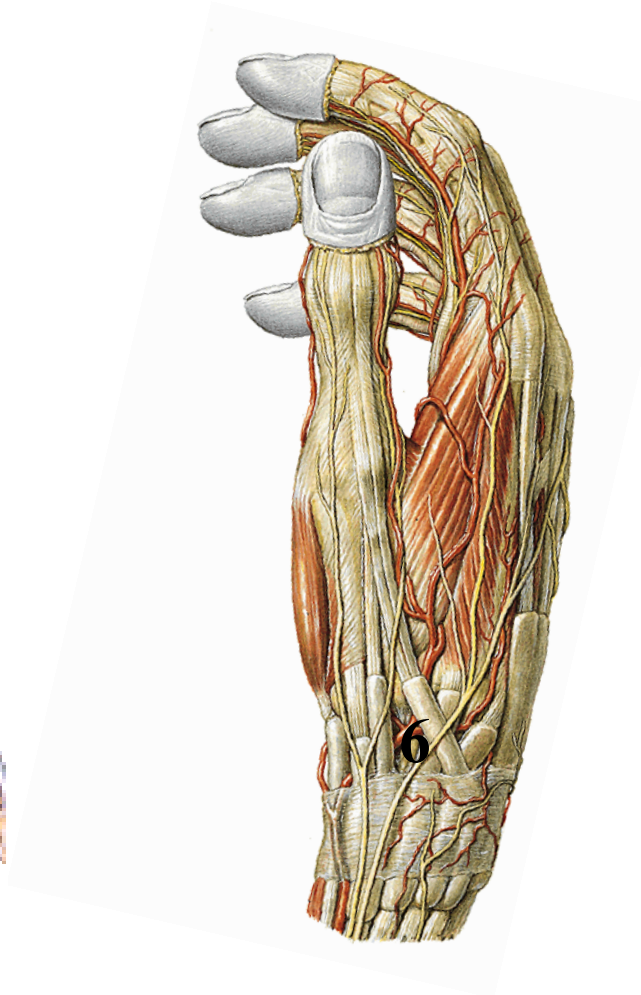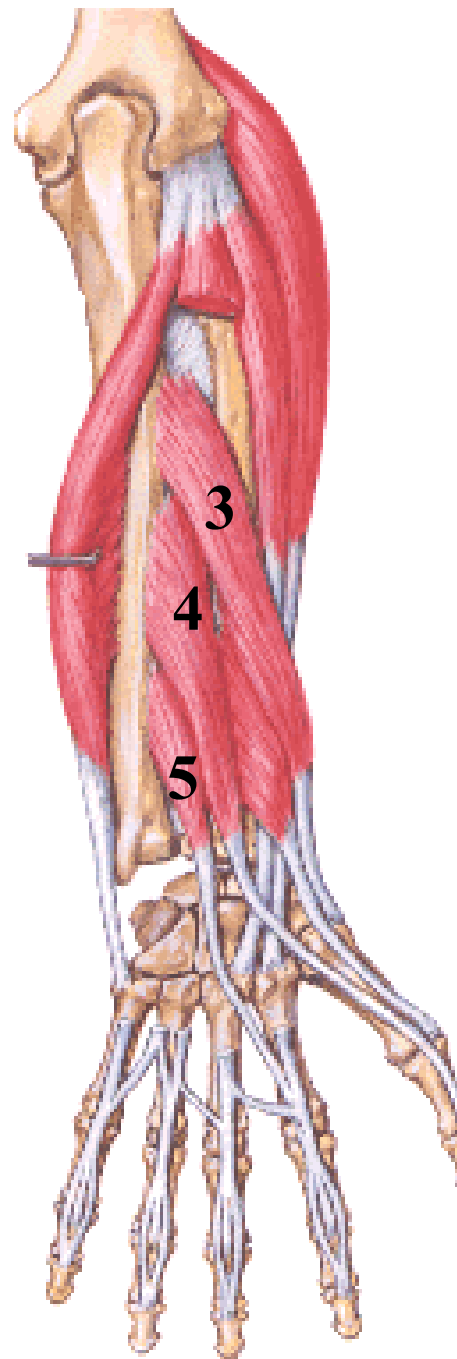
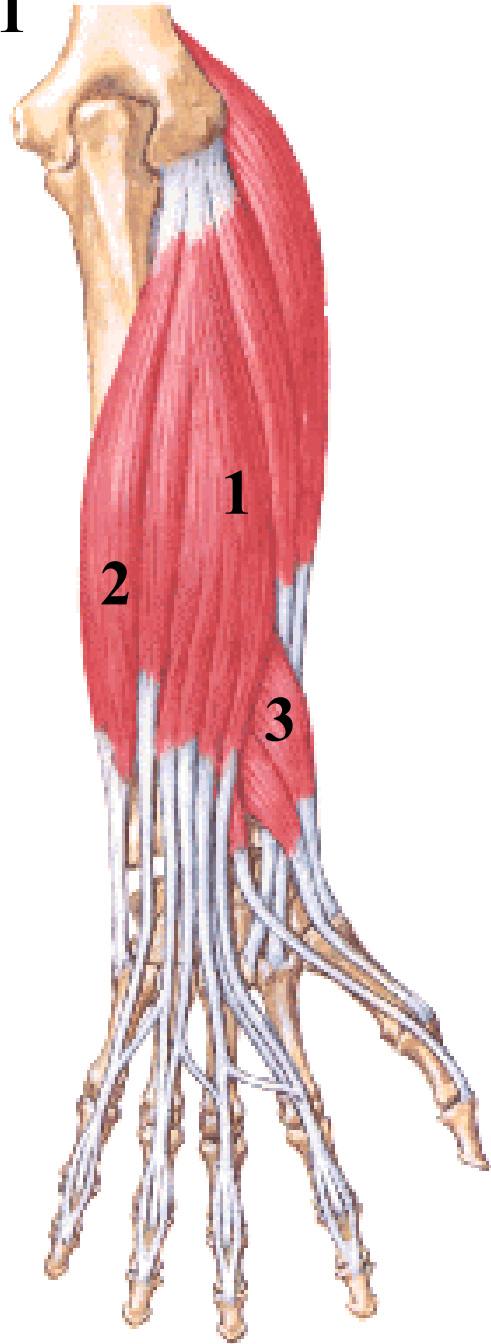
Svaly předloktí (*musculi antebrachii*)



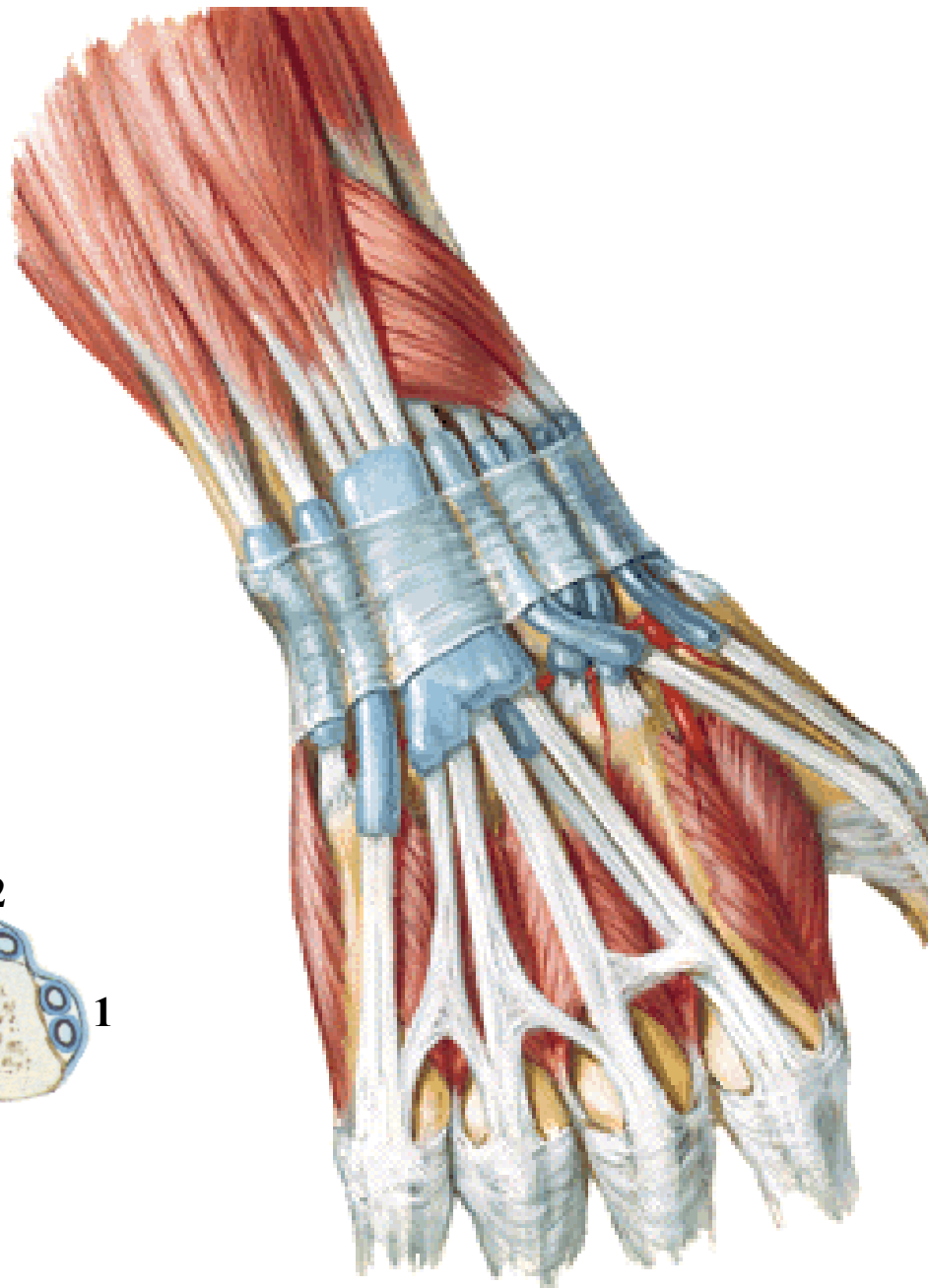
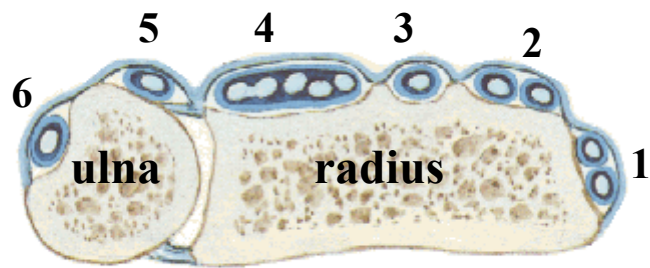
Obr. 10



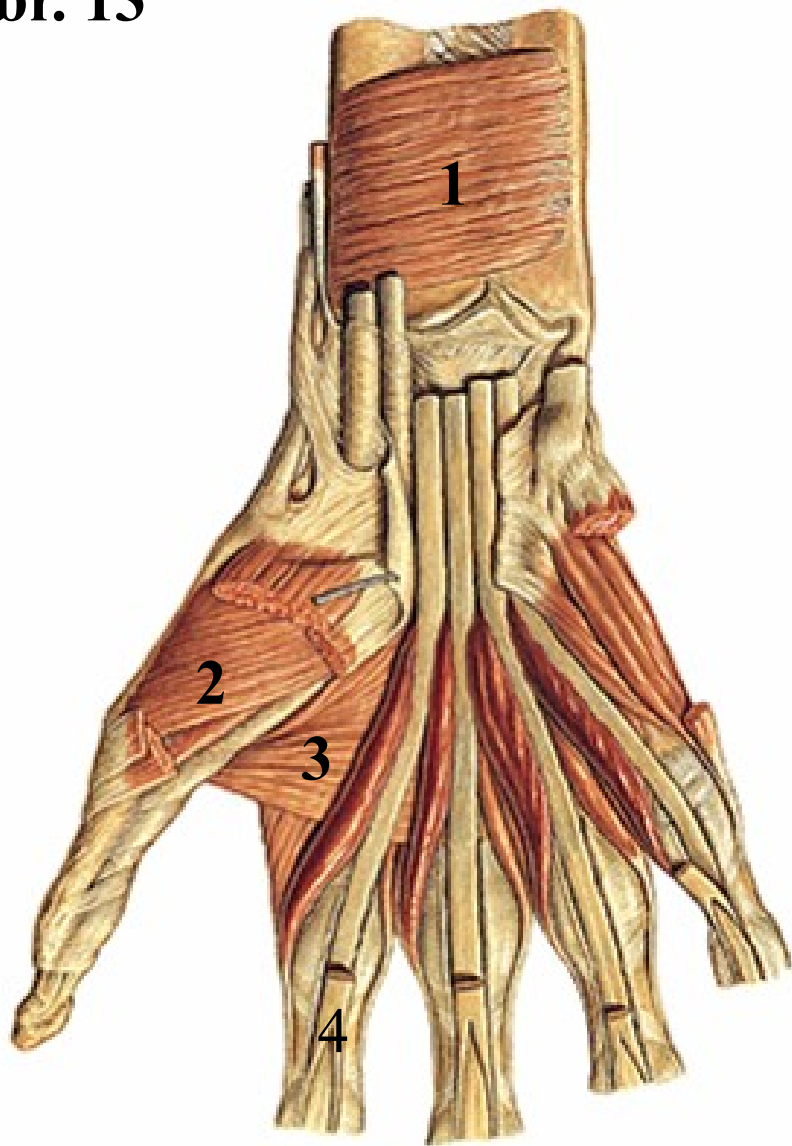
Obr. 11



Obr. 12

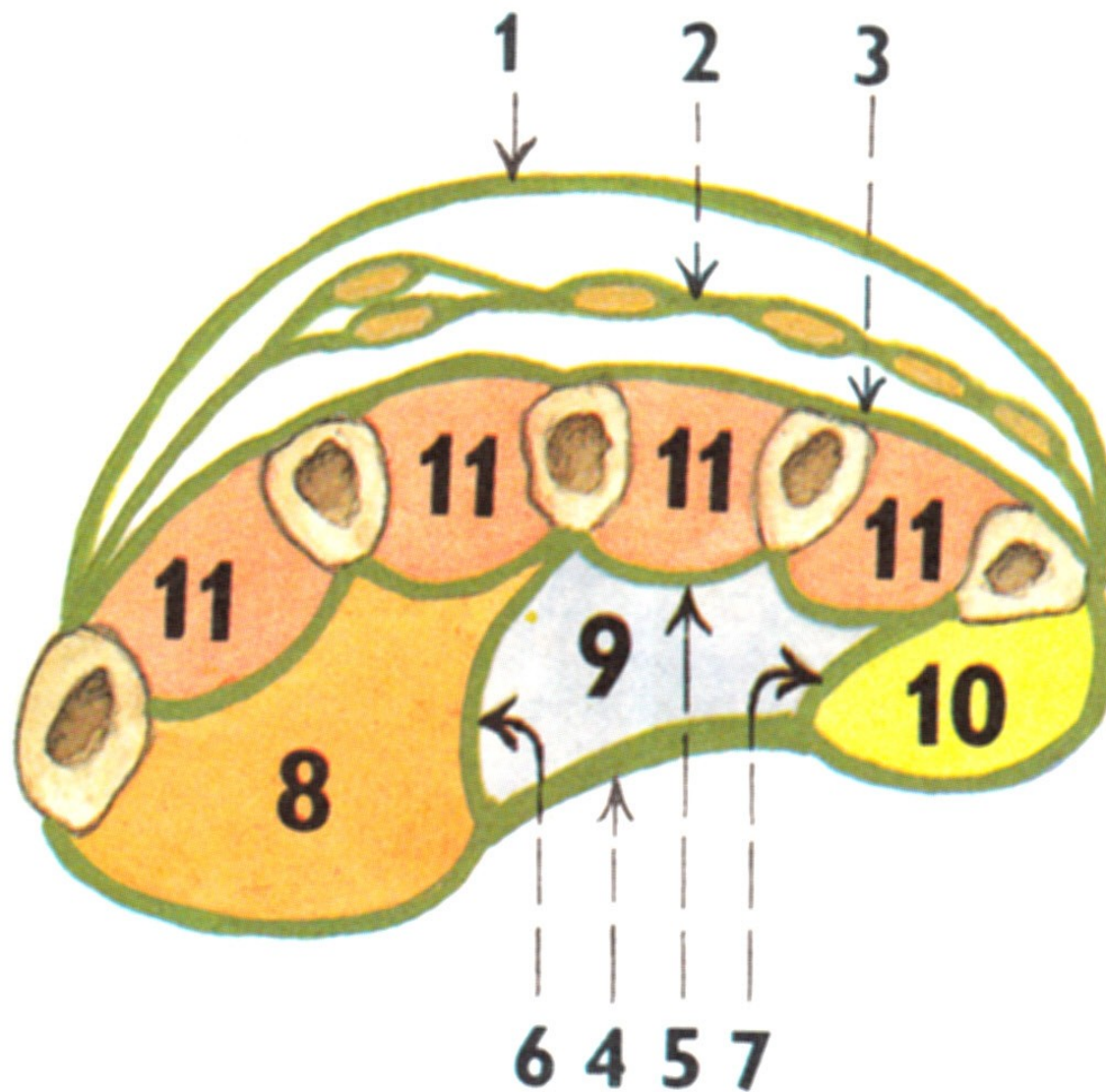


Obr. 13



Obr. 14

Fasciae manus



Pro přednášku byly použity obrázky z publikací:

Moore, K. L. (1992): Clinical oriented anatomy. Third edition.
Williams&Wilkins, A Waverly Company.

Gilroy, A. M. et all. (2009): Atlas of Anatomy. Thieme New York, Stuttgart.

Putz, R. (2008):
Atlas of Human Anatomy Sobotta. Elsevier Books.

Platzer, W., Kahle, W., Leonhardt H. (1992):
**Locomotor system. Georg Thieme Verlag, Stuttgart,
New York, 4th edition.**

Čihák, R. (1987): Anatomie 1. Avicenum, Zdravotnické nakladatelství.