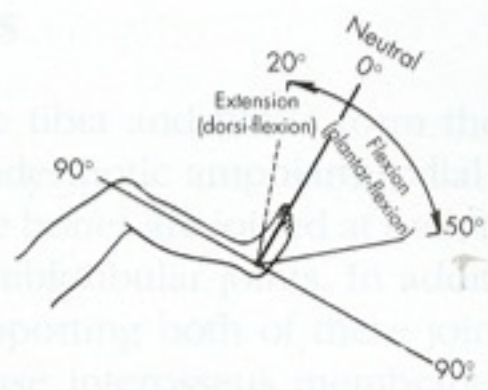


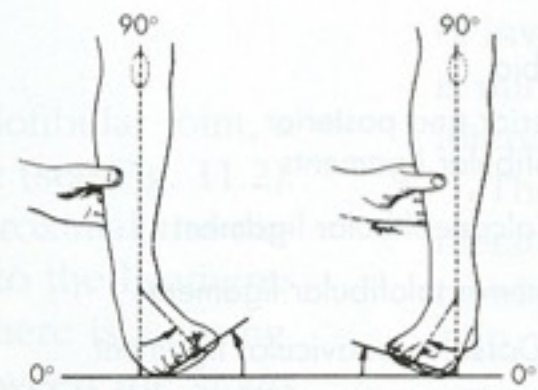
Kineziologie nohy

Mgr. Klára Vomáčková



Ankle joint

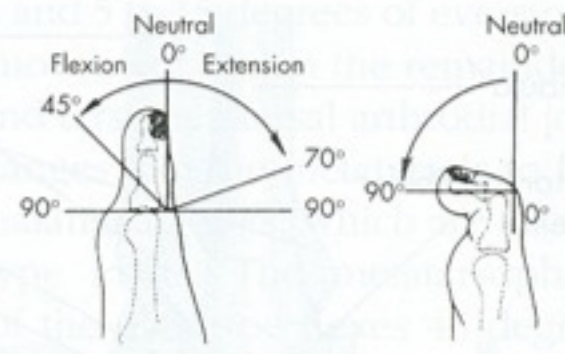
A



Inversion

Eversion

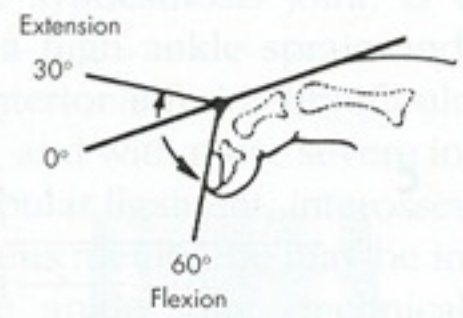
B



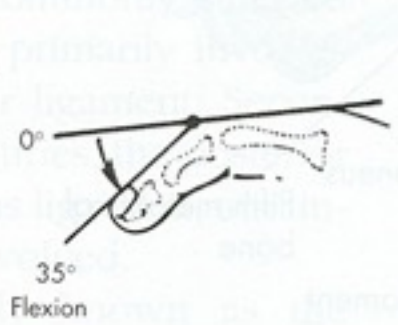
Metatarsophalangeal joint

Interphalangeal joint

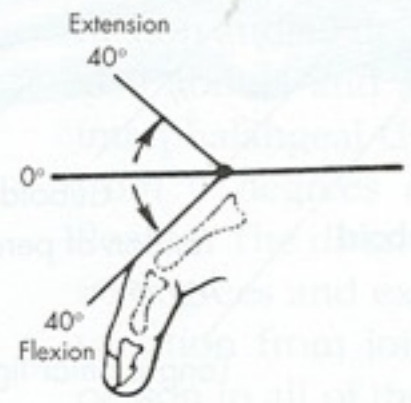
C



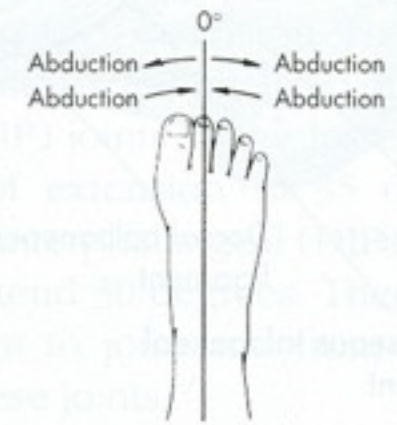
Distal interphalangeal joint



Proximal interphalangeal joint

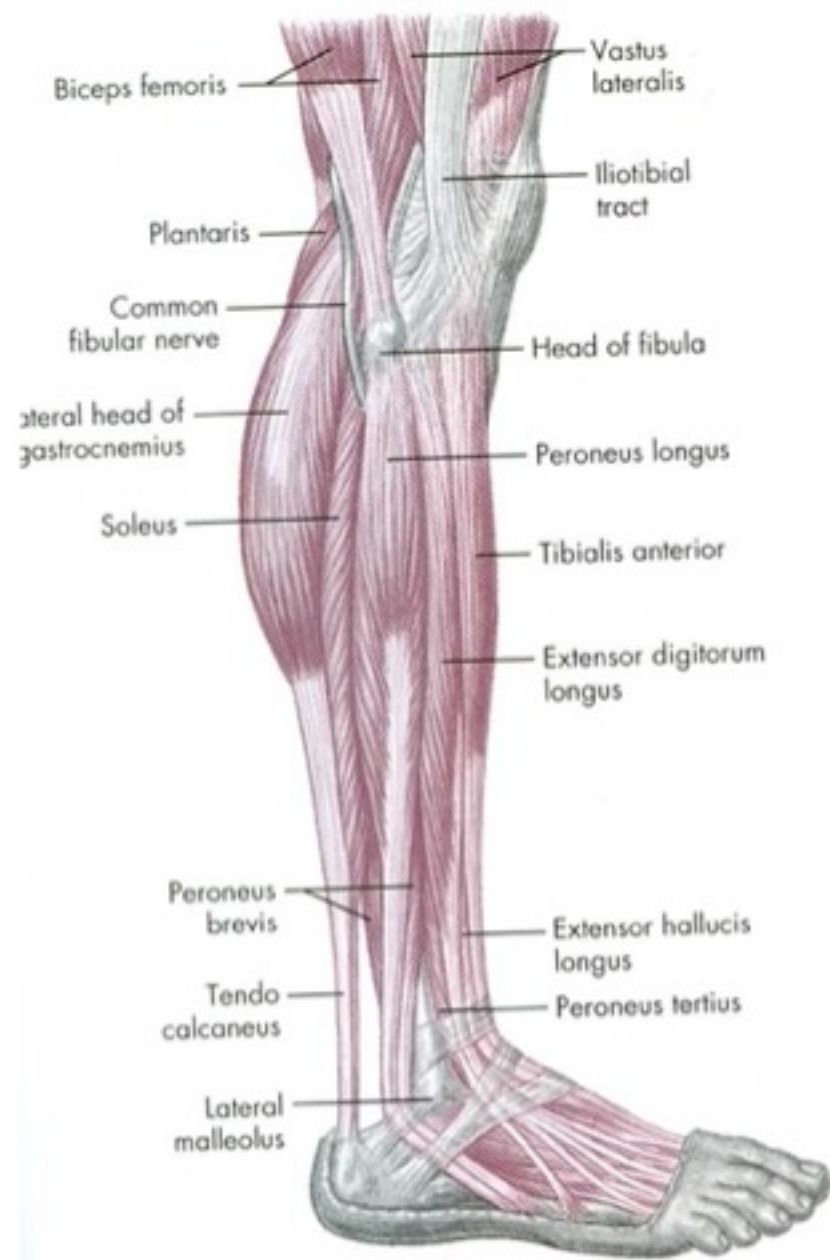


Metatarsophalangeal joint

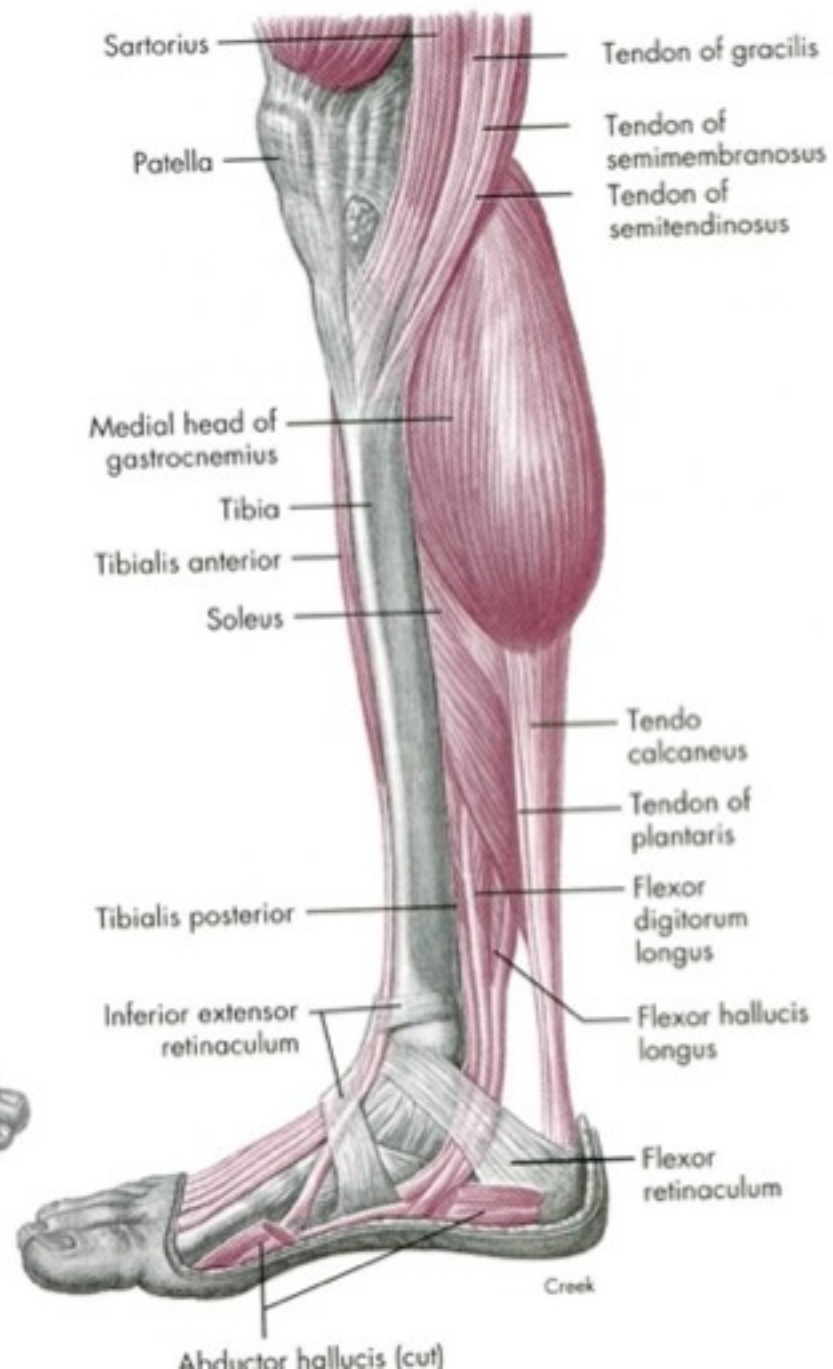


Toe spread

D

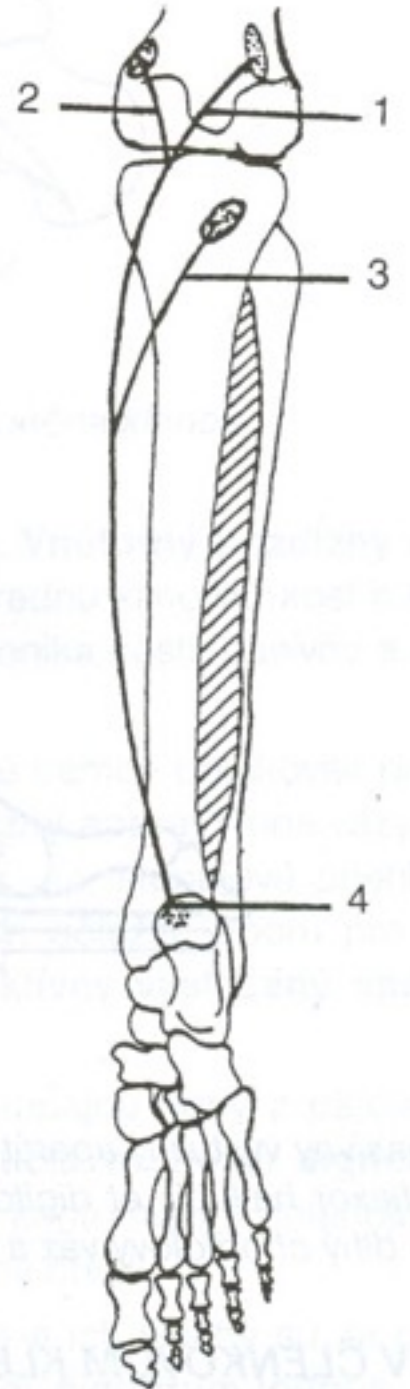
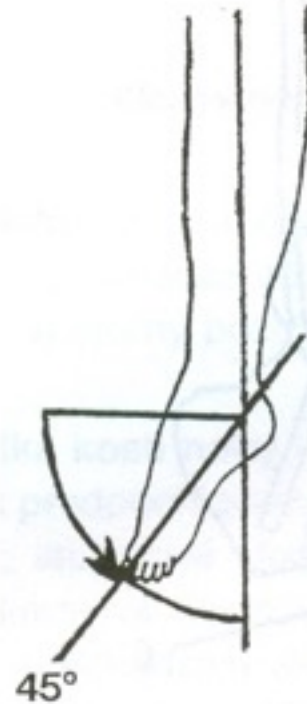

A



Plantární flexe

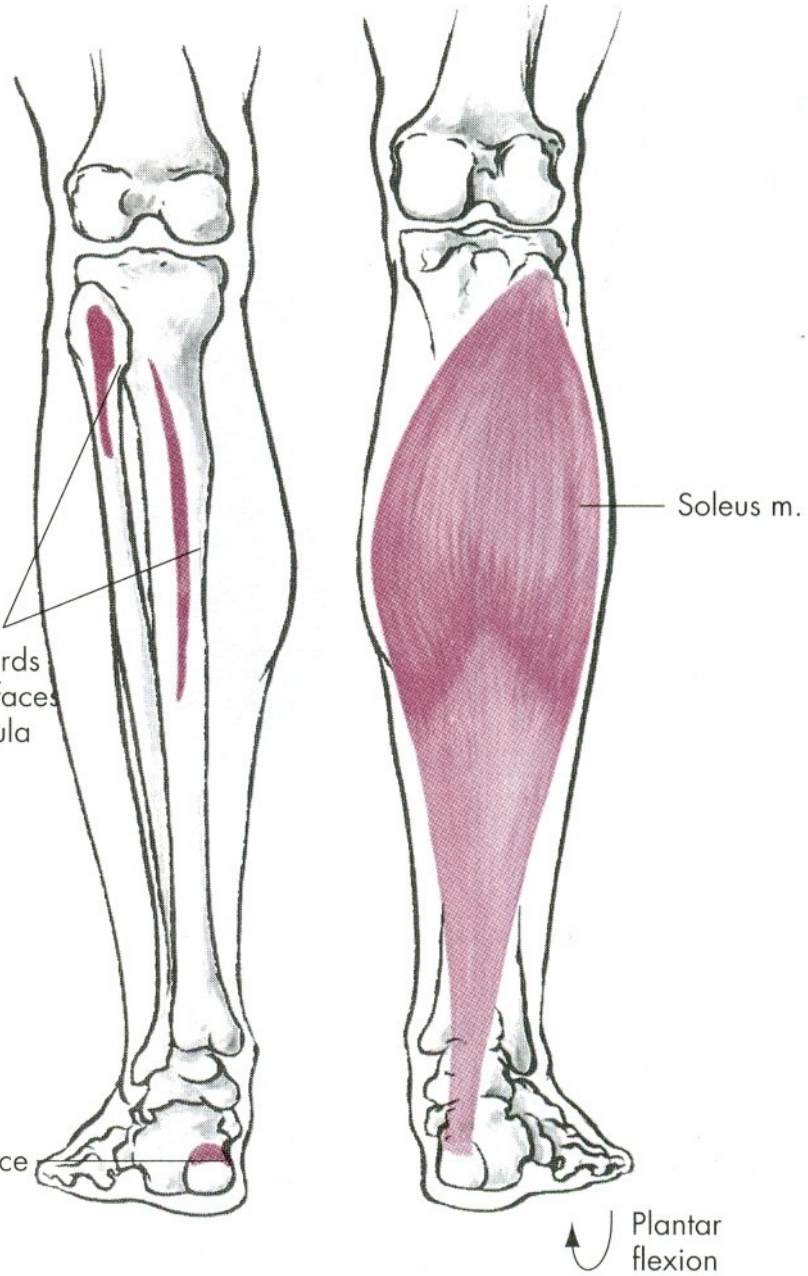
- Triceps surae



cially true
ses up on
y be seen
has exer-
ming and

O, Proximal two-thirds
of posterior surfaces
of tibia and fibula

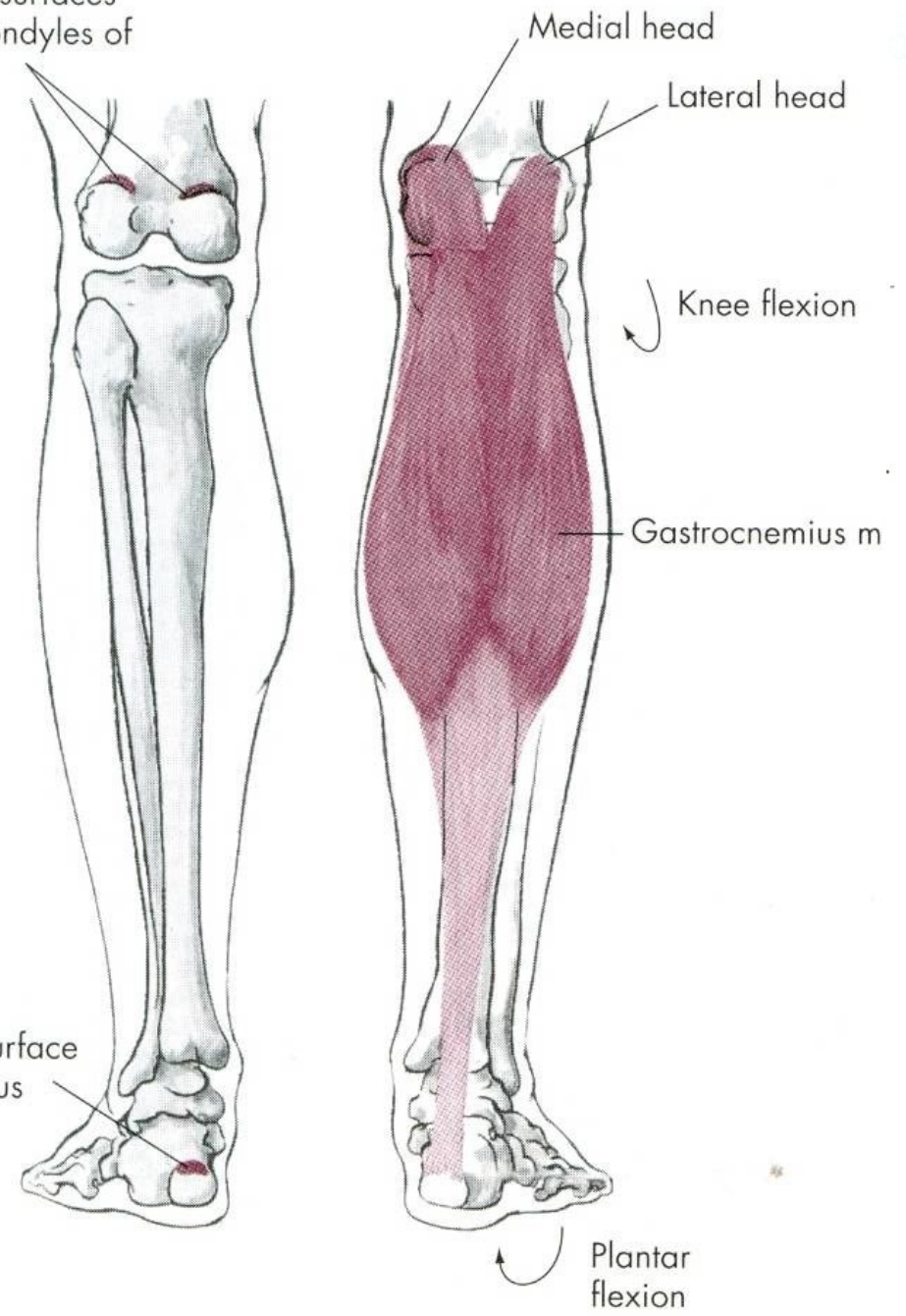
I, Posterior surface
of calcaneus



cially true

O, Posterior surfaces
of two condyles
of femur

I, Posterior surface
of calcaneus

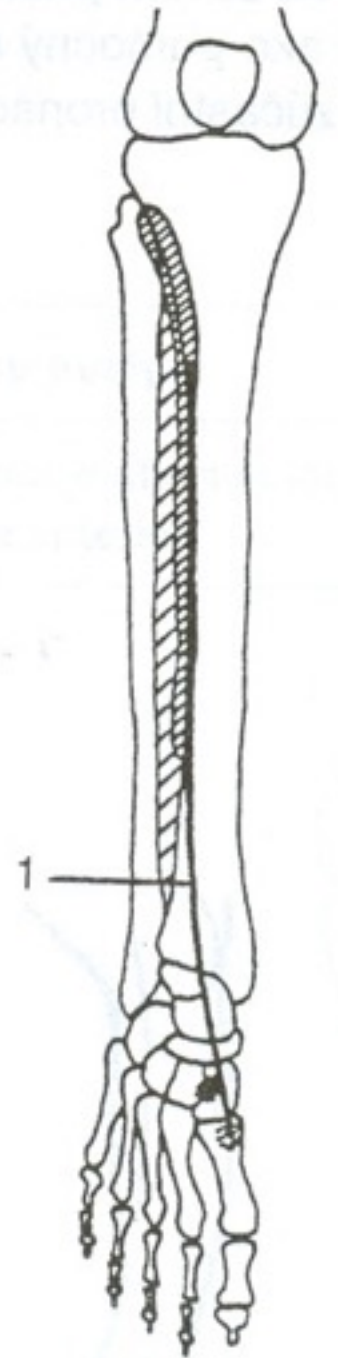
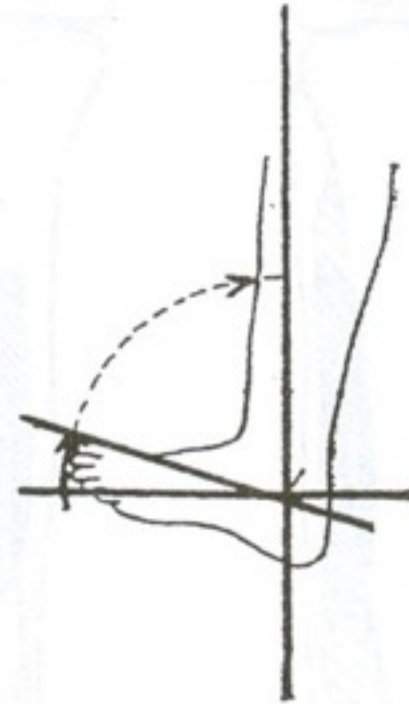


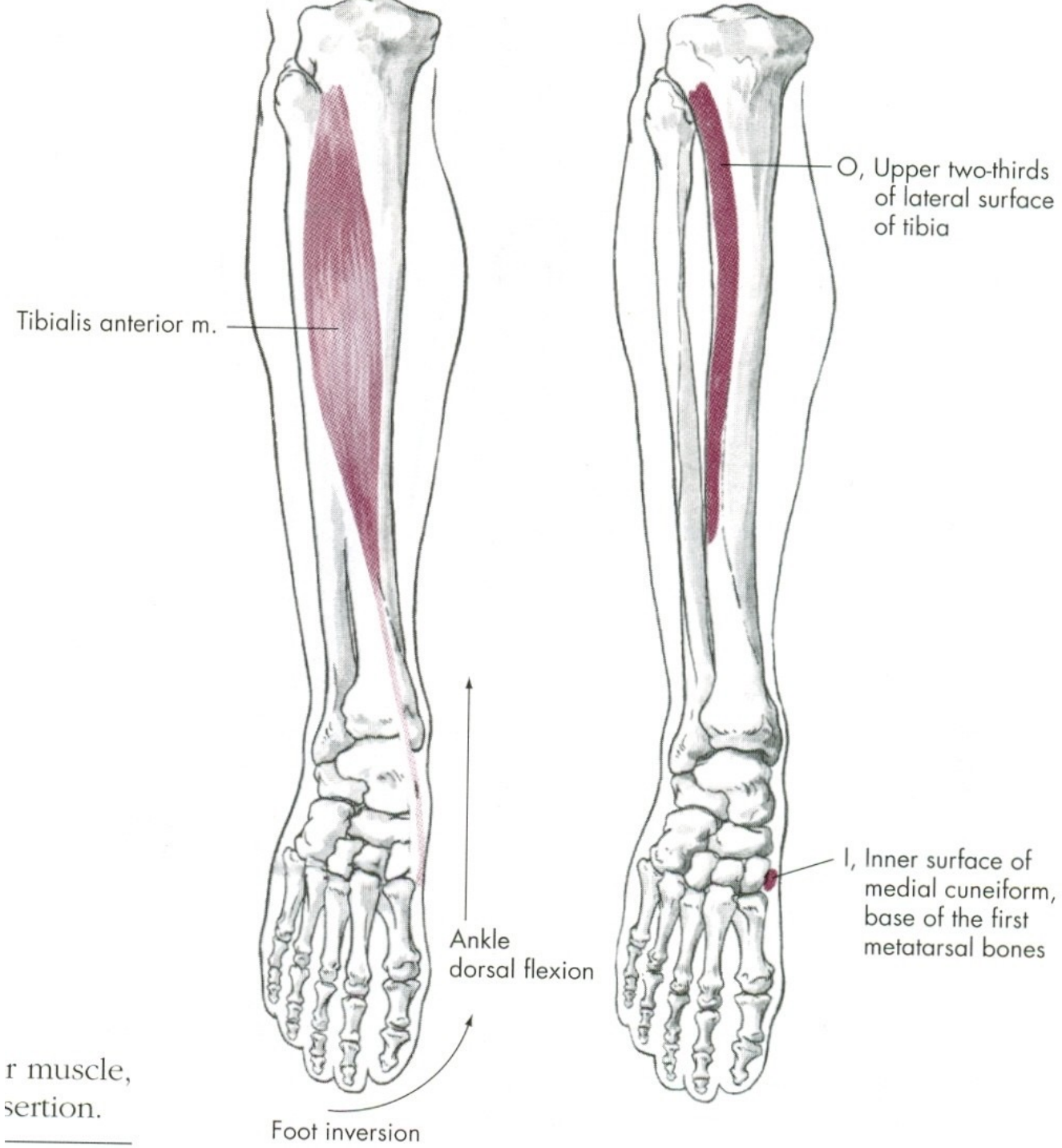
M. Triceps surae

- Z: m. gastrocnemius caput mediale – epicondylus medialis femoris, m.
gastrocnemius caput laterale – epicondylus lateralis femoris, m.
soleus – proximální konec tibie a fibuly
- Ú: tuber calcanei (achilova šlacha)
- I: n. tibialis
- F: KOK – flexe (pouze gastrocnemius), noha – plantární flexe

Dorzální flexe

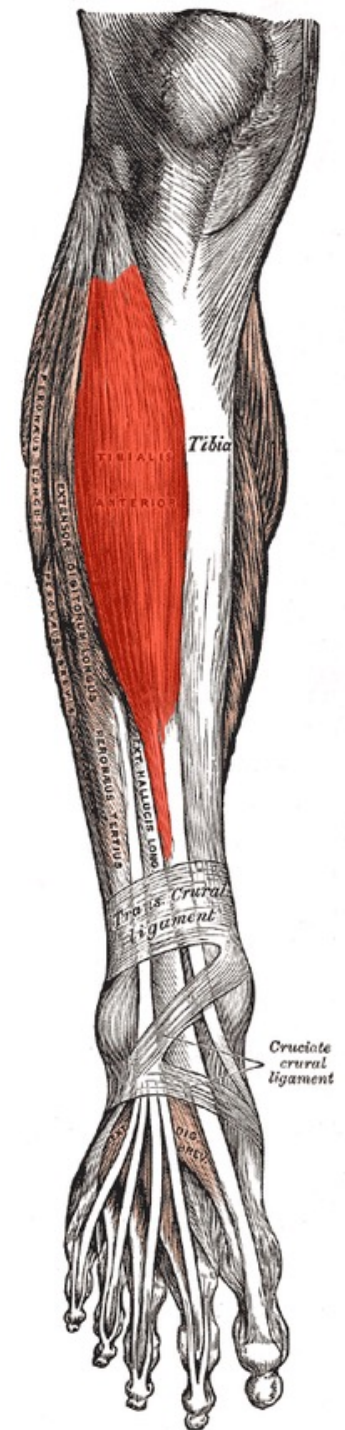
- M. tibialis anterior





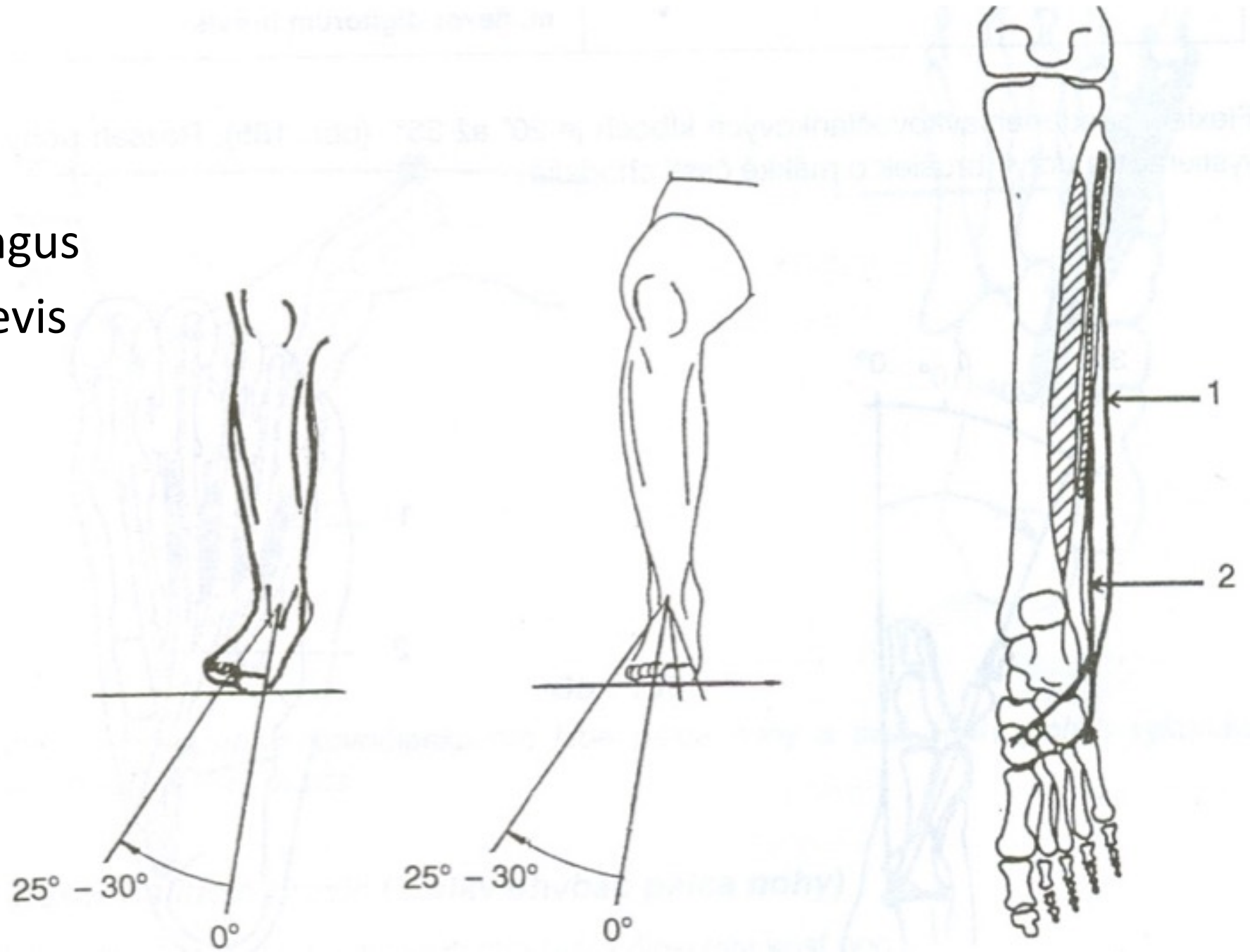
m. Tibialis anterior

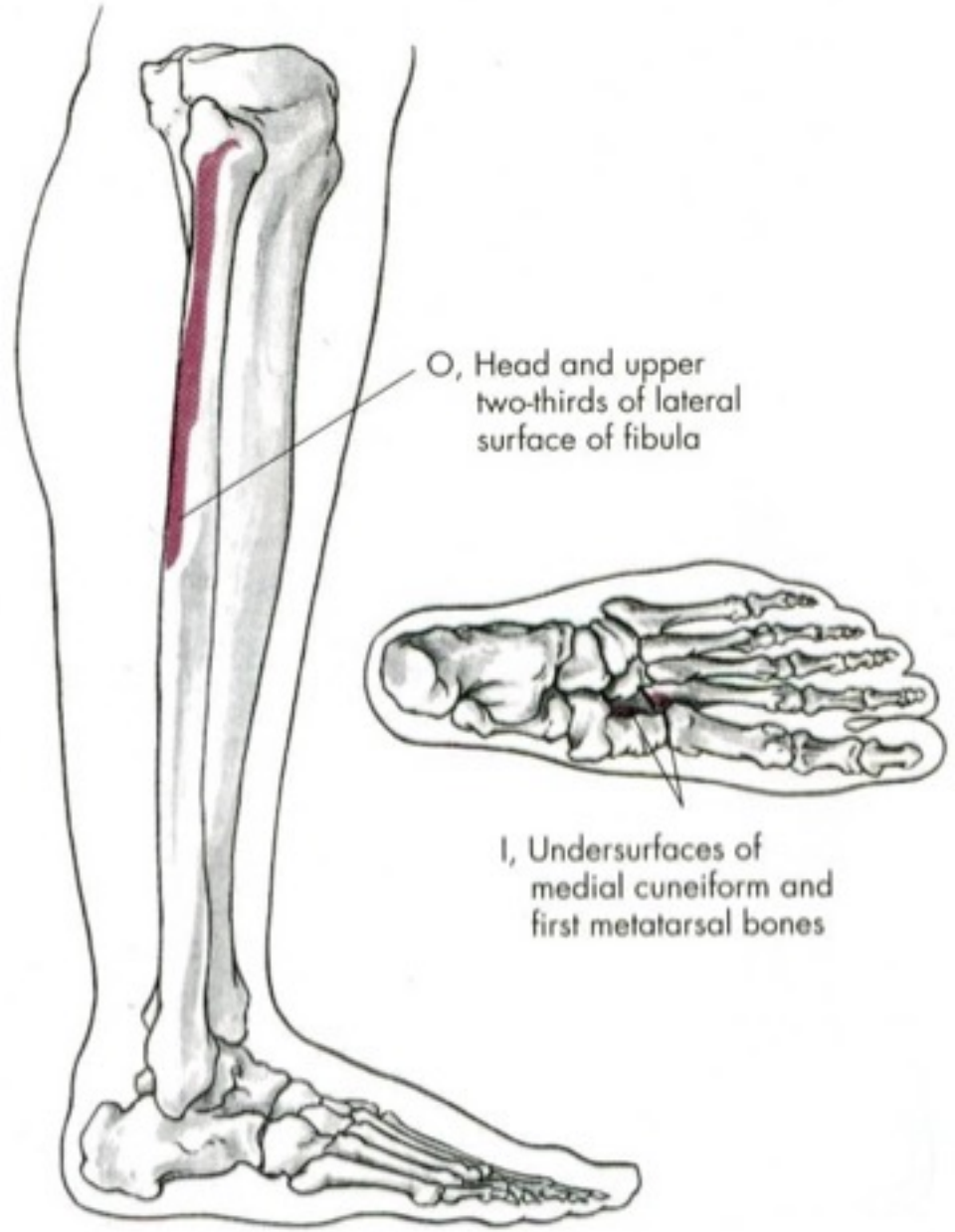
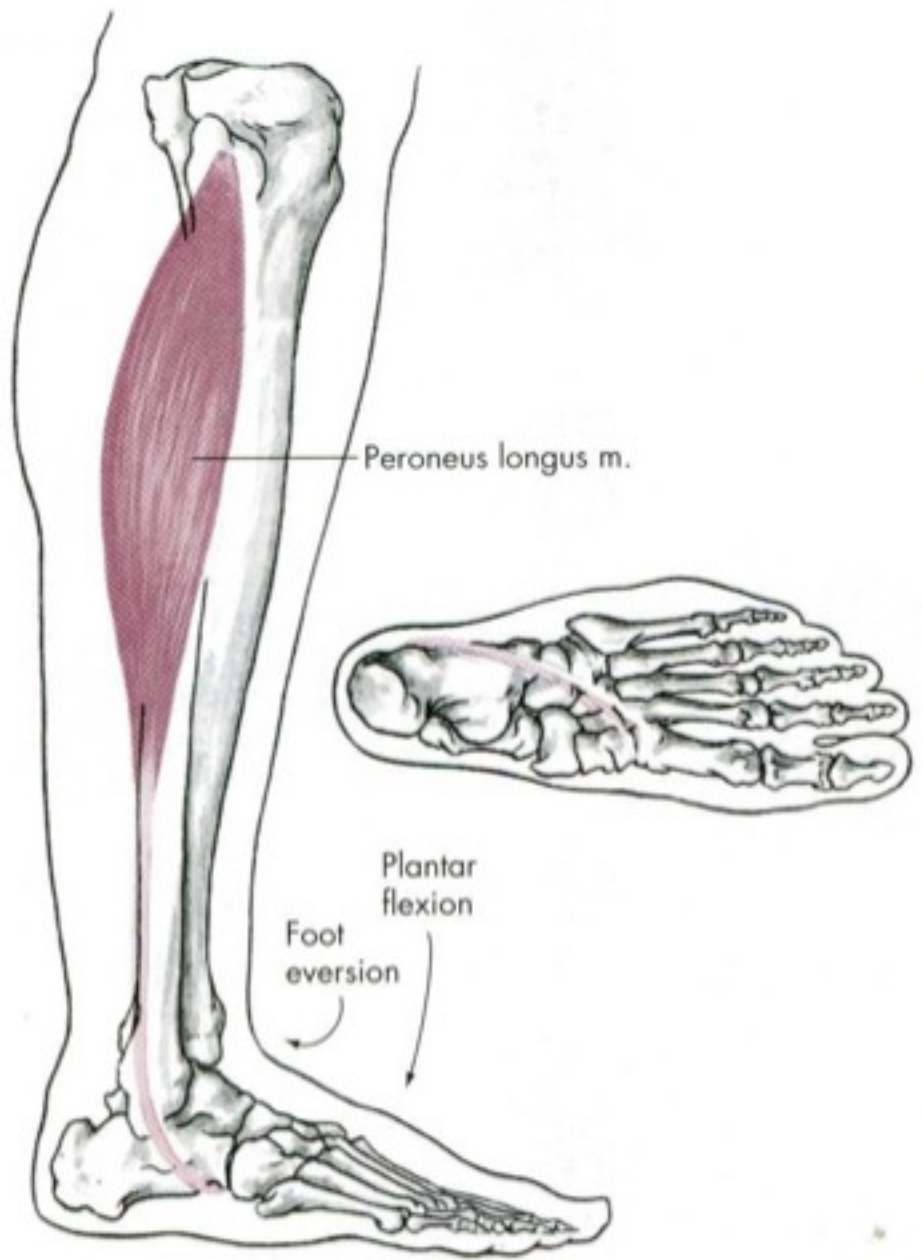
- Z: zevní okraj tibiae, membrana interossea cruris
- Ú: os cuneiforme mediale, baze palcového metatarsu
- I: n. fibularis profundus
- F: supinace, dorzální flexe nohy (příčná klenba nohy)



Everze

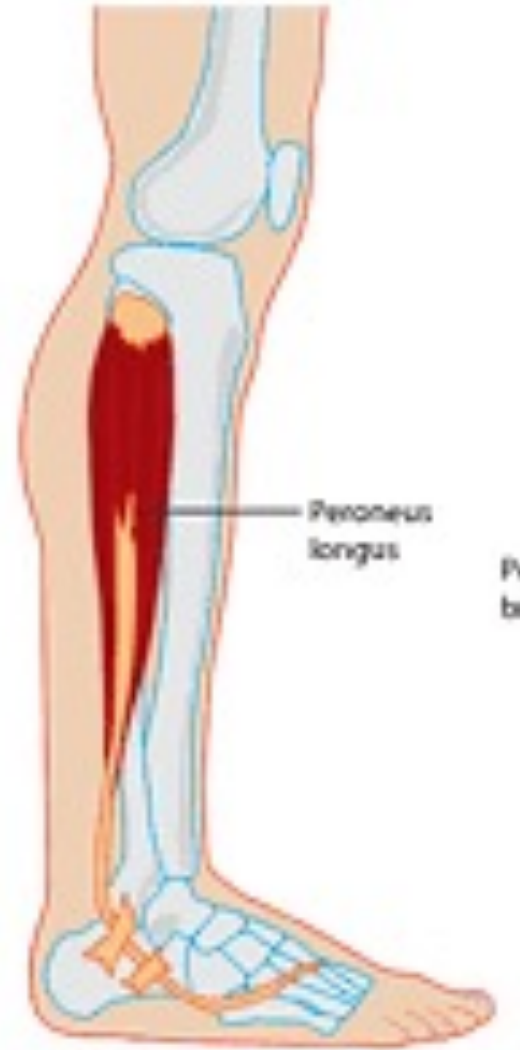
- M. peroneus longus
- M. peroneus brevis

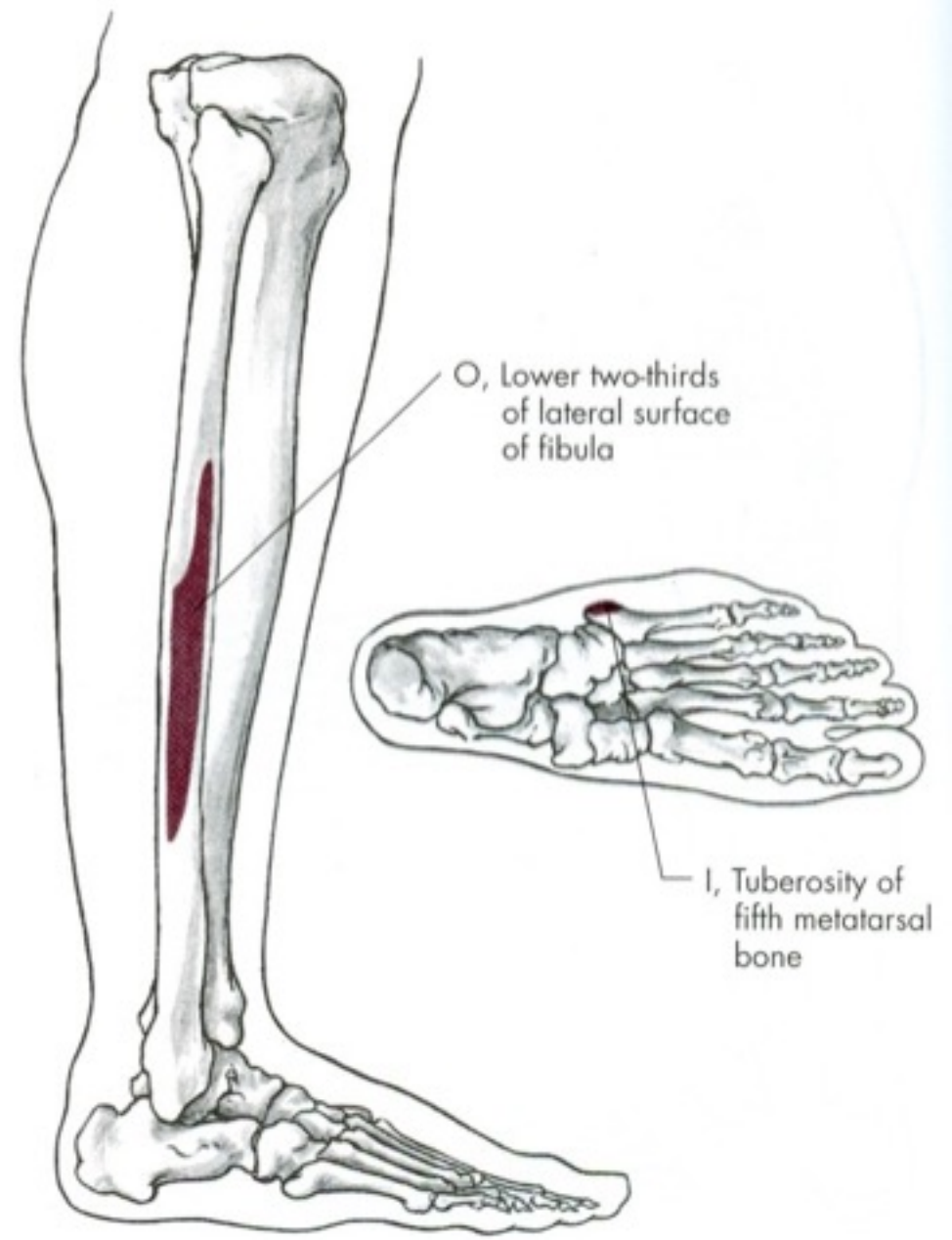
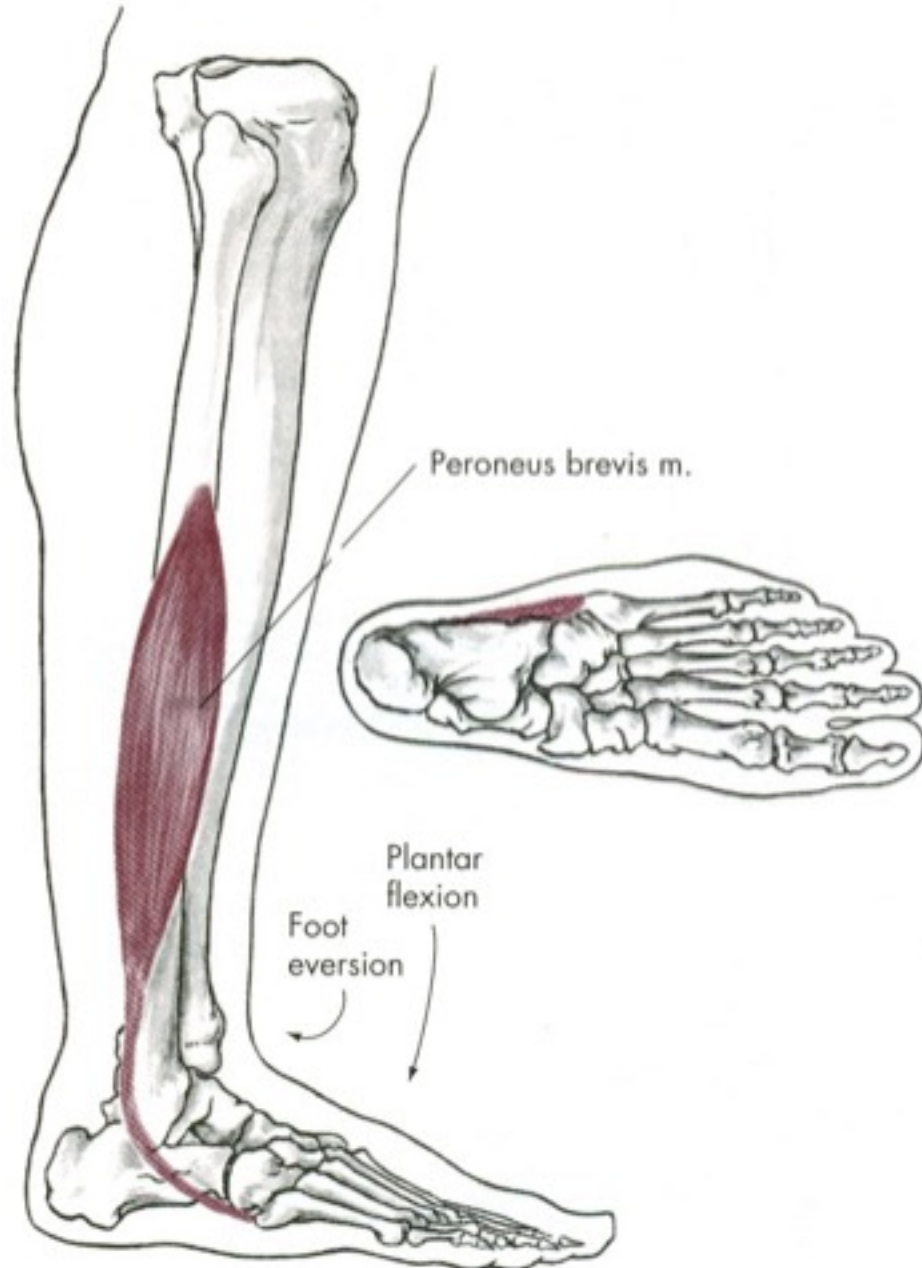




M. Peroneus longus

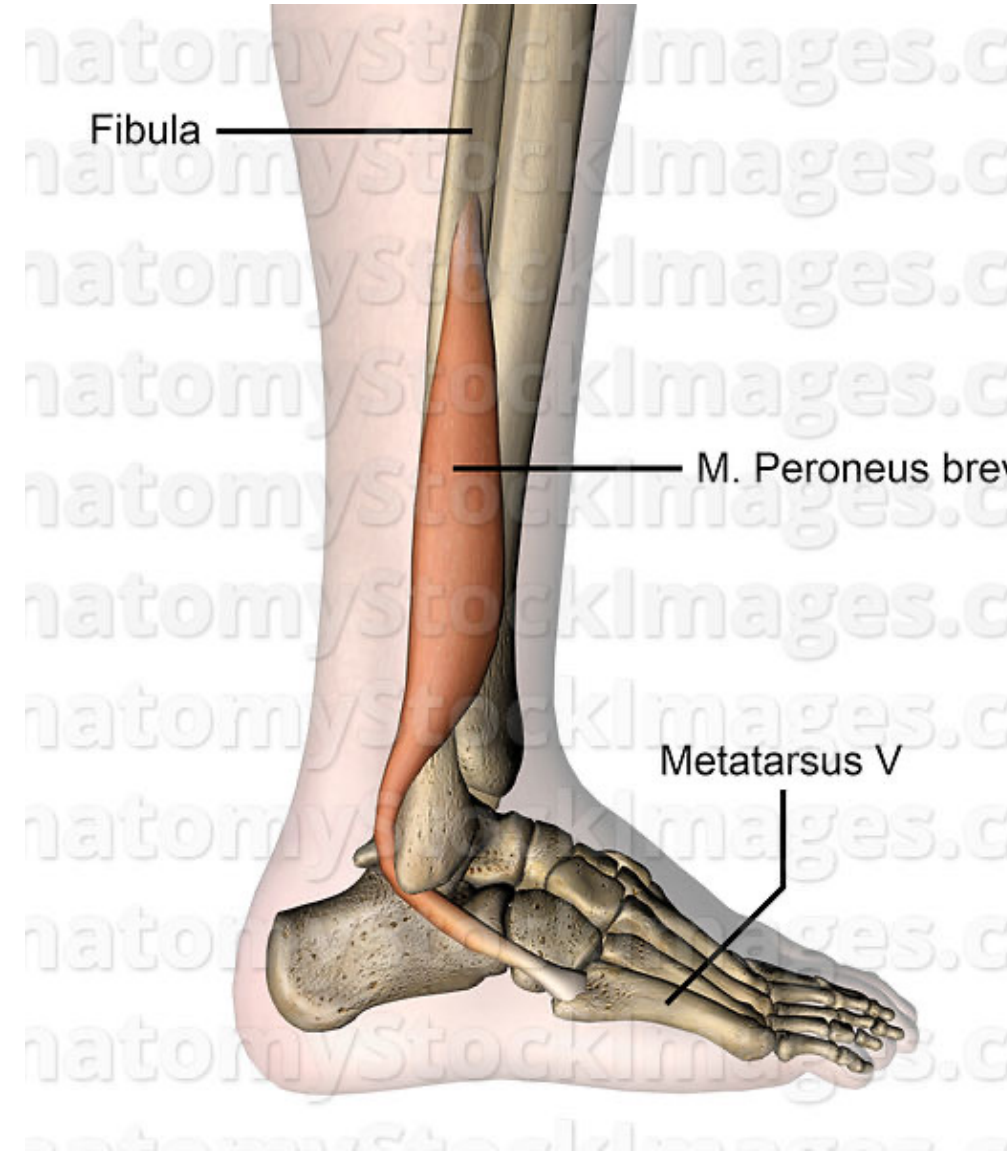
- Z: horní polovina fibuly
- Ú: plantární strana os cuneiforme mediale, bez palcového metatarsu
- I: n. fibularis superficialis
- F: pronace, abdukce, plantární flexe (příčná klenba)





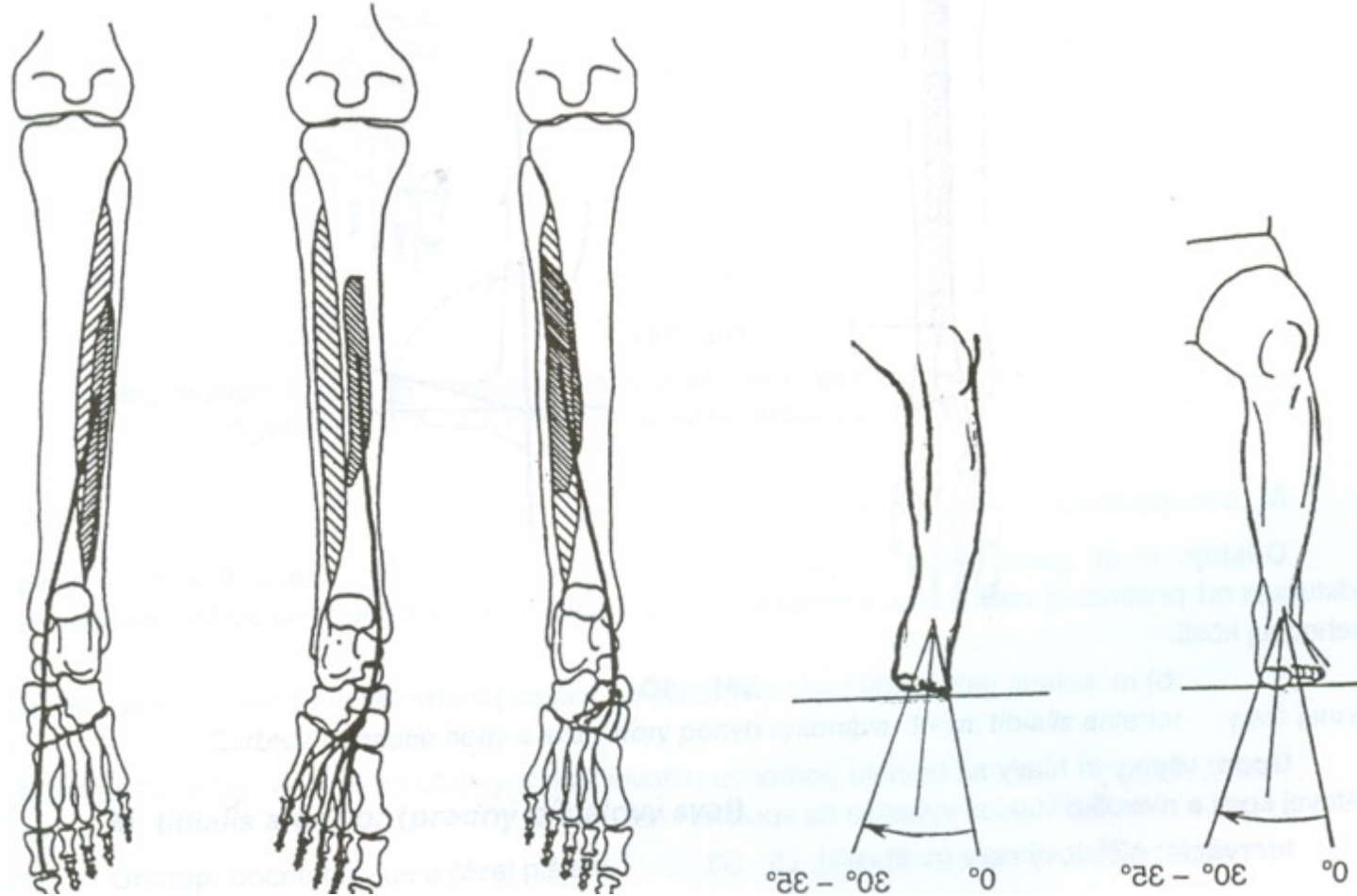
M. Peroneus brevis

- Z: dolní plocha fibuly
- Ú: tuberositas metatarsi quinti
- I: n. fibularis superficialis
- F: pronace, abdukce, plantární flexe



Inverze

- M. tibialis posterior
- M. flexor digitorum longus
- M. flexor hallucis longus

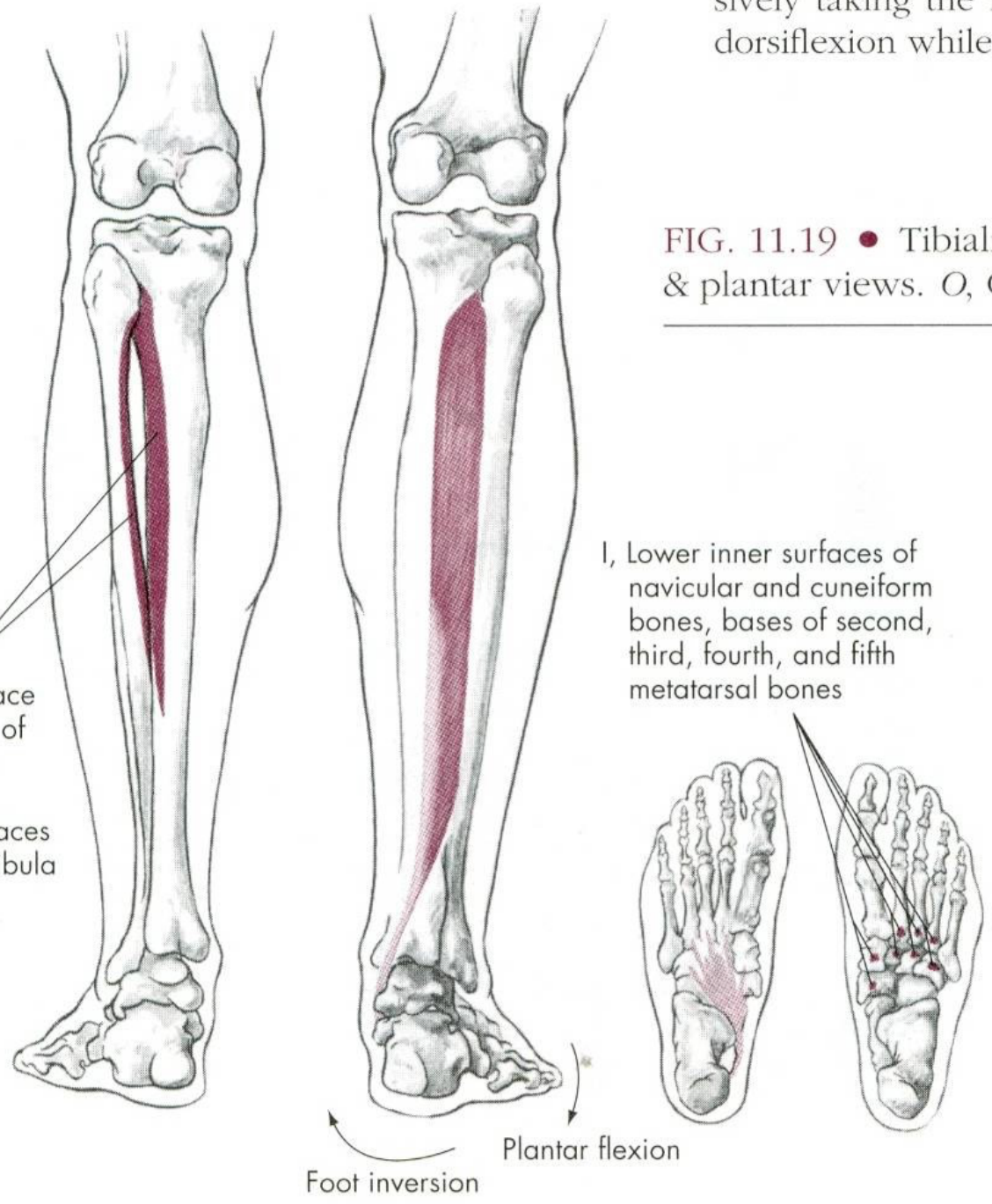


sively taking the 1
dorsiflexion while

FIG. 11.19 • Tibiali
& plantar views. O, C

O, Posterior surface
of upper half of
interosseous
membrane,
adjacent surfaces
of tibia and fibula

I, Lower inner surfaces of
navicular and cuneiform
bones, bases of second,
third, fourth, and fifth
metatarsal bones

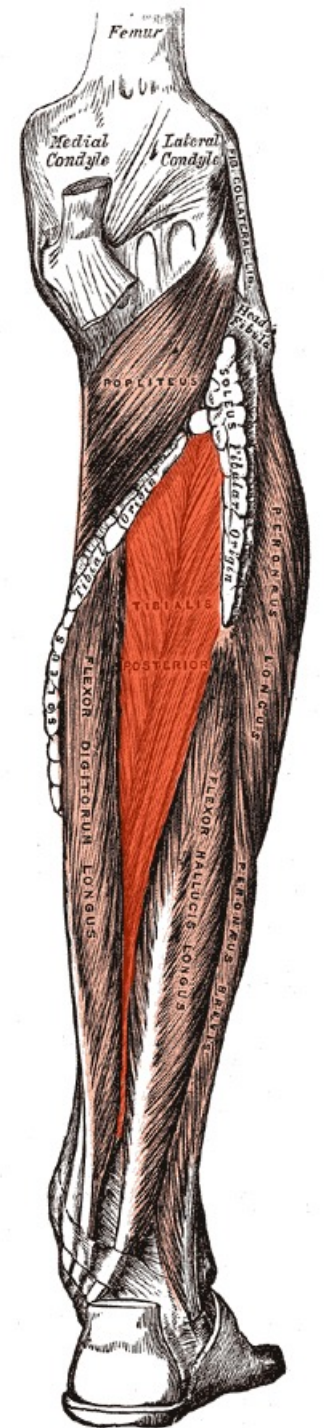


Foot inversion

Plantar flexion

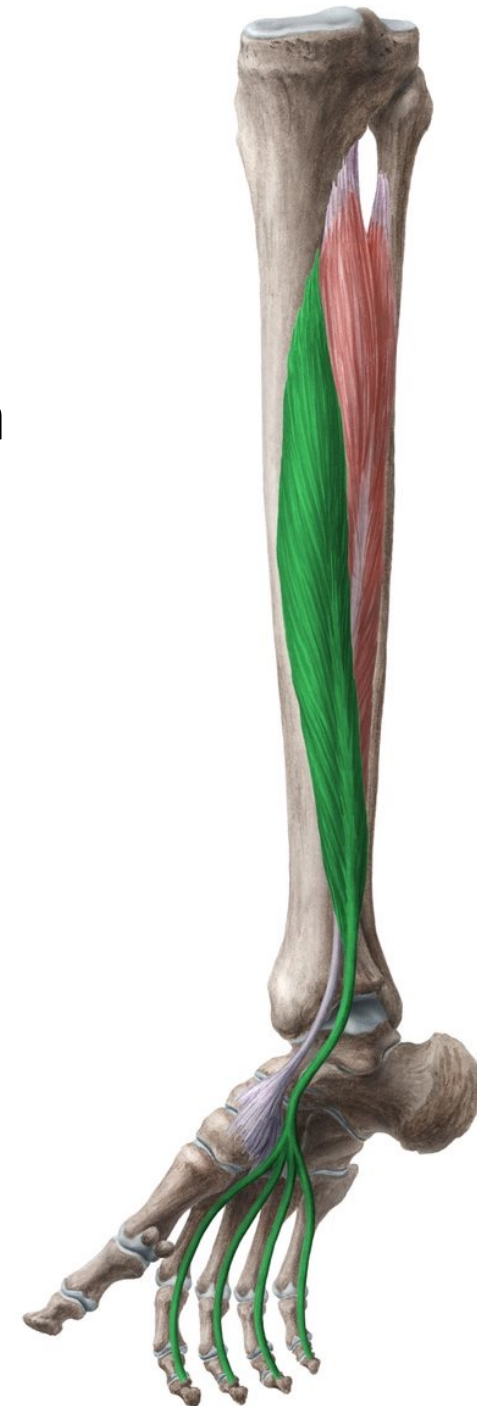M. Tibialis posterior

- Z: membrána interossea cruris, okraje fibuly a tibie
- Ú: tuberositas ossis navicularis, spodní plocha klínových kostí
- I: n. tibialis
- F: plantární flexe nohy, podpora podélné klenby nohy



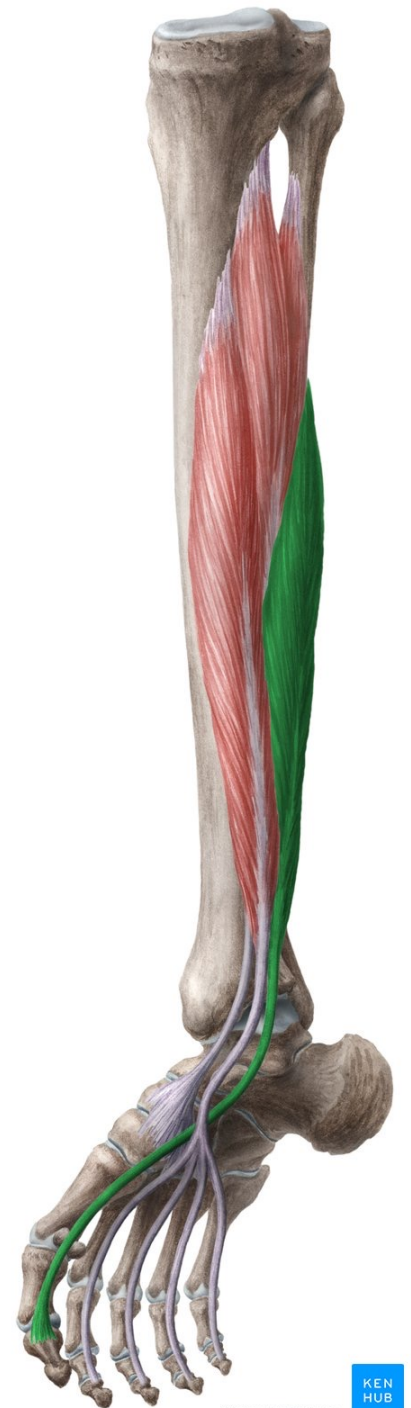M. Flexor digitorum longus

- Z: dolní část zadní strany tibiae, přilehlá membrána interossea curis
- Ú: distální články 2.-5. prstu
- I: nervus tibialis
- F: flexe nohy i prstů



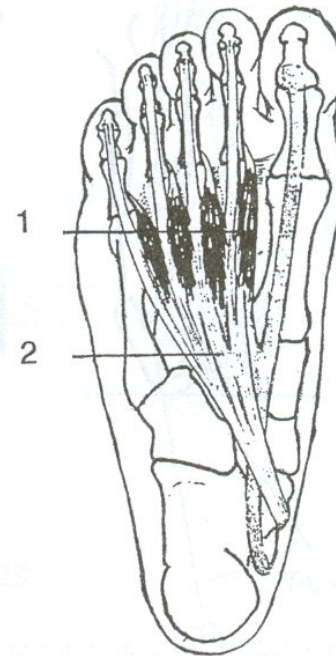
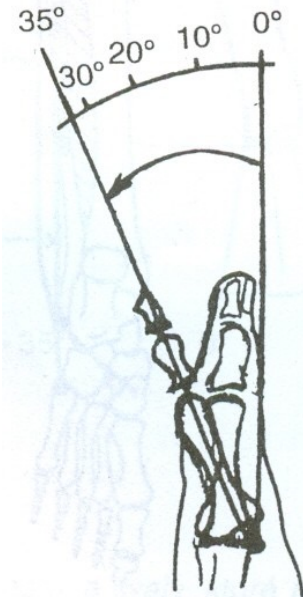
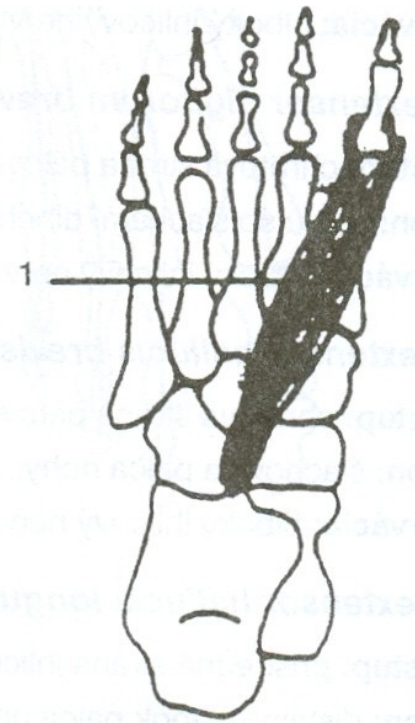
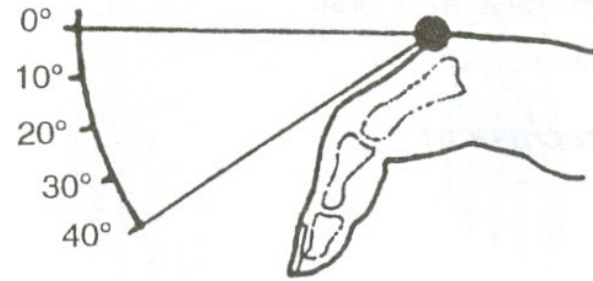
M. Flexor hallucis longus

- Z: dolní část zadní strany fibuly, přilehlá membrána interossea cruris
- Ú: plantární strana distálního článku palce
- I: n. tibialis
- F: flexe palce, pomocná flexe nohy



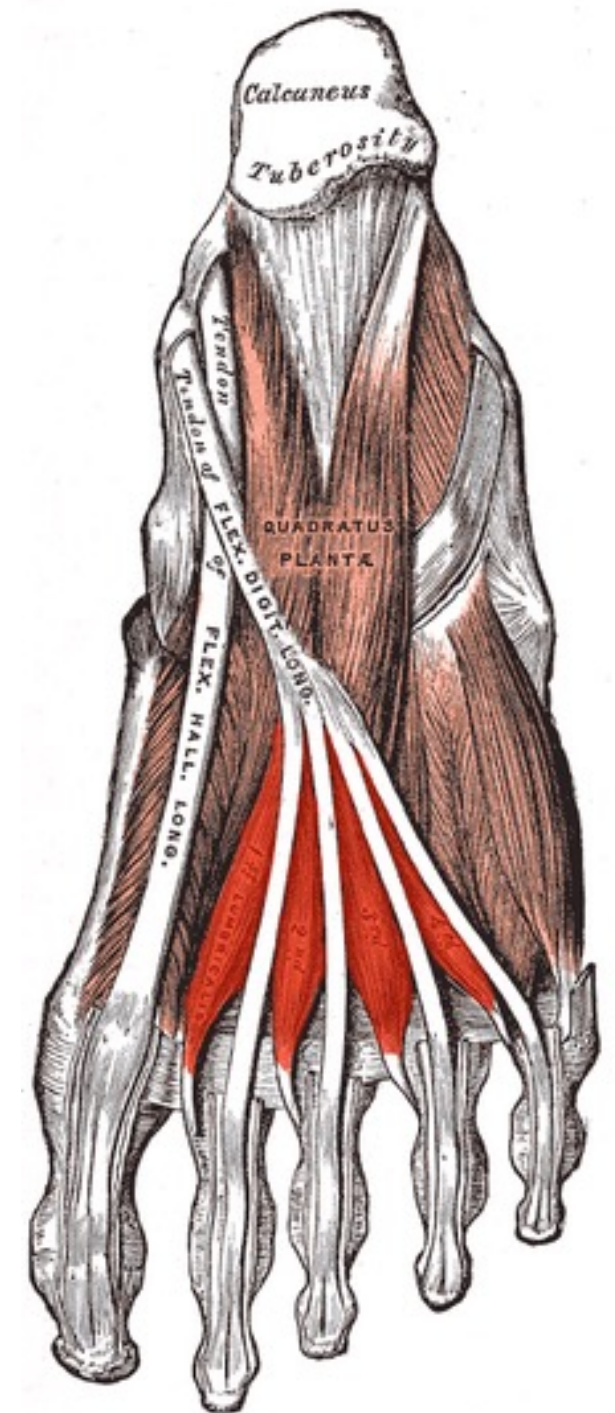
Flexe prstů

- Mm. Lumbricales
- M. flexor hallucis brevis et longus
- M. flexor digitorum brevis et longus



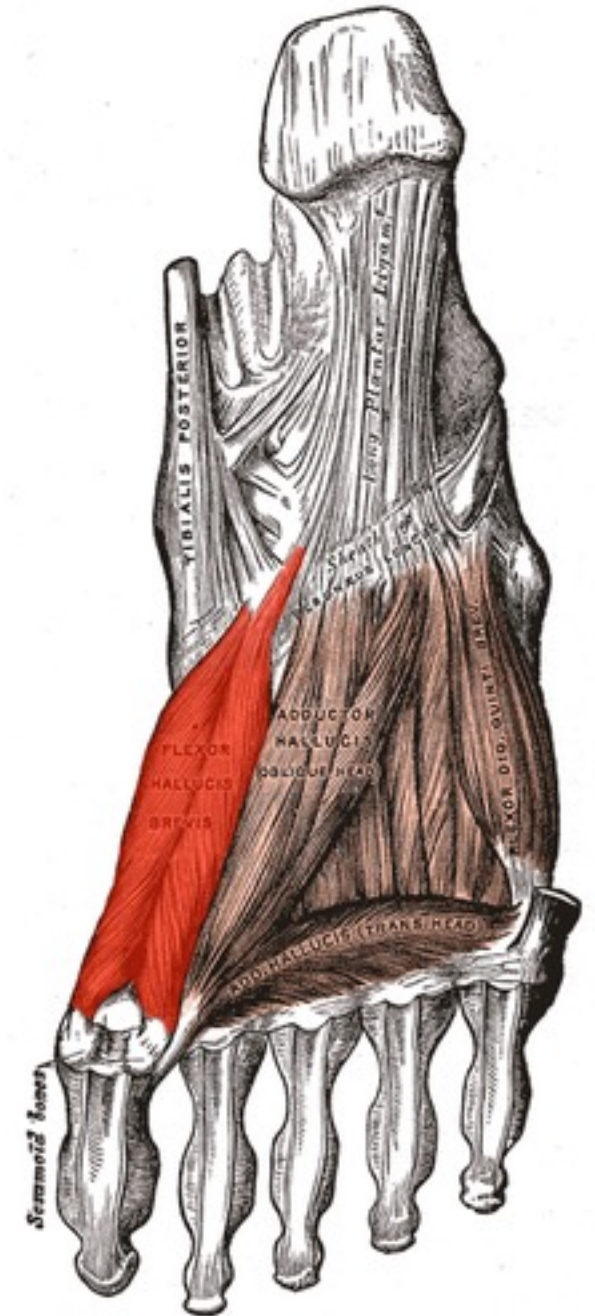
Mm. lumbricales

- Z: mediálně od šlach musculus flexor digitorum longus
- Ú: dorsální aponeurosa 2.-5. prstu
- I: n. plantaris medialis a medialis
- F: flexe metatarsofalangeálních kloubů, extenze interfalangeálních kloubů



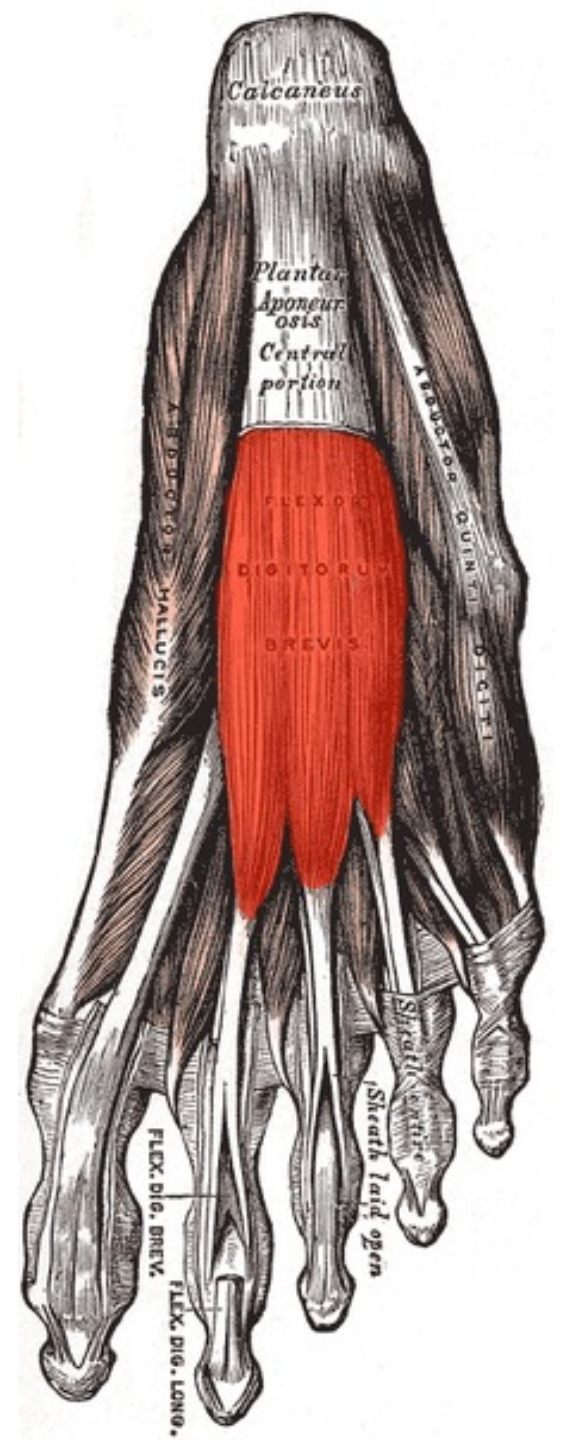
M. Flexor hallucis brevis


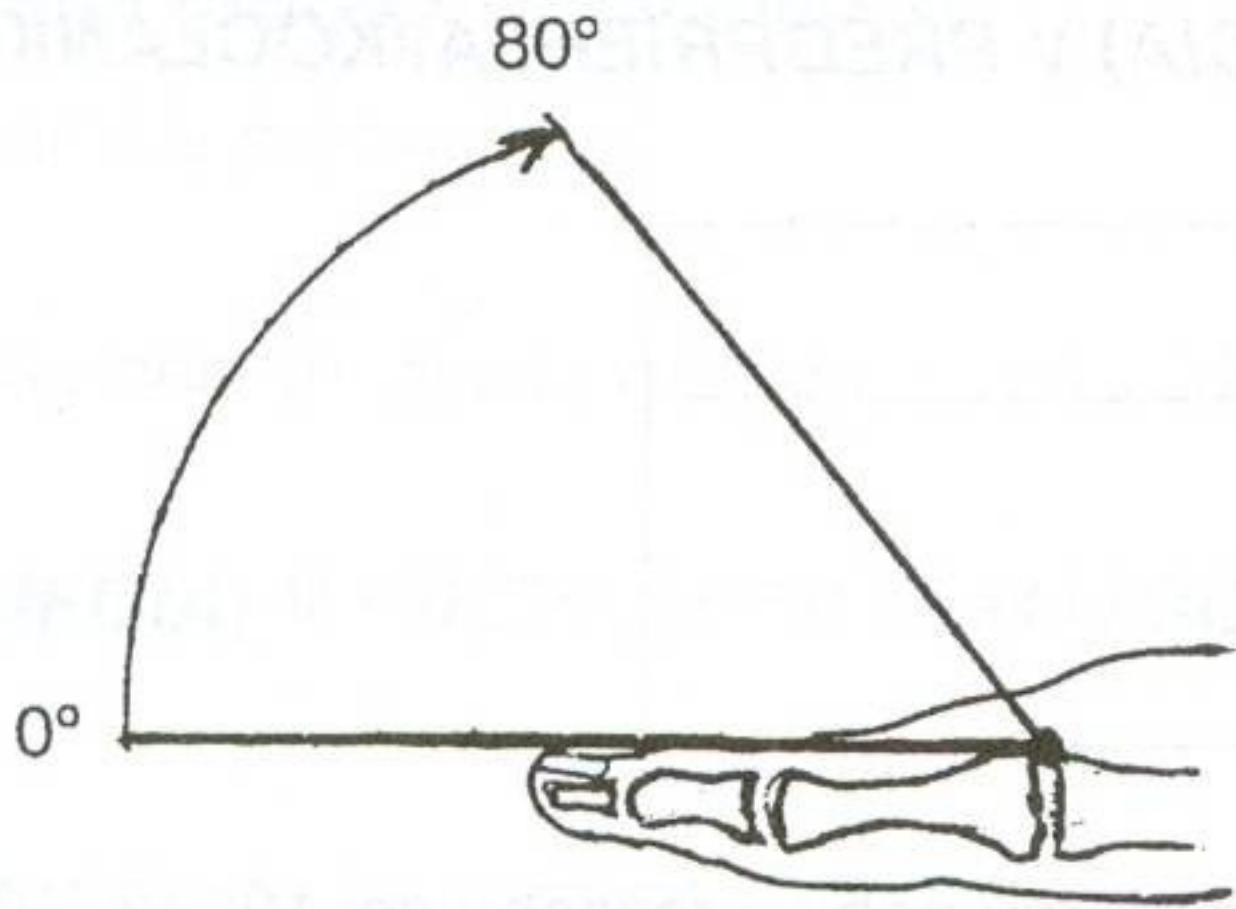
- Z: plantární plocha ossa cuneiforma, os naviculare, os cuboideum
- Ú: caput mediale – os sesamoideum mediale, přilehlá část basis phalangis proximální hallucis, caput laterale – os sesamoideum laterale, přilehlá část basis phalangis proximalis hallucis
- I: caput mediale – n. plantaris medialis, caput laterale – n. plantaris lateralis nebo medialis (oba z větve nervus tibialis)
- F: flexe palce v metatarsofalangovém kloubu



M. Flexor digitorum brevis

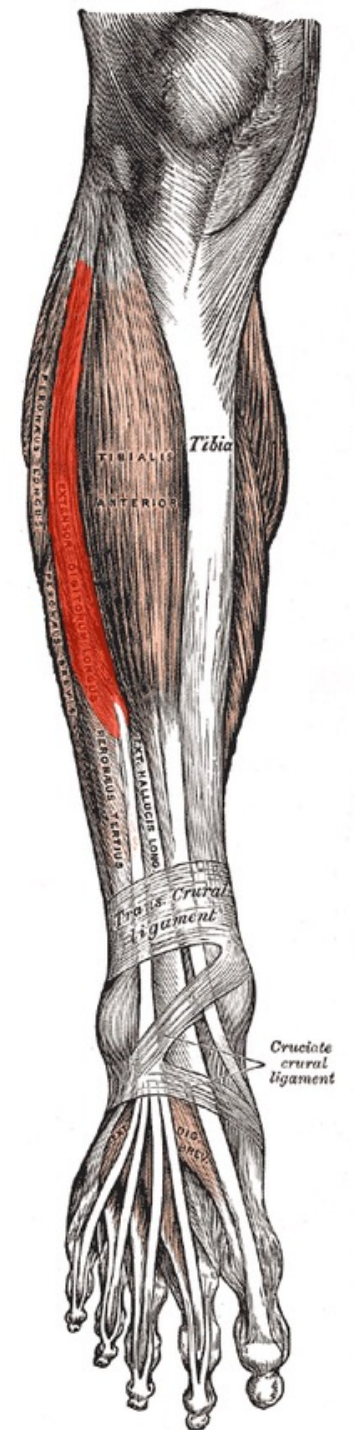
- Z: tuber calcanei, plantární aponeurosa
- Ú: šlachami na 2.-5. prst na plochu středních článků prstů
- I: n. plantaris medialis
- F: flexe proximálních interfalangeálních kloubů 2.-5. prstu





M. Extensor digitorum longus

- Z: Condylus lateralis tibiae fibula, membrána interossea cruris
- Ú: dorzální aponeuróza 2.-5. prstu, base malíkového metatarsu
- I: n. fibularis profundus
- F: pronace, dorzální flexe nohy, extenze prstů



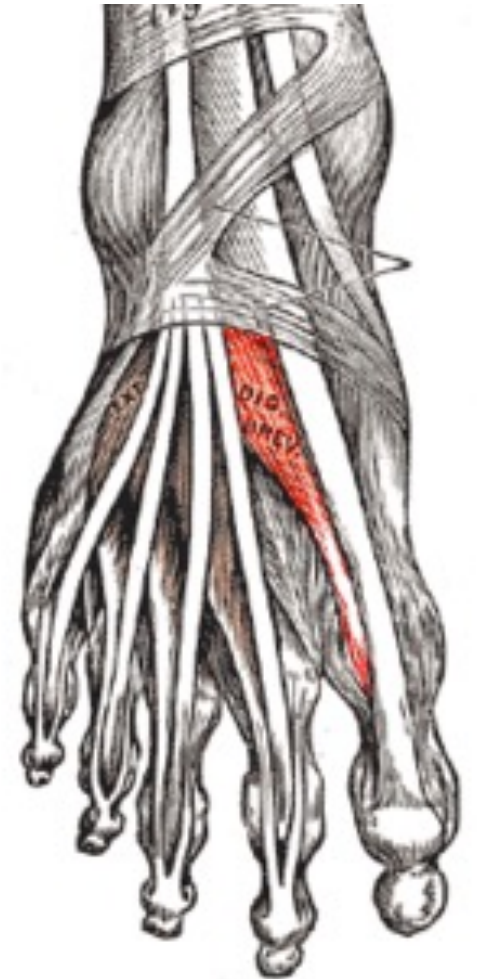M. Extensor hallucis longus

- Z: mediální plocha fibuly, membrána interossea cruris
- Ú: distální článek palce
- I: n. fibularis profundus
- F: extenze palce, dorzální flexe nohy



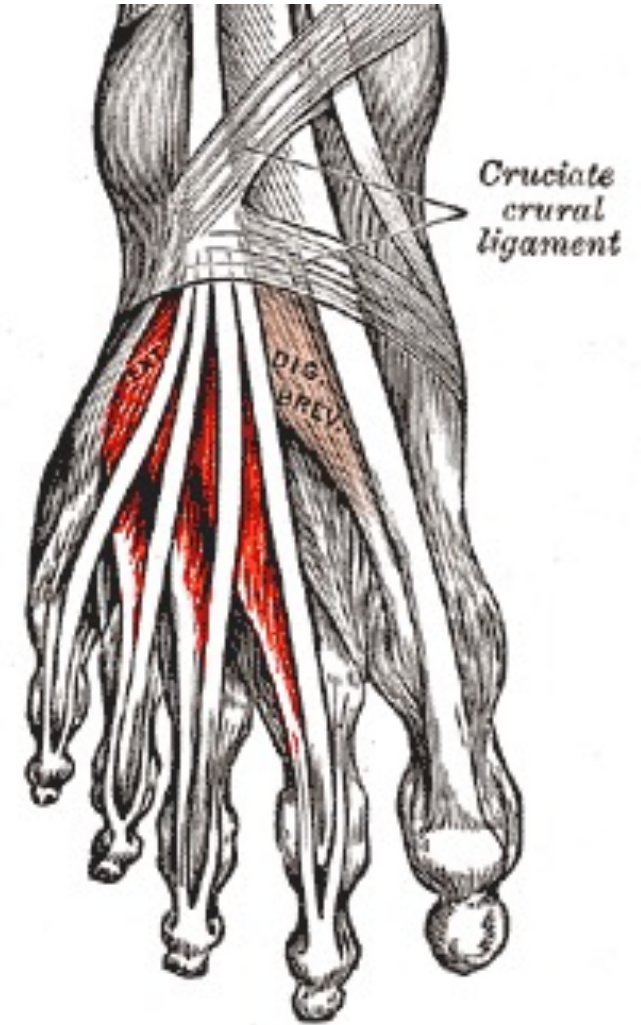
M. Extensor hallucis brevis

- Z: hřbetní strana calcaneu přilehlé vazy tarzální kosti
- Ú: dorzální aponeuróza palce
- I: nervus fibularis profundus
- F: extenze metatarzofalangeálních i interfalangových kloubů palce



M. Extensor digitorum brevis

- Z: hřbetní strana calcaneu přilehlé vazy tarzu
- Ú: dorzální aponeuróza 2.-4. prstu
- I: n. fibularis profundus
- F: extenze MP a IP kloubů 2.-4. prstu



Dotazy

Děkuji za pozornost