

DIGESTIVE SYSTEM I.

ORAL CAVITY

GASTROINTESTINAL TRACT – GIT (APPARATUS DIGESTORIUS)

Oral cavity (Cavitas oralis)

Pharynx

Oesophagus

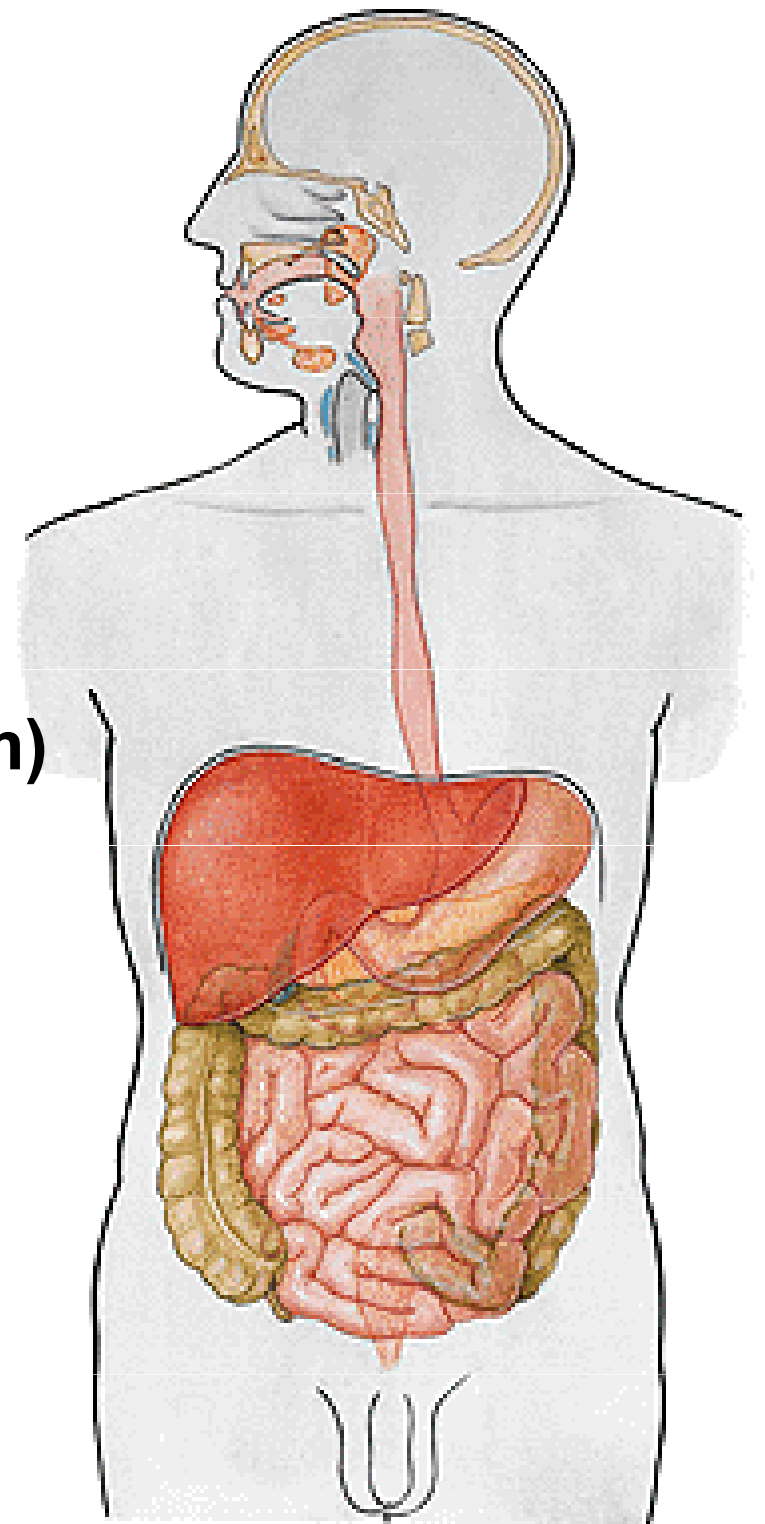
Stomach (Ventriculus)

Small intestine (Intestinum tenue)

Large intestine (Intestinum crassum)

Liver (Hepar)

Pancreas

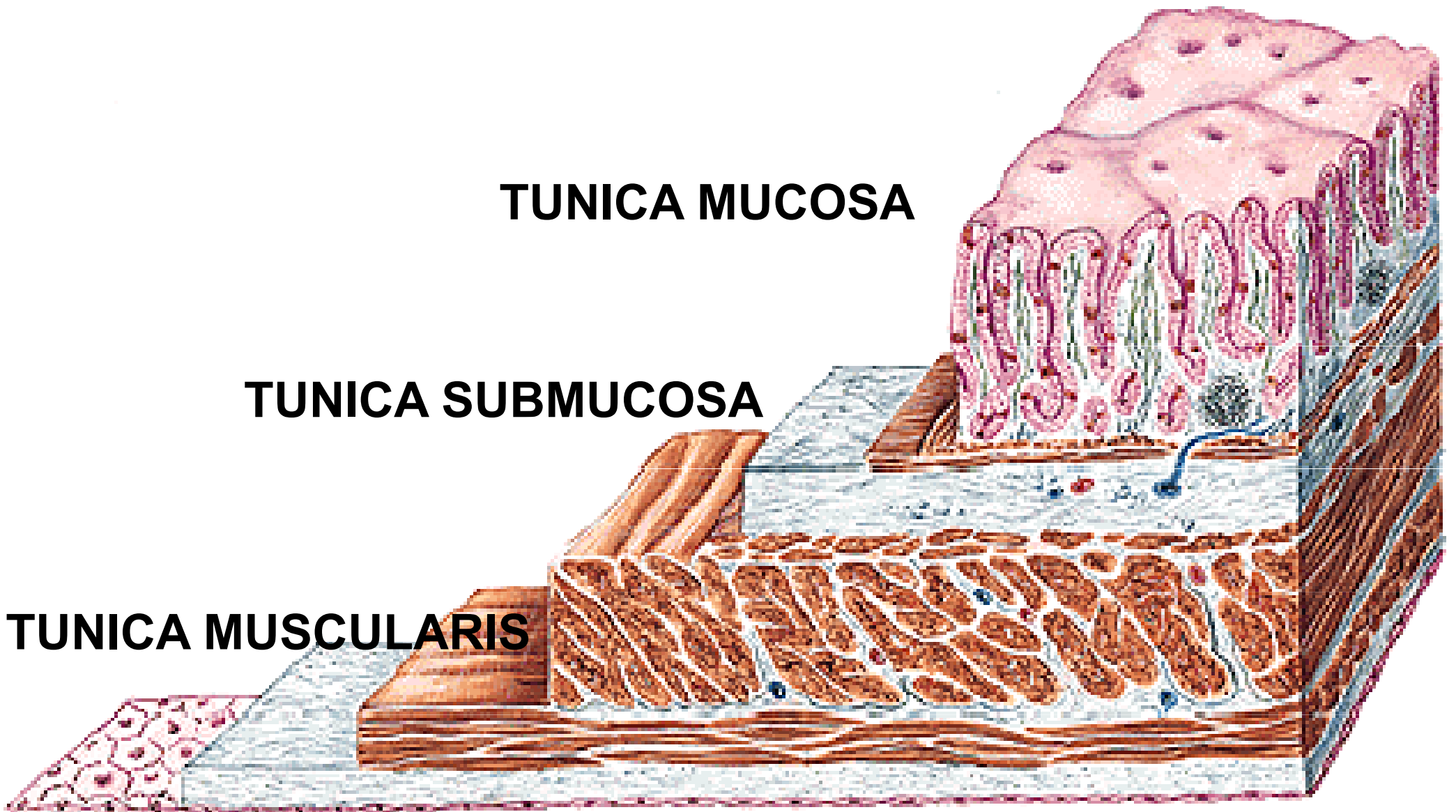


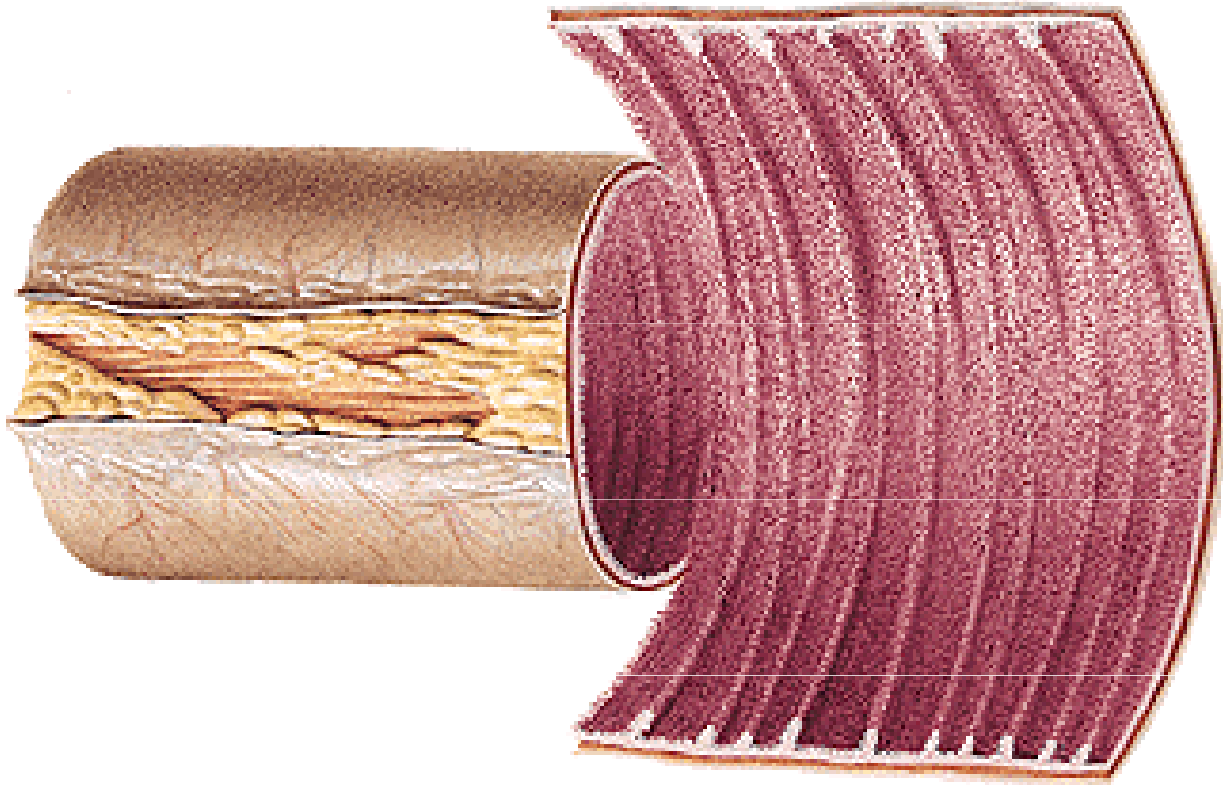
TUNICA MUCOSA

TUNICA SUBMUCOSA

TUNICA MUSCULARIS

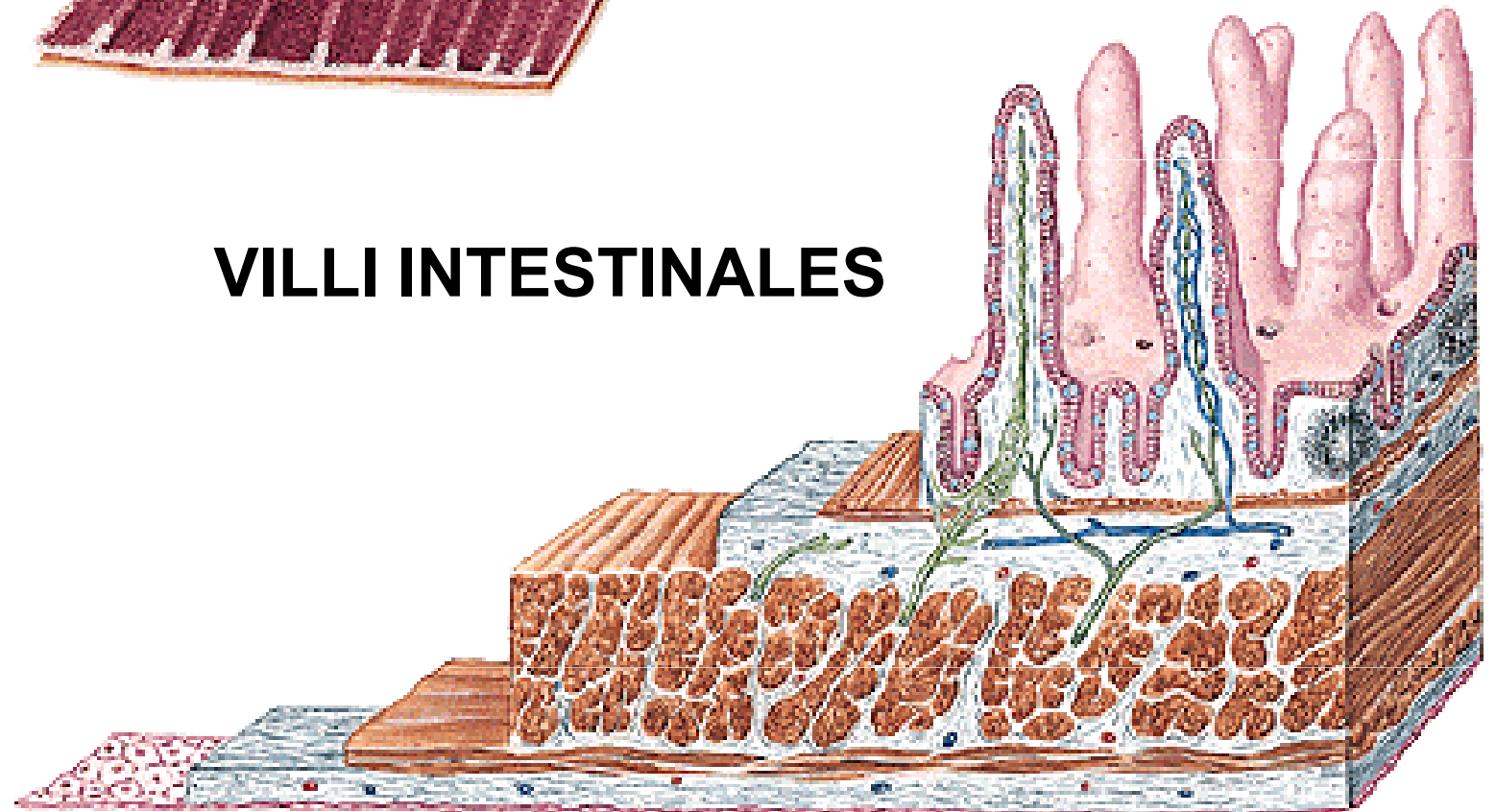
TUNICA ADVENTITIA (TUNICA SEROSA)

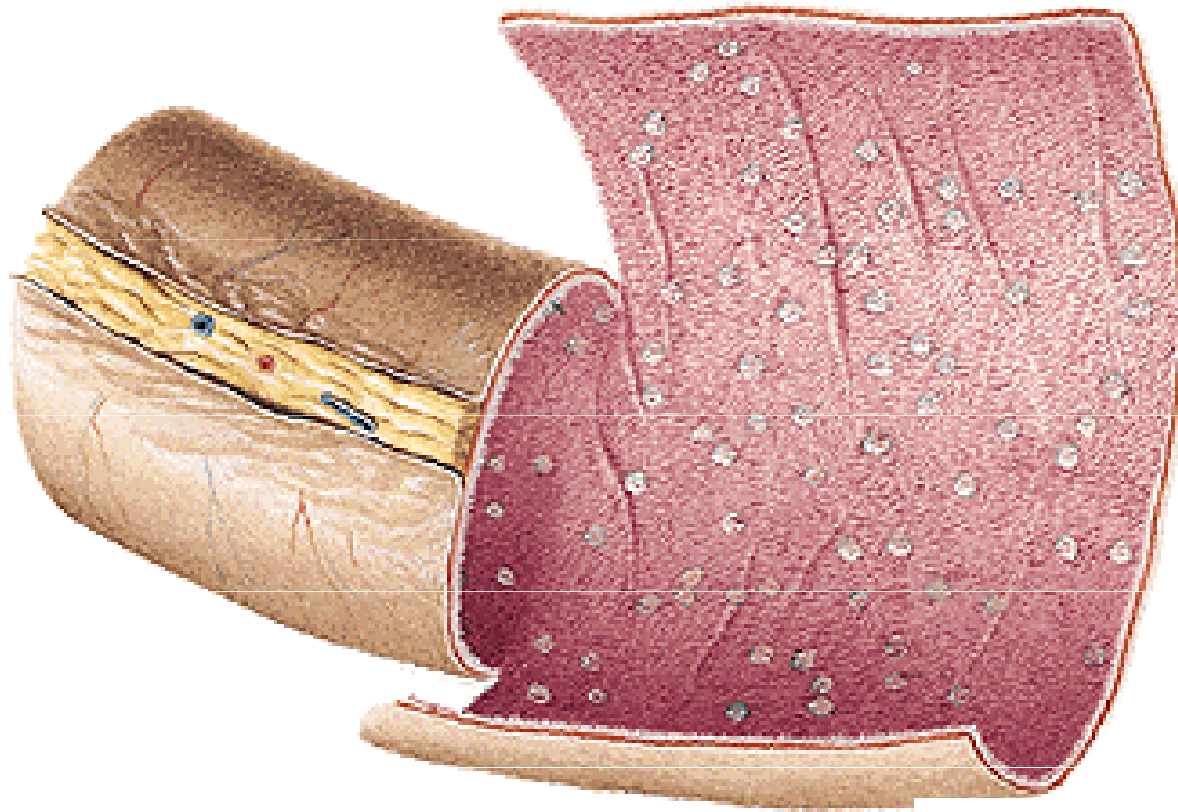



PLICAE

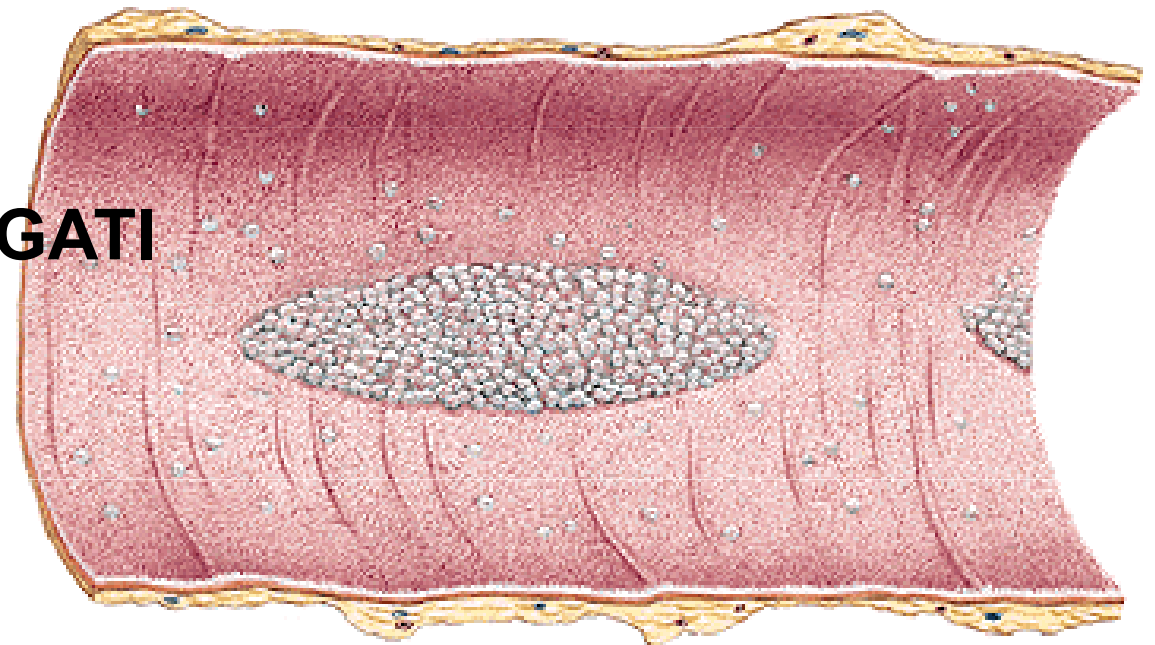
VILLI INTESTINALES





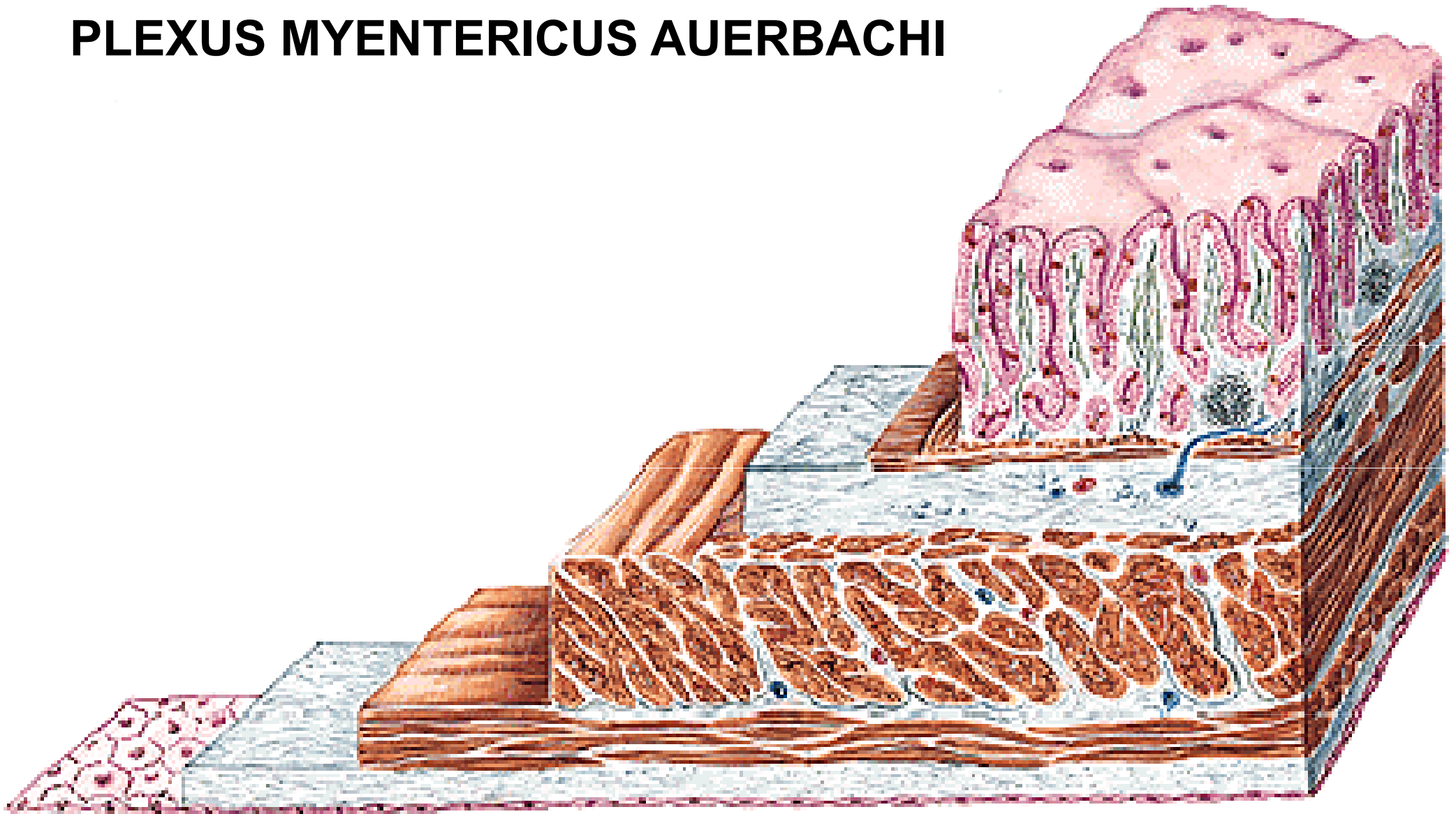
**FOLLICULI
LYMPHATICI SOLITARI**

**FOLLICULI LYMPH. AGGREGATI
– PEYER'S PATCHES**



PLEXUS SUBMUCOSUS MEISSNERI

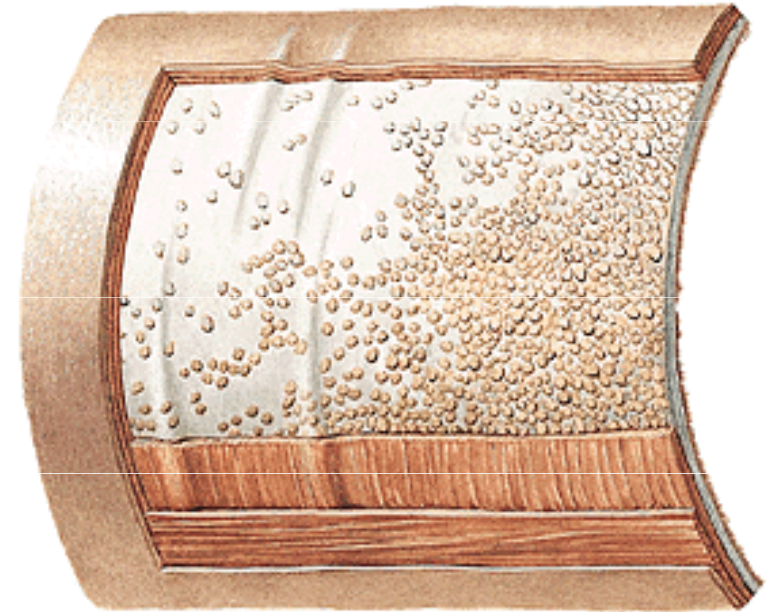
PLEXUS MYENTERICUS AUERBACHI



GLANDS OF GIT:

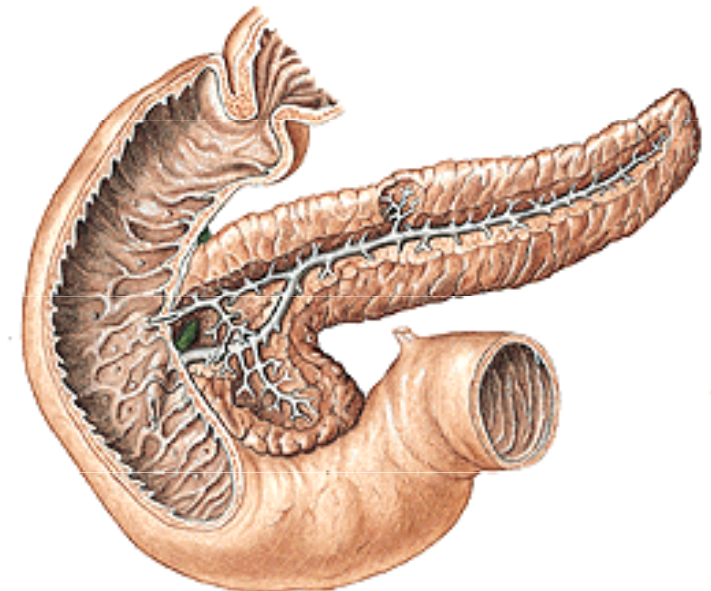
Intramural – goblet cells

- glandulae duodnales

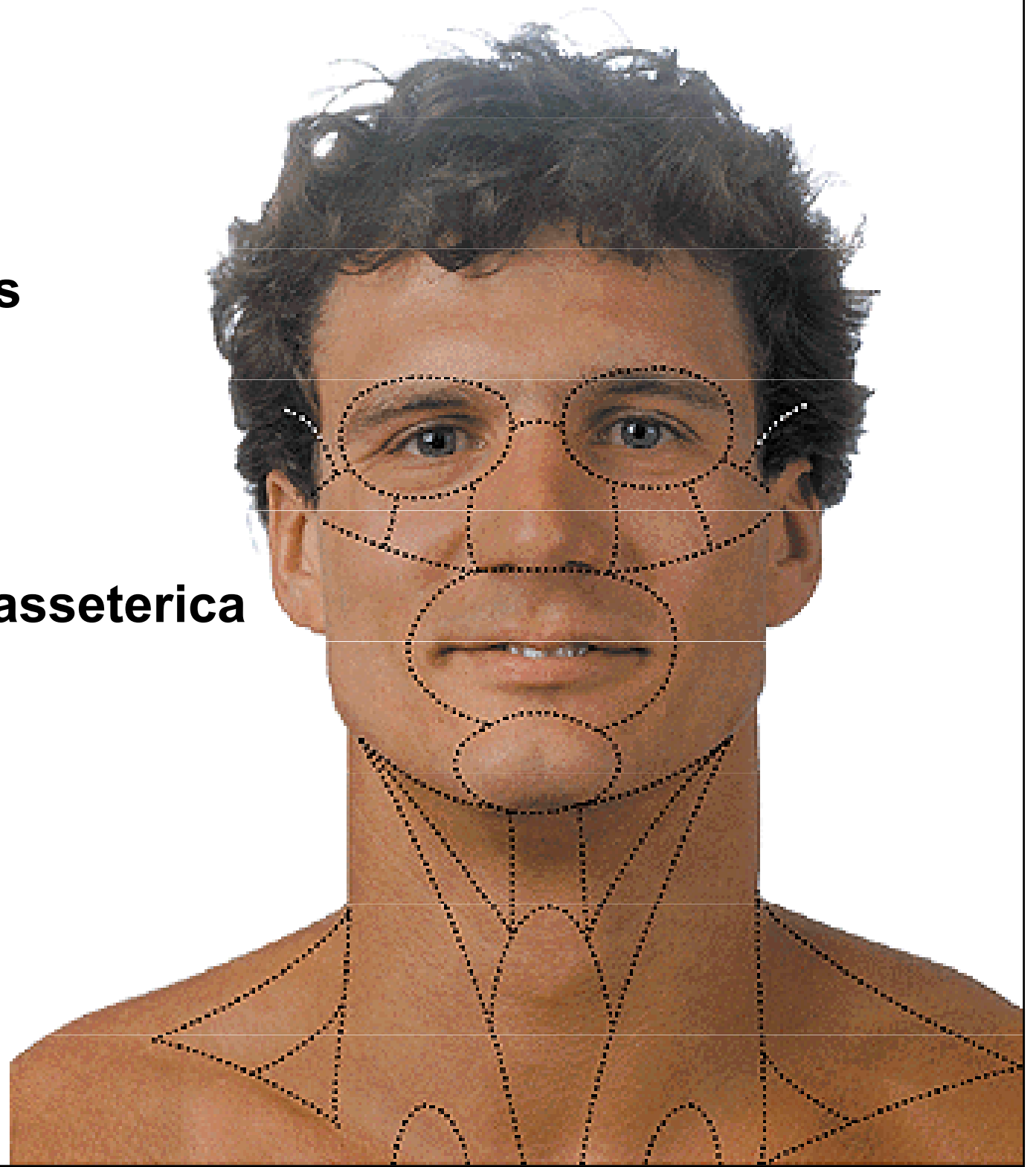


Extramural – great salivary glands

- liver
- pancreas



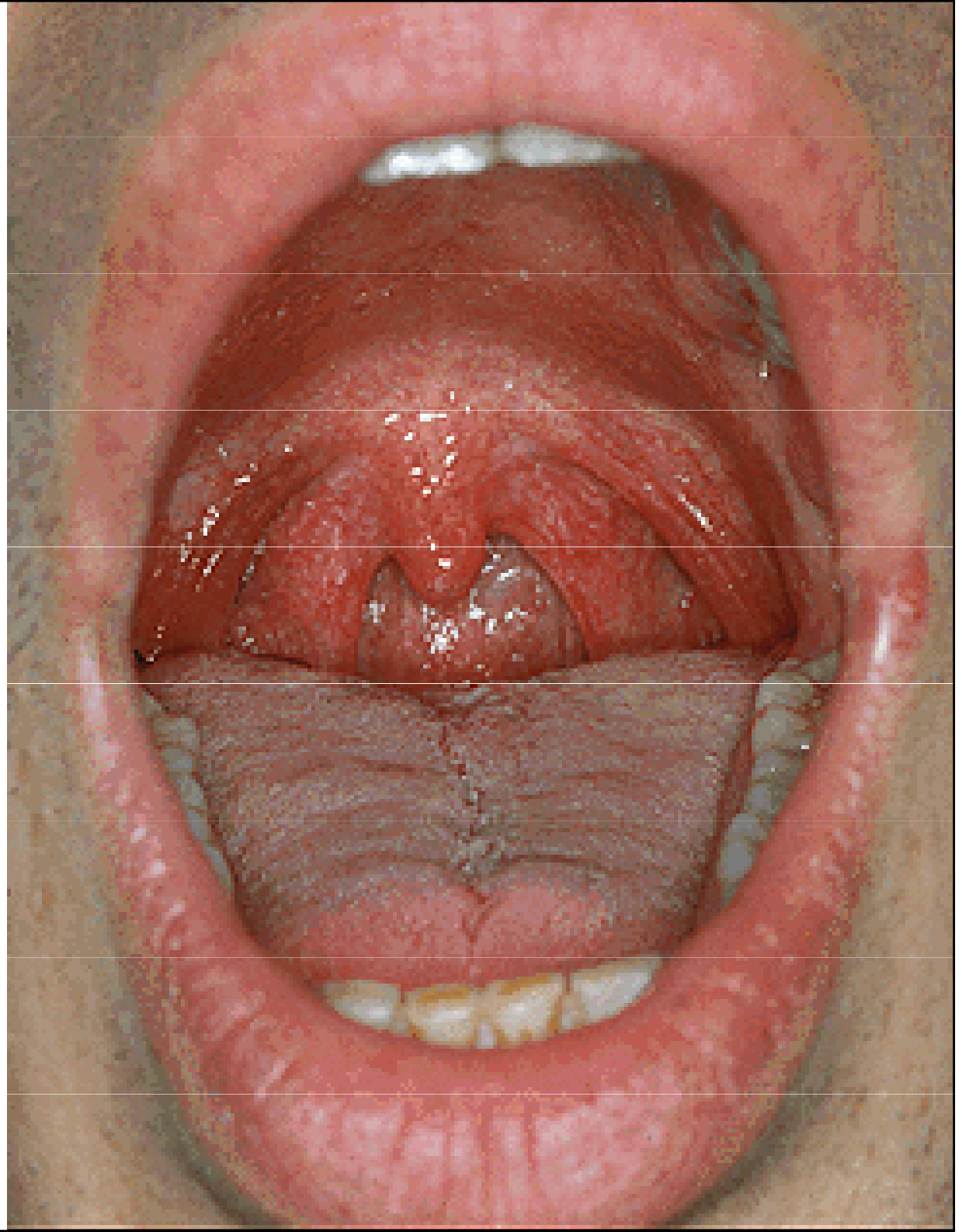Regio frontalis
Regio orbitalis
Regio nasalis
Regio infraorbitalis
Regio zygomatica
Regio oralis
Regio mentalis
Regio buccalis
Regio parotideomasseterica

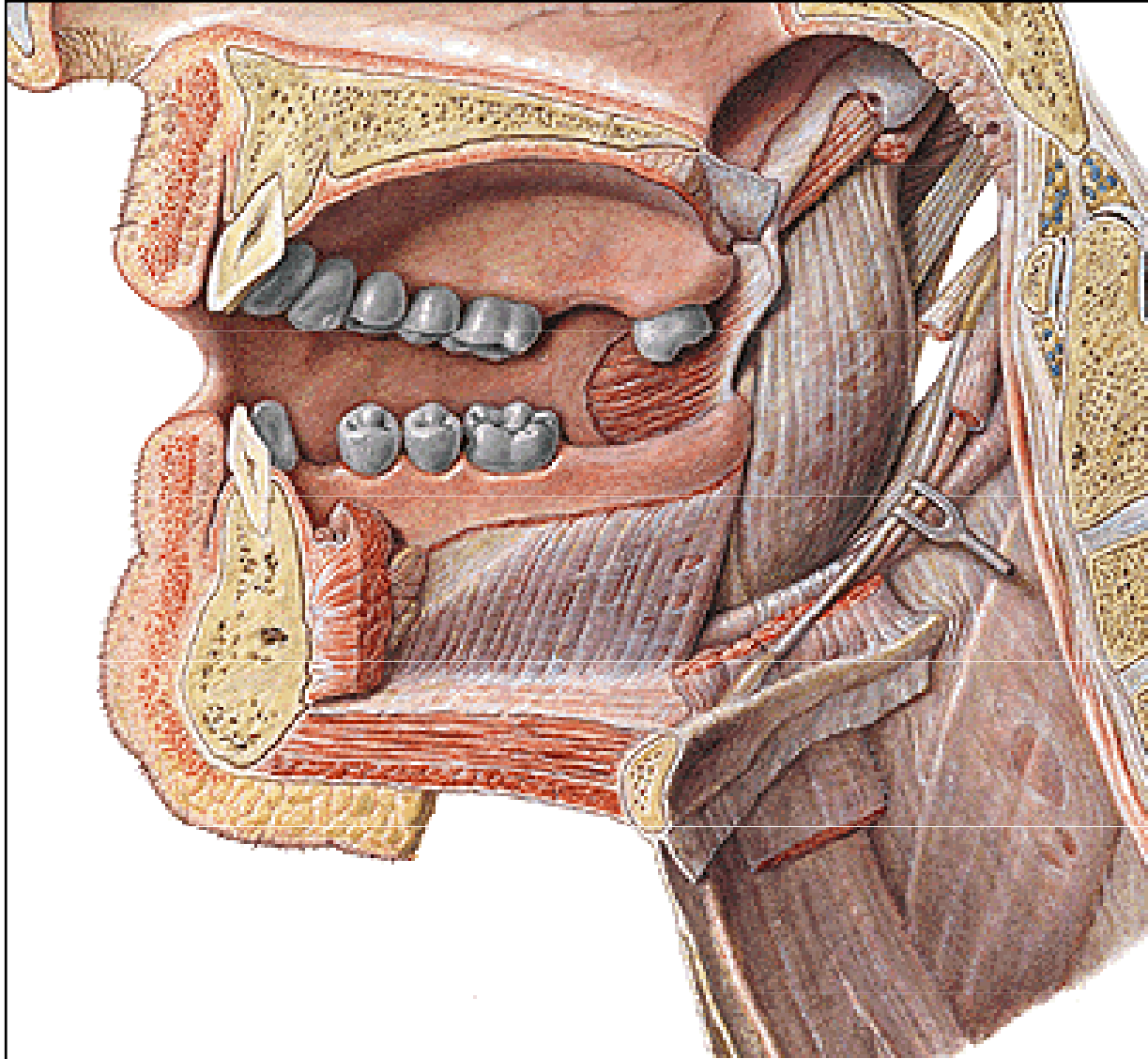


**CAVUM ORIS
(CAVITAS ORIS)**

Rima oris

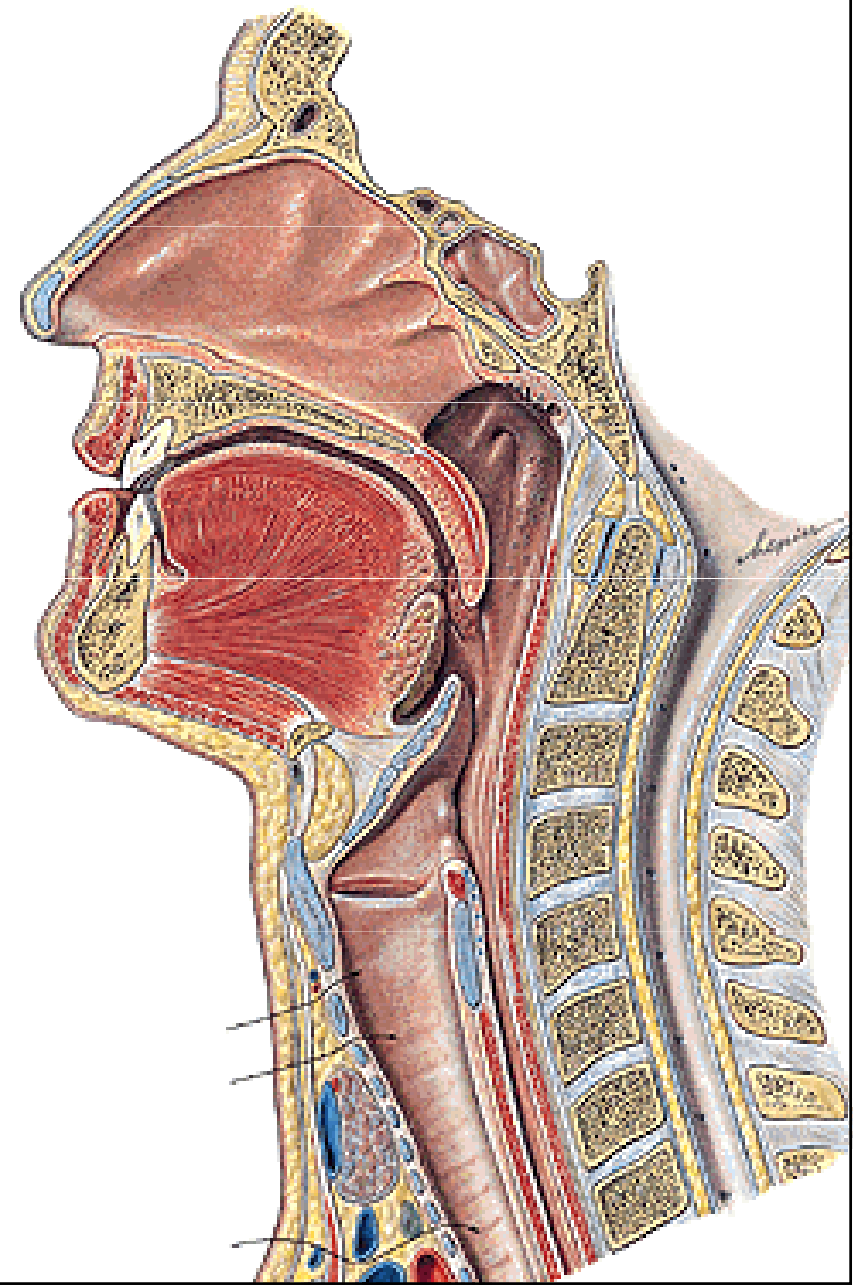
Isthmus faucium





CAVUM ORIS

- vestibulum oris**
- cavum oris proprium**



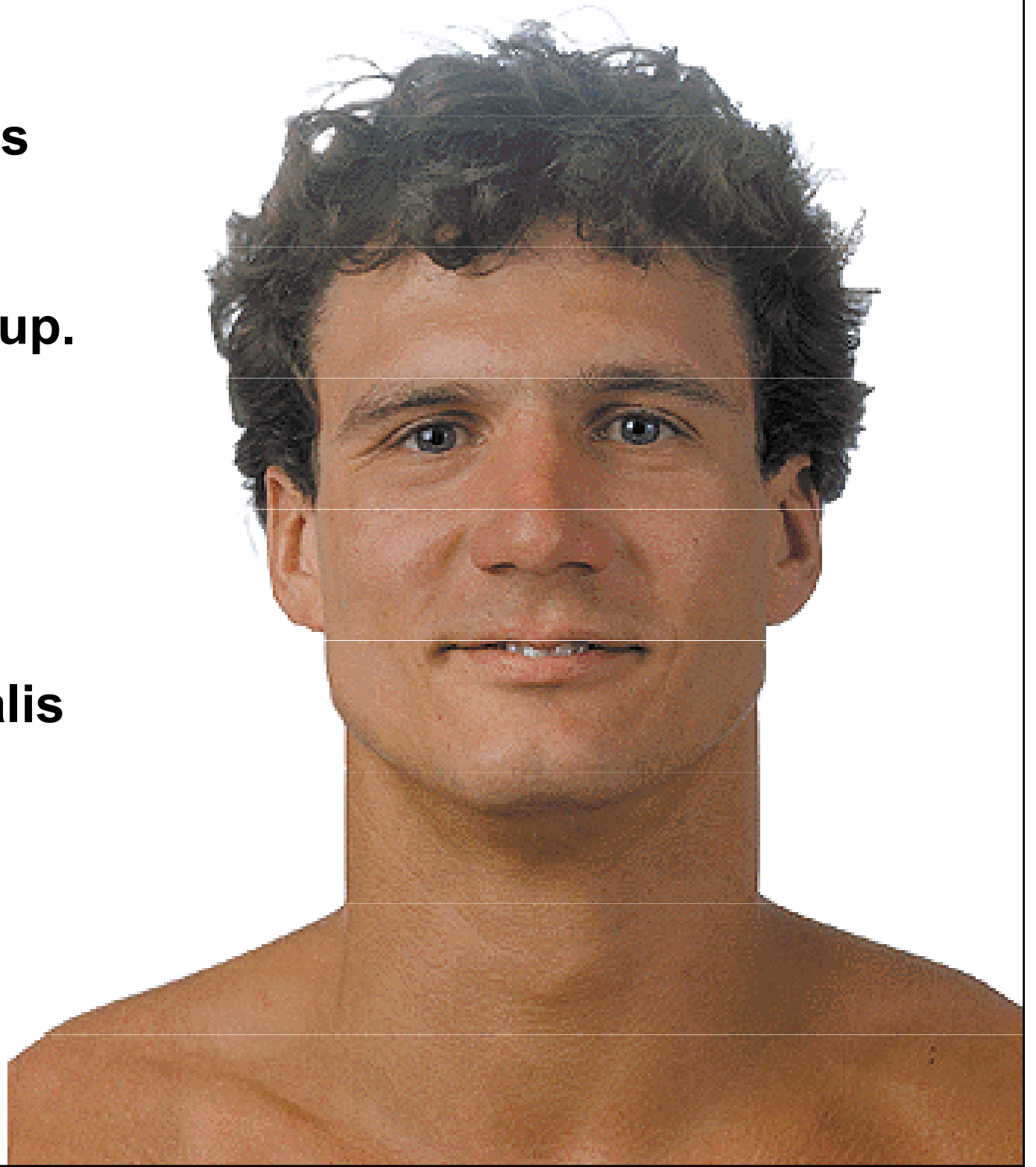
Labium superius

- **sulcus nasolabialis**
- **pars intermedia**
- **philtrum**
- **tuberculum labii sup.**
- **cheiloschisis**
- **gnathoschisis**
- **palatoschisis**

Labium inferius

- **sulcus mentolabialis**

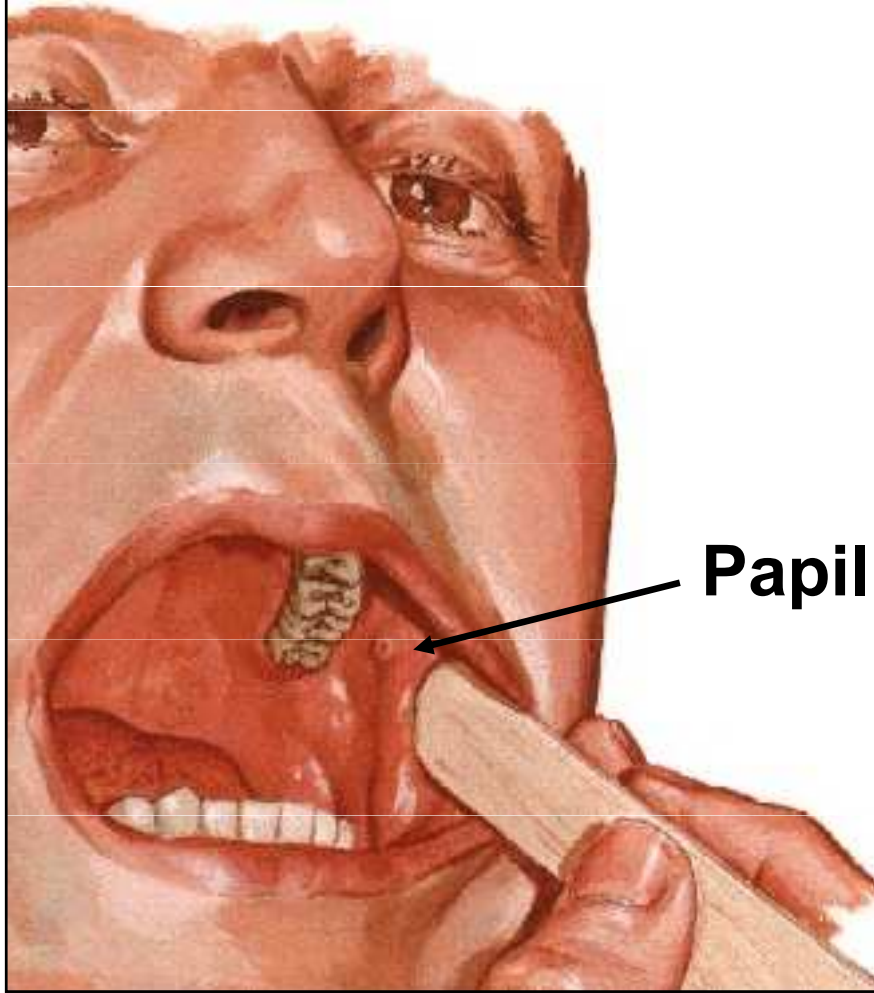
Anguli oris



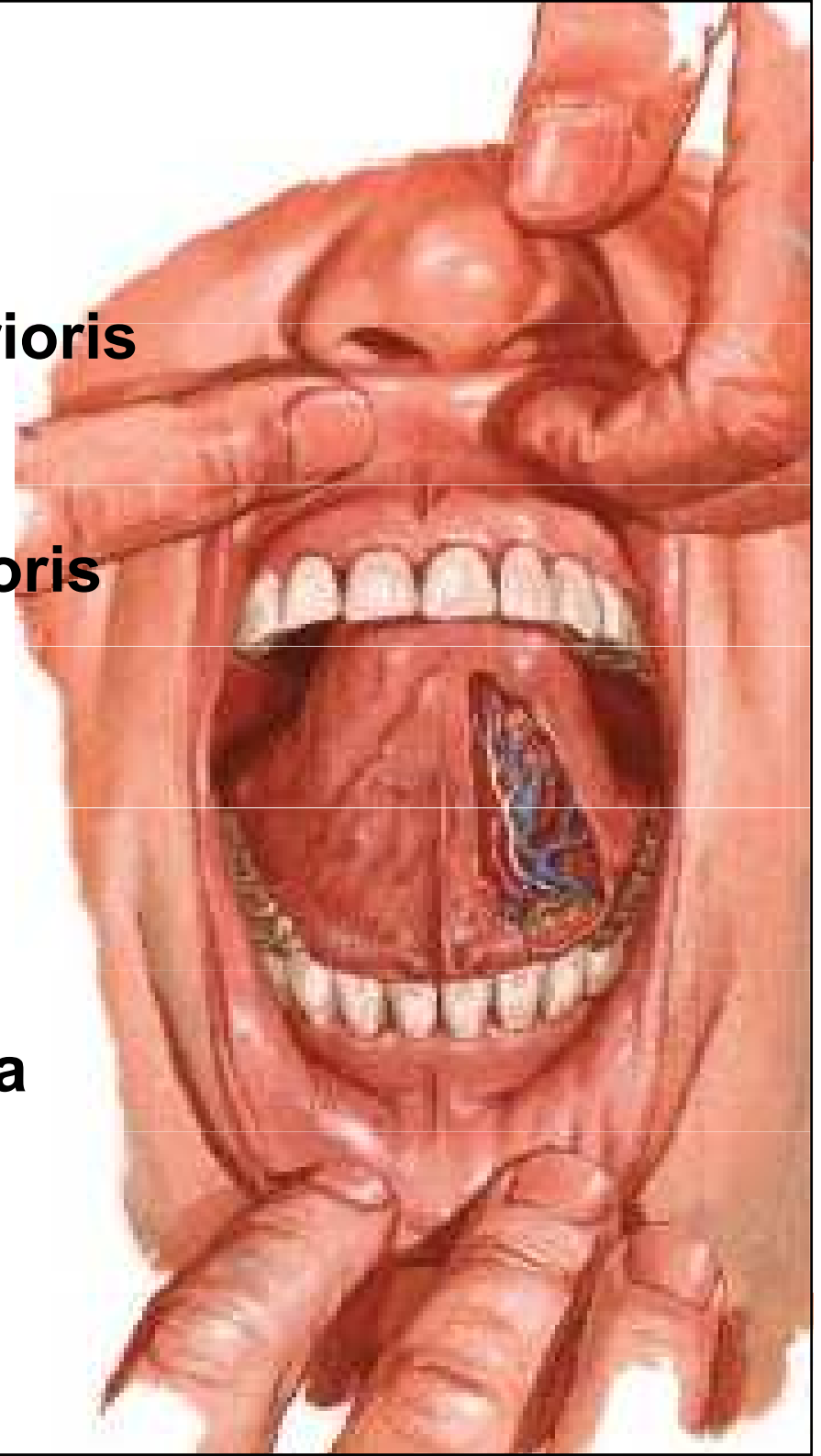
VESTIBULUM ORIS

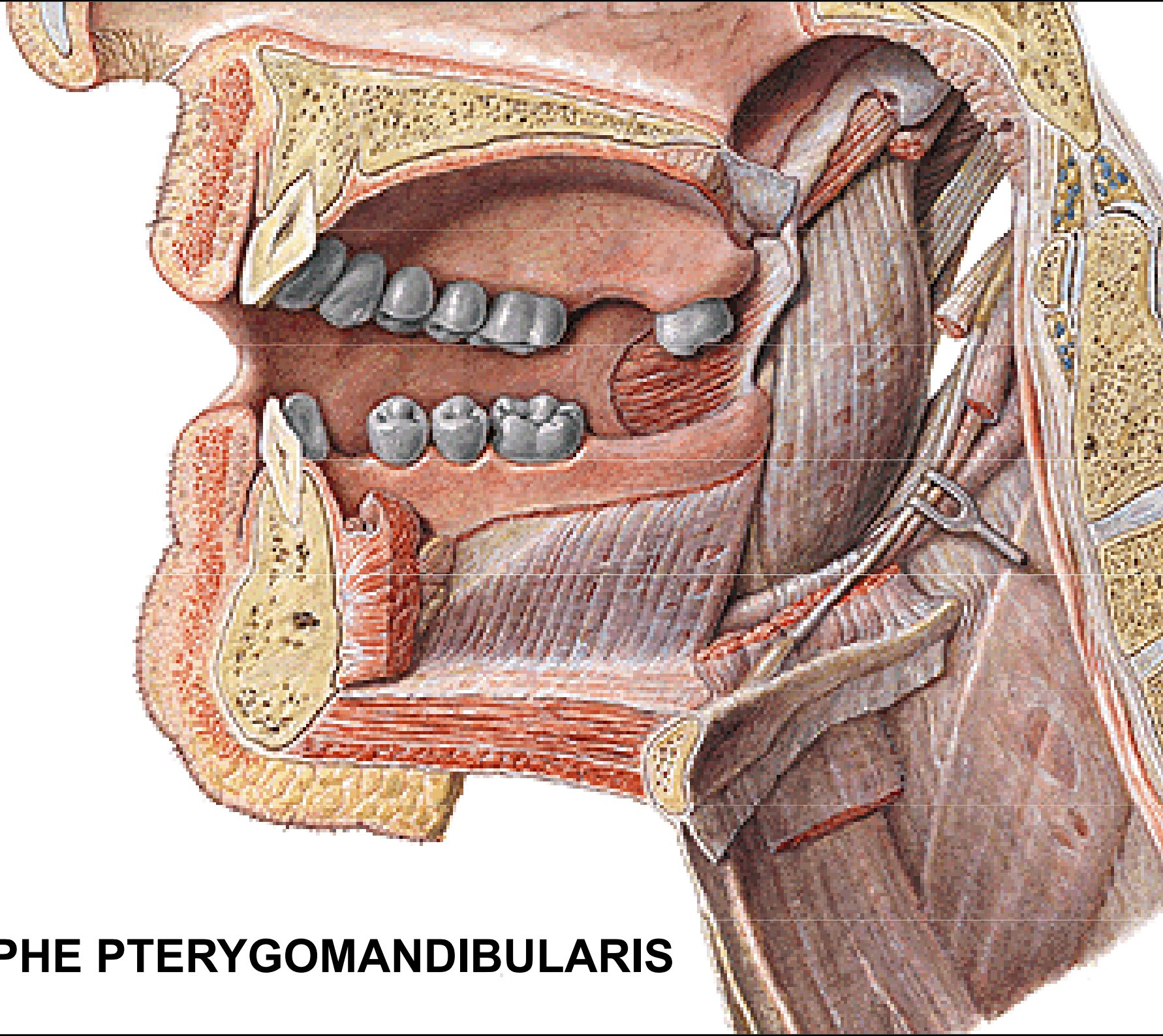
**Fornix vestibuli sup.
- frenulum labii superioris**

**Fornix vestibuli inf.
labii inferioris**



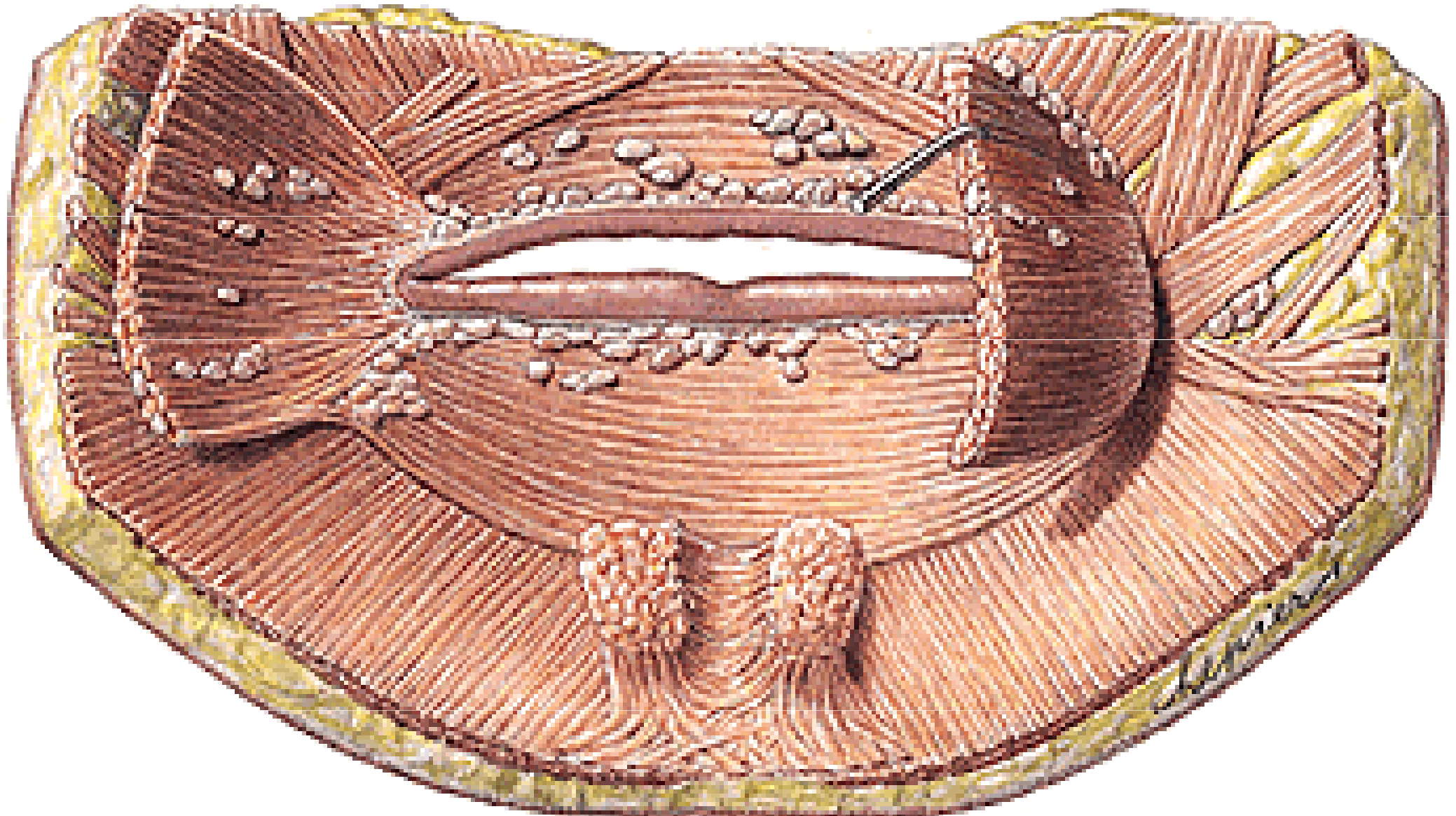
Papilla parotidea



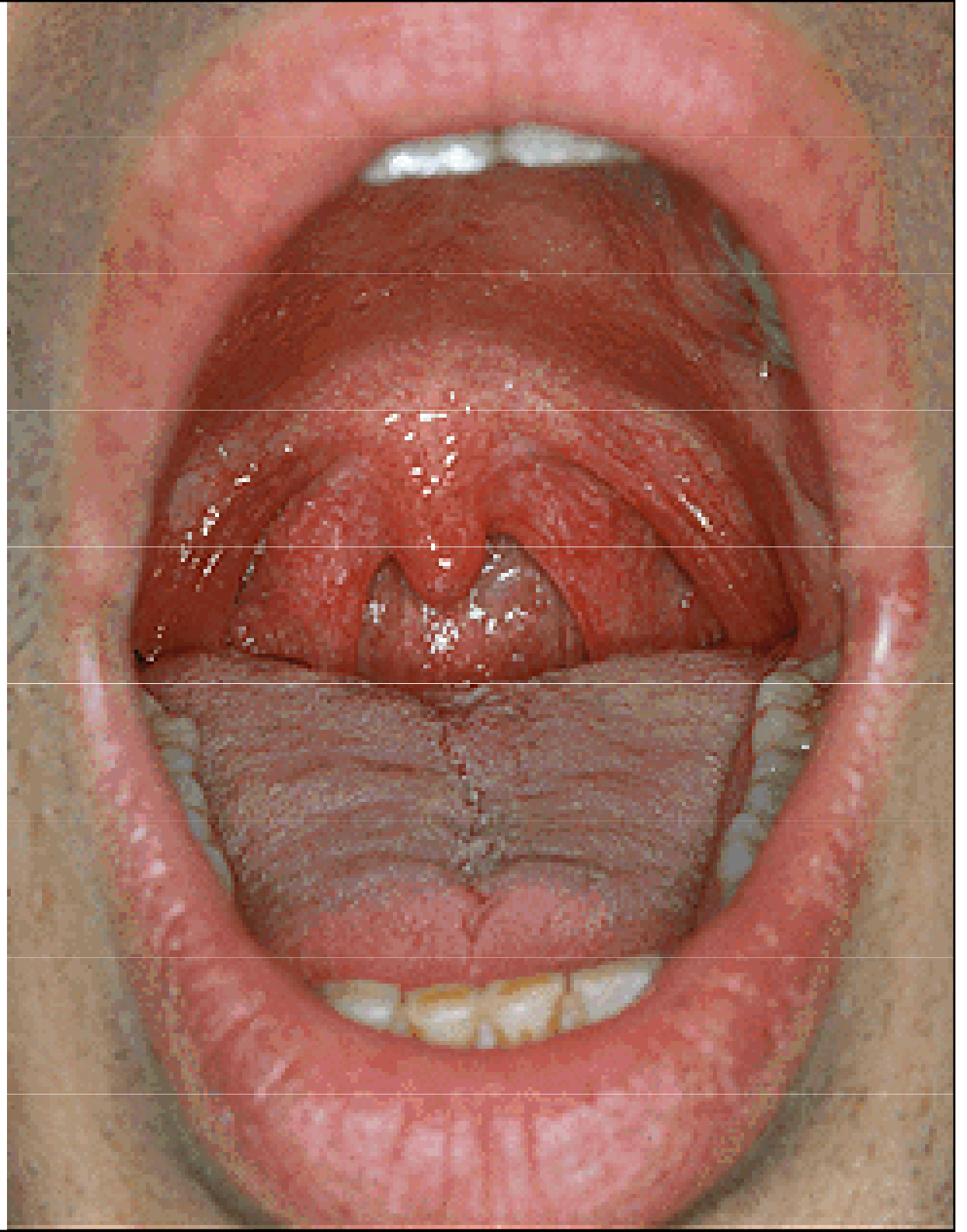

RAPHE PTERYGOMANDIBULARIS

Glandulae labiales
M. orbicularis oris
M. buccinator

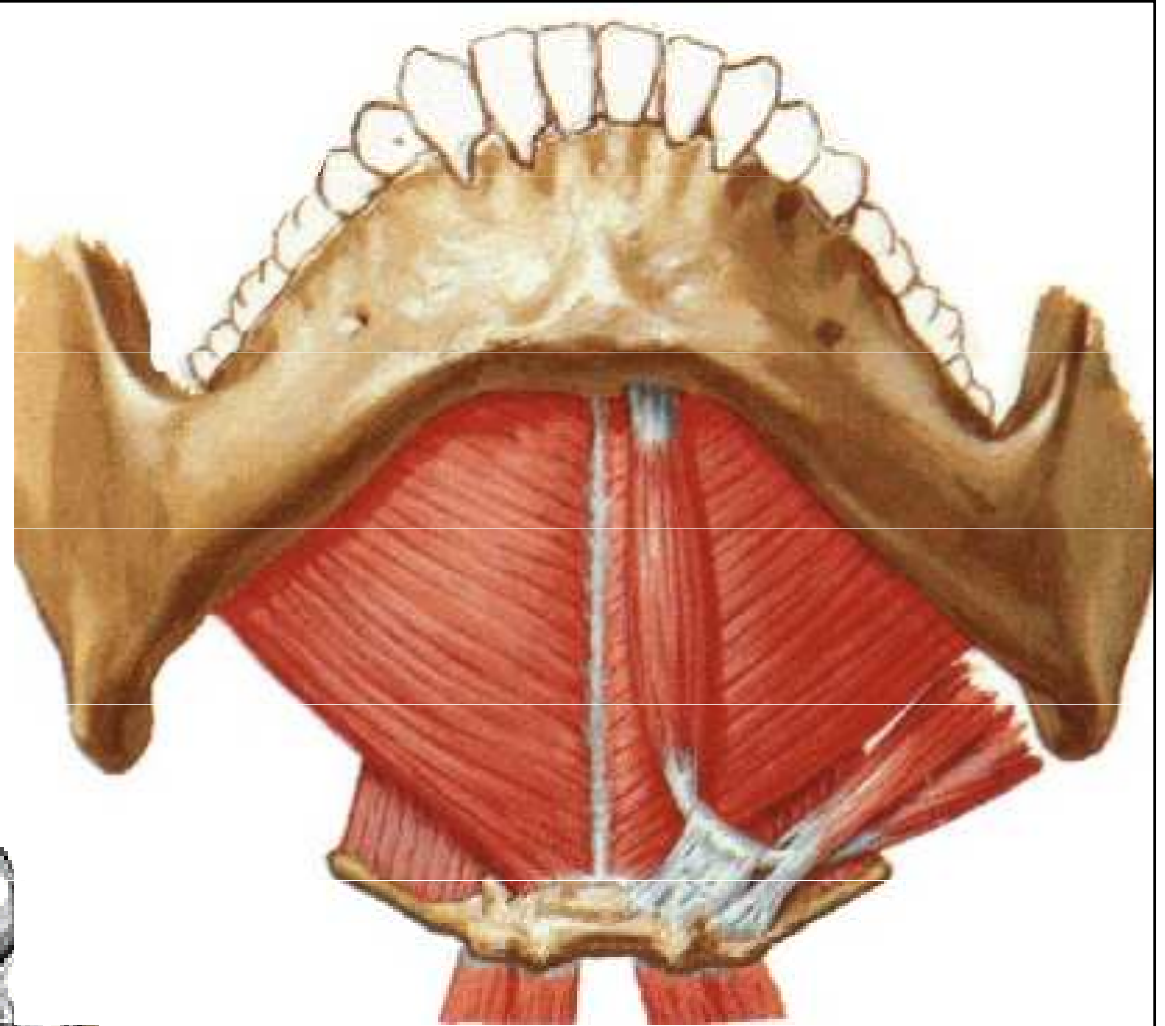
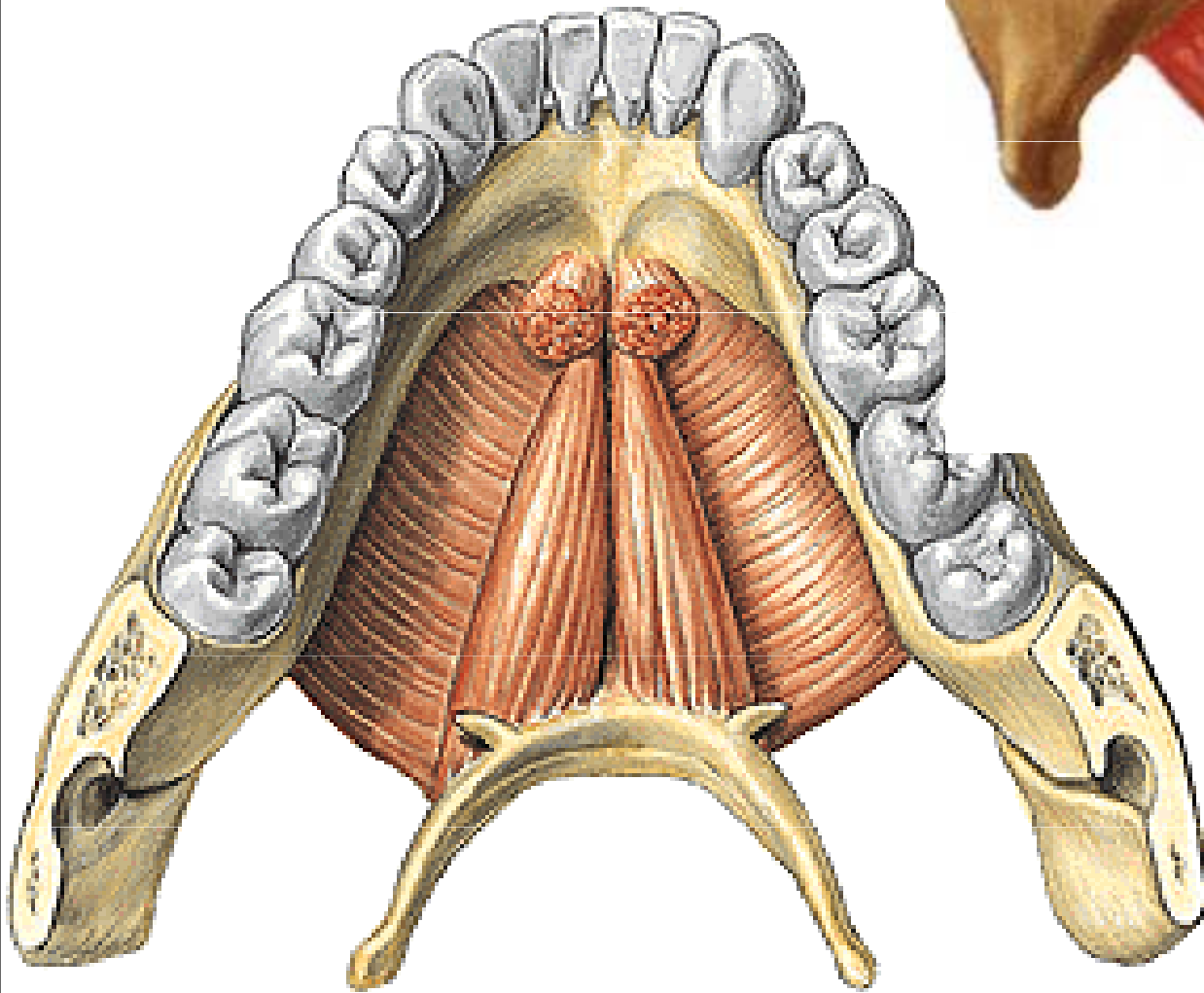


CAVUM ORIS PROPRIUM



DIAPHRAGMA ORIS

- m. mylohyoideus
- m. geniohyoideus
- m. digastricus

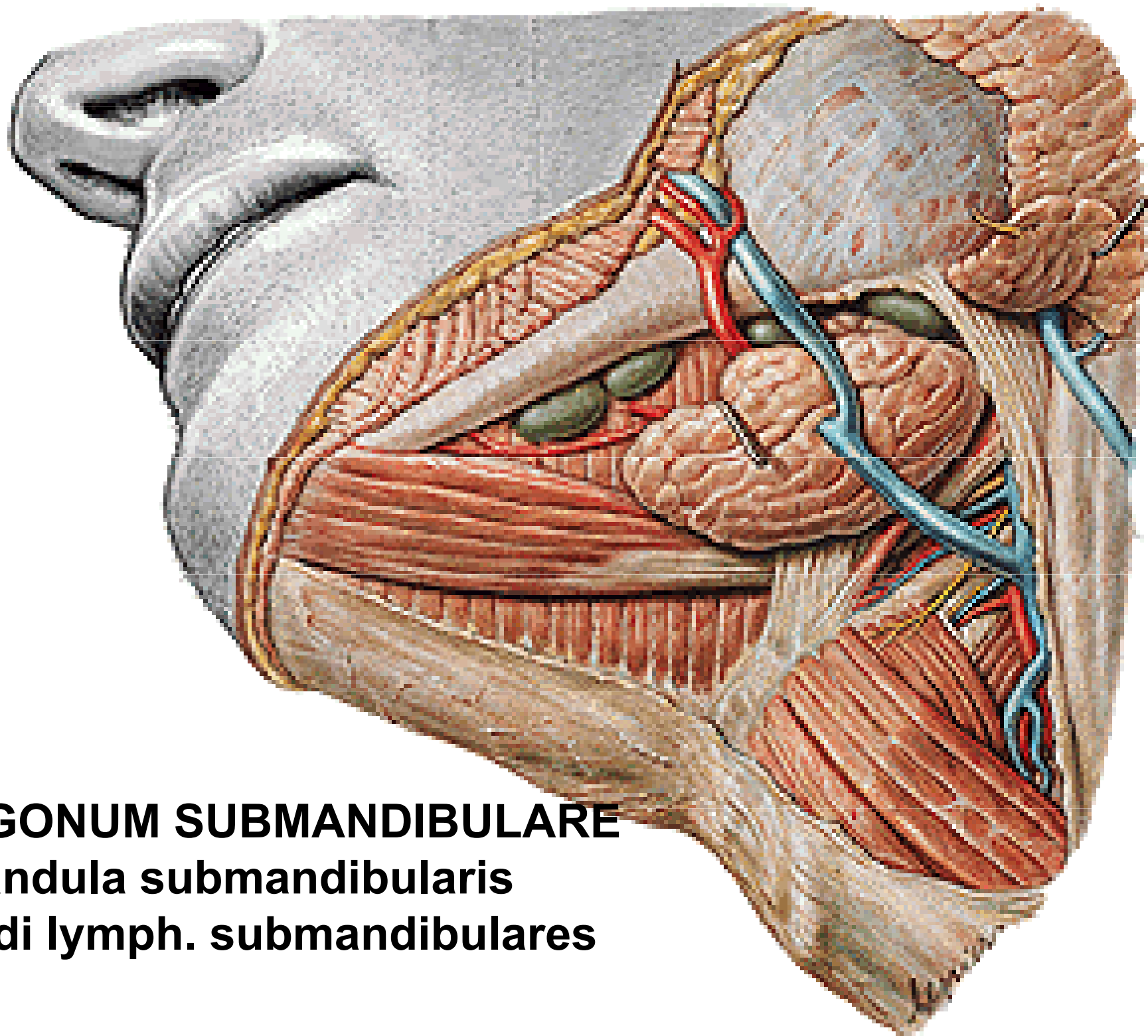


GLANDULAE SALIVARIAE MINORES

- labiales, buccales, molares, palatinae, linguales

GLANDULAE SALIVARIAE MAJORES

- submandibularis
- sublingualis
- parotis



TRIGONUM SUBMANDIBULARE

- glandula submandibularis

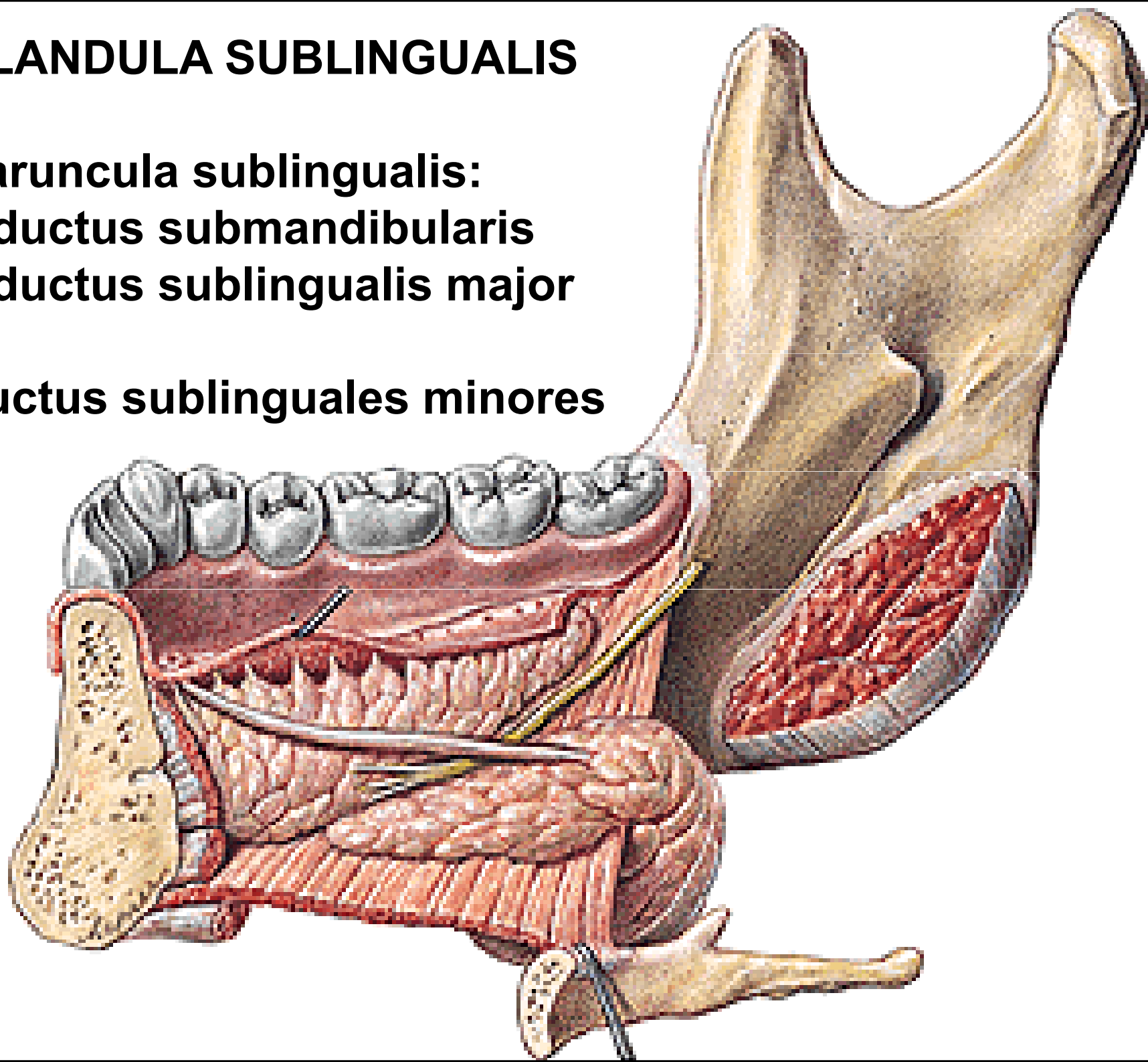
- nodi lymph. submandibulares

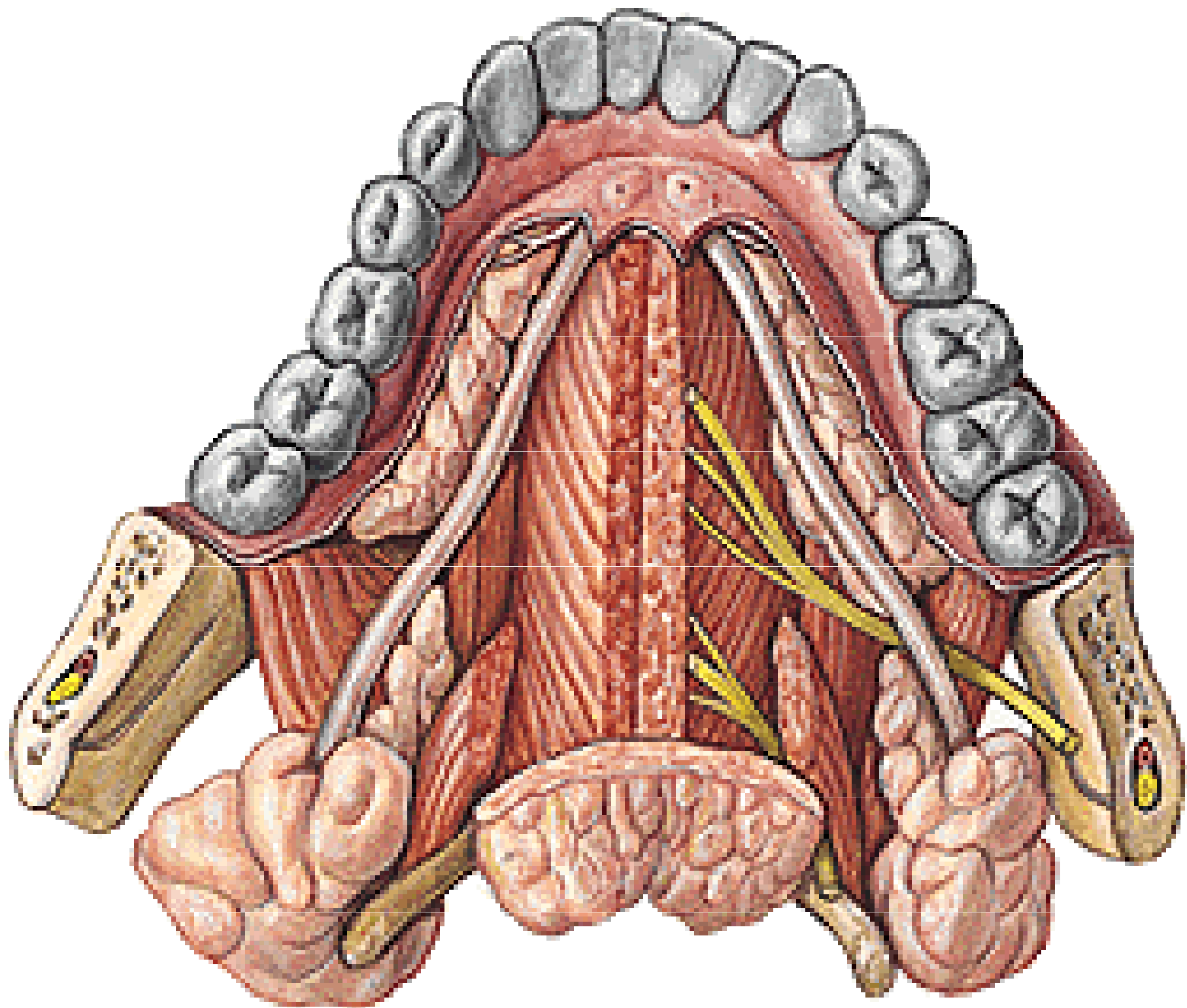
GLANDULA SUBLINGUALIS

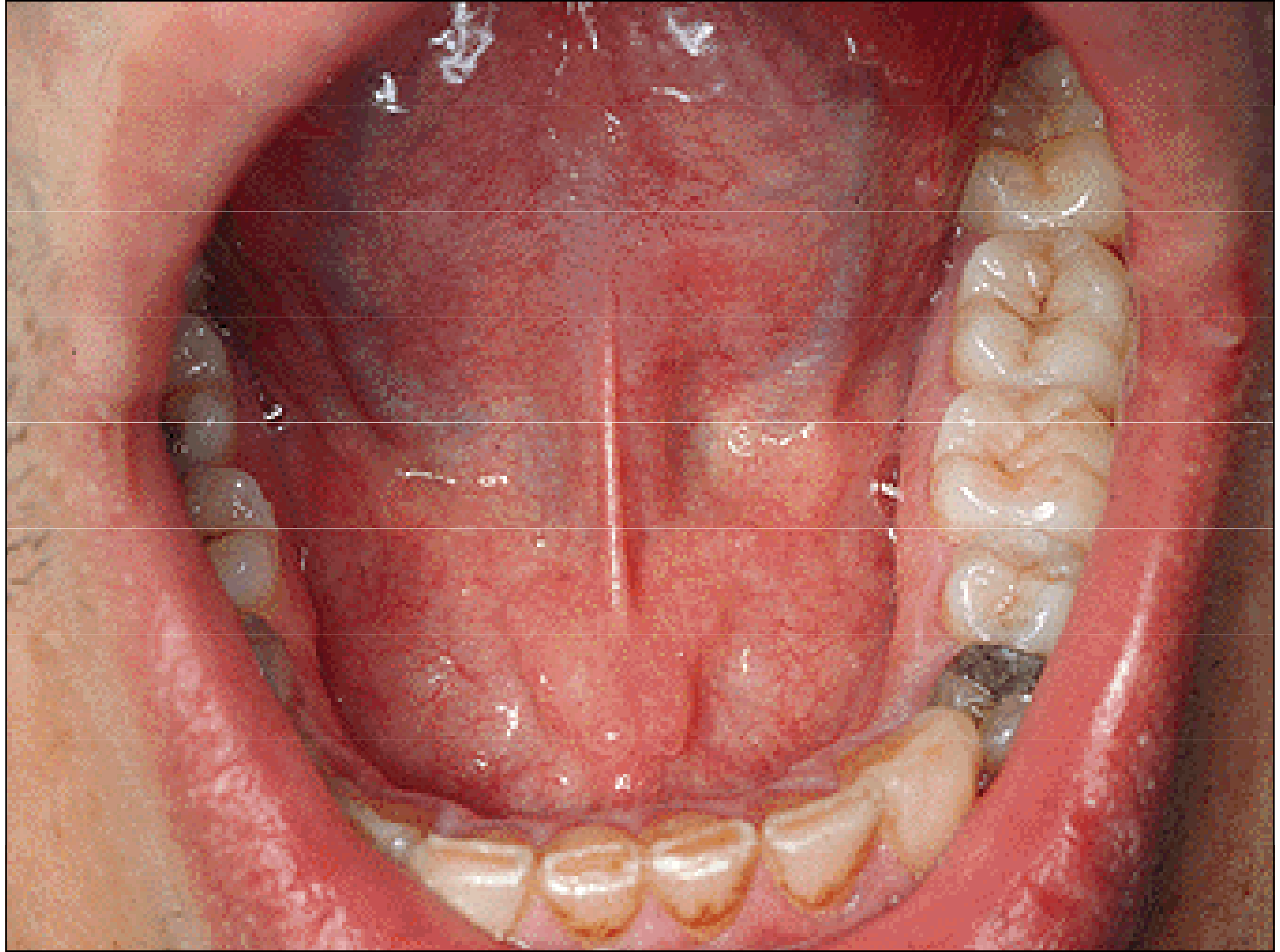
Caruncula sublingualis:

- ductus submandibularis
- ductus sublingualis major

Ductus sublinguales minores







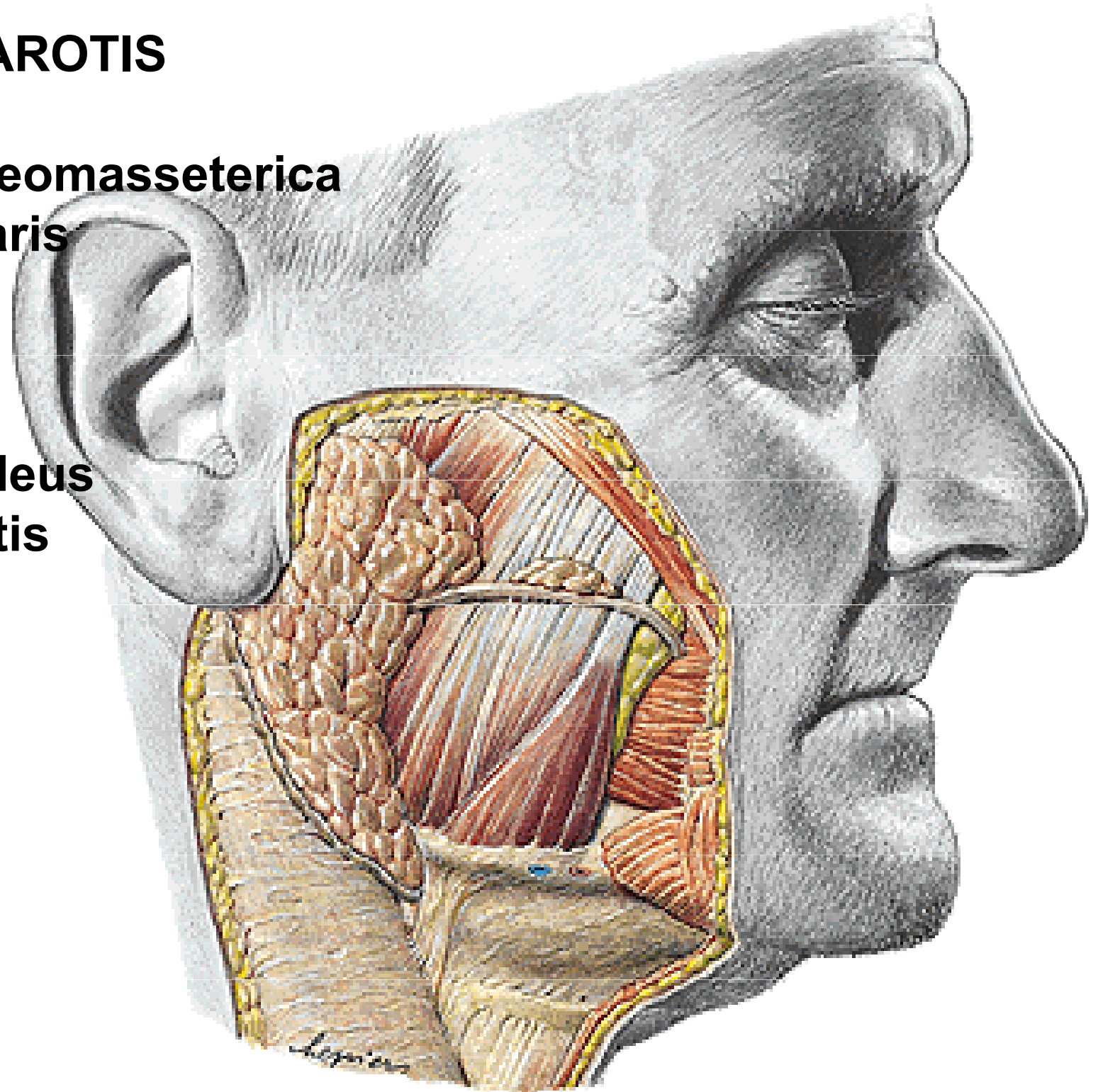
GLANDULA PAROTIS

Fascia parotideomasseterica

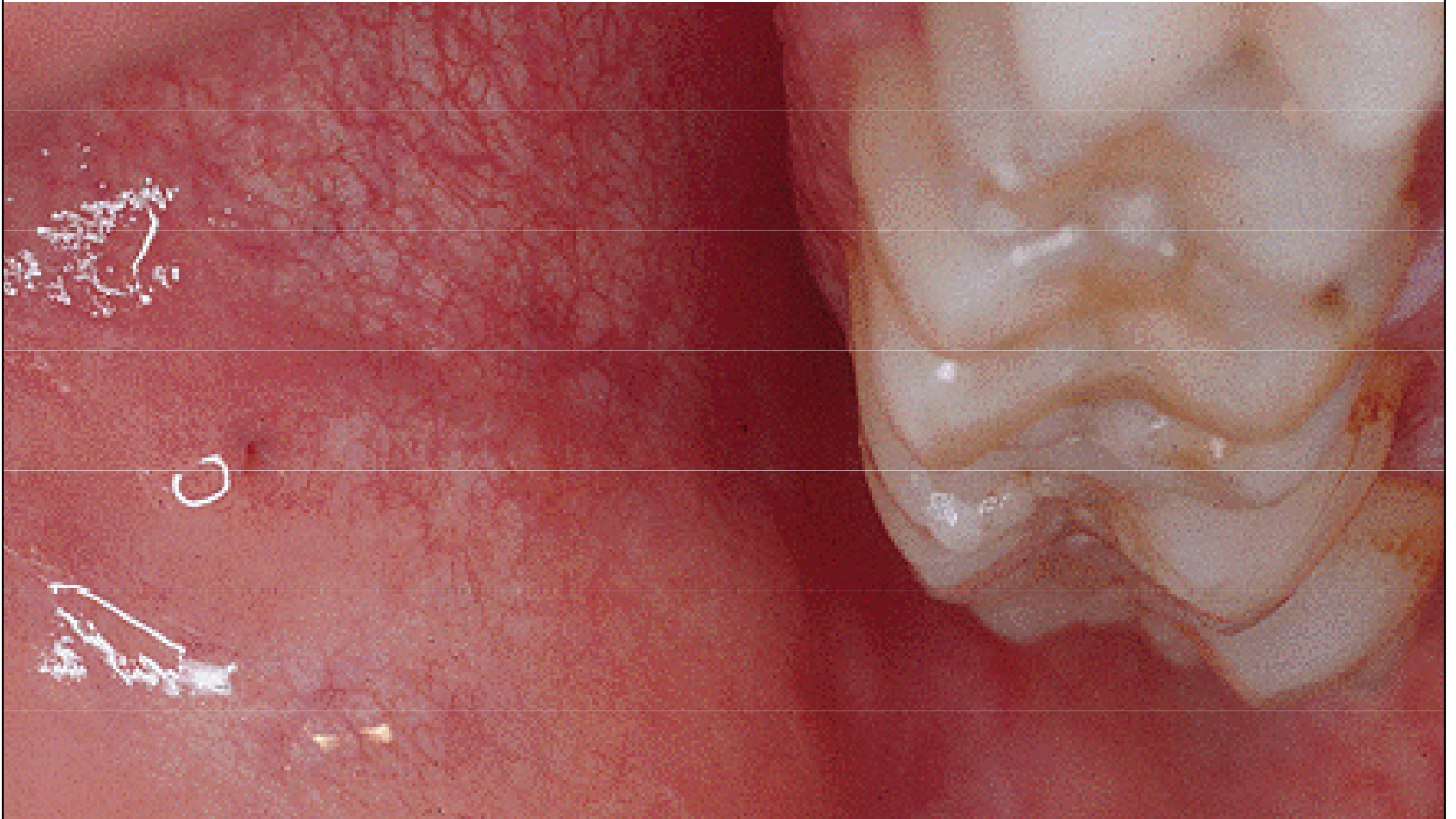
Tractus angularis

Ductus parotideus

Glandula parotis
accessoria

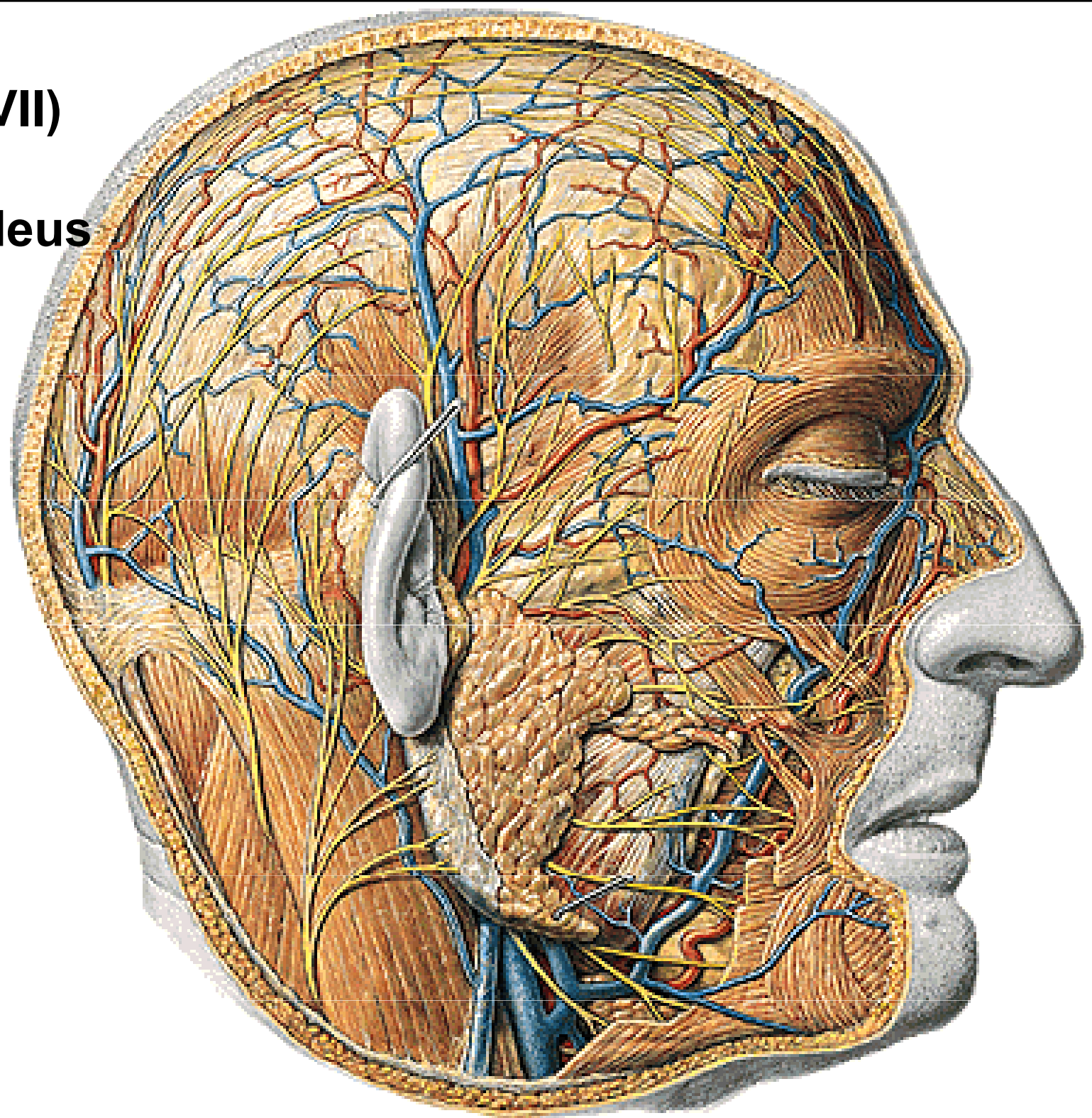


PAPILLA PAROTIDEA

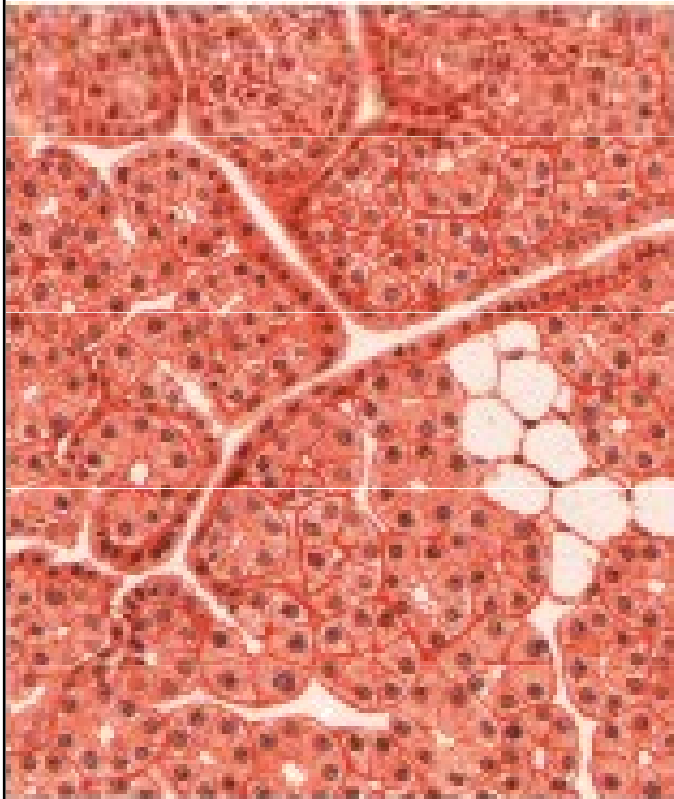


N. facialis (CN VII)

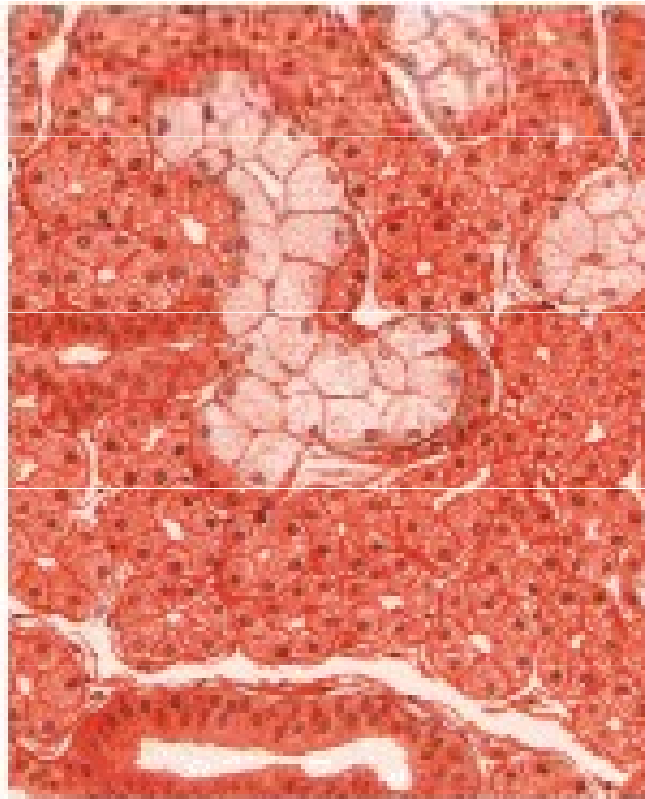
- plexus parotideus



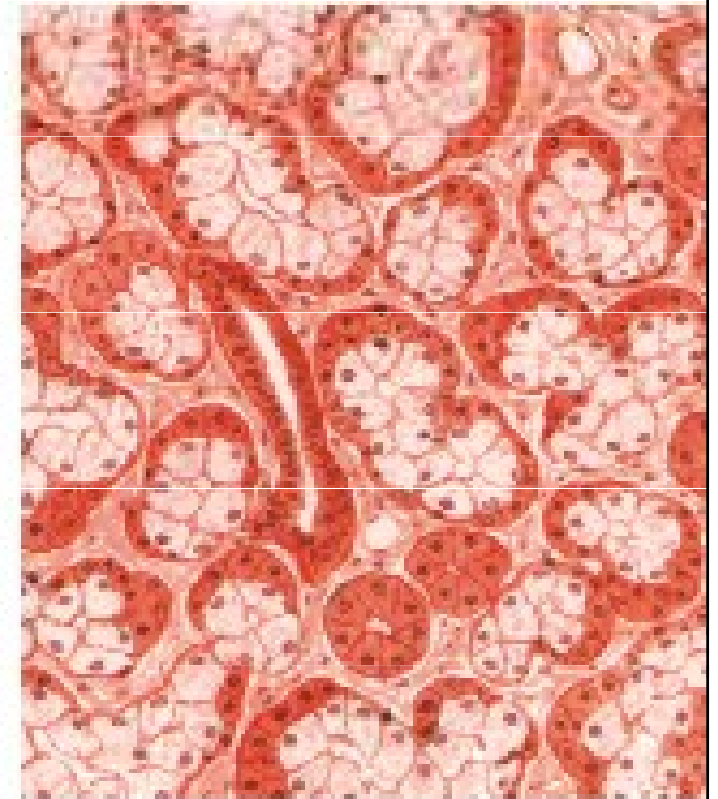
SALIVARY GLANDS



Parotid gland: totally serous

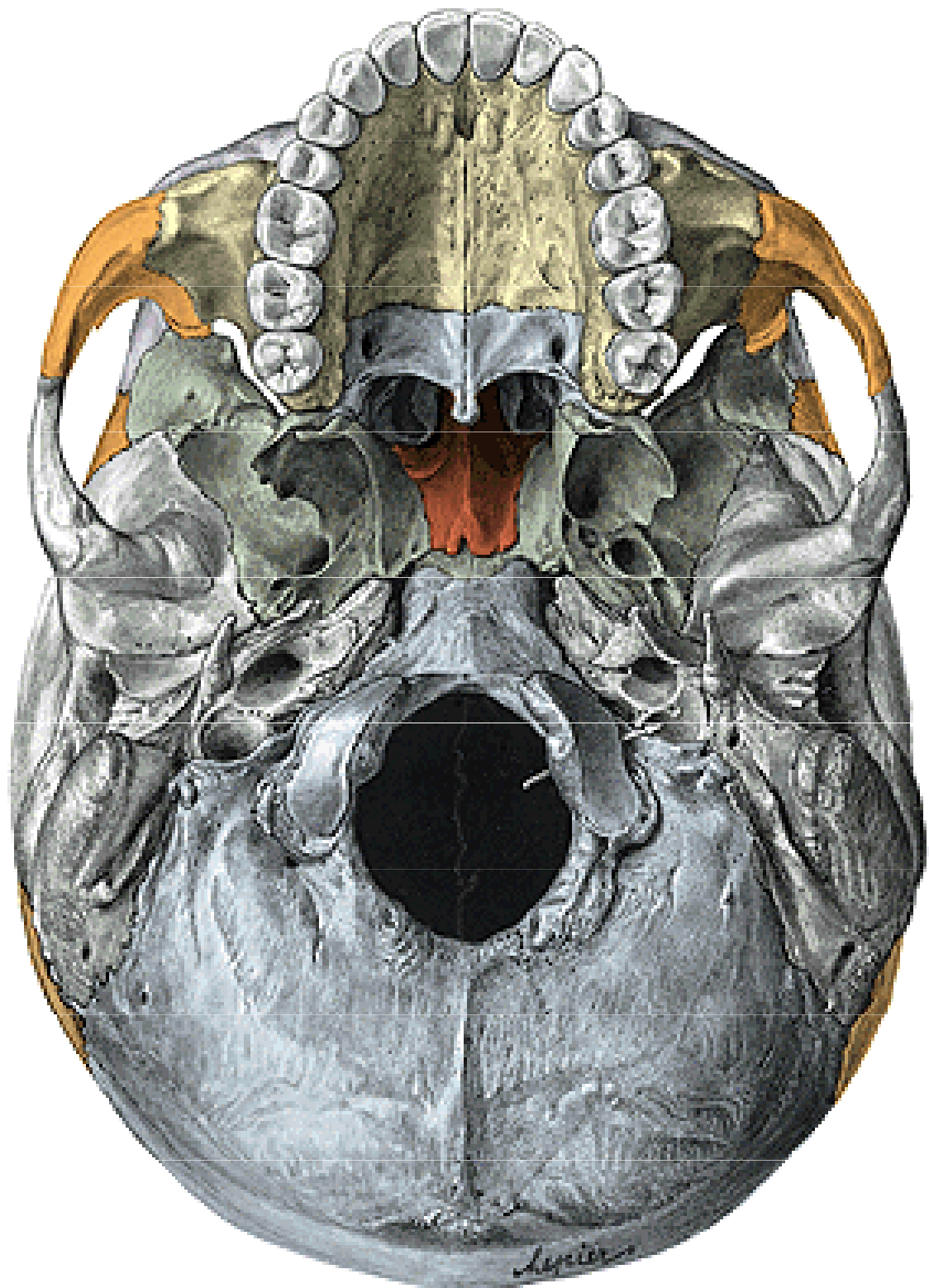


Submandibular gland:
mostly serous, partially mucous



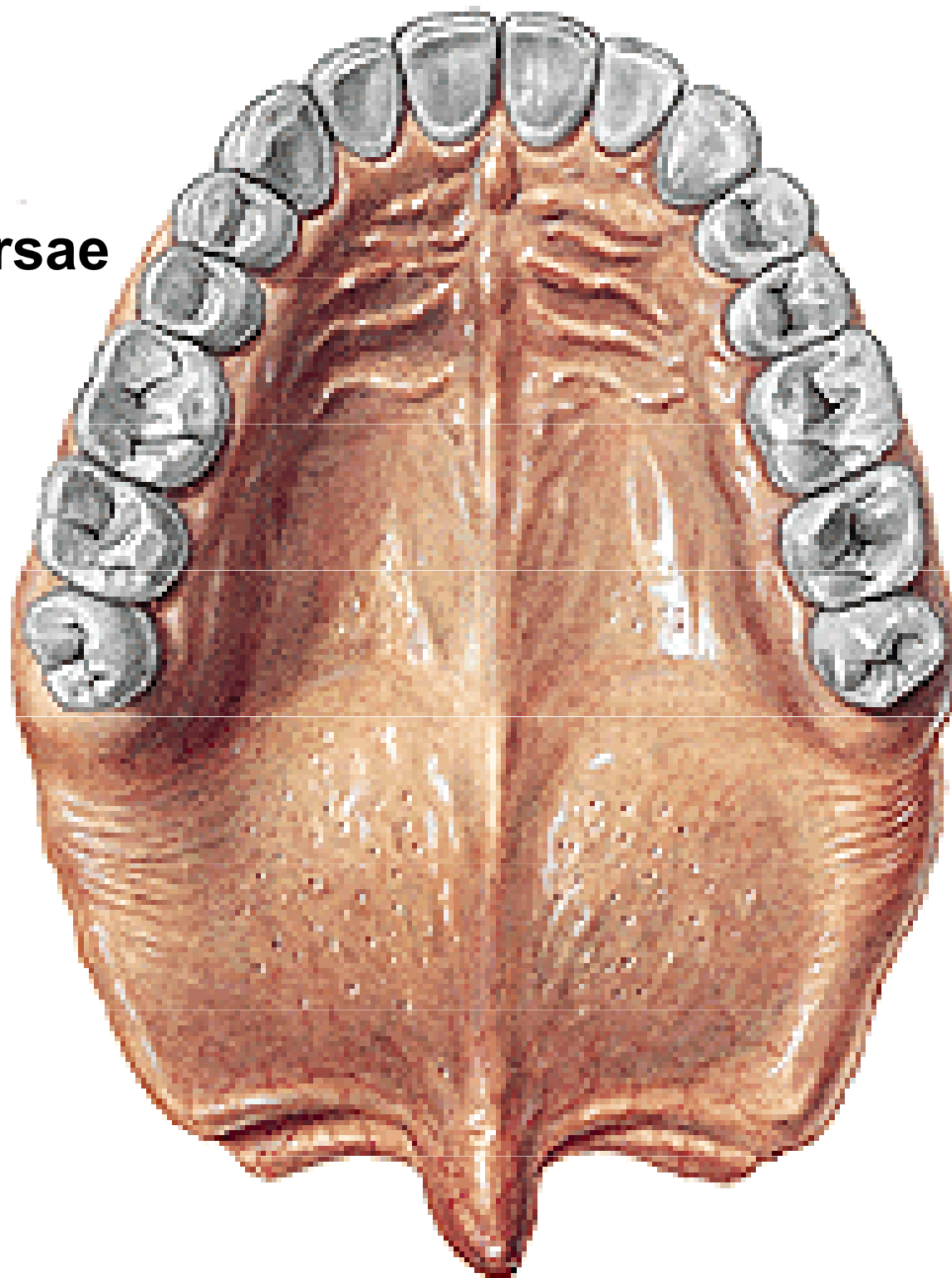
Sublingual gland:
almost completely mucous

PALATUM DURUM



Leysner

Raphe palati
Papilla incisiva
Plicae palatinae transversae

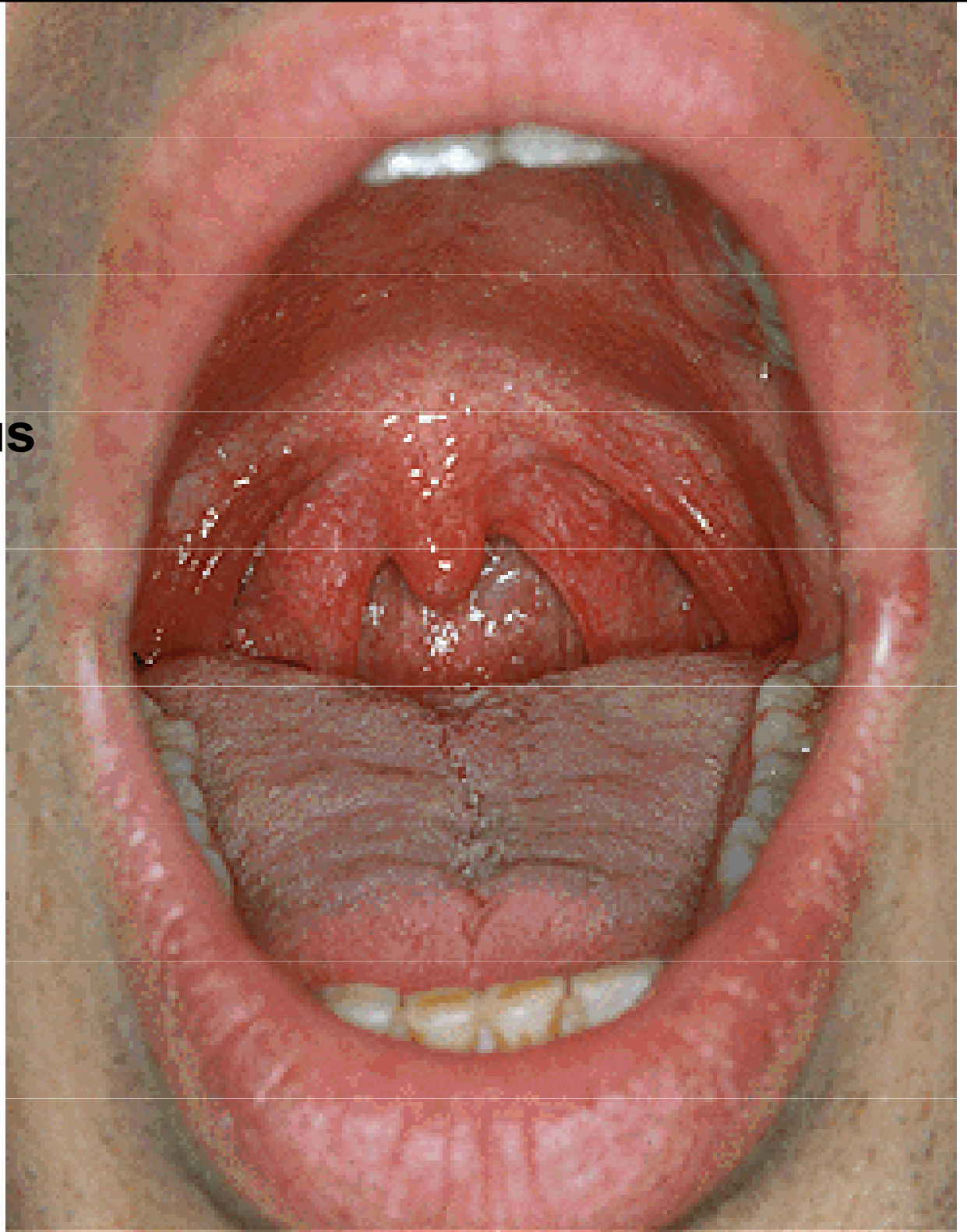

**PALATUM MOLLE
(VELUM PALATINUM)**

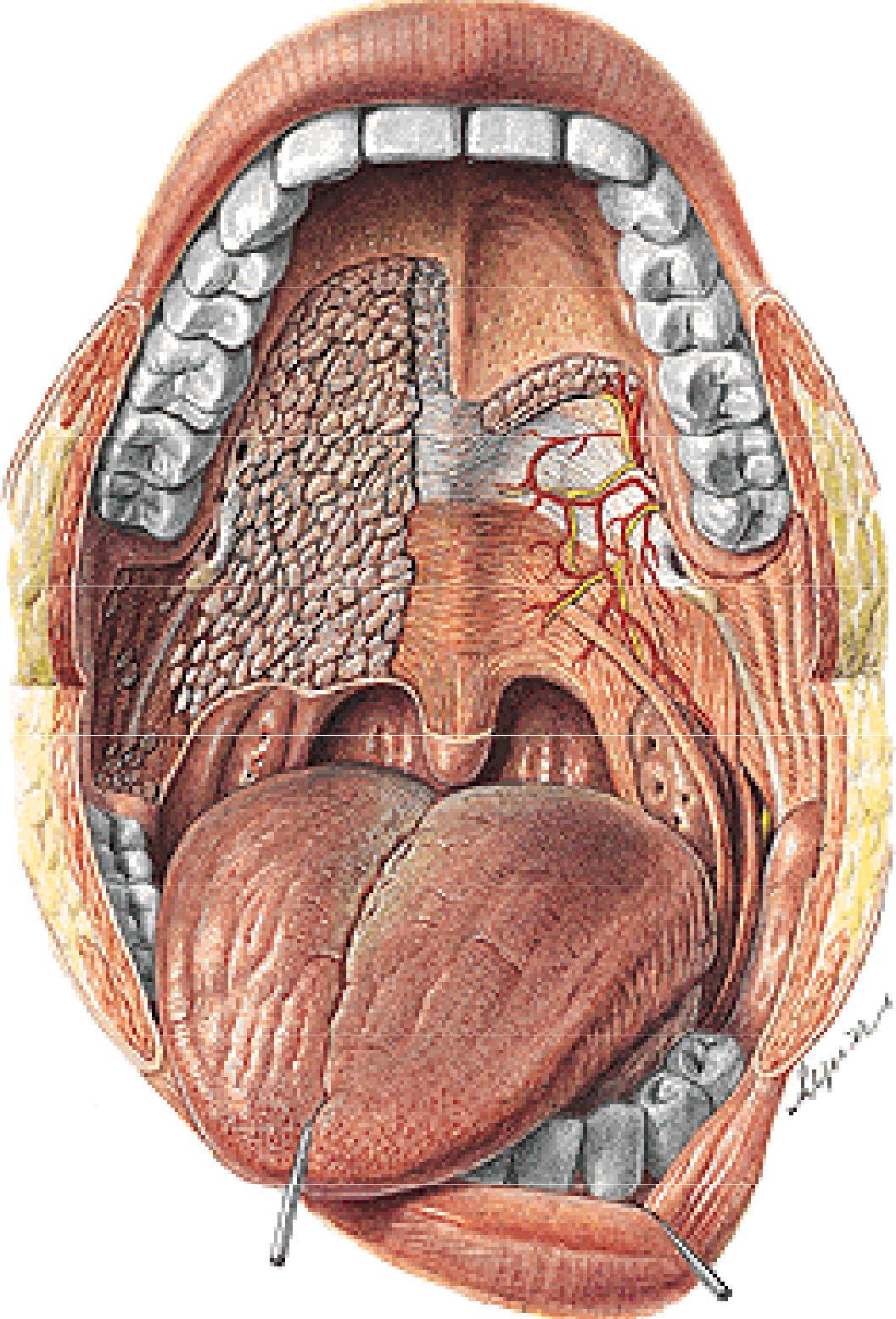
Uvula

Arcus palatoglossus

Arcus palatopharyngeus



Glandulae palatinae



TONSILLA PALATINA

Fossa tonsillaris

Plica semilunaris

Fossa supratonsillaris

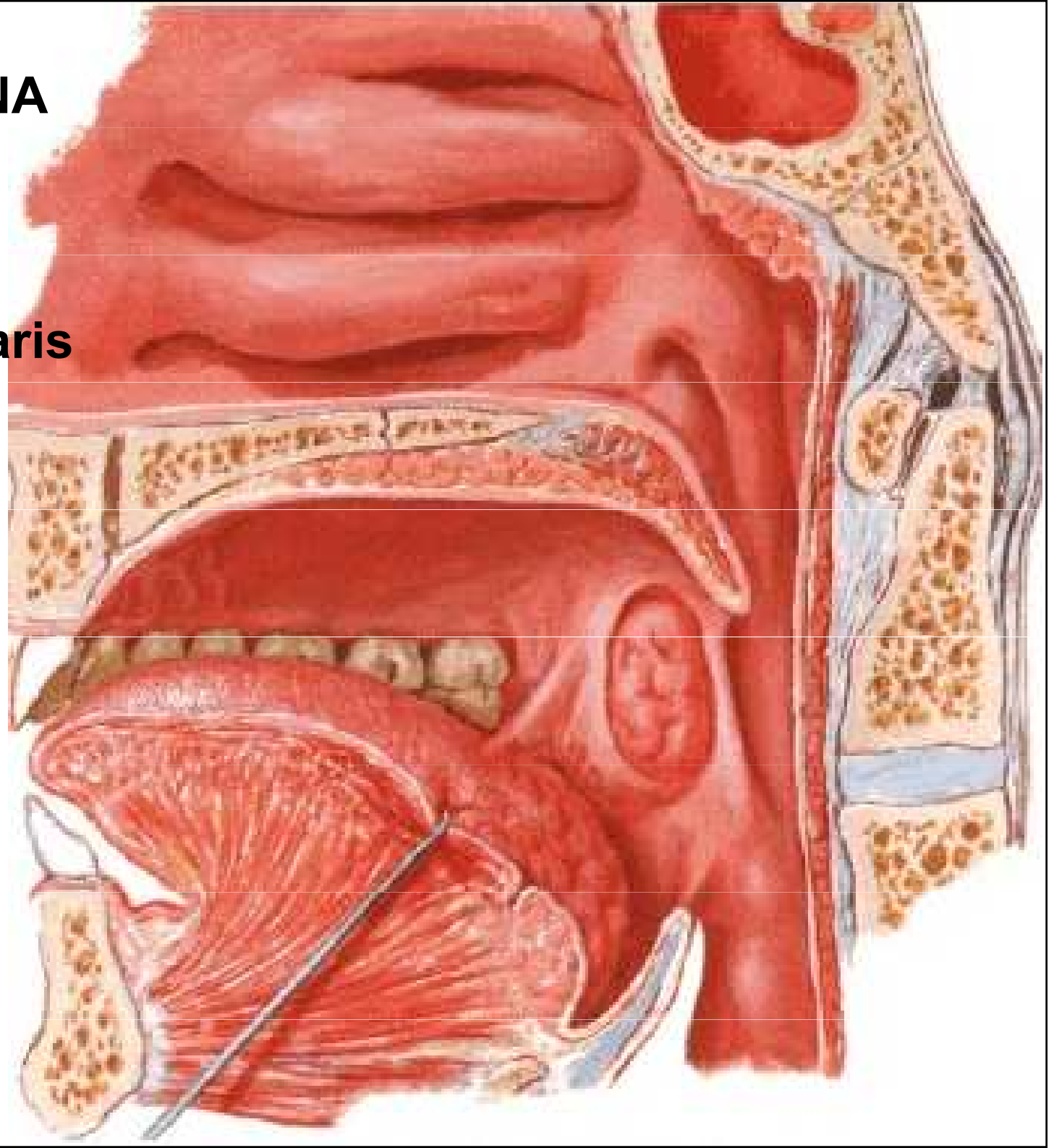
Plica triangularis

Capsula tonsillaris

Paratonsillar vein

Cryptae tonsillares

Tonsillar pegs

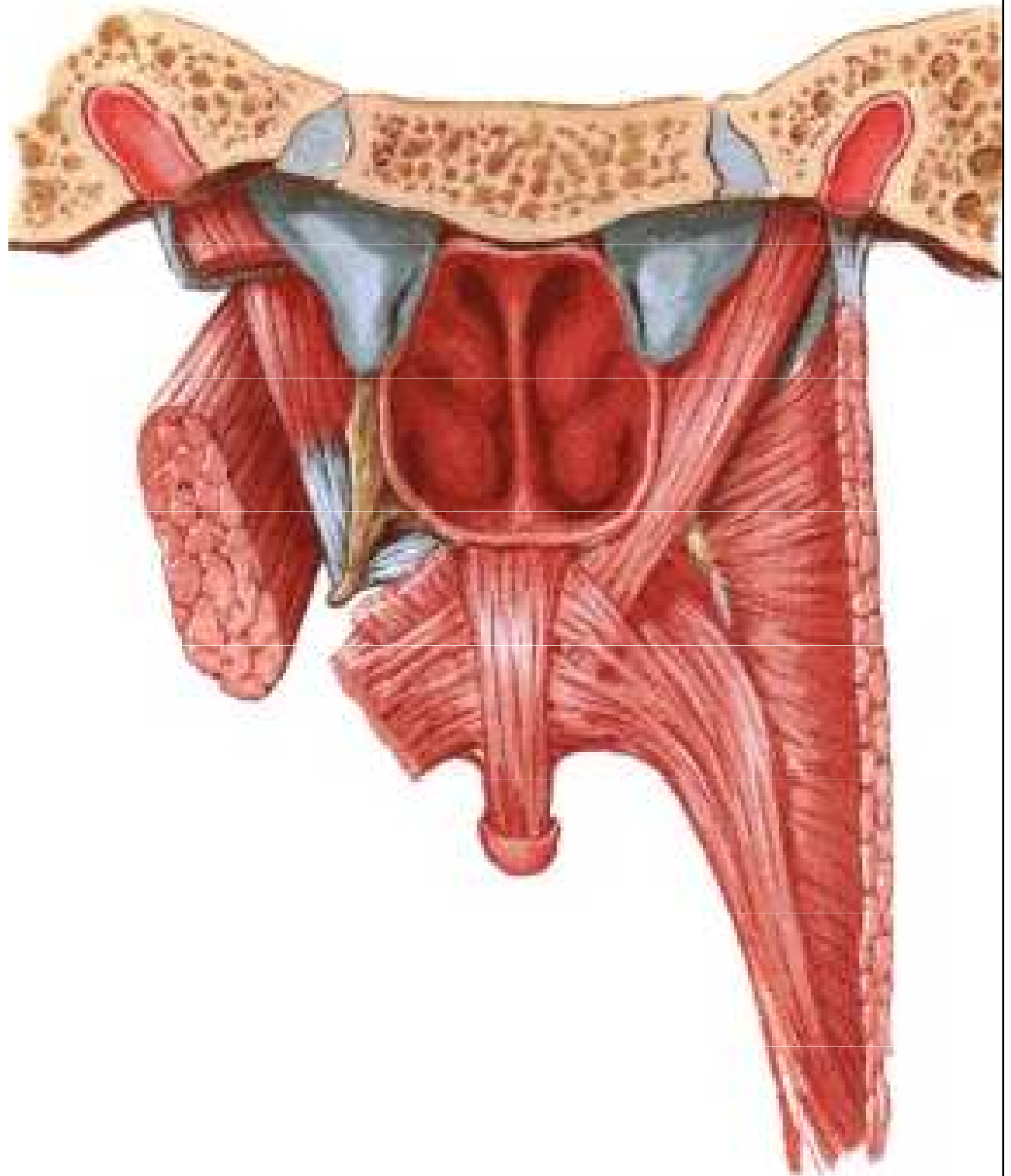


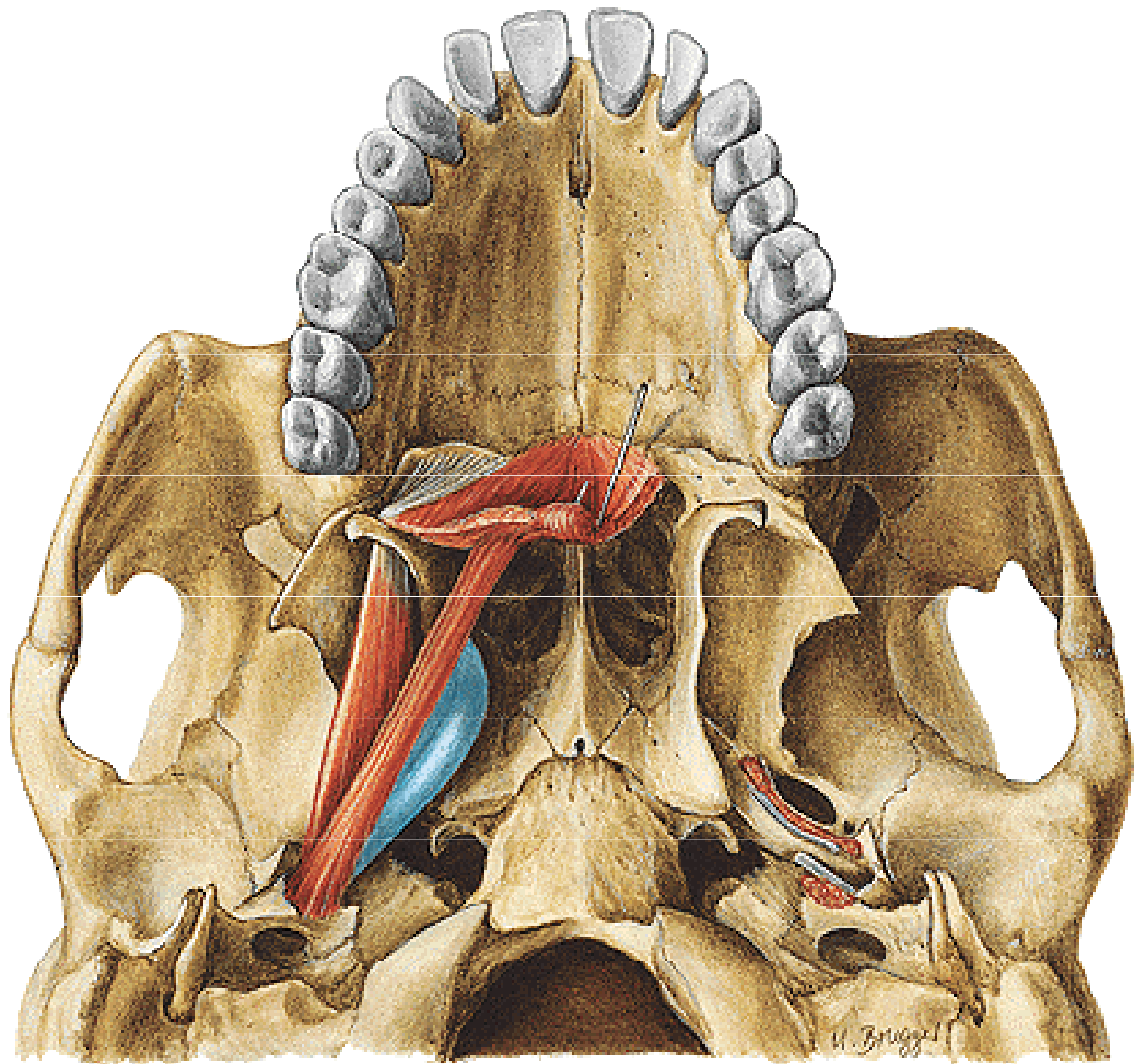
M. levator veli palatini
M. tensor veli palatini
M. uvulae
M. palatopharyngeus
M. palatoglossus

Aponeurosis palatina

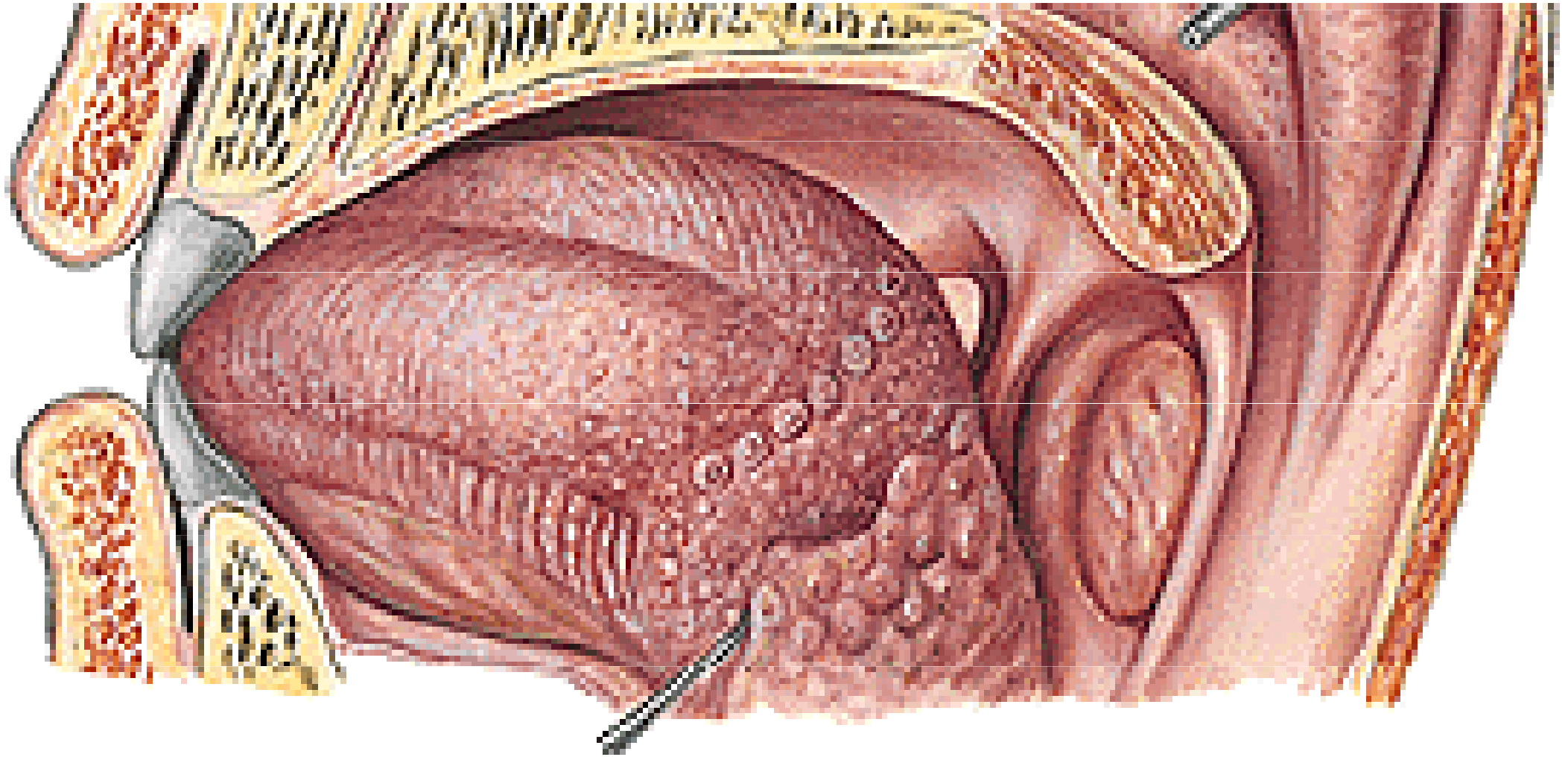
Plexus pharyngeus
– CN IX, X

Tensor – CN V





LINGUA – APEX, CORPUS, RADIX



DORSUM LINGUAE

Sulcus terminalis

Sulcus medianus

Foramen caecum

Ductus thyroglossus

Margines linguae

Papillae filiformes

Papillae fungiformes

Papillae foliatae

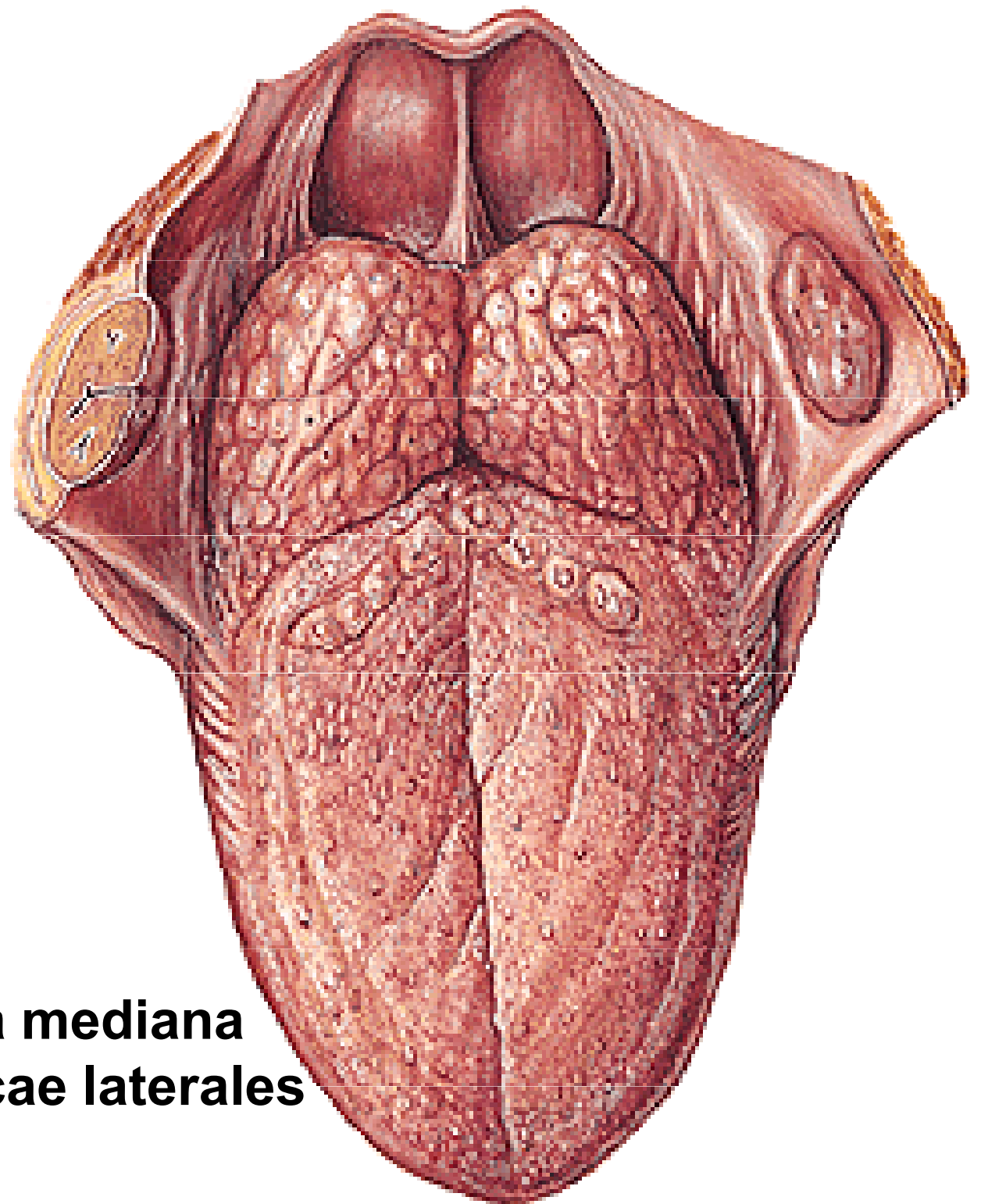
Papillae vallatae

Tonsilla lingualis

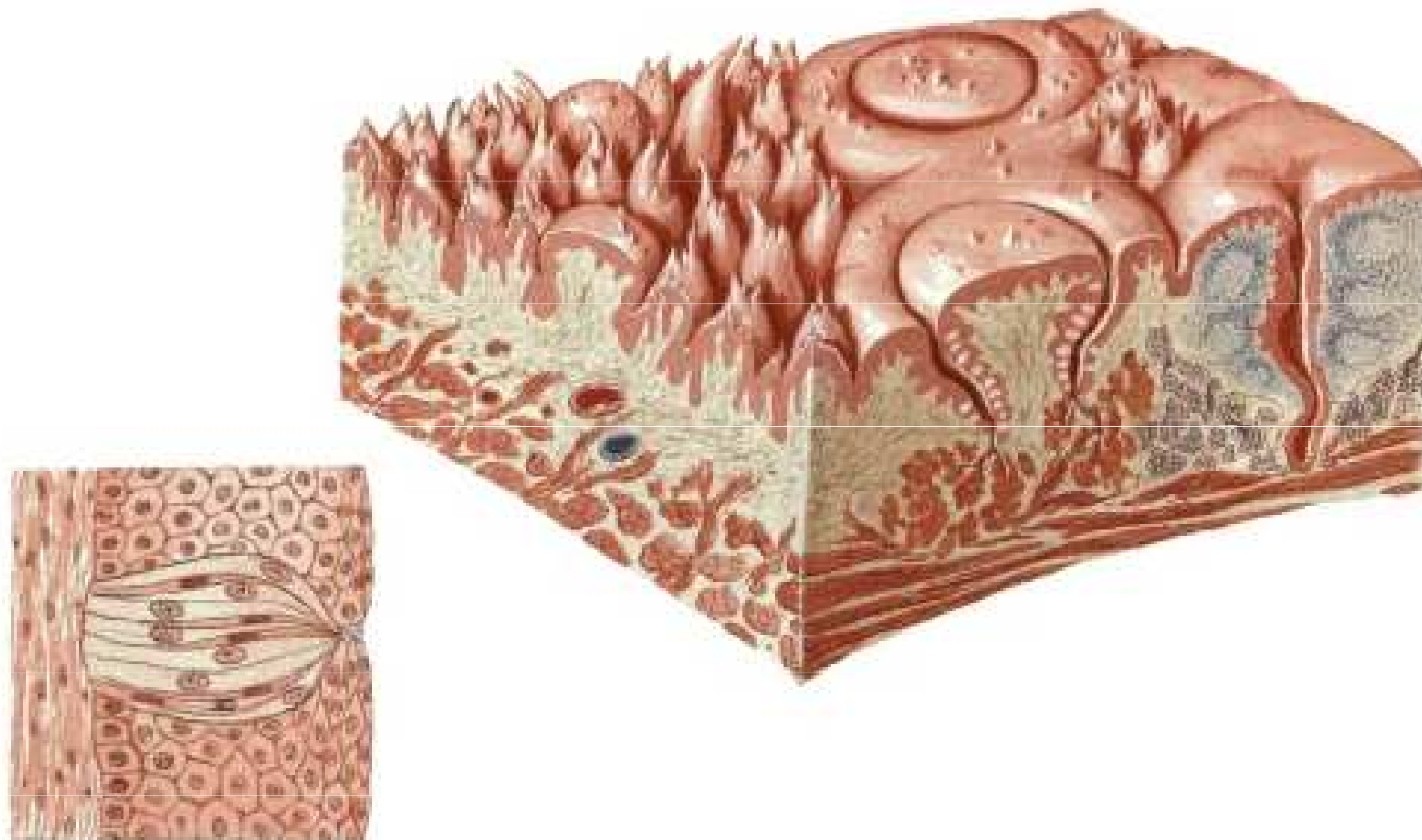
Plica glossoepiglottica mediana

Plicae glossoepiglotticae laterales

Valleculae epiglotticae

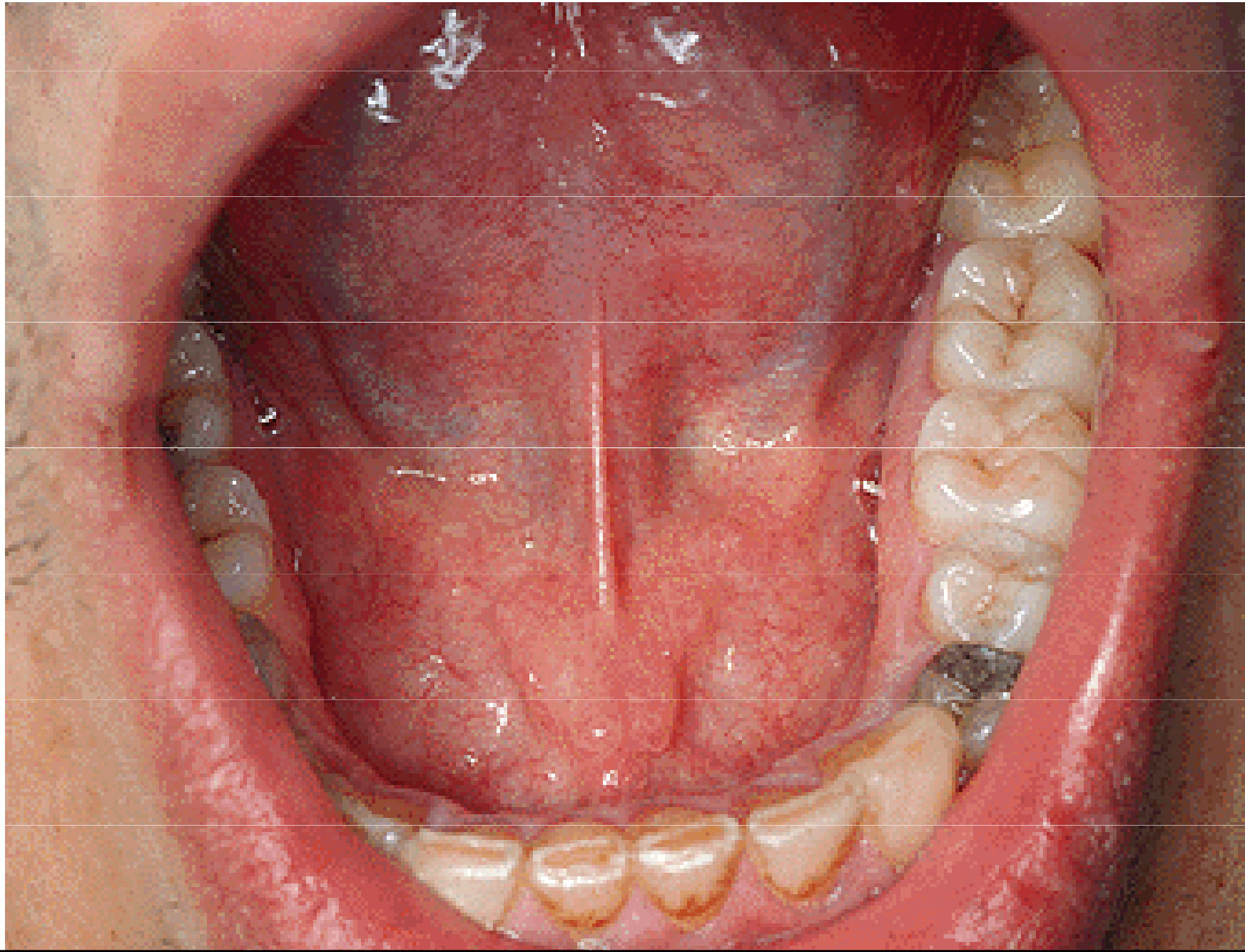


Caliculi gustatorii



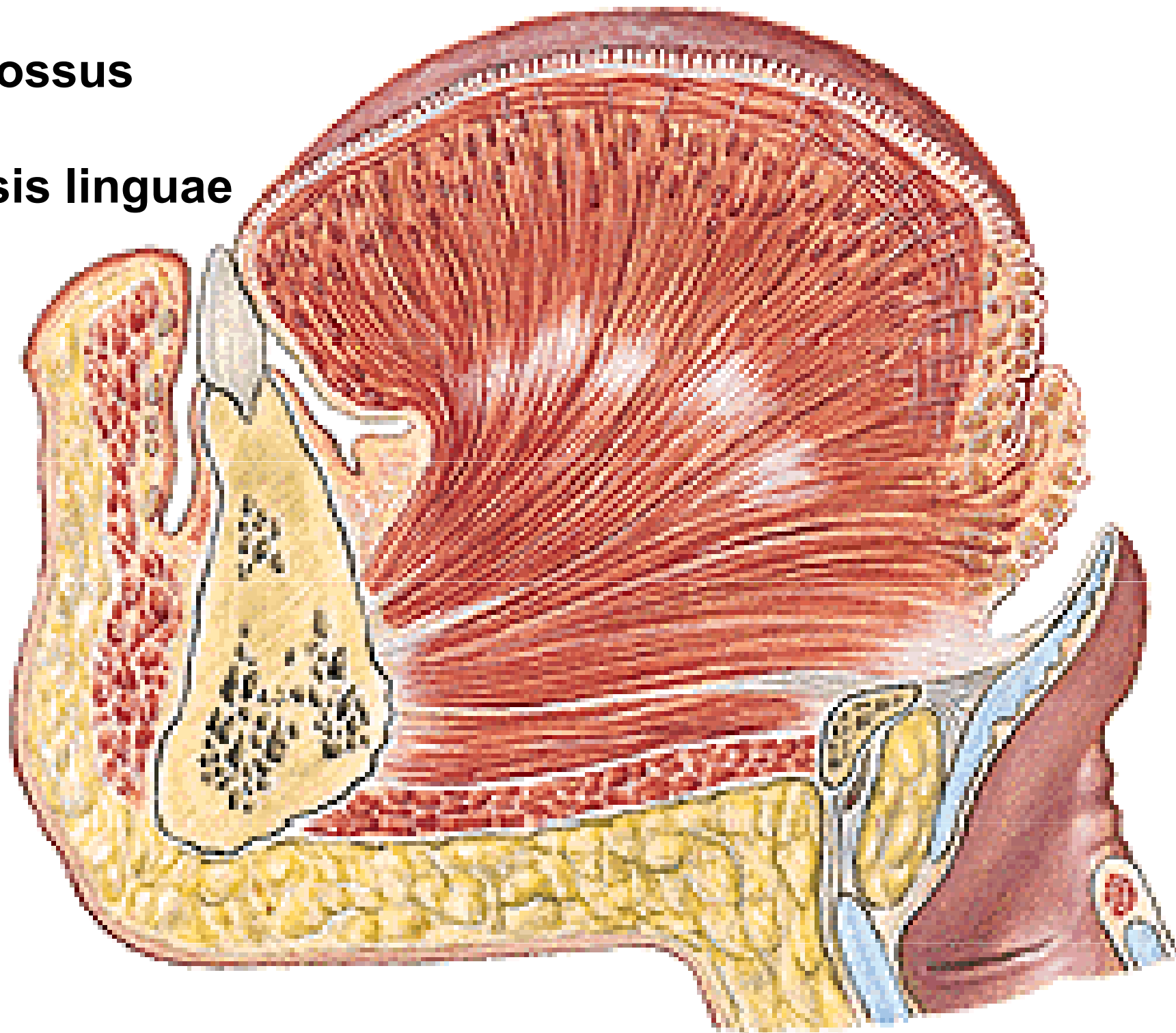
Facies inferior linguae
Plica fimbriata

Frenulum linguae
Plica sublingualis



M. genioglossus

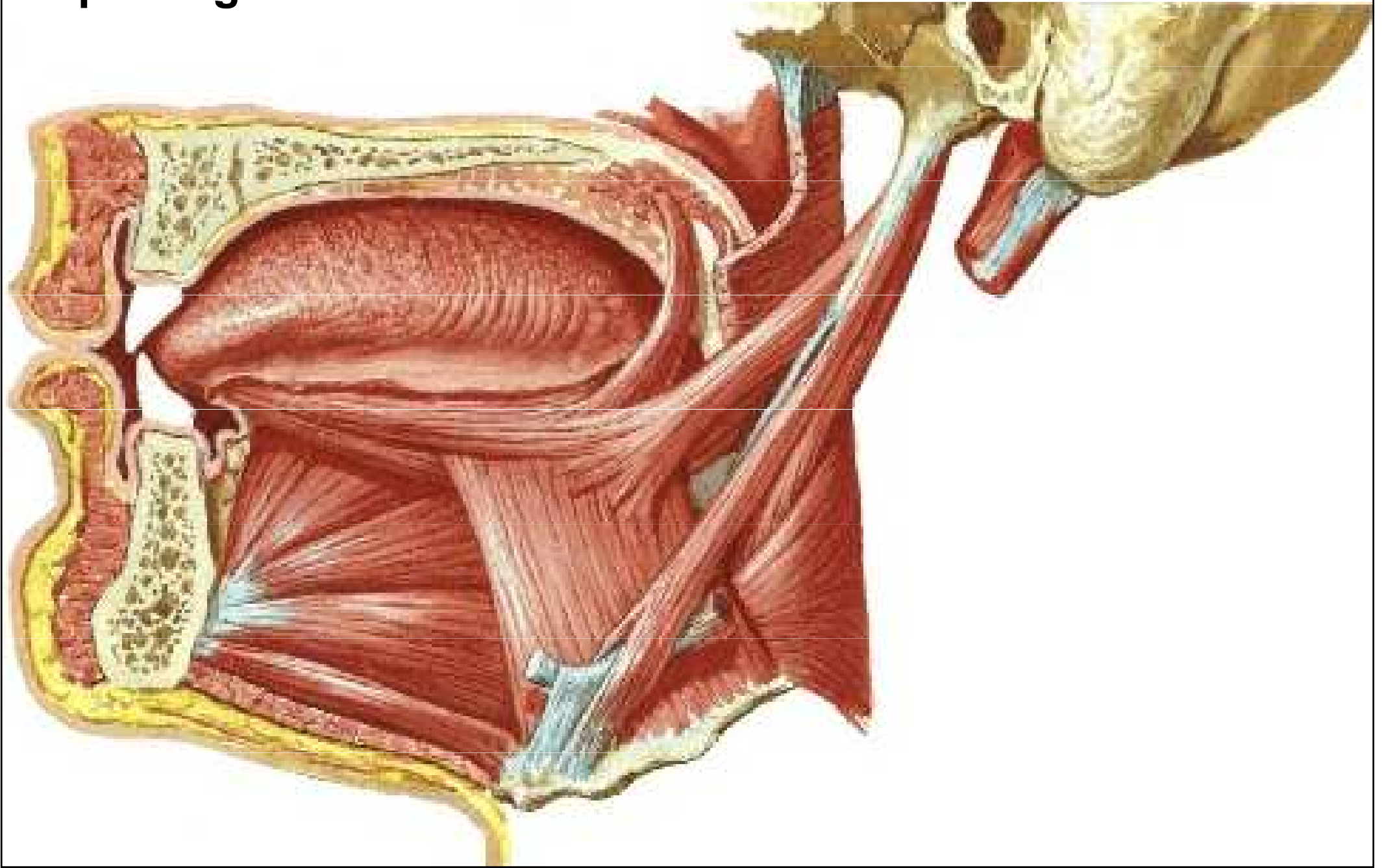
Aponeurosis linguae



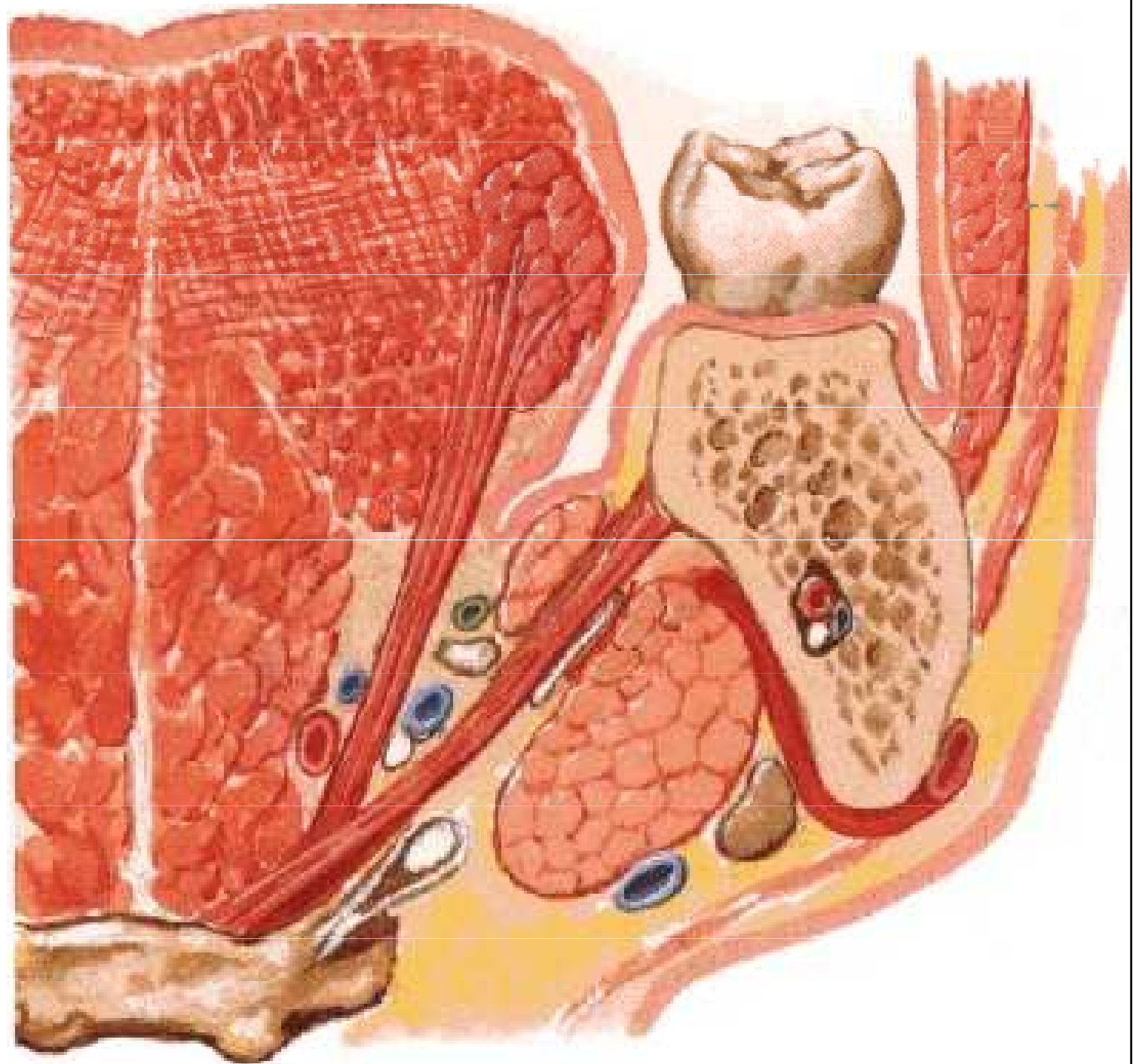
M. hyoglossus

M. styloglossus

M. palatoglossus



Canalis paralingualis – a. lingualis




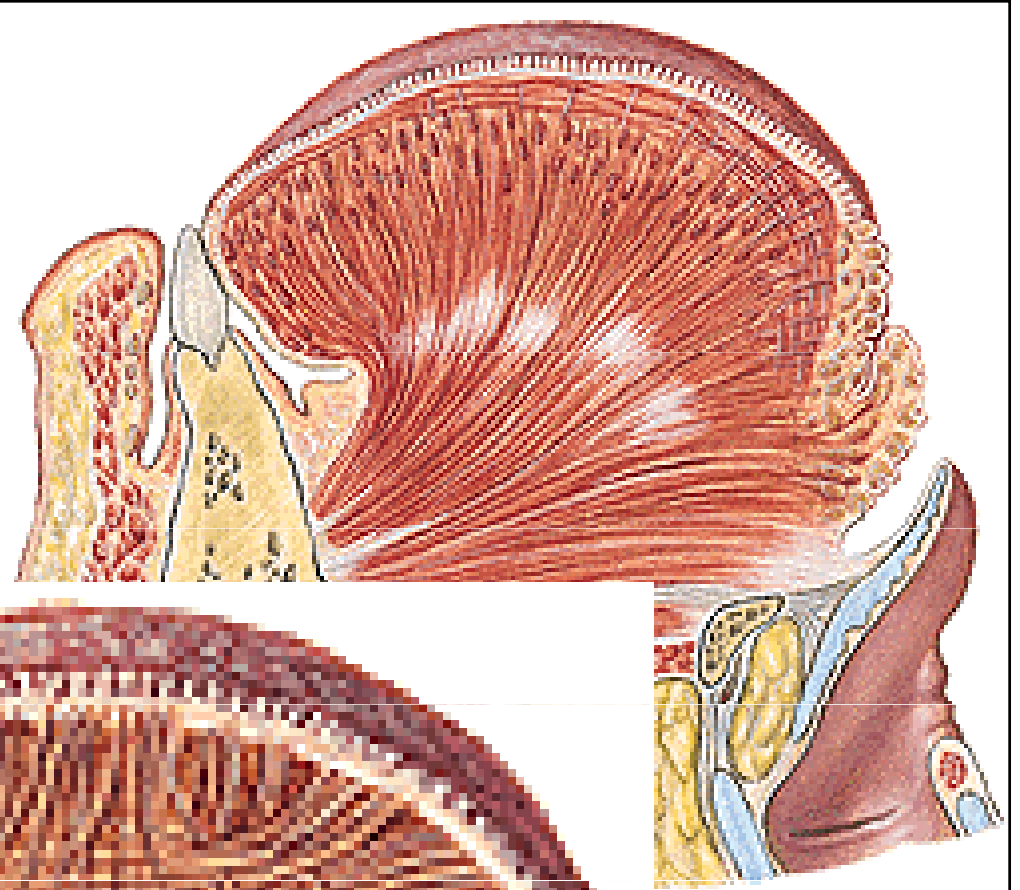
Septum linguae

M. longitudinalis sup.

M. longitudinalis inf.

M. transversus linguae

M. verticalis linguae

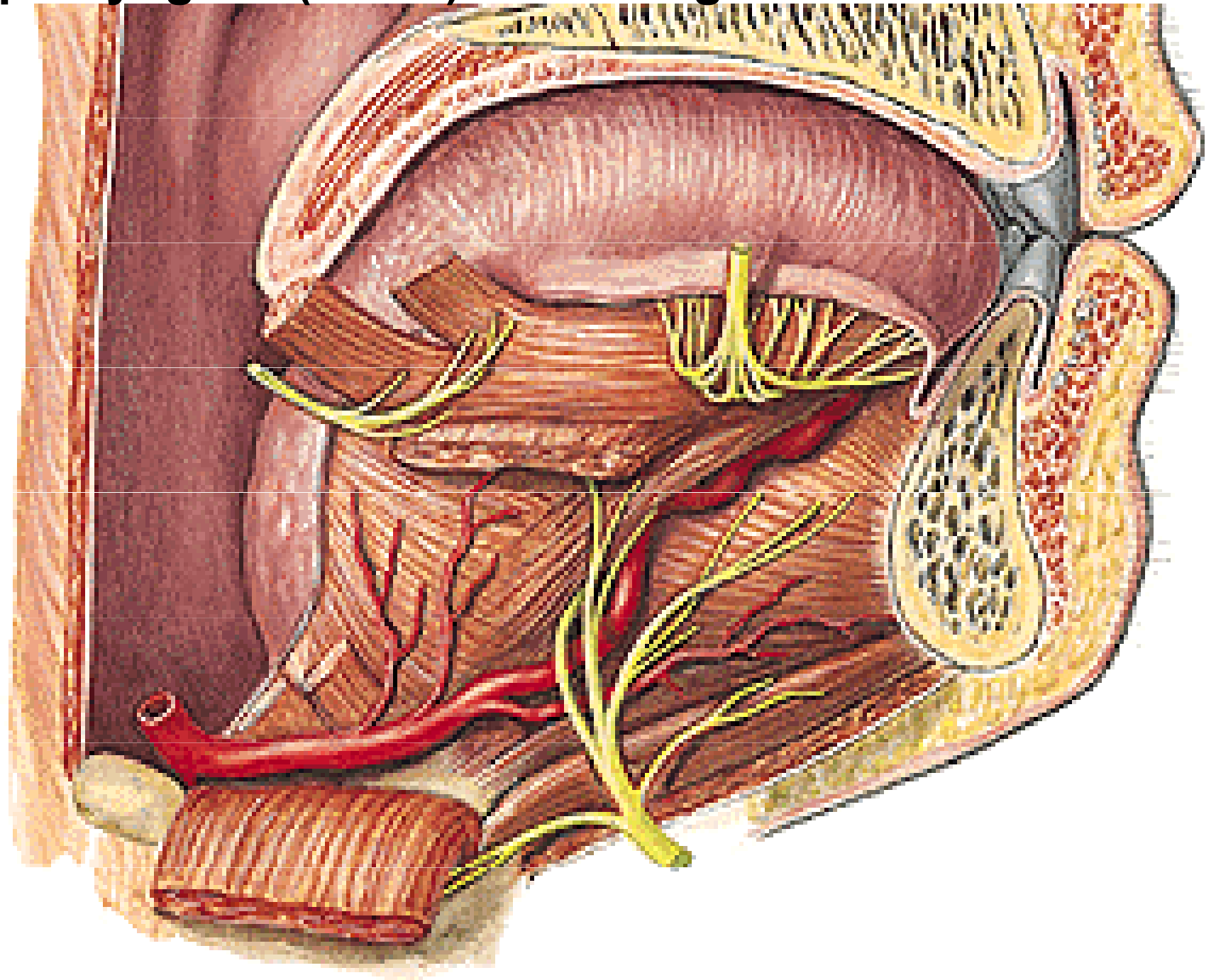


N. lingualis

N. glossopharyngeus (CN IX)

N. hypoglossus (CN XII)

A. lingualis



Illustrations and photographs were copied from:
Atlas der Anatomie des Menschen/Sobotta.
Putz,R., und Pabst,R. 20. Auflage. München:
Urban & Schwarzenberg, 1993)