

Endodontics I.

Morphology

Pulp disease

Indication

Contraindication

Instrumentarium

Endodontics

**Pulp and periodontal diseases –
diagnosis, therapy, prevention**

Aim of endodontic treatment

**Healing of pulp diseases or removal
bacteria from the root canal system
and regeneration of damaged periodontal
tissues. (Canal shaping, cleaning and filling)**

„ *Endodontist helps nature only* “

W.D.Miller

Endodoncie I.

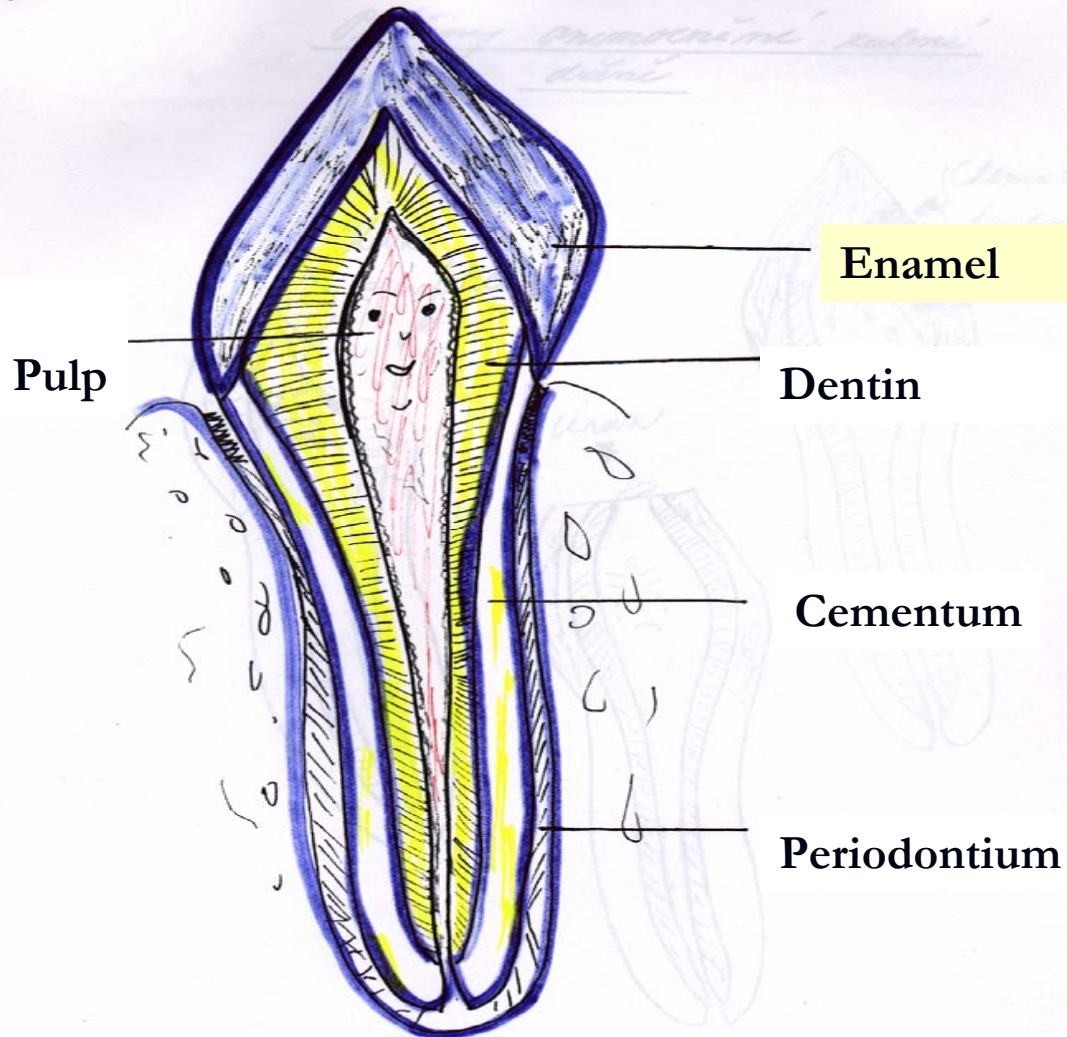
Morphology

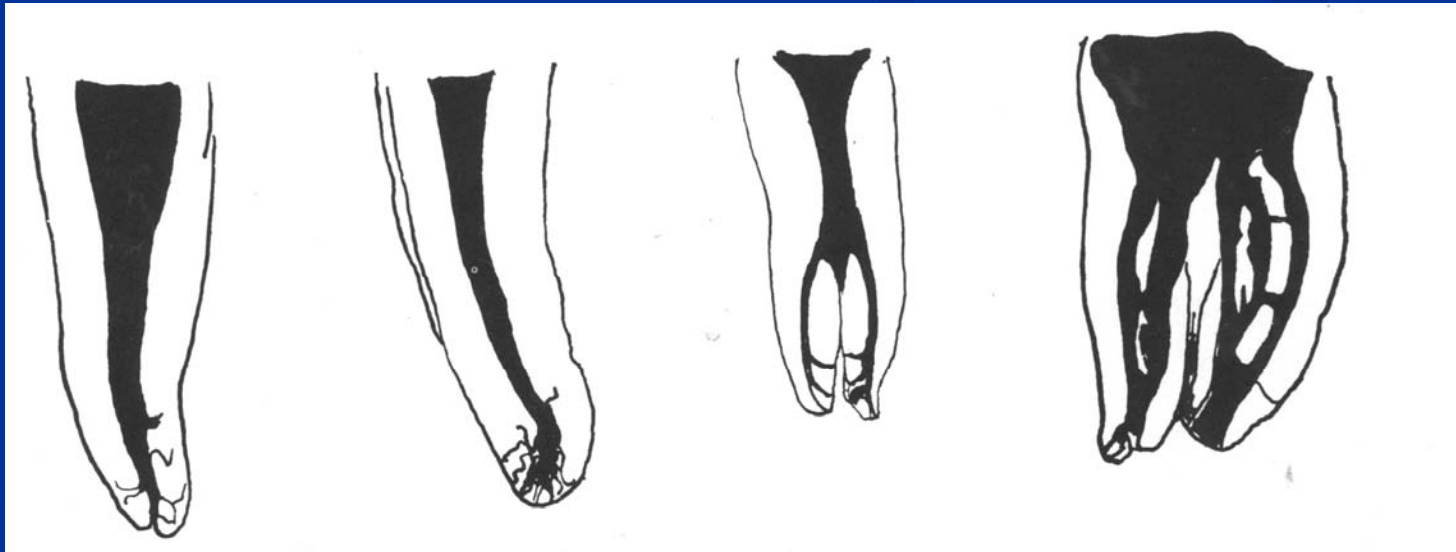
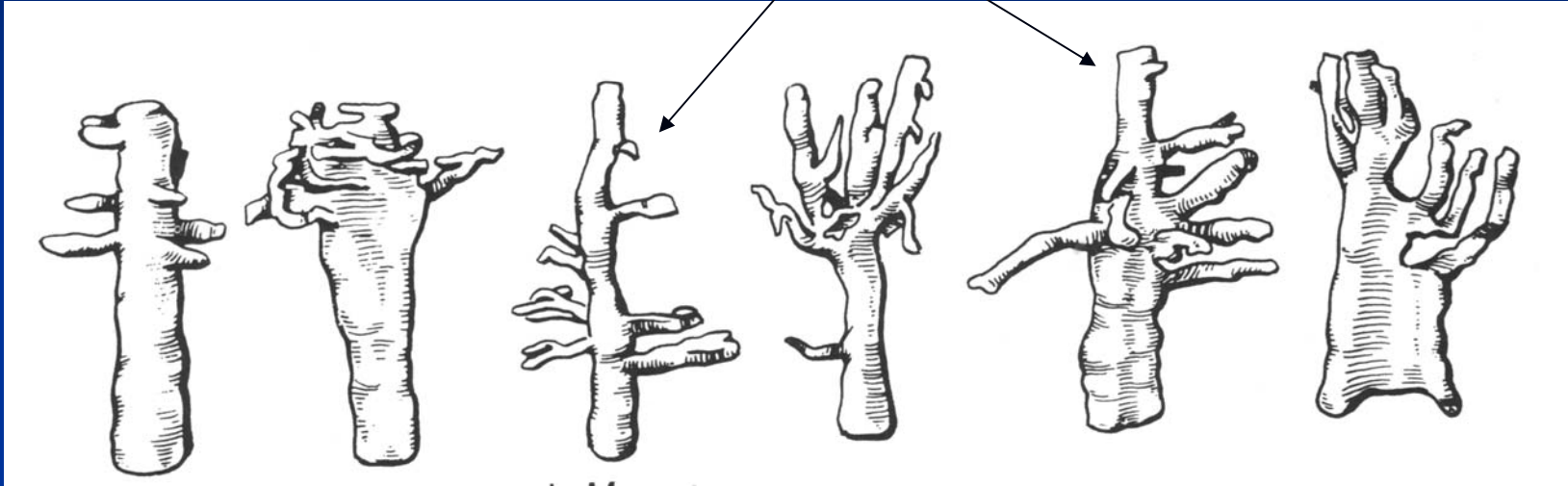
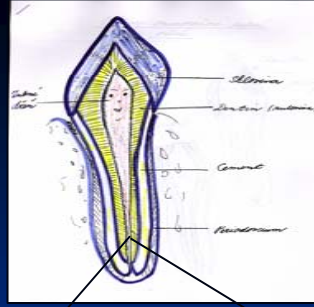
Onemocnění zubní dřeně

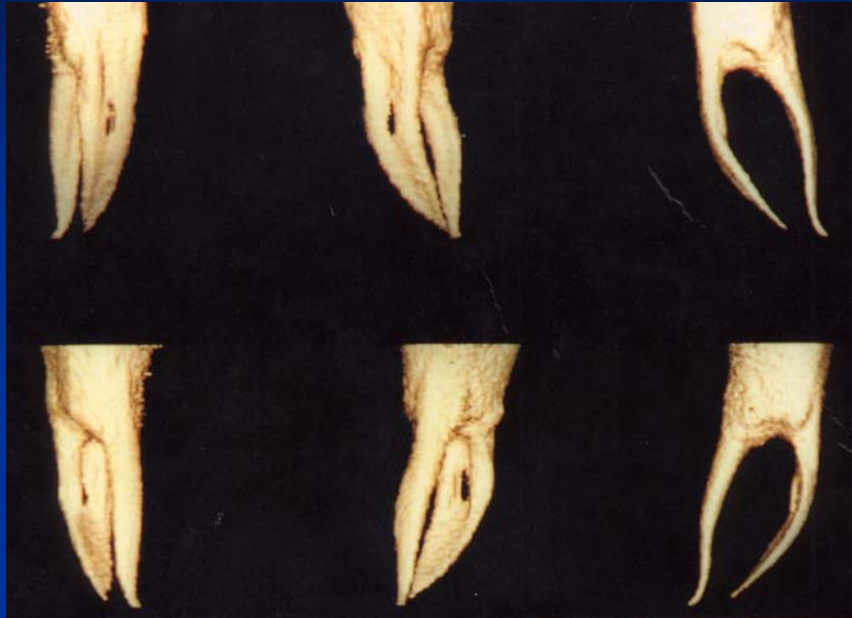Indikace a kontraindikace
endodontického ošetření

Instrumentarium

Morphology







3D

Meyer's conclusions

- The root canal is not round but oval (long axis mesiodistal)
- The root canal does not go straight but it deflects distal
- The outfall is not on the top of the root but below (distal or distooral)

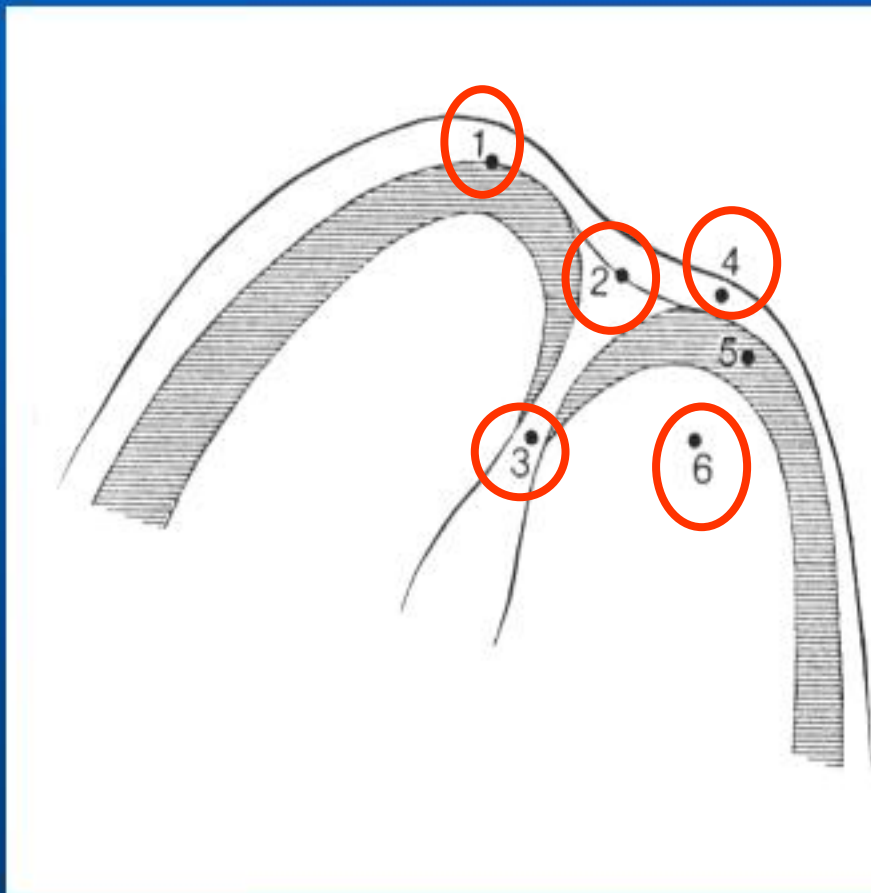
Meyer's conclusions

- The form of the outfall is funnel - shaped
- The root canal system has usually more outfalls (ramifications)
- The ramifications are situated mostly in apical area (first apical mm)
- All outfalls are situated in cementum

Basic forms of the root canal system (Weine)



Apical morphology

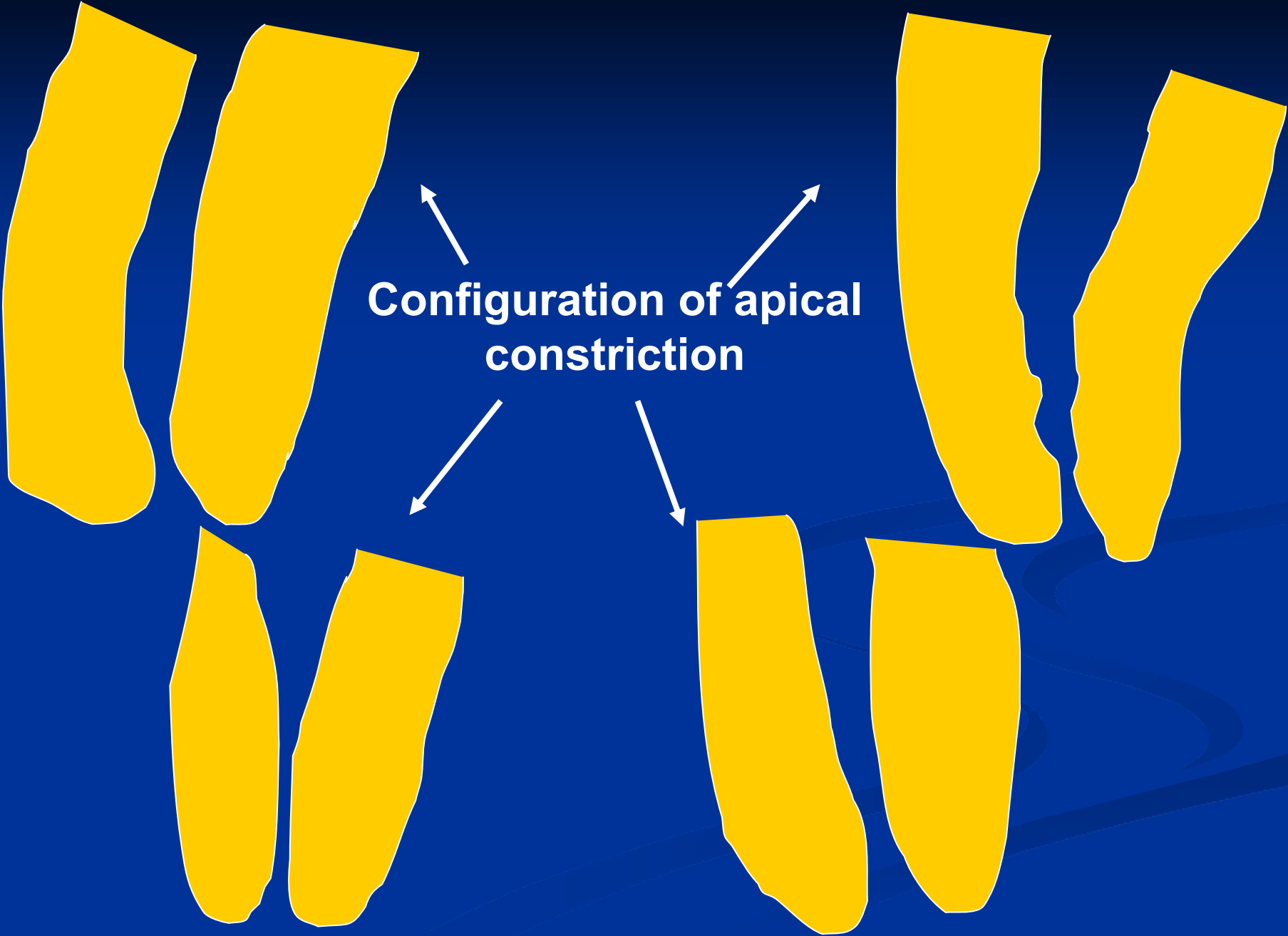



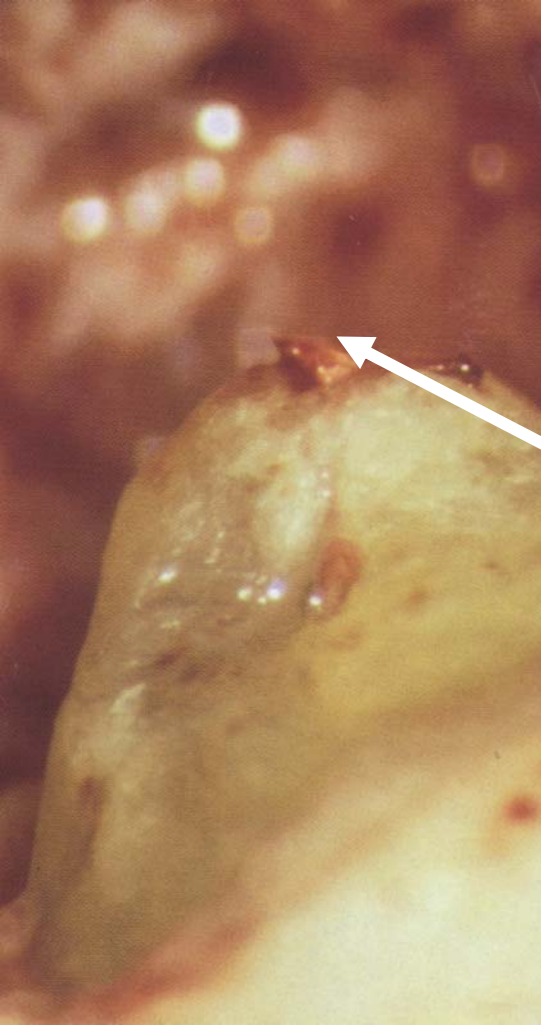
1. X – ray apex
2. Foramen apicale
3. Apical constriction
4. Periodontal ligament
5. Root cementum
6. Dentin

Canal shaping terminates in apical constriction

- Small communication
- Less risk of periodontal damage
- Prevention of overfilling
- Prevention of apical transport of infectious material
- Possibility of good bacterial decontamination
- Possibility of good condensation of the root filling

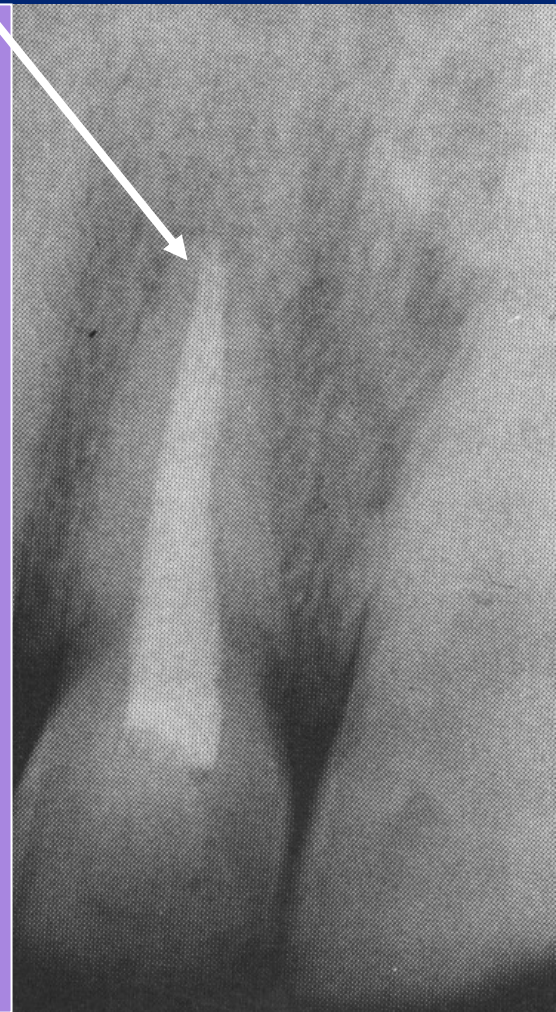**Configuration of apical
constriction**






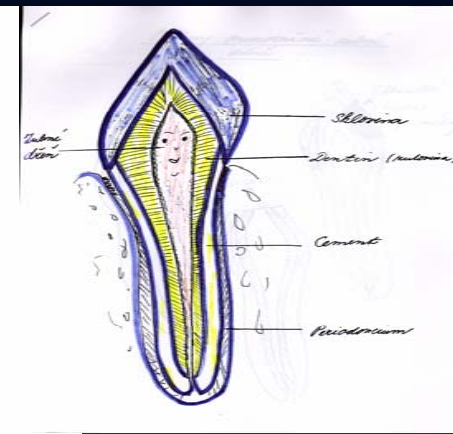
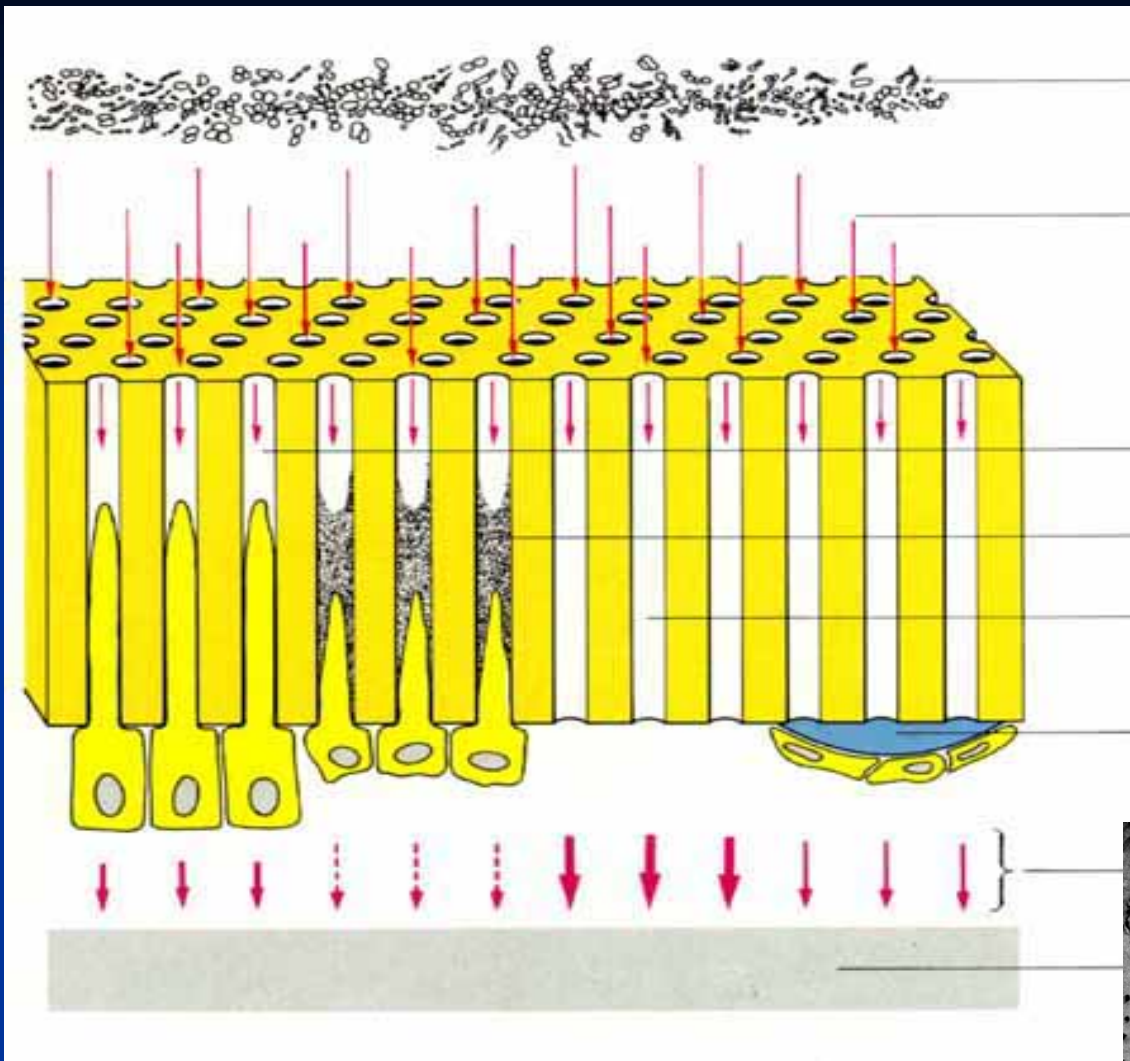
Real situation

X- ray apex




- Macrocanal system

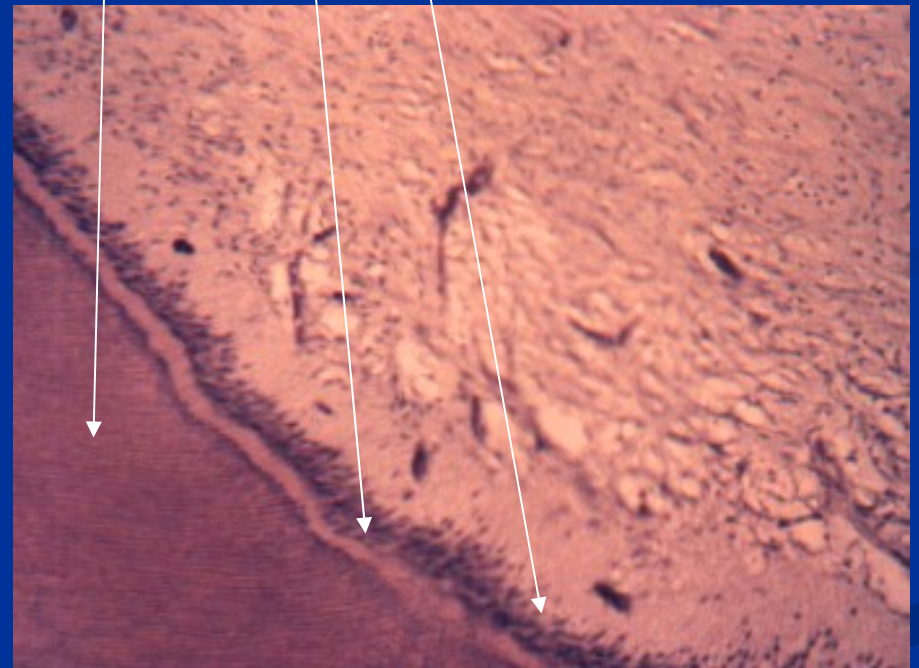
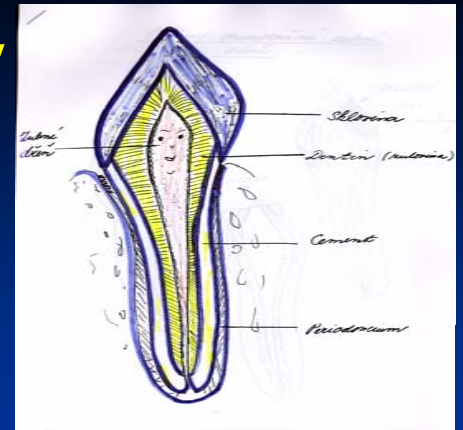
- Microcanal system



**Endodont: dentin and pulp
(morphological and functional unit)**



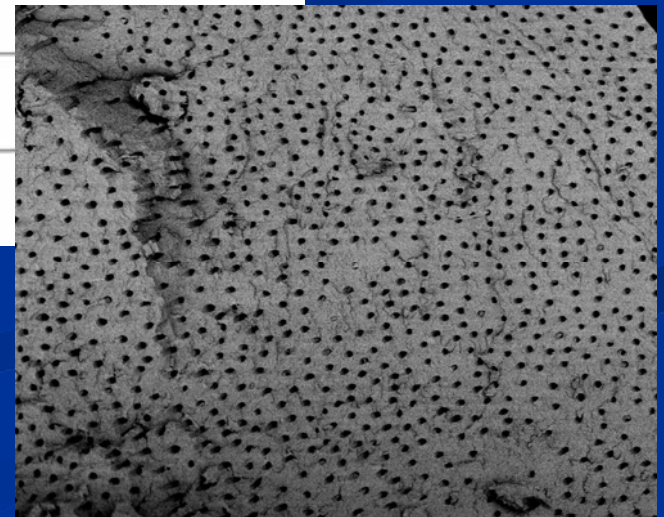
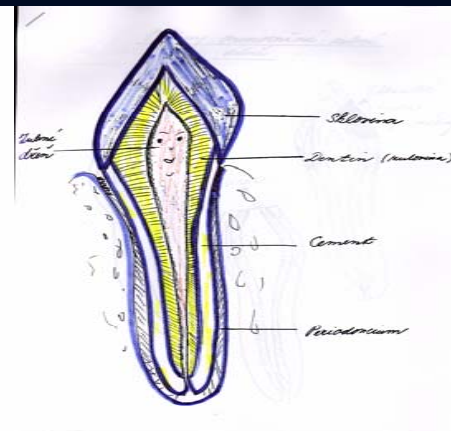
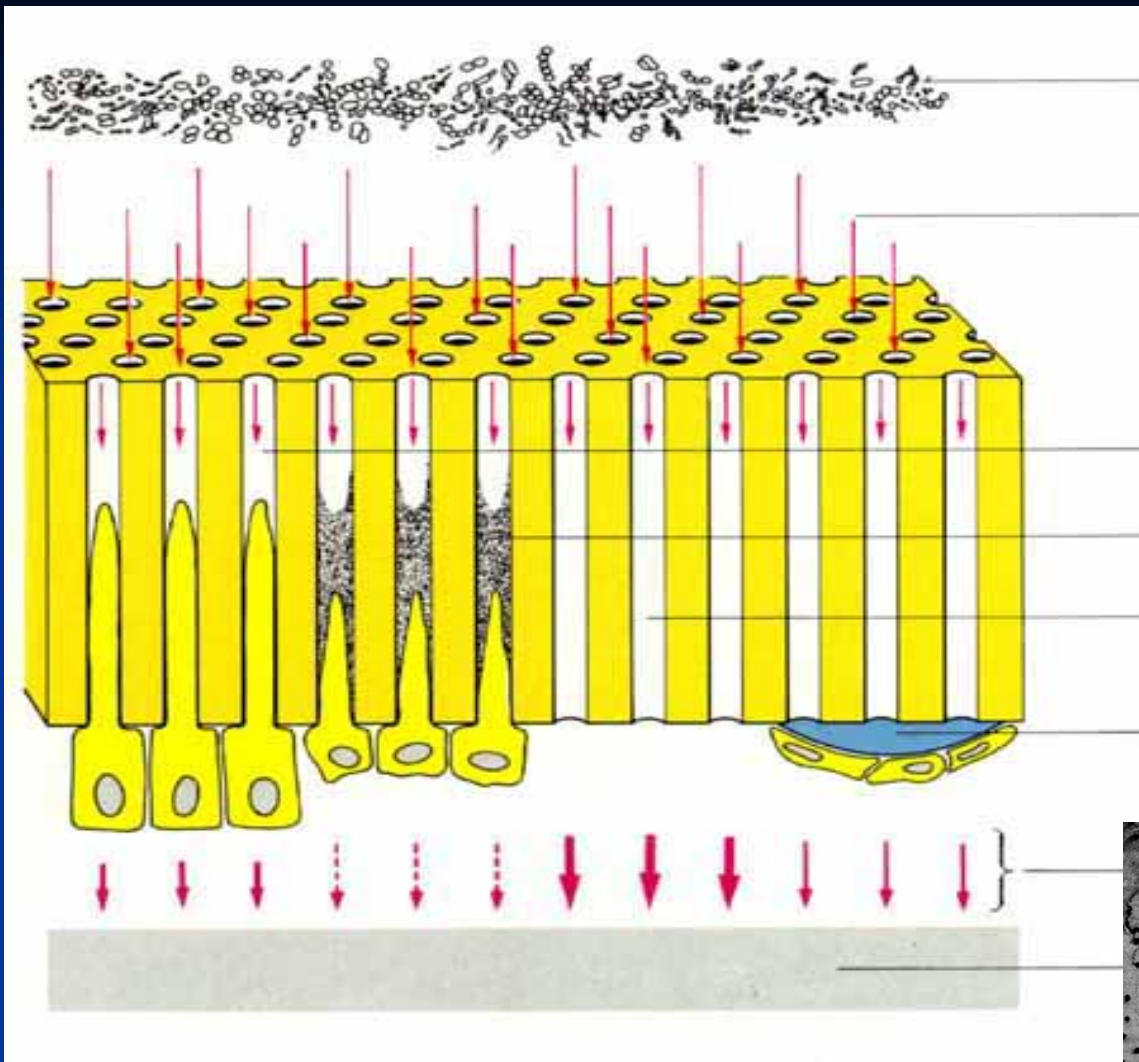
Odontoblasty Predentin Dentin



Dental pulp

Defense mechanisms of the pulp

- Sclerosis
- Tertiary dentin
- Dentin bridge



Endodont – dentin and pulp

Pulp diseases

Inflammation - pulpitis

Consequences

- Necrosis
- Gangraena
- Apical periodontitis

Reasons

- Bacteria
- Mechanical irritants (overinstrumentation, trauma)
- Chemical irritants (esp. phenolic based intracanal medicaments, overfilling, irrigants)

Classification of pulp diseases

- **Histopatological**

Hyperemia pulpae

**Pulpitis acuta serosa partialis
totalis**

**Pulpitis acuta purulenta partialis
totalis**

Classification of pulp diseases

- Histopathological

Pulpitis chronica clausa

aperta

ulcerosa

polyposa

Classification of pulp diseases

Clinical

Reversible pulpitis

Pain does not linger after stimulus is removed

Pain is difficult to localize

Normal periradicular appearance

Teeth are not tender to percussion

Classification of pulp diseases

Clinical

Irreversible pulpitis

Pain may develop spontaneously or from stimuli

In later stages heat is more significant

Response lasts from minutes to hours

When the periodontal ligament is involved, the pain is localized

A widened periodontal ligament may be seen in later stages



Úprava ad integrum ?

ZUBNÍ DŘEŇ



Zánět

Akutní

Chronický

Nekróza

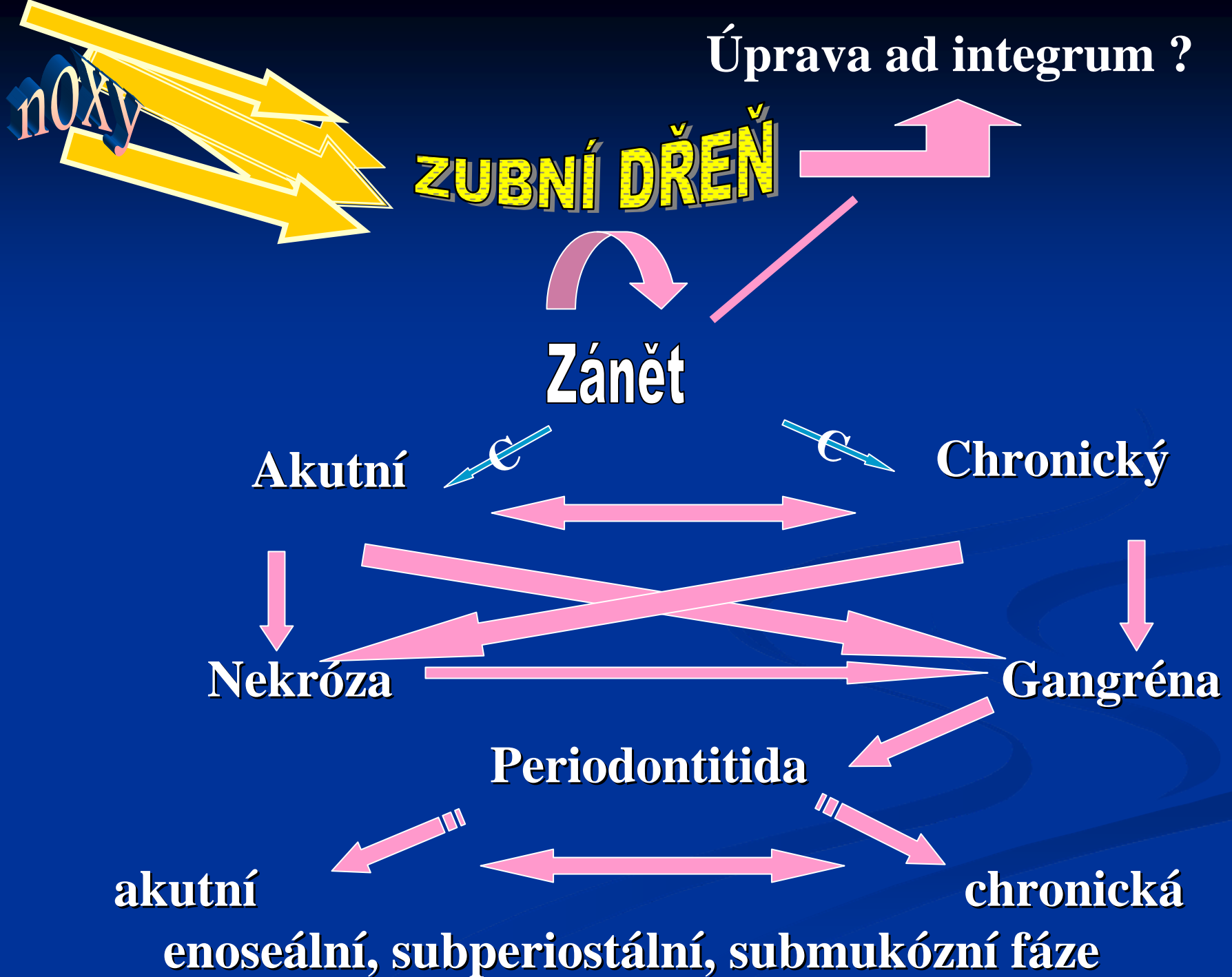
Gangréna

Periodontitida


akutní

chronická

enoseální, subperiostální, submukózní fáze



Cumulative trauma pf dental pulp



Diagnosis

■ History

Presenting complaint

Medical history

Dental history

Pain history

Location

Type and intensity of pain

Duration

Stimulus

Relief (analgetics, antibiotics, sipping cold drinks)

Diagnosis

Clinical examination

Extraoral (swelling, redness, extraoral sinuses, lymph nodes, degree of mouth opening)

Intraoral examination

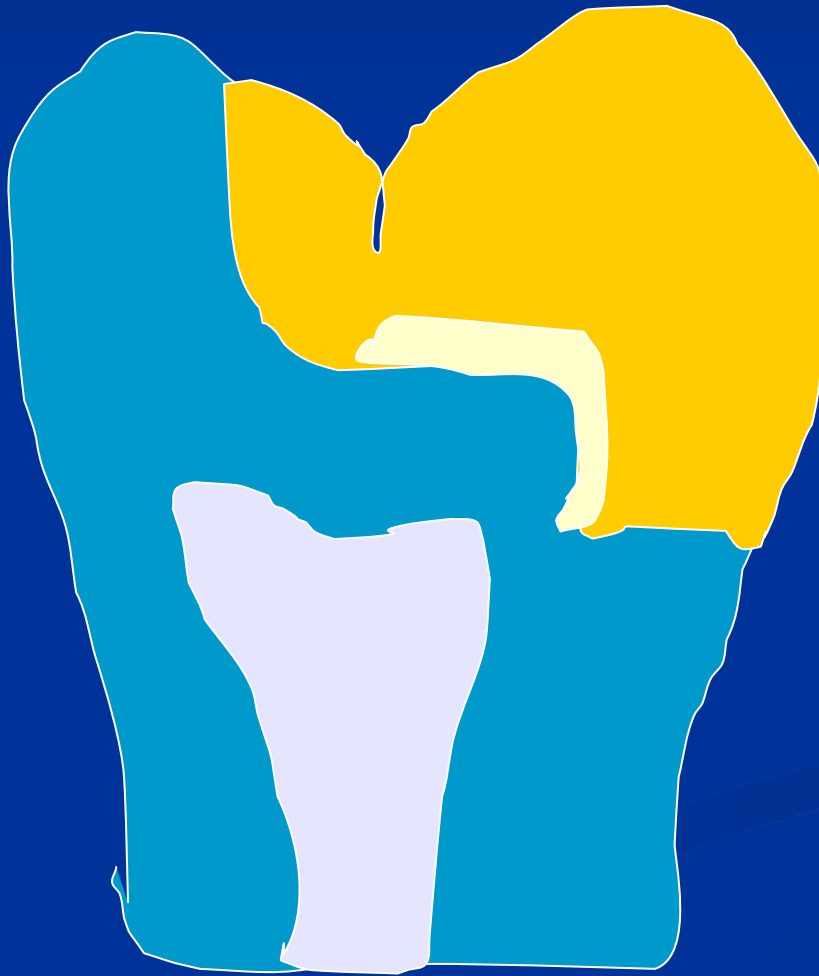Swelling, redness, palpation, percussion, sinus tract examination, teeth mobility, pockets

Diagnosis

Clinical examination

Pulp sensitivity tests, radiographic examination, transillumination.

Protection of dentin wound



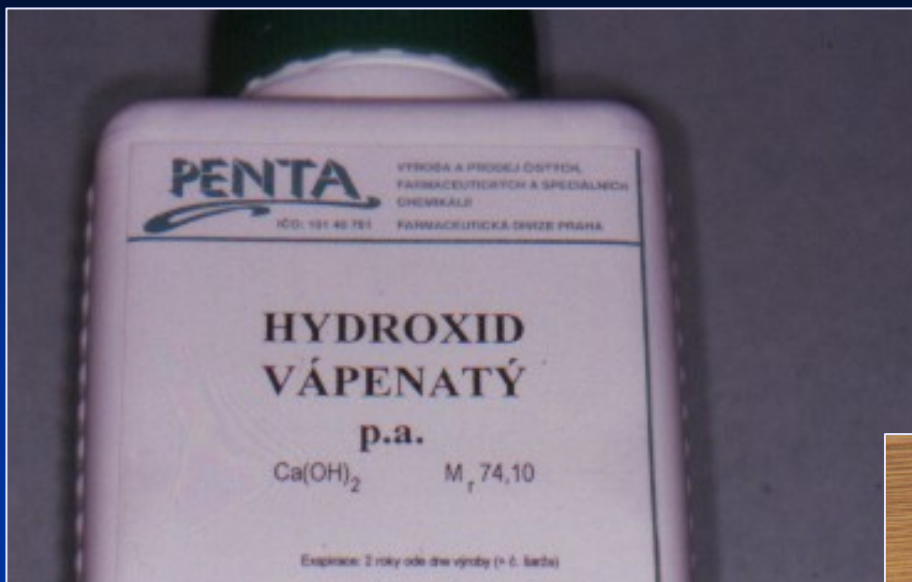
Against:

Thermal

Chemical

Electrical

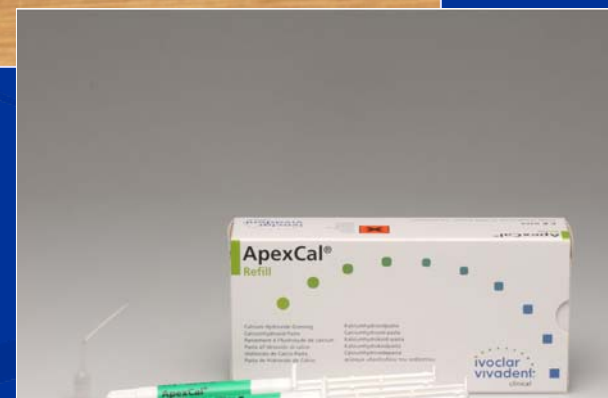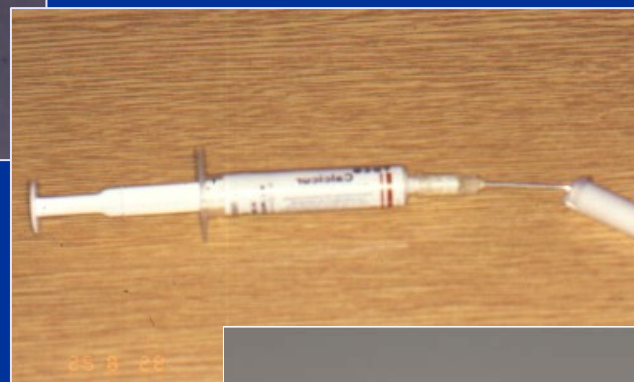
Irritation

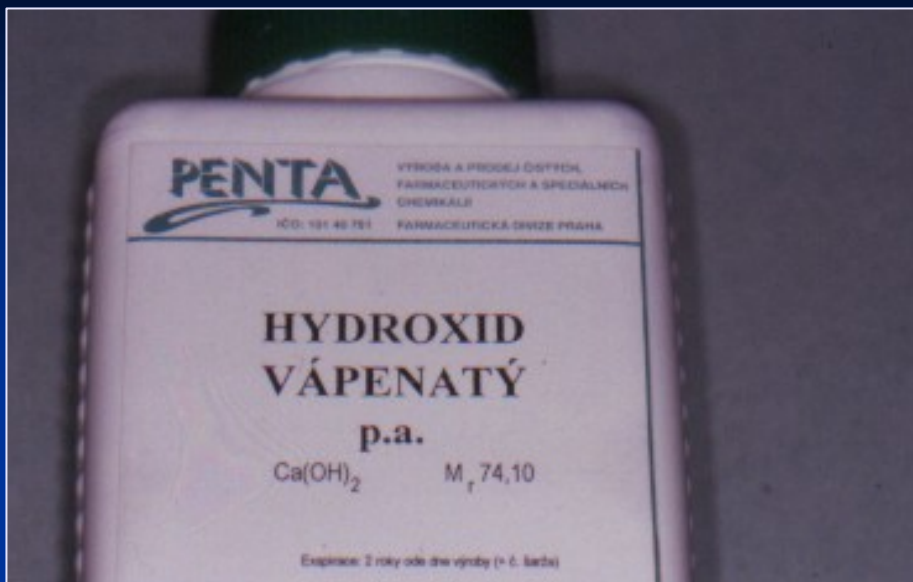


Disociace – silná alkalita

Malá rozpustnost – vápenná voda

Suspenze (vápenné mléko, vápenná kaše)





Antiflogistický

Dentinogenní

Antimikrobiální efekt

Suspenze

Cementy

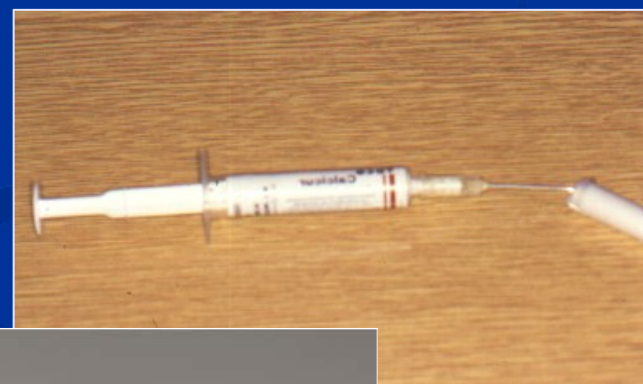
Subbase

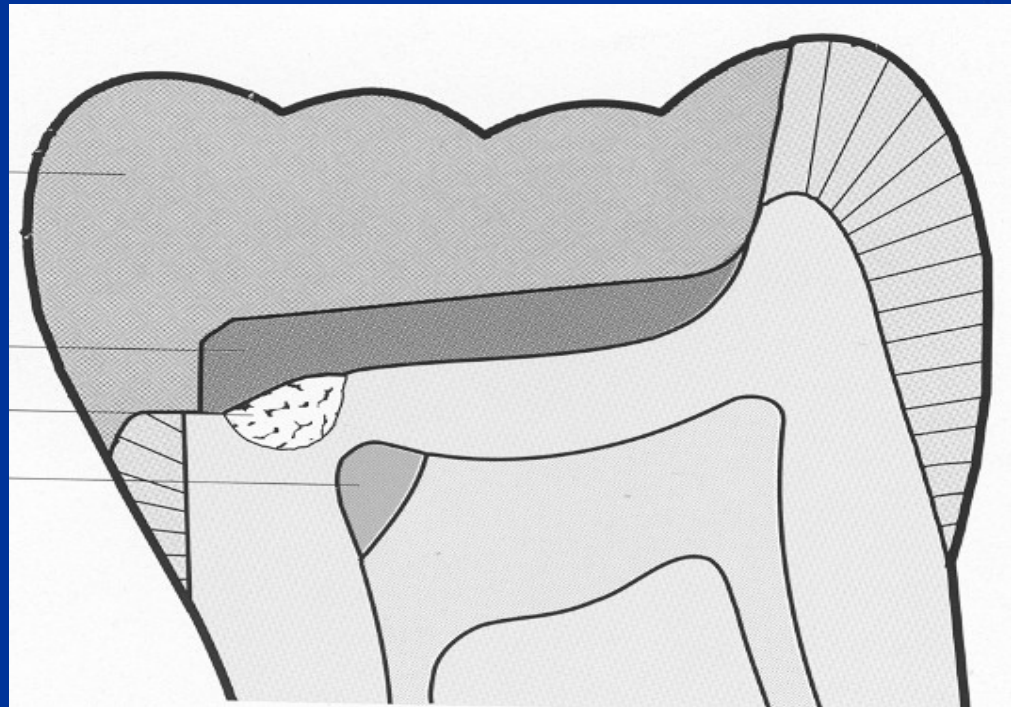
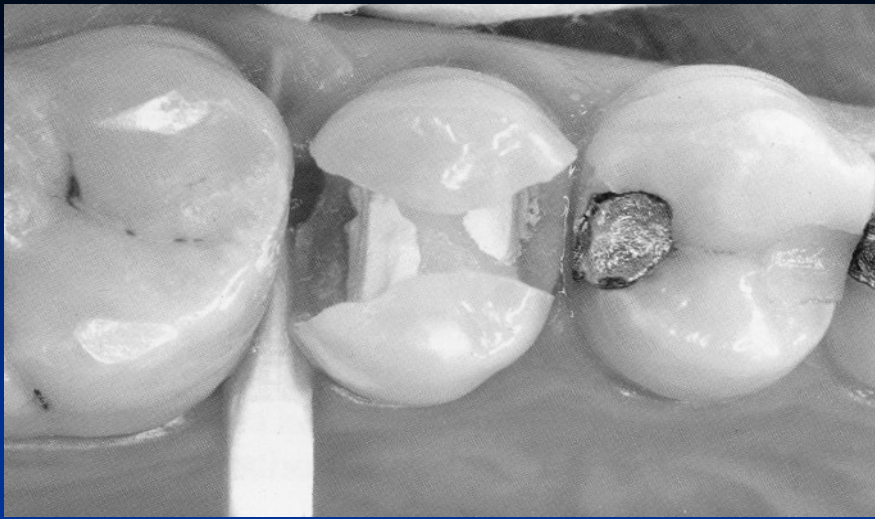
Kořenová výplň

- krátkodobě

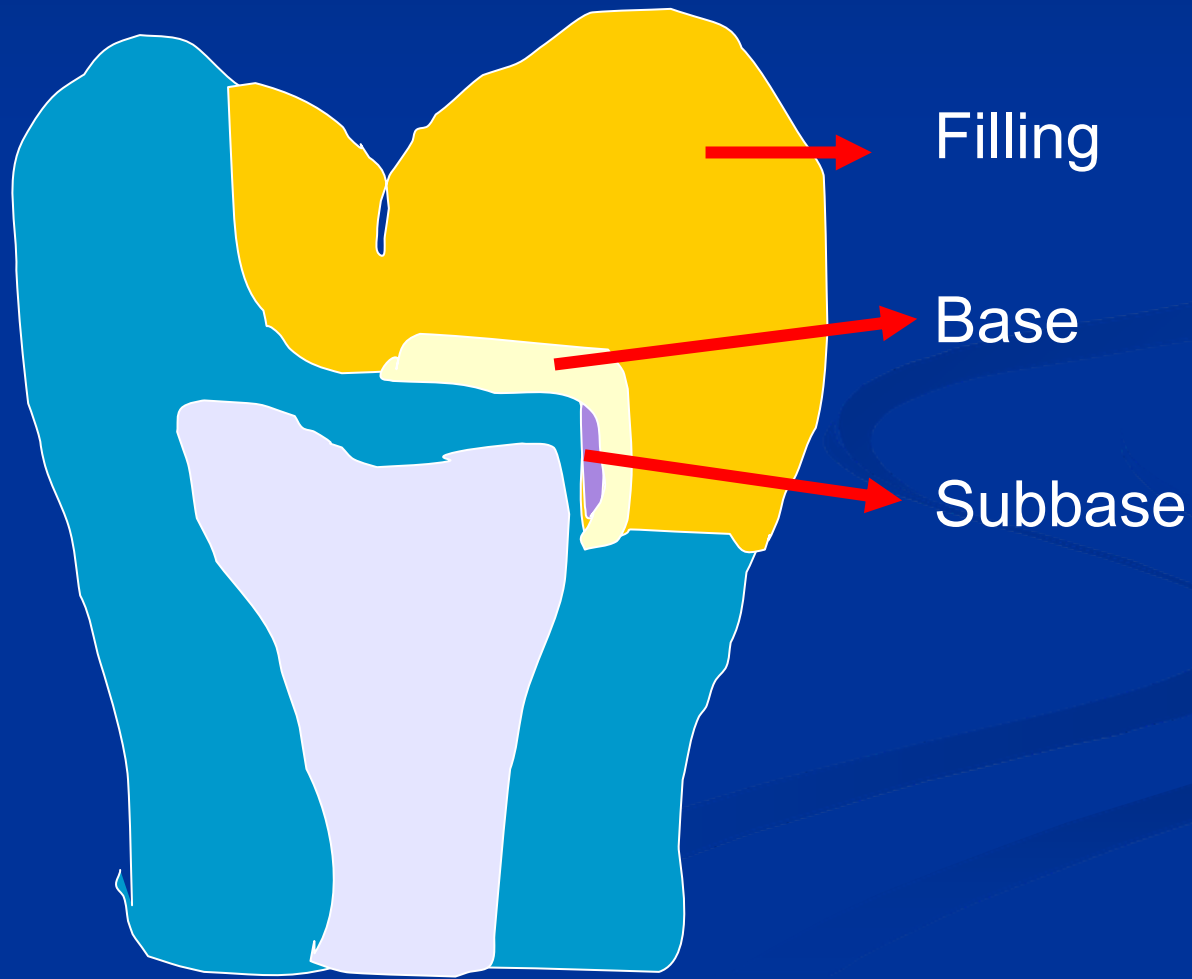
- střednědobě

- dlouhodobě





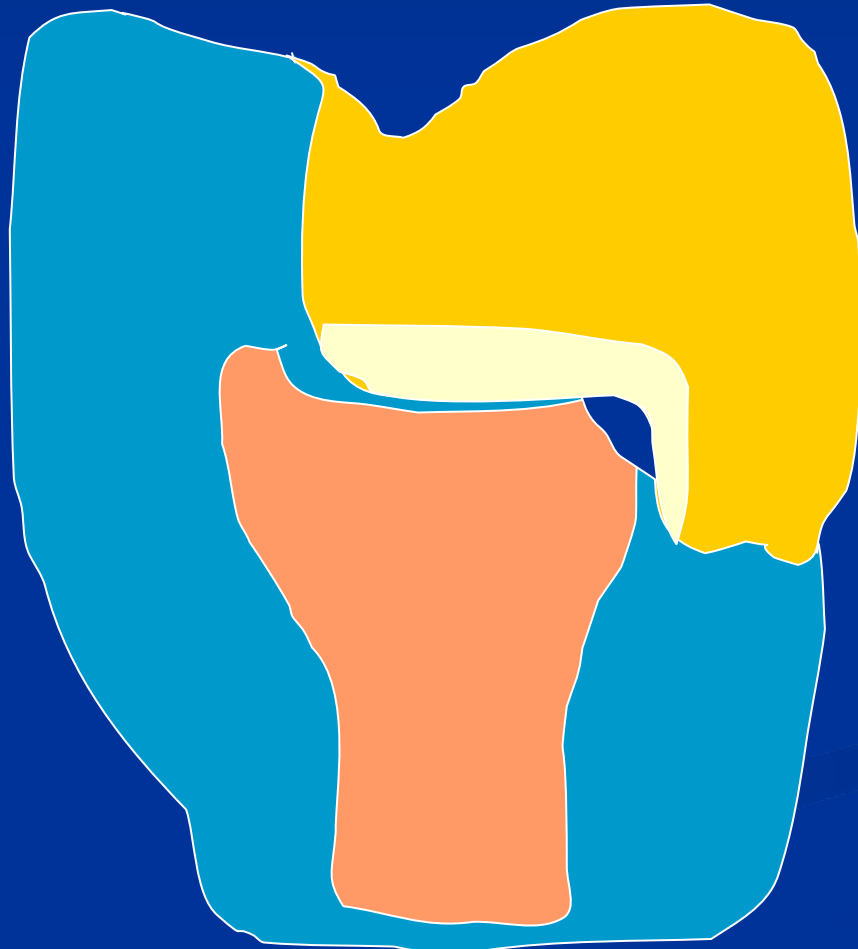
Indirect pulp capping



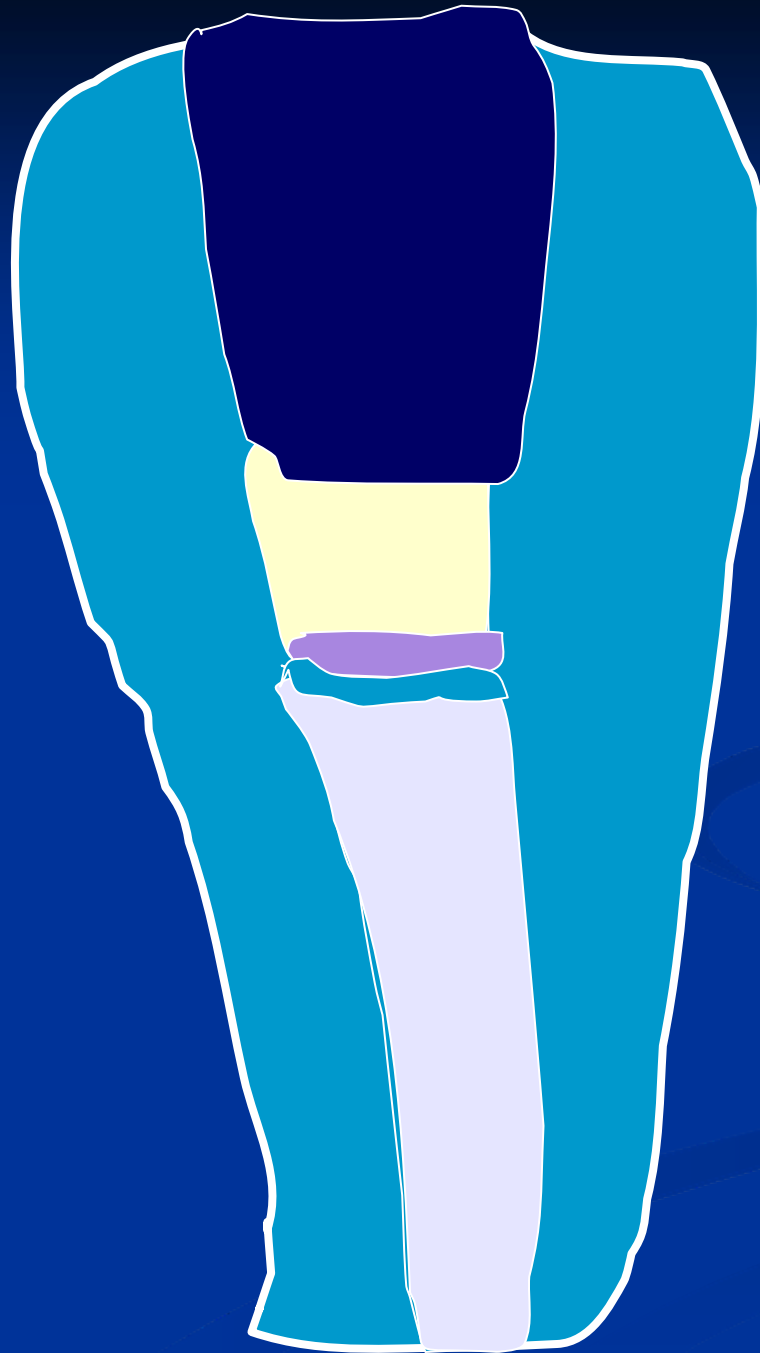
Intermittent excavation



Direct pulp capping



Necrosis
Inflammation
Dentin Bridge



Pulpotomy