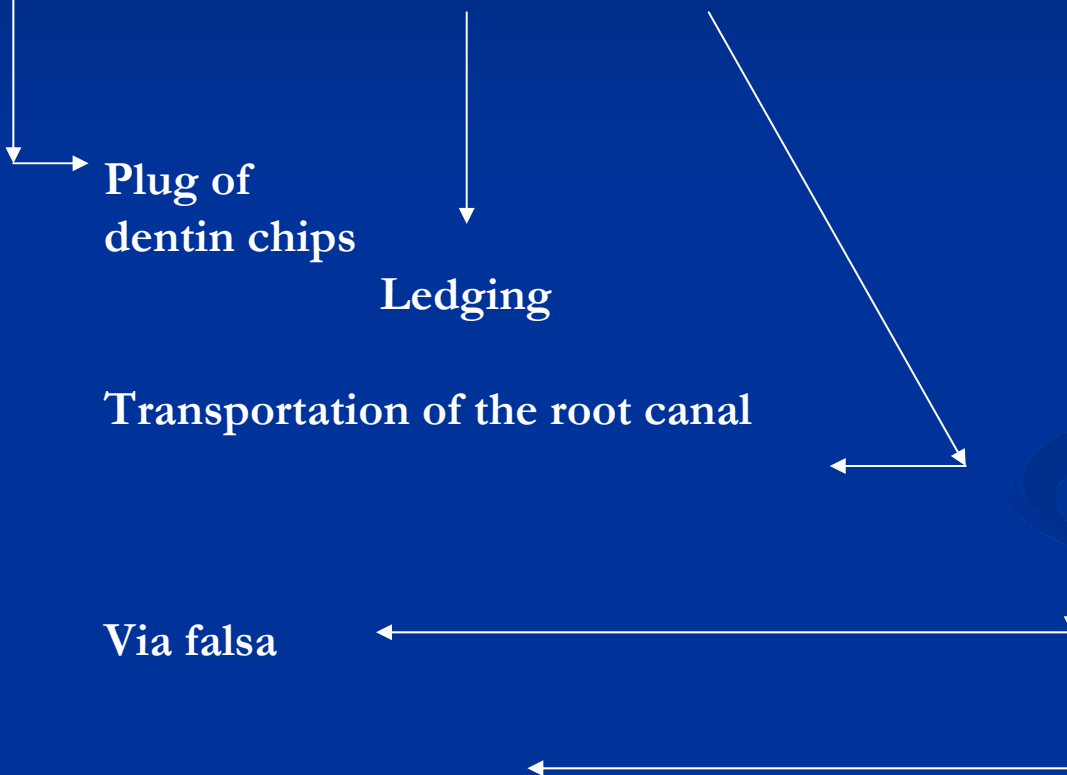
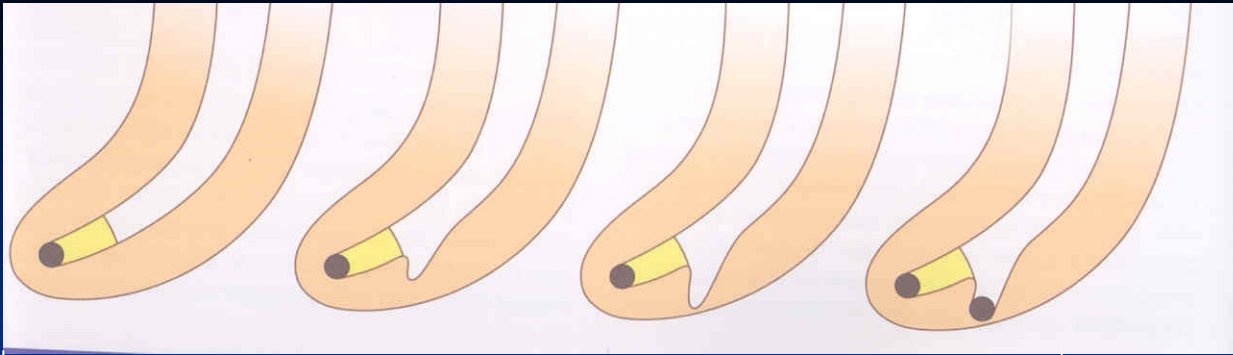


# Complications of endodontic treatment

Local

Regional

Systemic



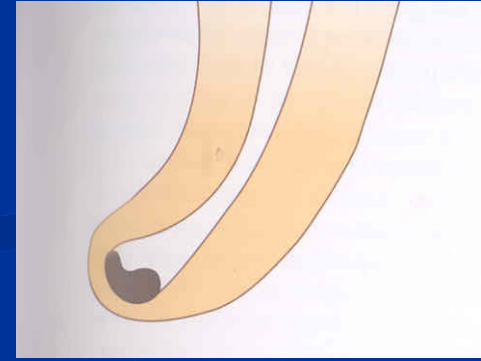
Plug of  
dentin chips

Ledging

Transportation of the root canal

Via falsa

Zipping a elbow



# Local complications

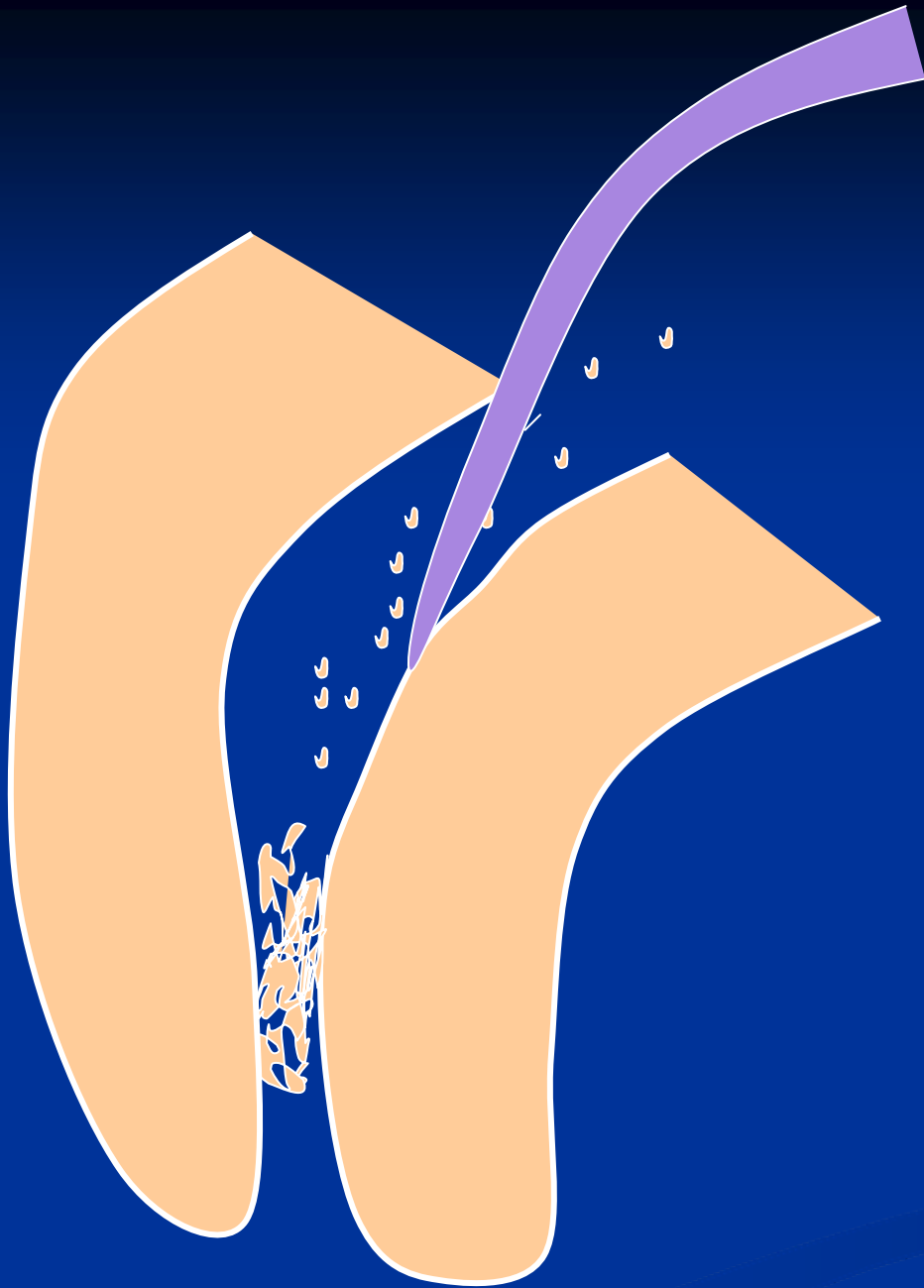
# Plug



## Reasons

**Insufficient irrigation and  
recapitulation**

*Loss of the working length*



## Solution

Repeated careful  
instrumentation  
with a thin  
instrument

*Irrigation is not  
effective in this  
case!!!*

# Ledging

## Reasons


The instrument is not bended in advance!

No control of the WL

=

No recapitulation Loss of the WL





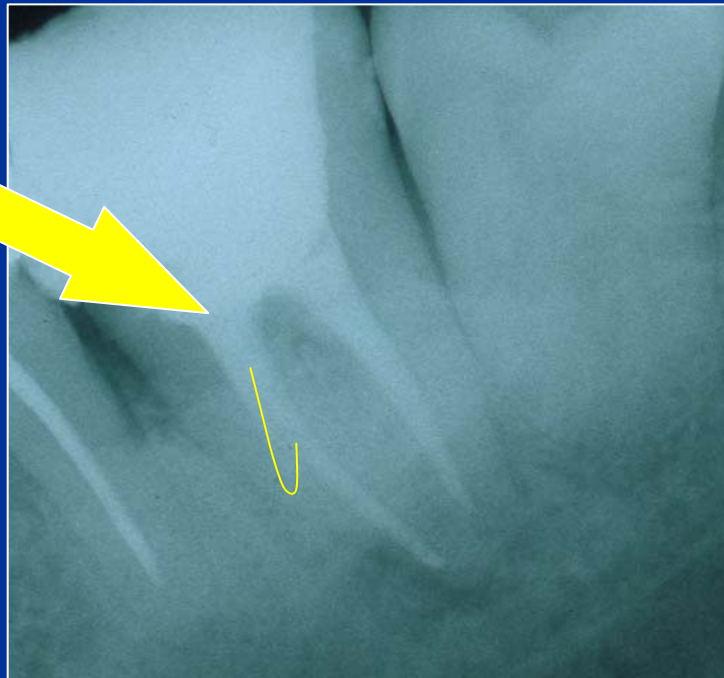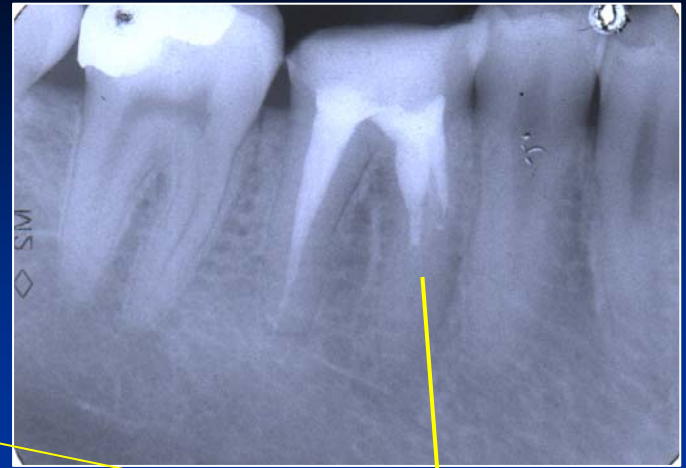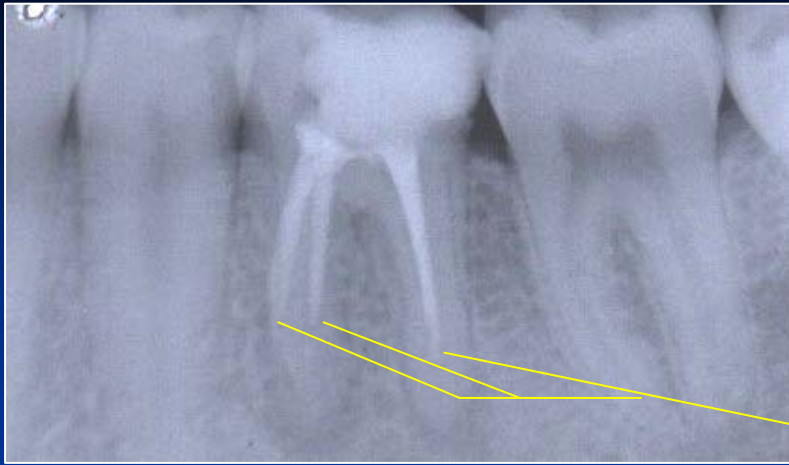
### Solution

The instrument must be  
bended in advance

Careful but complete rotation

Finishing with the fine filing

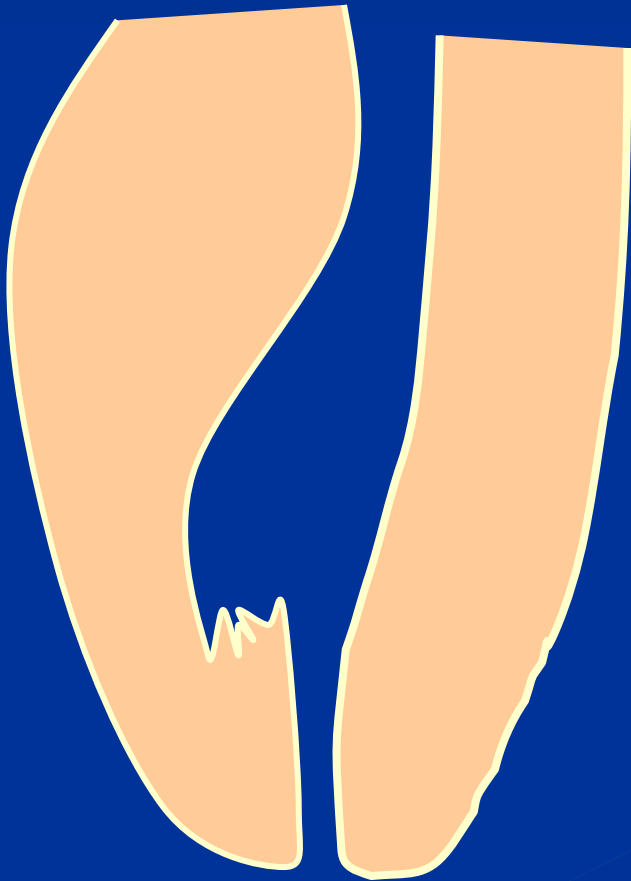*No NiTi!!!*



Ledging


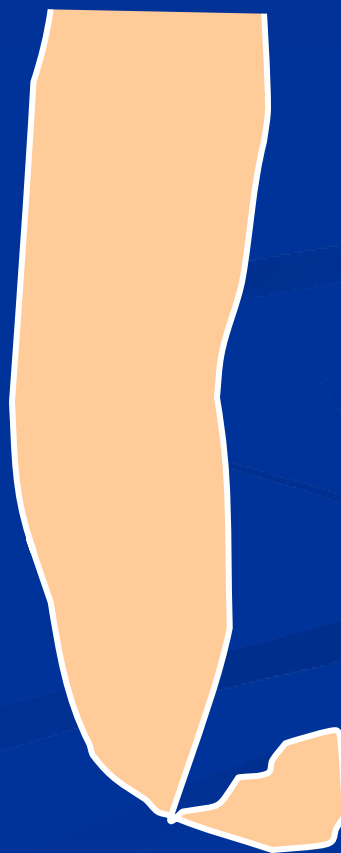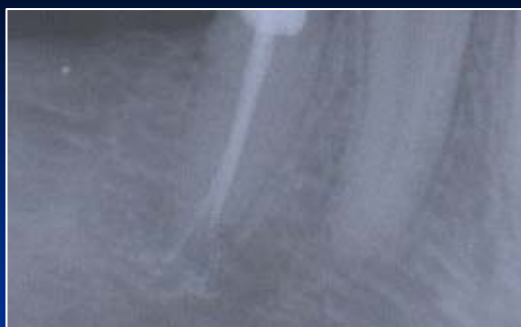



# Zippering a Elbow



The instrument is not bended in advance!

Rotation in curved canals



# Stripping

## Reasons

Bad orientation in morphology – no diagnostic x-  
Instruments are not bended  
Rotary NiTi with a big taper


## *Dangerous zones*

*Mandibular molars – mesial roots*

*Premolars, esp. maxillar*

*Mandibular incisors*

*Oblast isthmu*




# Stripping

**Důkladný přehled!**

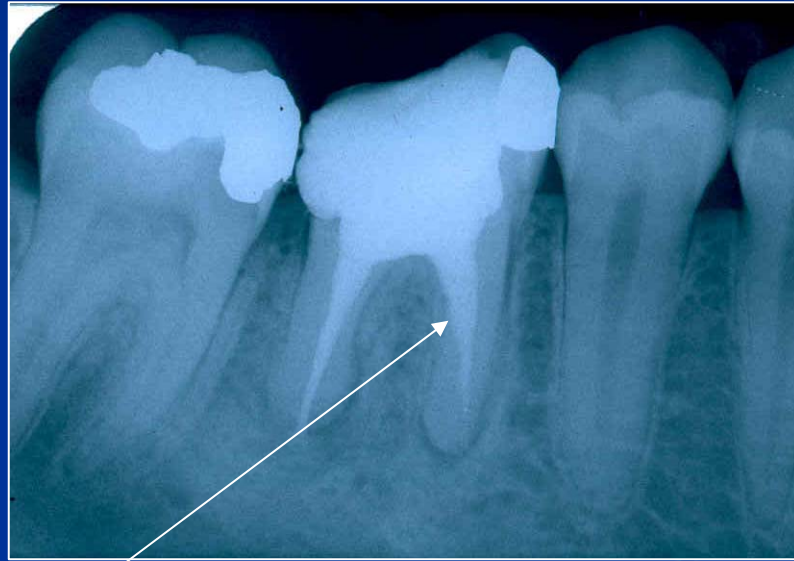
**Šetřit oblast isthmu!**

**Ruční preparace!**

**Menší kónus NiTi !**



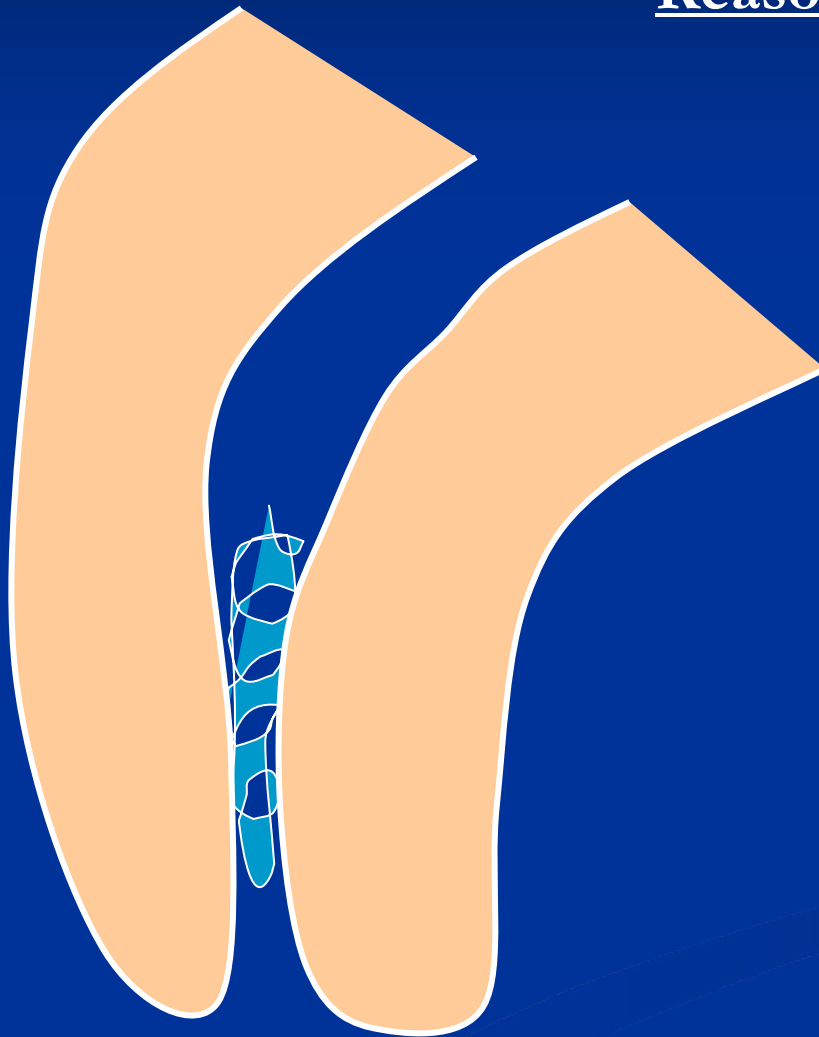
# Stripping



**Bend the instrument and eventually blunt it !**

# Fracture of the root canal instrument

## Reasons



**Insufficient  
coronal flaring**

**Old root canal  
instrument**

**Aggressive force**

**Incorrect  
movement of the  
root canal  
instrument**

## Solution

Enlargement of the  
root canal till the  
instrument

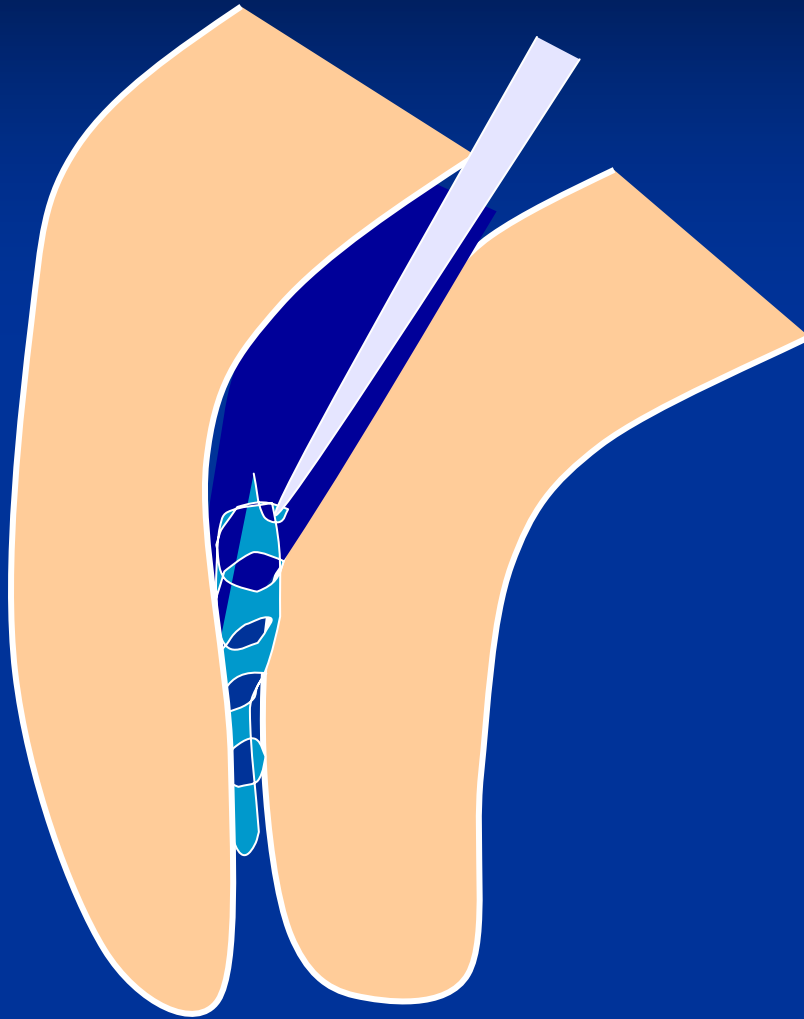
Ultrasound tips


Rotating root canal  
instrument – caution!

Bypass

Leaving in

Surgical treatment

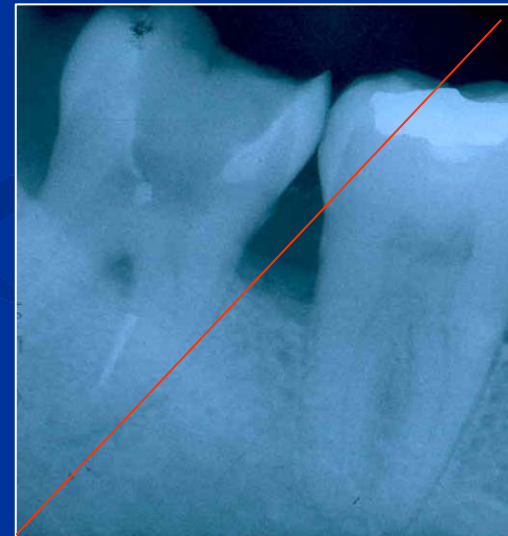
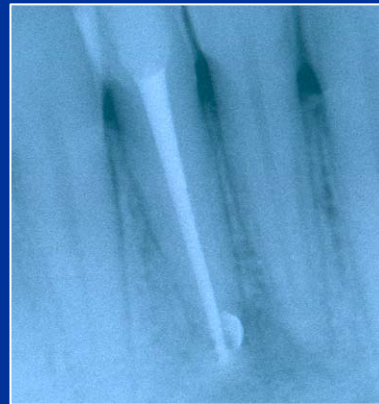
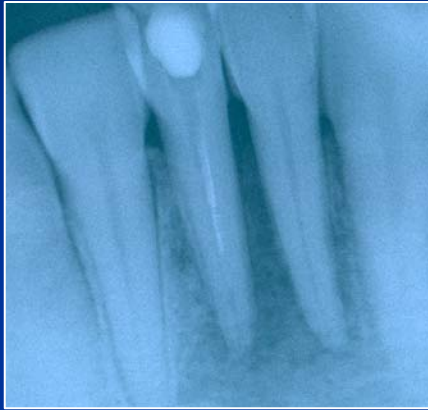




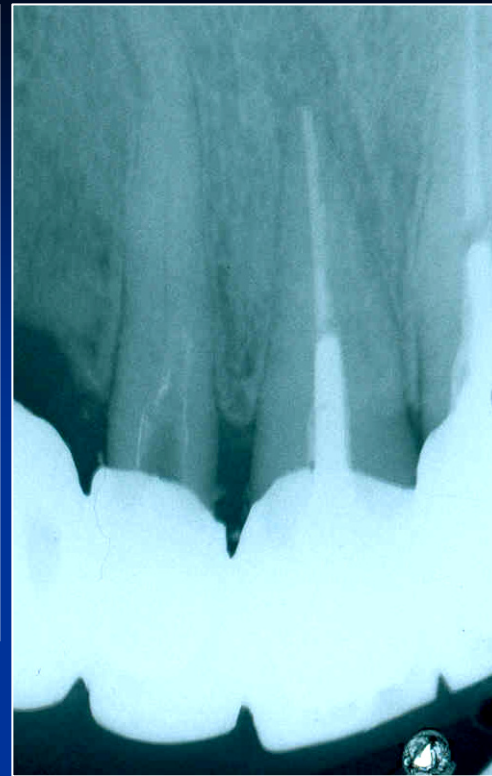
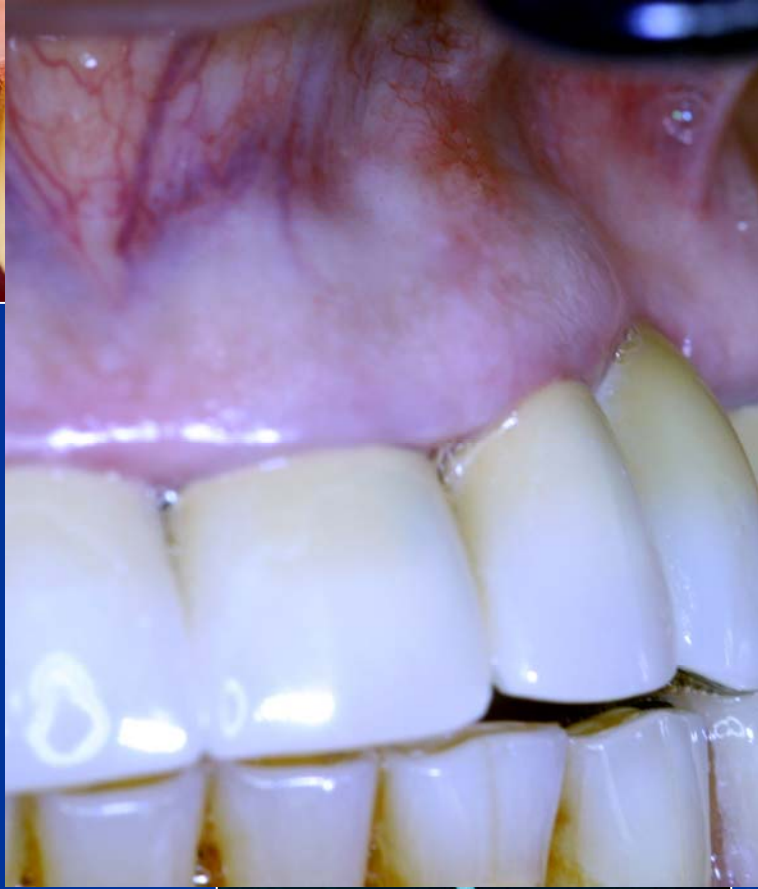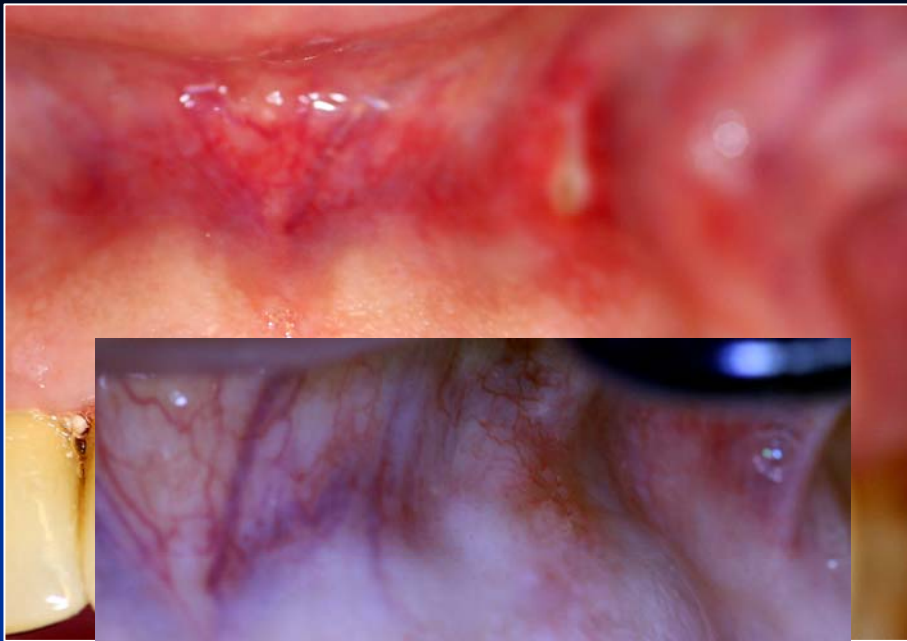
**Bypass**

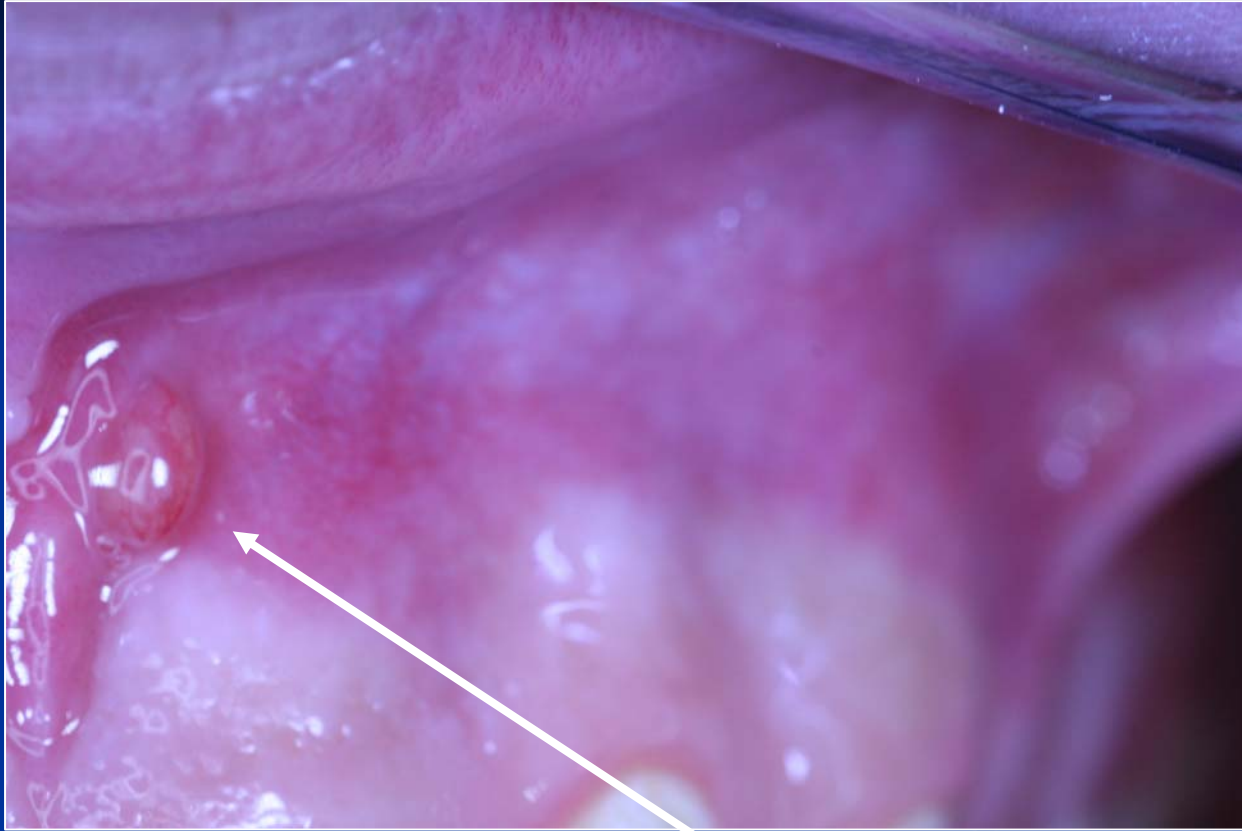


# Fractured instrument



# Regional complications





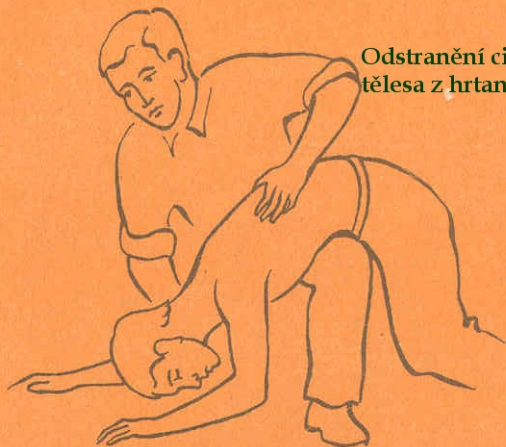**Píštěl**

# Systemic complications

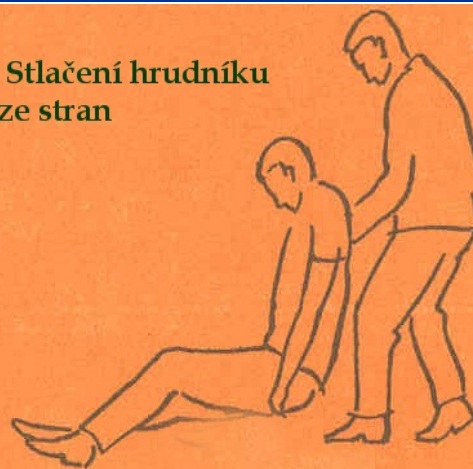# Systemic complications

- Periostitis
- Inflammation of soft tissues (face, neck)
- Gulp of the instrument (X ray, remnant diet, information)- cough
- Aspiration of the instrument -emesis

**Odstranění cizího  
tělesa z hrtanu**



**Stlačení hrudníku  
ze stran**



# Caution!

*Always find the loss instrument !!!!!!*