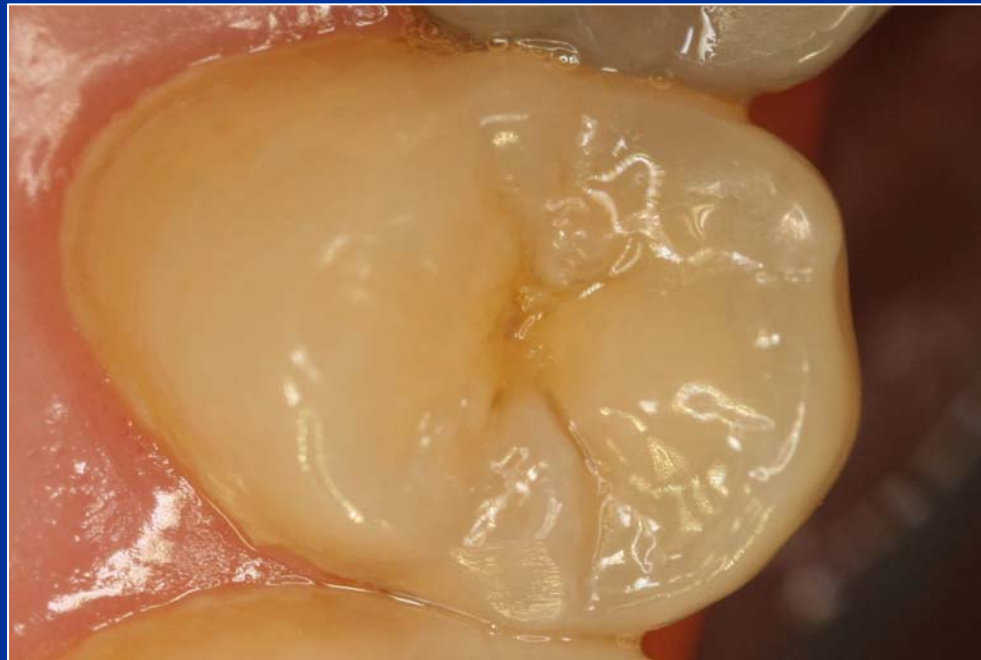

Class II. cavity preparation

Defects affecting one or both proximal surfaces of posterior teeth.

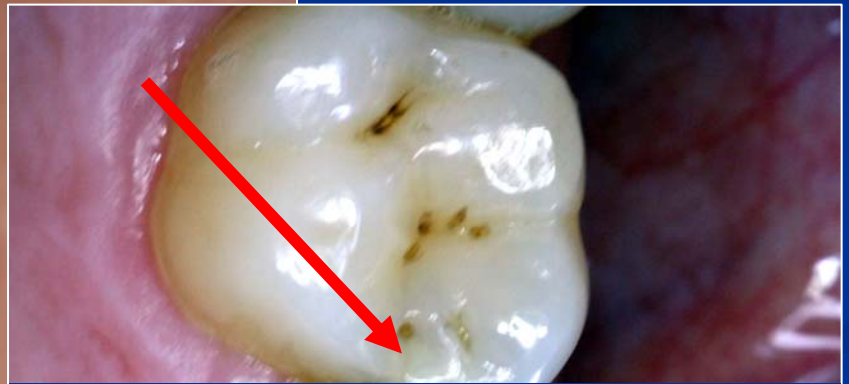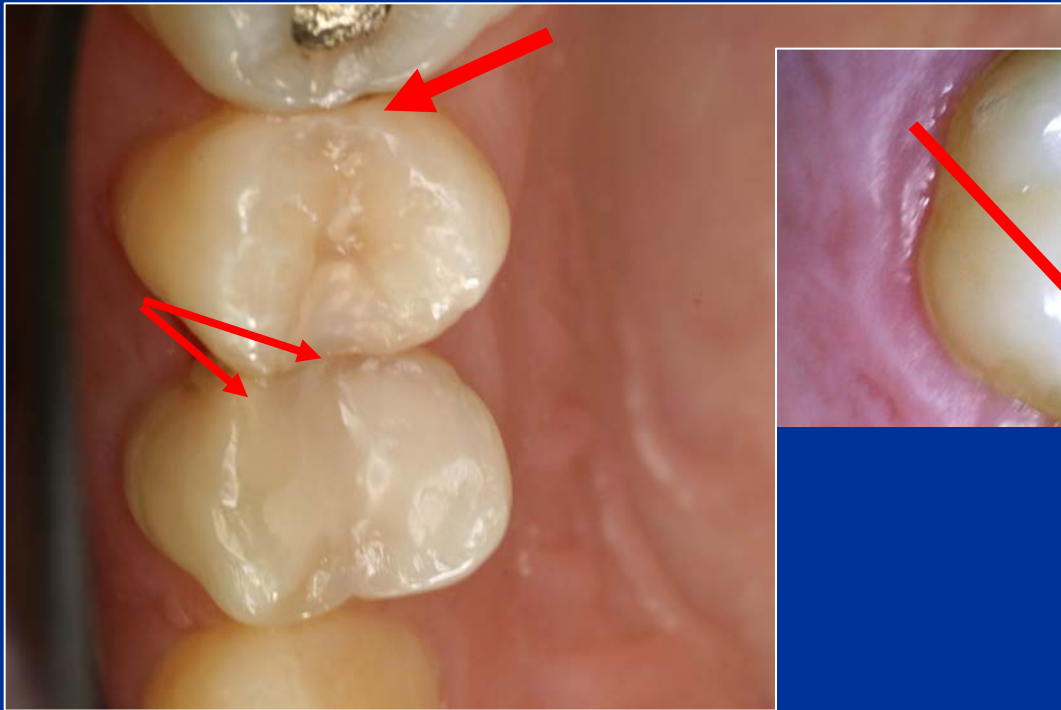


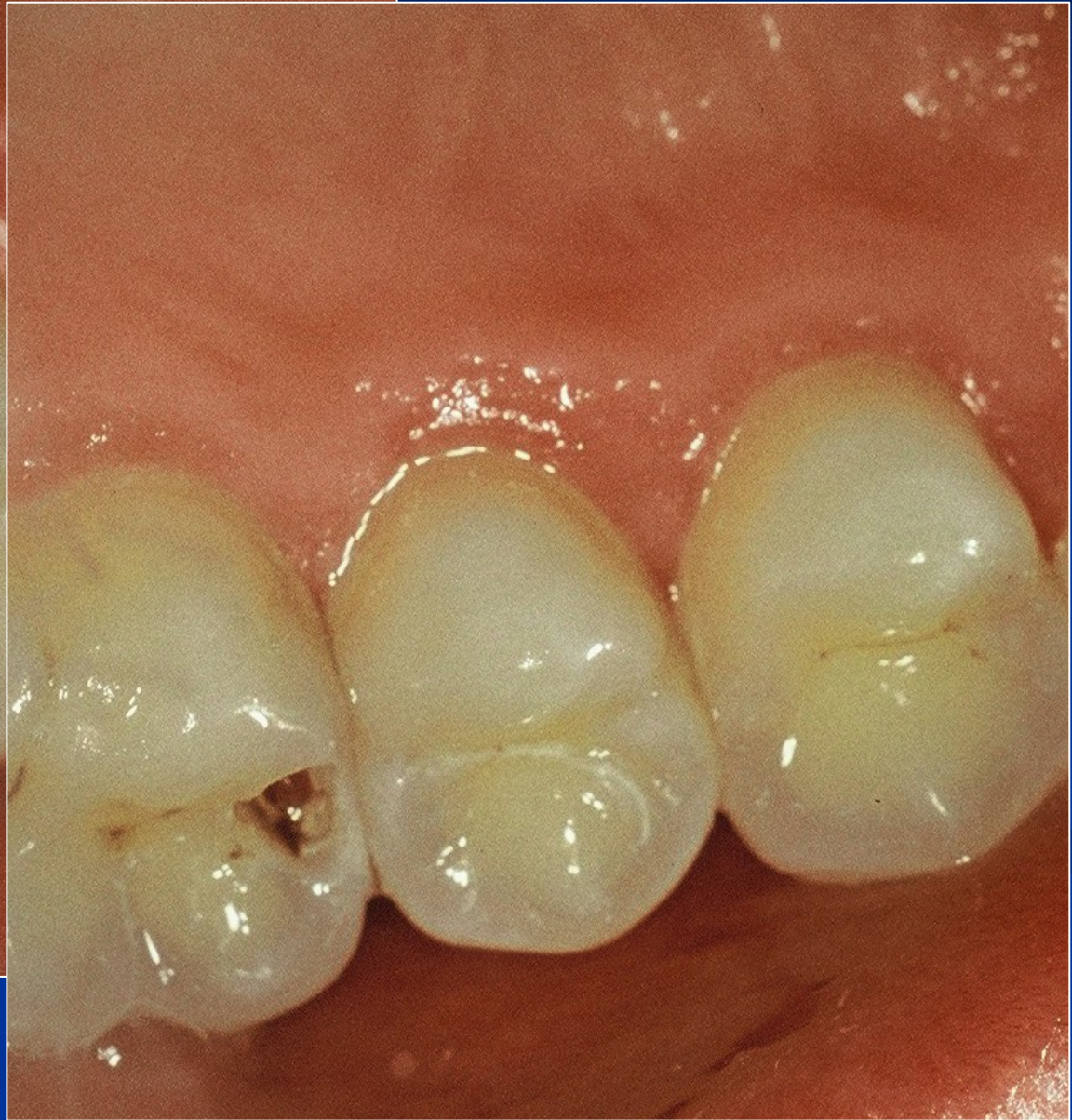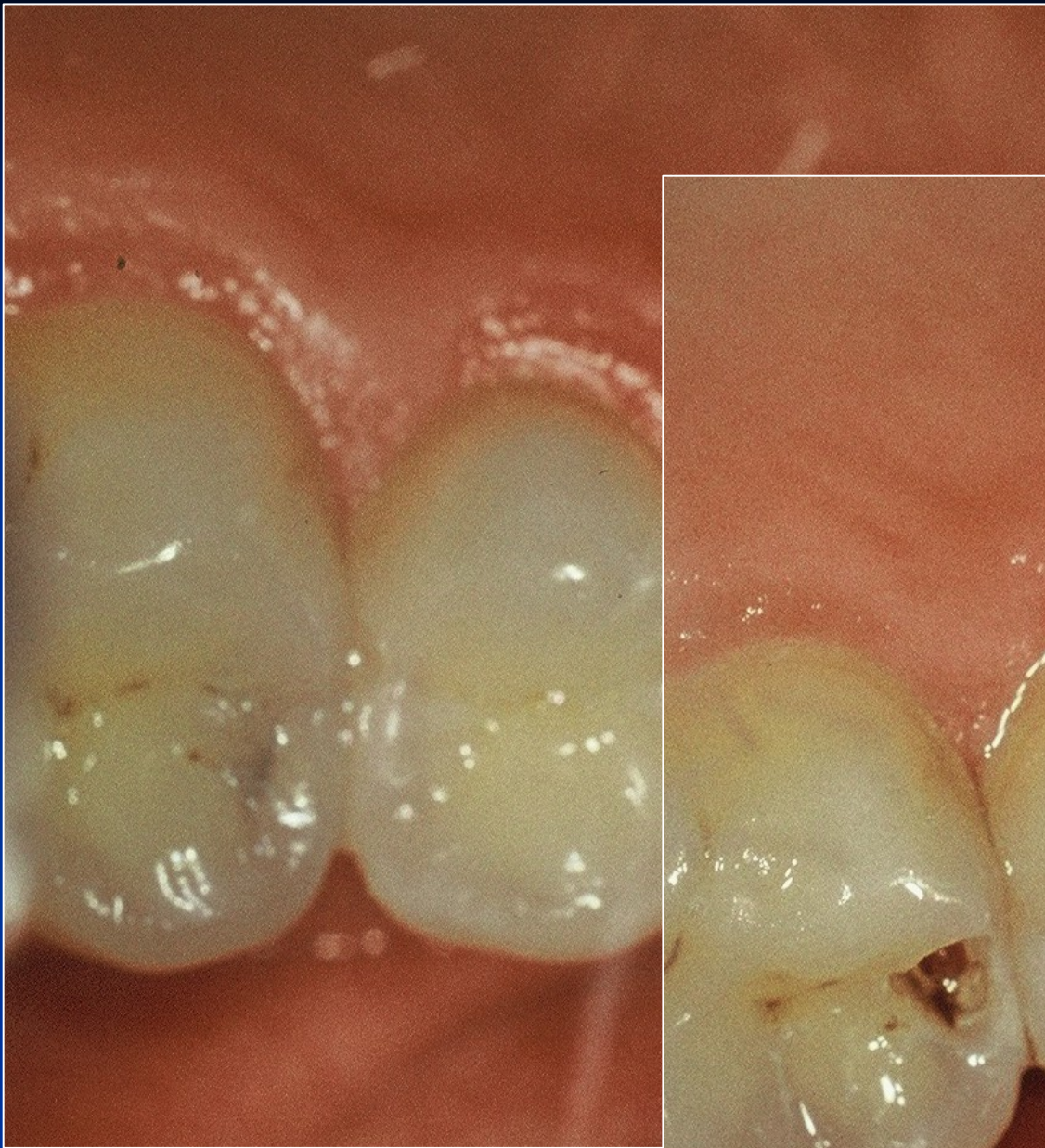Symptoms

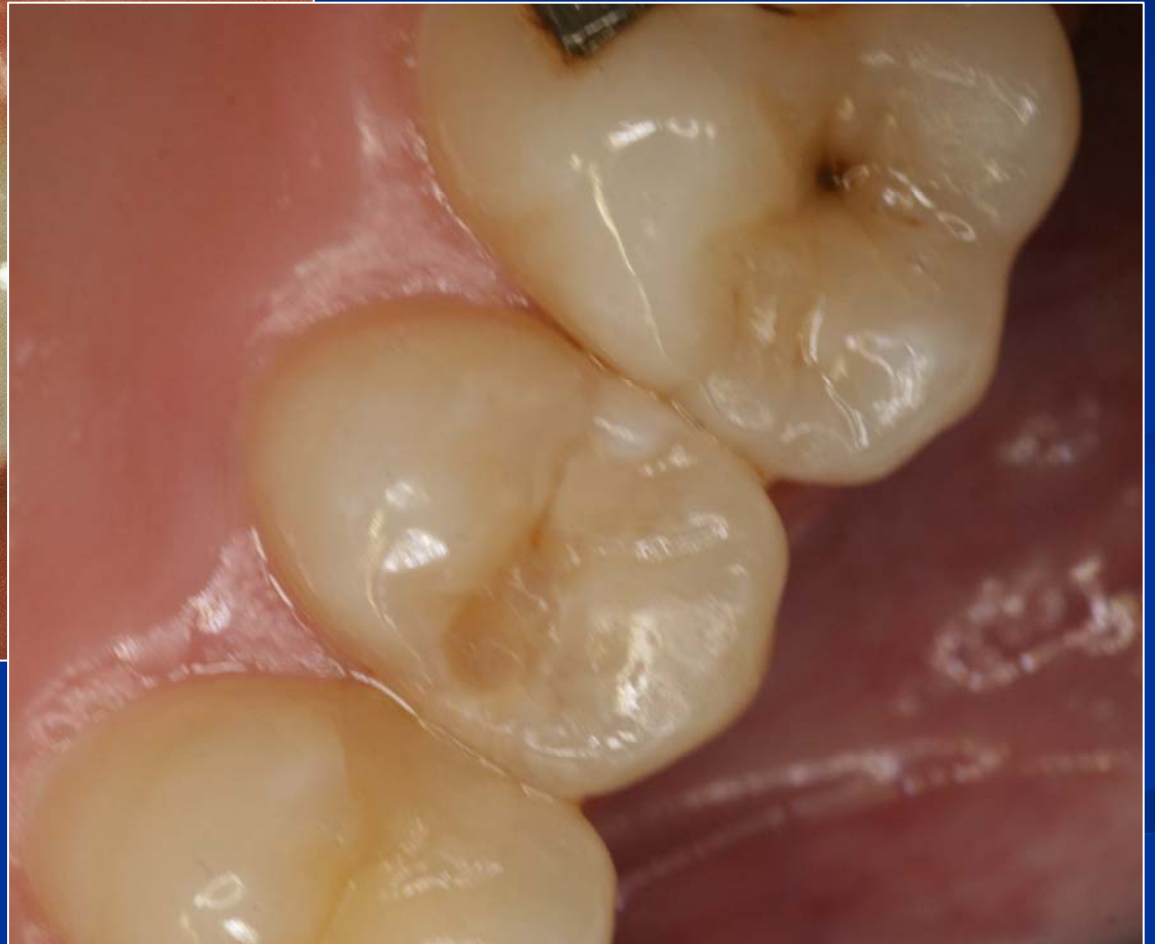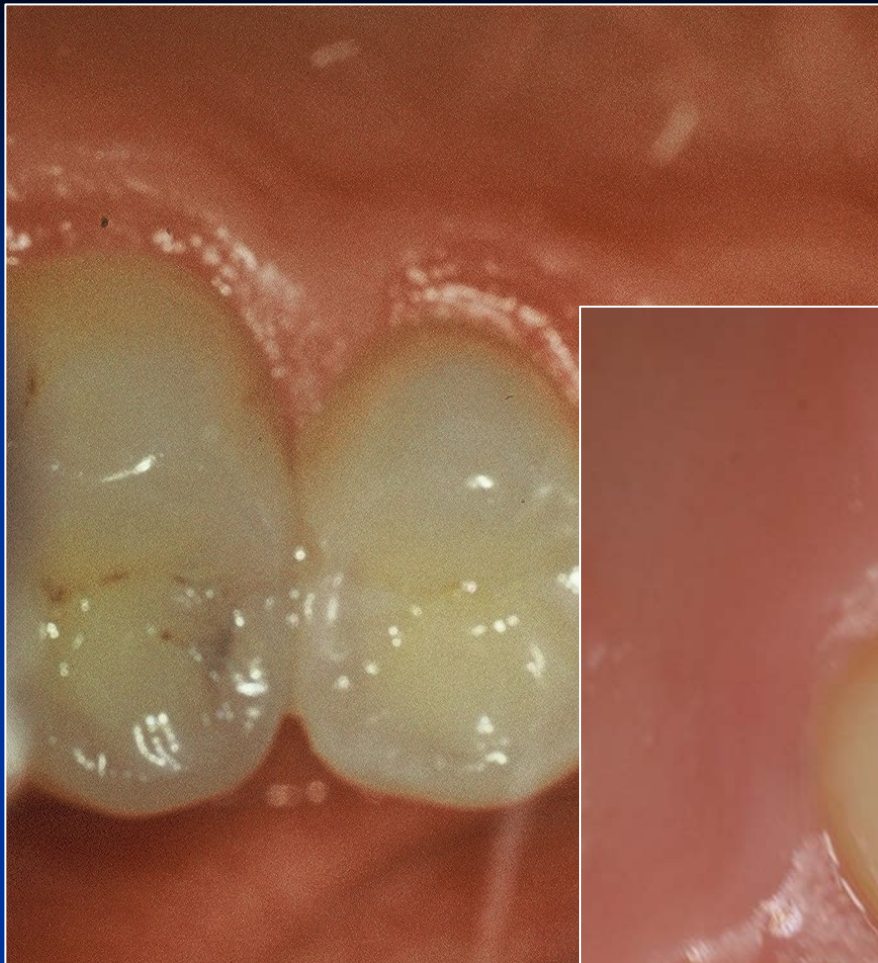- No symptoms
- Increased sensitivity (cold, sweet)
- Retention of food
- Defect (cariious lesion is open – the enamel is broken)
- Bite sensitivity (when cariious lesion is open)

Diagnosis

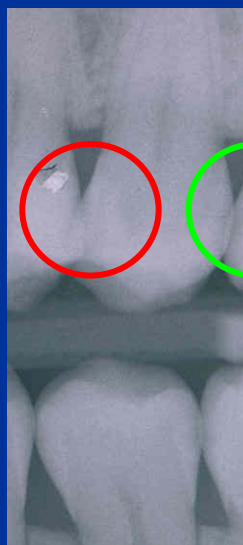
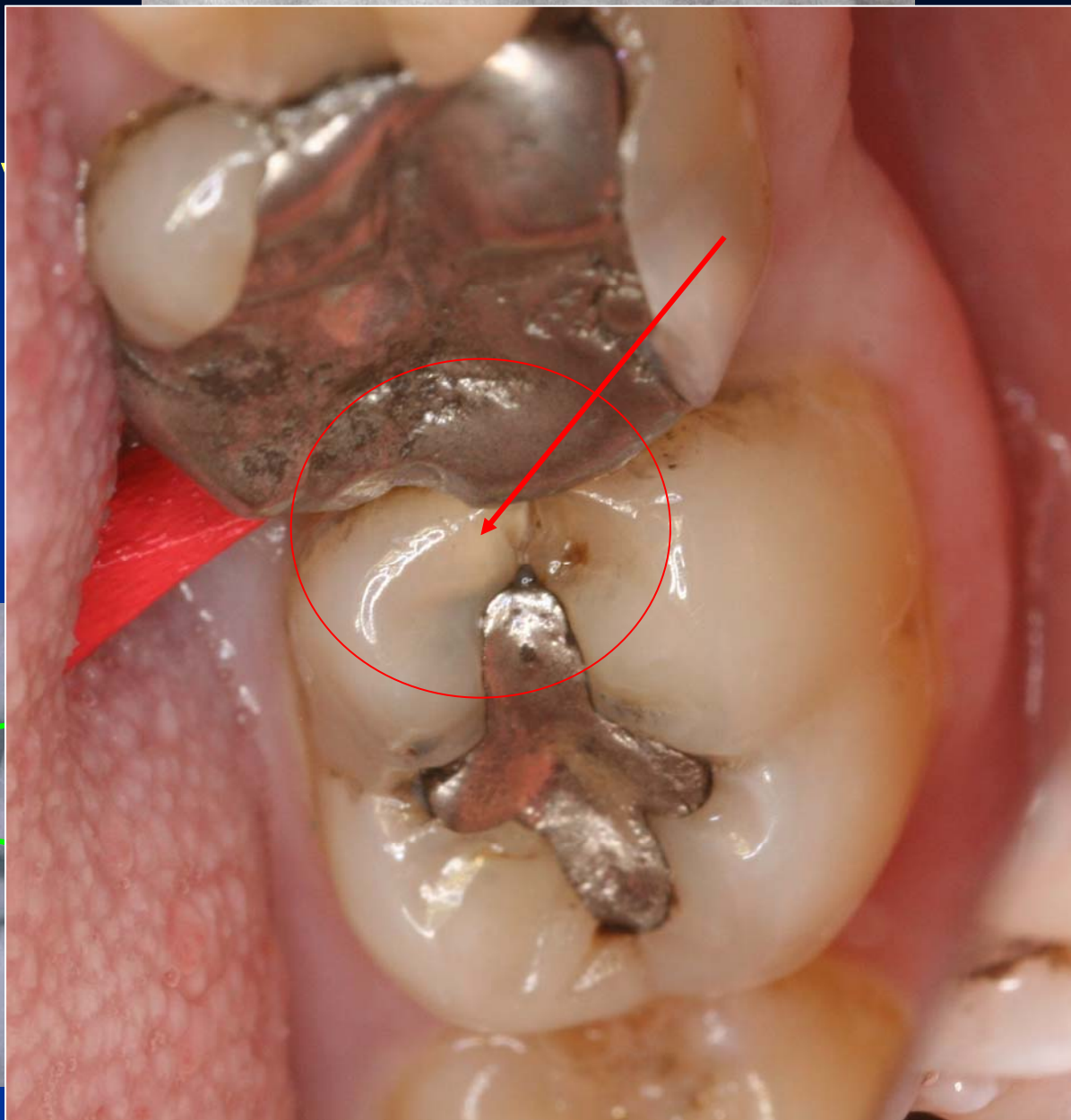
- Visual changes of tooth structure
- Transillumination
- Radiography







4 stupňo
grading



KTG vyšetření – Bite wing

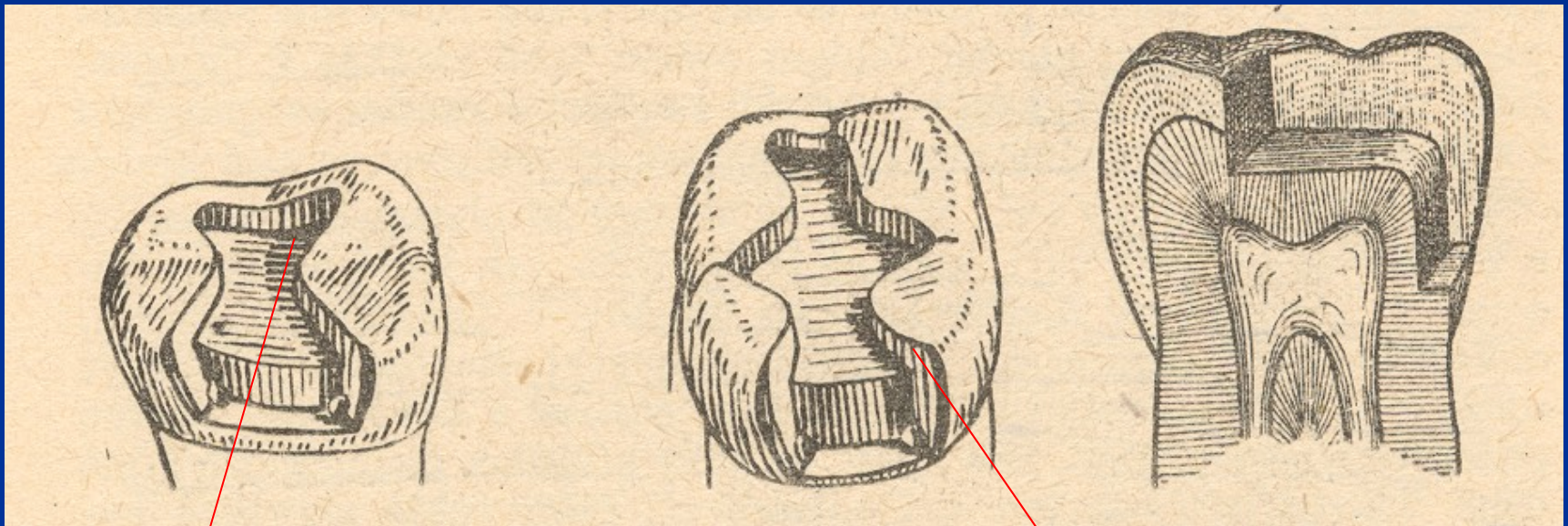
Preparation - amalgam

- Conventional preparation acc. to the Black's rules
- Slot preparation
- Large preparation – cusp(s) involved

Preparation - adhesive materials

- Conventional preparation for composites
- Adhesive slot
- Tunnel preparation

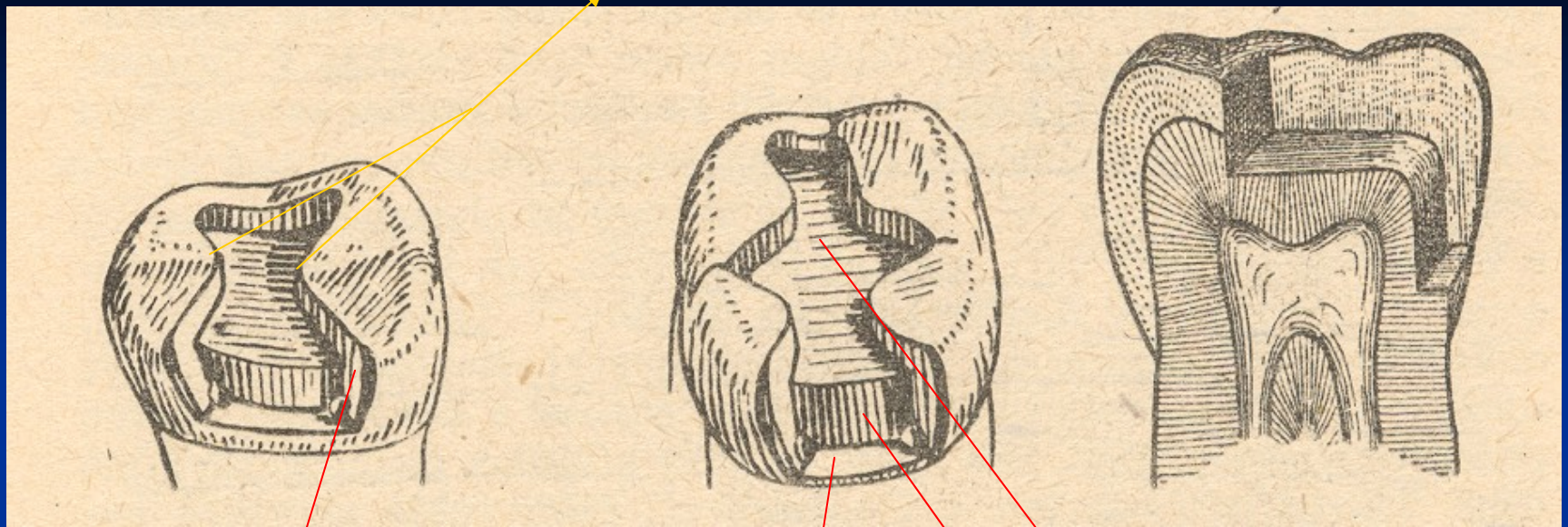
Conventional preparation



Occlusal cavity

Proximal cavity - box

Isthmus



Axial wall

Pulpal walls

Gingival wall

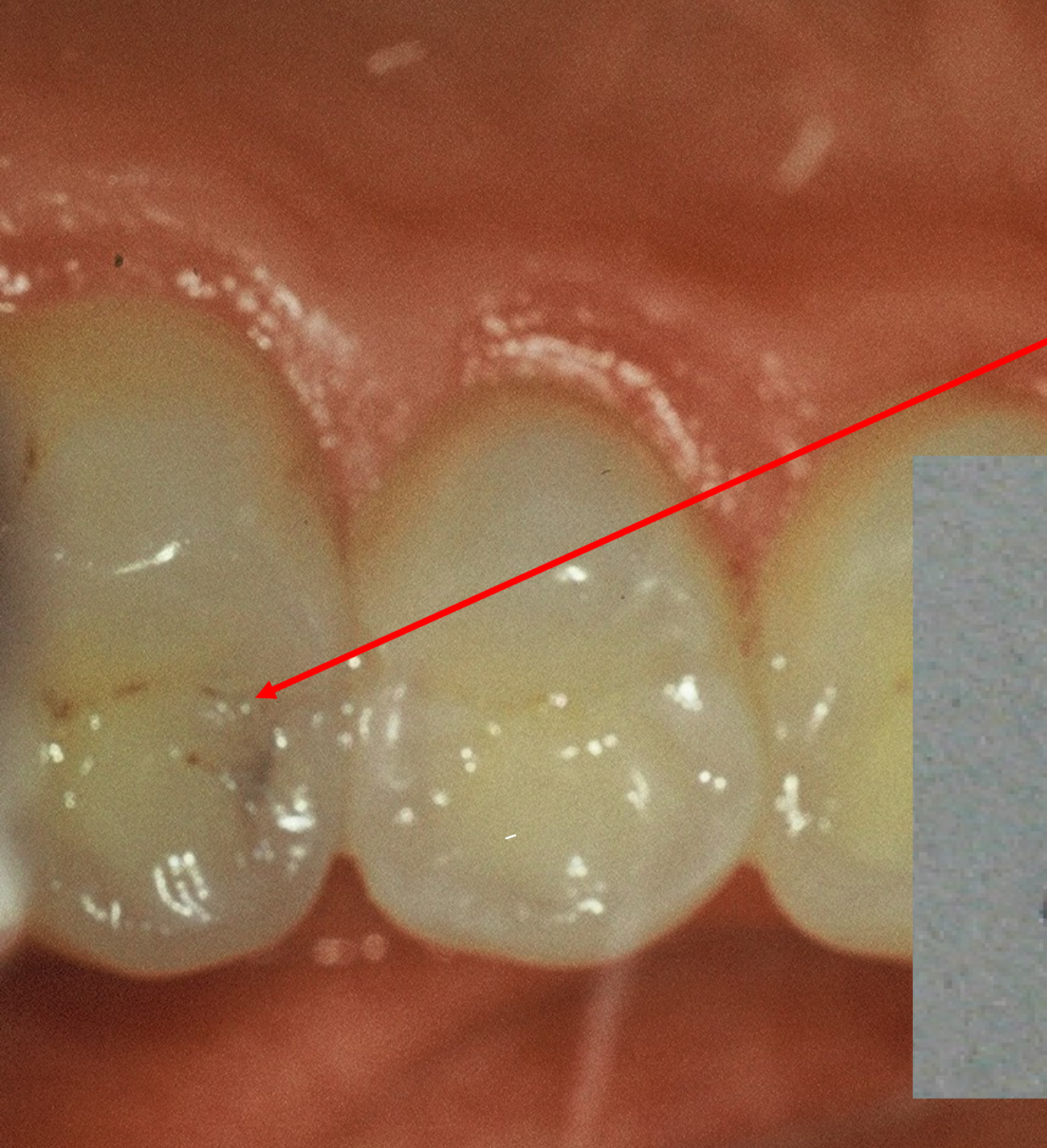
Access to the cavity

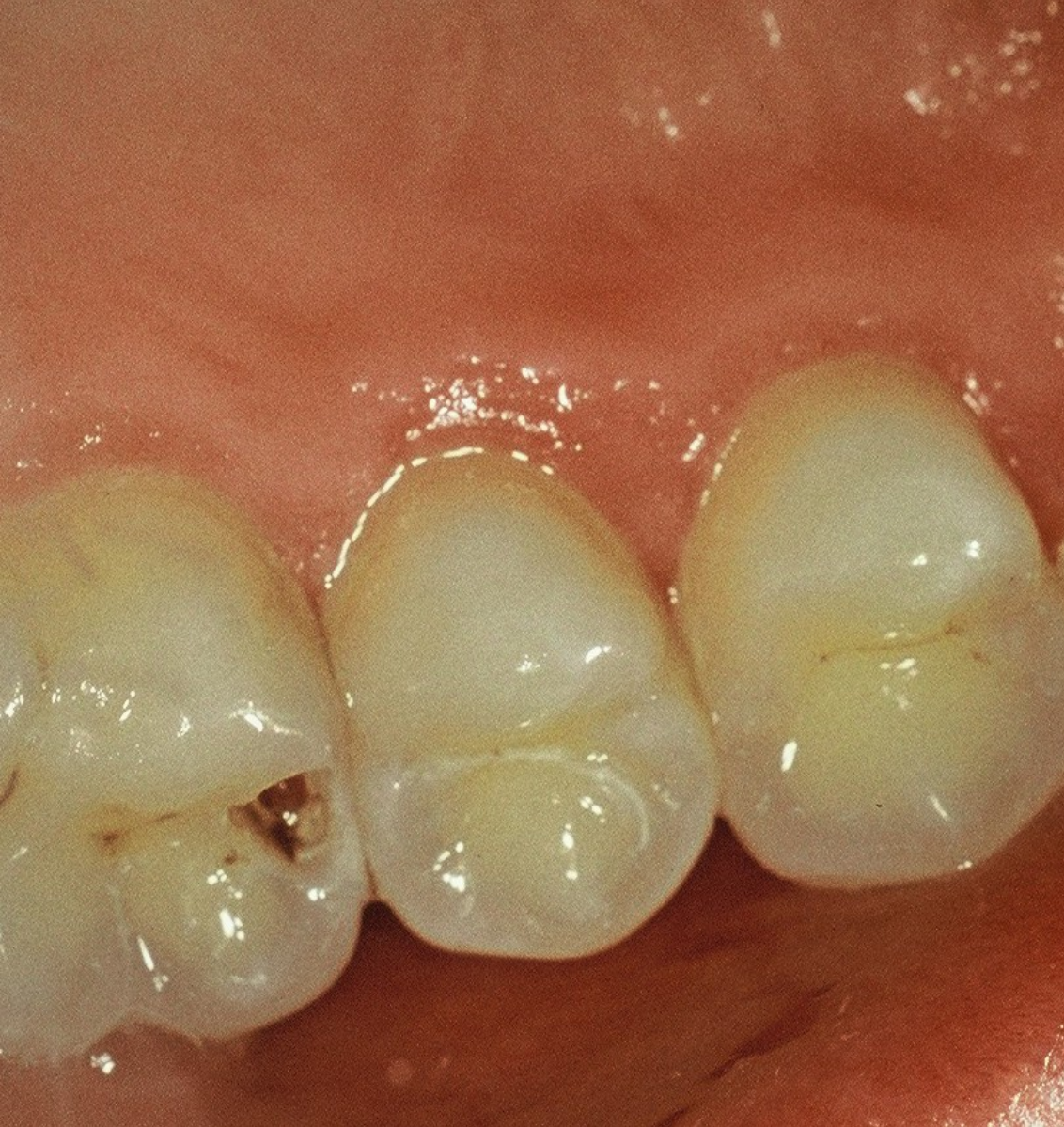From the occlusal surface

Through the undermined enamel

Separation using wooden wedges is useful

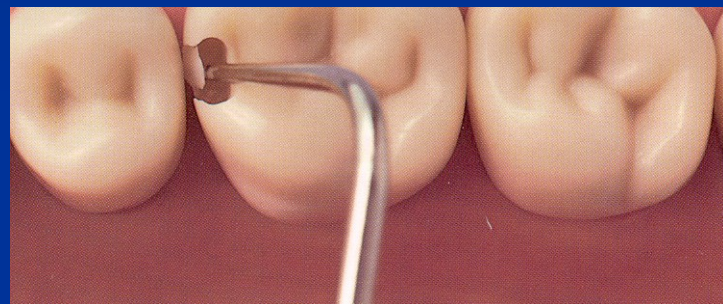
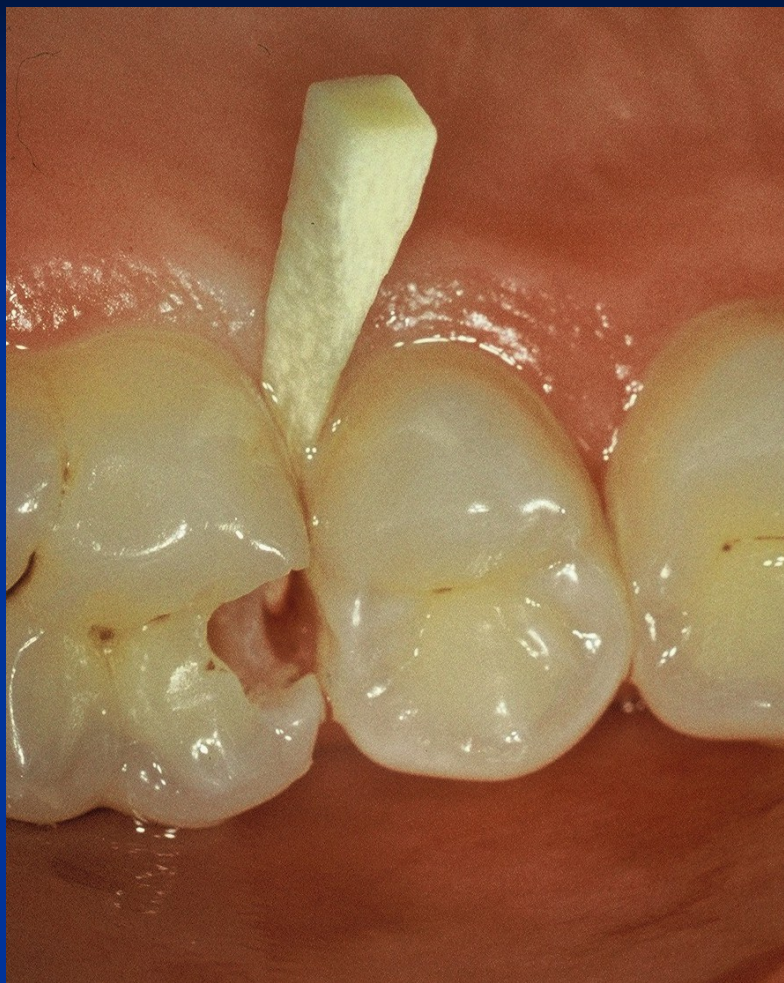Pre op

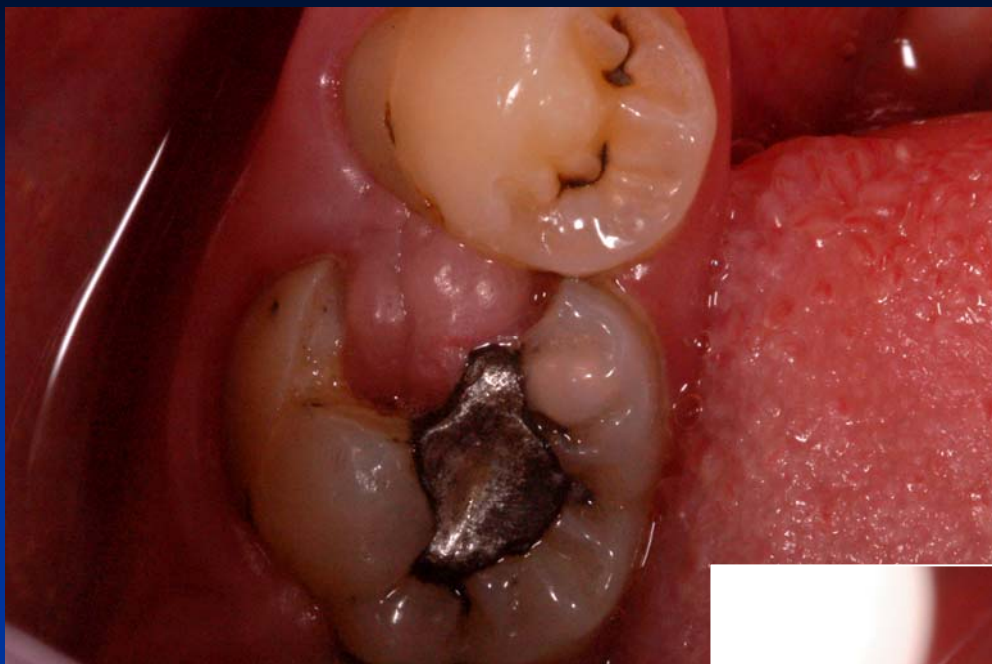




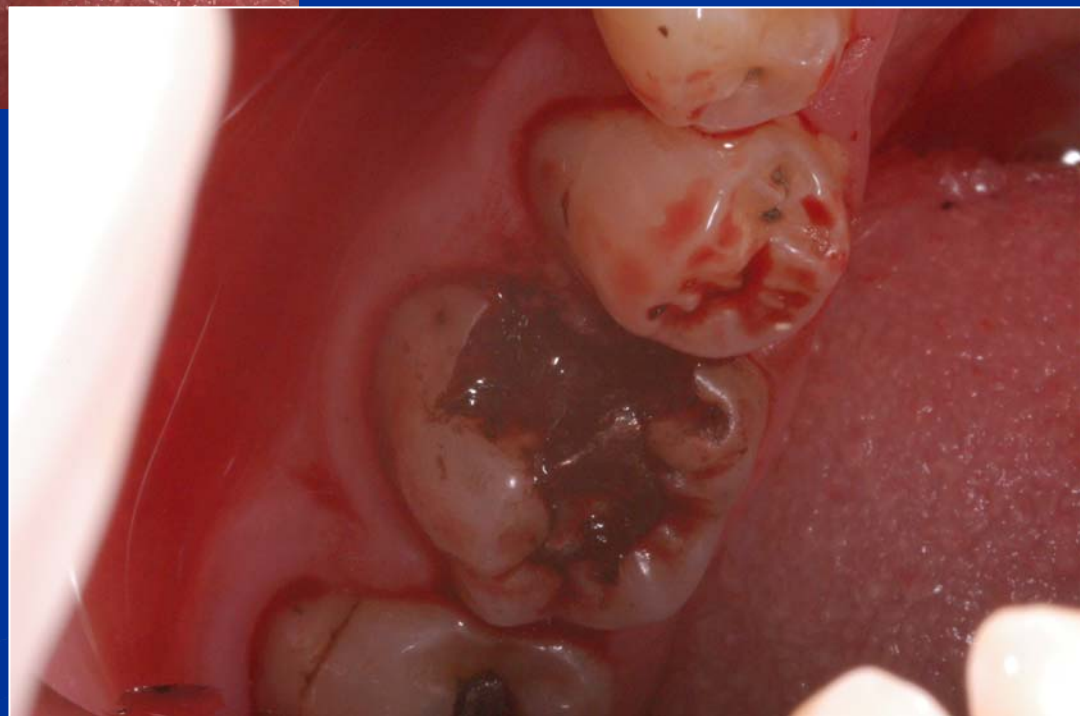Access to the cavity

lroubal@med.muni.cz





- Skalpel
- Kauter
- Laser
- Temporary filling



Cavity border and extension for prevention

Proximal box:


Axial wedges

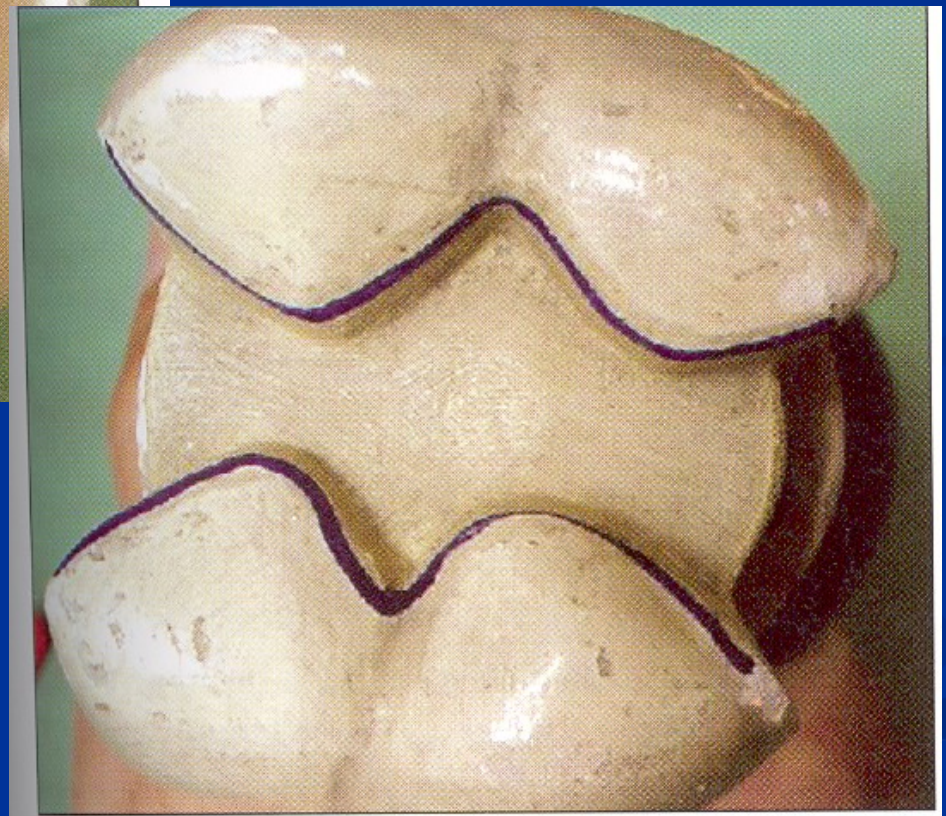
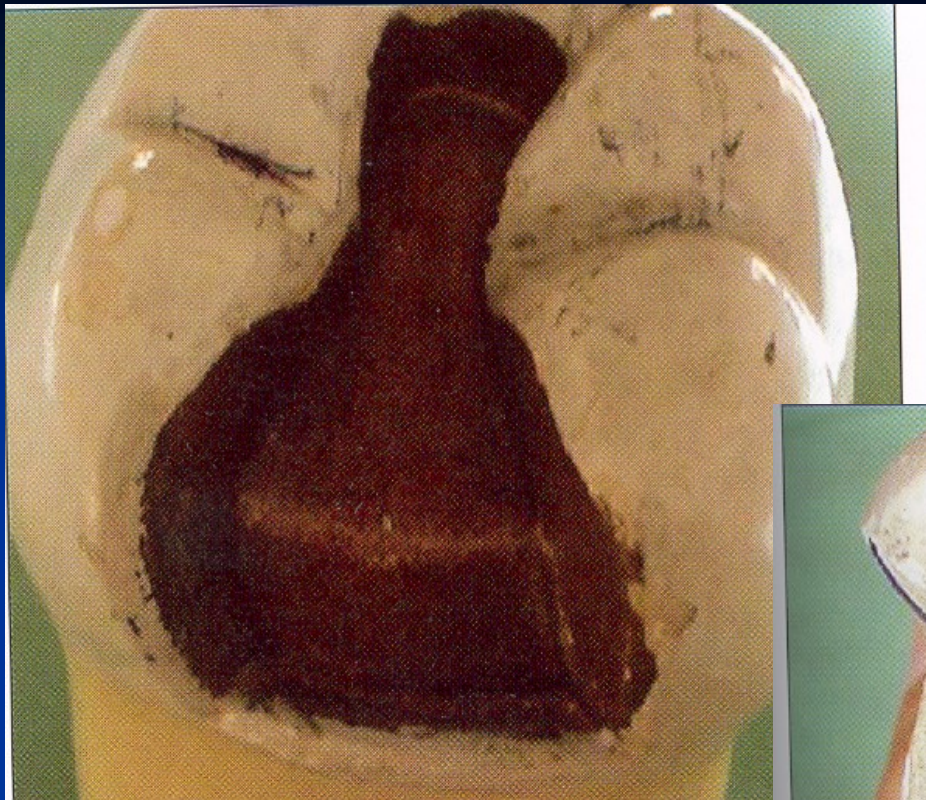Under the free gingiva

Occlusal

Class I. cavity preparation

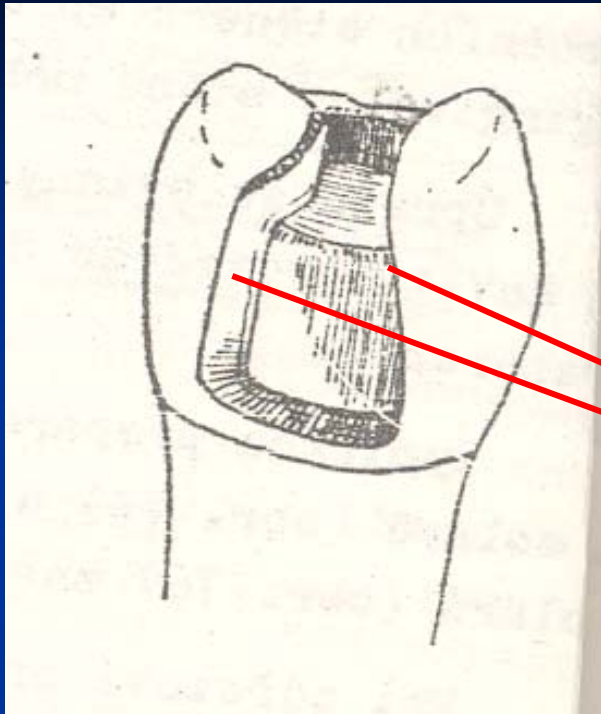
American rule



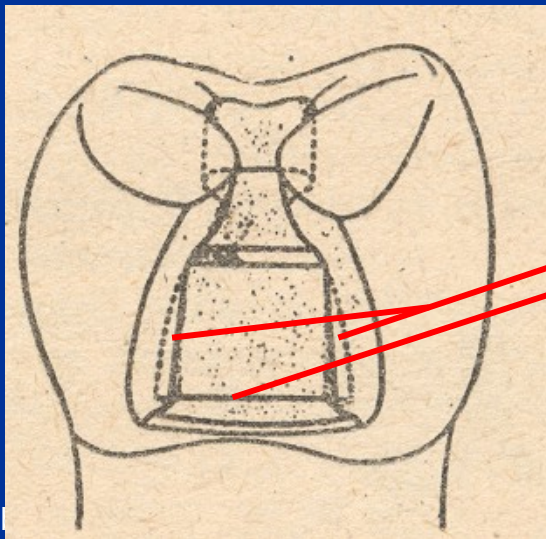
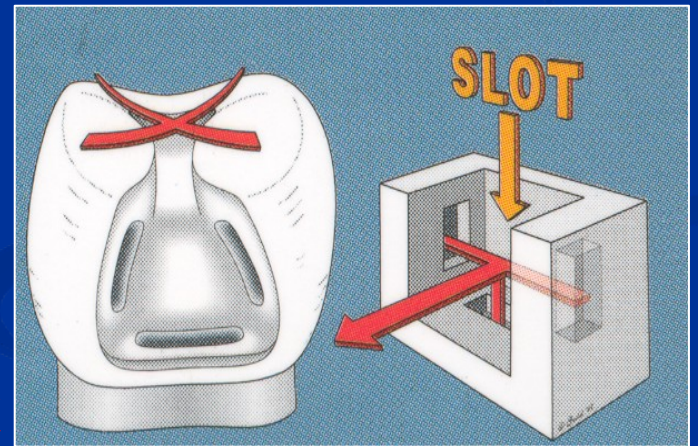


Retention

- Occlusal cavity – auxiliary cavity
- Undercuts
- Grooves



Autoretention

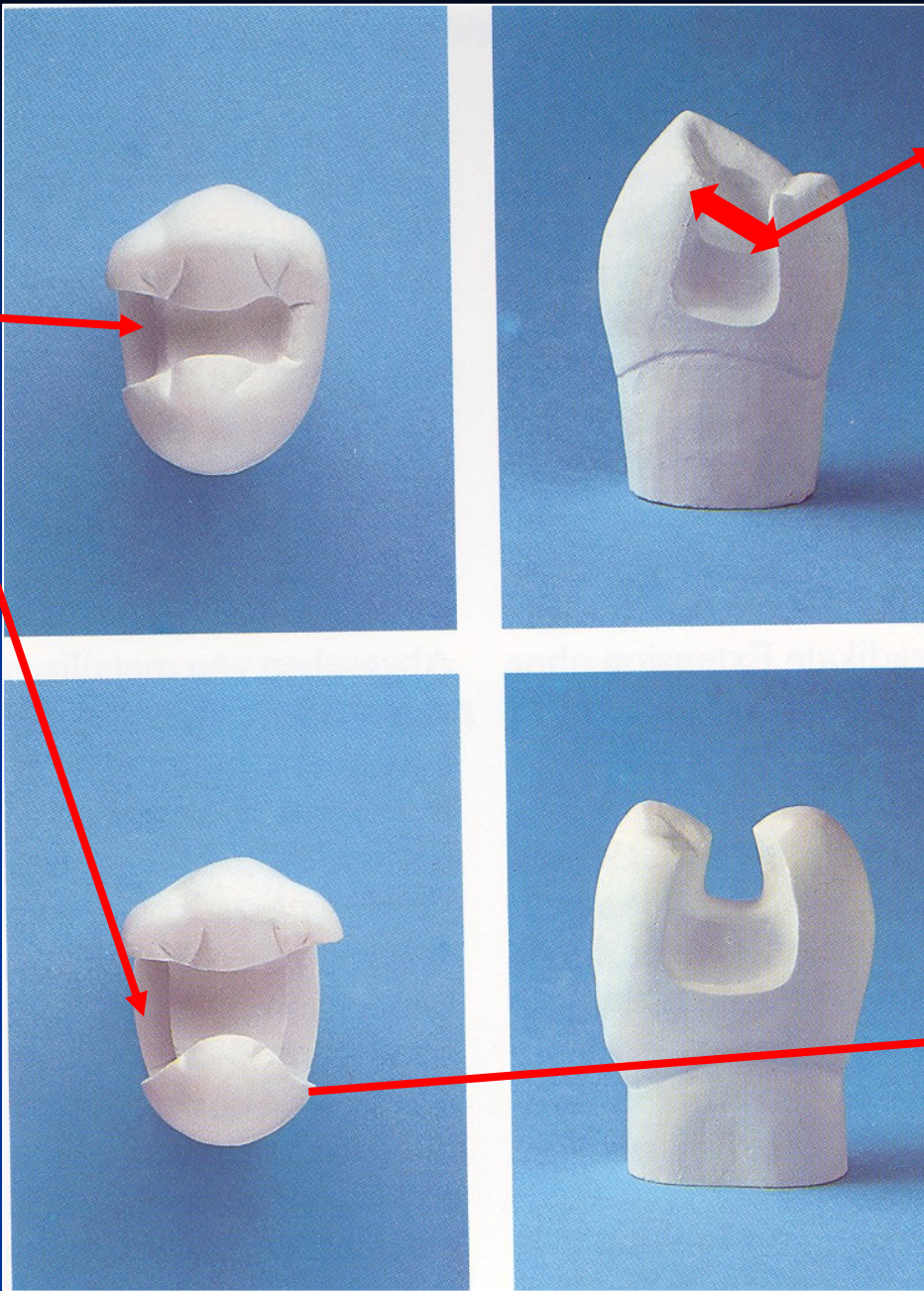


Grooves

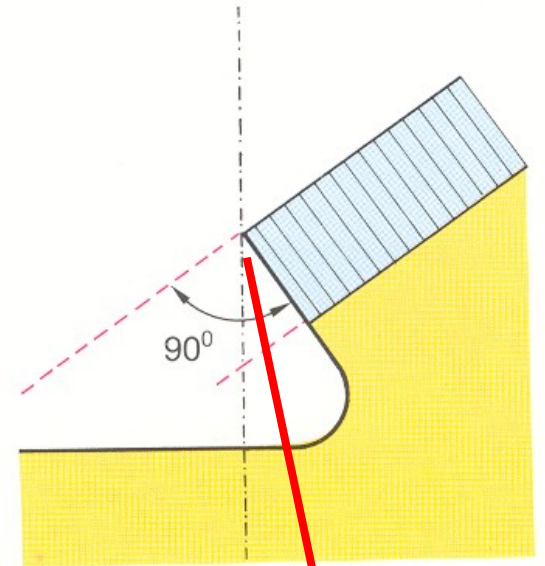
Resistance

- No undermined enamel
- No sharp wedges
- Isthmus is $1/3 - 1/4$ intercuspidal distance
- Angle between axial and gingival wall: 90° , or 85°
- Width of gingival wall is 1 mm at least
- Thickness of the filling 2 – 4 mm (4mm cusp replacing)

G. wall



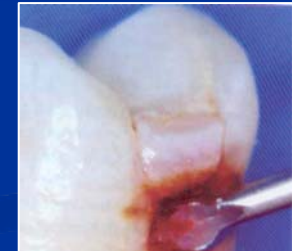
Isthmus



Cavosurface angle

Excavation of carious dentin

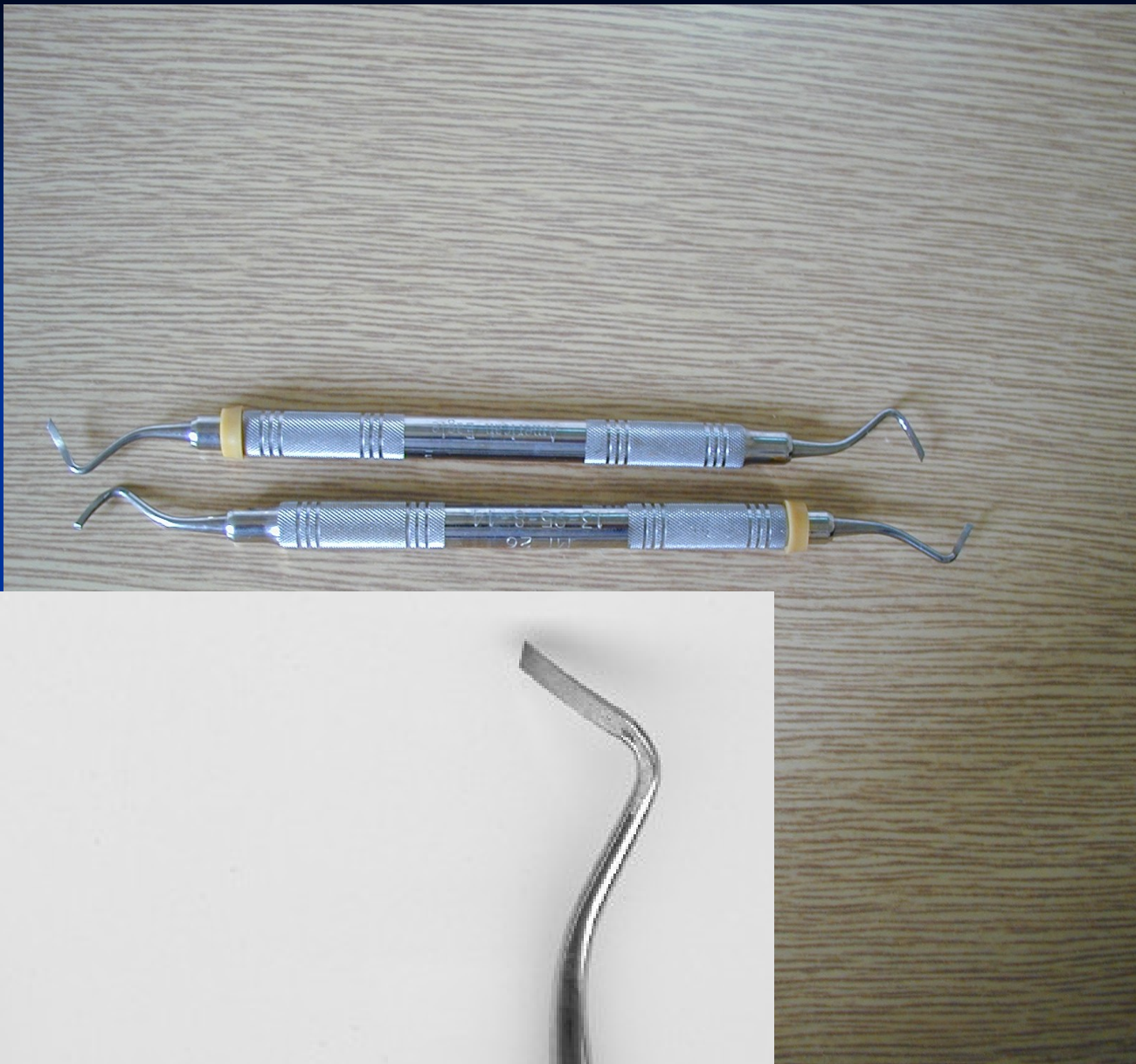
Rounded bur

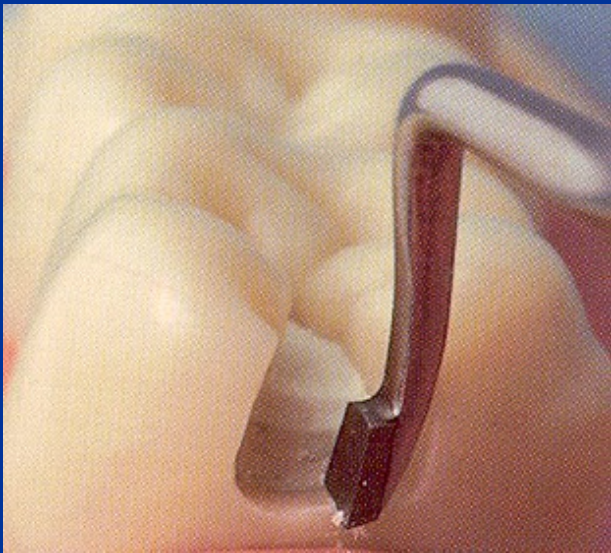
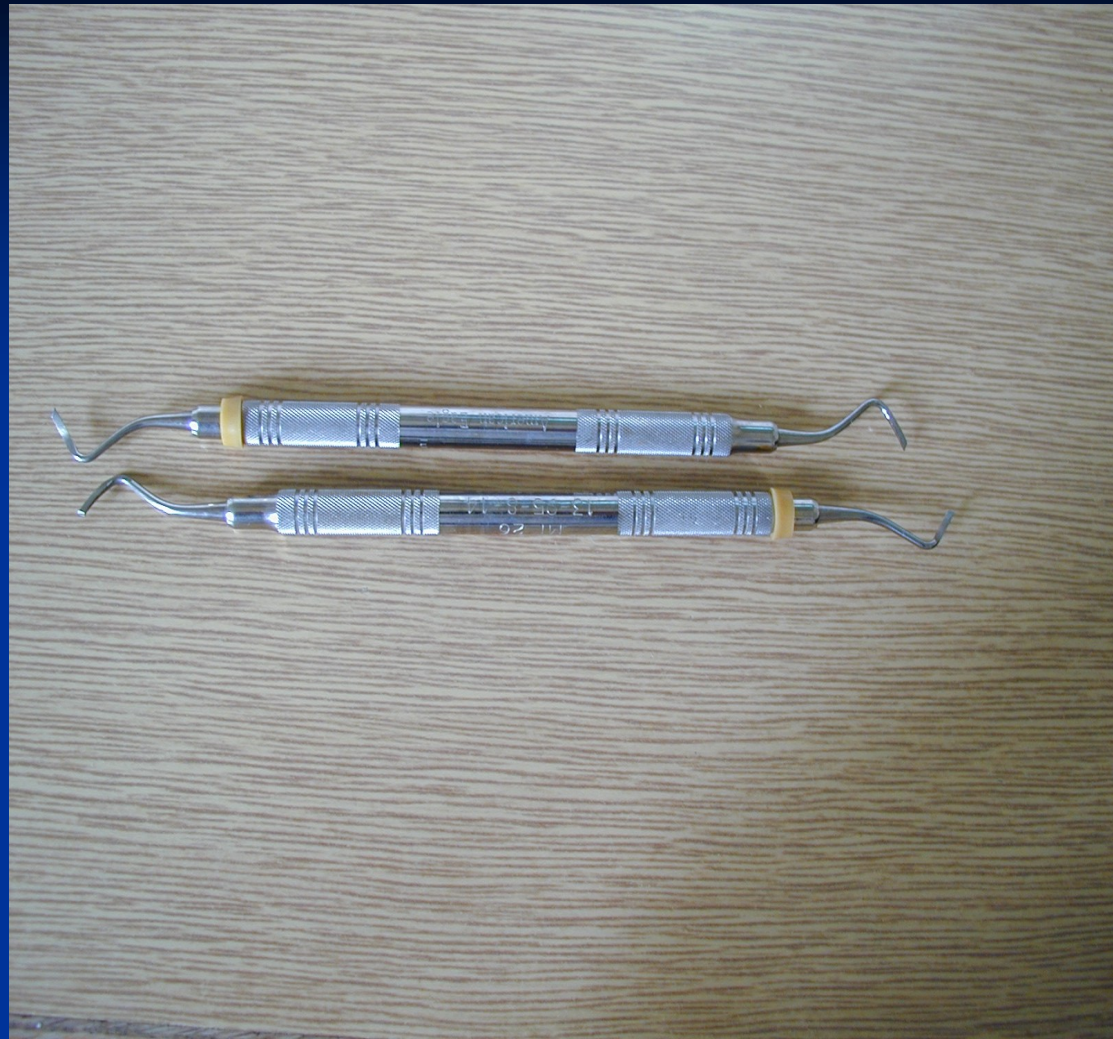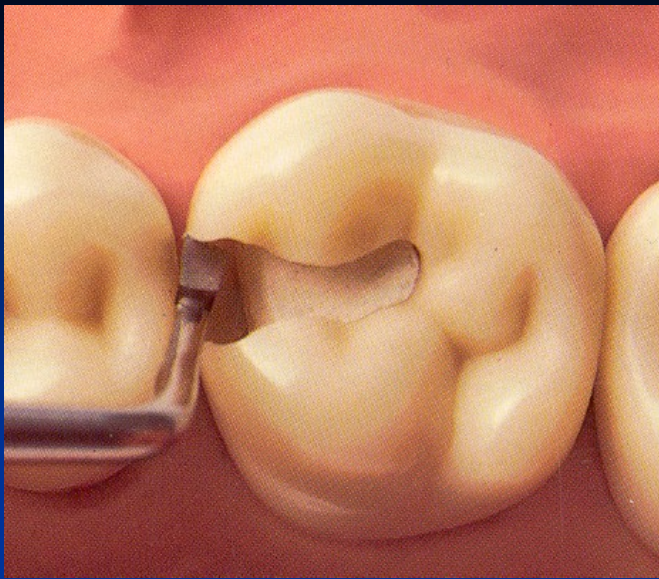


(Caries Detector, Kuraray, Japonsko; Caries Marker, VOCO, Německo)

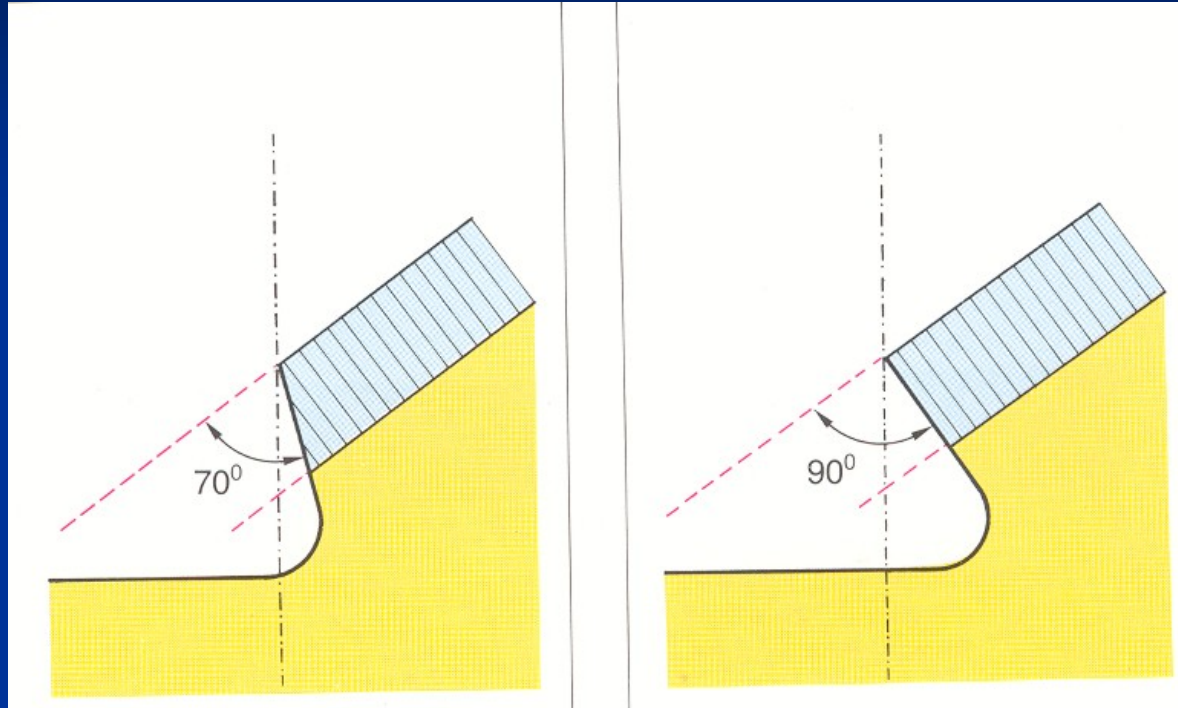
Finishing of cavity walls

- Red coded diamond bur
- Chisel on the gingival wall (if in enamel)





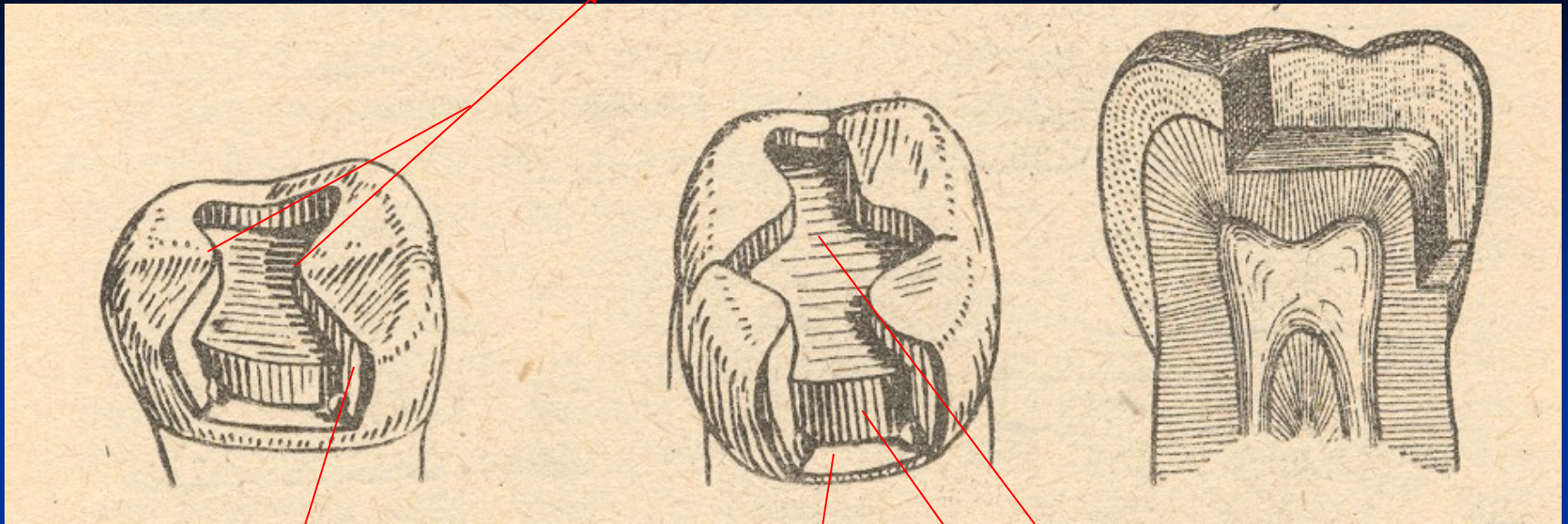




Cavity control

➤ Goog light, miror

Isthmus



Axial wall

Gingival wall

Pulpal wall

Matrix placement

- Matrix primarily is used when a proximal surface is to be restored

The objectives:

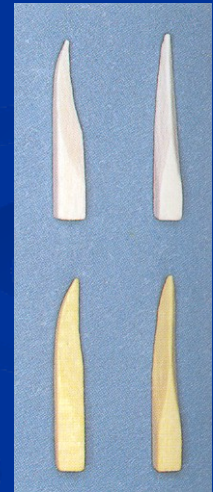
- Provide proper contact
- Provide proper contour
- Confine the restorative material
- Reduce the amount of excess material

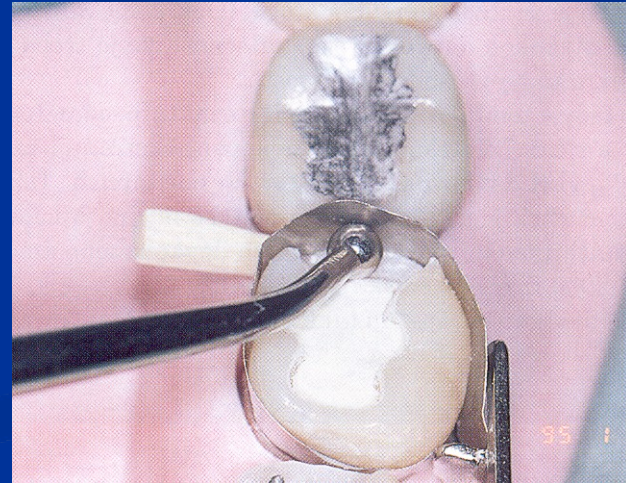
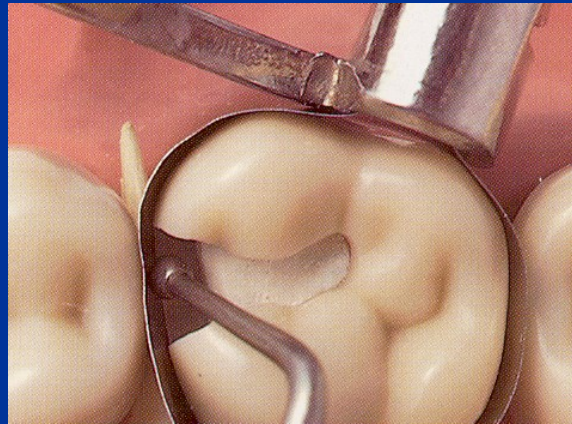
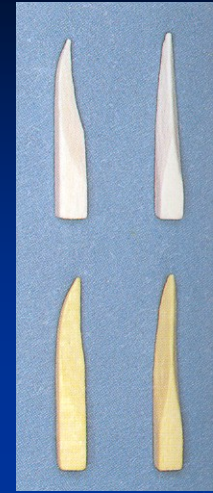Matrices

- Ivory I retainer Ivory 1
- Hawe Neos retainer Ivory 8
- Tofelmire matix and retainer

Wedges

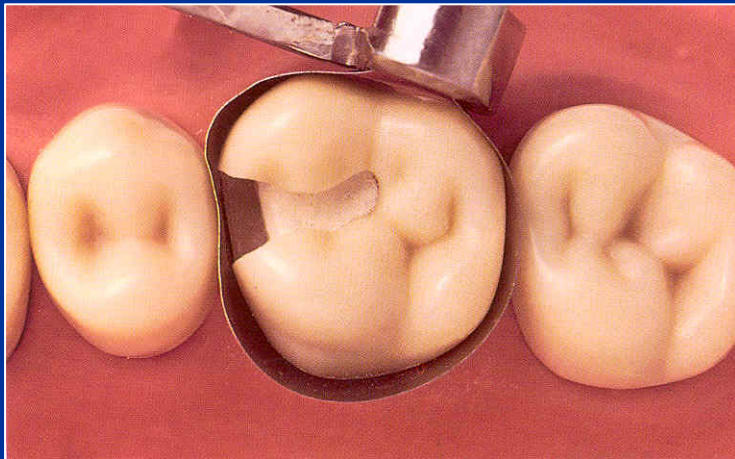
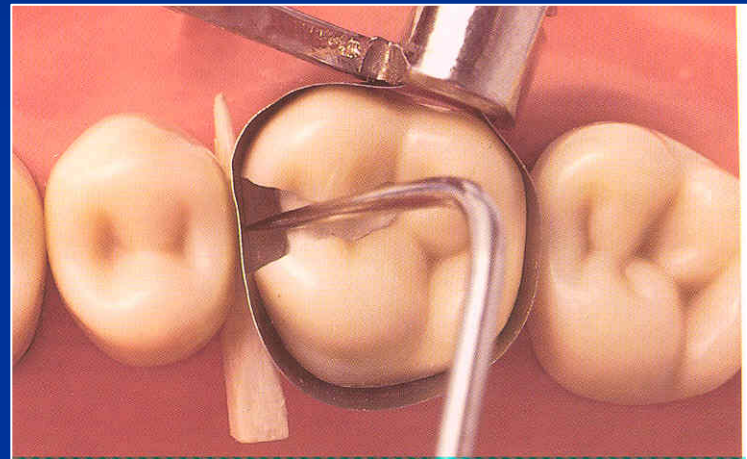

- Wooden wedges
 - tighten the matrix band
 - compress the gingiva
 - separate the teeth

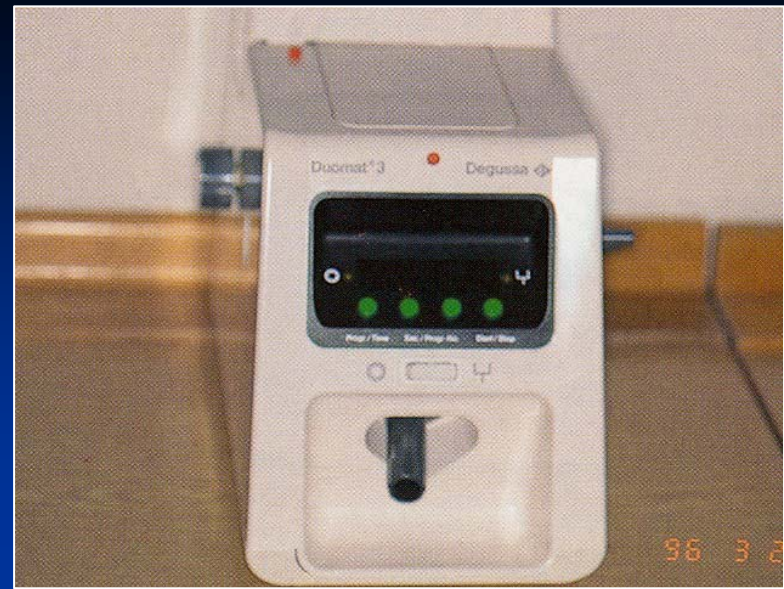




Wedging

- Slip the matrix band over the tooth (apical to the gingiva margin – 0,5, - 1 mm)
- Tighten the matrix, check it with probe
- Place a wedge
- Turn the retainer $\frac{1}{4}$ counterclockwise
- Contour the band



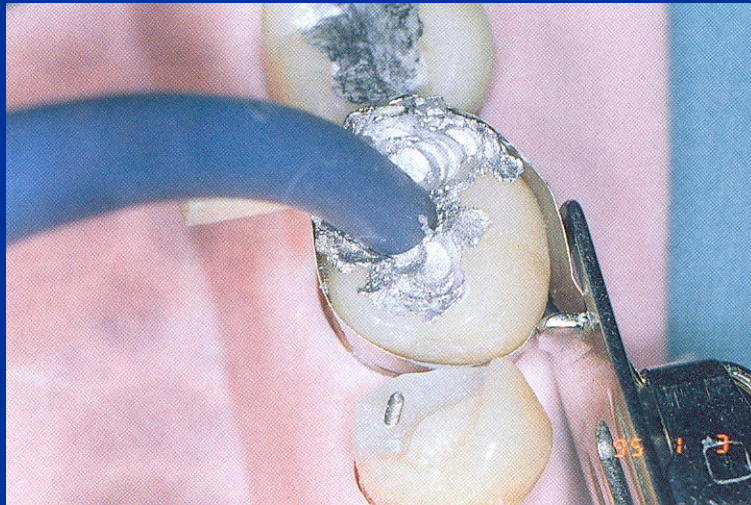
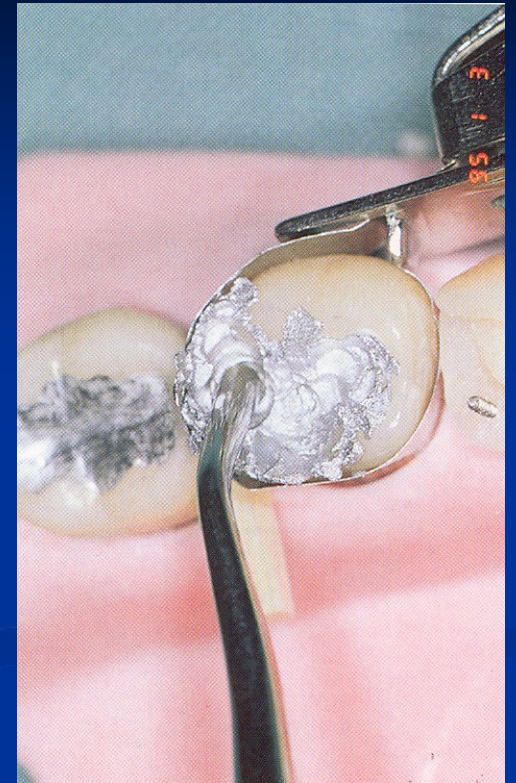


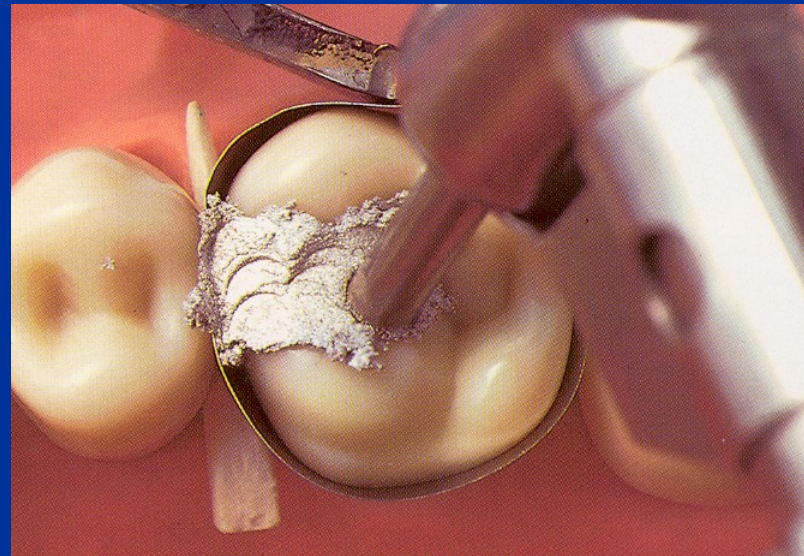
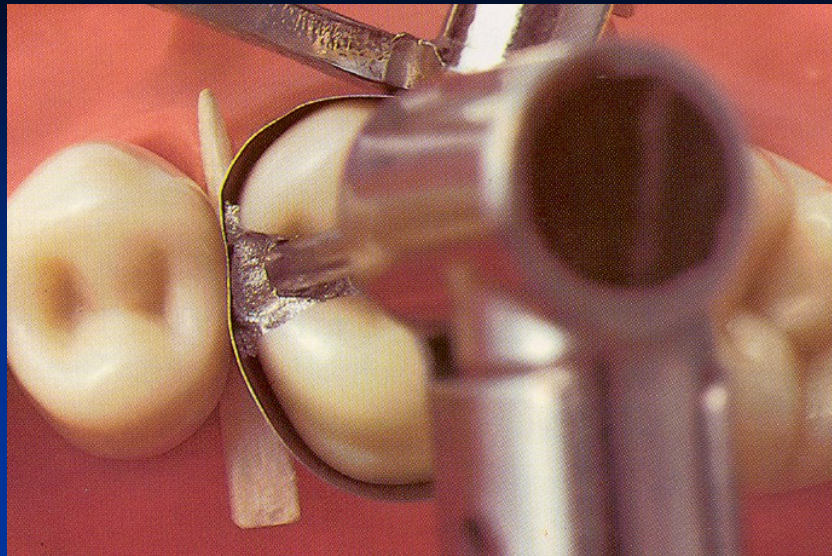
Trituration!

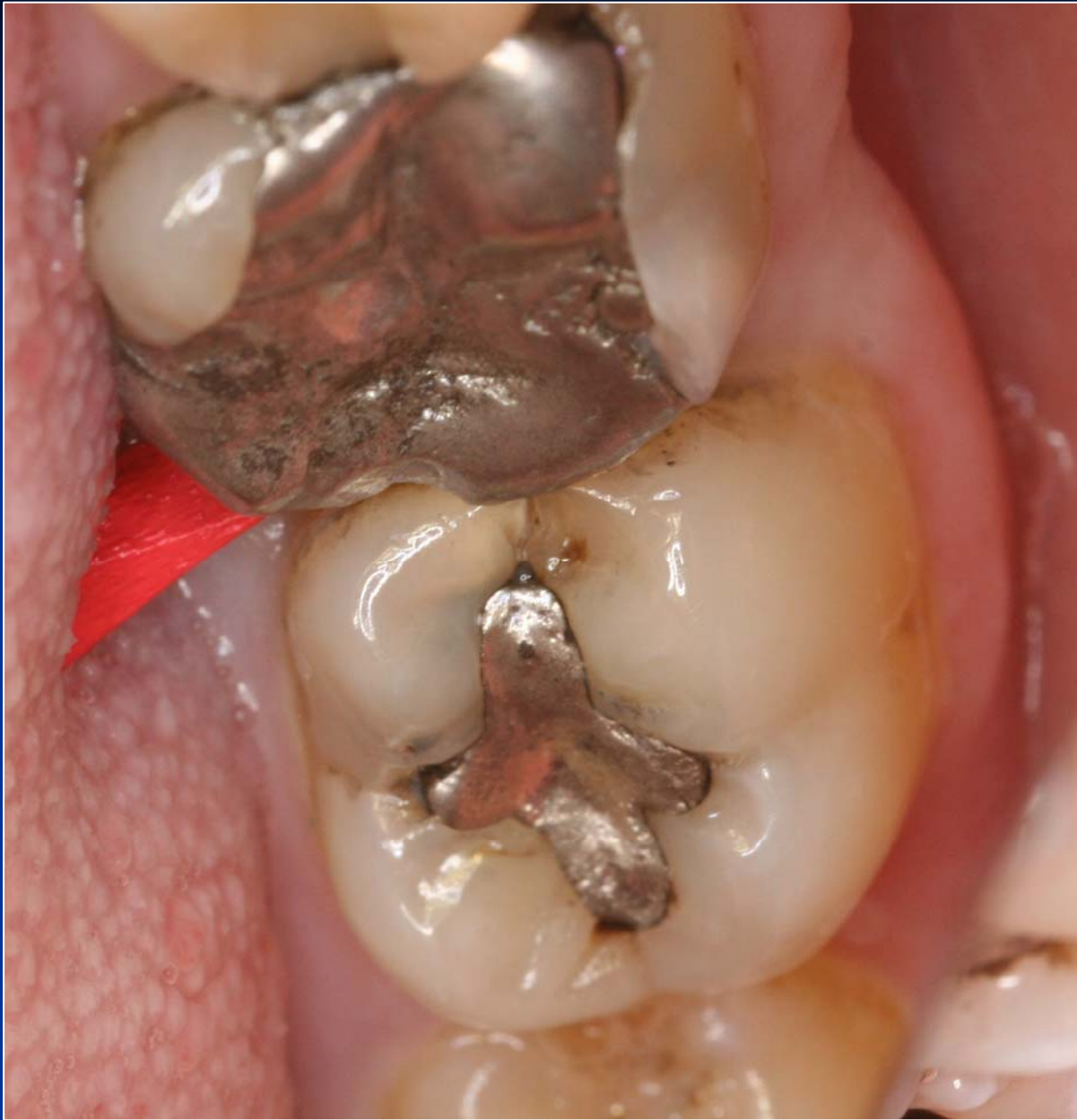Condensation of amalgam

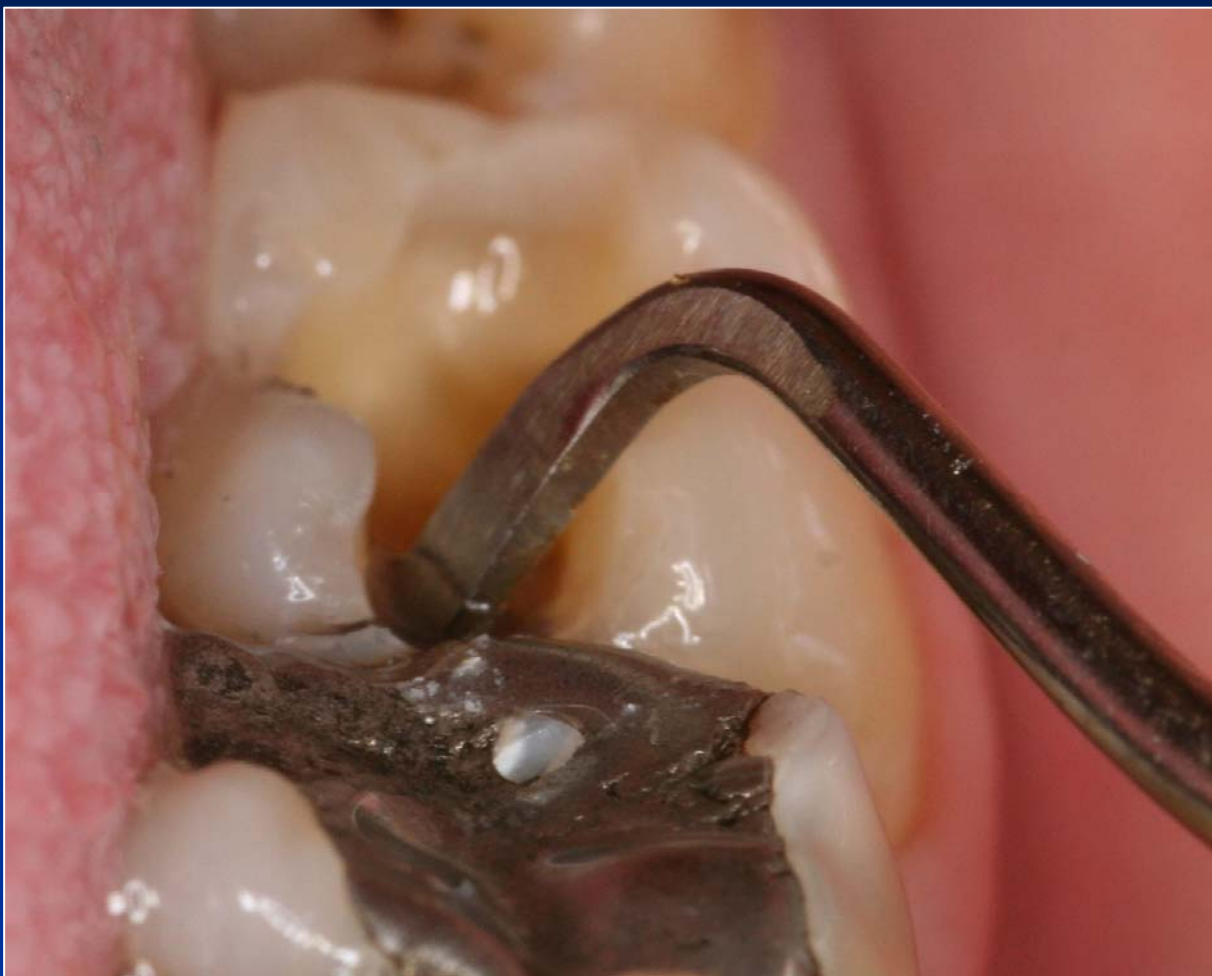- Condensor – stamen is the best one
- Power driven condensation

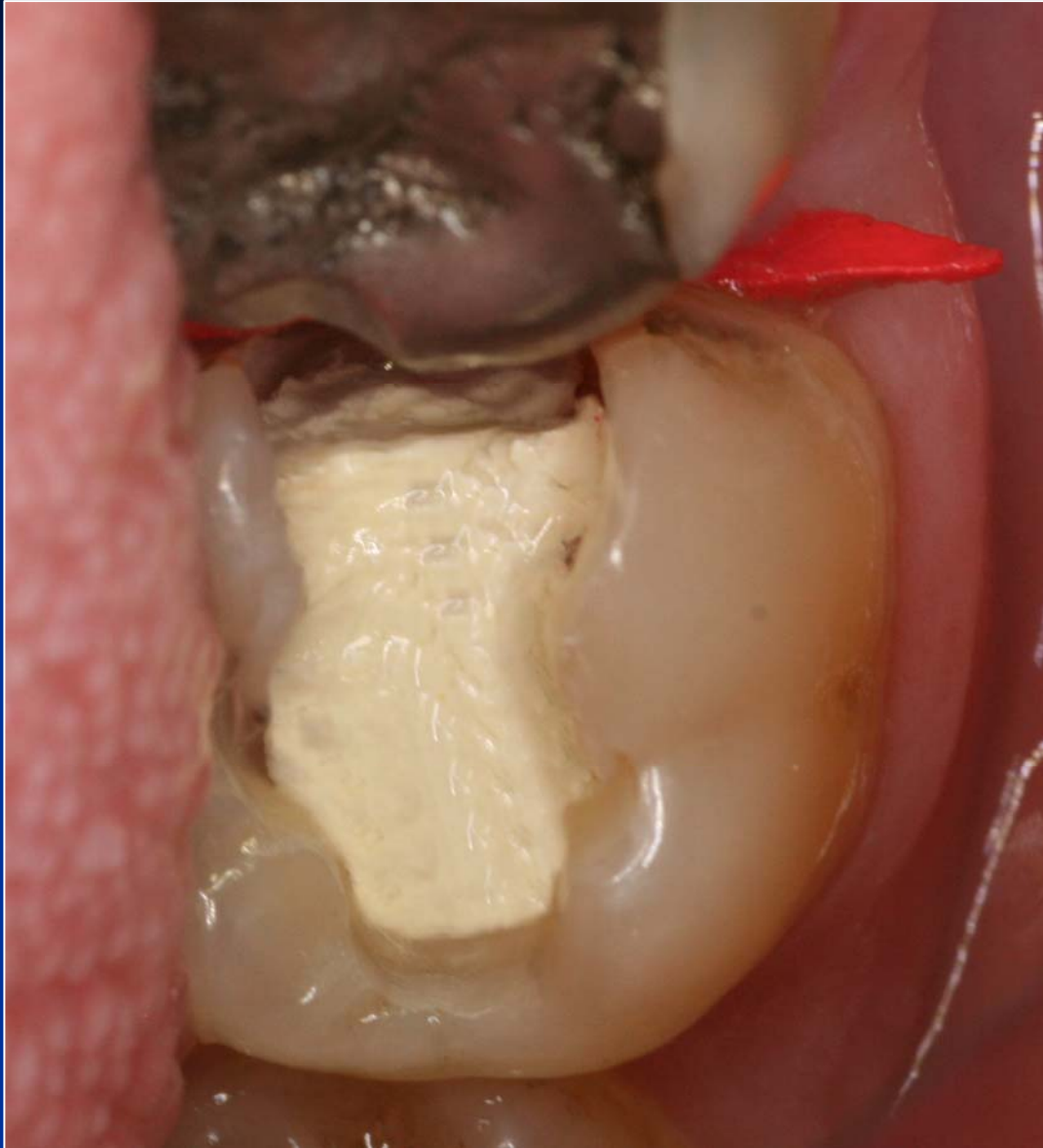
How big the stamen should be??

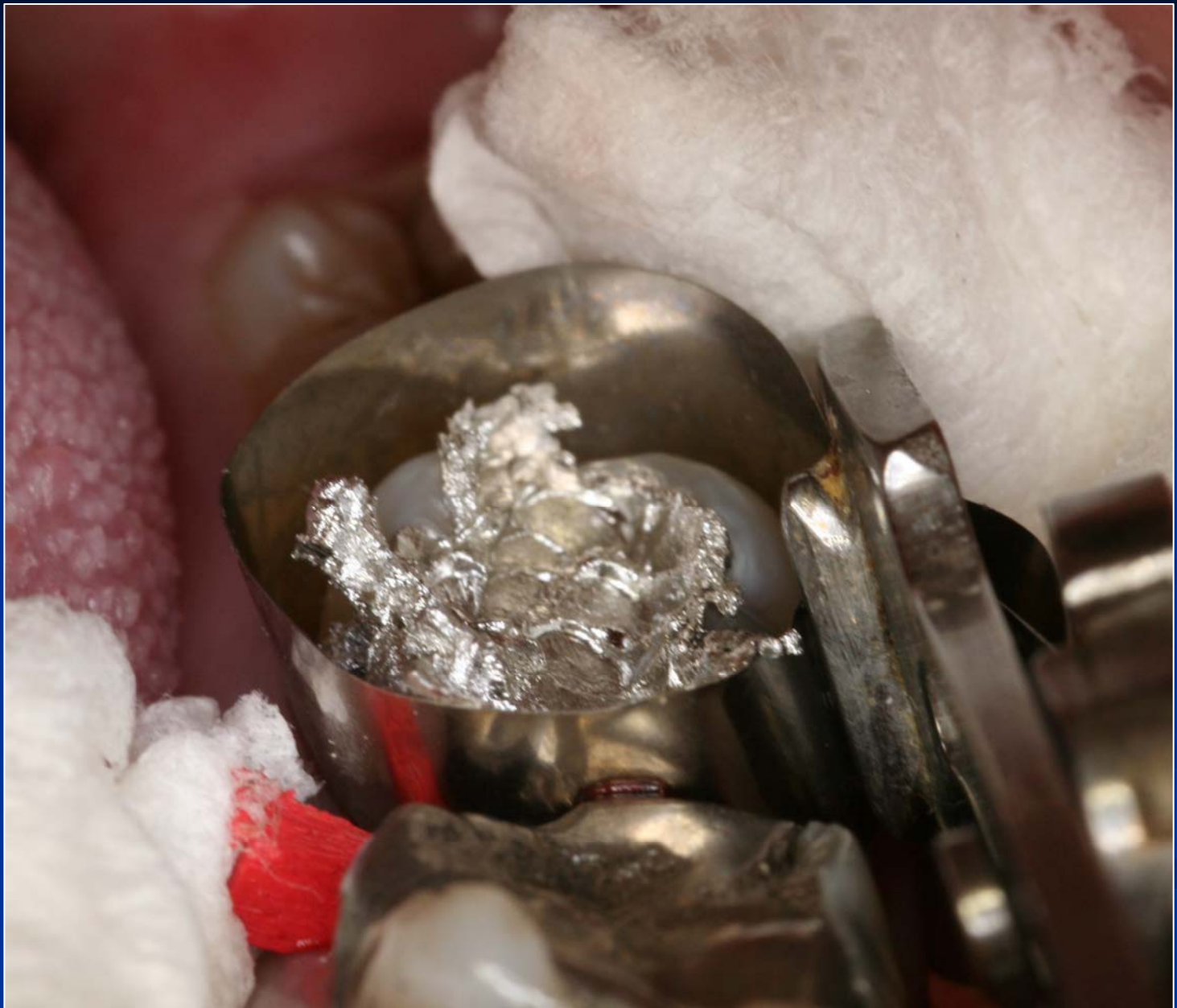


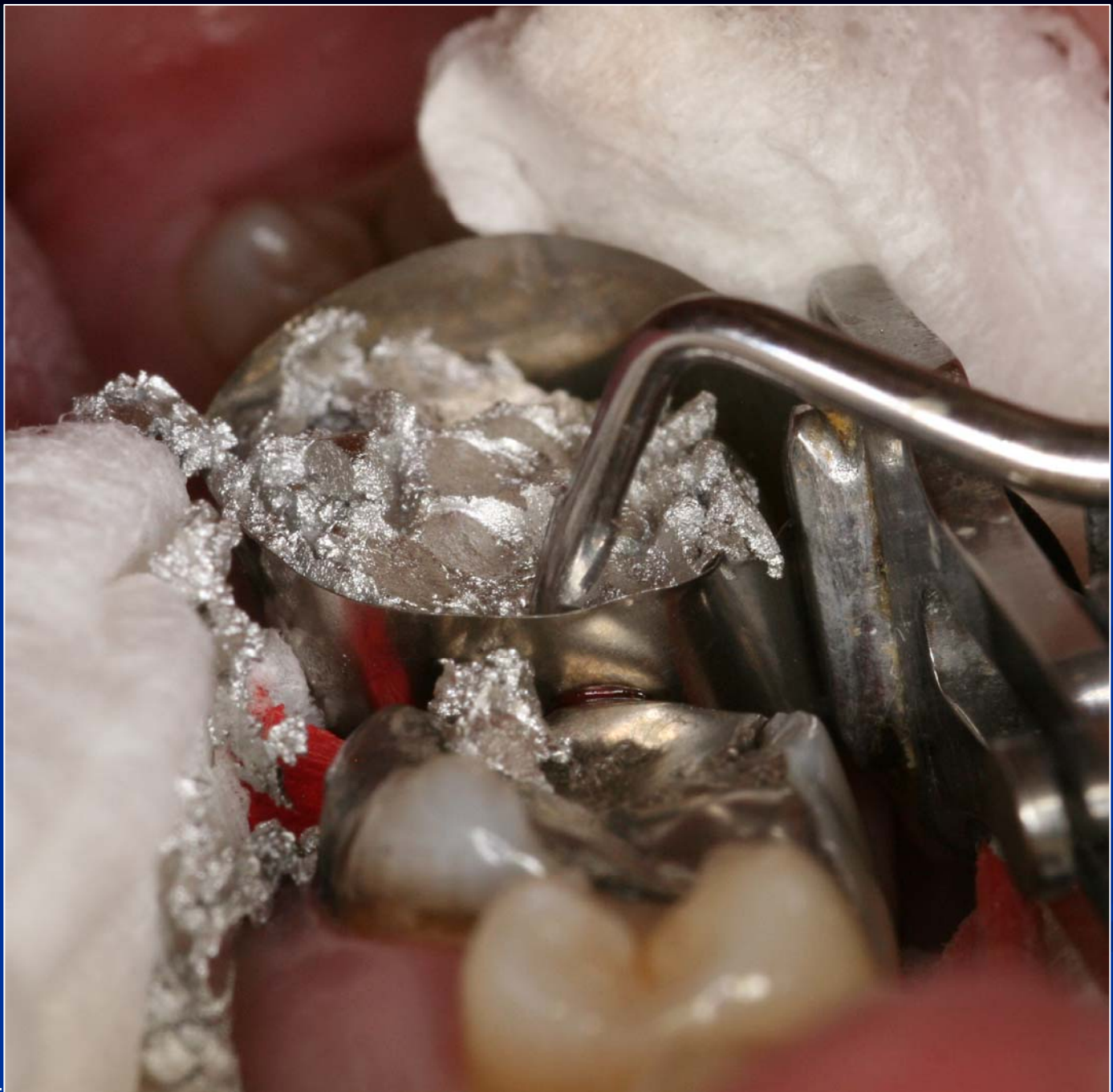


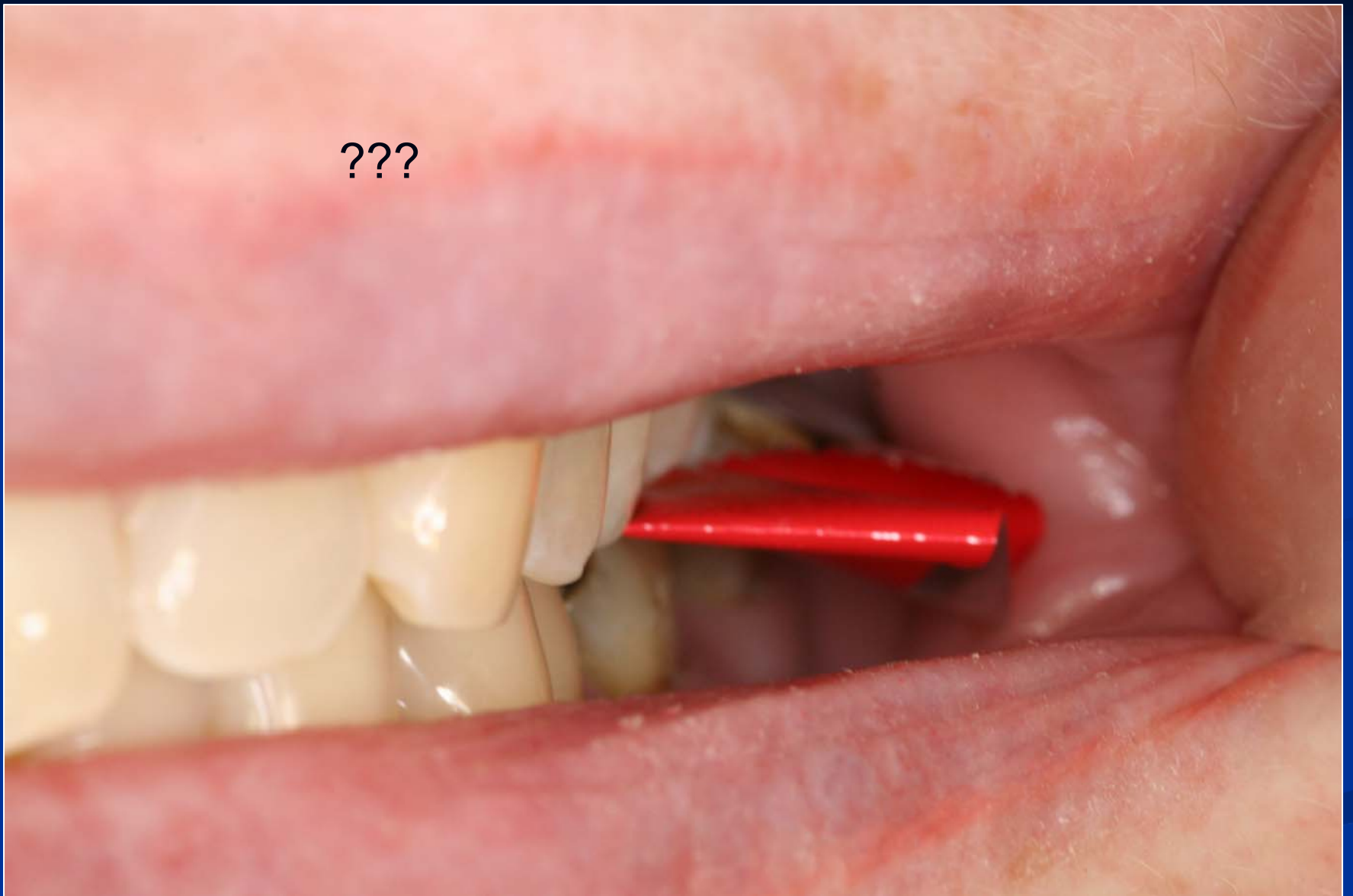




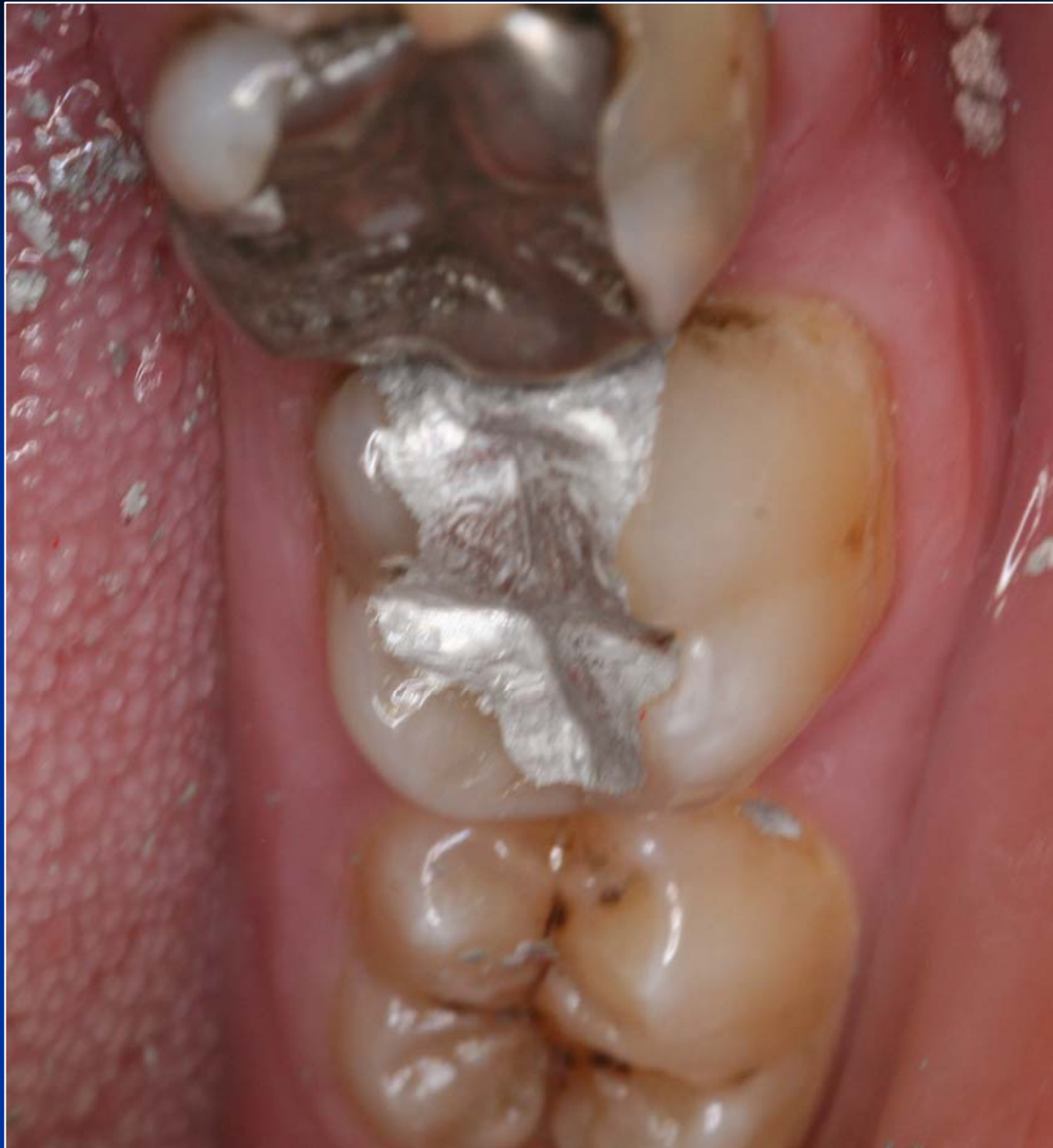



???

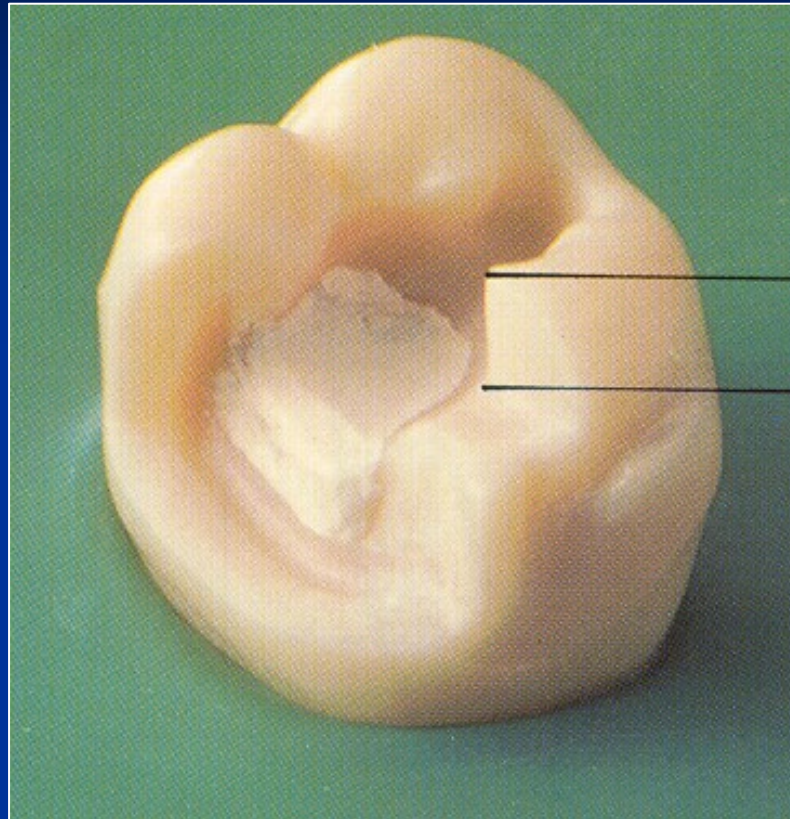


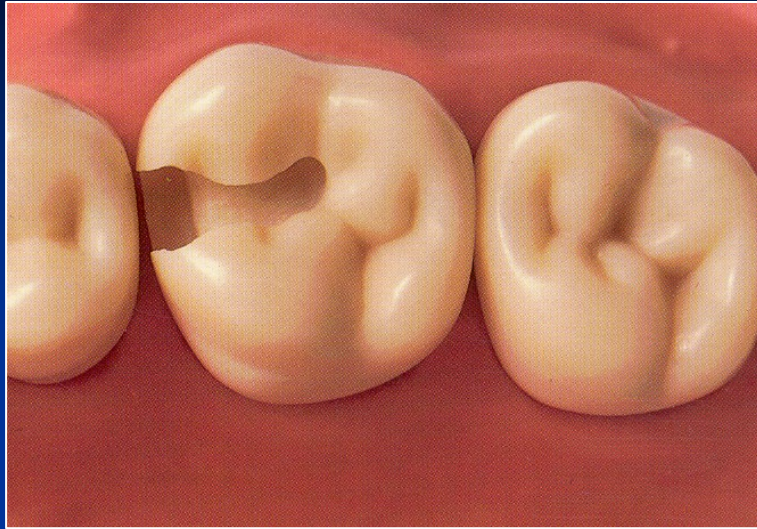


Base

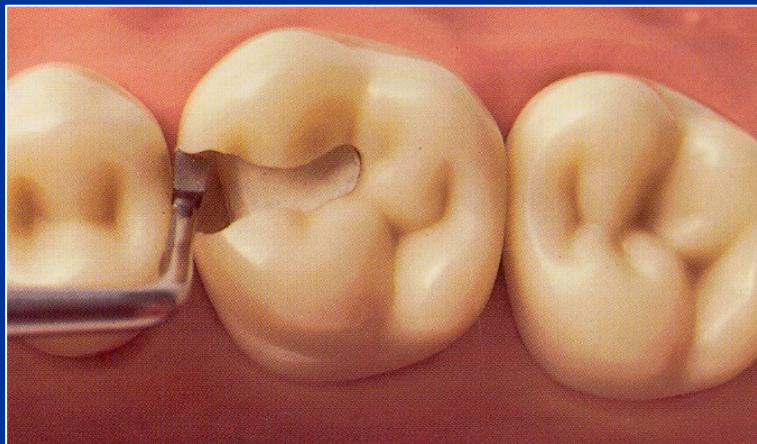
- Zinkoxidphosphate cement
- Zinkoxidkarboxylate cement
- Glass ionomer cement
- Zinkoxideugenol

On pulpal walls only!



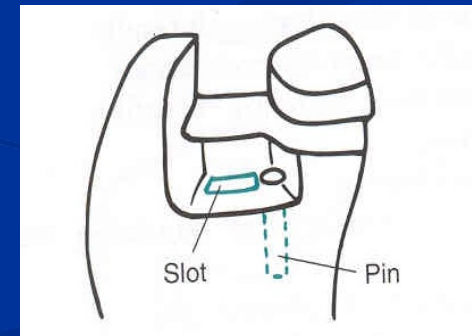
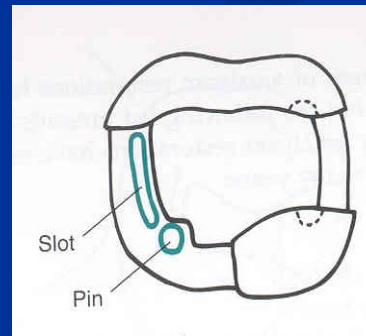
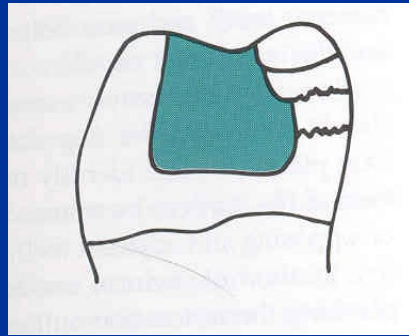
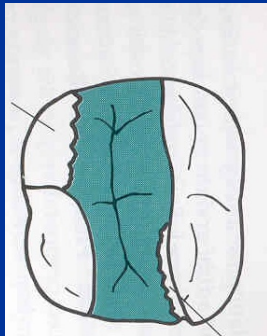


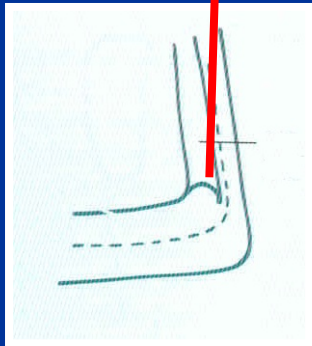
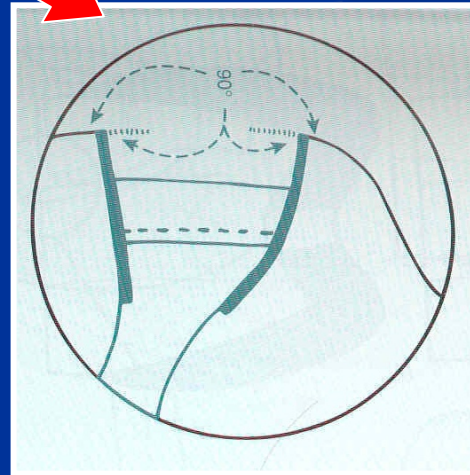
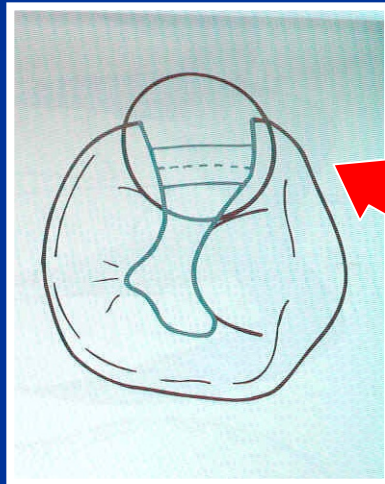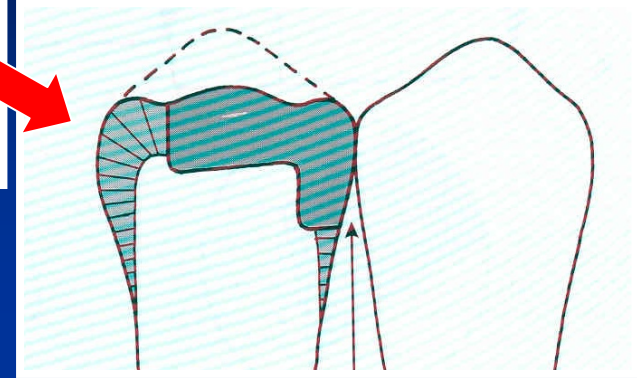
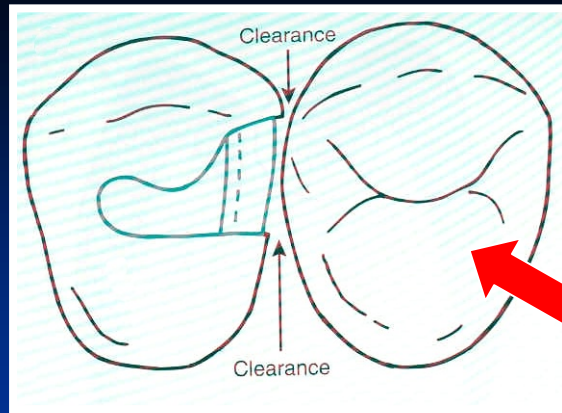
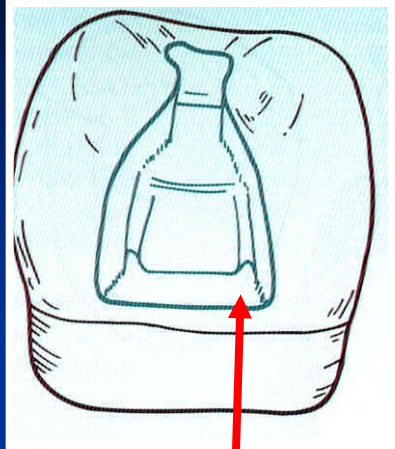
The base must be hardened

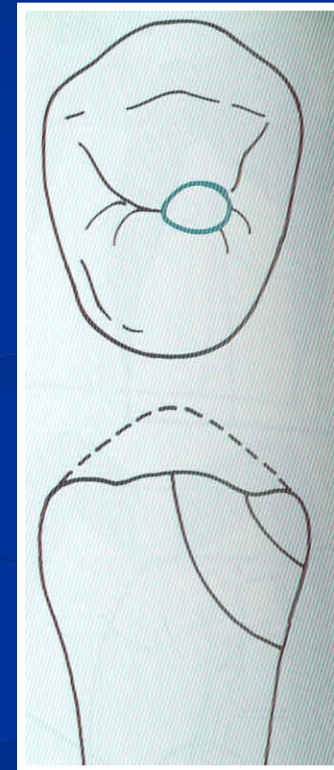
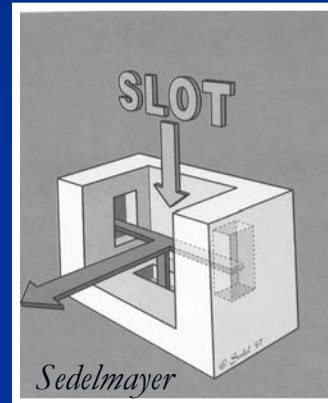
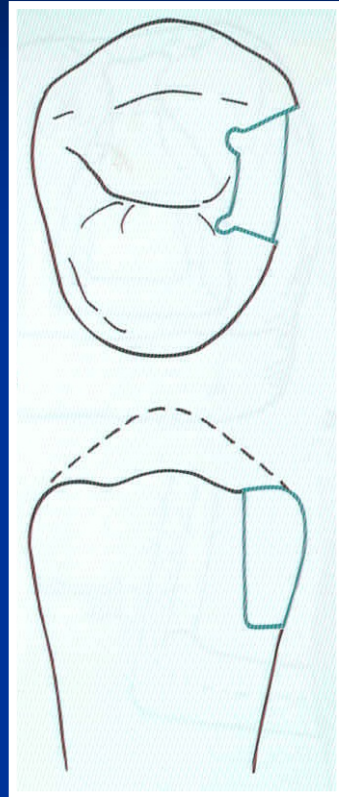
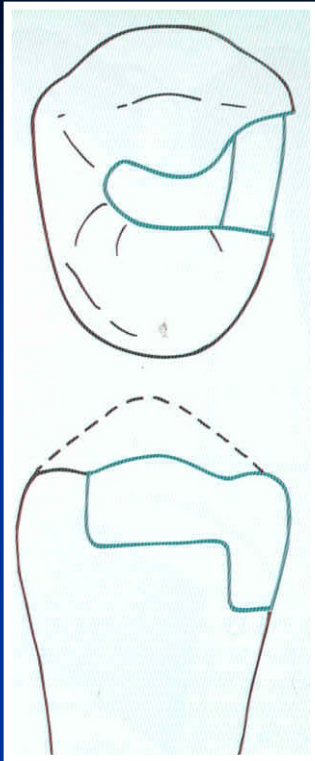


Amalgam

Retention



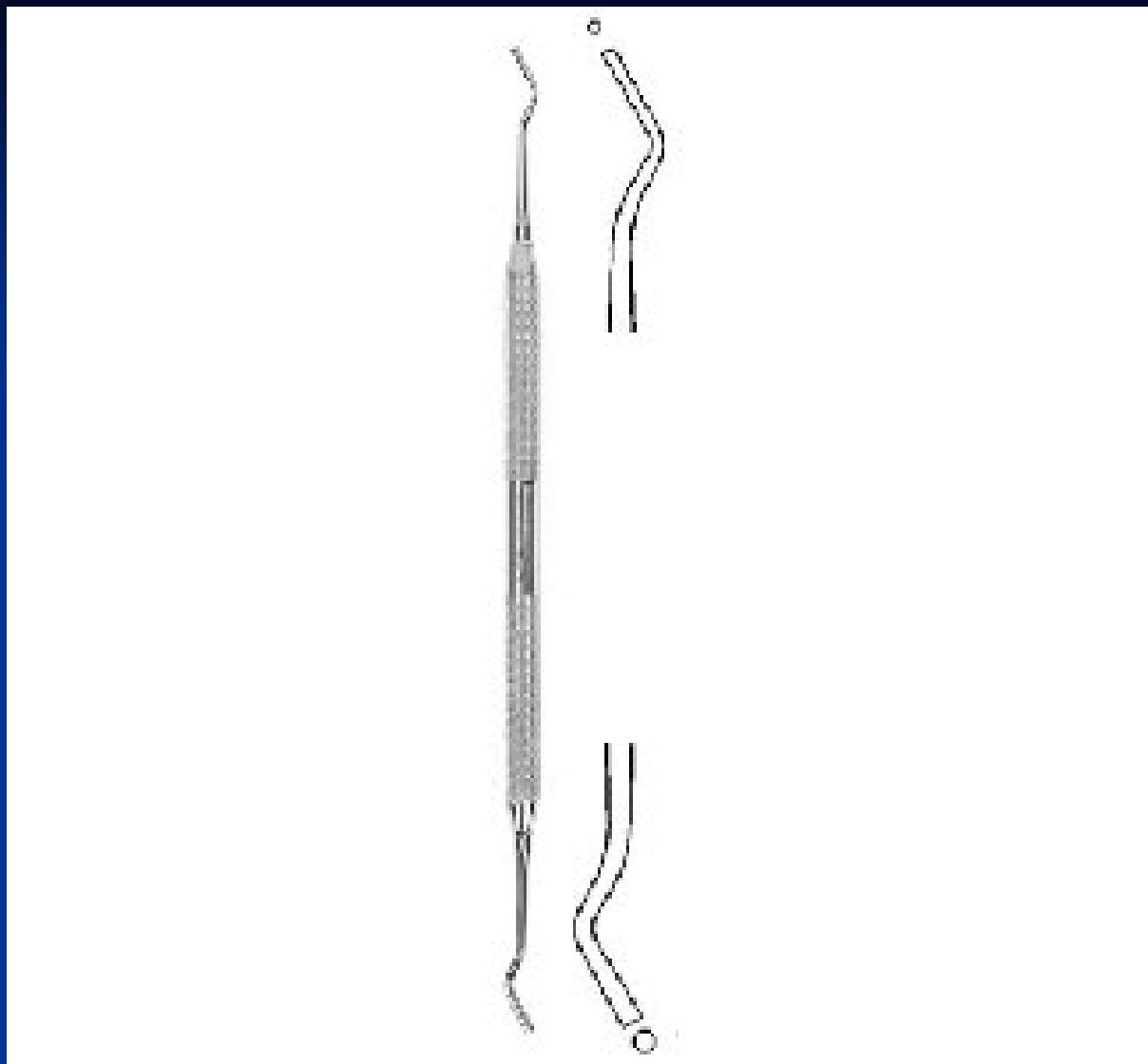




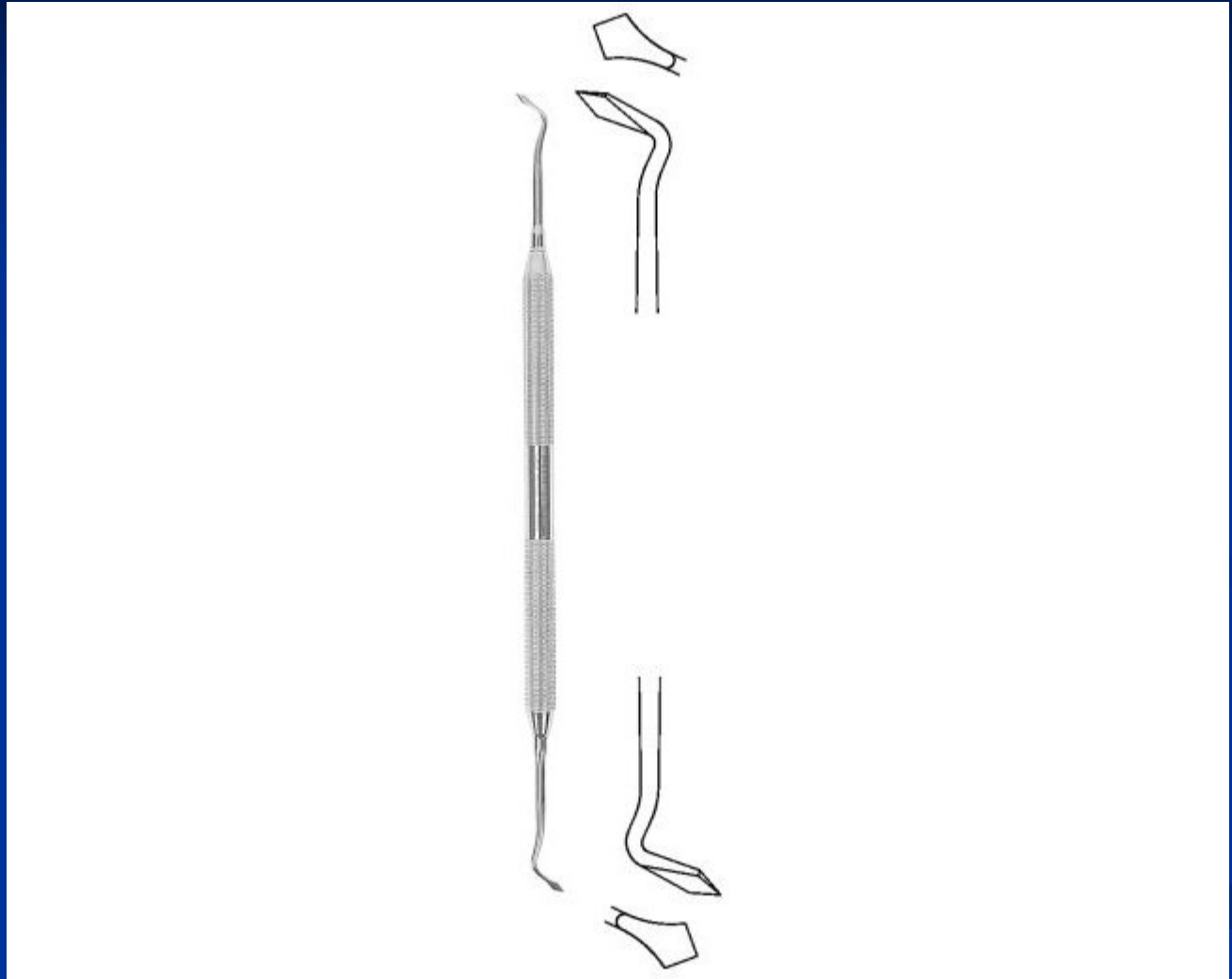
Instruments

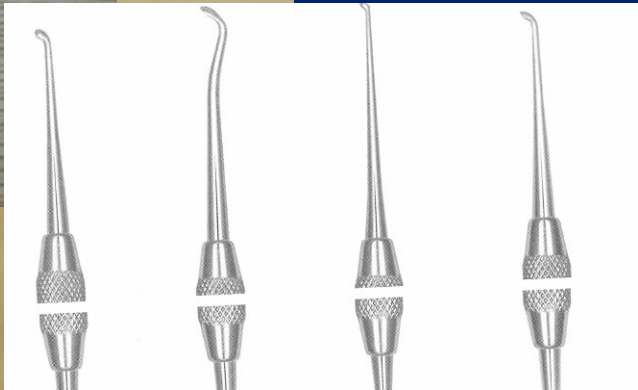- Preparation
- Filling
- Finishing and polishing

Cpátko tyčinkové



Ořezávač -Frahm






Ořezávač - Sapin



Ořezávač discoid-cleoid



Nosič amalgámu

