

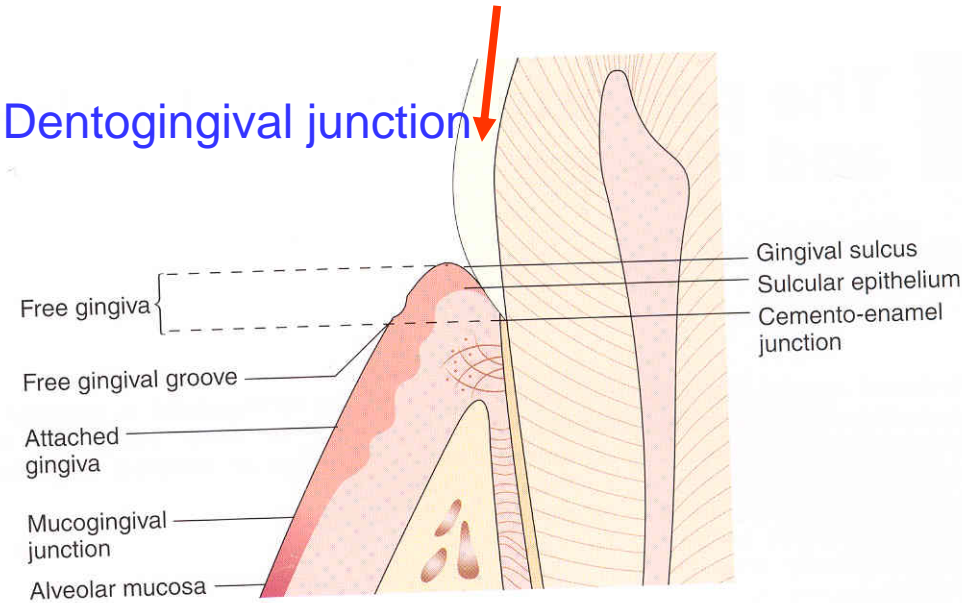
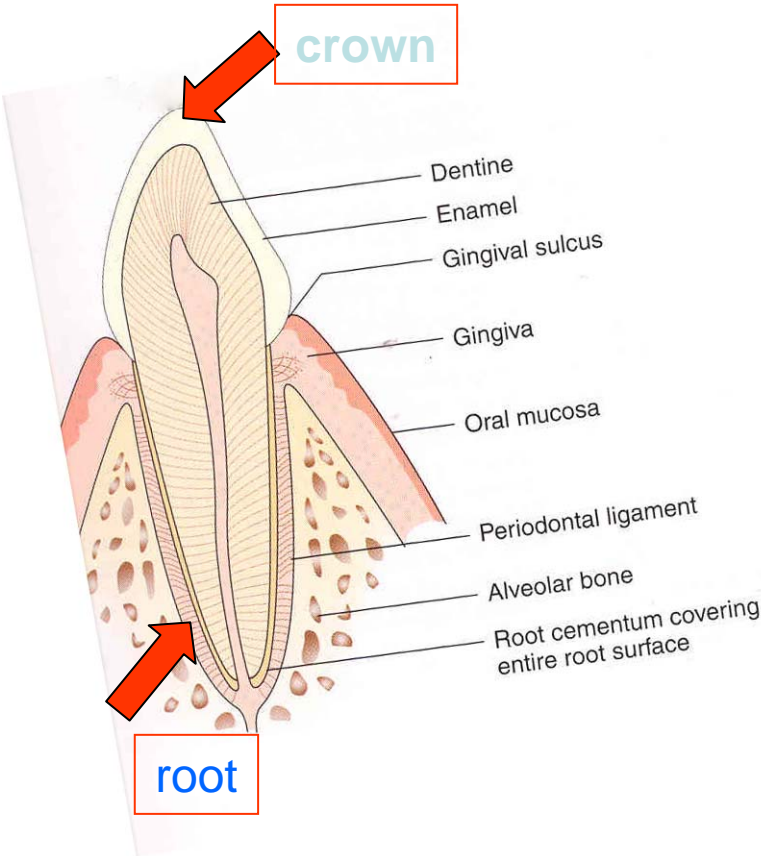
Periodontology

Periodontology

- Periodontal tissues
 - alveolar bone
 - cementum
 - periodontal ligament
 - gingiva

Morphology

Supportive tissues



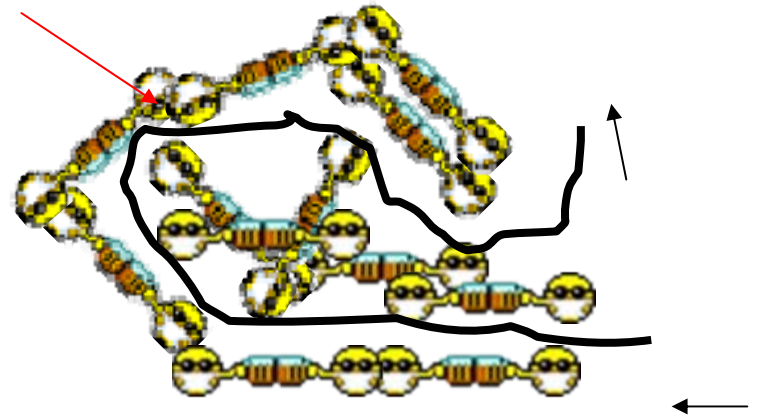
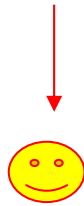Periodontal diseases

- Inflammation at most!!!!
- The most important ethiological factor?

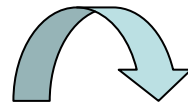
 **Dental plaque!!!!** 
BIOFILM

Dental plaque = biofilm

- **Comunity**



- **Primitive circulation**



More species

Higher metabolic activity


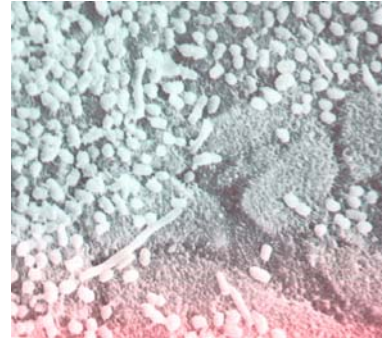
Higher resistance

(*S. sobrinus* CHX 300x, AF 75x)


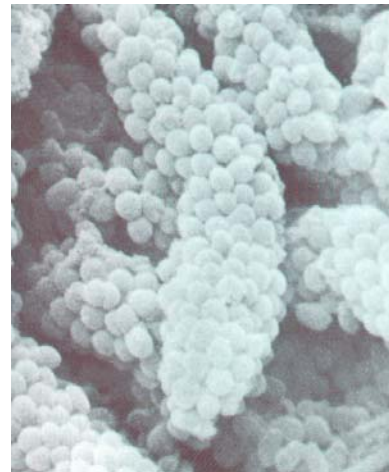
} better conditions to survive
higher virulence

Biofilm

Well organized
community
of microbes



Adherence
Colonisation
Maturation

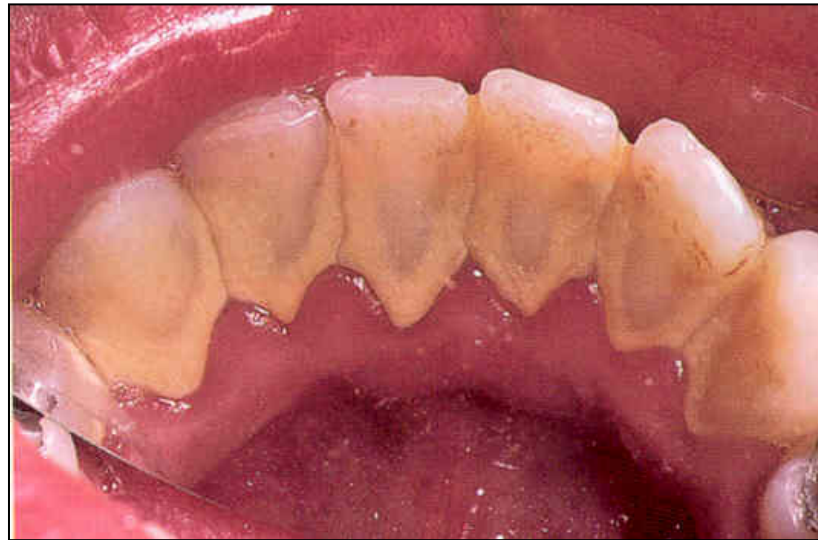


It can be removed
mechanically
only

Other aetiological factors

- Calcified deposit on teeth, plaque on the surface
- Overhangs, crowns, dentures
- Genetic factors – gen polymorphism

Dental calculus



Parodontopathies

Gingivitis

- Plaque associated gingivitis

Chronic form

Erythema

No pain

Easy bleeding

Plaque on the tooth

Acute form

Erythema

Pain

Easy bleeding

Plaque on the
tooth

Acute necrotising gingivitis - ANUG

- Necrotizing ulcerative gingivitis

Aetiology

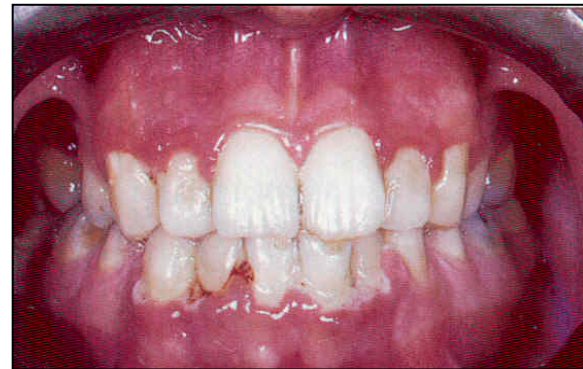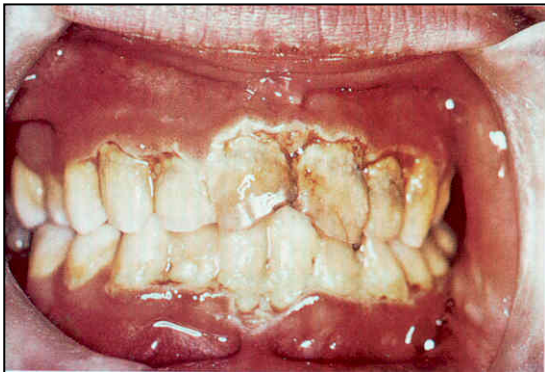Special microbes - anaerobs

The clinical picture

- Gingival inflammation and destruction



Severe pain, bleeding gums, halitosis



Diferential diagnosis

- Herpetic gingivostomatitis
 - Young people
 - Prodroms
 - Pyrexia
 - Lymphadenopathy
 - Lesions more widespread and diffuse

Diferential diagnosis

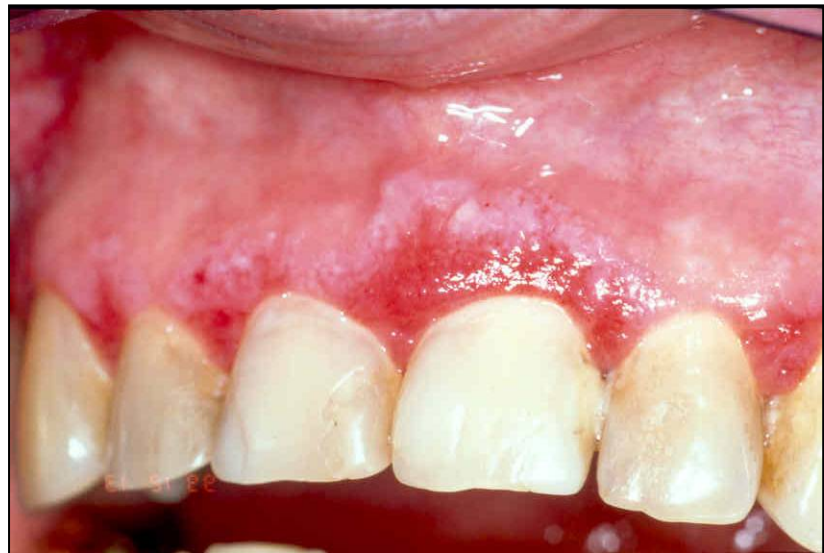- If ANUG does not tend to recover in 10 days – check the blood picture!



Atrophic or desquamative gingivitis

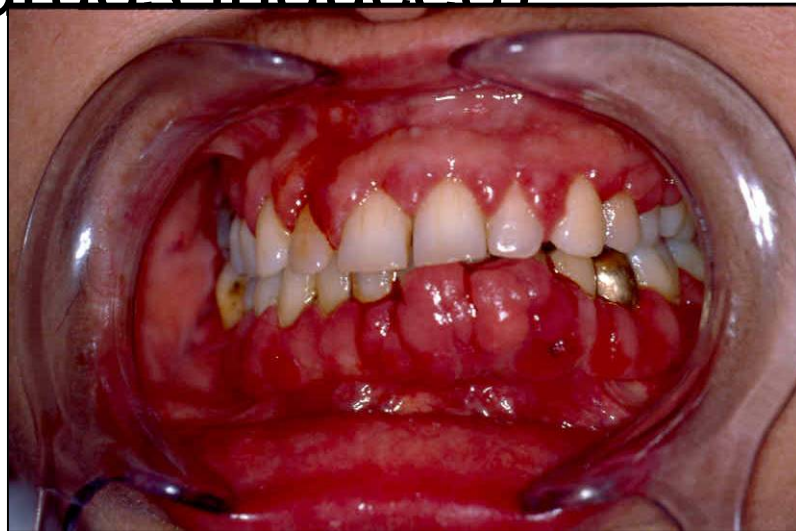
symptoms

- Erythema on free gingiva – loss of the epithelium
- Variety of symptoms: itching, tenderness of eating, burning.



Hyperplastic gingivitis

- High standard of oral hygiene must be achieved!
- Gingivectomy (drugs induced)



Parodontopathies

Periodontitis

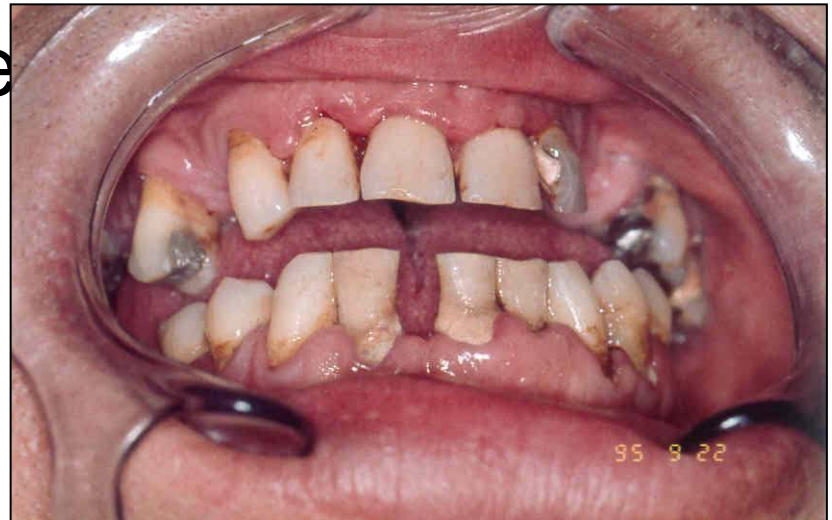- Chronic periodontitis.
- Aggressive periodontitis.
- Periodontitis as a manifestation of systemic disease.
- Necrotizing periodontal diseases.
- Abscesses of the periodontium.
- Periodontitis associated with endodontic lesions.
- Development or acquired deformities and conditions.

Parodontopathies

Periodontitis

Periodontitis

- Gingivitis
- Pocketing
- Loss of alveolar bone
- Drifting and mobility
- Furcation exposures
- Recession

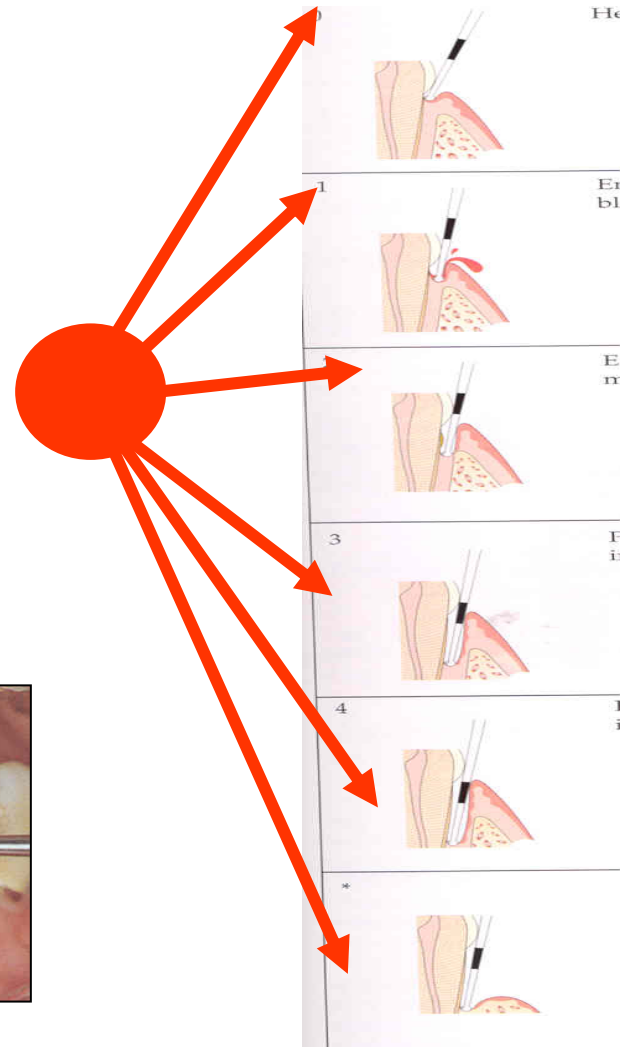
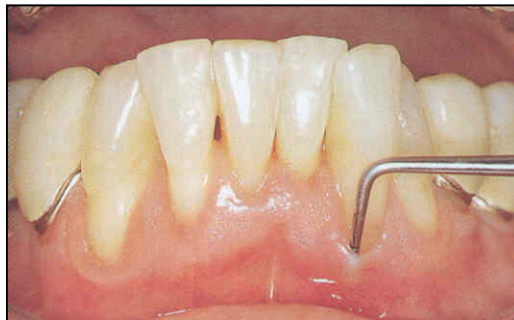

Periodontitis

- Gingivitis
- Pocketing
- Loss of alveolar bone
- Drifting and mobility
- Furcation exposures
- Recession

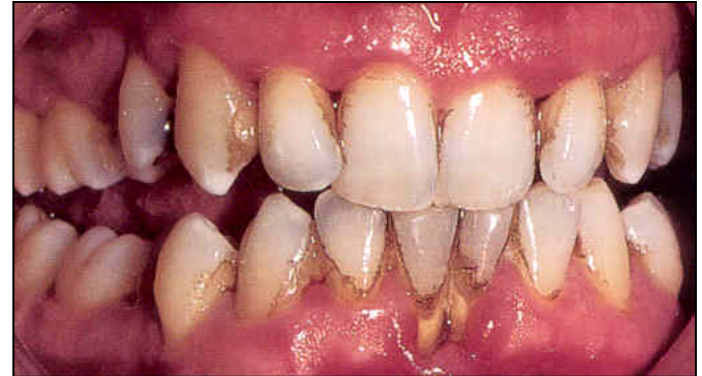Periodontitis

- Gingivitis
- Pocketing
- Loss of alveolar bone
- Drifting and mobility
- Furcation exposures
- Recession



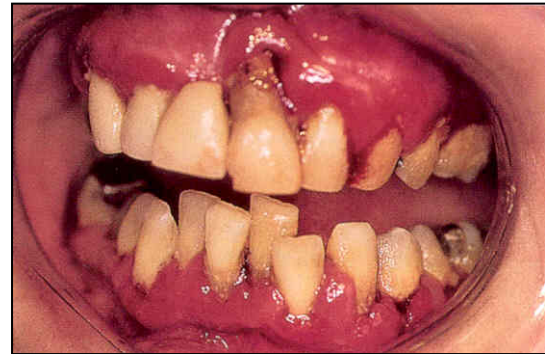Periodontitis

- Gingivitis
- Pocketing
- Loss of alveolar bone
- Drifting and mobility
- Furcation exposures
- Recession



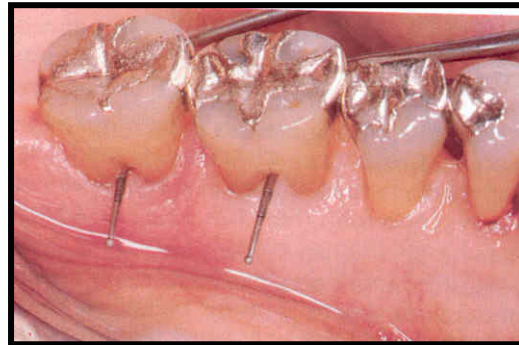
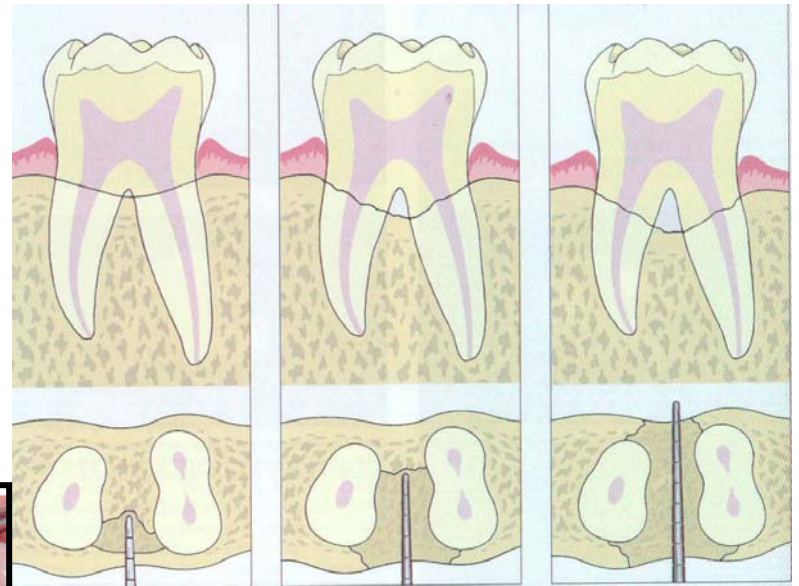

Periodontitis

- Gingivitis
- Pocketing
- Loss of alveolar bone
- Drifting and mobility
- Furcation exposures
- Recession



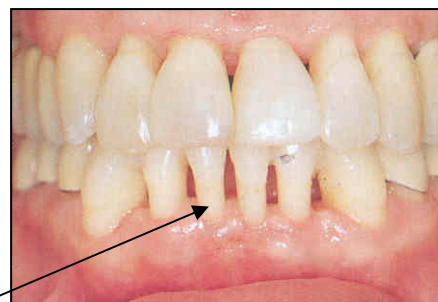
Periodontitis

- Gingivitis
- Pocketing
- Loss of alveolar bone
- Drifting and mobility
- Furcation exposures
- Recession



Periodontitis

- Gingivitis
- Pocketing
- Loss of alveolar bone
- Drifting and mobility
- Furcation exposures
- Recession

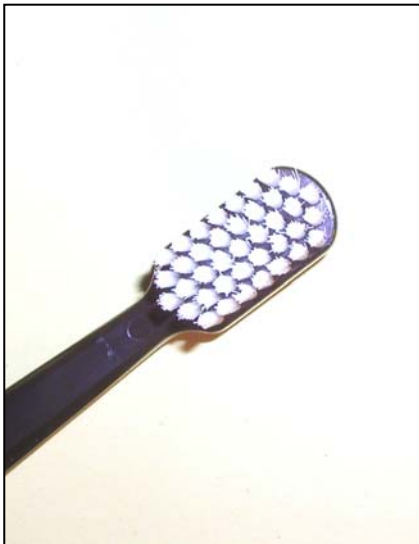

Periodontitis

- Chronic adult periodontitis
- Aggressive periodontitis
- Early onset periodontitis

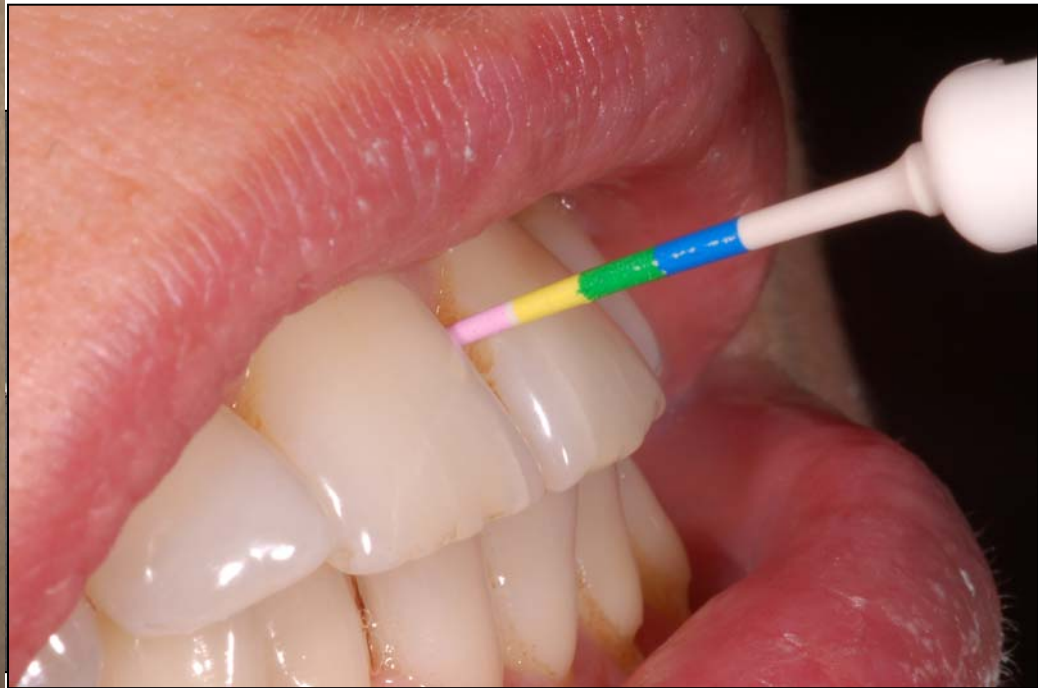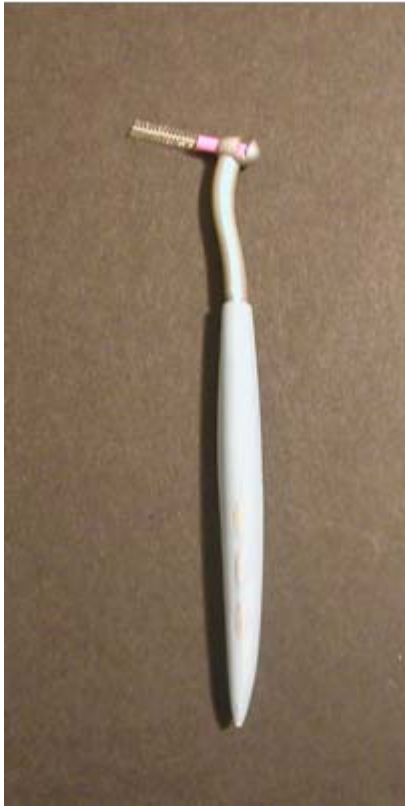Therapy

- 1. Oral hygiene - professional, home care
INDIVIDUAL



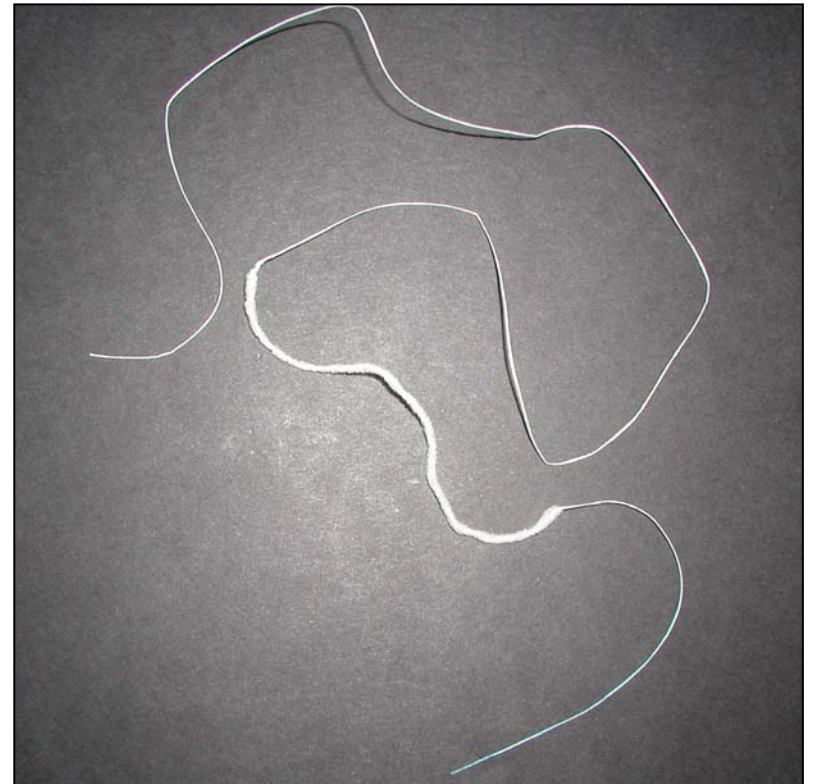

Therapy

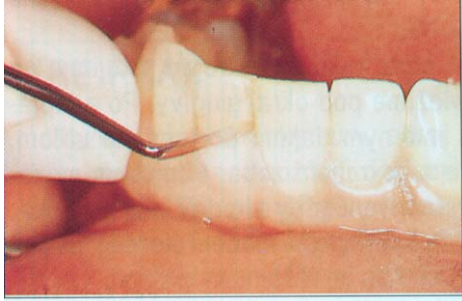- 1. Oral hygiene - professional, home care
INDIVIDUAL



Therapy

- 1. Oral hygiene - professional, home care
INDIVIDUAL

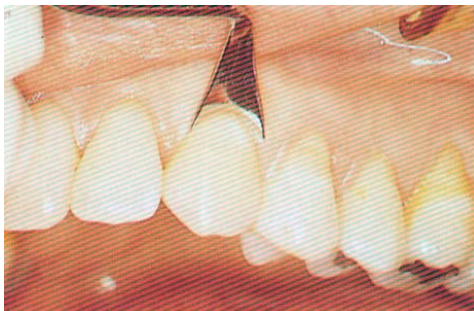
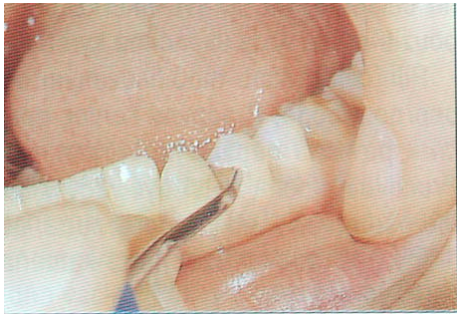
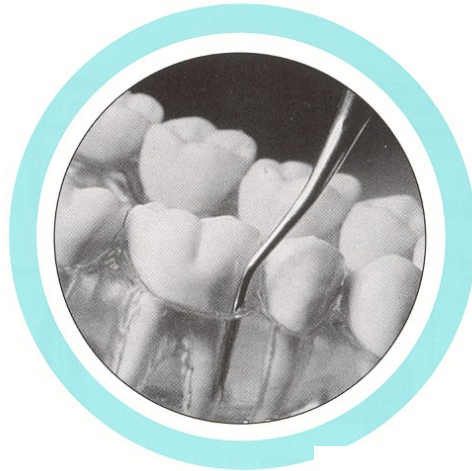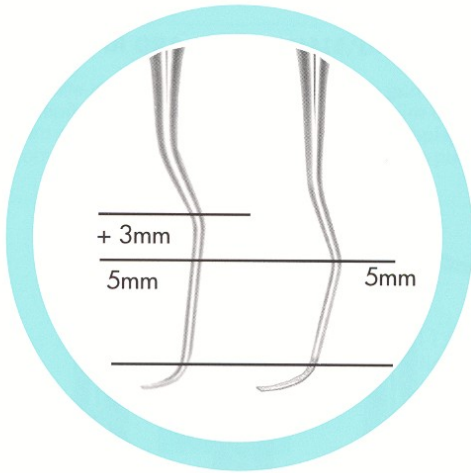
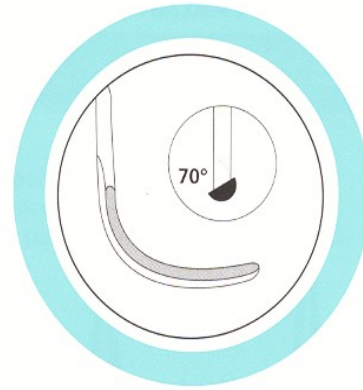
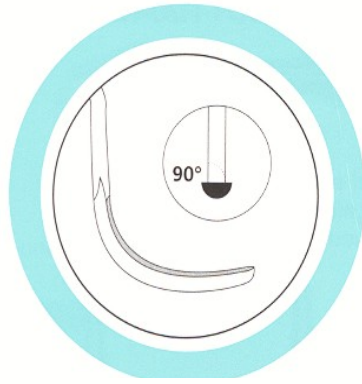


Removal of dental calculus –

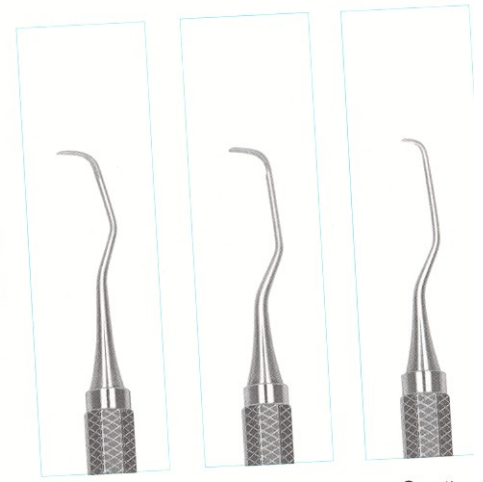
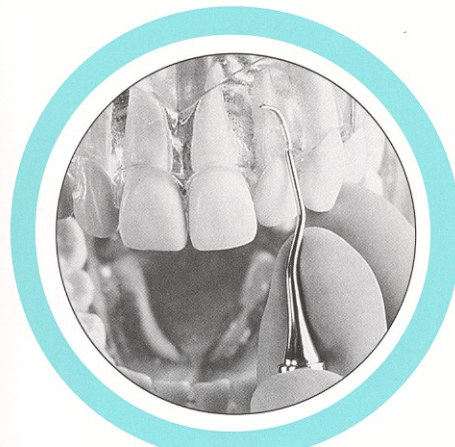
Instruments are pointed, sharp

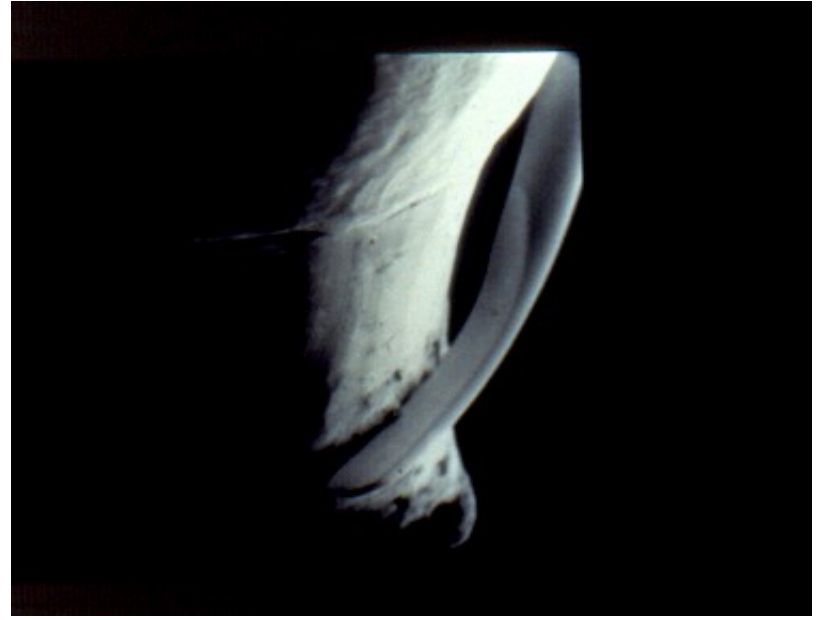
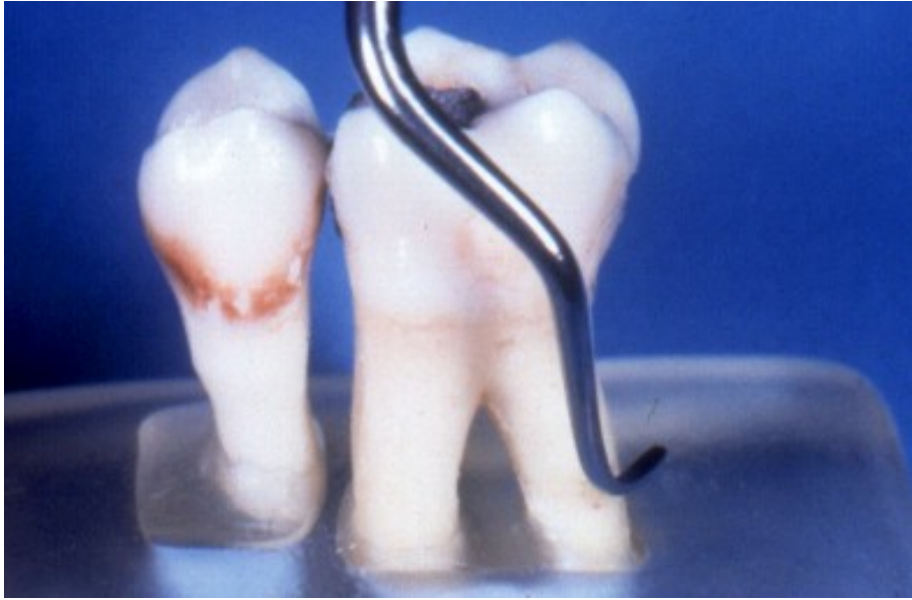= scalers



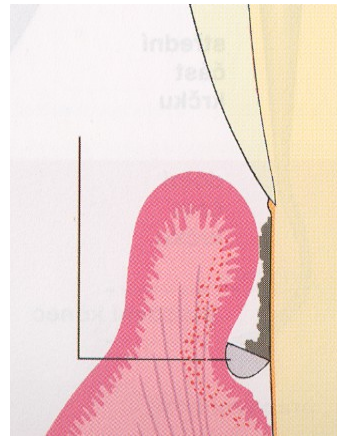
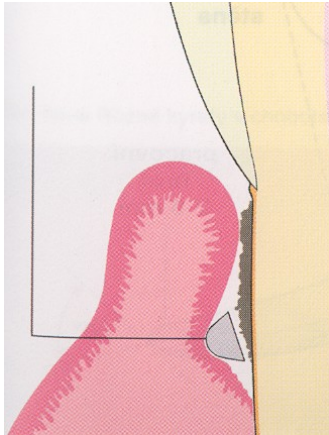


Curettes



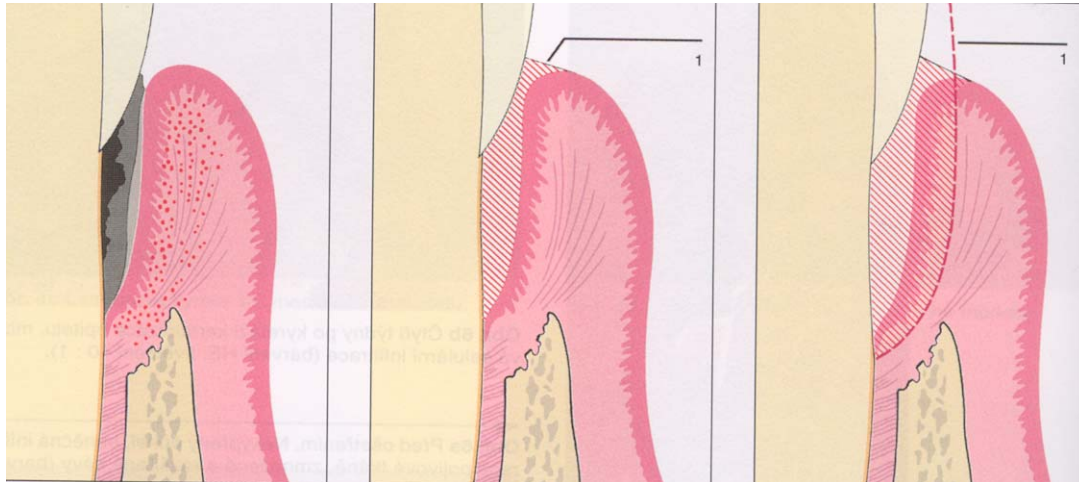
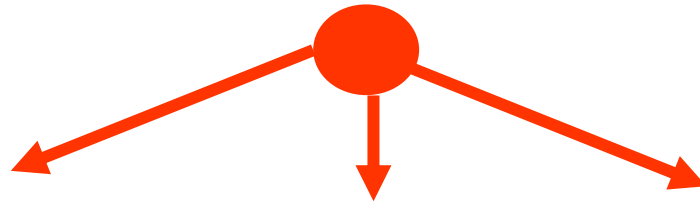


Scaling, root planing



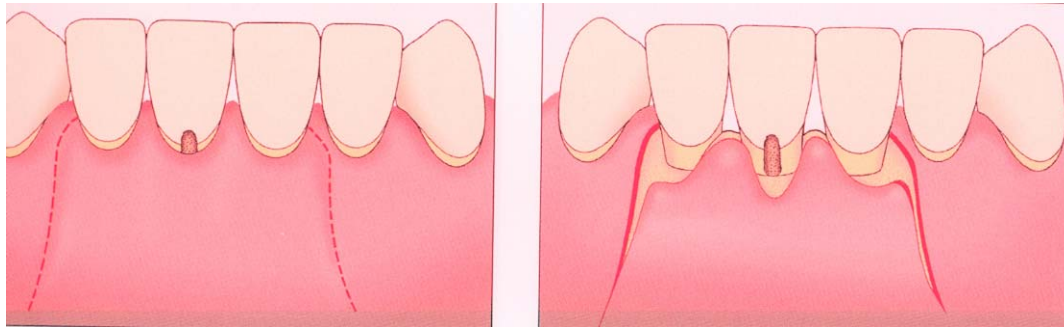
Therapy

- 2. Subgingival treatment – scaling root planing, curettage



Therapy

- 3. Periodontal surgery

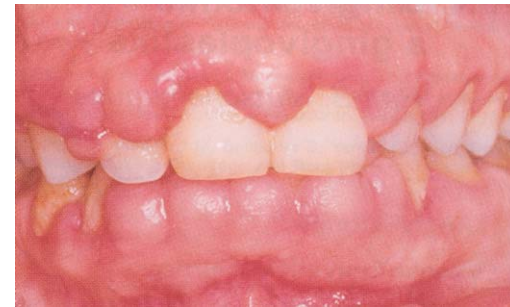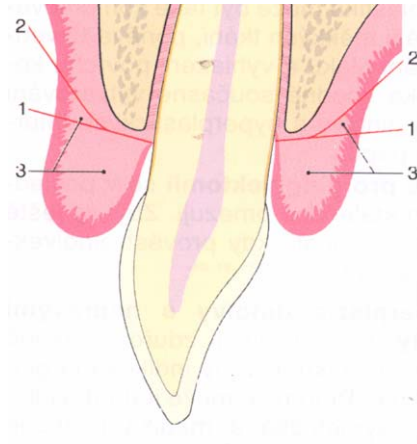


Gingivectomy, gingivoplastic

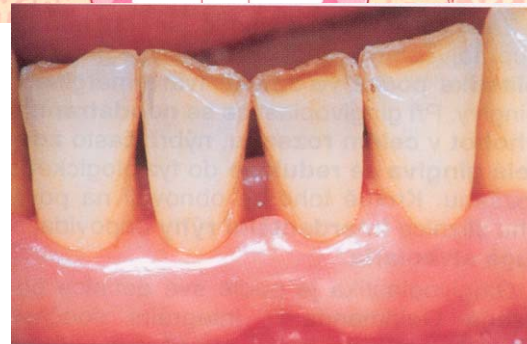
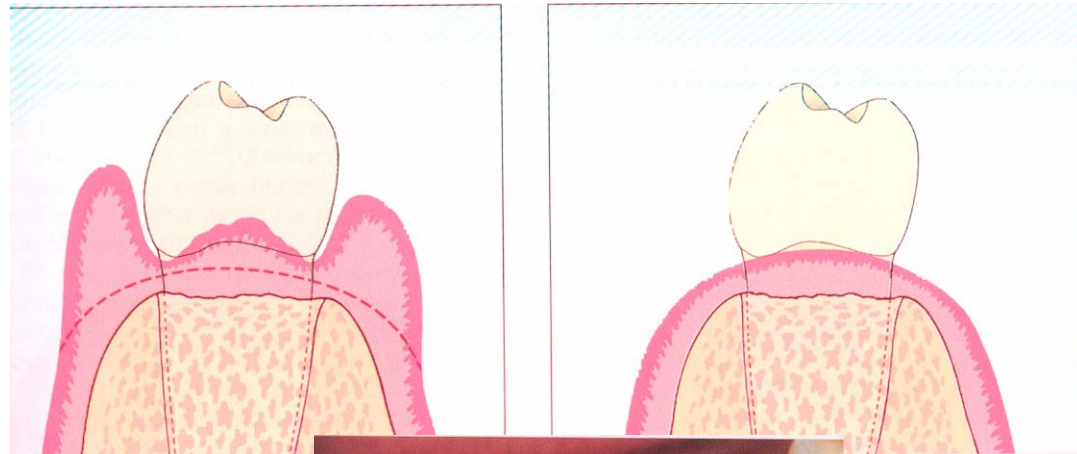
Indications of gingivectomy

- Hyperplasia gingivae (pseudopockets)
- Supraalveolar periodontal pockets with the horizontal bone resorption
- Bad configuration of the gingival margin or papilla.

Gingivectomy

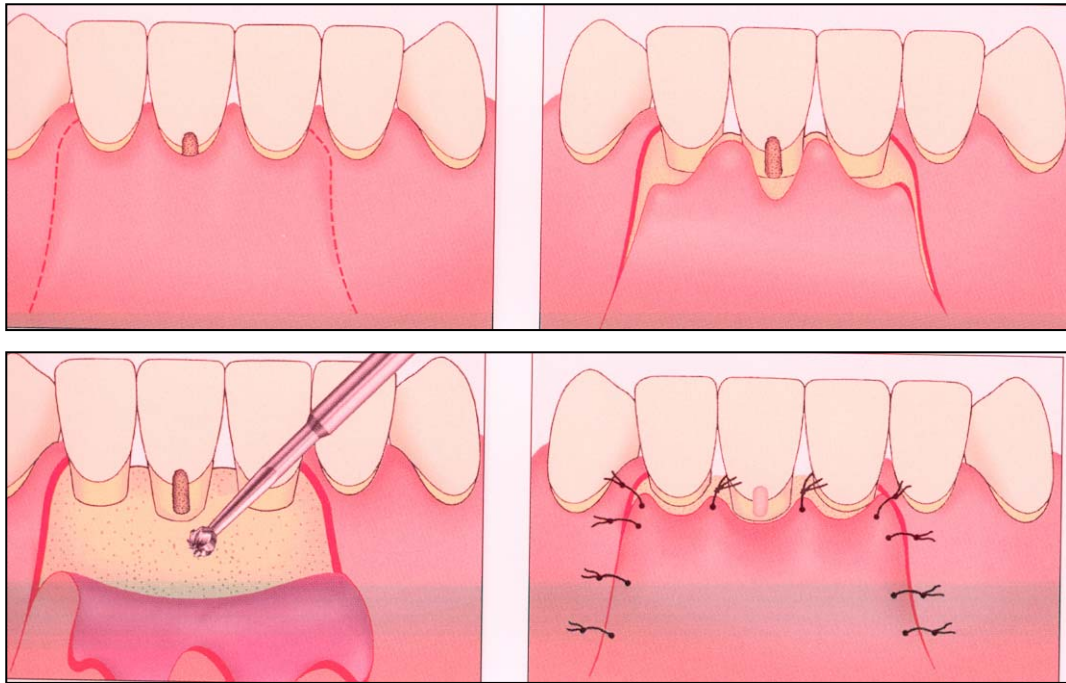


Gingivoplastic



Flap operations – principle

Raising of the flap – removal of pathological changed tissues, flap back.



Mucogingival surgery

□ Enlargement of attached gingiva

- Frenulectomy
- Vestibuloplastic

□ Plastic of recessus

- Lateral flap
- Bridge flap
- Mucous or mesenchymal grafts



