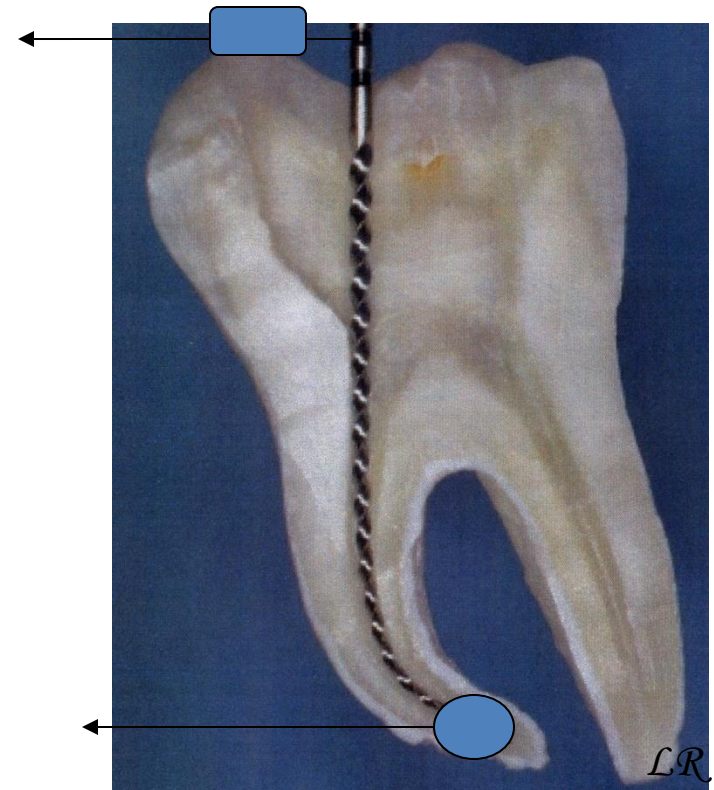


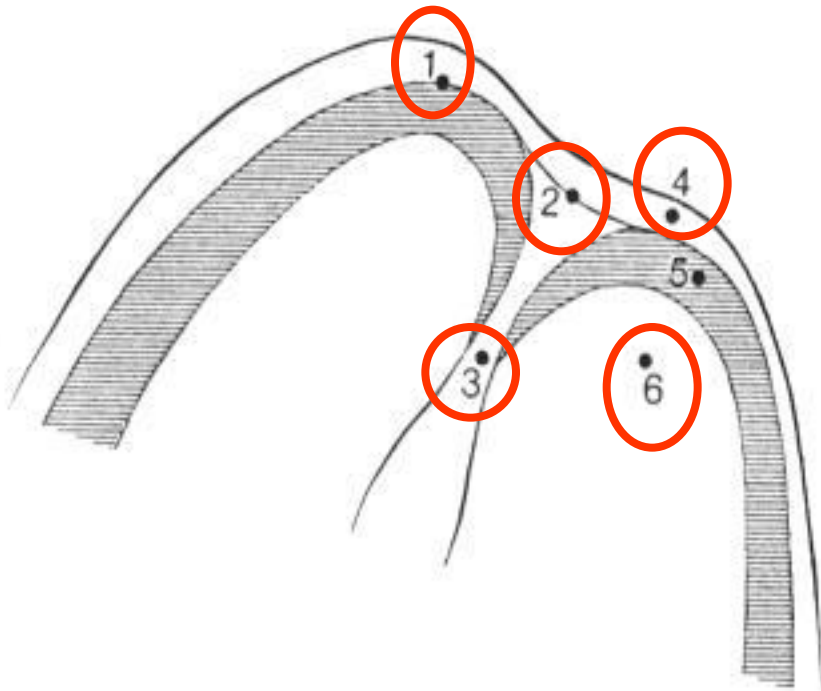
Working length

Working length

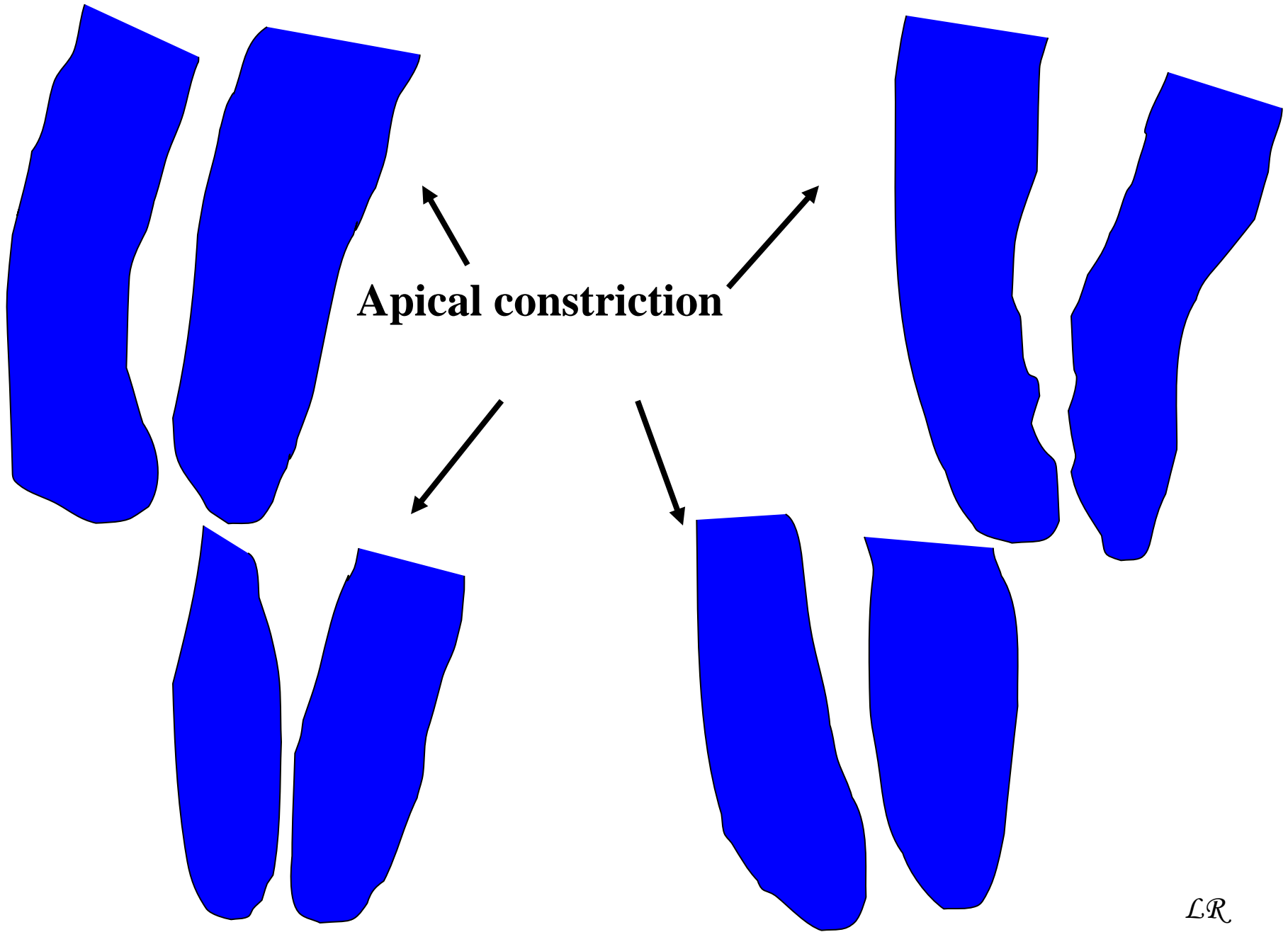
- Distance between referential point on tooth crown and apical constriction



Apical morphology

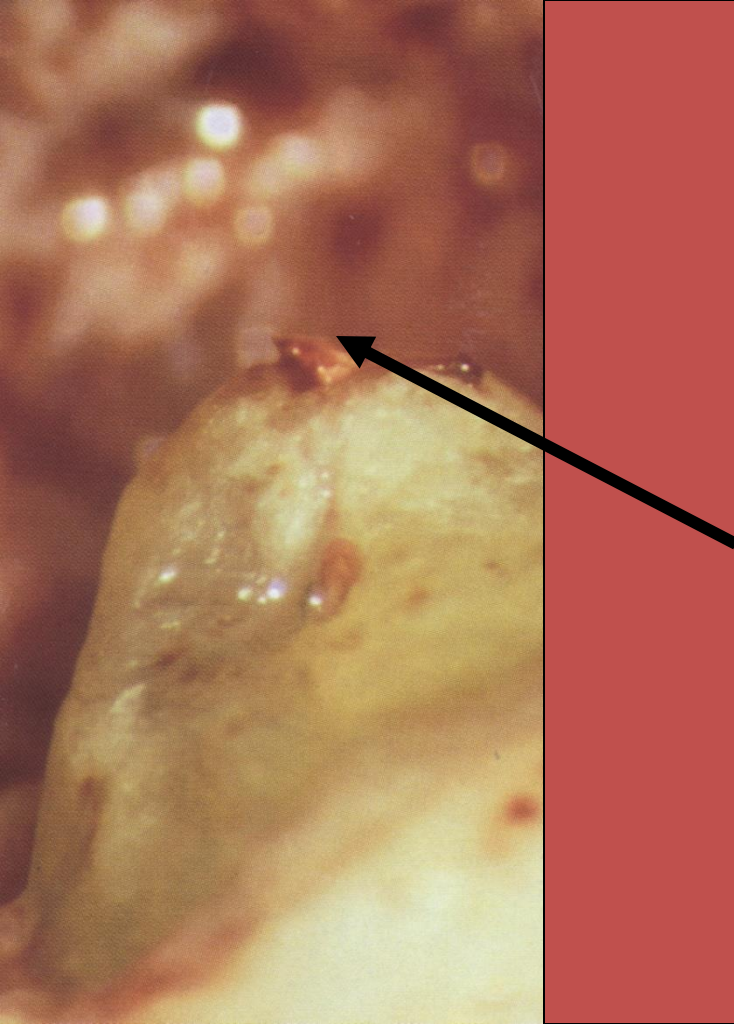


1. X-ray apex
2. Apical foramen
3. Apical constriction
4. Periodontal ligament
5. Root cementum
6. Dentin



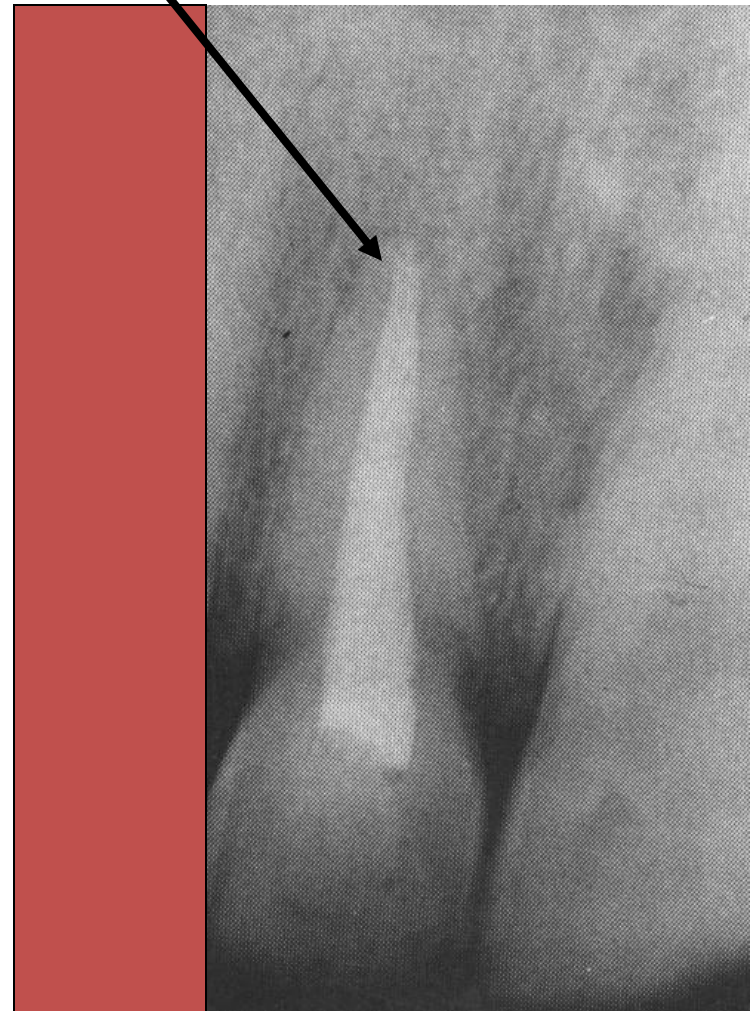
Why RTC terminates in apical constriction?

- Small apical communication
- Less risk of damage pof periodontium
- Prevention of overfilling
- Prevention of apical transport of infected metarial
- Possibility of good removal of debris
- Good compaction of guttapercha




Skutečnost

X-ray apex

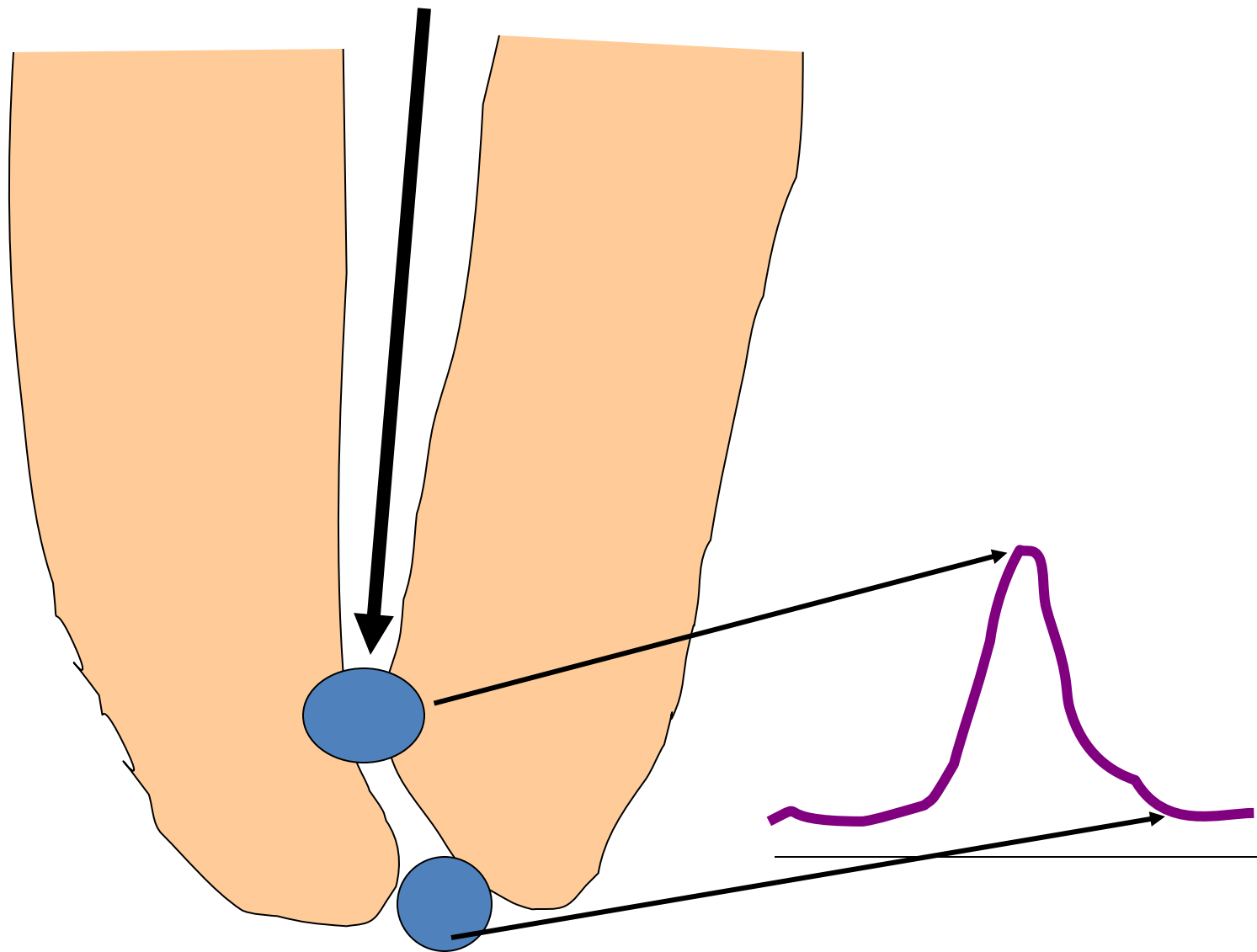


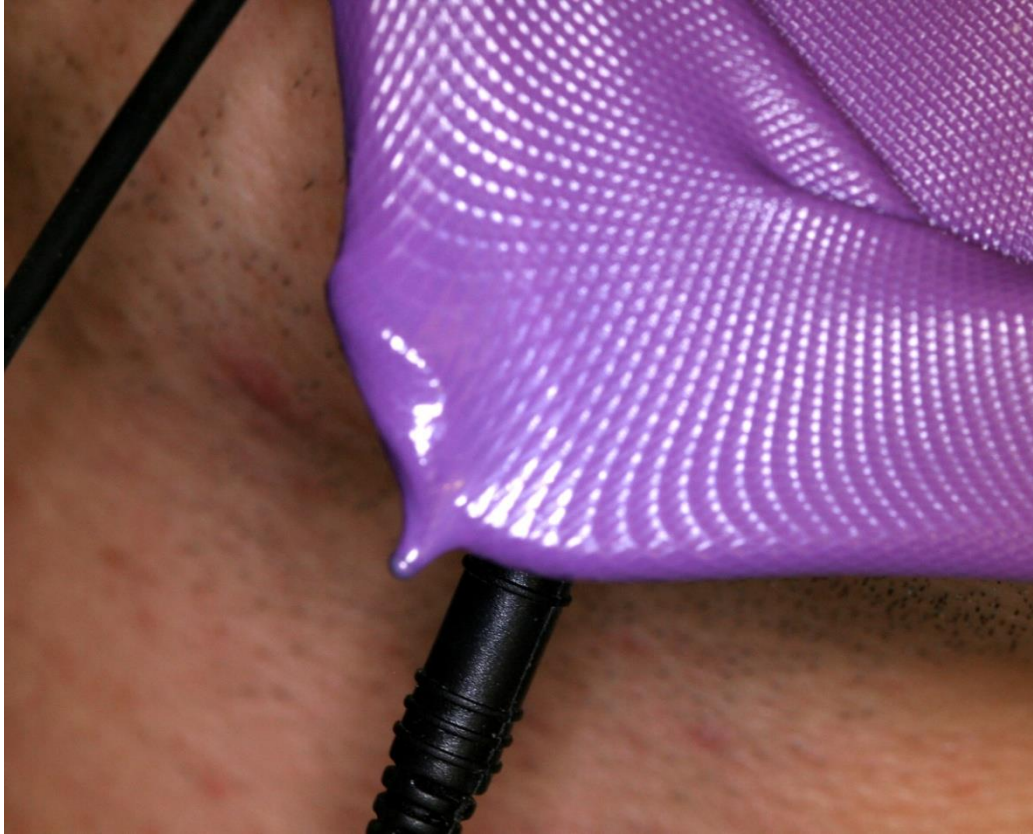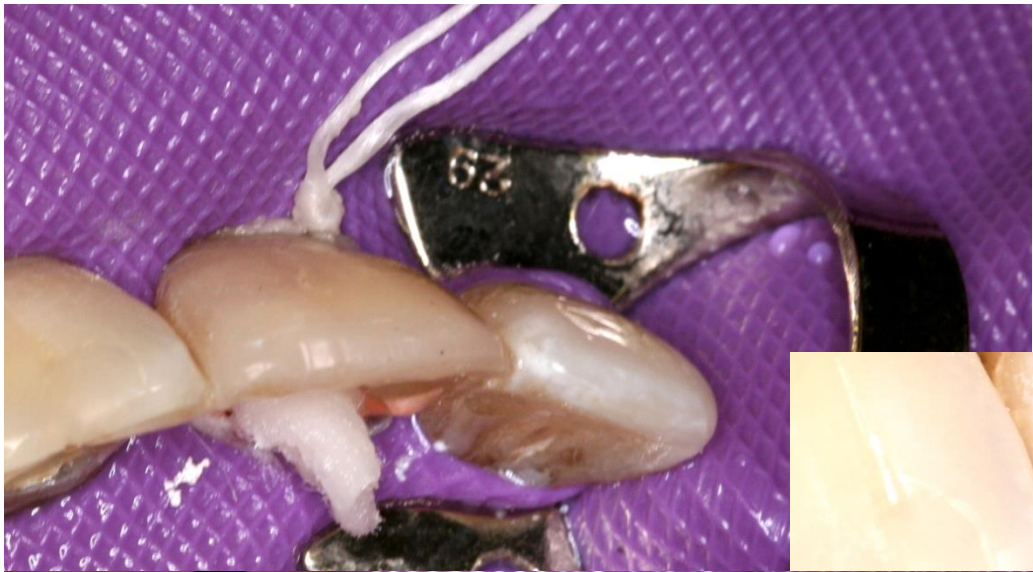
Principle of apexlocators

- Endometrie



measurement of impedance





X- ray method

X-ray with root canal instrument (ISO 15 no smaller because of x ray contrast)

Introduced to the safe length – this length have been measured on many teeth, we know this length for each tooth)

Take x- ray using the rubber stop at the referential point.

If there difference no more than 2 mm we can measure the working length, if more – new x ray with instrument thai is introduced deeper.

