

Radiography

Radiography

- Roentgen tube – x- ray tube:

Cathode – Anode – Tension

Catode (heated) - Electrons – go against
Anode – brake - x ray originates



Radiography

- Imaging method completing clinical examination of patients

Radiography

Principle:


X- rays going through various materials
(tissues) are absorbed – image on the film
(a special suspension AgBr – silver bromide)

Roentgen tube X ray tube

Cathode
wolfram
(tungsten) filament inside
(heated – brought to white heat)

Focus – made of wolfram

Anode



Extraoral and intraoral radiography

- Extraoral:

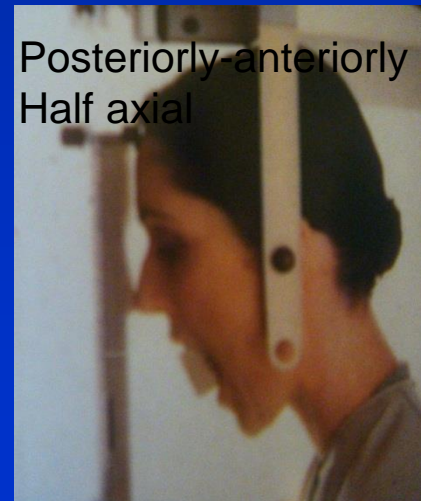
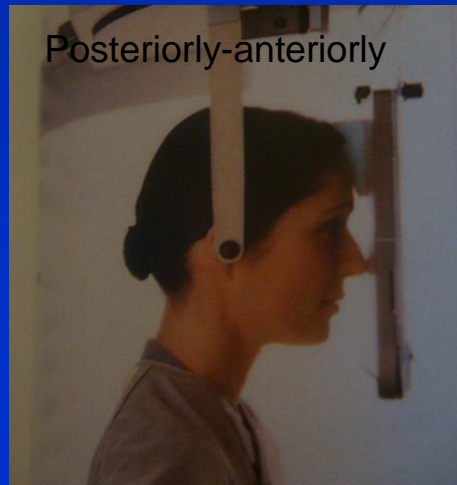

The film is placed outside of oral cavity

- OPG (orthopantomography)
- Teleradiography
- Special projections of a skull (posteriorly – anteriorly)
- Half axial
- Side projection (TMJ, mandible)
- CT

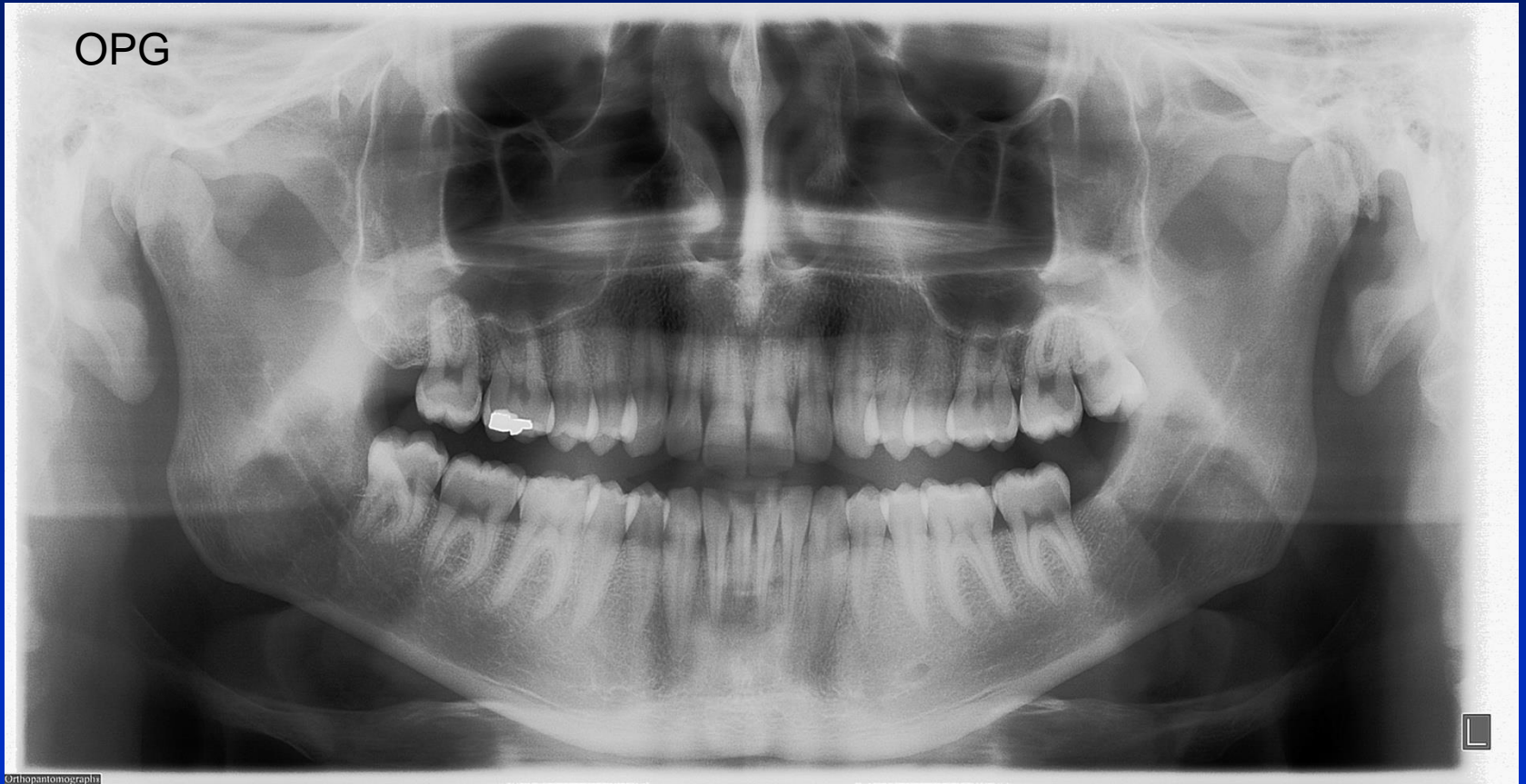Extraoral and intraoral radiography

Intraoral – the film is placed into the oral
Cavity – a special x-ray apparatus.

- Teeth
- Alveolar bone
- Periodontal space
- Fillings
- Caries
- Level of endodontic treatment



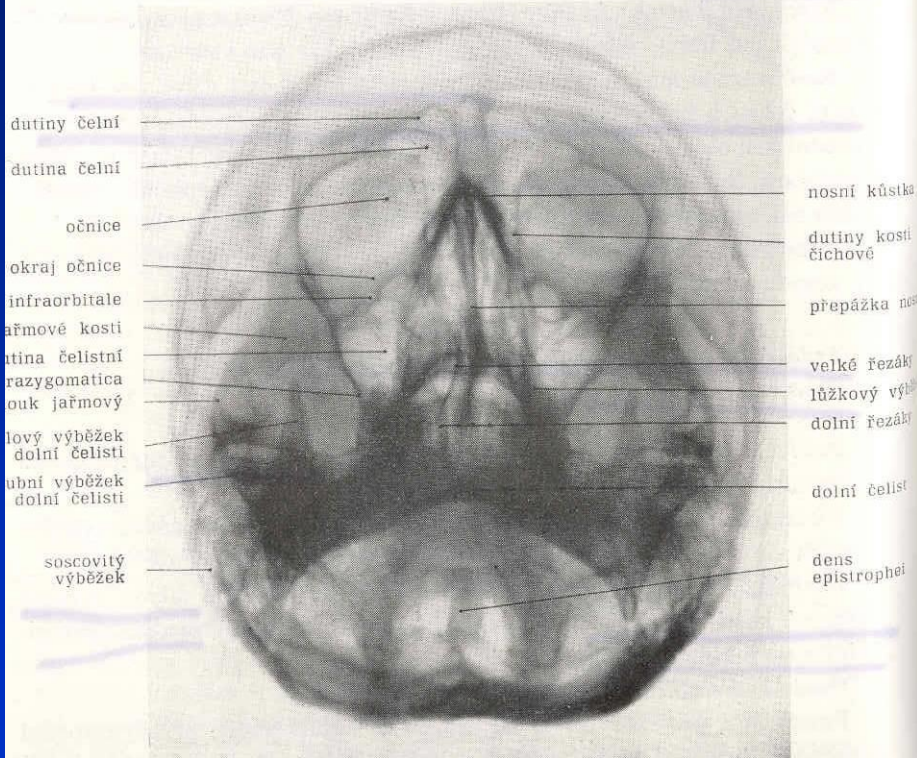
OPG



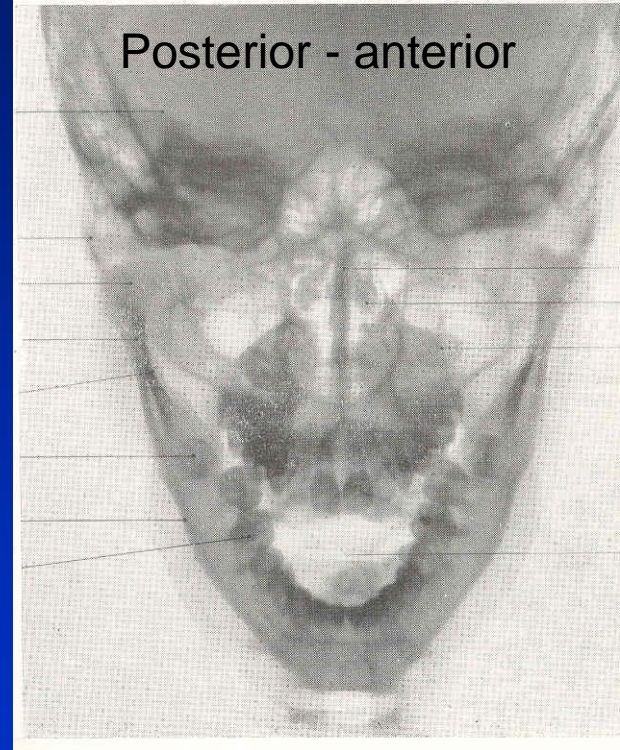
pohled zprůdu

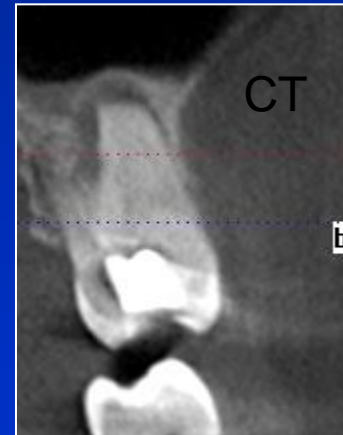
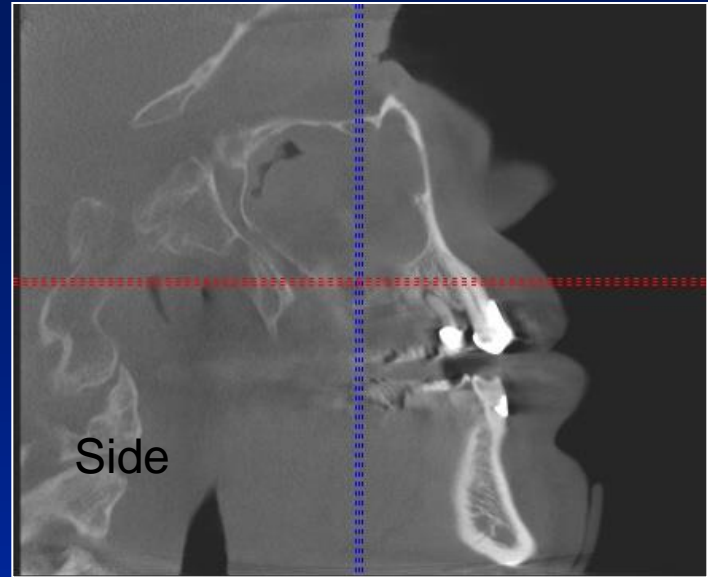
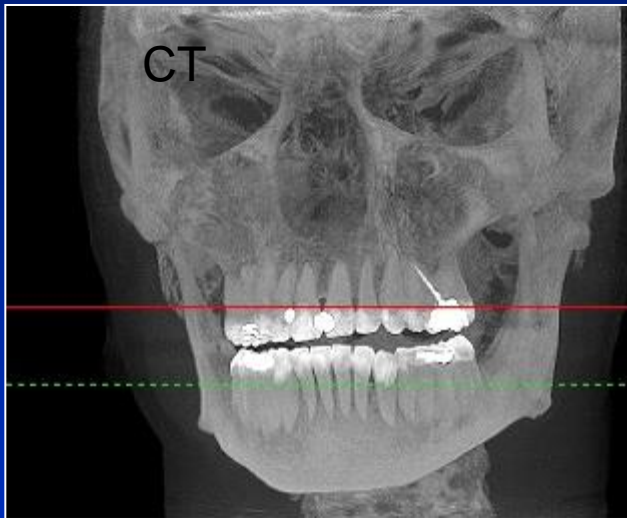
pohled z boku

Half axial



Posterior - anterior



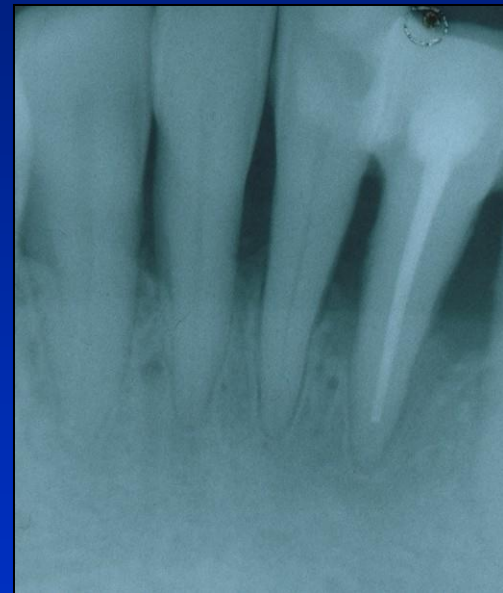


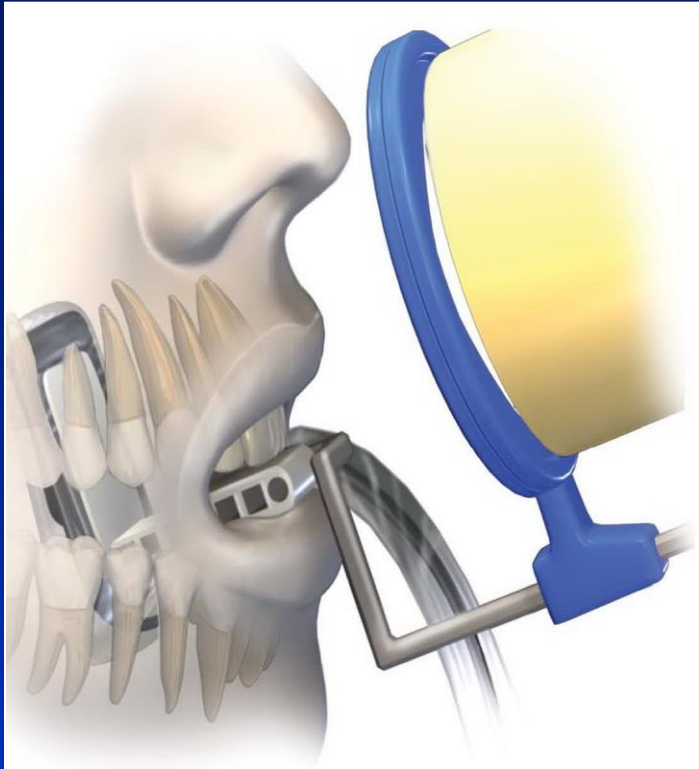
Intraoral radiography

Film or sensor placed in oral cavity

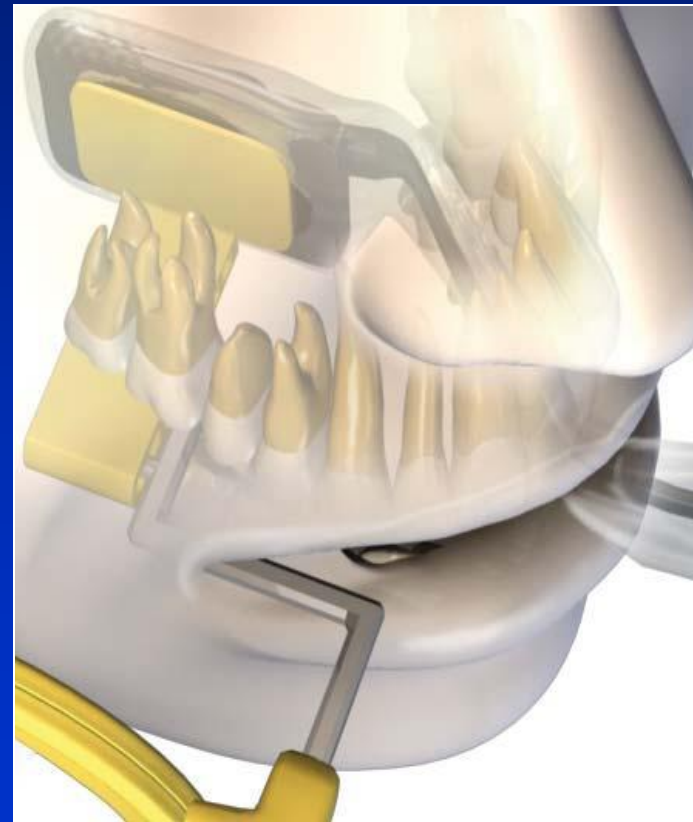Special apparatus

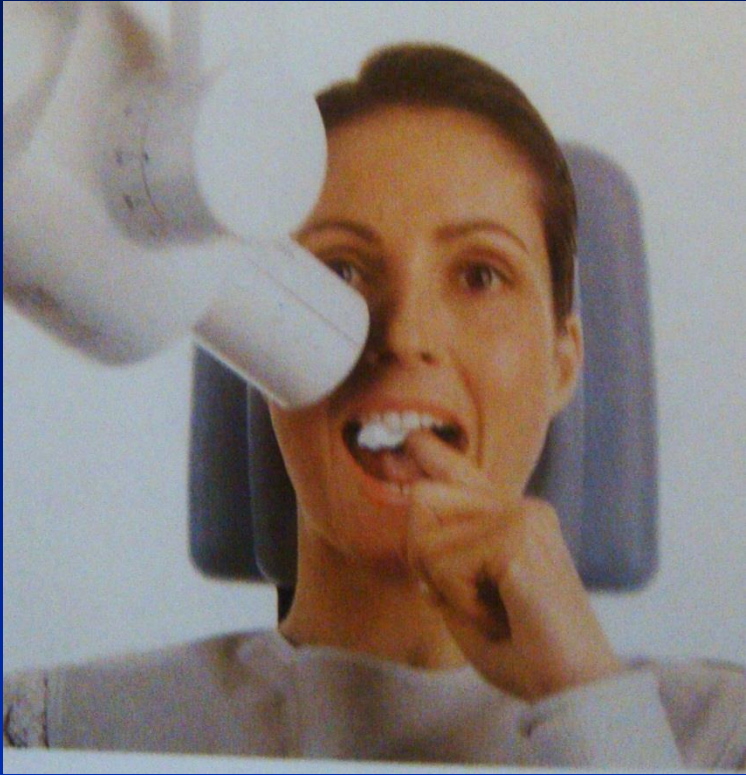
- Teeth
- Alveolar bone
- Periodontal space
- Fillings
- Caries
- Impacted teeth
- Level of endodontic treatment



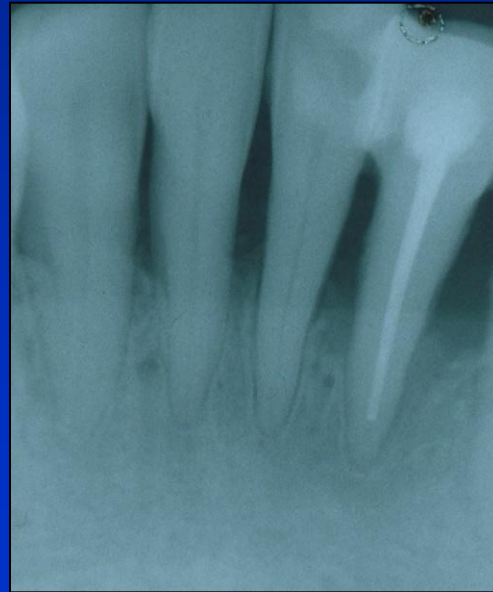


Parallel technique
Film or sensor in a special holder
Parallel to long axis of teeth

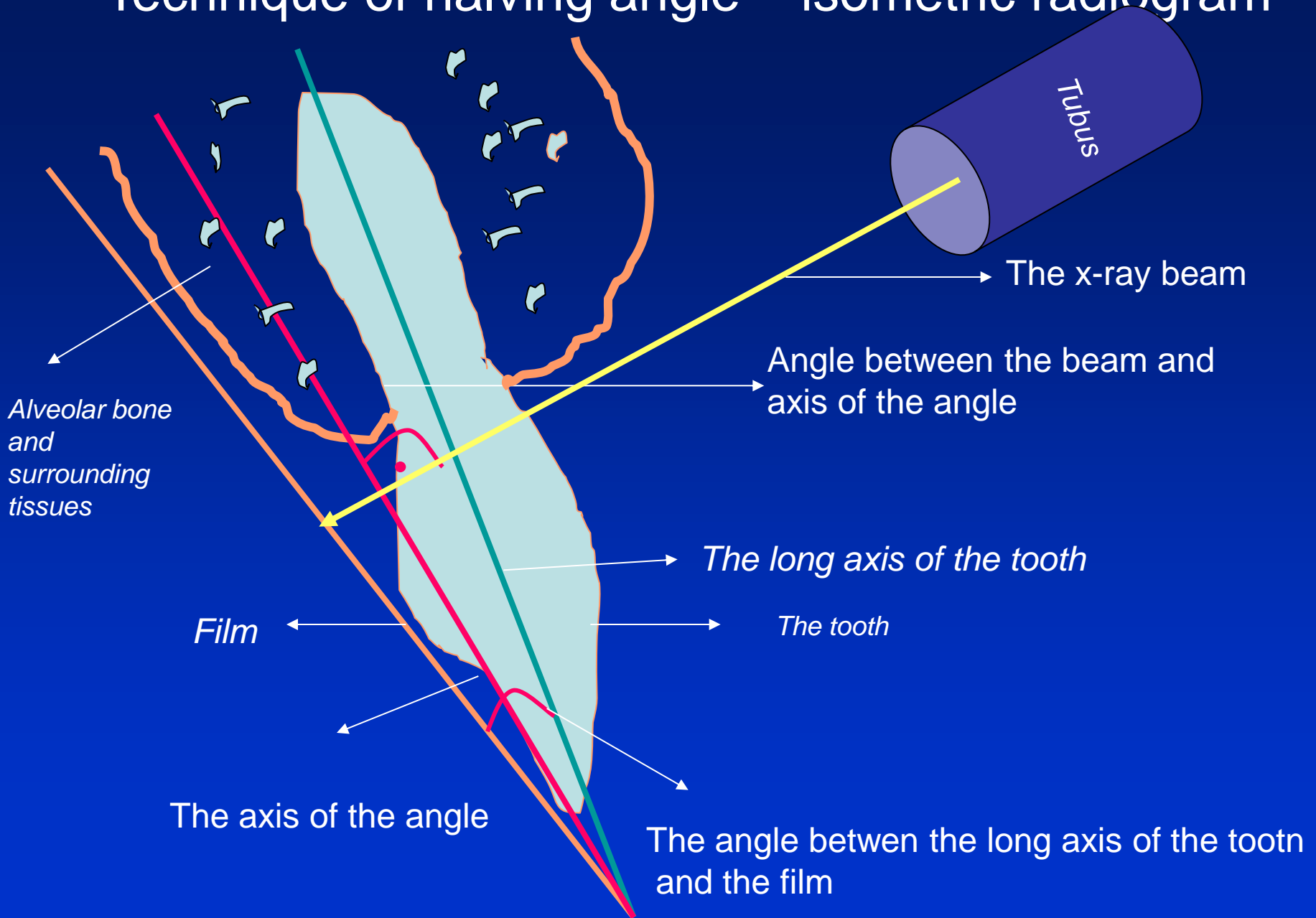




Technique of isometric
and orthoradial radiogram



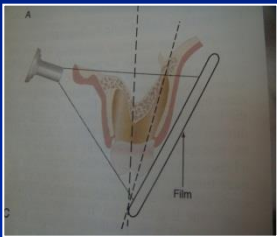
Technique of halving angle – isometric radiogram



Hypometric and hypermetric picture

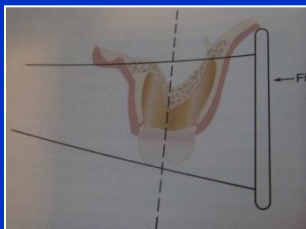
Hypometric – the picture is smaller

Central beam goes perpendicular on the tooth



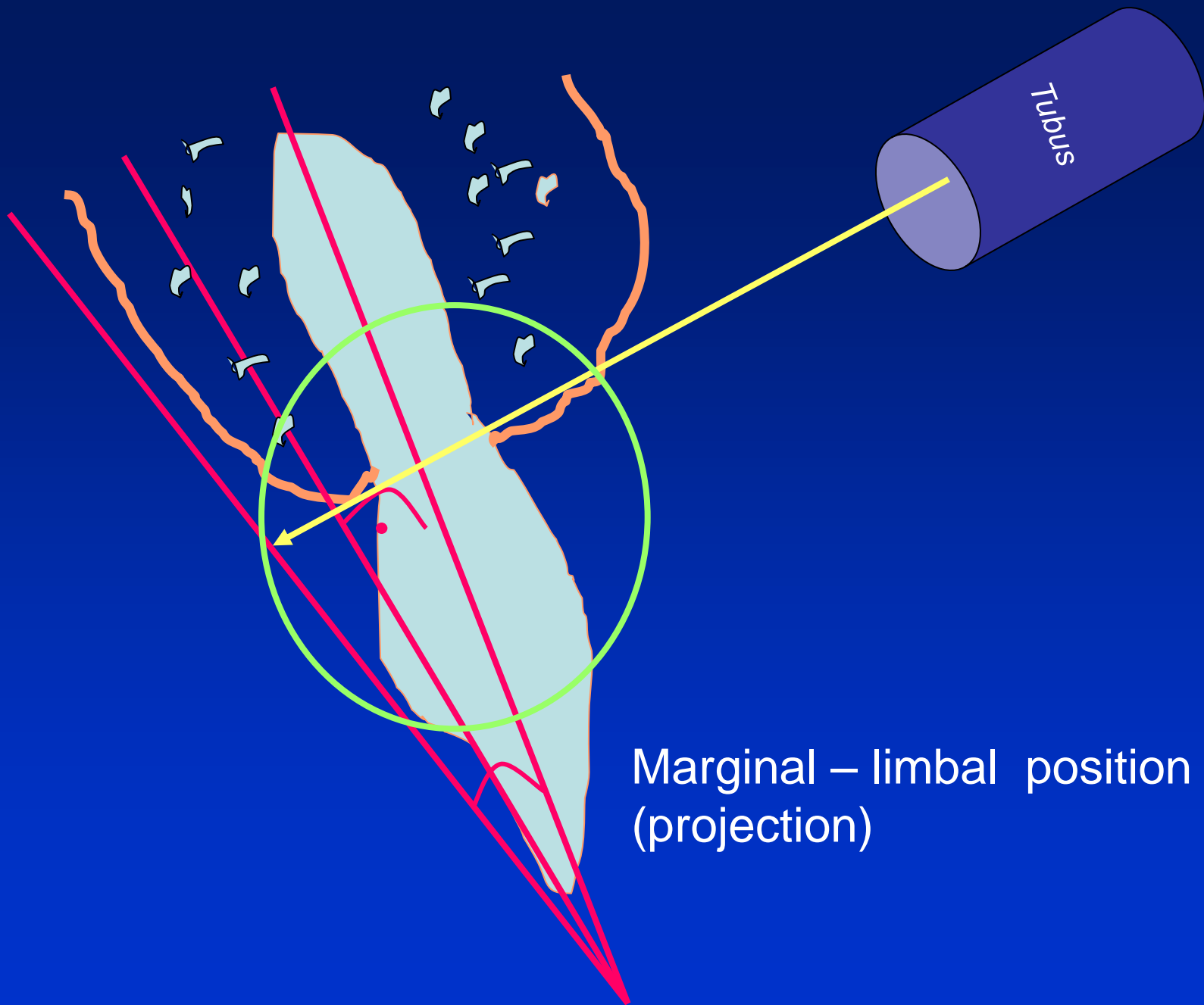
Hypermetric picture – the picture is bigger

– central beam goes perpendicular to the film paprsek jde kolmo na film.

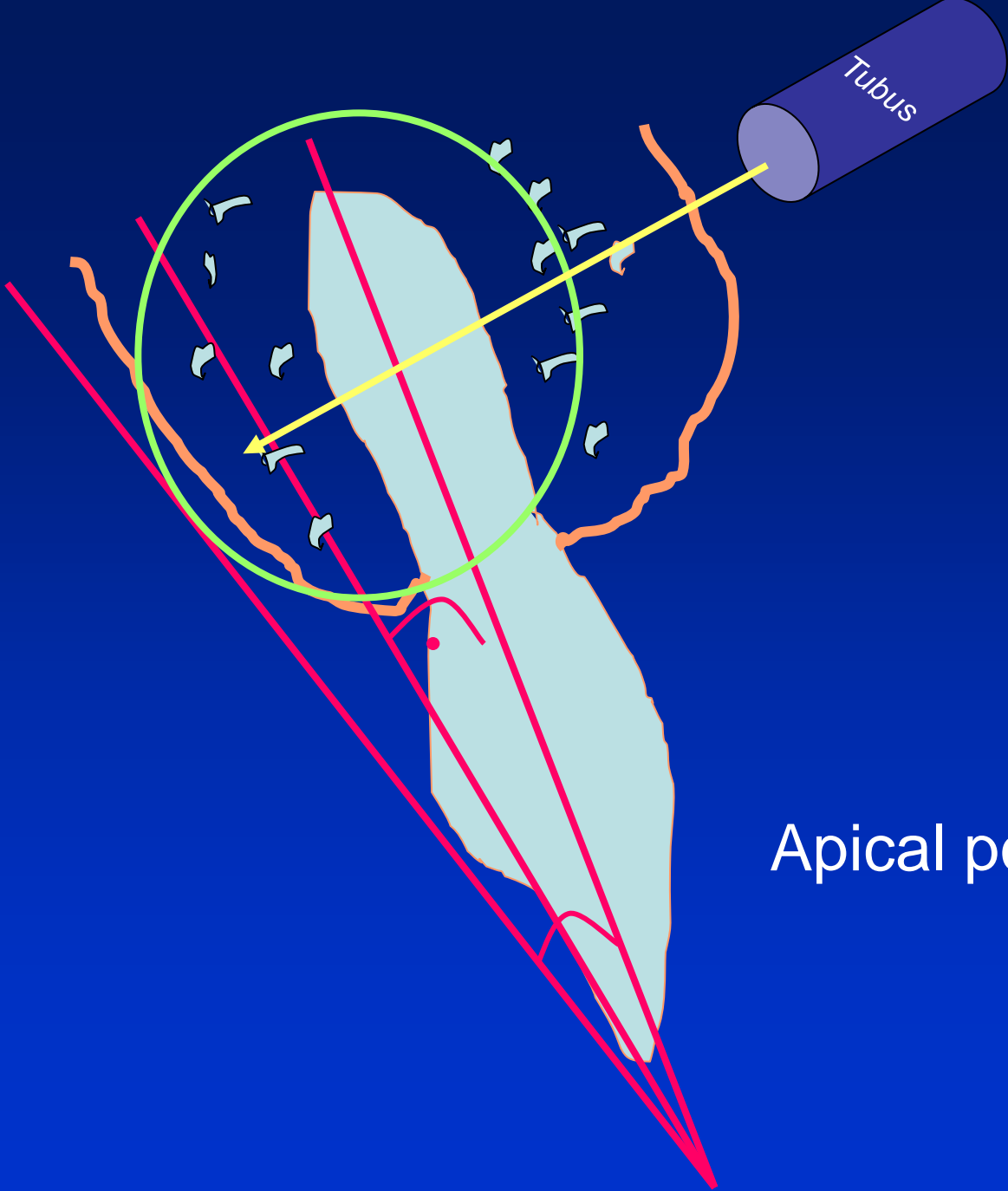


The tubus can have vairous position

- Apical projection: the central beam goes through the apex area
- Periodontal projection: the central beam goes through the uper third of the root
- Coronal projection: the central beam goes through the crown.



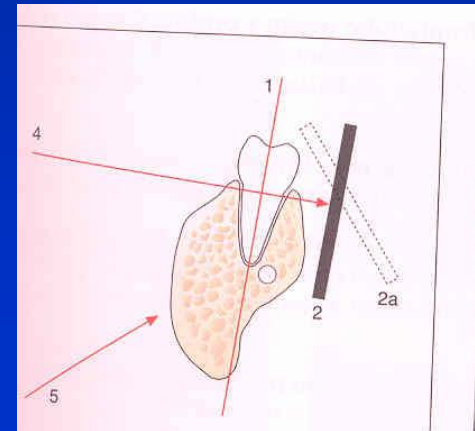
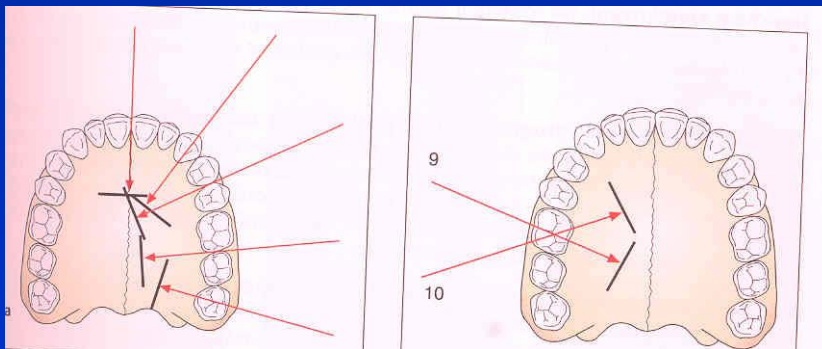
Marginal – limbal position
(projection)



Apical position - projection

Orthoradial and excentric projektion

- Orthoradial – the central beam goes parallel to interdental septa
- Excentric– the central beam goes from distal or mesial side.



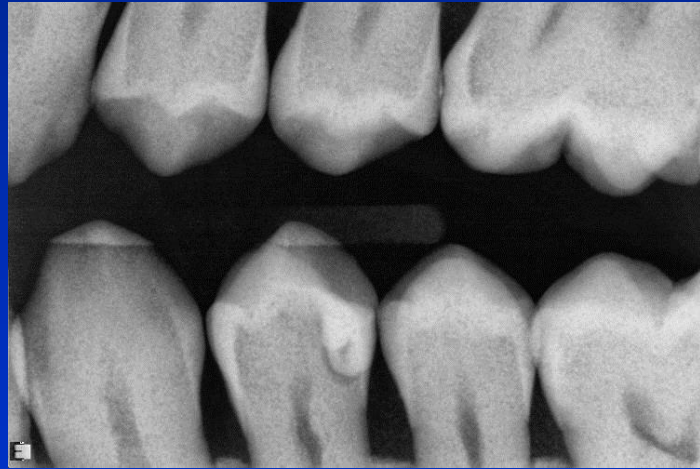
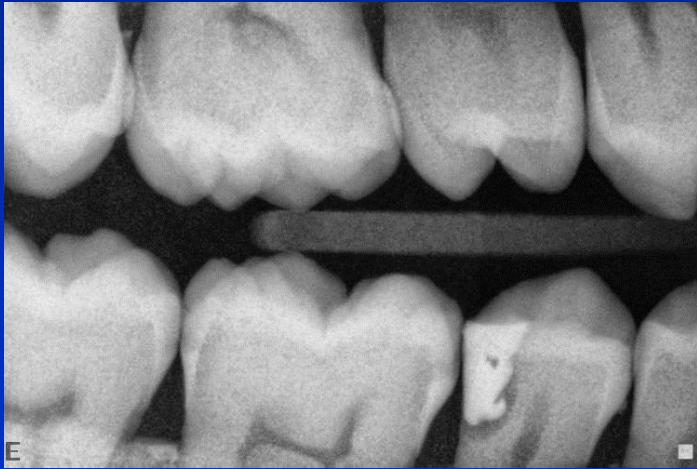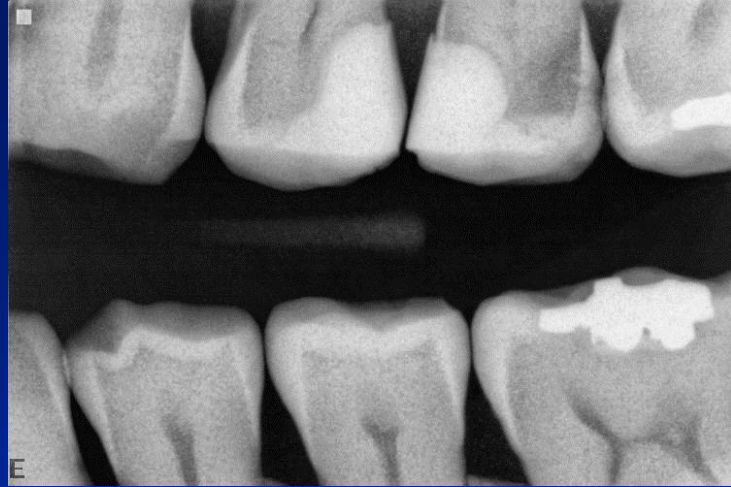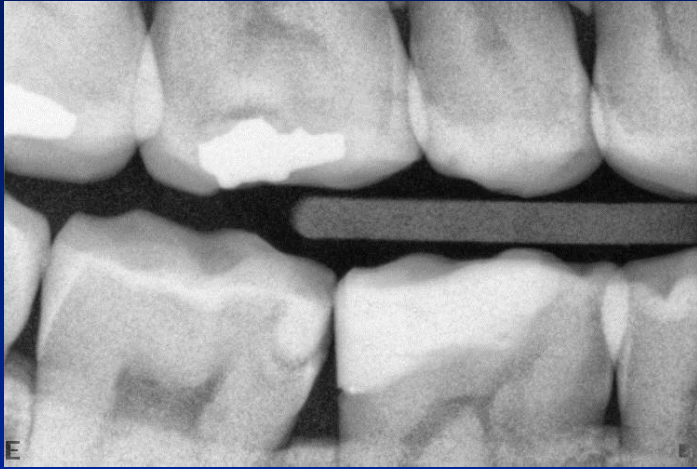Bitewing

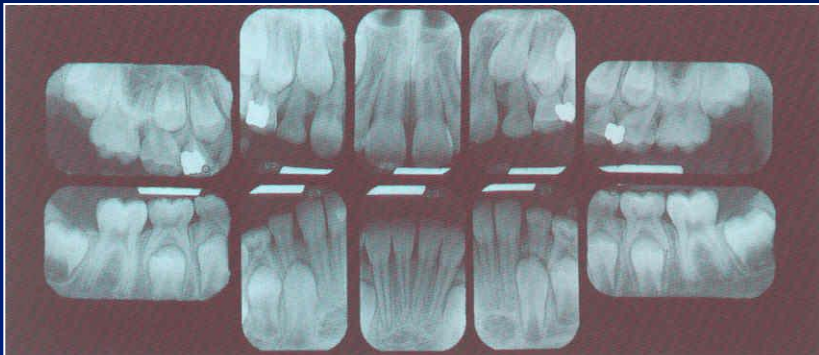


Film or sensor is in a special holder,
patient bites into

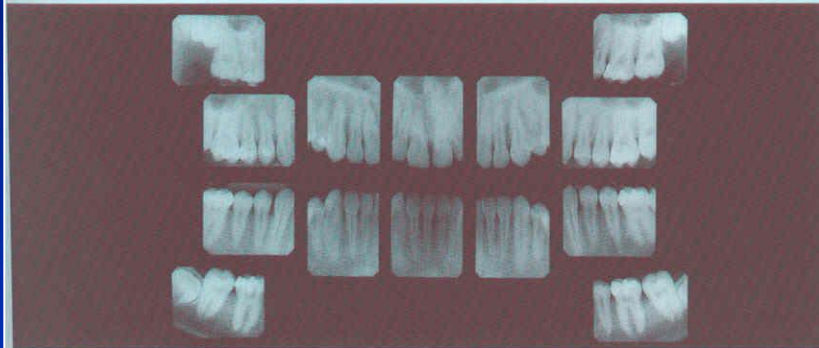
The central beam goes parallel to
interdental septa

Crowns of teeth are well seen – good for
early diagnosis of dental caries

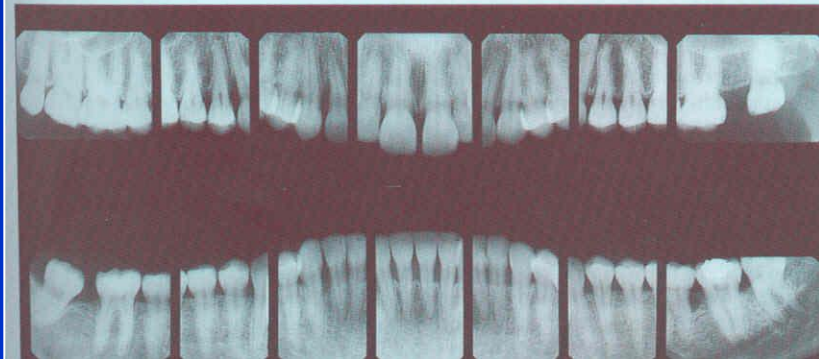



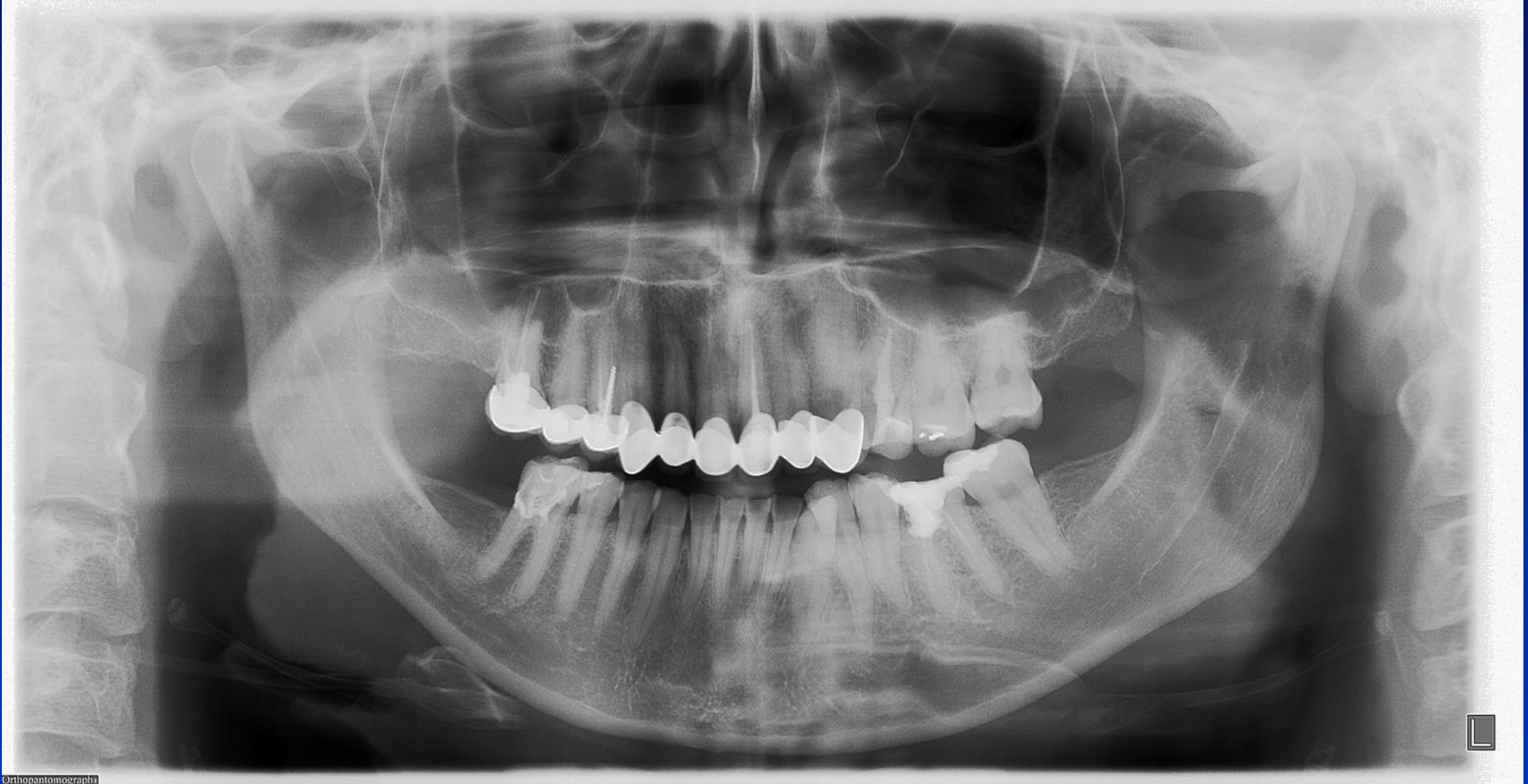58



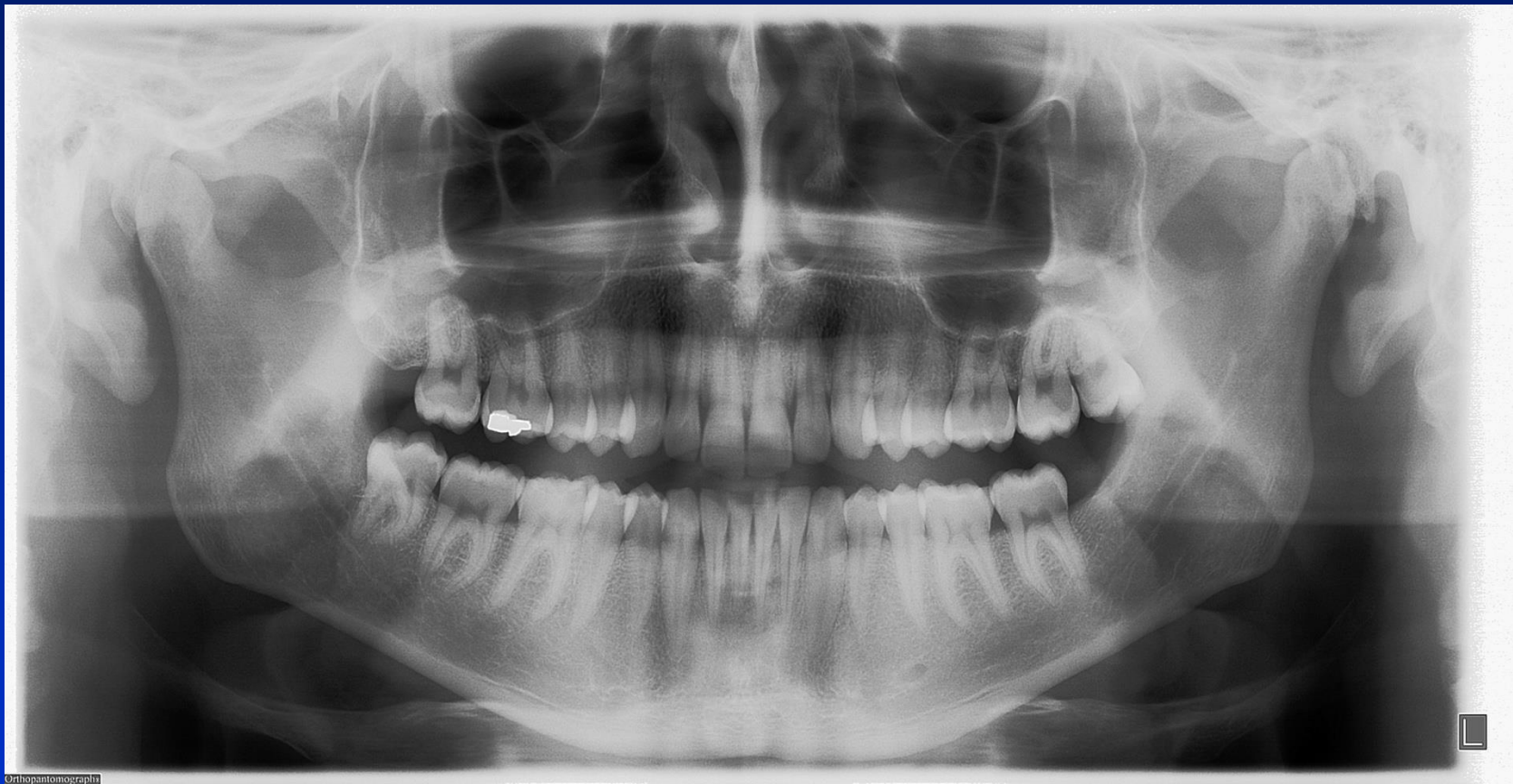59



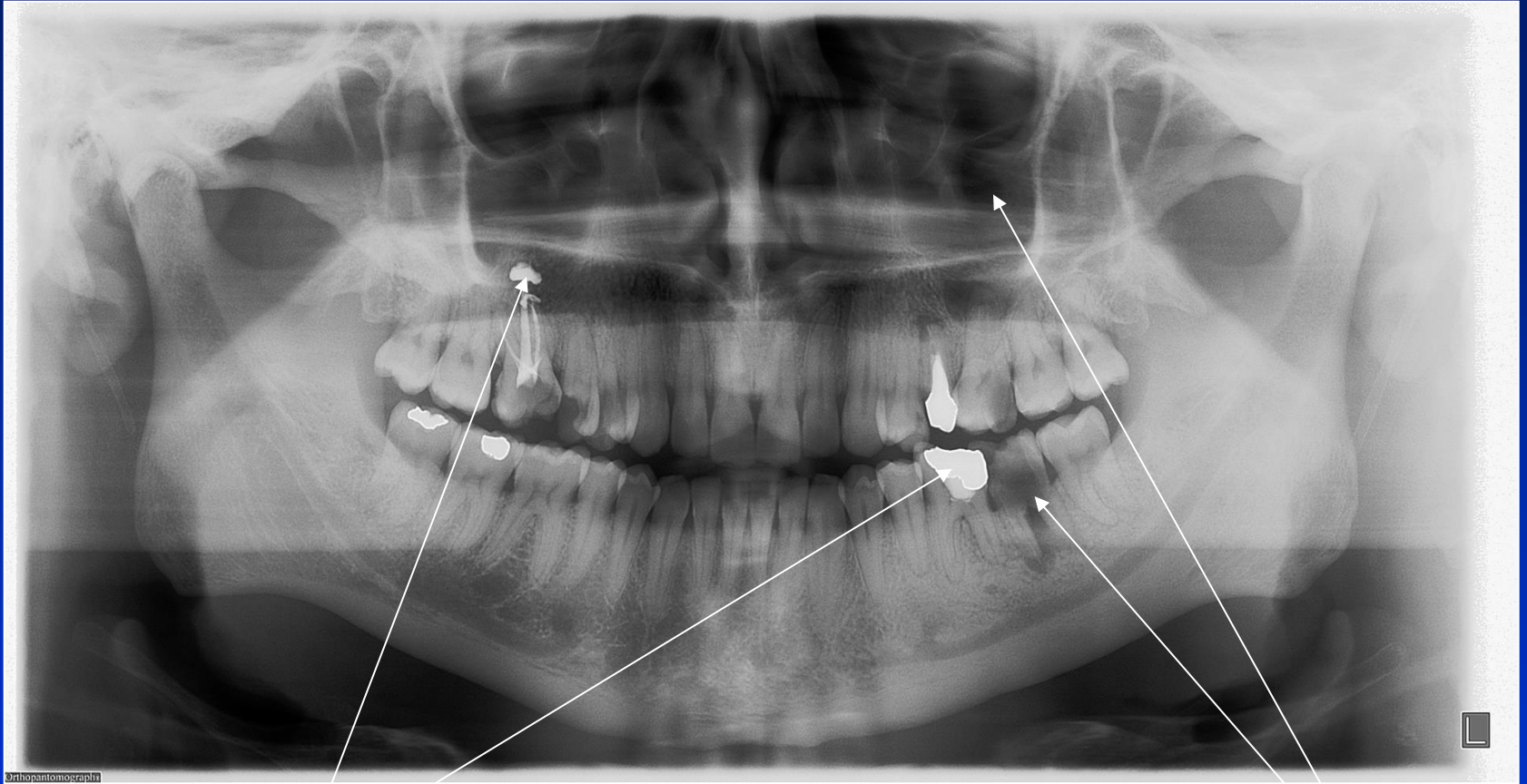
- Rtg status



OPG



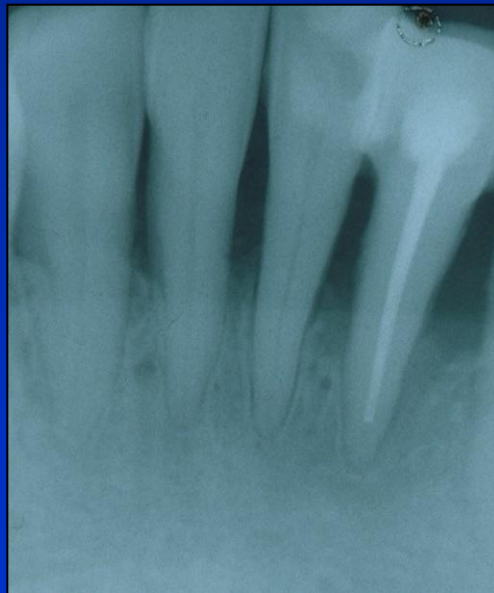
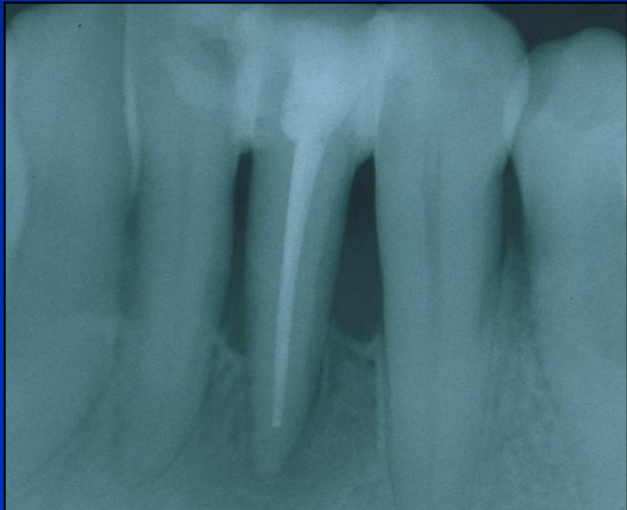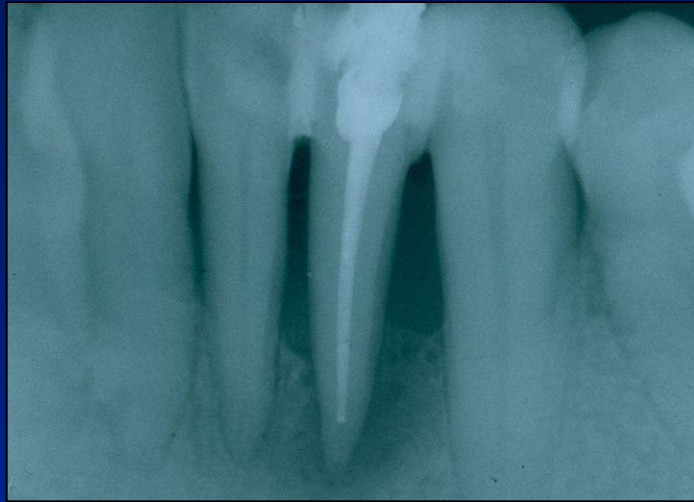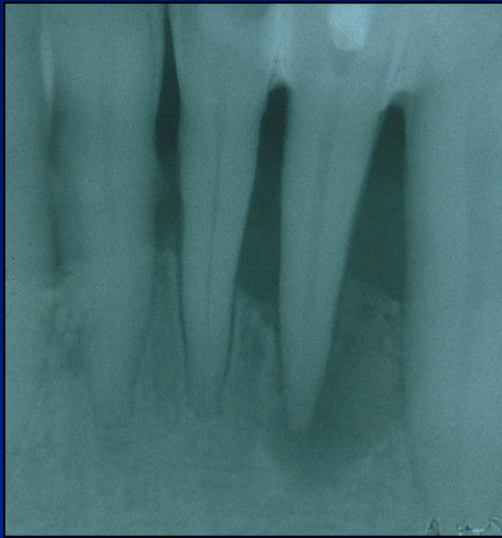Orthopantomograph



Orthopantomograph

radioopacity

radiolucency



i.o.



