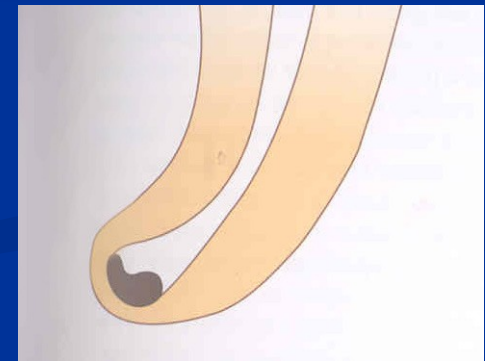
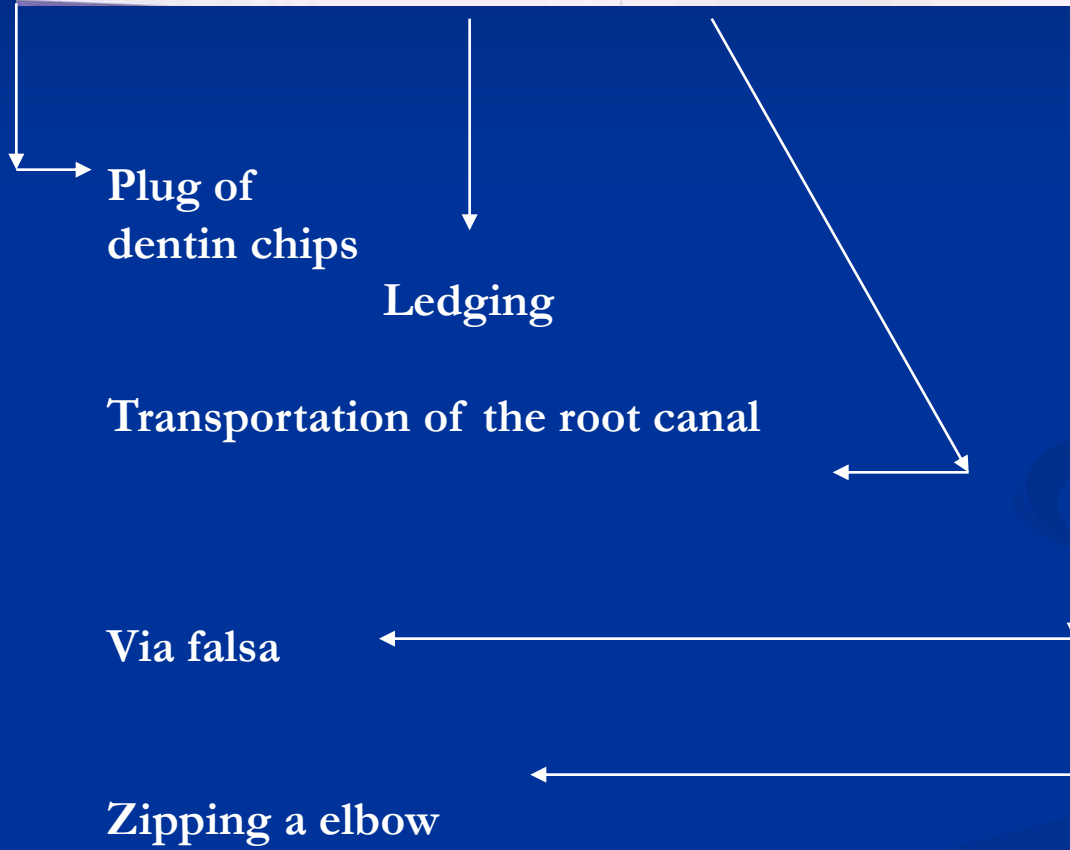
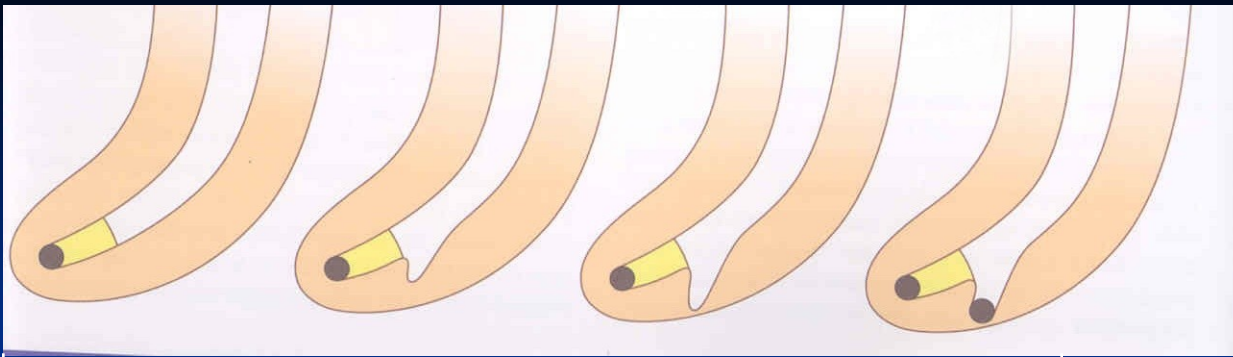


# Complications of endodontic treatment

**Local**

**Regional**

**Systemic**



# Local complications

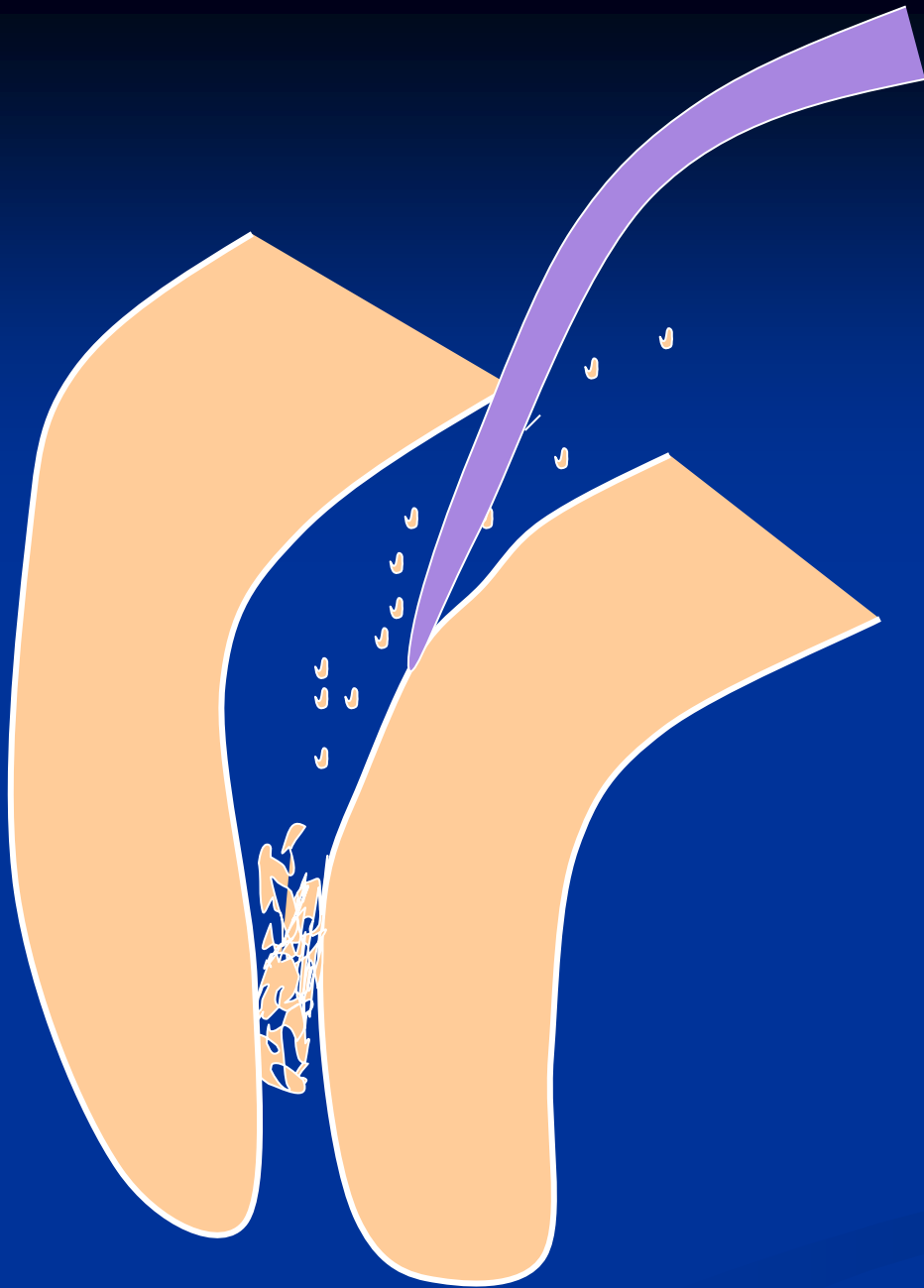
# Plug



## Reasons

**Insufficient irrigation and  
recapitulation**

*Loss of the working length*



## Solution

Repeated careful  
instrumentation  
with a thin  
instrument

*Irrigation is not  
effective in this  
case!!!*

# Ledging




## Reasons

The instrument is not bended in advance!

No control of the WL

=

No recapitulation Loss of the WL



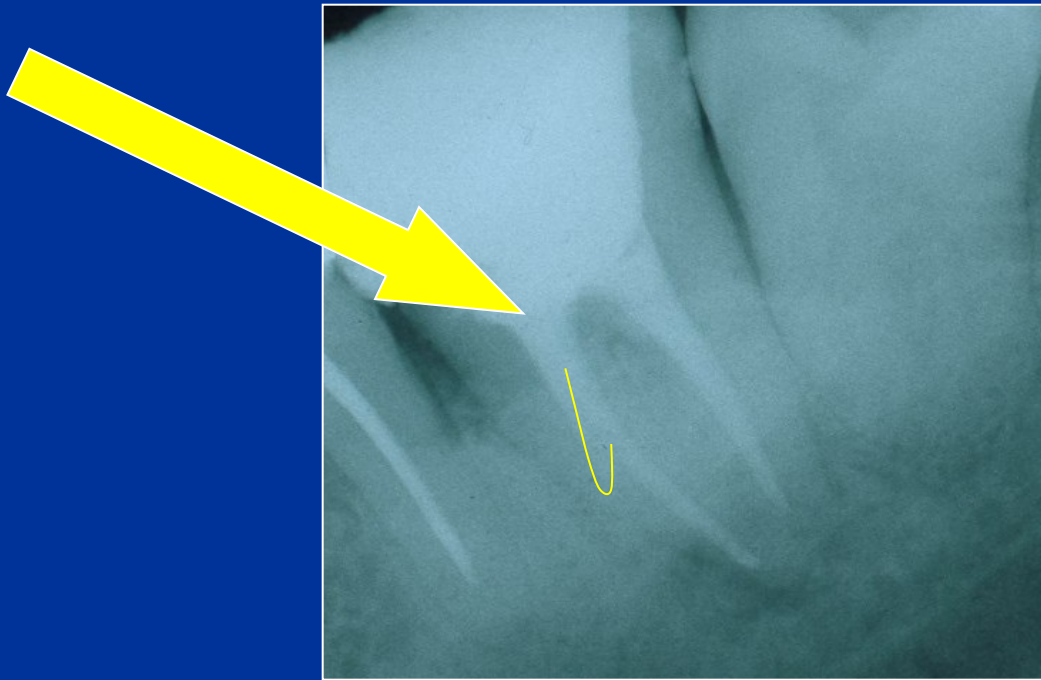
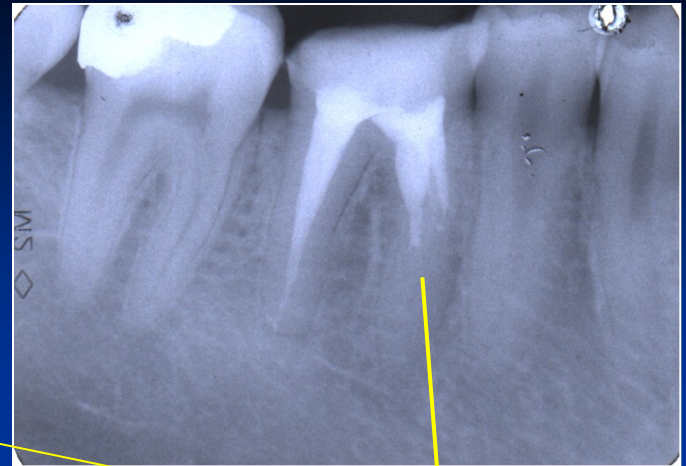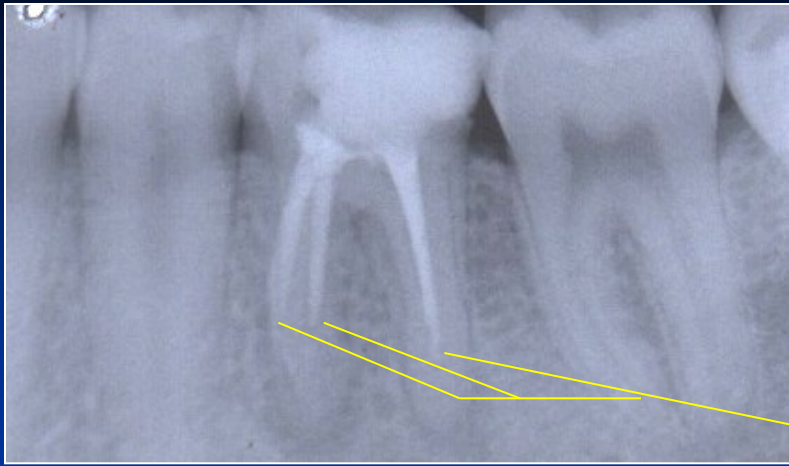
### Solution

The instrument must be  
bended in advance

Careful but complete rotation

Finishing with the fine filing

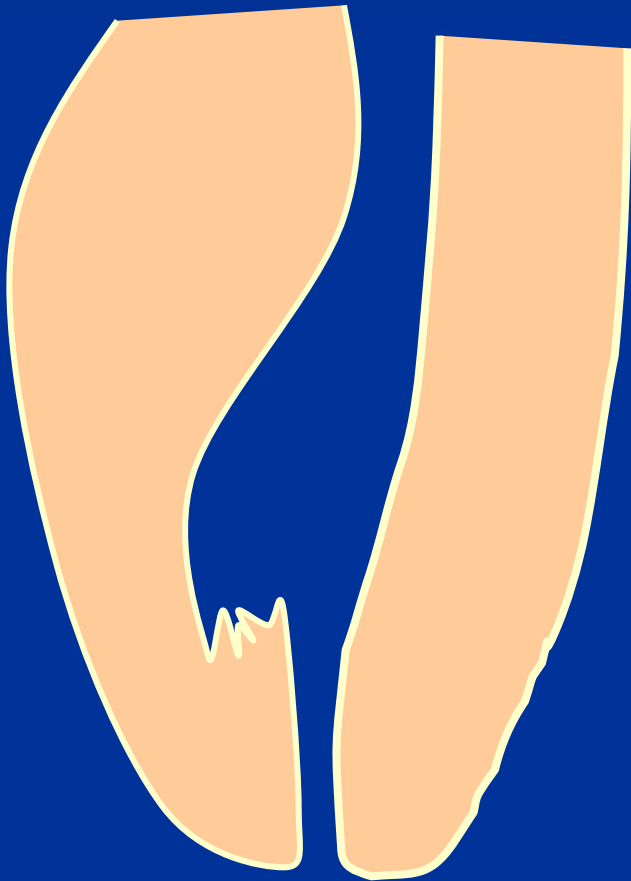*No NiTi!!!*



Ledging

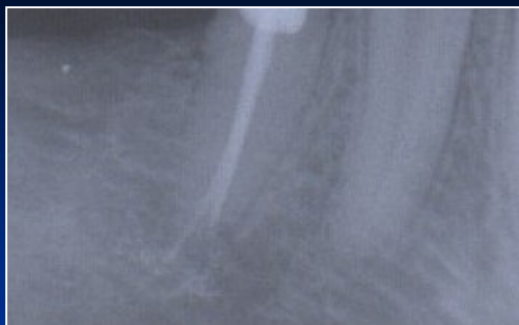



# Zippering a Elbow



The instrument is not bended in advance!

Rotation in curved canals



# Stripping

## Reasons

Bad orientation in morphology – no diagnostic x-  
Instruments are not bended  
Rotary NiTi with a big taper


## *Dangerous zones*

*Mandibular molars – mesial roots*

*Premolars, esp. maxillar*

*Mandibular incisors*

*Oblast isthmu*




# Stripping

**Důkladný přehled!**

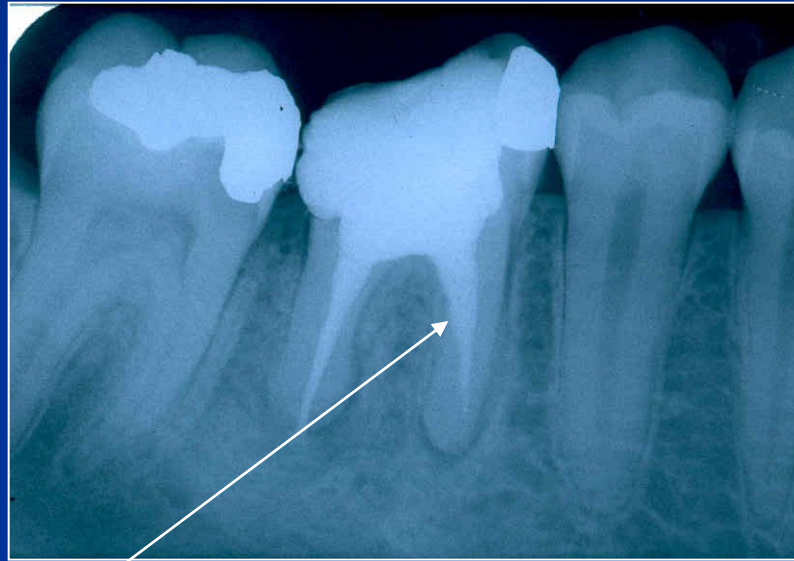
**Šetřit oblast isthmu!**

**Ruční preparace!**

**Menší kónus NiTi !**



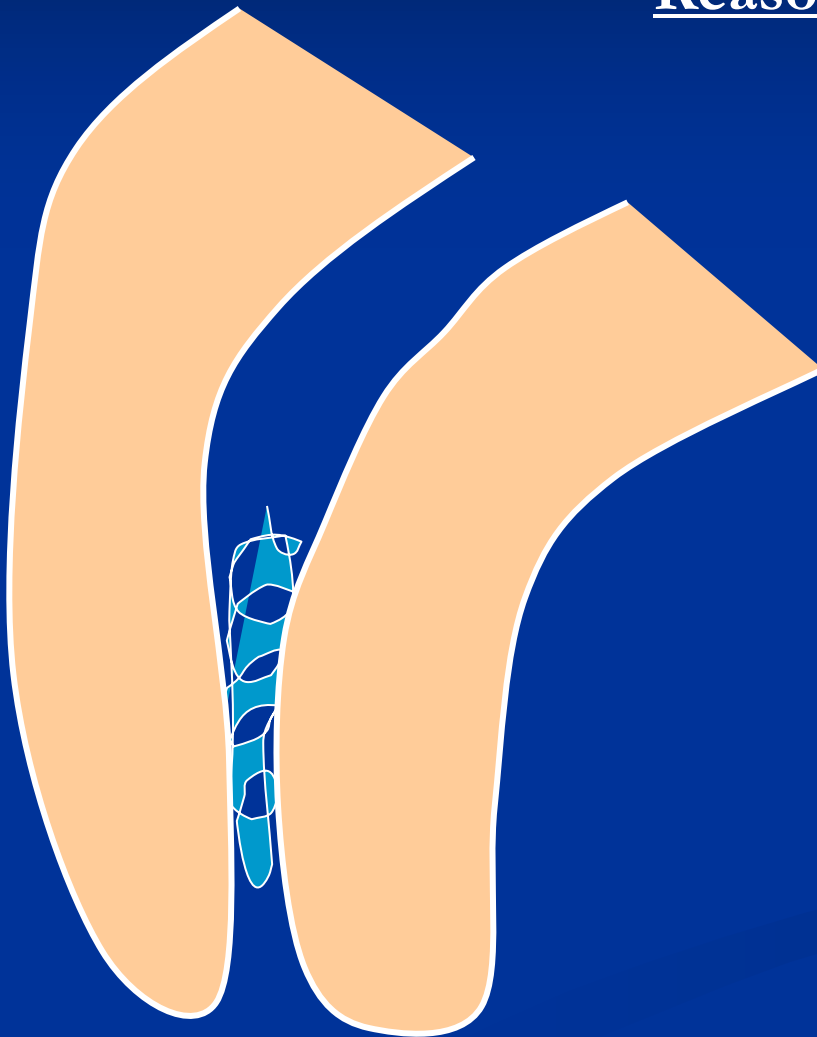
# Stripping



**Bend the instrument and eventually blunt it !**

# Fracture of the root canal instrument

## Reasons



**Insufficient  
coronal flaring**

**Old root canal  
instrument**

**Aggressive force**

**Incorrect  
movement of the  
root canal  
instrument**

## Solution

Enlargement of the  
root canal till the  
instrument

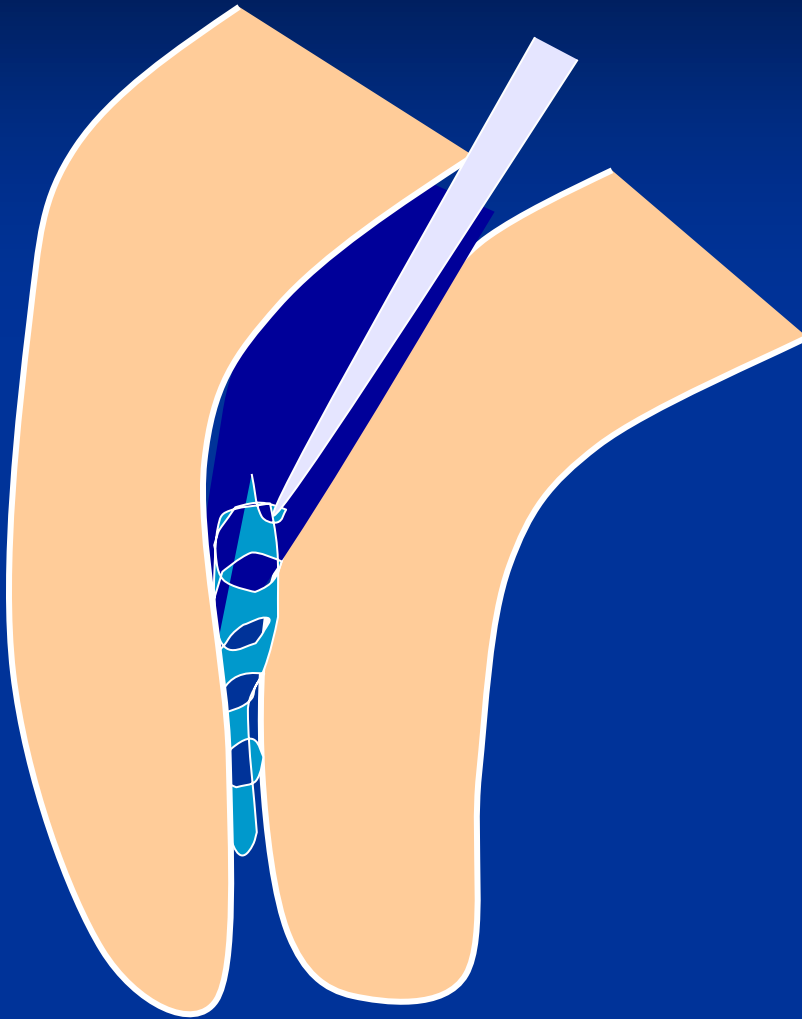
Ultrasound tips


Rotating root canal  
instrument – caution!

Bypass

Leaving in

Surgical treatment

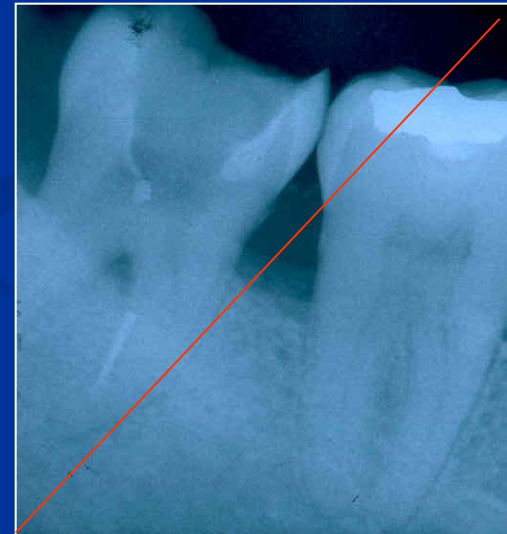
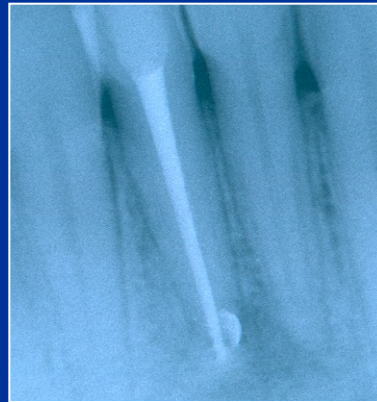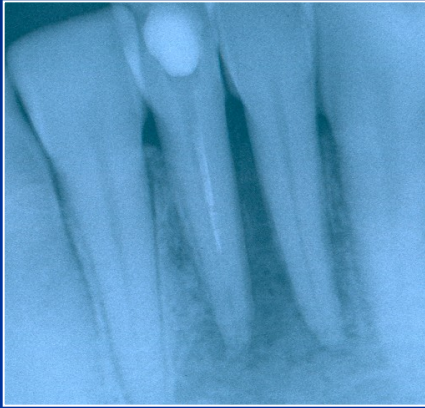




Bypass



# Fractured instrument

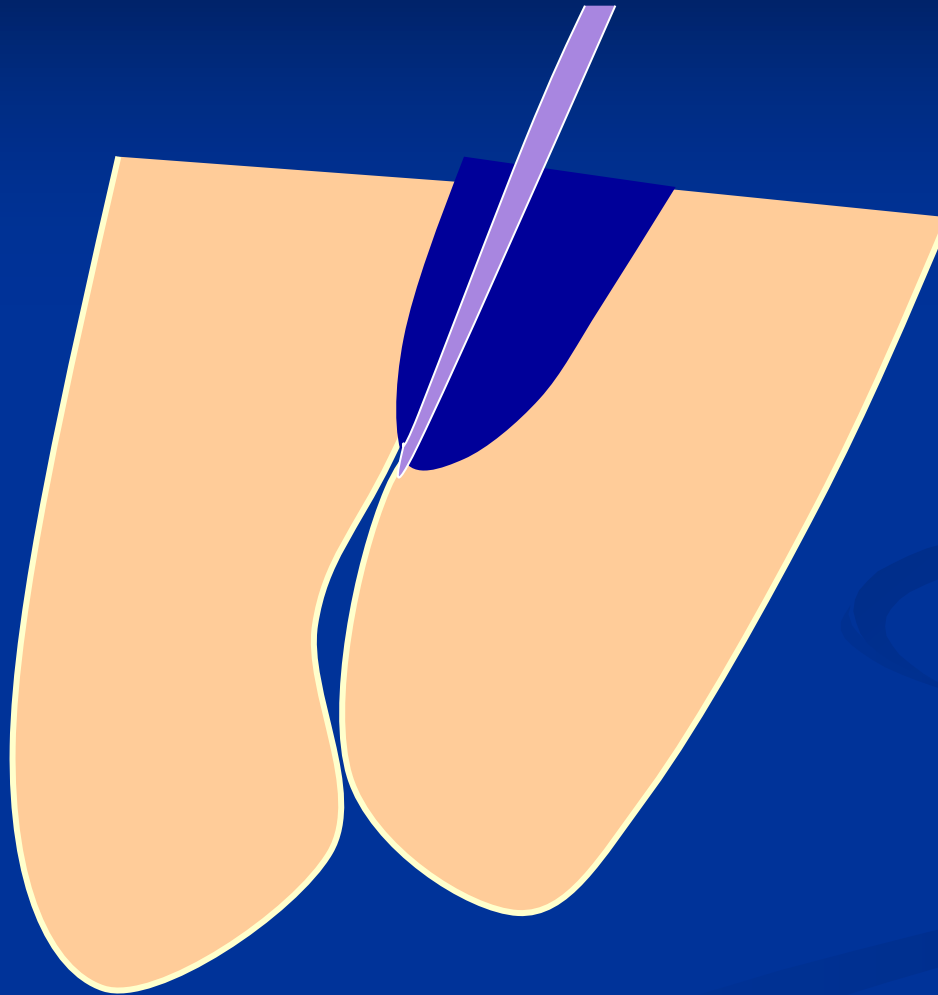


# Obliteration



Partial

# Obliterate



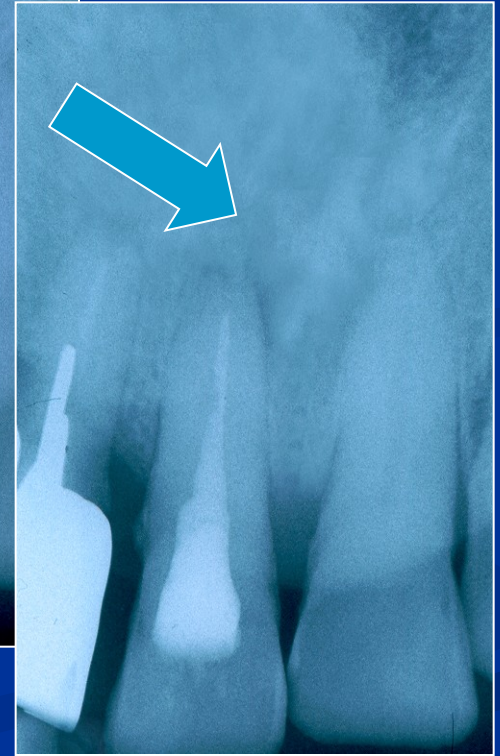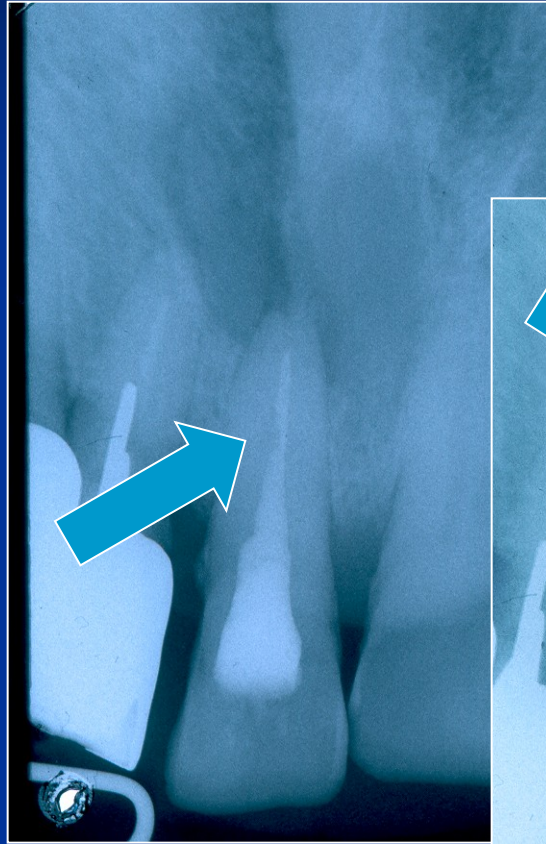
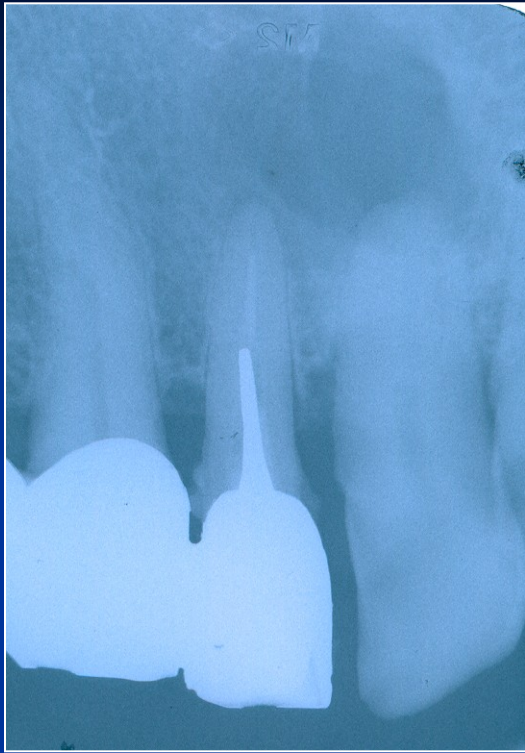
Access!!!

Hand thion  
Instrument!

Steel or NiTi

*EDTA*

*Patience*

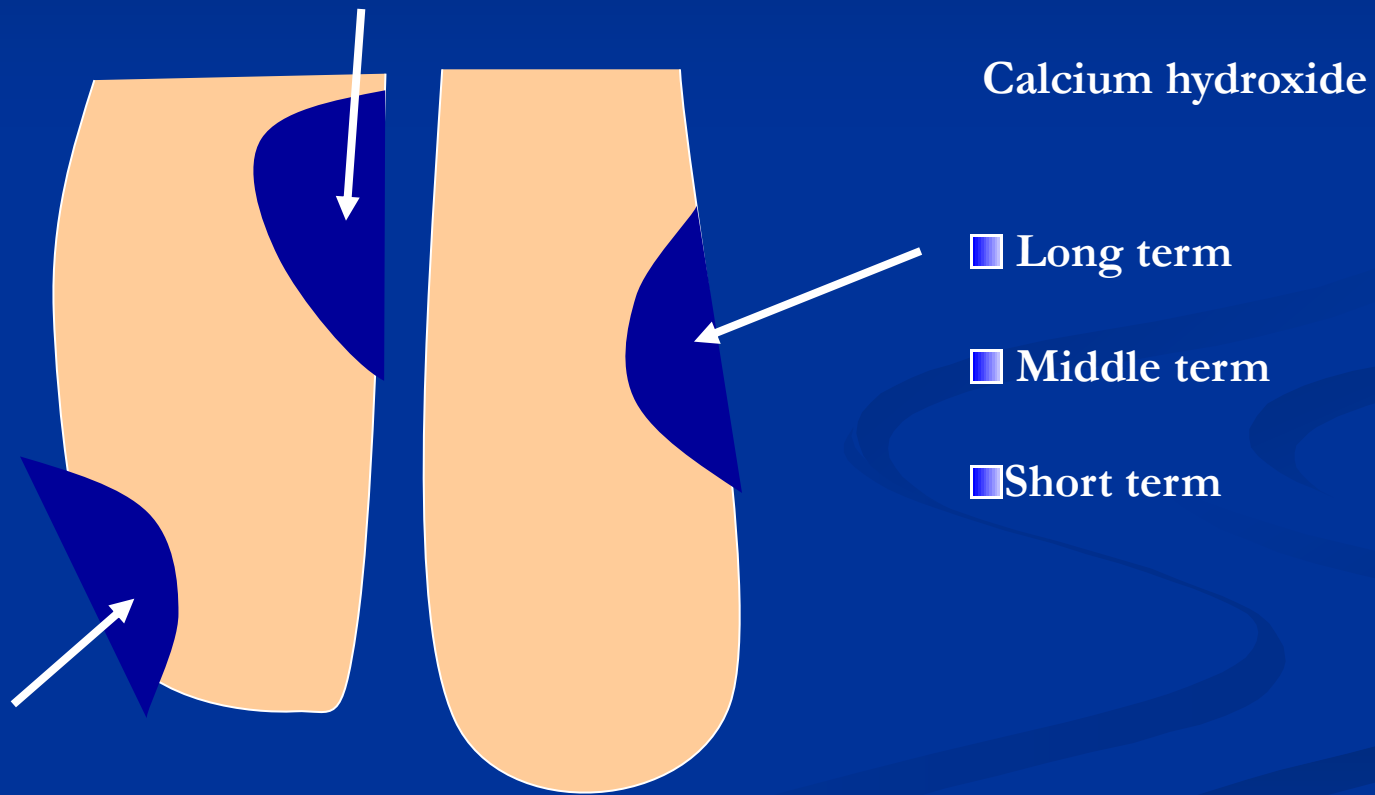


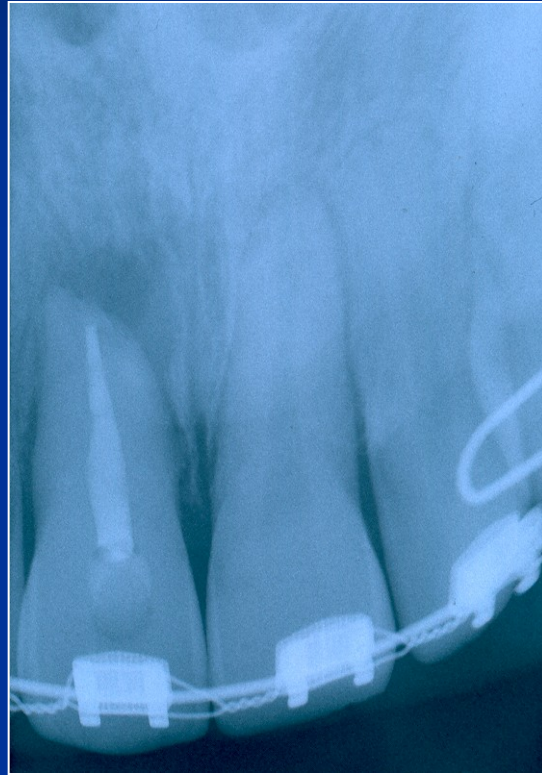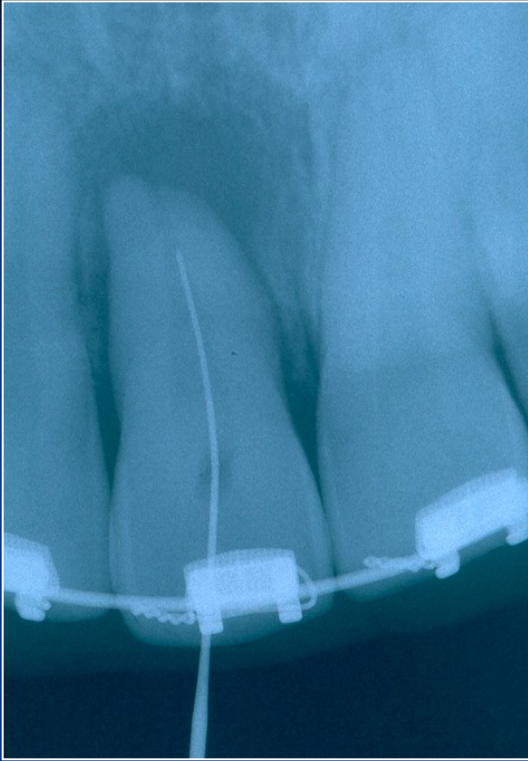
# Obliterace

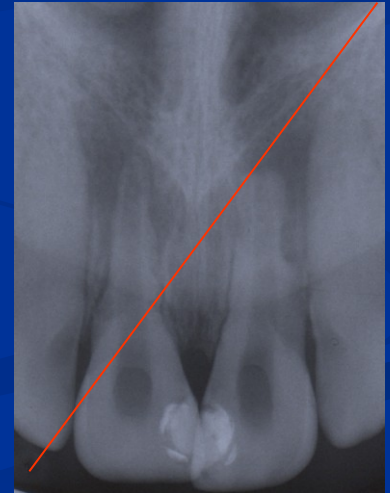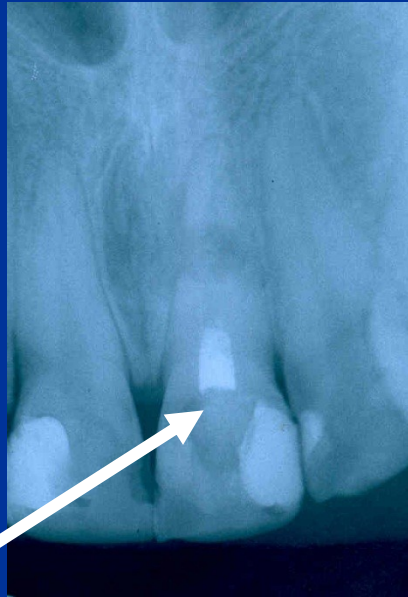
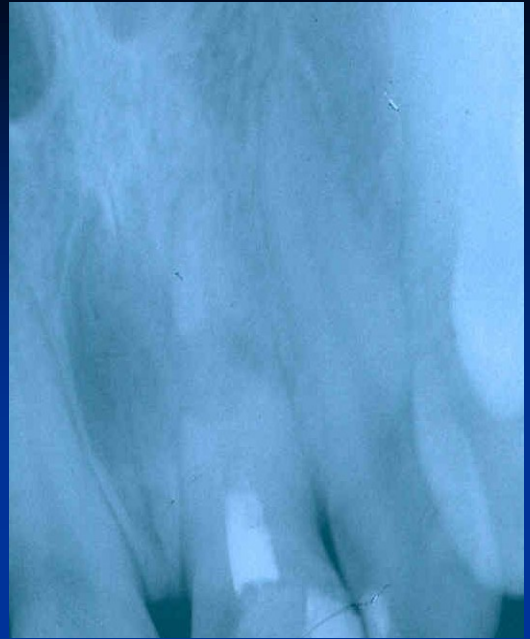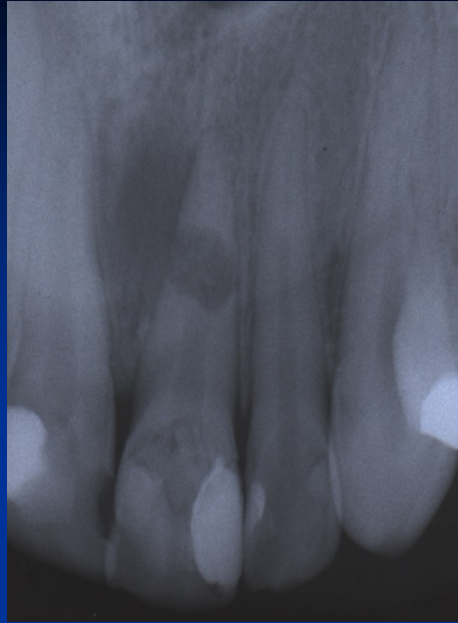


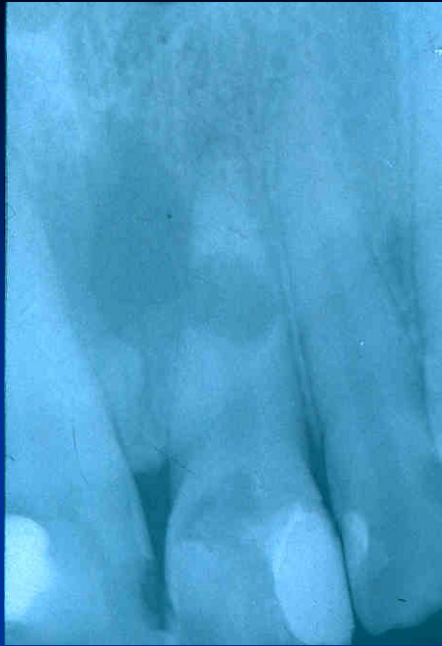Úplná -  
ponechat.

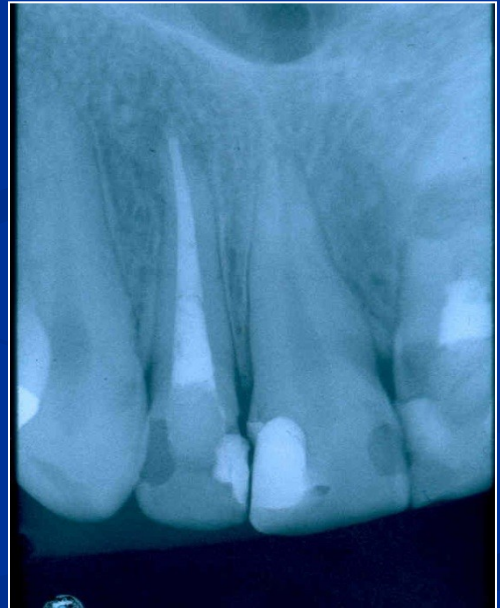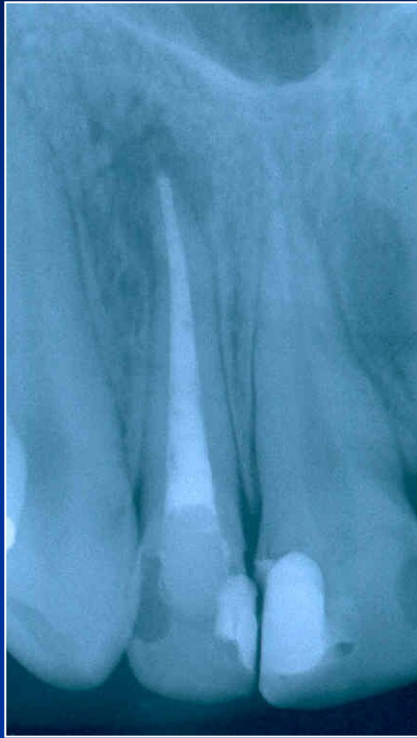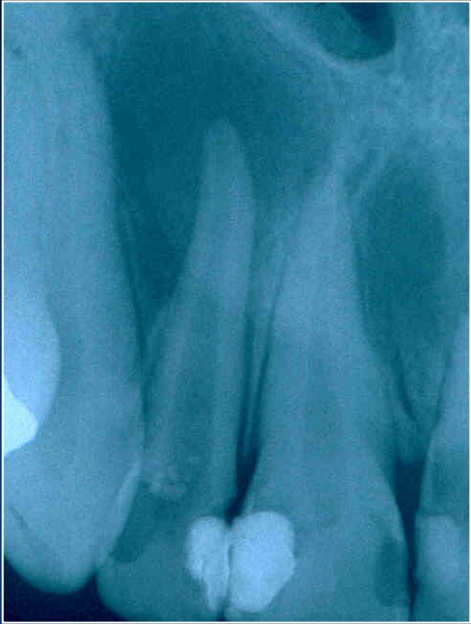# Resorption

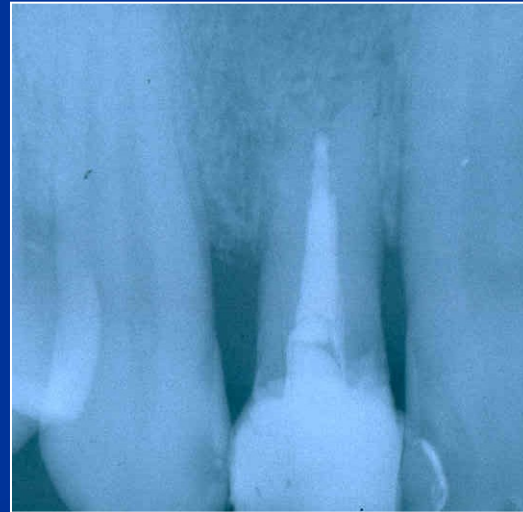
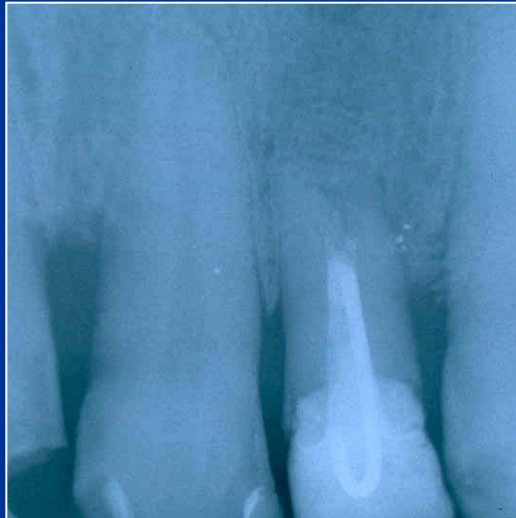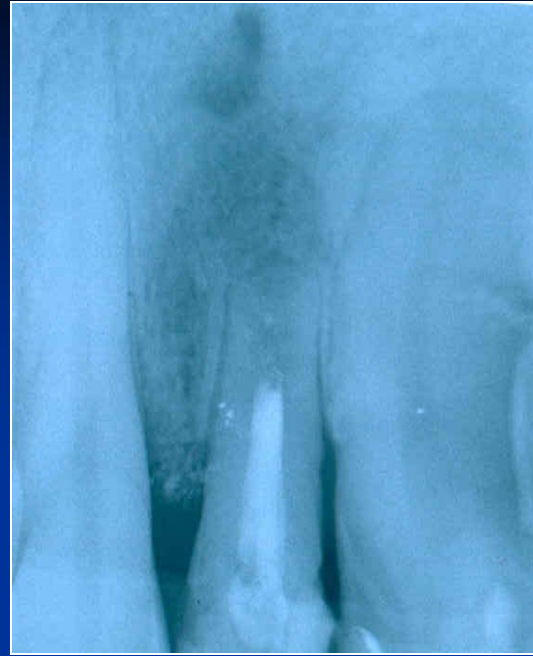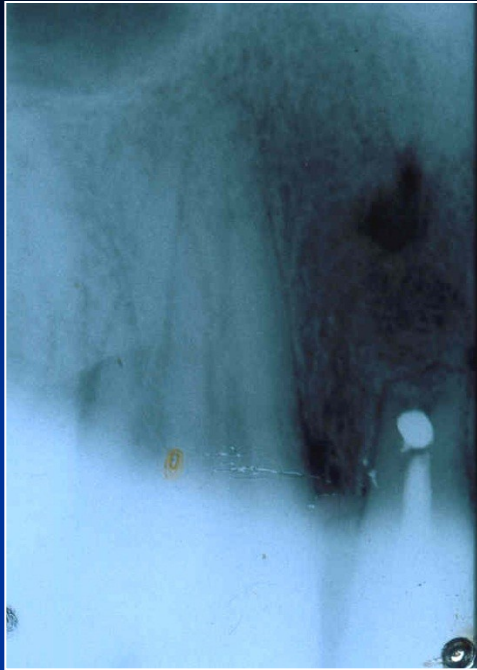












# Via falsa

- Perforation of the bottom of the pulp chamber or the coronal part of the root canal
- Perforation in the middle part of the root canal
- Apical perforation

LOT 000724 EXP 0307

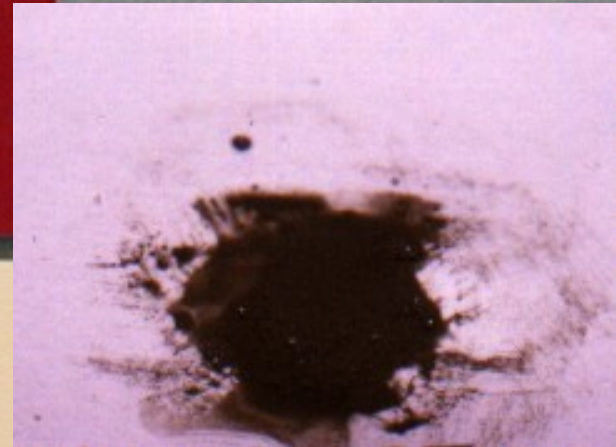
DENTSPLY

# PRO ROOT™

*MTA (Mineral Trioxide Aggregate)  
Root Canal Repair Material*

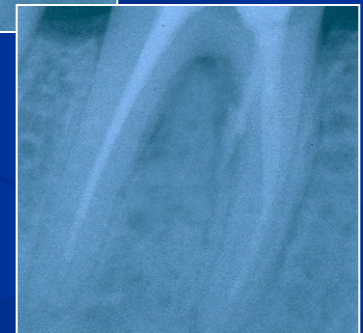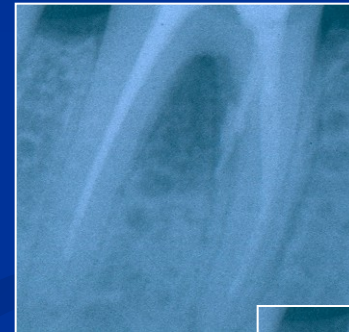Contents: 1 gram (1 treatment)

CE  
0120



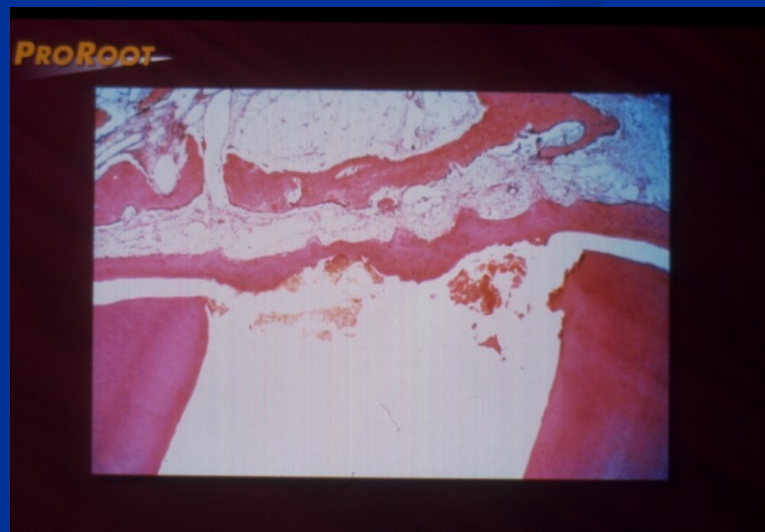# MTA composition

- Dicalcium silicate
  - Trikalcium silicate
  - Trikalcium aluminate
  - Tetrakalcium aluminate
  - Cuprum sulphate
  - Bismuthum trioxide
- = Portland cement

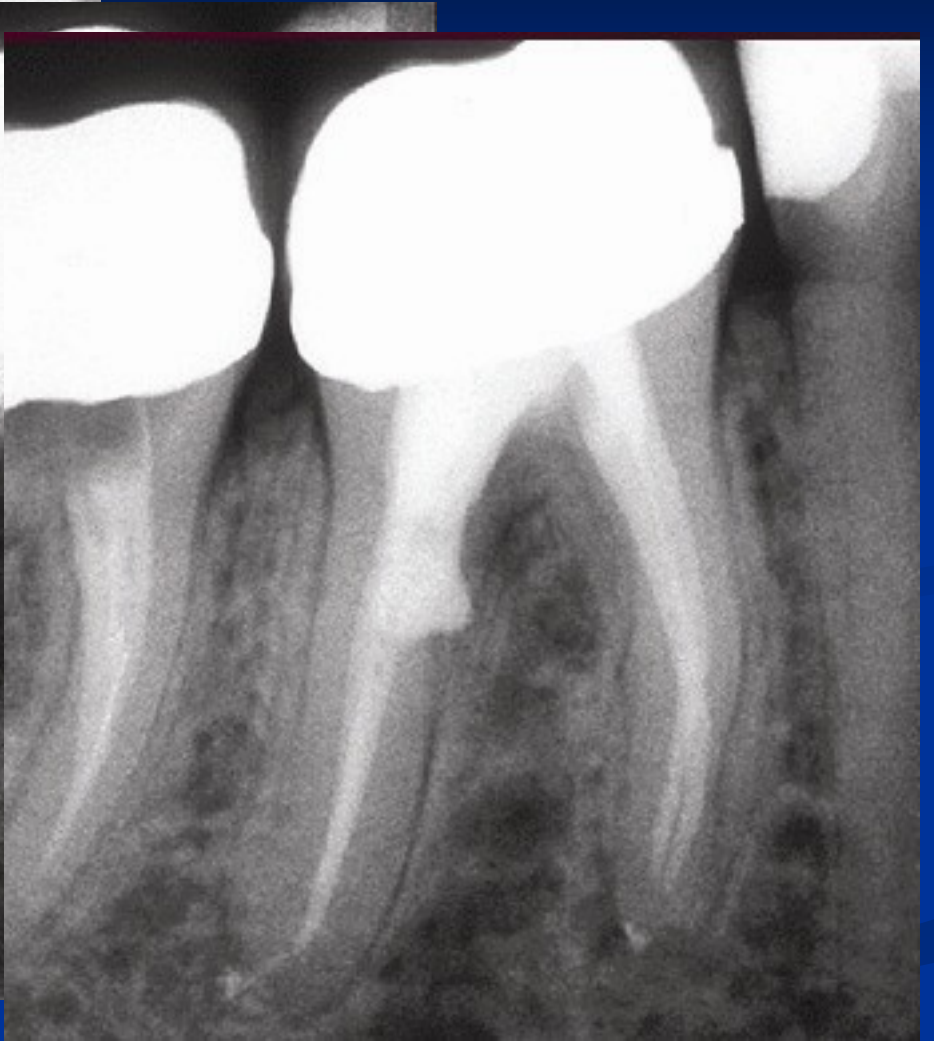
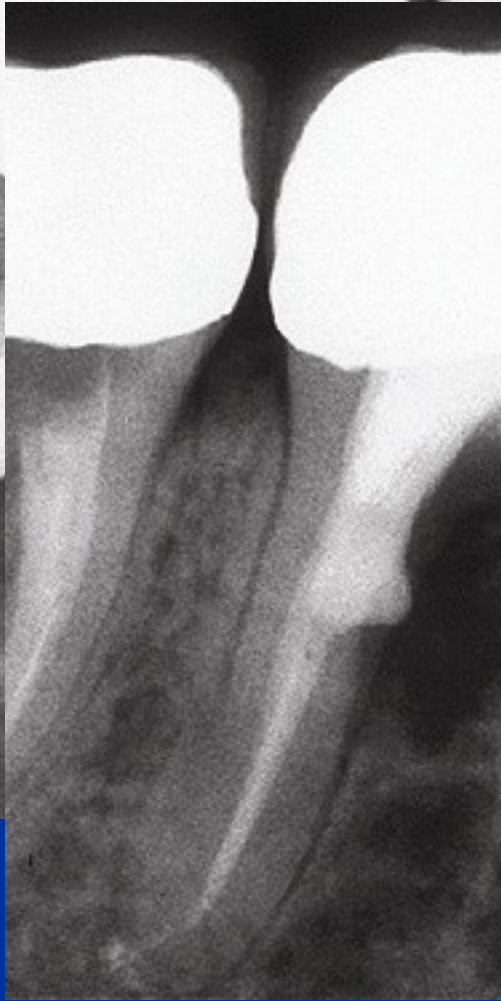
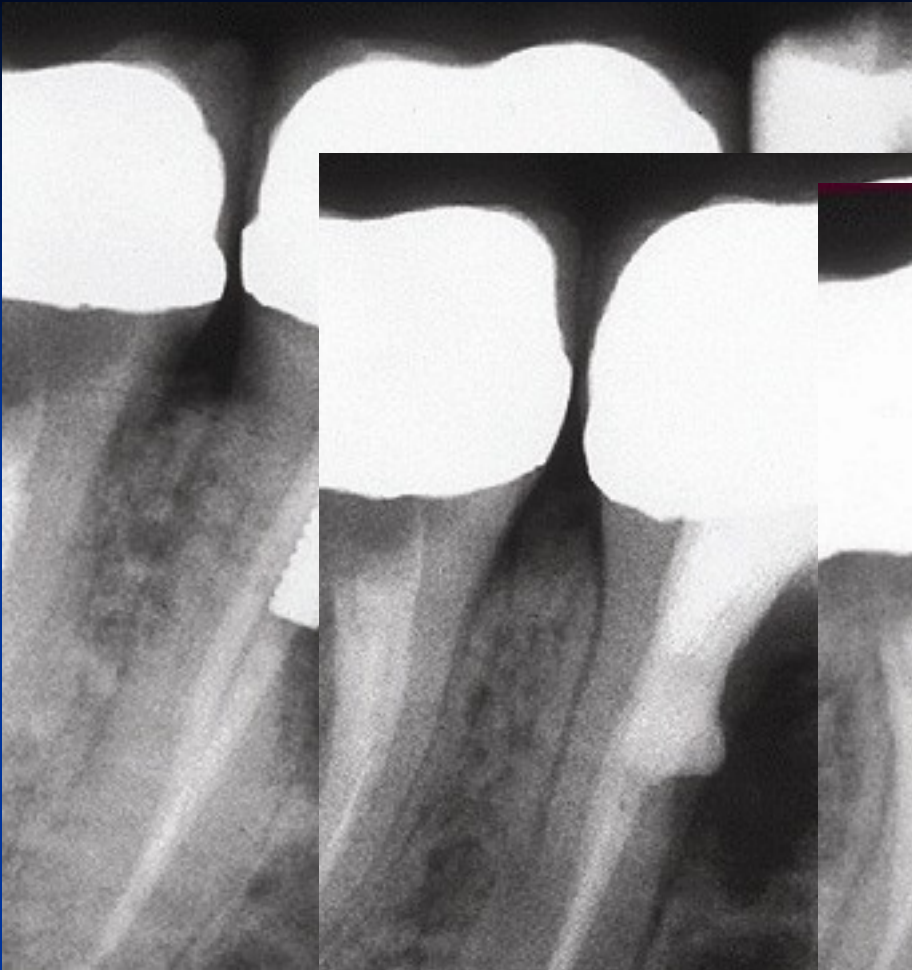# MTA

- Umožňuje hojení – dobrý okrajový uzávěr !  
Zabraňuje přístupu mikroorganismům,  
umožňuje hojení dřeně a periodoncia tvrdou tkání.



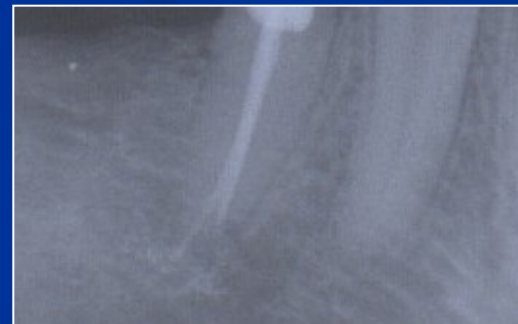


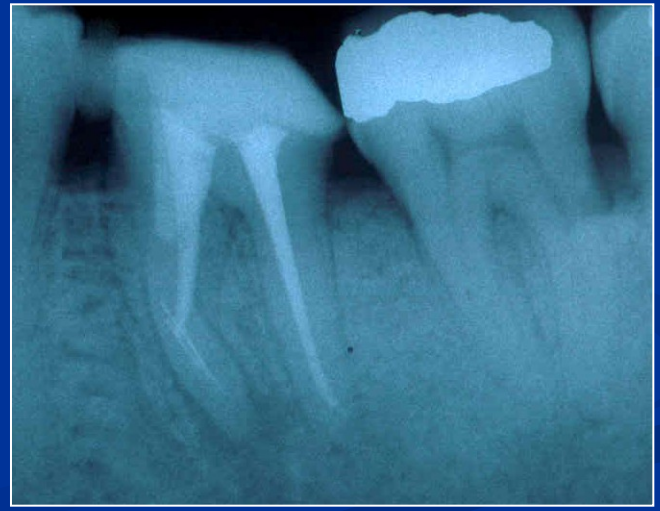
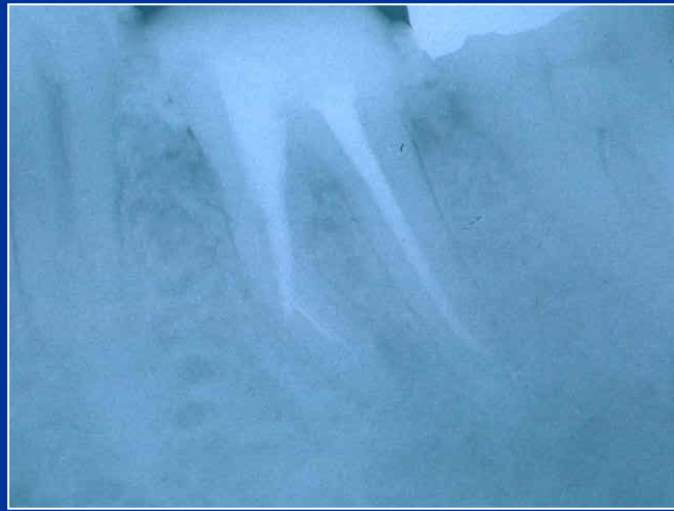
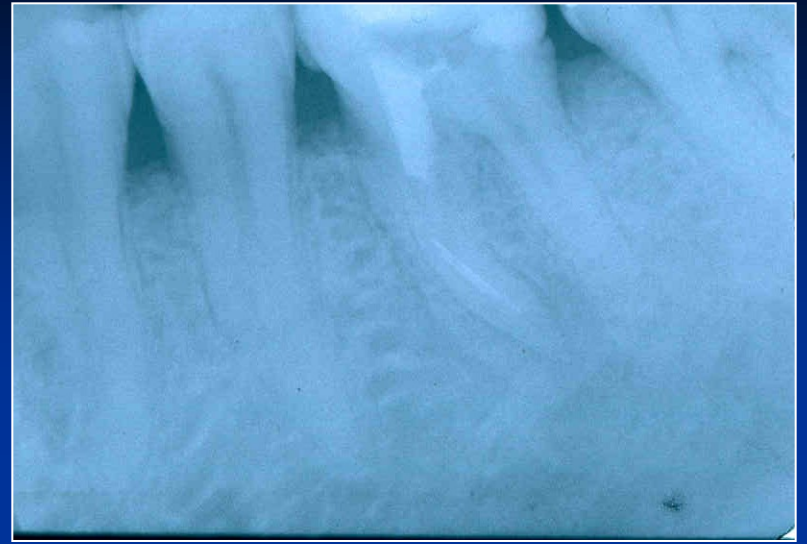
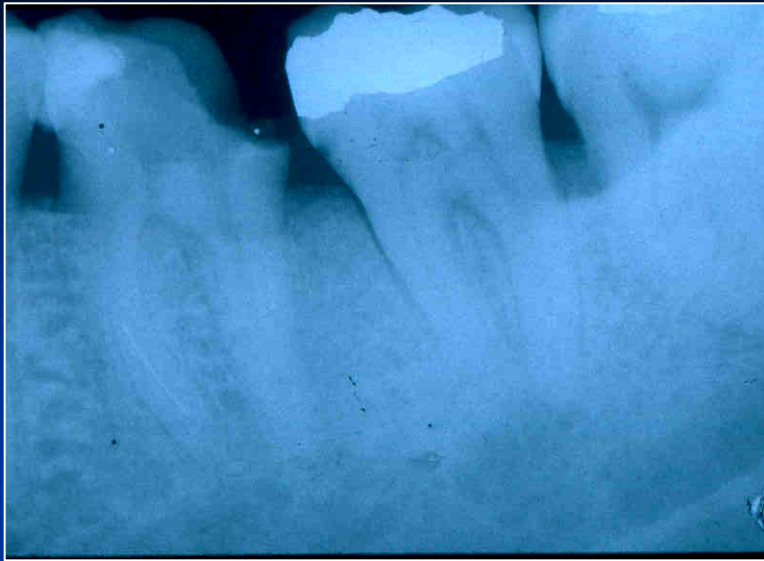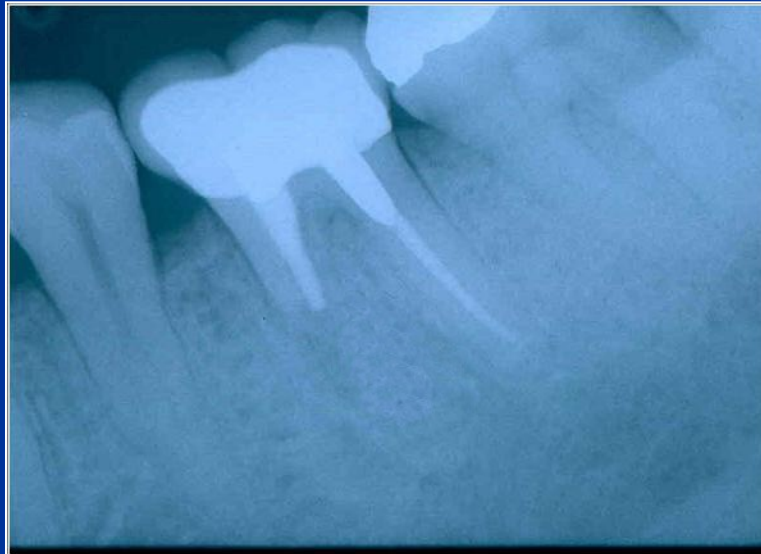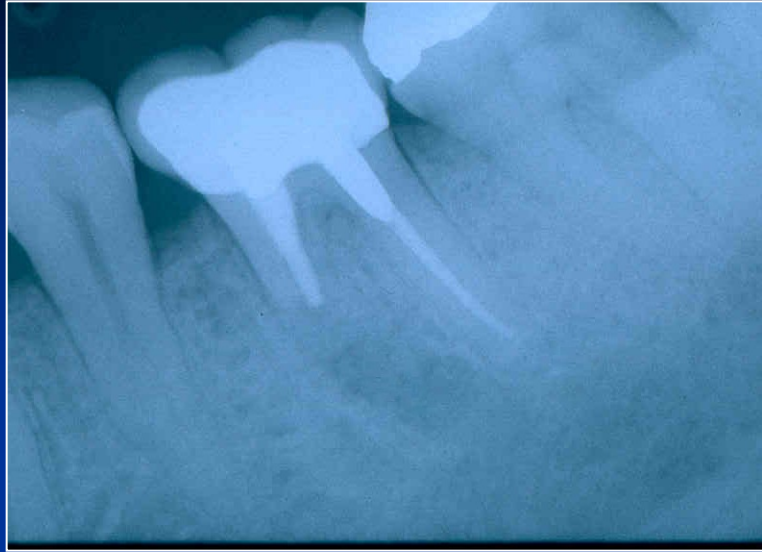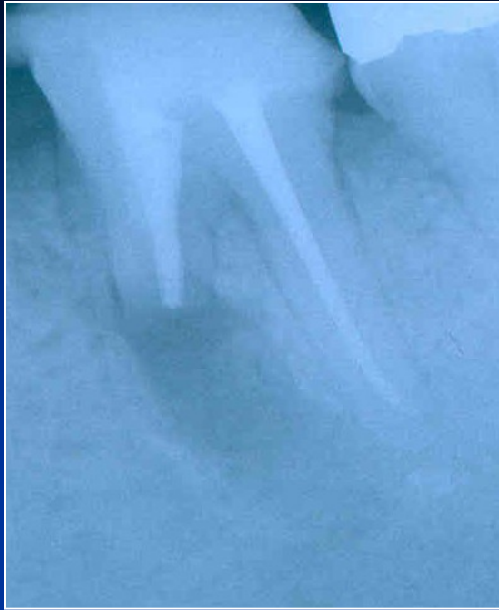# Via falsa - treatment

- No bleeding
- Desinfection
- MTA – moisture (wet cotton pellet)
- Calcium hydroxide
- Filling



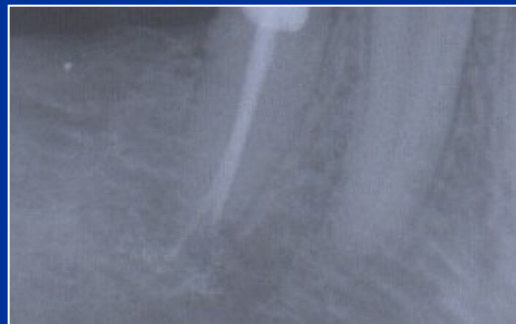



# Via falsa

- Perforace apikálně

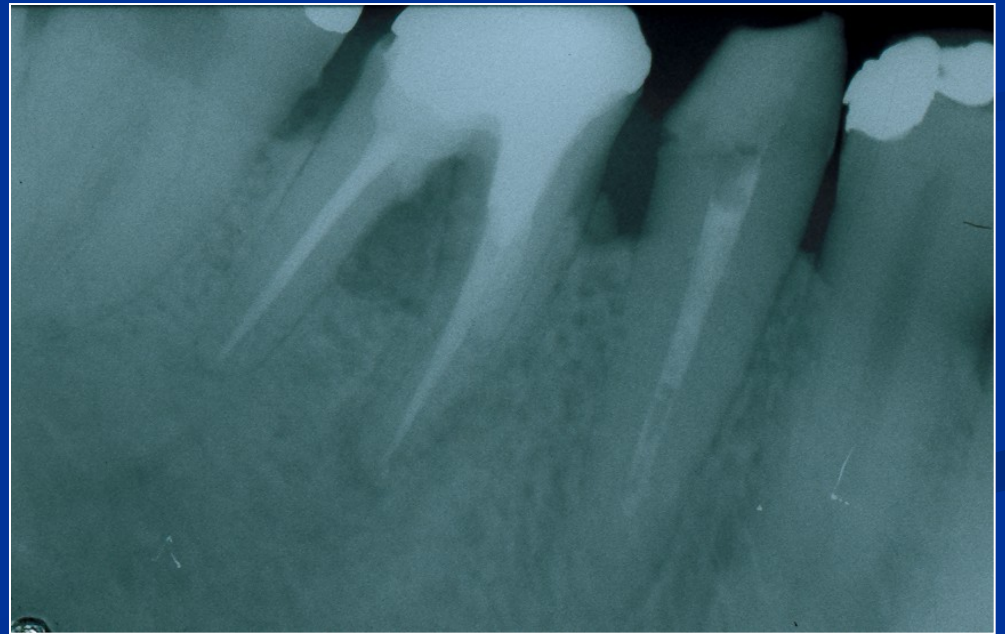
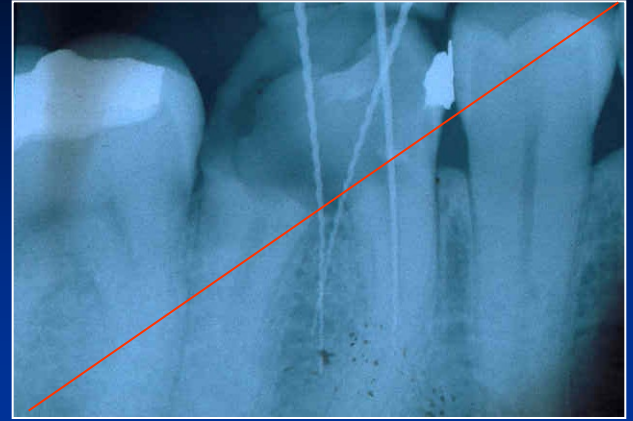
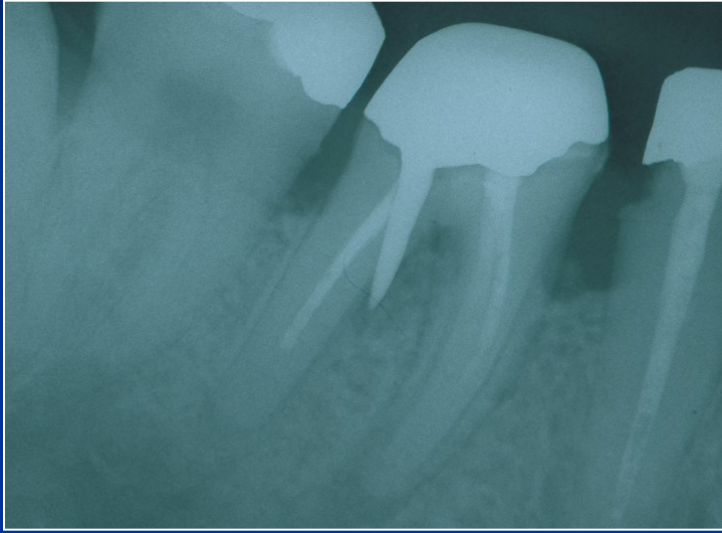Hydroxid kalcia, kořenová výplň.




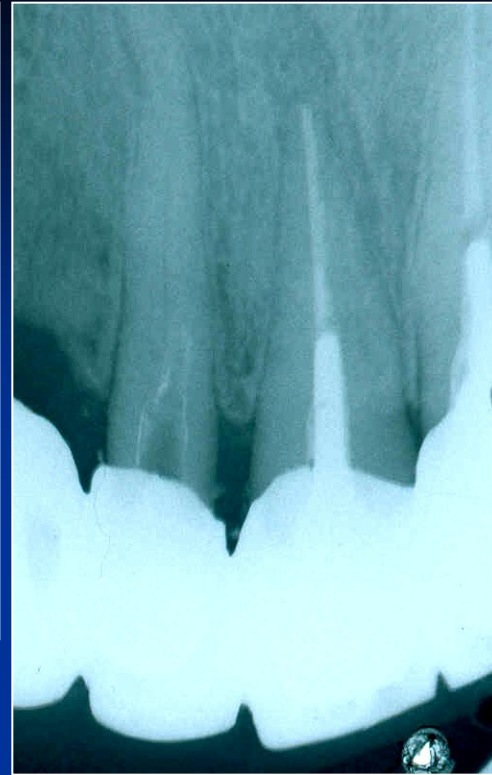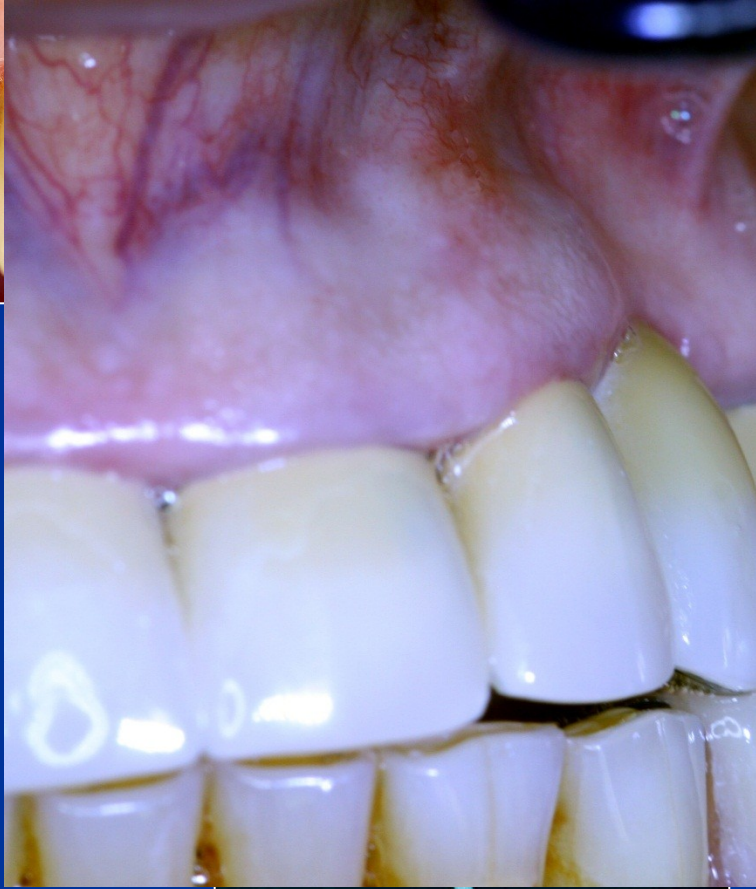
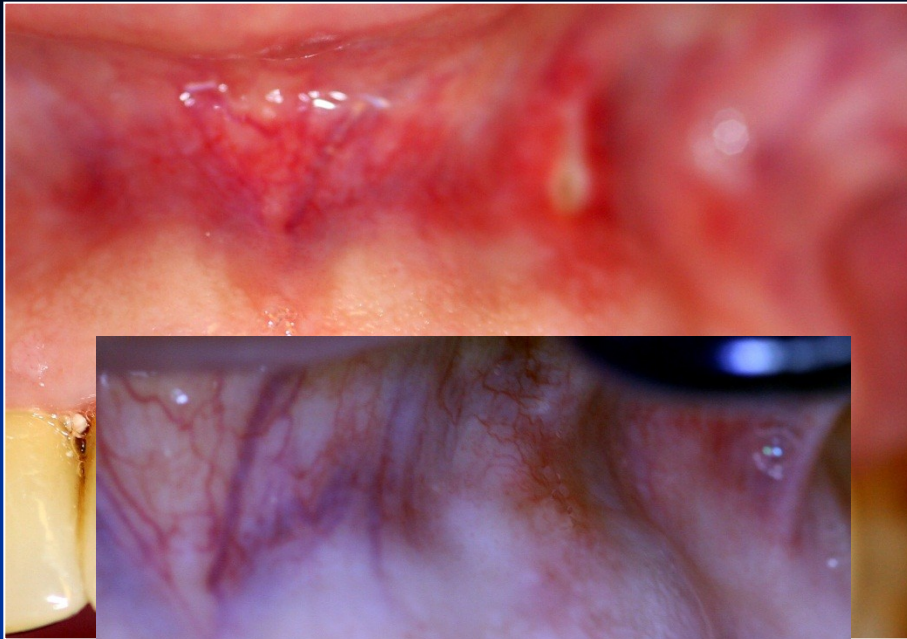
# MTA

- Umožňuje hojení – dobrý okrajový uzávěr !  
Zabraňuje přístupu mikroorganismům,  
umožňuje hojení dřeně a periodoncia tvrdou  
tkání.

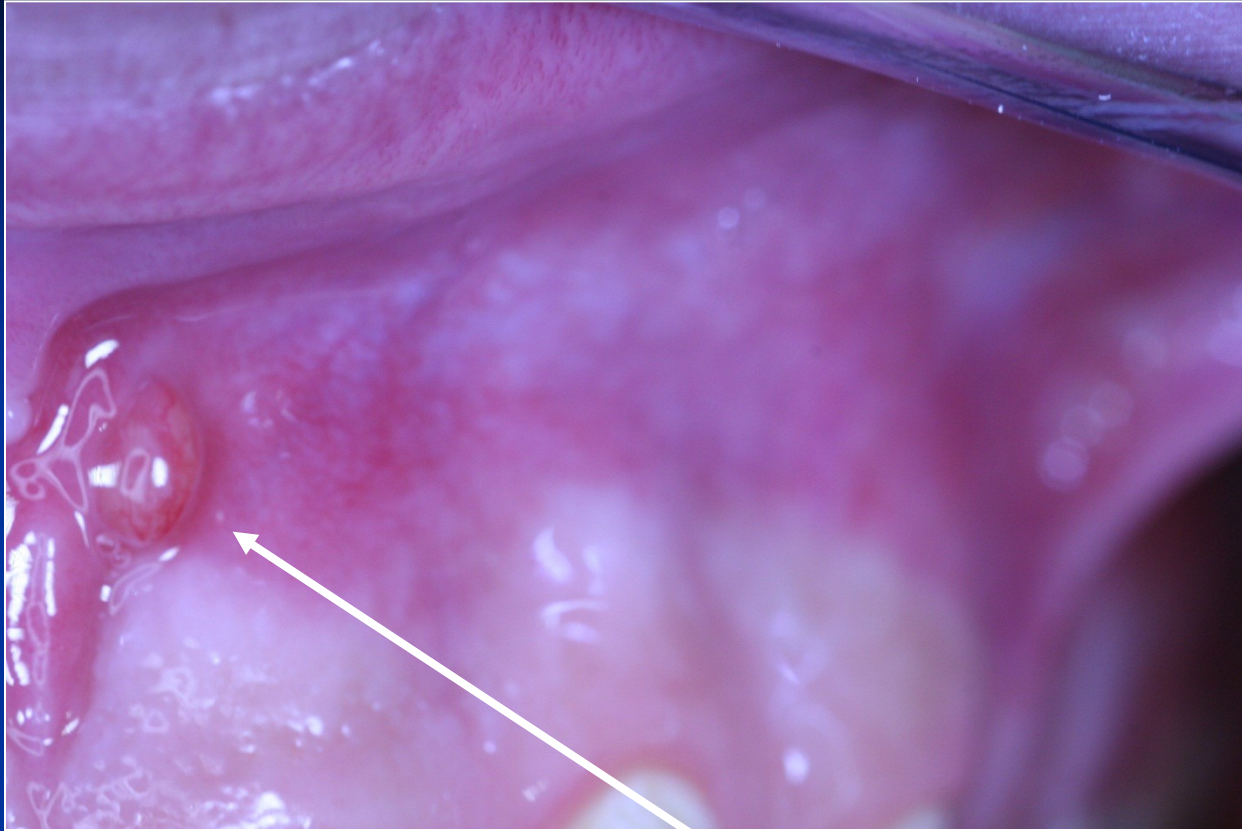




# Regional complications







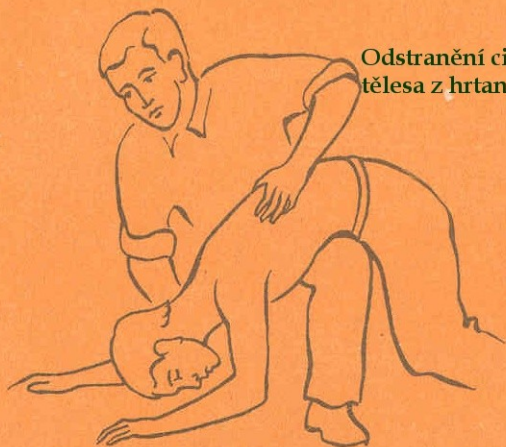**Píštěl**

# Systemic complications

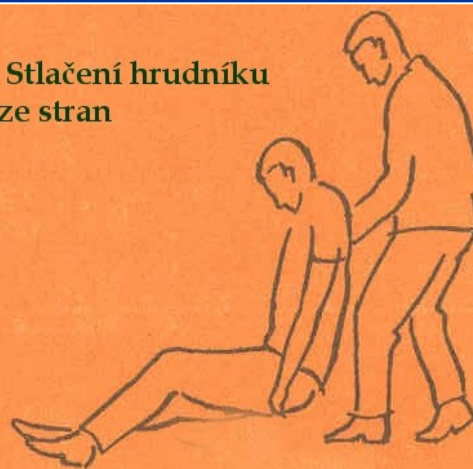# Systemic complications

- Periostitis
- Inflammation of soft tissues (face, neck)
- Gulp of the instrument (X ray, remnant diet, information)- cough
- Aspiration of the instrument -emesis

**Odstranění cizího  
tělesa z hrtanu**



**Stlačení hrudníku  
ze stran**



# Caution!

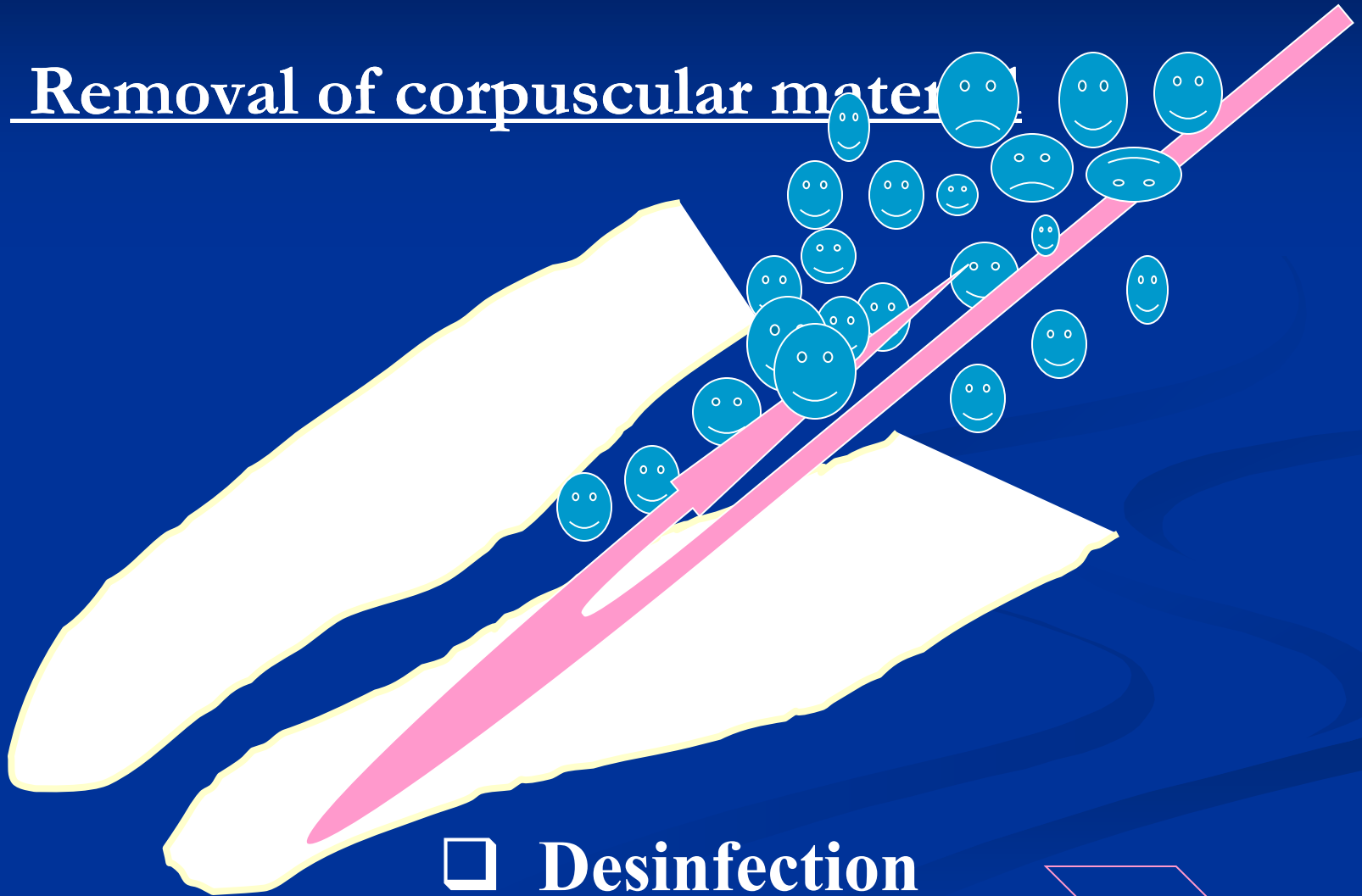
Always find the loss instrument !!!!!

# Medicaments in endodontics

- Irrigants and lubricants
- Calcium hydroxide
- MTA
- Antibiotics and corticoids
- Disinfectants
- Agents for devitalization of dental pulp

# Irrigation of the root canal

- Removal of corpuscular material



# Irrigants

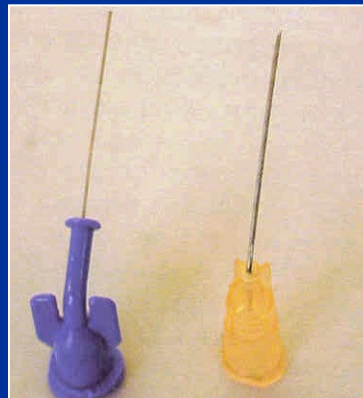

- Sodium hypochlorite (2% - 5.5%)
- Chlorhexidine 0,12 – 0.2%
- EDTA (17%)



# Lubricants

- Gel EDTA, carbamide peroxide
- Sodiumhypochlorite

## ■ Cannula



## Activation of irrigation

- Hand
- Ultrasound
- Hydrodynamic
- Laser

# Disinfection

➤ Calcium hydroxide

➤ Antibiotics and corticosteroids

# Calcium hydroxide

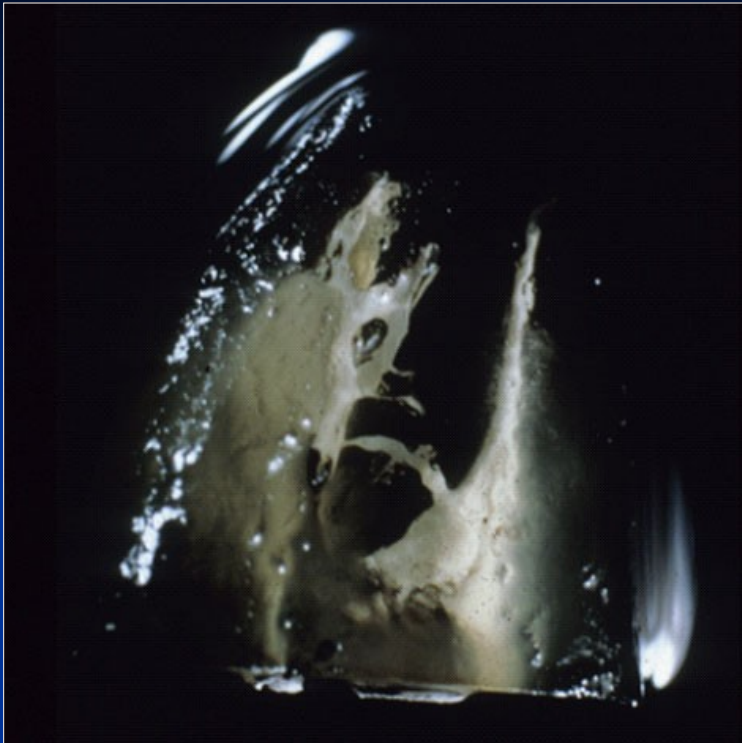- Alkaline
- Antibacterial
- Stimulation of hard tissue formation
- Haemostatic and antiphlogistic

# Calcium hydroxide

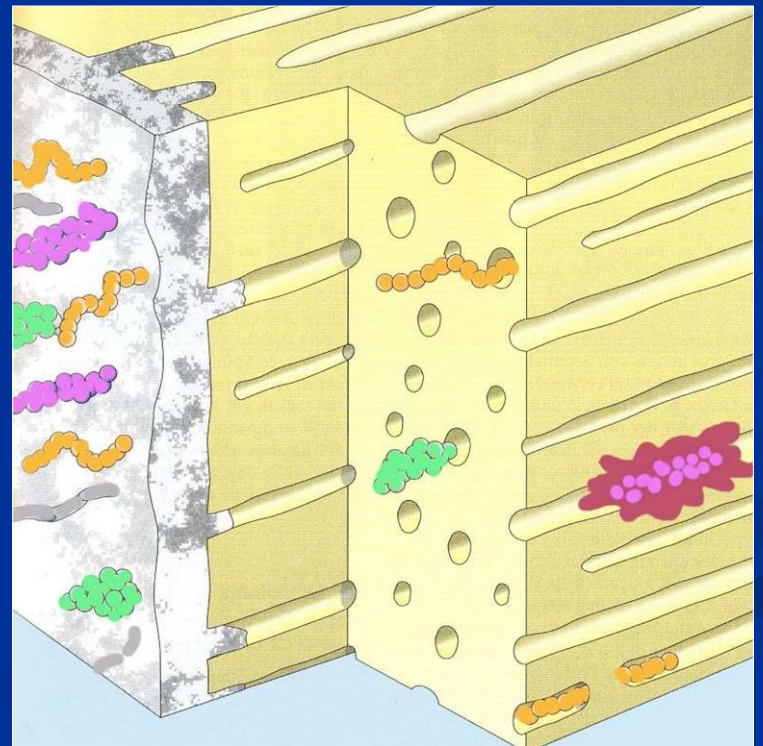
Temporary root canal filling

Subbase

Component of sealers



# Dressing



# Calcium hydroxide

- Short term action

1 – 2 weeks

Desinfection, haemostasis

# Calcium hydroxide

- Middle term action

2 – 3 months

Apexification

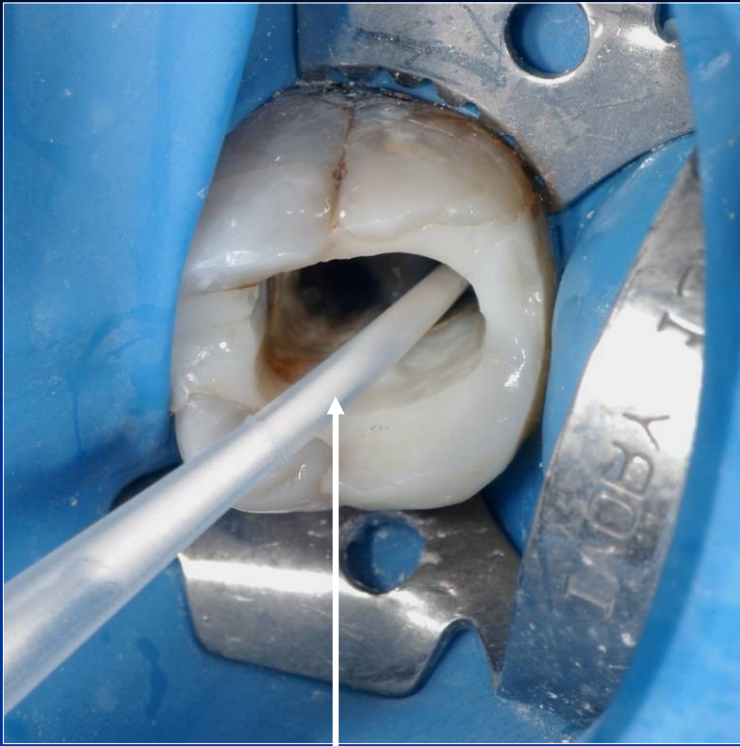
Chronic form of apical periodontitis



# Calcium hydroxide

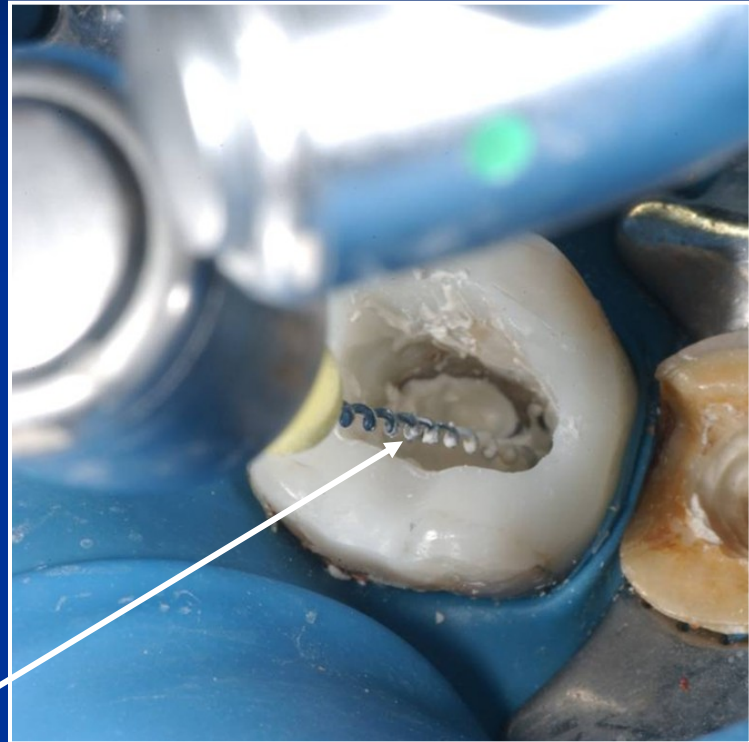
- Long term action  
3 months and more

Prevention of resorption

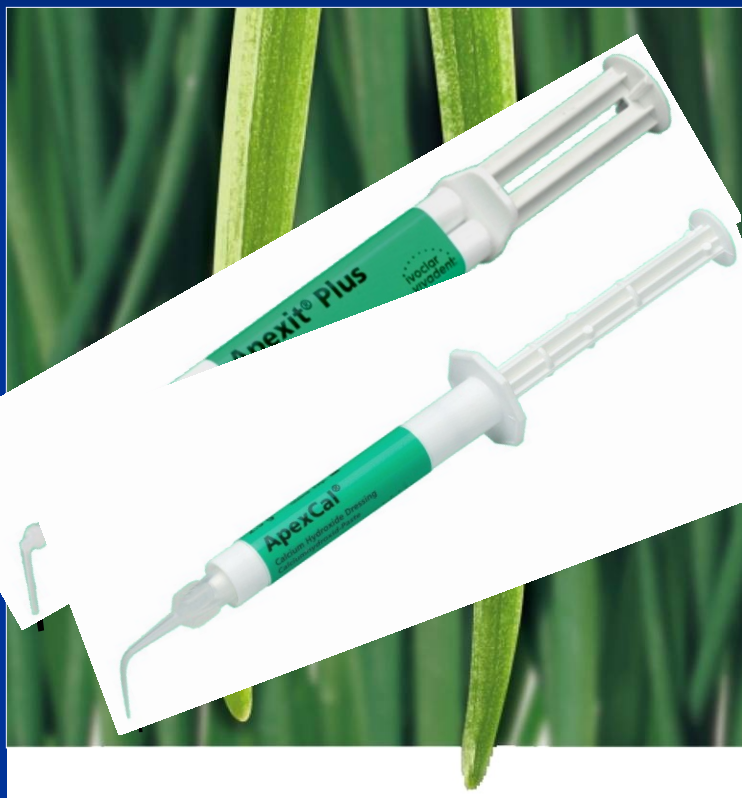

Magistraliter

The powder is mixed with distilled water



**Lentule 2 mm less than WL !!!!!**



Apexit® Plus

ApexCal®

LOT 000724 EXP 0307

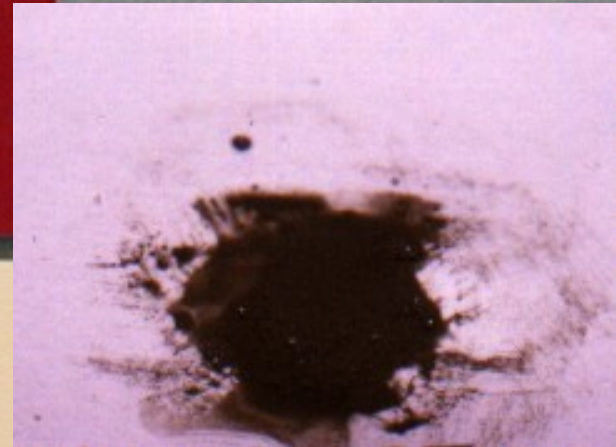
DENTSPLY

# PRO ROOT™

*MTA (Mineral Trioxide Aggregate)  
Root Canal Repair Material*

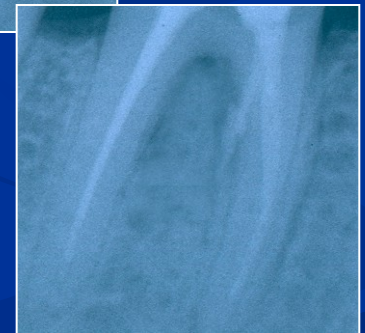Contents: 1 gram (1 treatment)

CE  
0120



# MTA composition

- Dicalcium silicate
  - Trikalcium silicate
  - Trikalcium aluminate
  - Tetraalkalium aluminate
  - Cuprum sulphate
  - Bismuthum trioxide
- = Portland cement

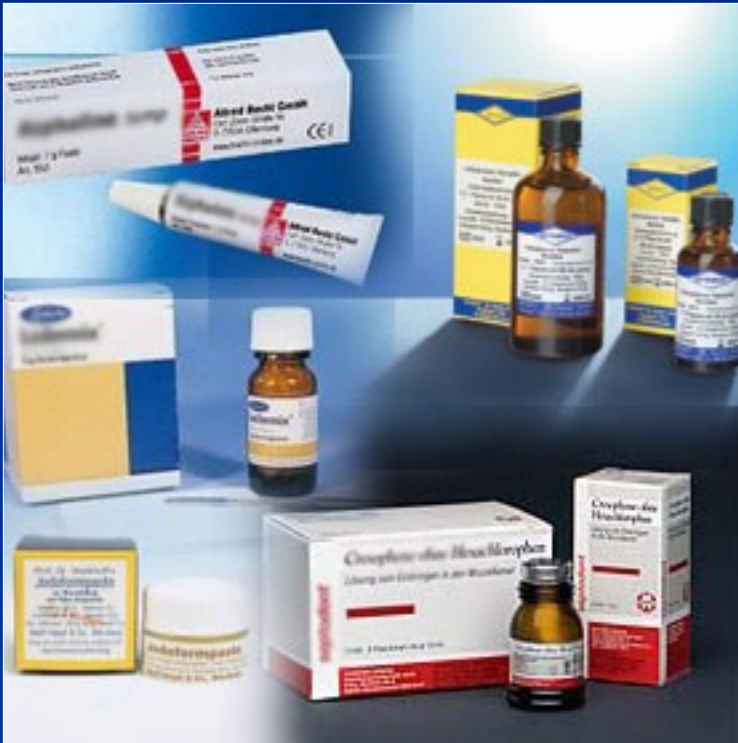

# MTA

- Umožňuje hojení – dobrý okrajový uzávěr !  
Zabraňuje přístupu mikroorganismům,  
umožňuje hojení dřeně a periodoncia tvrdou  
tkání.



# Phenolic agents and aldehyds



## Fenolické látky

Chlumského roztok

Chlorophenol kafr mentol (ChCM)

Chlorophenol kafr thymol

Iodoformová pasta

## Aldehydy

Formaldehyd

Formokresol

Trikresolformalin

***Caution!***

***Toxic, allergenic, mutagenic !!!!!***

# Antibiotics and corticoids

- Ledermix
- Septomyxin

*Antibiotics, corticoids, Zinoxid eugenol,  
Paraformaldehyd  
Exceptionally 1 -3 days.*



# Agents for devitalization

- They causes necrosis of dental pulp

As<sub>2</sub>O<sub>3</sub>

Cobalt paste

Parafphormaldehyd paste (Depulpin, Caustinerf)