

Periodontology

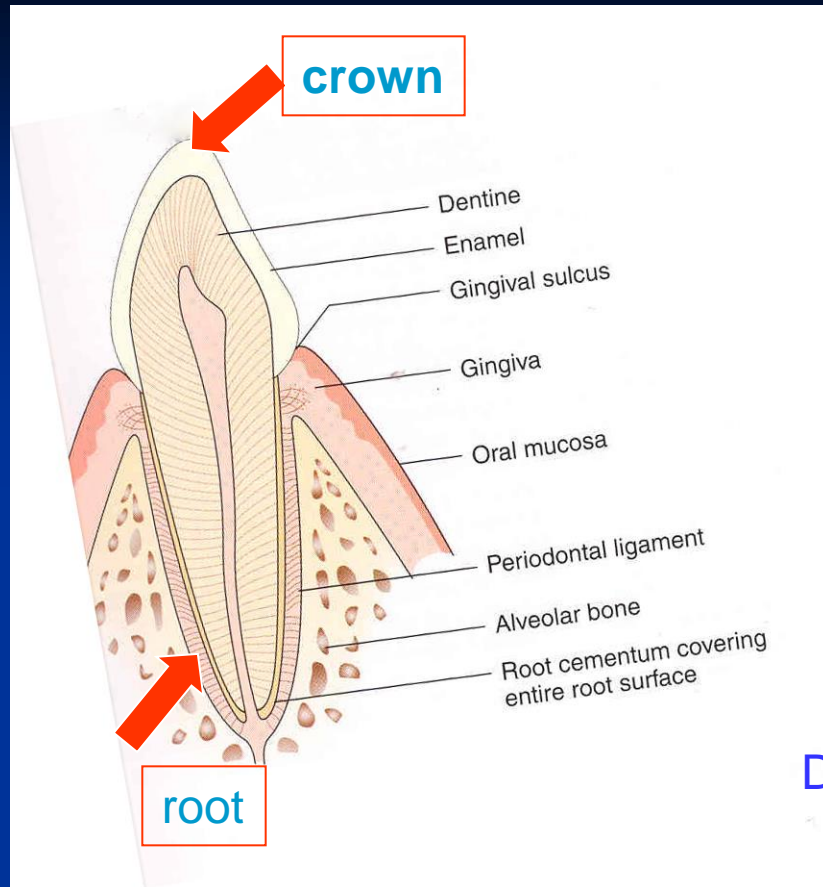
Etiology
Pathogenesis
Diagnosis
Therapy prevention

Periodontology

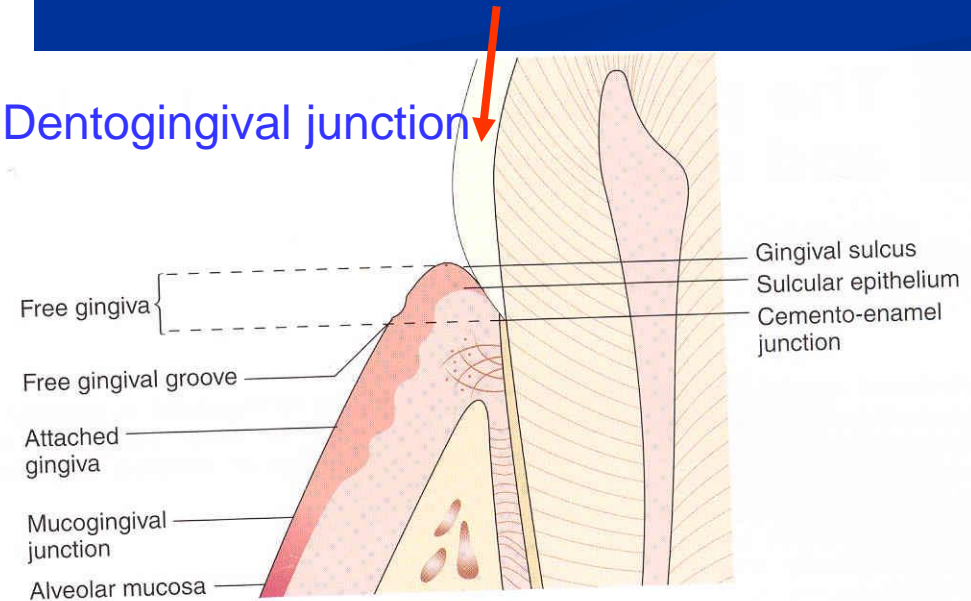
- Periodontal tissues (supportive tissues)
 - alveolar bone
 - cementum
 - periodontal ligament
 - gingiva

Morphology

Supportive tissues



Dentogingival junction



Periodontal diseases

- Etiology

Local factors

Systemic factors

Local factors

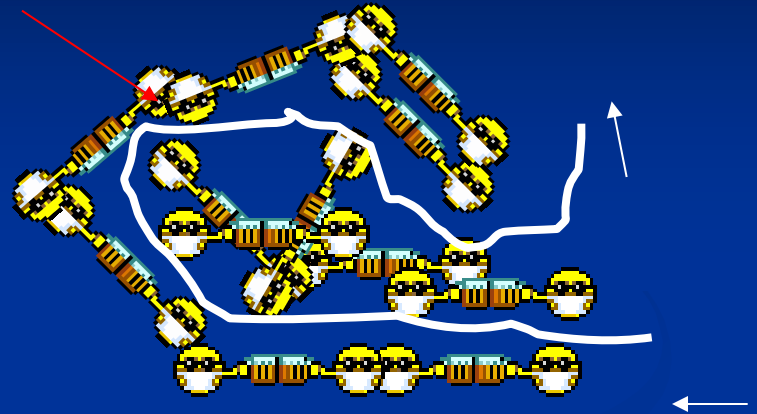

- Dental plaque (biofilm)
- Dental calculus
- Bad fillings
 - Overhangs
 - No contact poing
 - Not polished (esp composite fillings)

Local factors

- Bad made crowns and prothesis
- Mucosal disorders – frenum
- Trauma (bad occlusion)- high fillings

Dental plaque = biofilm

■ Community



■ Primitive circulation

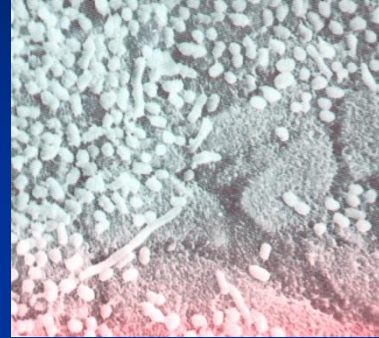

More species
Higher metabolic activity
Higher resistance
(*S. sobrinus* CHX 300x, AF 75x)

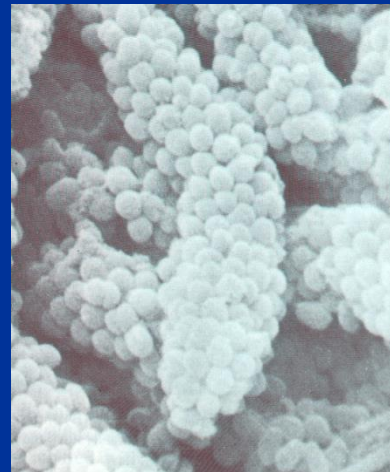
} better conditions to survive
higher virulence

Biofilm

- Adherence

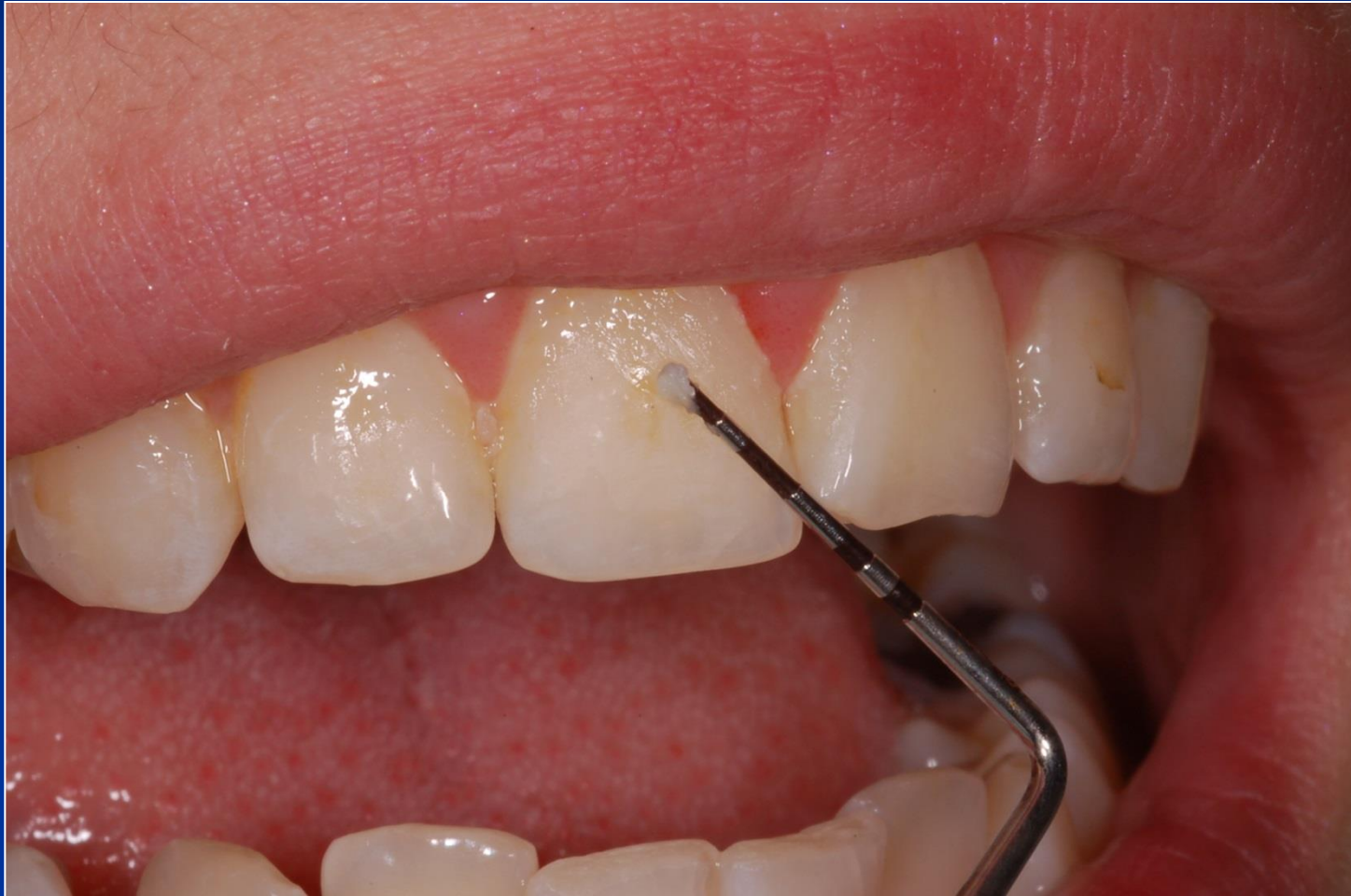

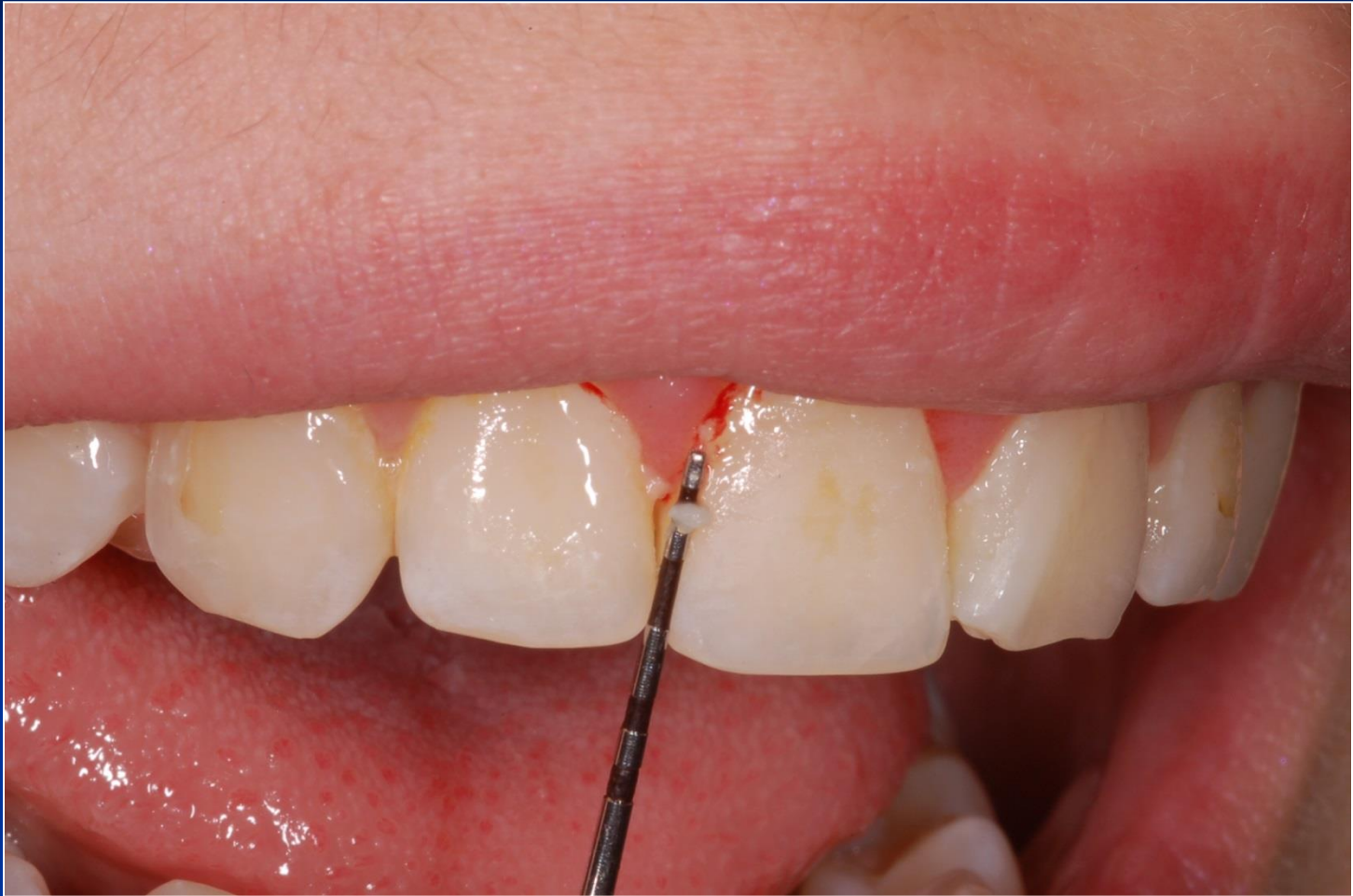- Colonisation



- Maturation

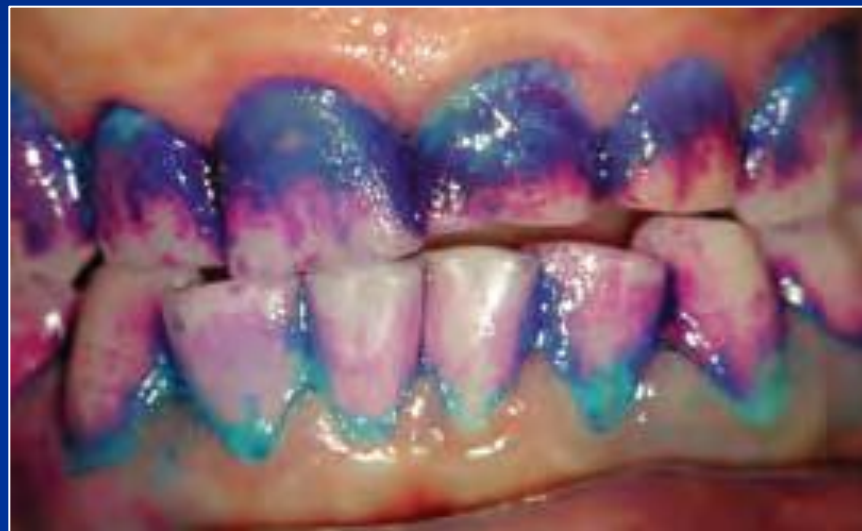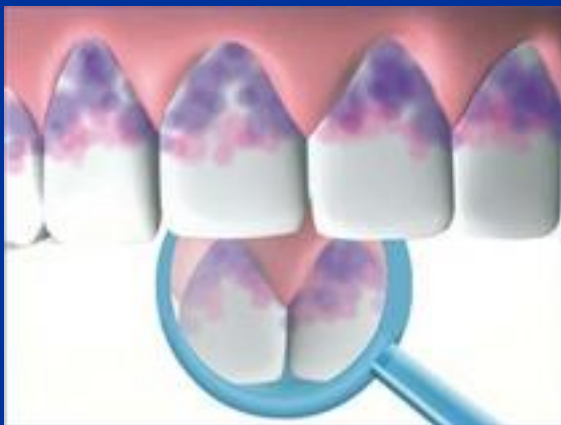Can it be recognised and removed easily?



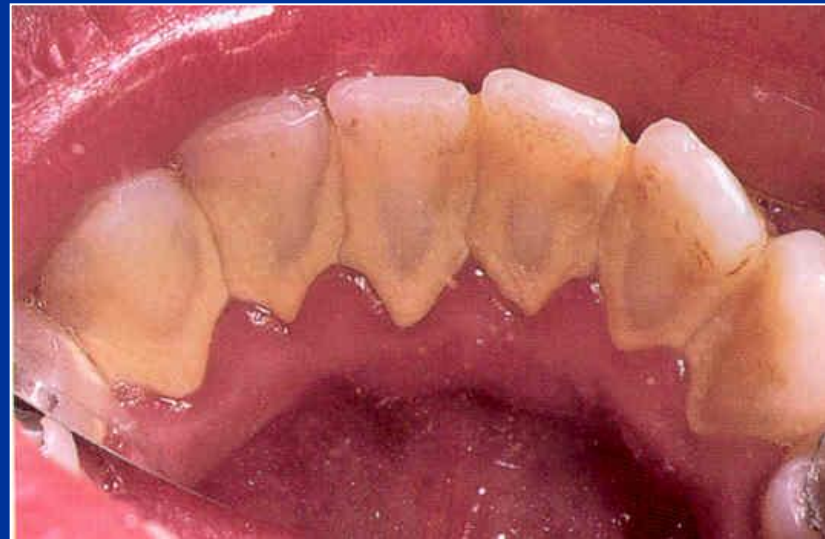
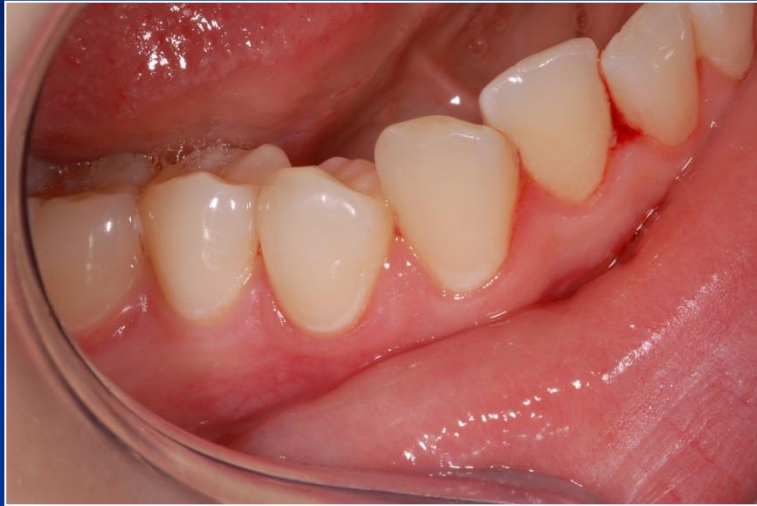
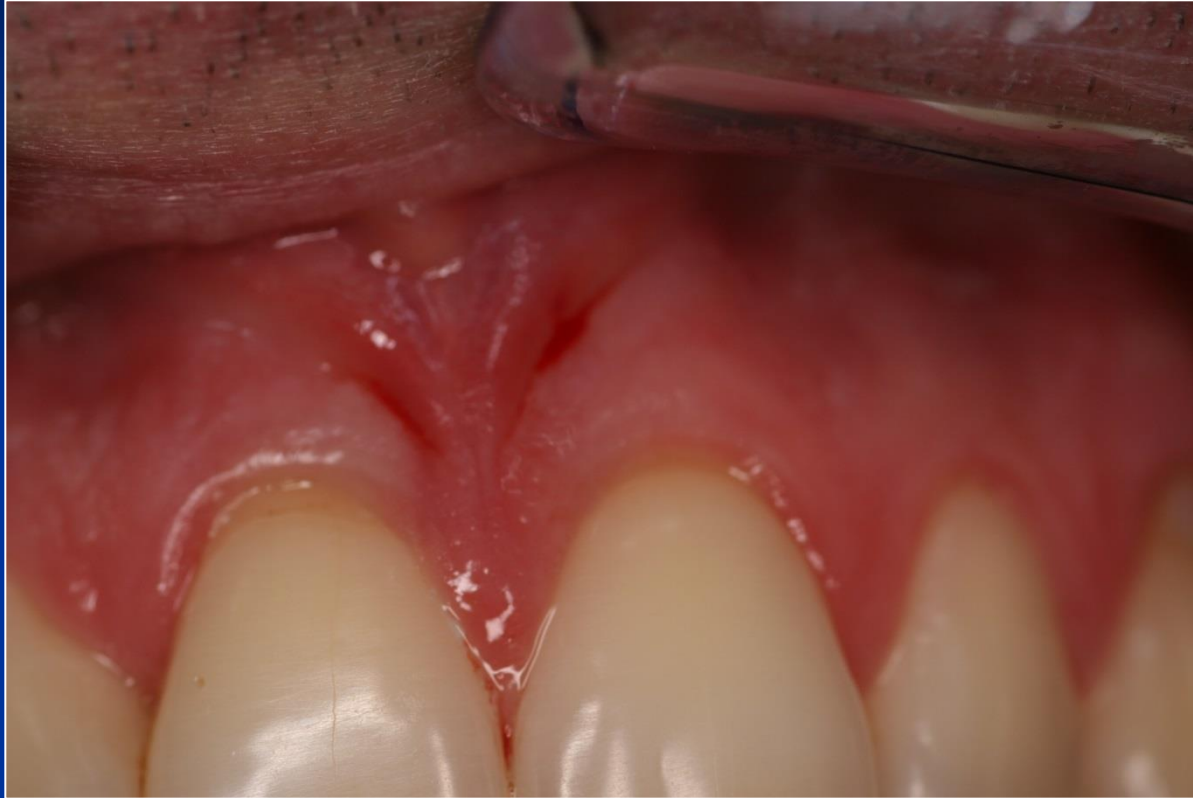Plaque detection

- Special liquids
- Tablets
- Gels



Dental calculus





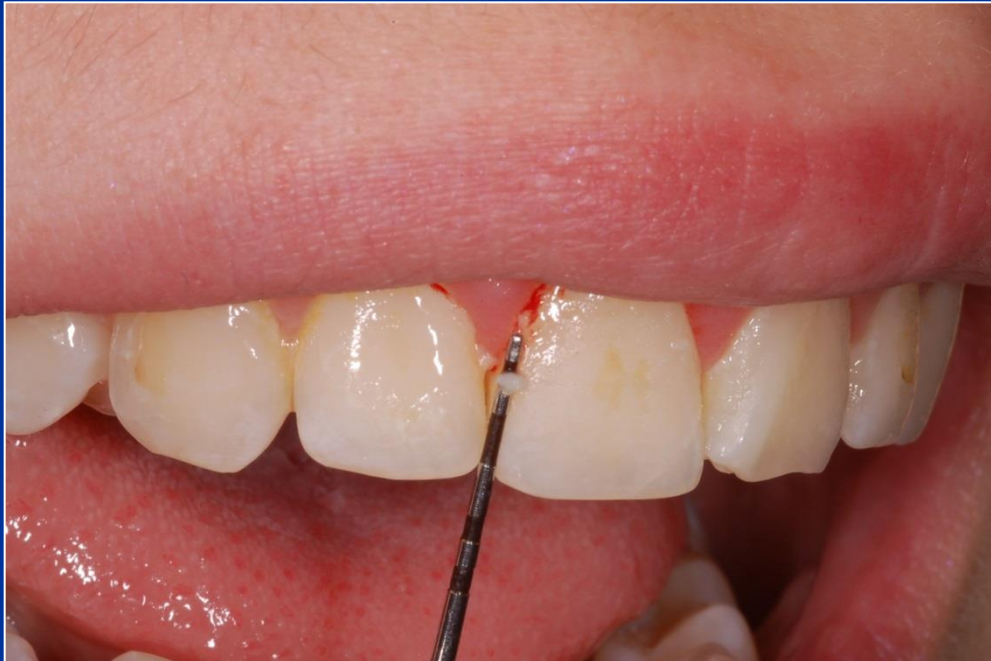Periodontal diseases

- Plaque associated
- Plaque modulated

Parodontopathies

Gingivitis

■ Plaque associated gingivitis



Chronic form

Erythema

No pain

Easy bleeding

Plaque on the tooth

Acute form

Erythema

Pain

Easy bleeding

Plaque on the
tooth

Acute necrotising gingivitis - ANUG

- Necrotizing ulcerative gingivitis

Aetiology

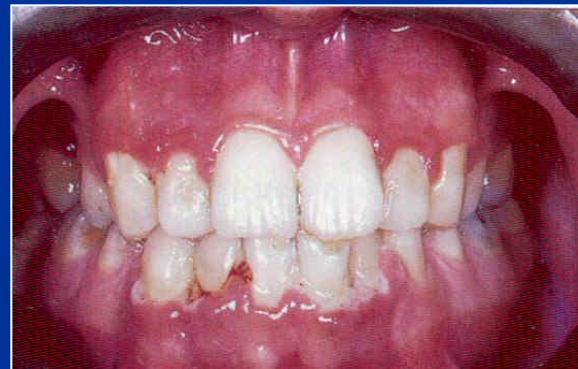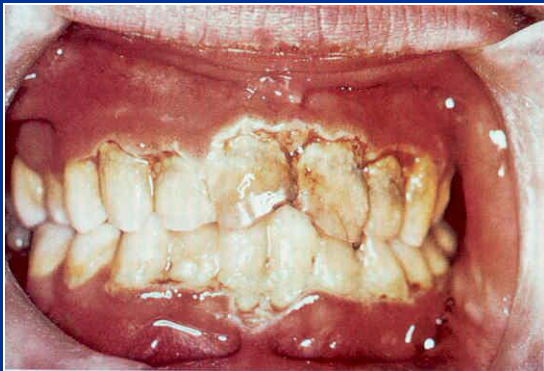Special microbes - anaerobes

The clinical picture

- Gingival inflammation and destruction



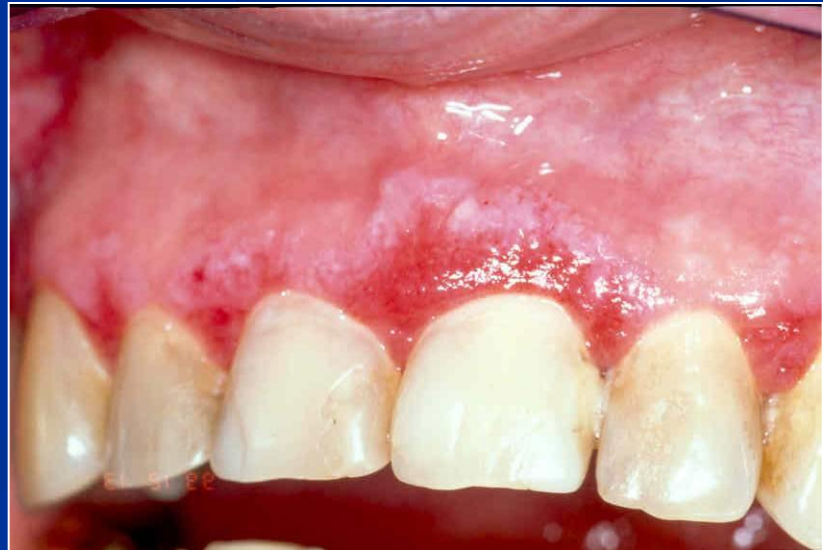Severe pain, bleeding gums, halitosis



Atrophic or desquamative gingivitis

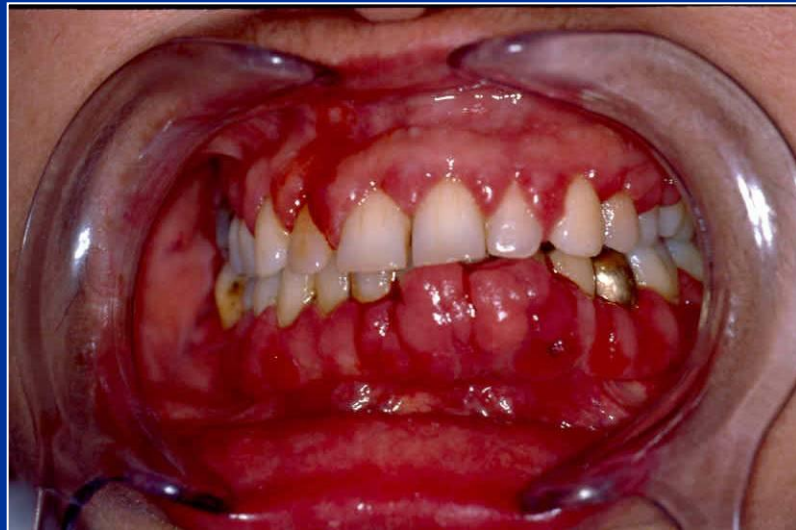
symptoms

- Erythema on free gingiva – loss of the epithelium
- Variety of symptoms: itching, tenderness of eating, burning.



Hyperplastic gingivitis

- High standard of oral hygiene must be achieved!
- Gingivectomy (drugs induced)



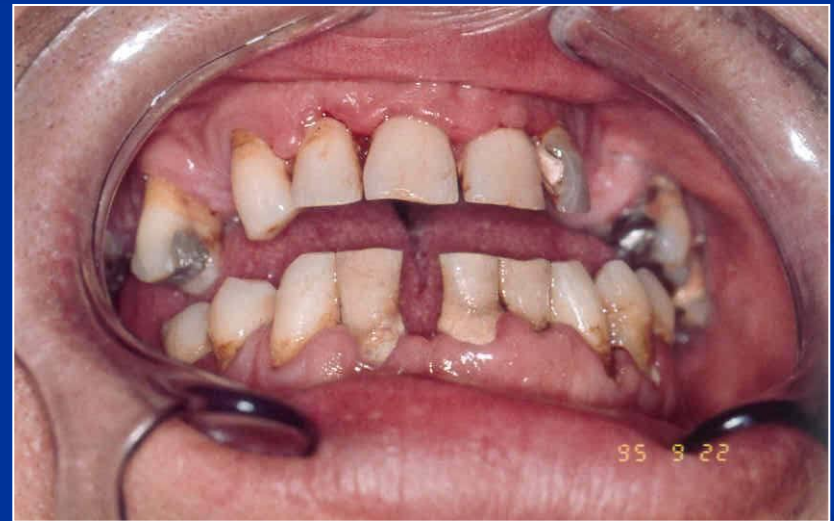Parodontopathies

Periodontitis

- Chronic periodontitis.
- Aggressive periodontitis.
- Periodontitis as a manifestation of systemic disease.
- Necrotizing periodontal diseases.
- Abscesses of the periodontium.
- Periodontitis associated with endodontic lesions.
- Development or acquired deformities and conditions.

Periodontitis

- Gingivitis
- Pocketing
- Loss of alveolar bone
- Drifting and mobility
- Furcation exposures
- Recession

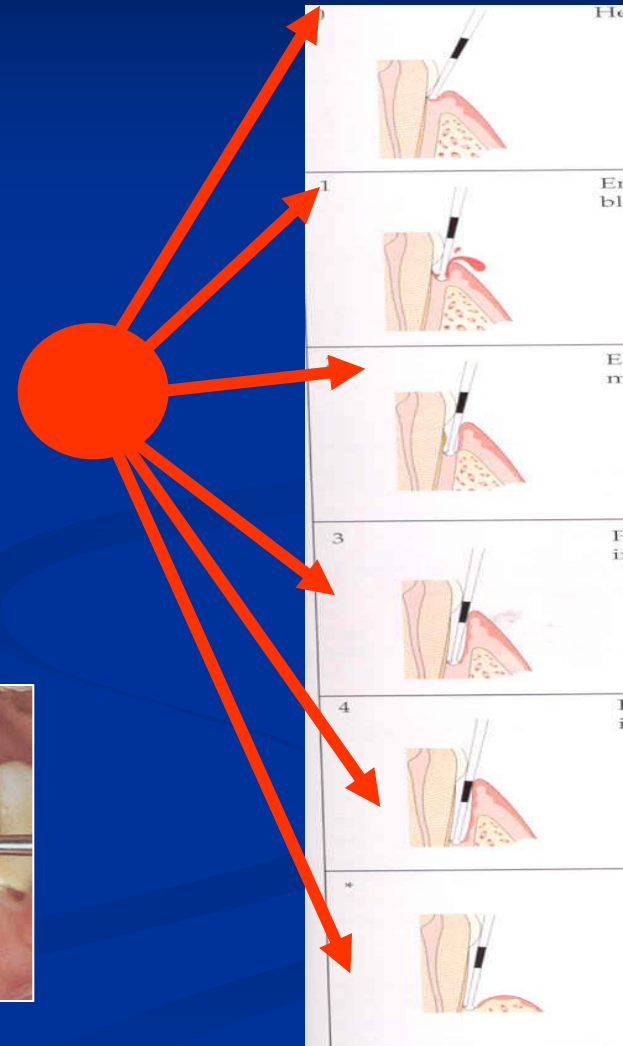
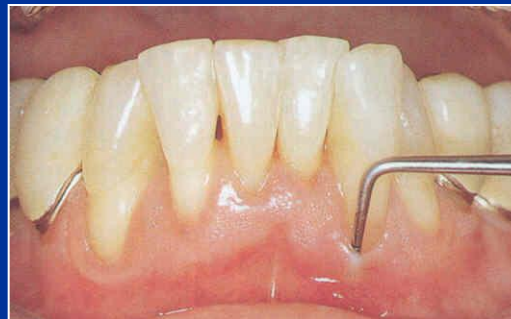

Periodontitis

- Gingivitis
- Pocketing - increasing depth of gingival sulcus
- Loss of alveolar bone
- Drifting and mobility
- Furcation exposures
- Recession

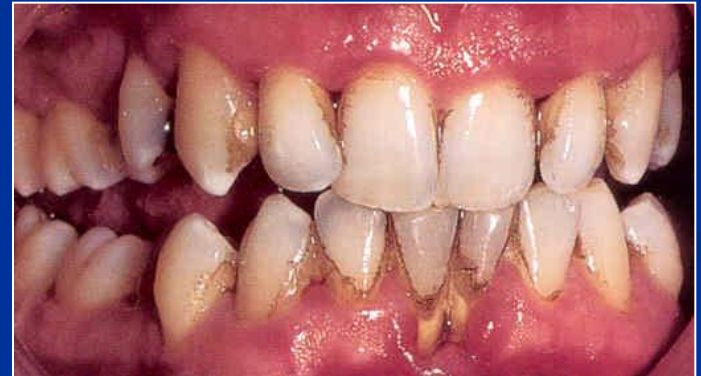Periodontitis

- Gingivitis
- Pocketing
- Loss of alveolar bone
- Drifting and mobility
- Furcation exposures
- Recession



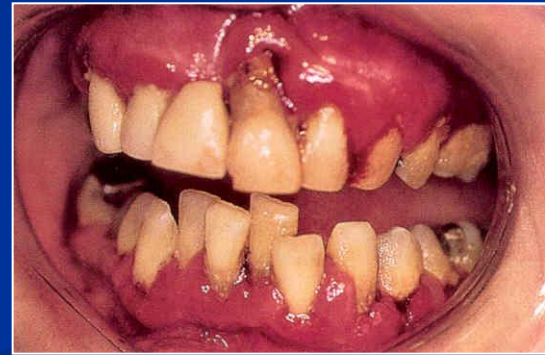Periodontitis

- Gingivitis
- Pocketing
- Loss of alveolar bone
- Drifting and mobility
- Furcation exposures
- Recession



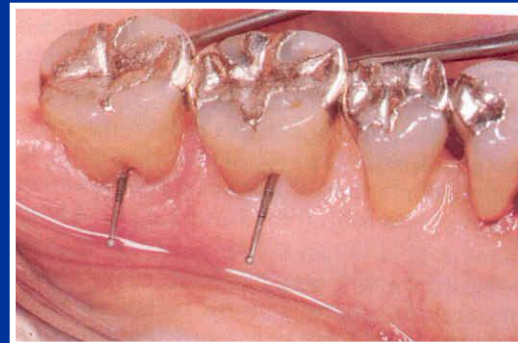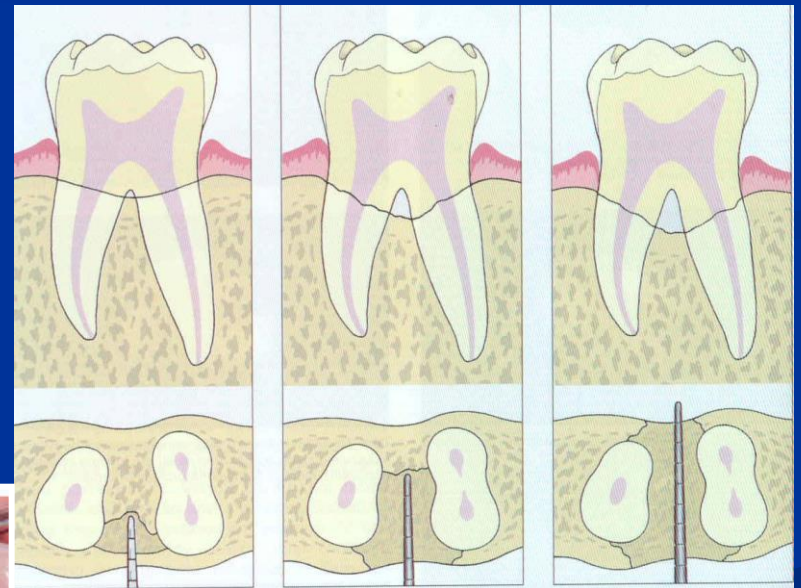

Periodontitis

- Gingivitis
- Pocketing
- Loss of alveolar bone
- Drifting and mobility
- Furcation exposures
- Recession



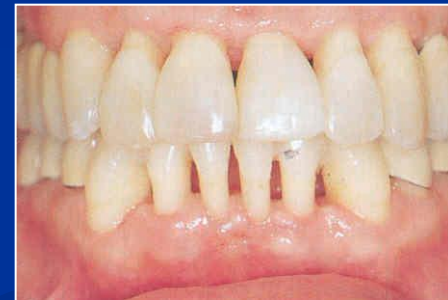Periodontitis

- Gingivitis
- Pocketing
- Loss of alveolar bone
- Drifting and mobility
- Furcation exposures
- Recession



Periodontitis

- Gingivitis
- Pocketing
- Loss of alveolar bone
- Drifting and mobility
- Furcation exposures
- Recession



Periodontitis

- Chronic adult periodontitis
- Aggressive periodontitis
- Early onset periodontitis

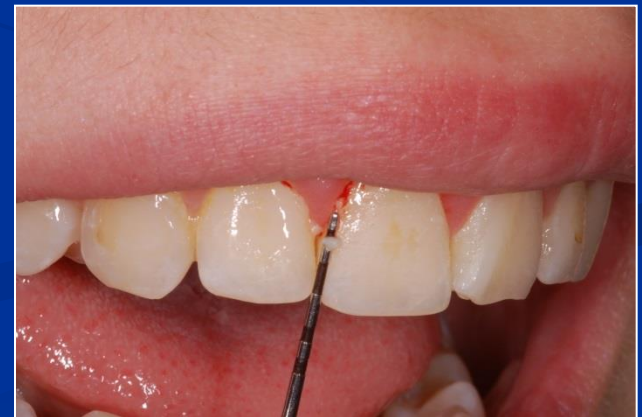Diagnosis

- History
- Clinical examination
 - Level of oral hygiene
 - Periodontal status
- Radiography

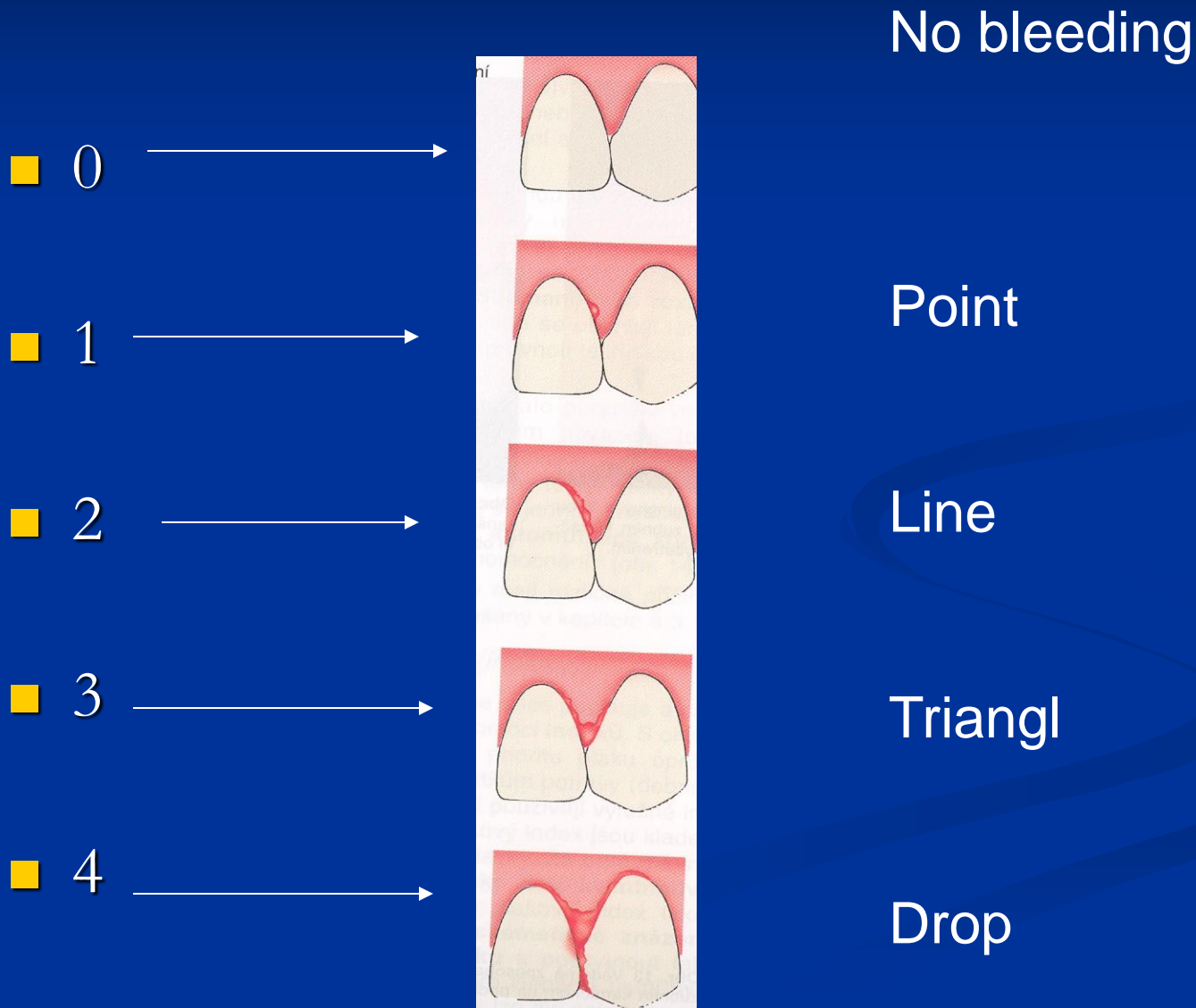
Investigative instruments in periodontology

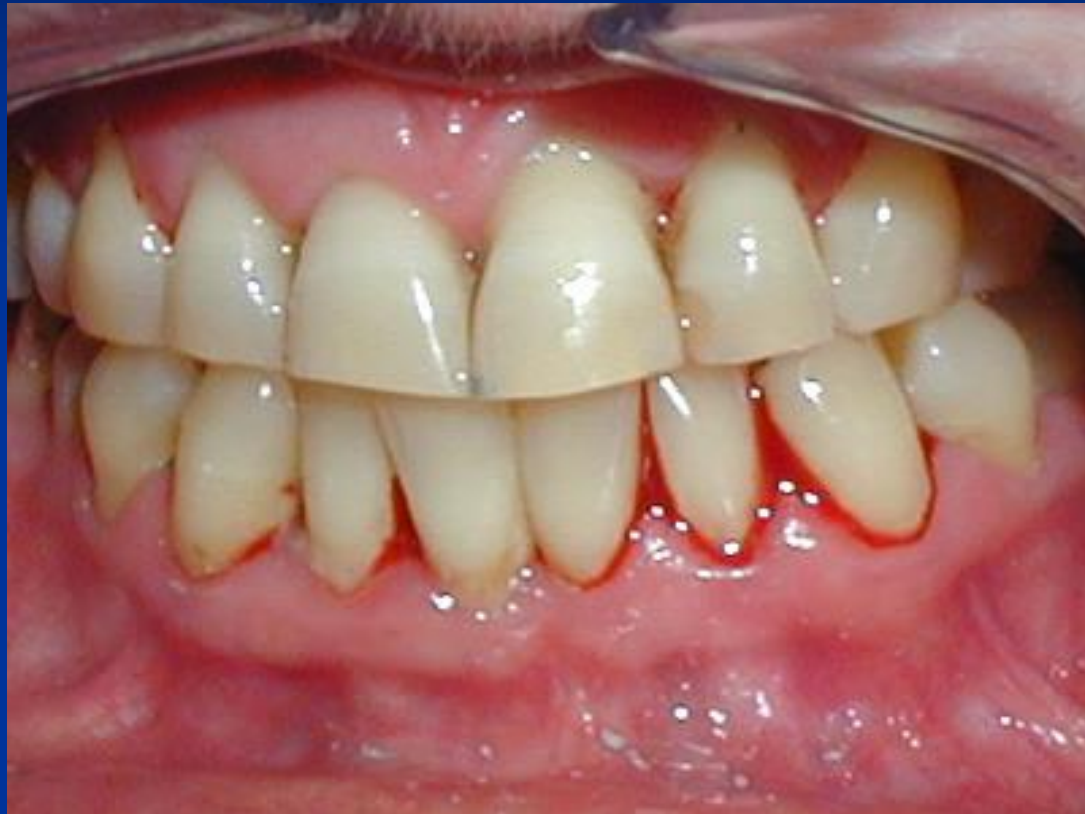■ Periodontal probes

- blunt (no damage of periodontal ligament)
- calibrated (measurement of depth of sulcus or pocket)
- Some with the ball at the end (tactile investigation – calculus)



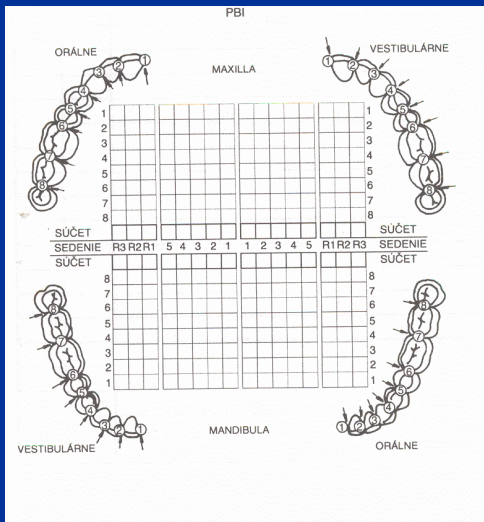
PBI – papilla bleeding index





Importance

- Sume divided with number of investigated points - figure



1	2
3	2
3	1
2	2
1	0
0	2
2	3
<hr style="border: 0; border-top: 1px solid black;"/>	
12	14
1	1
2	2
0	4
0	3
3	4
2	3
1	0
<hr style="border: 0; border-top: 1px solid black;"/>	
9	17

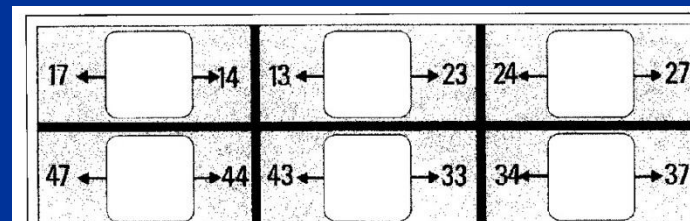

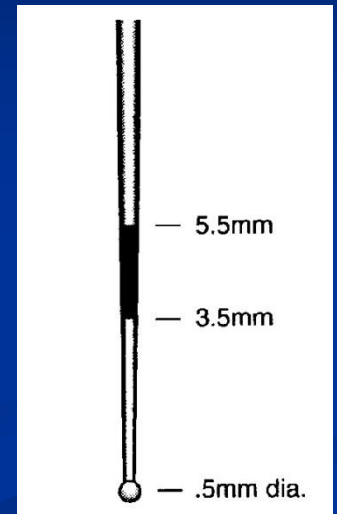
$$52:28 = 1,8$$

$$52/28$$

CPITN

(Community periodontal index of treatment needs)

Kód	Nález	Potřeba ošetření
0	normální	0 bez potřeby léčení
1	krvácení po sondování	I hygienická instruktáž
2	supra- nebo subgingivální zubí kámen, iatrogenní marginální dráždění	II I + supra- a subgingivální scaling
3	choboty 3,5–5,5 mm	
4	choboty > 6 mm	III I + II + chirurgická léčba



CPITN

WHO probe

Slight pressure

Around the teeth

Wait 1 min

CPITN

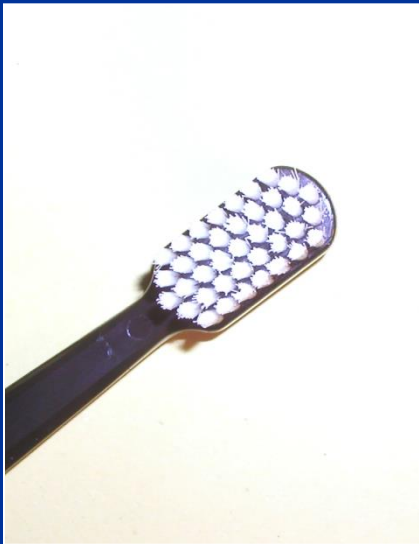- 0 no bleeding
- 1 bleeding
- 2 dental calculus
- 3 periodontal pocket 3 – 5 mm
- 4 periodontal pocket deeper than 5 mm

CPITN

- 0 -no therapy
- 1 bleeding – improve oral hygiene
- 2 dental calculus – professional oral hygiene, home care
- 3 periodontal pocket 3 – 5 mm complex periodontal therapy – more conservative
- 4 periodontal pocket deeper than 5 mm – complex periodontal therapy including surgical

Therapy

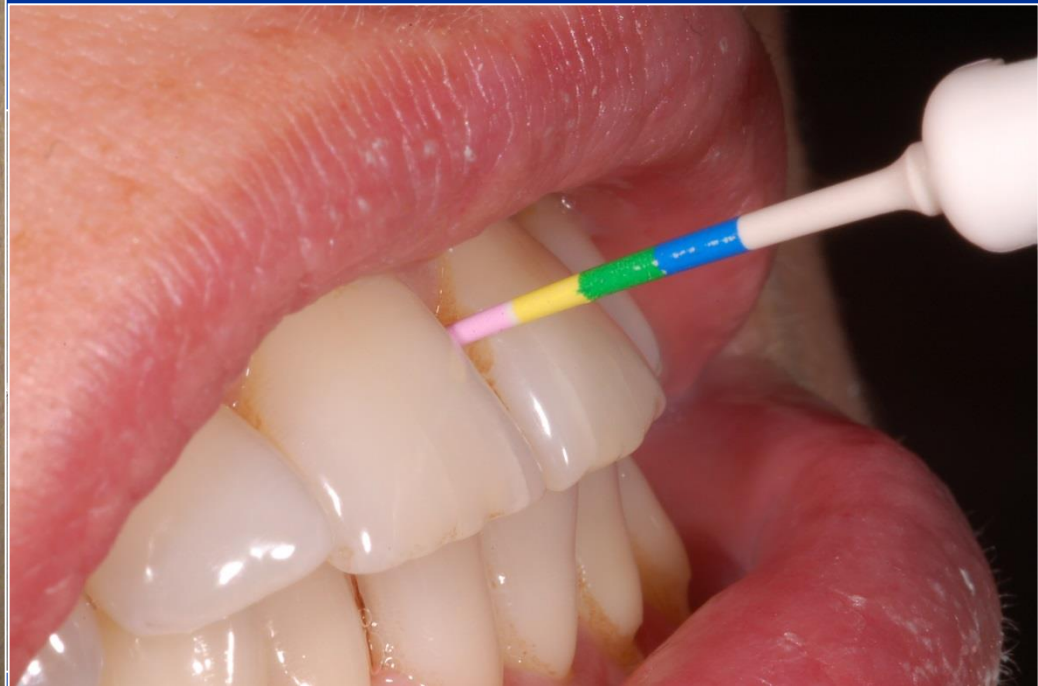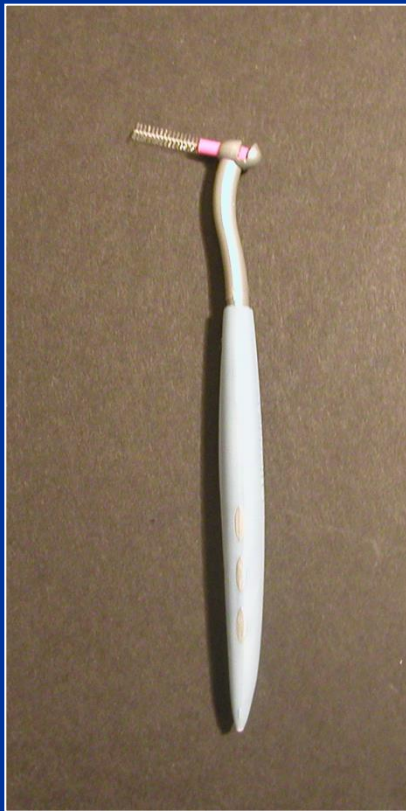- 1. Oral hygiene - professional, home care
INDIVIDUAL



Therapy

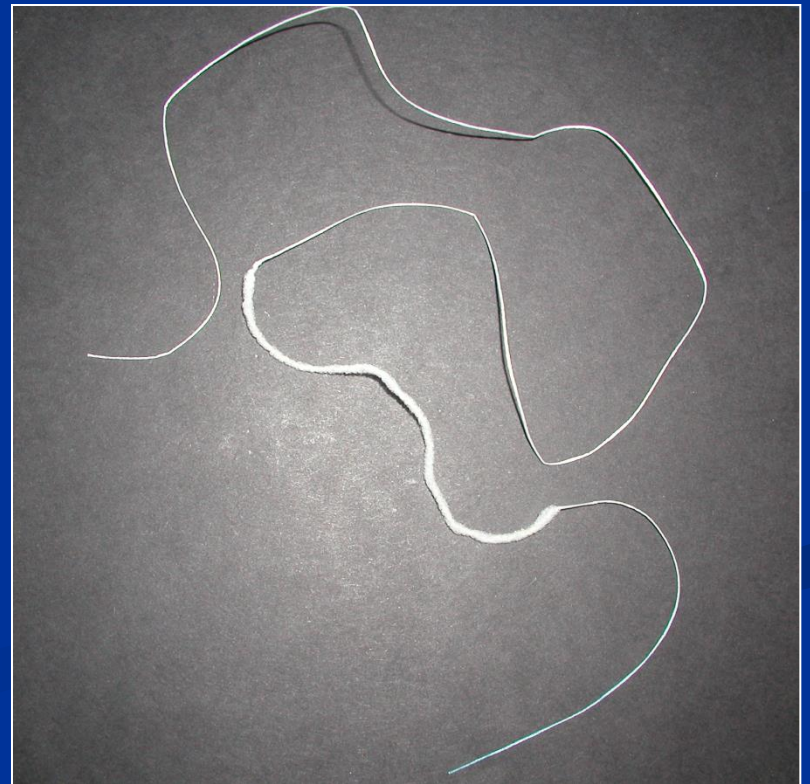

- 1. Oral hygiene - professional, home care

INDIVIDUAL



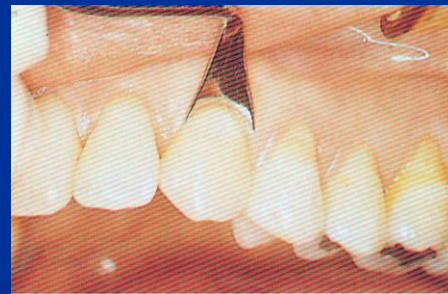
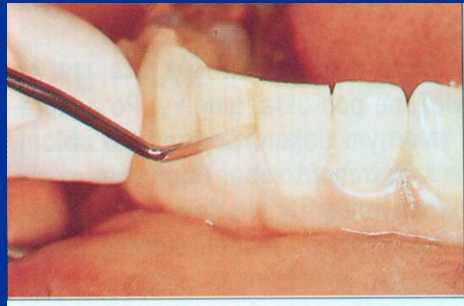
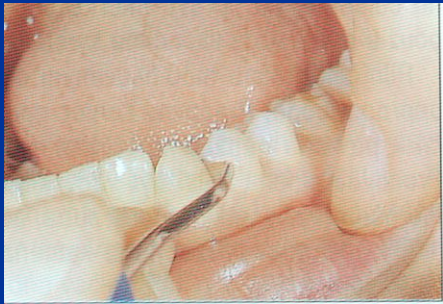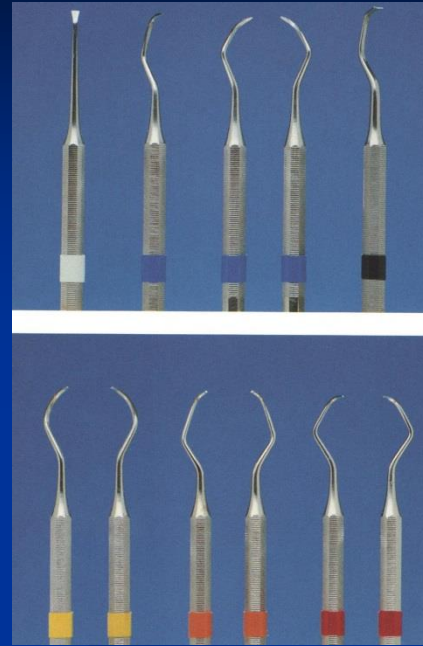
Therapy

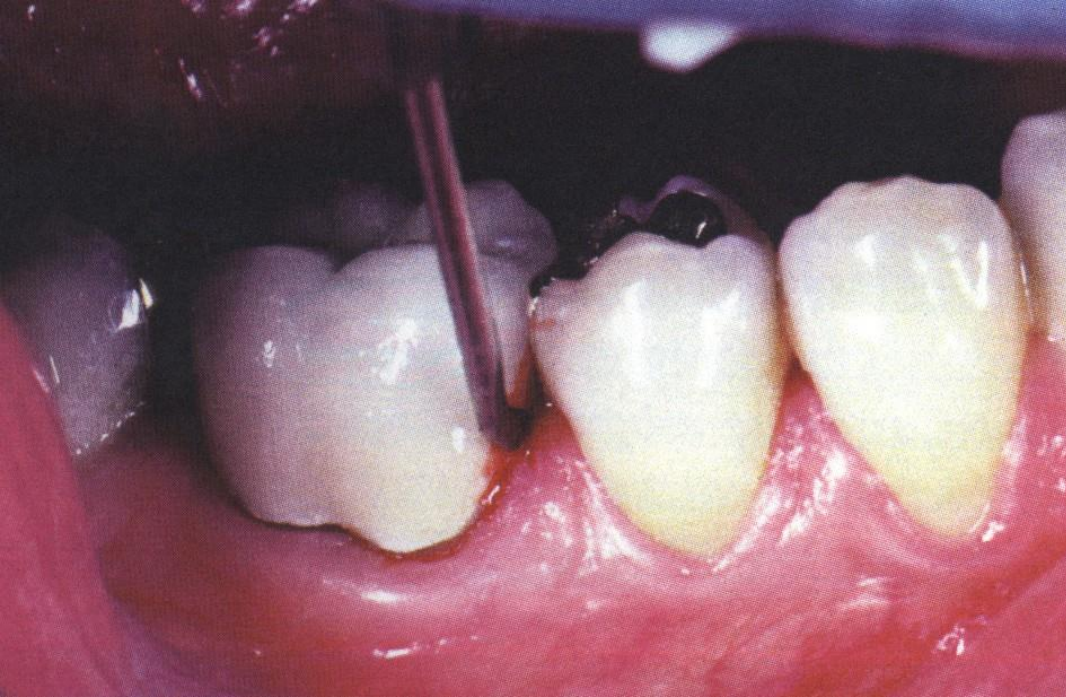
- 1. Oral hygiene - professional, home care
INDIVIDUAL



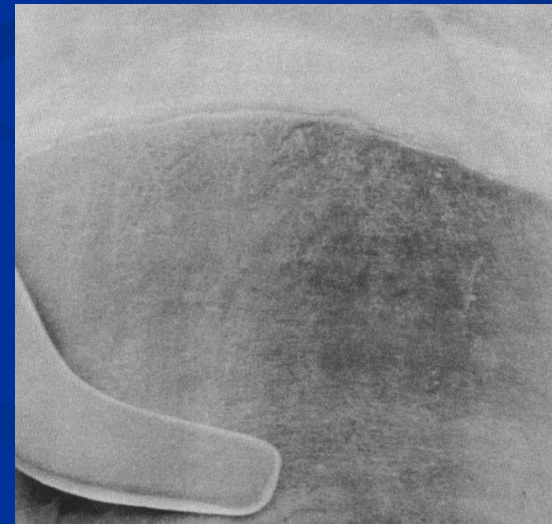

Scalers

sharp pointed instruments
removal supragingival calculus only





Sonic and ultrasonic scalers



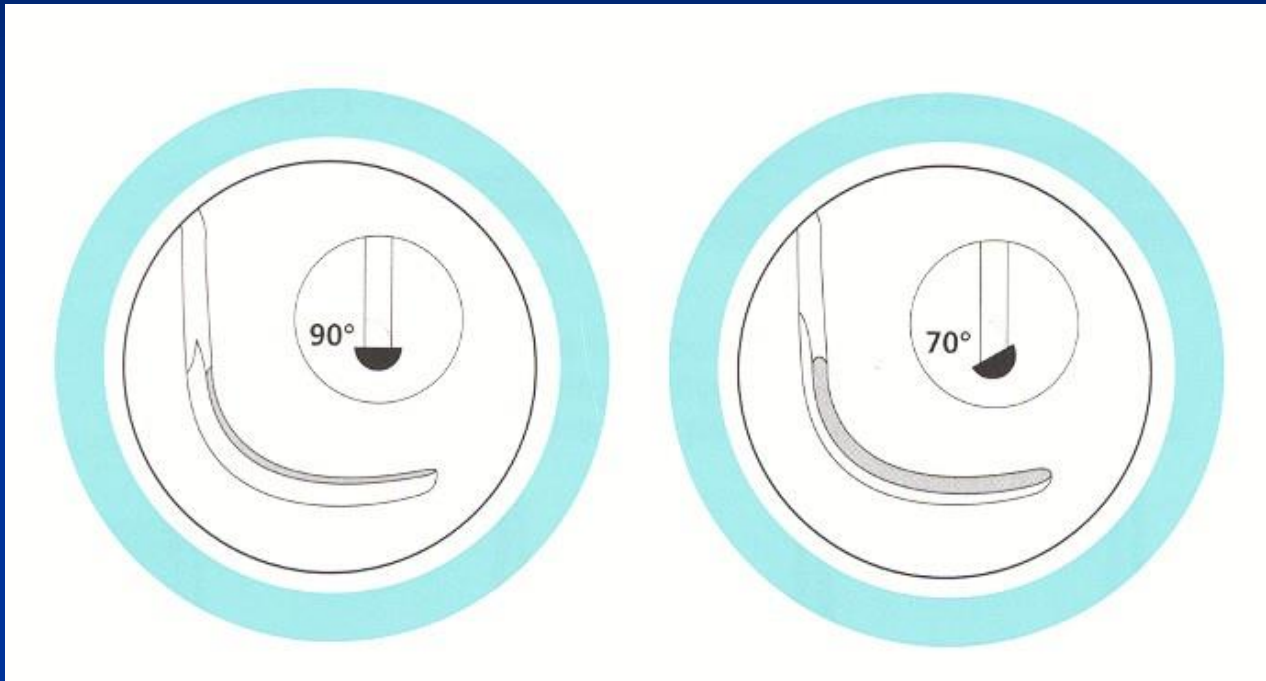Air flow



Currettes

- Sharp spoons for subgingival treatment
- Not pointed
- Two sharp blades - universal
- One sharp blade - special

Universal and special curette



Universal

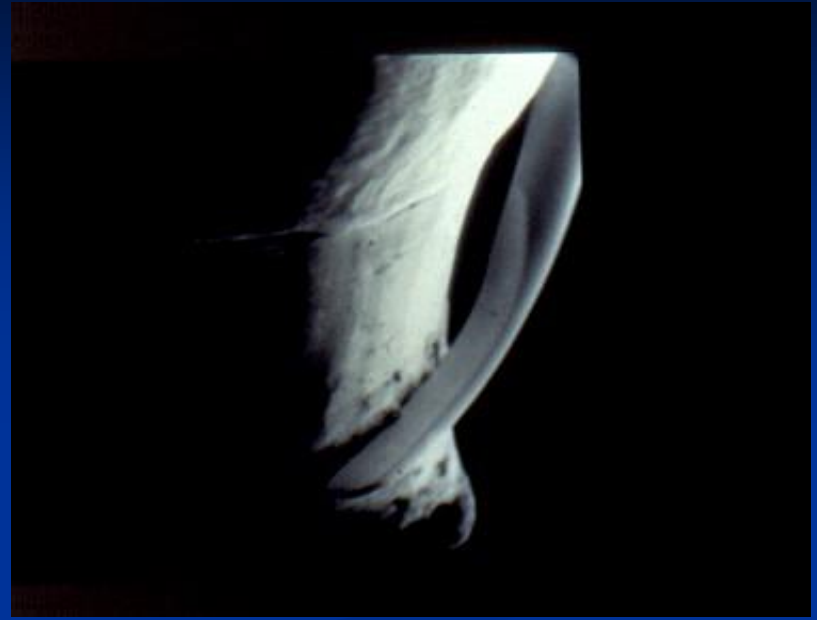
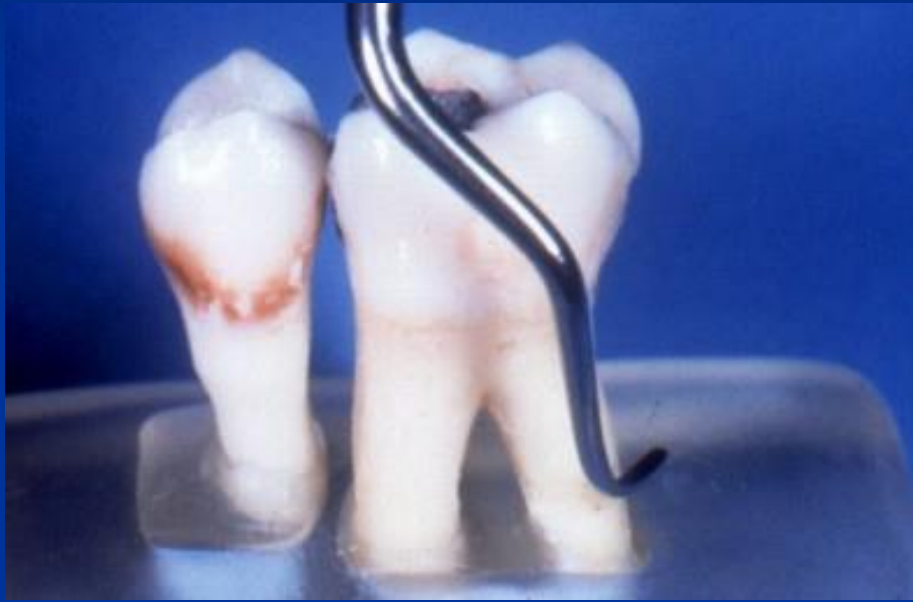Working part and shaft 90°

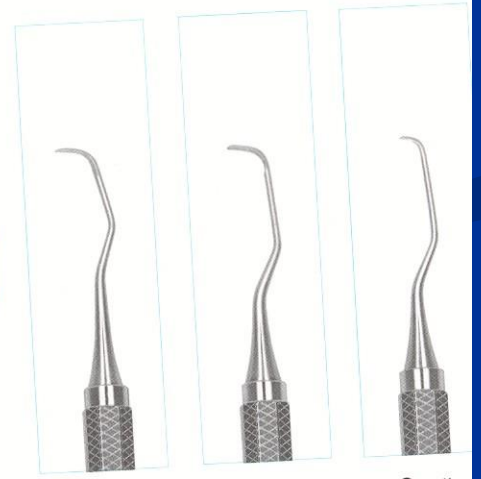
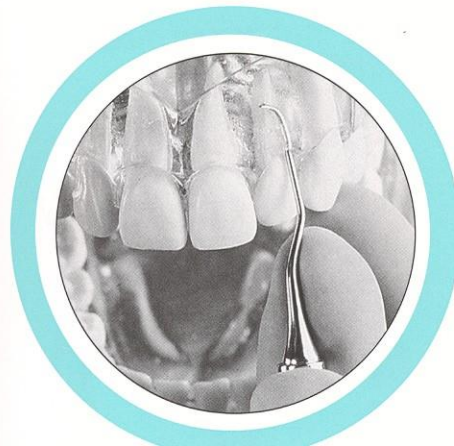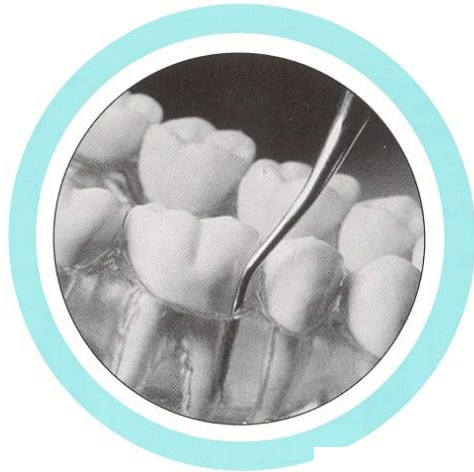
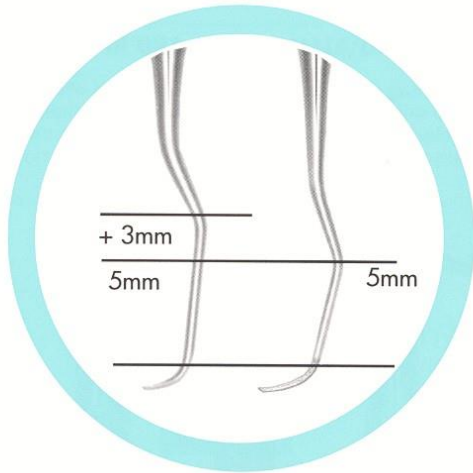
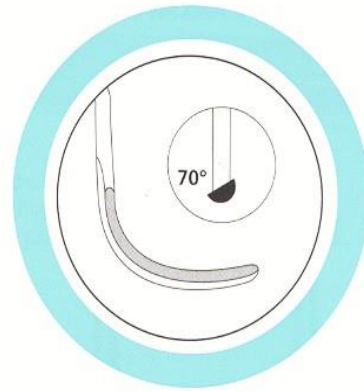
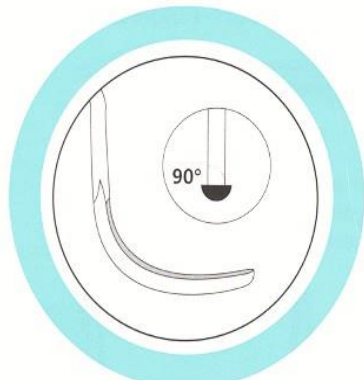Cut also soft tissue

Special

Working part and shaft 70°

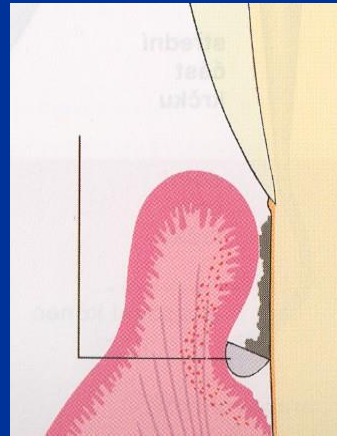
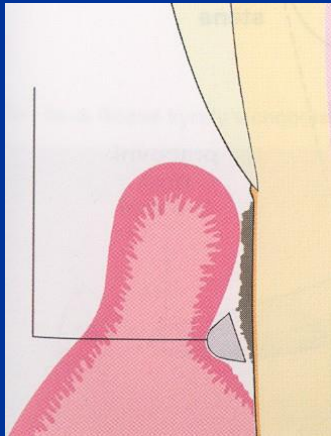
Clean only root of the tooth

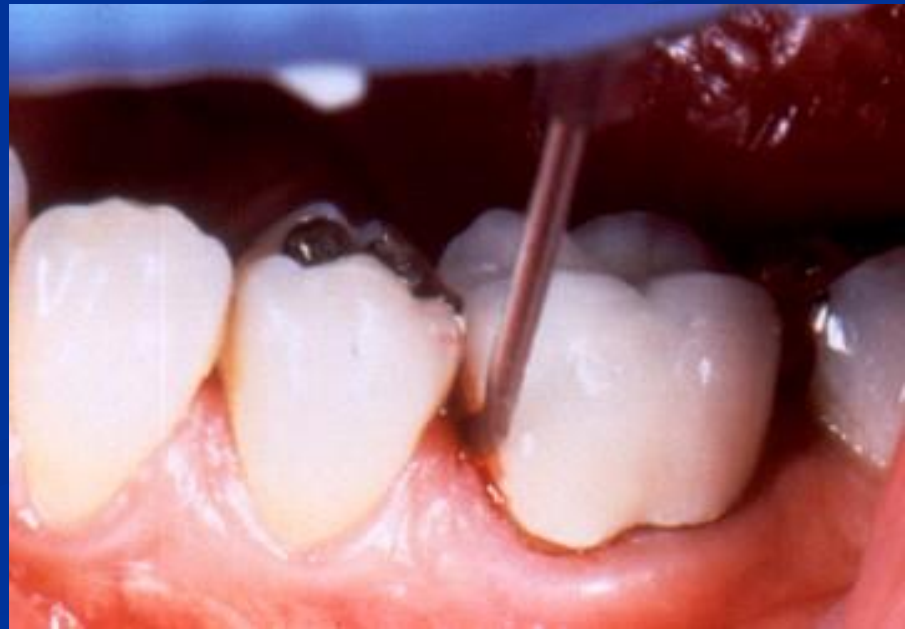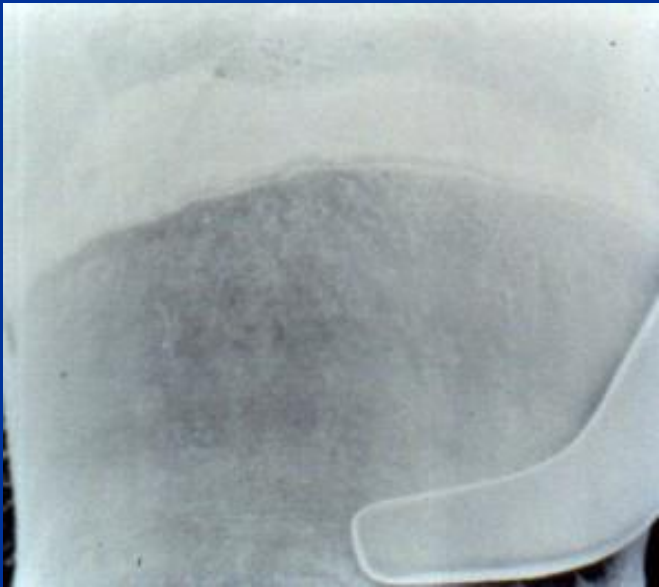

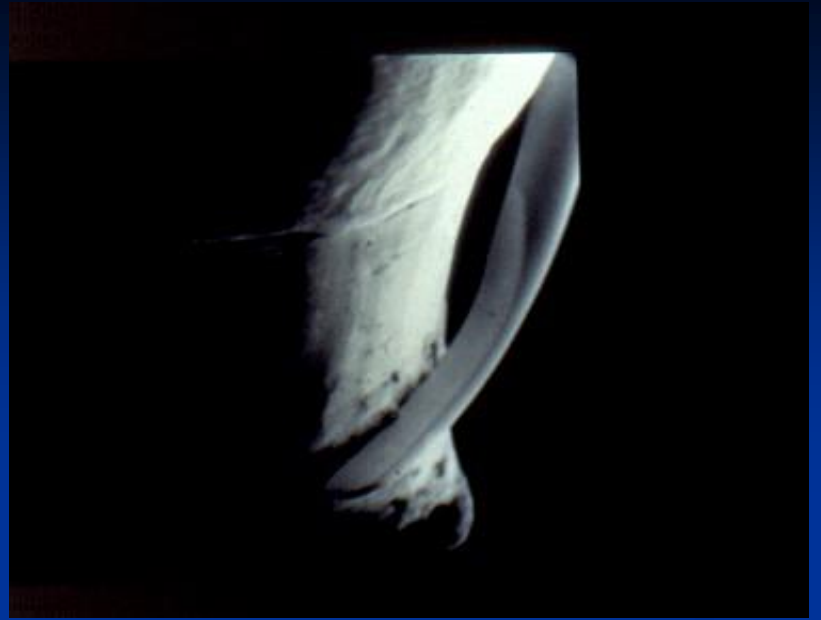
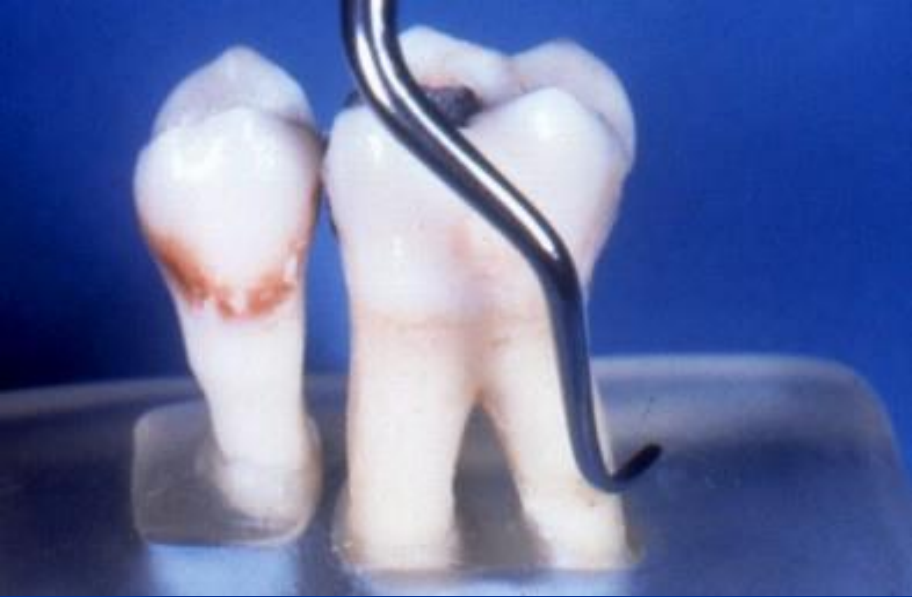

Scaling, root planing

- Action of the curette



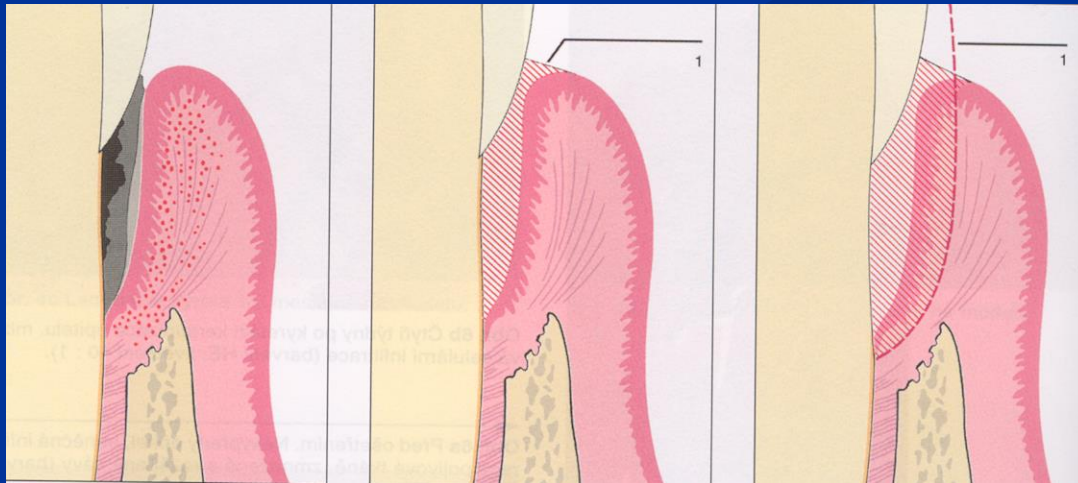



Therapy

- Oral hygiene
- Scaling – root planning
- Surgery
- Prosthetic treatment
- Recall

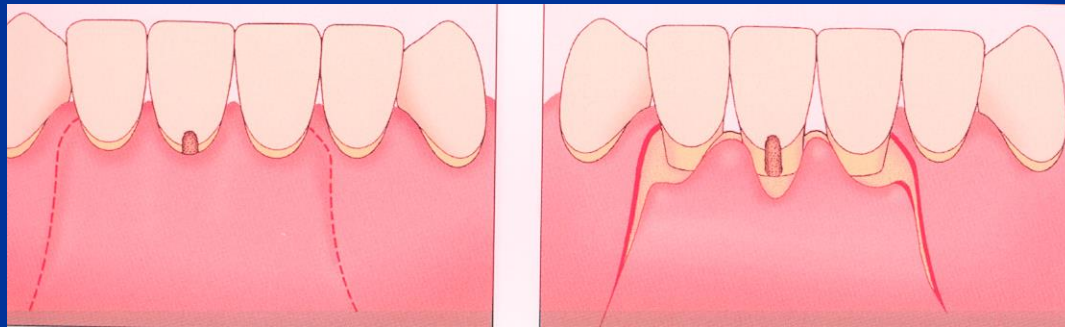
Therapy

- 2. Subgingival treatment – scaling root planing, curettage



Therapy

- 3. Periodontal surgery

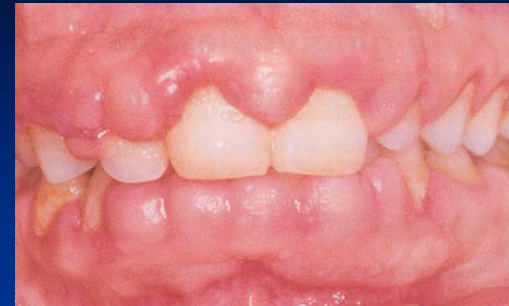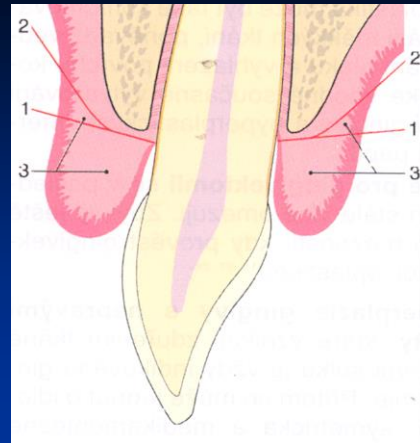


Gingivectomy, gingivoplasty

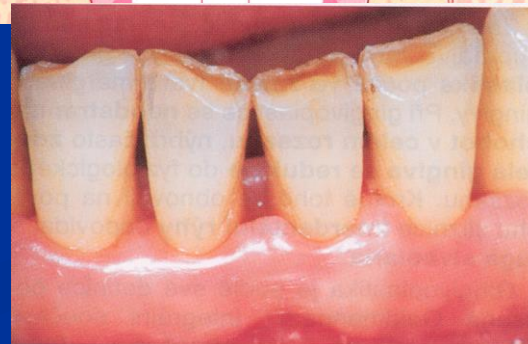
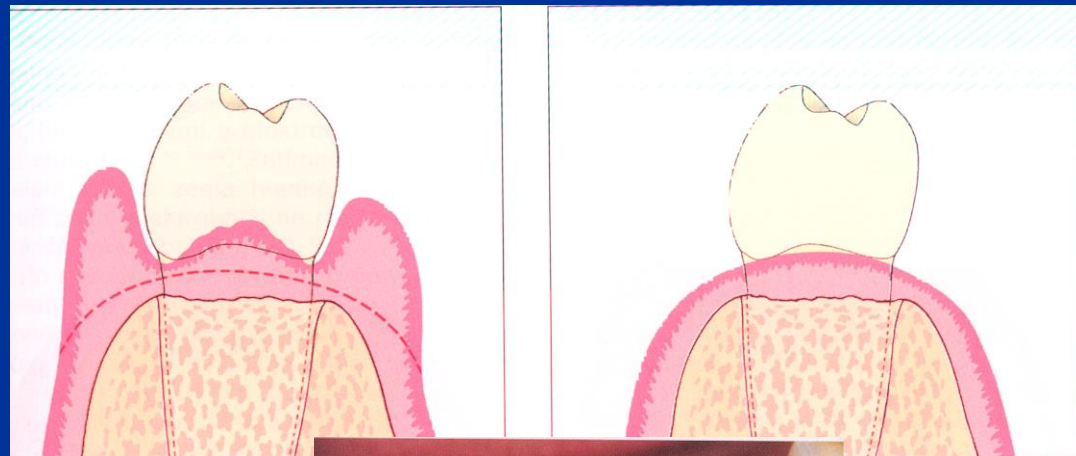
Indications of gingivectomy

- Hyperplasia gingivae (pseudopockets)
- Supraalveolar periodontal pockets with the horizontal bone resorption
- - Bad configuration of the gingival margin or papilla fol. ANUG or extraction.

Gingivectomy

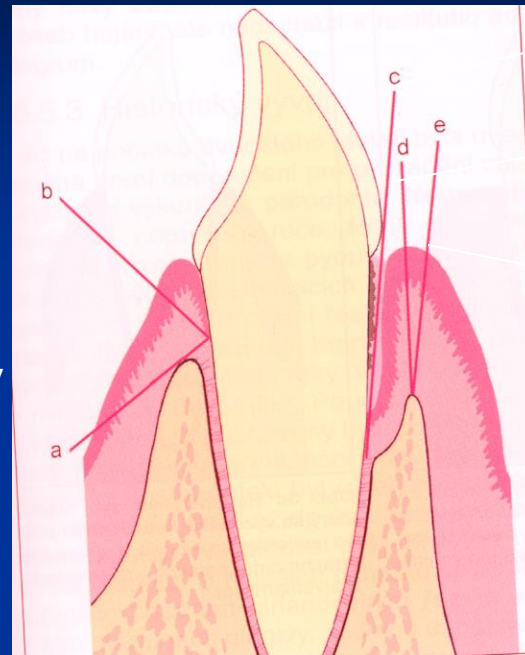


Gingivoplastic



Internal gingivectomy

External gingivectomy



Intrasulcular

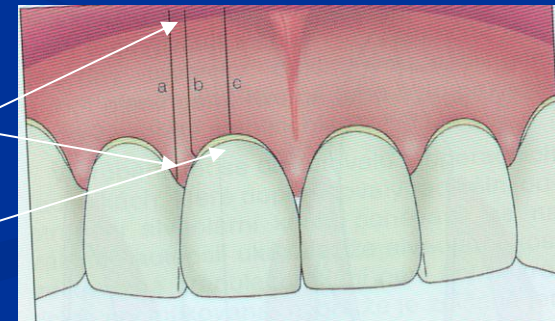
Marginal

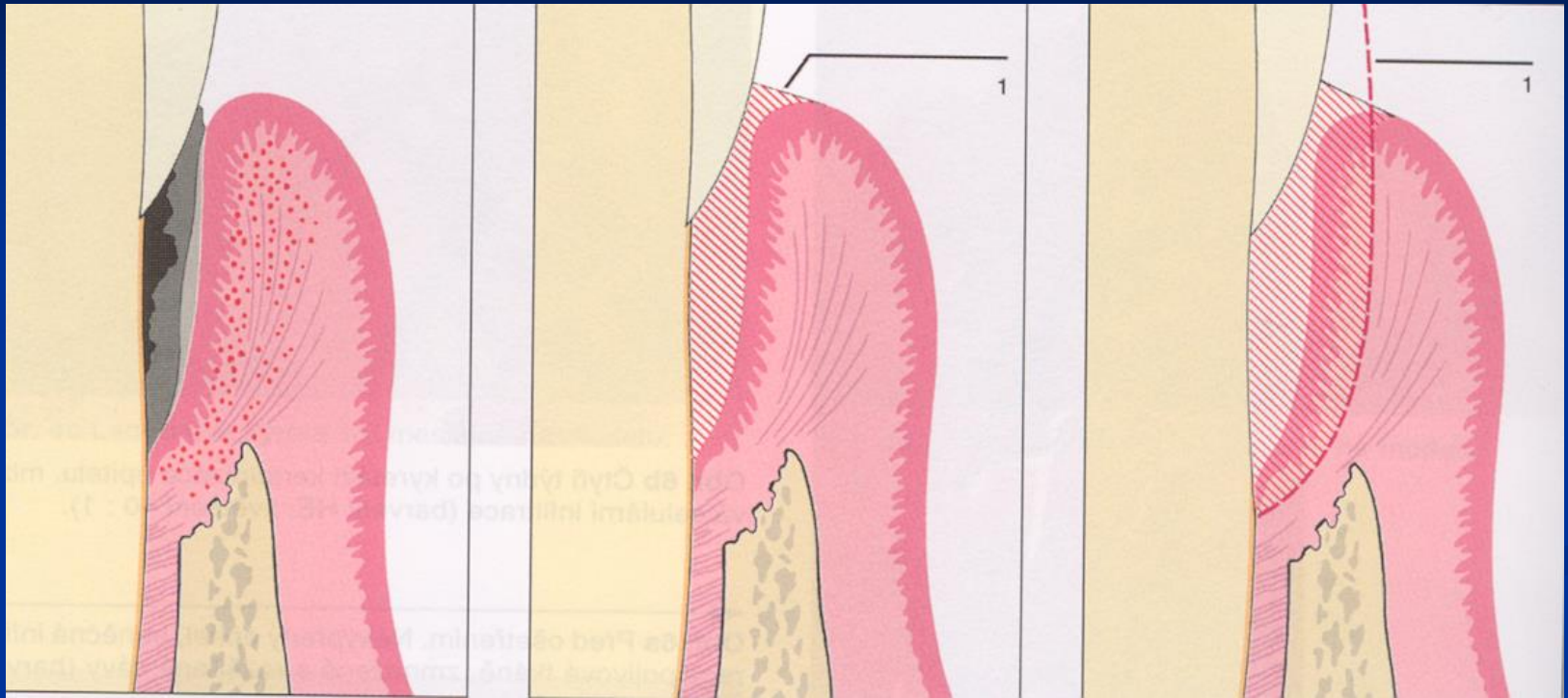
Paramarginal

Papilar

Paramedial

Medial





Closed curettage

Flap operation

Modified Widman flap

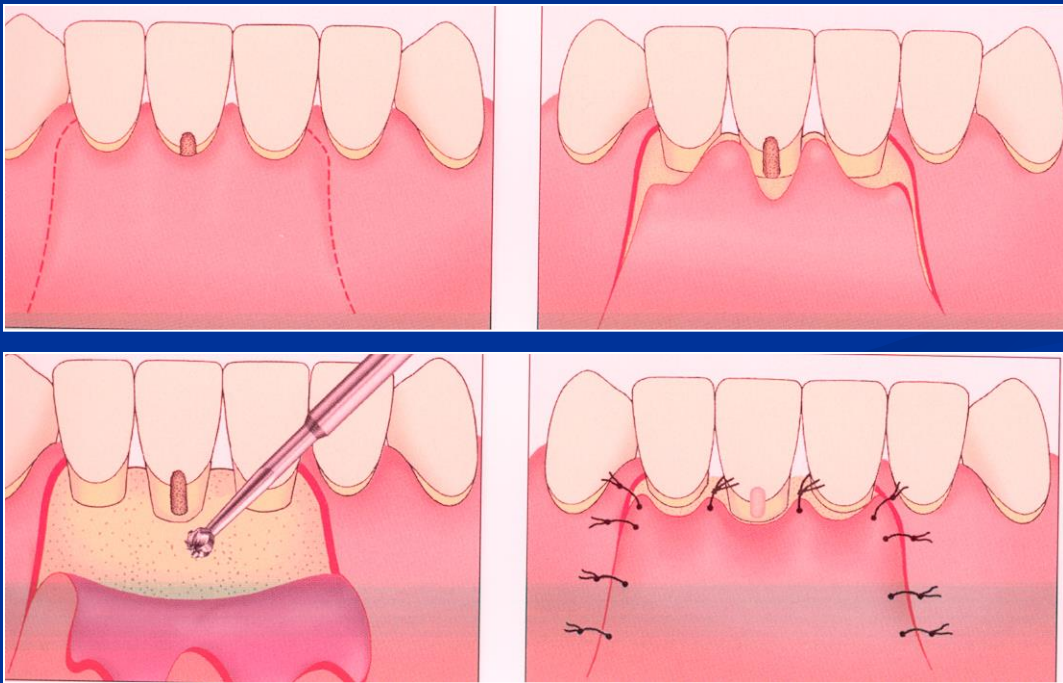
Apical flap, replaced flap

Papilla preservation technique

Wedge excision

Apical flap

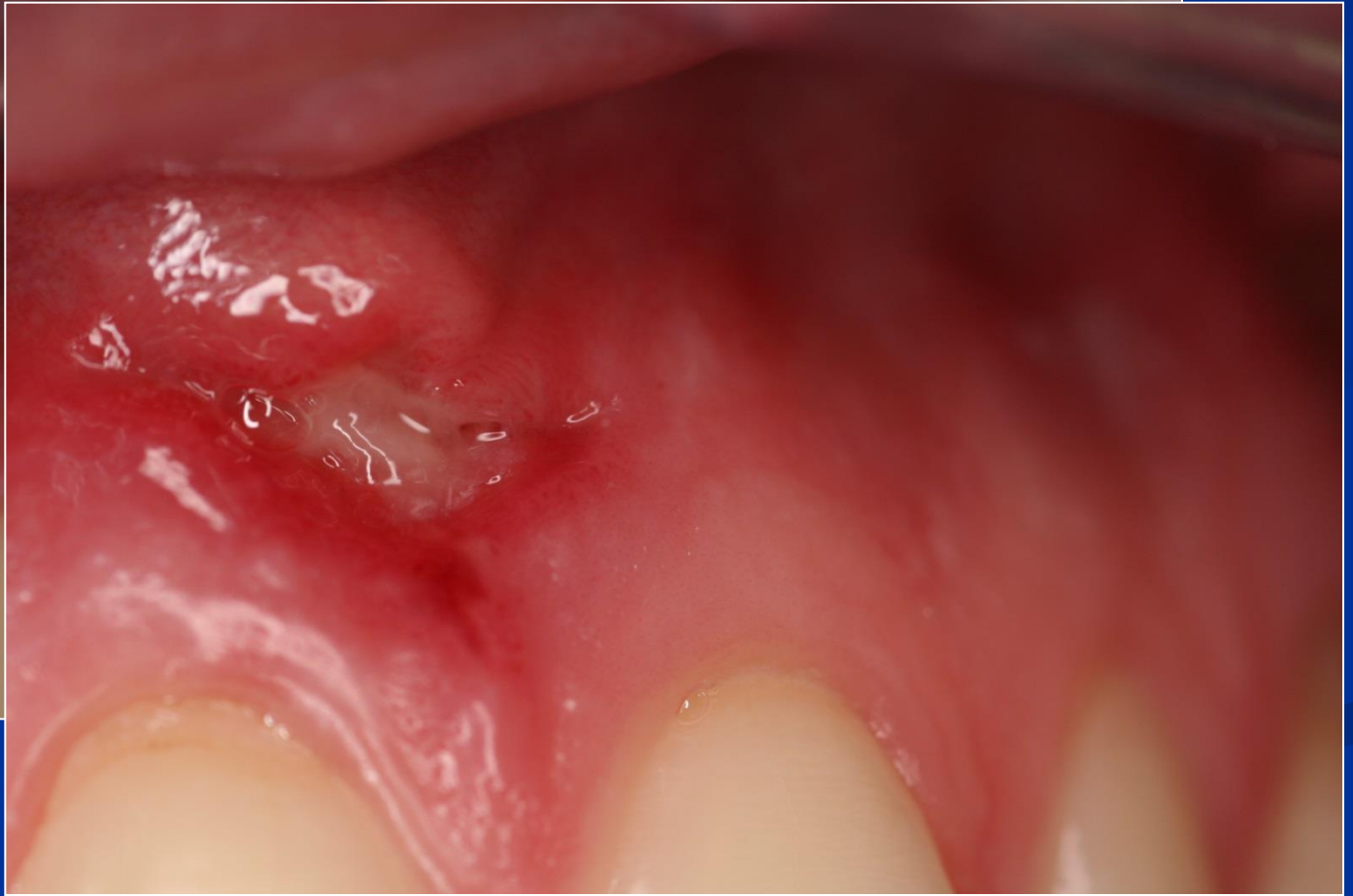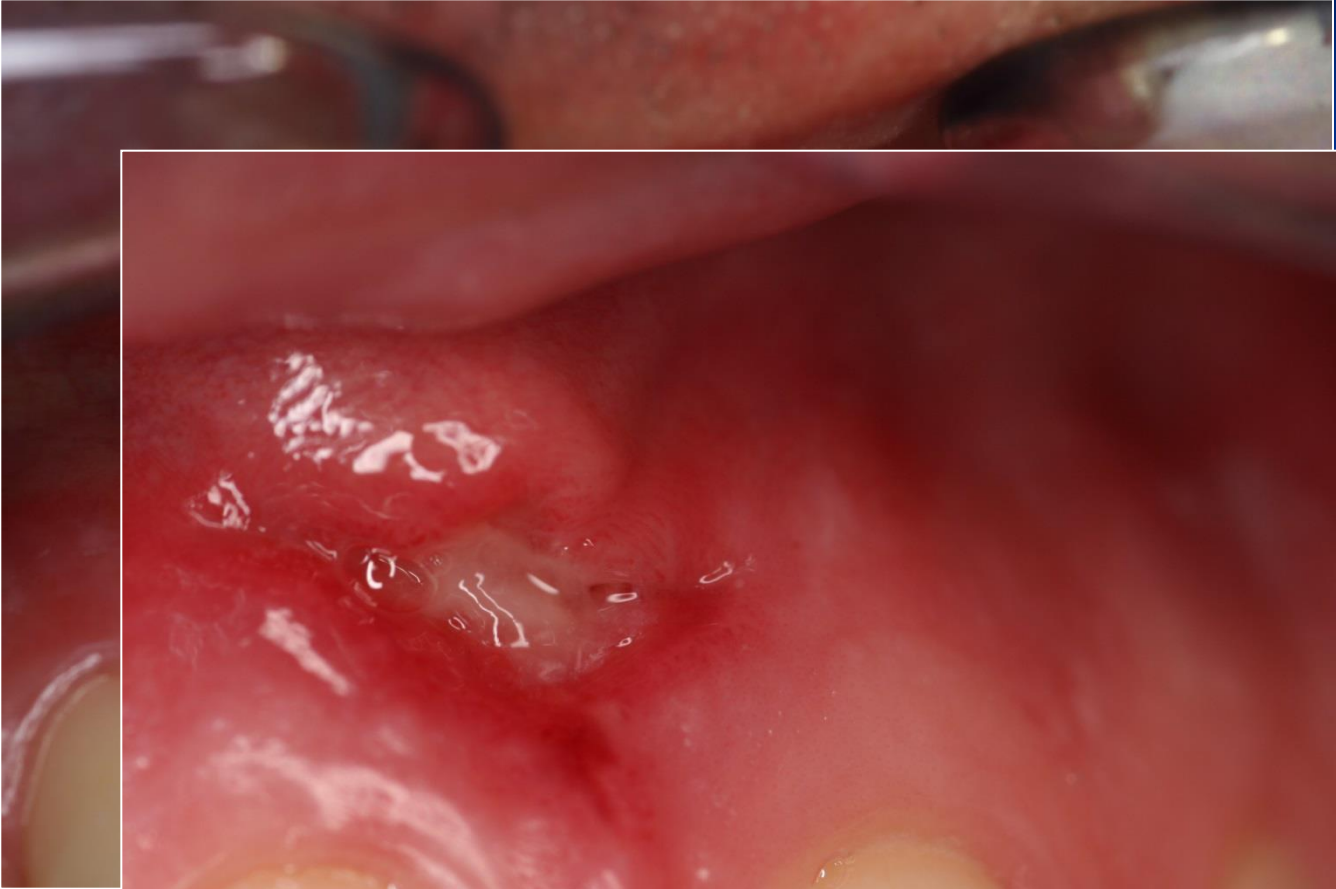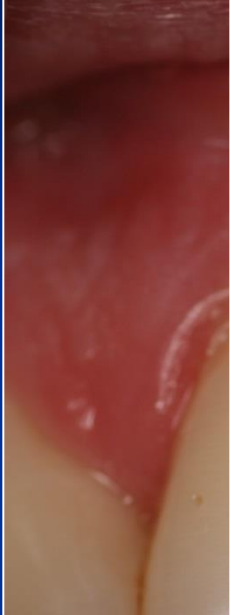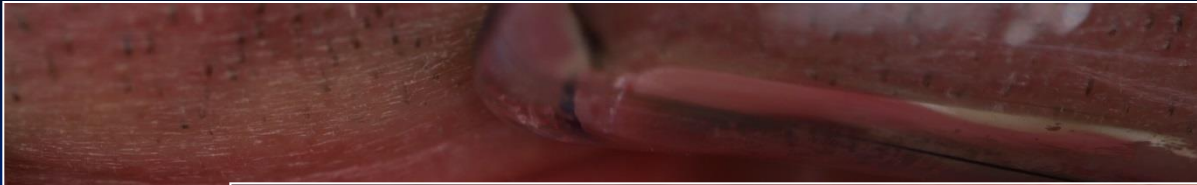
Replaced flap



Mucogingival surgery

- Enlargement of attached gingiva
 - Frenulectomy
 - Vestibuloplastic

- Plastic of recessus
 - Lateral flap
 - Bridge flap
 - Mucous or mesenchymal grafts



Graft

Bone regeneration

Tissue engineering.....

