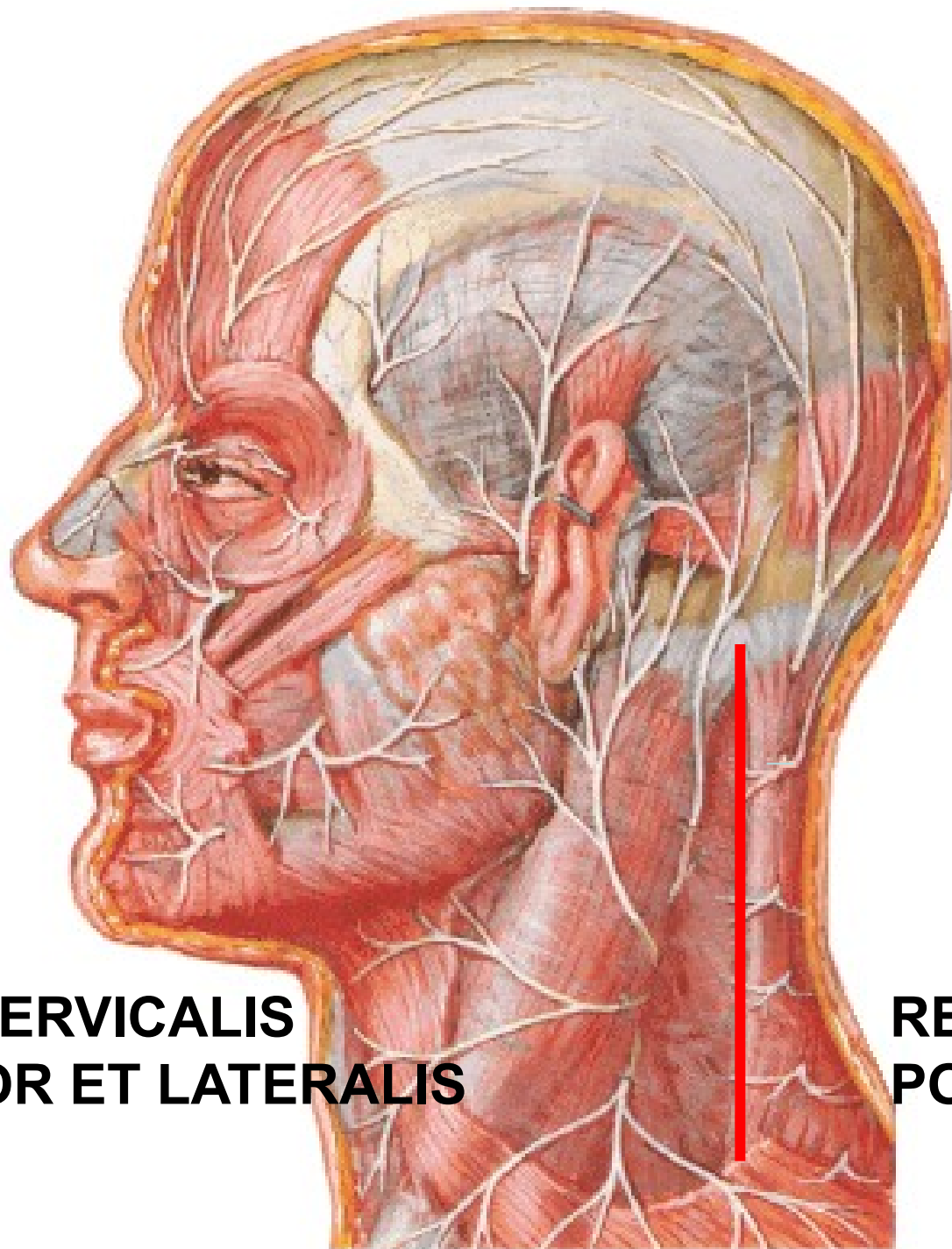
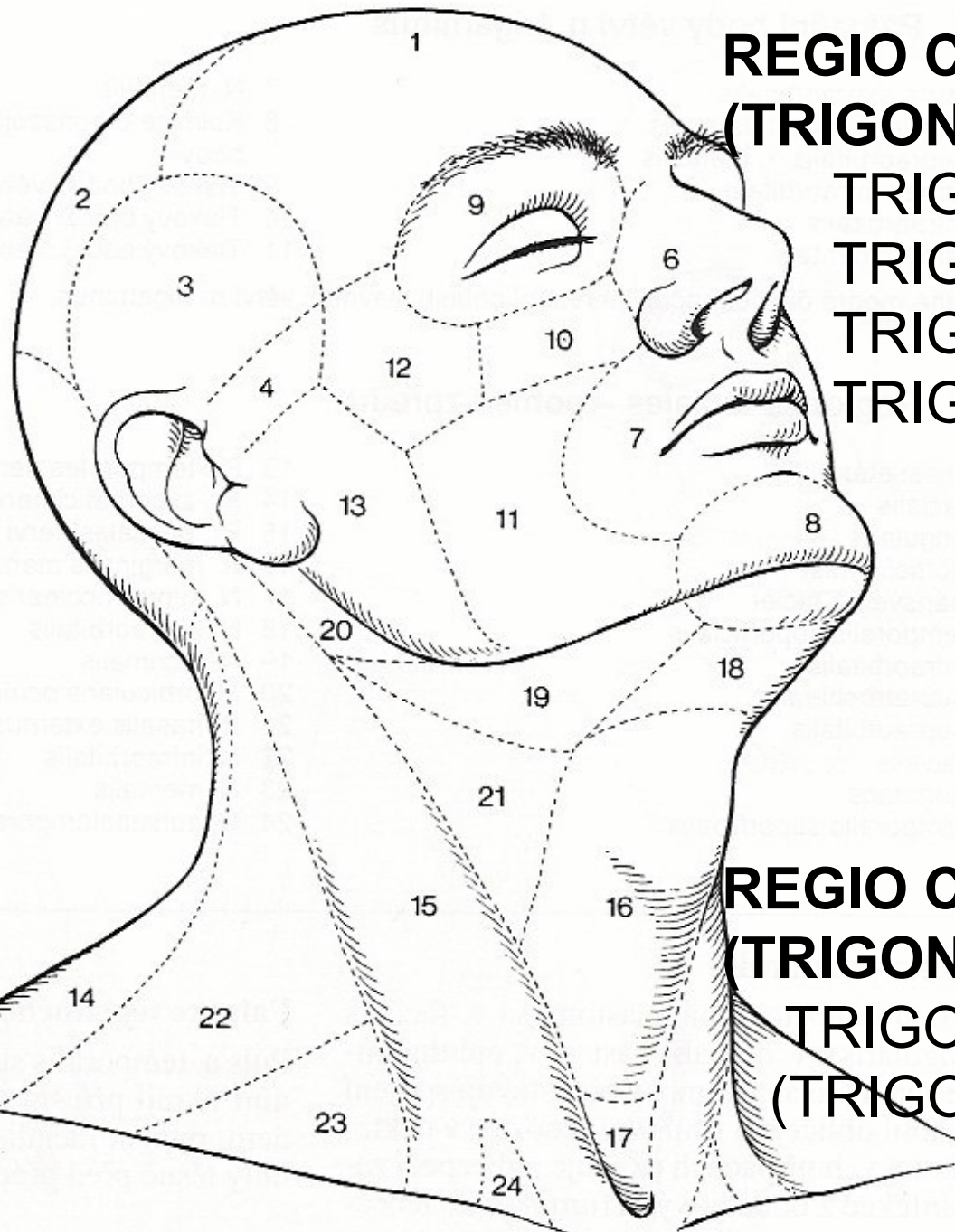


REGIONAL ANATOMY OF THE NECK



**REGIO CERVICALIS
ANTERIOR ET LATERALIS**

**REGIO CERVICALIS
POSTERIOR**

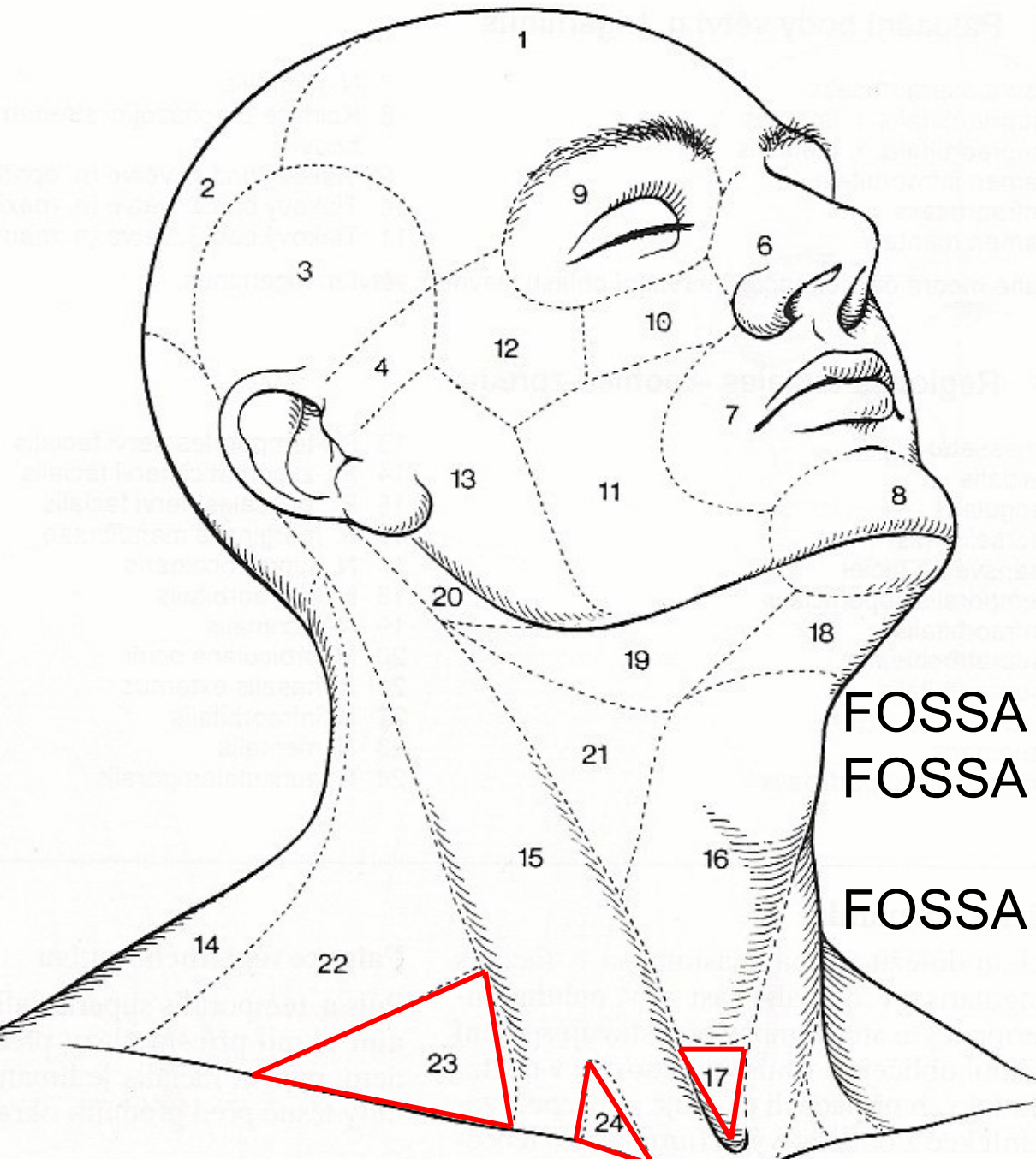


**REGIO CERVICALIS ANTERIOR
(TRIGONUM CERVICALE MEDIALE):**

- TRIGONUM SUBMENTALE
- TRIGONUM SUBMANDIBULARE
- TRIGONUM CAROTICUM
- TRIGONUM MUSCULARE/
OMOTRACHEALE

**REGIO CERVICALIS LATERALIS)
(TRIGONUM CERVICALE LATERALE:**

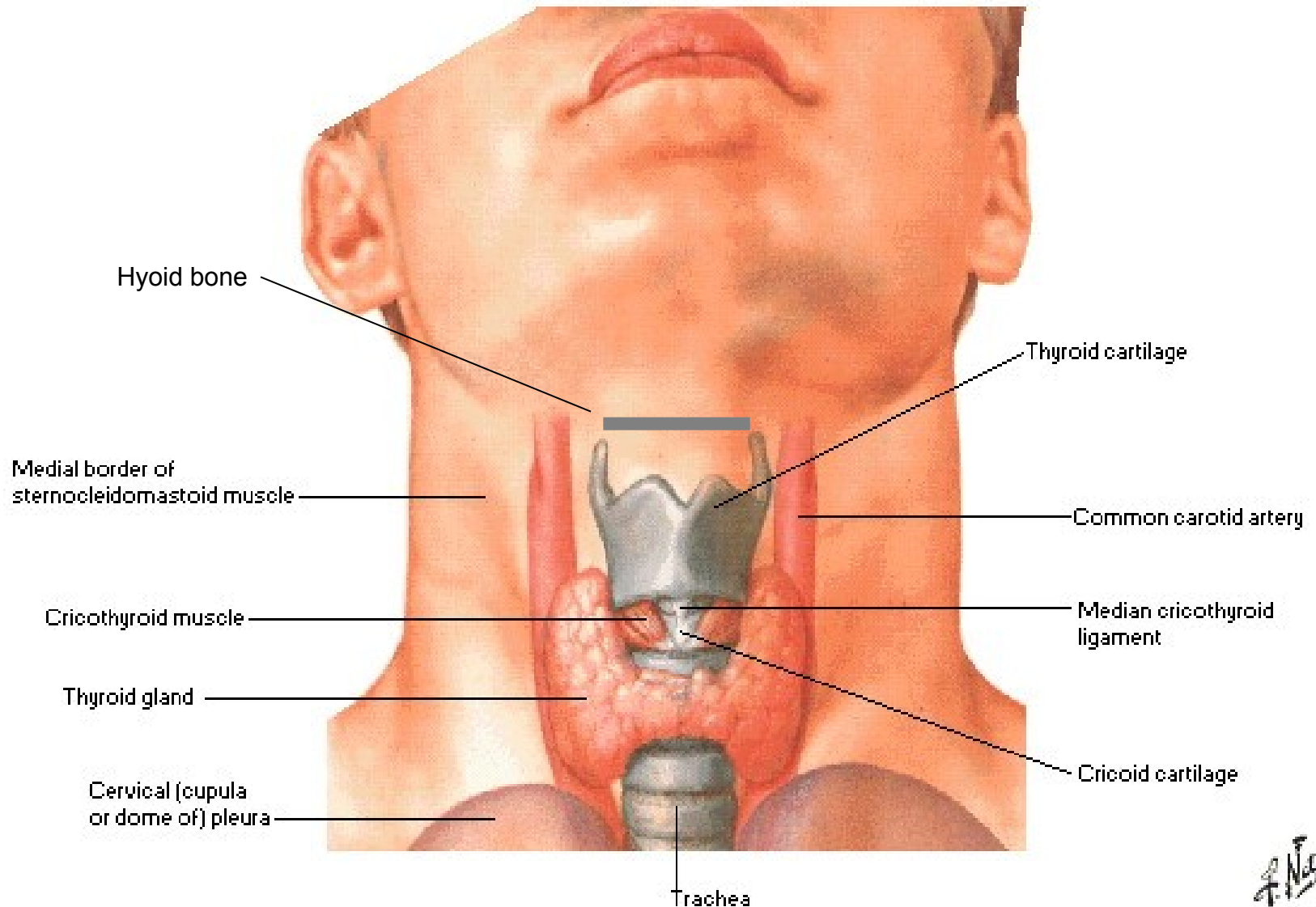
- TRIGONUM OMOCLAVICULARE
(TRIGONUM OMOTRAPEZIUM)

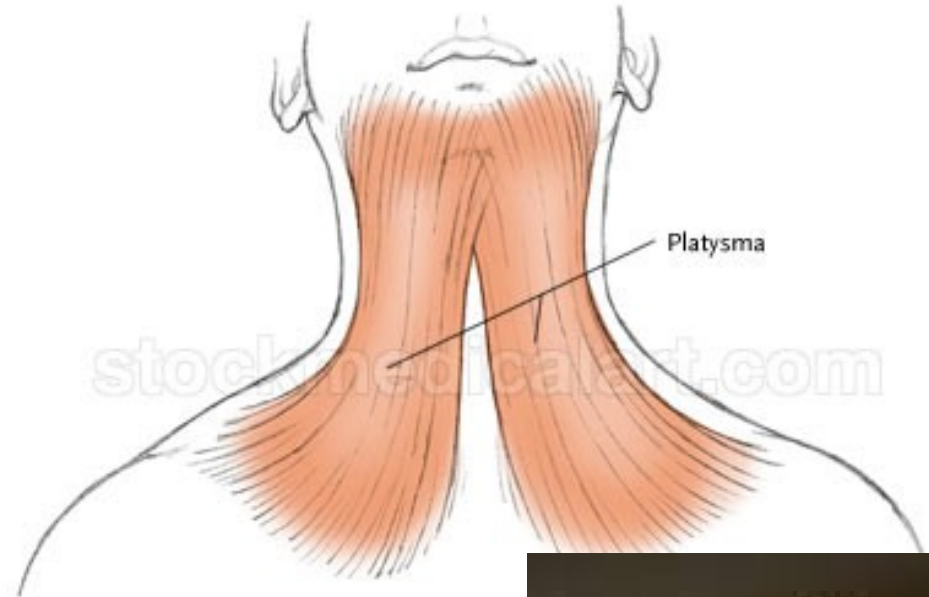
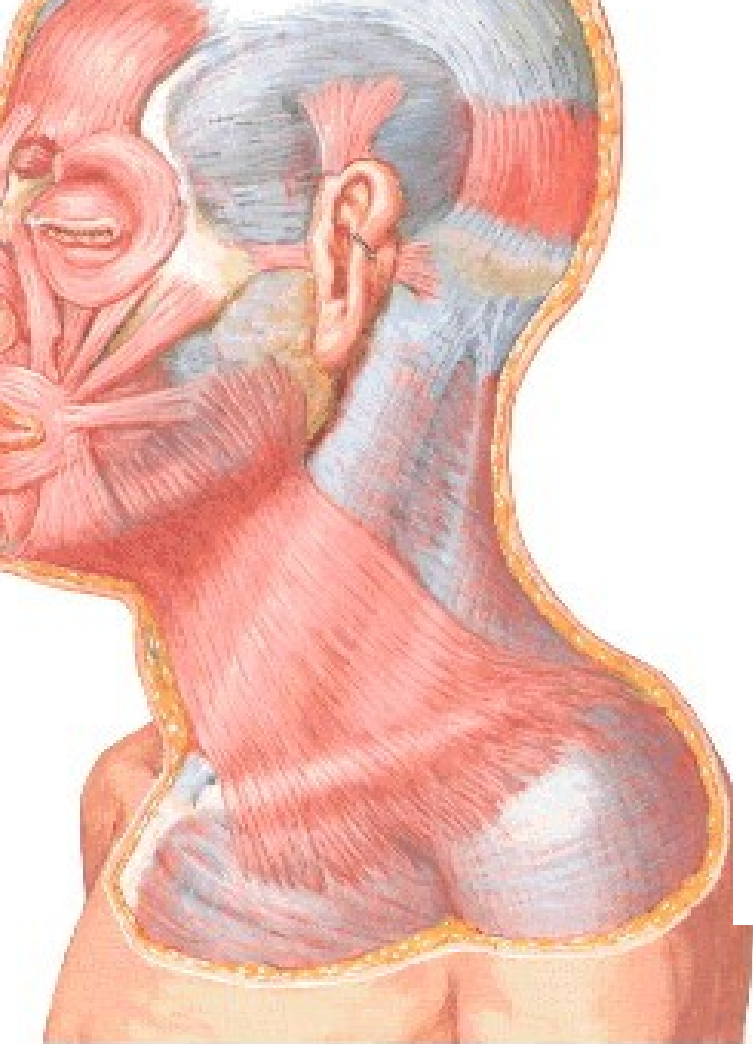


FOSSA JUGULARIS
FOSSA SUPRACLAVICULARIS
MINOR
FOSSA SUPRACLAVICULARIS
MAJOR

Thyroid Gland in Situ

Anterior View

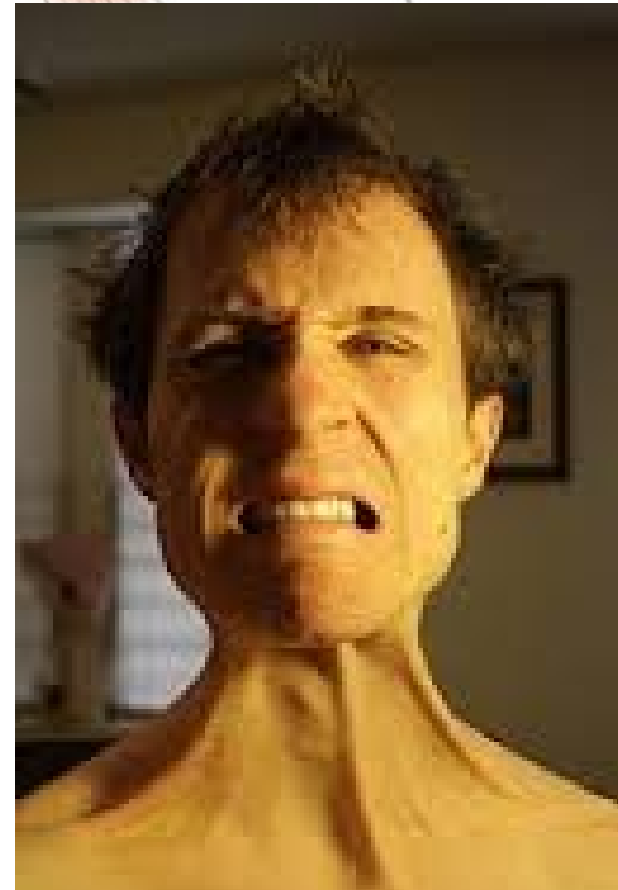



stockmedicalart.com

© 2013 stockmedicalart.com

Novartis
©Novartis



PLATYSMA

Punctum nervosum (Erb)

N. OCCIPITALIS MINOR

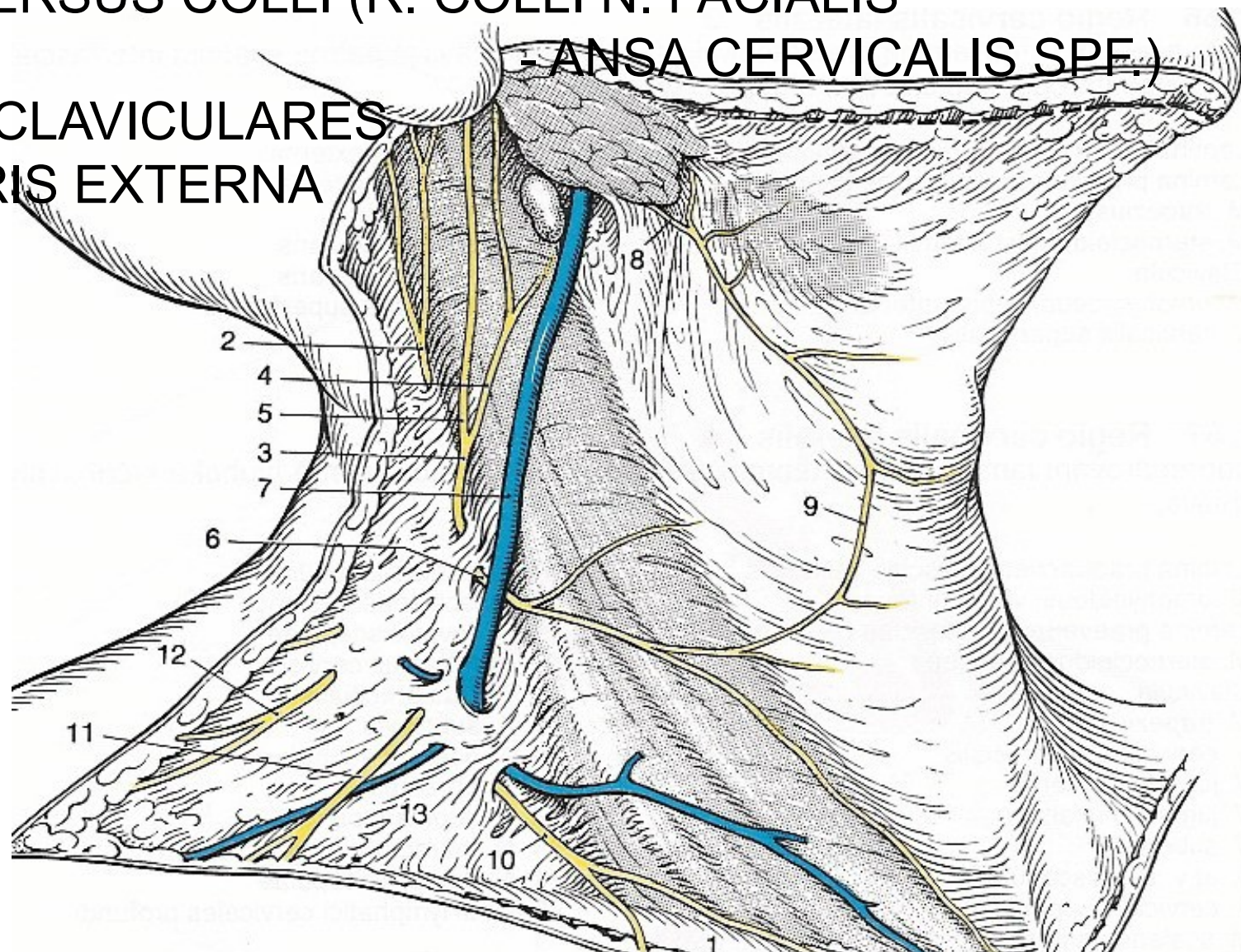
N. AURICULARIS MAGNUS

N. TRANSVERSUS COLLI (R. COLLI N. FACIALIS

- ANSA CERVICALIS SPF.)

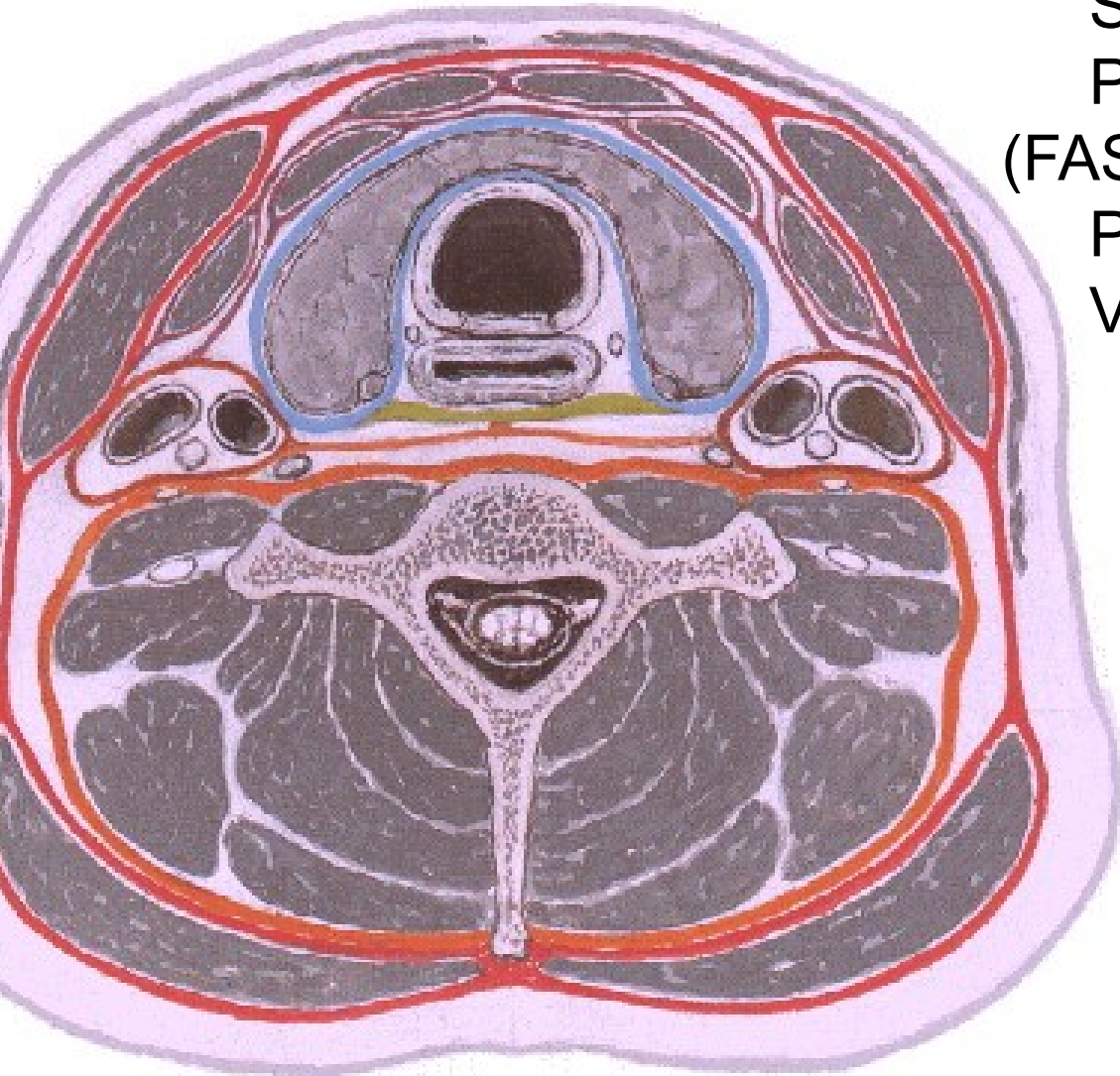
NN. SUPRACLAVICULARES

V. JUGULARIS EXTERNA



Fascial Layers of Neck

Cross Section



FASCIA CERVICALIS:

LAMINA

SUPERFICIALIS

PRAETRACHEALIS

(FASCIA BUCCOPHARYNGEA)

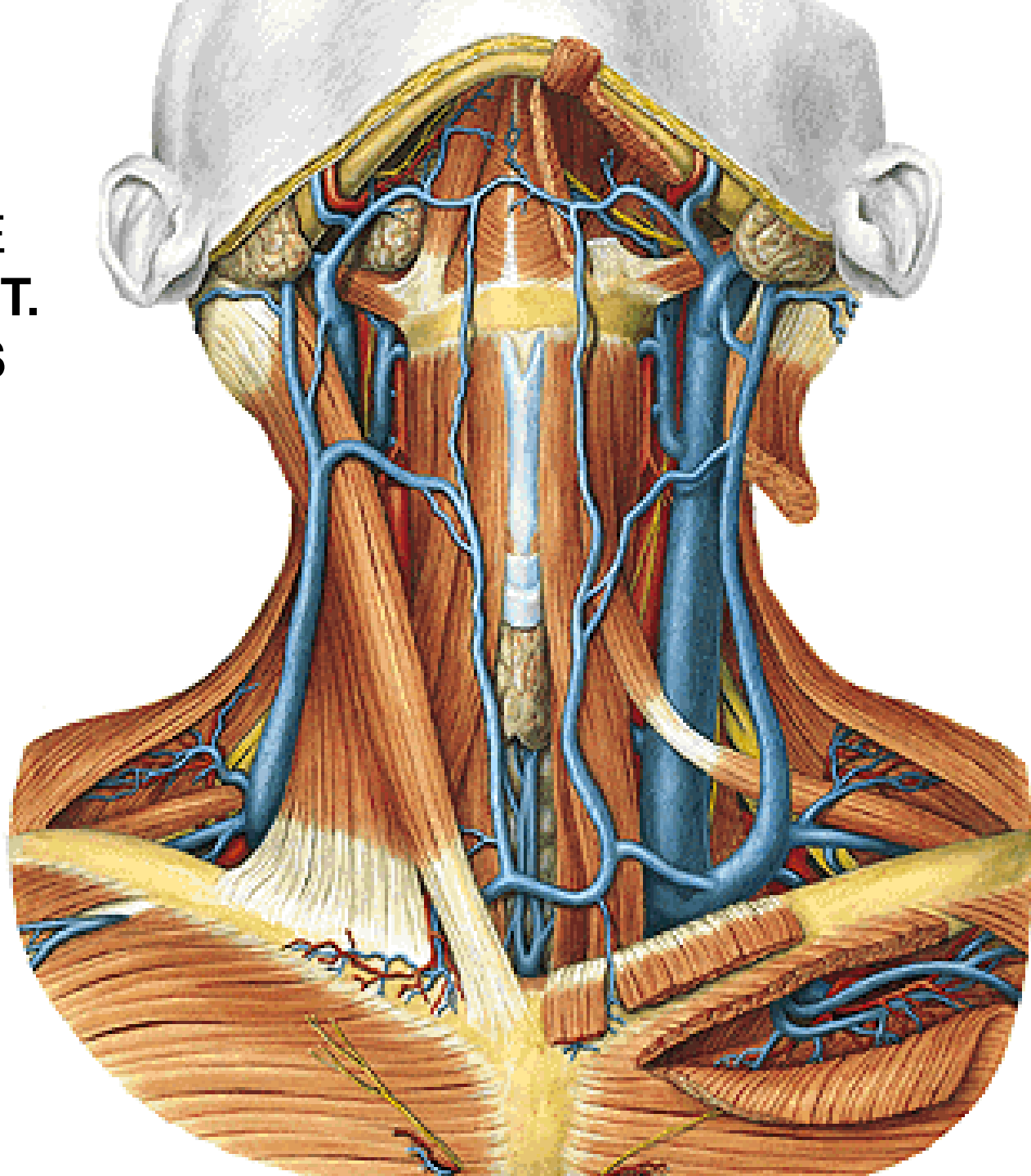
PRAEVERTEBRALIS

VAGINA CAROTICA

SPATIUM

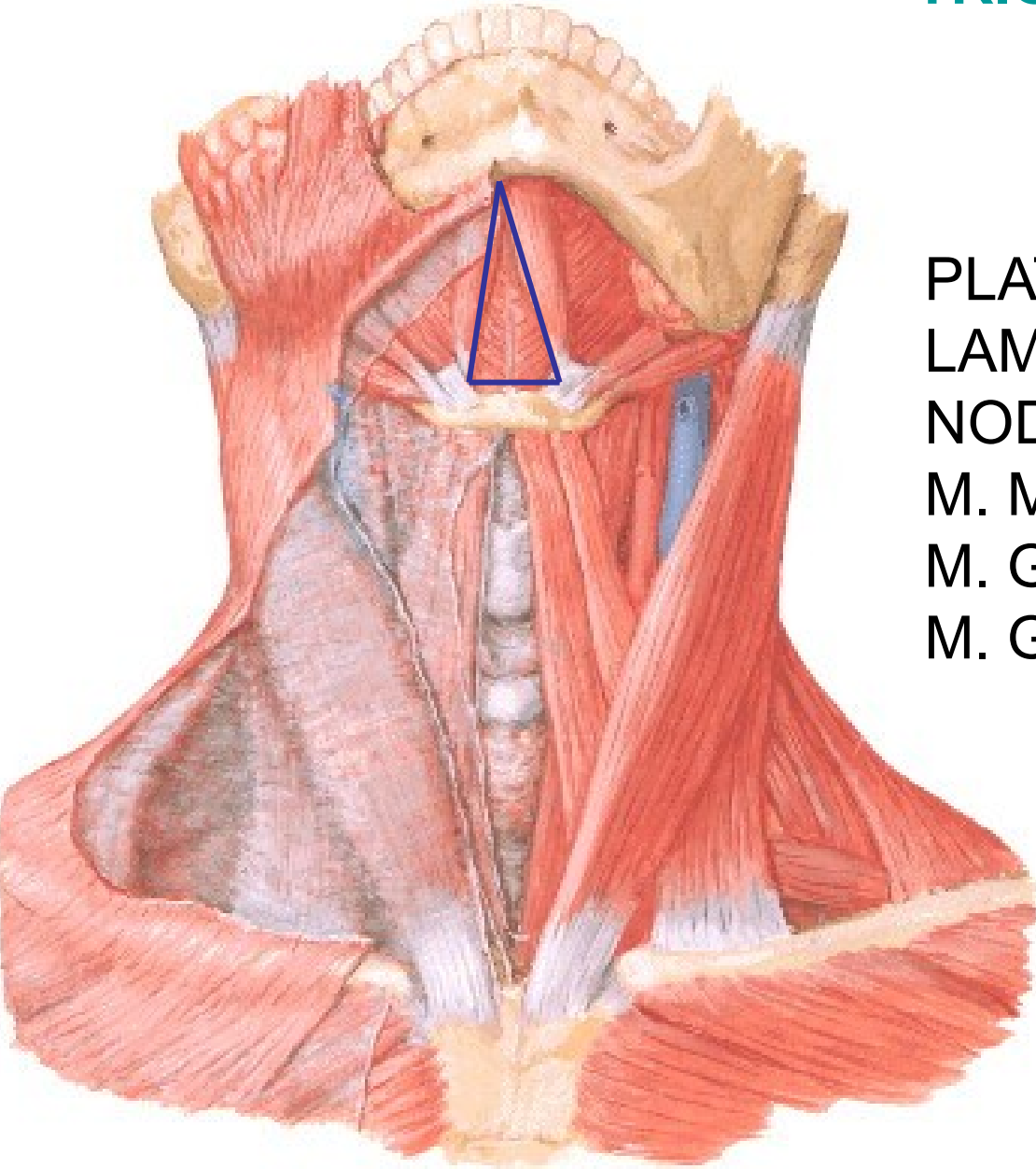
RETROPHARYNGEALE

**SPATIUM
SUPRASTERNALE
V. JUGULARIS ANT.
ARCUS VENOSUS
JUGULI**



Anterior View

TRIGONUM SUBMENTALE



PLATYSMA

LAMINA SPF. FASCIAE CERVICIS

NODI LYMPH. SUBMENTALES

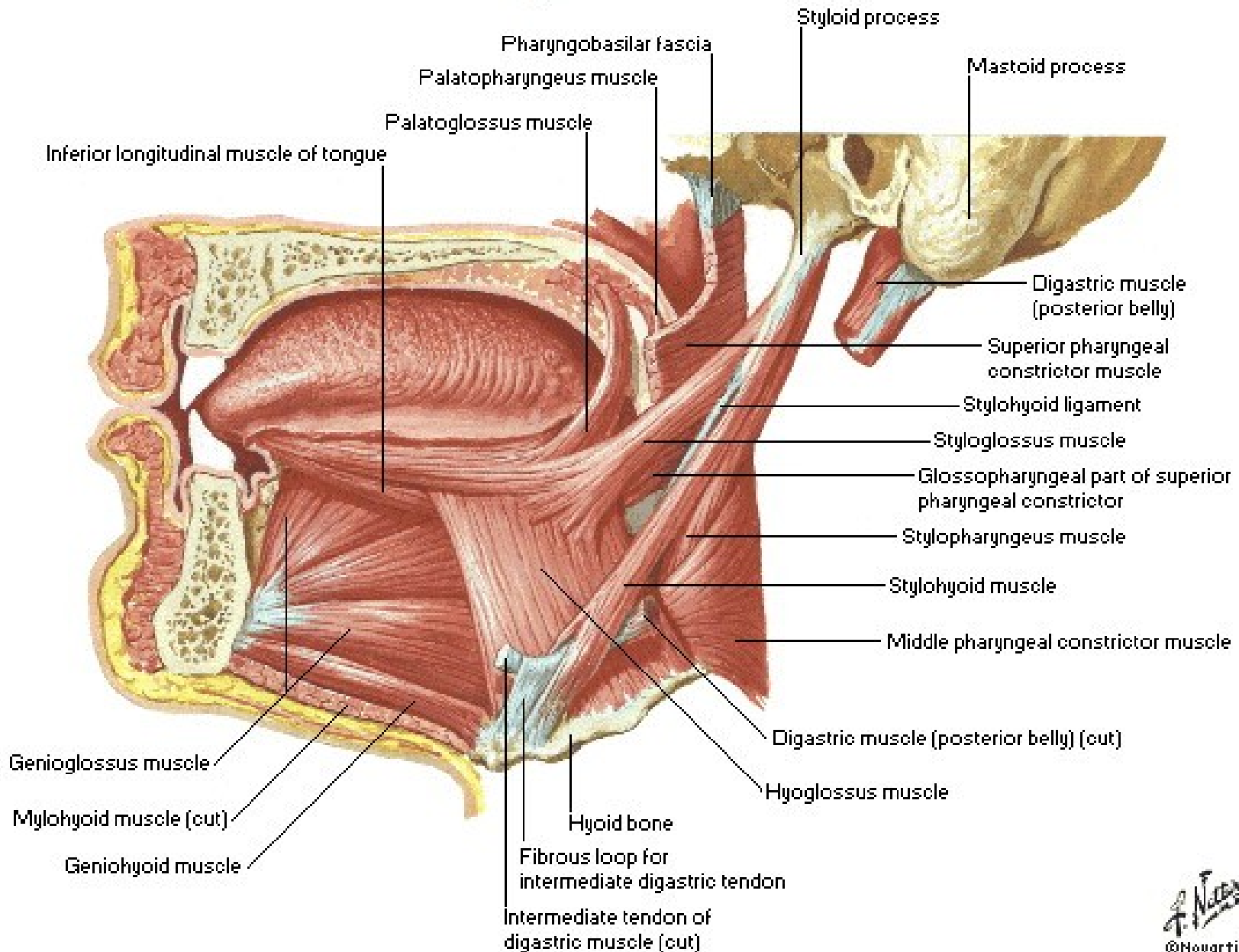
M. MYLOHYOIDEUS

M. GENIOHYOIDEUS

M. GENIOGLOSSUS

Muscles of Tongue

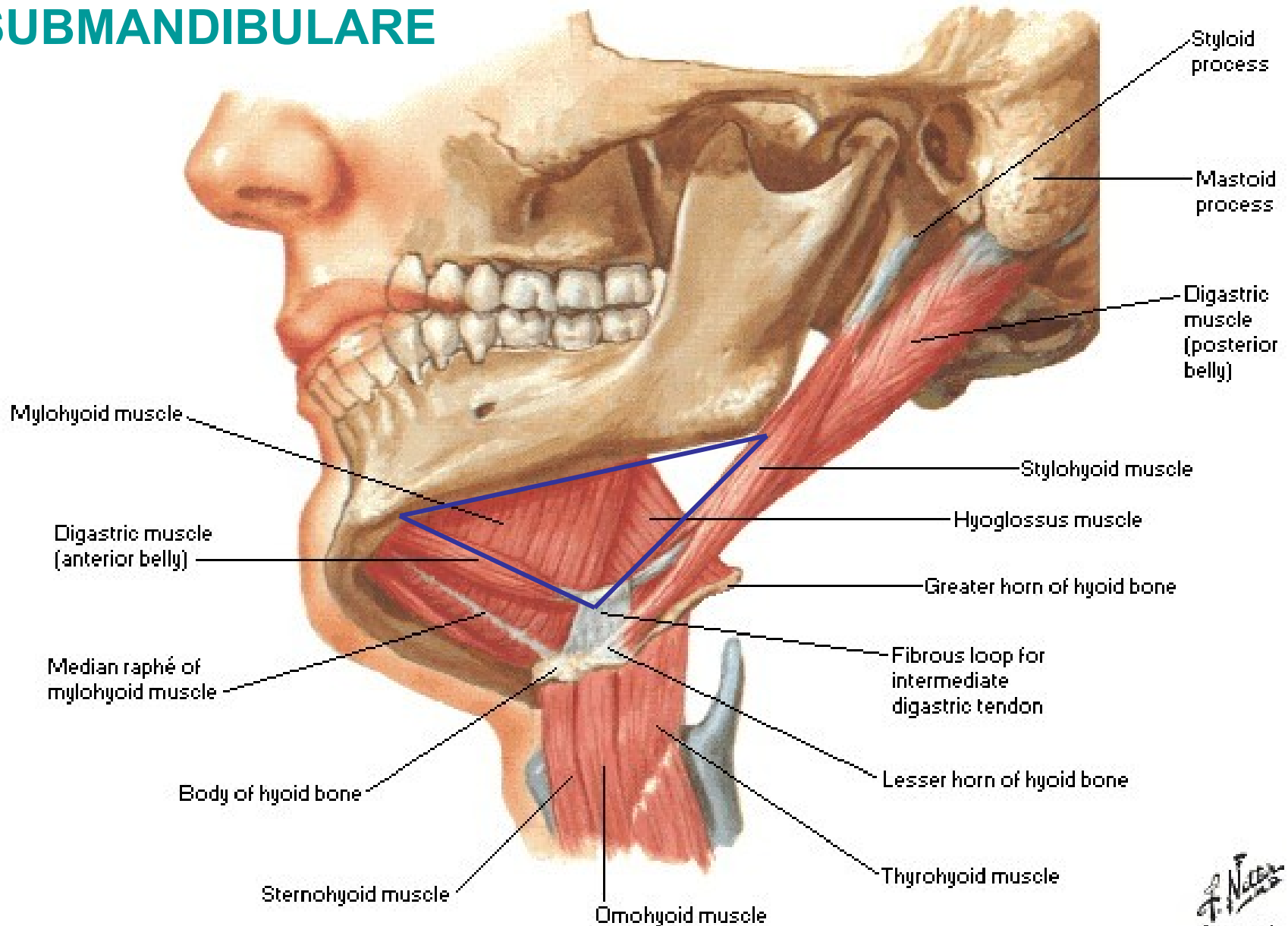
Sagittal Section

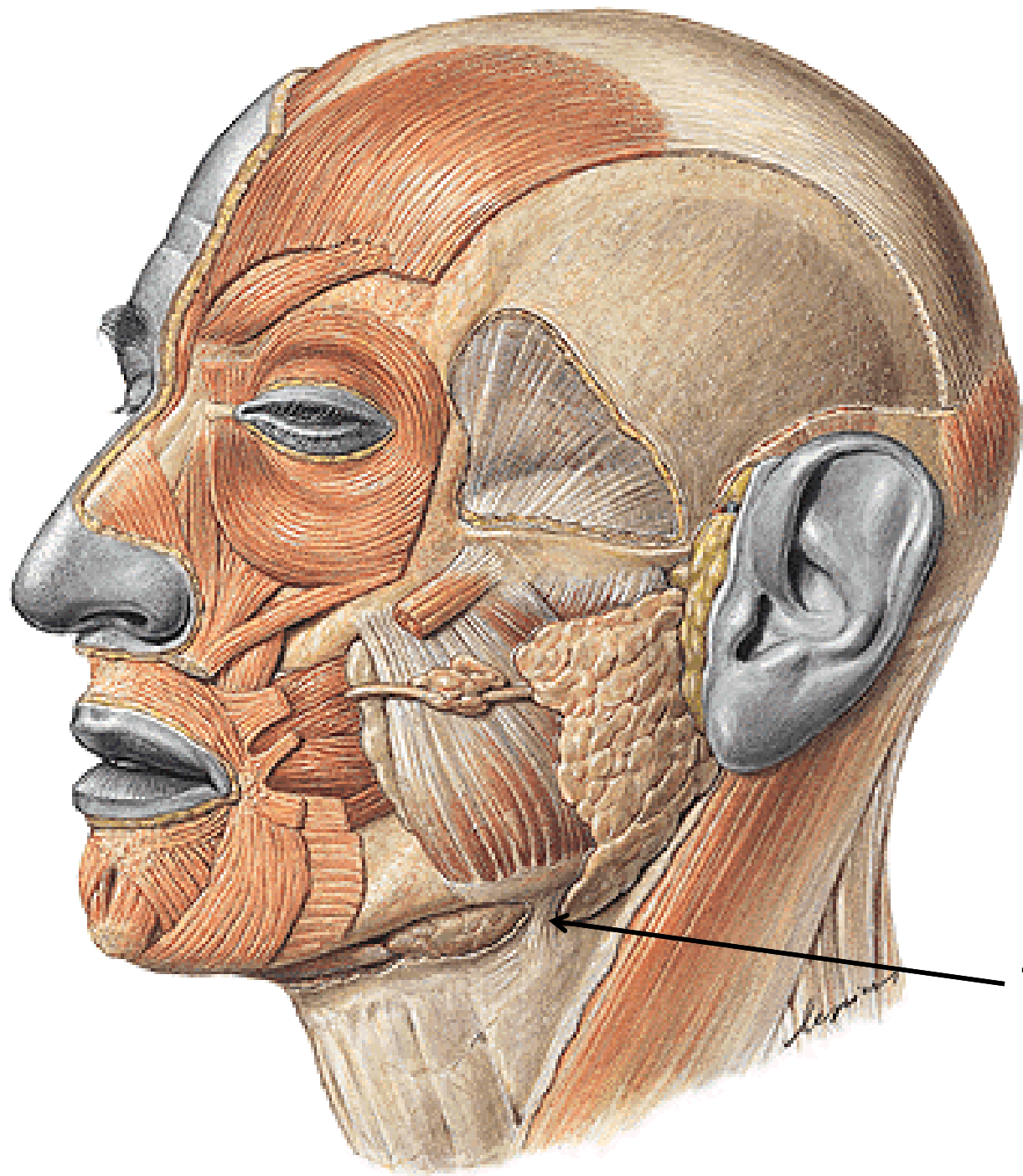


Floor of Mouth - Musculature

Lateral, Slightly Inferior View

TRIGONUM SUBMANDIBULARE

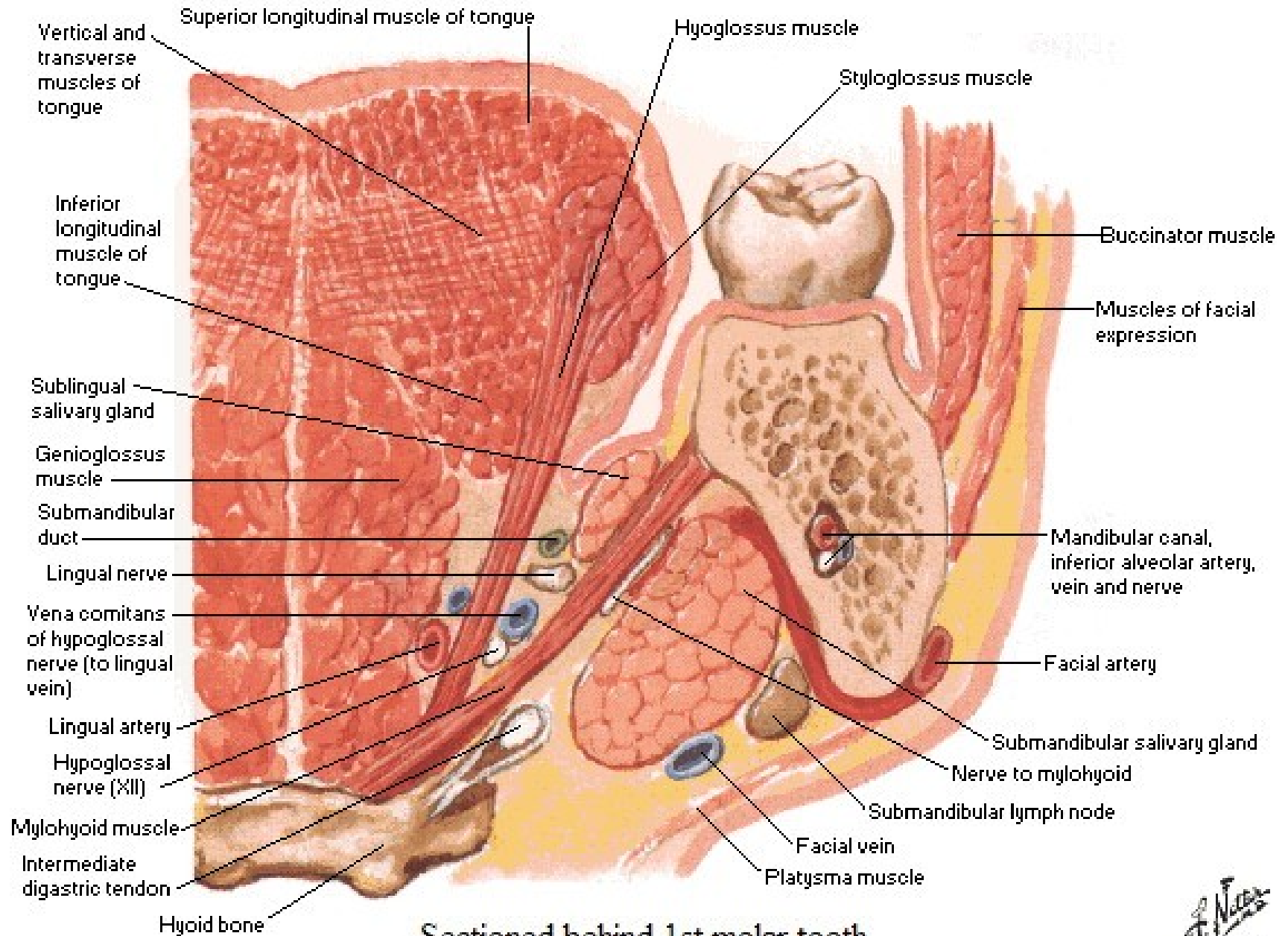


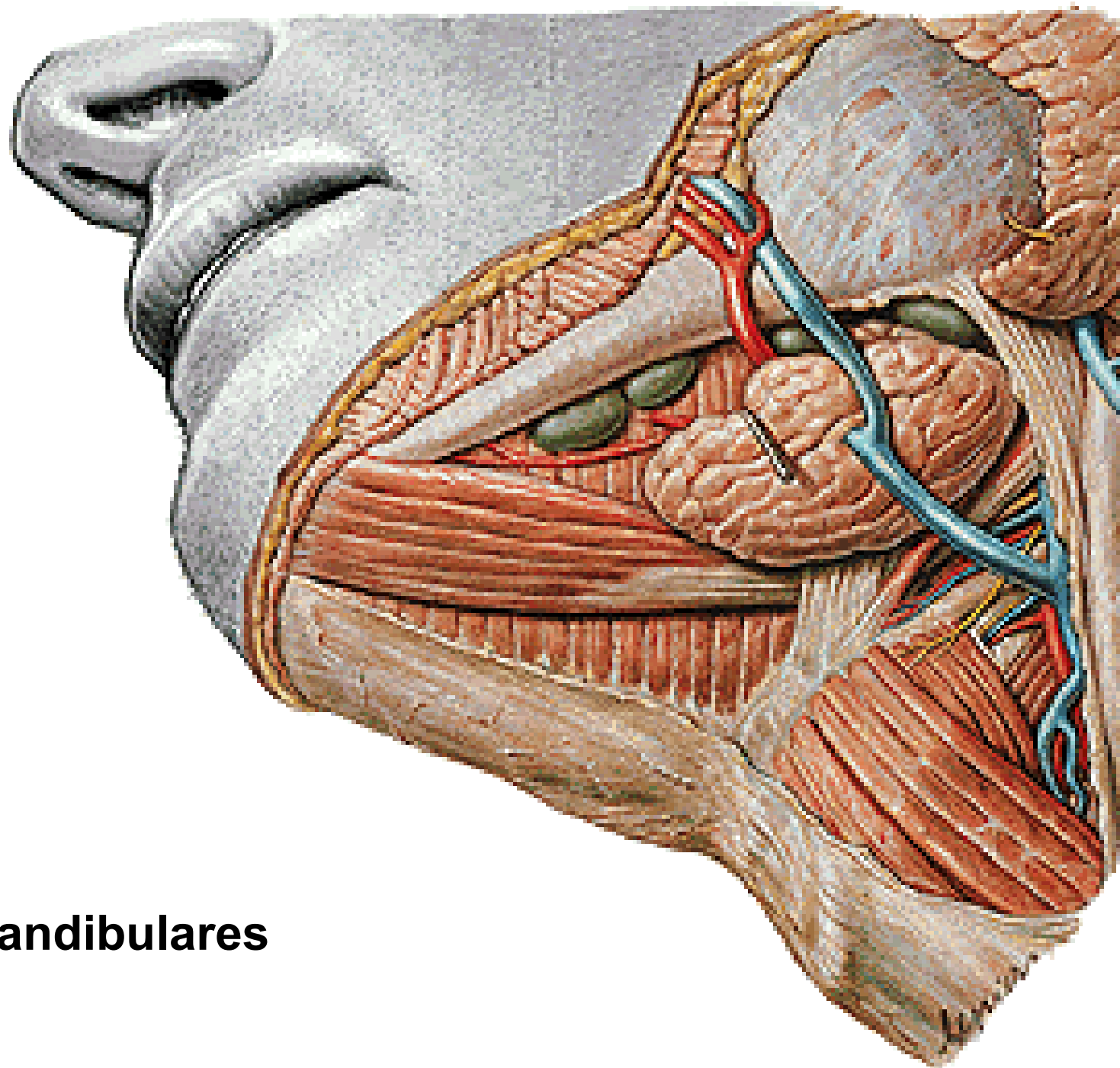


TRACTUS
ANGULARIS

Tongue and Mouth

Frontal Section - Anterior View

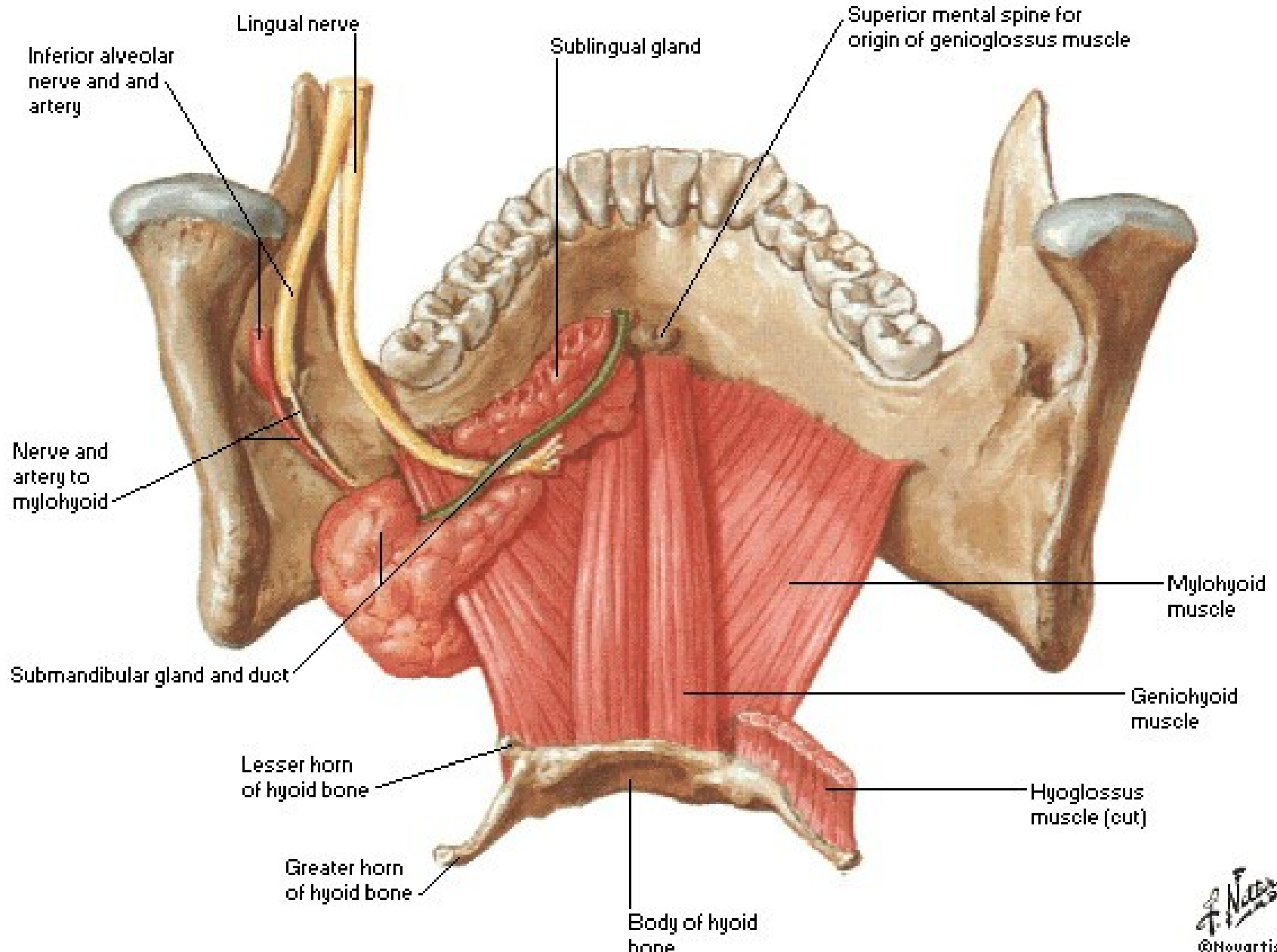


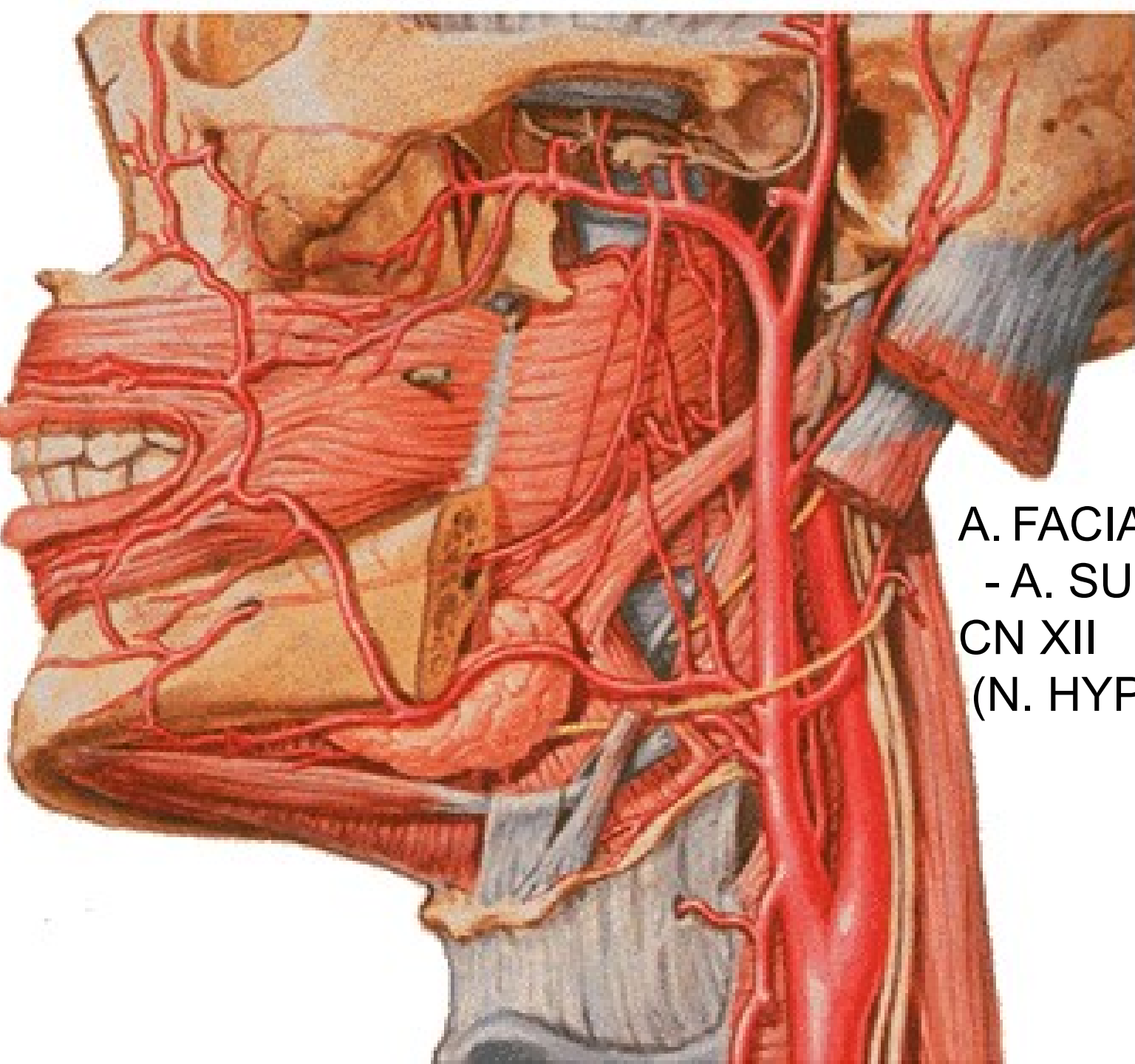


NII. submandibulares

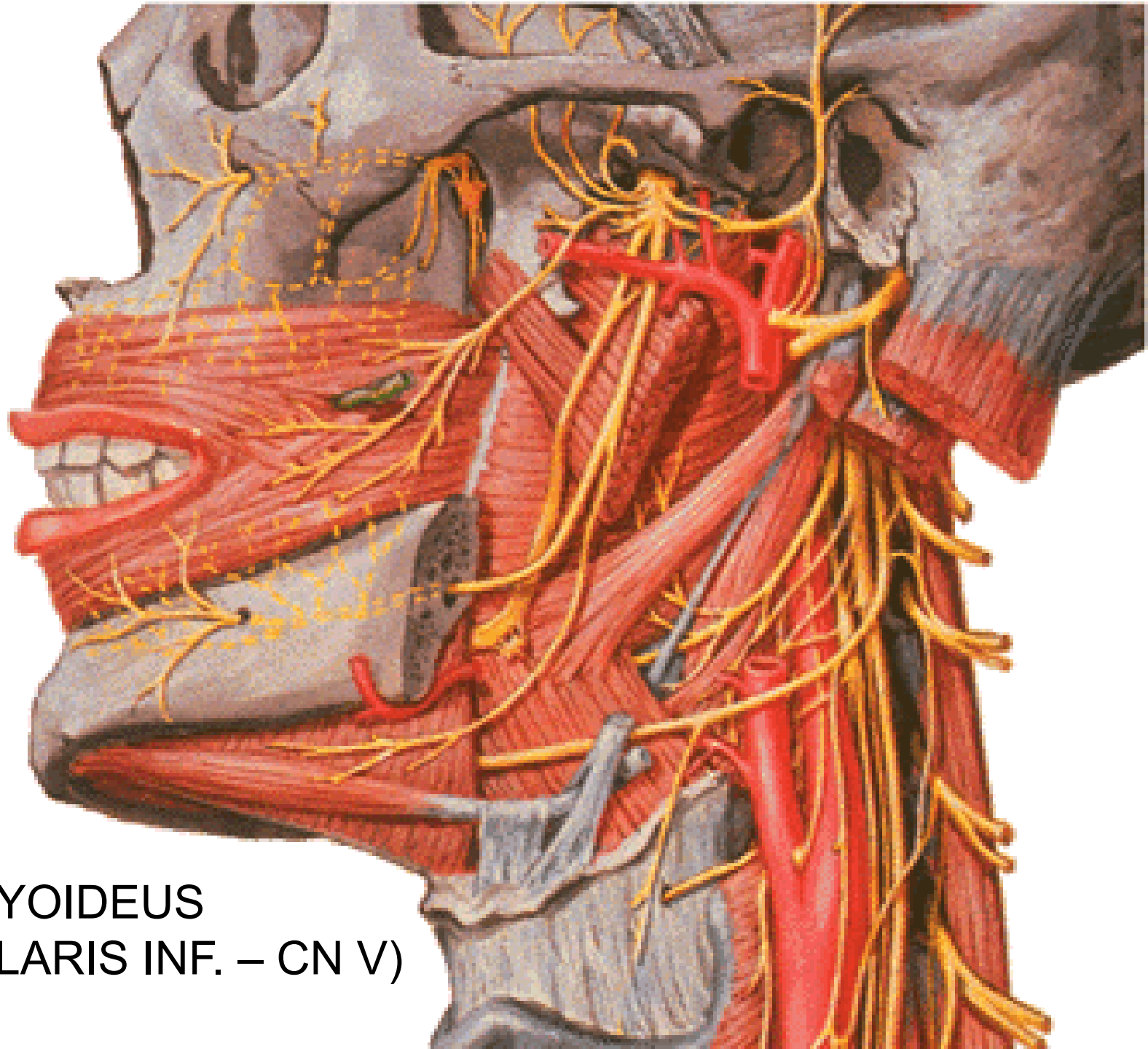
Floor of Mouth - Musculature

Posterosuperior View



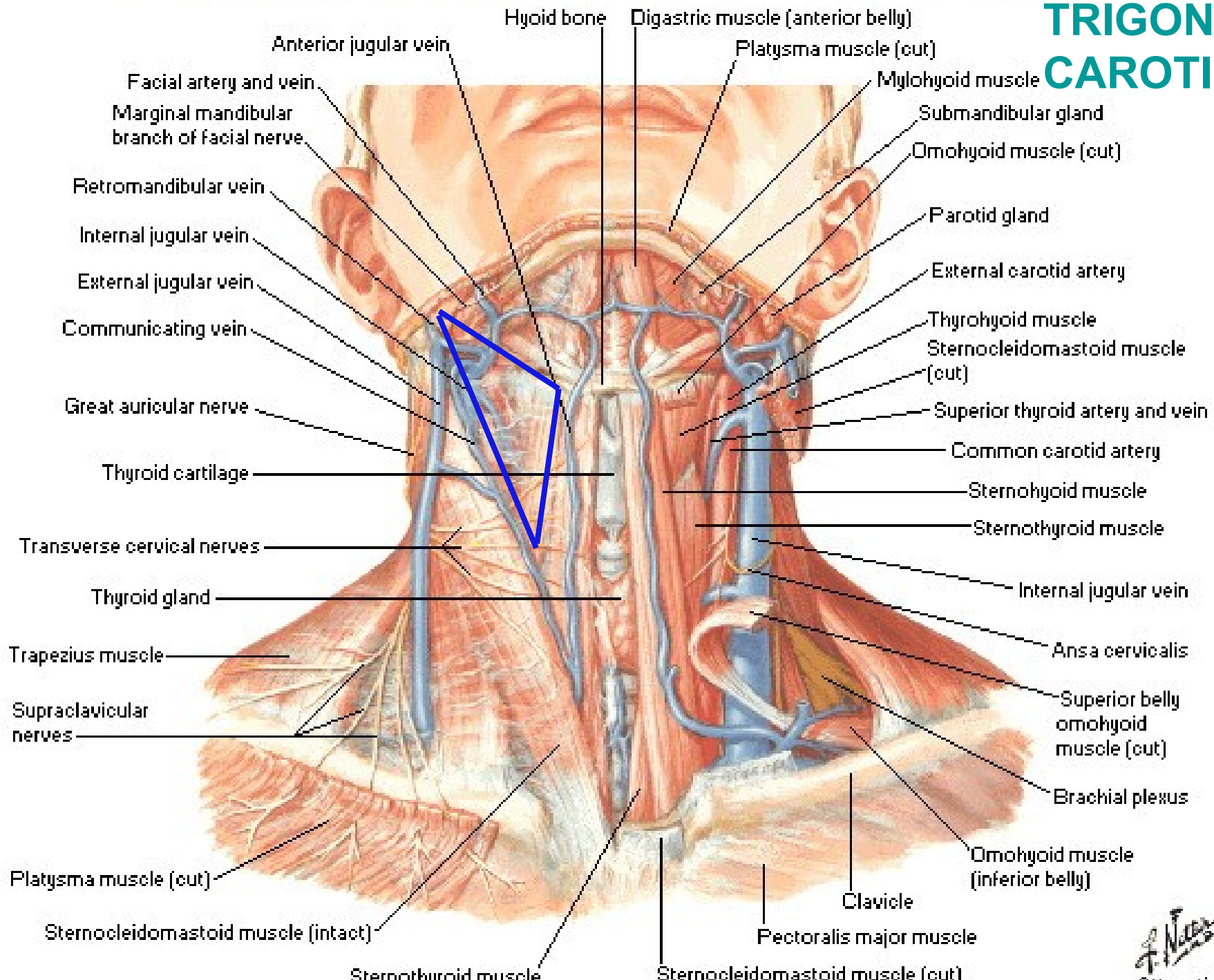


A. FACIALIS
- A. SUBMENTALIS
CN XII
(N. HYPOGLOSSUS)

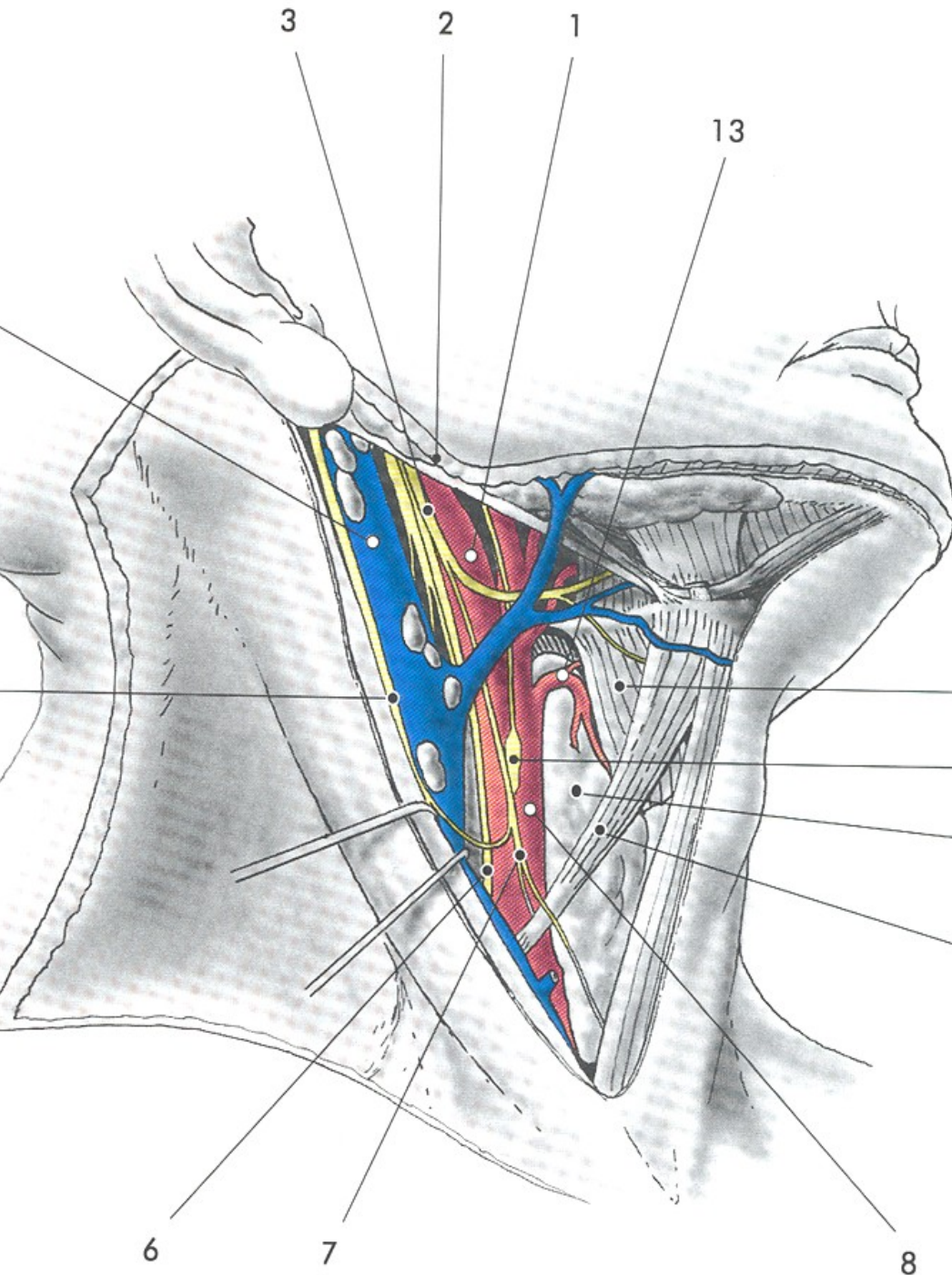


N. MYLOHYOIDEUS
(N. ALVEOLARIS INF. – CN V)

TRIGONUM CAROTICUM



F. Netter



CONTENTS:
V. FACIALIS
V. JUGULARIS INT.
NL. CERVICALES PROF.
A. CAROTIS COMM.-
EXT.+INT.
N. VAGUS
N. HYPOGLOSSUS
ANSA CERVICALIS PROF.
GLOMUS CAROTICUM
SINUS CAROTICUS

11

10

9

12

13

3

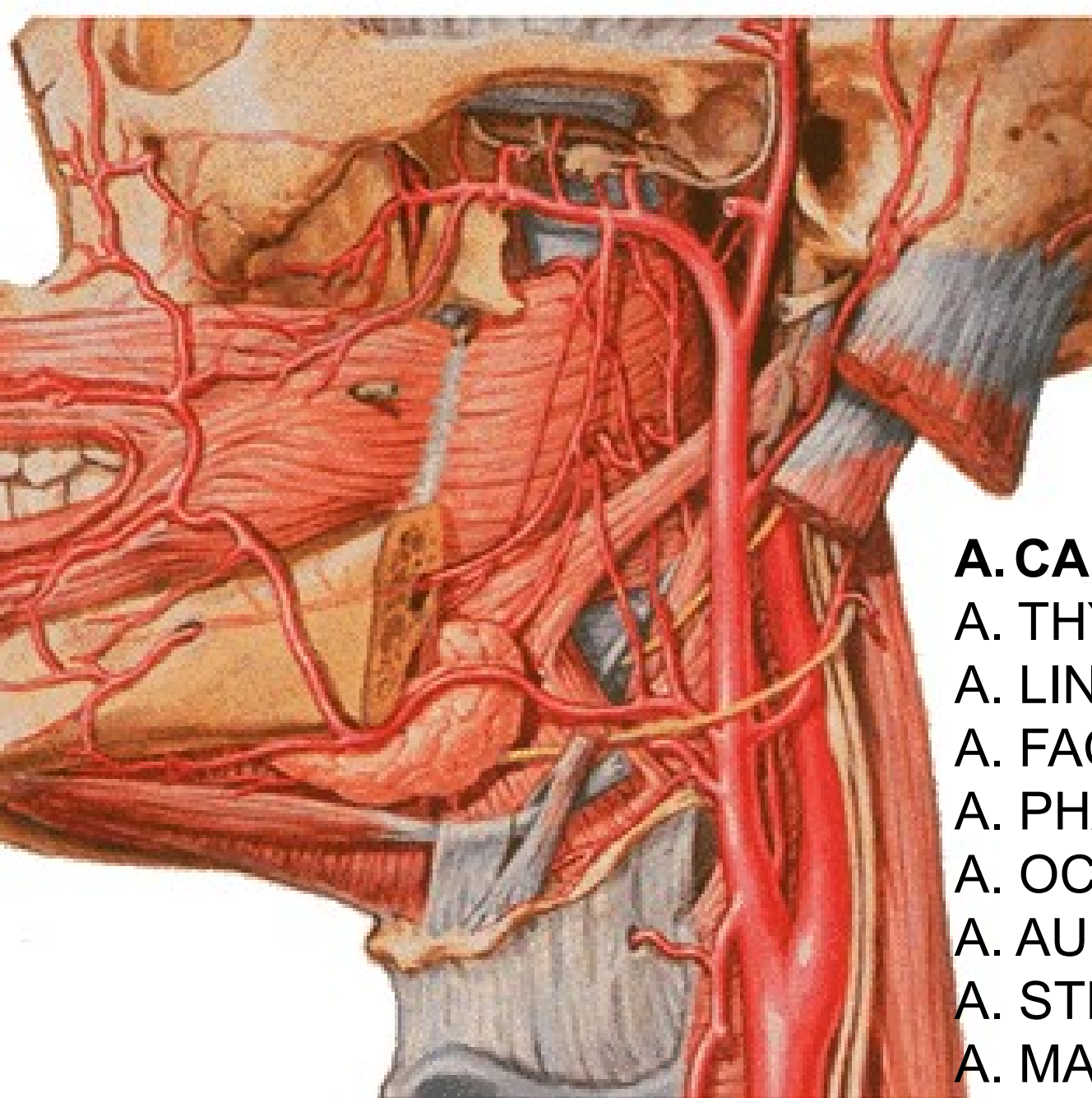
2

1

6

7

8



A. CAROTIS EXT:

A. THYROIDEA SUP.

A. LINGUALIS

A. FACIALIS

A. PHARYNGEA ASC.

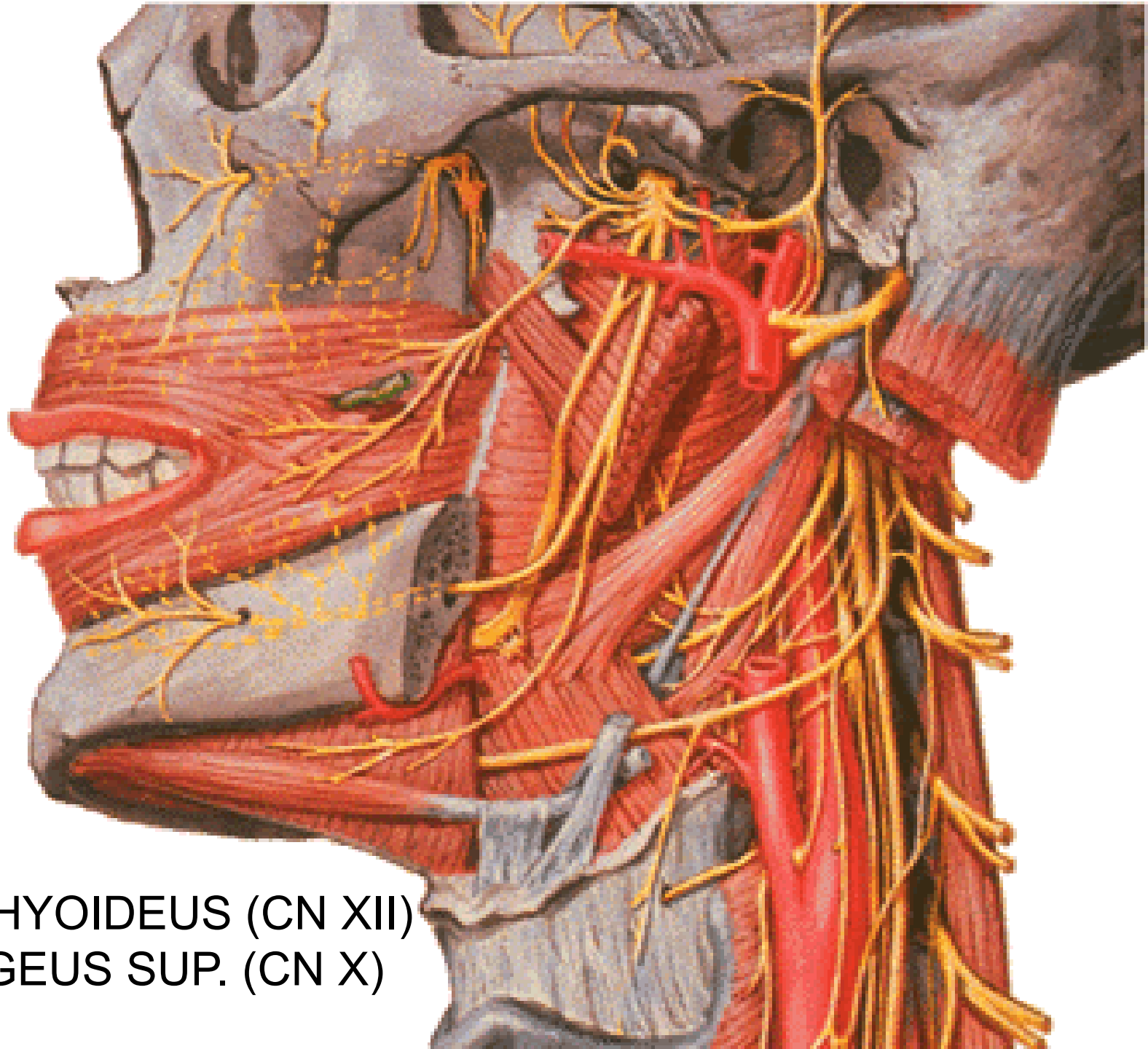
A. OCCIPITALIS

A. AURICULARIS POST.

A. STERNOCLEIDOMAST

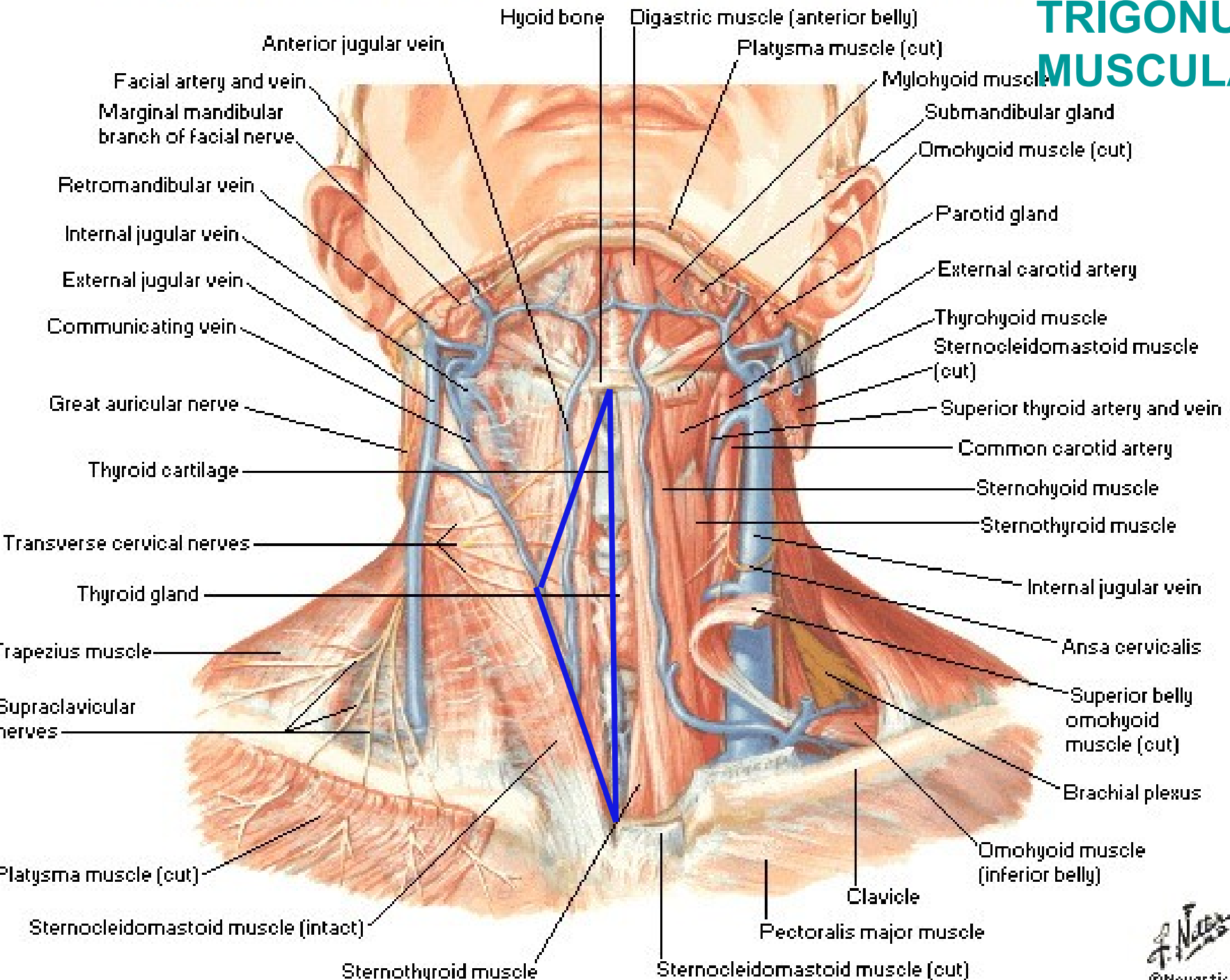
A. MAXILLARIS

A. TEMPORALIS SPF.

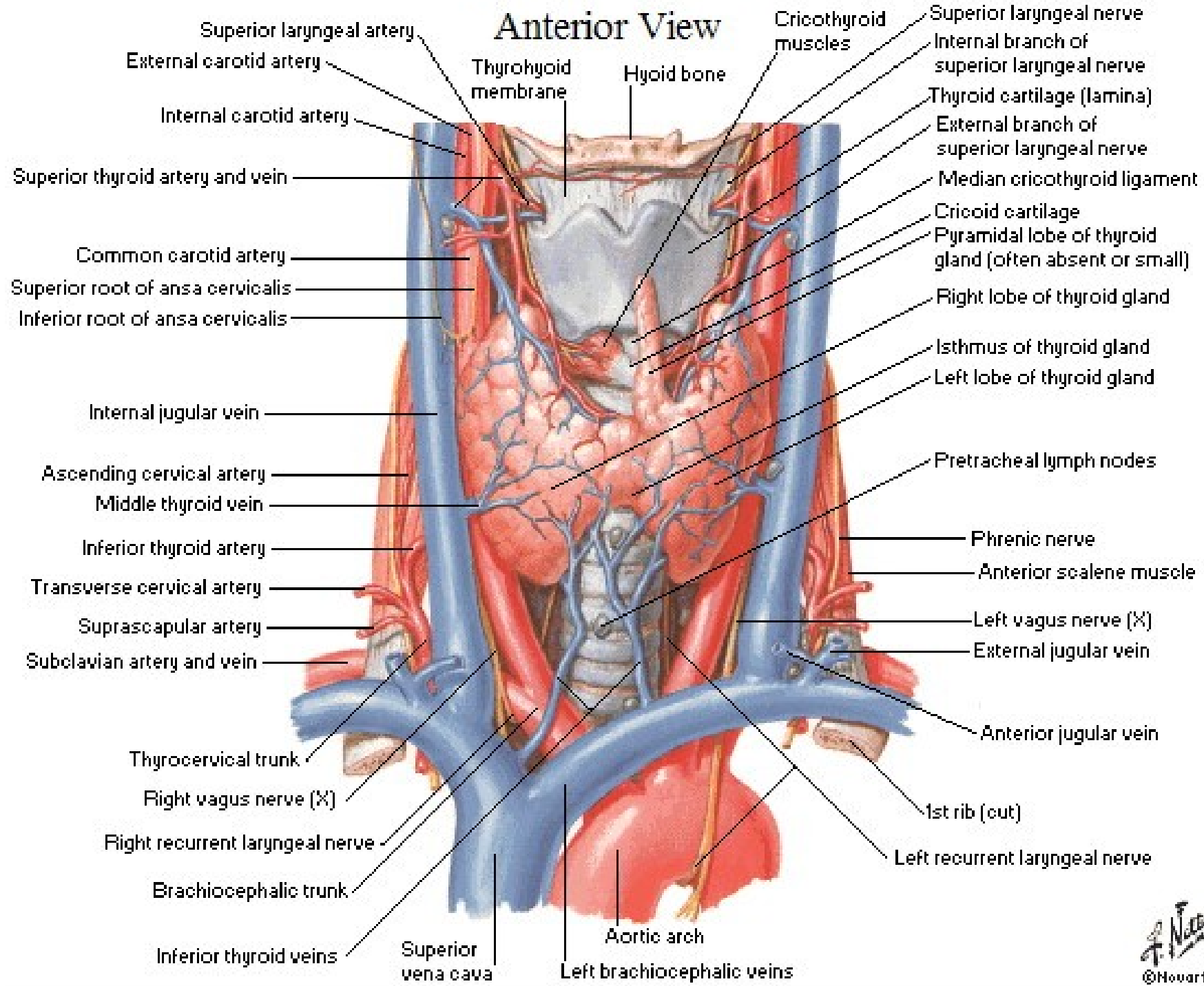


R. THYROHYOIDEUS (CN XII)
N. LARYNGEUS SUP. (CN X)

TRIGONUM MUSCULARE



Anterior View



Superior laryngeal artery
 External carotid artery
 Internal carotid artery

Thyroid membrane
 Hyoid bone

Cricothyroid muscles
 Superior laryngeal nerve
 Internal branch of superior laryngeal nerve
 Thyroid cartilage (lamina)
 External branch of superior laryngeal nerve
 Median cricothyroid ligament

Superior thyroid artery and vein
 Common carotid artery
 Superior root of ansa cervicalis
 Inferior root of ansa cervicalis

Cricoid cartilage
 Pyramidal lobe of thyroid gland (often absent or small)
 Right lobe of thyroid gland
 Isthmus of thyroid gland
 Left lobe of thyroid gland

Internal jugular vein
 Ascending cervical artery
 Middle thyroid vein
 Inferior thyroid artery
 Transverse cervical artery
 Suprascapular artery
 Subclavian artery and vein

Pretracheal lymph nodes
 Phrenic nerve
 Anterior scalene muscle
 Left vagus nerve (X)
 External jugular vein

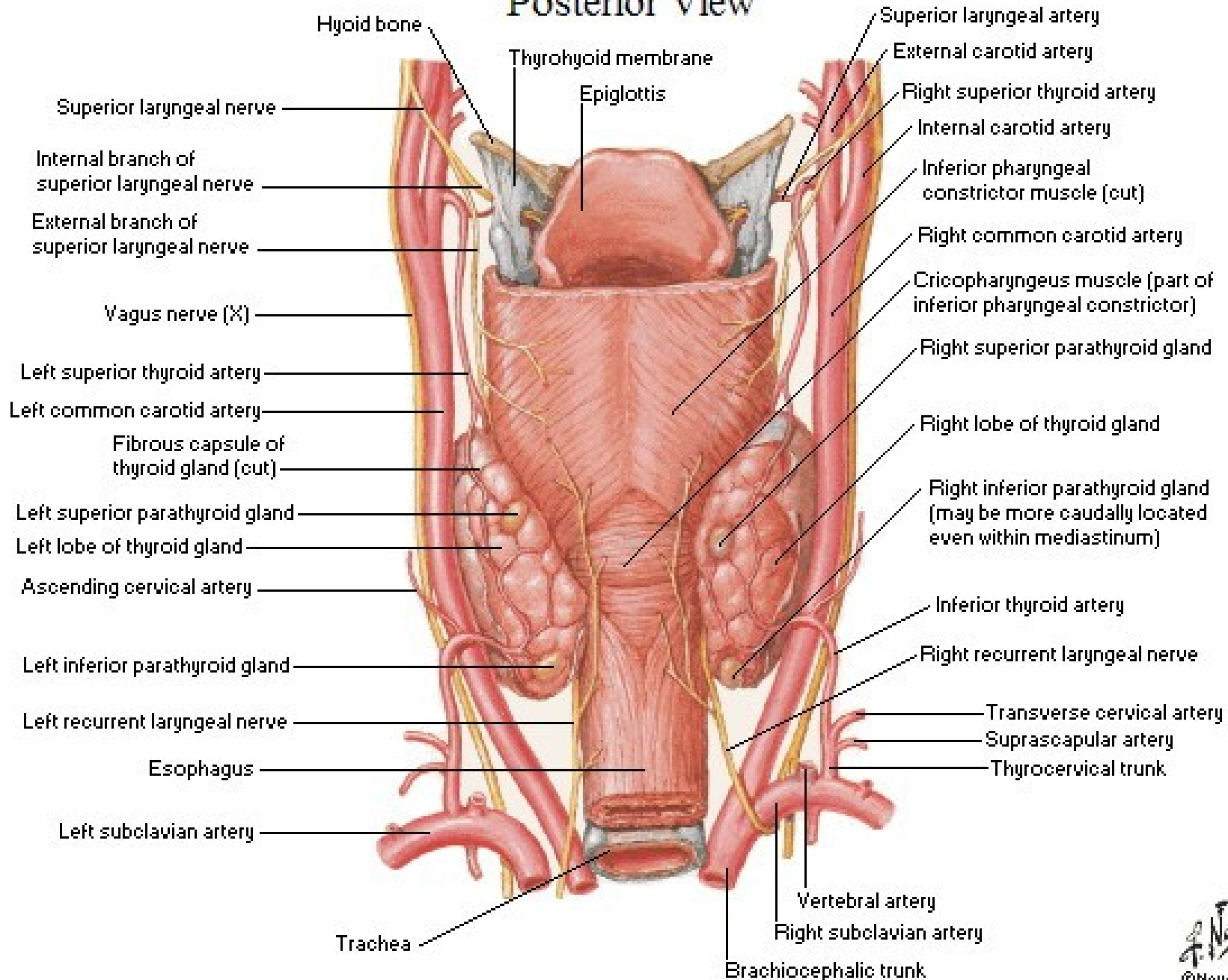
Thyrocervical trunk
 Right vagus nerve (X)
 Right recurrent laryngeal nerve
 Brachiocephalic trunk

Anterior jugular vein
 1st rib (cut)
 Left recurrent laryngeal nerve

Inferior thyroid veins
 Superior vena cava
 Aortic arch
 Left brachiocephalic veins

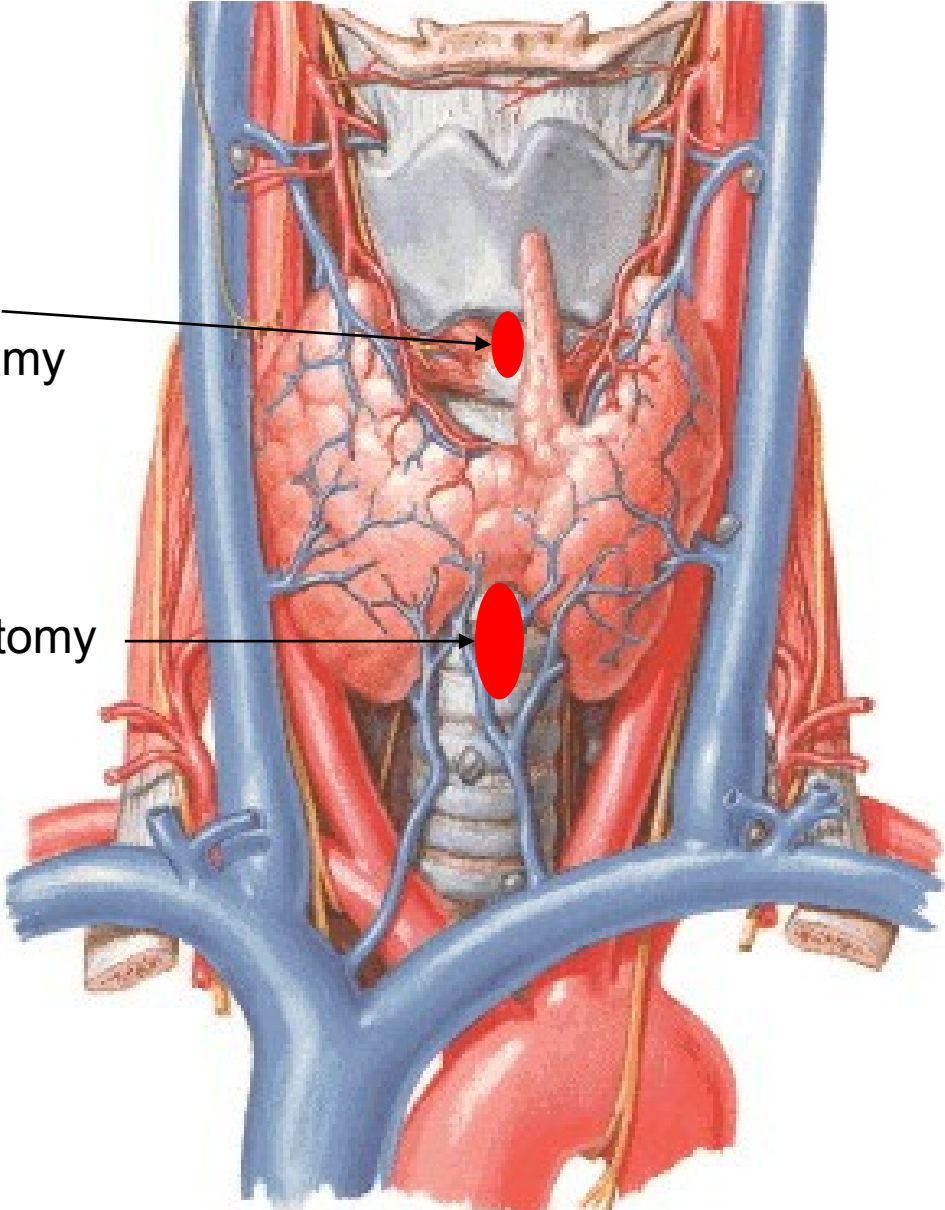
Parathyroid Glands

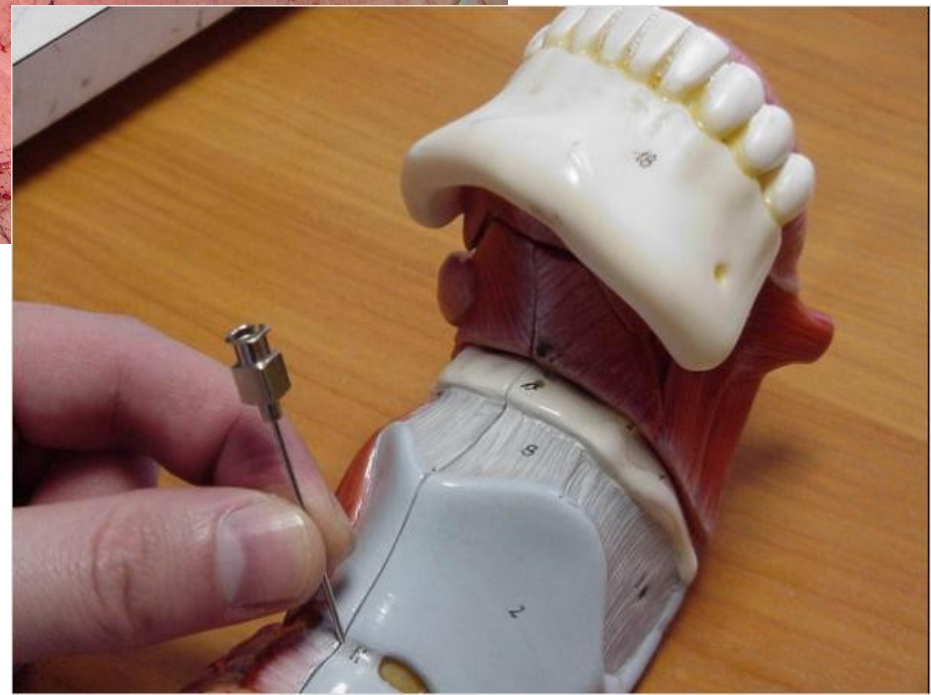
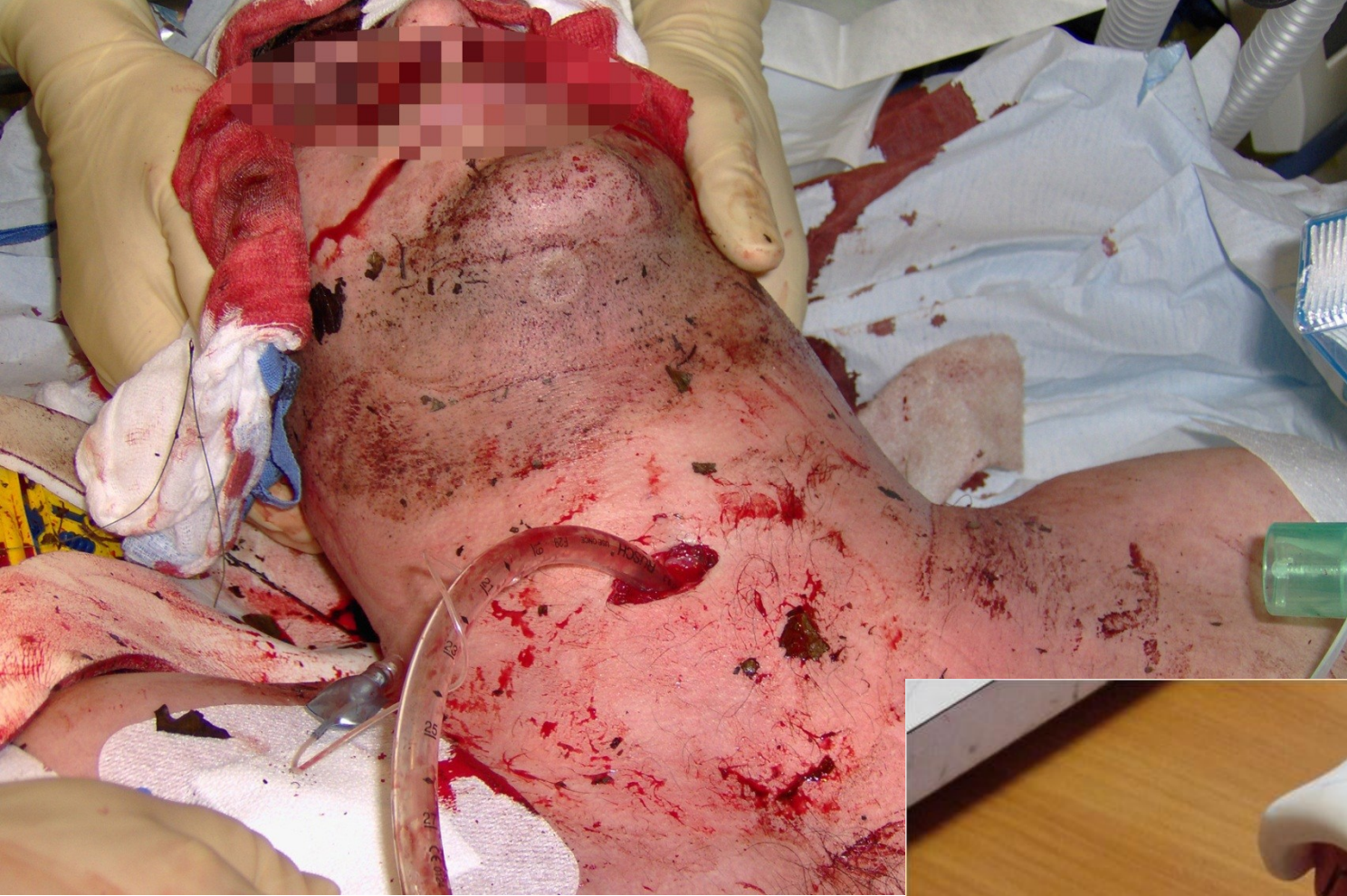Posterior View

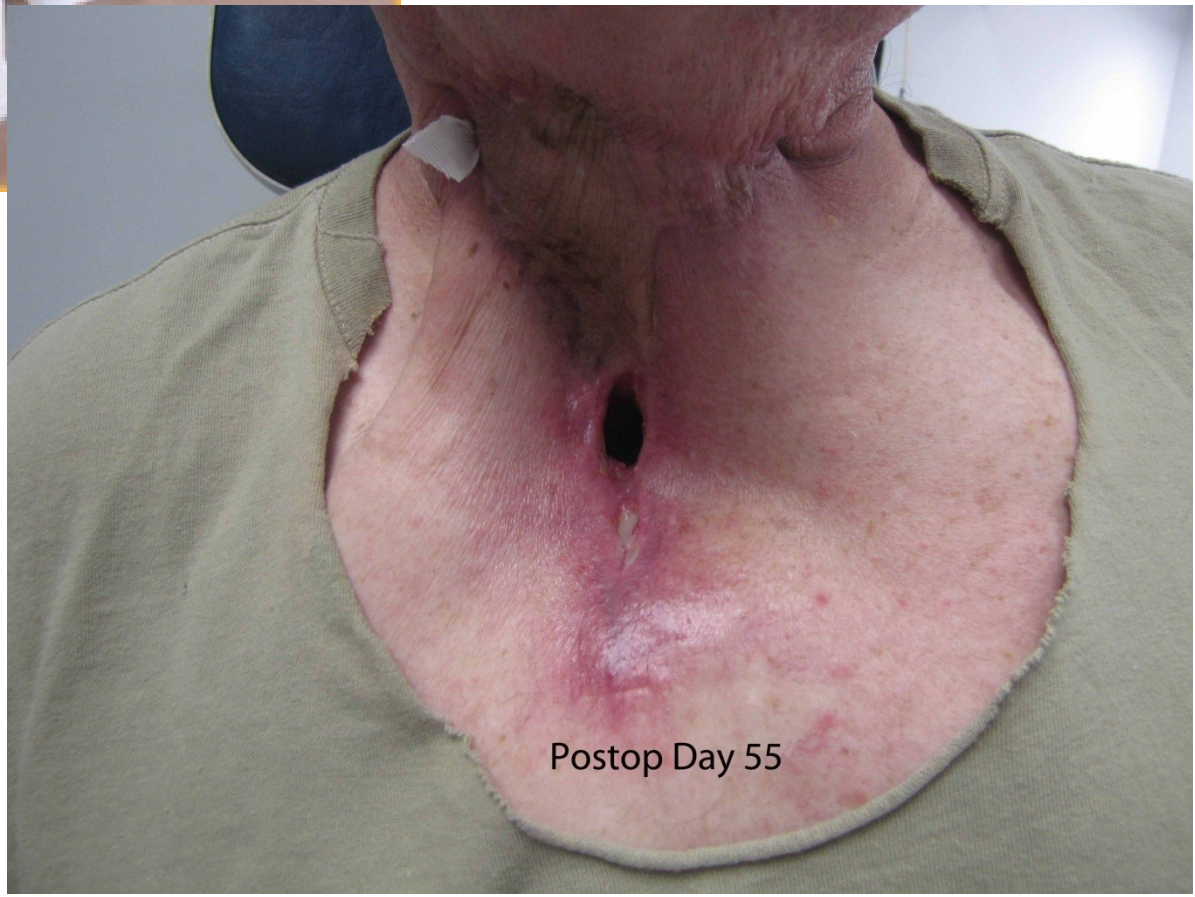
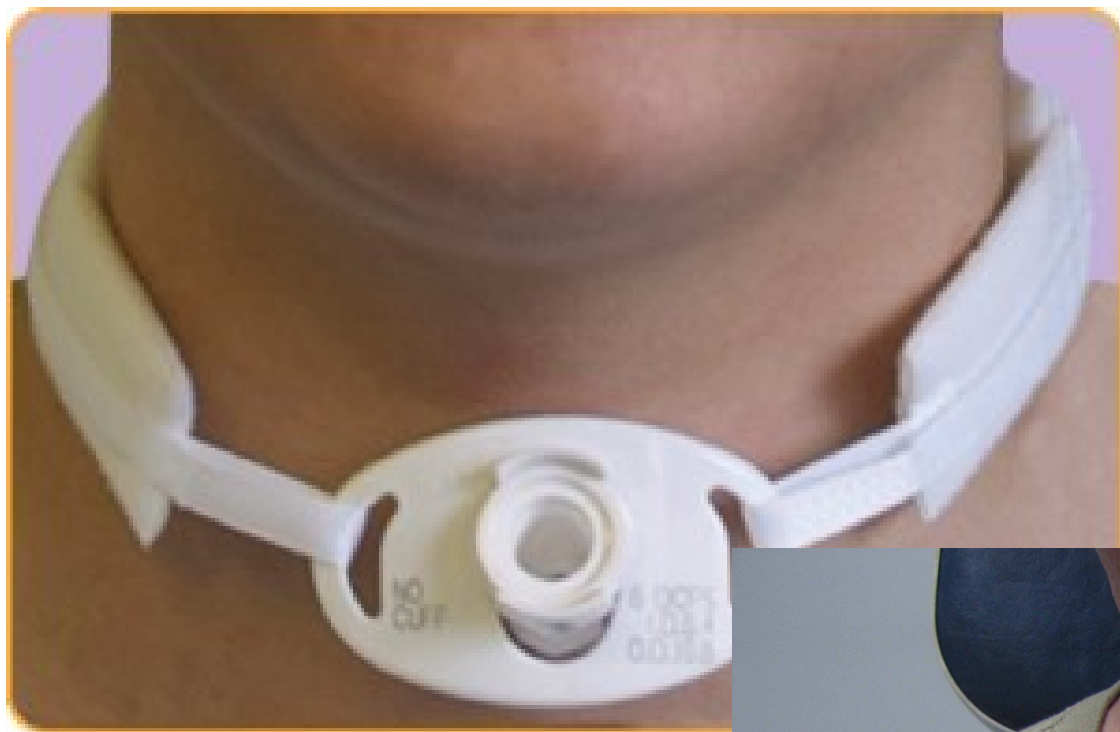
Coniotomy/
Cricothyrotomy

Inferior tracheotomy

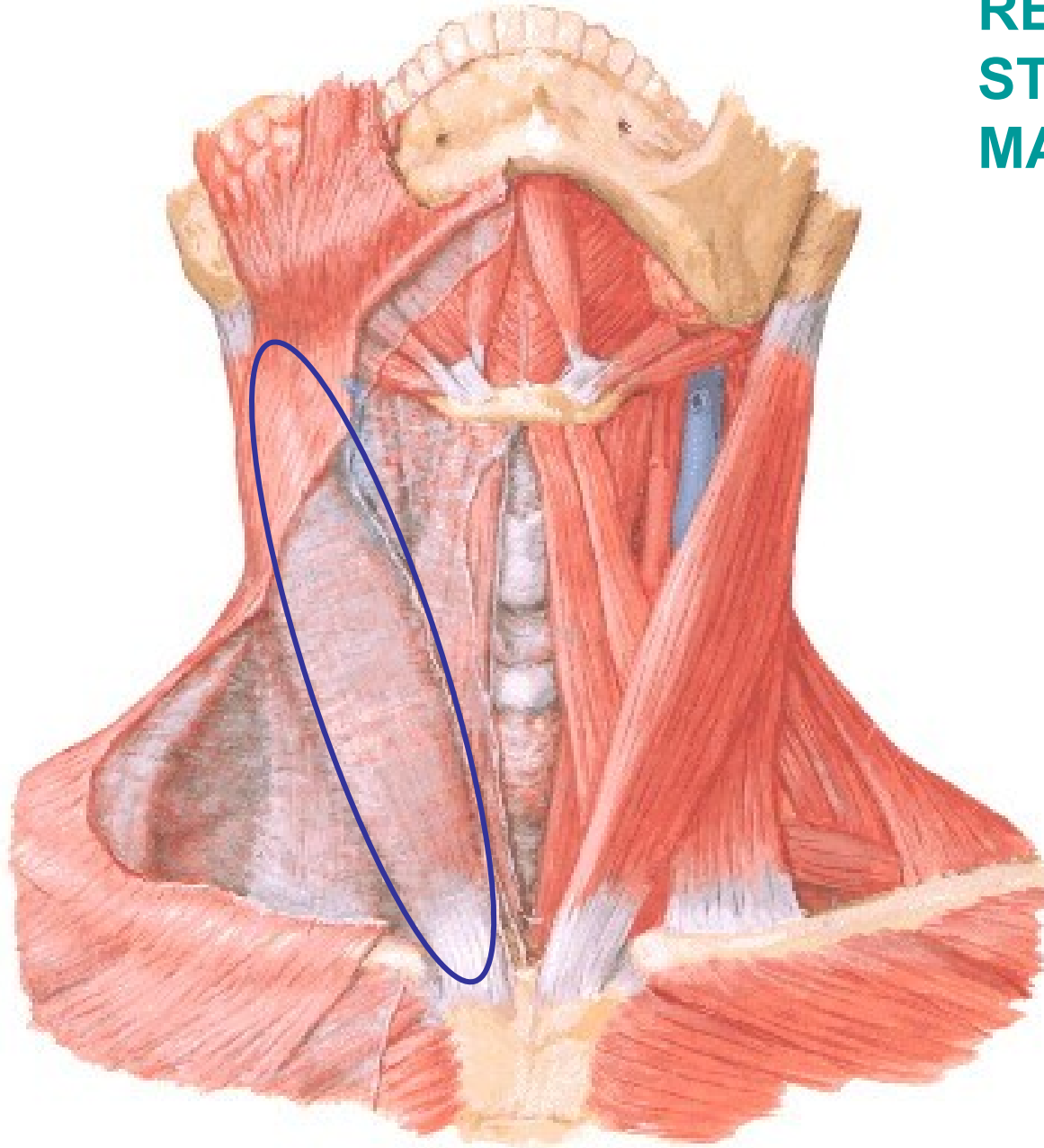


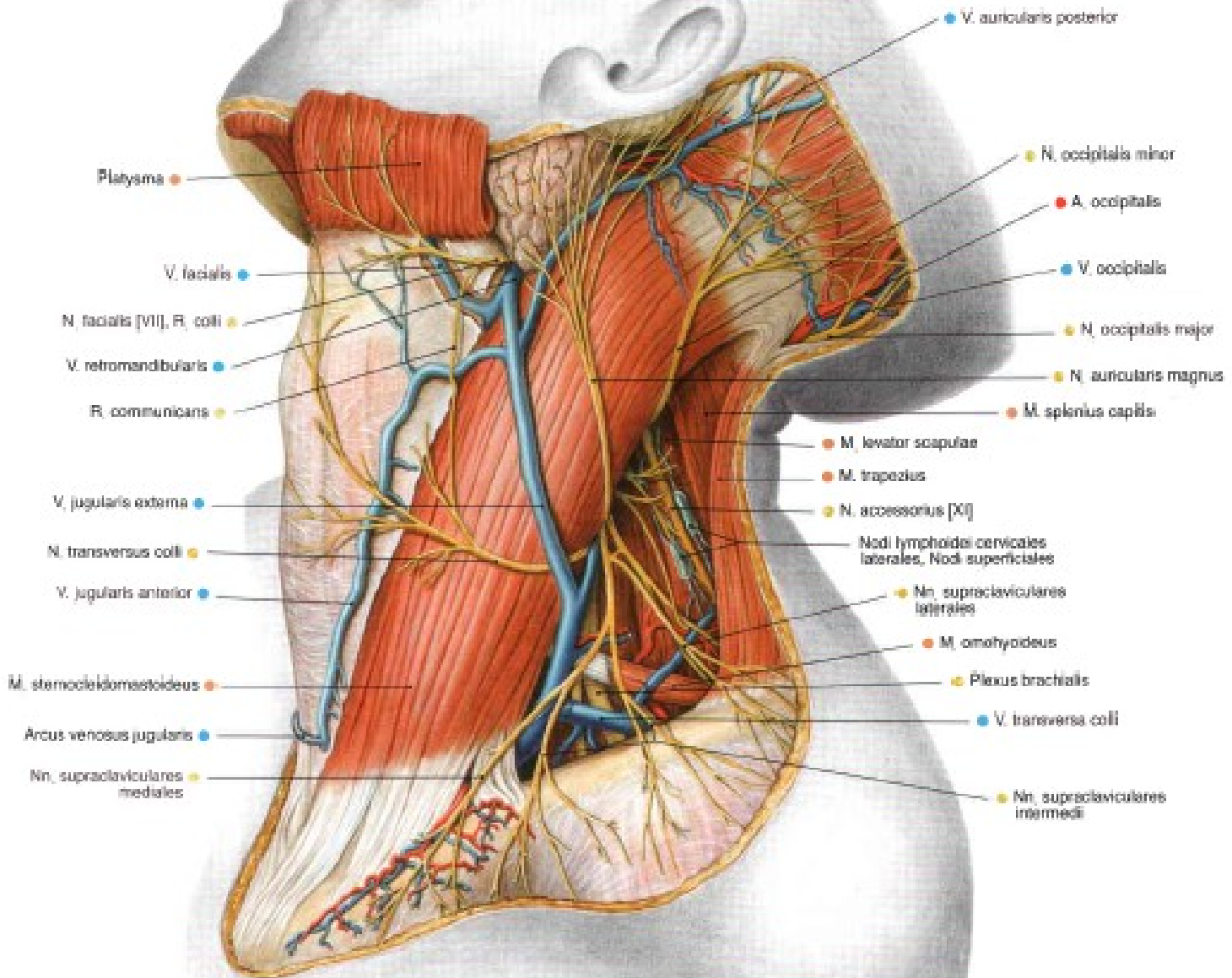




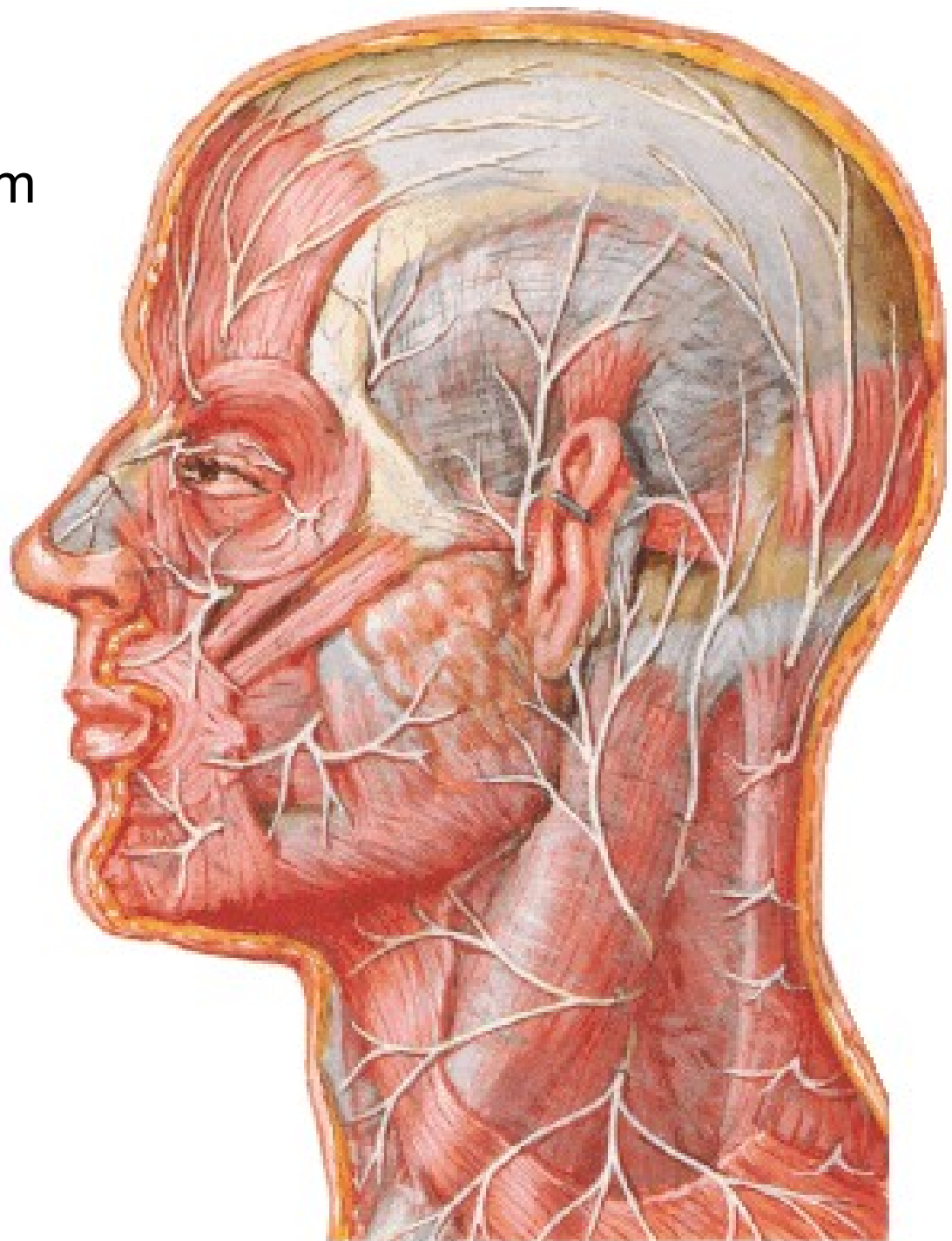
Postop Day 55

REGIO STERNOCLEIDO- MASTOIDEA





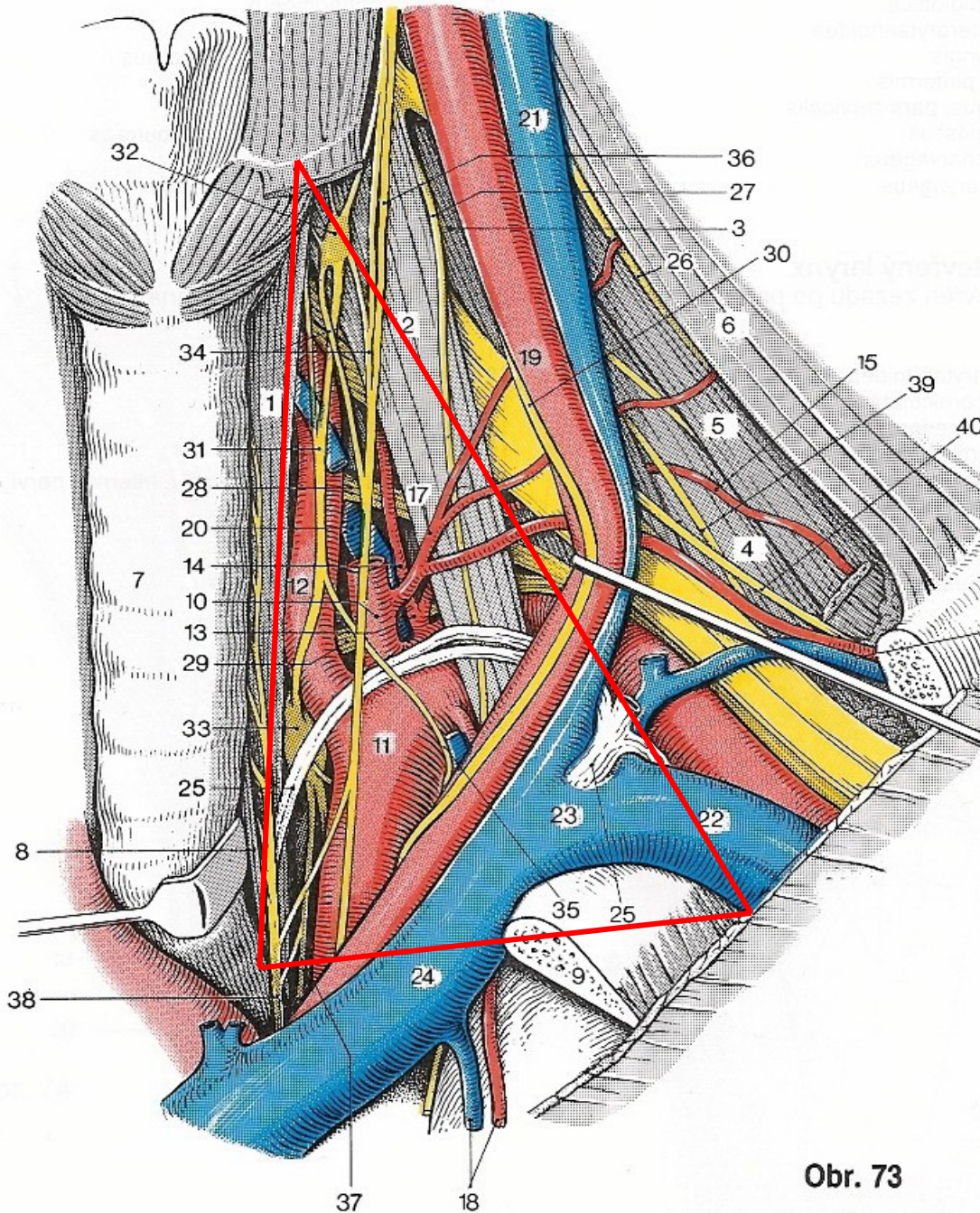
Punctum nervosum
(Erb's point)

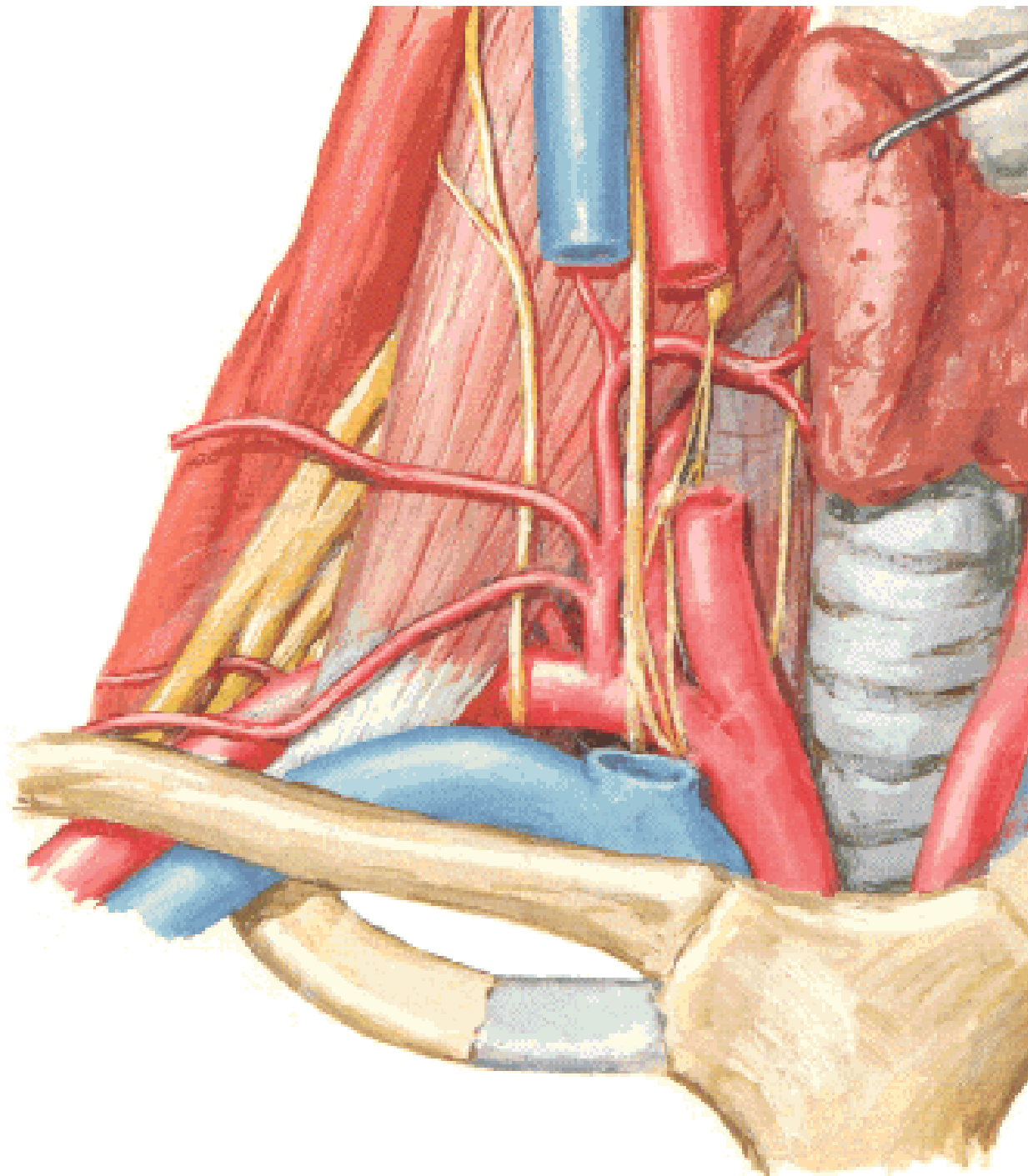


TRIGONUM SCALENOVERTEBRALE S. SUBCLAVIAE

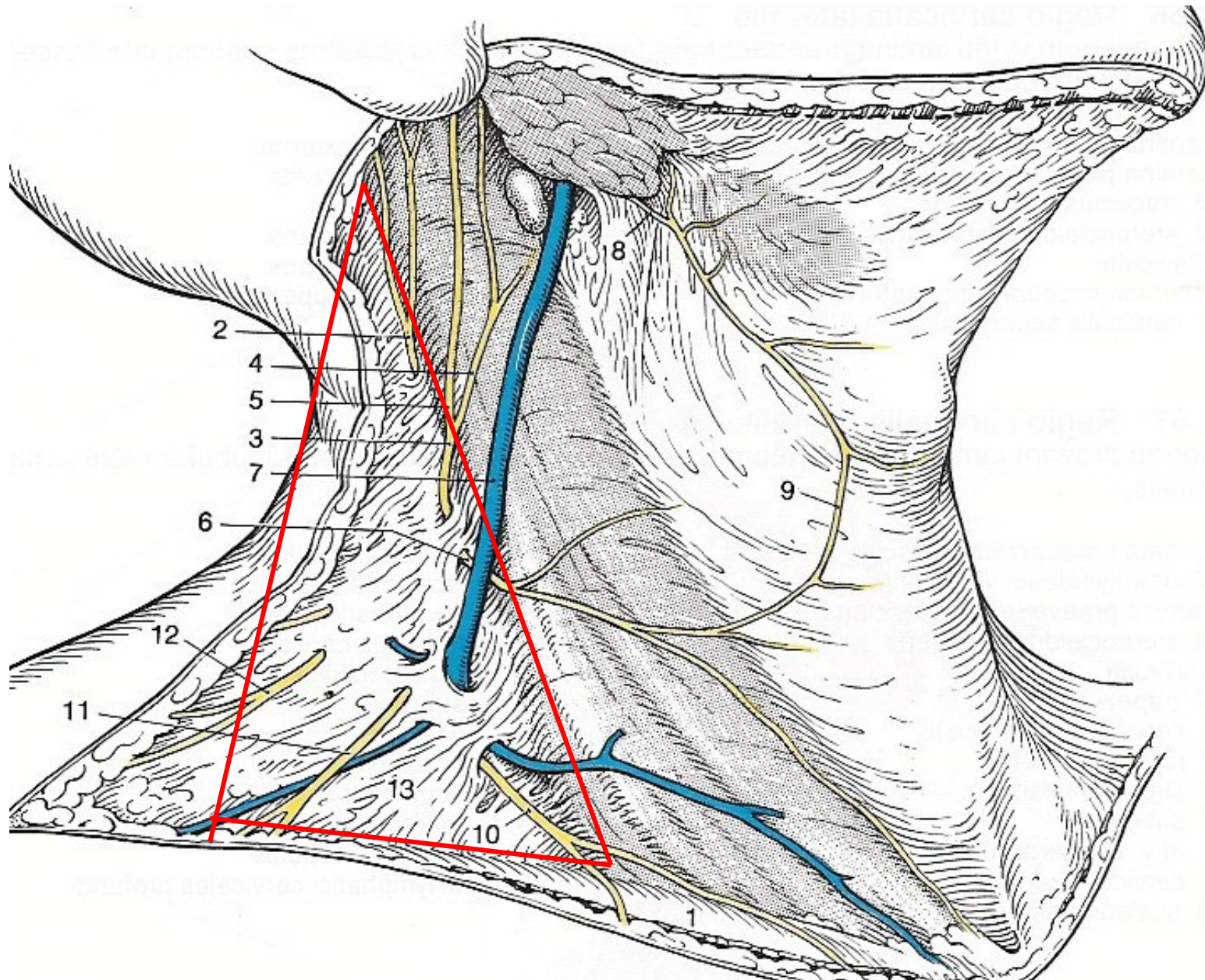
CONTENTS:

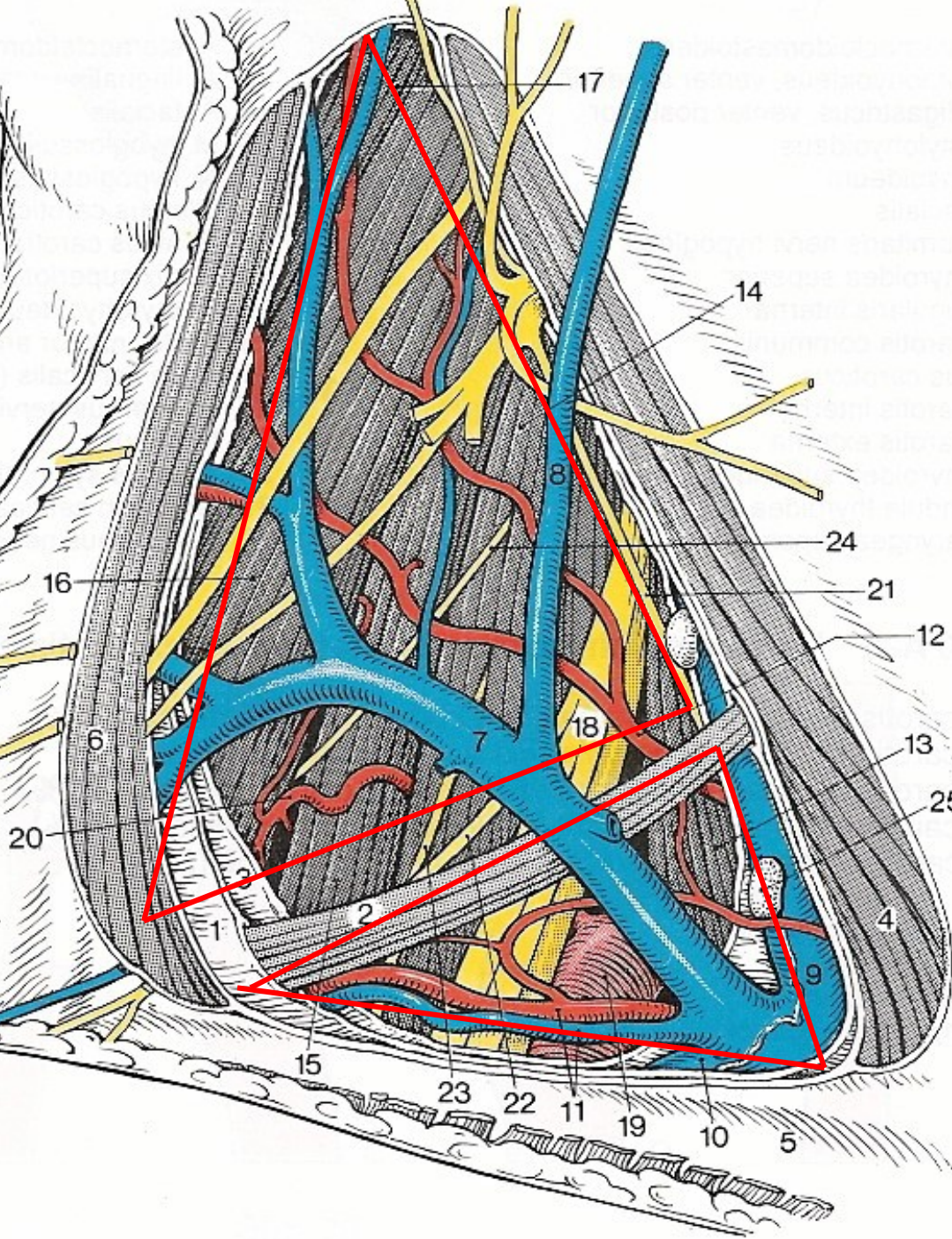
V. SUBCLAVIA
V. JUGULARIS INT.
V. JUGULARIS EXT.
DUCTUS THORACICUS
(TR. LYMPH. DEXTER)
A. CAROTIS COMM.
A. SUBCLAVIA
TR. SYMPATICUS
ANSA SUBCLAVIA
N. VAGUS
NN.+RR. CARDIACI
N. PHRENICUS





TRIGONUM COLLI LATERALE





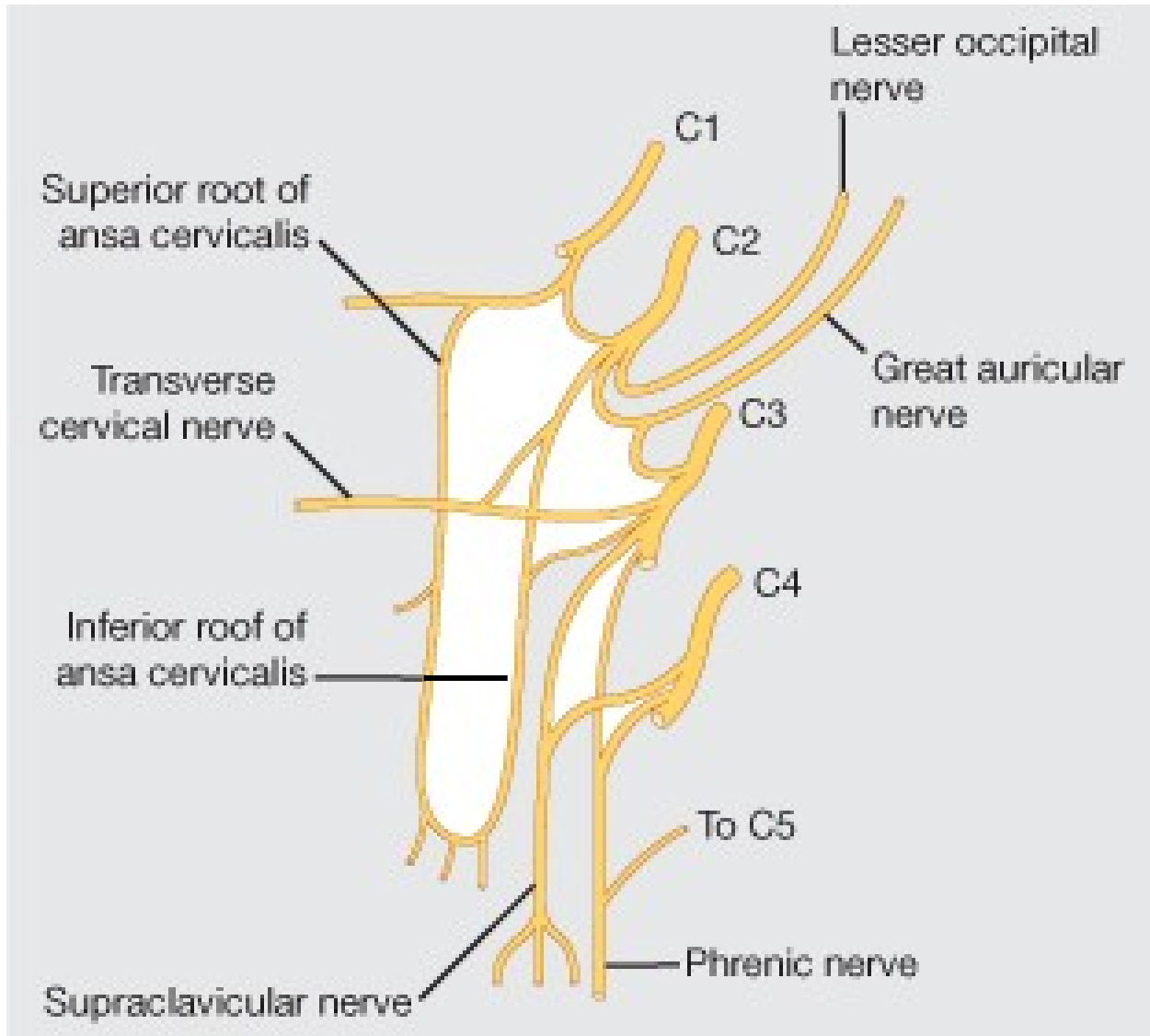
TRIGONUM OMOTRAPEZIUM

A. ET V. CERVICALIS SPF.
 A. DORSALIS SCAPULAE
 CN XI
 PLEXUS CERVICALIS
 N. DORSALIS SCAPULAE
 N. THORACICUS LONGUS
 N. SUPRASCAPULARIS

TRIGONUM OMOCLAVICULARE

V. SUBCLAVIA
 A. SUBCLAVIA
 A. SUPRASCAPULARIS
 PLEXUS BRACHIALIS
 NL. SUPRACLAVICULARES

PLEXUS CERVICALIS



PLEXUS CERVICALIS (C1 – C4)

N. occipitalis minor

N. auricularis magnus

N. transversus colli

Ansa cervicalis spf.

(r. colli CN VII)

Nn. supraclaviculares

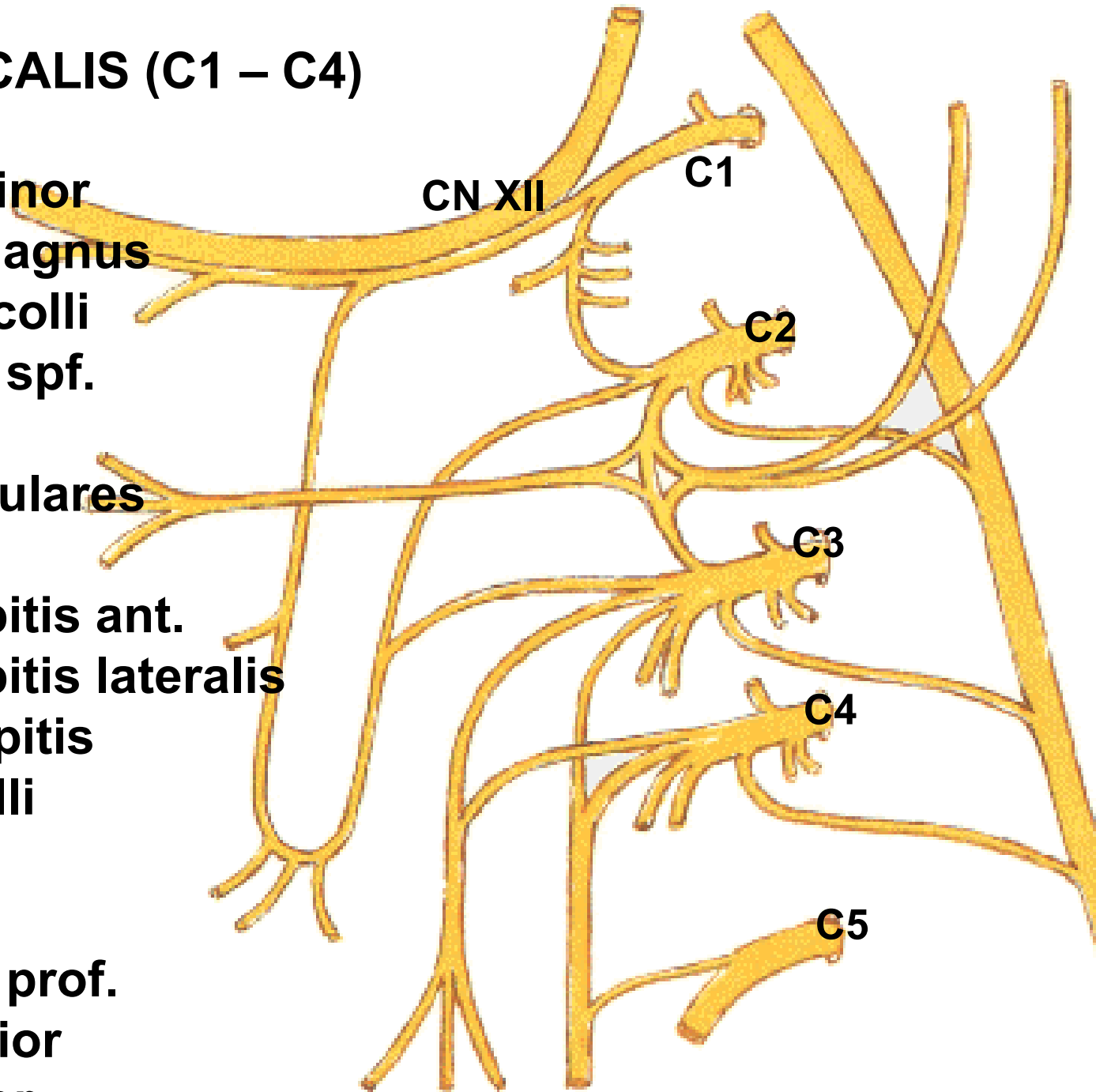
Rr. musculares

- m. rectus capitis ant.
- m. rectus capitis lateralis
- m. longus capitis
- m. longus colli
- mm. scaleni

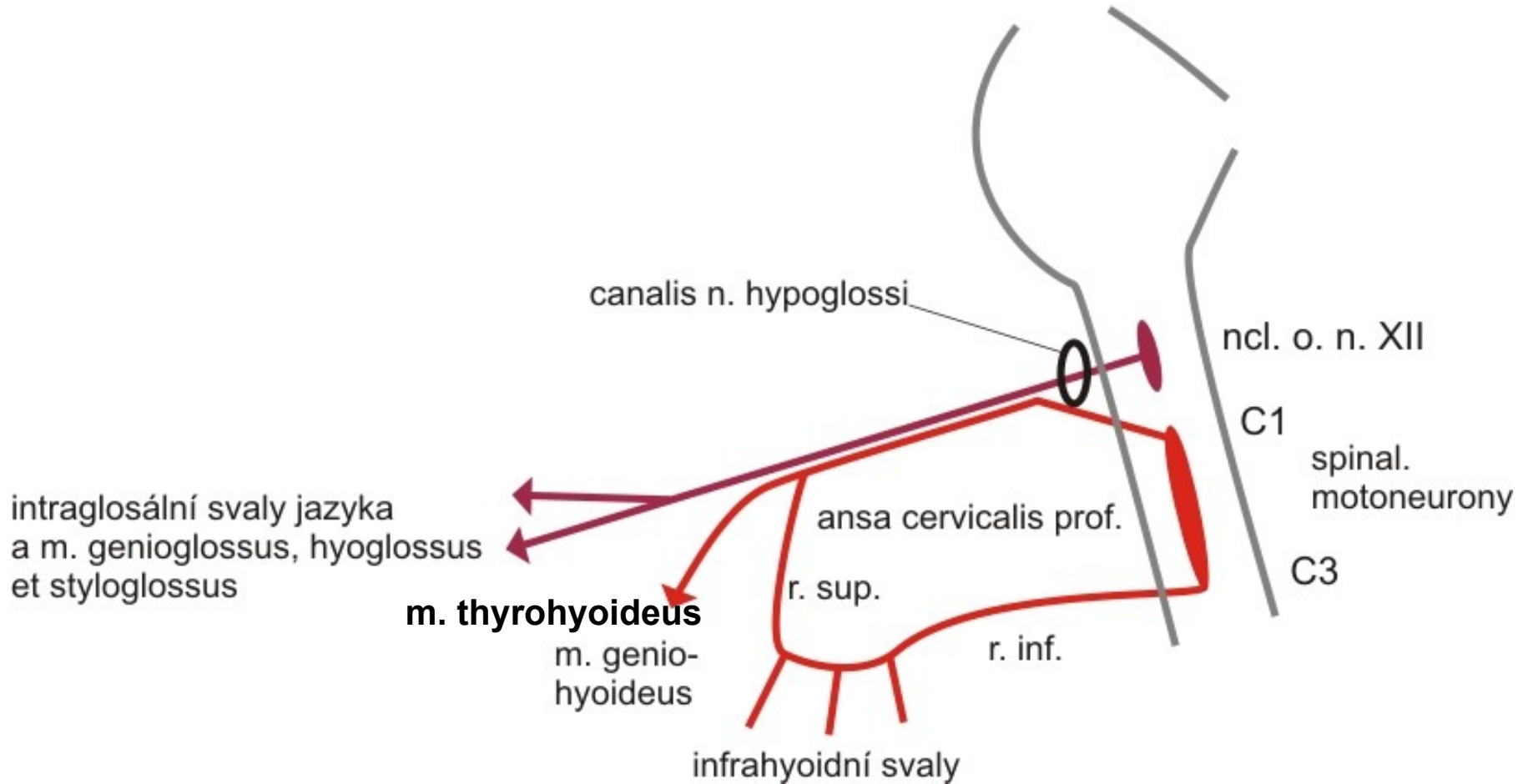
N. phrenicus

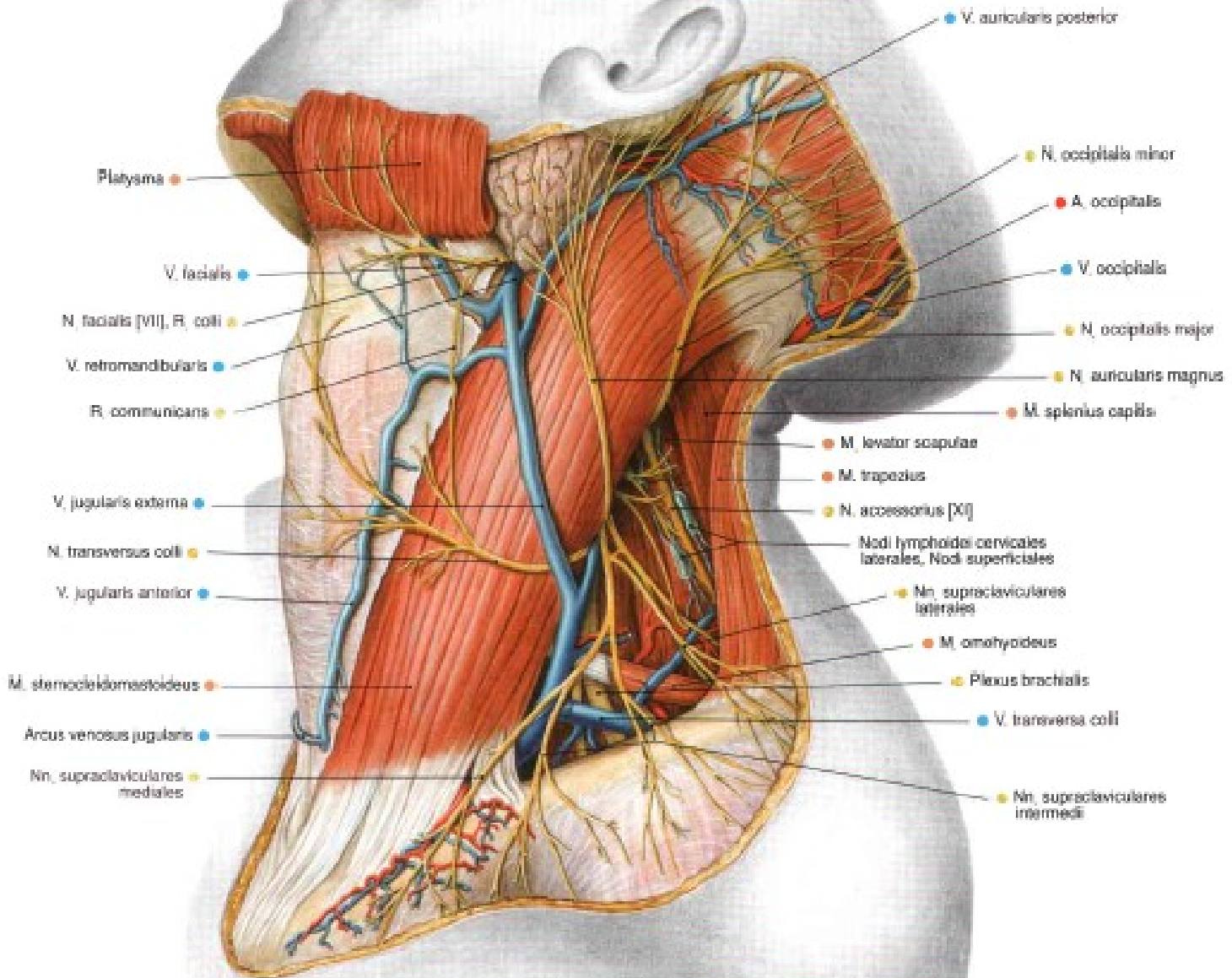
Ansa cervicalis prof.

- radix superior
- radix inferior

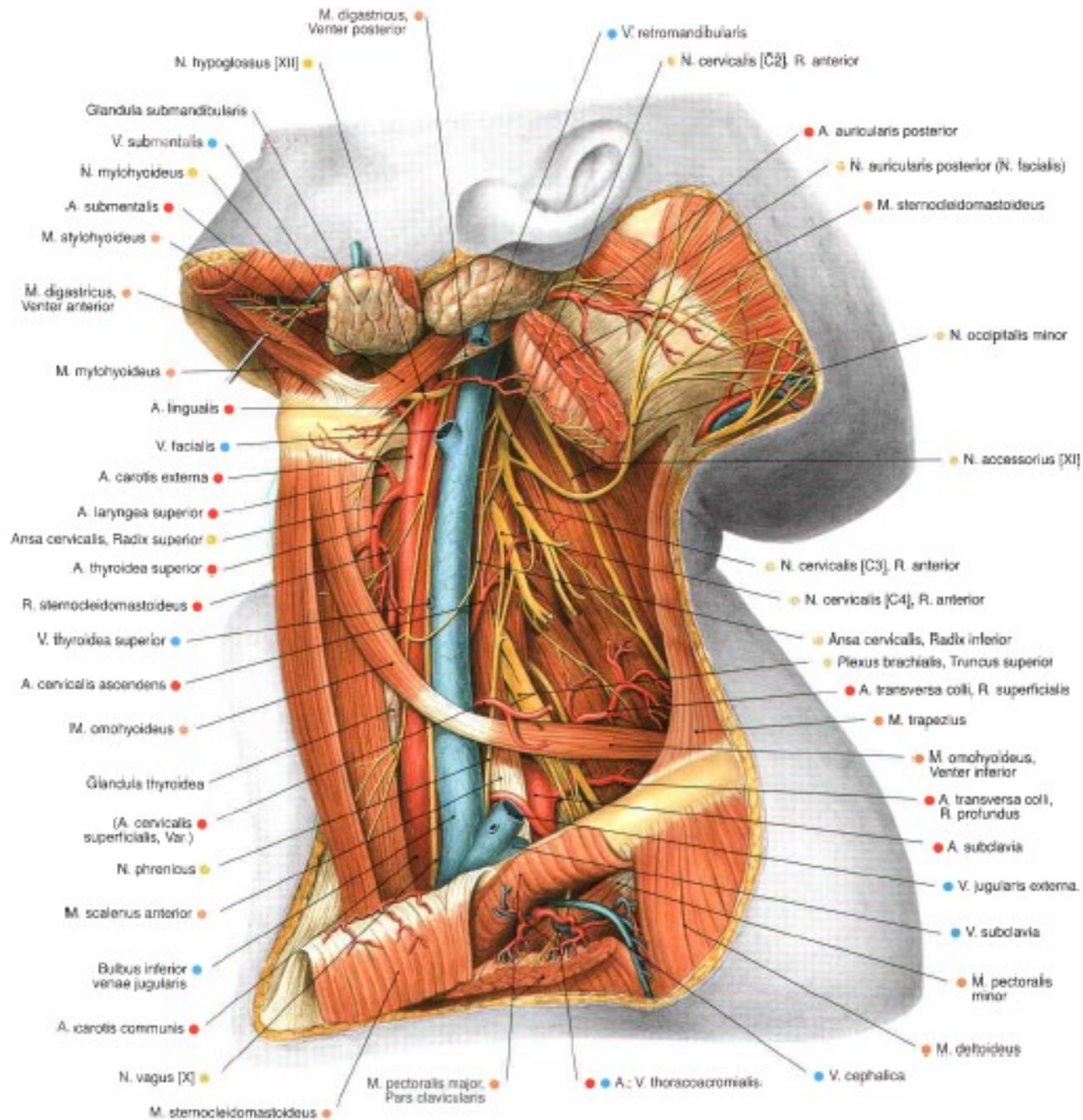


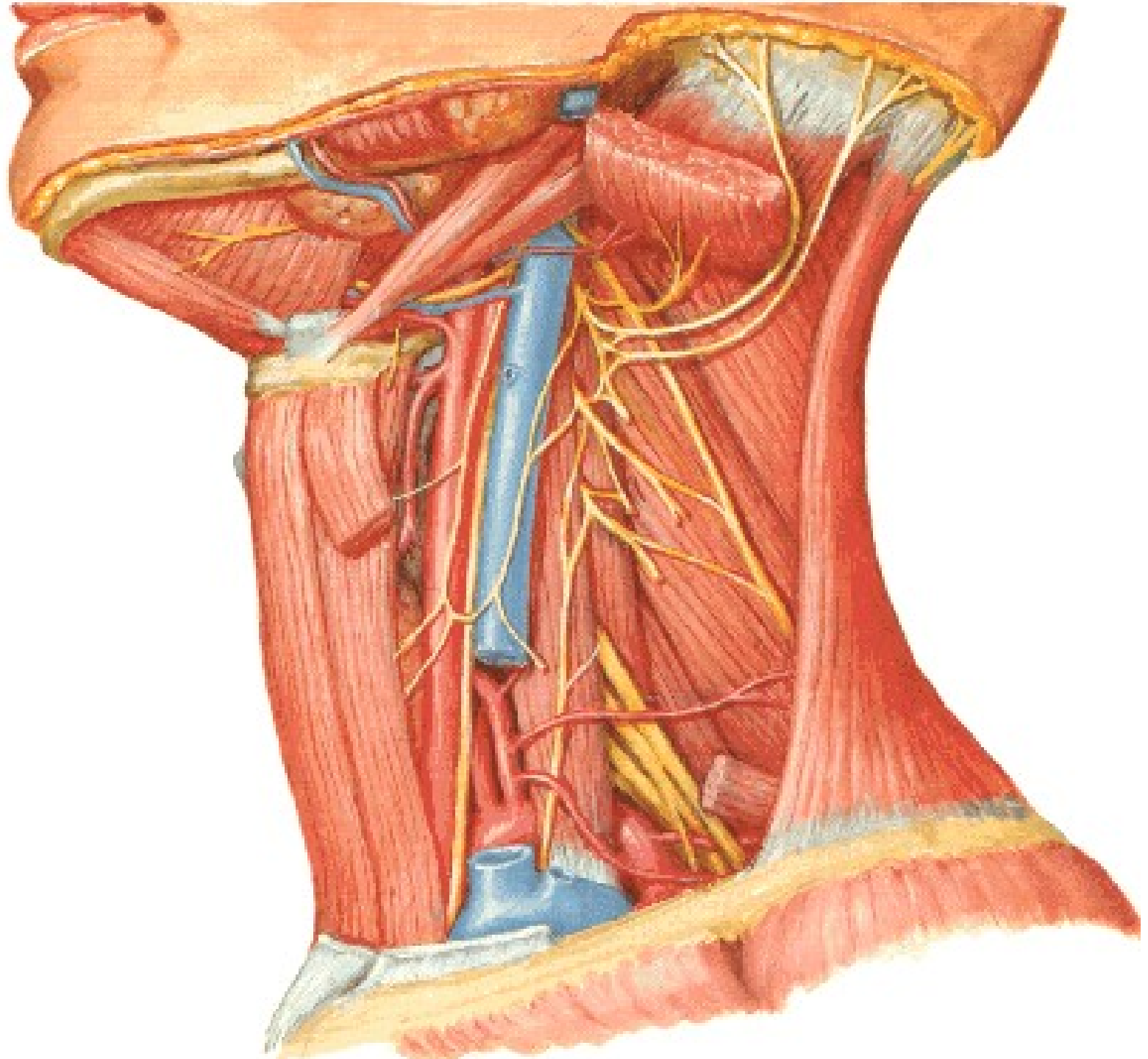
n. XII.



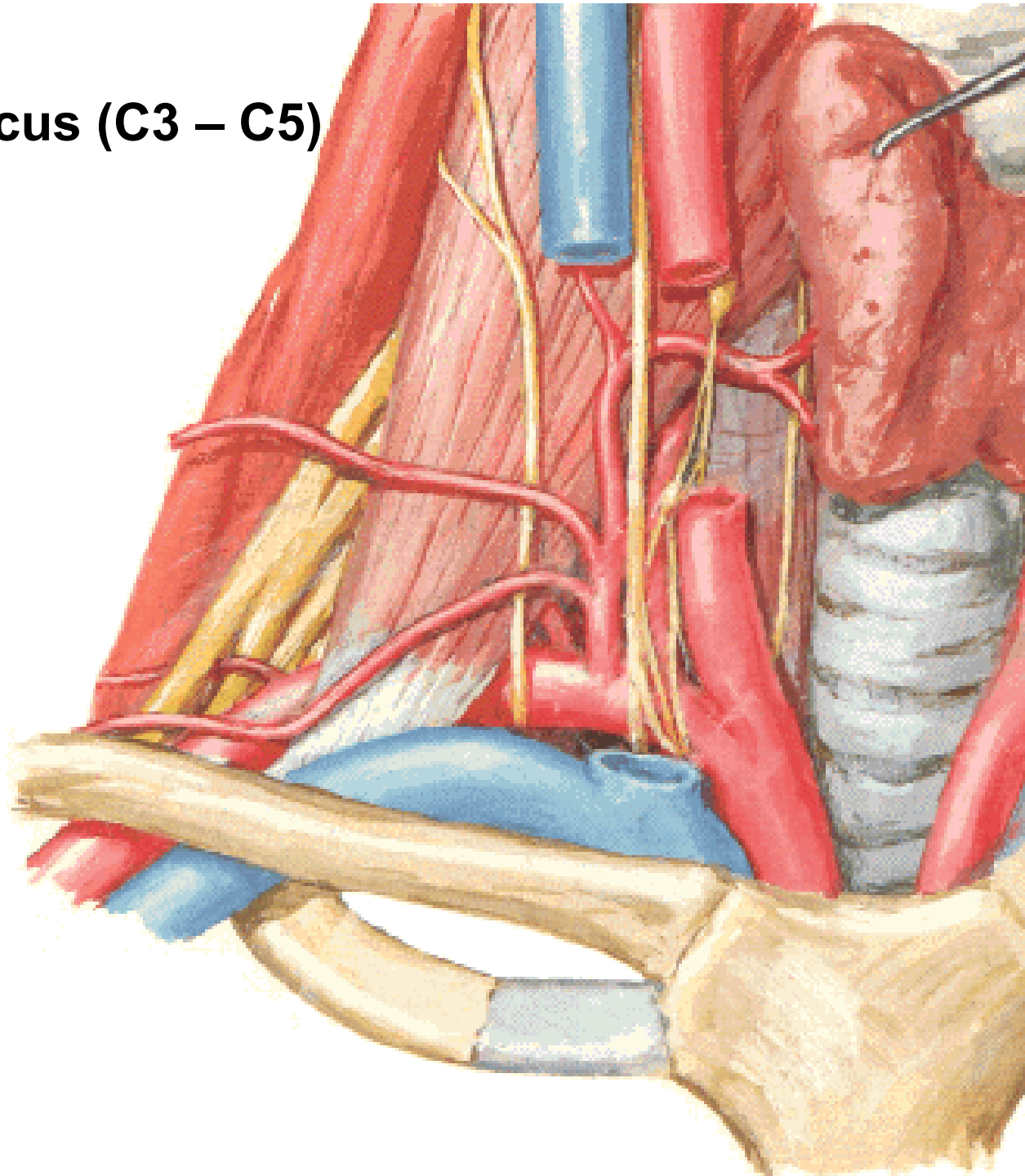


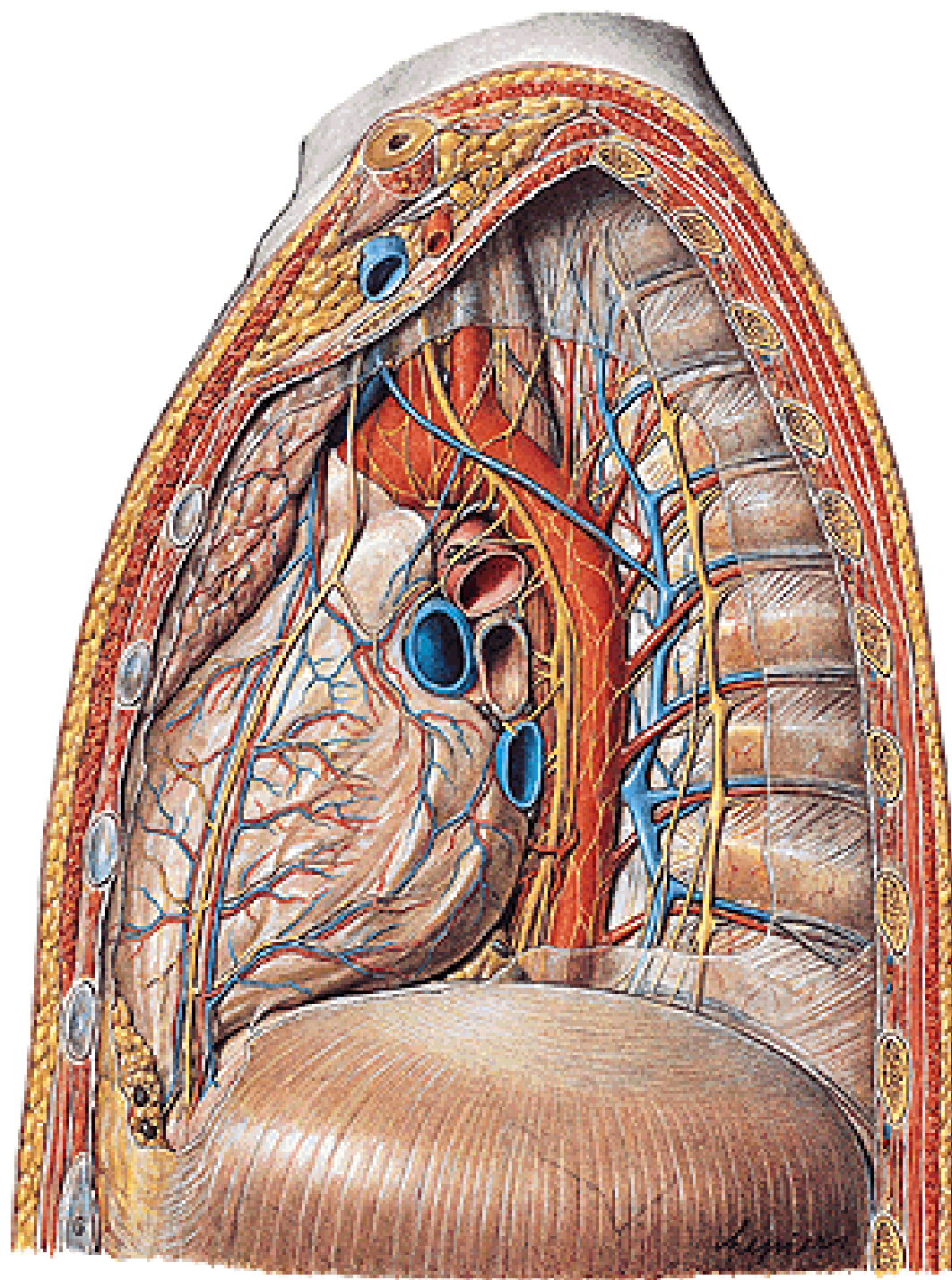
- V. auricularis posterior
- N. occipitalis minor
- A. occipitalis
- V. occipitalis
- N. occipitalis major
- N. auricularis magnus
- M. splenius capitis
- M. levator scapulae
- M. trapezius
- N. accessorius [XI]
- Nodi lymphoidei cervicales laterales, Nodi superficiales
- Nn. supraclaviculares laterales
- M. omohyoideus
- Plexus brachialis
- V. transversa colli
- Nn. supraclaviculares intermedii
- Platyisma
- V. facialis
- N. facialis [VII], R. colli
- V. retromandibularis
- R. communicans
- V. jugularis externa
- N. transversus colli
- V. jugularis anterior
- M. sternocleidomastoideus
- Arcus venosus jugularis
- Nn. supraclaviculares mediales

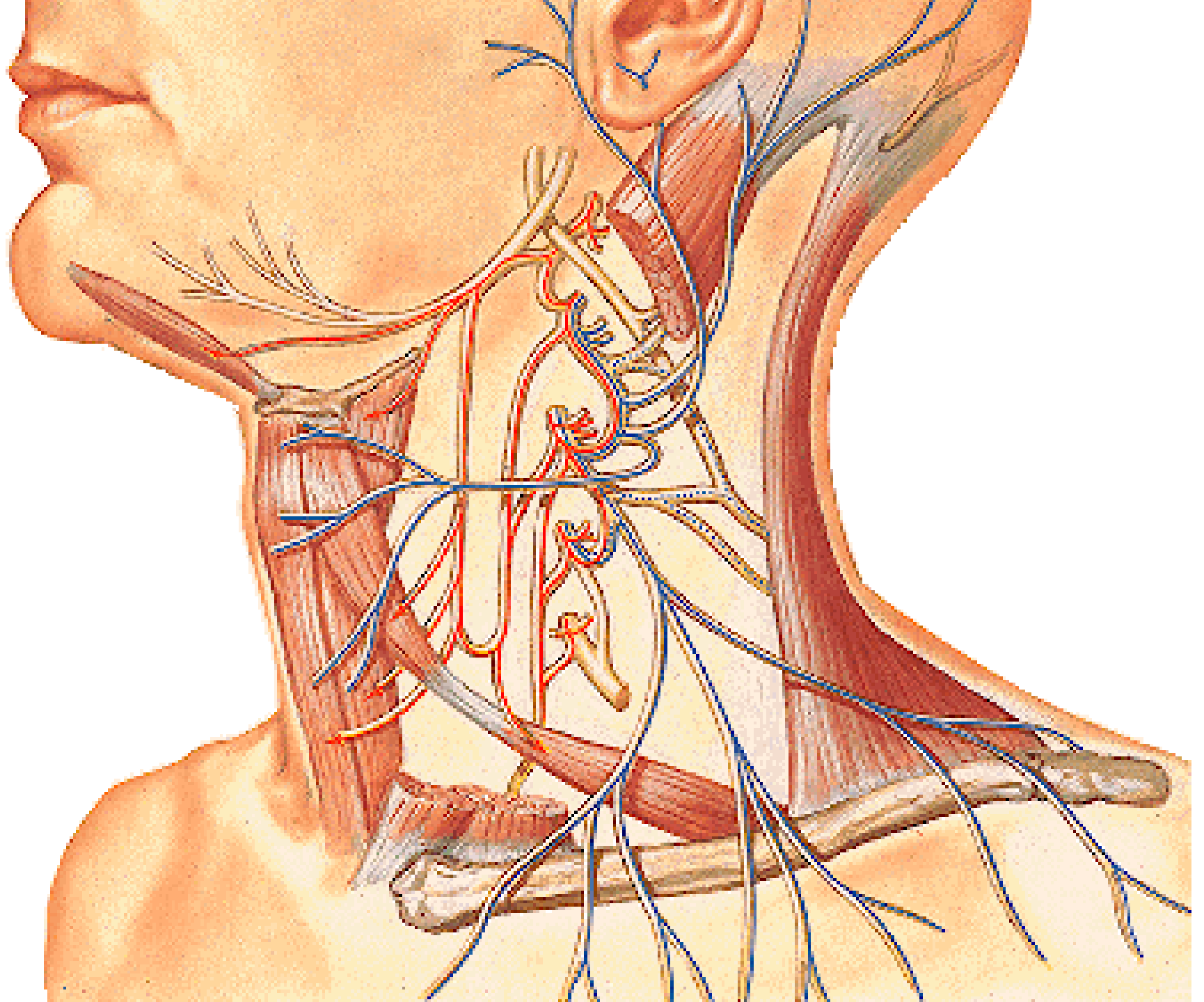




N. phrenicus (C3 – C5)







Illustrations were copied from:

**Atlas der Anatomie des Menschen/Sobotta.
Putz,R., und Pabst,R. 20. Auflage. München:
Urban & Schwarzenberg, 1993)**

**Čihák R: Anatomie 2 (Splanchnologia).
Avicenum,
zdravotnické nakladatelství, Praha, 1988.**