

Endodontics I.

Morphology

Pulp disease

Indication

Contraindication

Instrumentarium

Endodontics

**Pulp and periodontal diseases –
diagnosis, therapy, prevention**

Aim of endodontic treatment

**Healing of pulp diseases or removal
bacteria from the root canal system
and regeneration of damaged periodontal
tissues. (Canal shaping, cleaning and filling)**

„ *Endodontist helps nature only* “

W.D.Miller

Endodoncie I.

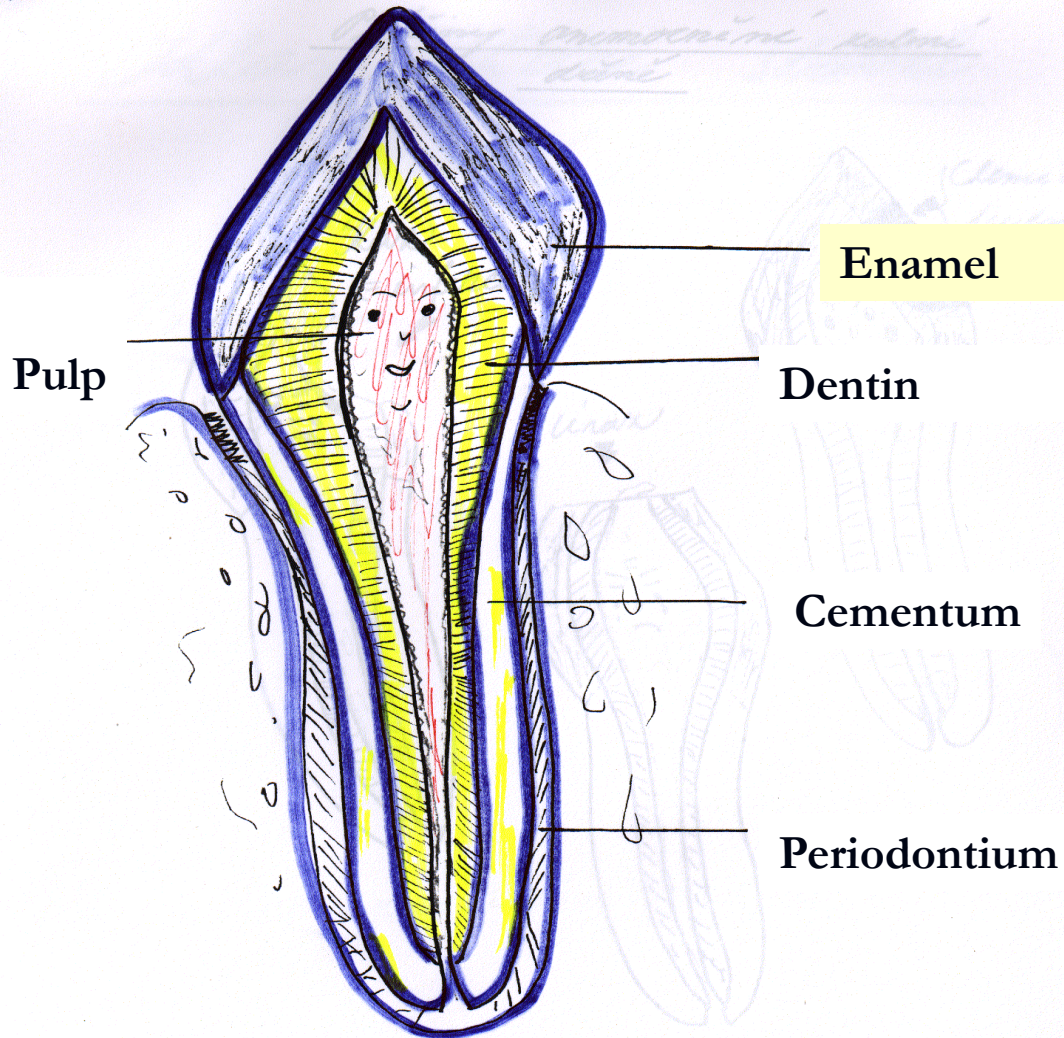
Morphology

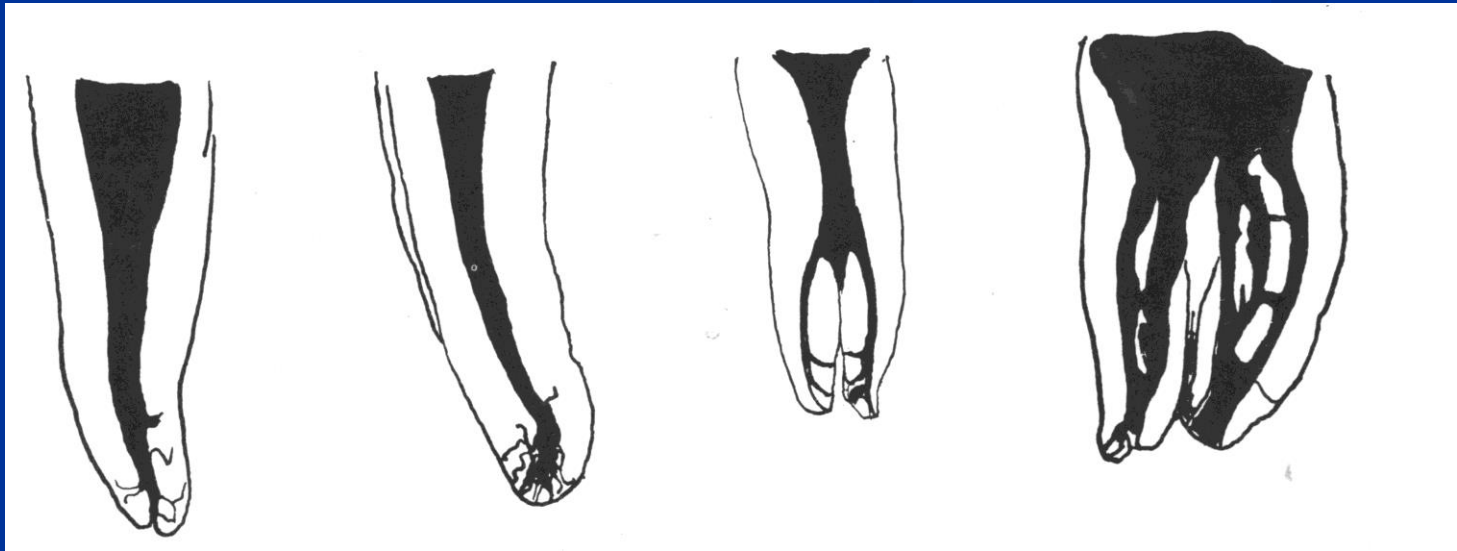
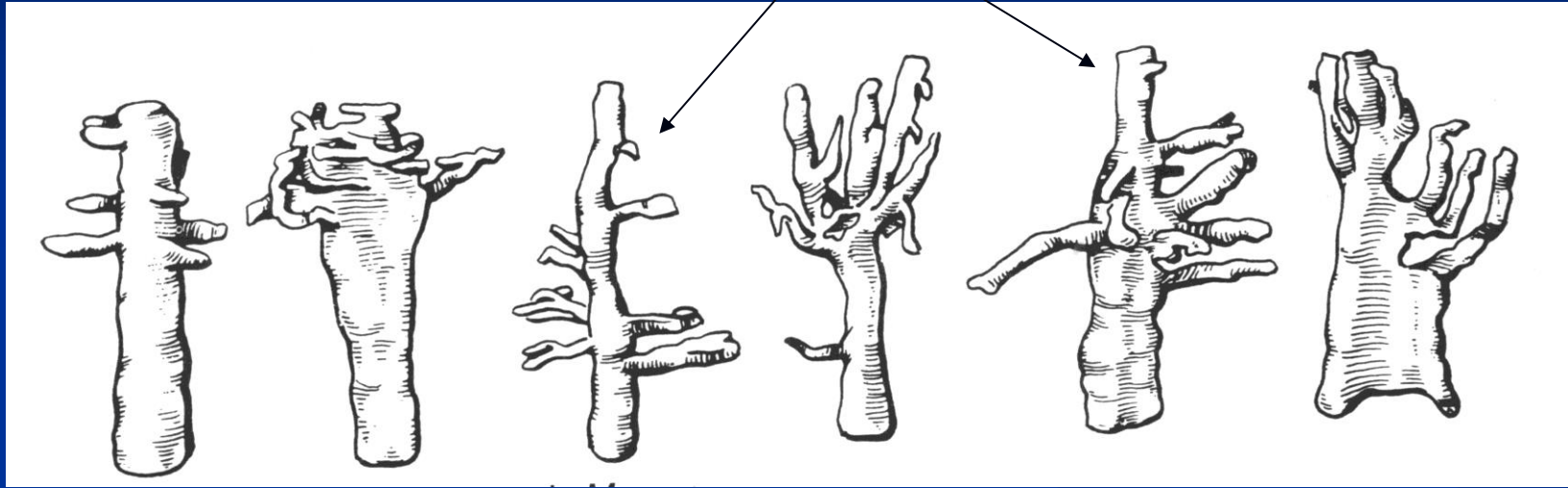
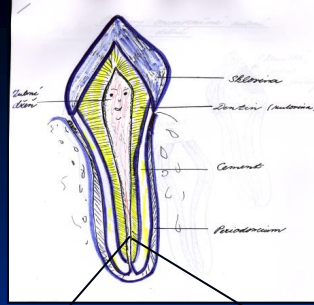
Onemocnění zubní dřeně

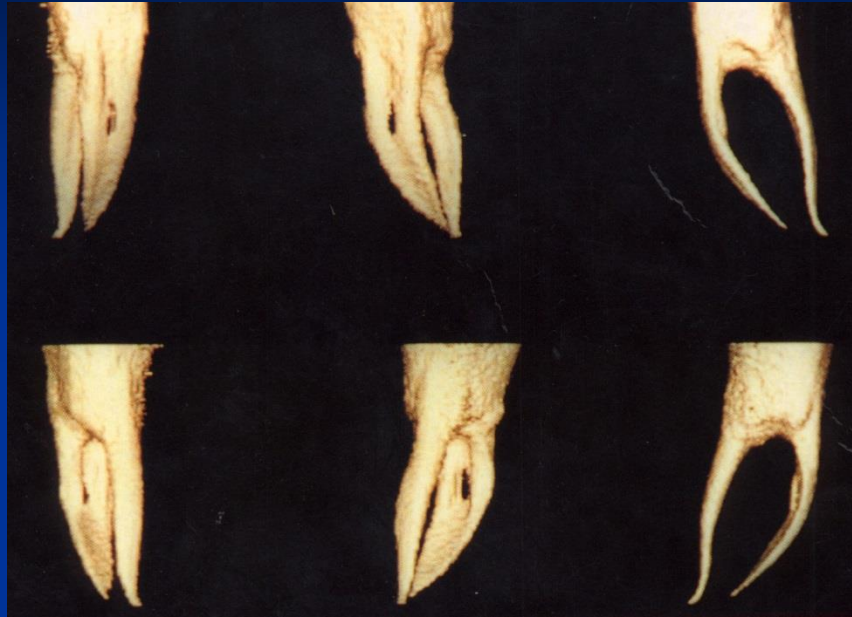Indikace a kontraindikace
endodontického ošetření

Instrumentarium

Morphology







3D

Meyers conclusions

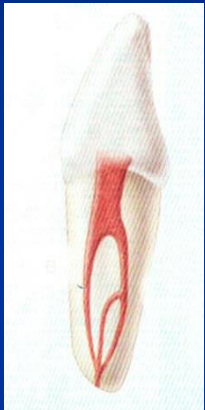
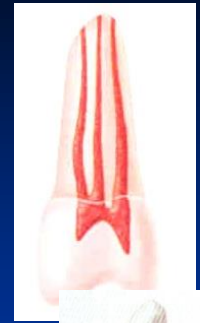
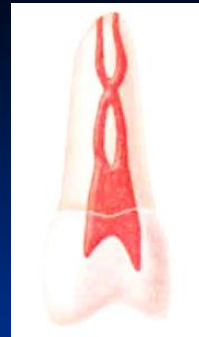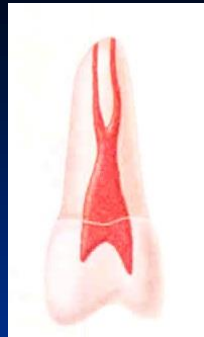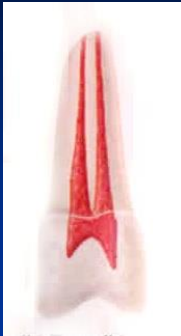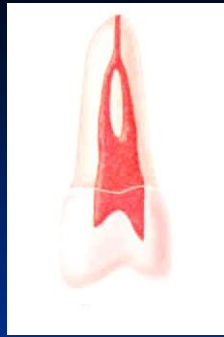- The root canal is not round but oval (long axis mesiodistal)
- The root canal does not go straight but it deflects distal
- The apical foramen is not on the top of the root but below (distal or distooral)

Meyer's conclusions

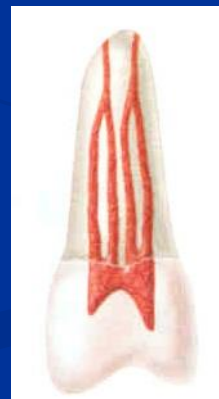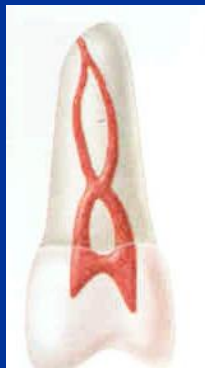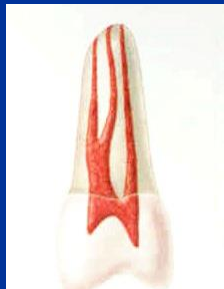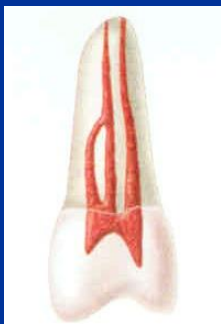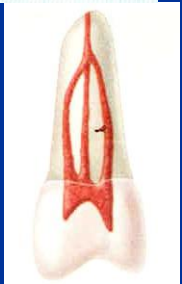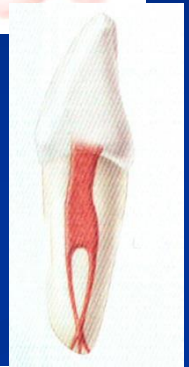- The walls of the root canal between apical constriction to apical foramen are divergent
- The root canal system has usually more apical foramina (side branches – ramifications)
- The ramifications are situated mostly in apical area (first apical mm)
- All foramina are situated in cementum

Basic forms of the root canal system (Weine)

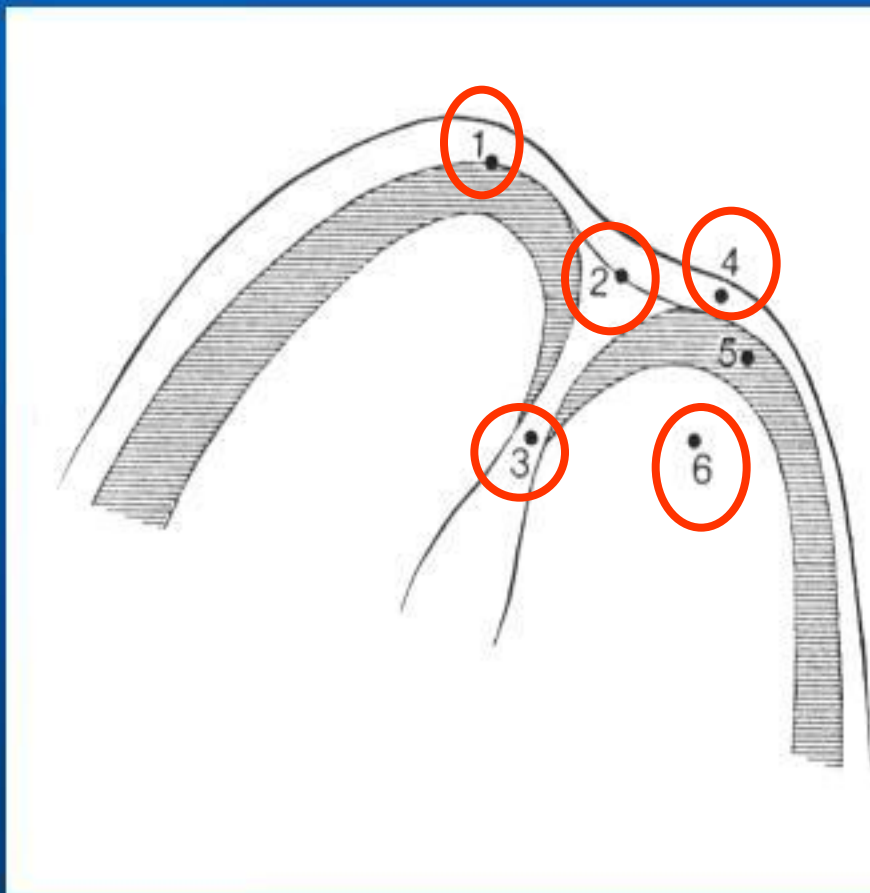




**Vertucci
Gulabivala
Kartal a Yanikoglu....**



Apical morphology

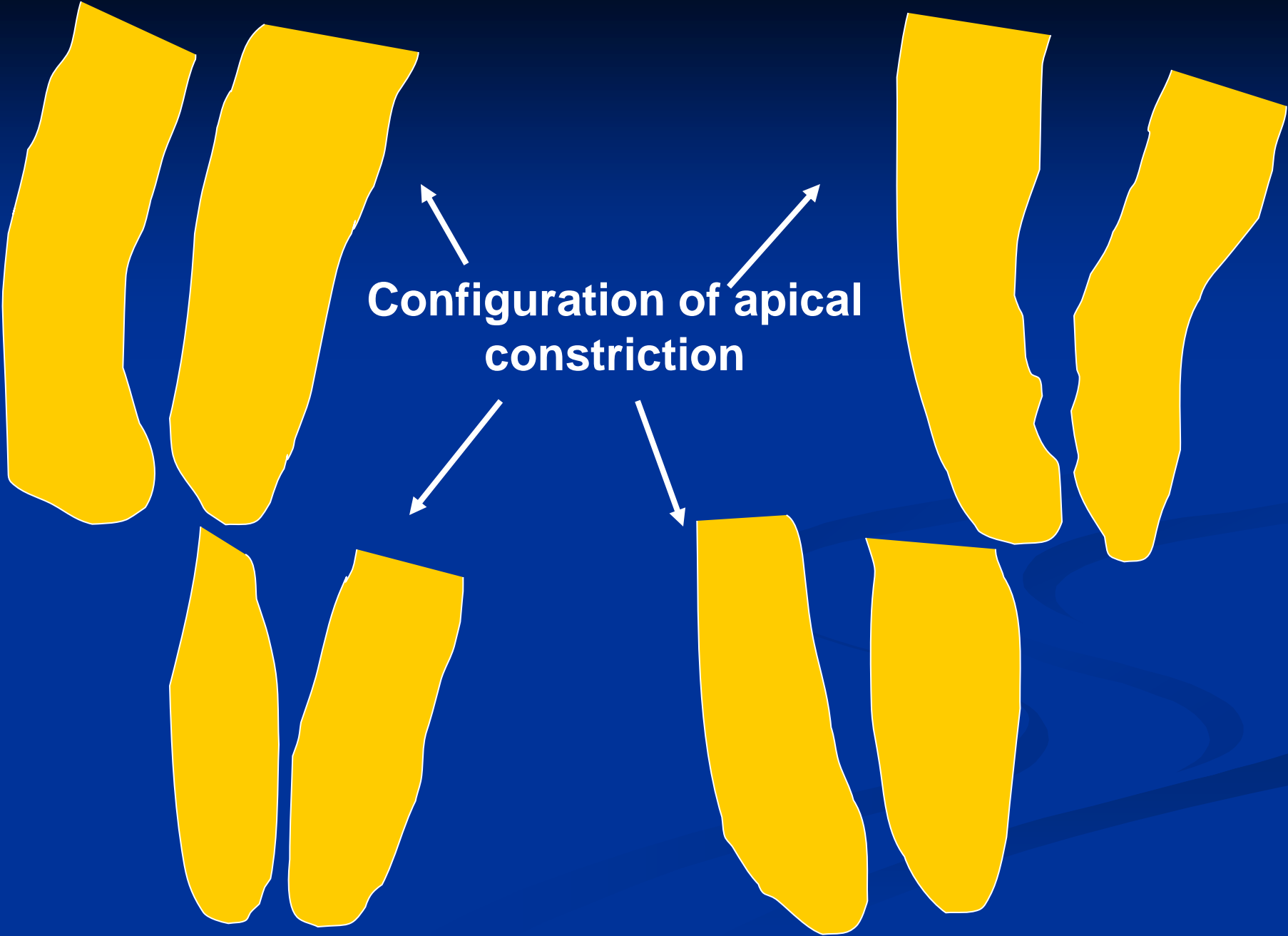



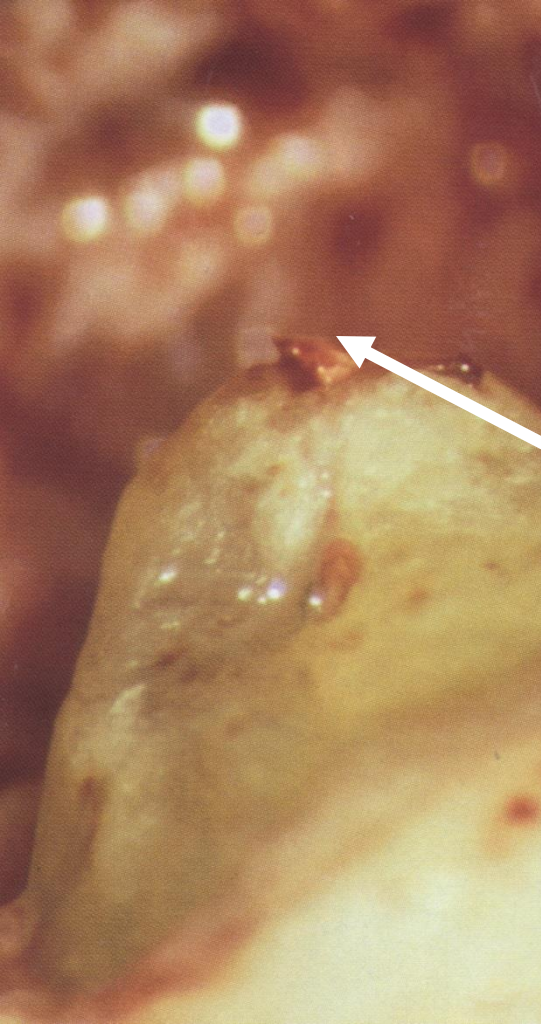
1. X – ray apex
2. Foramen apicale
3. Apical constriction
4. Periodontal ligament
5. Root cementum
6. Dentin

Canal shaping terminates in apical constriction

- Small communication
- Less risk of periodontal damage
- Prevention of overfilling
- Prevention of apical transport of infectious material
- Possibility of good bacterial decontamination
- Possibility of good condensation of the root filling

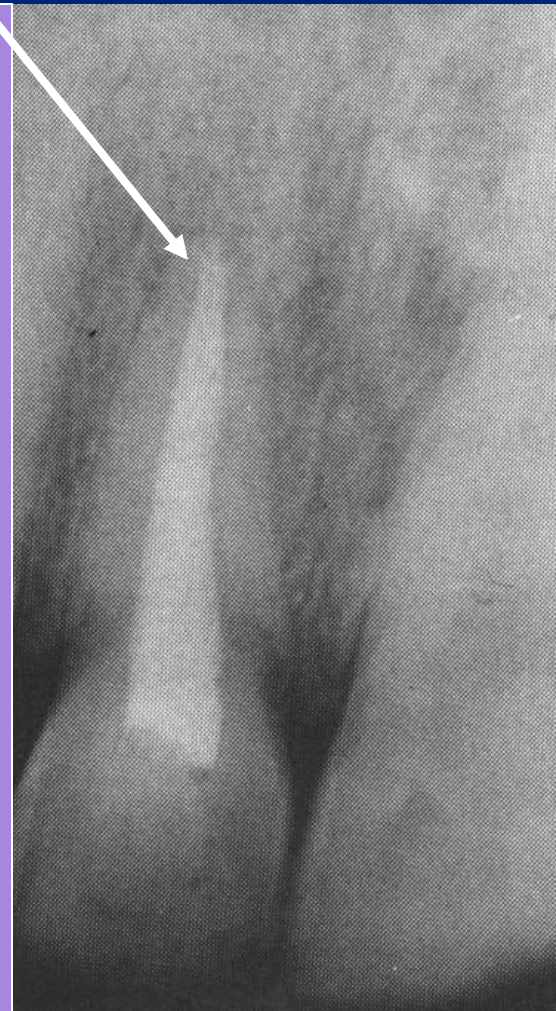
**Configuration of apical
constriction**





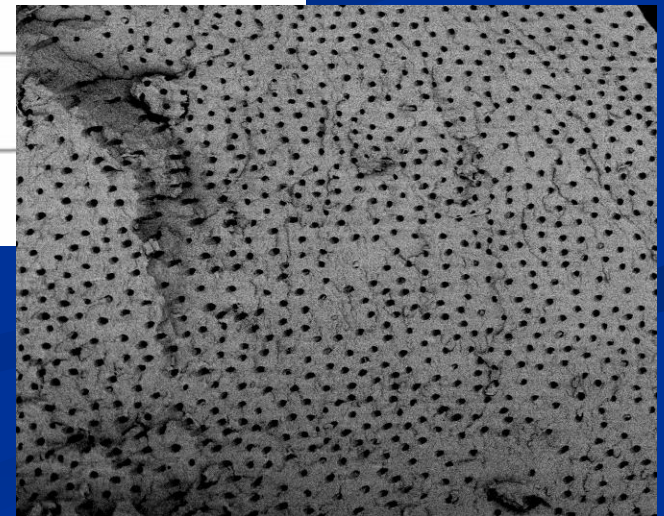
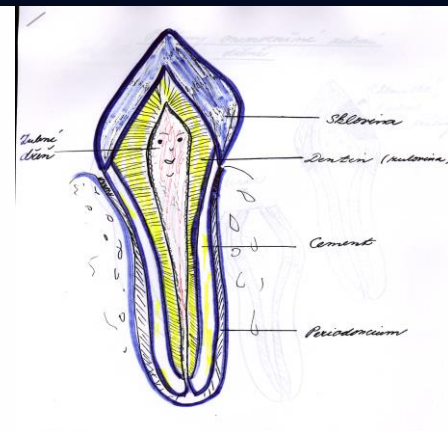
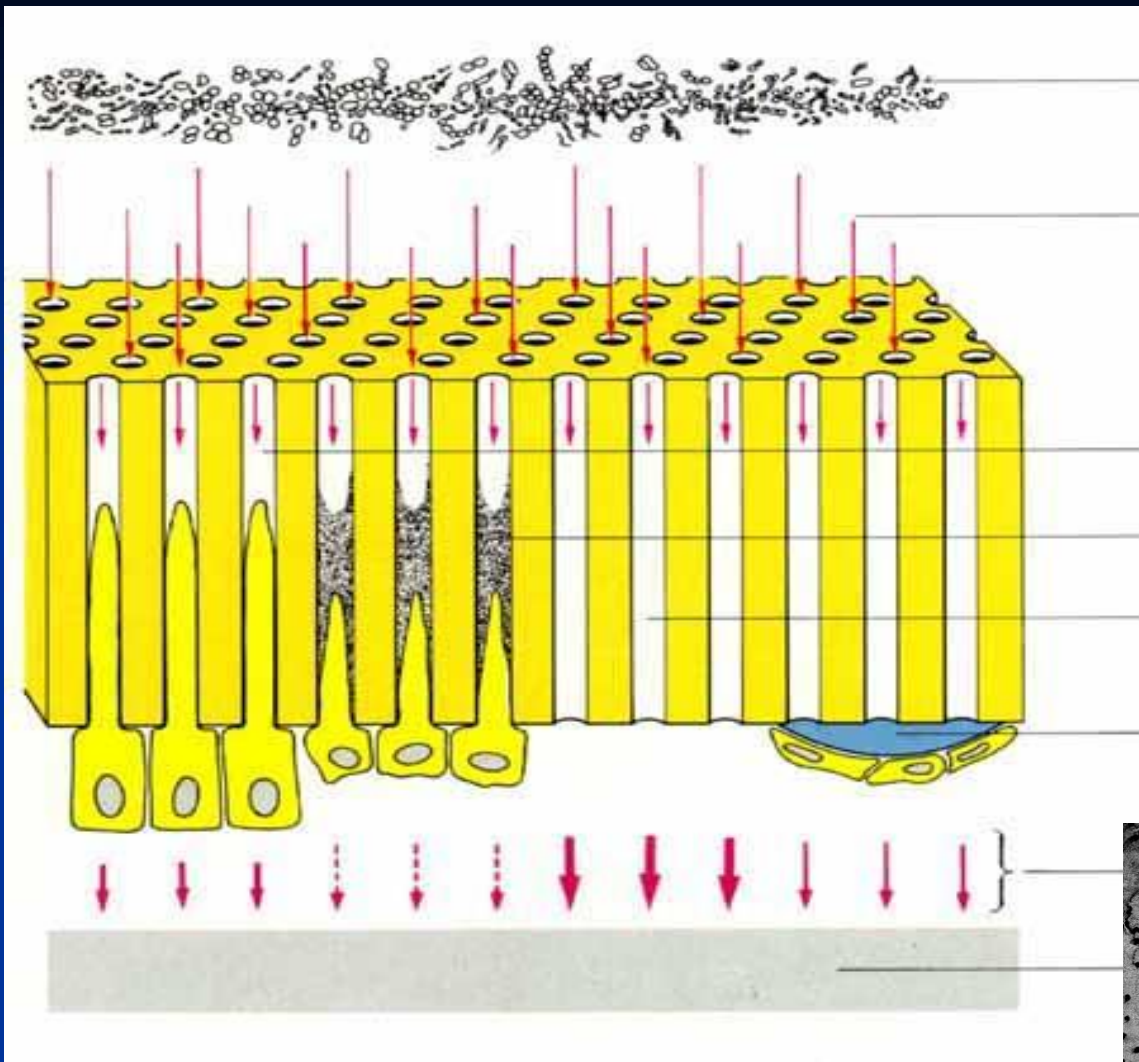
Real situation

X- ray apex




- Macrocanal system

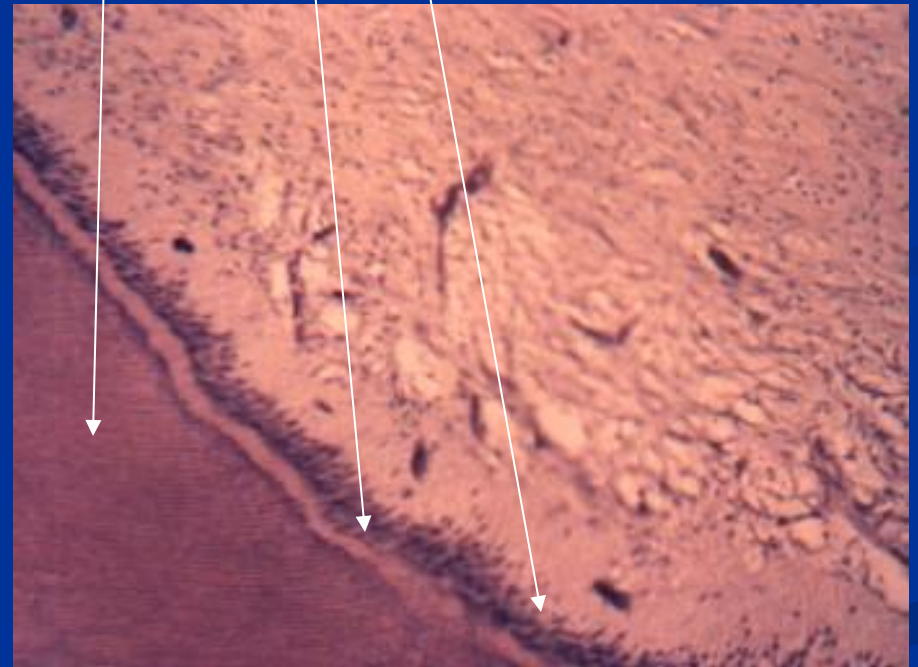
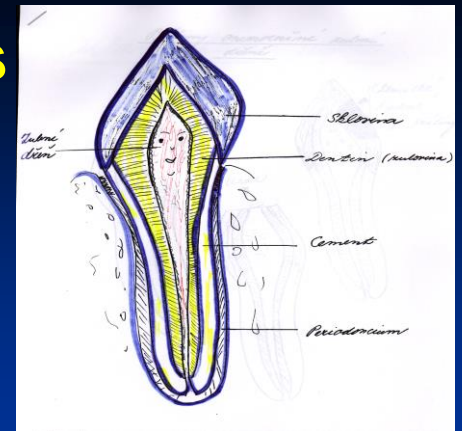
- Microcanal system



**Endodont: dentin and pulp
(morphological and functional unit)**



Odontoblasts
Predentin
Dentin



Dental pulp

Defense mechanisms of the pulp

- Sclerosis
- Tertiary dentin
- Dentin bridge



Pulp diseases

Inflammation - pulpitis

Consequences

- Necrosis
- Gangraena
- Apical periodontitis

Reasons

- Bacteria
- Mechanical irritants (overinstrumentation, trauma)
- Chemické (esp. phenolic based intracanal medicaments, overfilling, irrigants)

Classification of pulp diseases

- **Histopatological**

Hyperemia pulpae

**Pulpitis acuta serosa partialis
totalis**

**Pulpitis acuta purulenta partialis
totalis**

Classification of pulp diseases

- Histopathological

Pulpitis chronica clausa

aperta

ulcerosa

polyposa

Classification of pulp diseases

Clinical

Reversible pulpitis

Pain does not linger after stimulus is removed

Pain is difficult to localize

Normal periradicular appearance

Teeth are not tender to percussion

Classification of pulp diseases

Clinical

Irreversible pulpitis

Pain may develop spontaneously or from stimuli

In later stages heat is more significant

Response lasts from minutes to hours

When the periodontal ligament is involved, the pain is localized

A widened periodontal ligament may be seen in later stages



Úprava ad integrum ?

ZUBNÍ DŘEŇ

Zánět

Akutní

Chronický

Nekróza

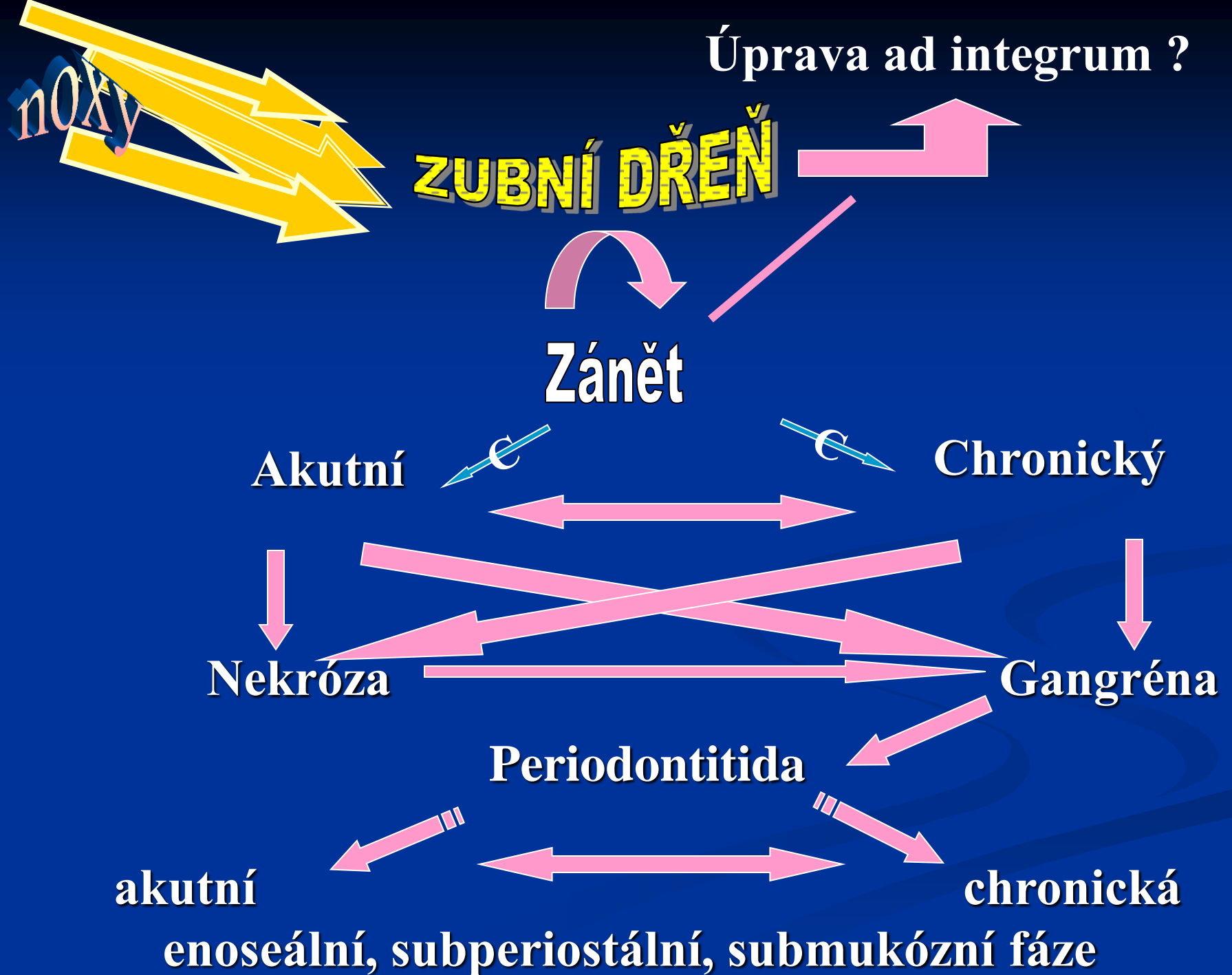
Gangréna

Periodontitida


akutní

chronická

enoseální, subperiostální, submukózní fáze



Cumulative trauma of dental pulp



Diagnosis

■ History

Presenting complaint

Medical history

Dental history

Pain history

Location

Type and intensity of pain

Duration

Stimulus

Relief (analgetics, antibiotics, sipping cold drinks)

Diagnosis

Clinical examination

Extraoral (swelling, redness, extraoral sinuses, lymph nodes, degree of mouth opening)

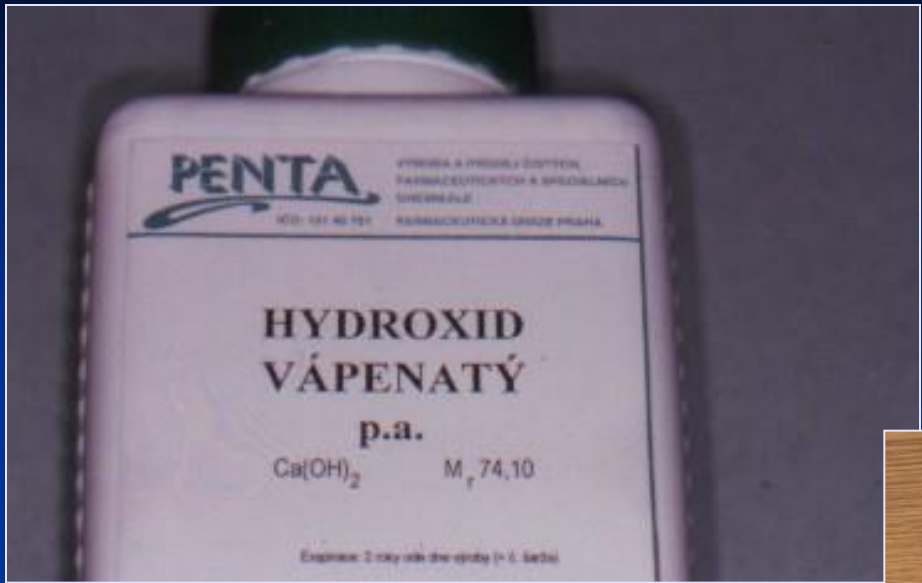
Intraoral examination

Swelling, redness, palpation, percussion, sinus tract examination, teeth mobility, pockets

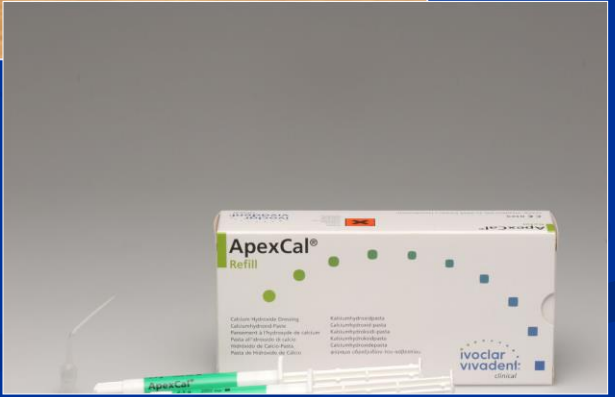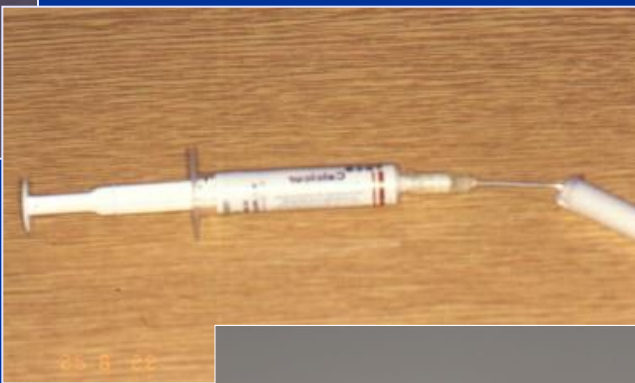Diagnosis

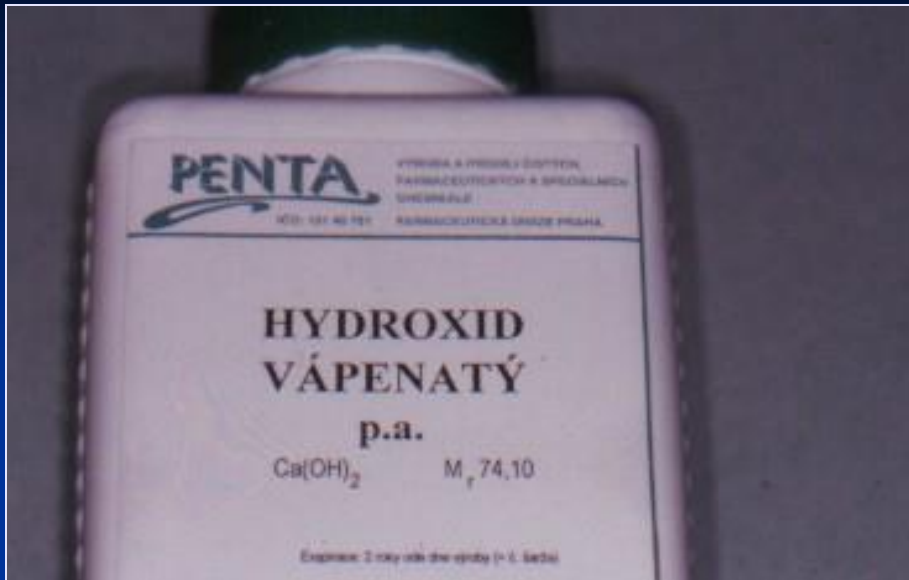
Clinical examination

Pulp sensitivity tests, radiographic examination, transillumination.



pH 12,5





Antiflogistický

Dentinogenní

Antimikrobiální efekt

Suspenze

Cementy

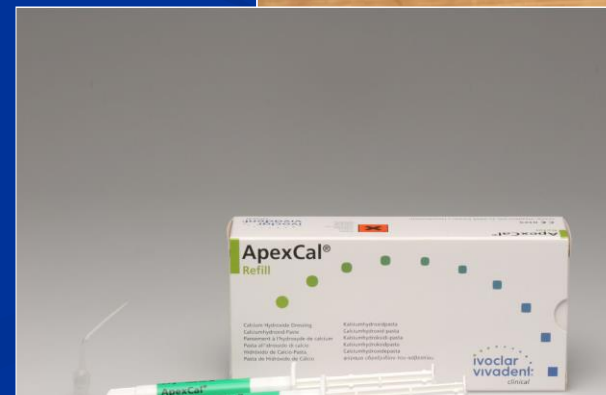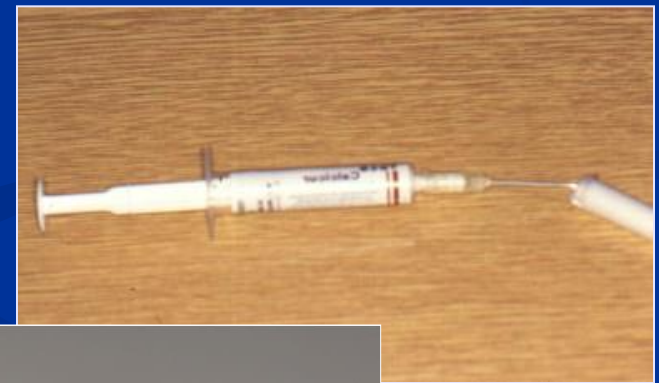Subbase

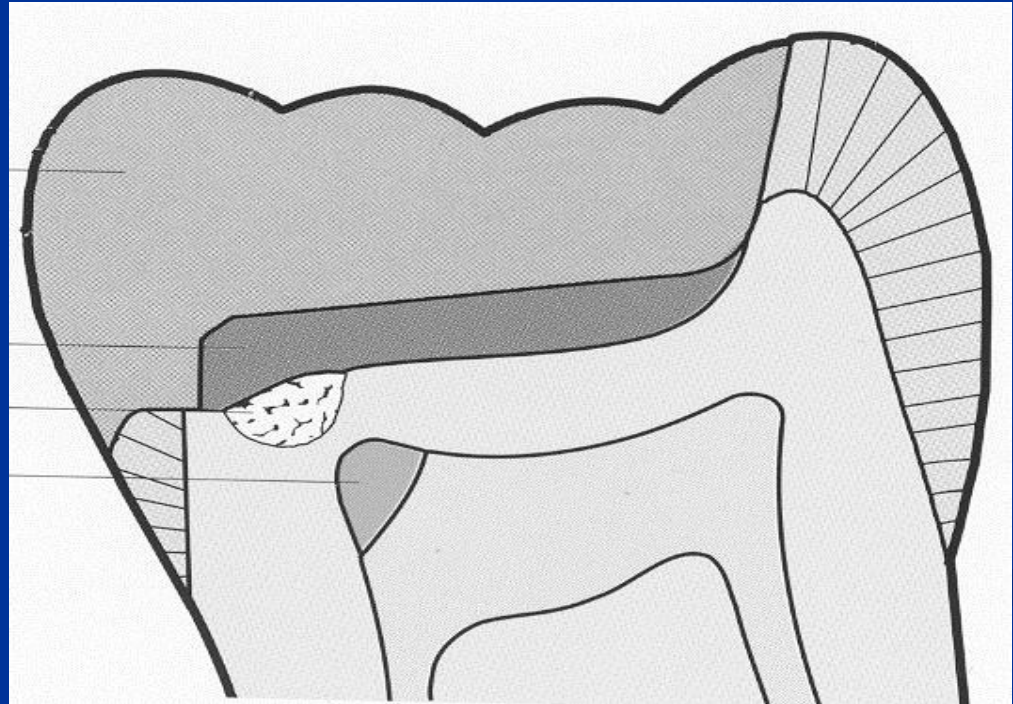
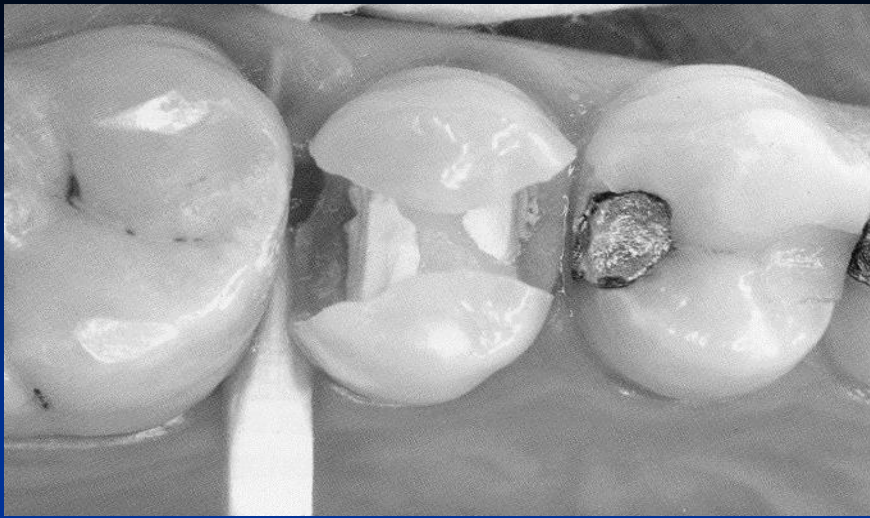
Kořenová výplň

- krátkodobě

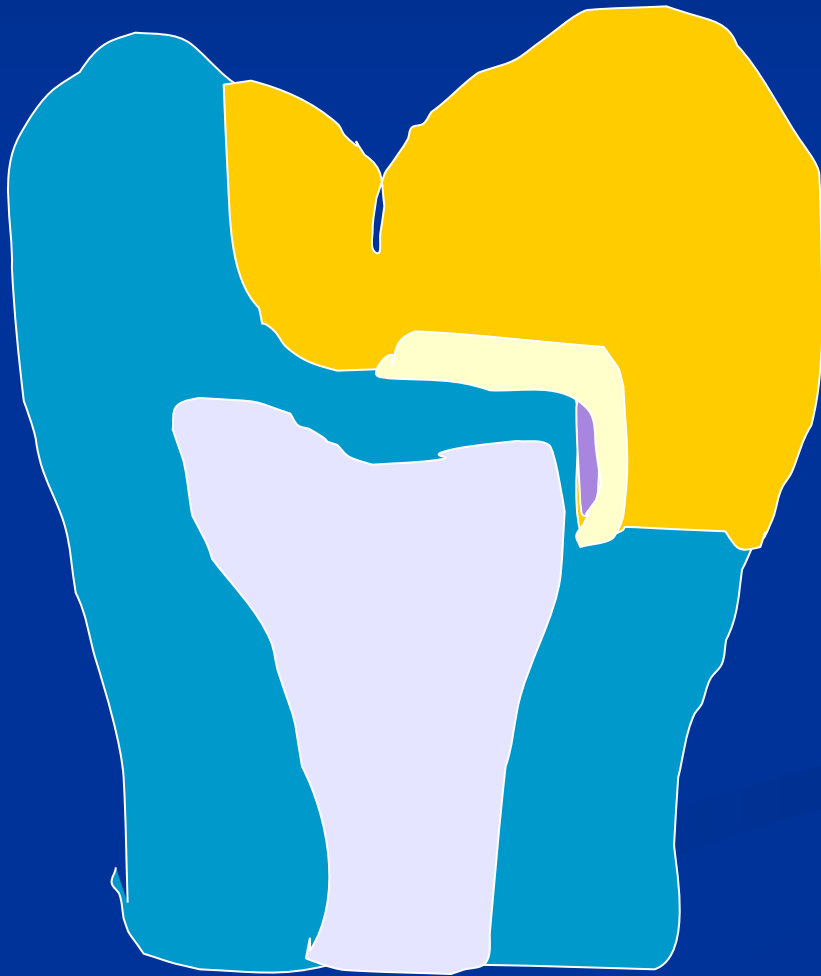- střednědobě

- dlouhodobě





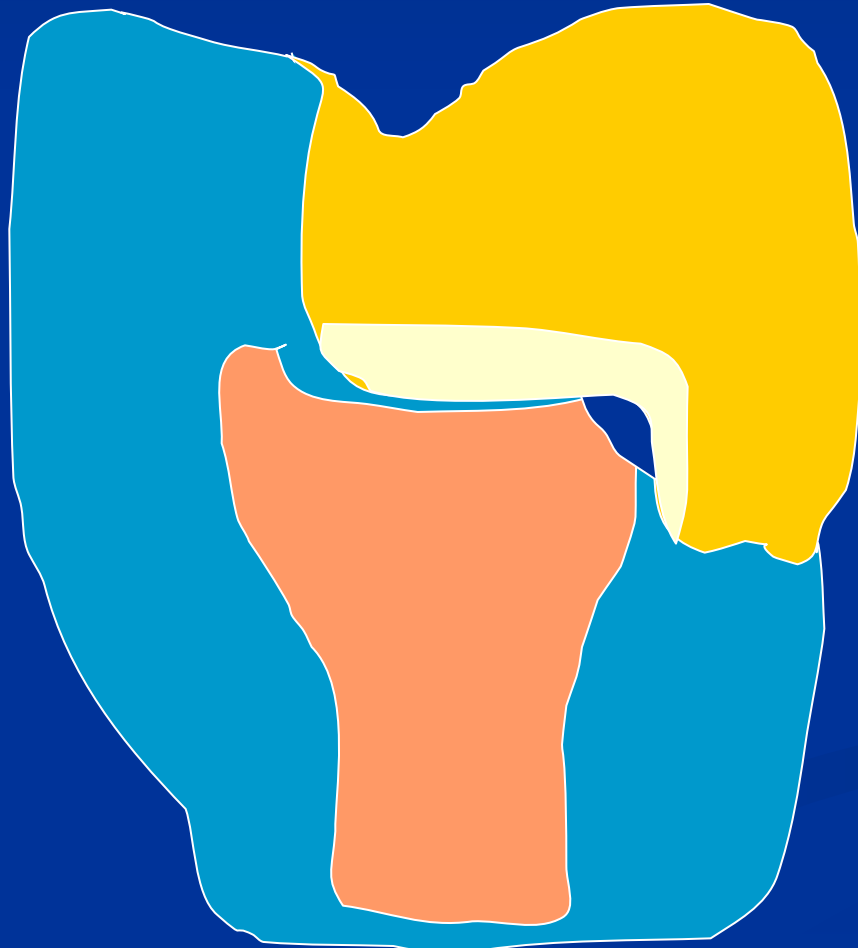
Indirect pulp capping



Intermittent excavation



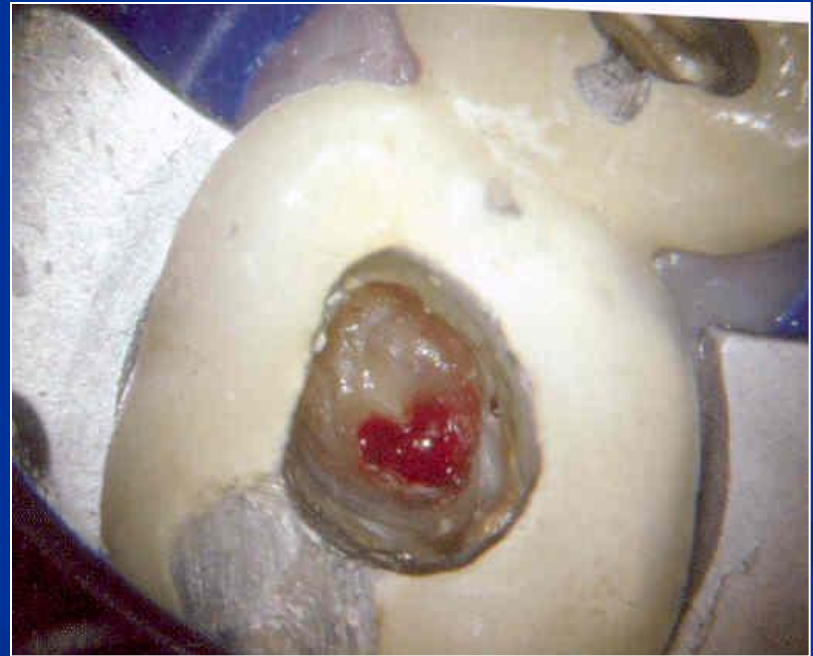Direct pulp capping



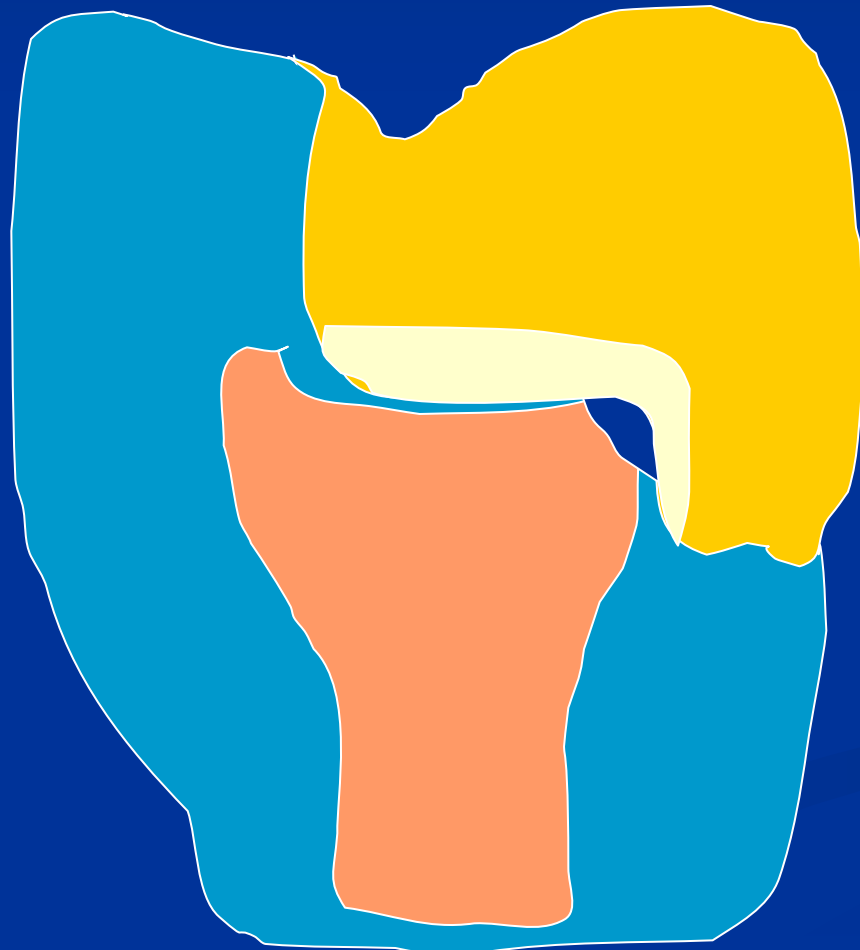
Directly on
dental pulp

Dentin bridge

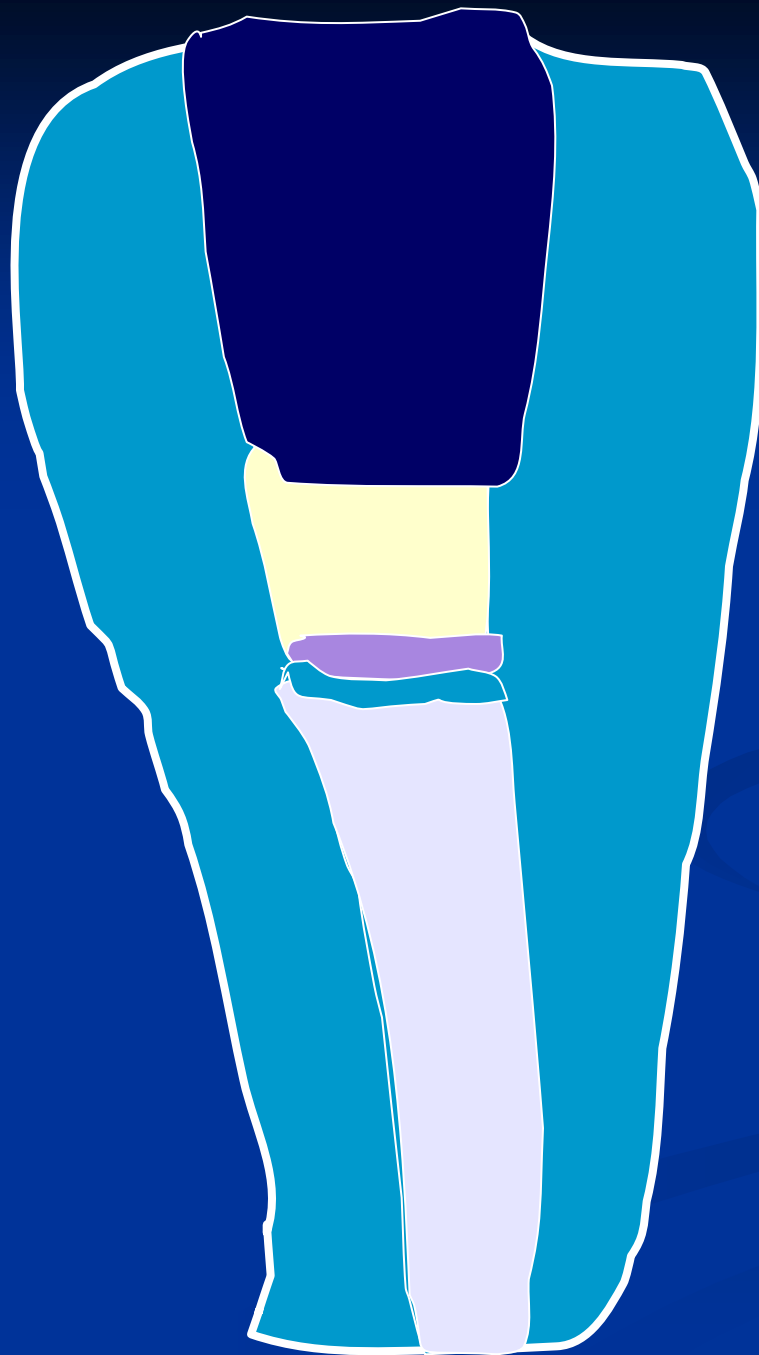
- Rests of calcium hydroxide
- Connective tissue
- Calcified connective tissue
- Dentin
- Predentin
- Odontoblasts



Přímé překrytí zubní dřeně



Přímé překrytí –
bodová
pforace ve
zdravém
dentinu,
okamžitě po
vzniku. Zvážit
rizika!



Vitální amputace