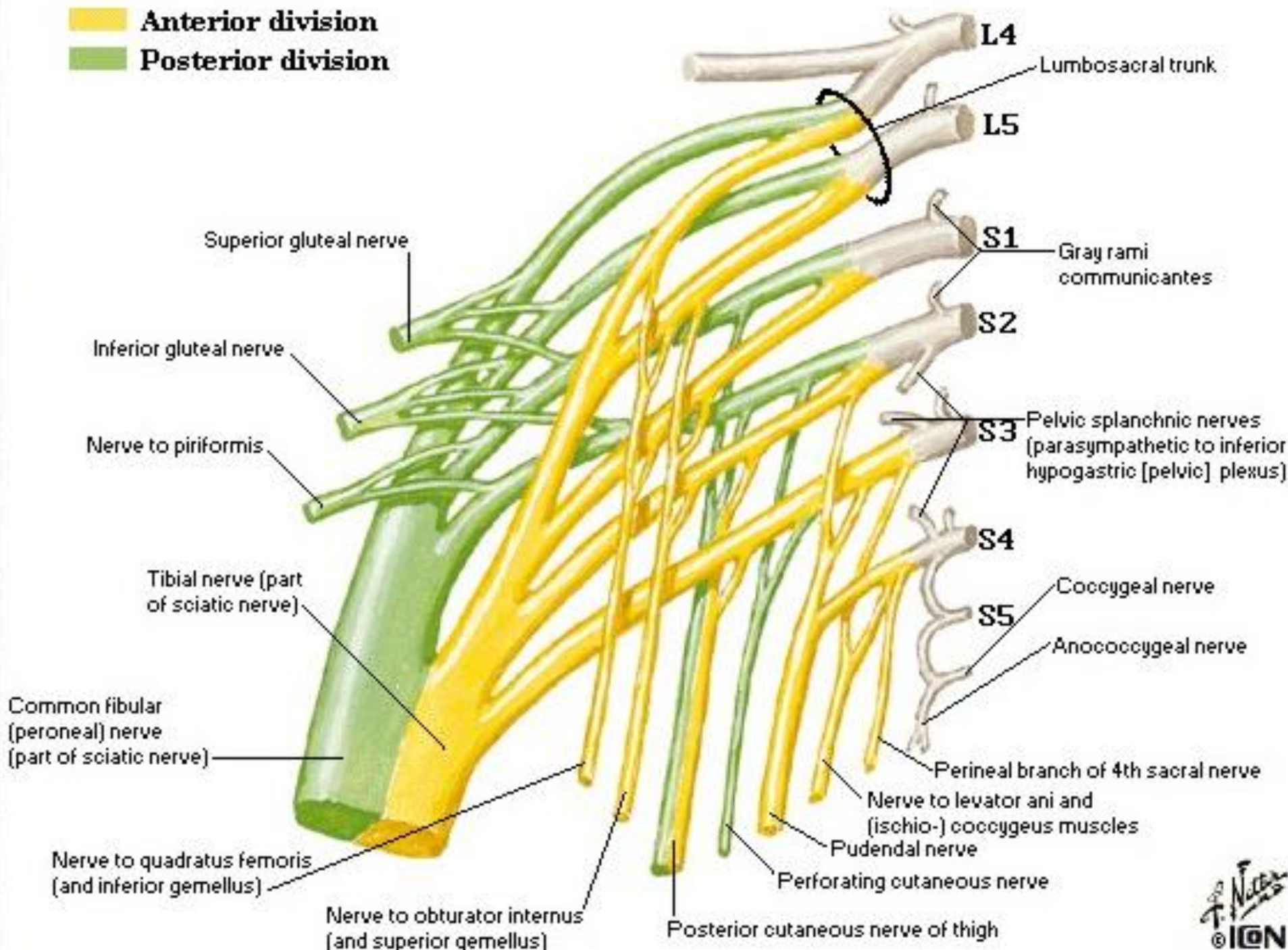
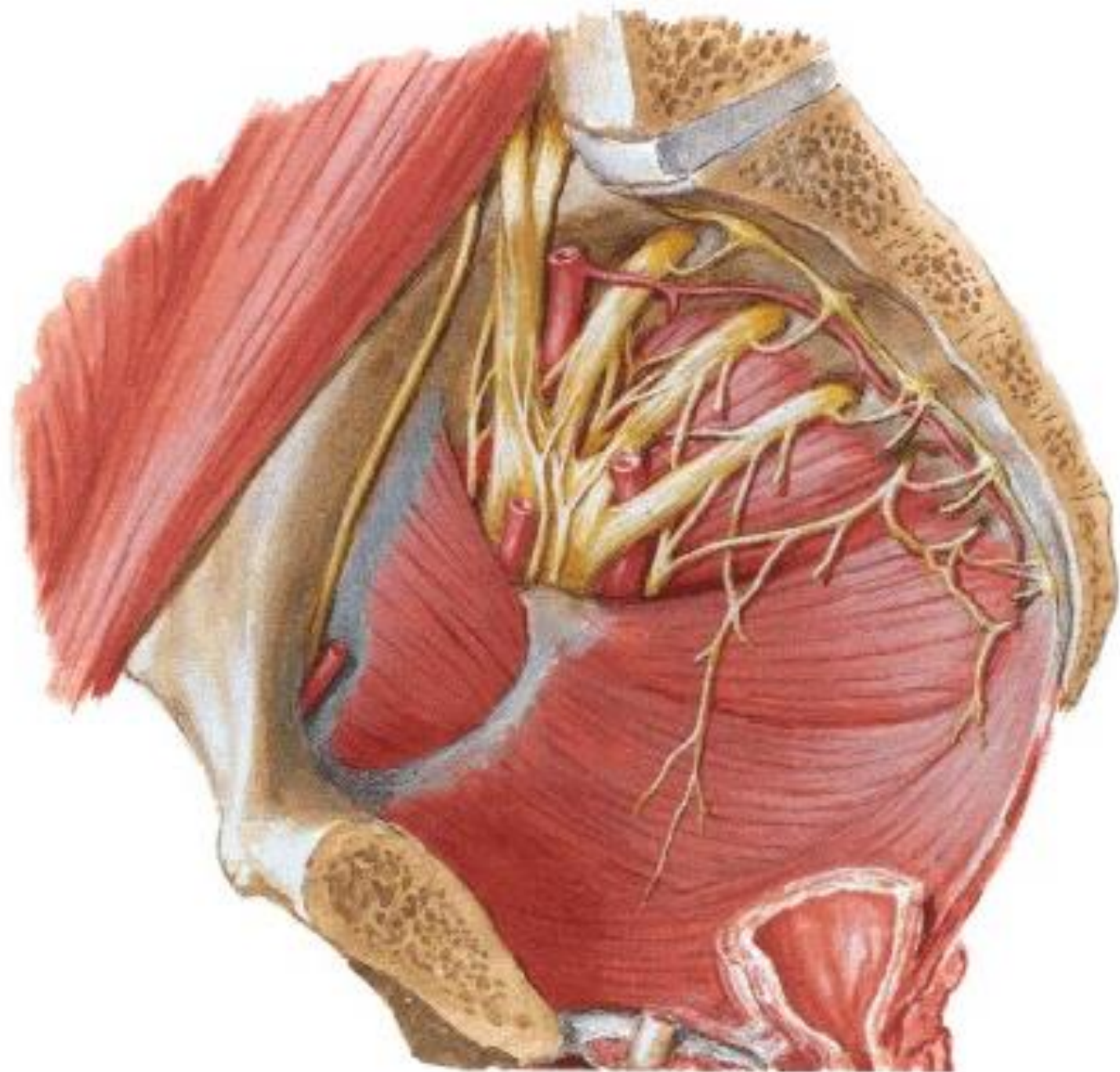


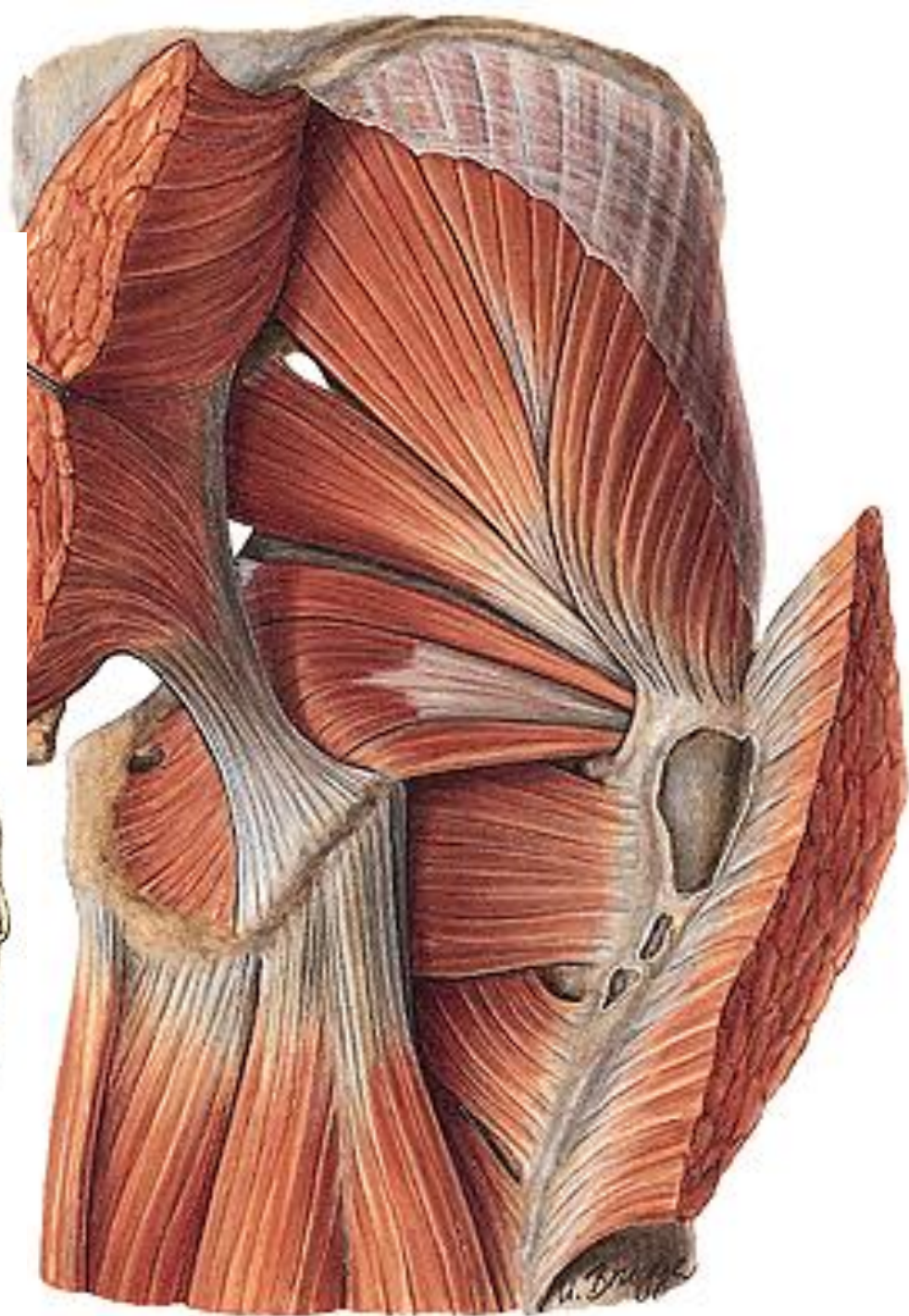
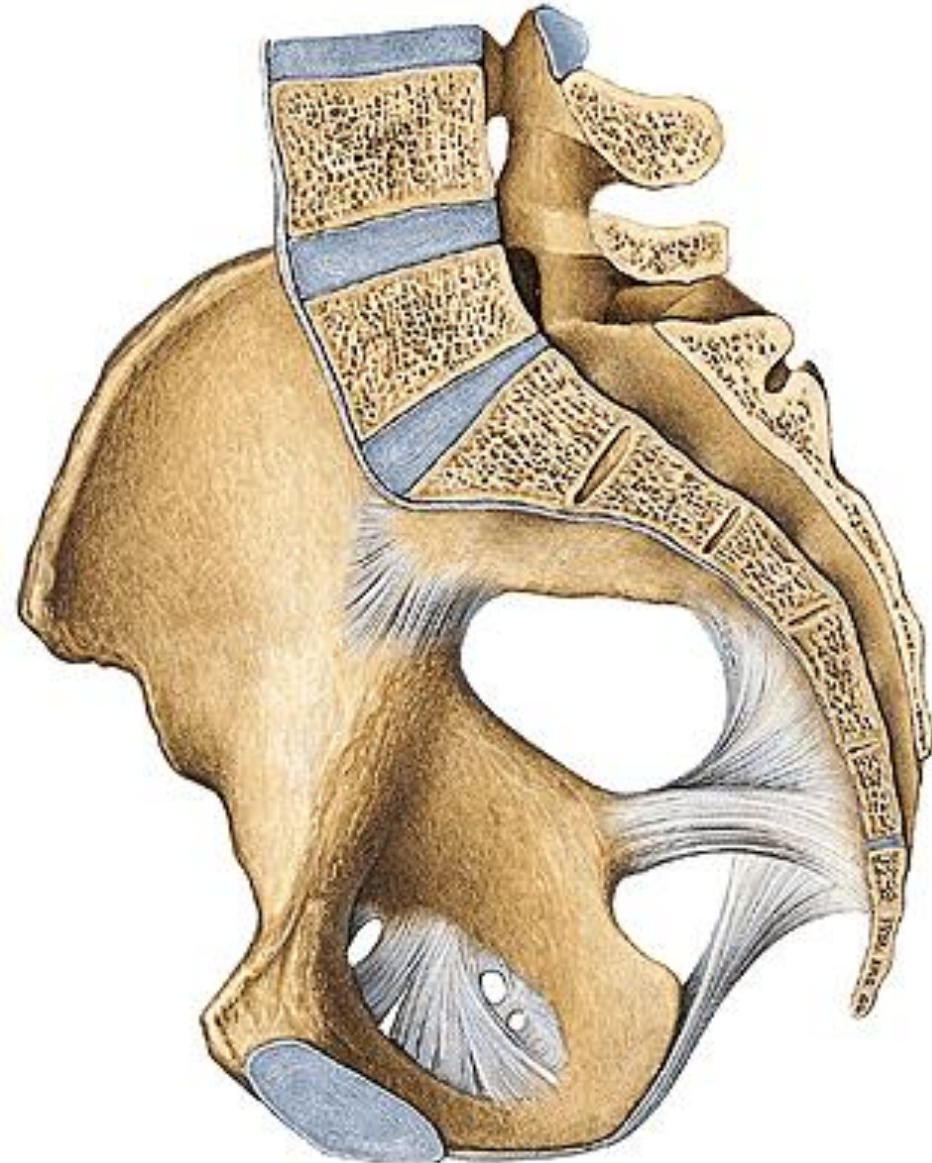
PLEXUS SACRALIS

Anterior division
 Posterior division

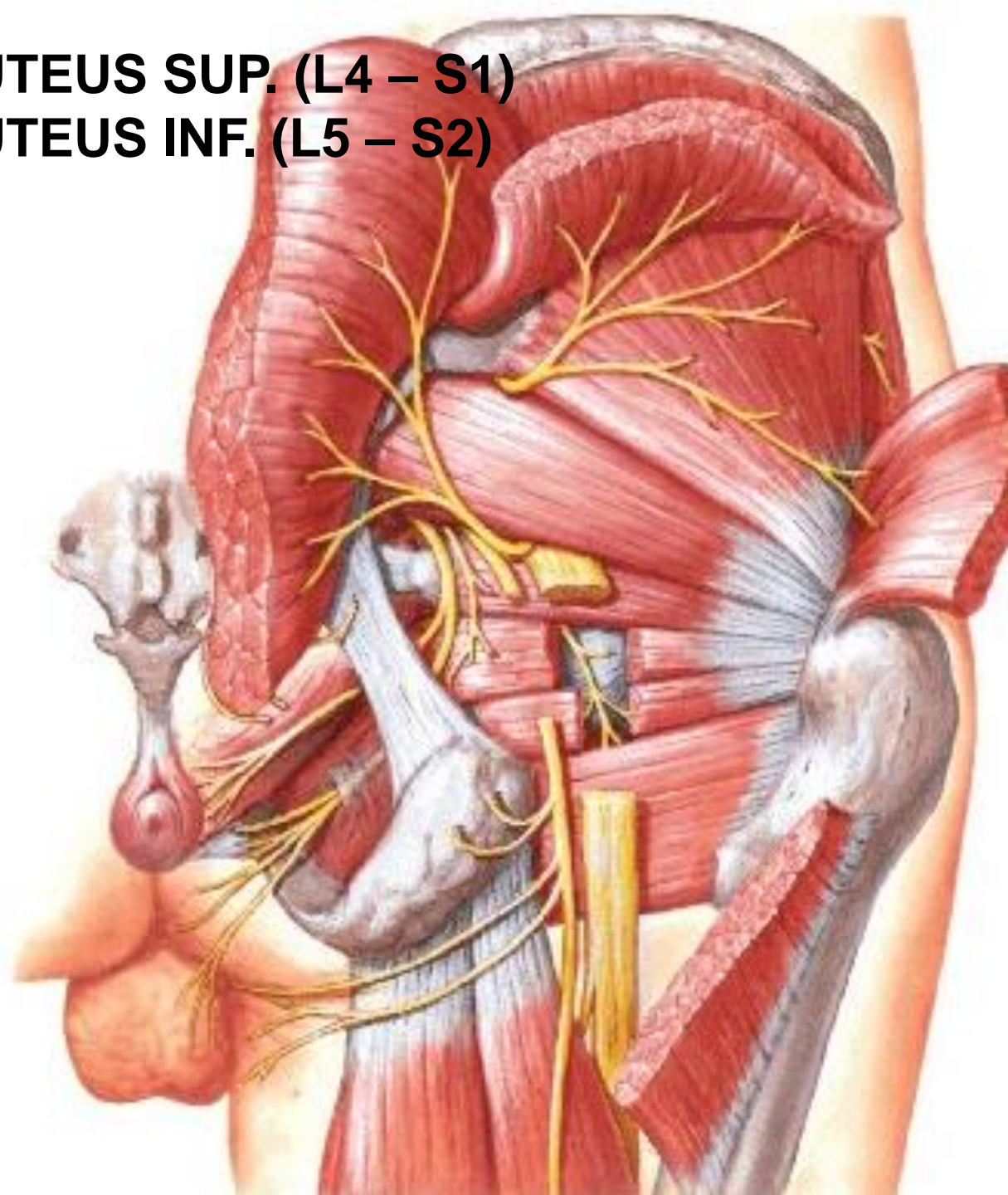
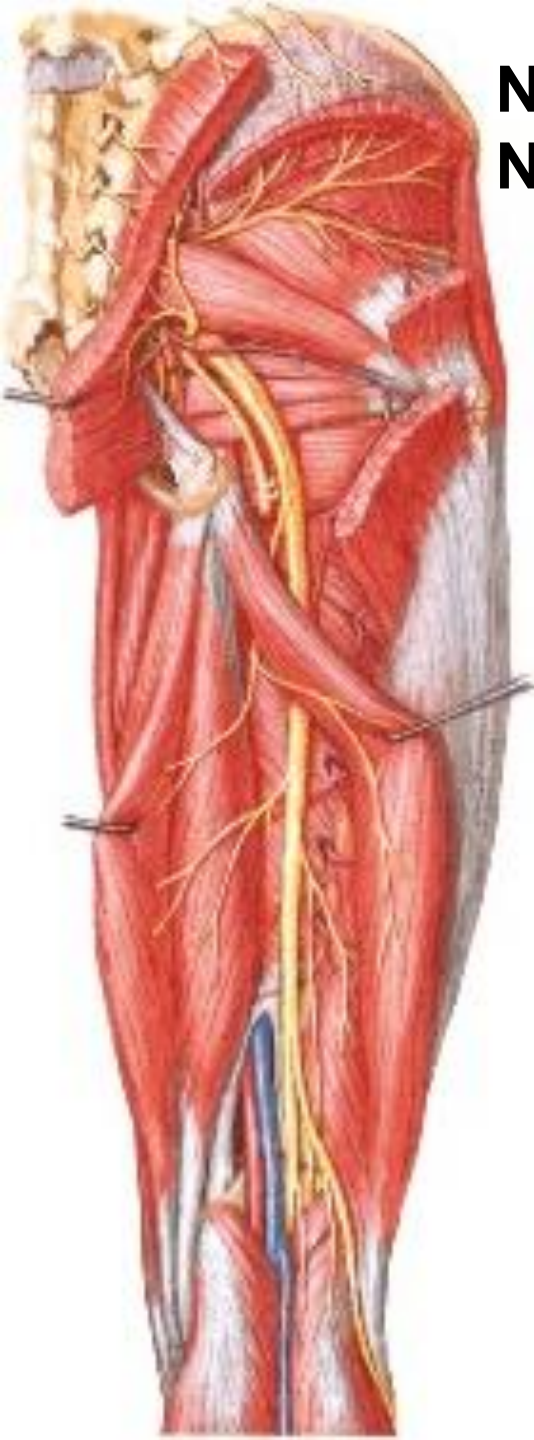


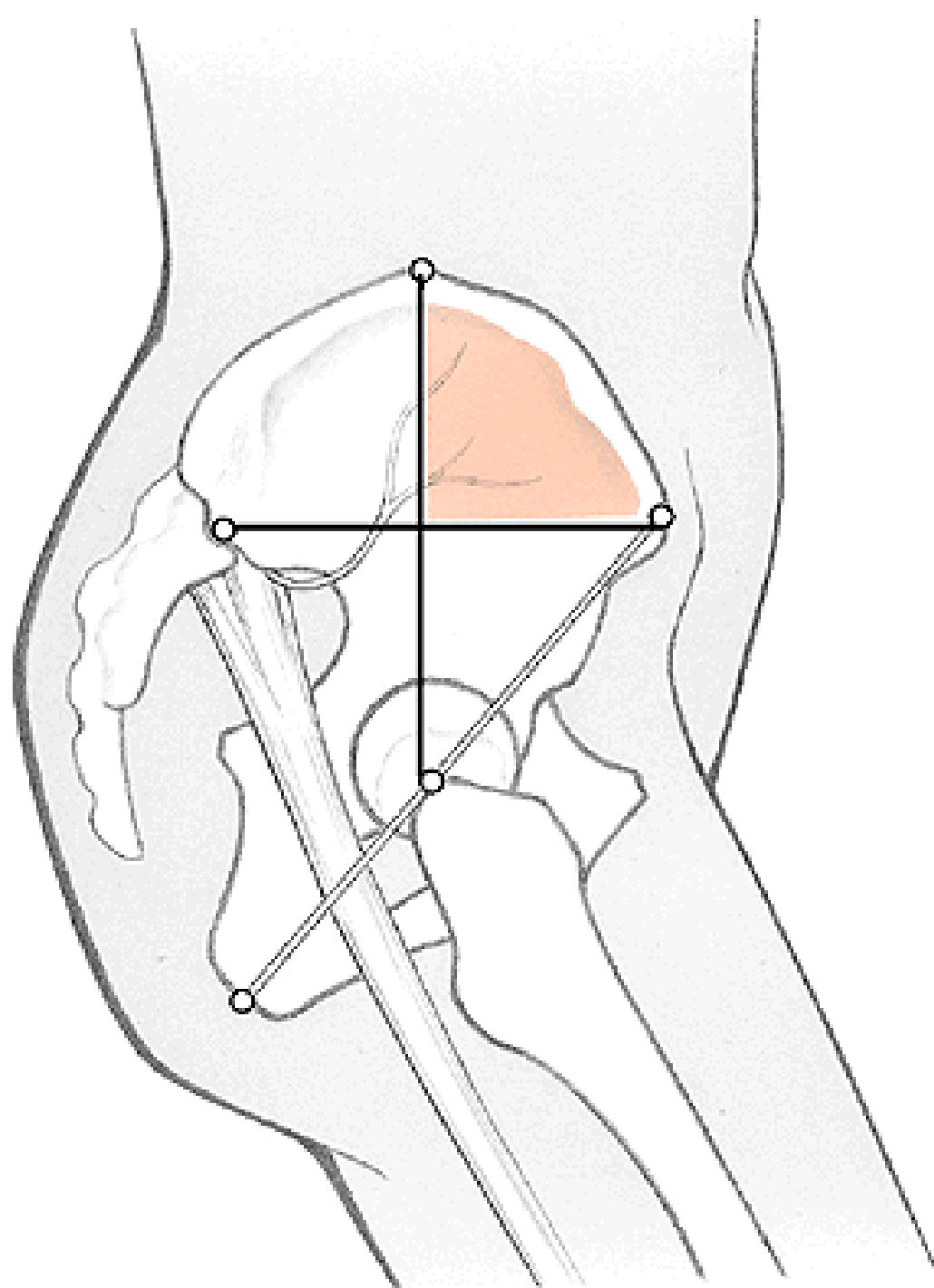


Foramen suprapiriforme
Foramen infrapiriforme

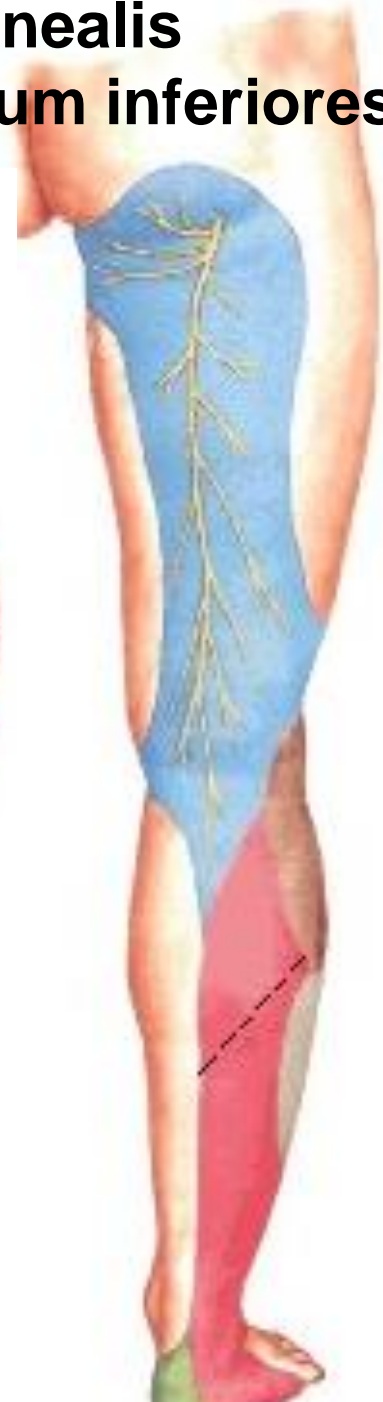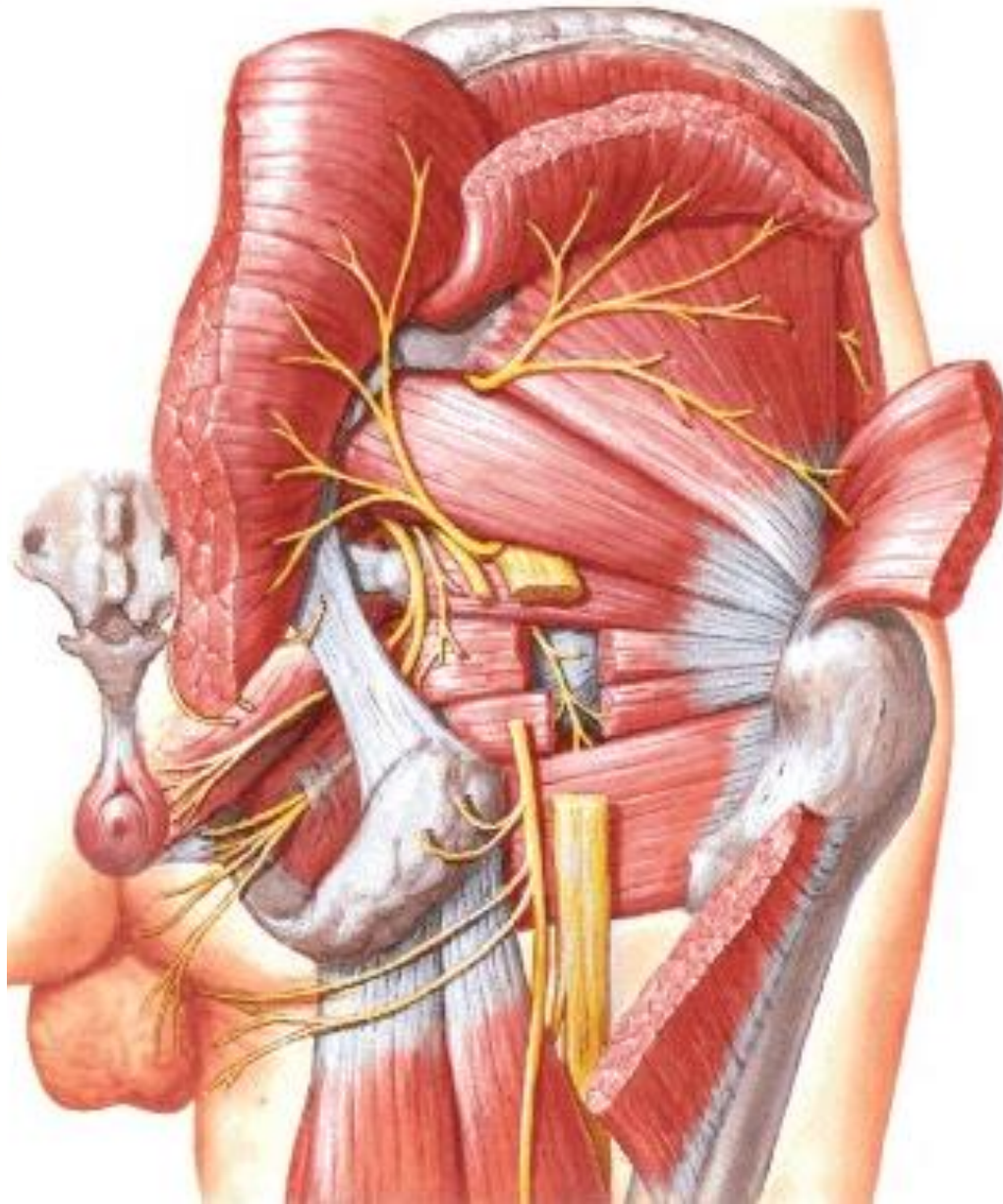

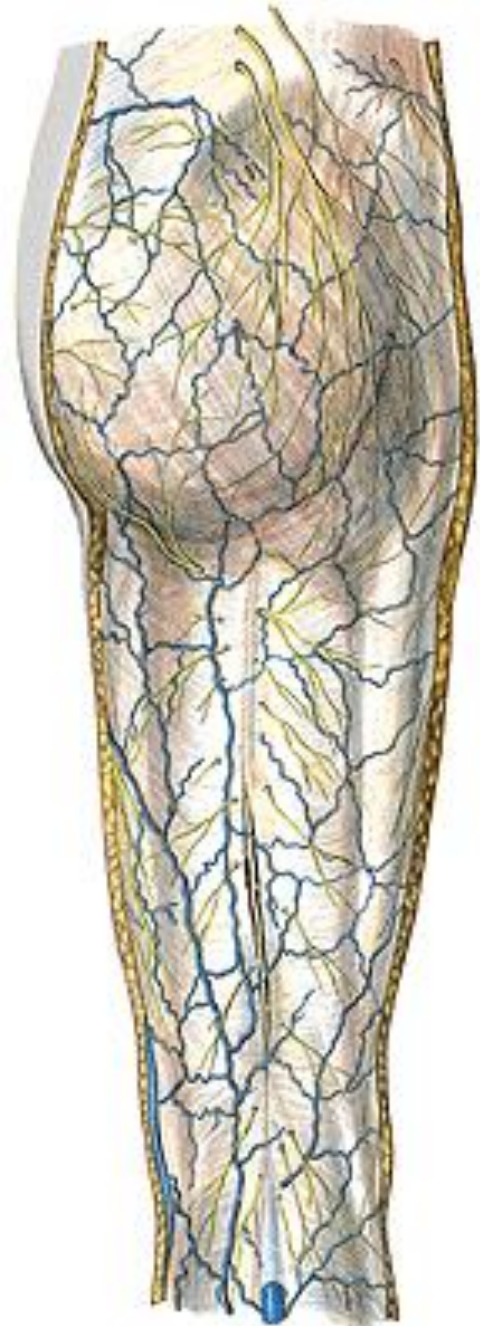
N. GLUTEUS SUP. (L4 – S1)
N. GLUTEUS INF. (L5 – S2)



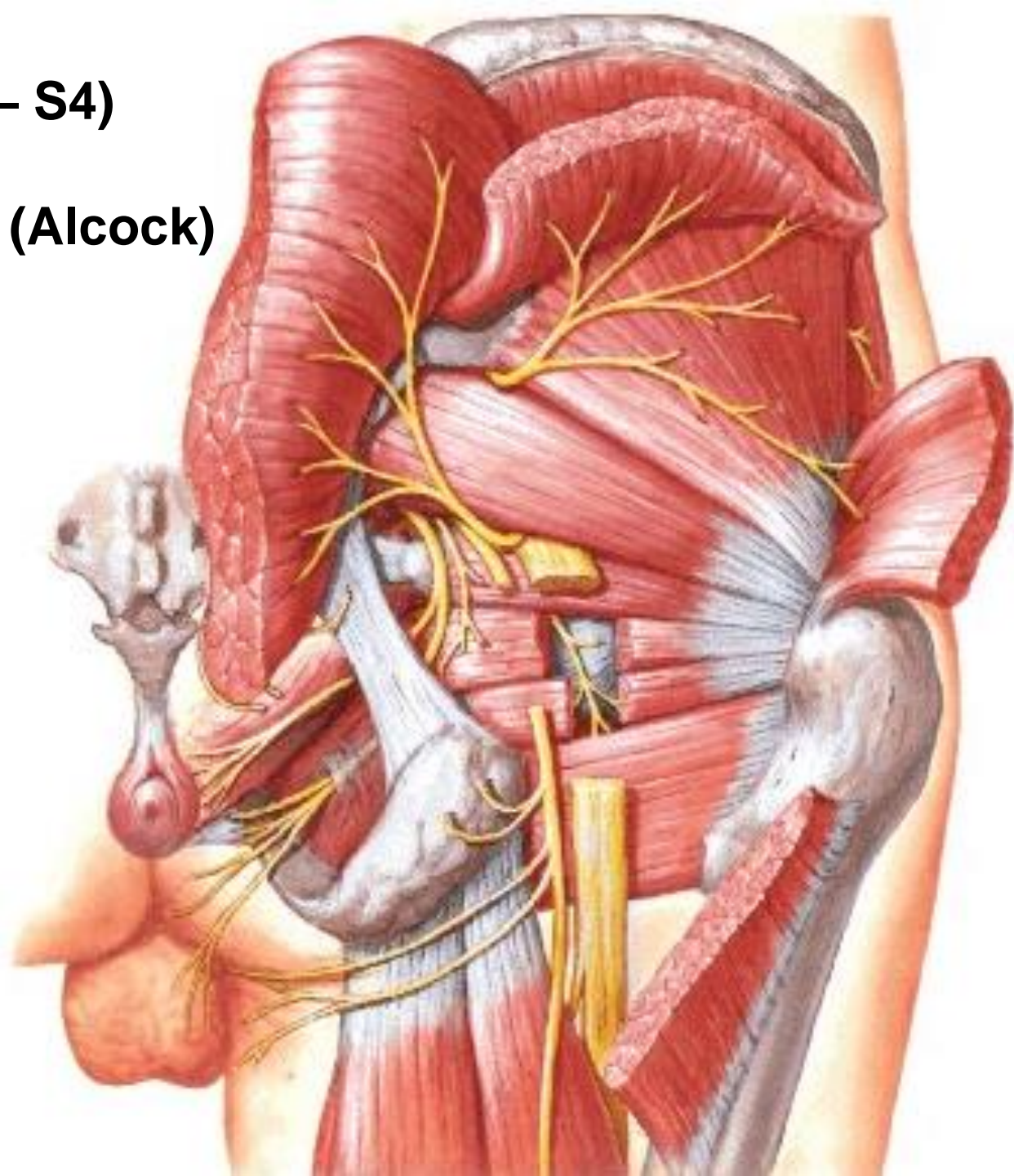


N. CUTANEUS FEMORIS POST. (S1 – S3) – r. perinealis
- nn. clunium inferiores



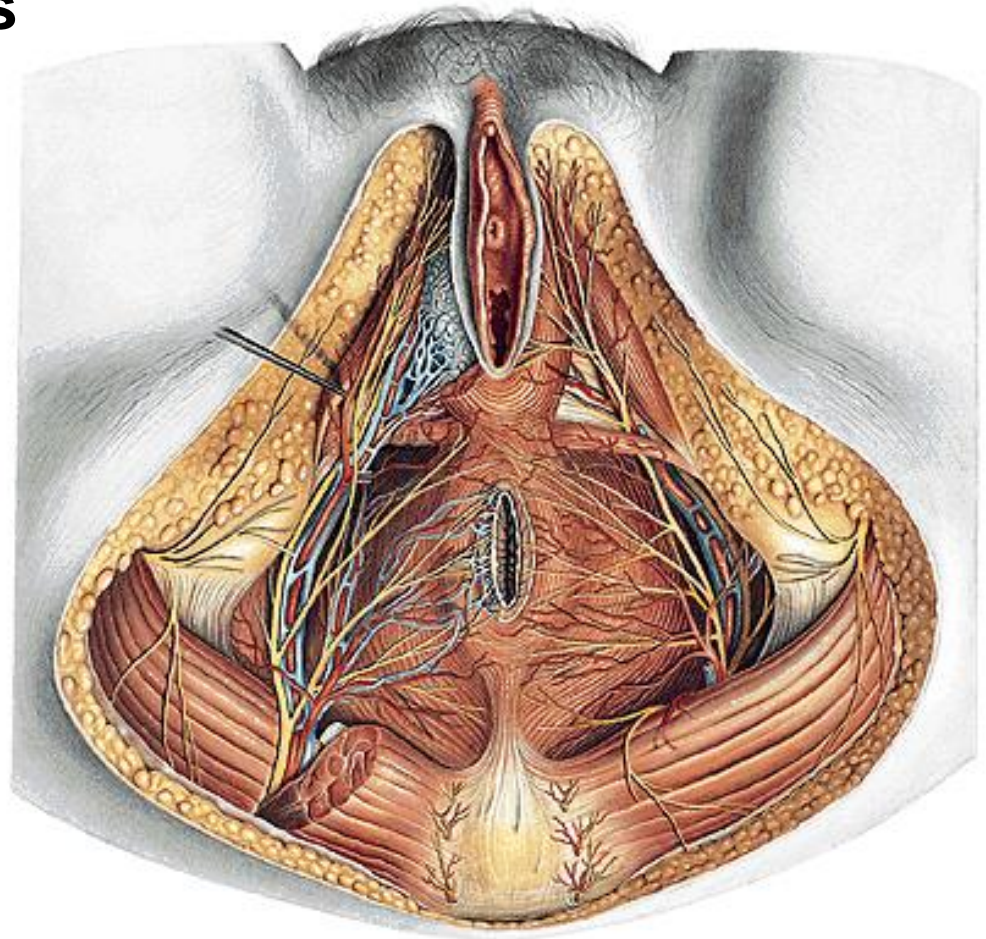
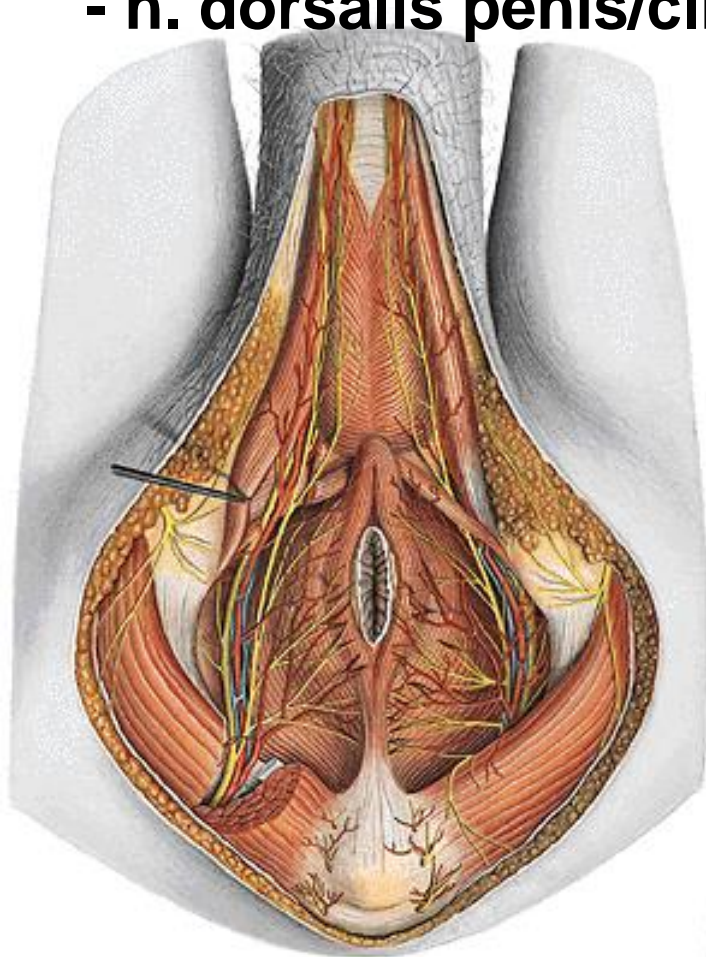
N. PUDENDUS (S2 – S4)

Canalis pudendalis (Alcock)

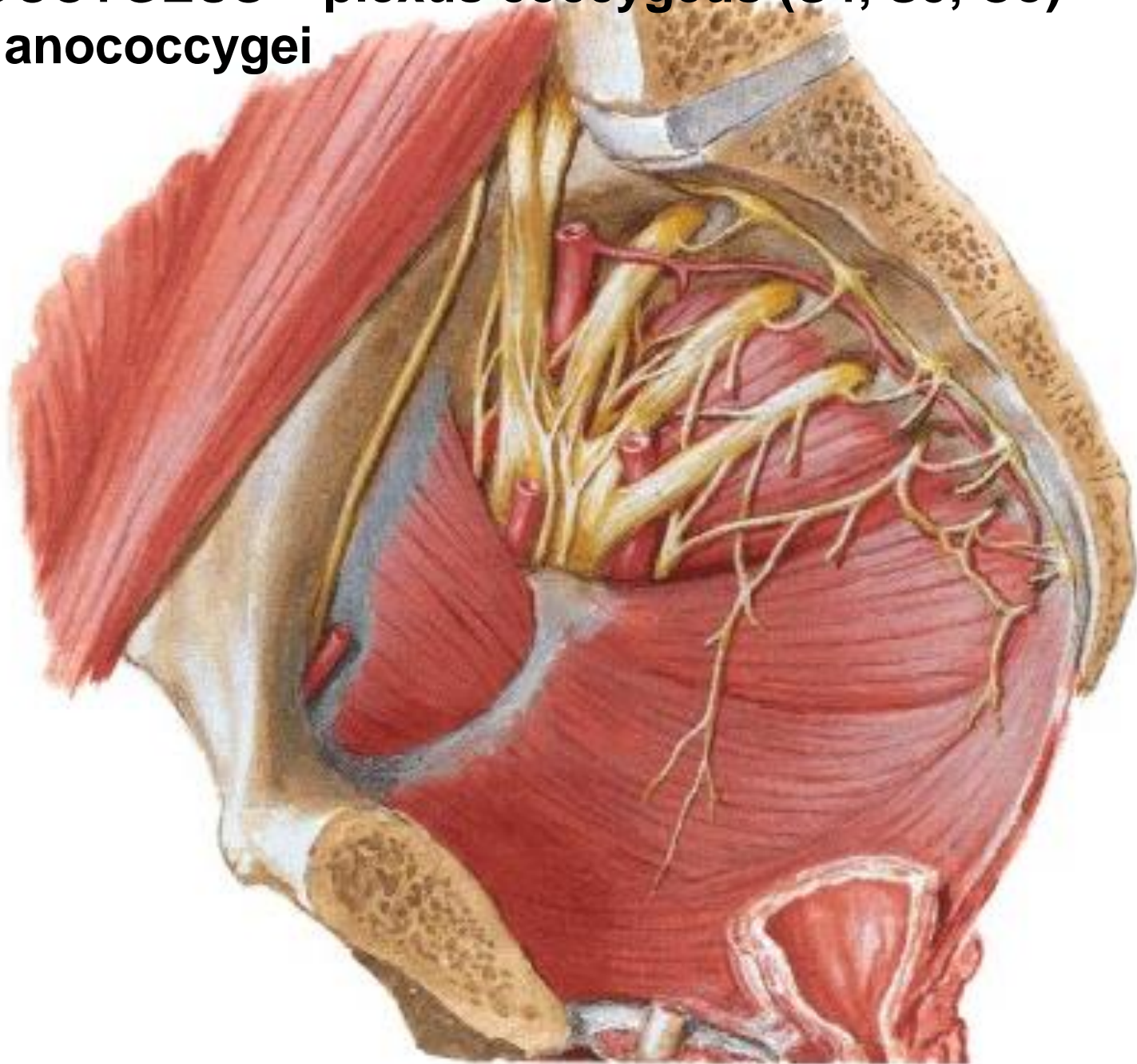


N. PUDENDUS

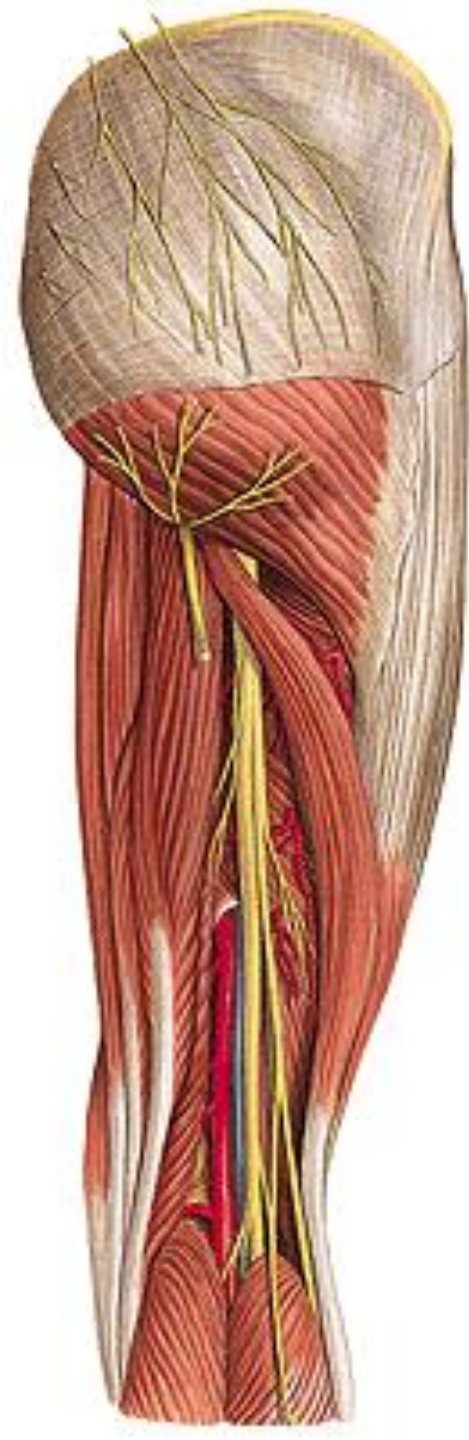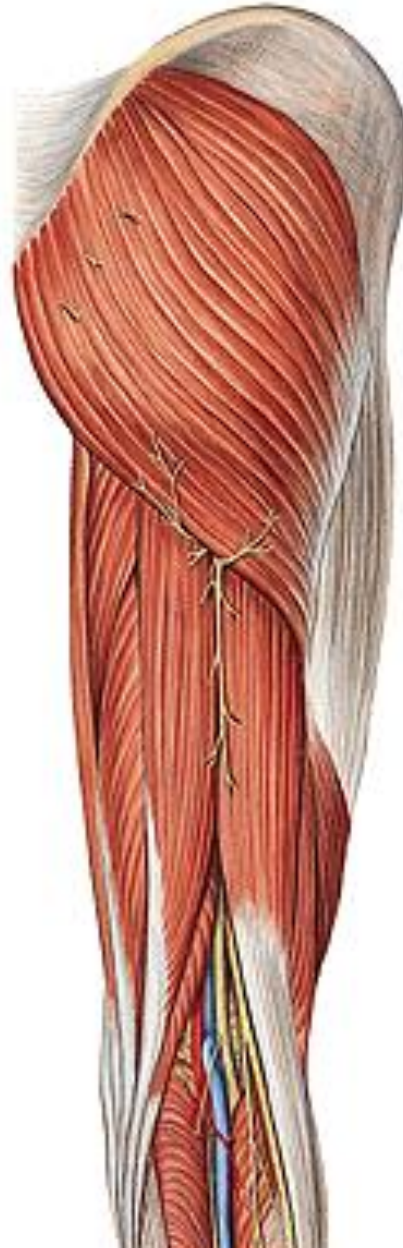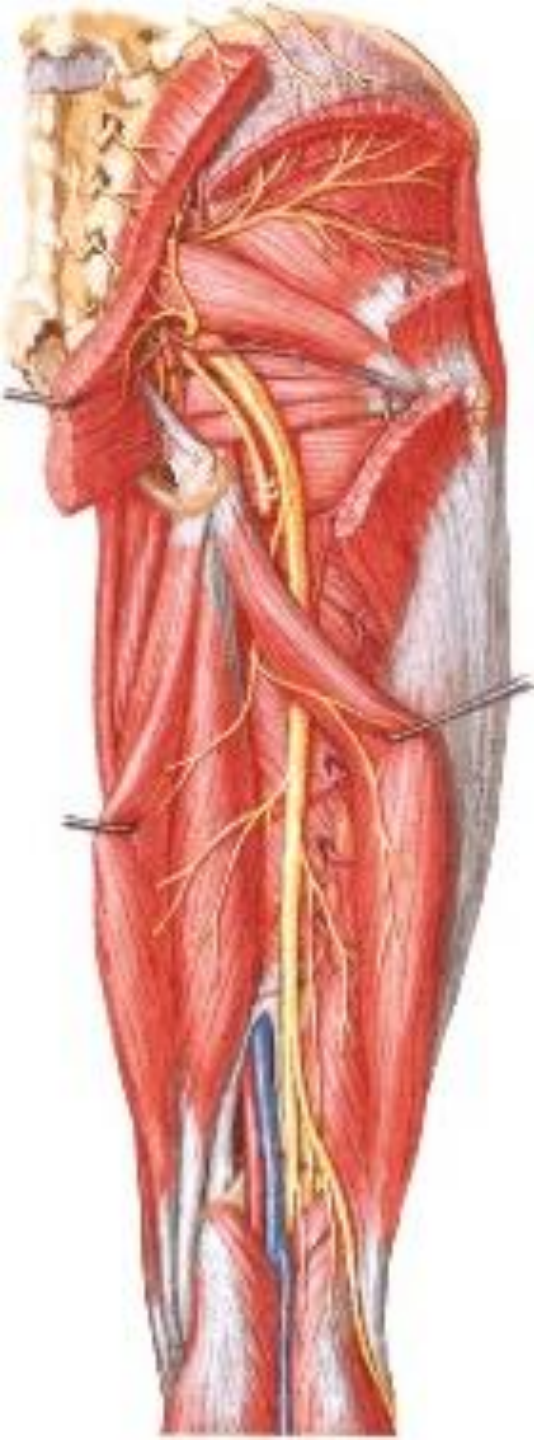
- nn. rectales inf.
- n. perinealis
 - n. perinealis spf. – rr. scrotales/labiales posteriores
 - n. perinealis prof.
- n. dorsalis penis/clitoridis

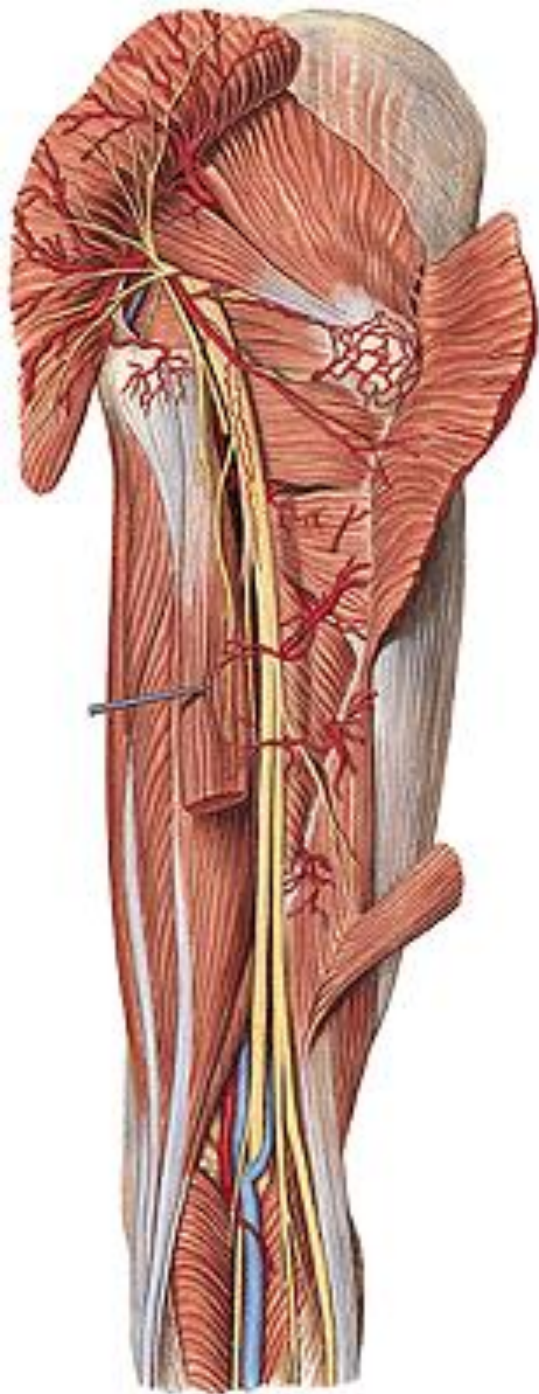


N. COCCYGEUS – plexus coccygeus (S4, S5, Co)
– nn. anococcygei



N. ISCHIADICUS (L4 – S3)





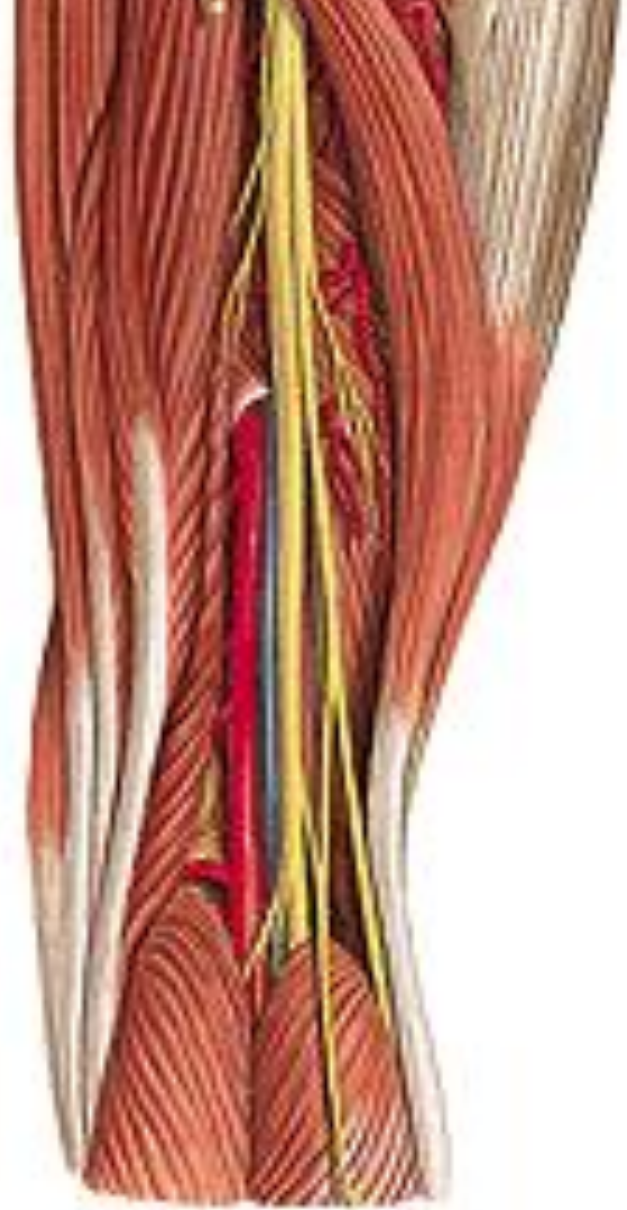
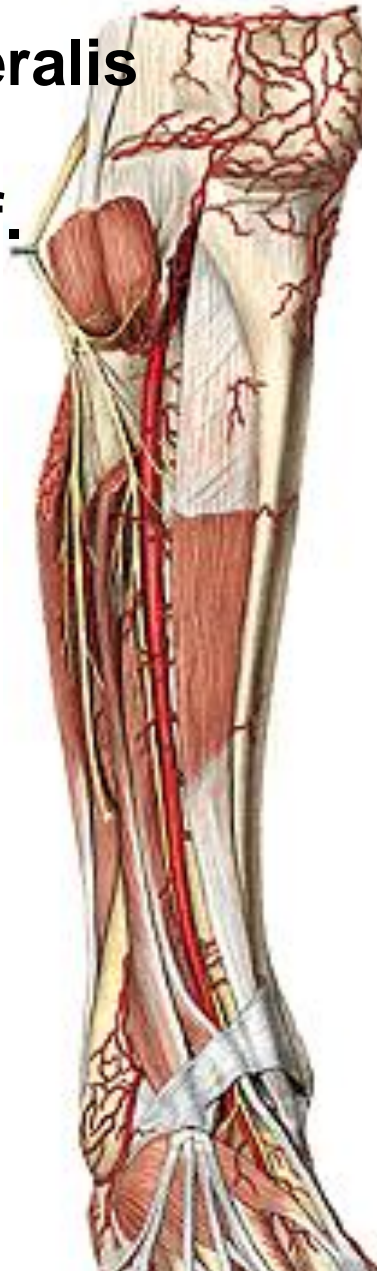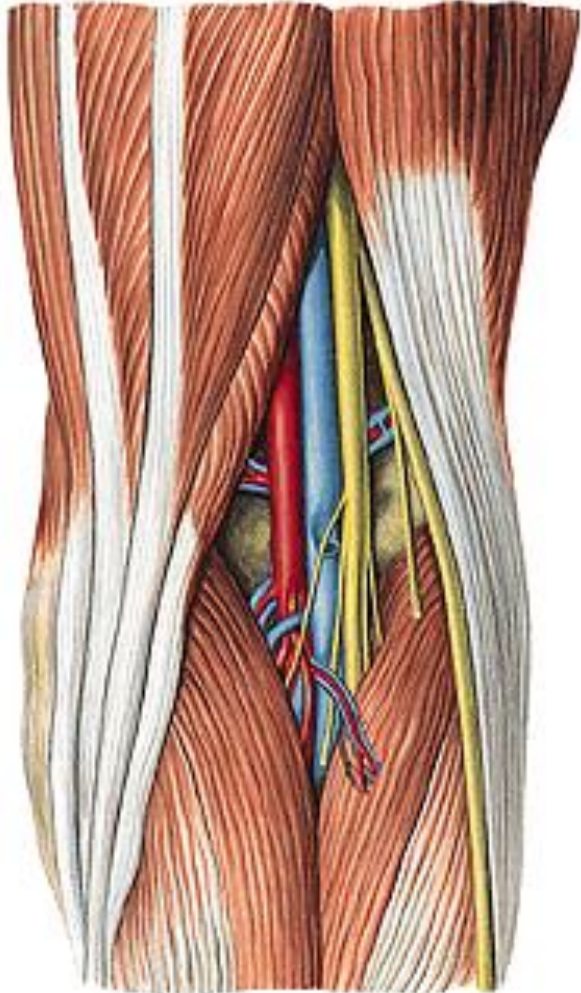
A. comitans n. ischiadici

N. ISCHIADICUS

- rr. musculares
- rr. articulares
- n. tibialis
- n. fibularis/peroneus communis

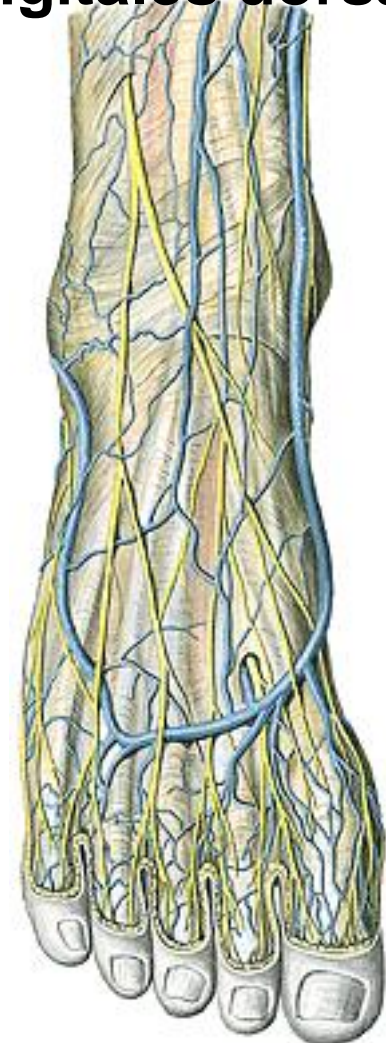
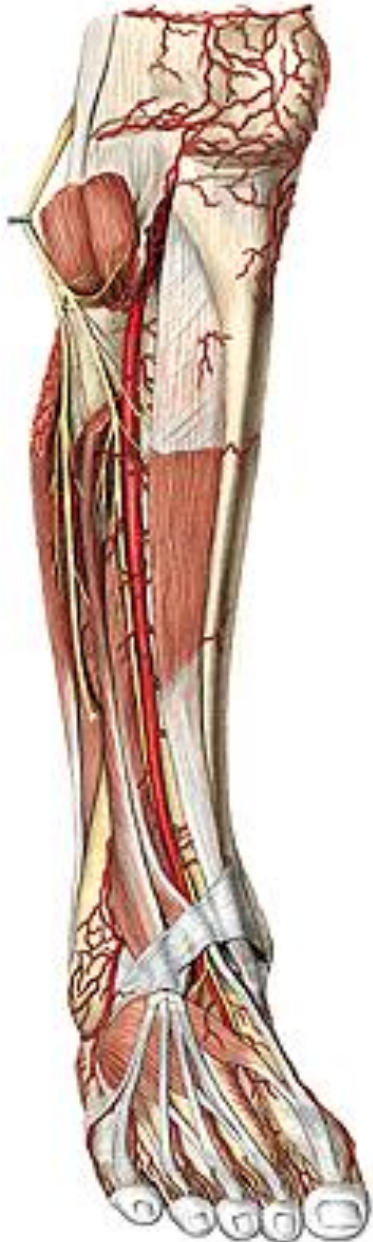N. FIBULARIS/PERONEUS COMMUNIS

- rr. articulares
- n. cutaneus surae lateralis
- r. comunicans
- n. fibularis spf. et prof.



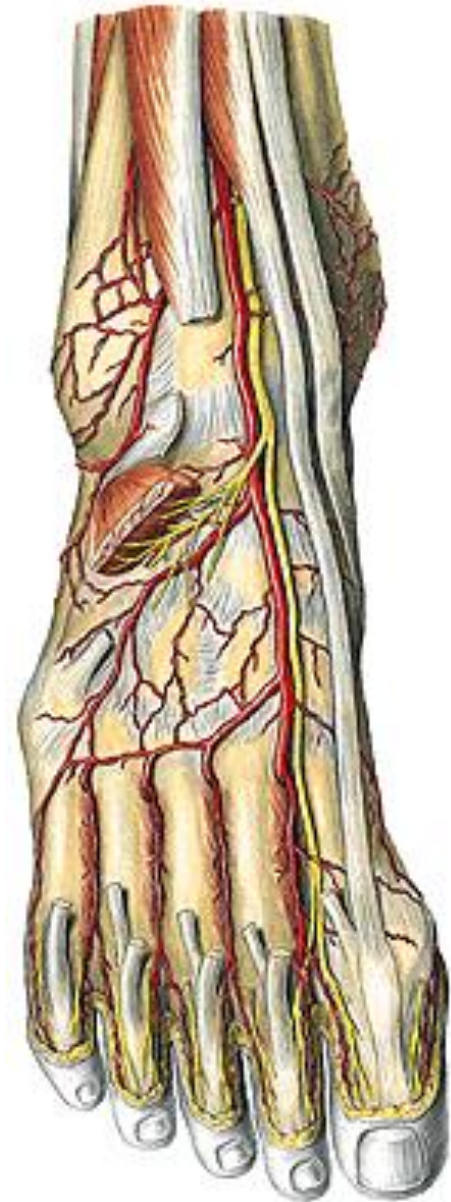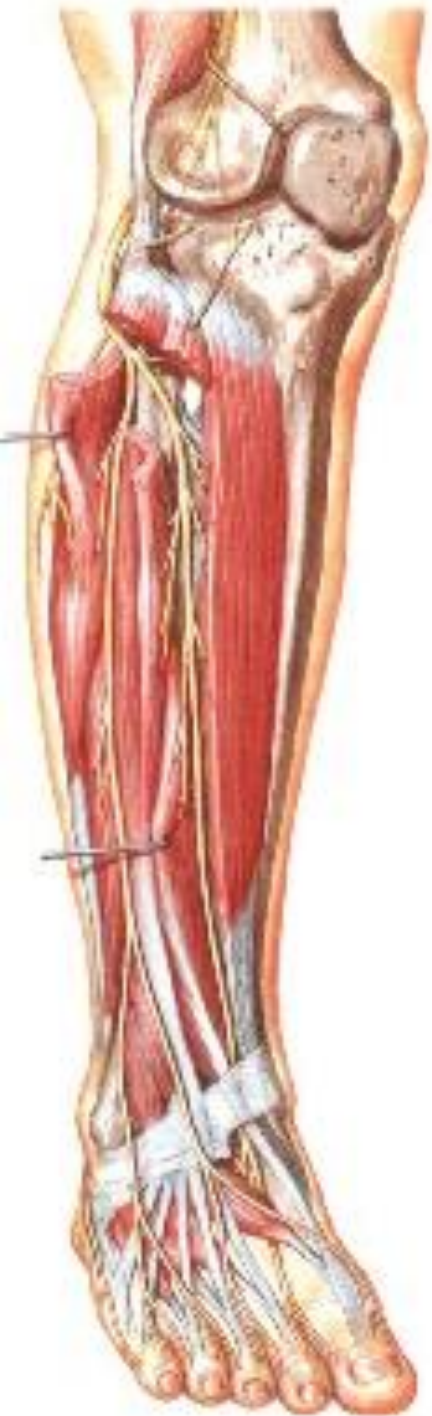N. FIBULARIS SPF.

- rr. musculares
- n. cutaneus dorsalis med.
- n. cutaneus dors. intermedius
- nn. digitales dorsales



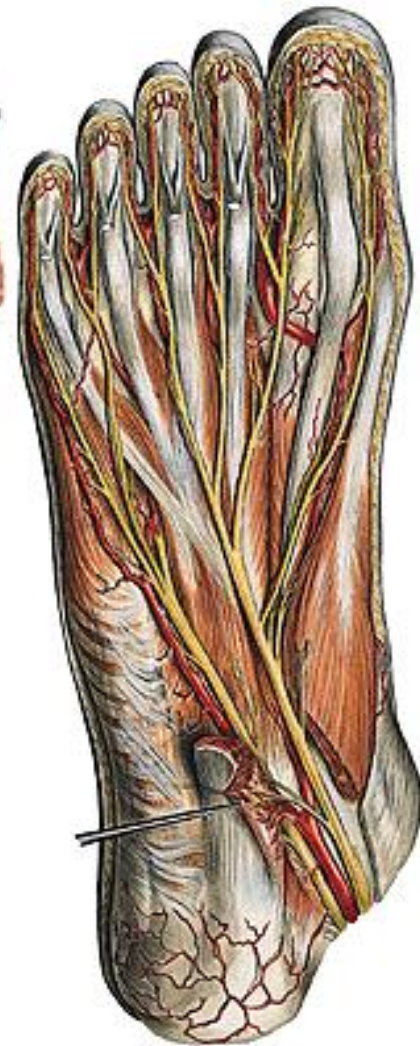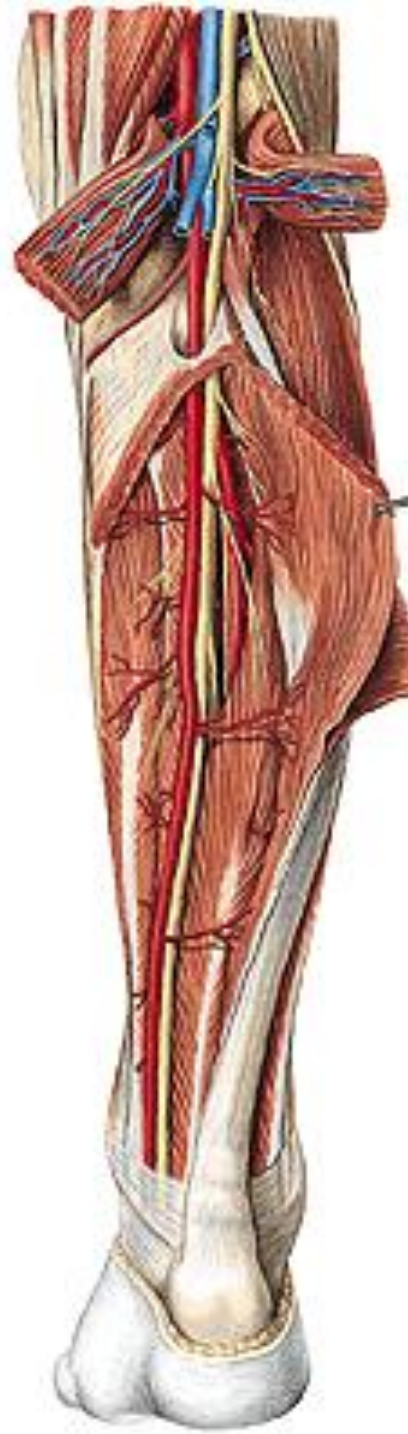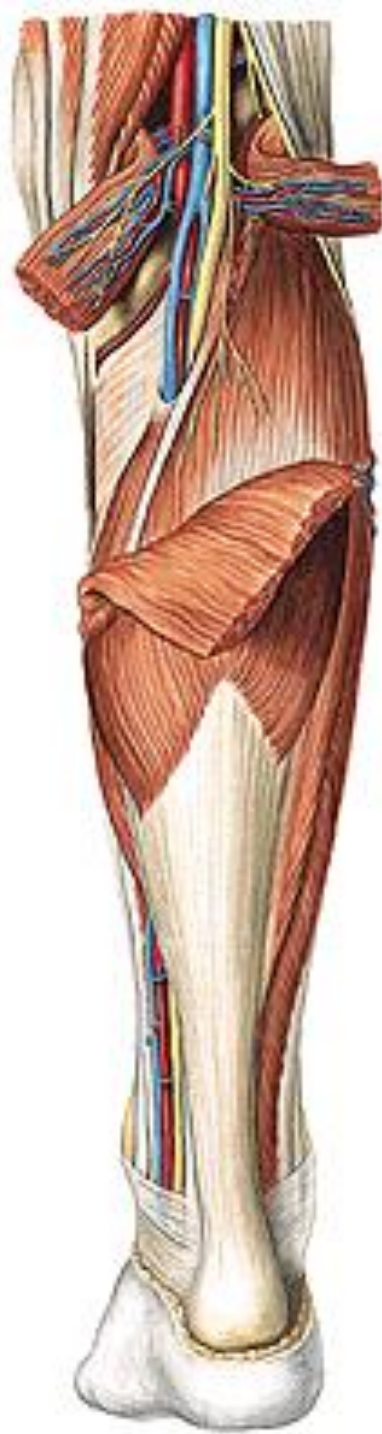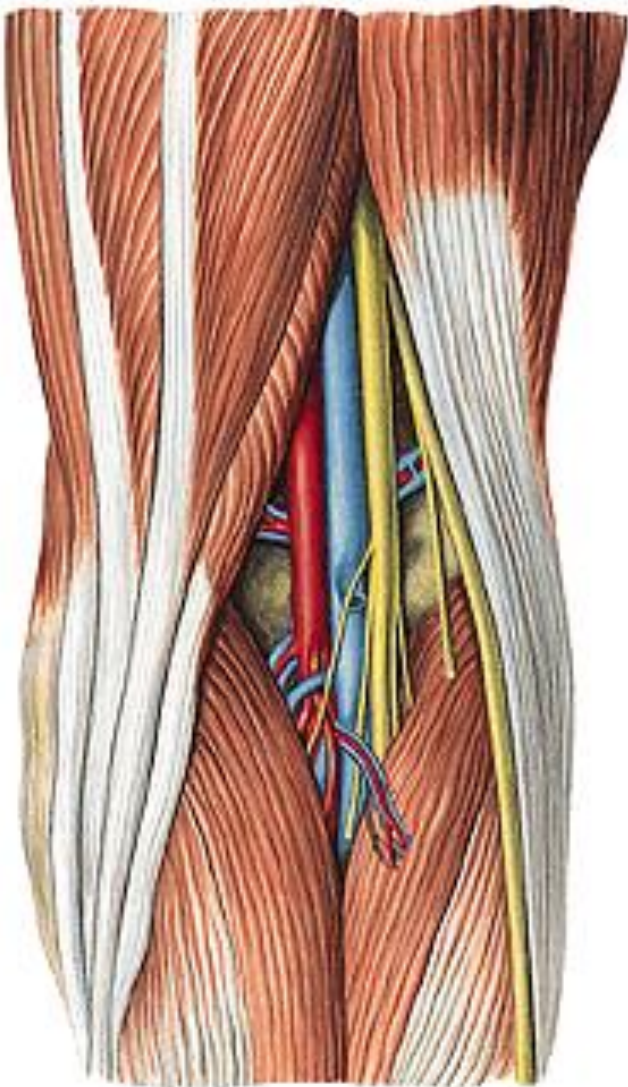
N. FIBULARIS PROF.

- rr. musculares
- nn. digitales dorsales



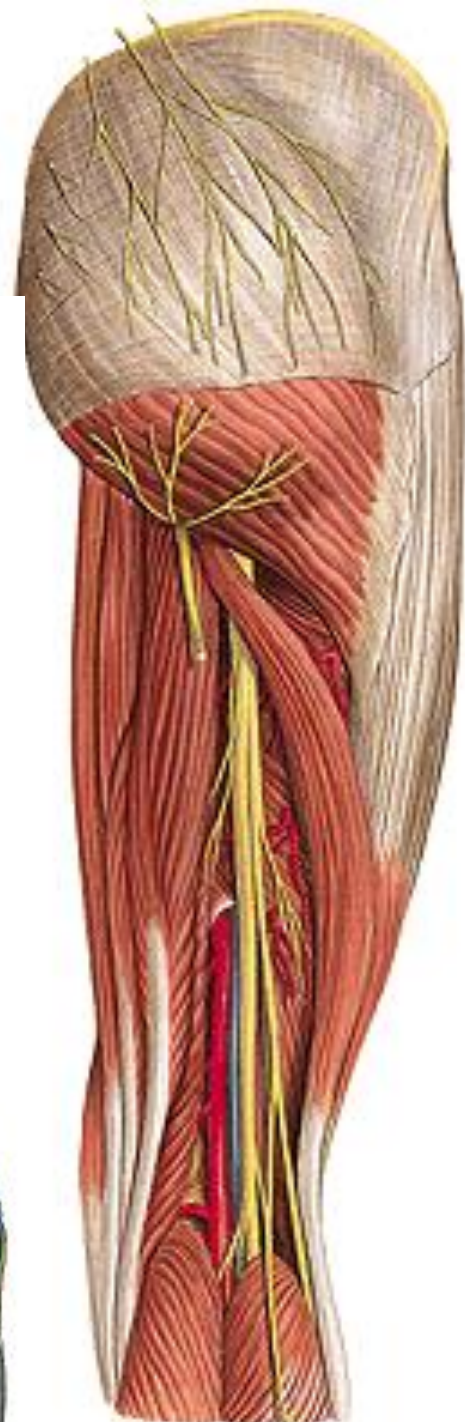
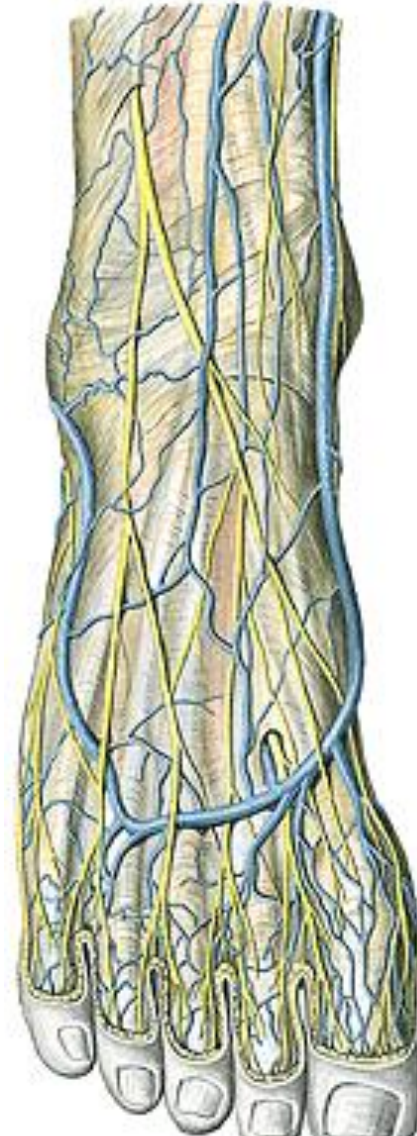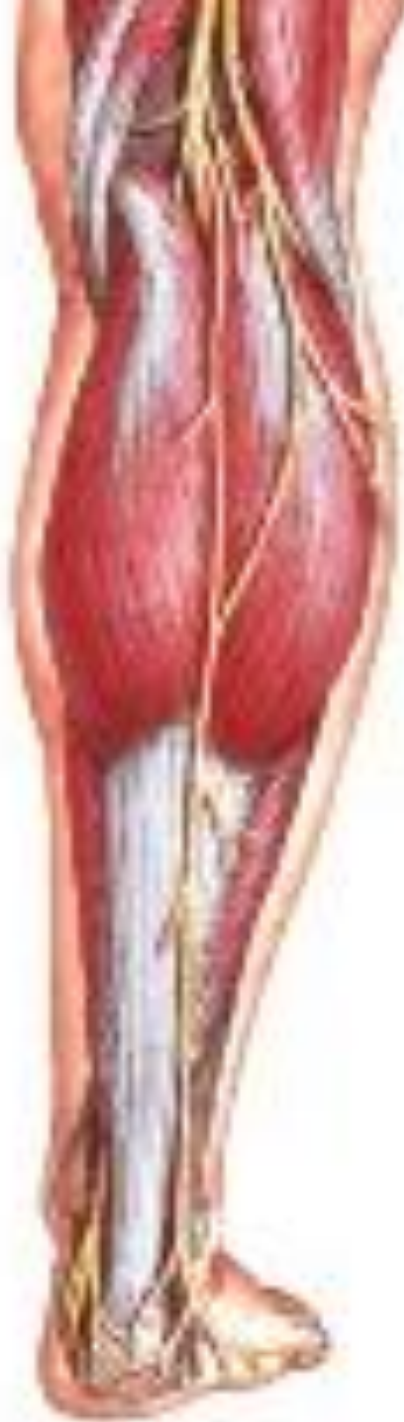N. TIBIALIS

(arcus tendineus m. solei)



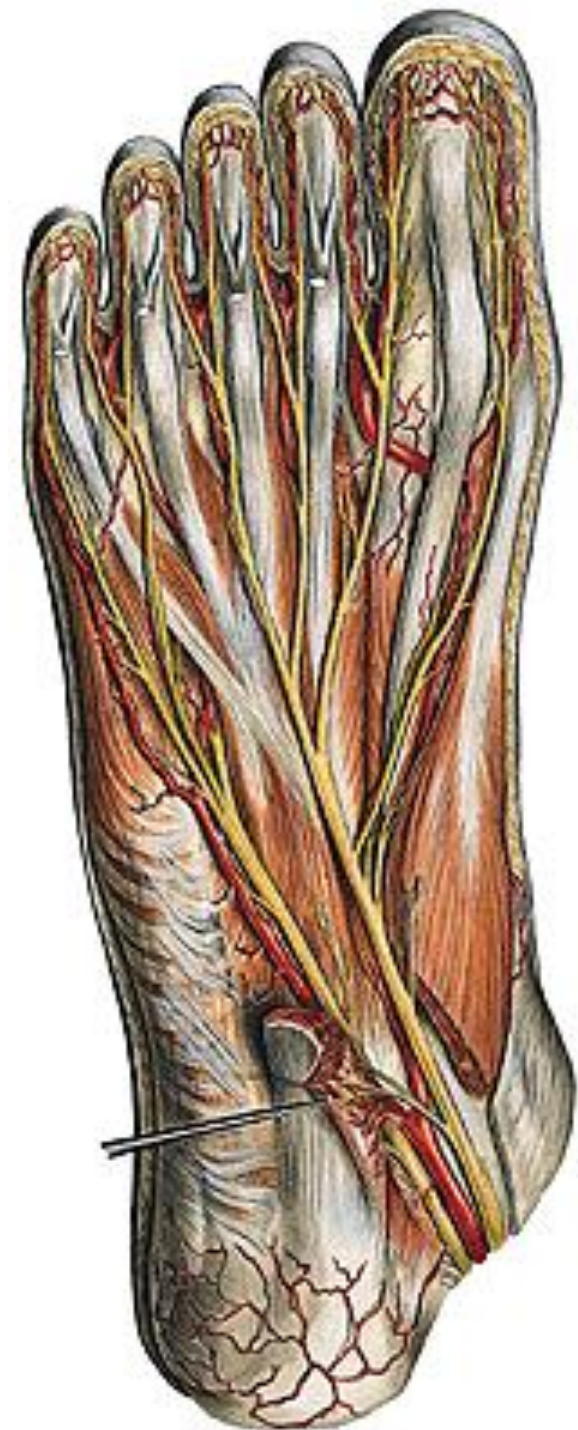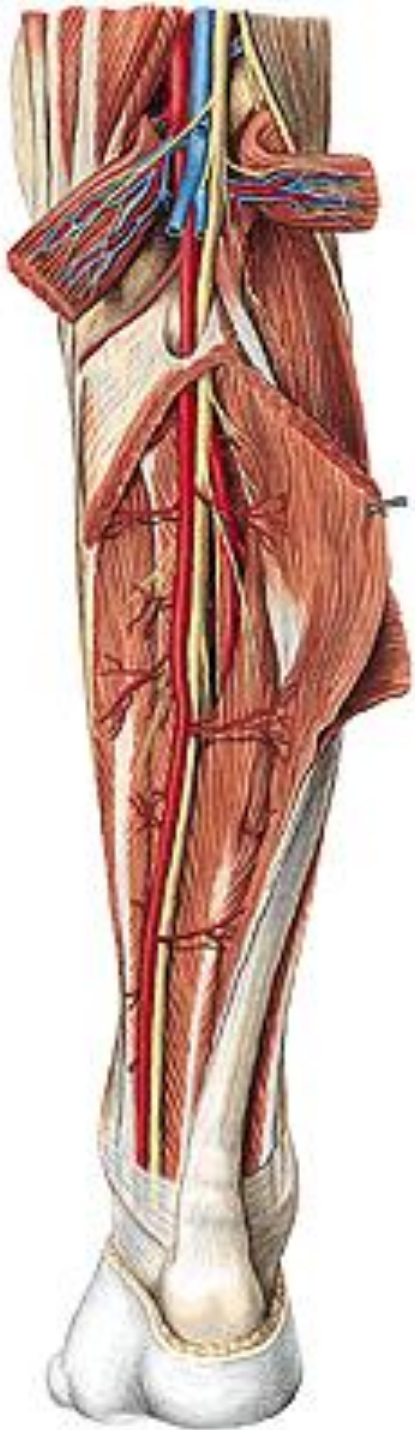
N. TIBIALIS

- n. cutaneus surae medialis
- n. suralis – n. cutaneus dorsalis lat.



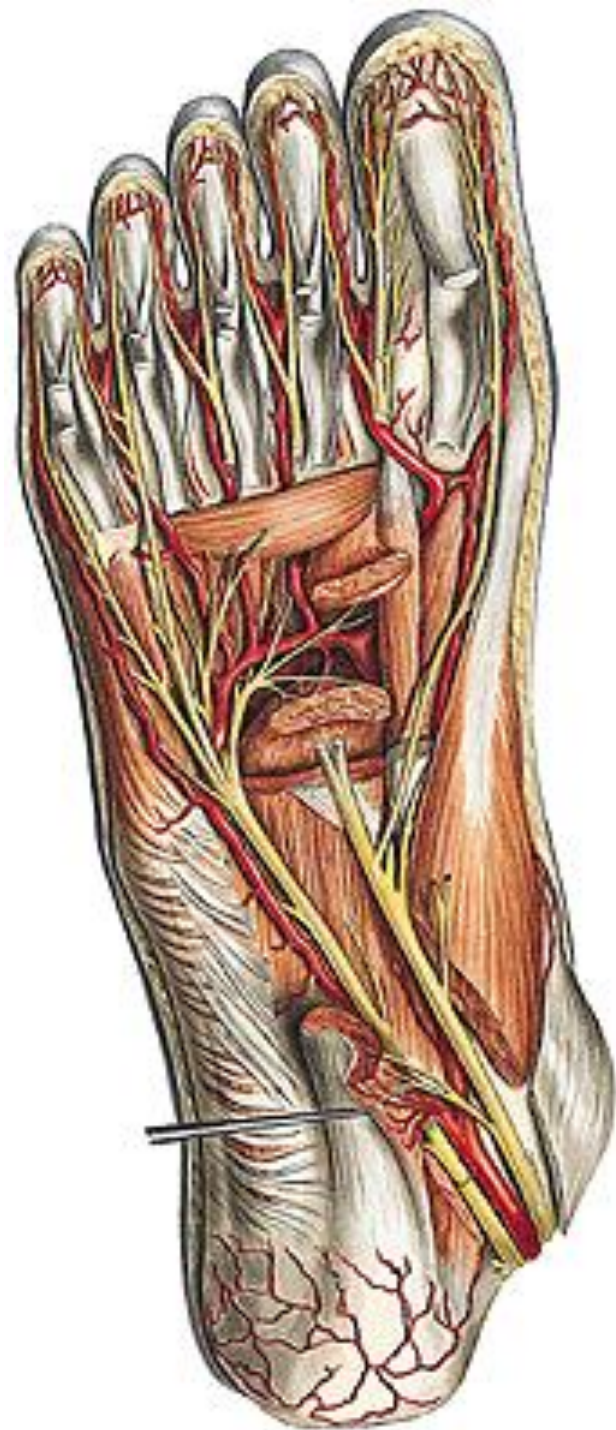N. TIBIALIS

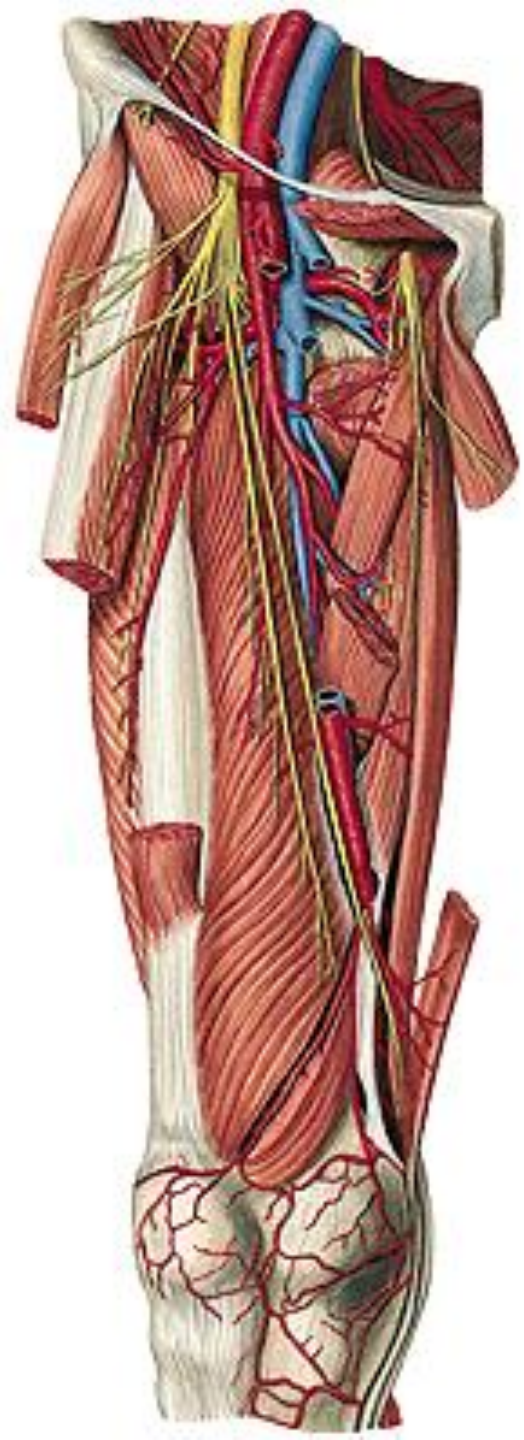
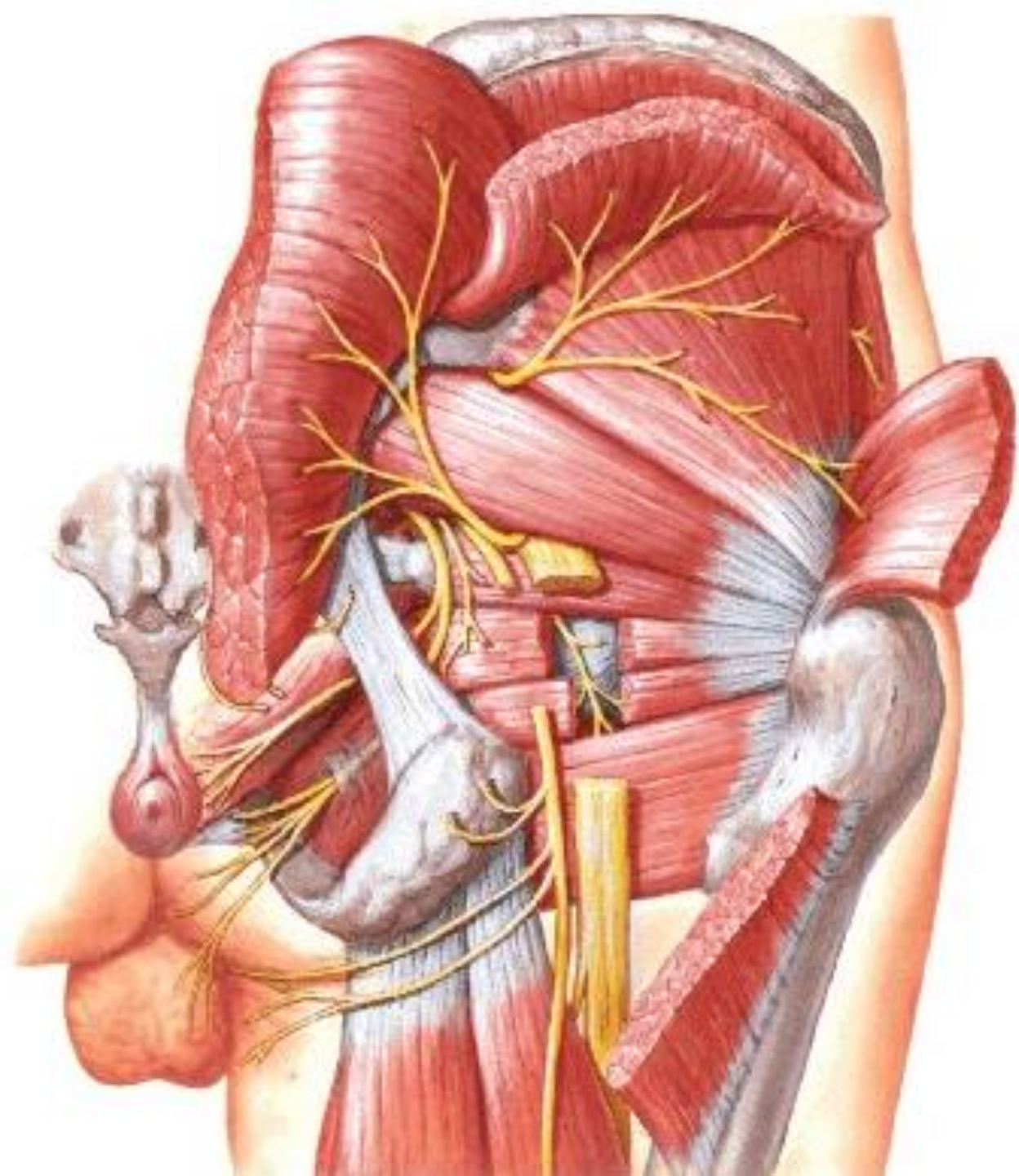
- rr. musculares
- n. interosseus cruris
- rr. calcanei med.
- n. plantaris med.
 - rr. musculares
 - nn. digitales plantares comm. et proprii
- n. plantaris lat.
 - r. spf. – nn. dig. plant. proprii
 - r. prof. – rr. musculares

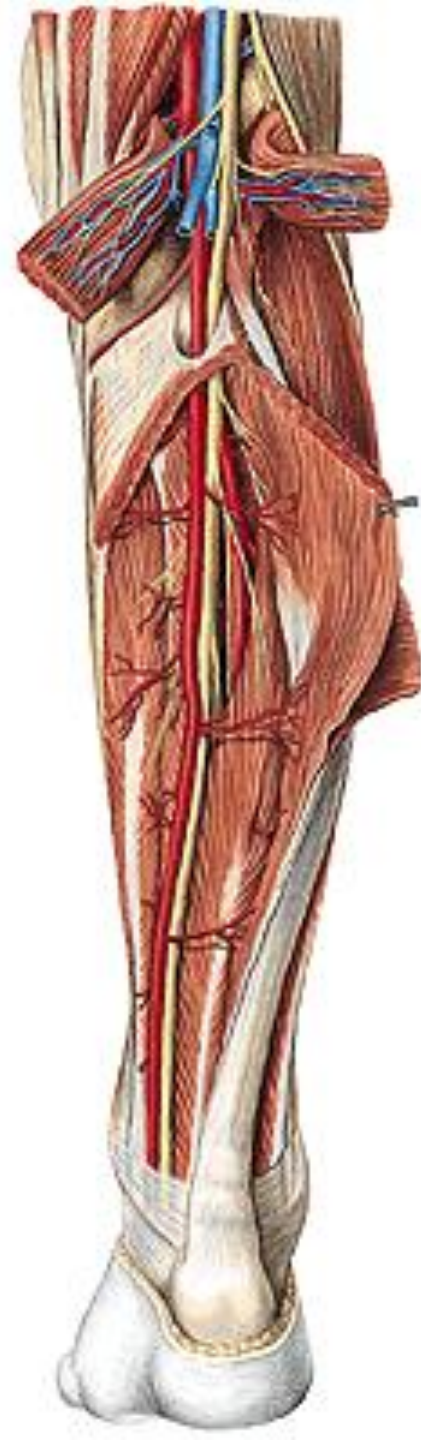
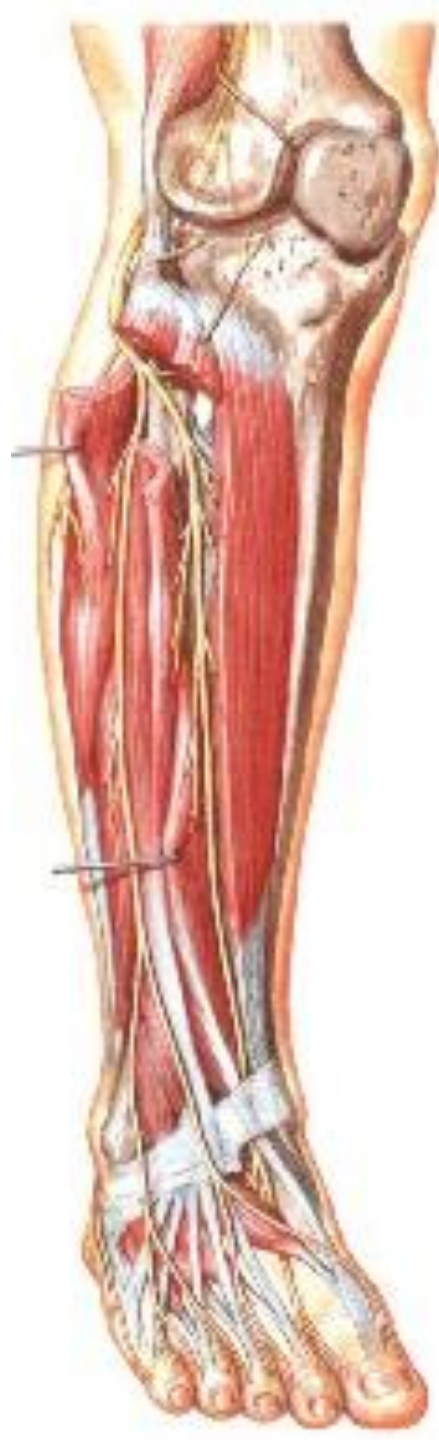
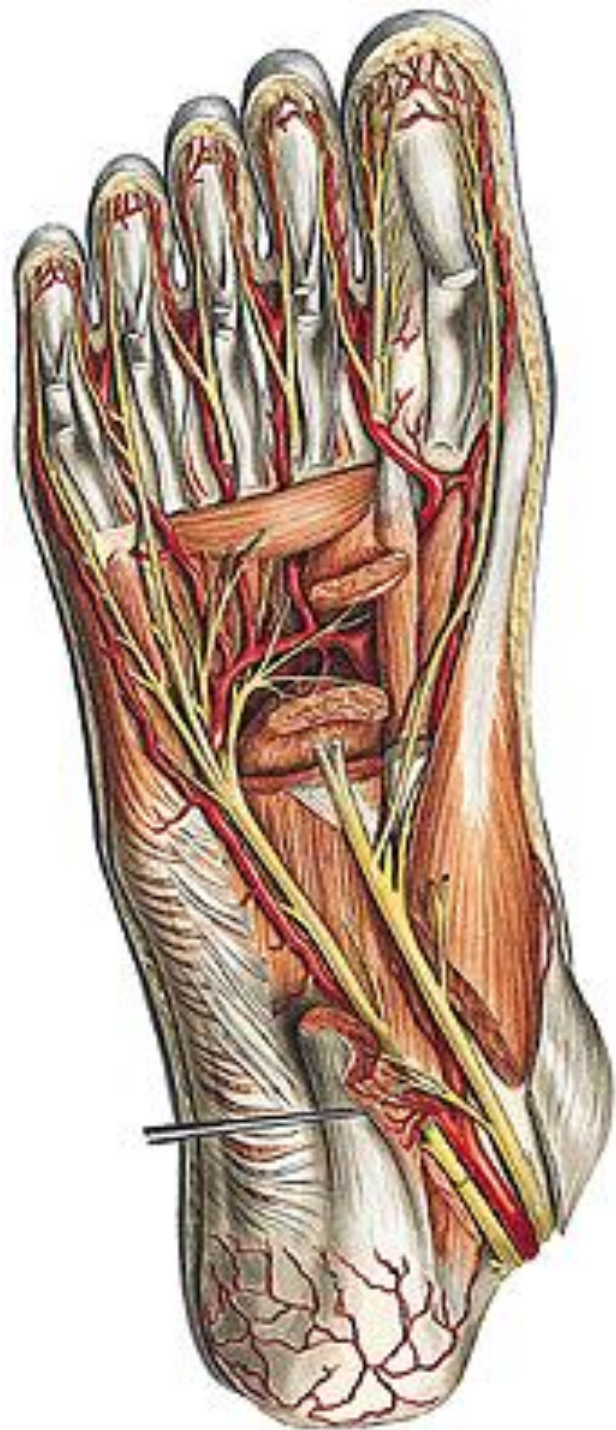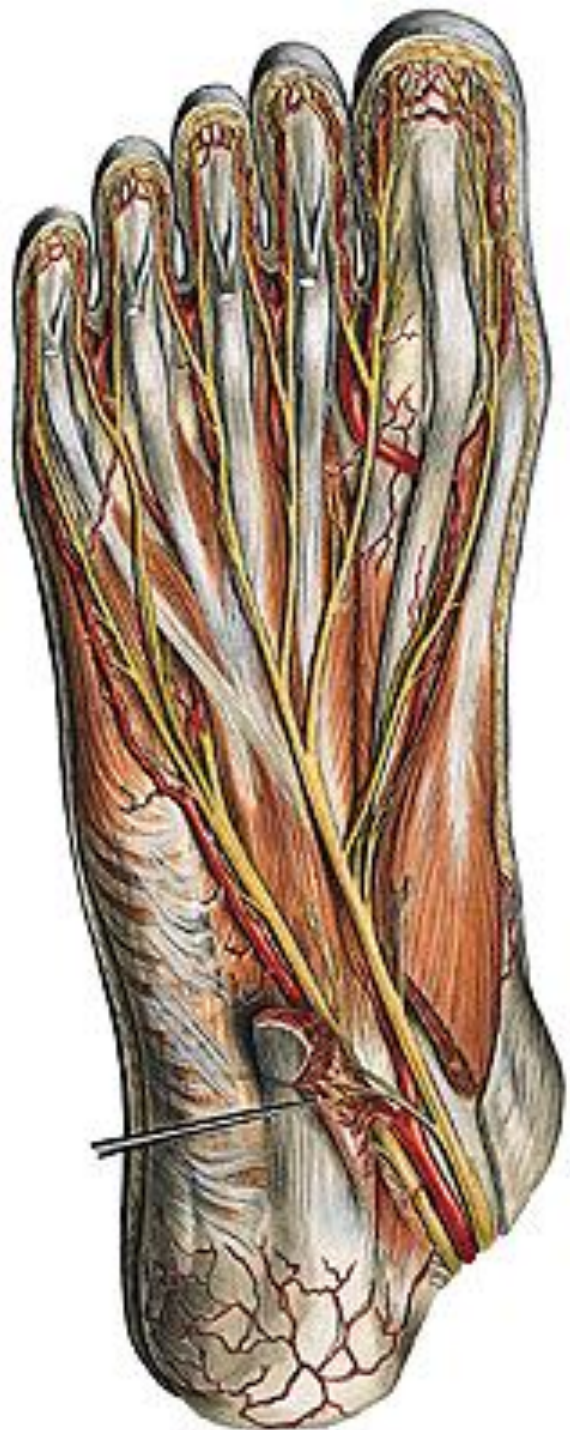N. TIBIALIS

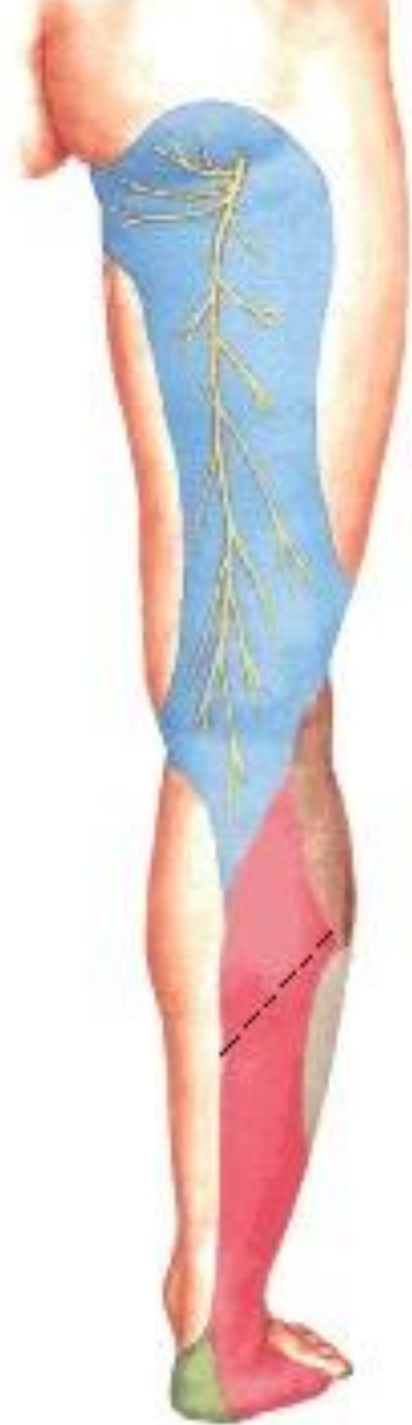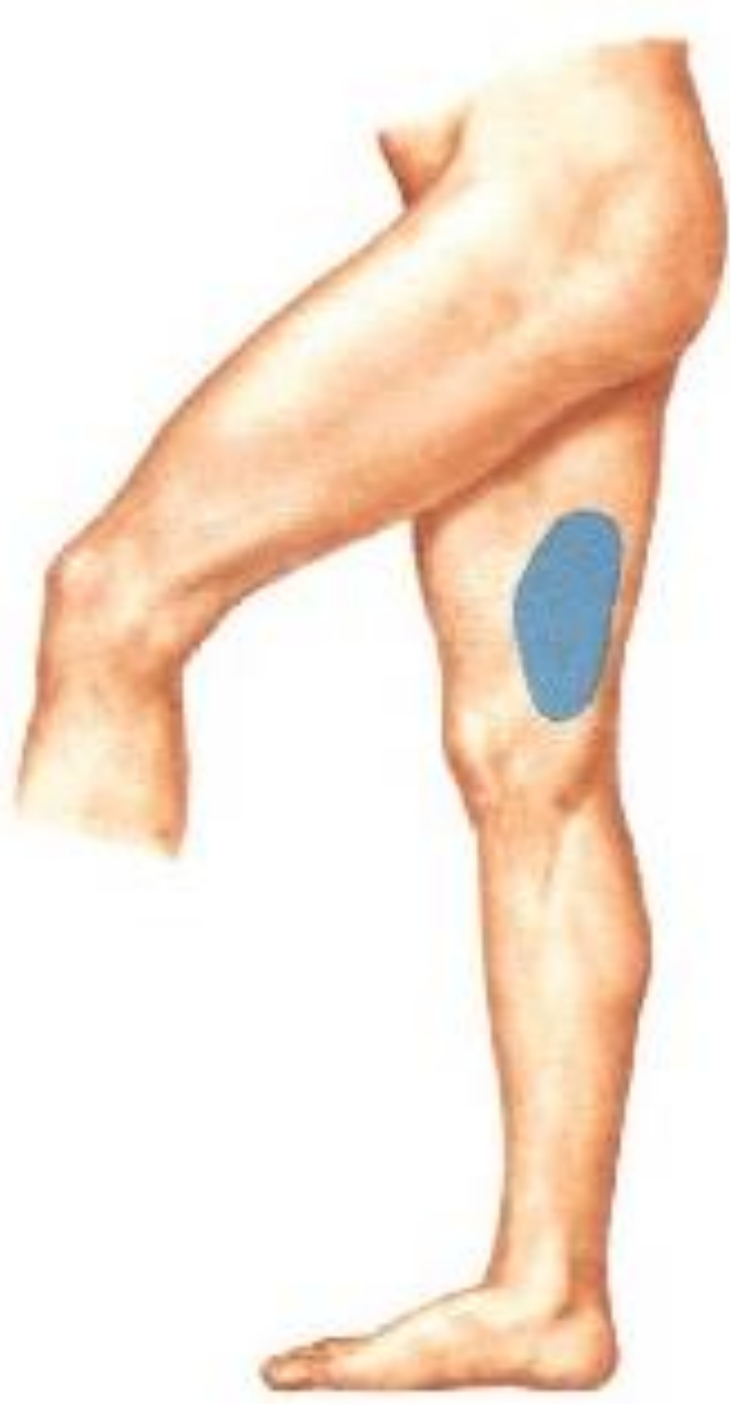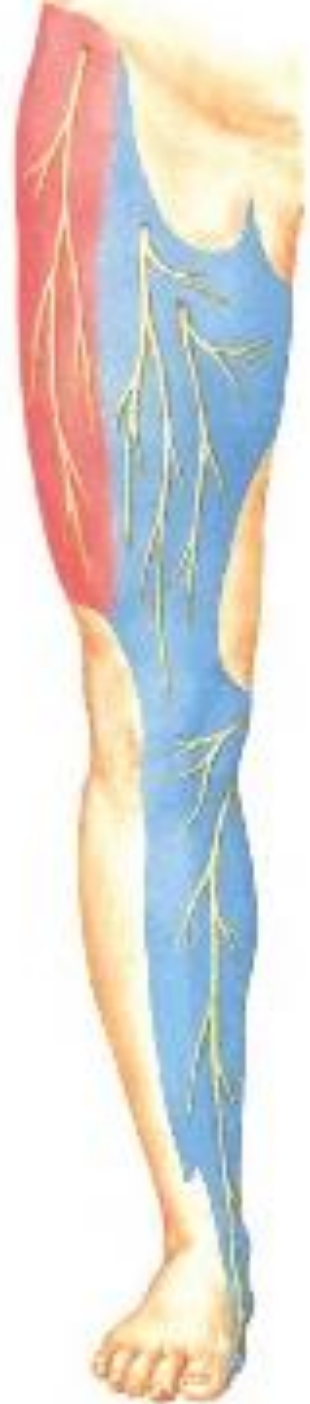- **n. plantaris lat.**
 - **r. spf. – nn. dig. plant. proprii**
 - **r. prof. – rr. musculares**













Illustrations were copied from:

**Atlas der Anatomie des Menschen/Sobotta.
Putz,R., und Pabst,R. 20. Auflage. München:
Urban & Schwarzenberg, 1993)
Netter: Interactive Atlas of Human Anatomy.
Windows Version 2.0**