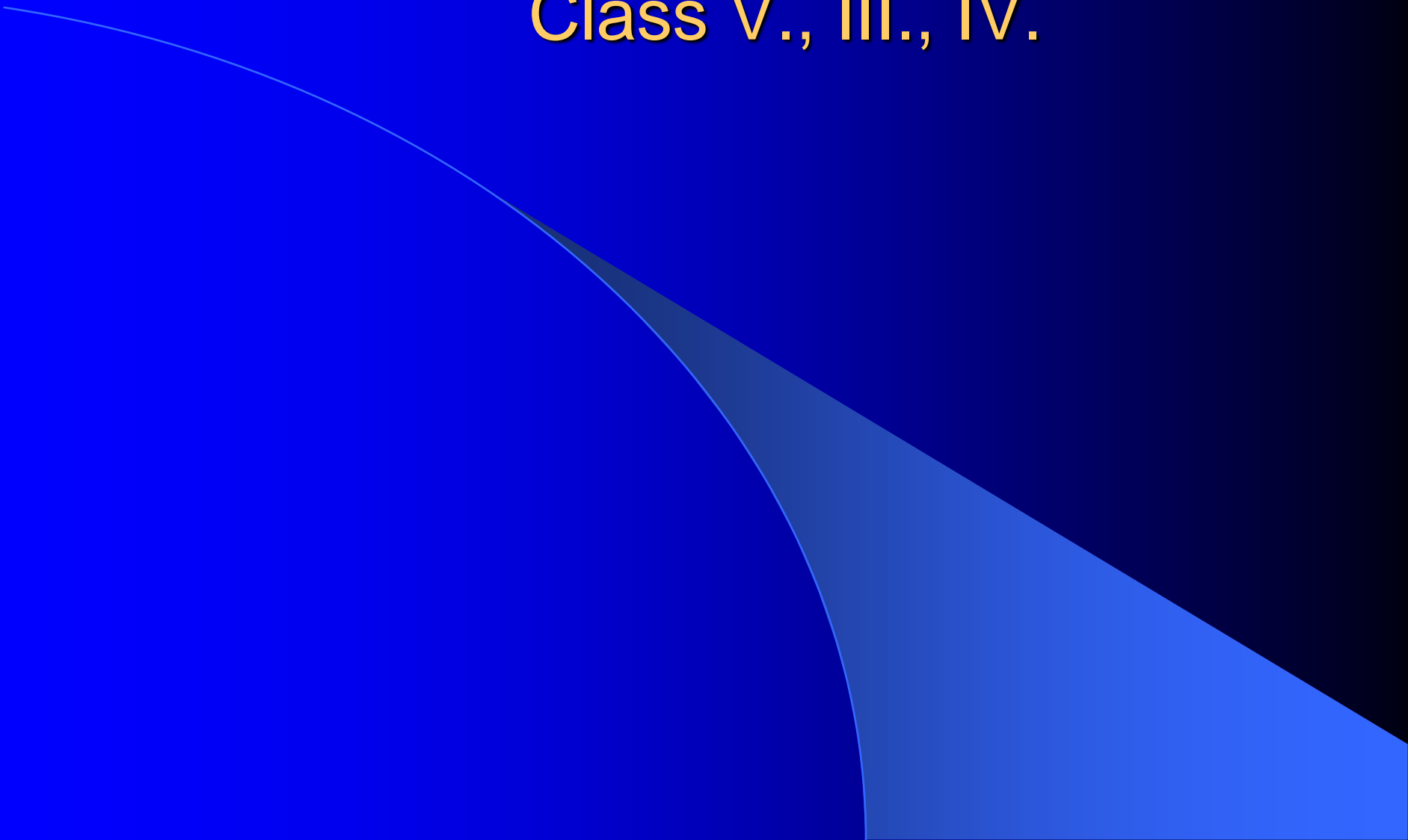


Preparation and making fillings

Class V., III., IV.

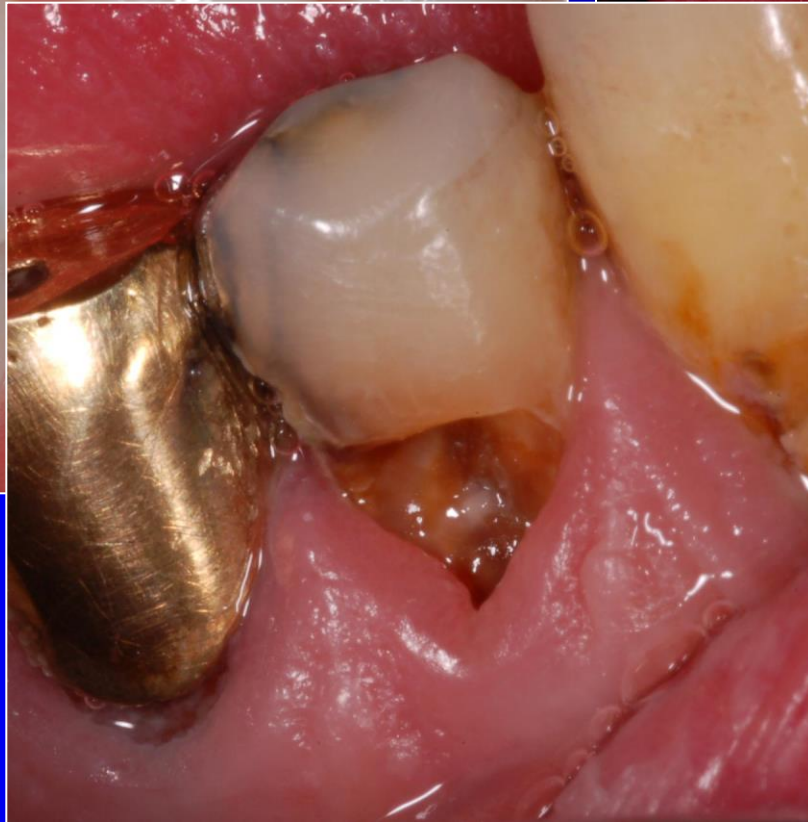
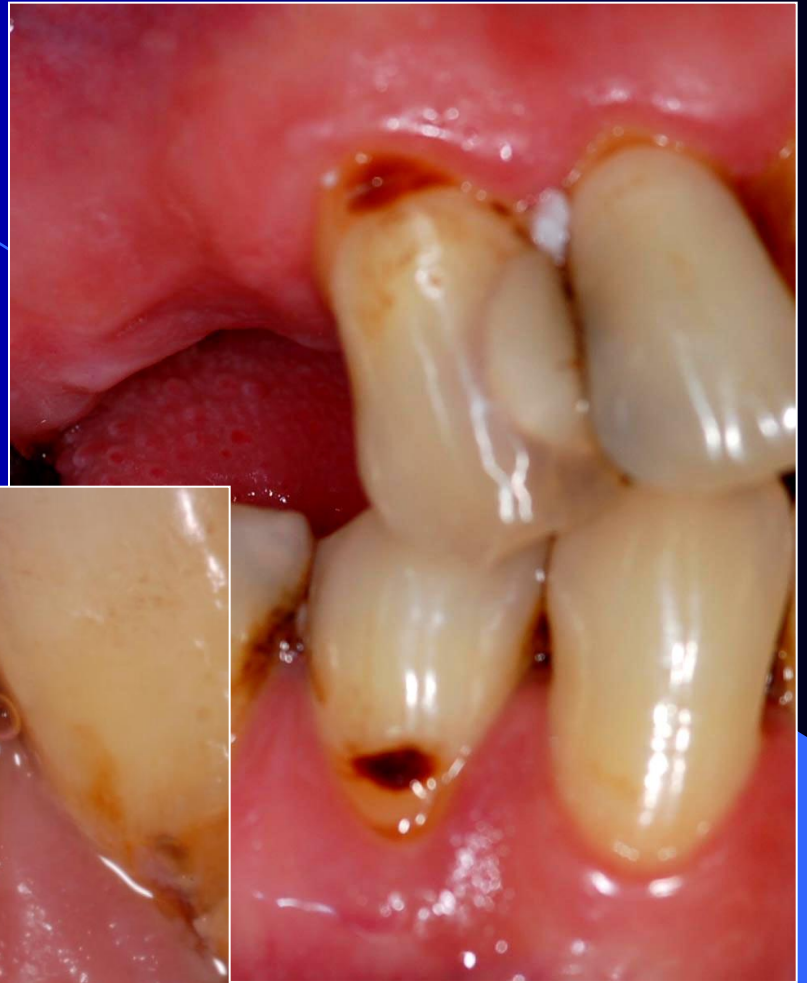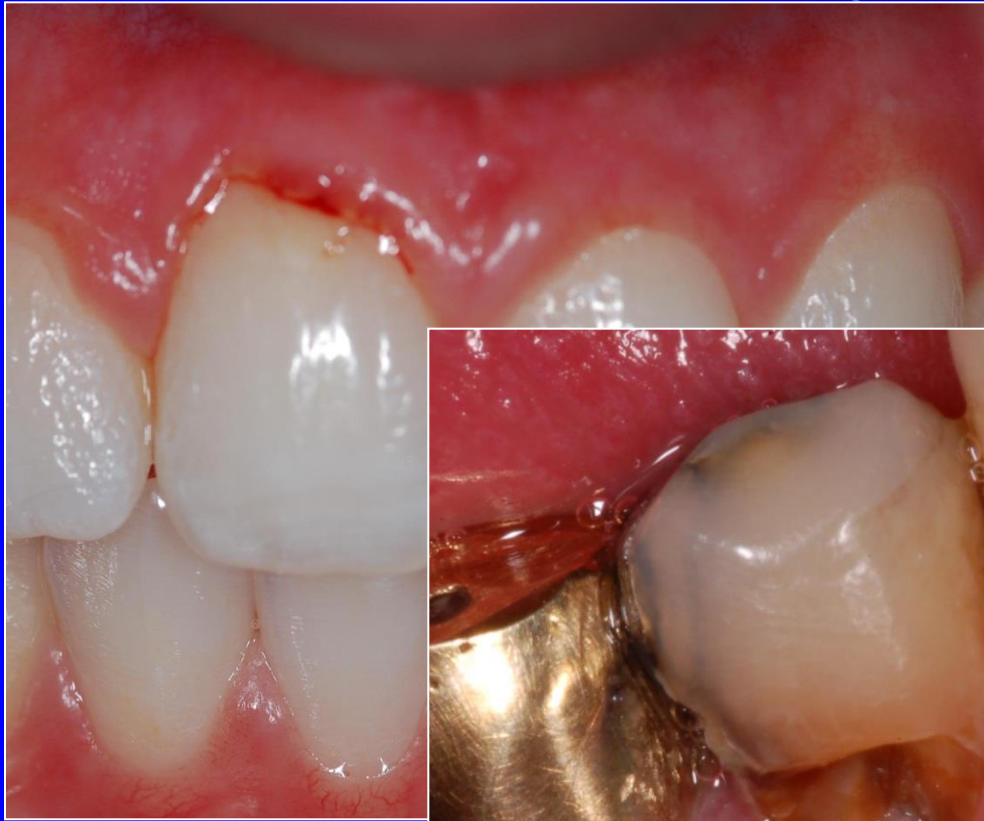A decorative graphic element consisting of a blue gradient shape that starts as a thin line on the left and curves downwards and to the right, ending as a solid blue area at the bottom right corner of the slide.

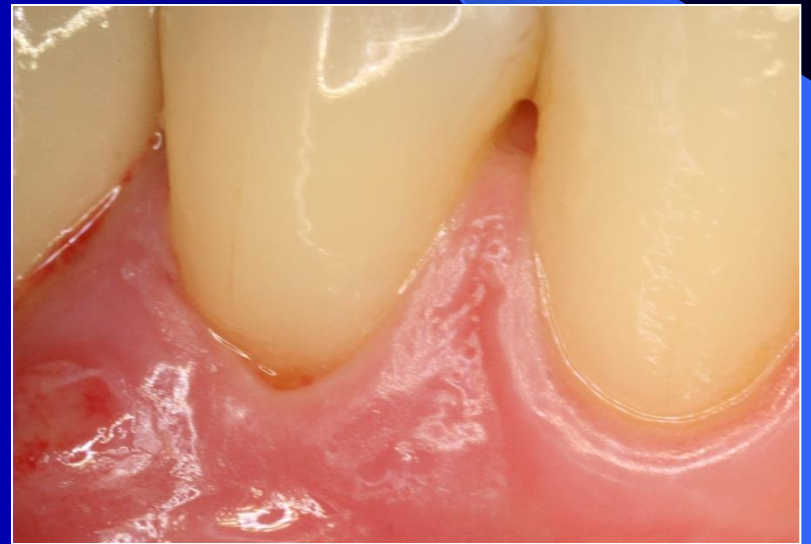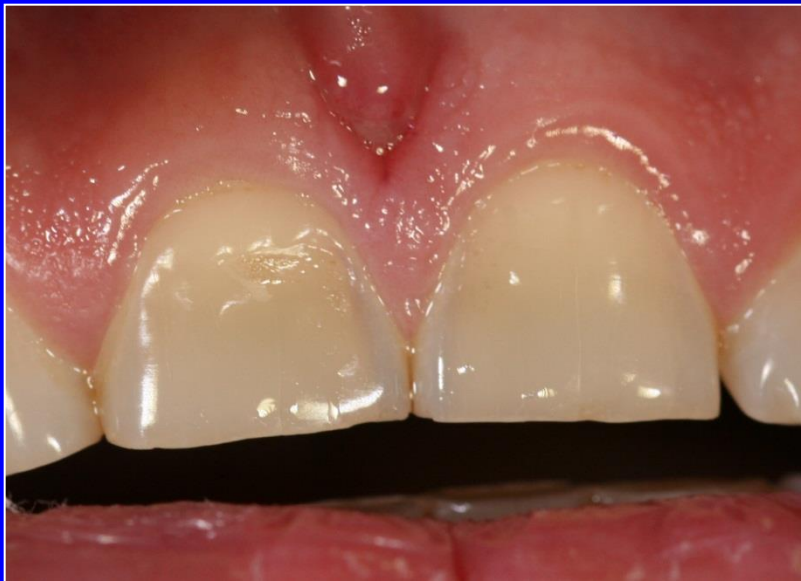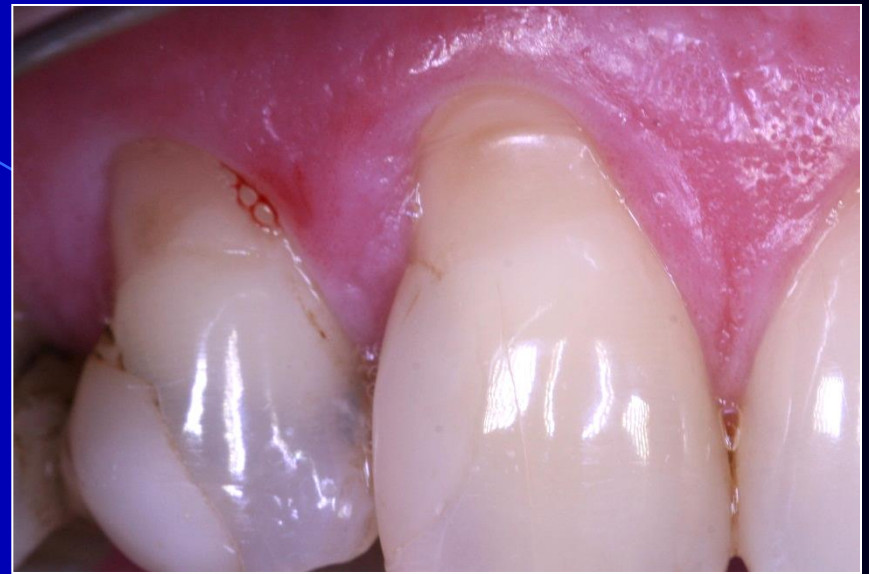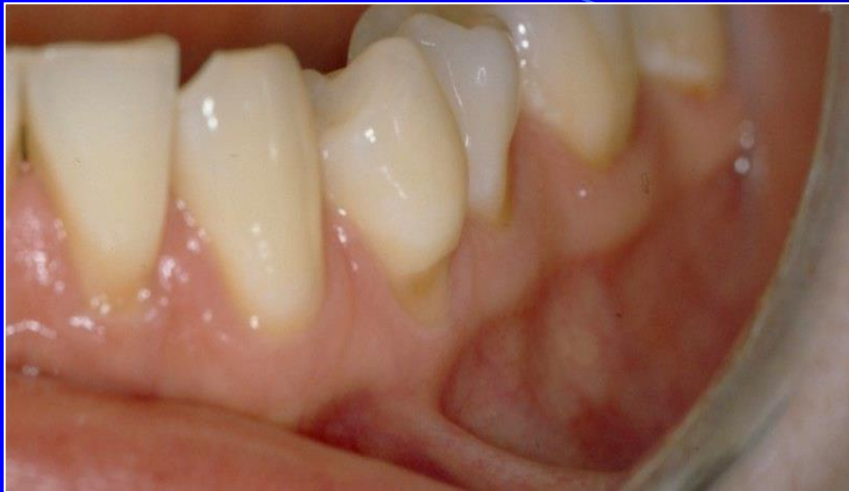Class V.

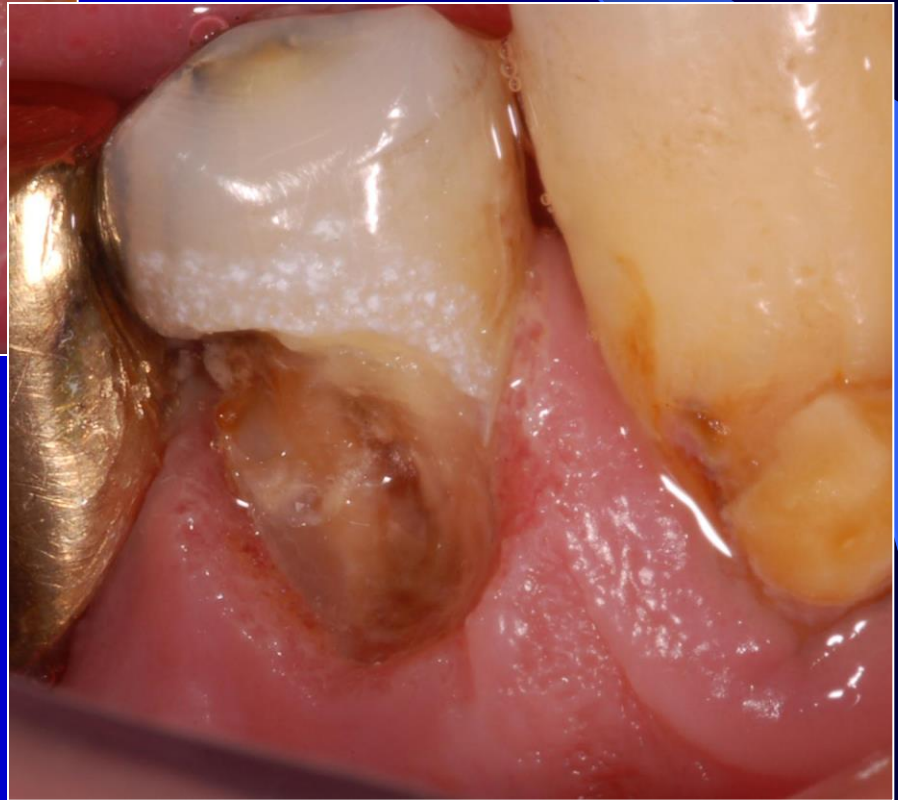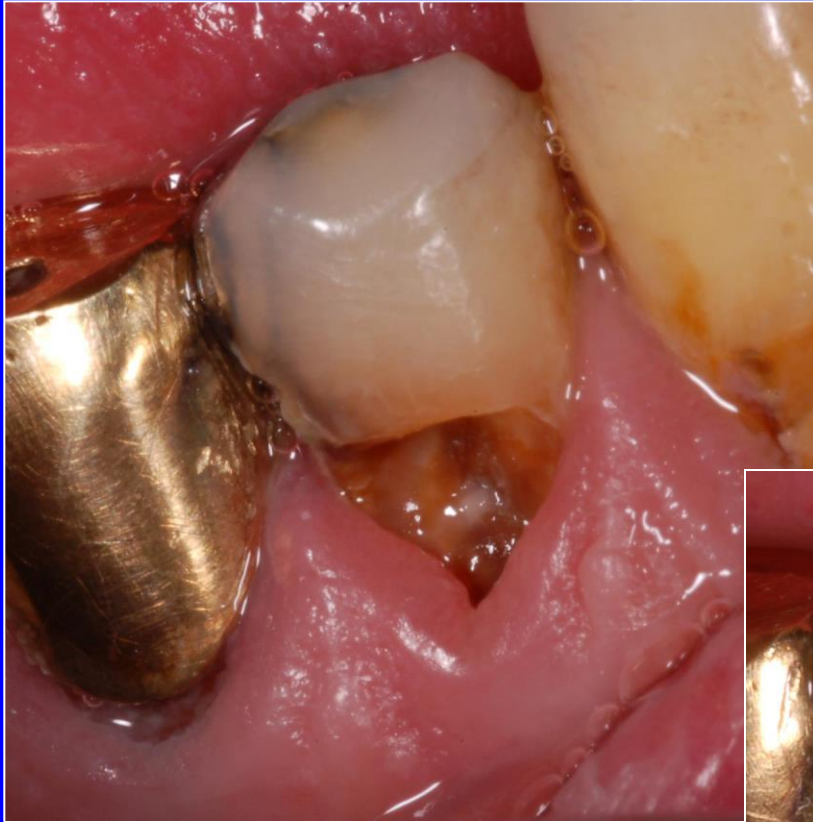
- Cervical defects
 - Dental caries
 - Non carious lesions (erosion, abrasion, V shaped defects)

Types of defects

- Caries
- Erosion
- Abrasion
- V shaped defects
- Erosion





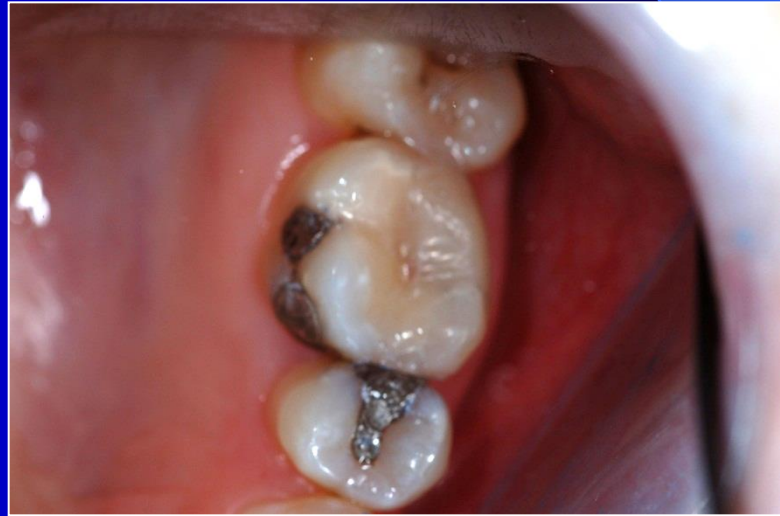

Choice of material

- Amalgam (posterior area)
- Composite (mainly in anterior teeth where the defect is situated in enamel)
- Glassionomer: caries defects, esp deeper, situated out of enamel, higher caries risk

V.Class Amalgam

- Posterior area



Access

- Elimination of the undermined enamel
 - Burs or diamonds (pear), tapered fissure bur
- Separation of the gingiva – temporary filling
guttapercha, fermit, clip, zinkoxidsulfate
cement, cavit, provimat).
- Ablation of ingrown gingiva – surgical
(scalpel, laser, high frequency current)

Cavosurface margins

Gingival: axial depth of 0,5 mm inside the DEJ.

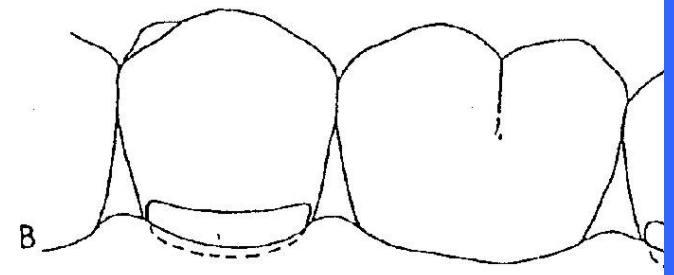
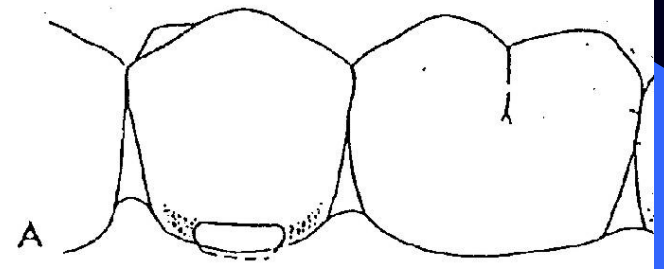
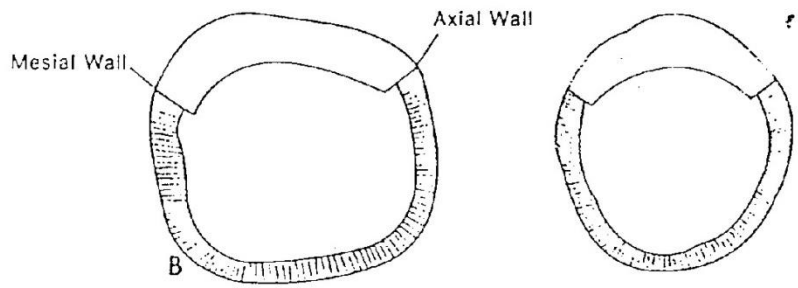
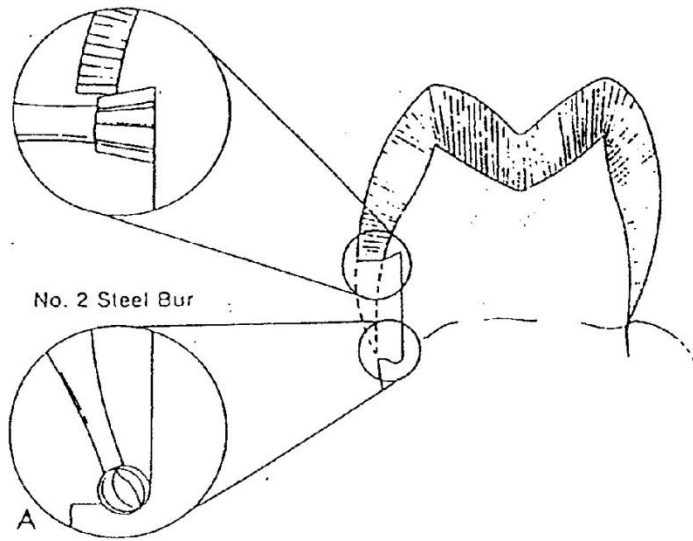
Extention of the preparation incisally,

Gingivally: 0,5 mm subgingivally

mesially and distally: to axial walls

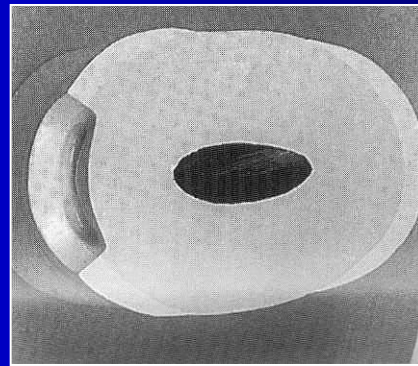

Or: untill the cavosurface margins are positioned in sound dental structure. (small cavities, good oral hygiene)

Total depth: 1 – 1.25 mm. If on root surface -0,75 mm



Retention

- Box 0,75 – 1,25 mm deep, undercuts,




Depth

Gingivally: axial depth of 0,5 mm inside the DEJ.

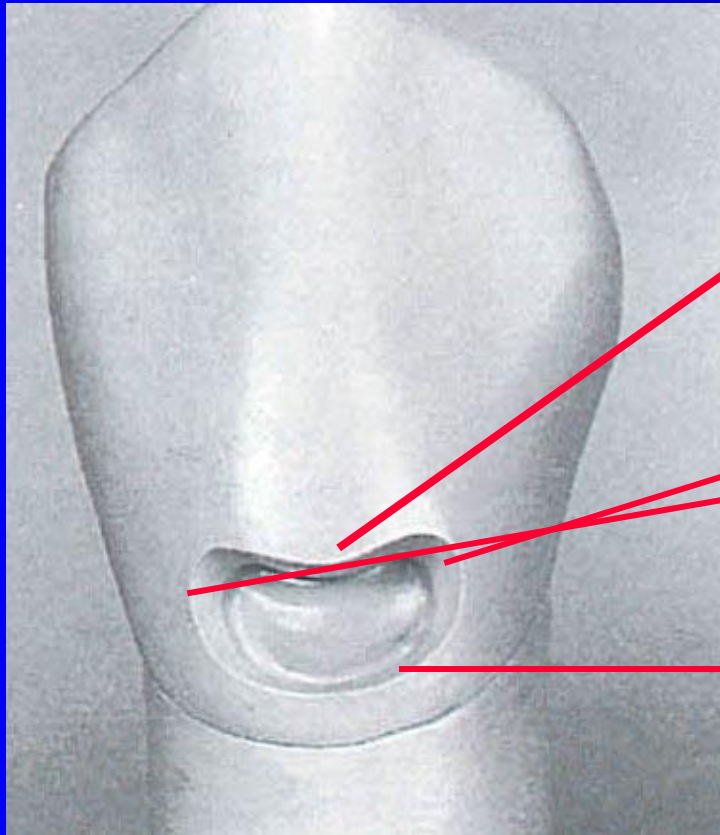
Total depth: 1 – 1.25 mm. If on root surface -0,75 mm

Resistance

No occlusal forces



The bottom of the cavity follows the convexity of the crown.



Occlusal margin

Mesial and
distal margin

Gingival margin

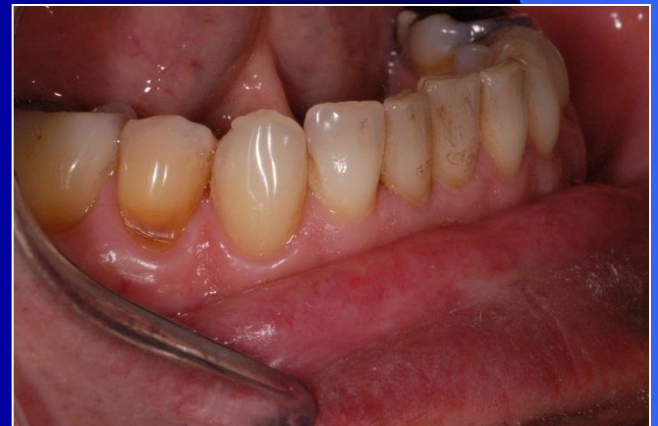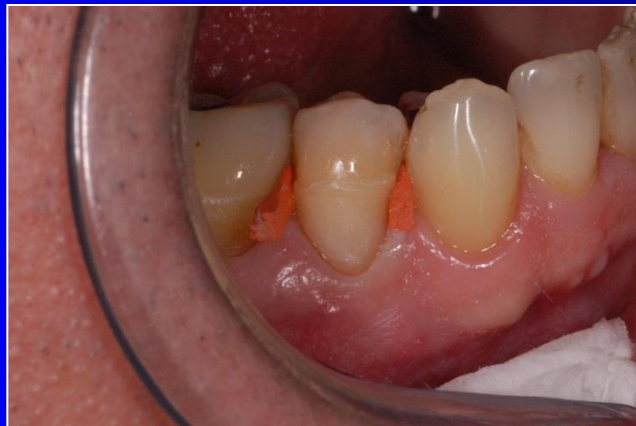Filling

Base – pulpal wall

Amalgam – portion by portion, condensor with straight front, burnisher (spatula).

Class V. composit

- Aesthetic area
- Margin in enamel



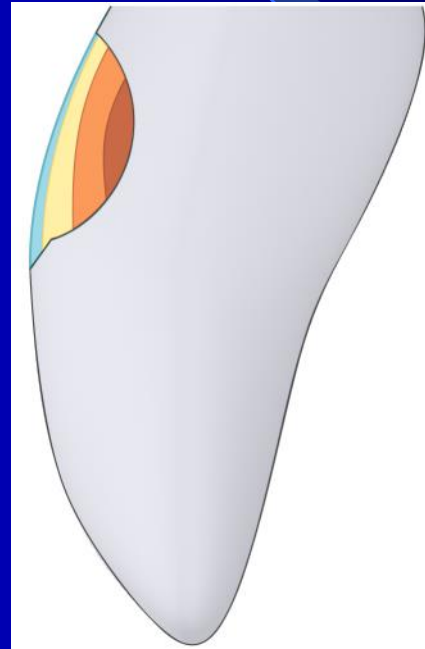
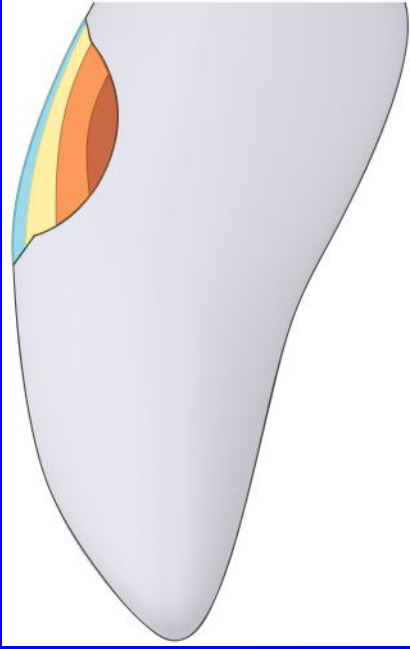
Preparation for composite, making filling

Cavity is limited on caries lesion only

Enamel must be beveled

Etching, priming + bonding

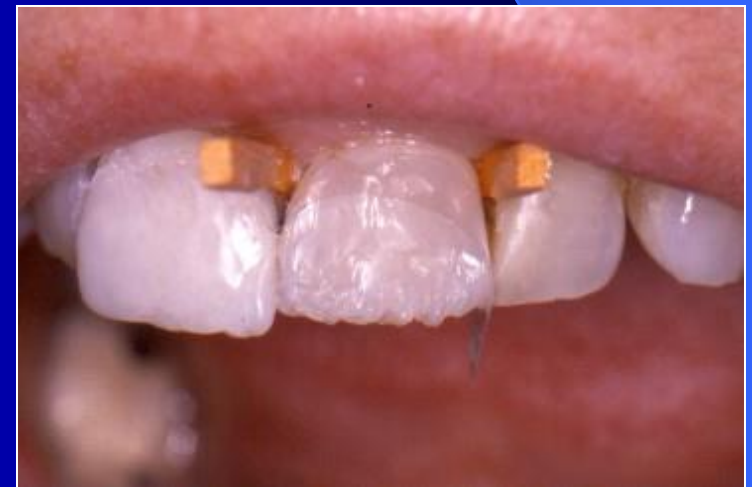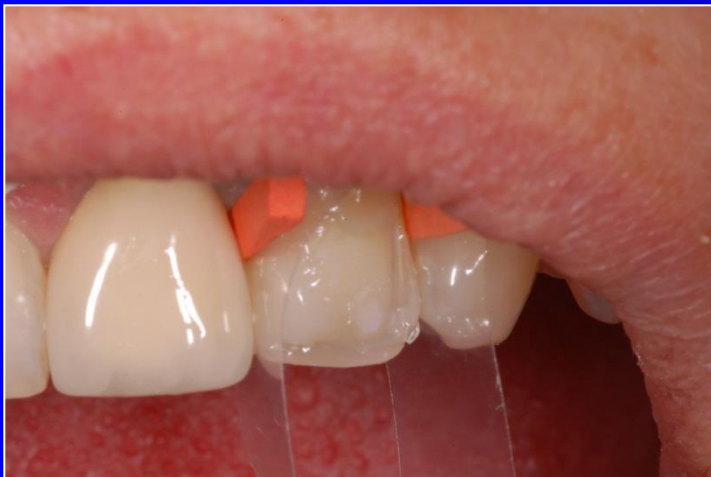Placement of composite

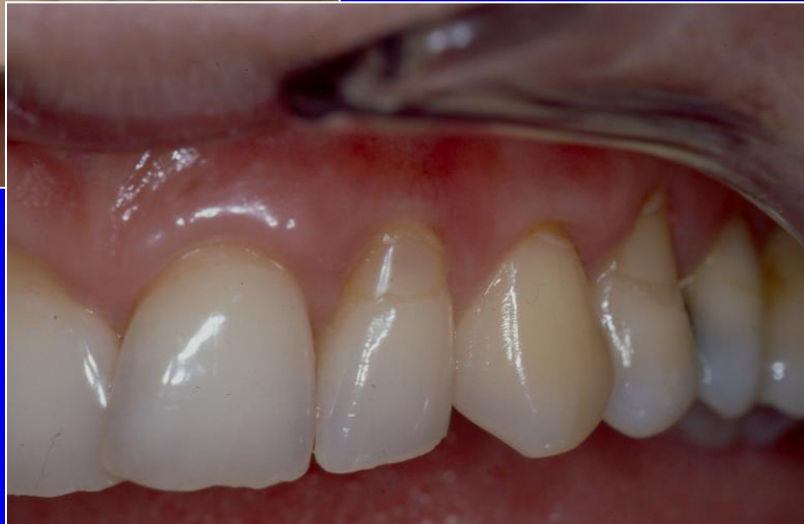
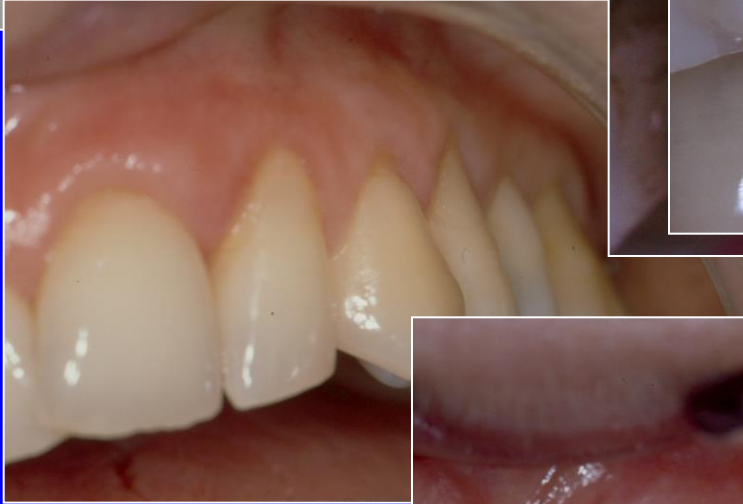
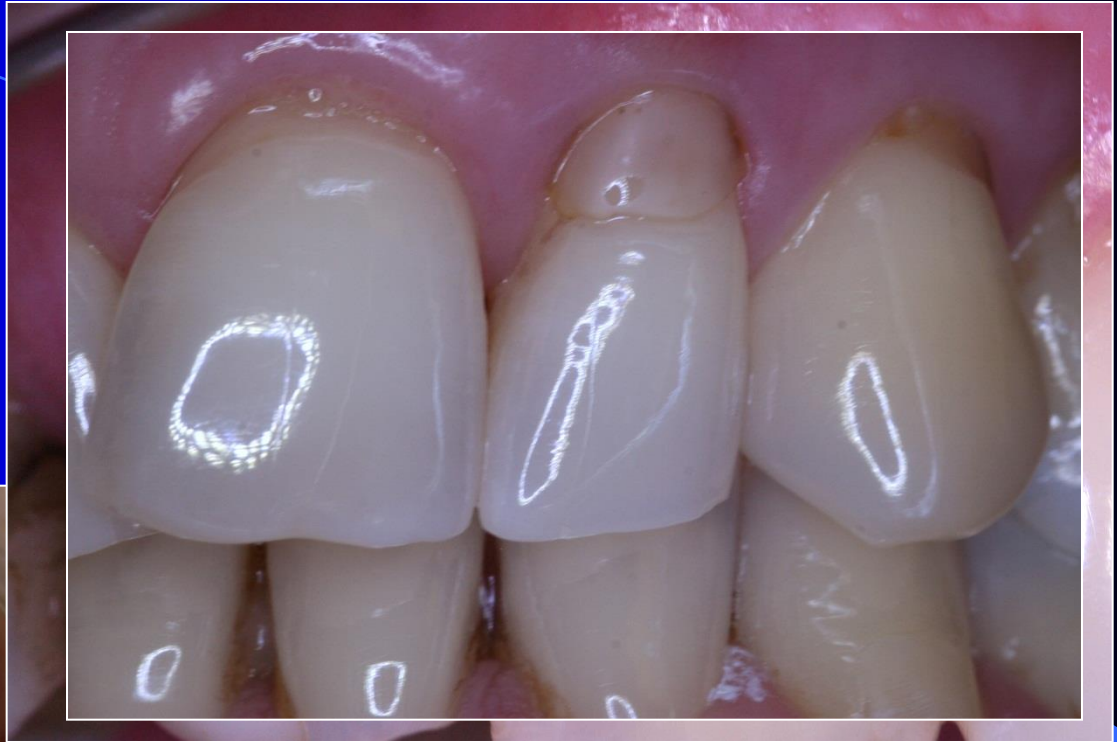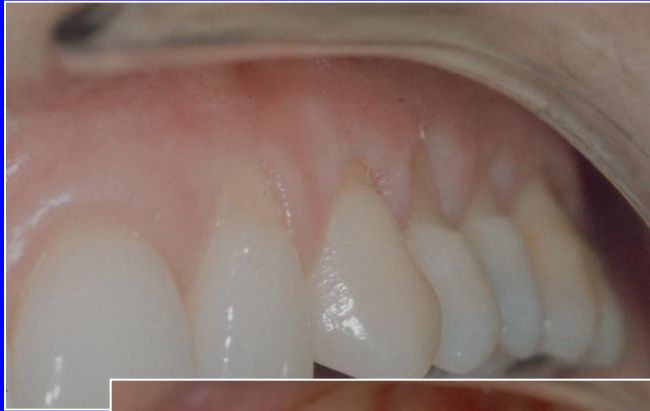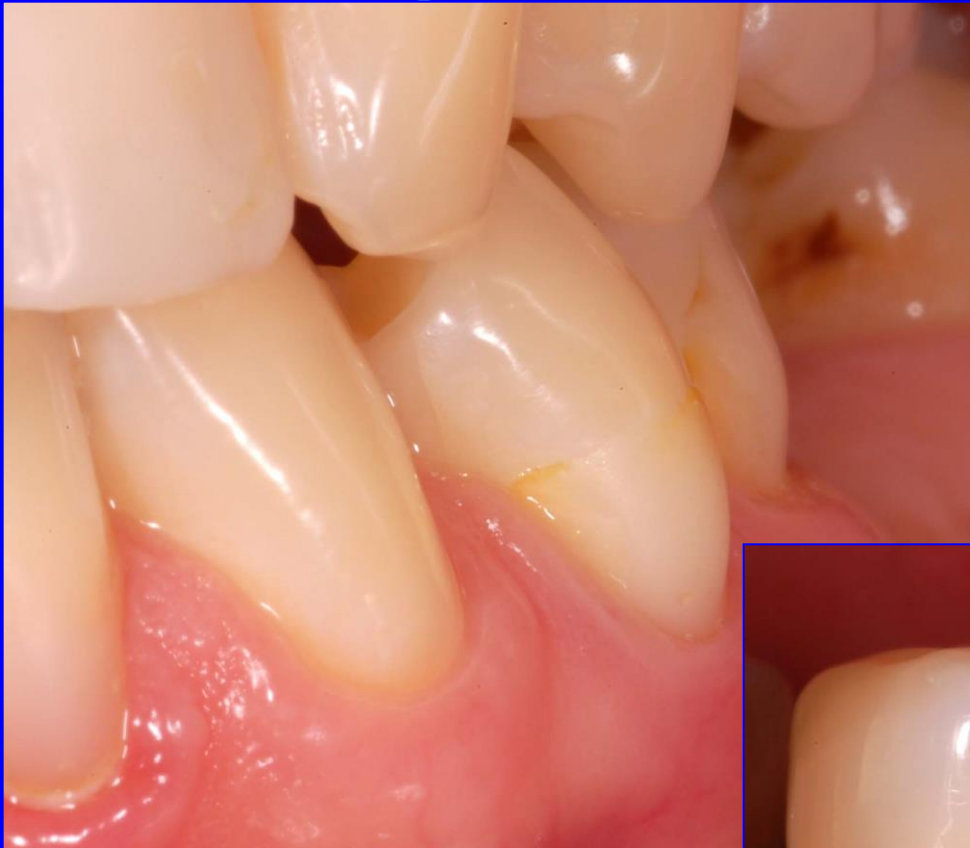Matrices

Transparent cervical matrices

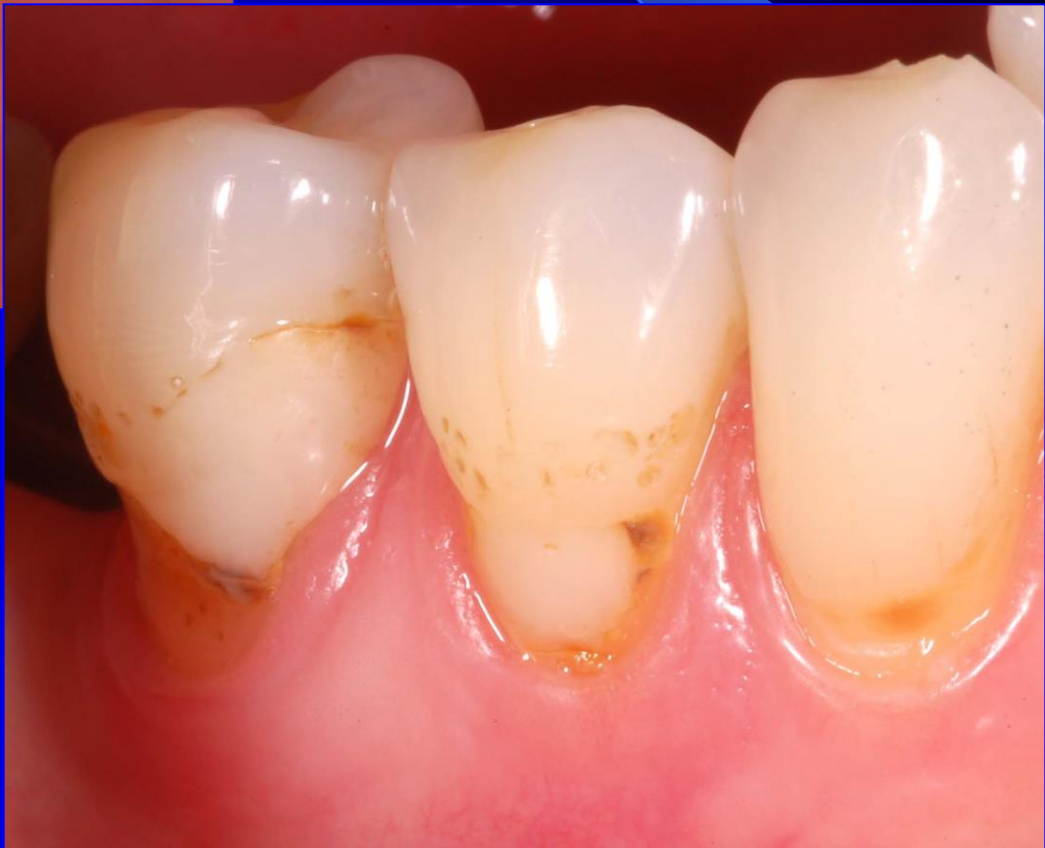Matrix band acc. to Belvedere







← Laser

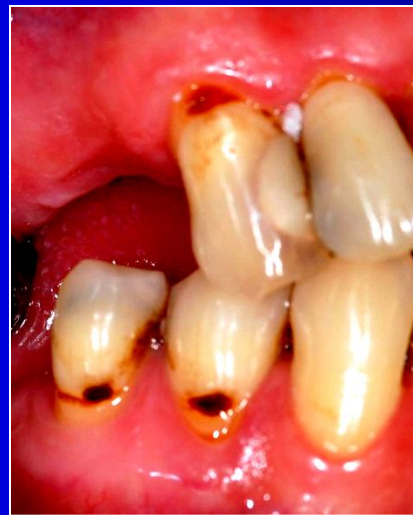

← laseri nastroj



Class V. glassionomer

- Cavities with margins in cementum
- Or also in enamel or partly in enamel (in patients with worse level of oral hygiene)

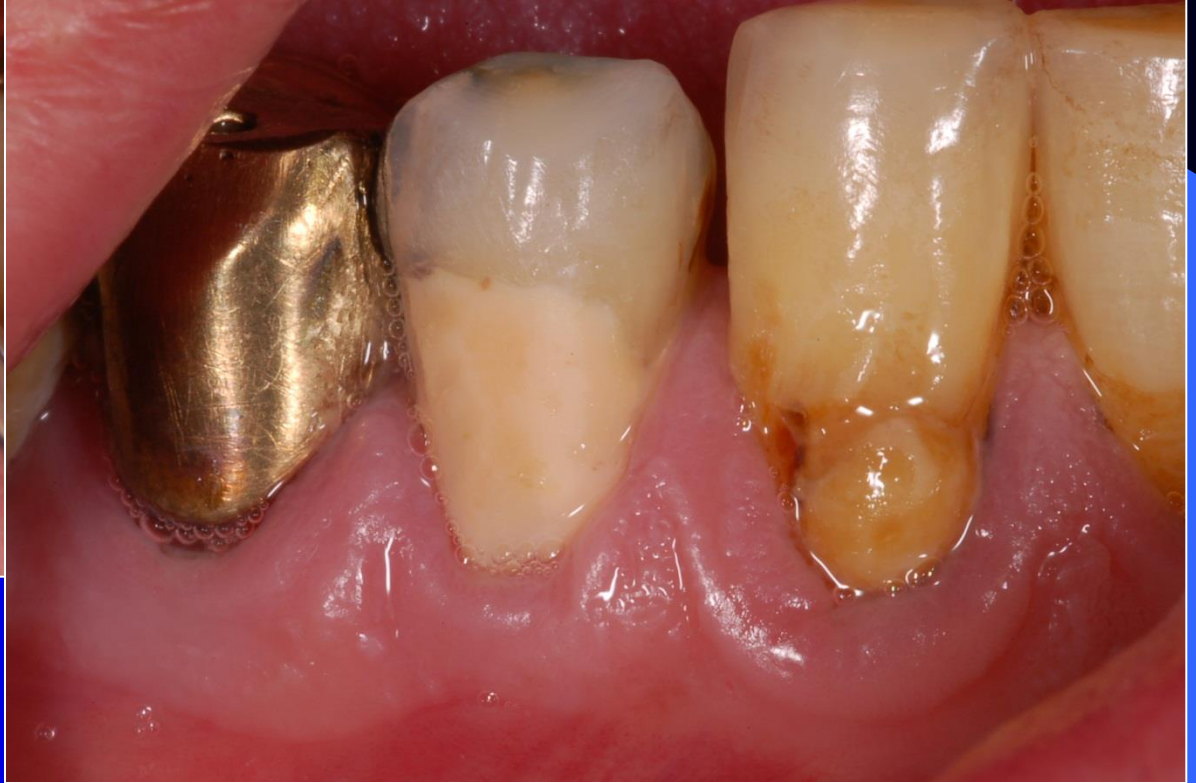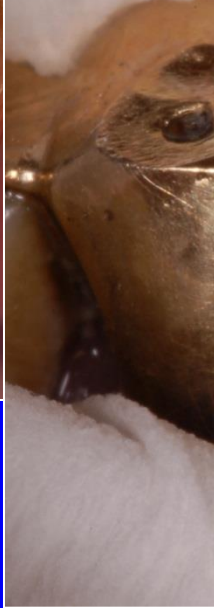
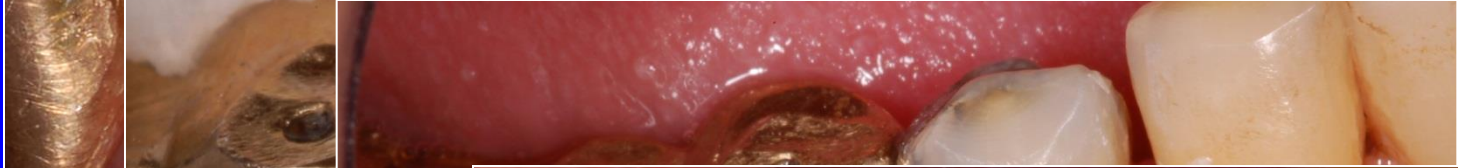

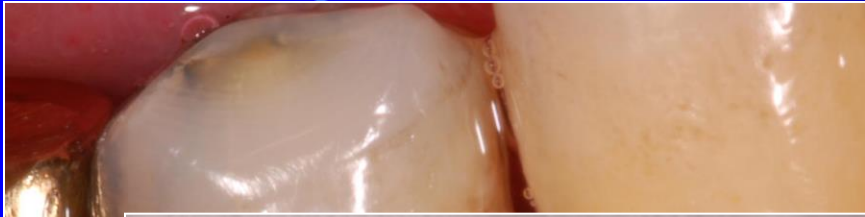
Glassionomer

- Bonds chemically
 - Realease fluoride ions
 - Thermal expansion similar to dentin
 - Acceptable aesthetics

Preparation for glassionomer making filling

- Cavity is limited on carious lesion only
- Margins should be smoothed (no bevel)
- Conditioner (polyacrylic acid) -20 s
- Washing
- Placement of glassionomer (one bulk)
- Matrix (transparent or aluminium cervical matrix)

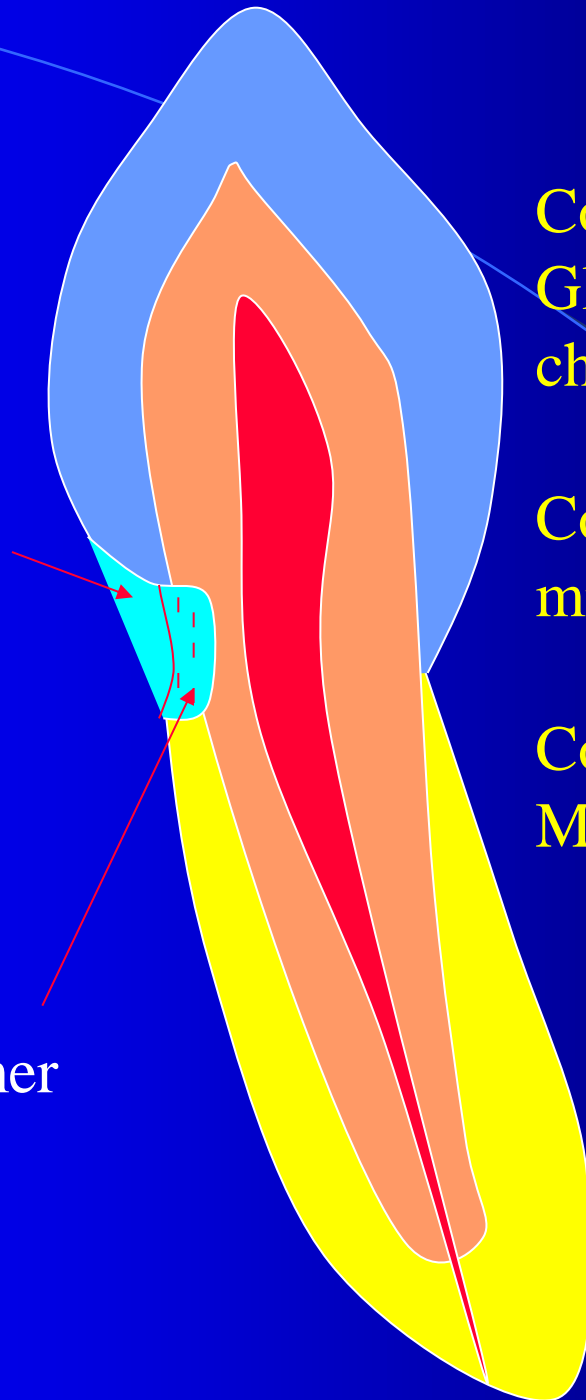


Combination of materials

- Glassionomer – replaces lost dentin
- Composite – replaces lost enamel

Composite

base of glassionomer

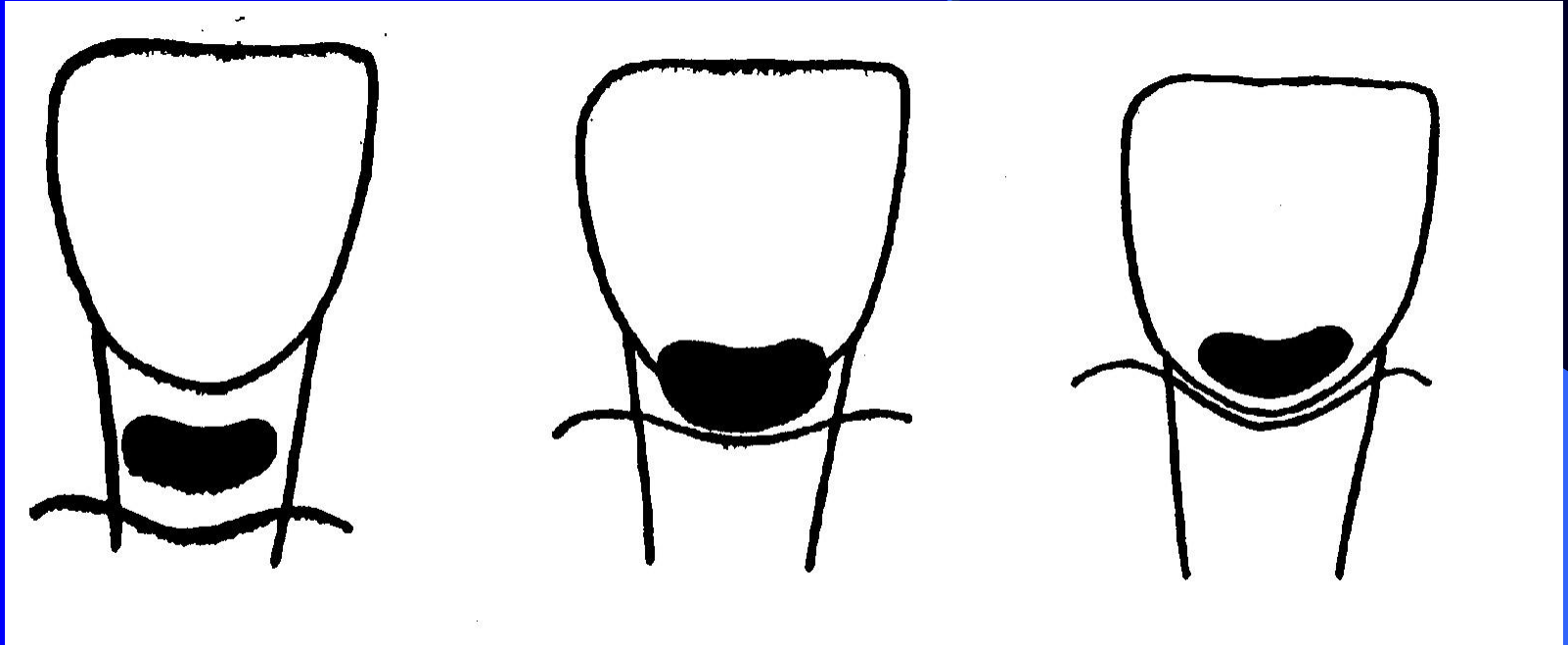


Connection
Glassionomer – tooth:
chemical

Composite – tooth:
micromechanical

Composite – glassionomer
Micromechanical.

Choice of materials



Glassionomer

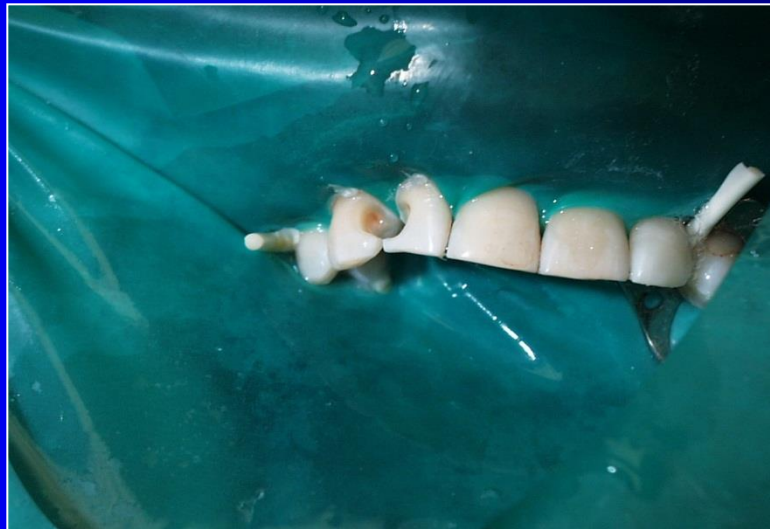Combination

Composite

Or amalgam in posterior area

Class III.

Proximal surface of frontal teeth (incisors and canines) without loss of incisal edge

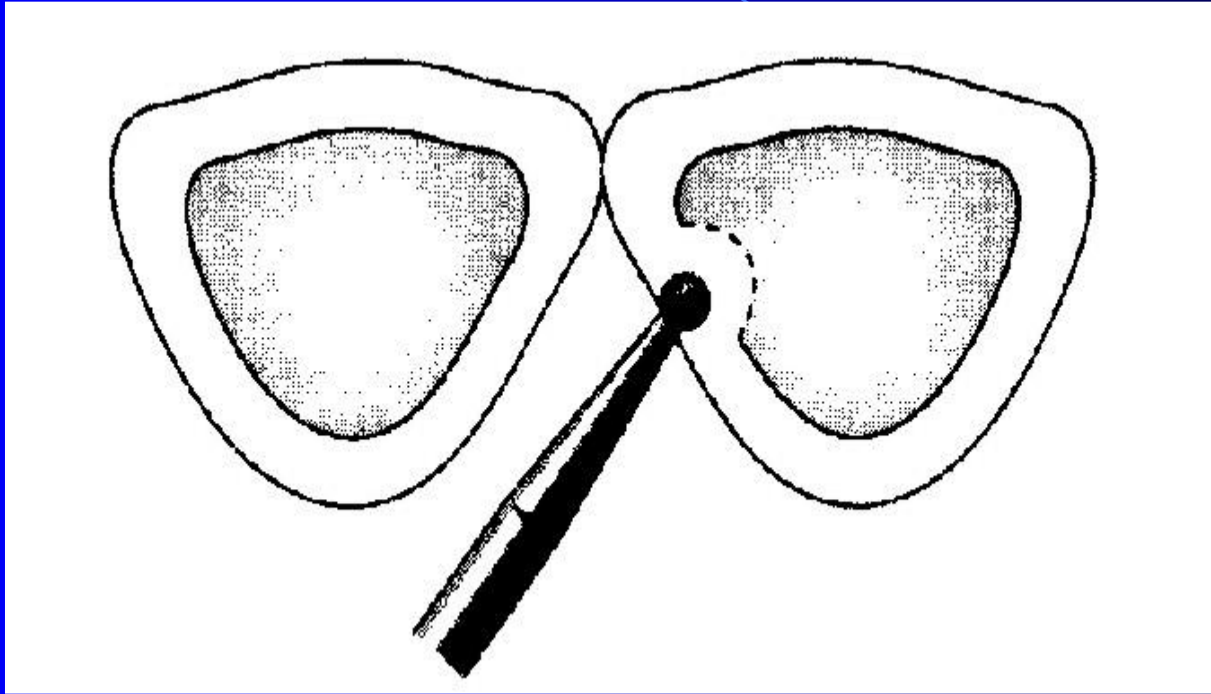


Access to the cavity

- **Through the enamel from the oral side**
- **Removal of old filling**
- **Separation of teeth - wedges**
- **Removal of hyperplastic gingiva**




Access



Round bur or diamond,
from oral side,
the caries lesion
on proximal wall must be reached

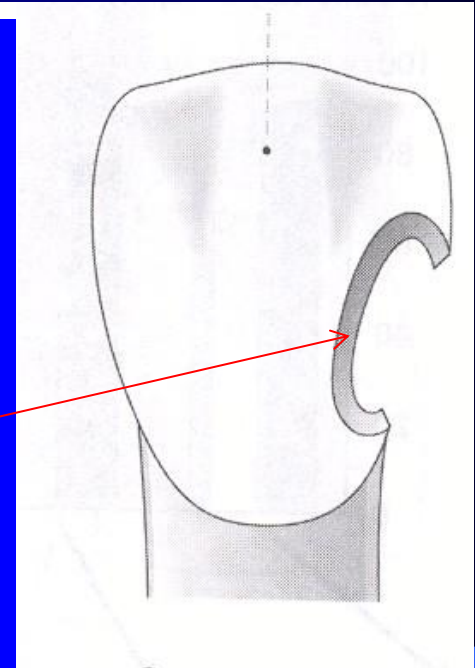
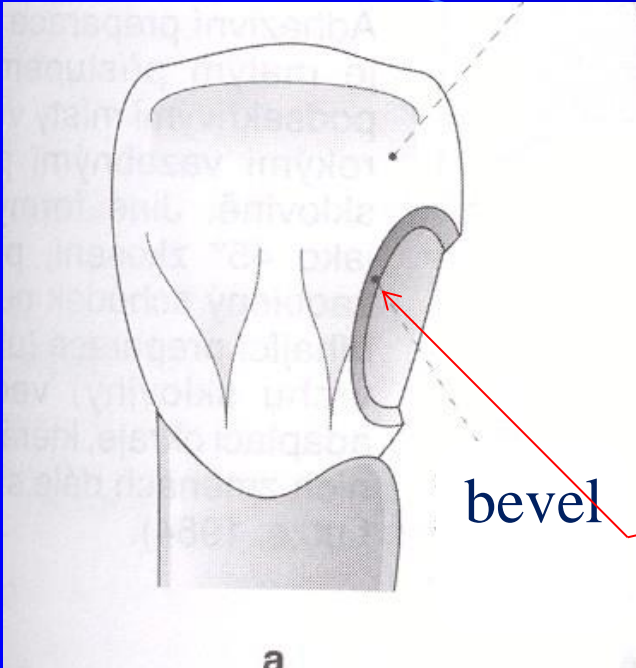
Cavosurface margin

- Cavity is limited on carious lesion only
- Margins must be beveled

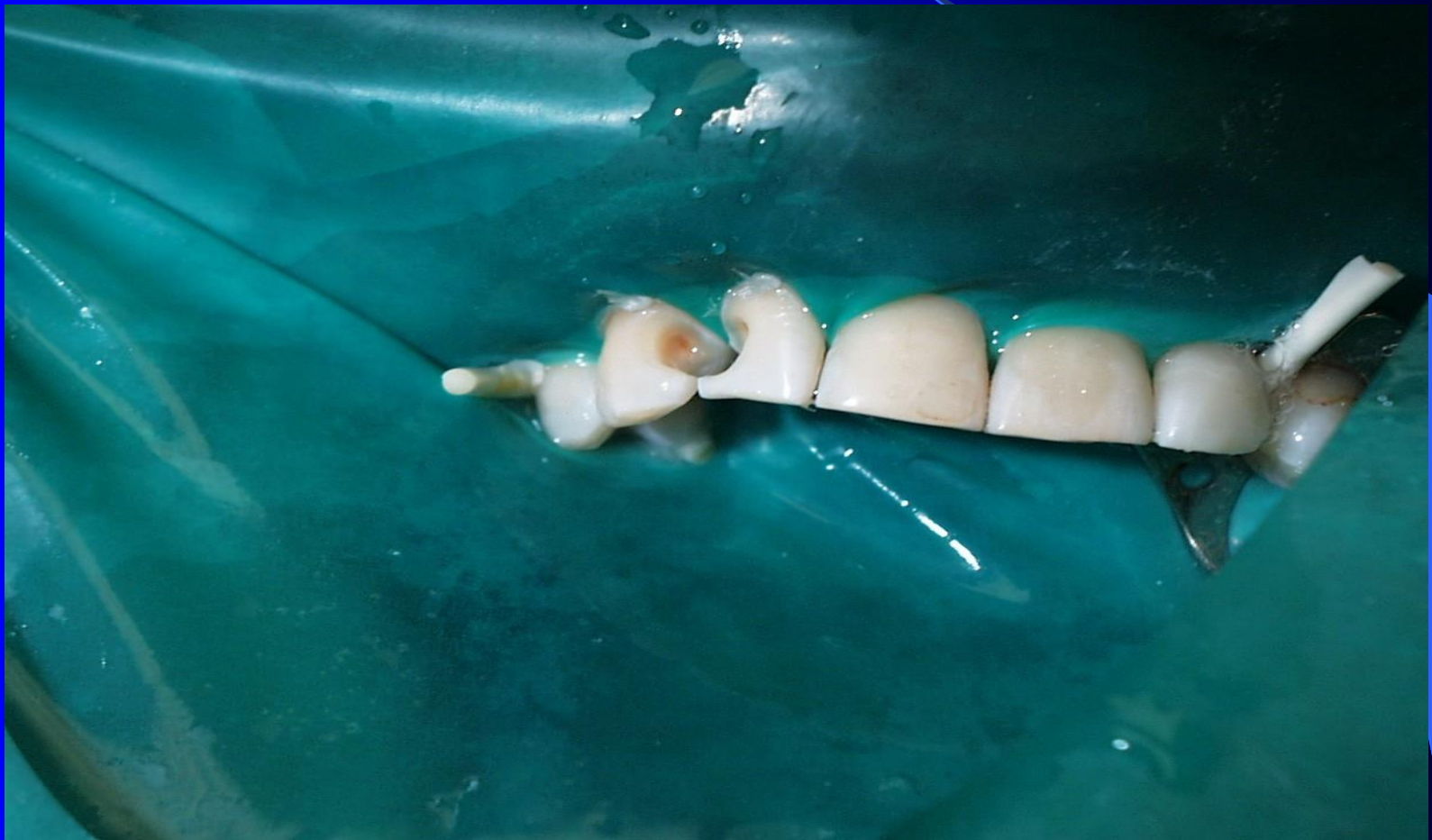

Retention

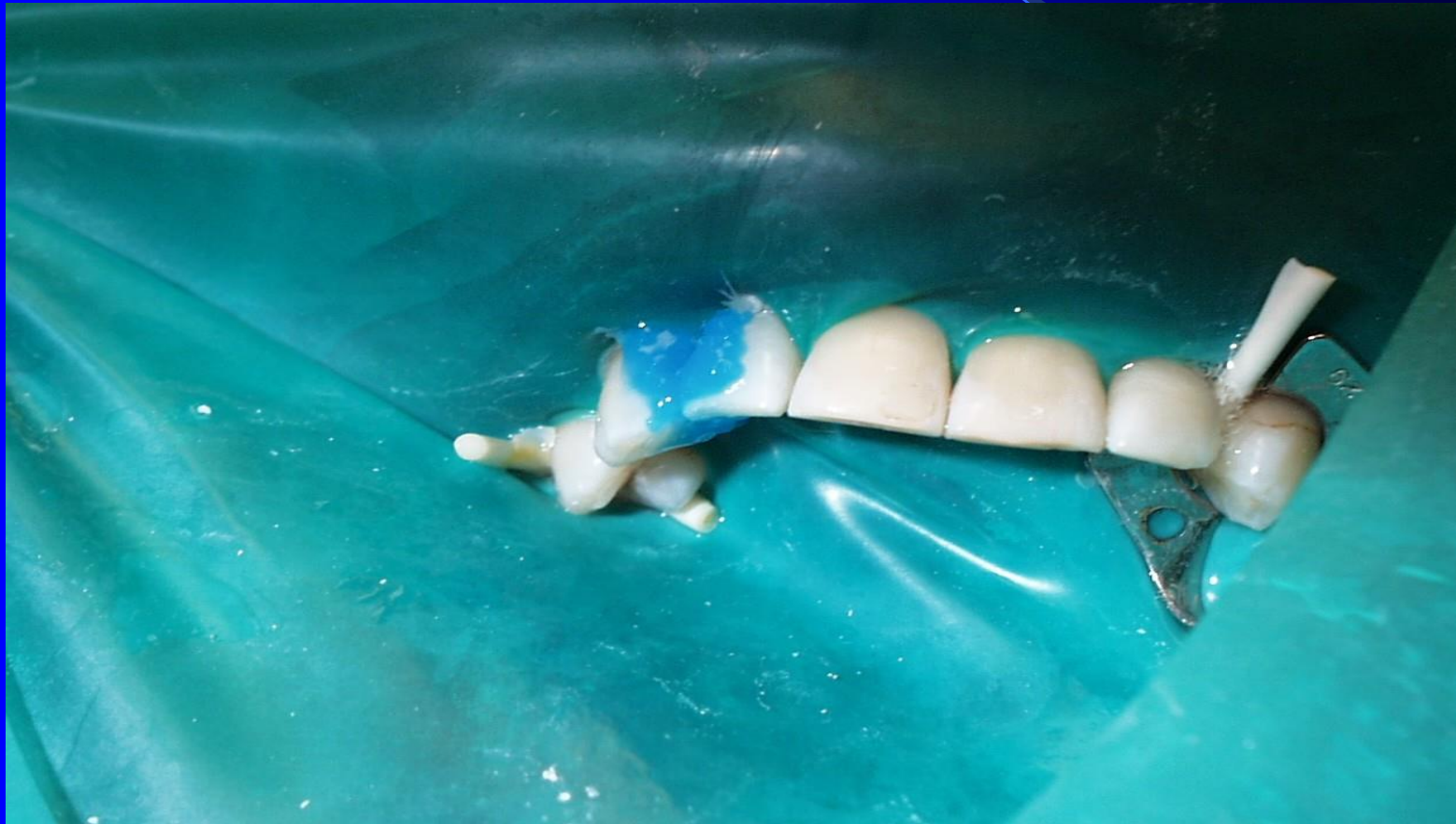- Margins must be beveled – micromechanical retention



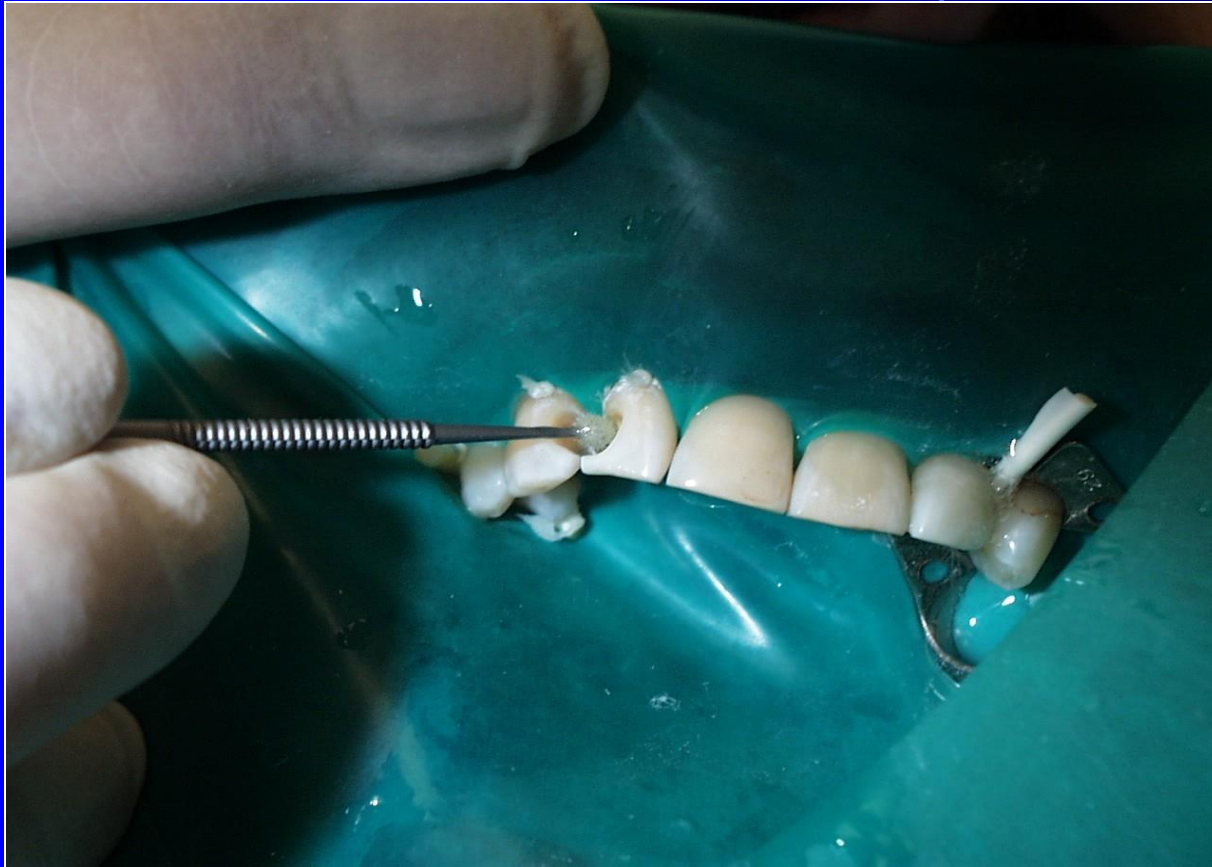Dry field!!!!



Etching of enamel and dentin




Bonding



Surface Morphology for Adhesion


➤ Enamel

- regular surface with opened inter/intraprismatic spaces

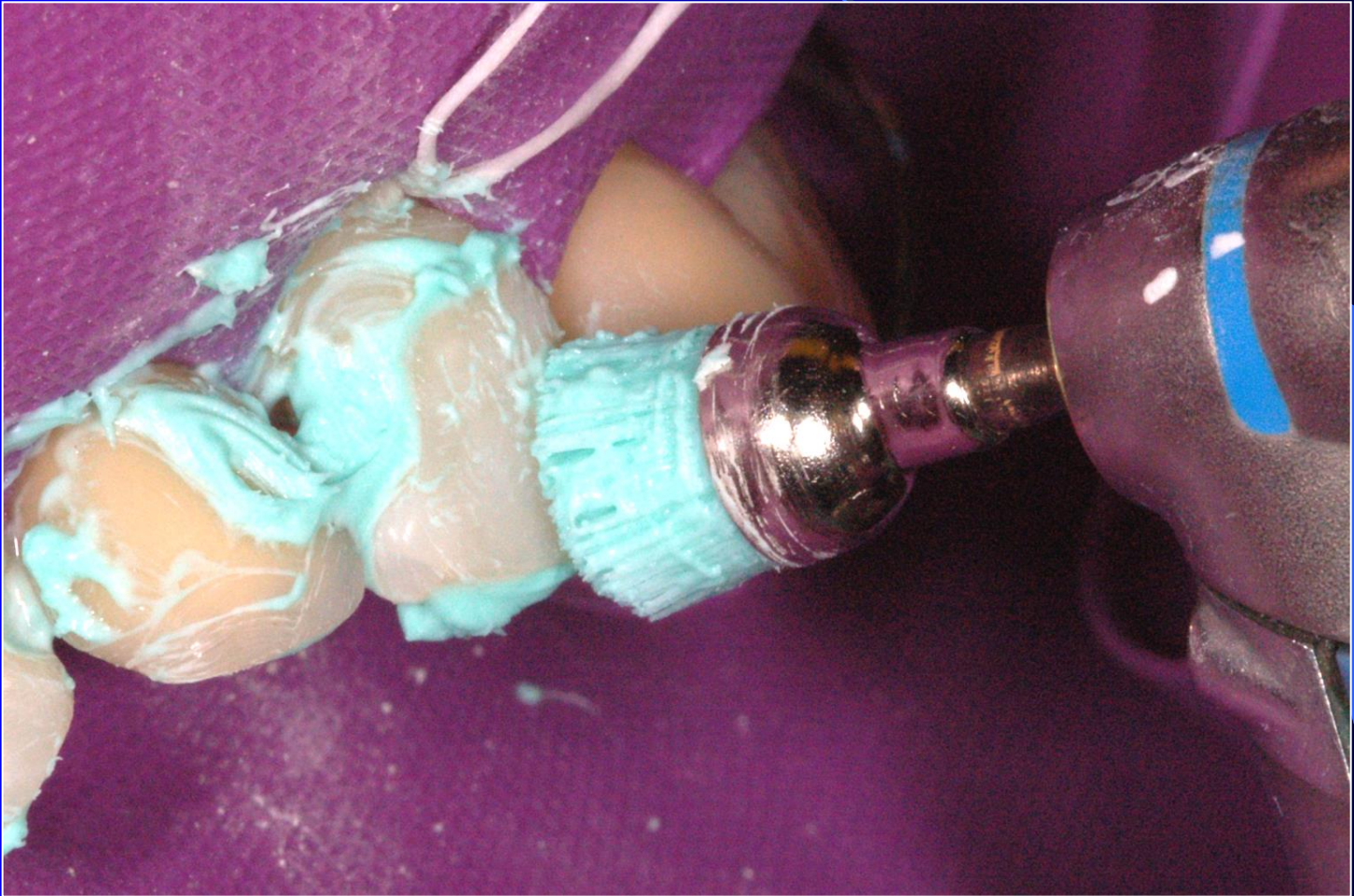

➤ Dentin

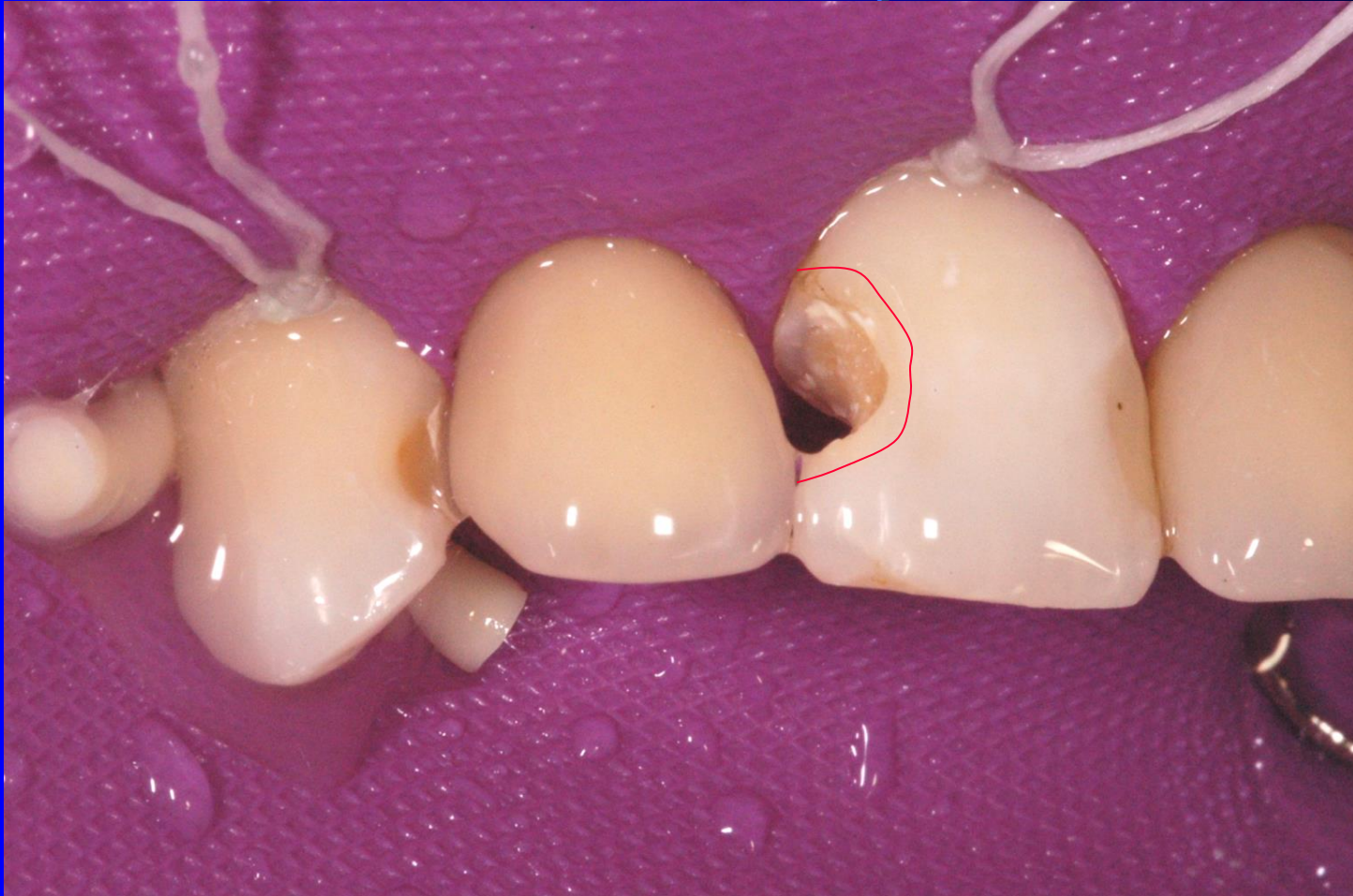- no smear layer
- opened dentinal tubules
- collagen with microscopic spaces (after etching)



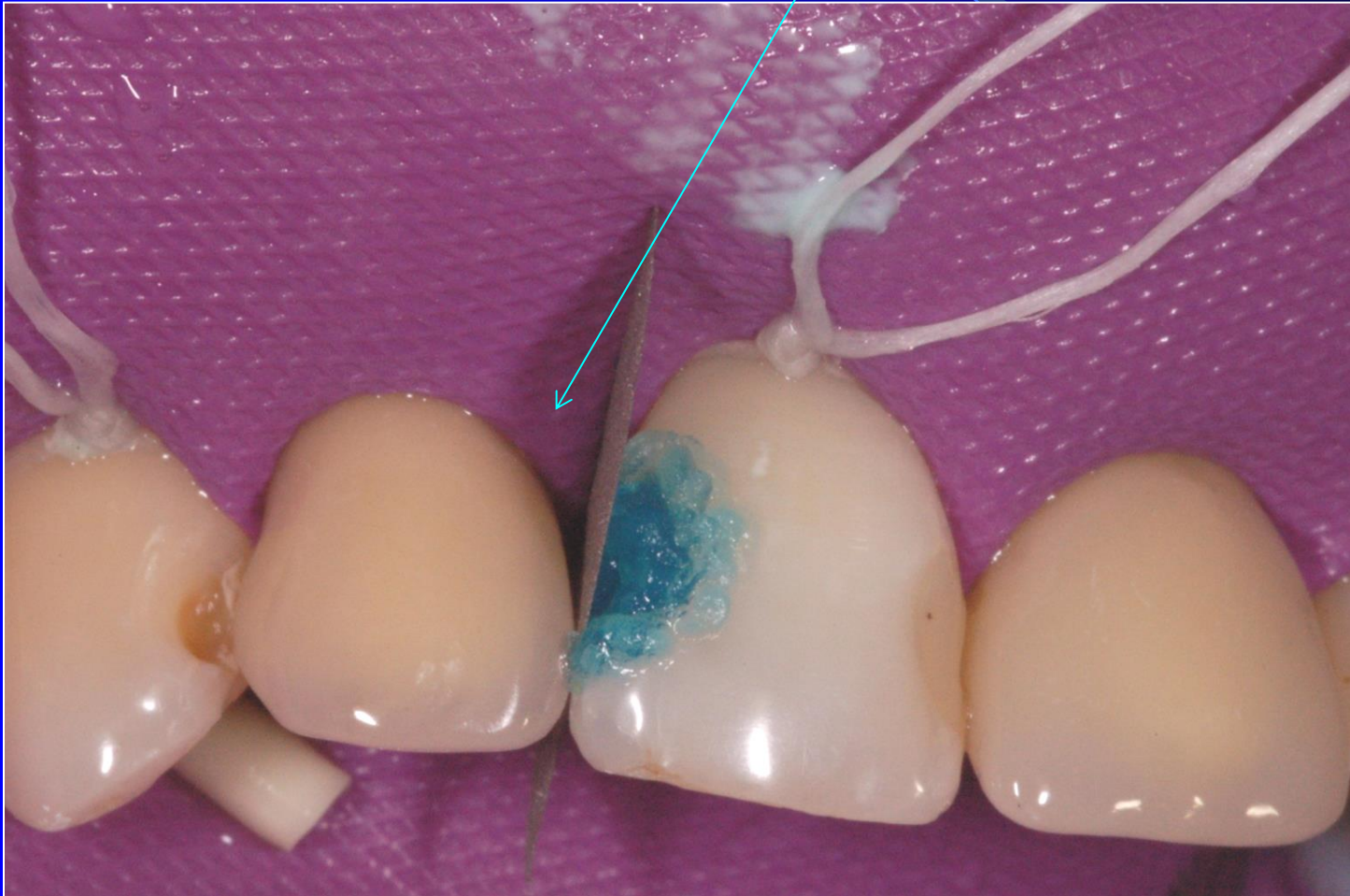Preparation



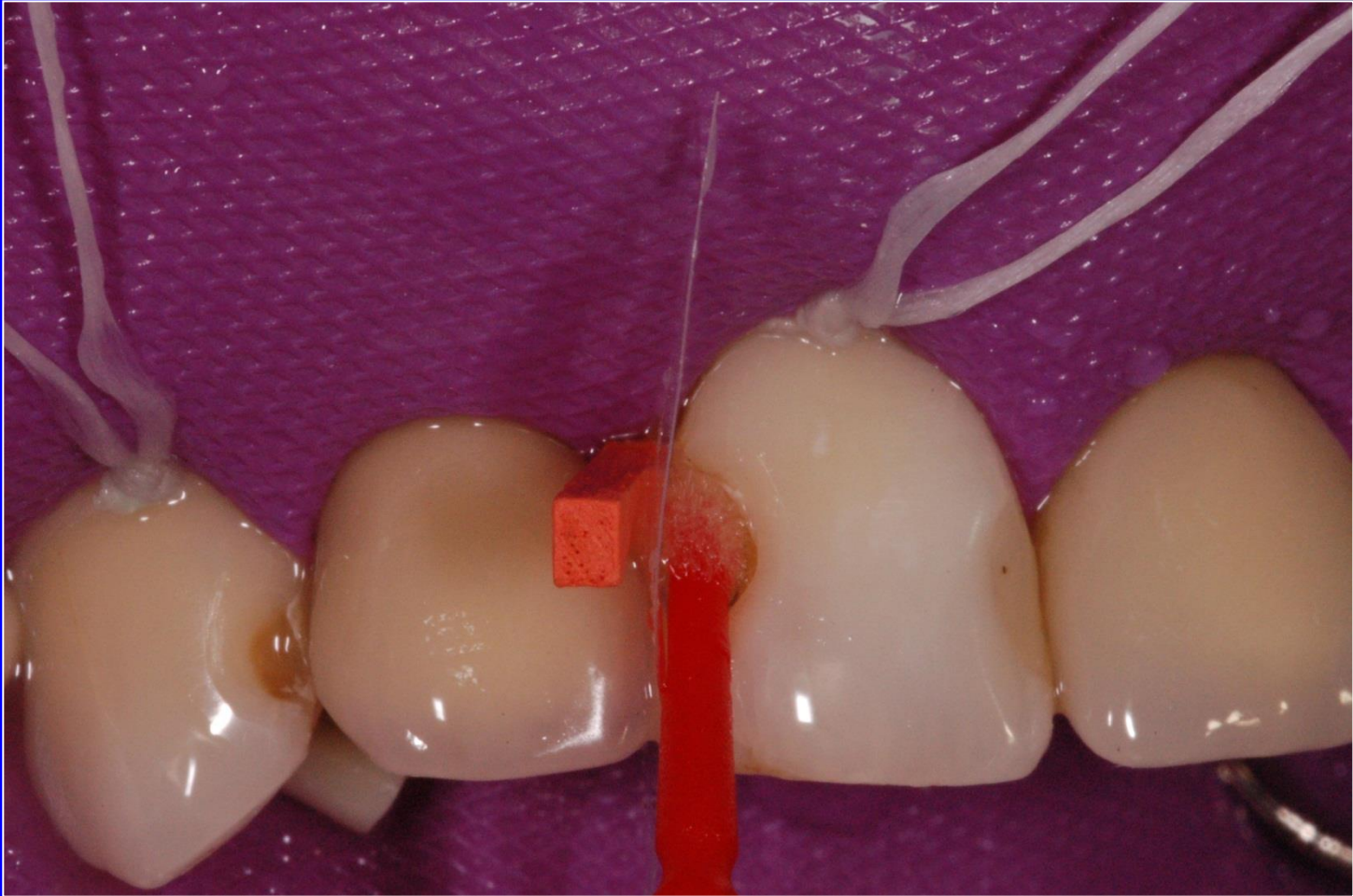Preparace kavity



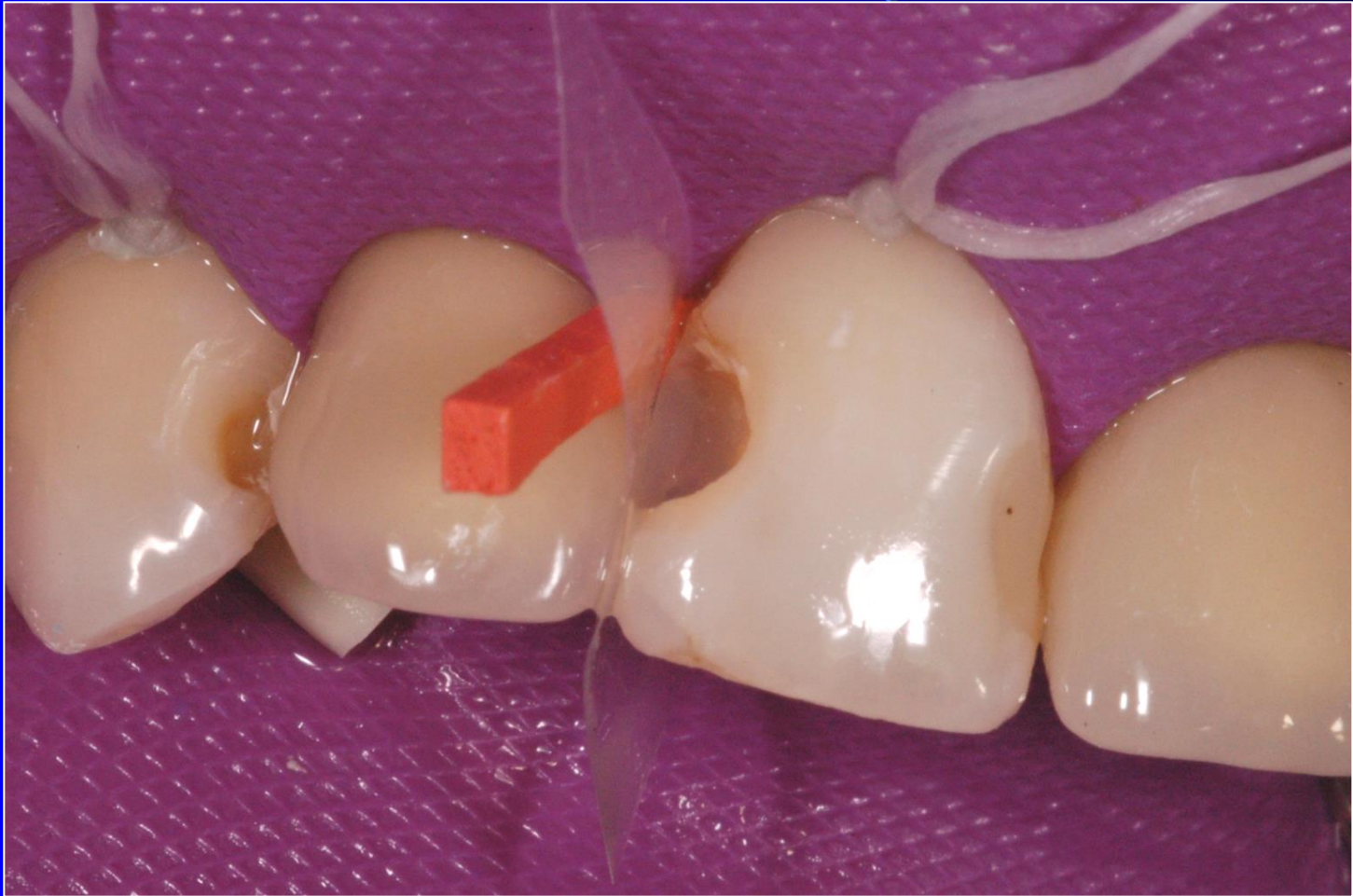Acid etching – protection of the tooth

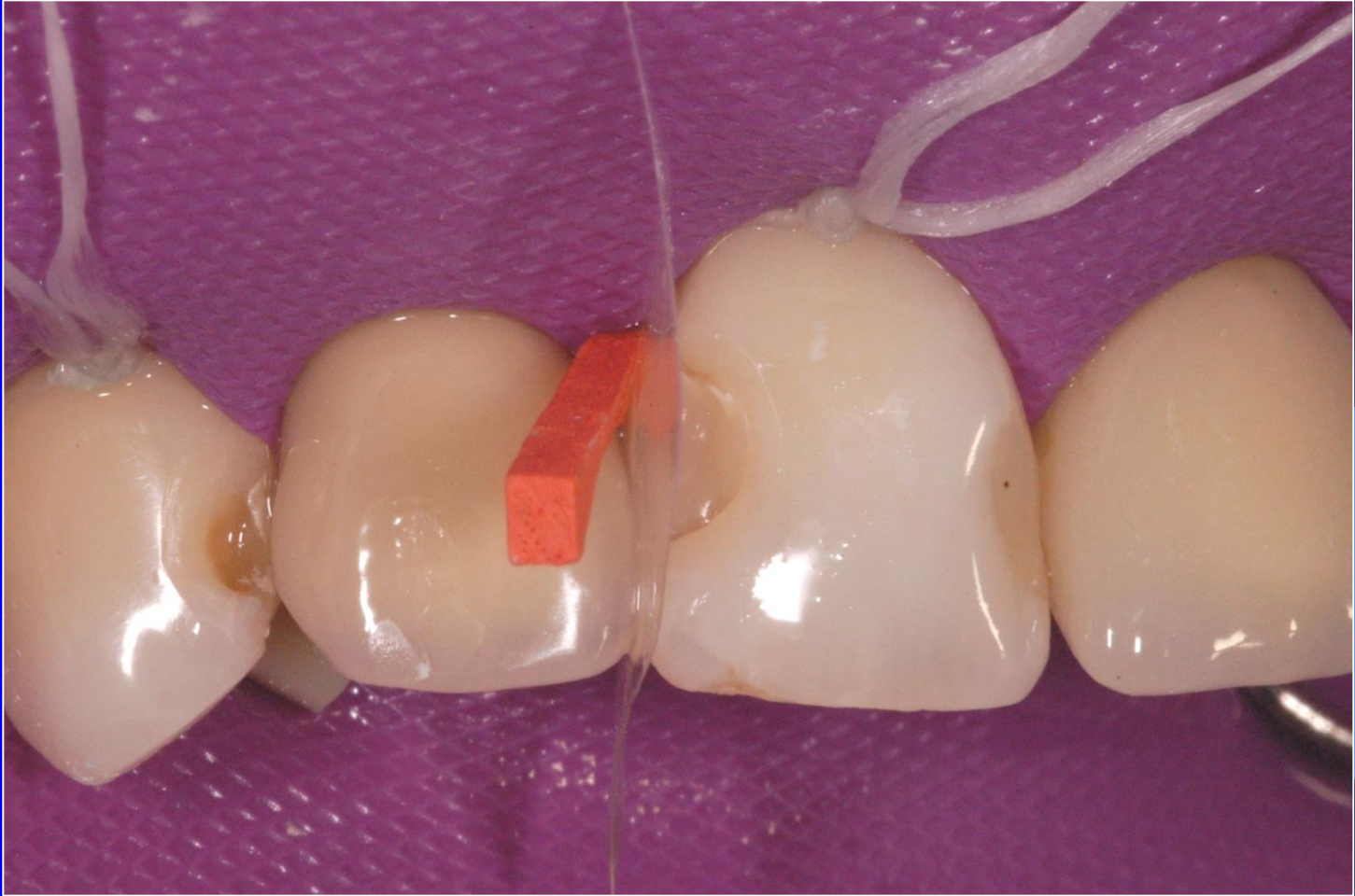

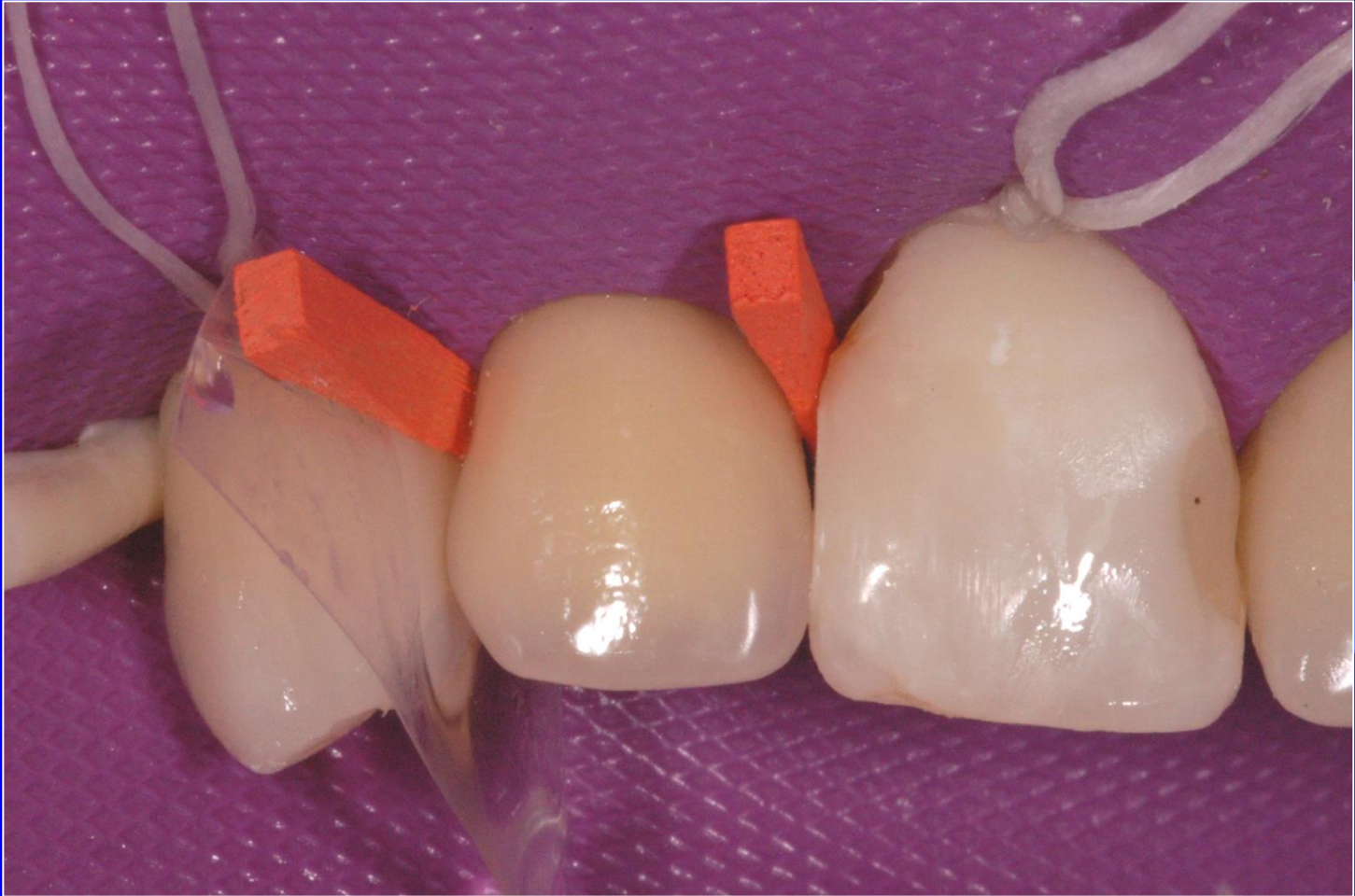Matrix and wedge, bonding



Palcement of the composite



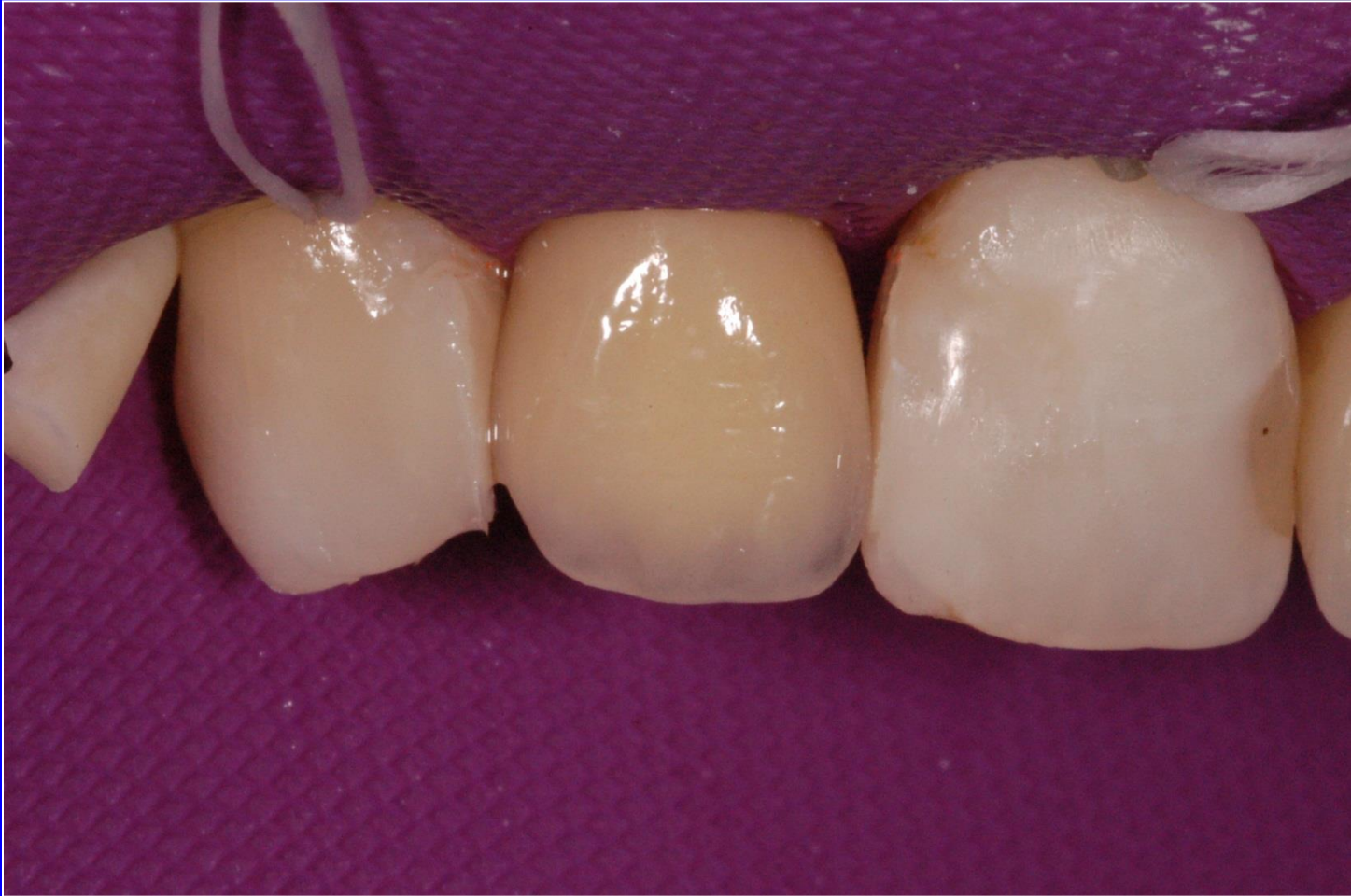



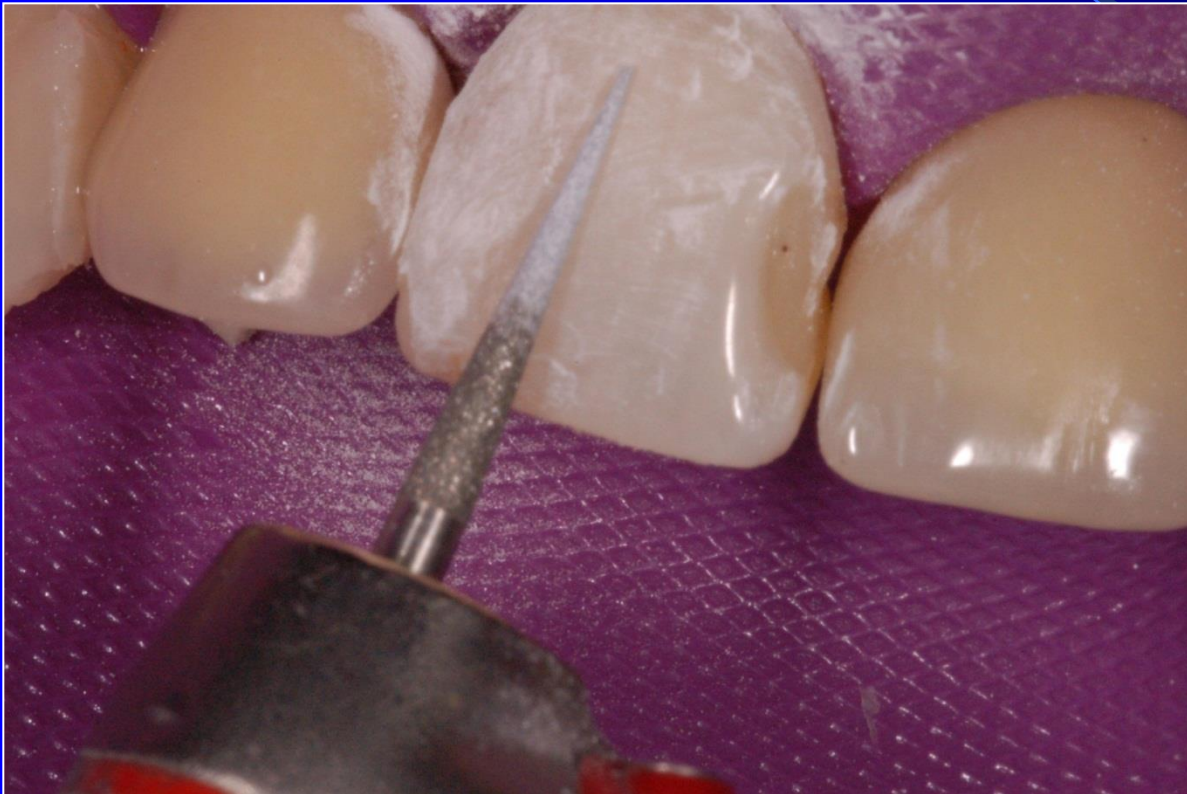Layering of the composite

- Palatal wall (matrix in situ) – enamel shade
- Dentin shade
- Enamel shade

Matrix has been removed

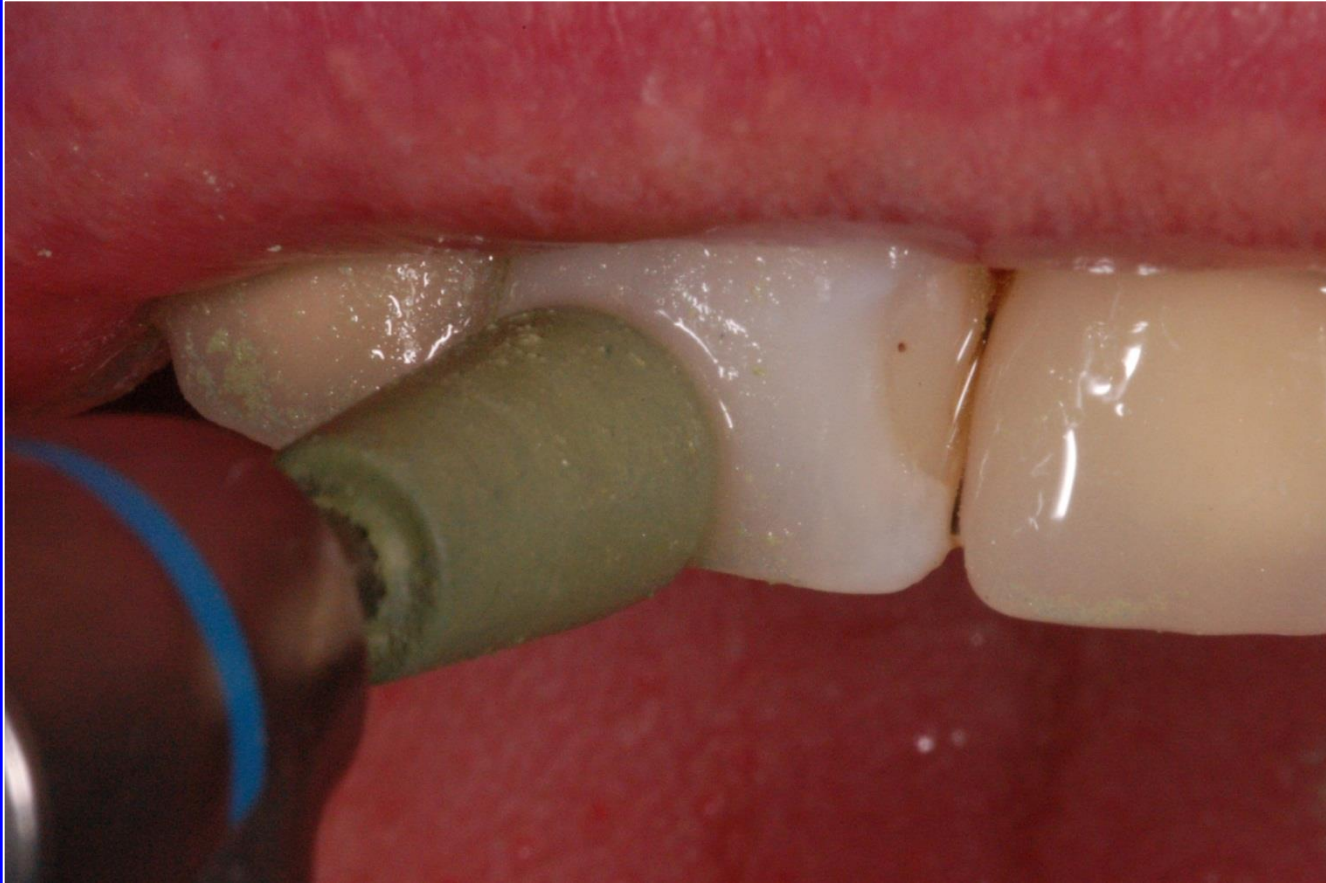

Finishing



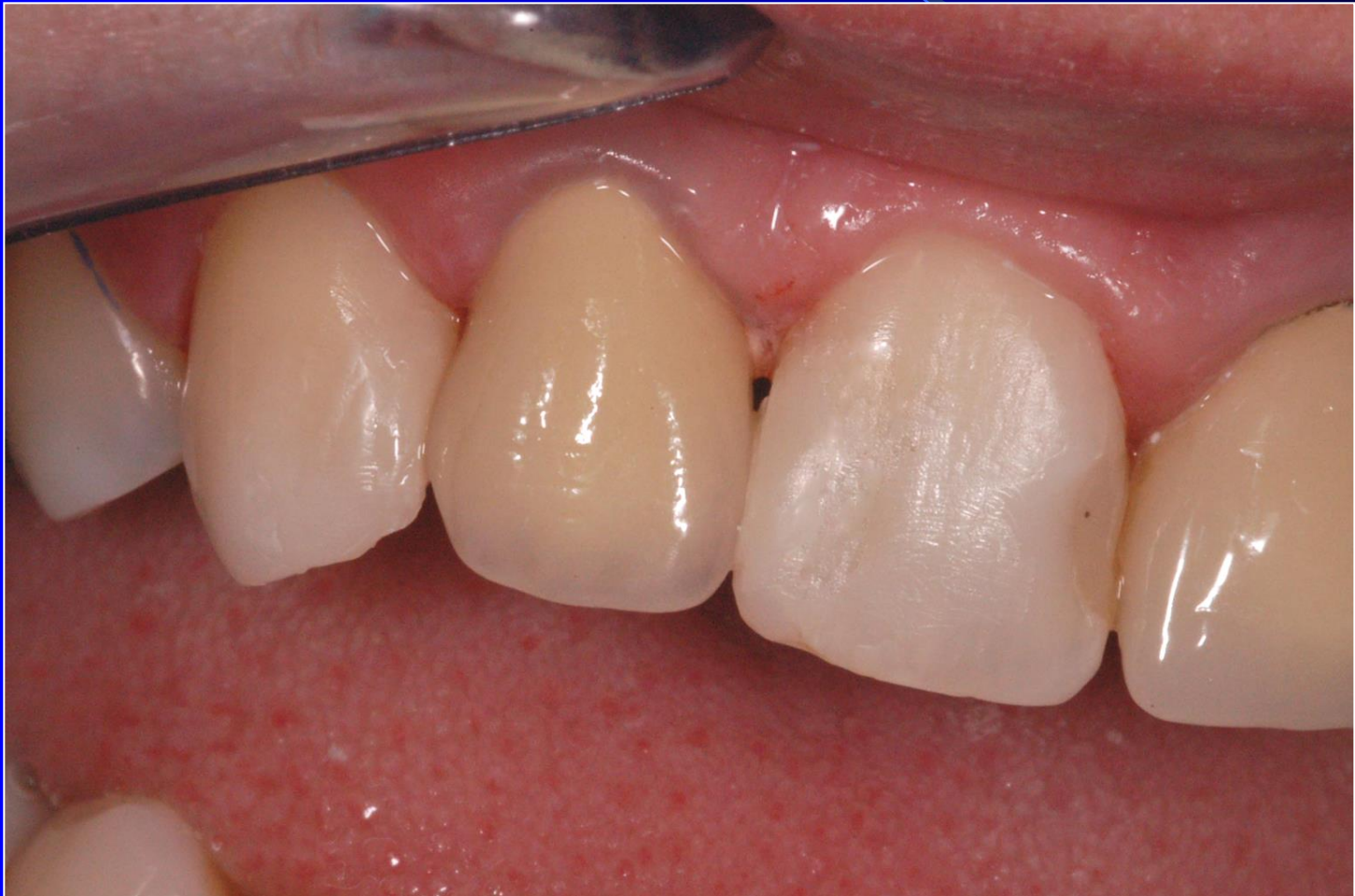Ultrafine diamonds.
Flexible discs


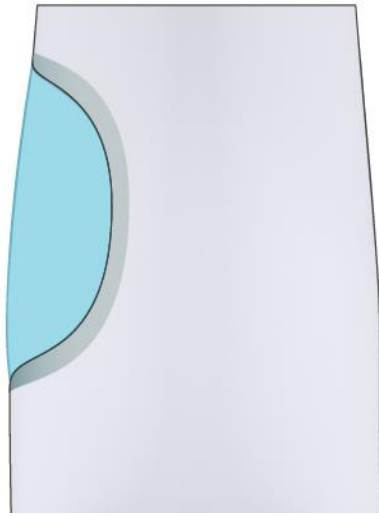
Polishing

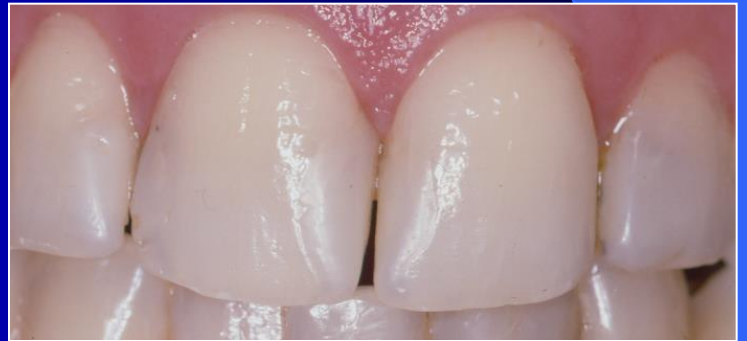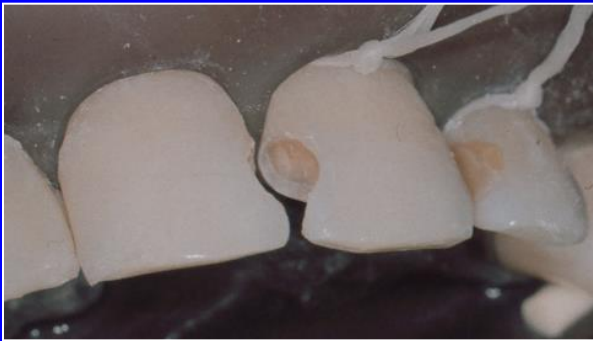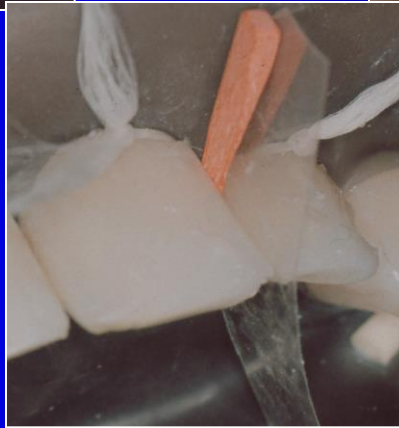


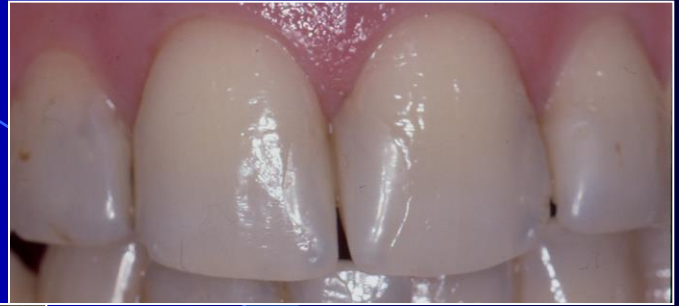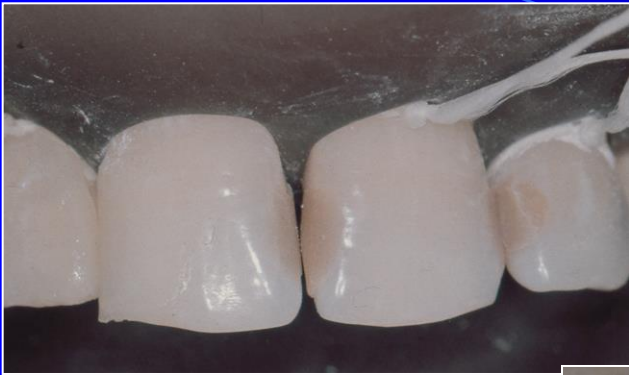Rubber cups,
brushes

Finished filling





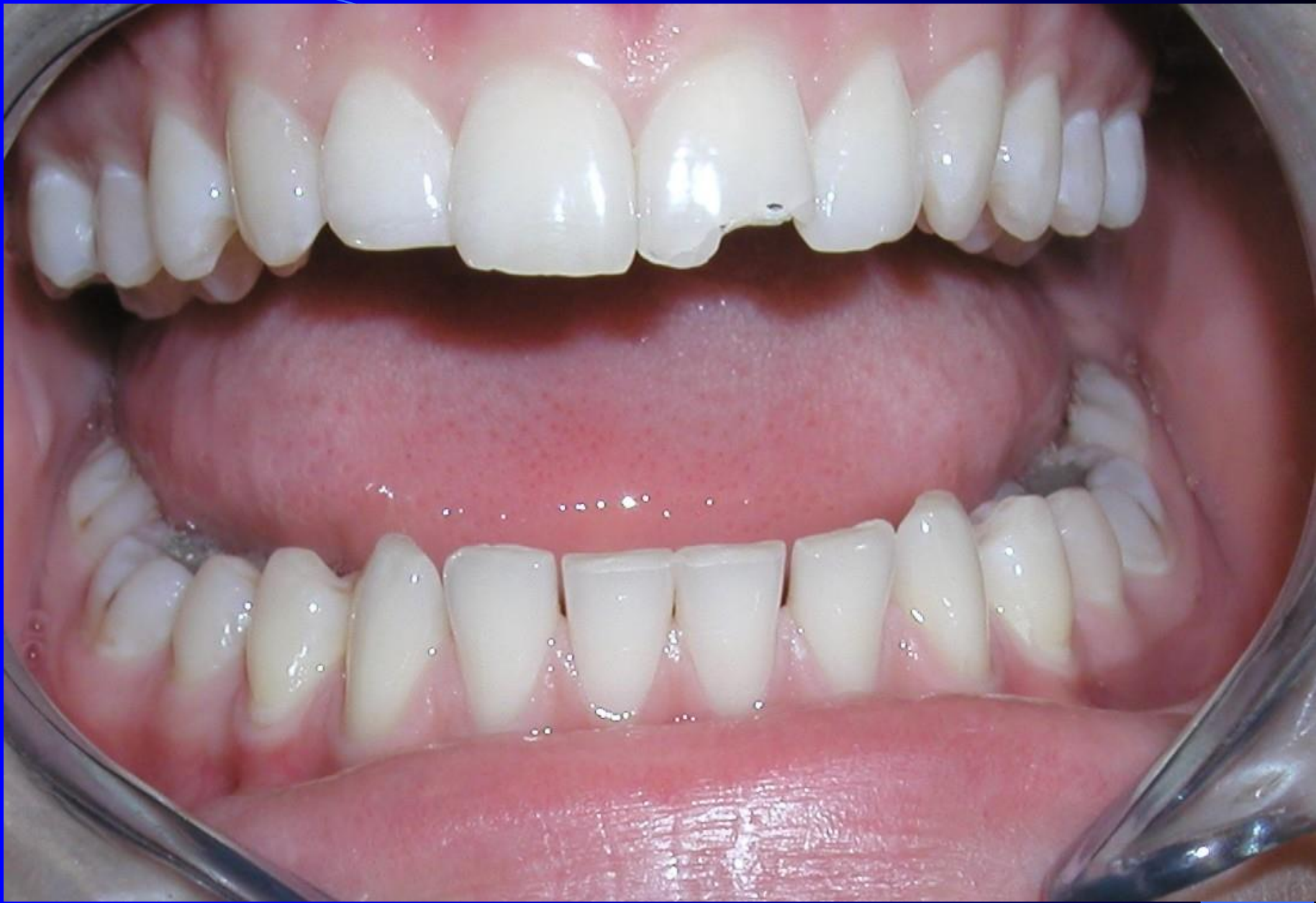

Class IV.

*Defects on proximal surfaces
premolars and molars with loss of
part or complete incisal edge*

Dental caries

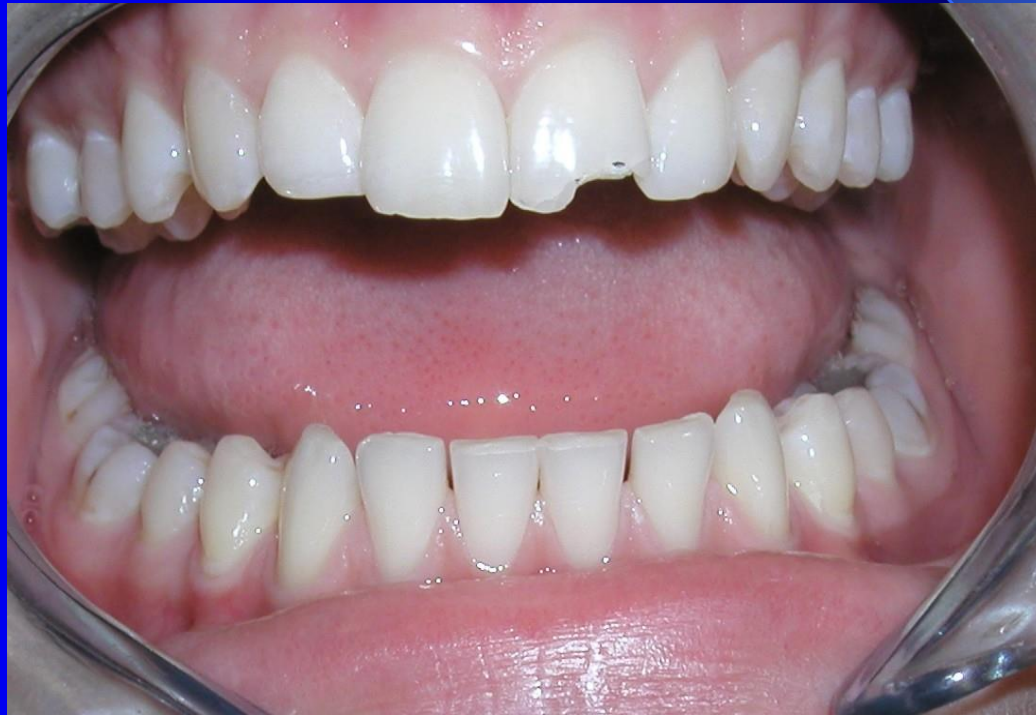Trauma



Access


Cavosurface margin

Preparation is limited on the defect



Compoiste is plastic material
of only choice



Enamel: micromechanical connection



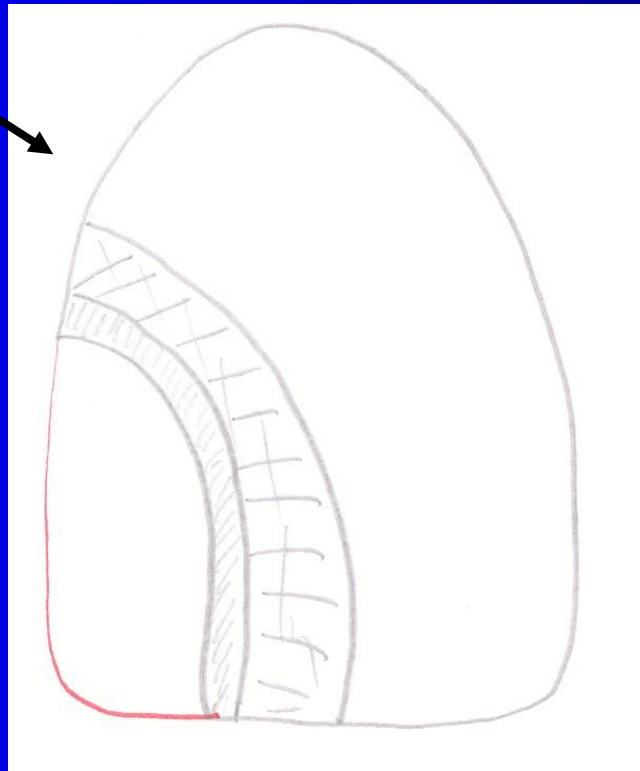

Dentin

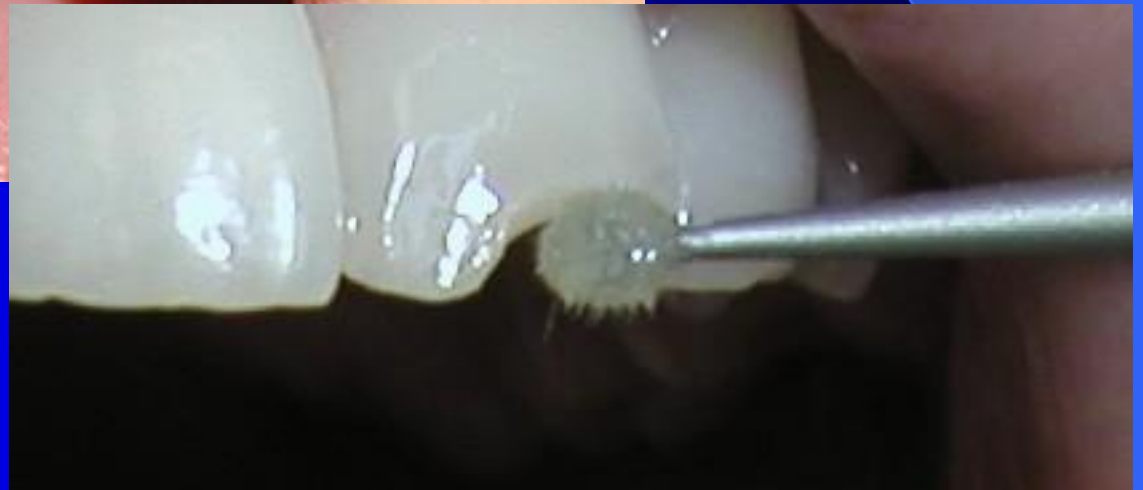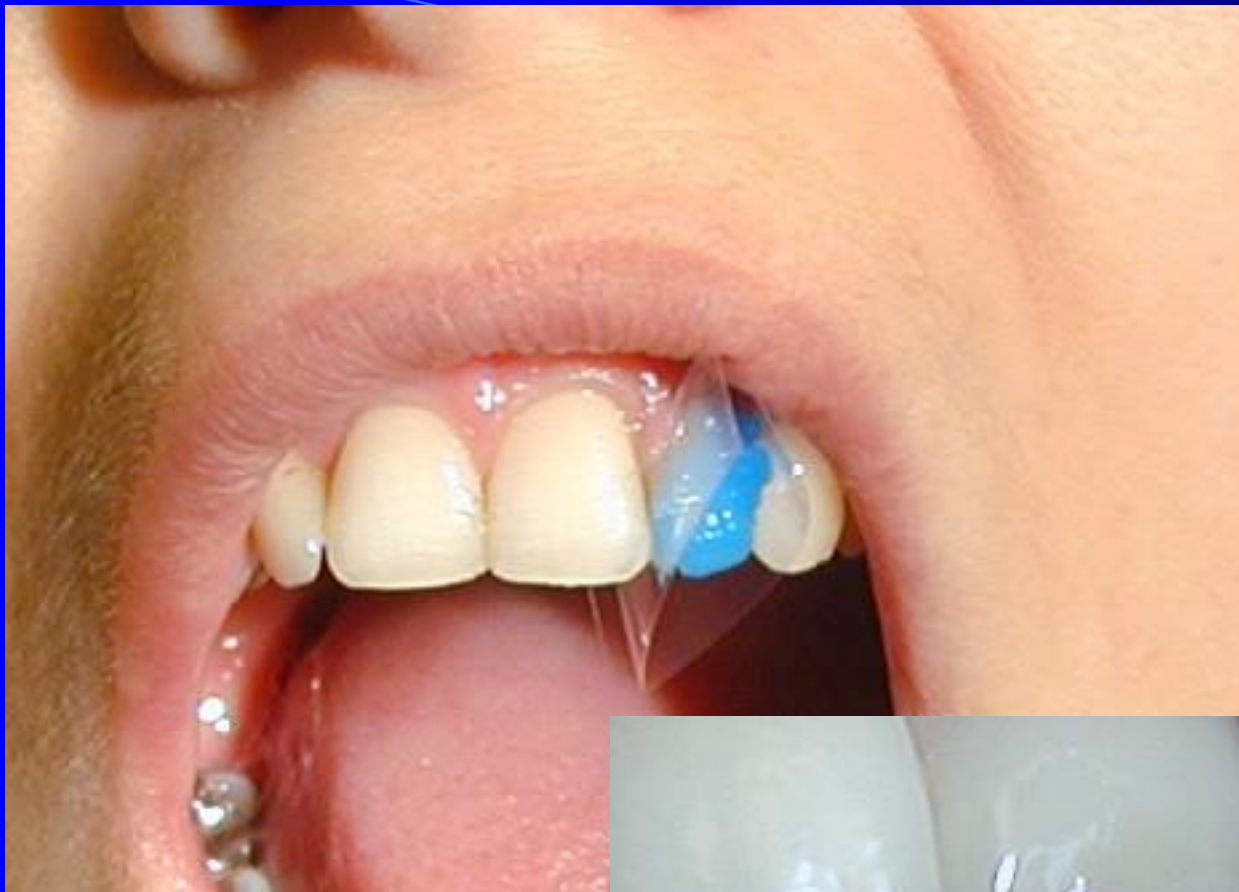Micromechanical connection

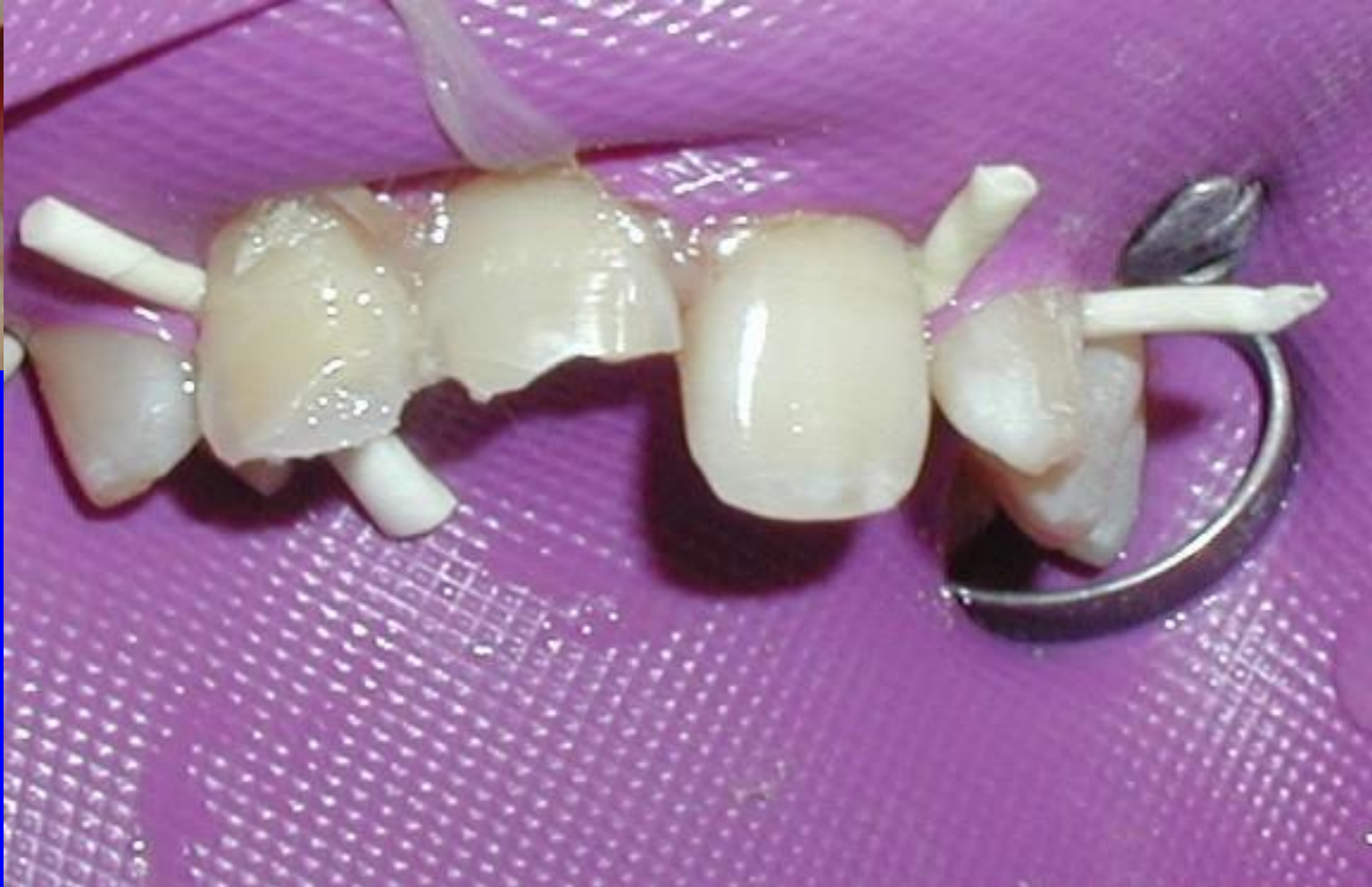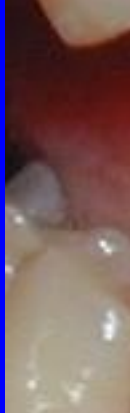
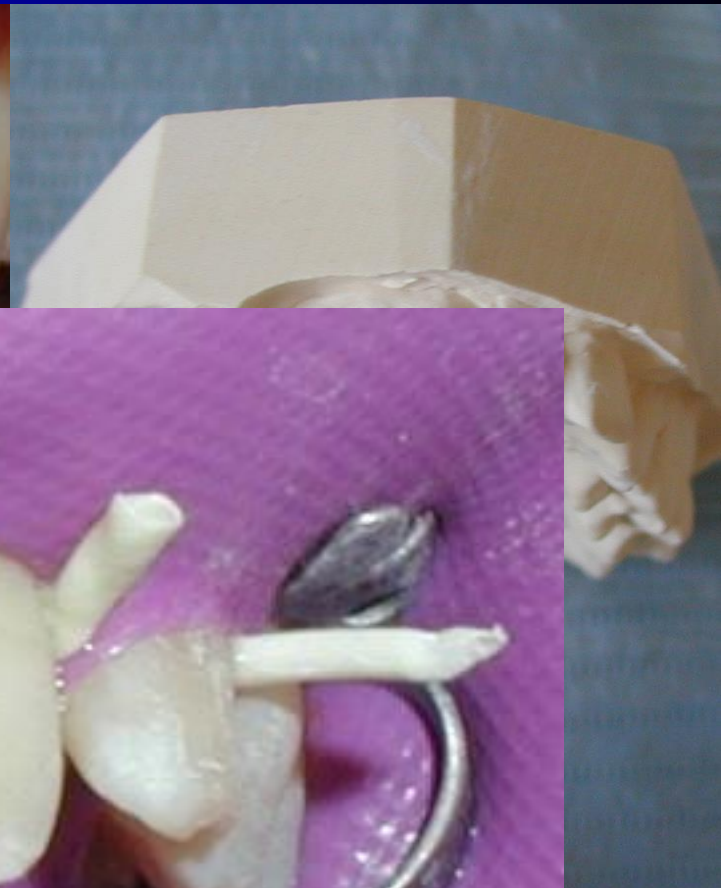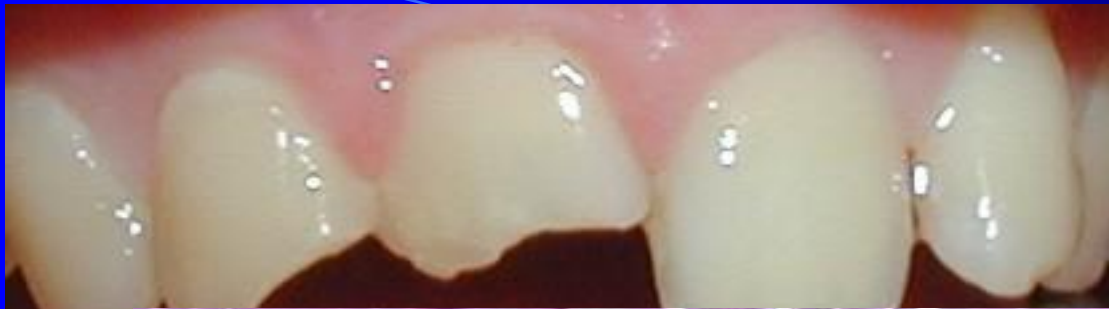Primer and
bond

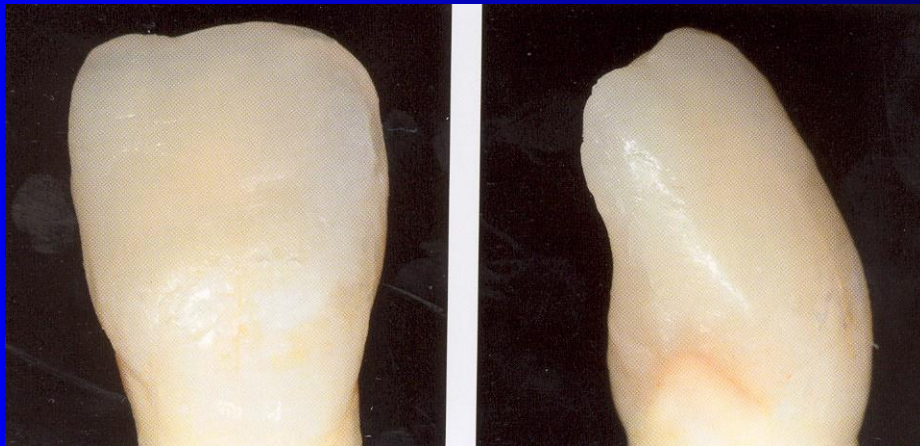
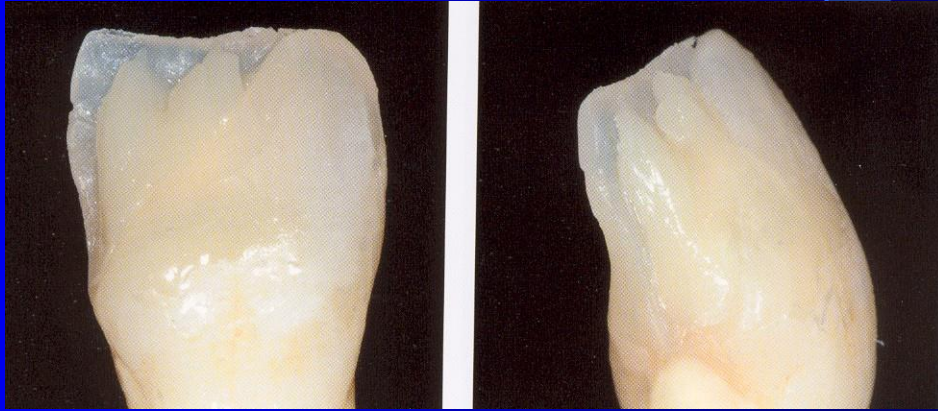
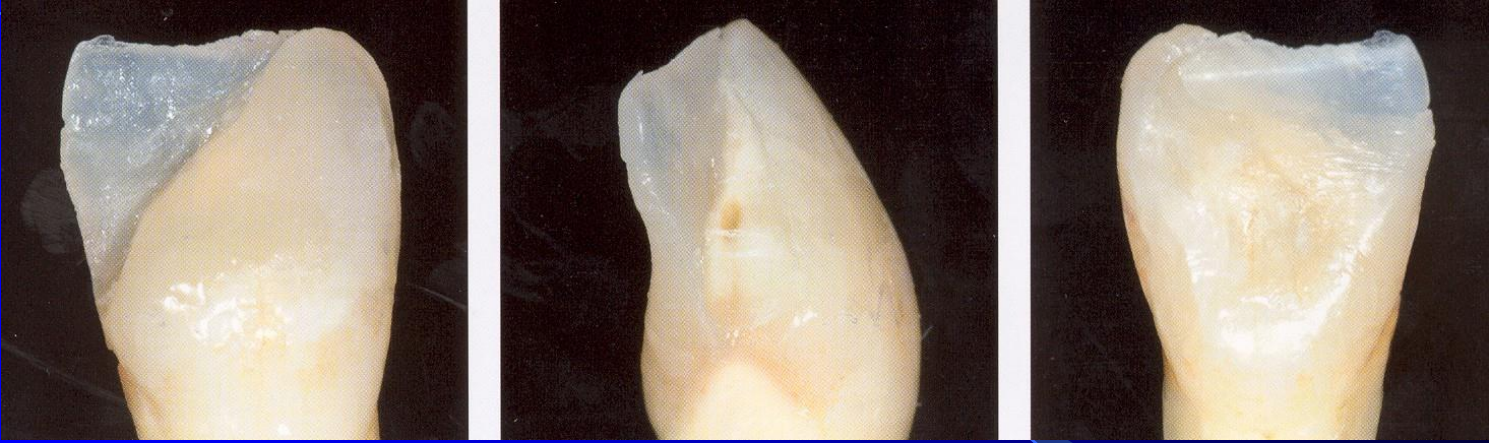

The enamel must be beveled

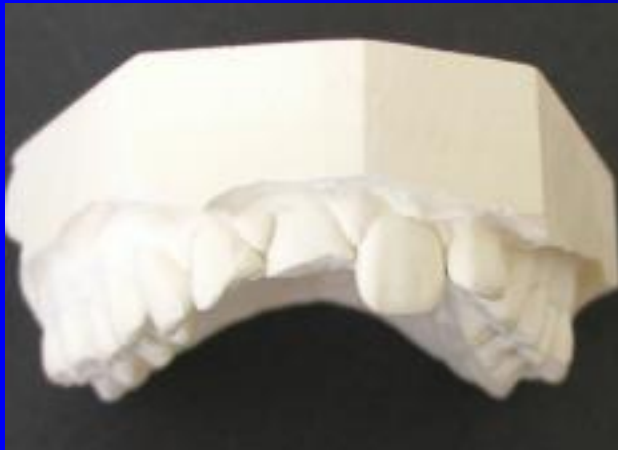




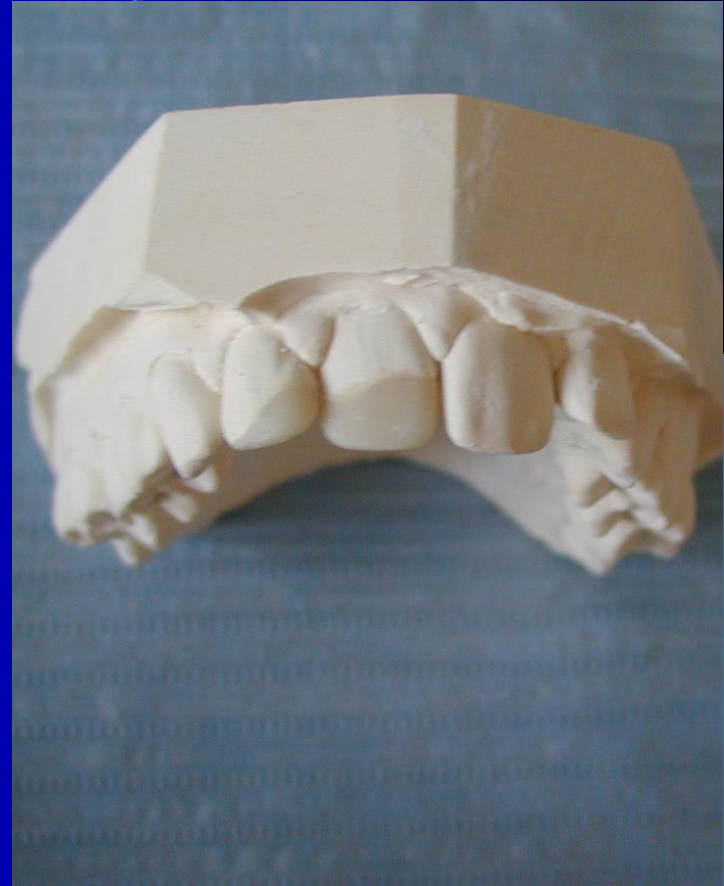


Silicone matrix



Oral surface



Incisal edge



















