

Onemocnění bělimy

Synek S.

KOO

Anatomické poznámky

- Episkléra
- Skléra
- Lamina fusca

Zánětlivá onemocnění skléry

- Episkleritis, ložiskové nebo difúzní, často bolestivé na tlak
- Skleritis, překrvení – hluboká injekce, bolestivé, u zadní skleritidy pak protruze bulbu, bolesti při pohybech oka
- Sklerokeratitidy- zánět přechází na rohovku- herpes viry, tbc, revmatismus, lepra, onchocerkóza

EPISCLERITIS AND SCLERITIS

1. Episcleritis

- Simple
- Nodular

2. Anterior scleritis

- Non-necrotizing diffuse
- Non-necrotizing nodular
- Necrotizing with inflammation
- Necrotizing without inflammation
(scleromalacia perforans)

3. Posterior scleritis


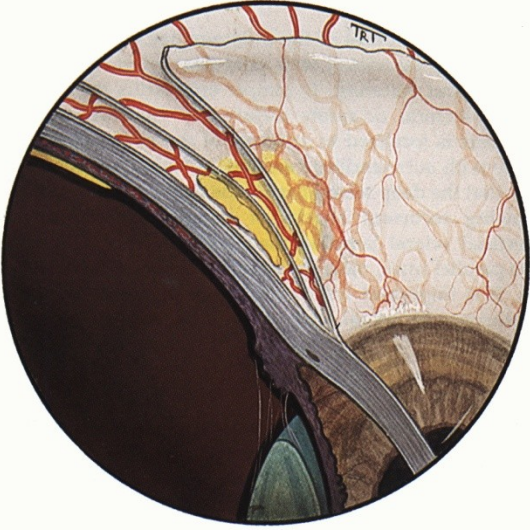
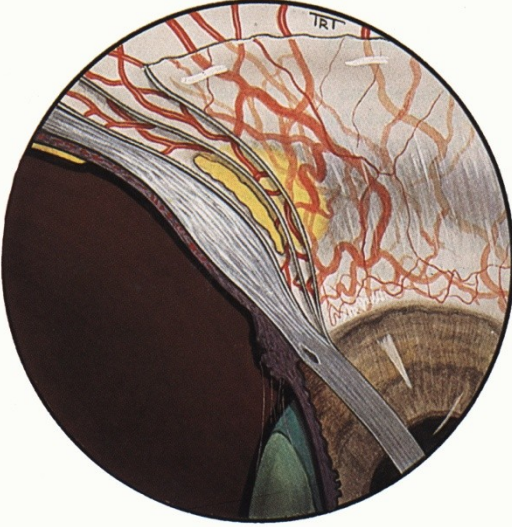
Etiologie

- Herpes zoster
- Choroby vaziva: rheumatoidní arthritida, lupus erythematoses, polyarteritis nodosa, Wegner`s granulomatosis
- Sarcoidosis, tuberculosis

Léčba

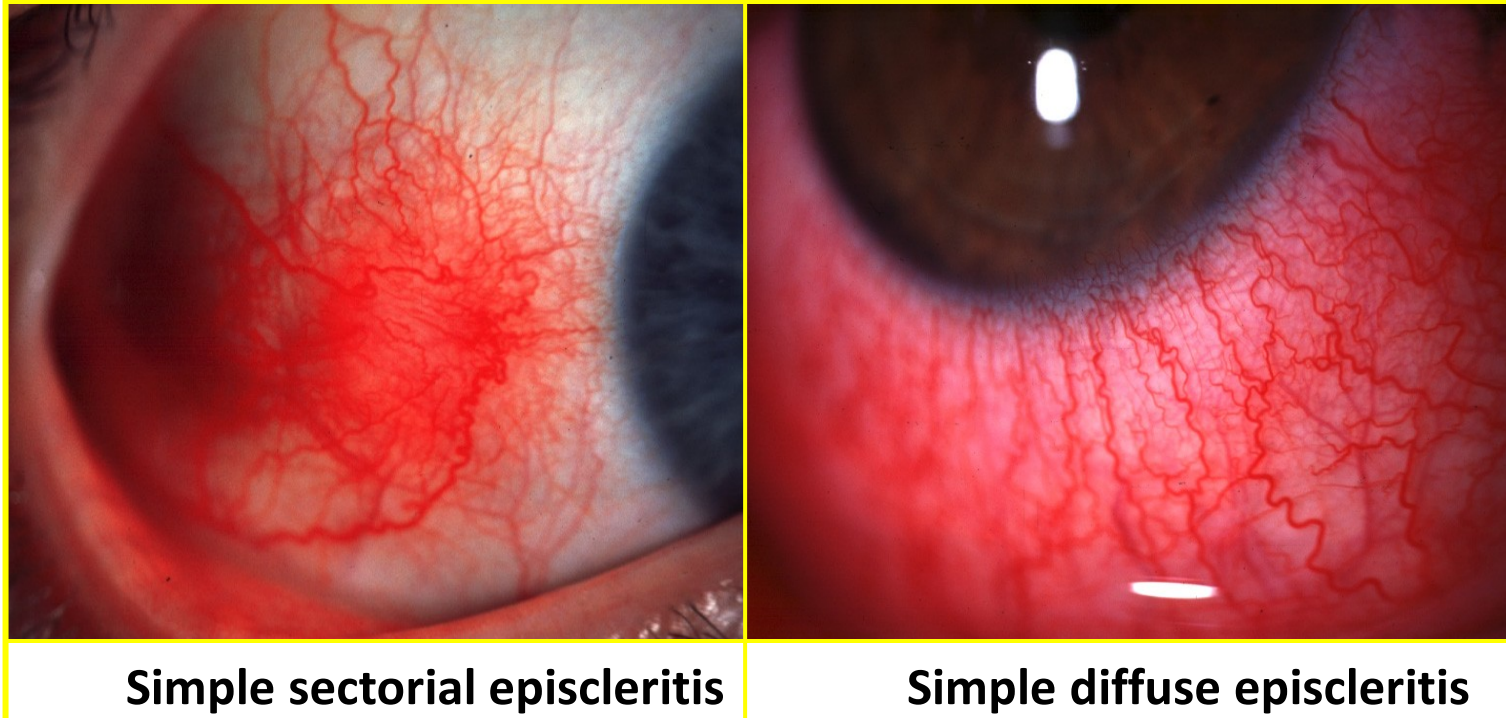
- Nesteroidní antiflogistika- indomethacin 100 mg for 4 days, celkkově prednisolone 60 / 80 mg, imunosupresiva
- Specifická léčba antituberculostatika

Applied anatomy of vascular coats

Normal	Episcleritis	Scleritis
 A circular cross-section diagram of the eye showing the normal vascular anatomy. The sclera is the outermost layer, followed by the episclera. Radial superficial episcleral vessels are shown as thin red lines. A deep vascular plexus is located adjacent to the sclera. The iris and lens are visible in the lower part of the diagram. The name 'TARRANT' is visible at the top of the diagram.	 A circular cross-section diagram of the eye showing episcleritis. The radial superficial episcleral vessels are significantly dilated and congested, appearing as thick, bright red lines. The deep vascular plexus is also visible. The iris and lens are visible in the lower part of the diagram. The name 'TARRANT' is visible at the top of the diagram.	 A circular cross-section diagram of the eye showing scleritis. The deep vascular plexus is highly congested, appearing as a dense network of thick, bright red vessels. The radial superficial episcleral vessels are also slightly congested. The iris and lens are visible in the lower part of the diagram. The name 'TARRANT' is visible at the top of the diagram.
<ul style="list-style-type: none">• Radial superficial episcleral vessels• Deep vascular plexus adjacent to sclera	<ul style="list-style-type: none">• Maximal congestion of episcleral vessels	<ul style="list-style-type: none">• Maximal congestion of deep vascular plexus• Slight congestion of episcleral vessels

Simple episcleritis

- Common, benign, self-limiting but frequently recurrent
- Typically affects young adults
- Seldom associated with a systemic disorder

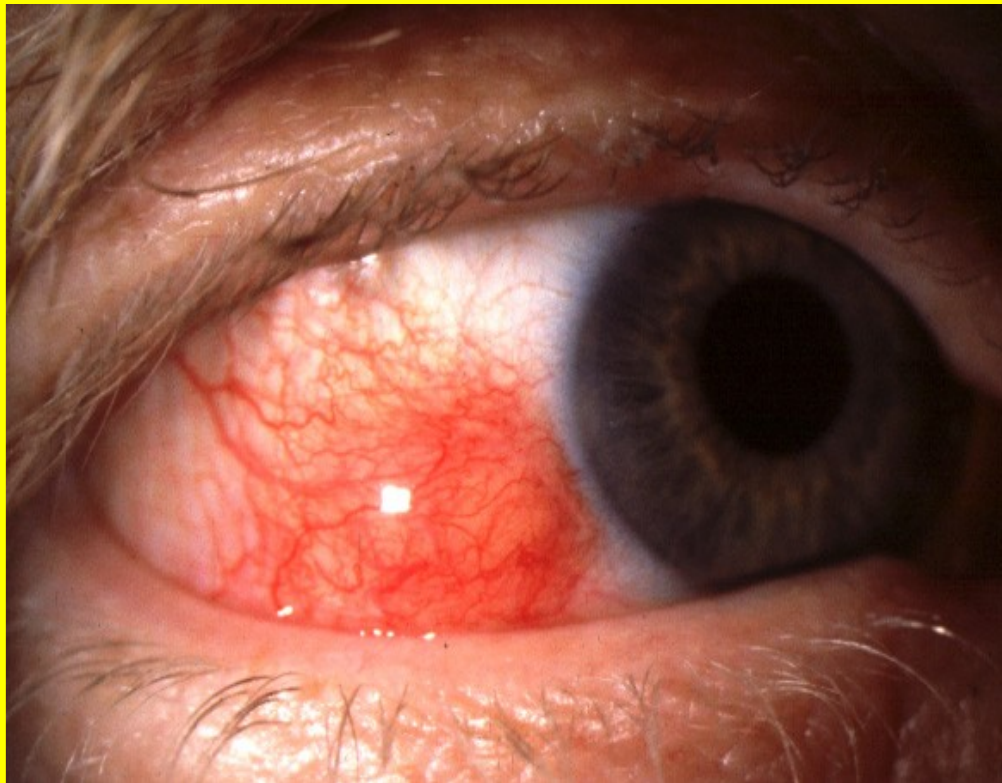

Treatment

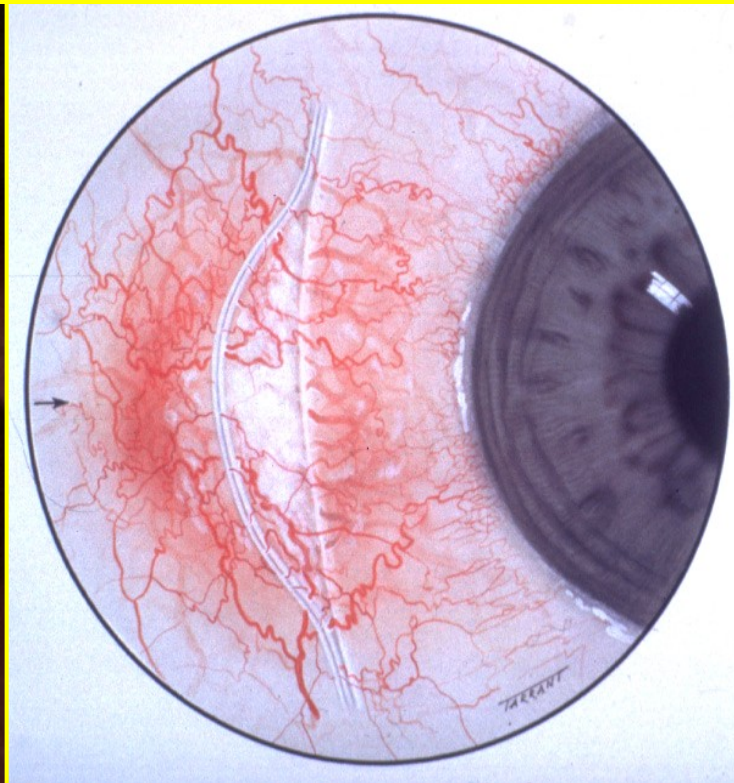
- Topical steroids
- Systemic flurbiprofen (00 mg tid if unresponsive

Nodular episcleritis

- Less common than simple episcleritis
- May take longer to resolve
- Treatment - similar to simple episcleritis



Localized nodule which can be moved over sclera



Deep scleral part of slit-beam not displaced

Causes and Systemic Associations of Scleritis

1. Rheumatoid arthritis

2. Connective tissue disorders

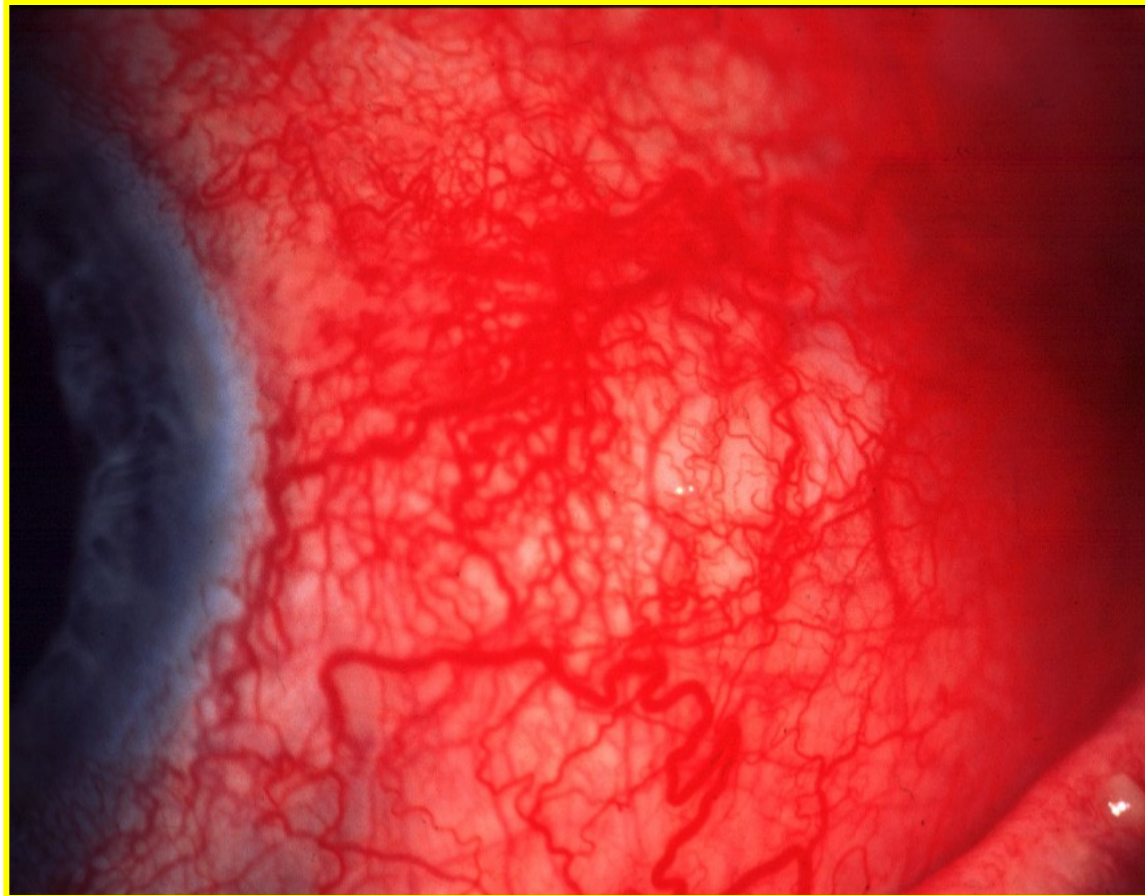
- Wegener granulomatosis
- Polyteritis nodosa
- Systemic lupus erythematosus

3. Miscellaneous

- Relapsing polychondritis
- Herpes zoster ophthalmicus
- Surgically induced

Diffuse anterior non-necrotizing scleritis

- Relatively benign - does not progress to necrosis
- Widespread scleral and episcleral injection

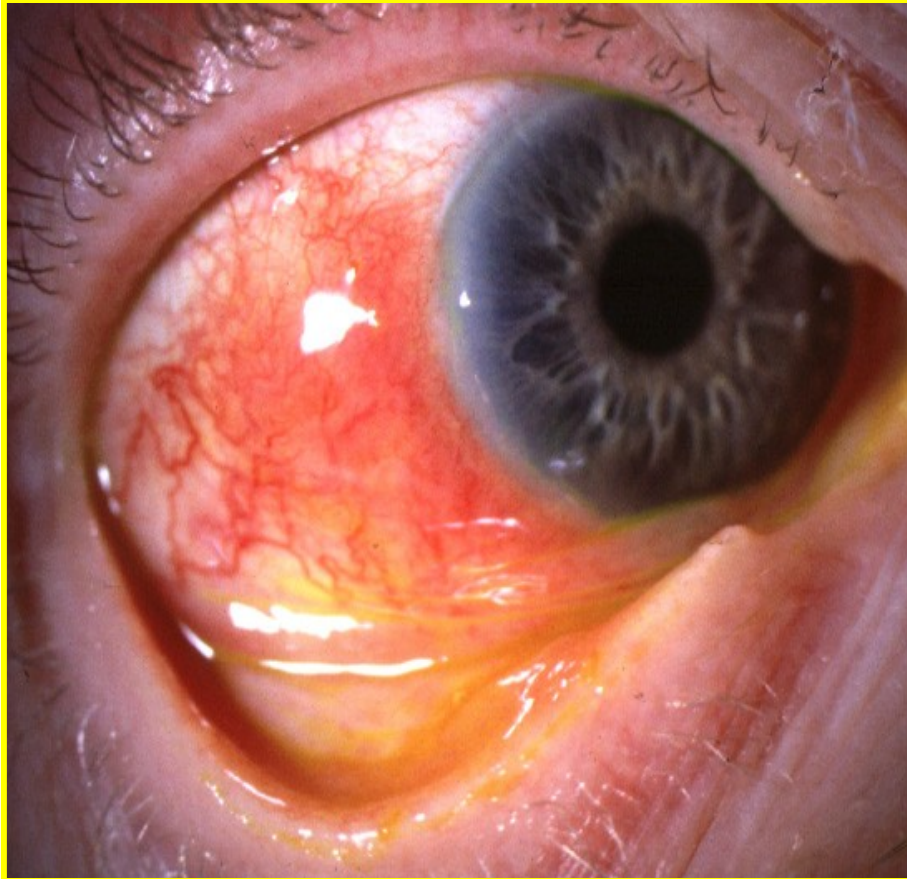


Treatment

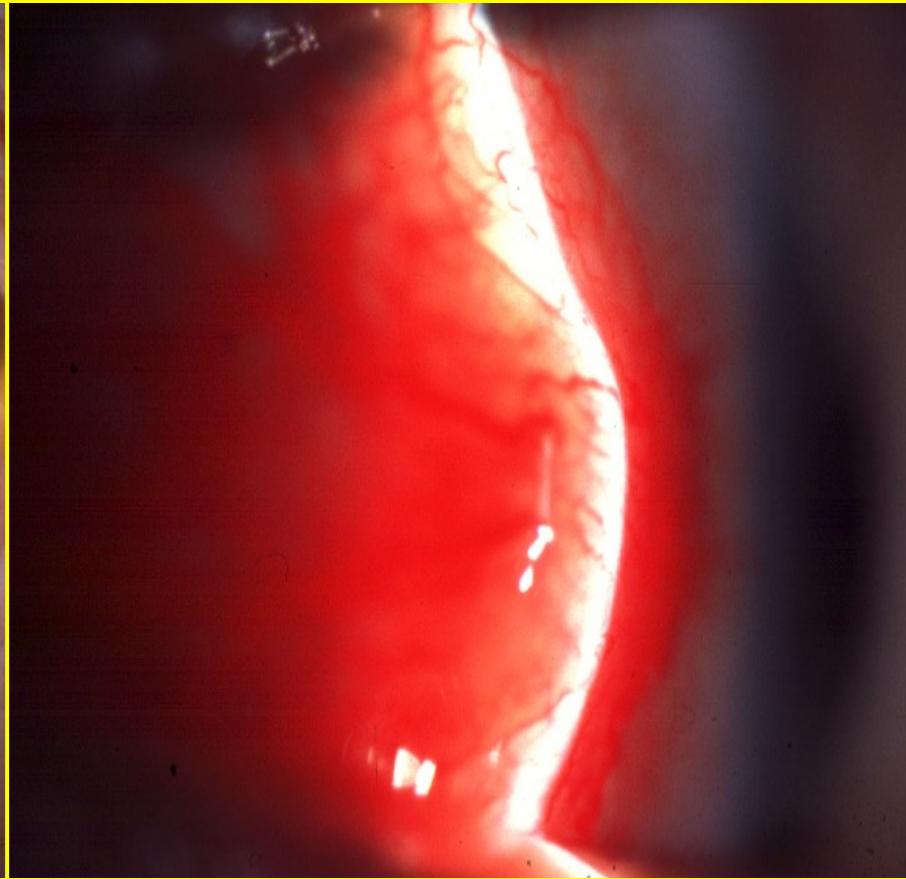
- Oral NSAIDs
- Oral steroids if unresponsive

Nodular anterior non-necrotizing scleritis

More serious than diffuse scleritis



On cursory examination resembles nodular episcleritis



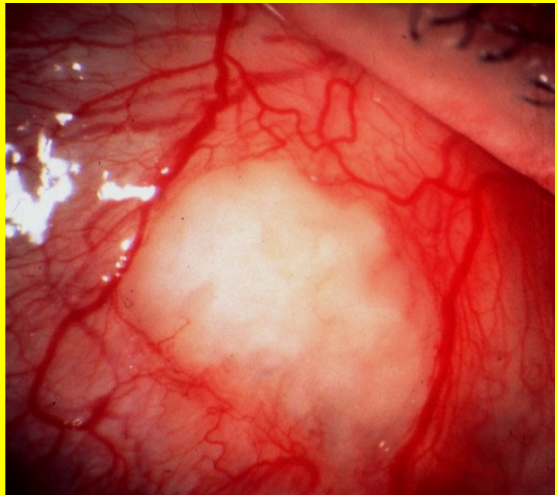
Scleral nodule cannot be moved over underlying tissue

Treatment - similar to diffuse non-necrotizing scleritis

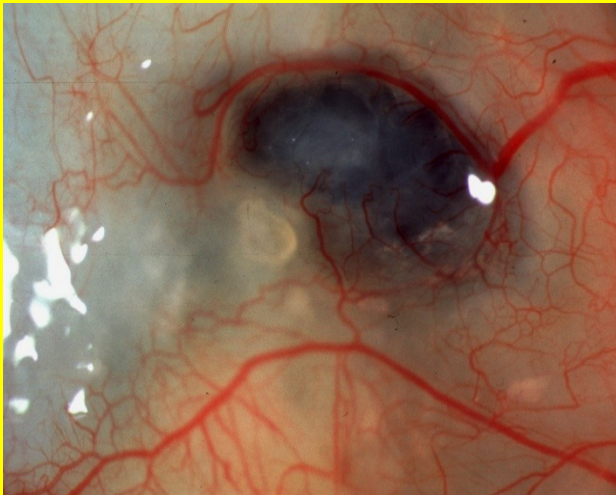
Anterior necrotizing scleritis with inflammation

- Painful and most severe type
- Complications - uveitis, keratitis, cataract and glaucoma

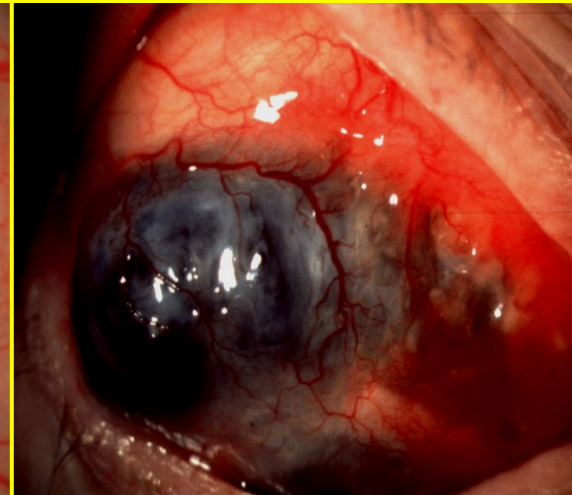
Progression



Avascular patches



Scleral necrosis and visibility of uvea



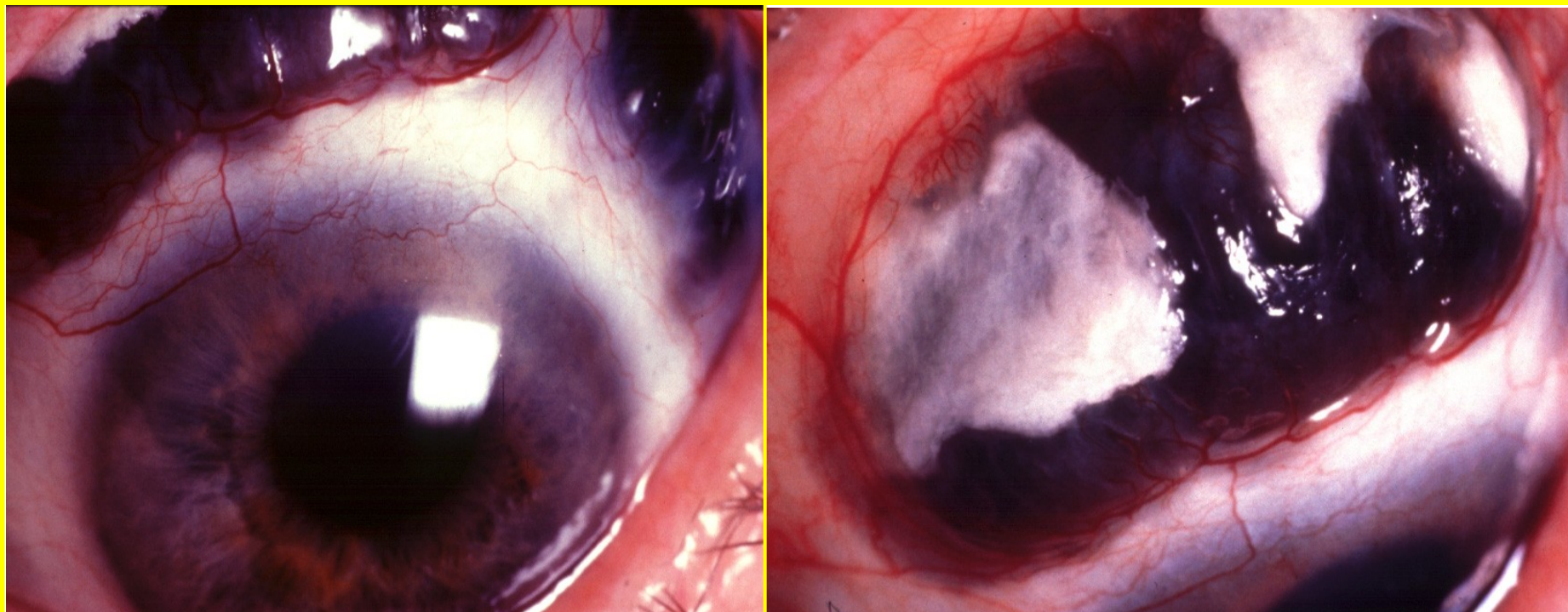
Spread and coalescence of necrosis

Treatment

- Oral steroids
- Immunosuppressive agents (cyclophosphamide, azathioprine, cyclosporin)
- Combined intravenous steroids and cyclophosphamide if unresponsive

Anterior necrotizing scleritis with inflammation (scleromalacia perforans)

- Associated with rheumatoid arthritis
- Asymptomatic and untreatable

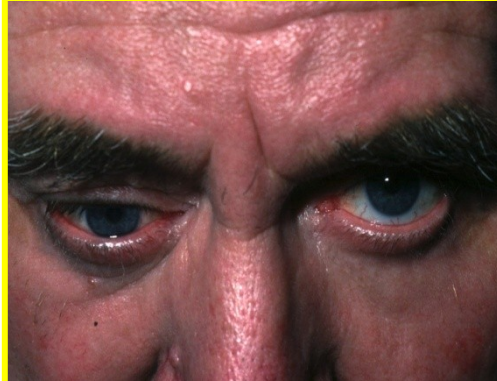

Progressive scleral thinning with exposure of underlying uvea

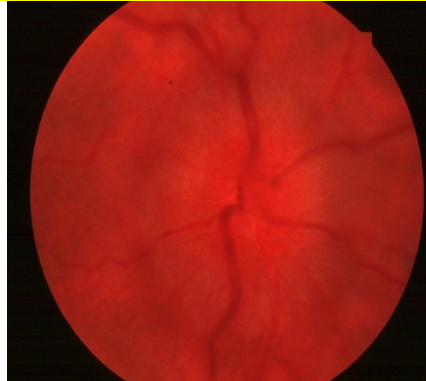
Posterior scleritis

- About 20% of all cases of scleritis
- About 30% of patients have systemic disease
- Treatment similar to necrotizing scleritis with inflammation

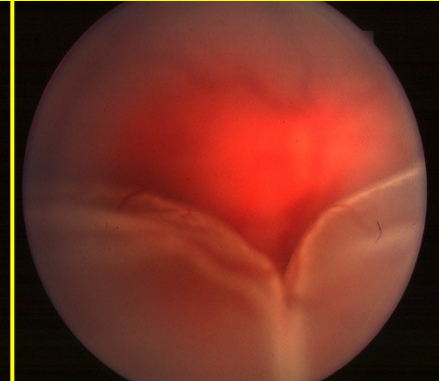
Signs



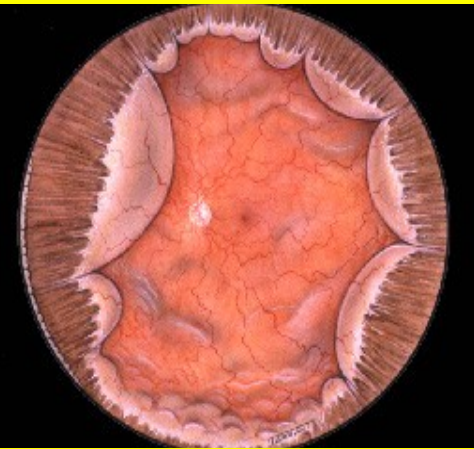
Proptosis and ophthalmoplegia



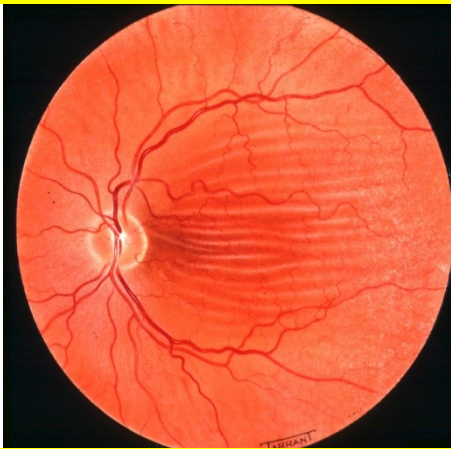
Disc swelling



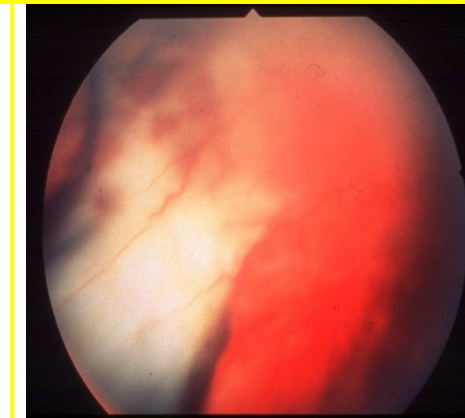
Exudative retinal detachment



Ring choroidal detachment



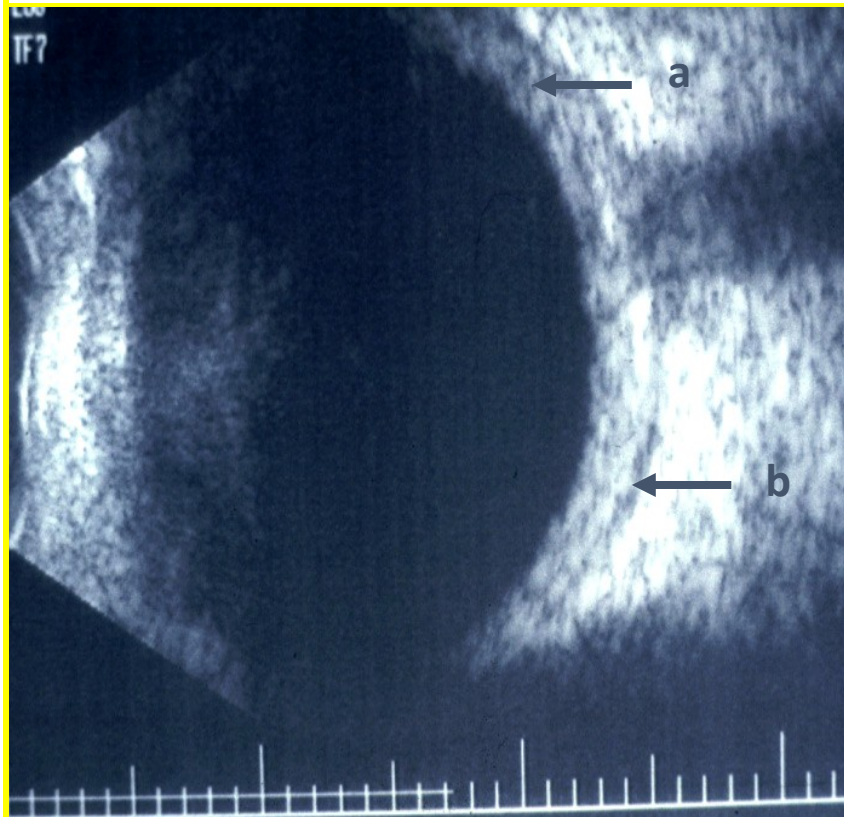
Choroidal folds



Subretinal exudation

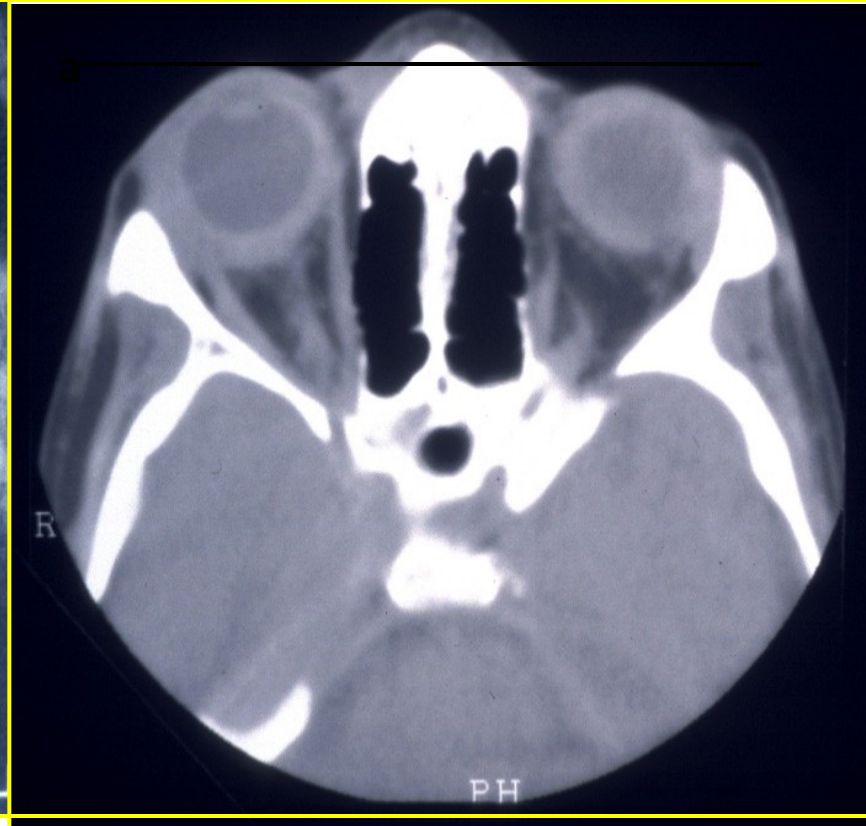
Imaging in posterior scleritis

Ultrasound



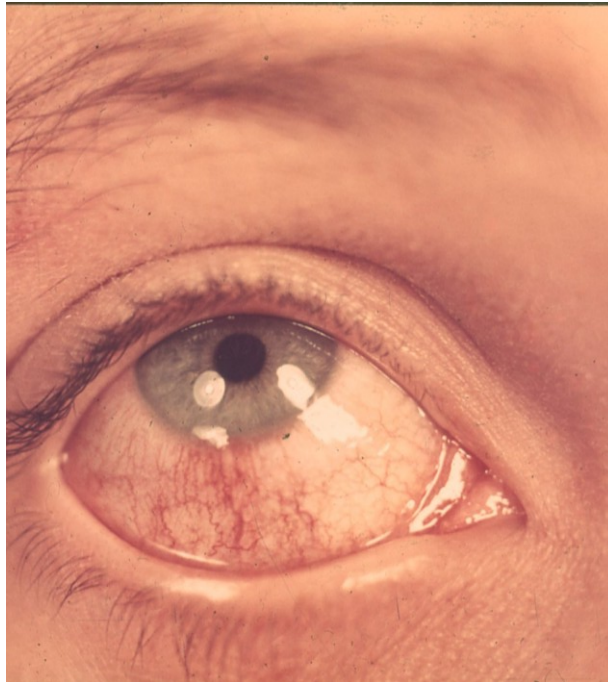
a - Thickening of posterior sclera
b - Fluid in Tenon space ('T' sign)

Axial CT

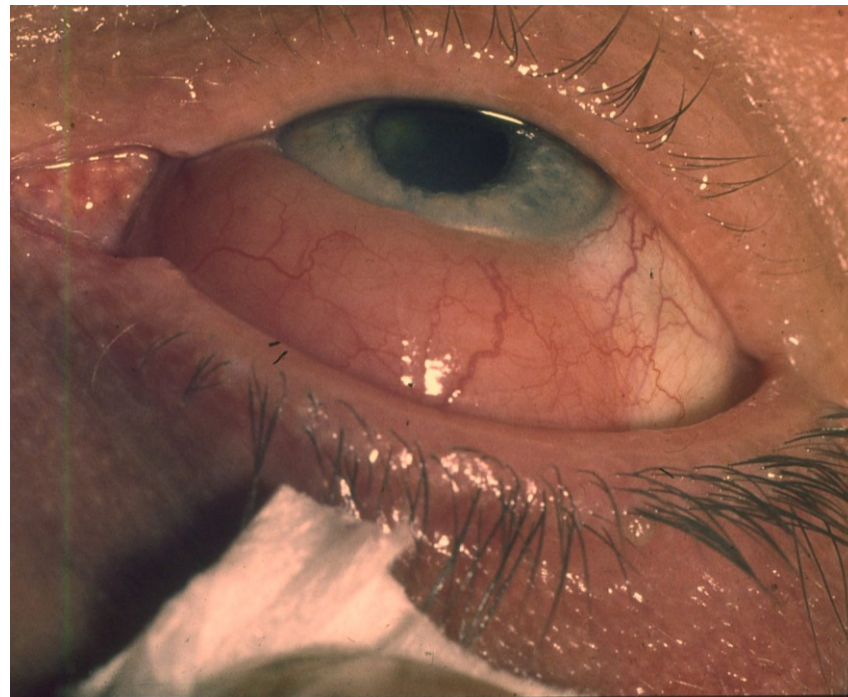


Posterior scleral thickening

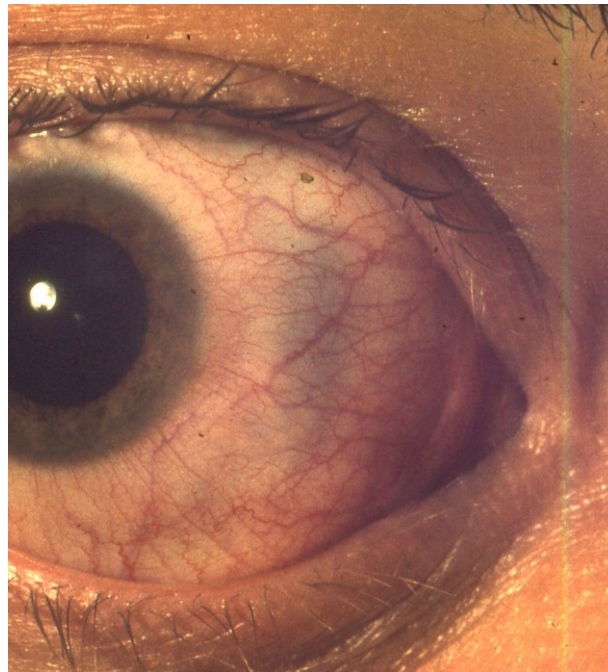
episkleritida



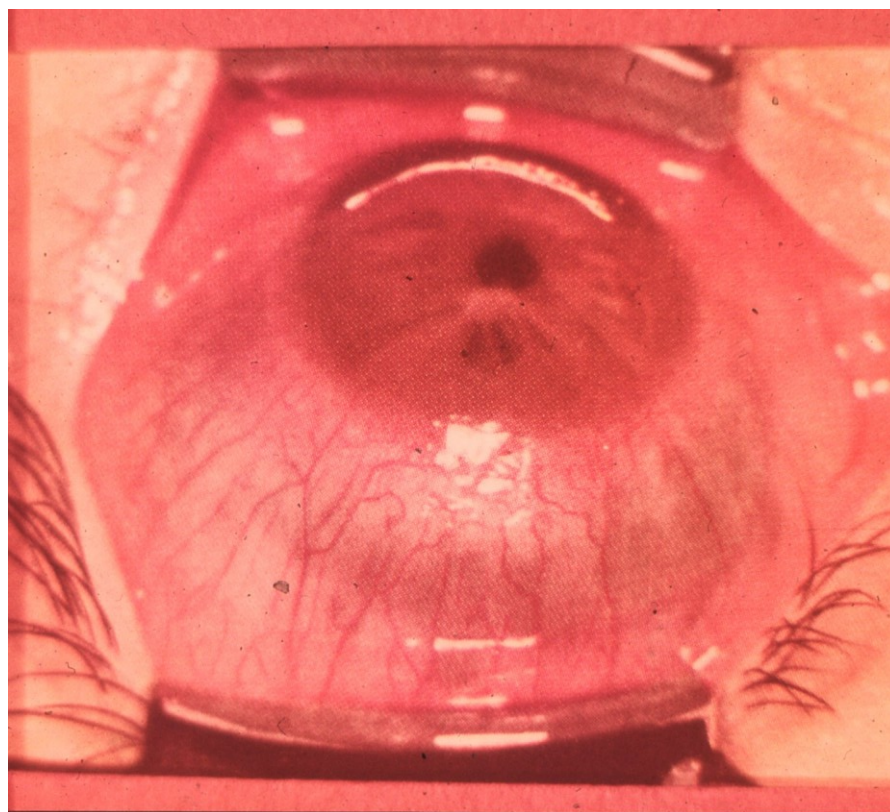
Skleritida



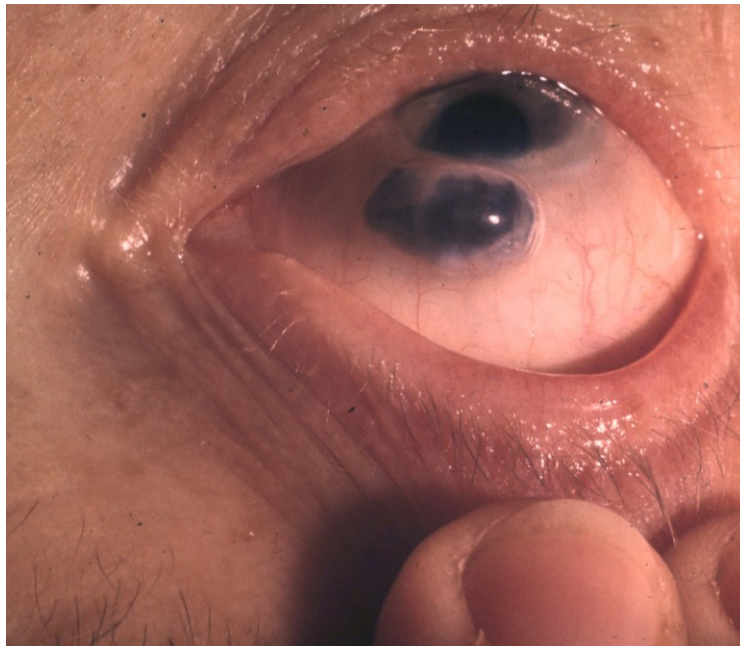Stafylom



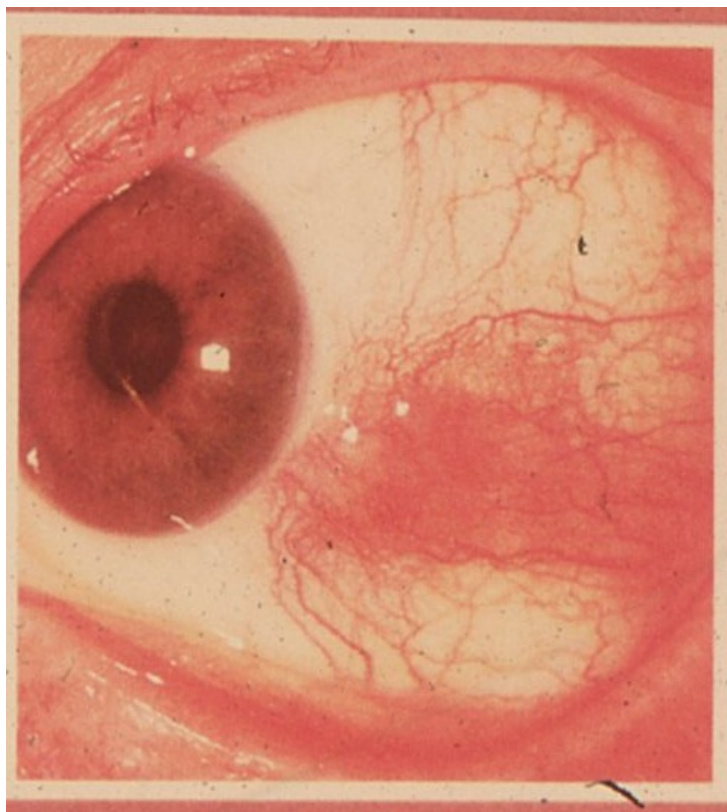
Skleritis



Stafylom



Episkleritida



Děkuji za pozornost