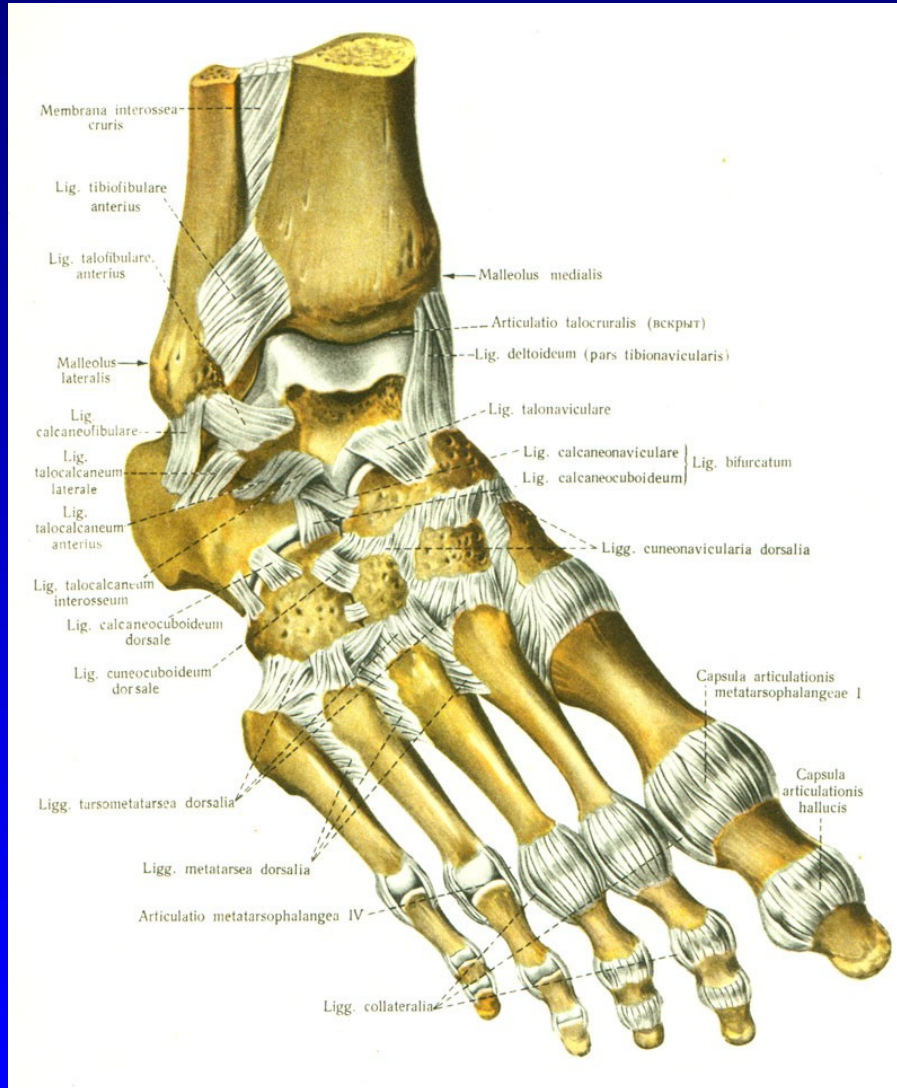


Diseases of the foot

Rozkydal. Z.

Anatomy



Art. talocruralis

Art. talocalcanearis

Art. Choparti

Art. Lisfranci

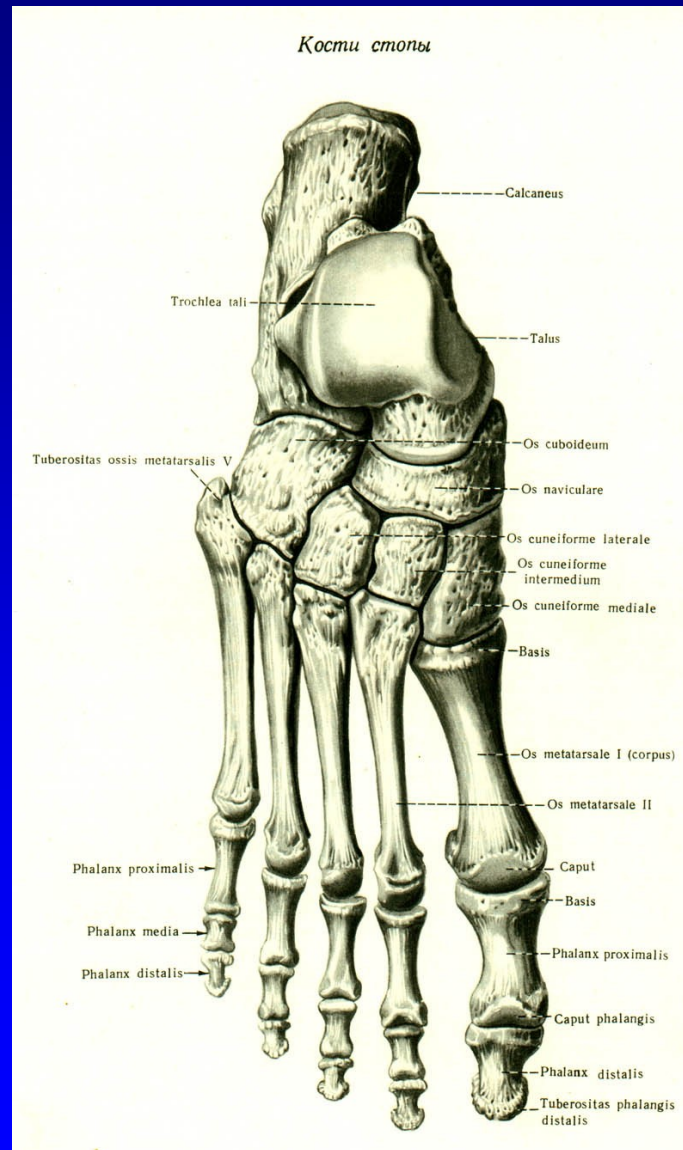
Art. metatarsophalangealis

Art. IP proximalis

Art. IP distalis

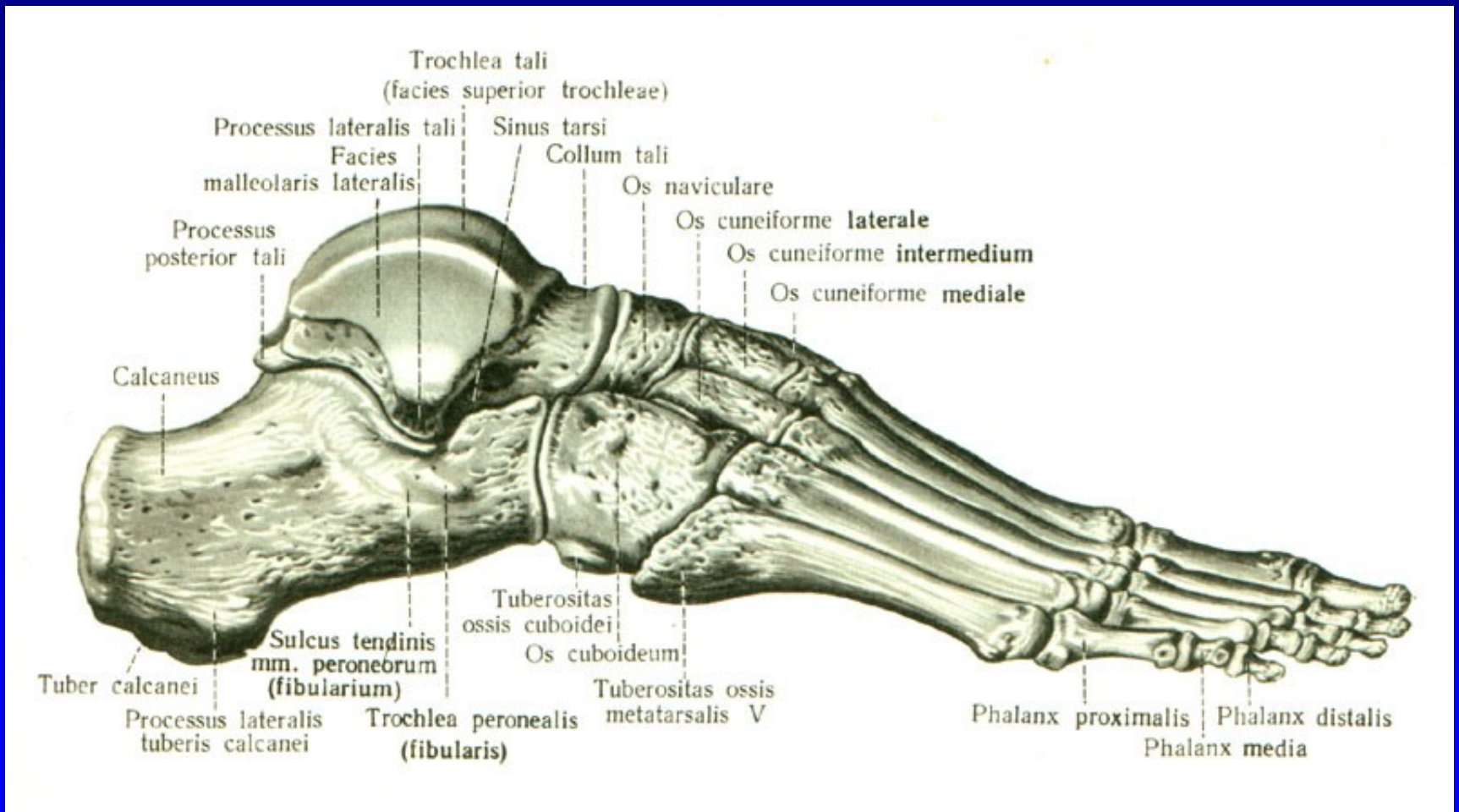
Obr. 1

Anatomy

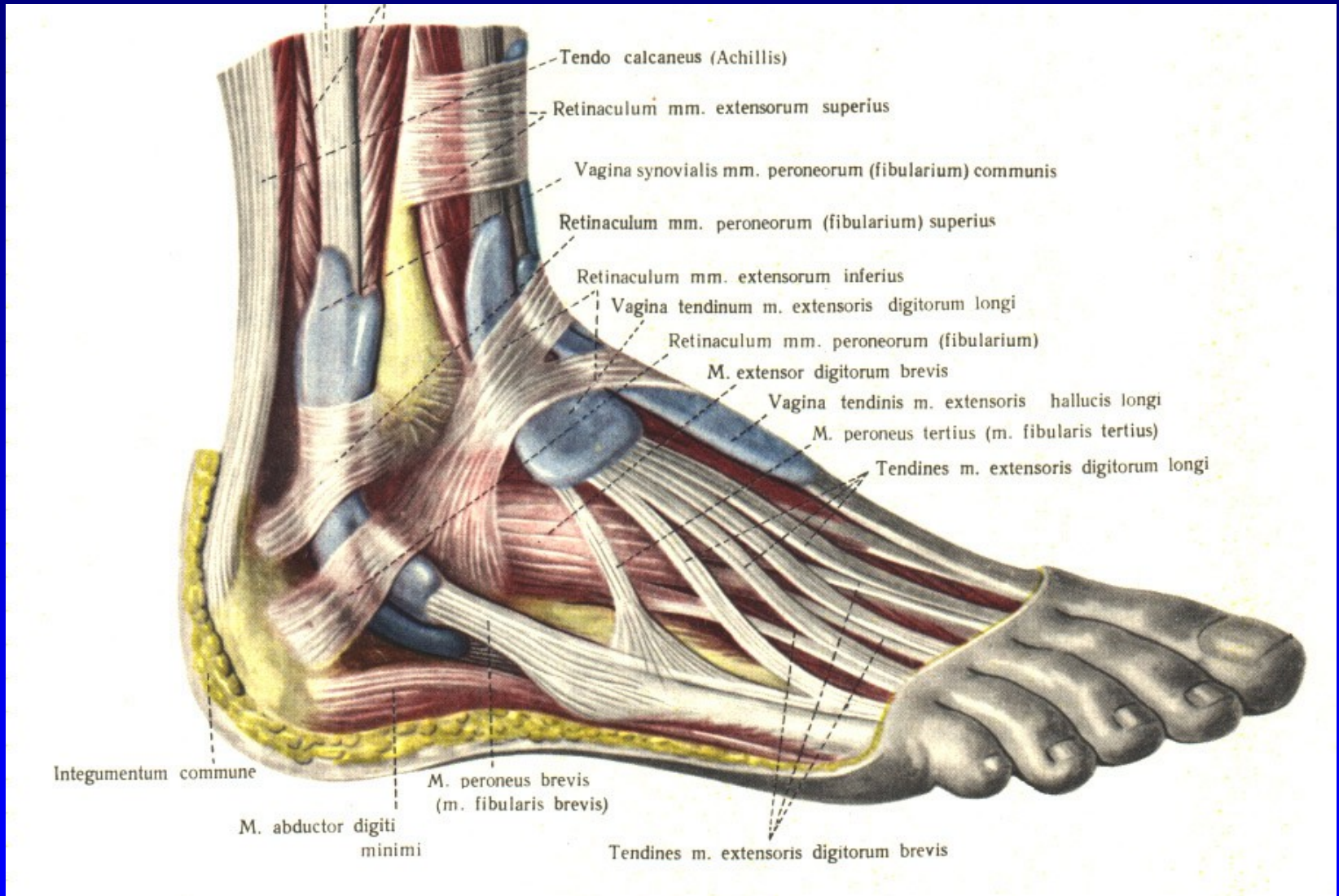


Obr. 3

Anatomy

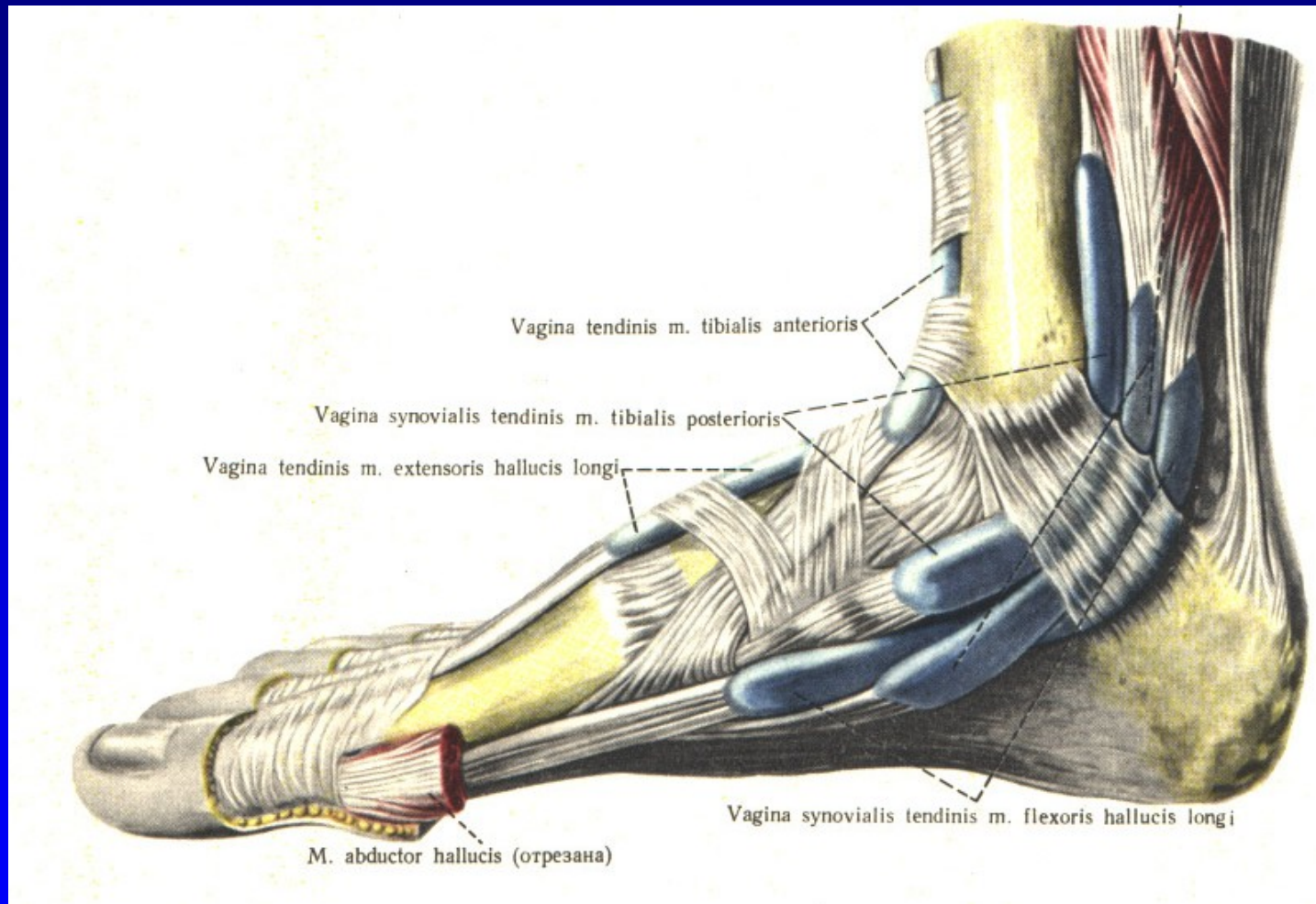


Anatomy



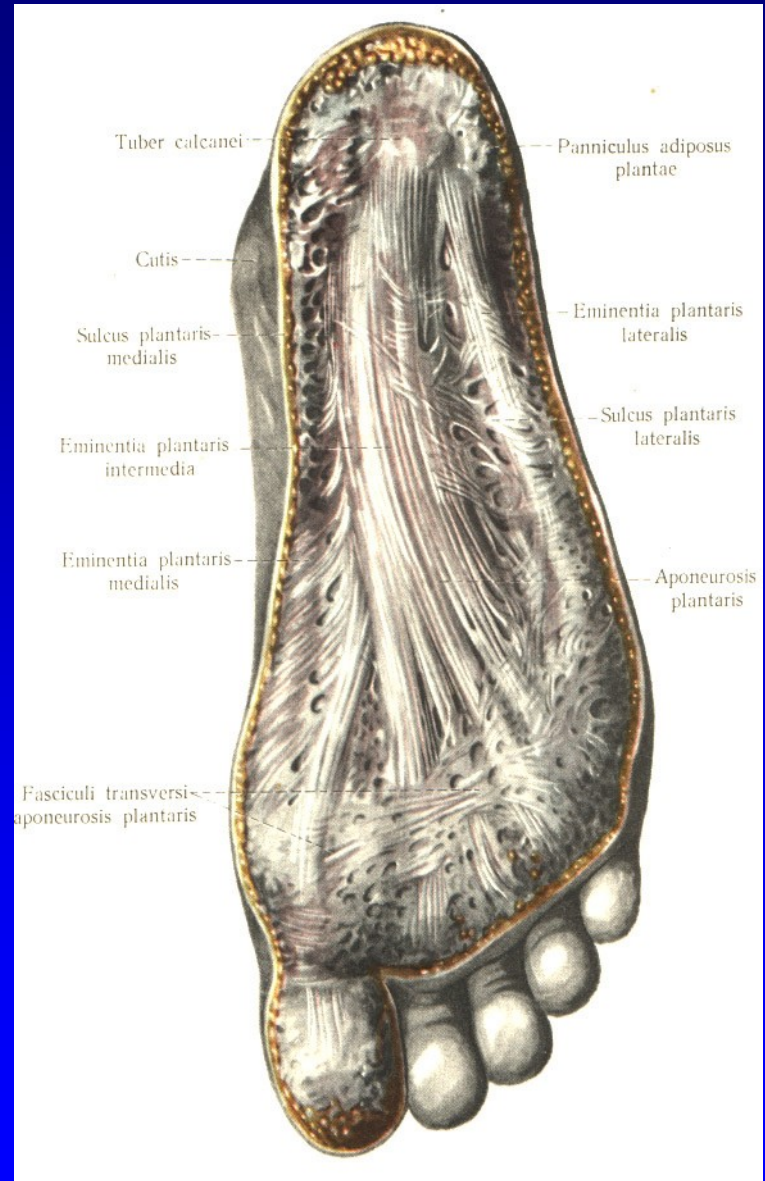
Obr. 6 Vaginae mm. peroneorum

Anatomy



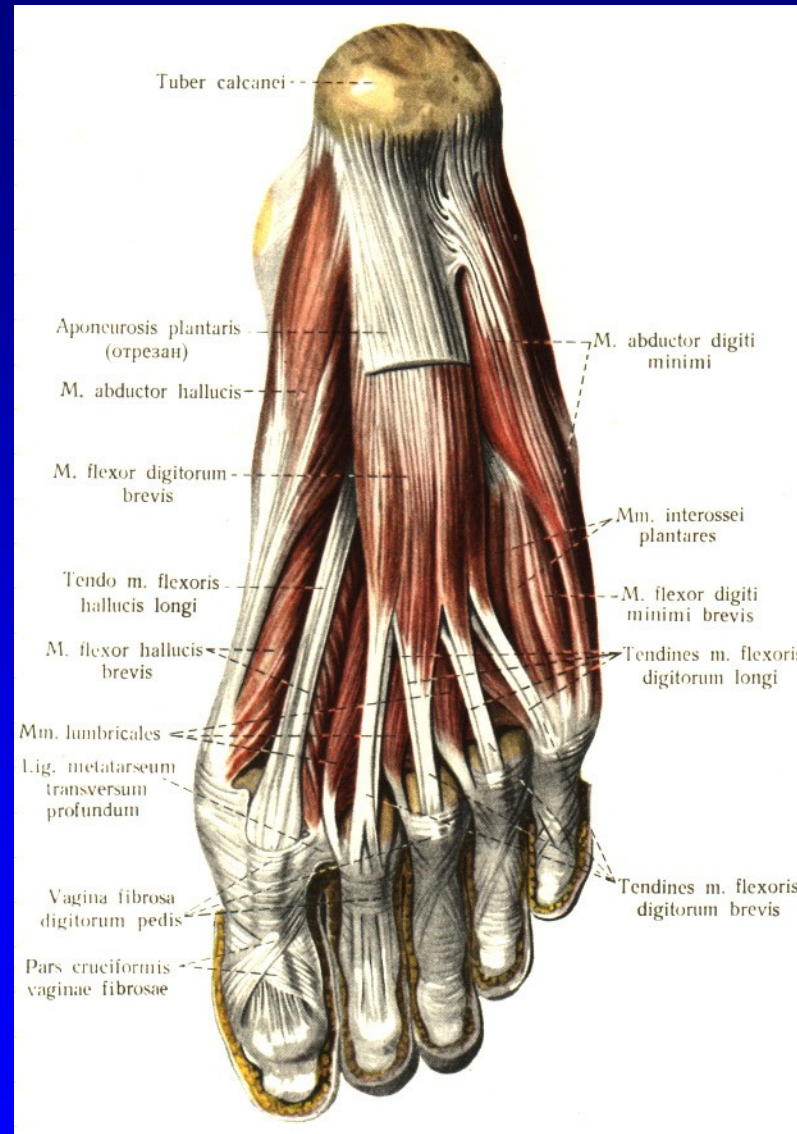
Obr. 7 Vaginae mm. flexorum pedis

Anatomy



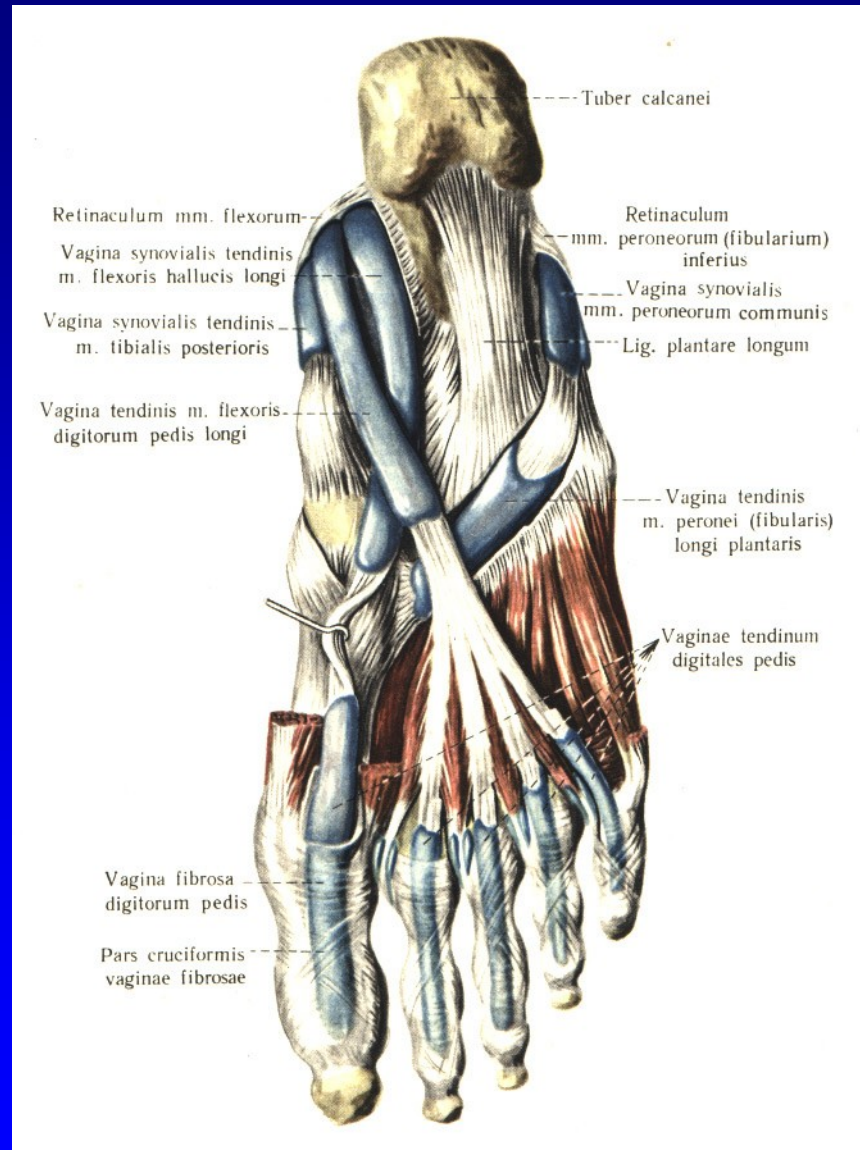Obr. 8 Aponeurosis plantaris

Anatomy



Obr. 9 Flexors

Anatomy



Obr. 10 Flexors

The ankle joint

Synovialitis

Osteoarthrosis

Trauma

Posttraumatic conditions

Static deformities

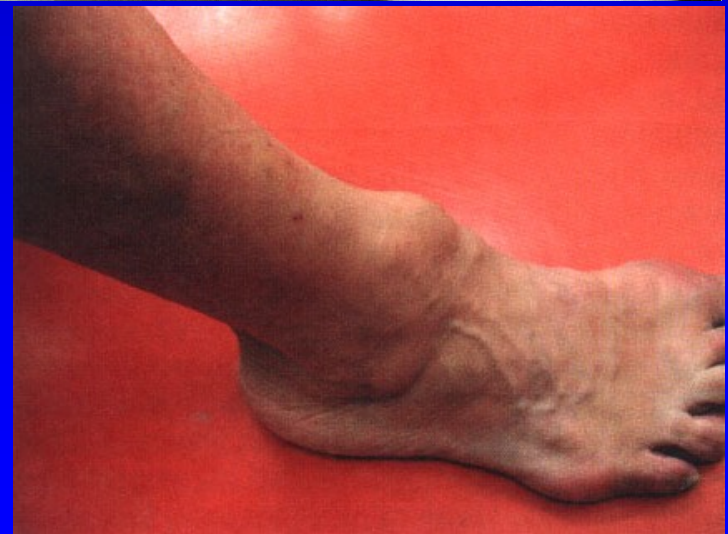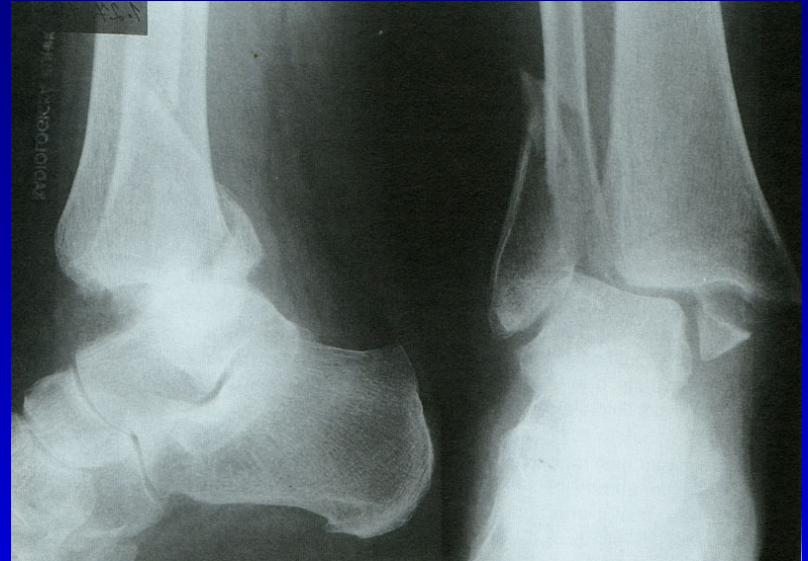
Congenital deformities

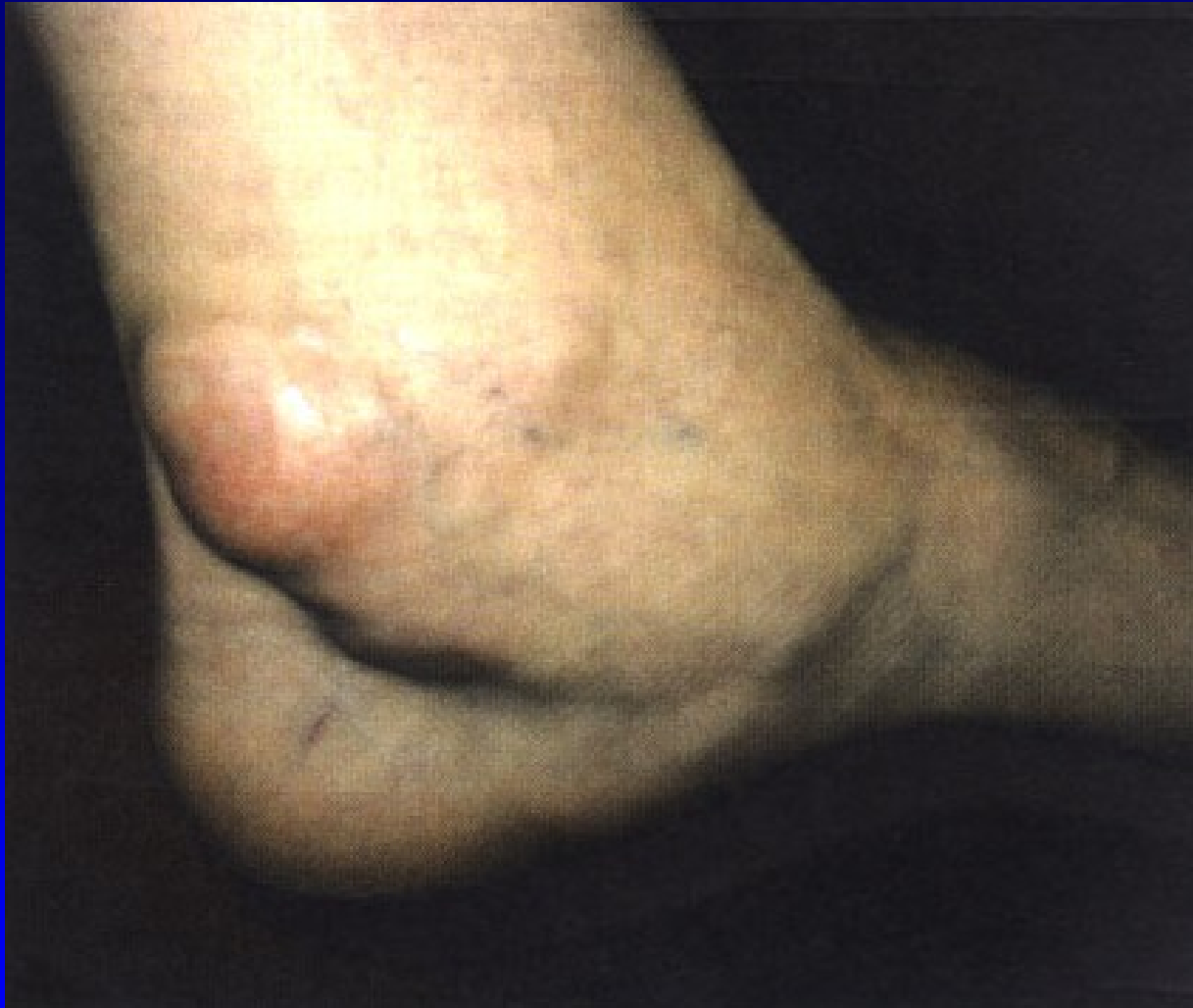Rheumatoid arthritis

Osteochondrosis dissecans - talus

Stenosing tenosynovitis

Tarsal tunnel syndrom

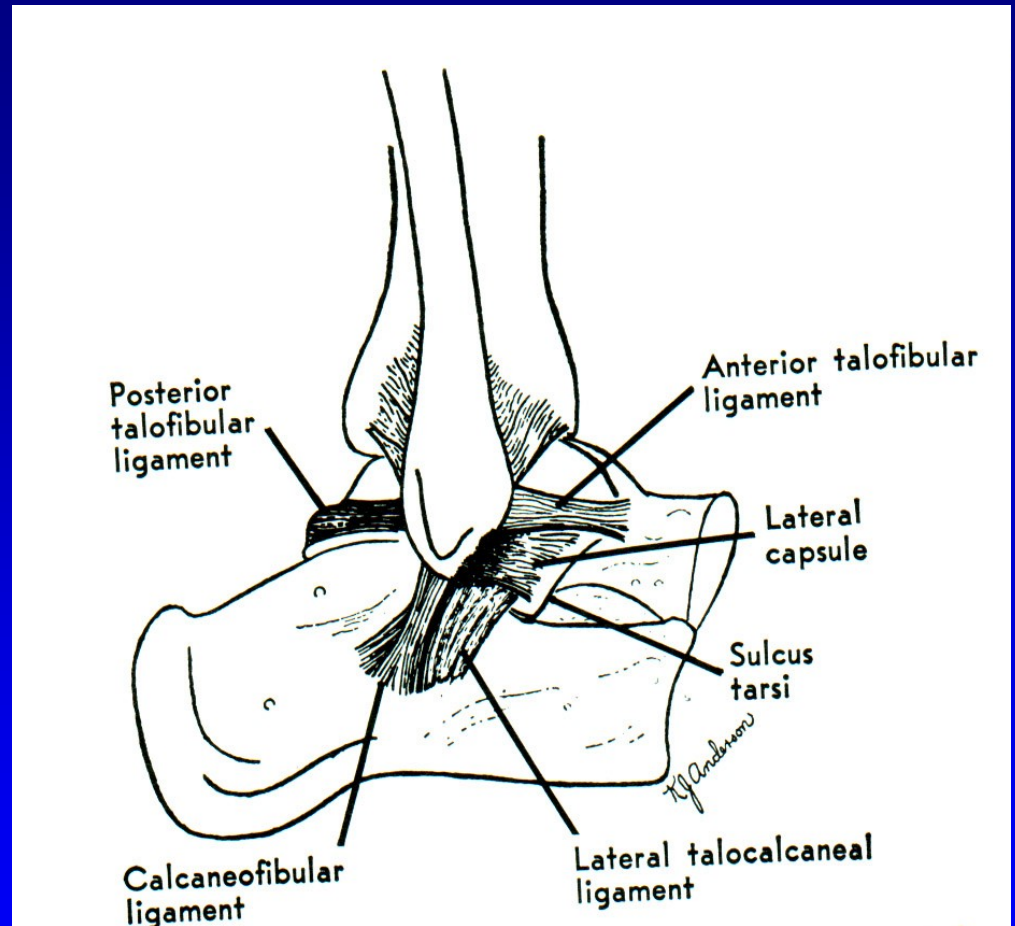




Synovialitis

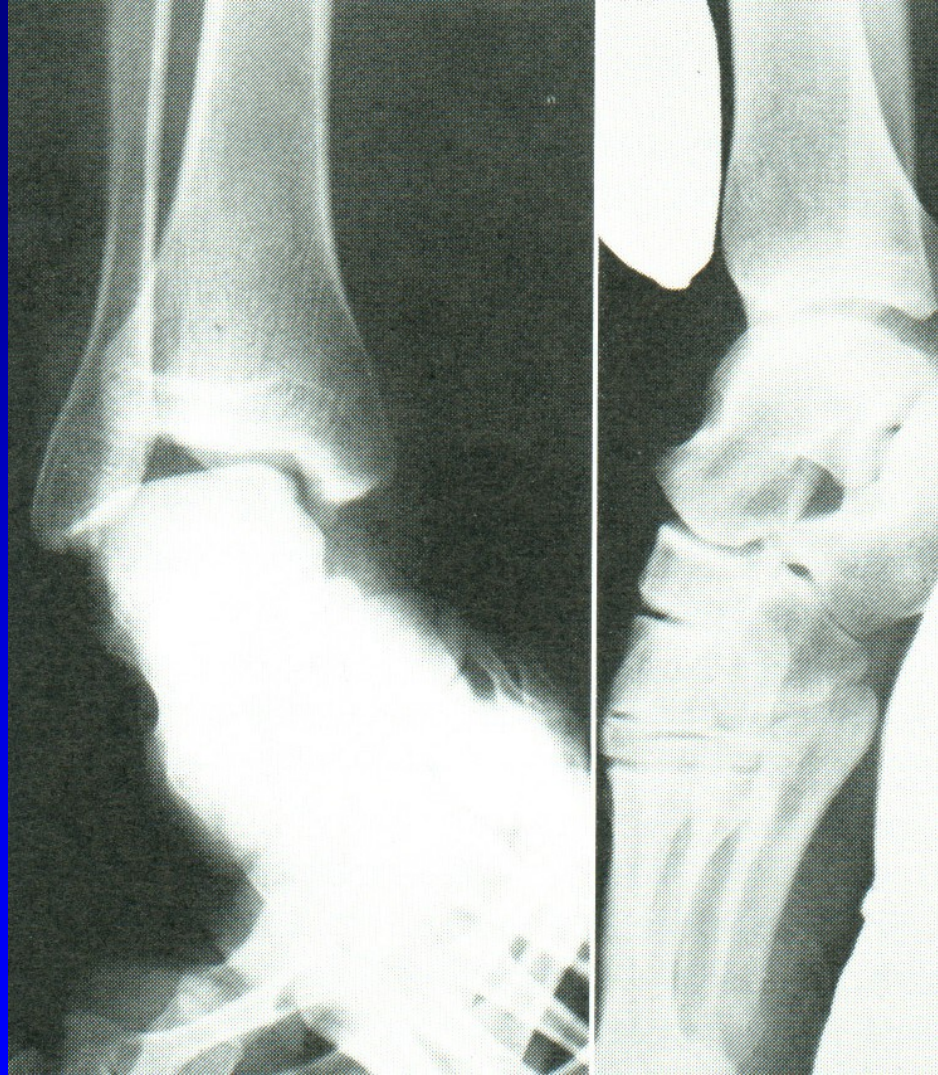Lateral ligaments

Sprain
Partial rupture
Complete rupture



Obr. 12 Lig. collaterale lat.

X- ray



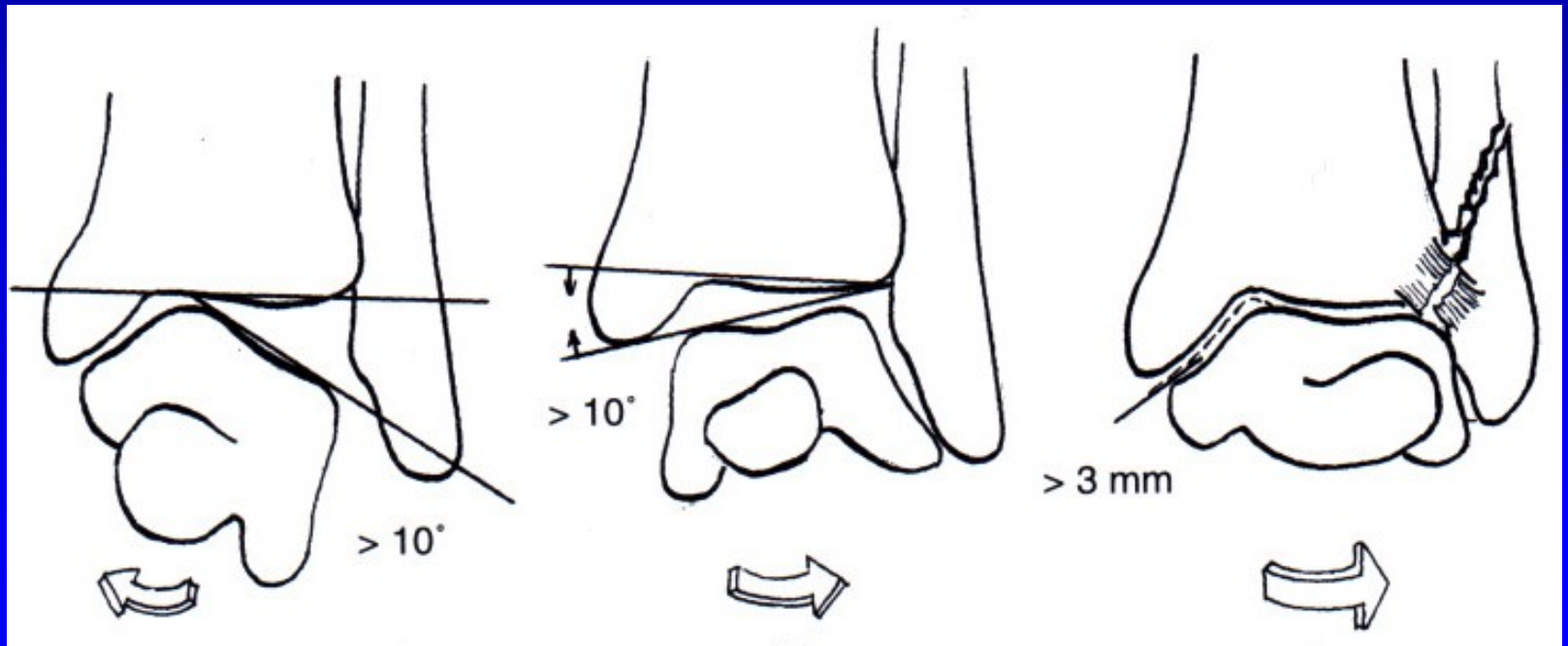
Obr. 13

Management

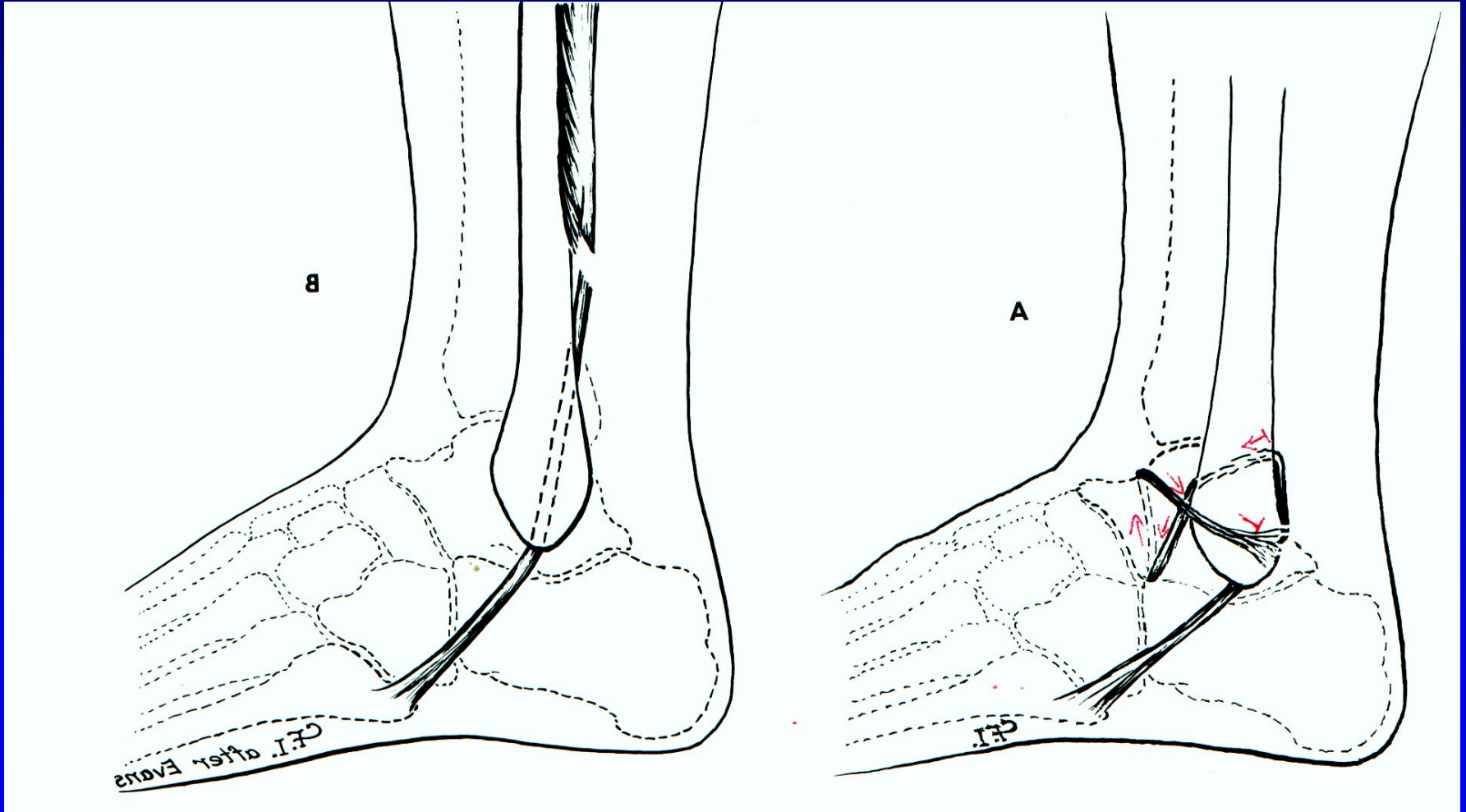
Sprain: bandage, othesis

Partial rpt.: orthosis, plaster

Complete rpt.: suture and plaster



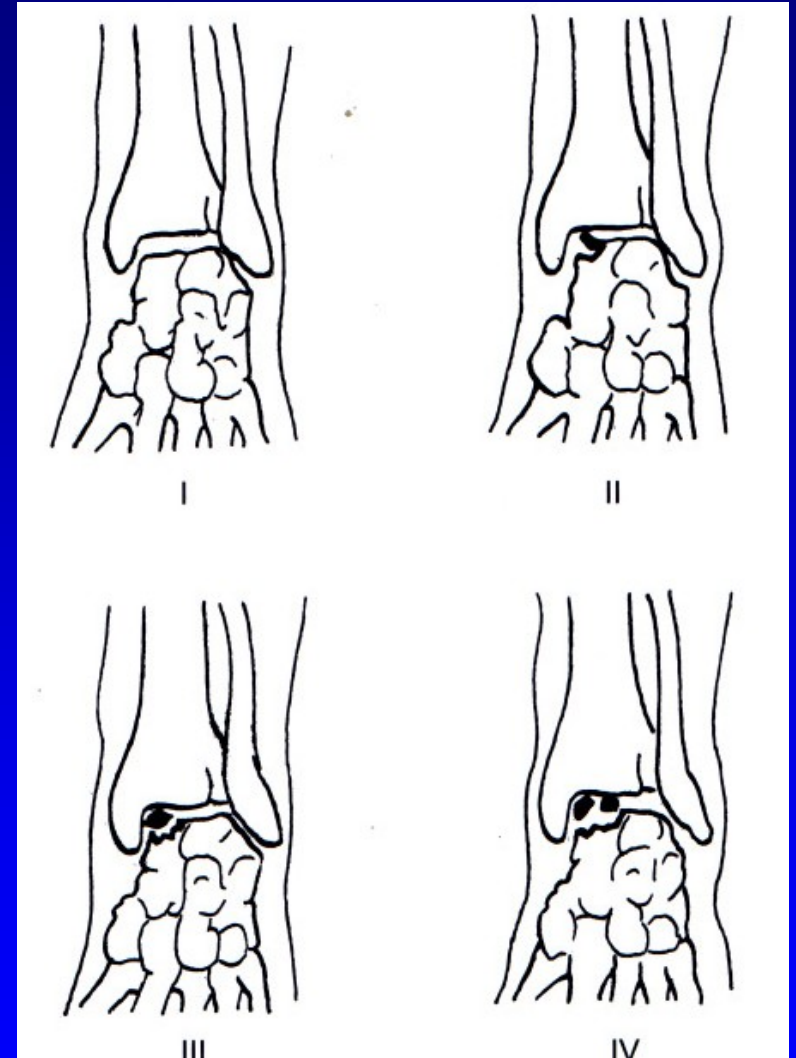
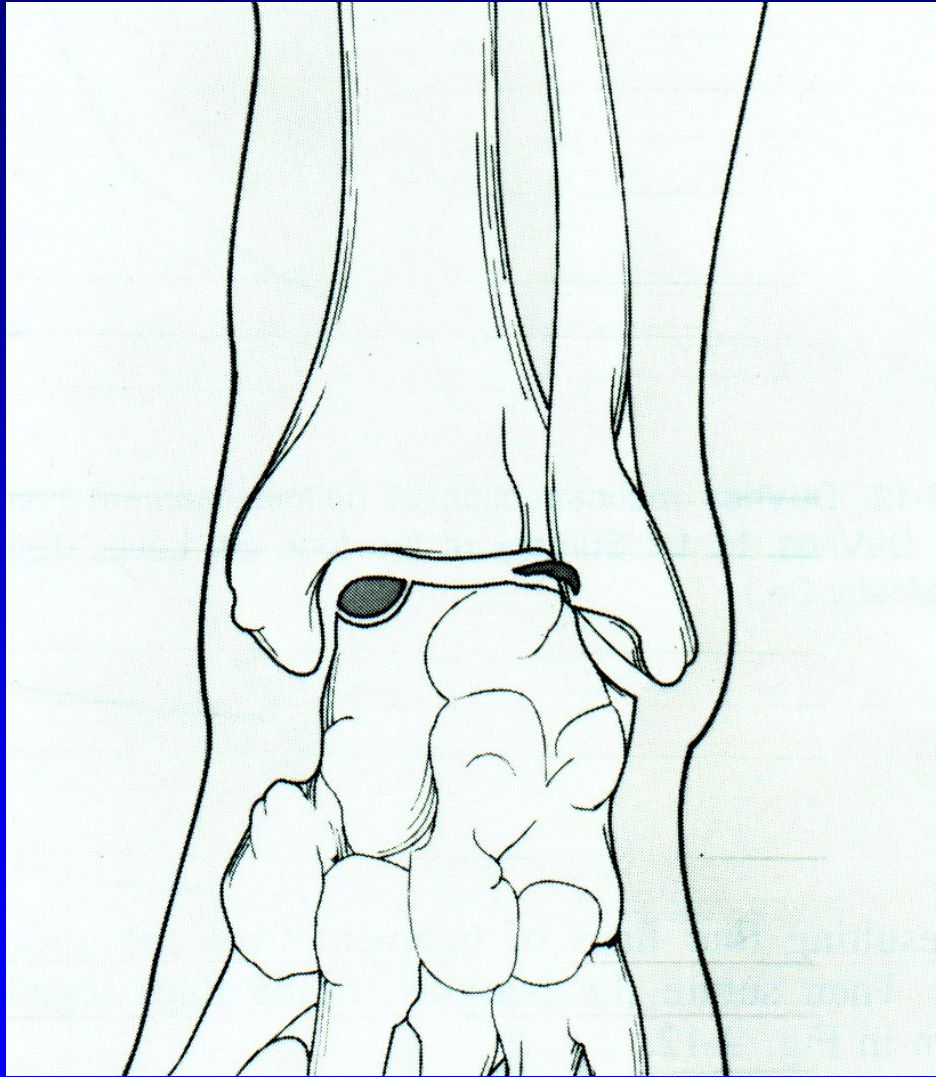
Chronic instability



Obr. 15 Evans plasty

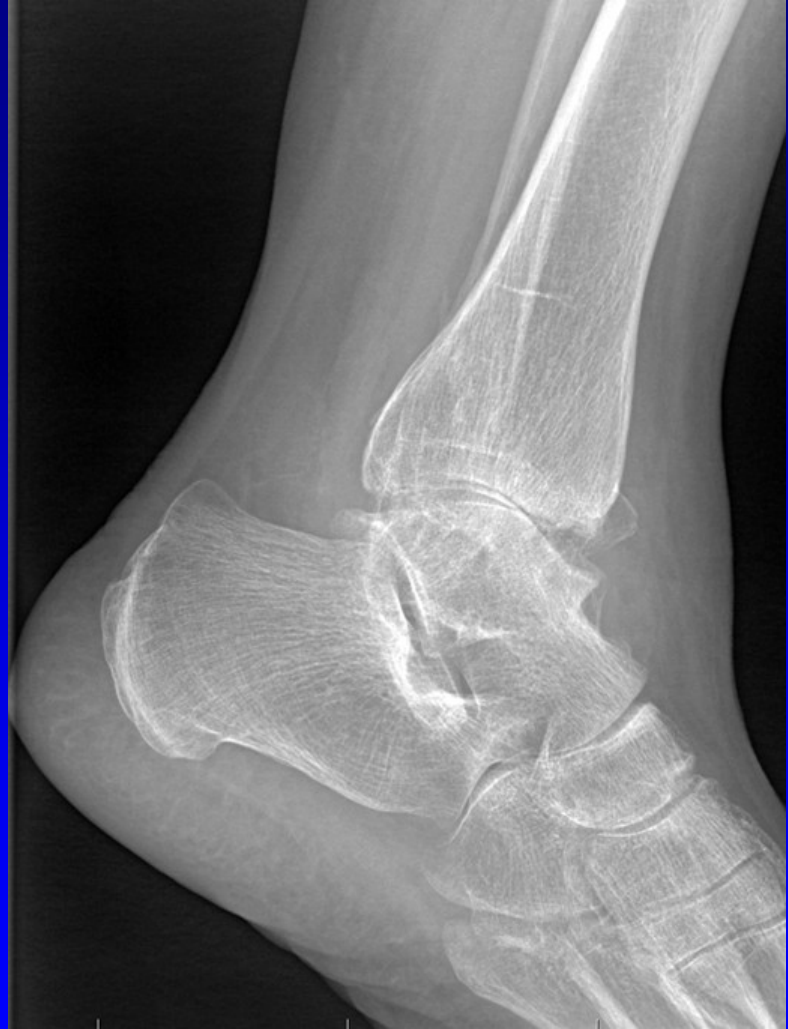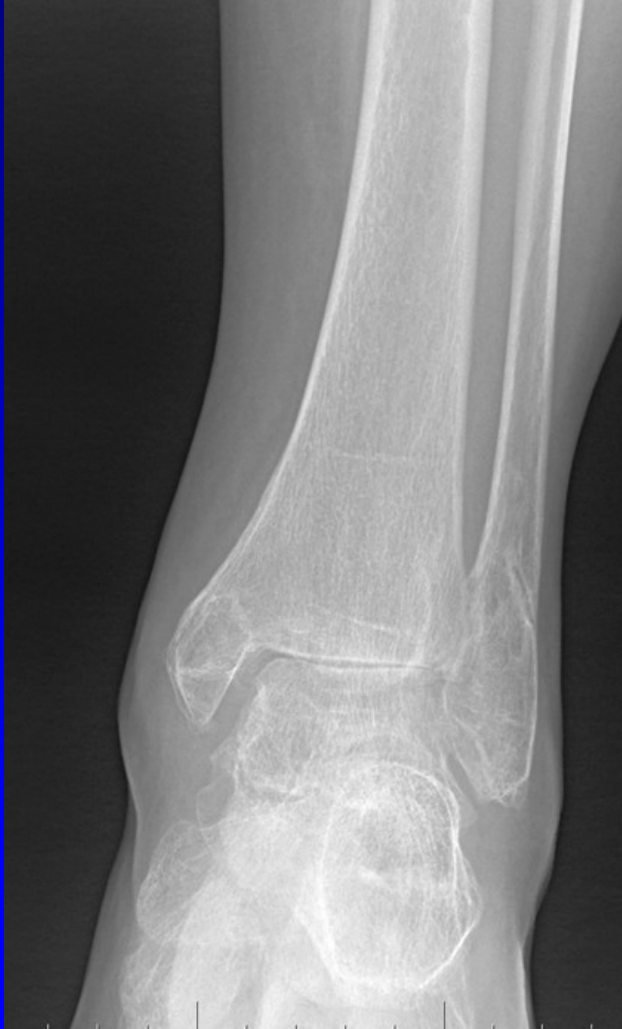Watson Jones plasty

Osteochondrosis dissecans tali



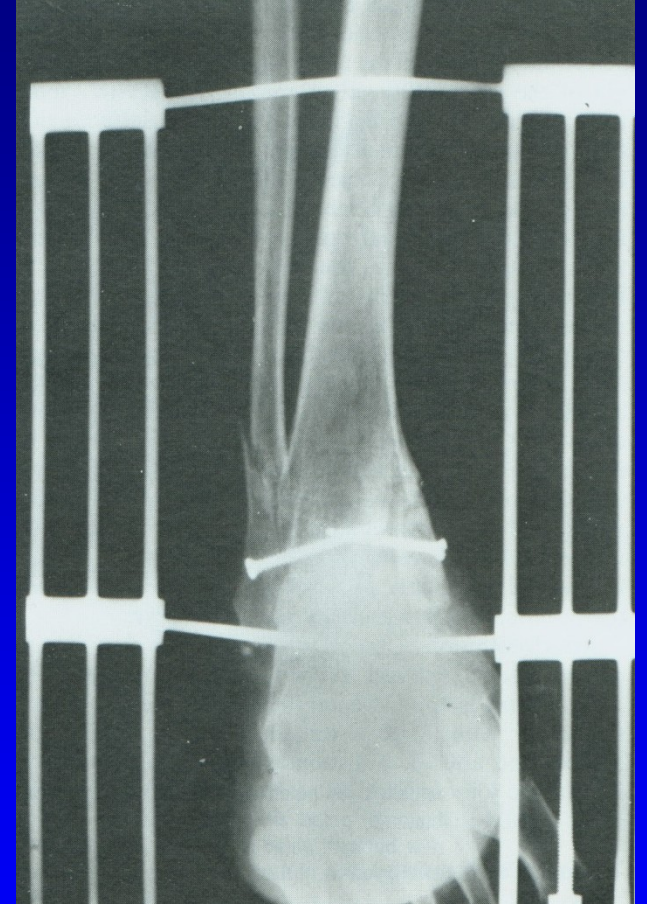
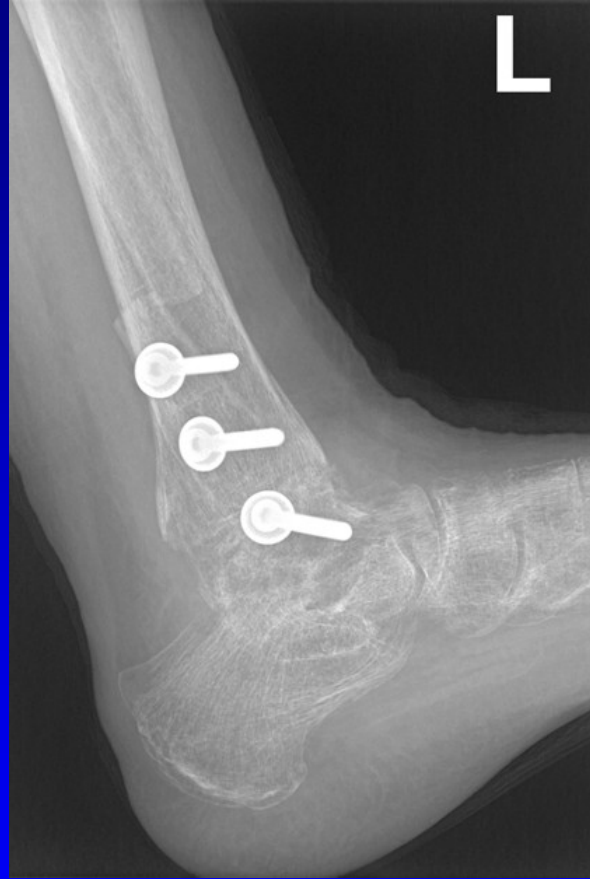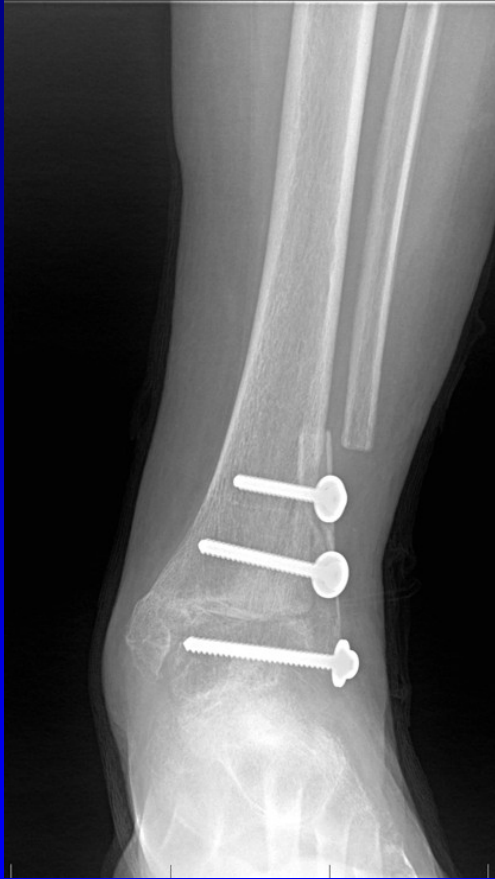Obr. 16

Arthritis of the ankle joint



Obr. 18

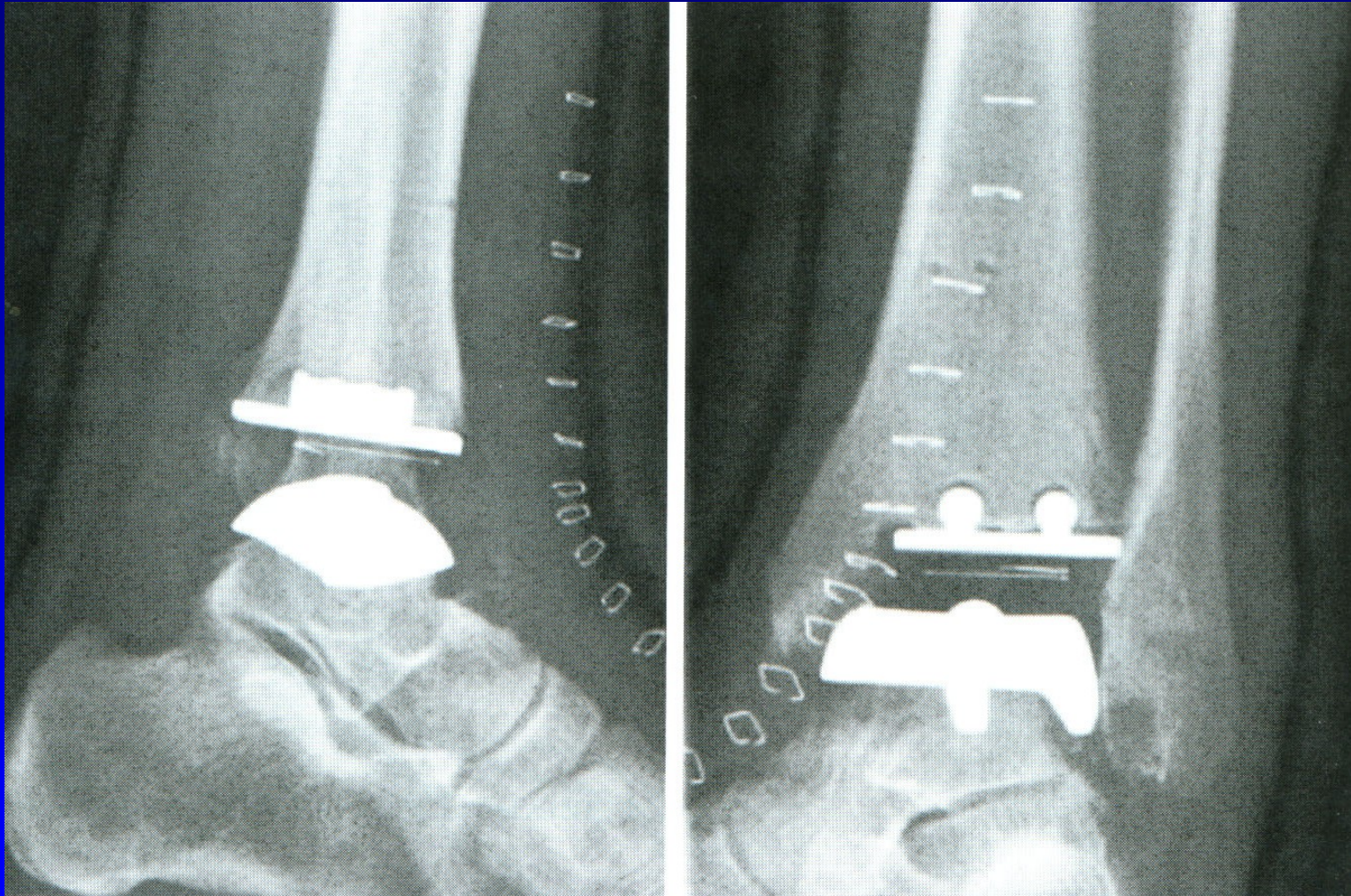
Arthrodesis



Adams- Horwitz arthrodesis

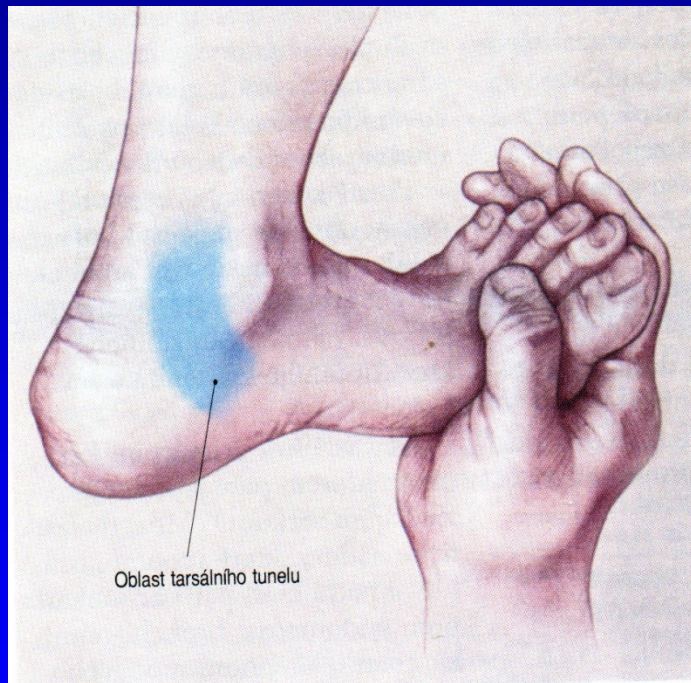
Charnley arthrodesis

Total ankle replacement

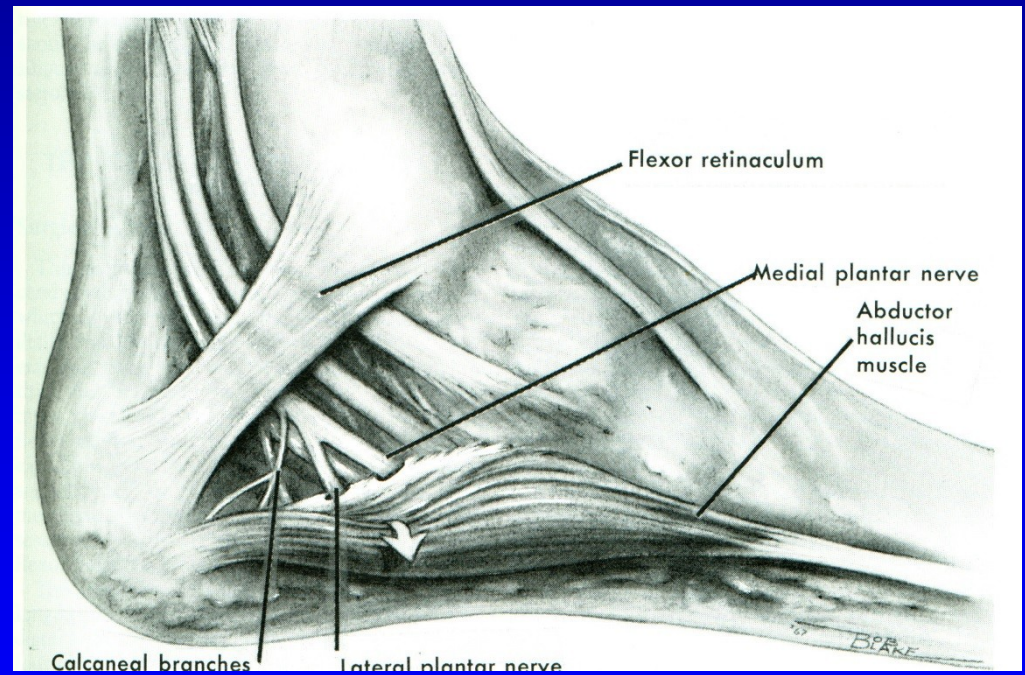


Obr. 21

Tarsal tunnel syndrom



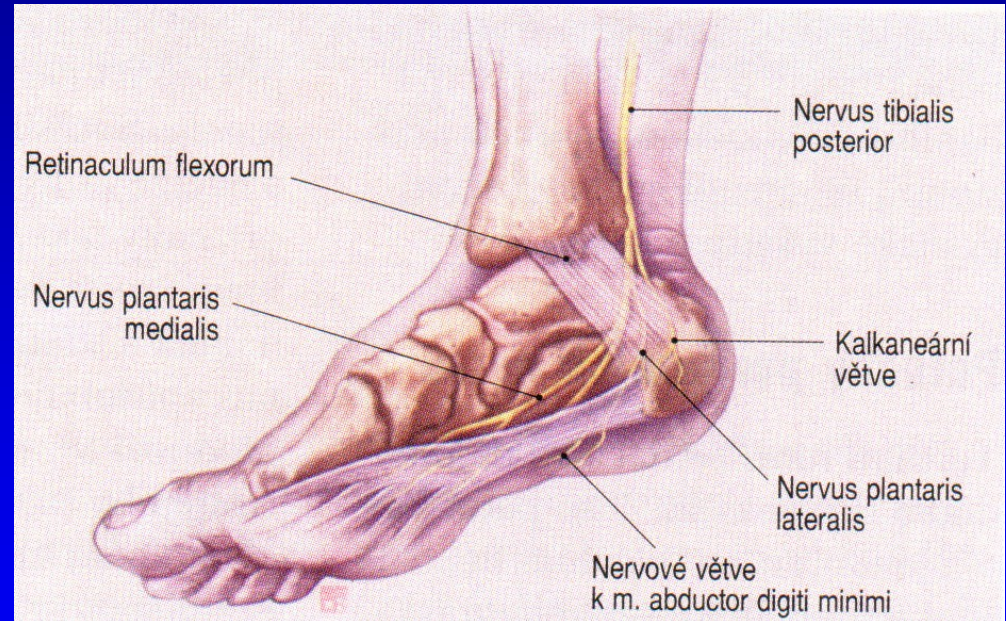
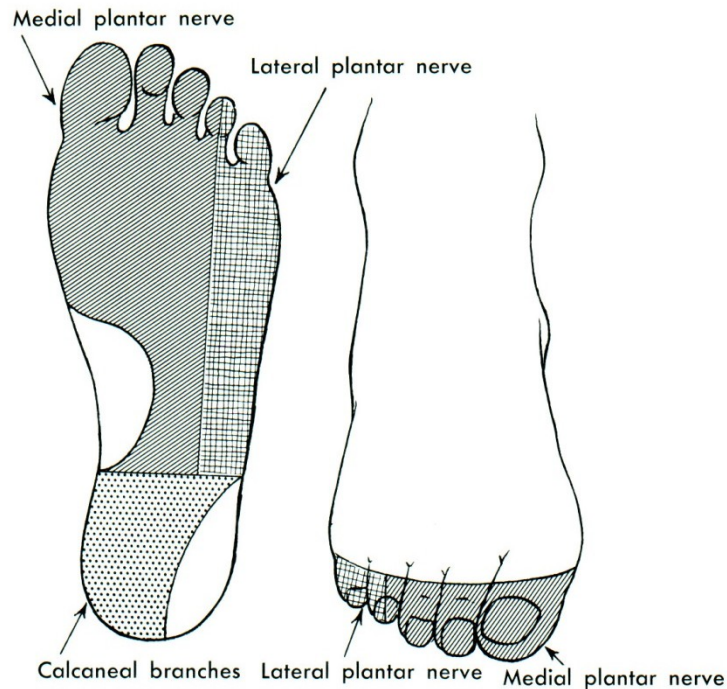
Obr. 22



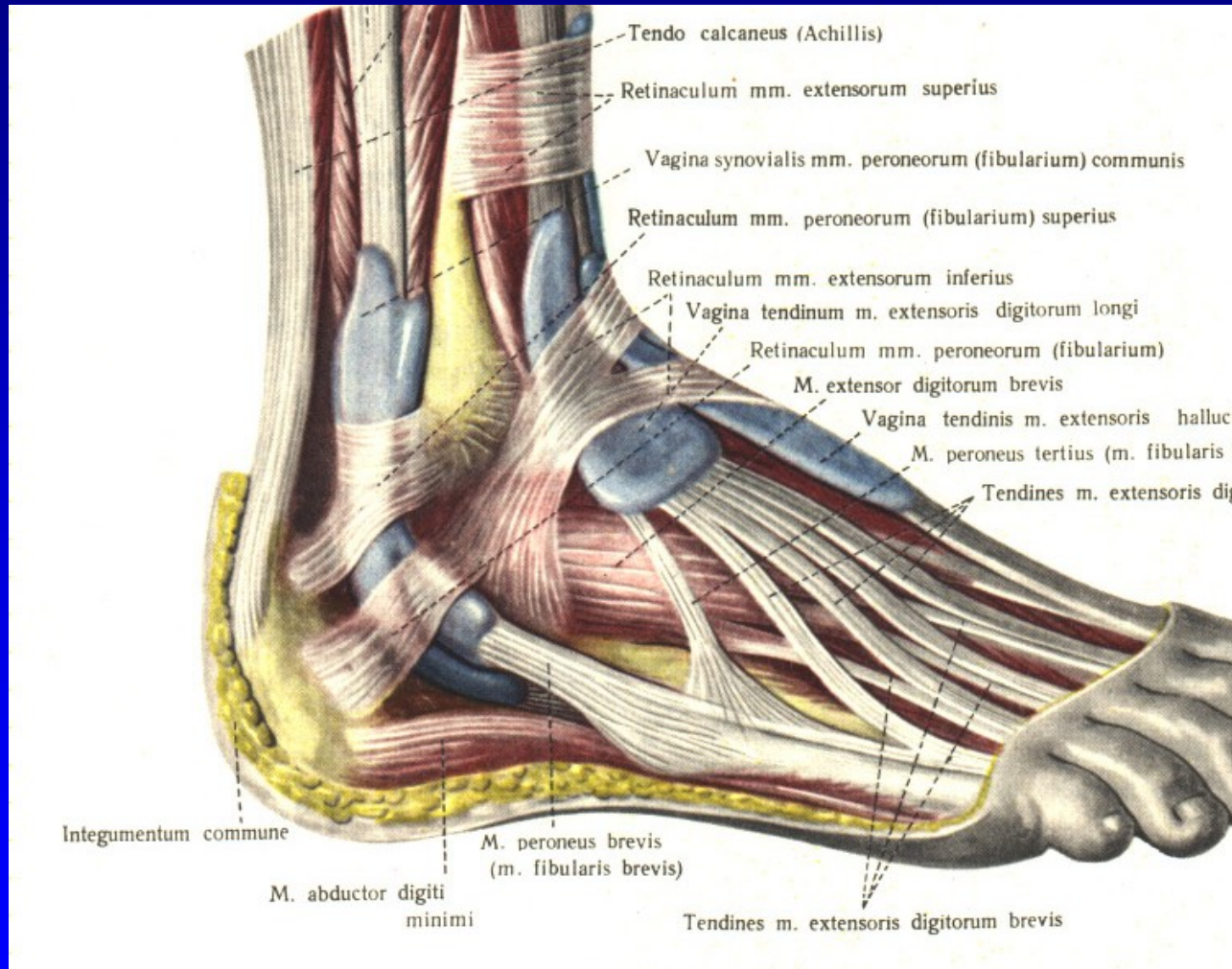
Obr. 23

Tarsal tunnel syndrom

Innervation of plantar side



Peroneal tenosynovitis

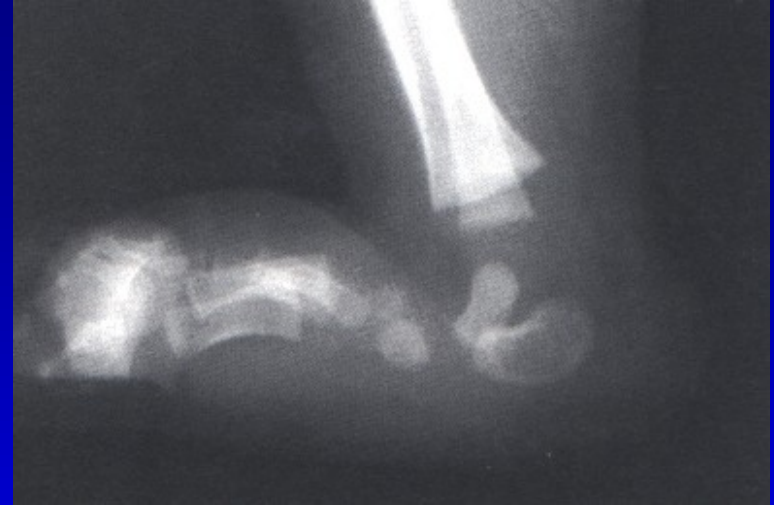

Pes planus- flat foot

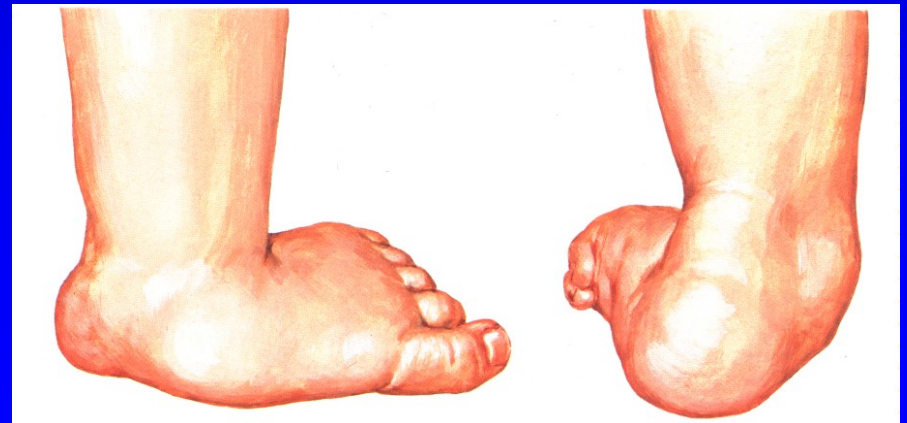Congenital flat foot

Rigid: Vertical talus
Tarsal coalition

Flexible: pes calcaneovalgus



Vertical talus



Flat foot

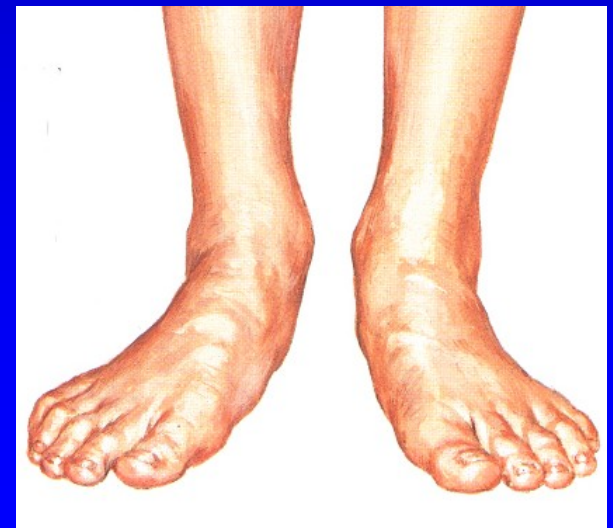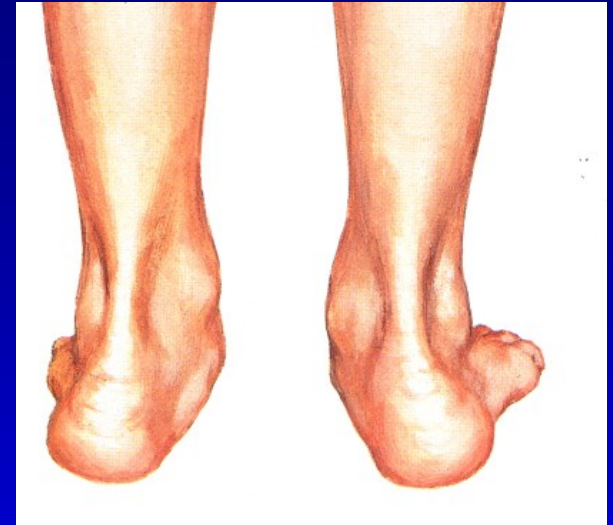Acquired flat foot

Laxicity

Marfan sy, Ehlers- Danlos sy,
Down sy

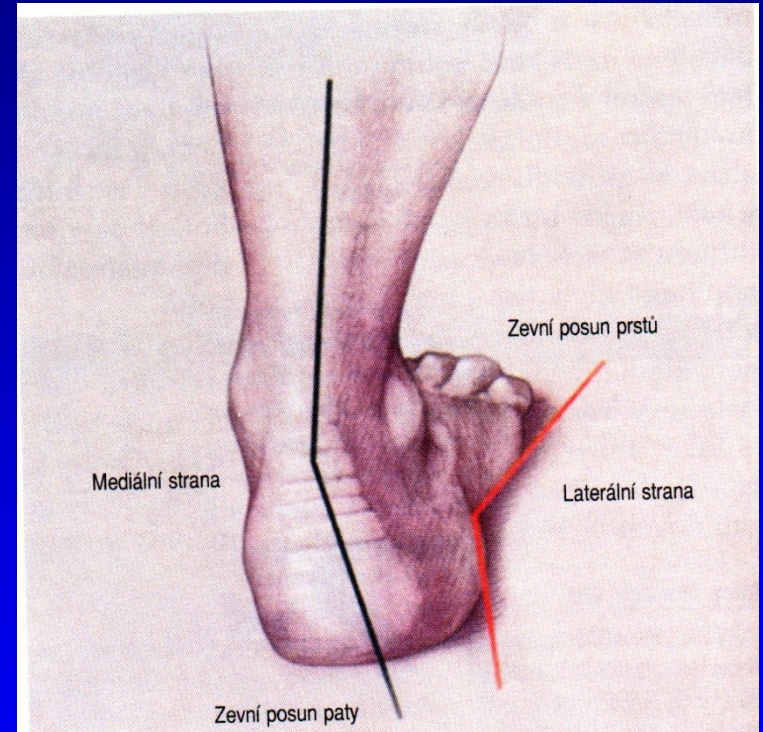
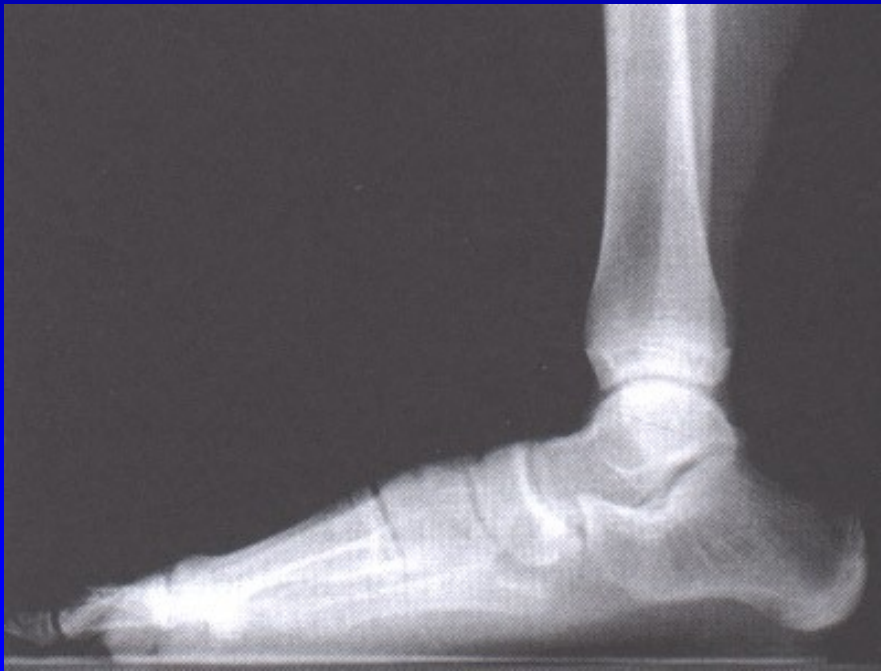Cerebral palsy, myopathies

Rheumatoid arthritis



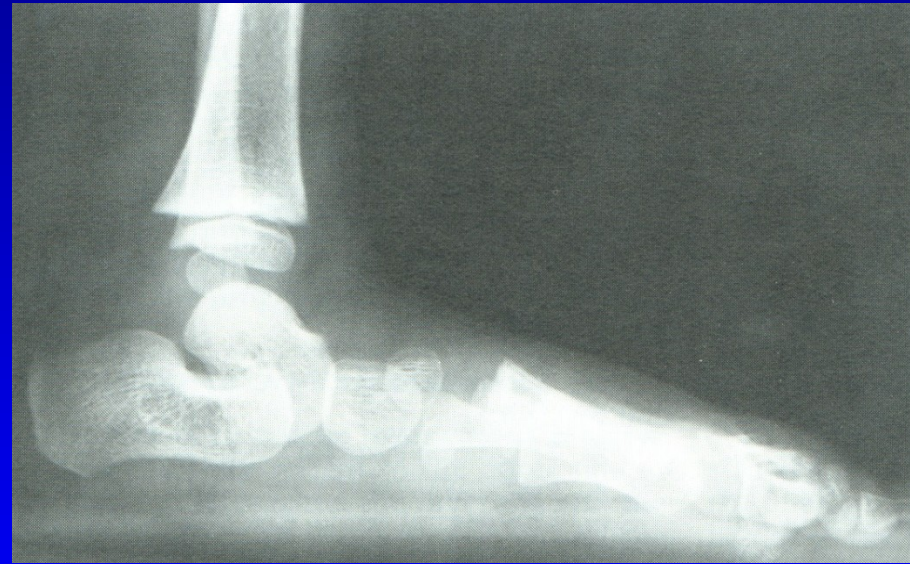
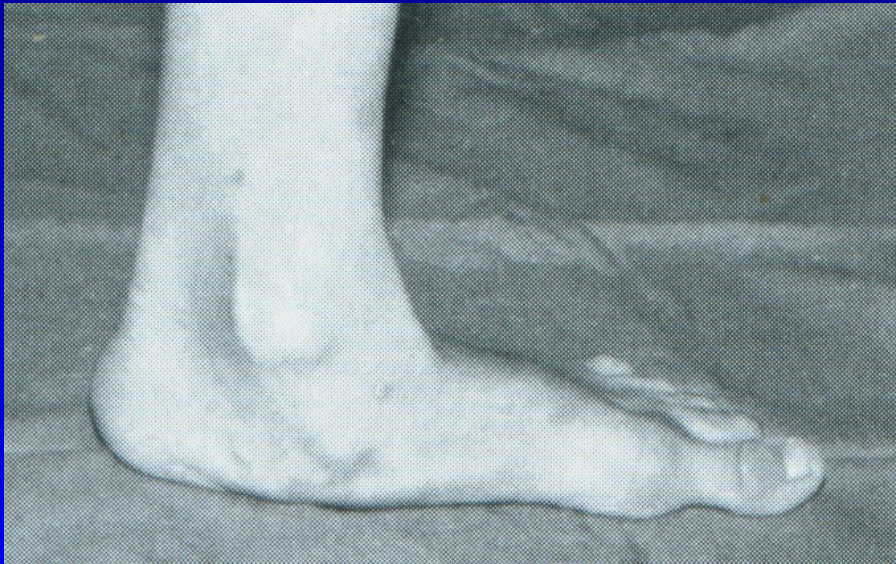Flat foot

1. Diminished arch
2. No arch
3. Arch convex plantarwards



Valgosity of the heel

Flat foot



3. degree flat foot

In small children - pes planovalgus

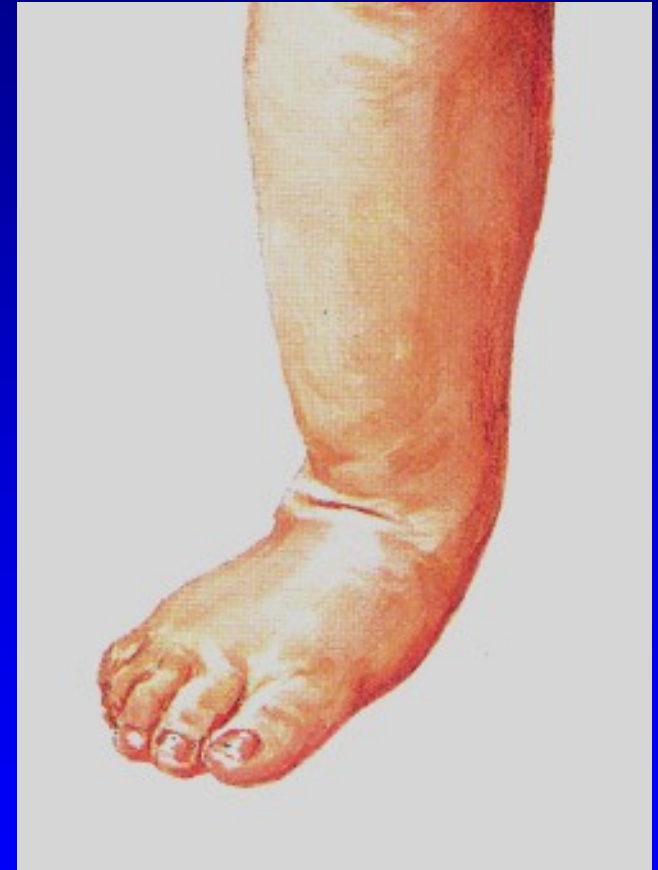3-6 years

Weak muscles of the calf

Valgosity of the heel

Talus is medially and plantarwards

Subluxation of navicular bone



In small children - pes planovalgus

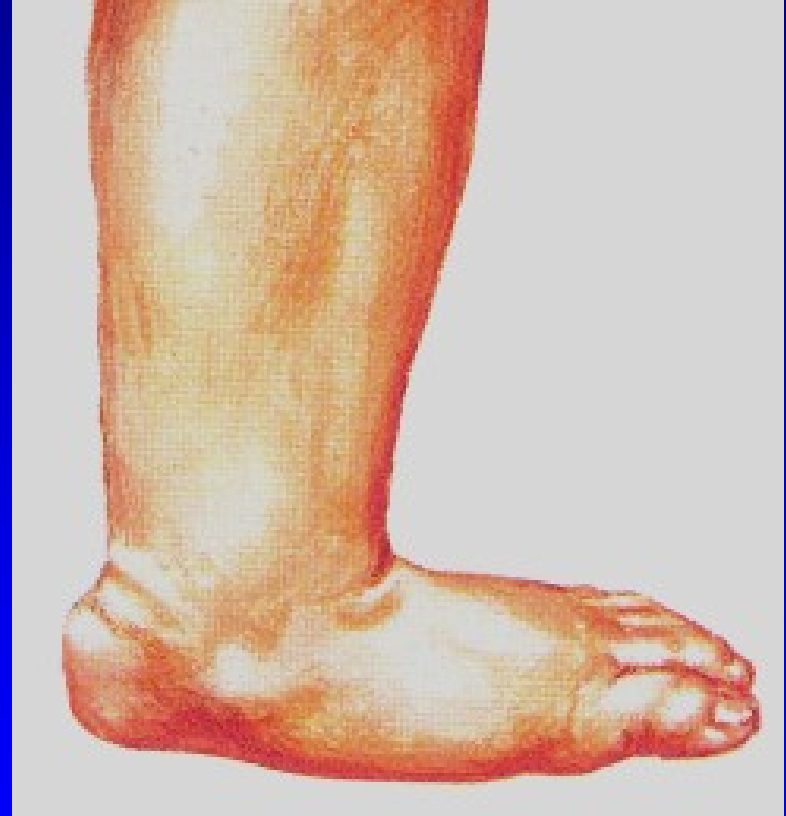
Symptoms:

Asymptomatic

Fatigue

Contractures of the muscles

Pain in the calf



Management

1.-2. stage

Exercise

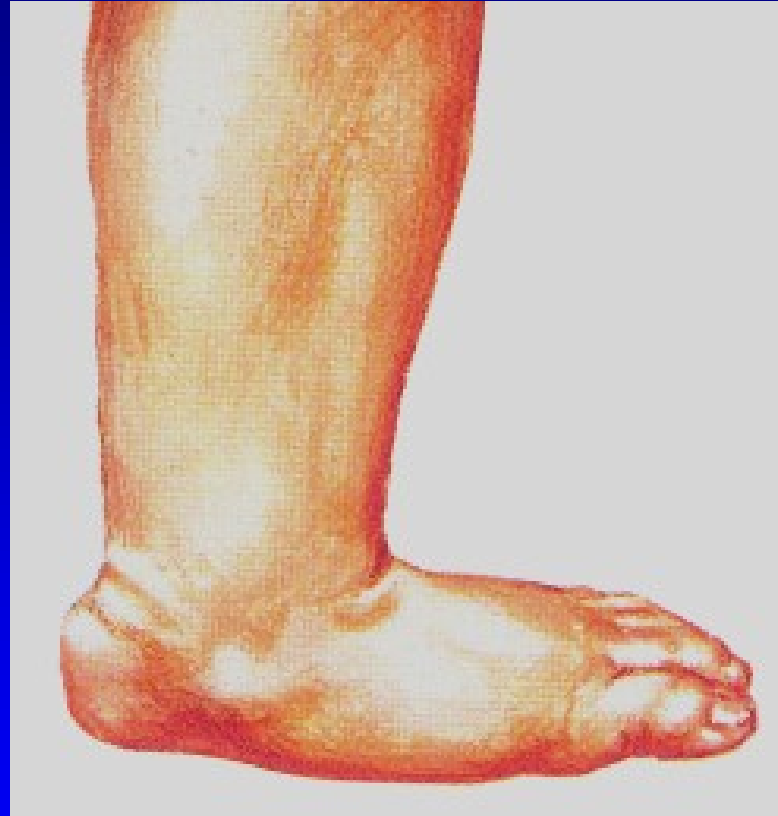Good shoes

Firm heel

Barfoot walking

Not to overload

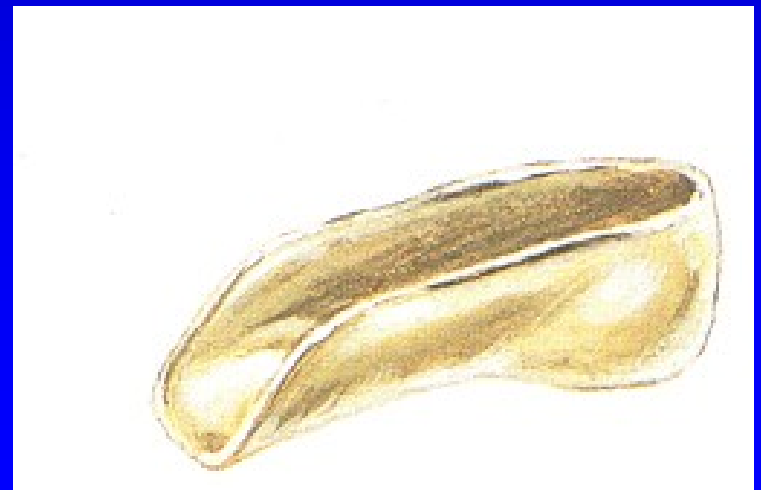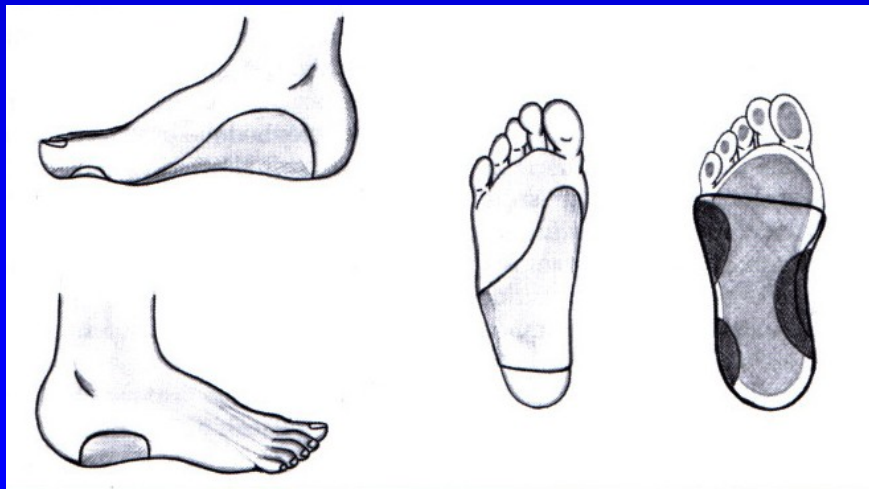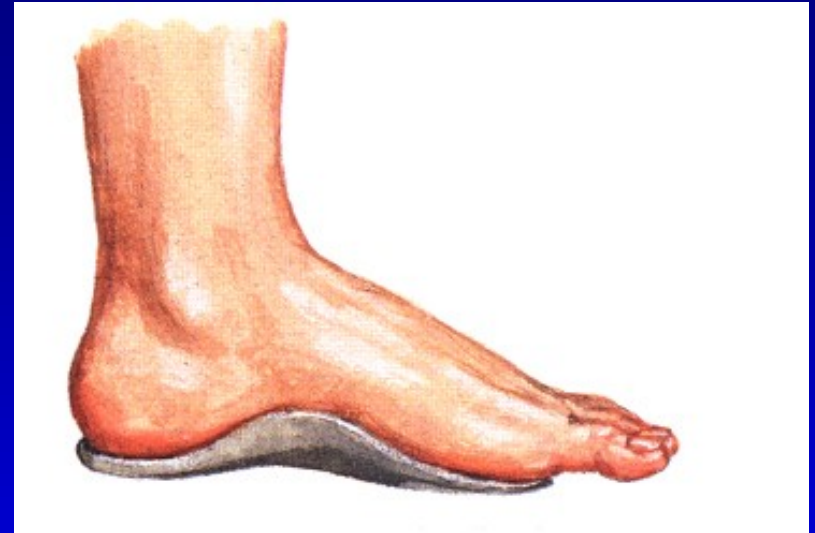
Stretching of m. triceps surae



Management

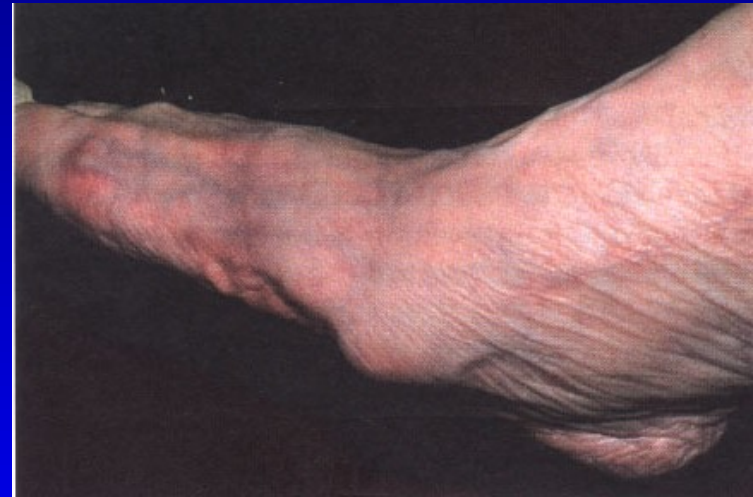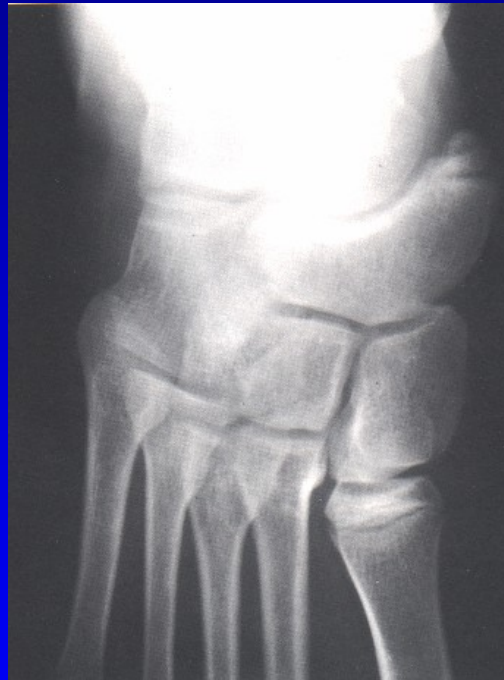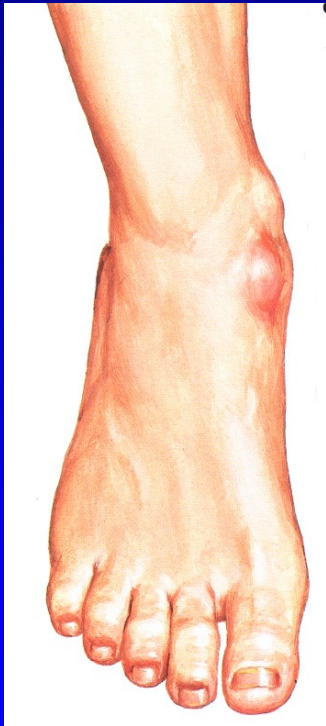
3. stage

Supports



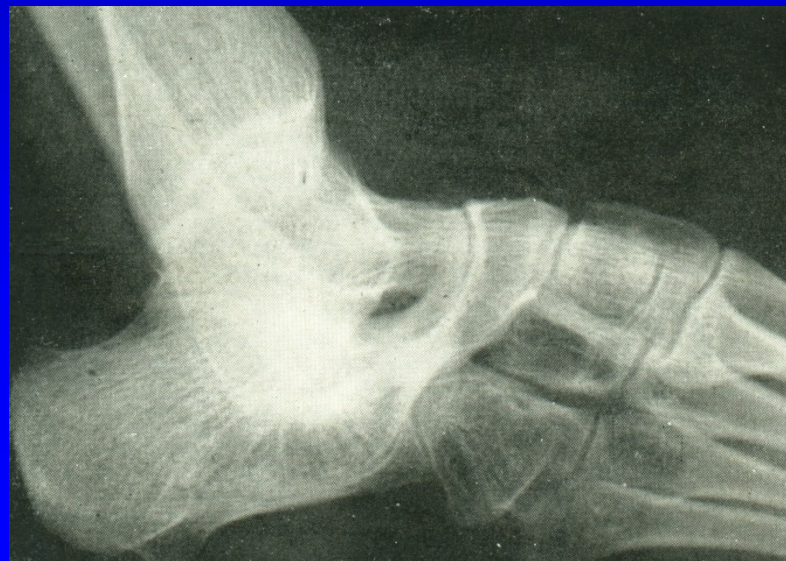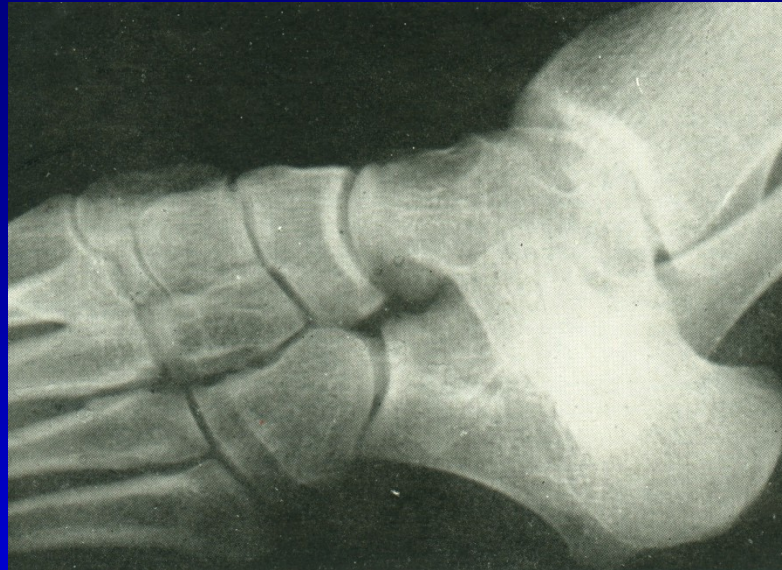Os tibiale externum

Can lead to the flat foot



Peroneal spastic flat foot

Tarsal coalition



Flat foot in adults

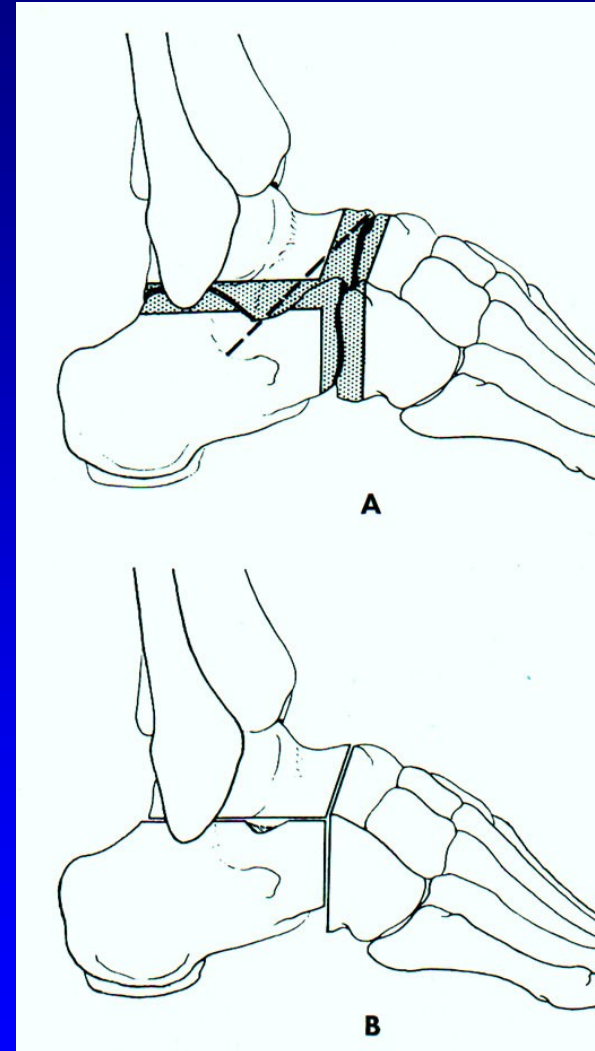
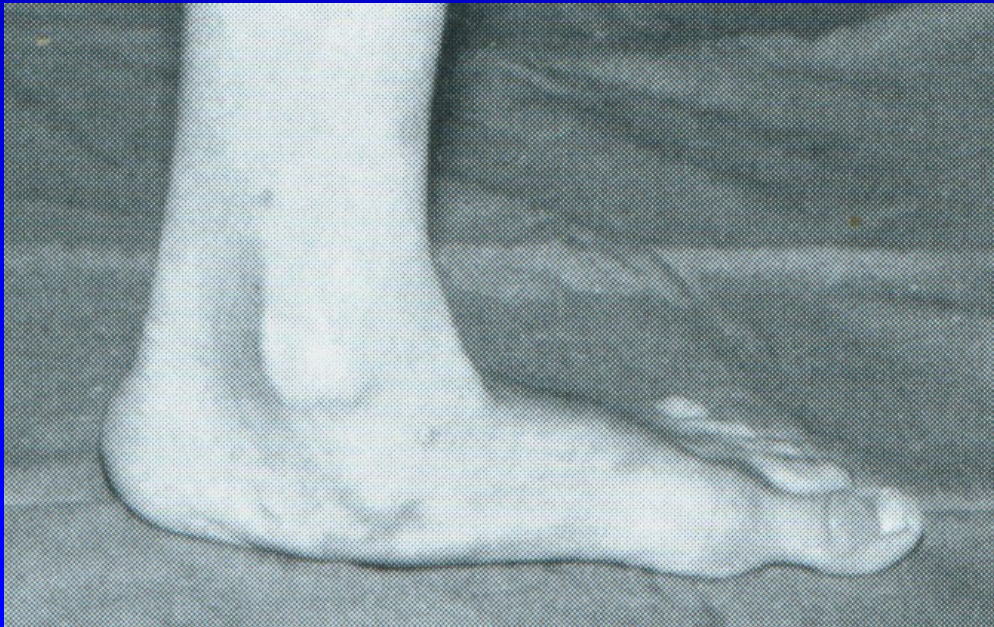Diminished weight bearing

Good shoes

Physiotherapy

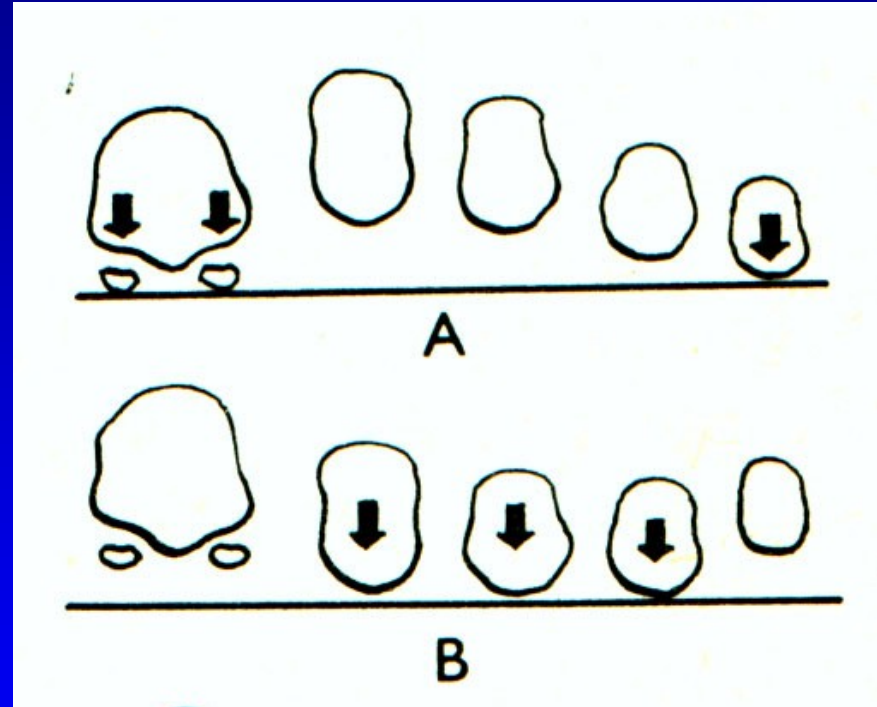
Supports

Surgery- triple arthrodesis



Transverse flat foot

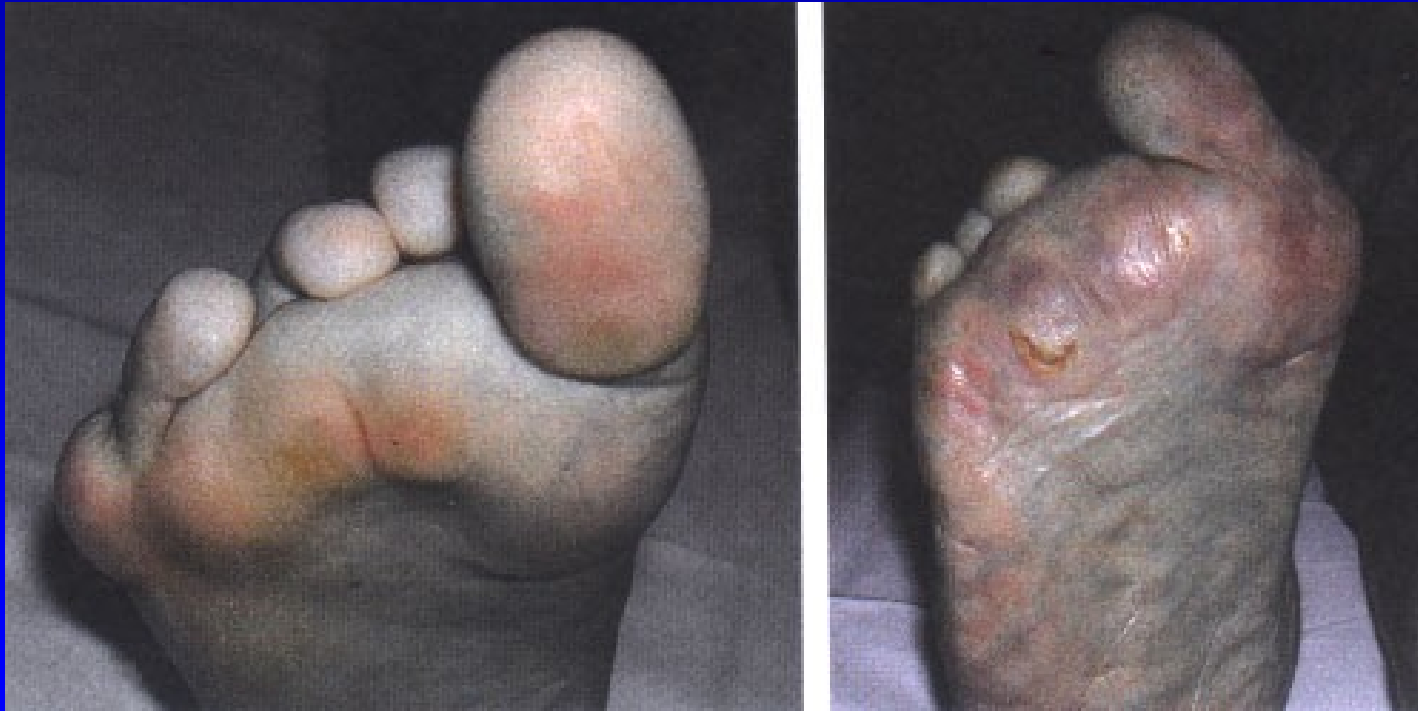Normal arch of metatarsal heads



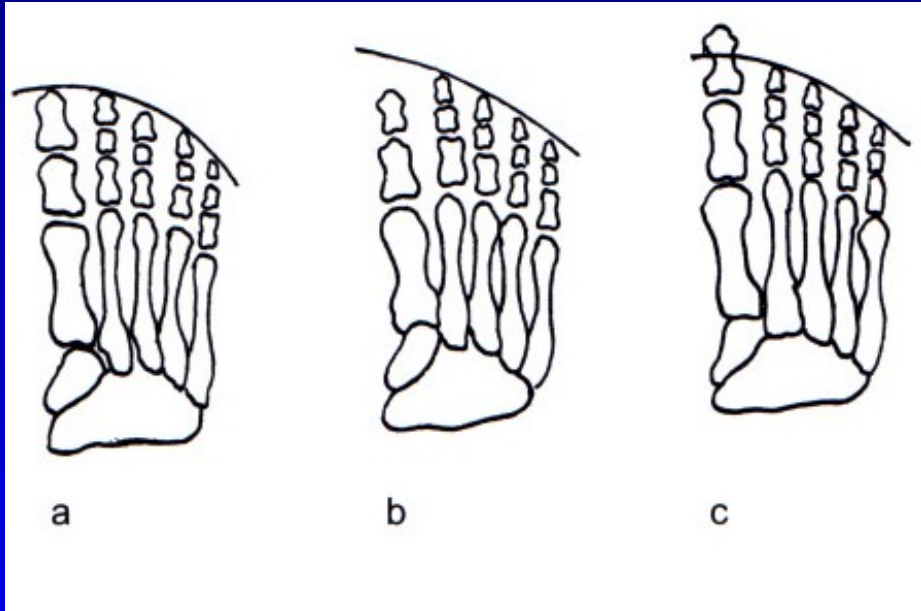
Arch of metatarsal heads
in transverse flat foot

Pes transversoplanus

Prominence of metatarsal heads
Callosities

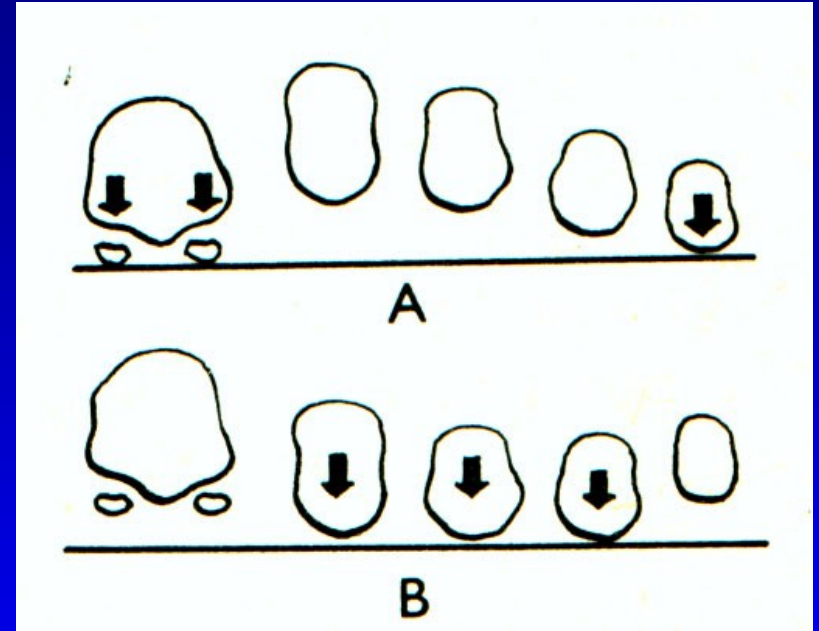
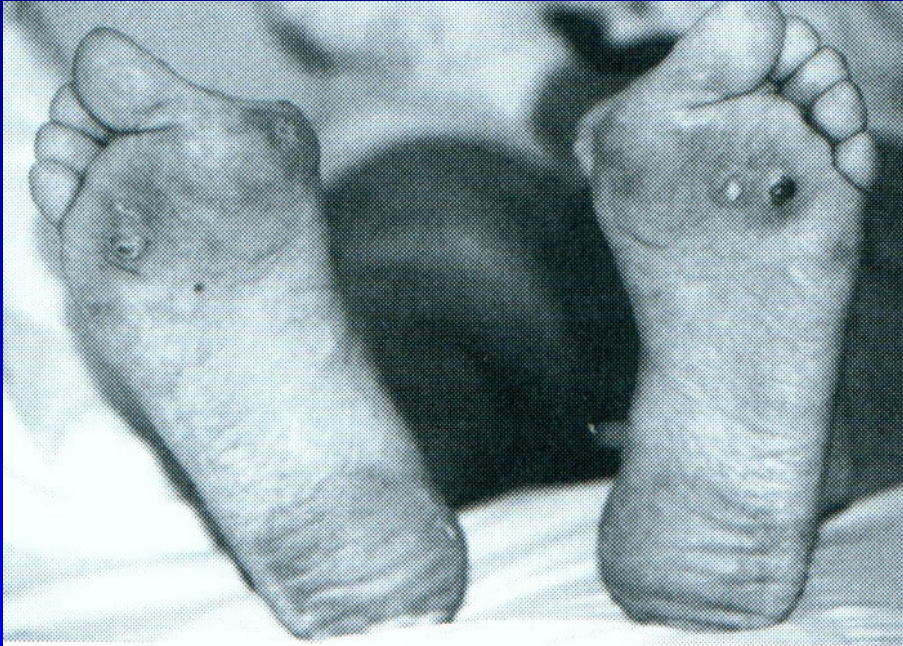

Types of the foot



- a quadratic
- b greece
- c egyptian

Transverse flat foot



Management

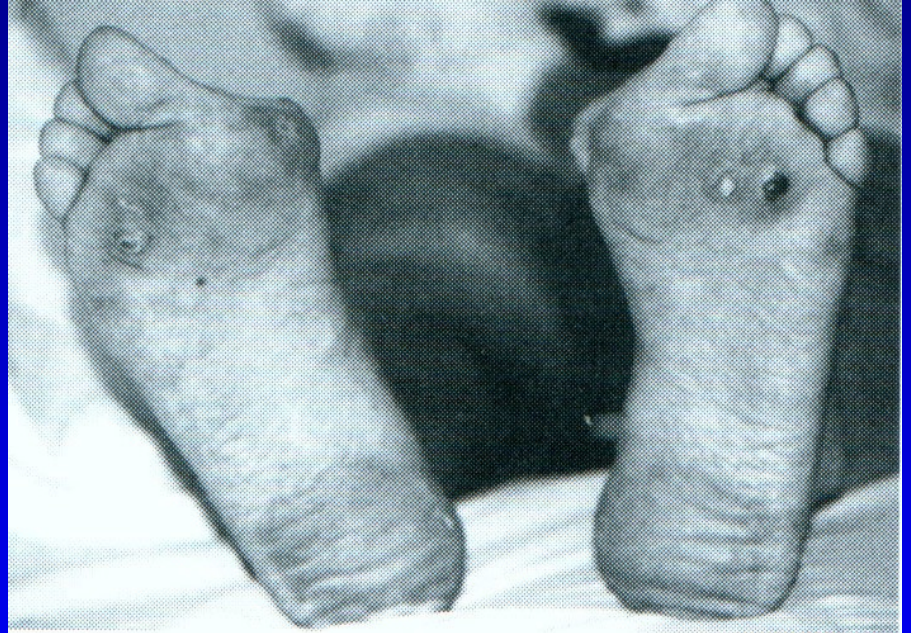Diminished weight bearing

Good shoes

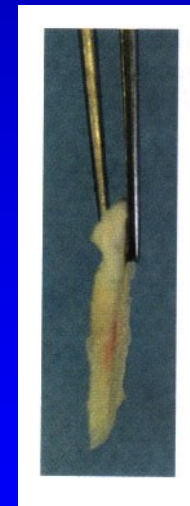
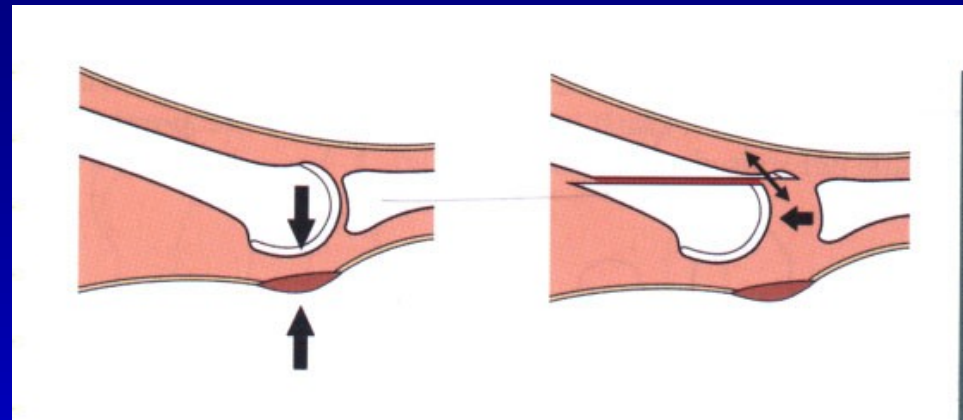
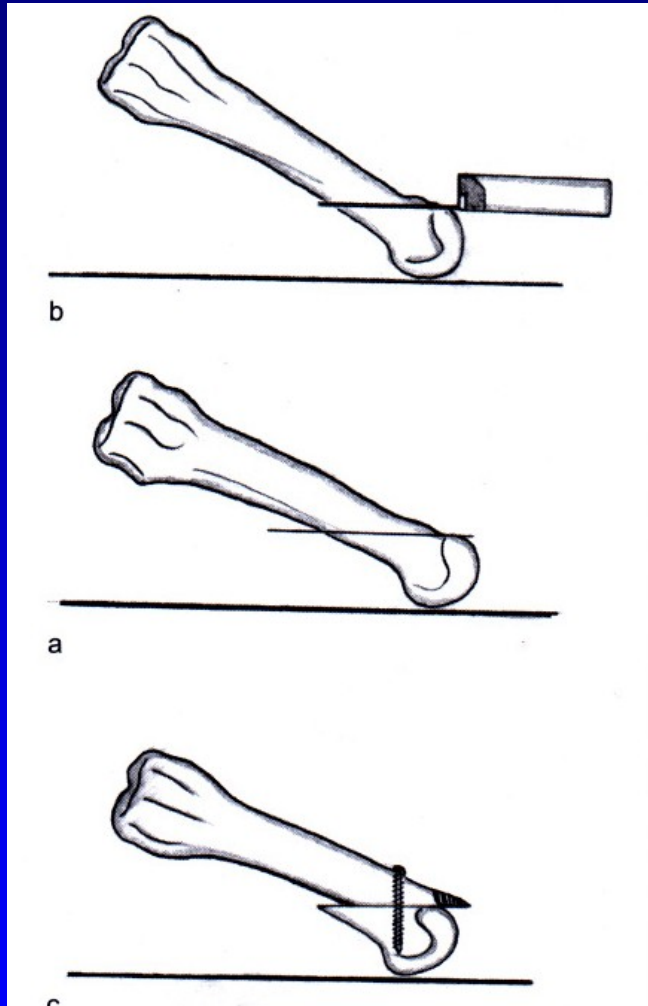
Physiotherapy

Supports

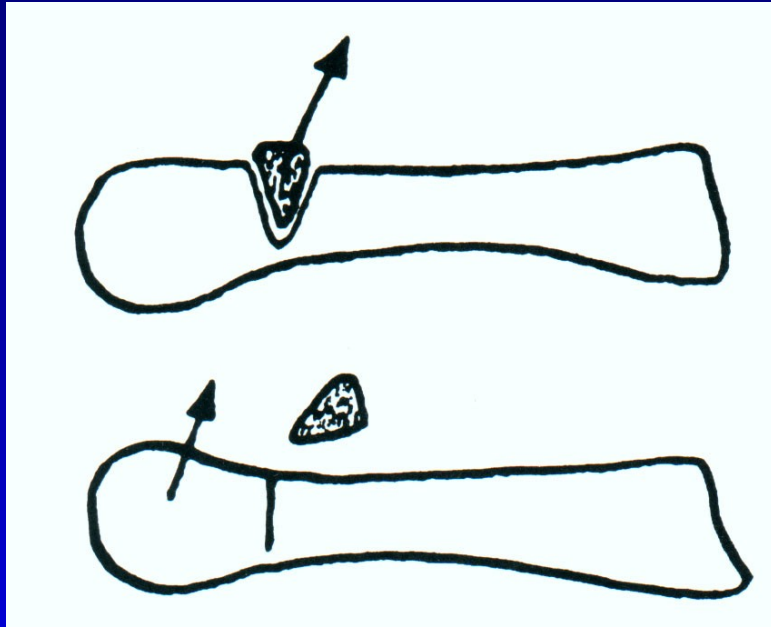
Surgery



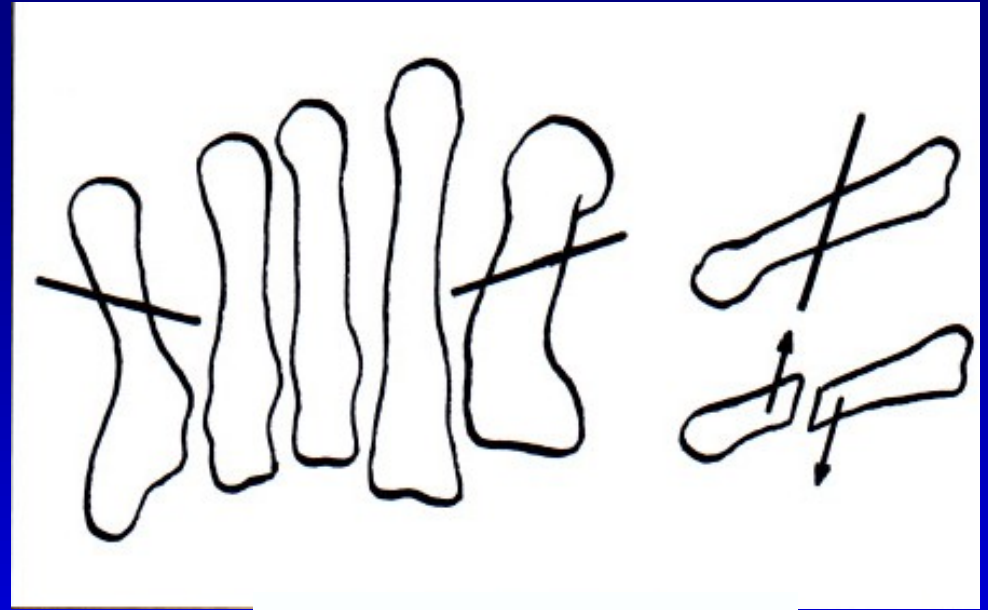
Weil osteotomy



Surgery

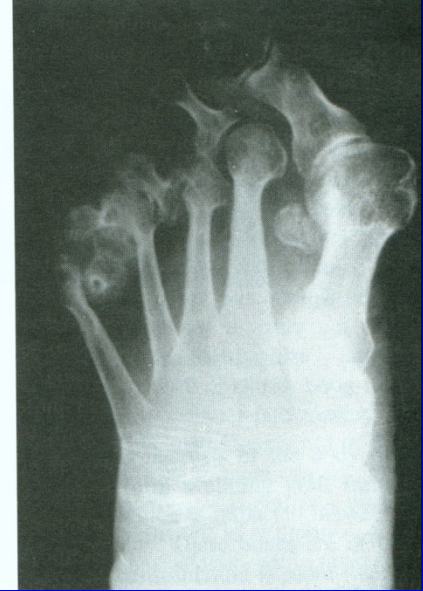
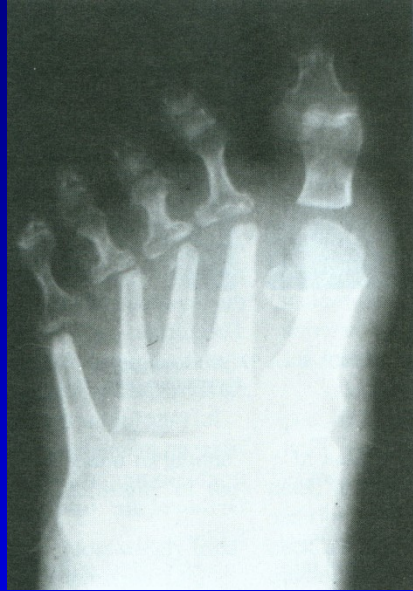
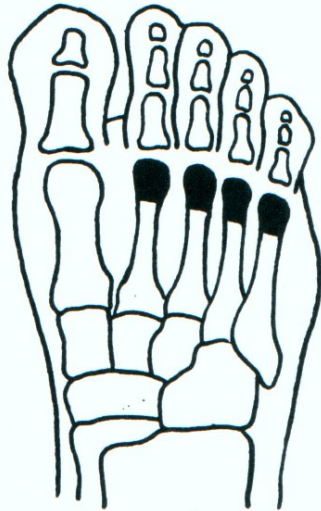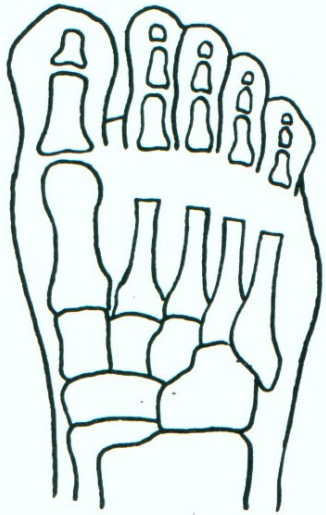Obr. 53 Wolf osteotomy

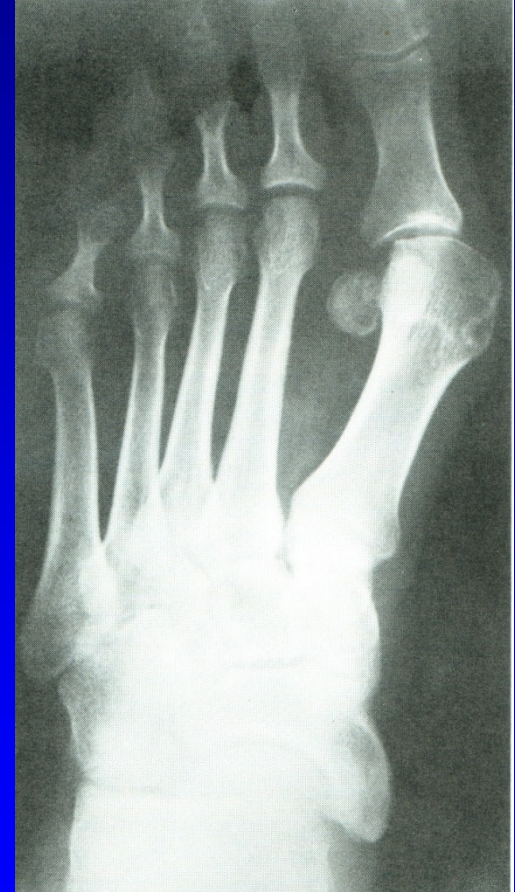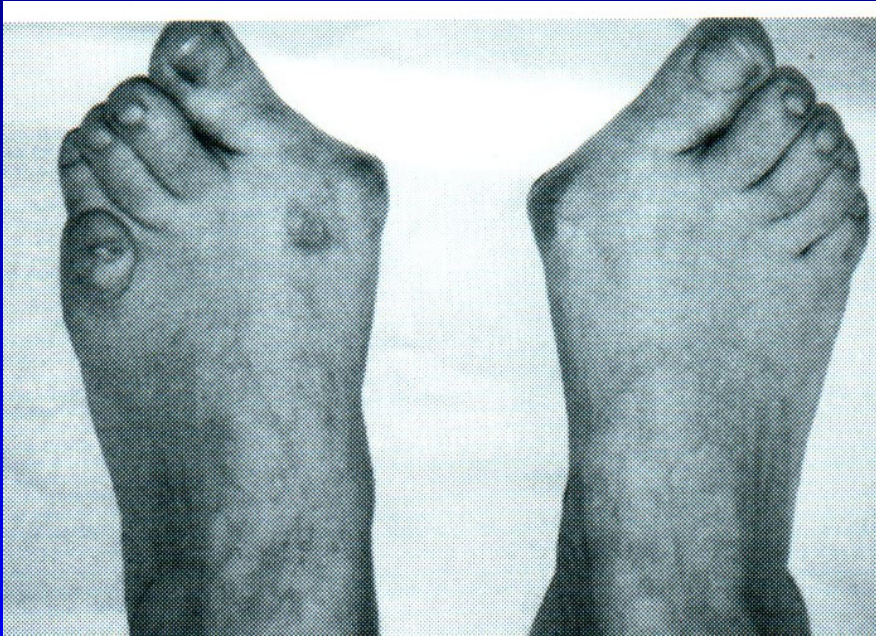


Helal osteotomy

Resection of metatarsal heads

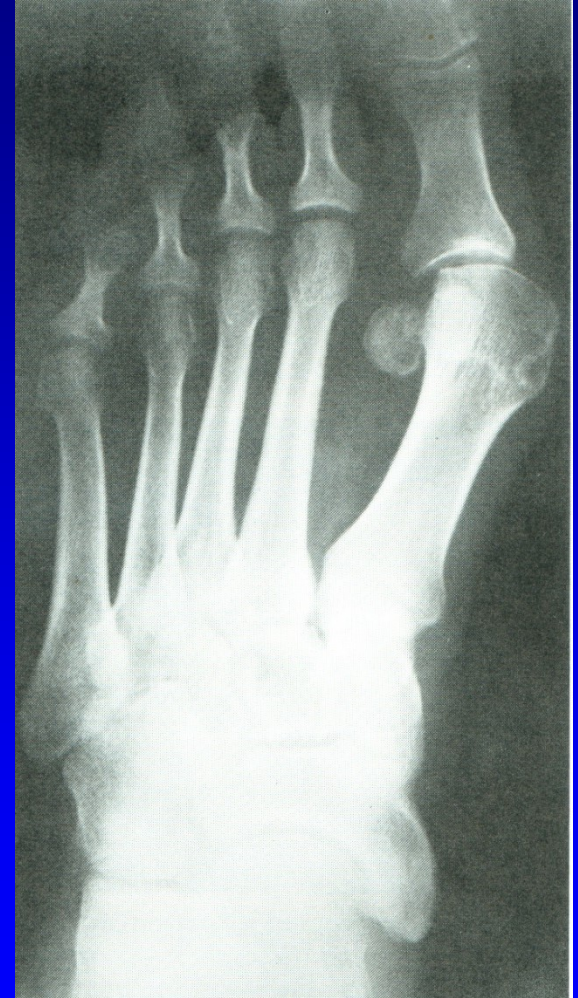

Hallux valgus- bunion



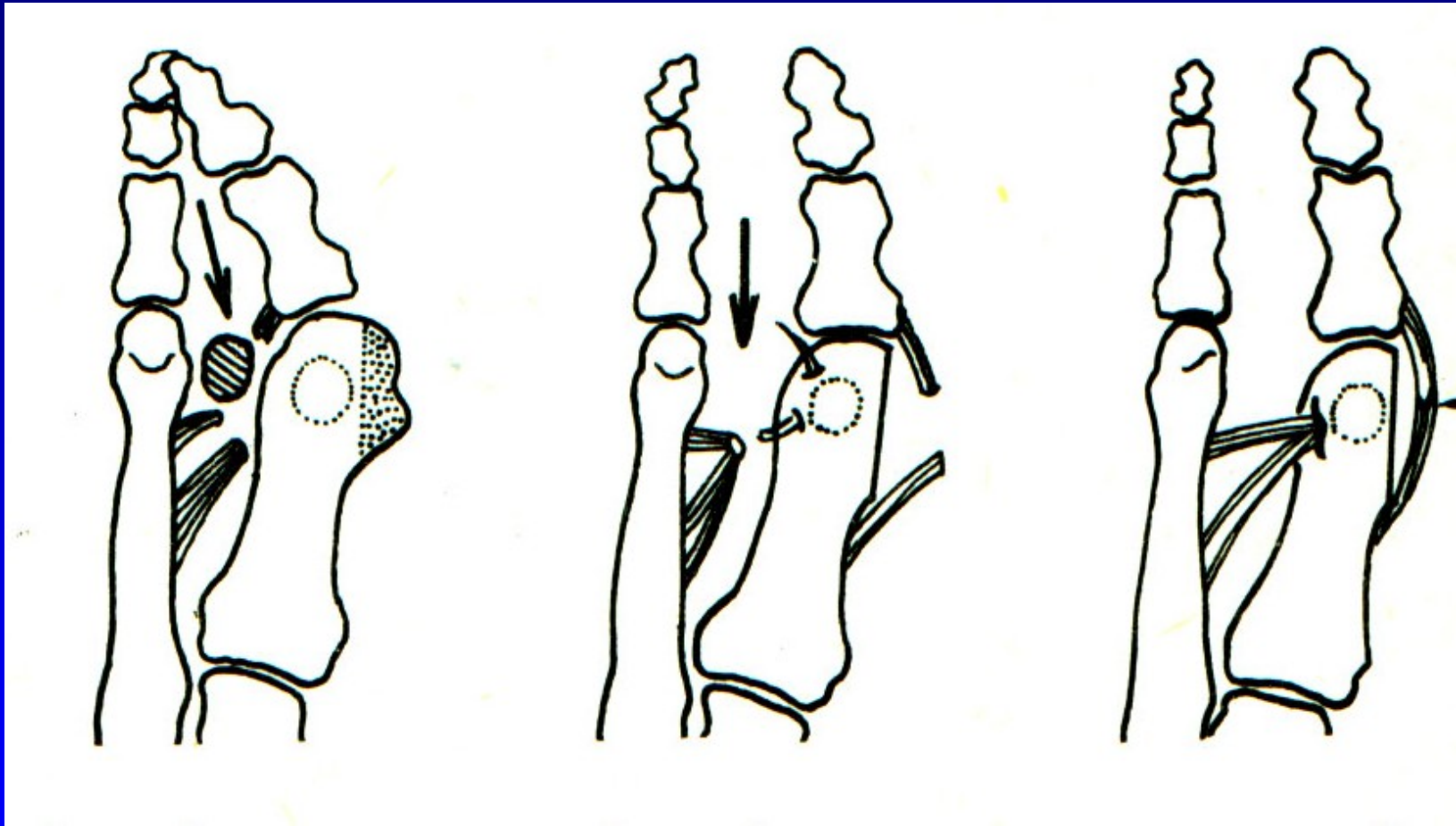
Surgery

Soft tissues
Osteotomies
Resection arthroplasty
Arthrodesis
Joint replacement

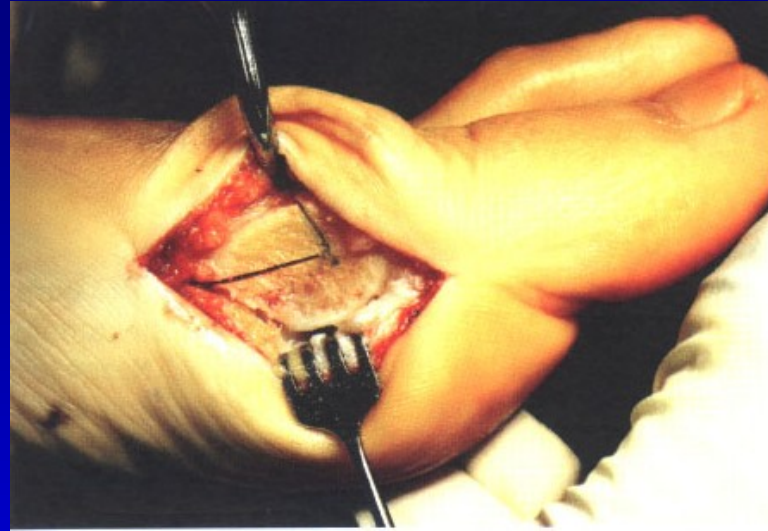


Obr. 61

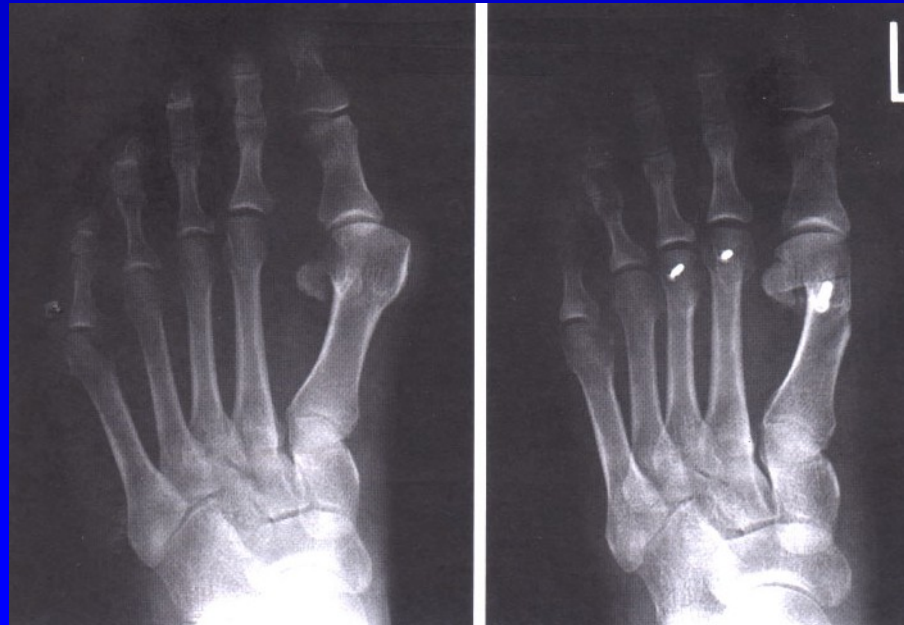
Mc Bride procedure



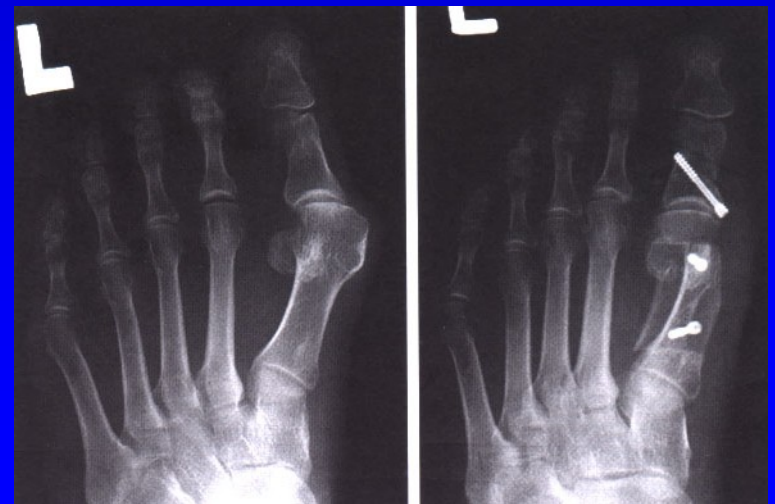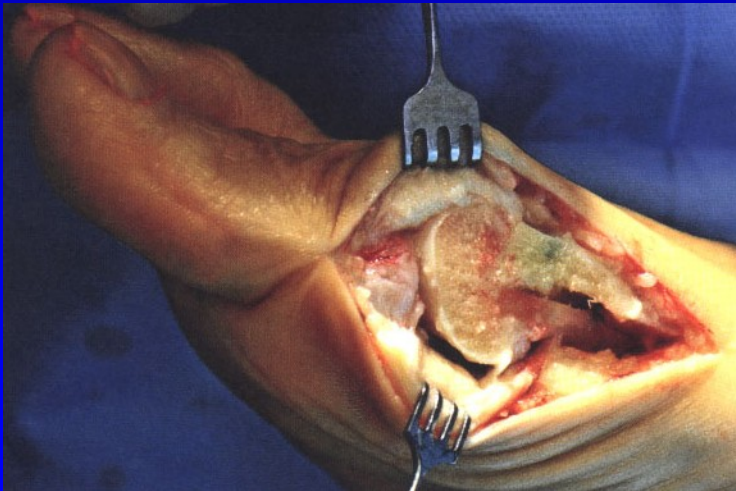
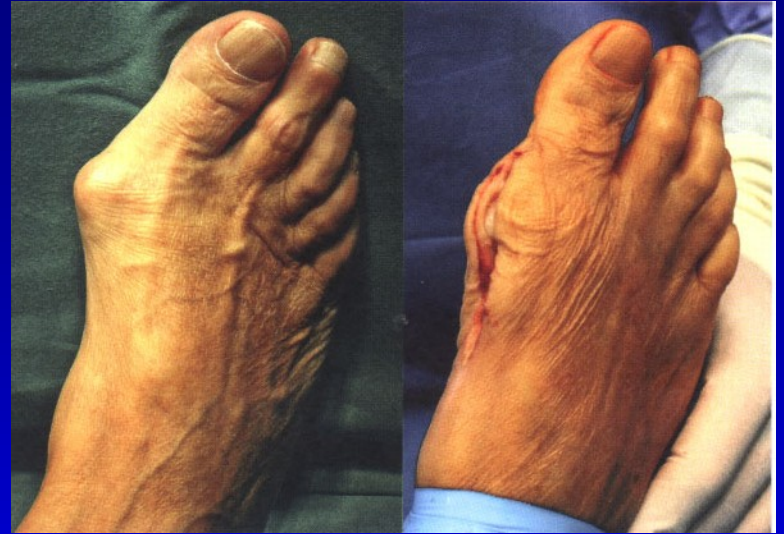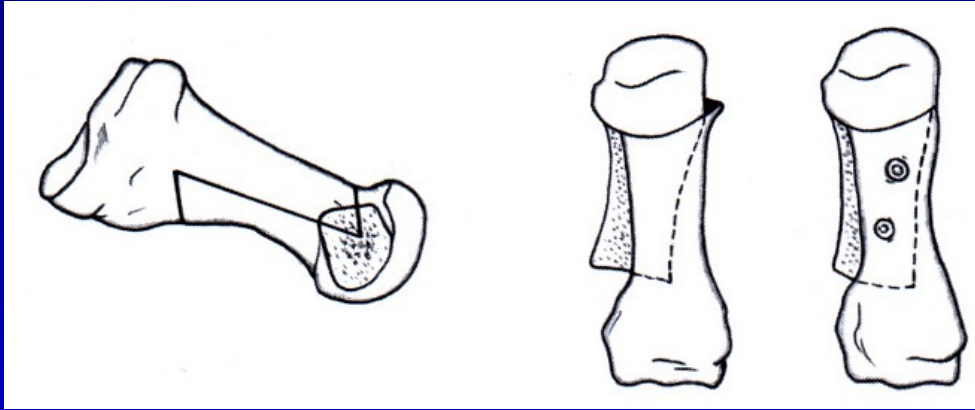
Osteotomy of the first metatarsal



Chevron osteotomy

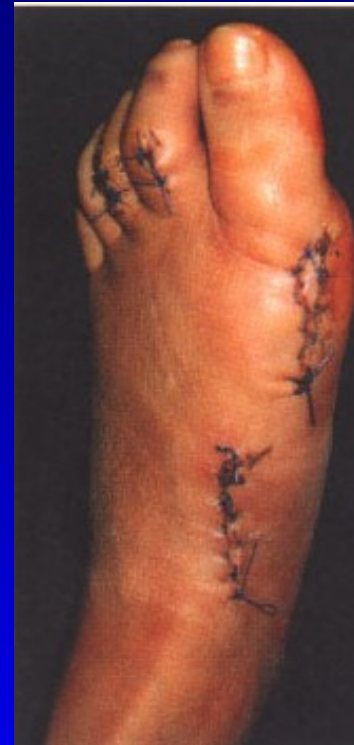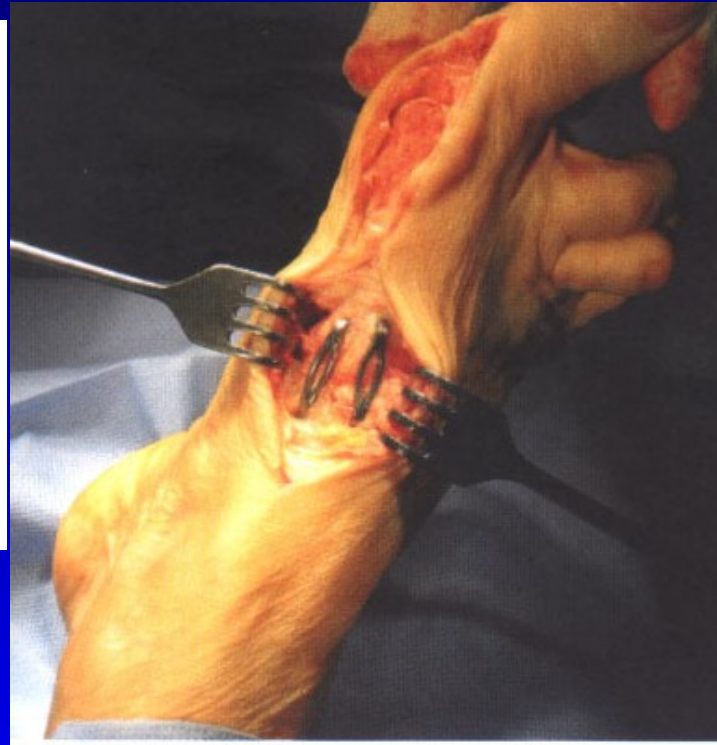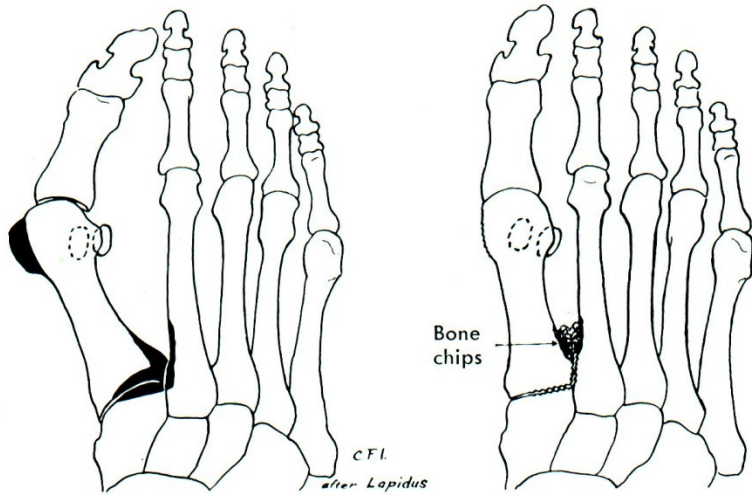


Osteotomy of the first metatarsal

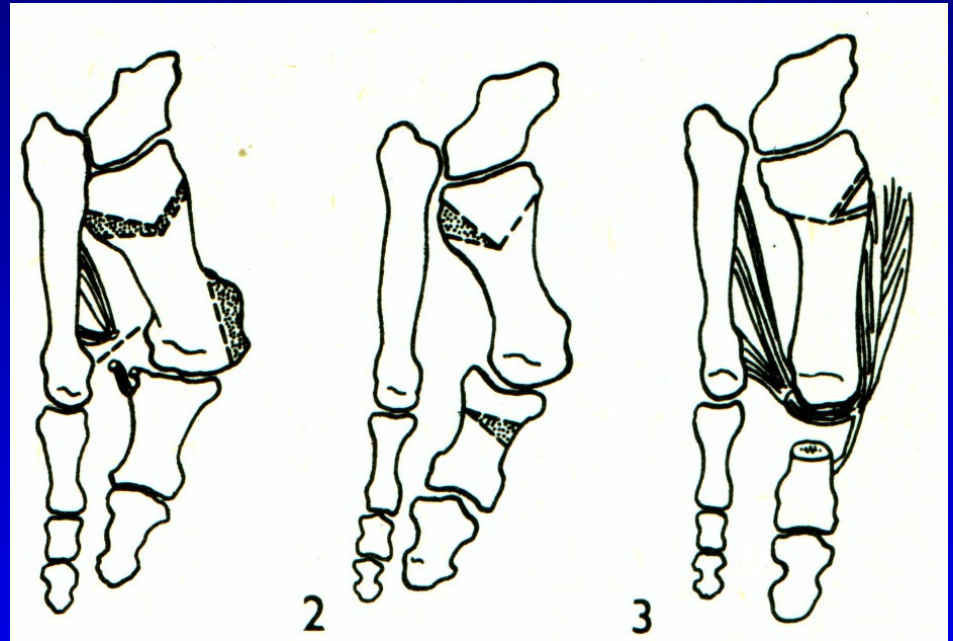
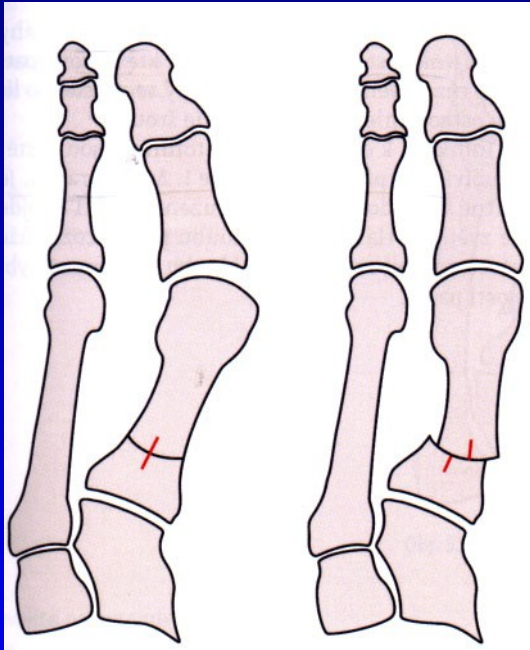


Obr. 64 Scarf osteotomy

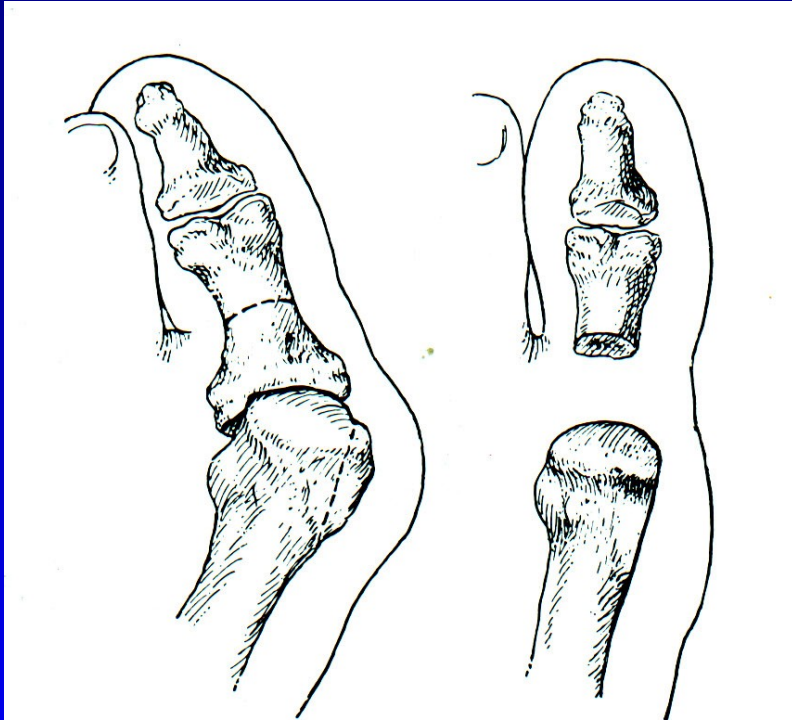
Op. sec. Lapidus



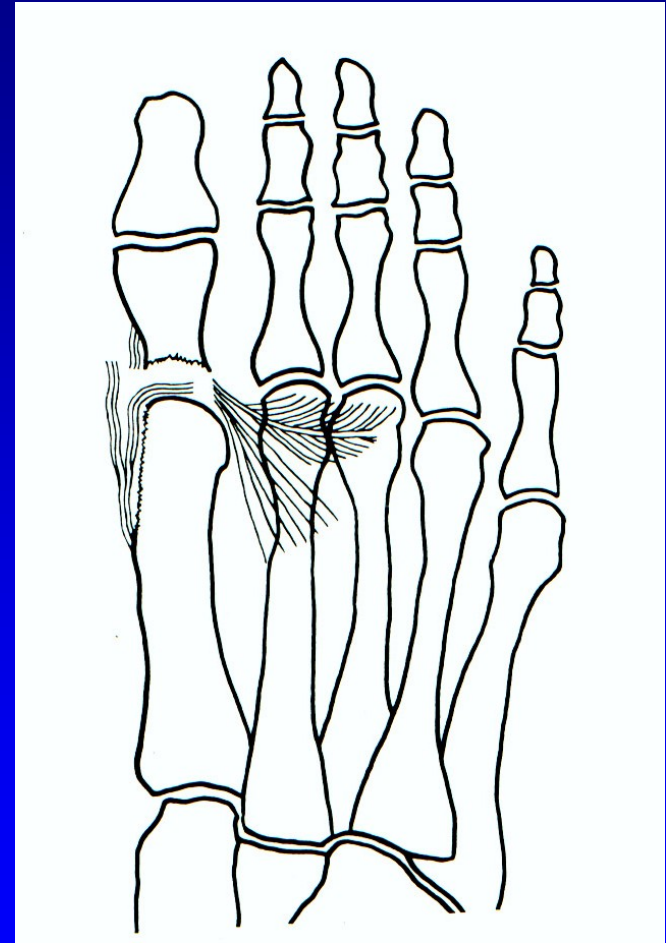
Proximal osteotomy of the first metatarsal



Op. sec. Keller – resection arthroplasty

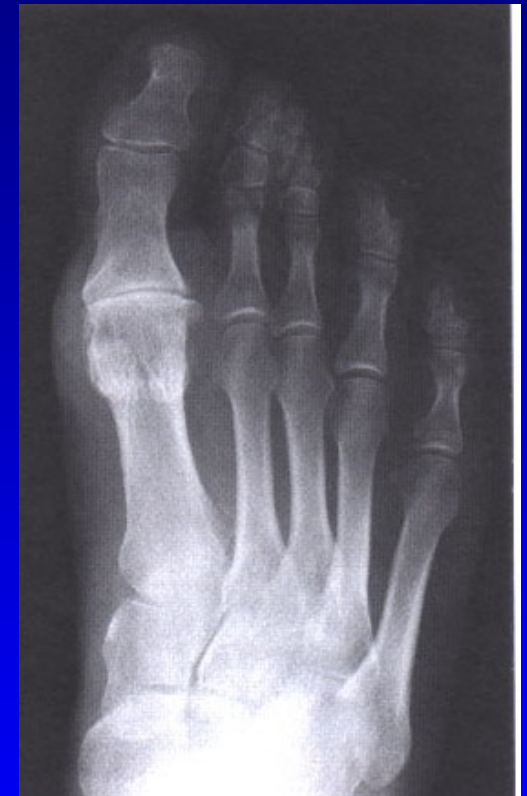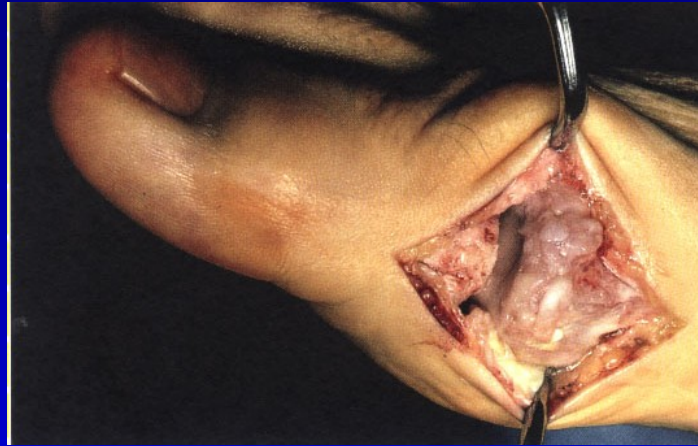

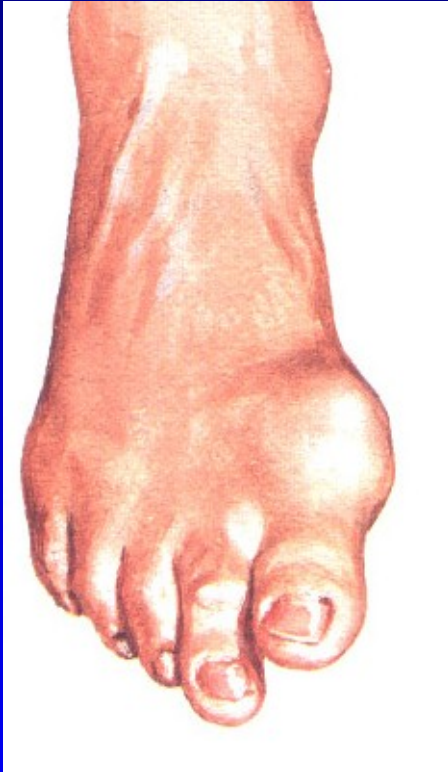
Obr. 67



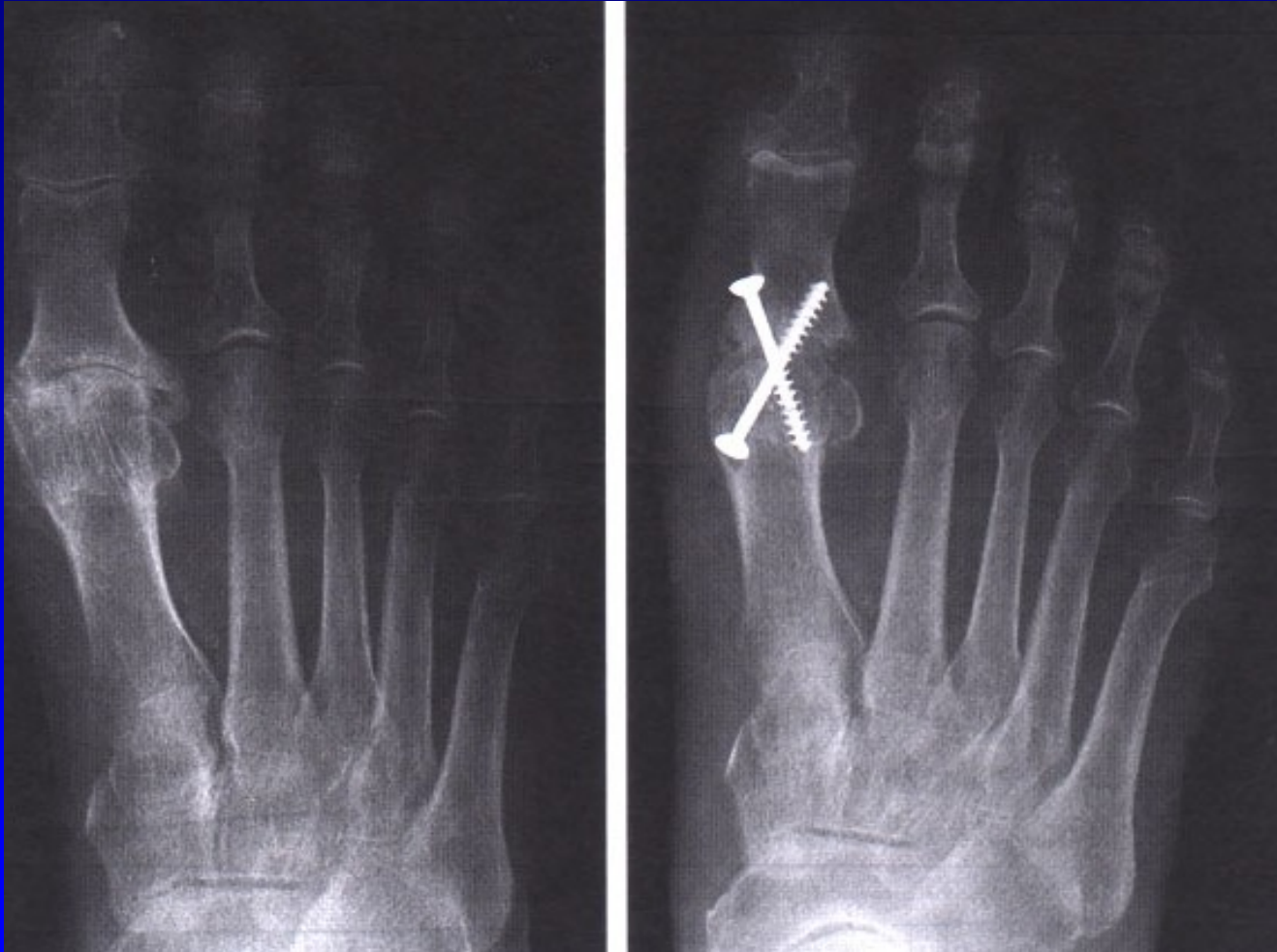
Obr. 68

Hallux rigidus

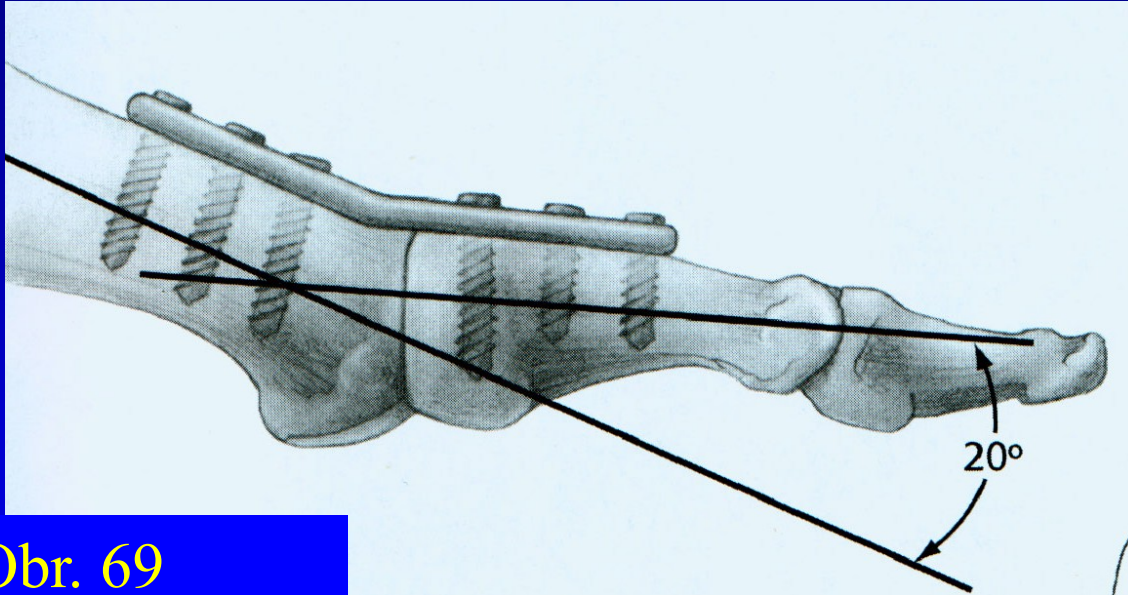


Arthrosis art. MTPPh. I.

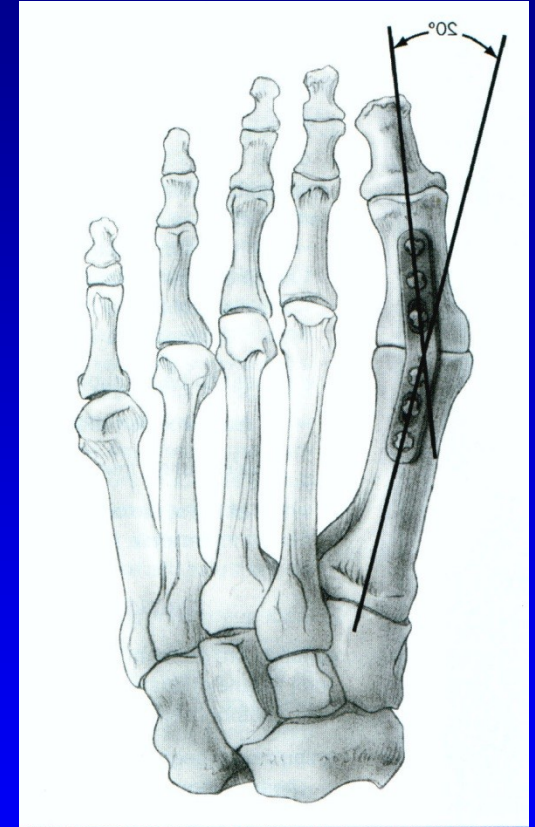
Arthrodesis of the big toe



Arthrodesis of the big toe

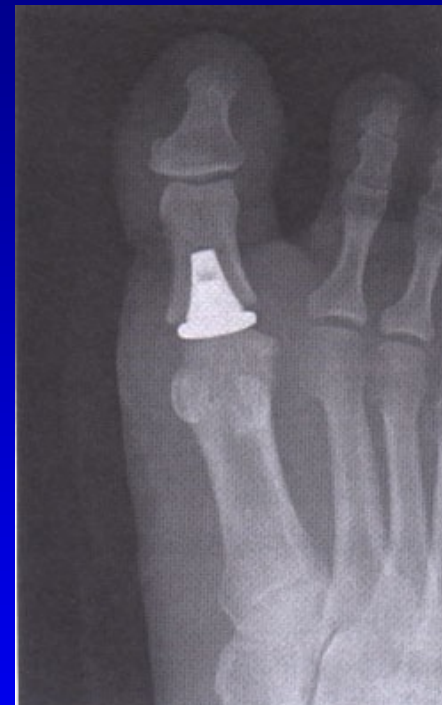
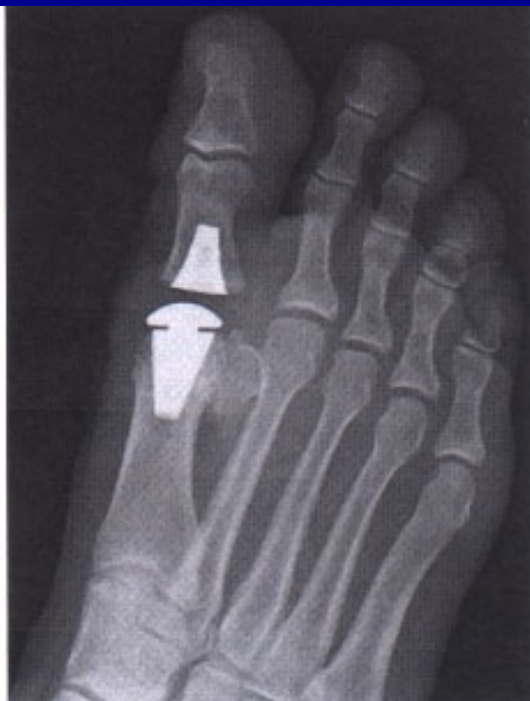
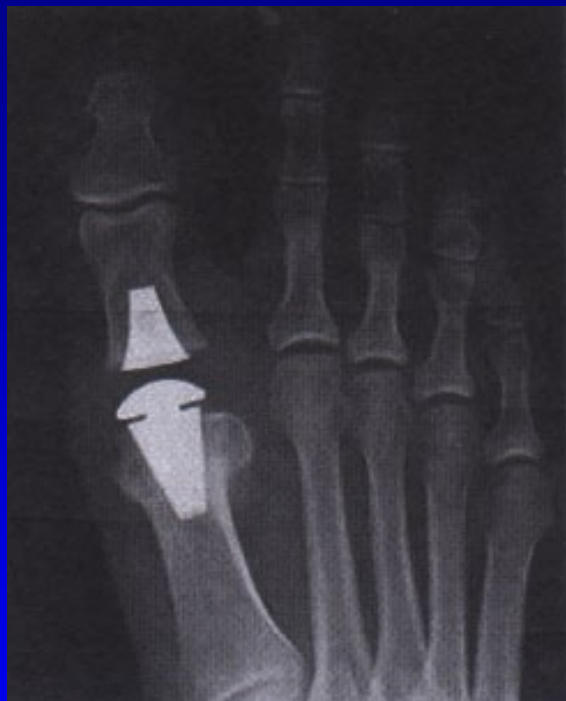Obr. 69



Obr. 70

Replacement of the first metatarsal joint



Deformities of the foot

Pes varus

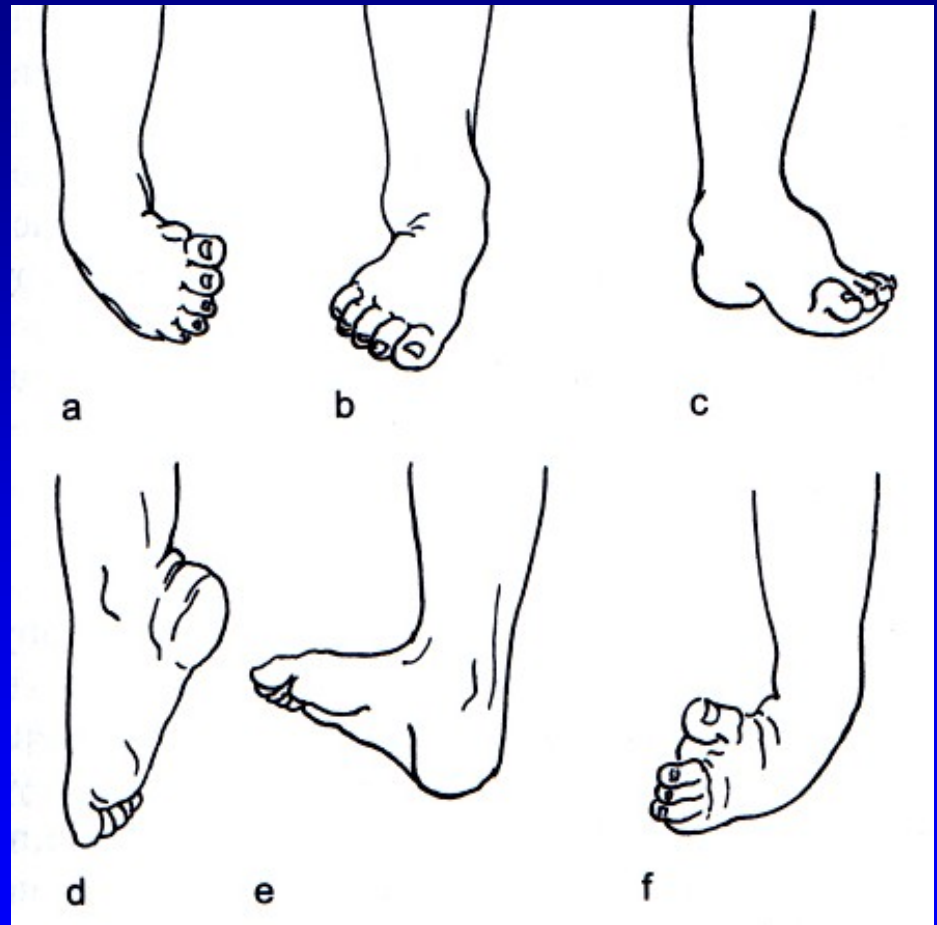
Pes valgus

Pes cavus

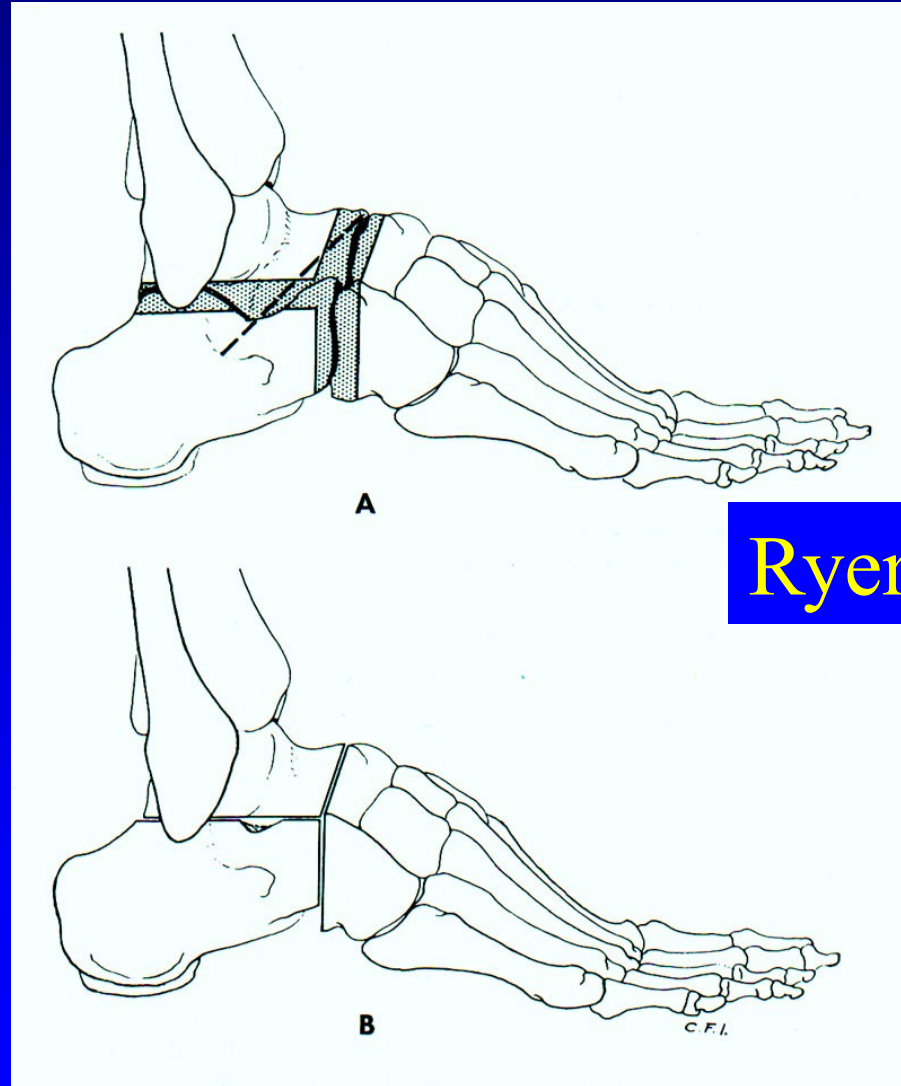
Pes equinus

Pes calcaneus

Pes equinovarus

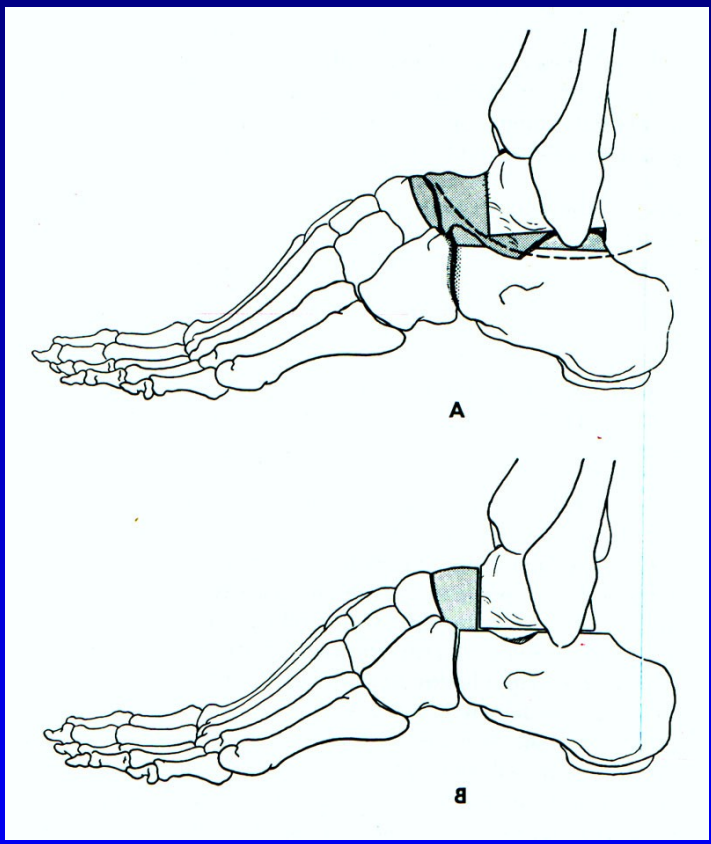


Triple arthrodesis

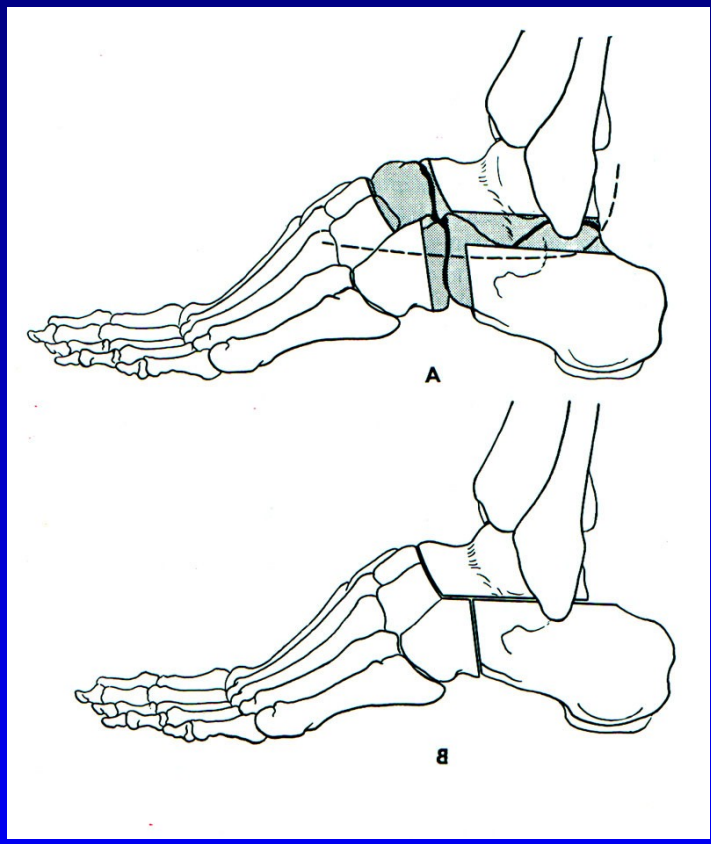


Obr. 74

Triple arthrodesis- modifications

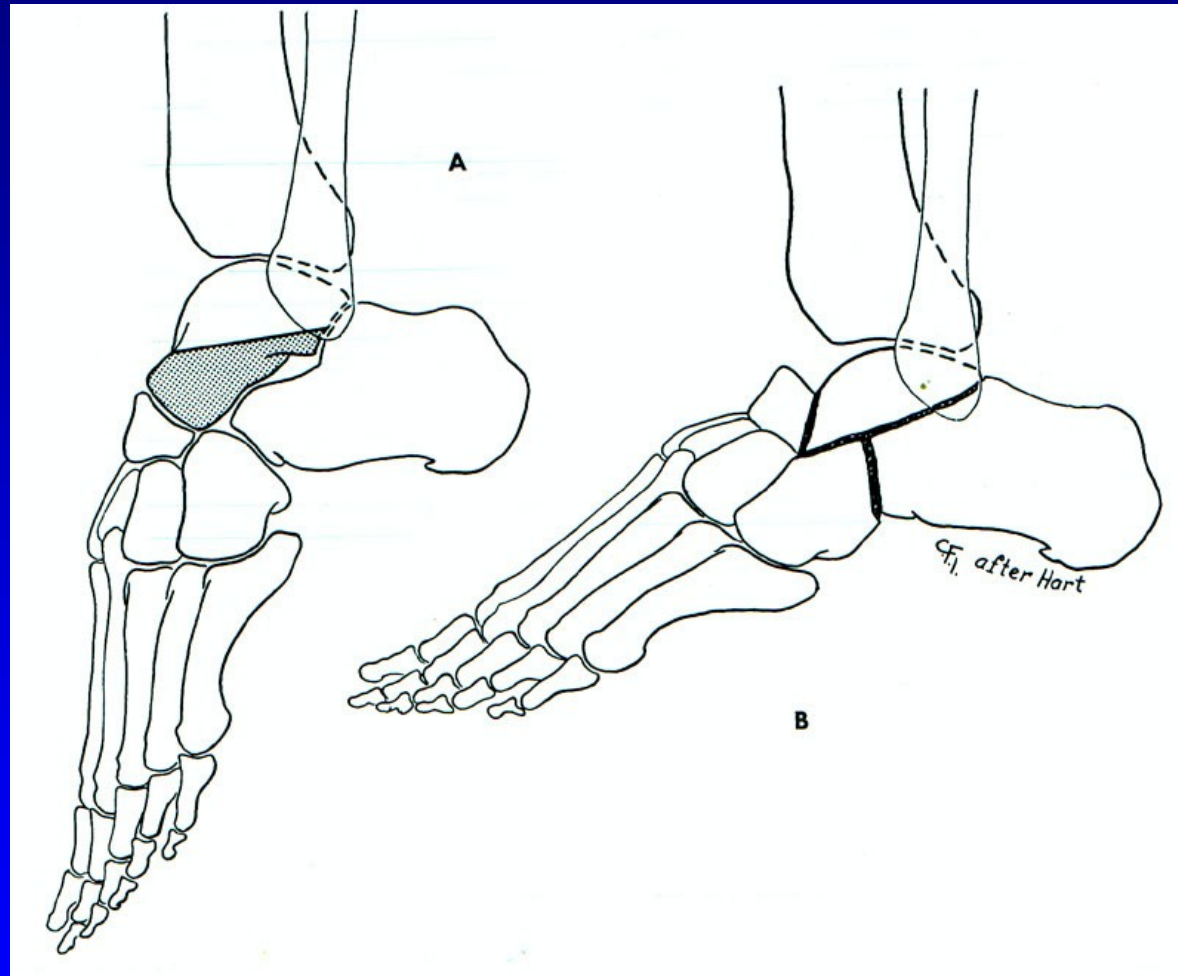


Obr. 75 Dunn



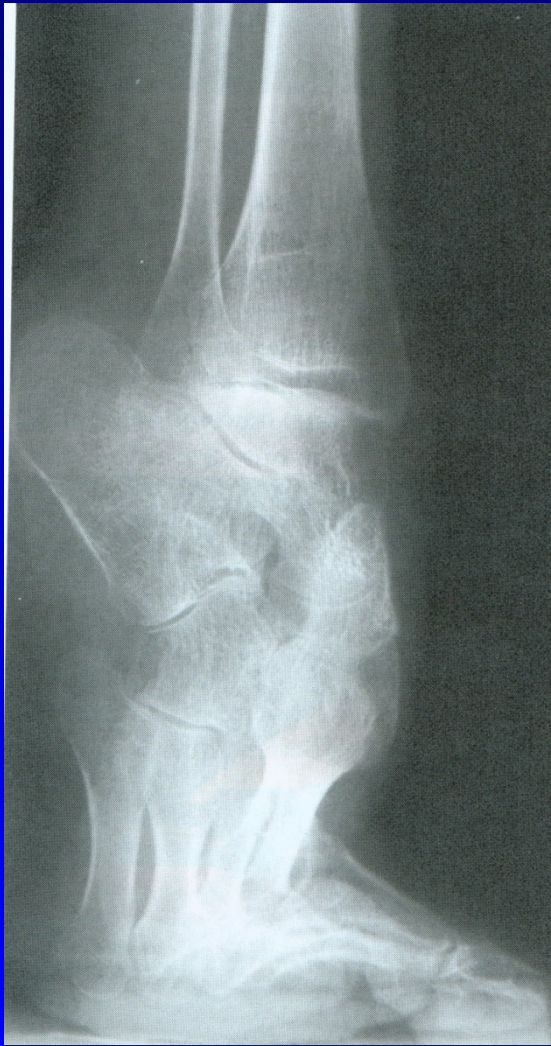Obr. 76 Hoke

Triple arthrodesis

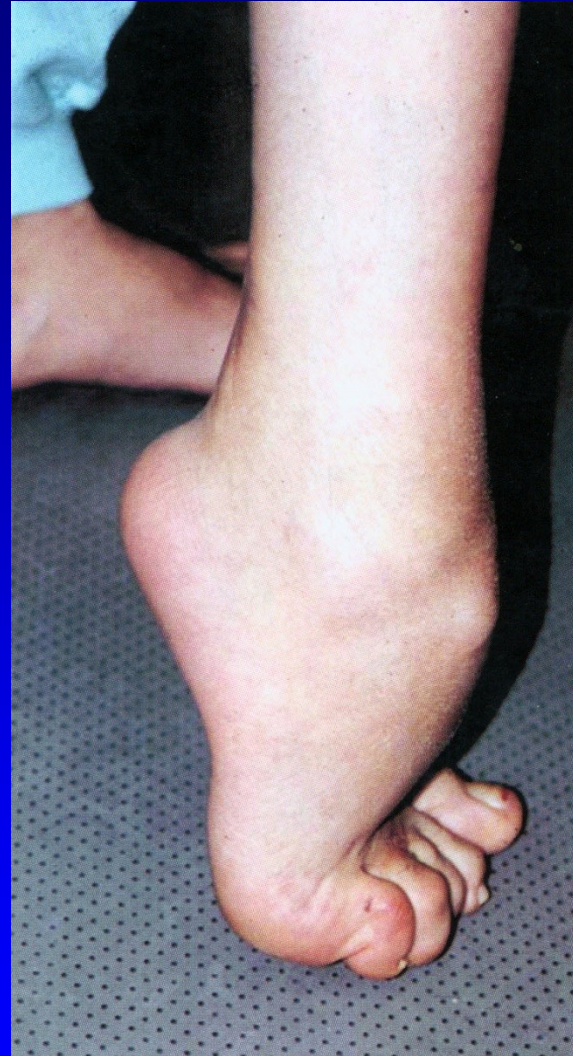

Obr. 77 Lambrinudi

Pes equinus- drop foot

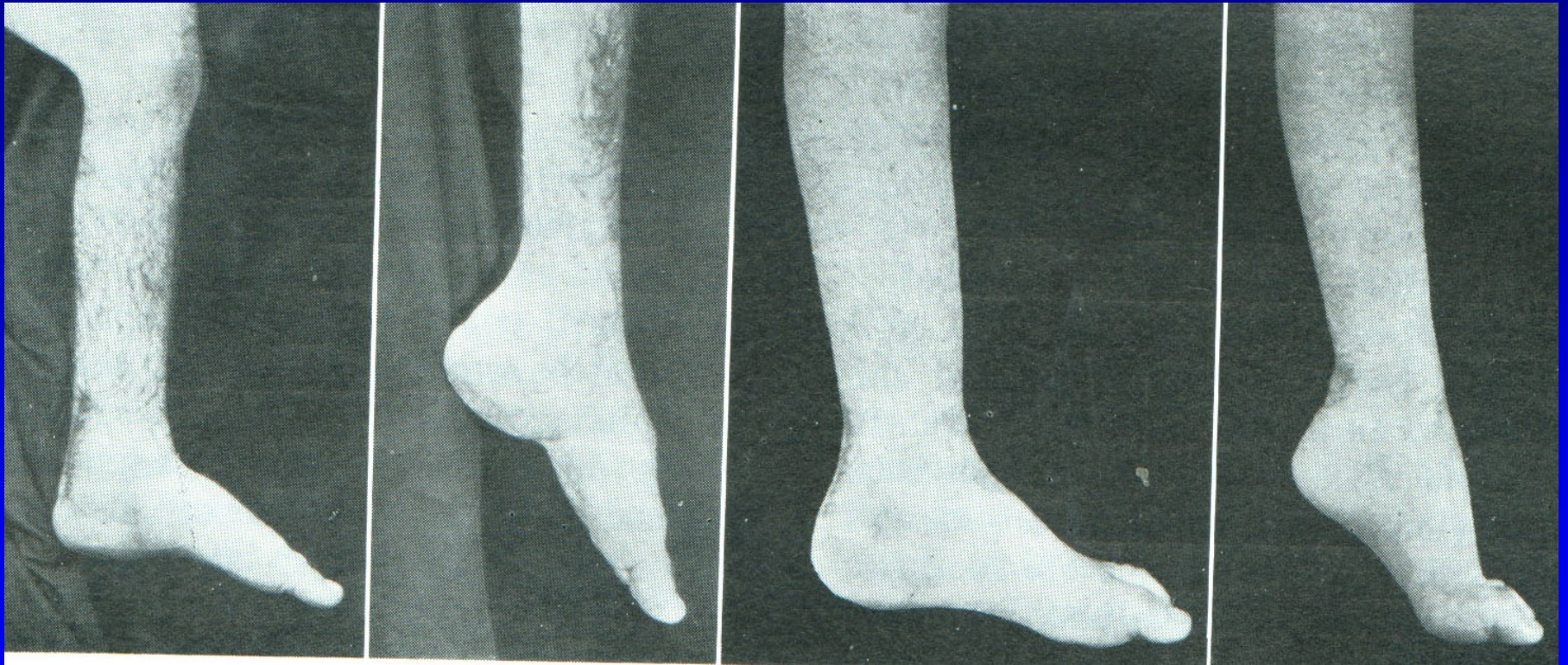

Obr. 78



Obr. 79

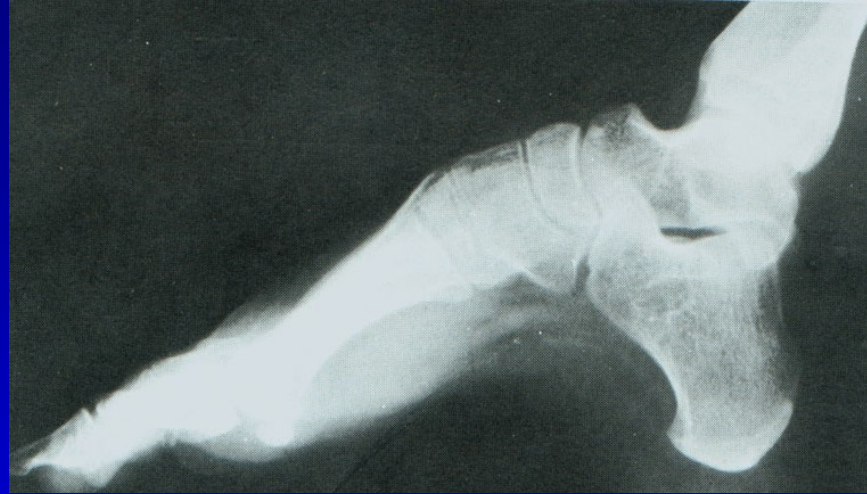Correction of the drop foot by triple arthrodesis



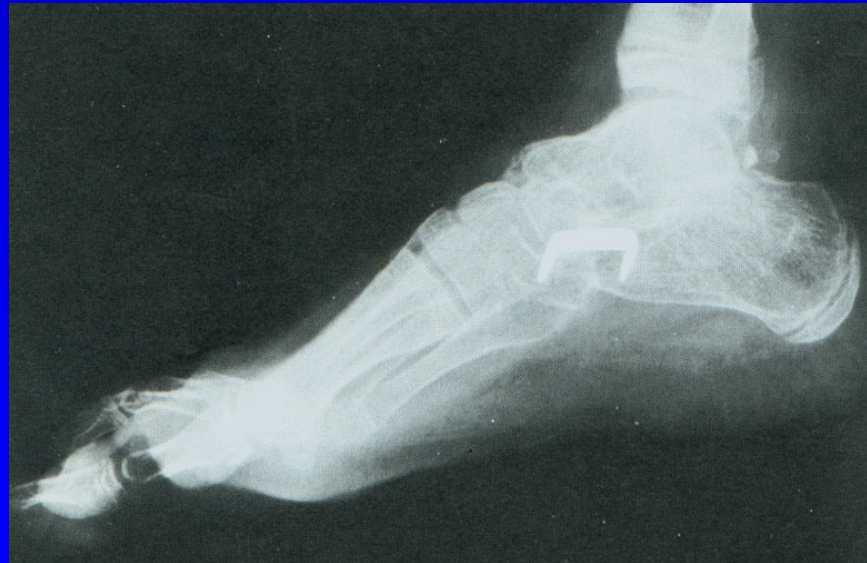Obr. 80

Triple arthrodesis for pes cavus

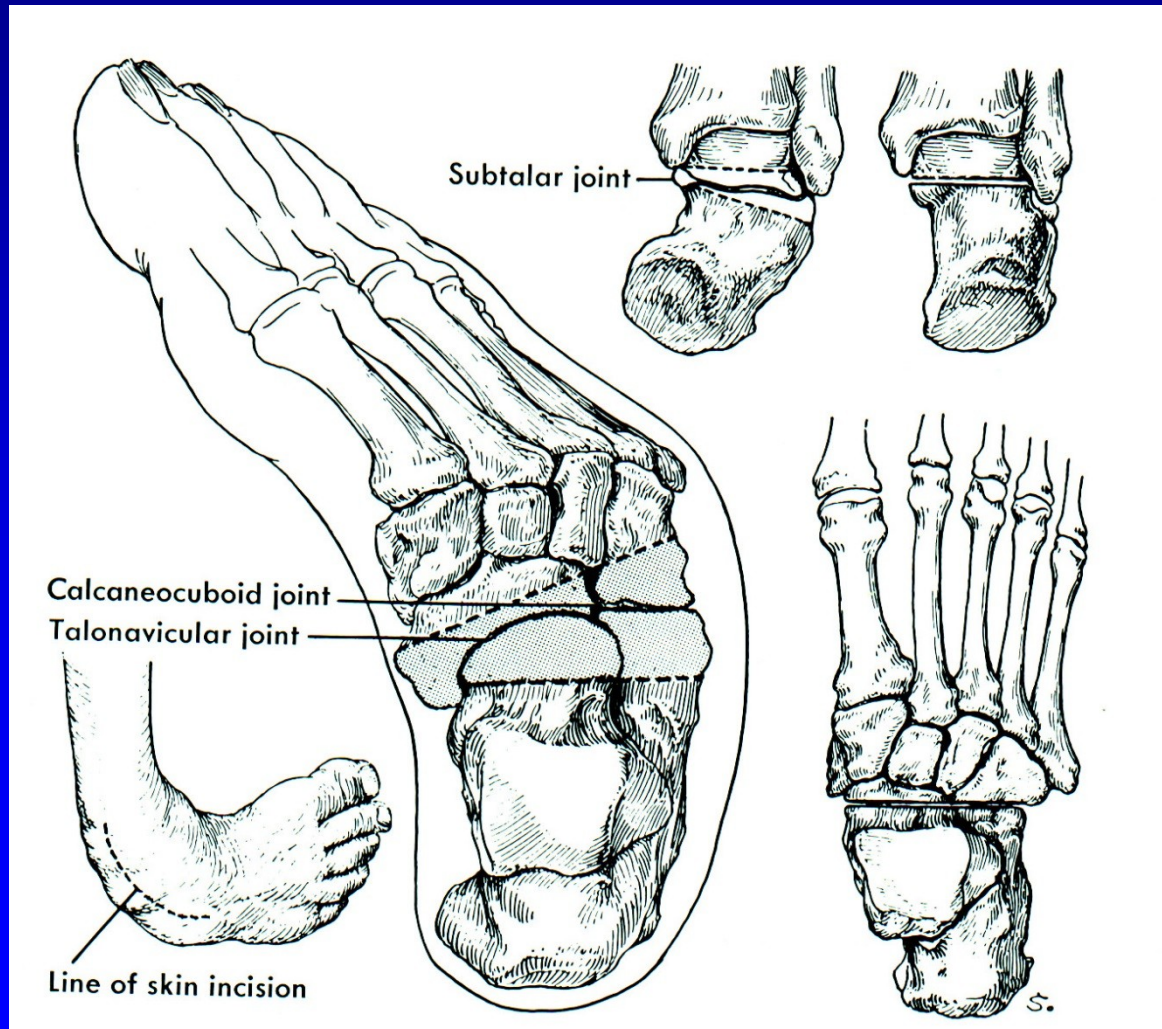
Preop.



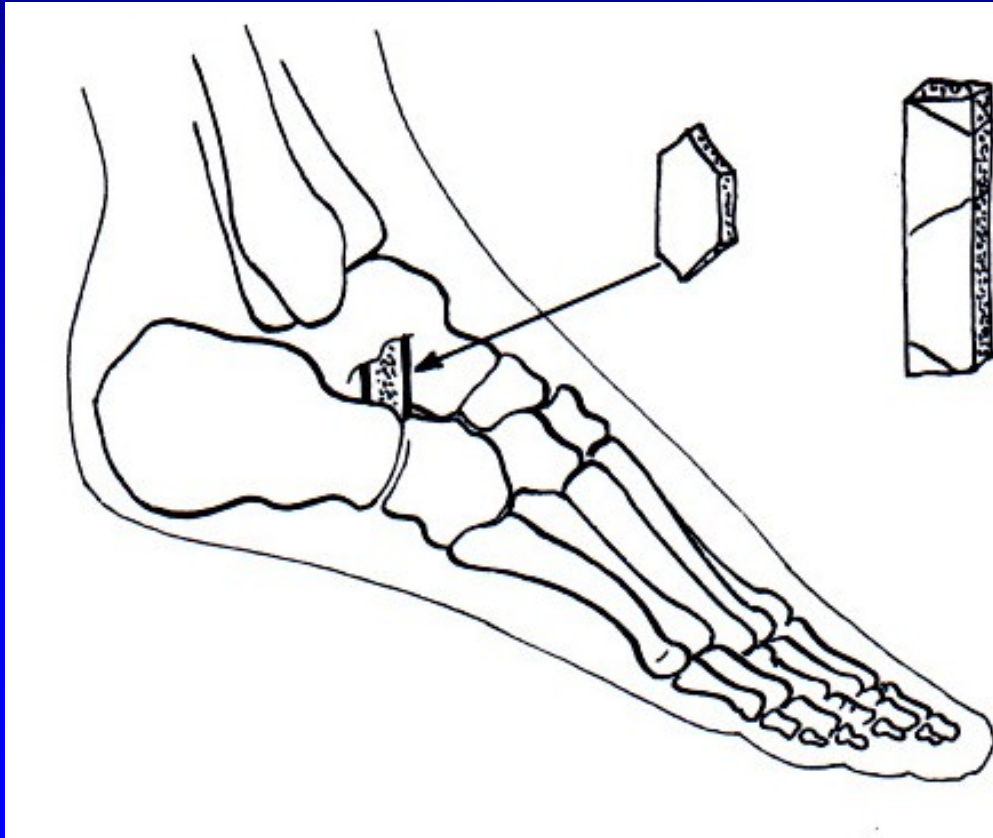
Postop.



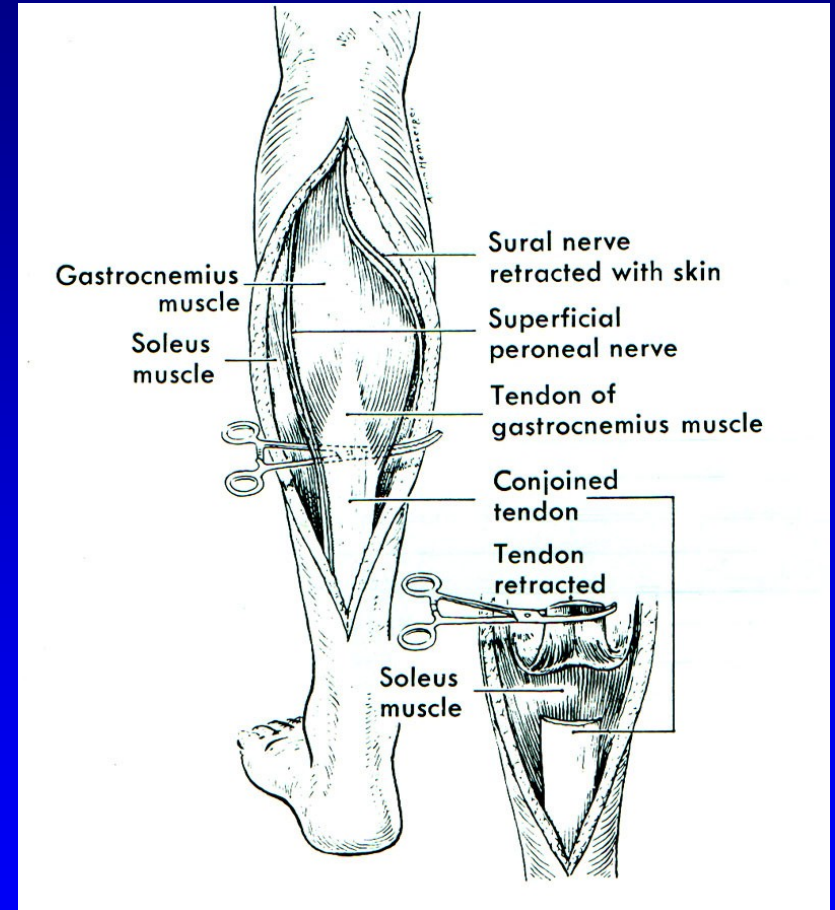
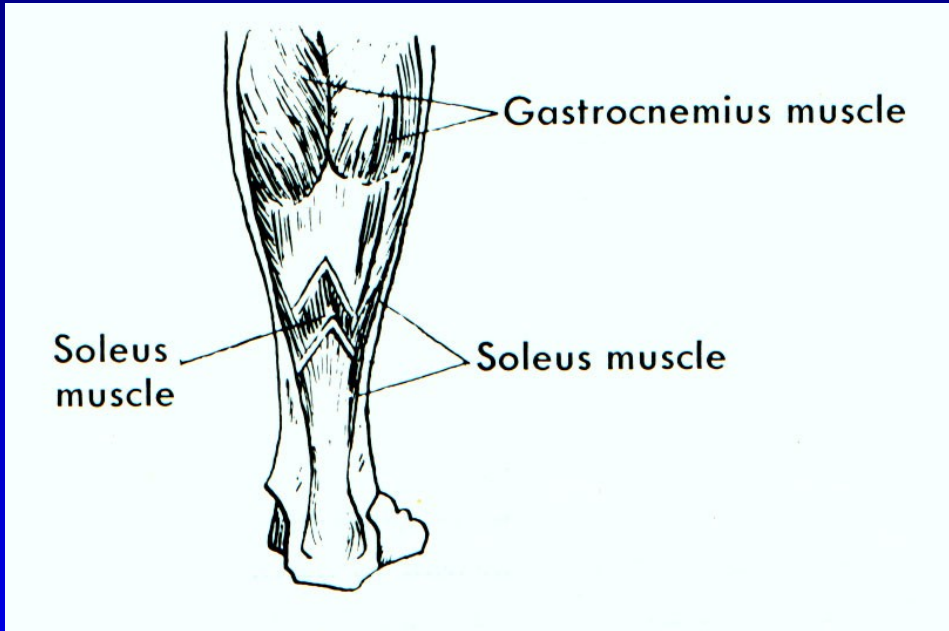
Tripple arthrodesis - pes equinovarus Talipes clubfoot



Correction of deformity of the foot in children Grice extraarticular arthrodesis




Prolongation of Achillis tendon




Obr. 88 Vulpius

Obr. 89 Strayer


Deformities of the toes



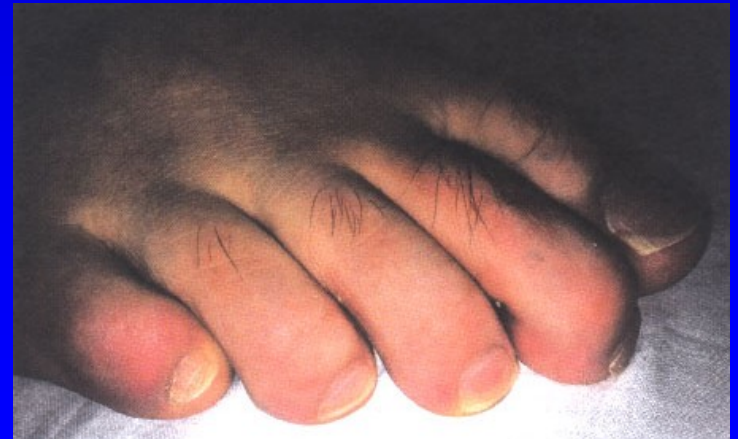
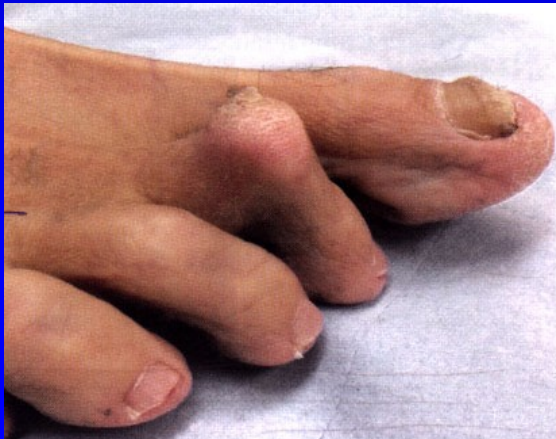mallet toe



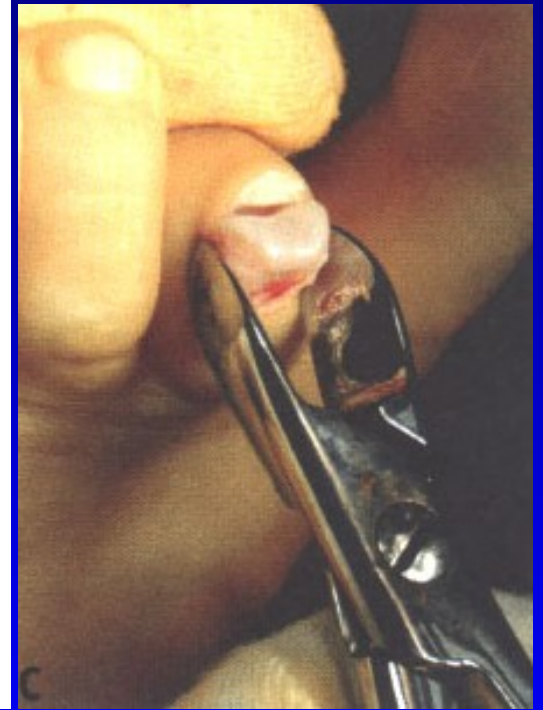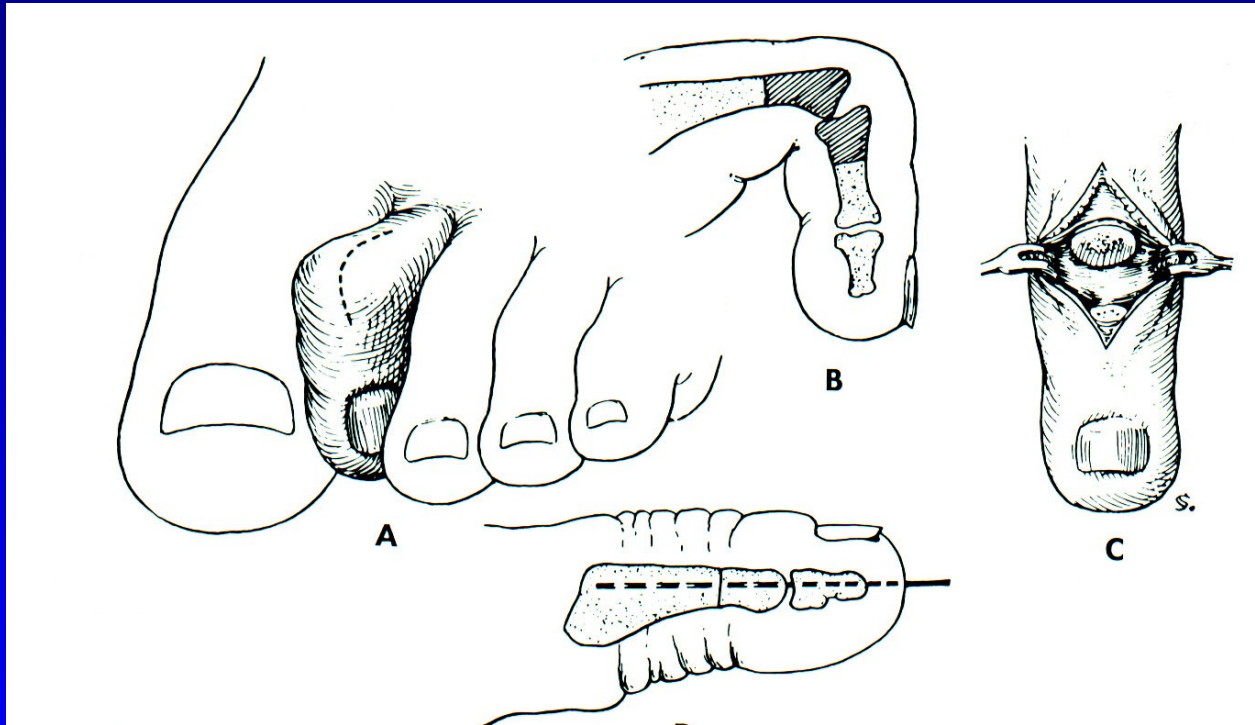
flexed toe



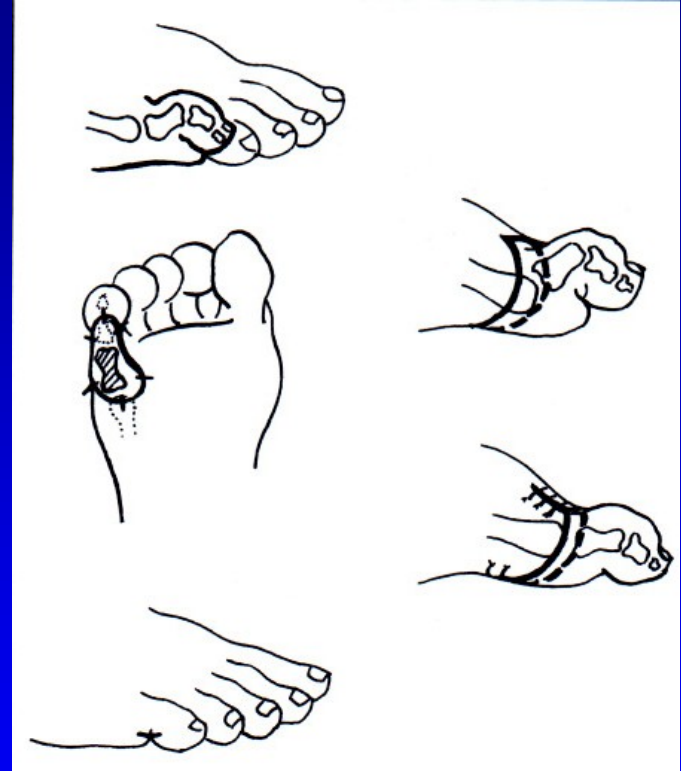
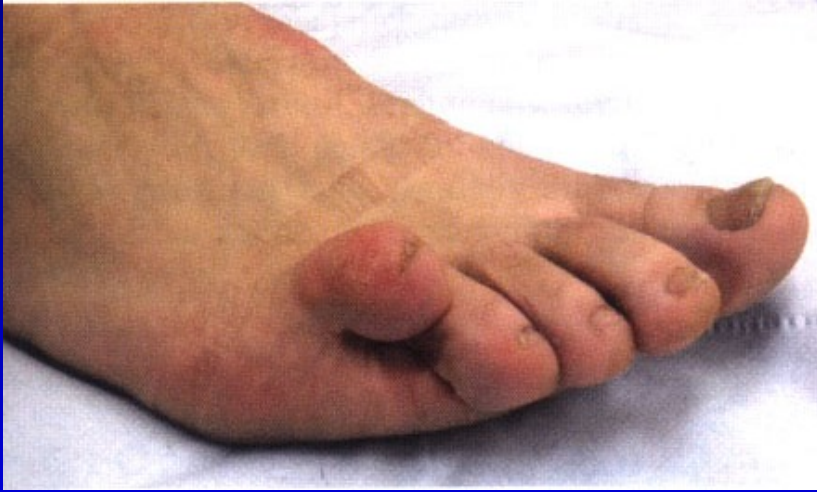flexed DIP joint



Mallet toe- dig. hamatus



Dig. superductus



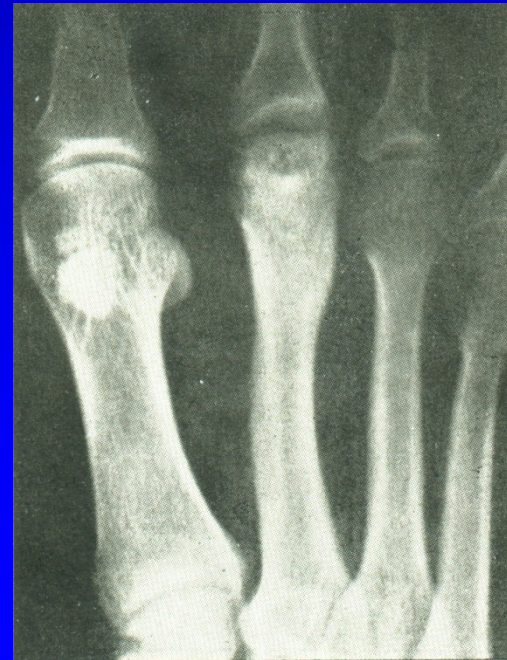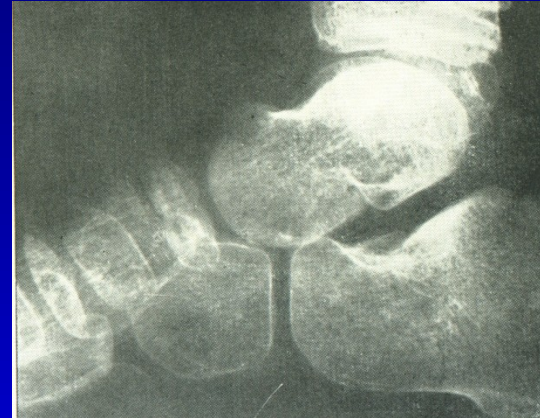
Aseptic necrosis of bones

m. Köhler I.

m. Köhler II.

m. Haglund- Sever

Osteochondropathy
of sesamoid bones



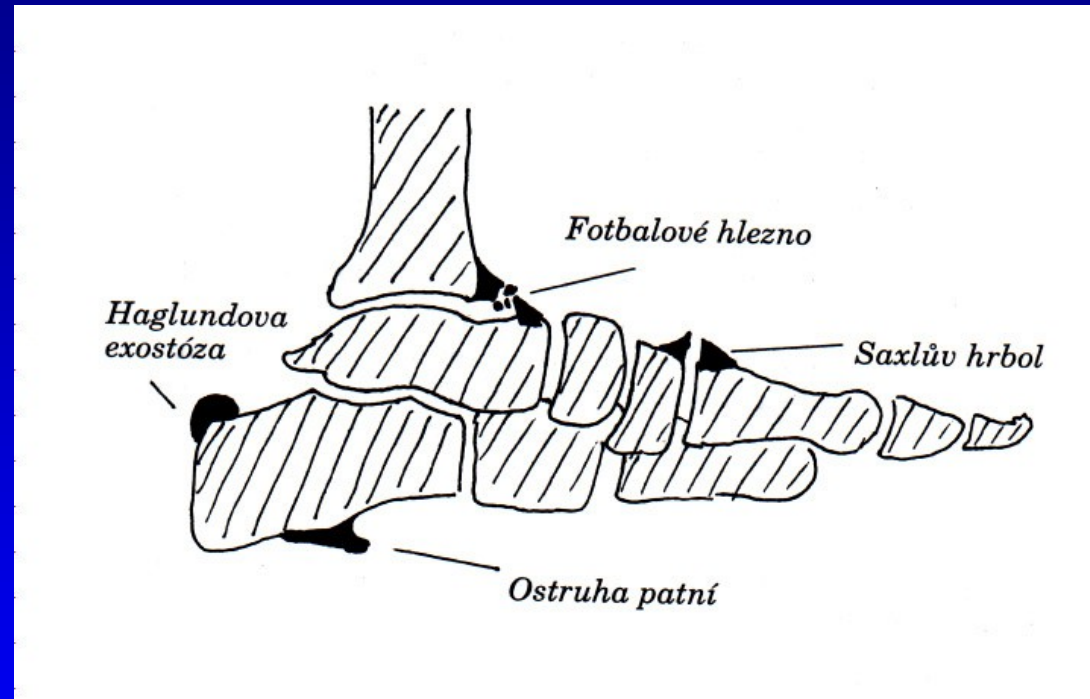
Bursitis and entesopathies

Achillodynia

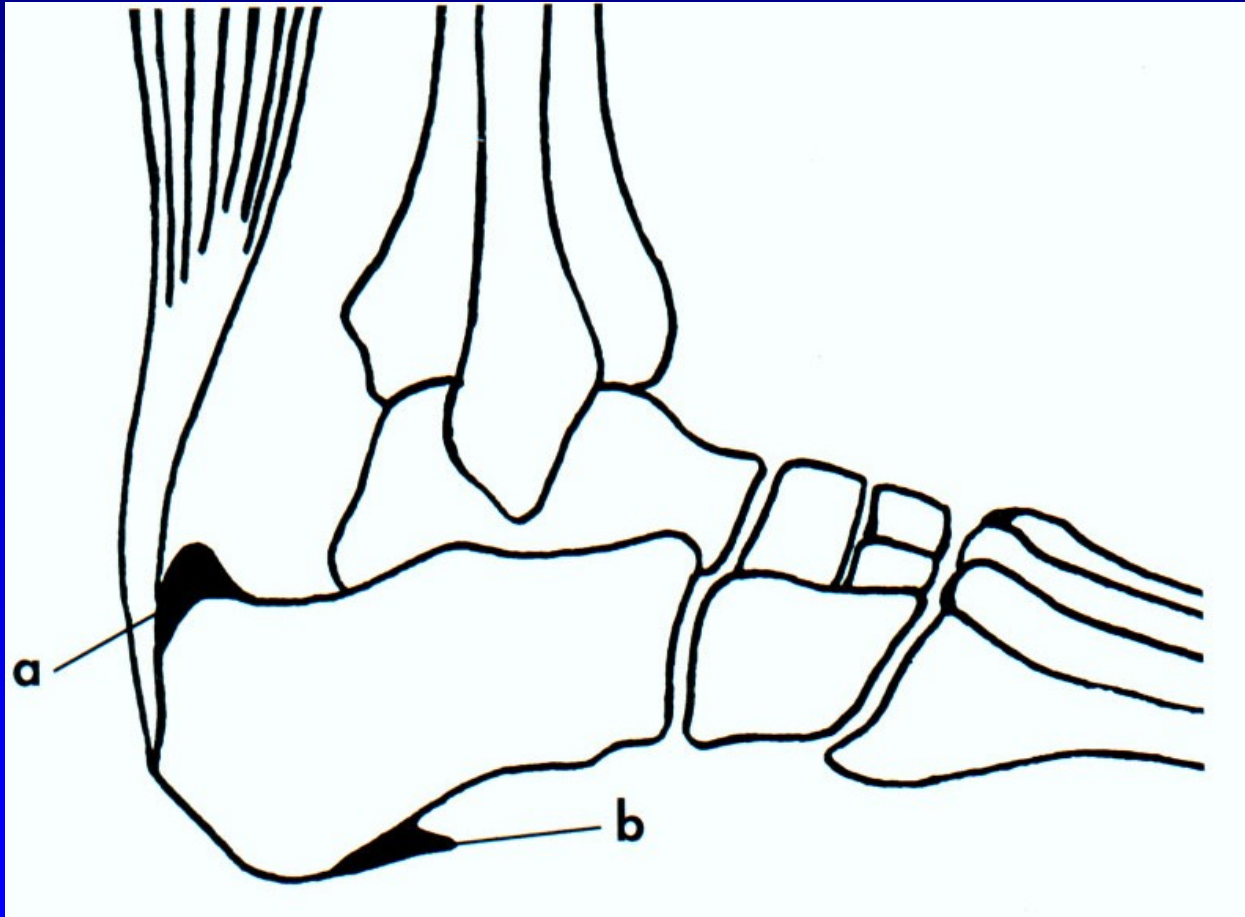
Calcaneal spur

Haglund exostosis

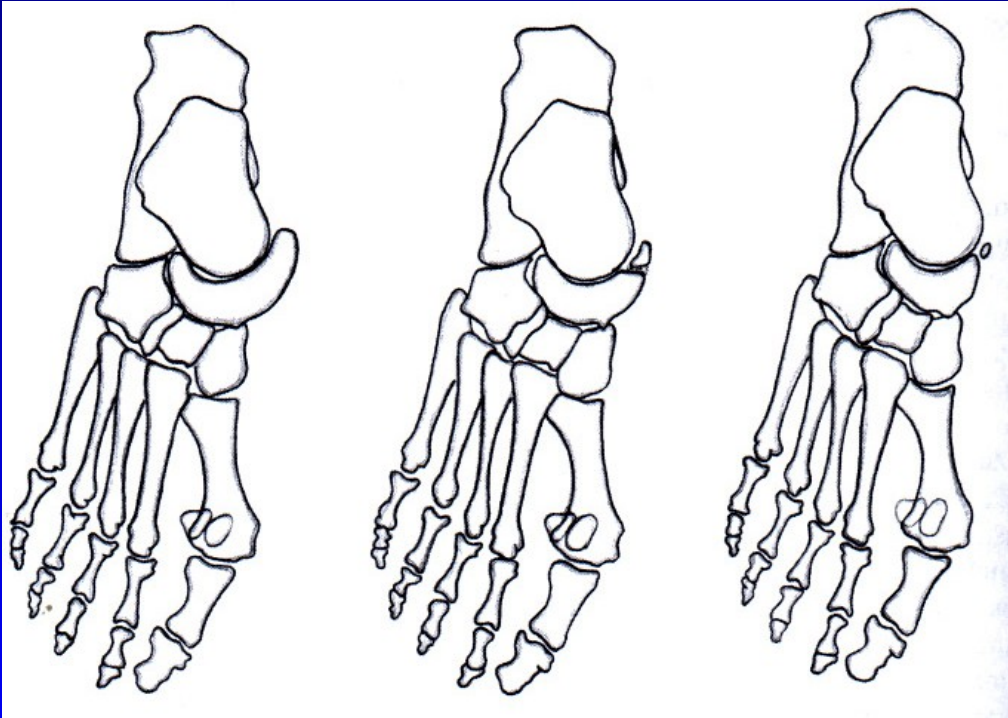
Os tibiale externum



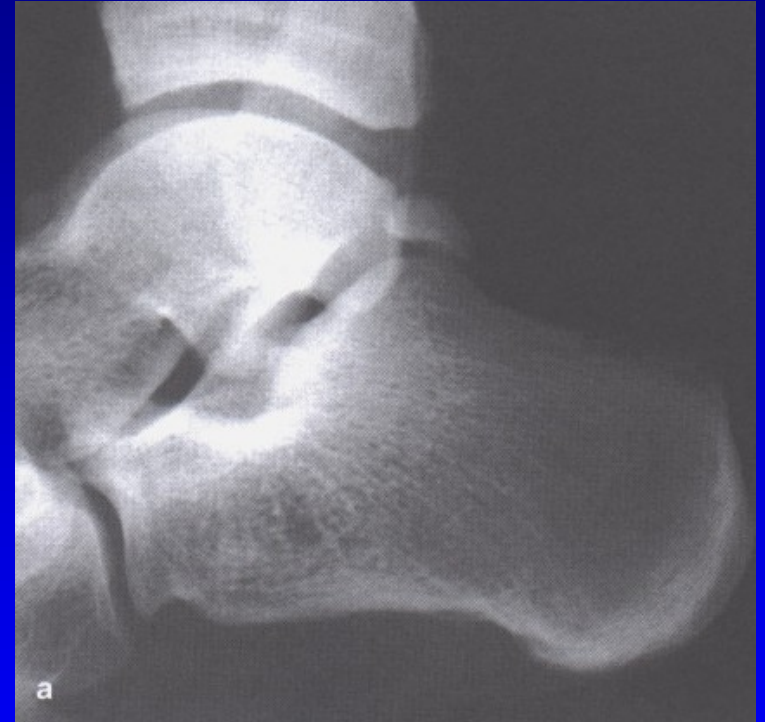Calcaneal spur



Accessory bones

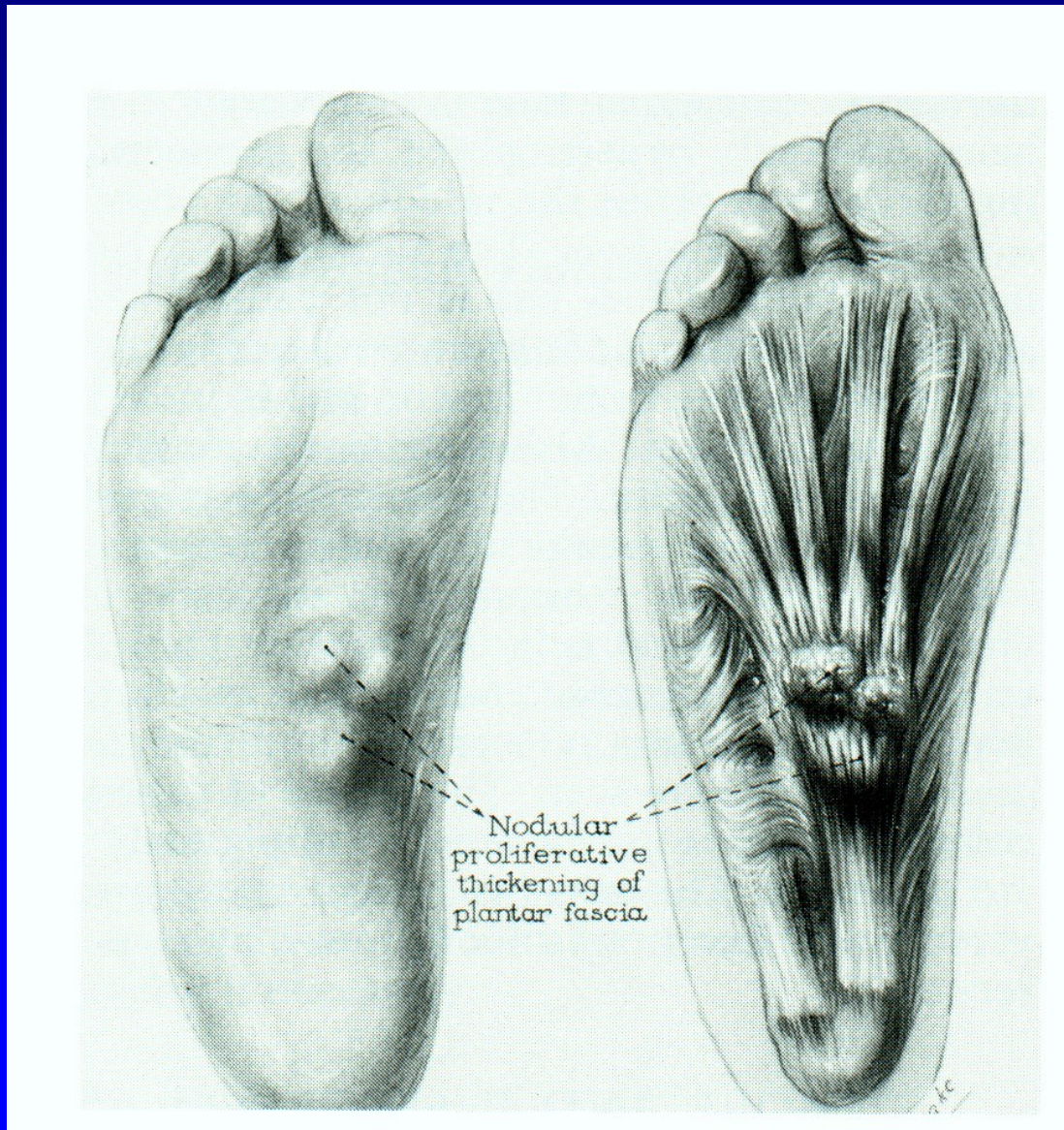


Obr. 97 Os tibiale externum

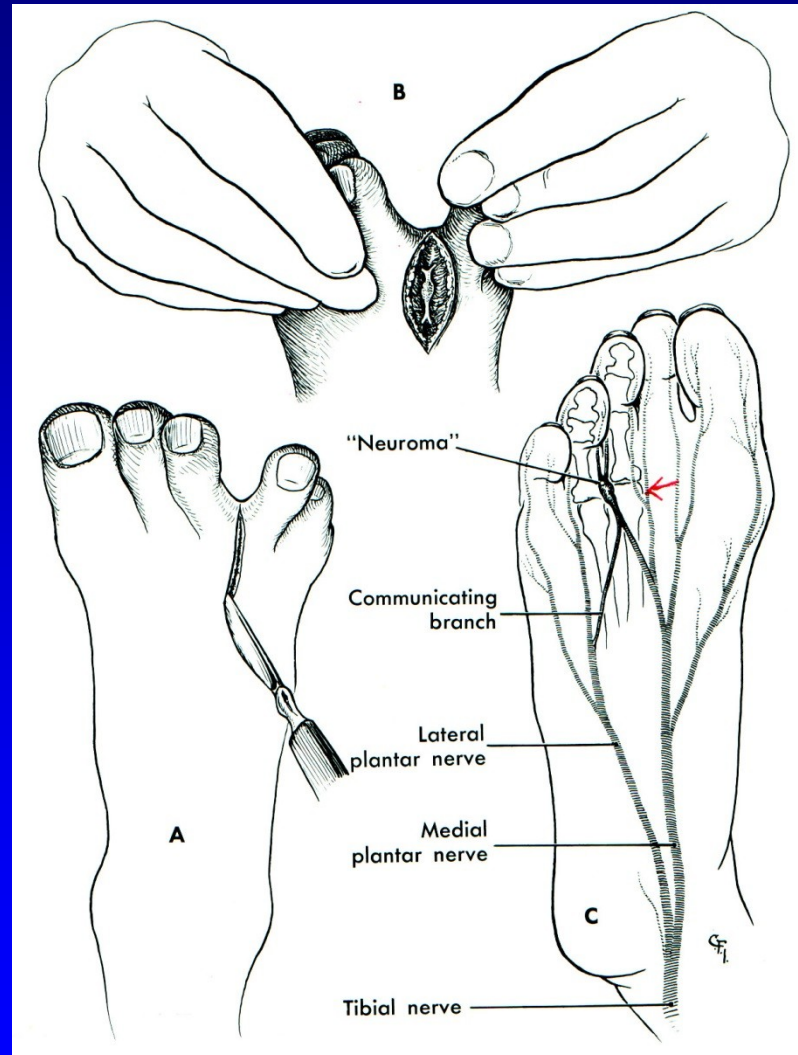


Obr. 98 Os trigonum

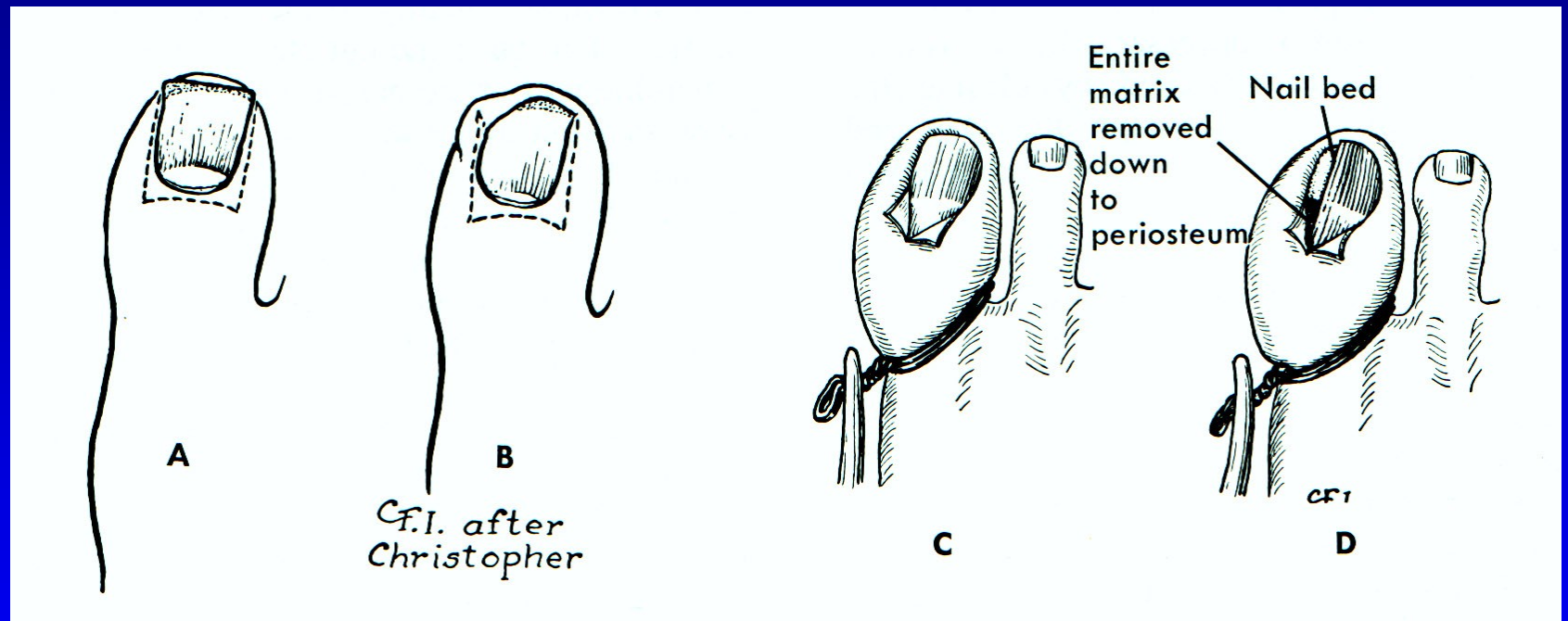
Plantar fibromatosis



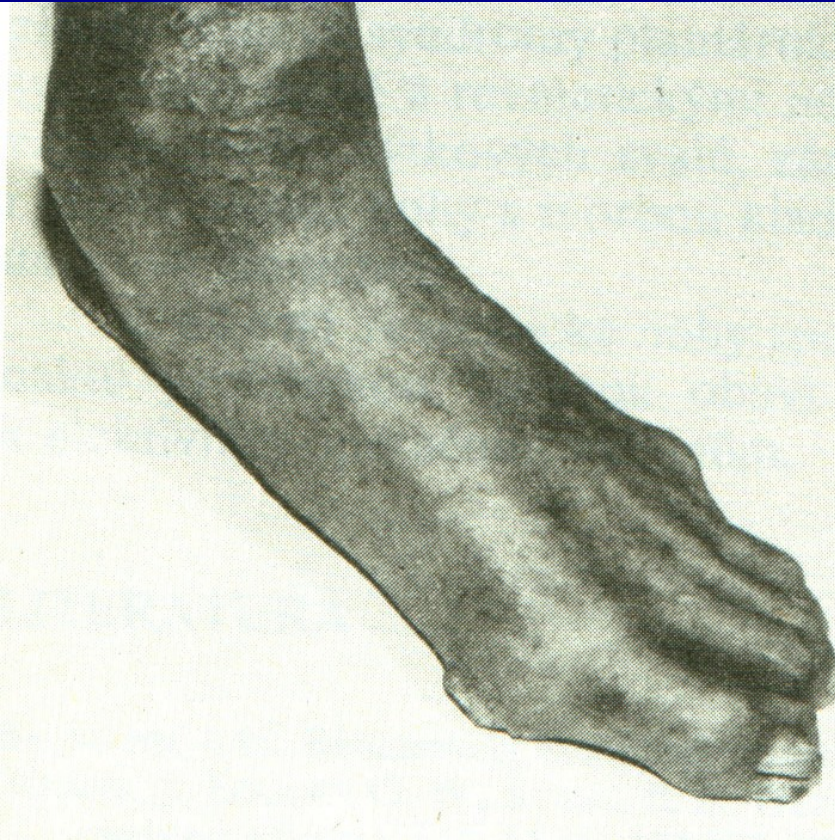
Morton neuralgia



Unquis incarnatus



Diabetic foot



7-15 % diabetics

Diabetic neuropathy

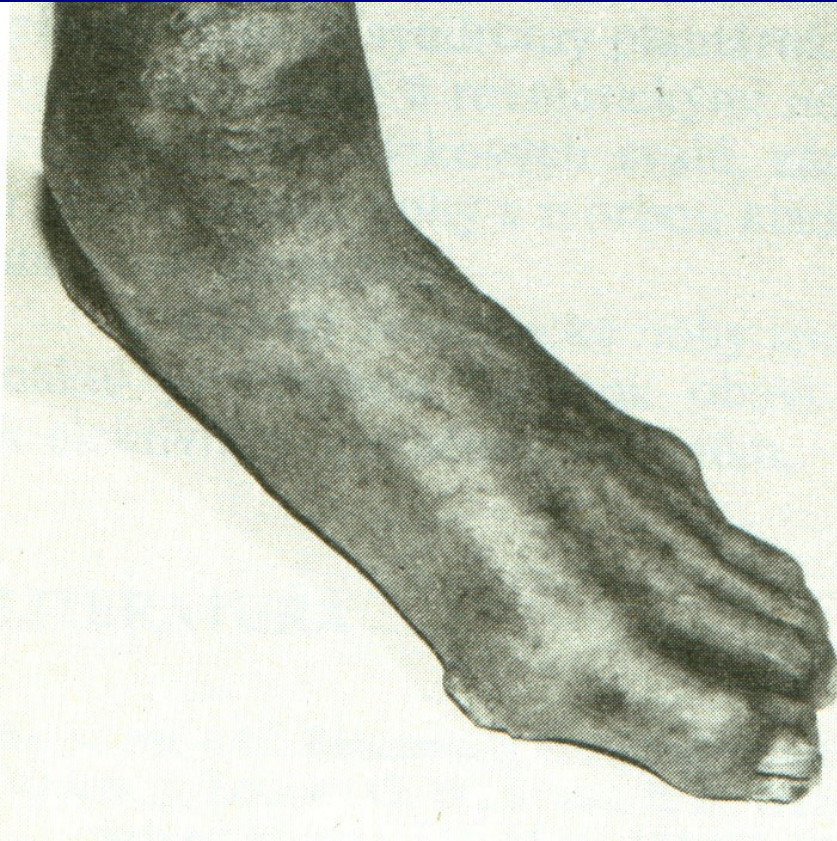Ischemic disease of lower
Extremity

Diabetic microangiopathy

Obr. 100

Diabetic foot

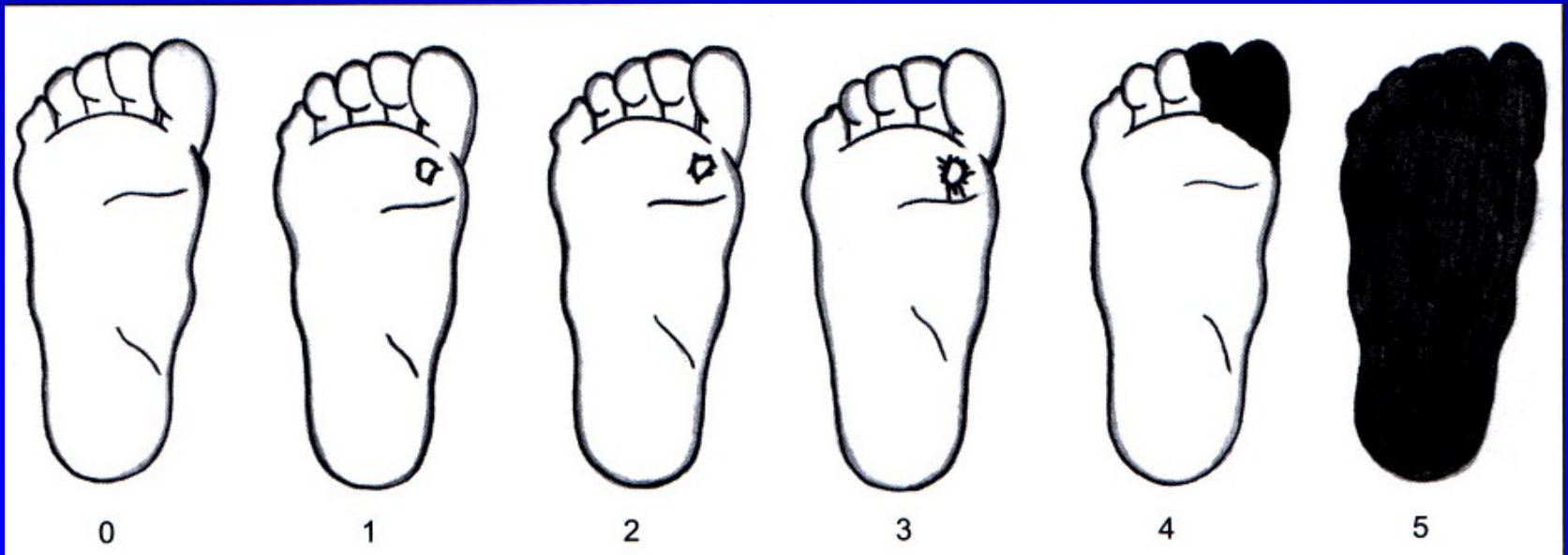
Charcot neuropathic joints



Diabetic foot

Ulcers

Necrosis



Management



Team work
Regular f/up
Insulin -therapy
Desinfection
Proteolytic agents
Antibiotics
Vasodilatancia, vit E
Angioplasty
Bypass
Hyperbaric chamber
Immobilisation
Arthrodesis
Amputation (15 %)

Other causes of pain in the foot

Neurogenic: sciatica, spinal stenosis

Vascular: varixes

chronic venous insufficiency,
ischemic vessel disease

Stress fractures

Synovitis of MTP₁ joints

Sesamoid bone problems

Tumors

Inflammations: pyogenic, R.A., psoriatic,
gout

Tenosynovitis

Neurogenic arthropathies

