

Clinical examination in orthopaedics

Z. Rozkydal

L. Pazourek

Clinical examination

The aim- establish the diagnosis

1. History
2. Objective examination - general
3. Objective examination - local
4. Laboratory tests
5. Imaging methods

History

Family

Personal

Pharmacological

Social

Occupation

Epidemiological

Current problems

Analysis of pain

Family

- Congenital abnormalities
- Important diseases in family (heart, DM, haemophilia, oncological diseases, neurological diseases, TB)
- Birth, miscarriage

Personal

- Important general diseases (hypertension, DM, heart, tumors, lung problems)
- Coagulopathies
- Infections
- Injuries: consequences, complications
- In children- pregnancy
psychomotor development

Current symptoms

Local

Pain, motor function, limping, deformity, ROM, swelling, loss of sensation

General: fever, shivering, cachexia

Cause of the problem

- injury
- overloading
- Infection
- systemic diseases (endocrine, metabolic, inflammation, neurological, haematological.)

- Development of symptoms
 - Onset, duration
 - Intensity
 - Aleviation, increasing factors
- Present management
 - Examination in the past time
 - Conservative therapy
 - Operative therapy
- Mobility, occupation
- Emotions, psychological condition
- Simulation, dissimulation, aggravation

Analysis of pain

Intensity, frequency, duration

Acute, chronic

Local, irradiating

Visceral

Type- sharp, blunt, burning, stabbing

Neuralgia

Nerve root pain

Phantom pain

Neurogenic claudication

Analysis of pain

Localised, diffuse

Psychological background

During activity or in rest

VAS – visual analogue scale

Scale of ten degrees

0 - no pain

10 - the most severe pain not bearable

Pain 5 or more- change of management

Pharmacology

- Medicines used currently
- Important medicines: warfarin, heparin, other anticoagulants, antiepileptics, cytostatics, immunosuppressives, NSA, corticoids, biological treatment,
- Alcohol, smoking, drugs
- Allergy (antibiotics, metal, disinfections)

Occupation and social

- Occupation, type of work, manual labor
- Rent
- Social situation (living, marriage)
- Subsequent management

Gynecological history

- Cycles, gravidity, menopause, current gynecological problems
- Epidemiological history
influenza, viral infections, herpes simplex, focal infections (UTI, stomatological infections, ulcers, erysipiel)

Objective examination

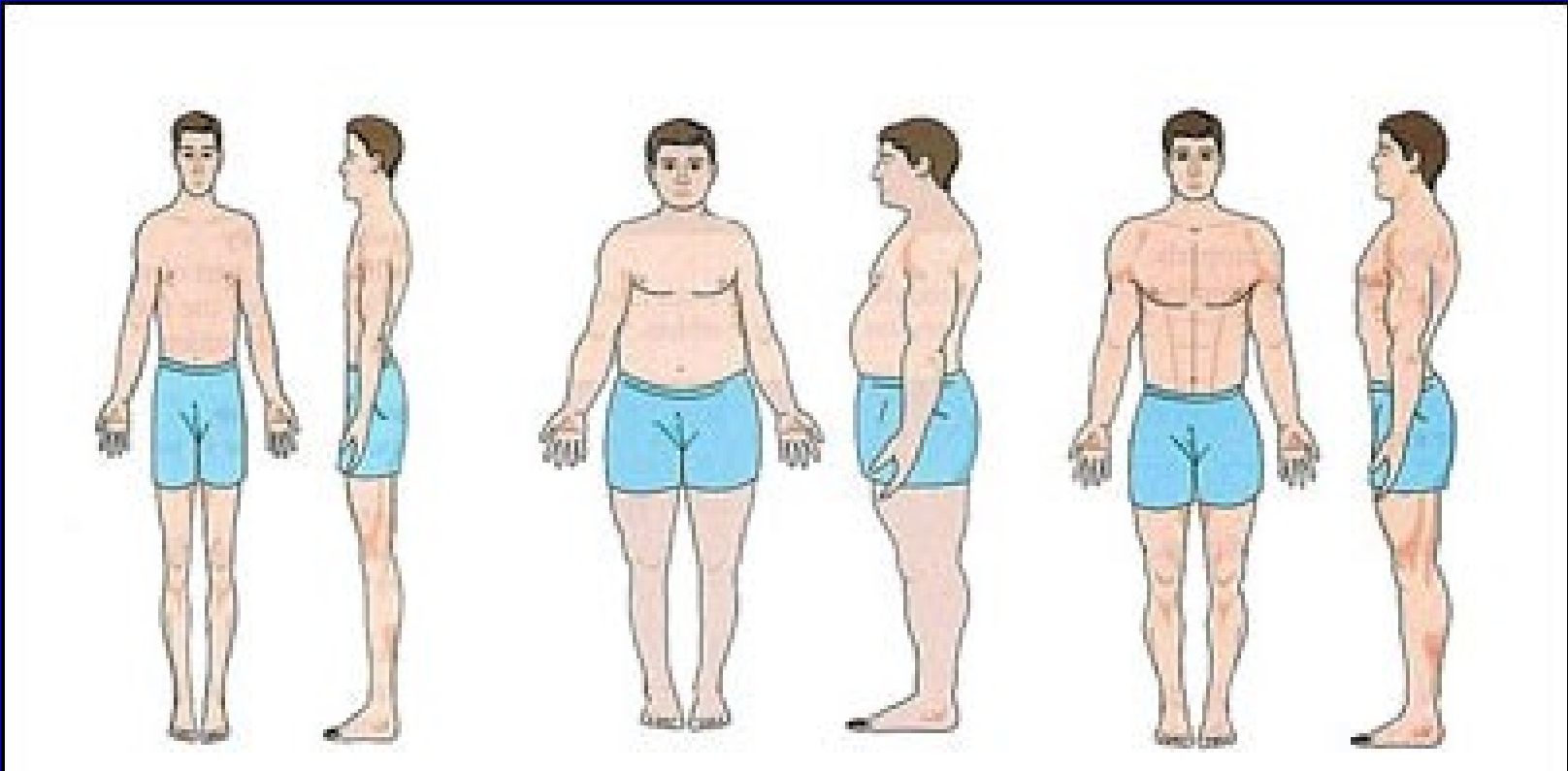
General examination

General orthopaedic examination

Local orthopaedic examination

Posture and gait

Somatotype



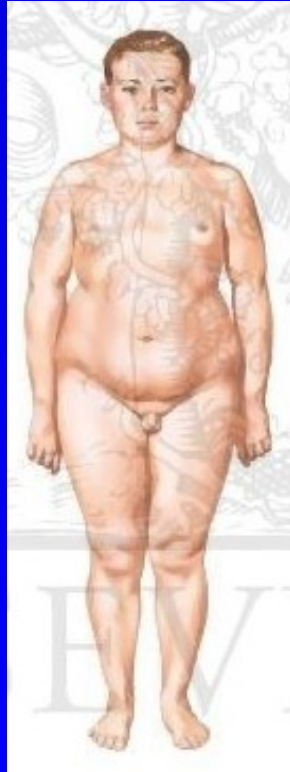asthenic

pycnic

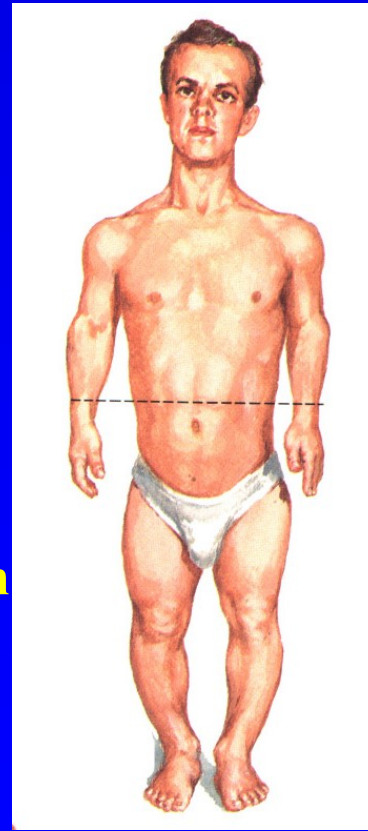
normosthenic



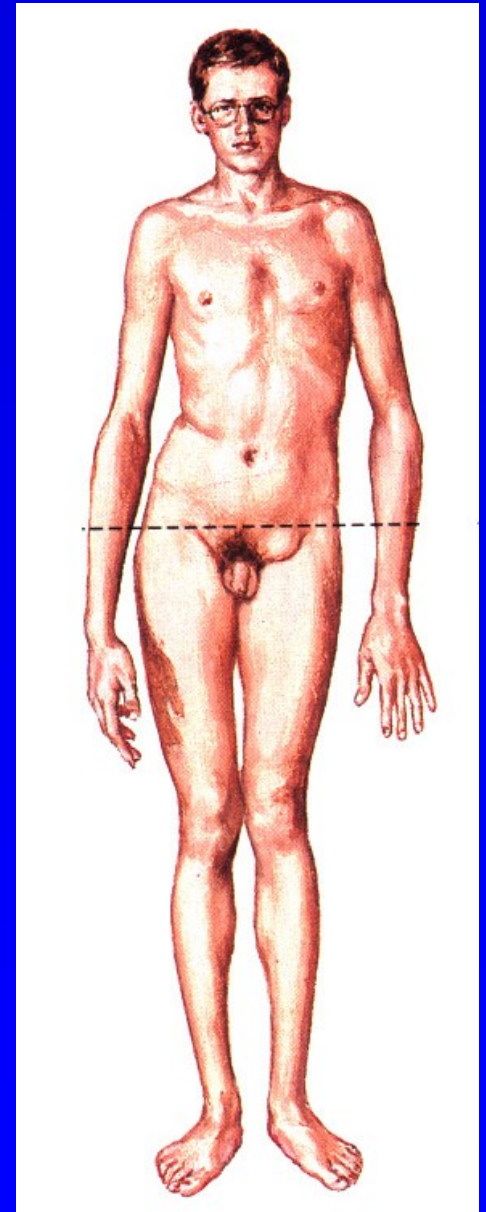
Gigantisms



Fröhlich syndrom



Achondroplasia



Marfan syndrom



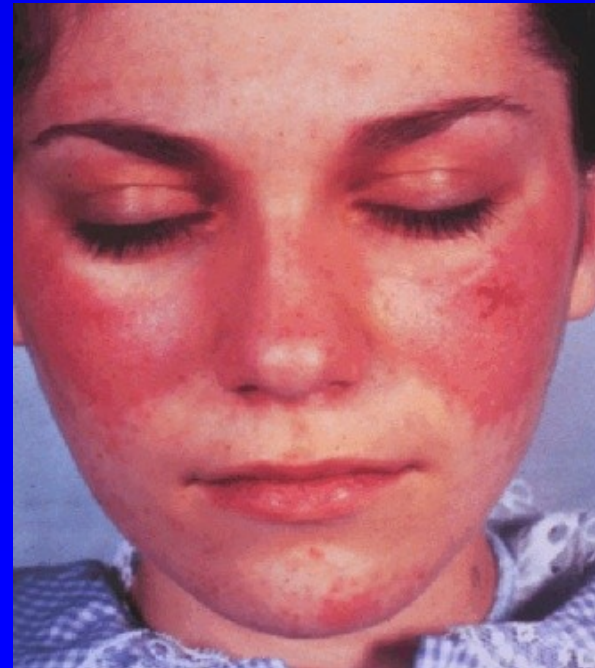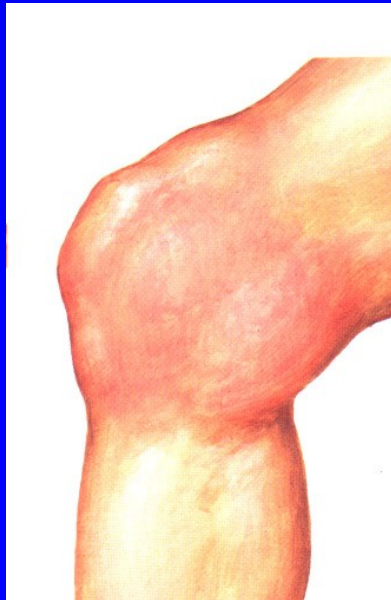
Nanisms

Nutrition

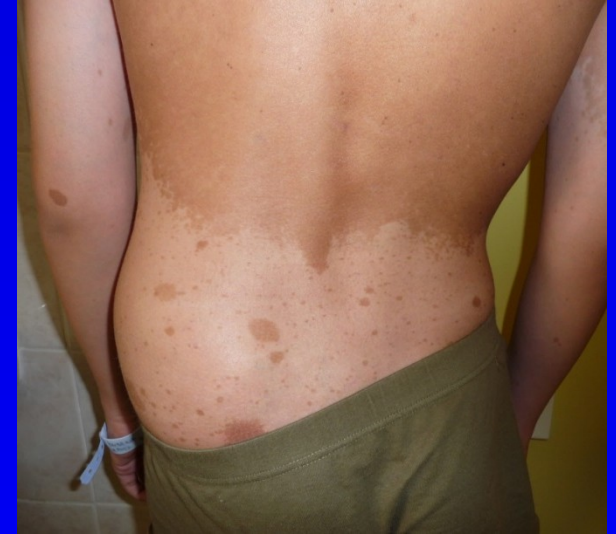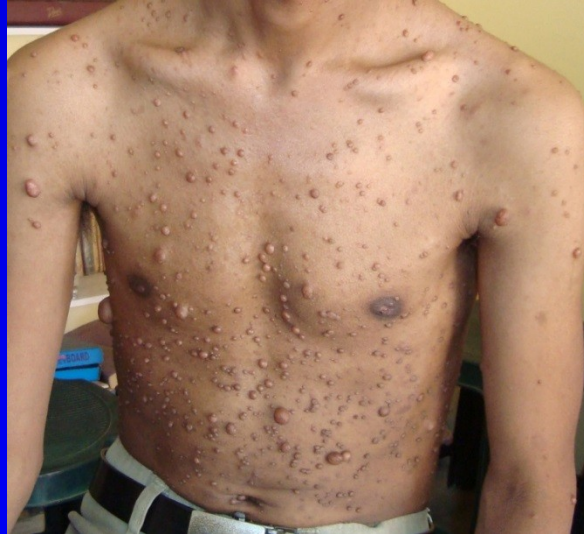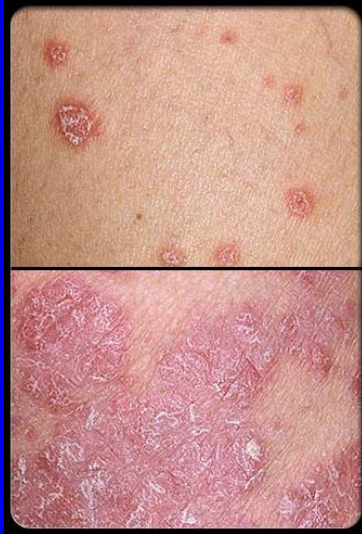- **Body mass index:** $\frac{\text{weight kg}}{\text{height}^2 \text{ m}^2}$
(BMI)
- Below 20 - cachexia
- 20-25 - normal weight
- 25-30 - overweight
- 30-35 - obesity
- Over 35 - severe obesity

Skin

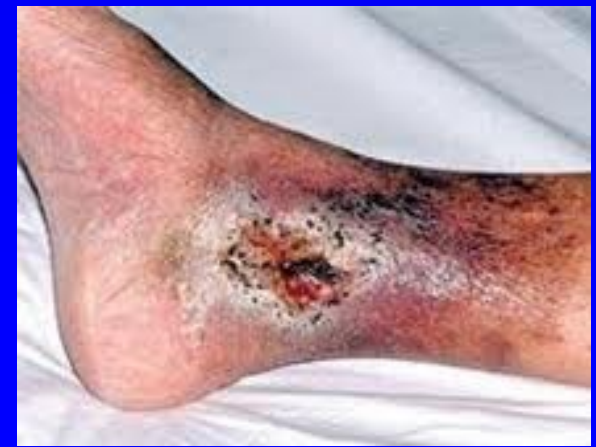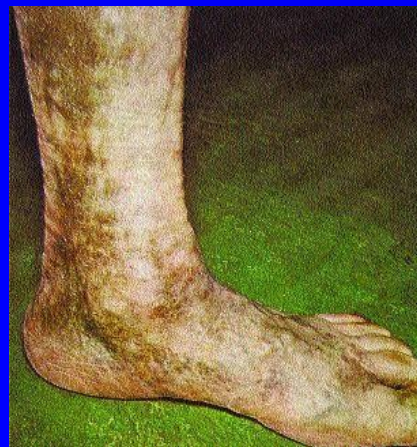
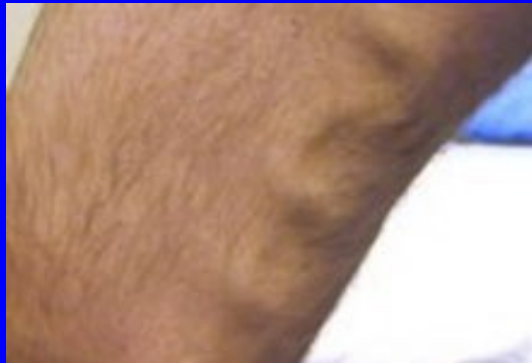- Colour



- pigmentation, naevus



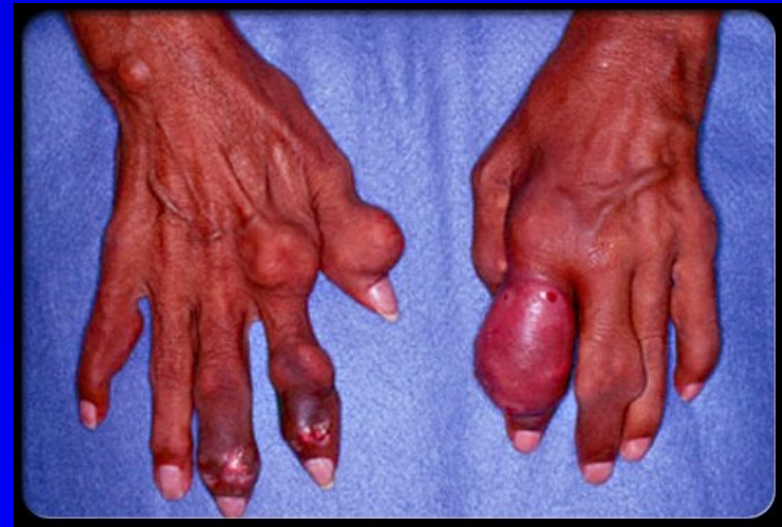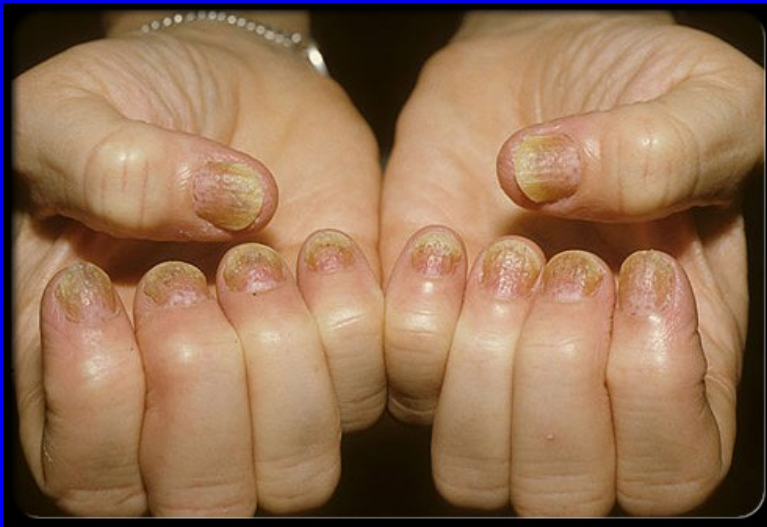- Trophicity, turgor



- Fistulas, ulcers

- Subcutaneous nodes

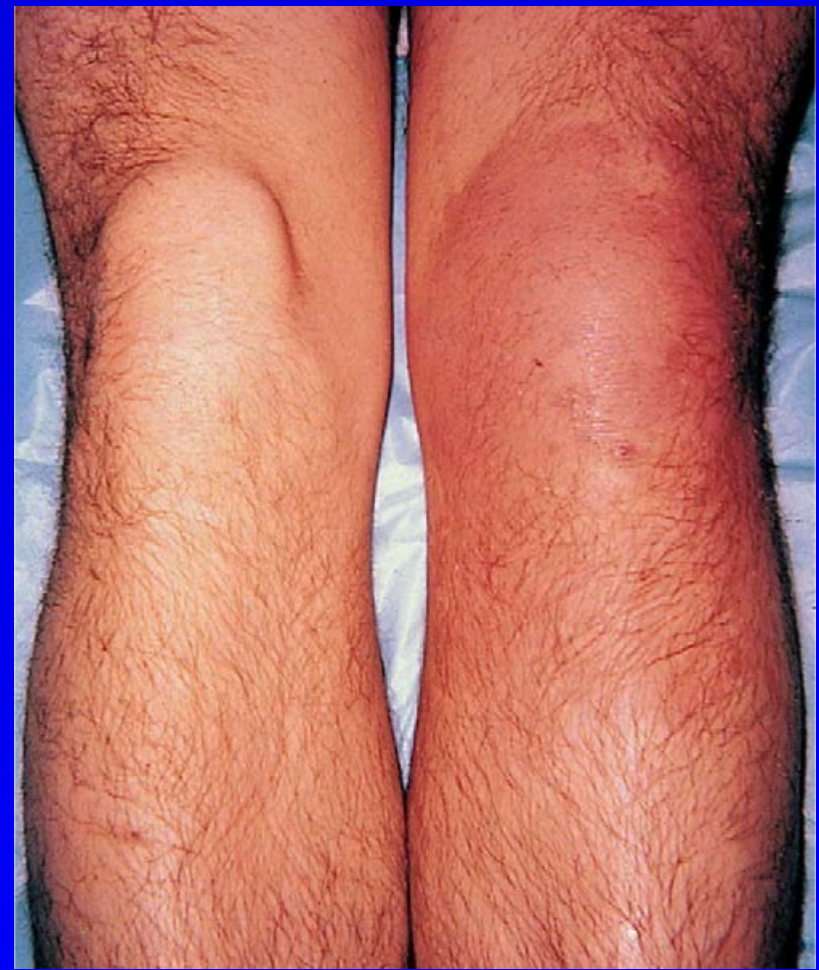- nails



- Lymfadenopathy, soft tumors, inflammations

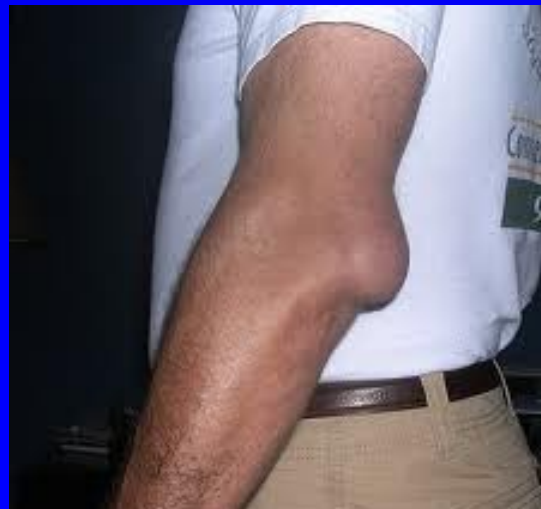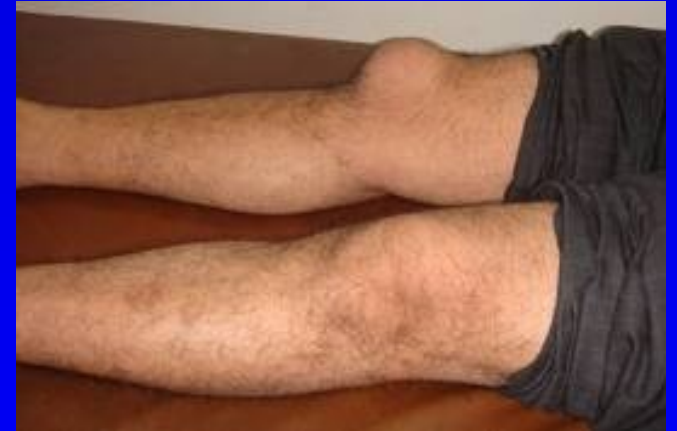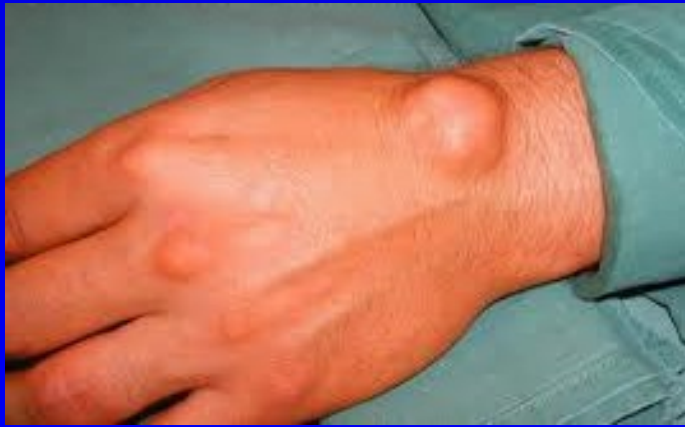Swelling

- Local
- General
- Anasarca
- Decollement

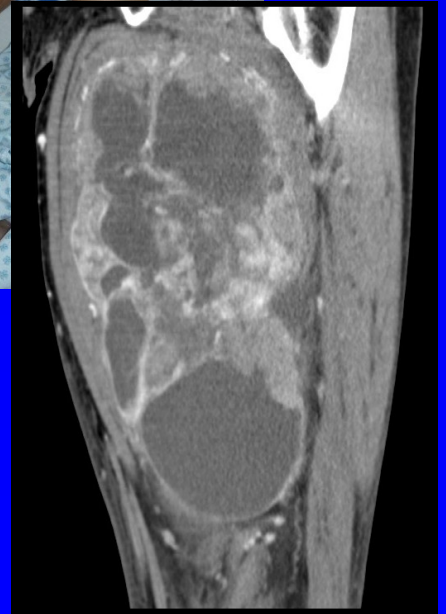
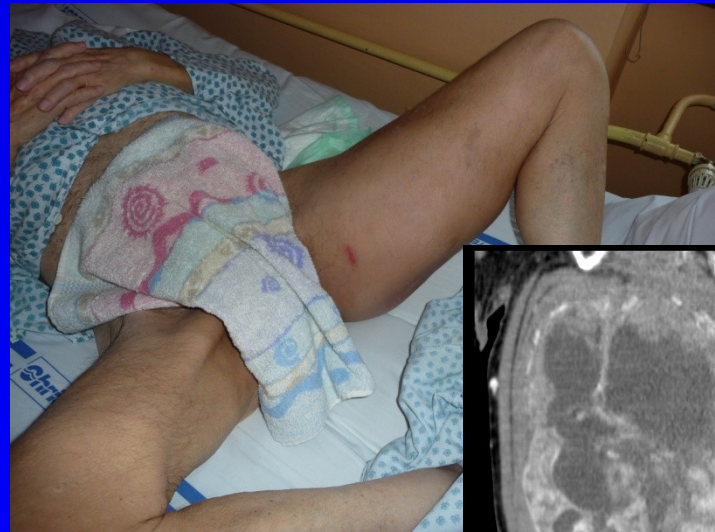
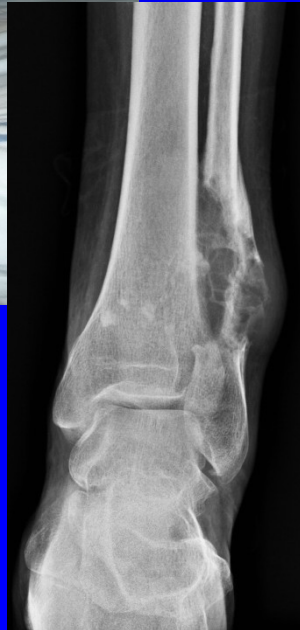
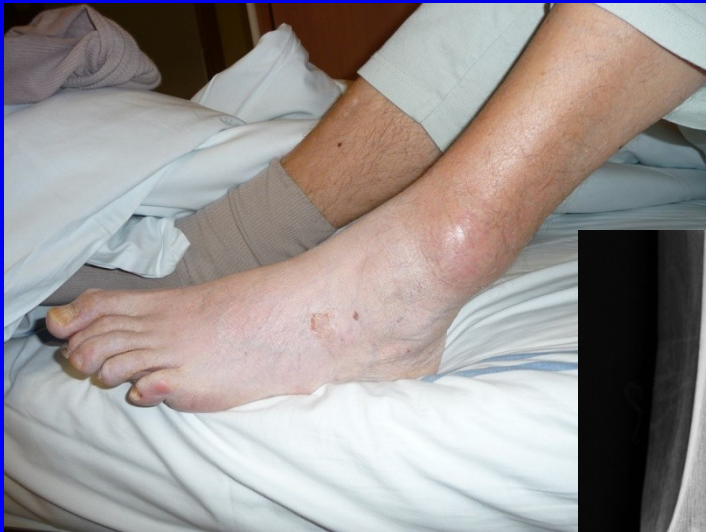Local signs of inflammations:
redness, swelling, pain, warm, limited
function, soft mass, effusion, discharge

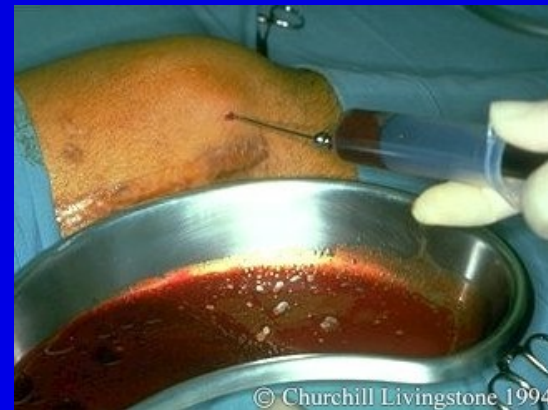
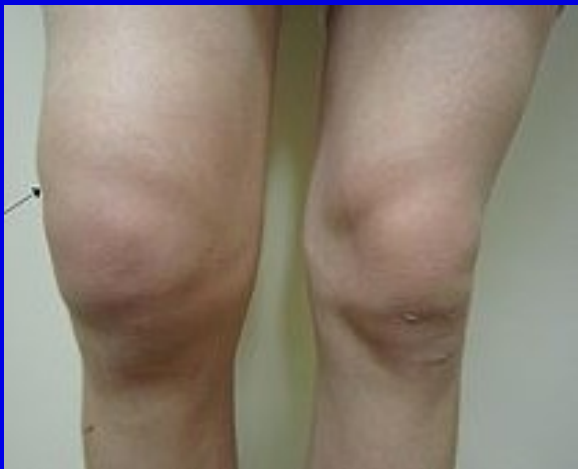Soft mass



- Haematoma
- Lymphonodes
- Tumor

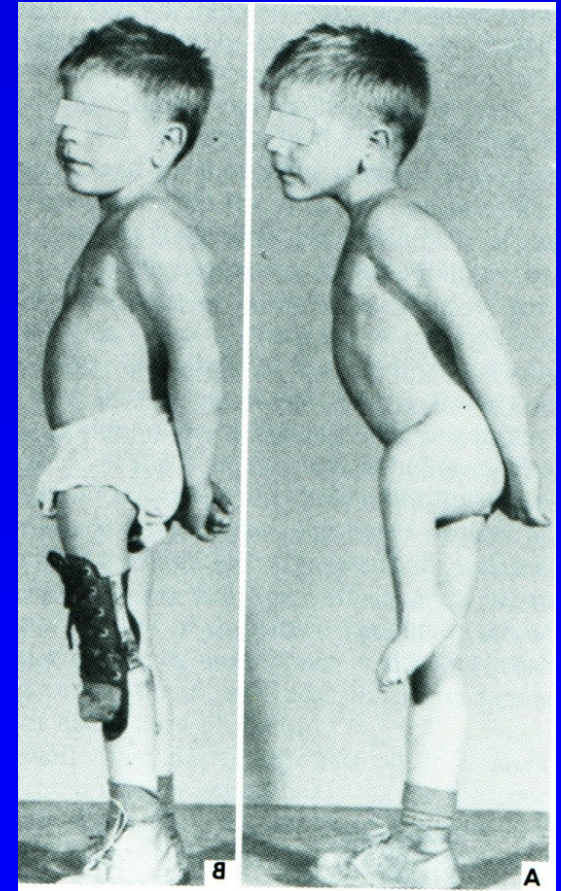
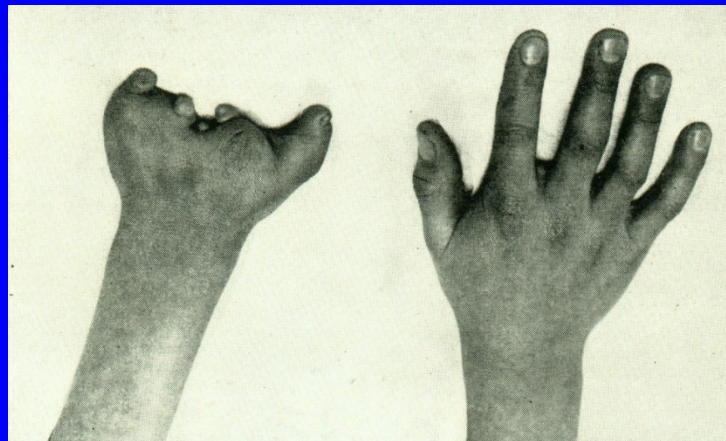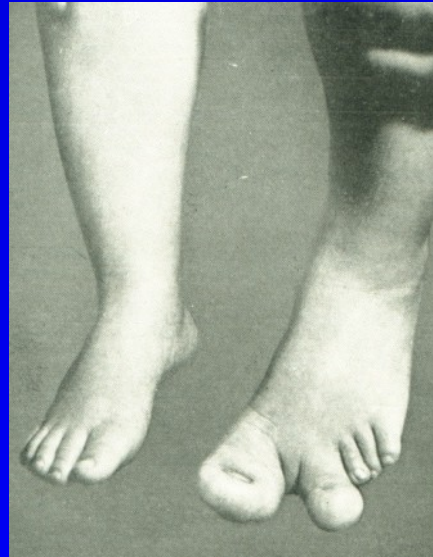


Effusion



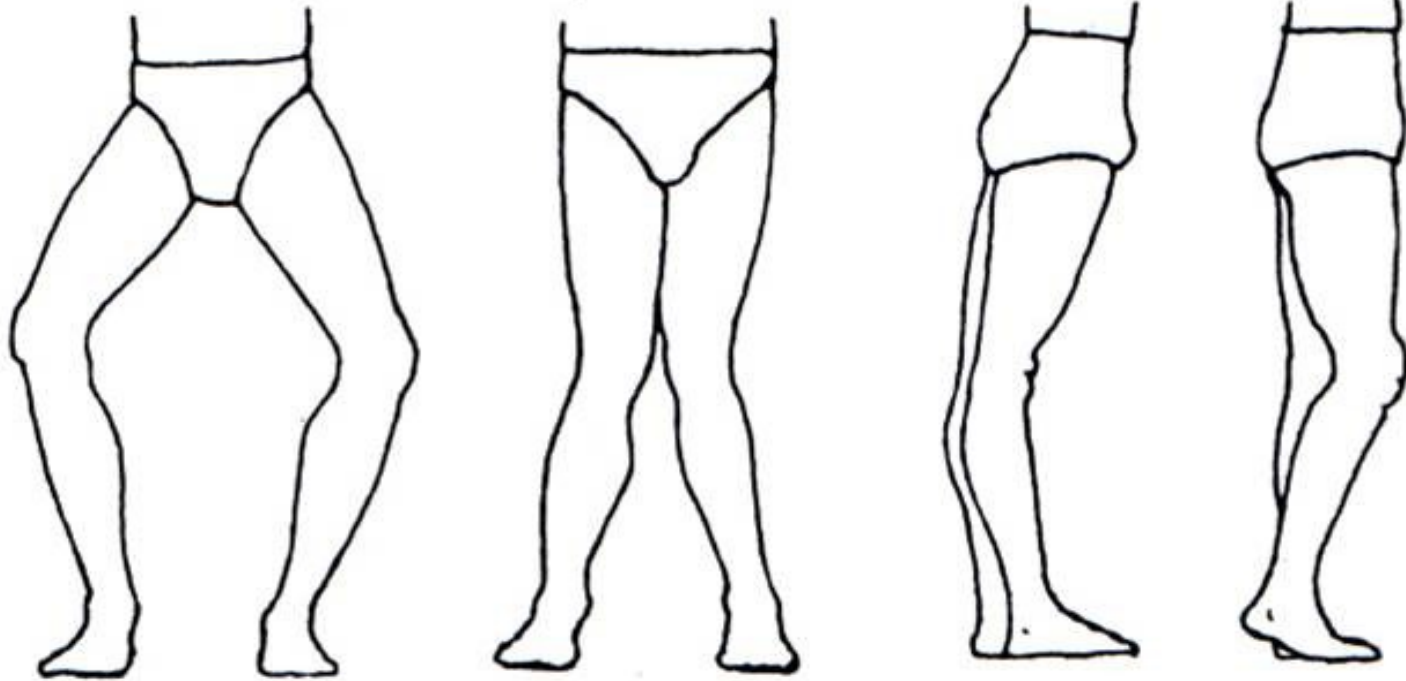
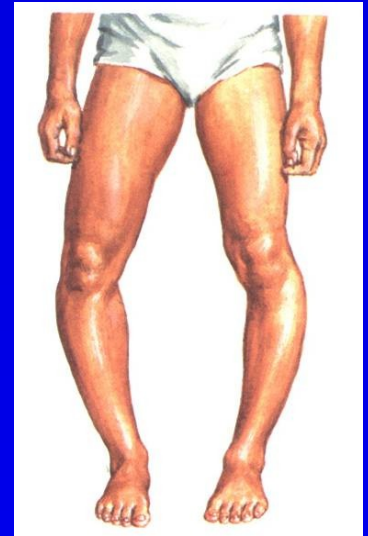Congenital deformity

- 1. Shape, size
- 2. Differential
- 3. Duplicity
- 4. Gigantisms
- 5. Hypoplasia



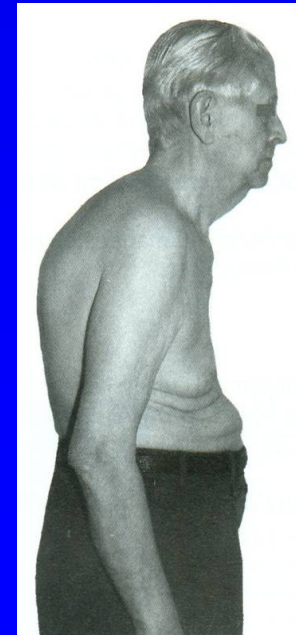
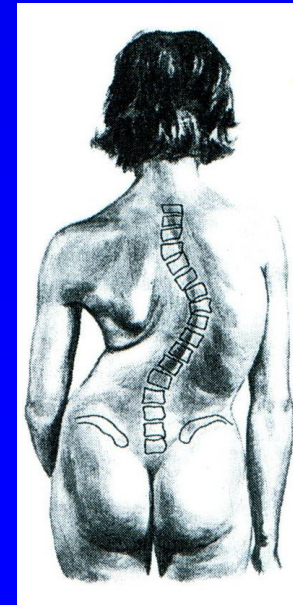
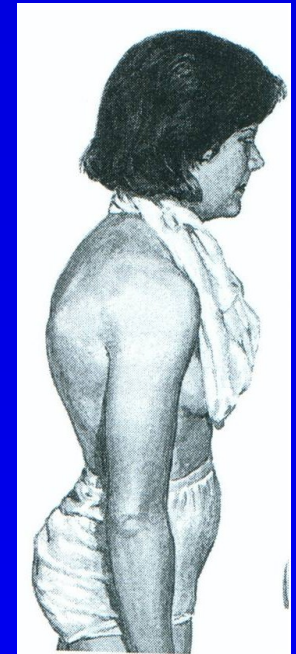
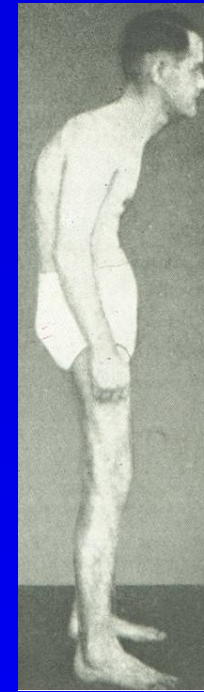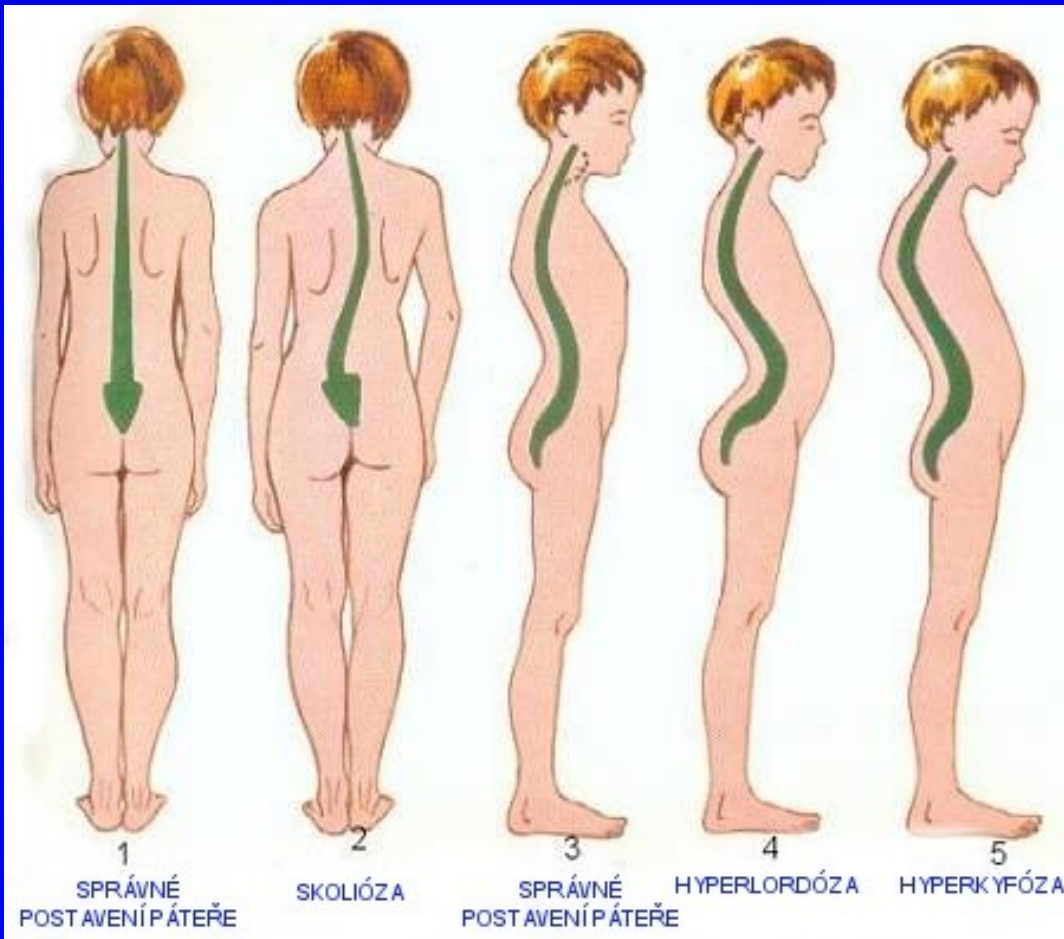
Malalignment

- varus x valgus
- antecurvation x recurvation
- rotation deformity

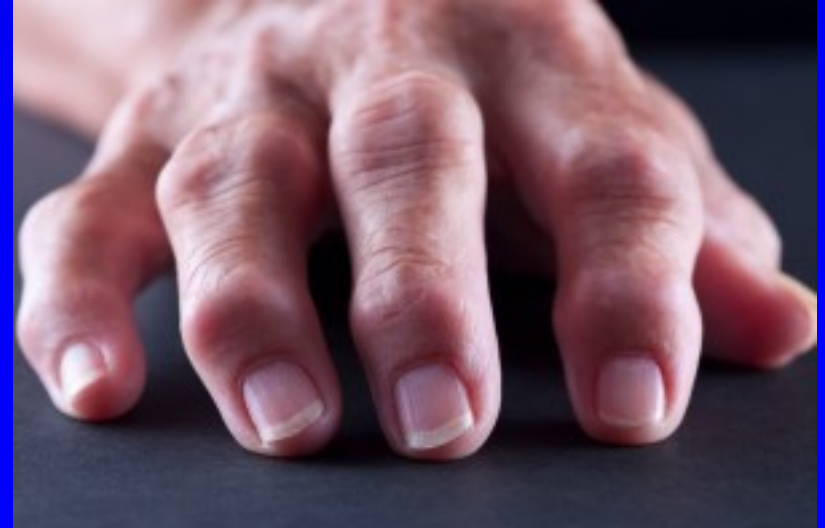
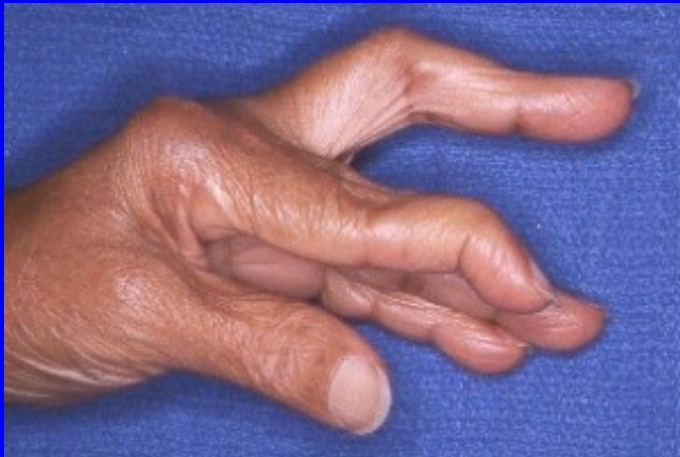
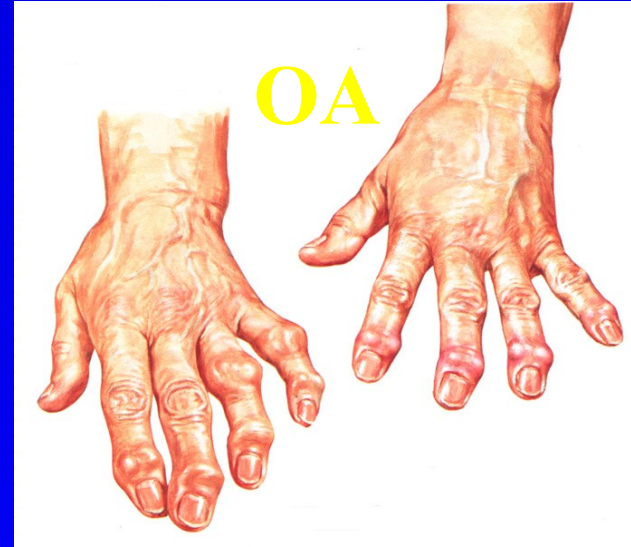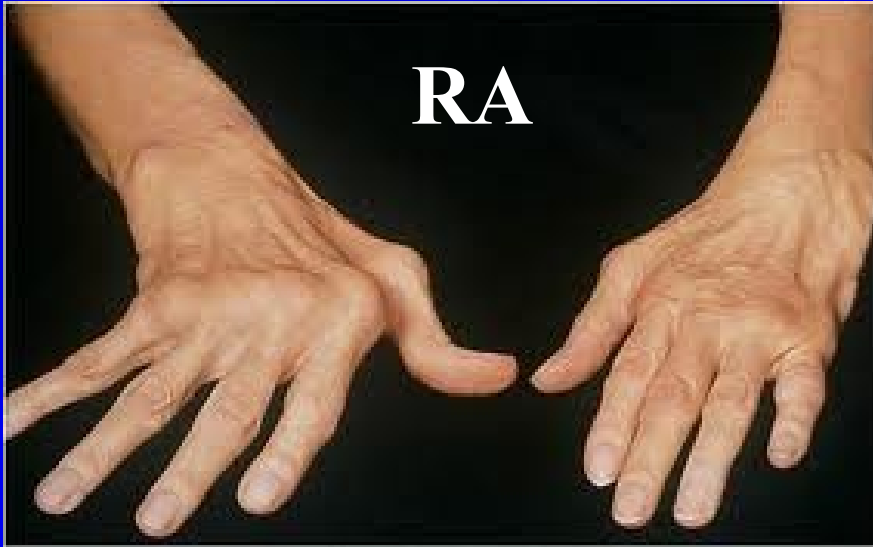Deformity of spine

- Scoliosis
- Hyperkyphosis, hyperlordosis



Hand deformities



Boutonniere deformity
Swan neck deformity

Foot deformities



Talipes cavus



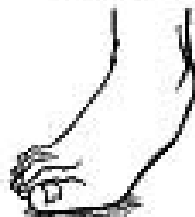Talipes equinus



Talipes calcaneus



Talipes valgus



Talipes equovalgus




Talipes calcaneovalgus



Talipes varus



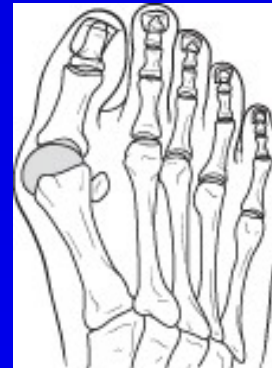Talipes equovarum



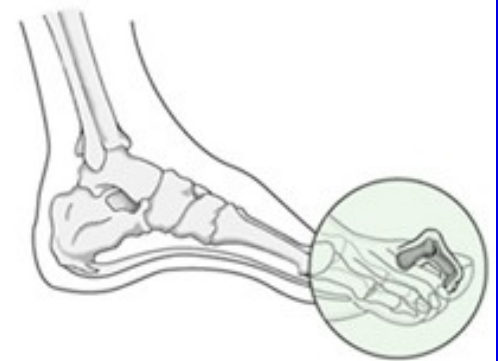
Talipes calcaneocavus



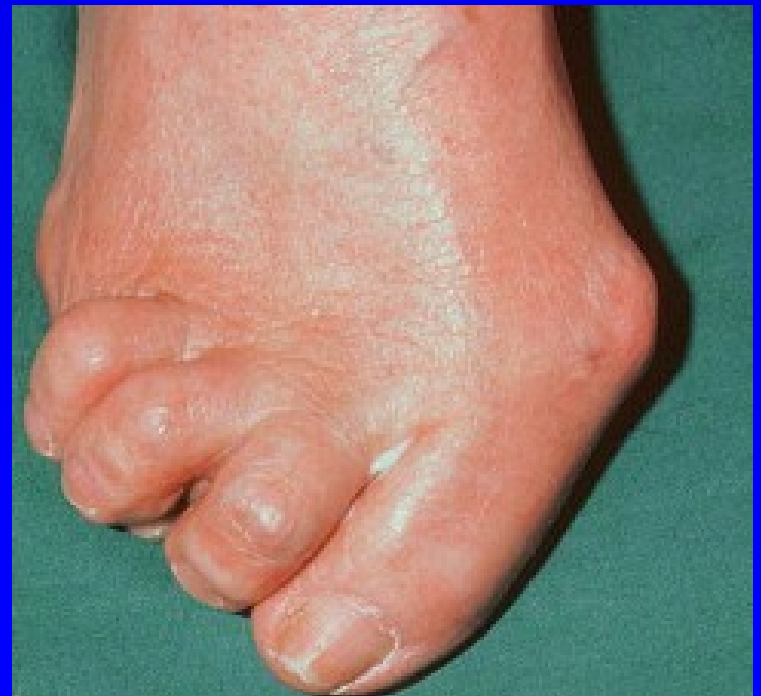Talipes cavovarum



Bunion



Clawtoe



Length of extremity

Lower extremity

- Spinomaleolar distance
- Umbilicomaleolar distance
- Support during standing
- X- ray of the hip, knee, ankle joint

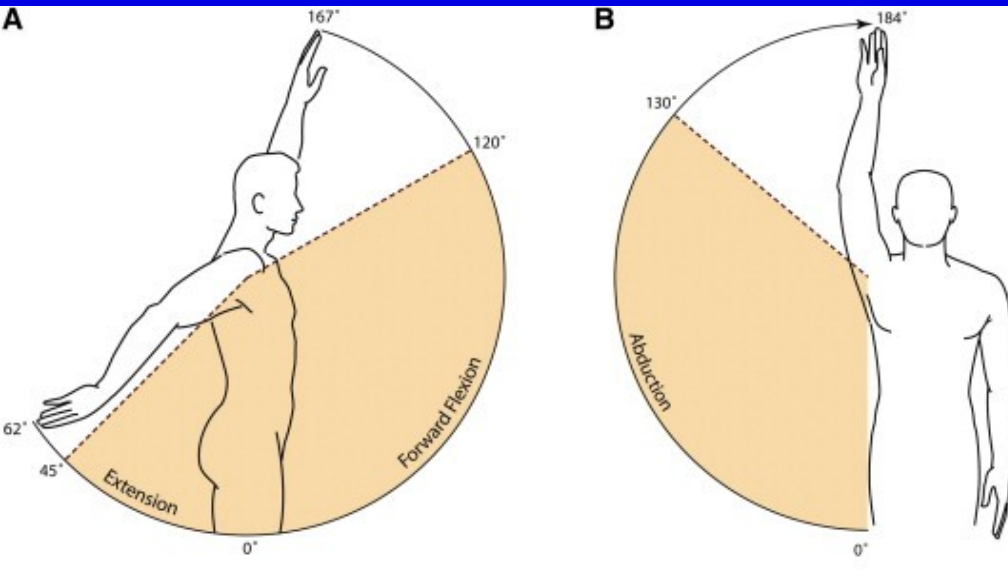
Upper extremity: acromion- 3. finger

- Circumferential measurement

ROM

- Active and passive movements
- **S**agittal
- **F**rontal
- **T**ransversal = horizontal
- **R**otation

Shoulder



S: extenze - 0 - flexe
50 - 0 - 180

F: abdukce - 0 -
addukce

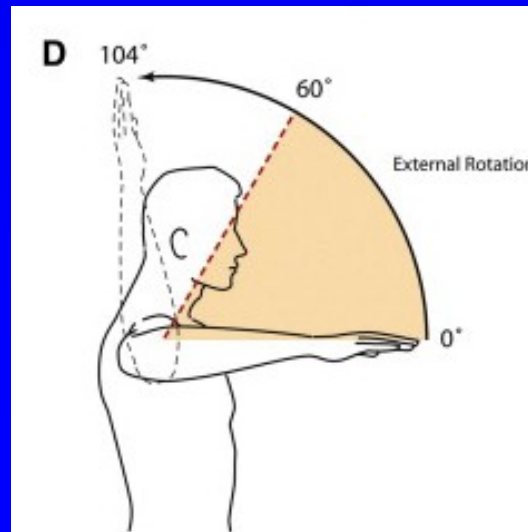
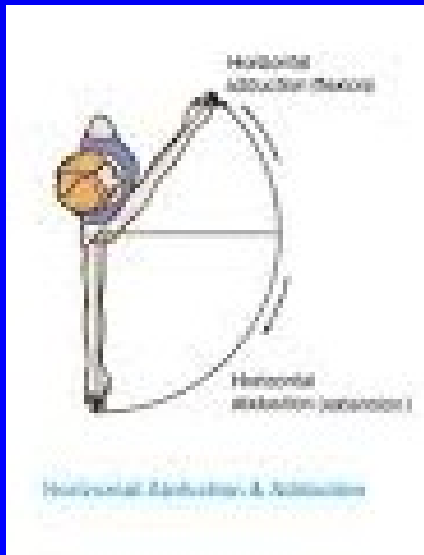
180 - 0 - 25

T: abdukce - 0 -
addukce

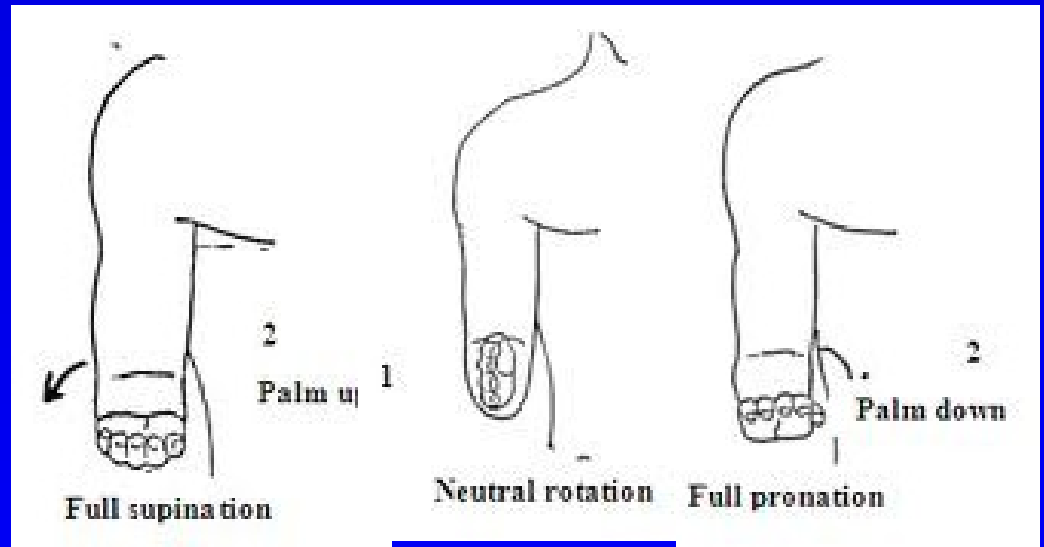
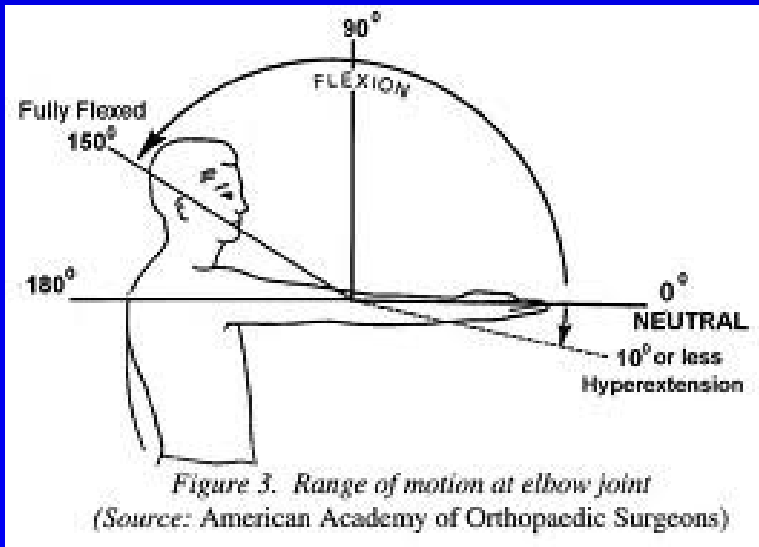
110 - 0 - 30

R: ZR - 0 - VR

90 - 0 - 90



Elbow



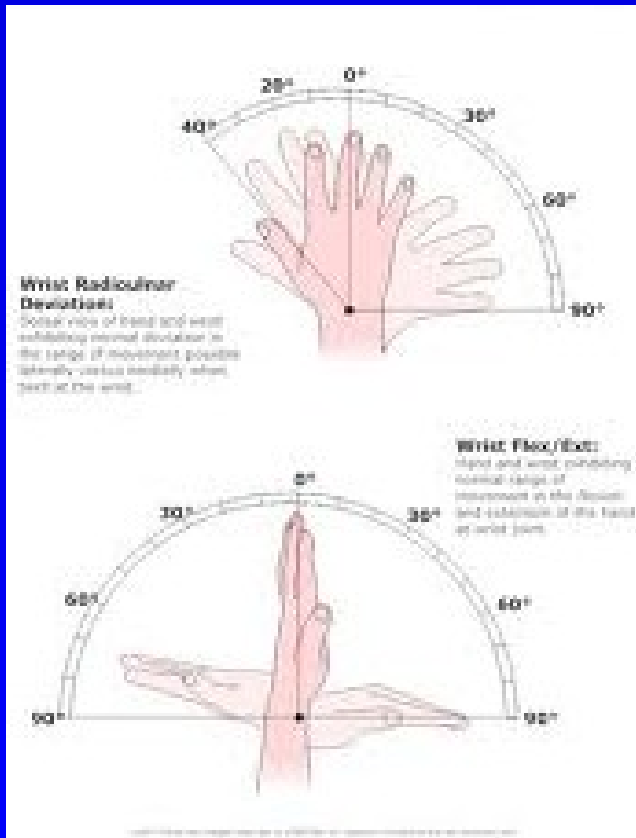
**S: extenze - 0 -
flexe**

10 - 0 - 150

R: supinace - 0 - pronace

90 - 0 - 90

Wrist



F: rad. dukce - 0 - uln. dukce

20 - 0 - 40

S:extenze (dor. flexe) - 0 – flexe (palm. flexe)

80 - 0 - 80

Hip

S: extenze - 0 - flexe
15 - 0 - 140

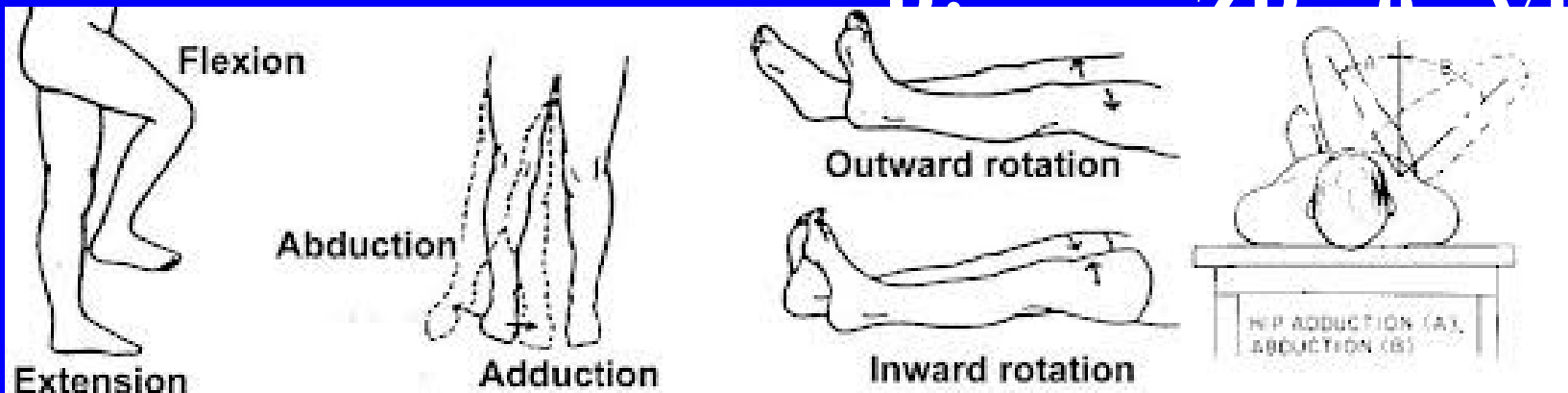
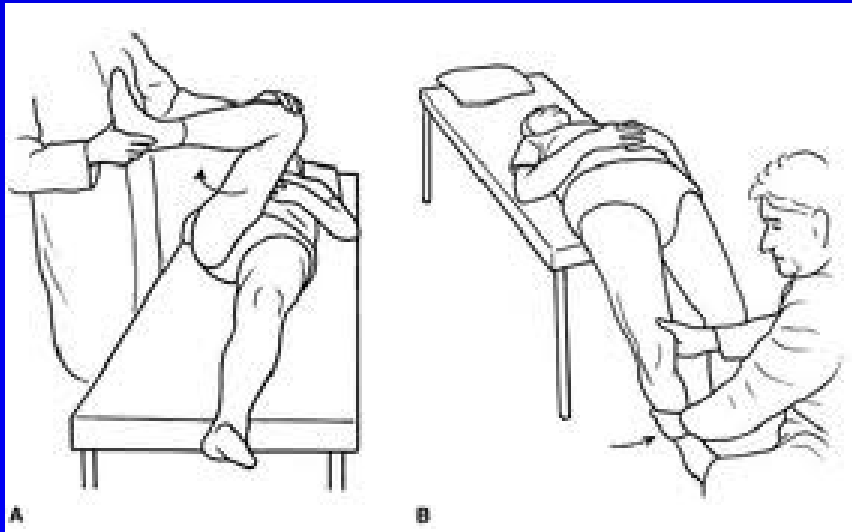
F: abdukce - 0 -
addukce

60 - 0 - 40

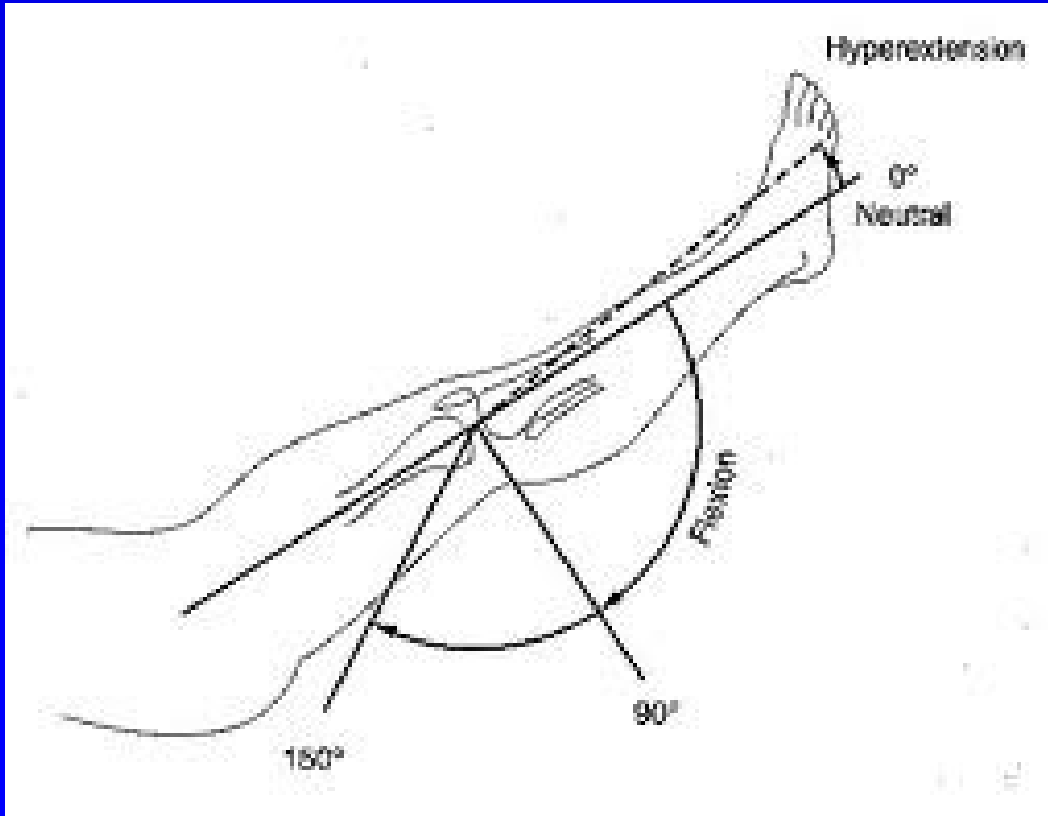
T: abdukce - 0 -
addukce

80 - 0 - 30

D: ZD 0 VR



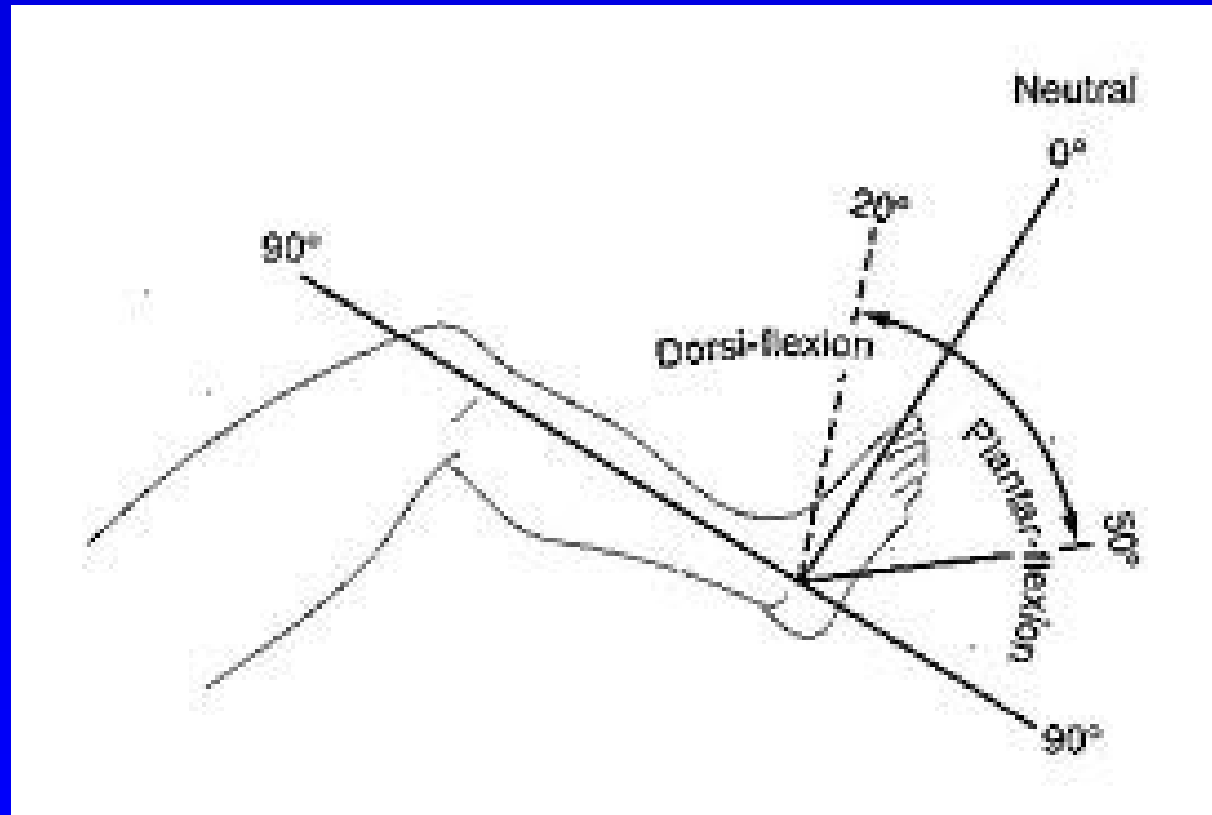
Knee



**S: extenze - 0 -
flexe**

0 - 0 - 140

Ankle

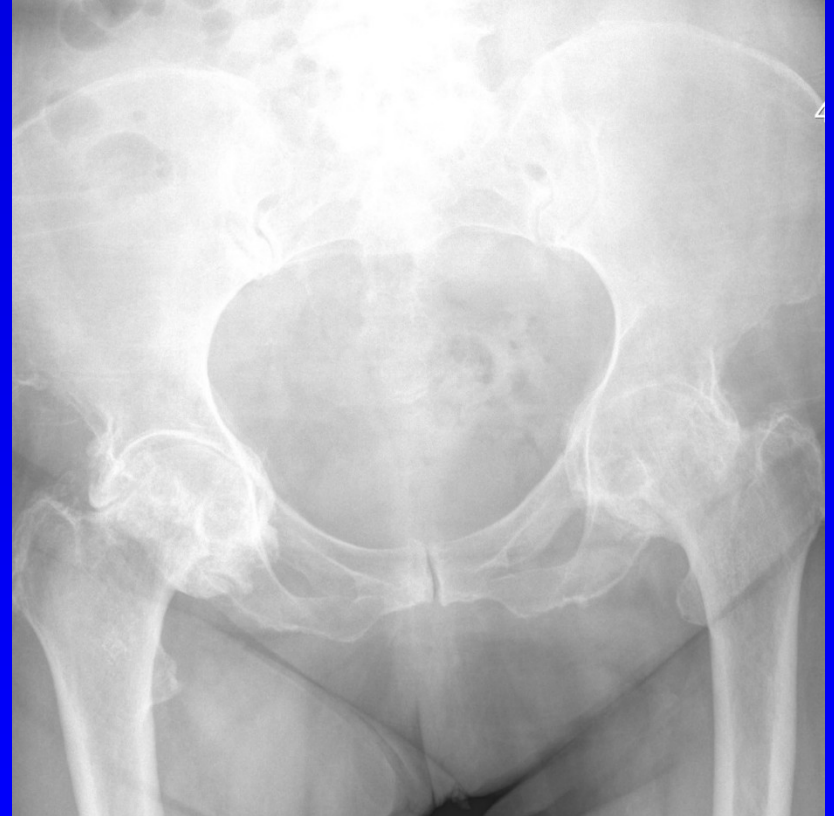

**S: extenze (dorzi flexe) - 0 - flexe
(plantiflexe)**

20 - 0 - 50

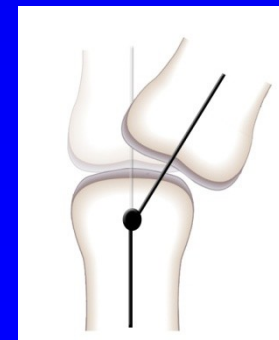
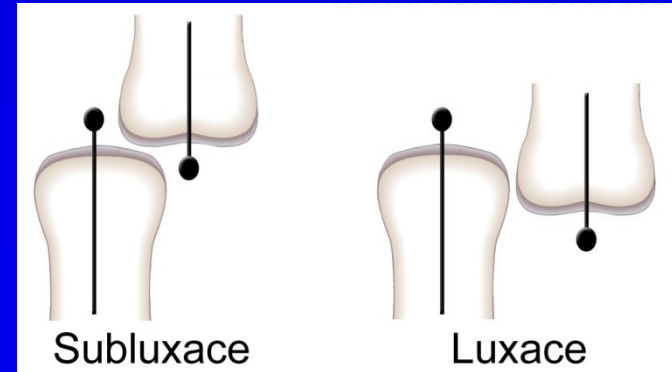
Ancylosis

- **Extrarticular**
- **Intraarticular**



Stability of joints

- Stable joint
- Unstable joint
- Instability
 - acute
 - chronic
 - habitual

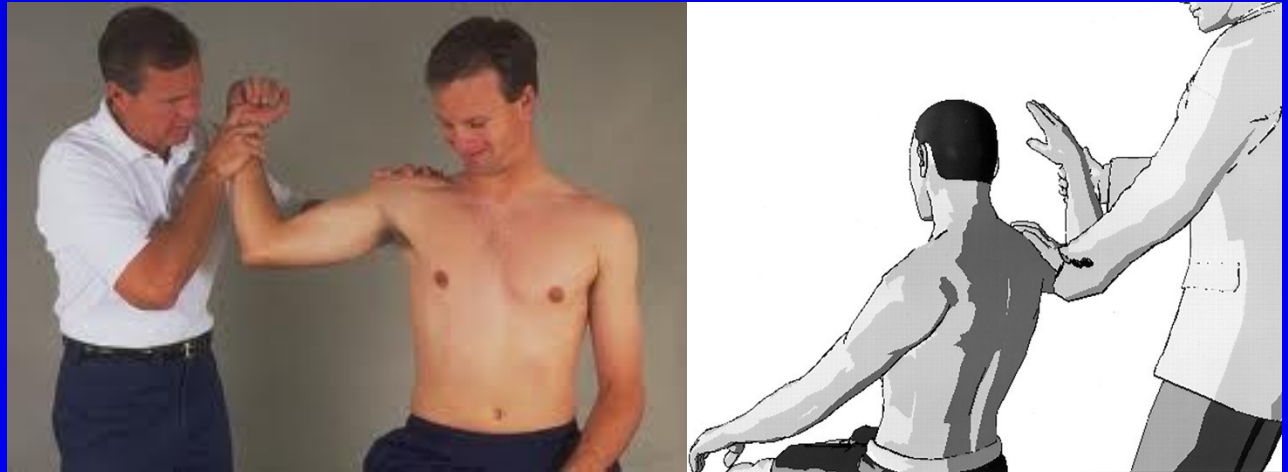


Deviace

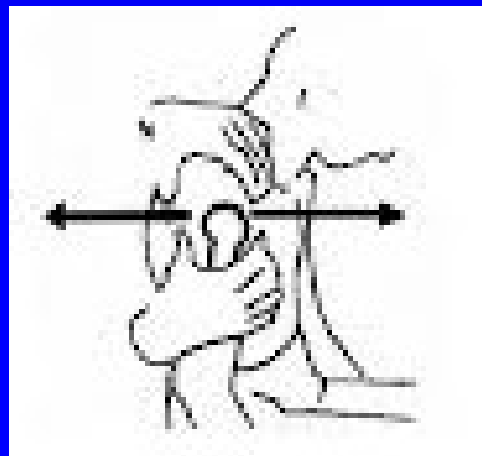
Desaxace

Shoulder

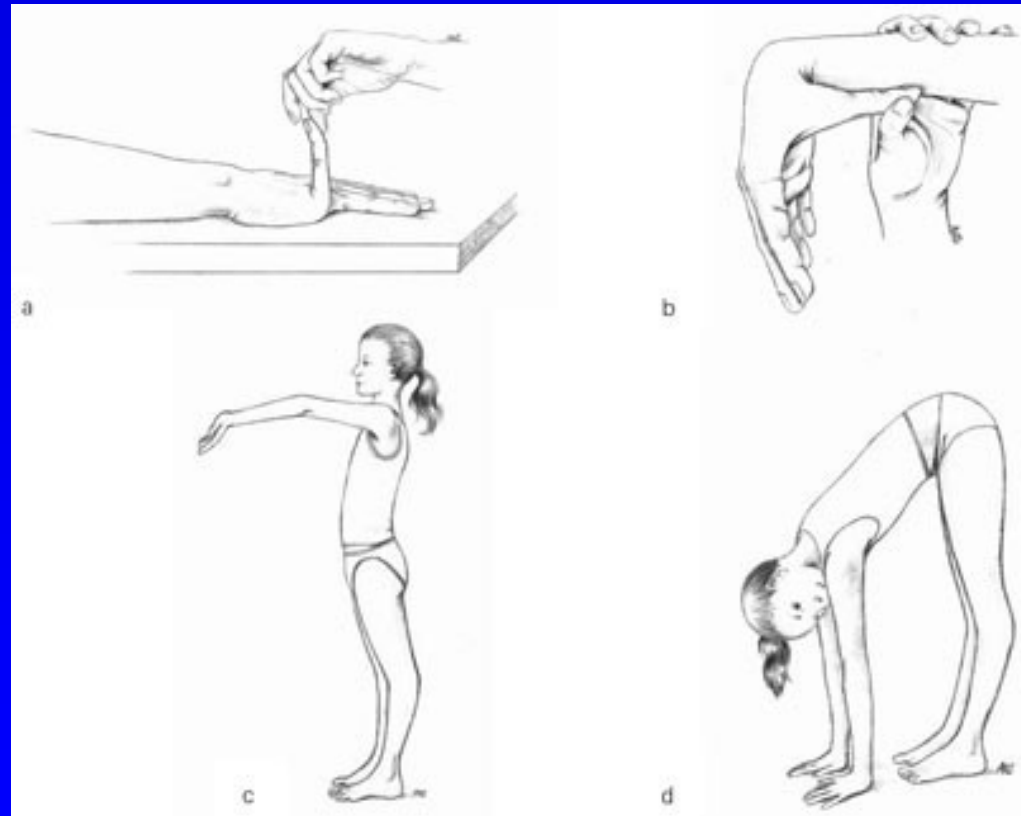
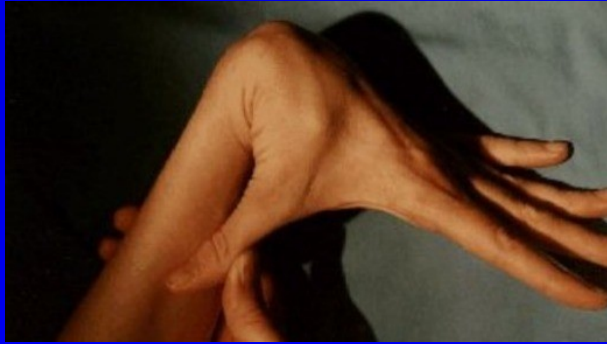Apperhension test



Drawer sign



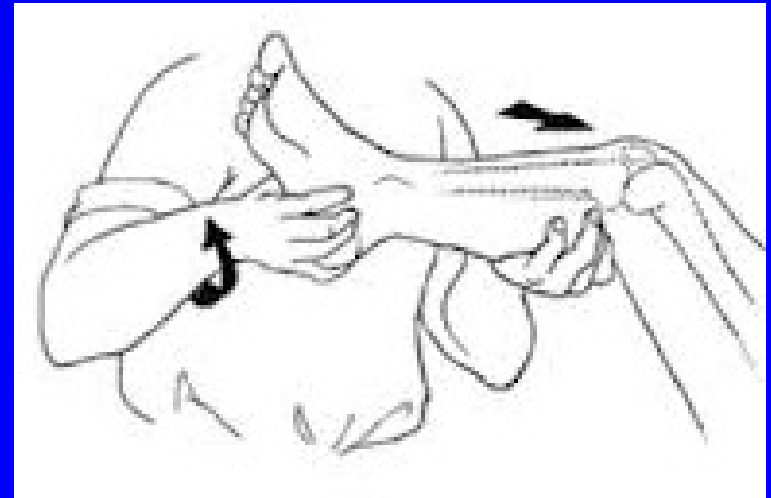
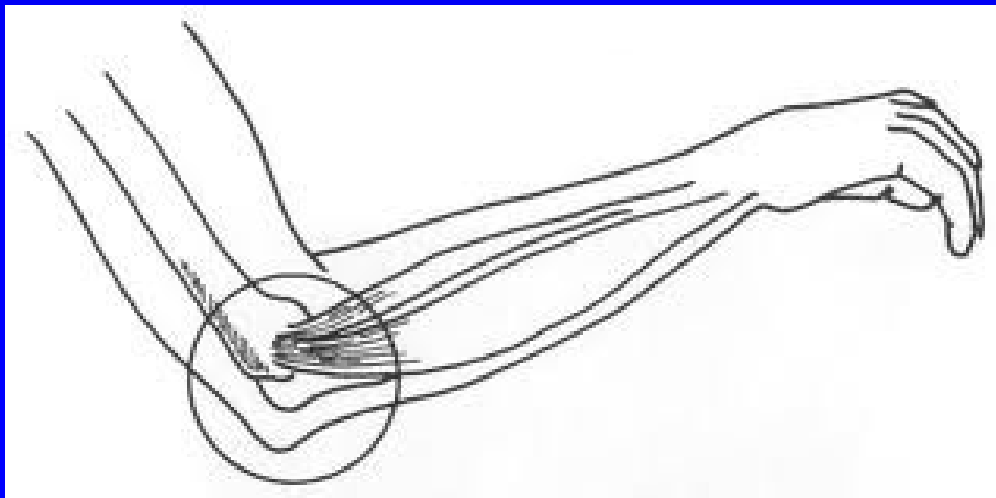
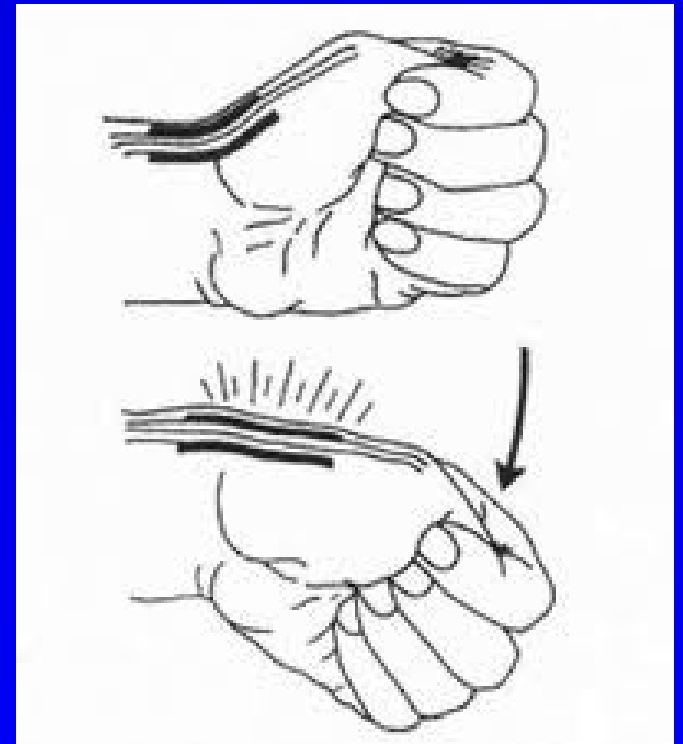
Laxity



- test

Maneuvers

- Maneuvers

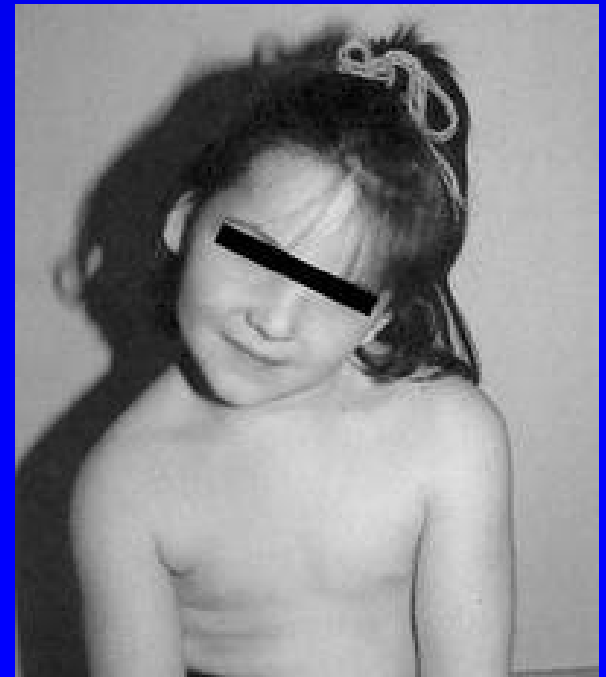
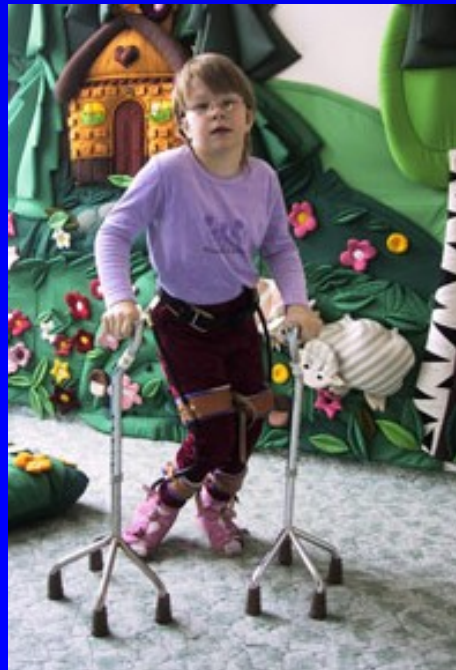
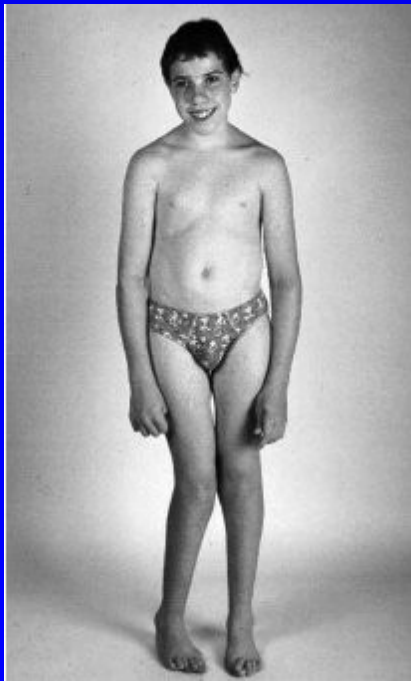Sound phenomenons

- Crepitus

Contracture

- Lumbago, torticollis
- Cerebral palsy



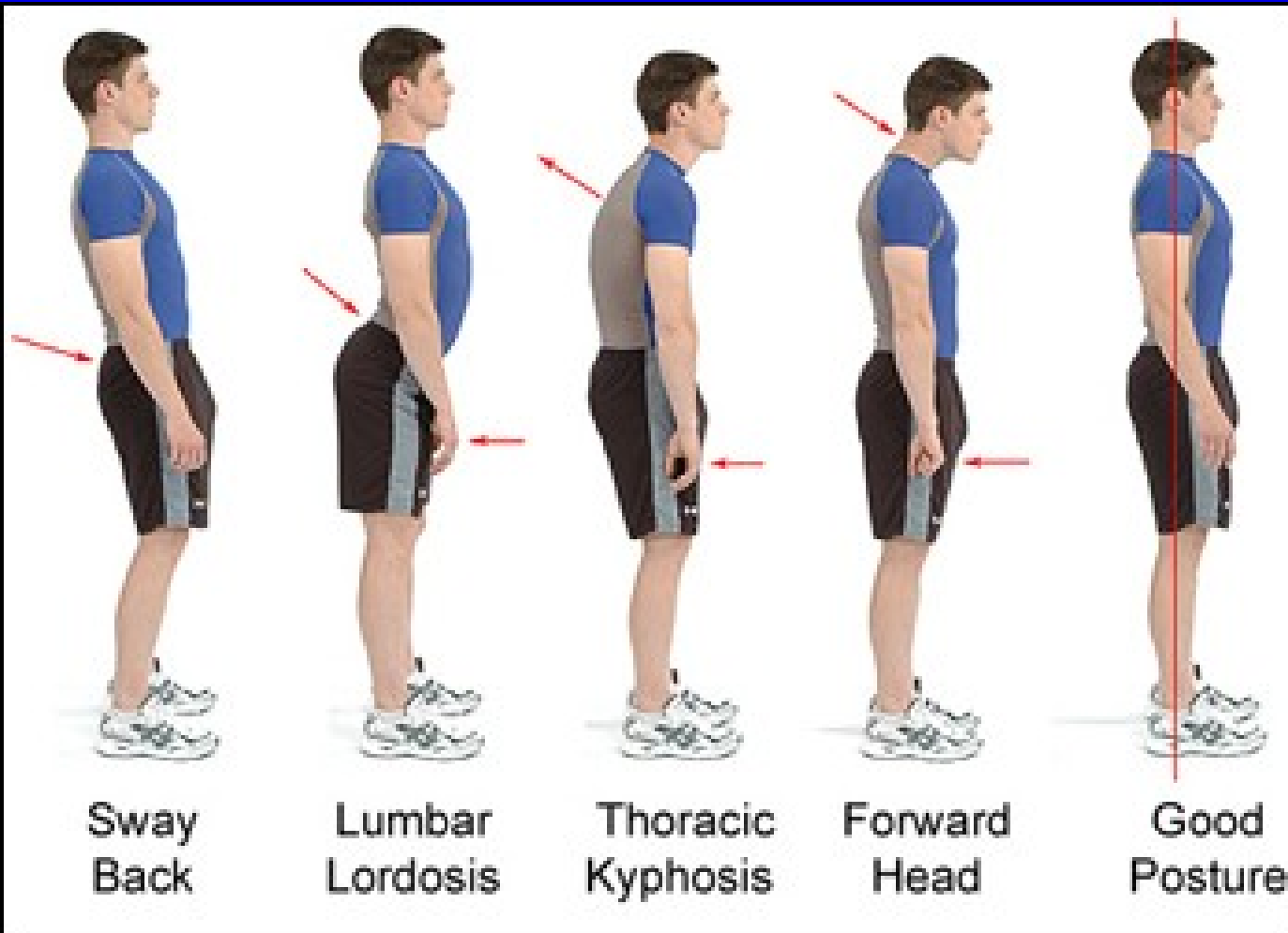
Muscles

- Trophicity
- Tonus
- Cramps
- Power

Muscle test

0 - no activity	0 %
1 - trace	10 %
2 - motion without gravity	25 %
3 - motion against gravity	50 %
4 - motion against gravity and slight resistance	75 %
5 - normal activity	100 %

Posture




Correct

Wrong

Gait

- 1. heel strike
- 2. standing
- 3. toe off
- 4. swing phase



Limping

- Antalgic gait
- Shortening of a lower extremity
- Ancylosis
- Trendeleburg sign and gait
- Hemiparetic gait
- Spastic gait
- Drop foot gait
- Parkinson gait

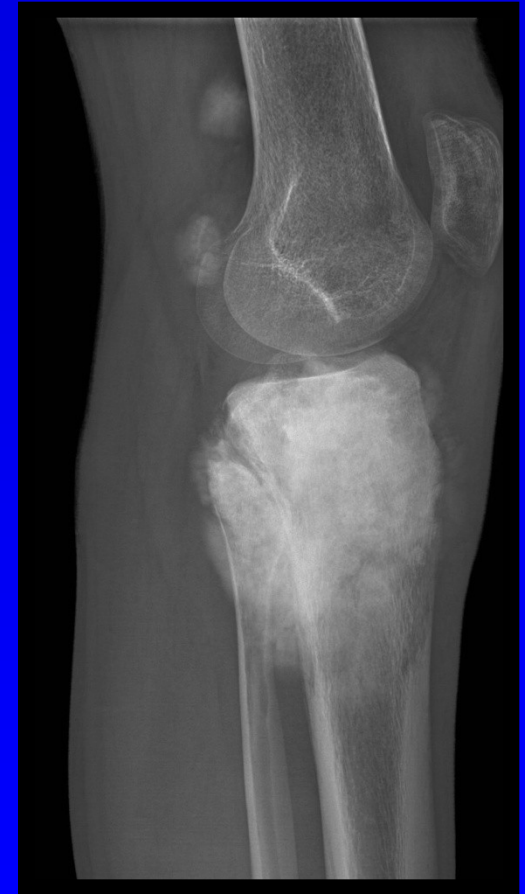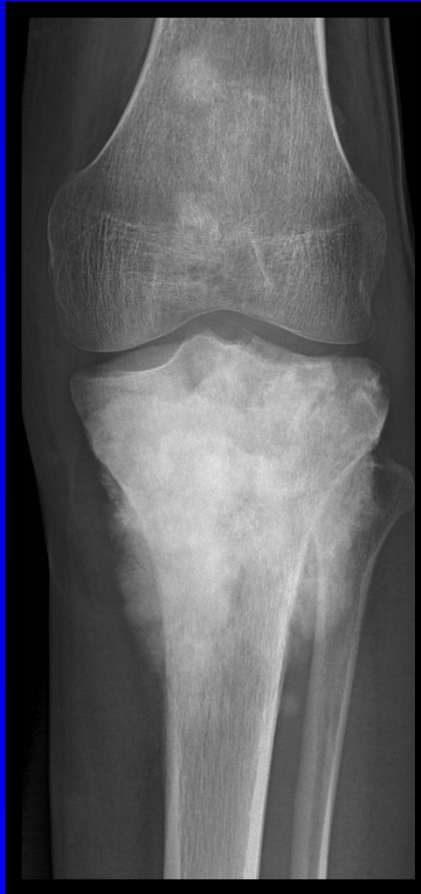Imaging methods

- X-ray, artrography
- Angiography
- Ultrasonography
- CT, MRI
- Scintigraphy
- DEXA
- Biopsy

X-ray

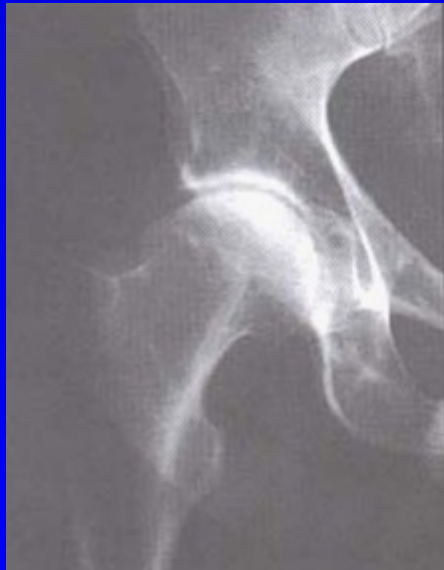In two planes

- bone hypertrophy
- bone atrophy
- osteolysis
- osteonecrosis

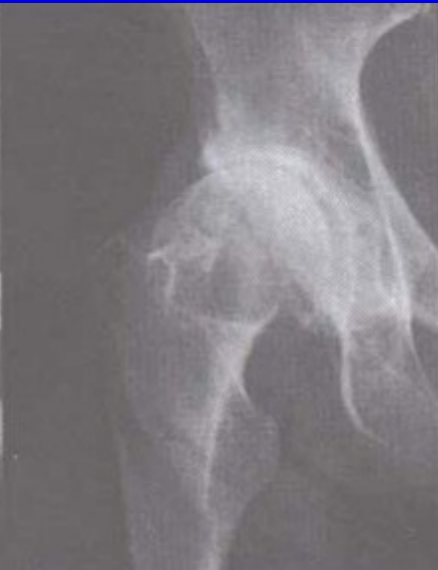

Kellgren- Lawrence clasification of O.A.

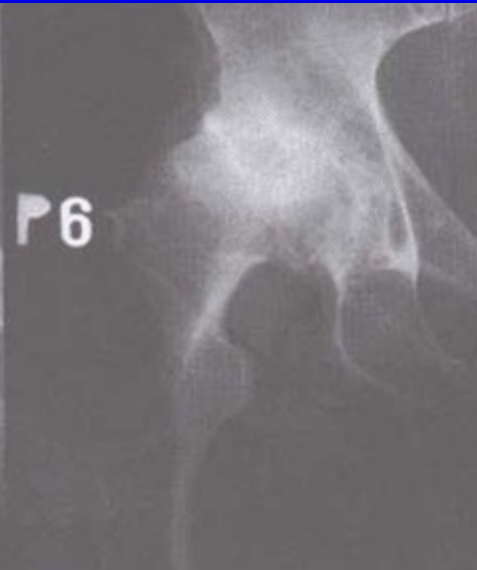I.



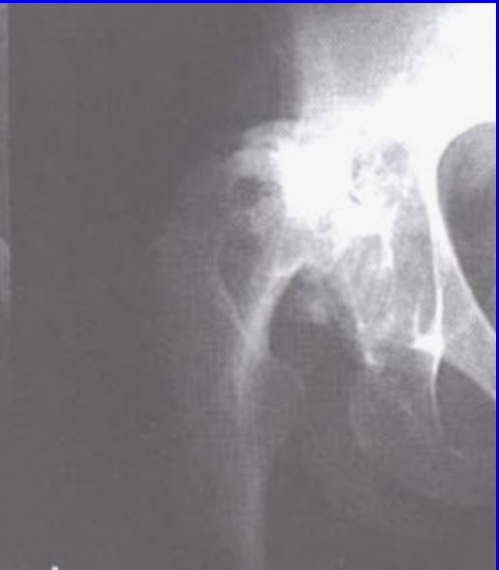II.



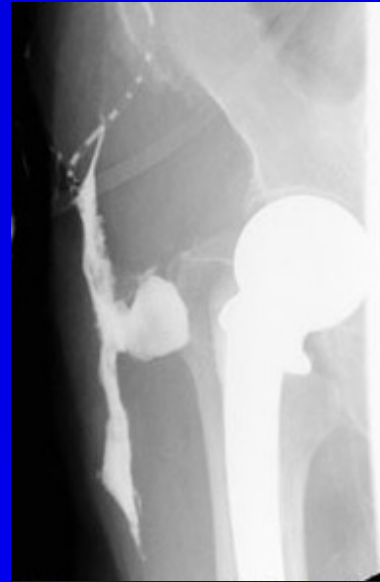
III.



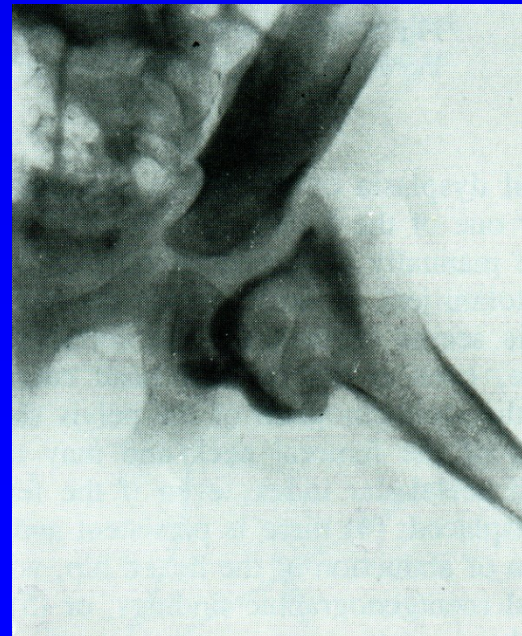IV.



Fistulography



Arthrography



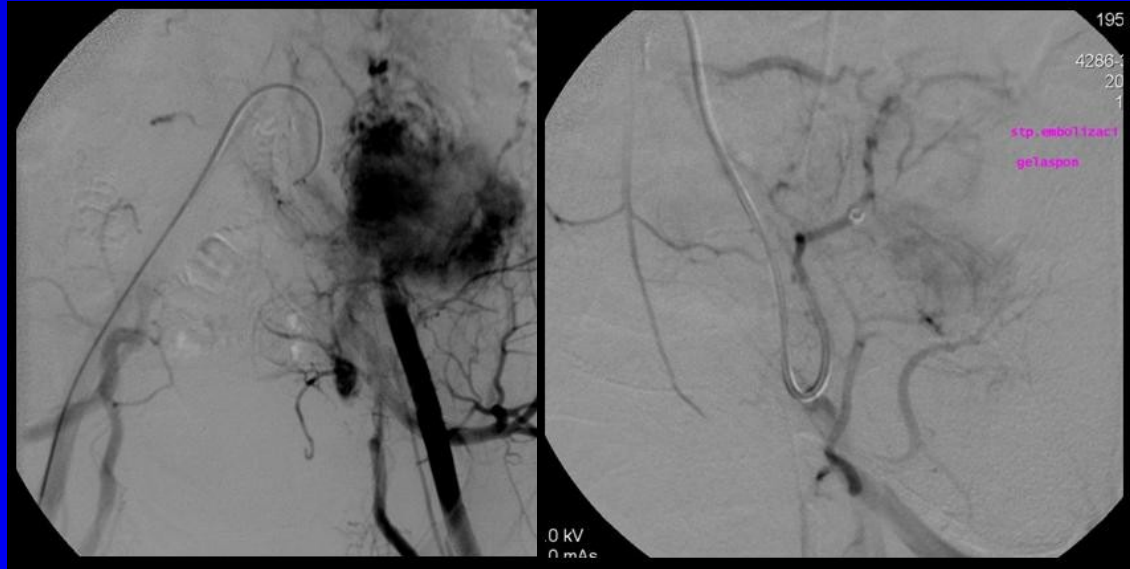
Angiography

Classical

CT angiography

MR angiography

Digital subtraction angiography



Ultrasonography

Echogenicity of tissues

Bone, fibrous tissue, muscles, adipous tissue, cartilage, fluid

Anechogenic structure- black

Hypoechogenic structure- grey

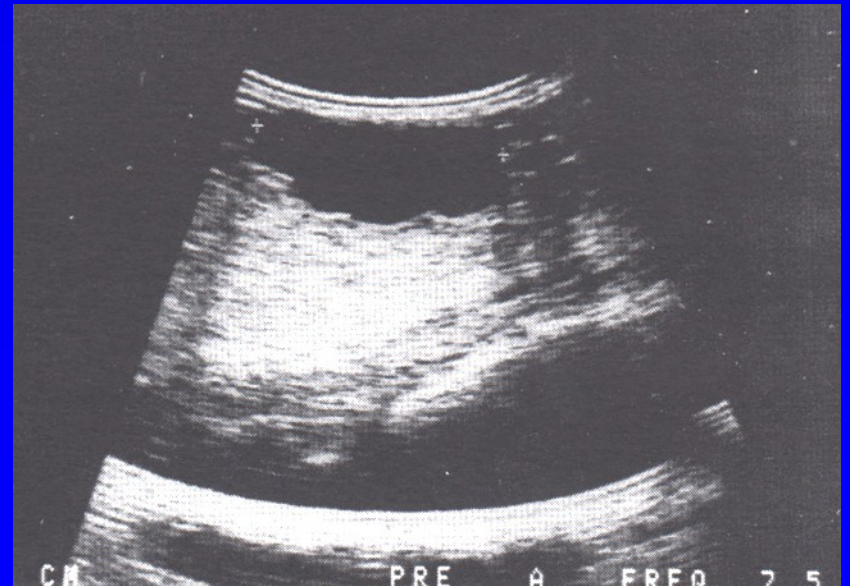
Hyperechogenic structure- white

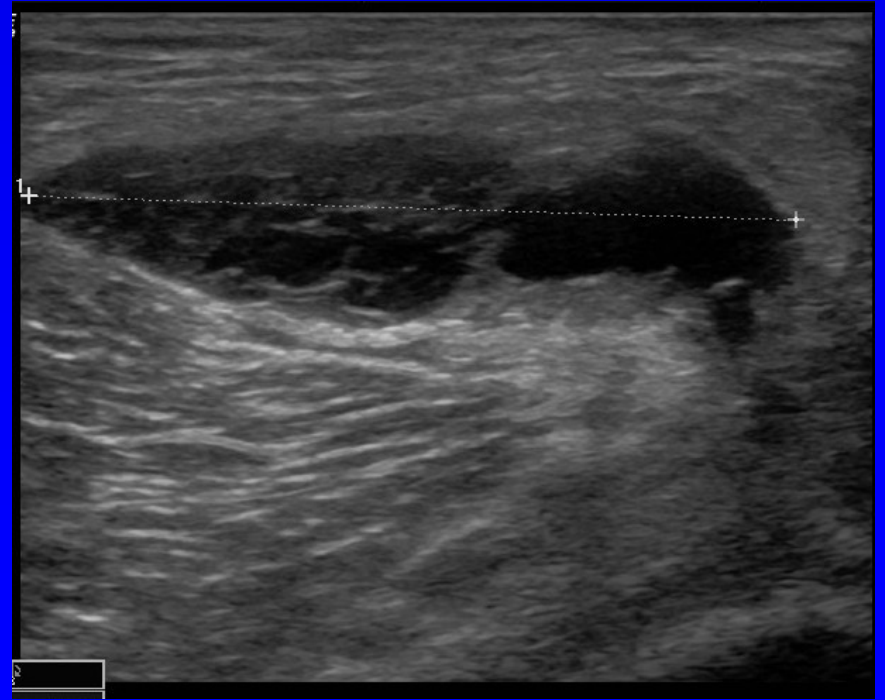
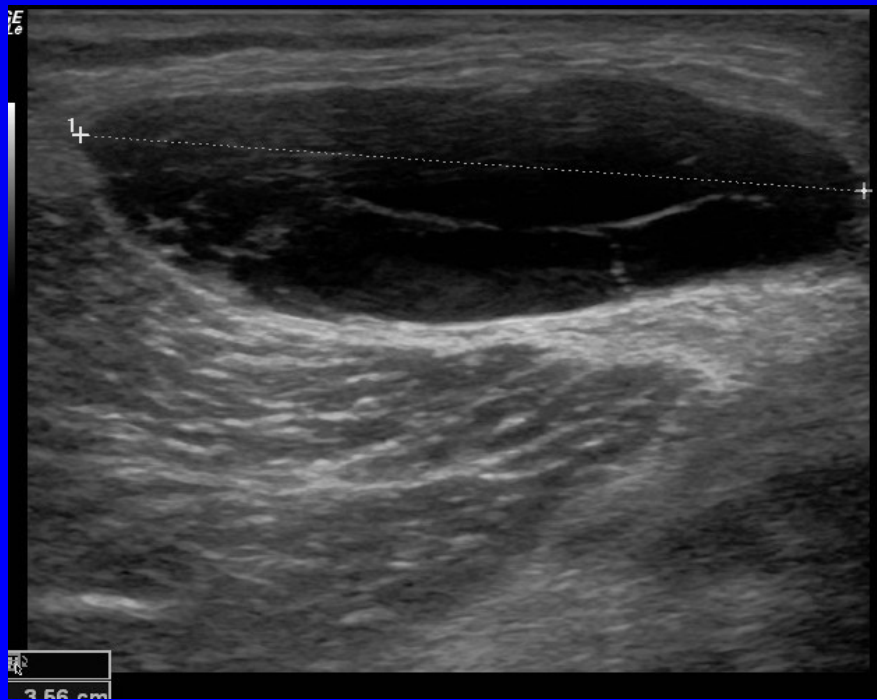
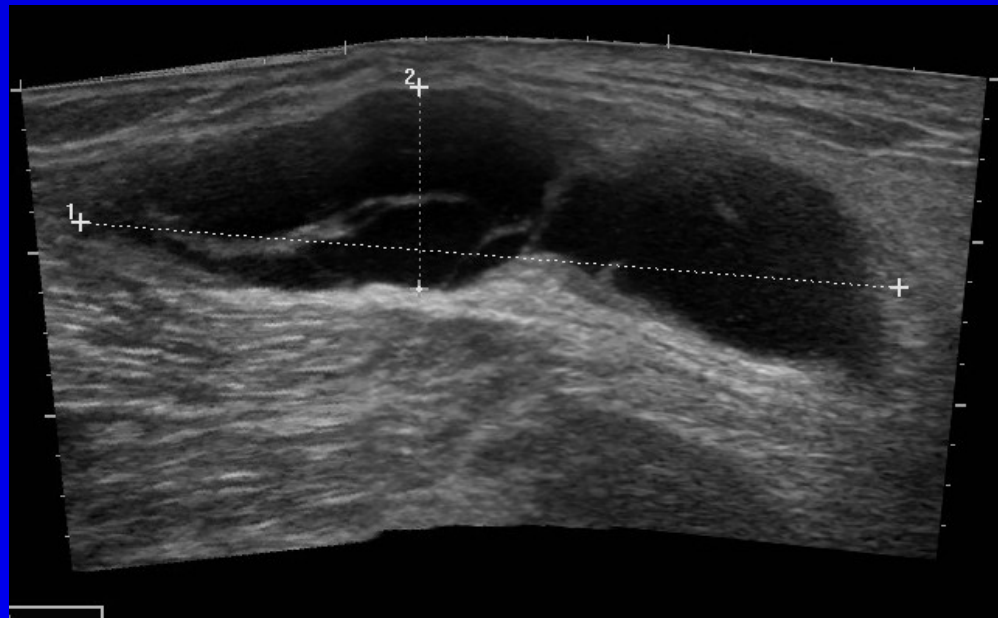
Soft tissues

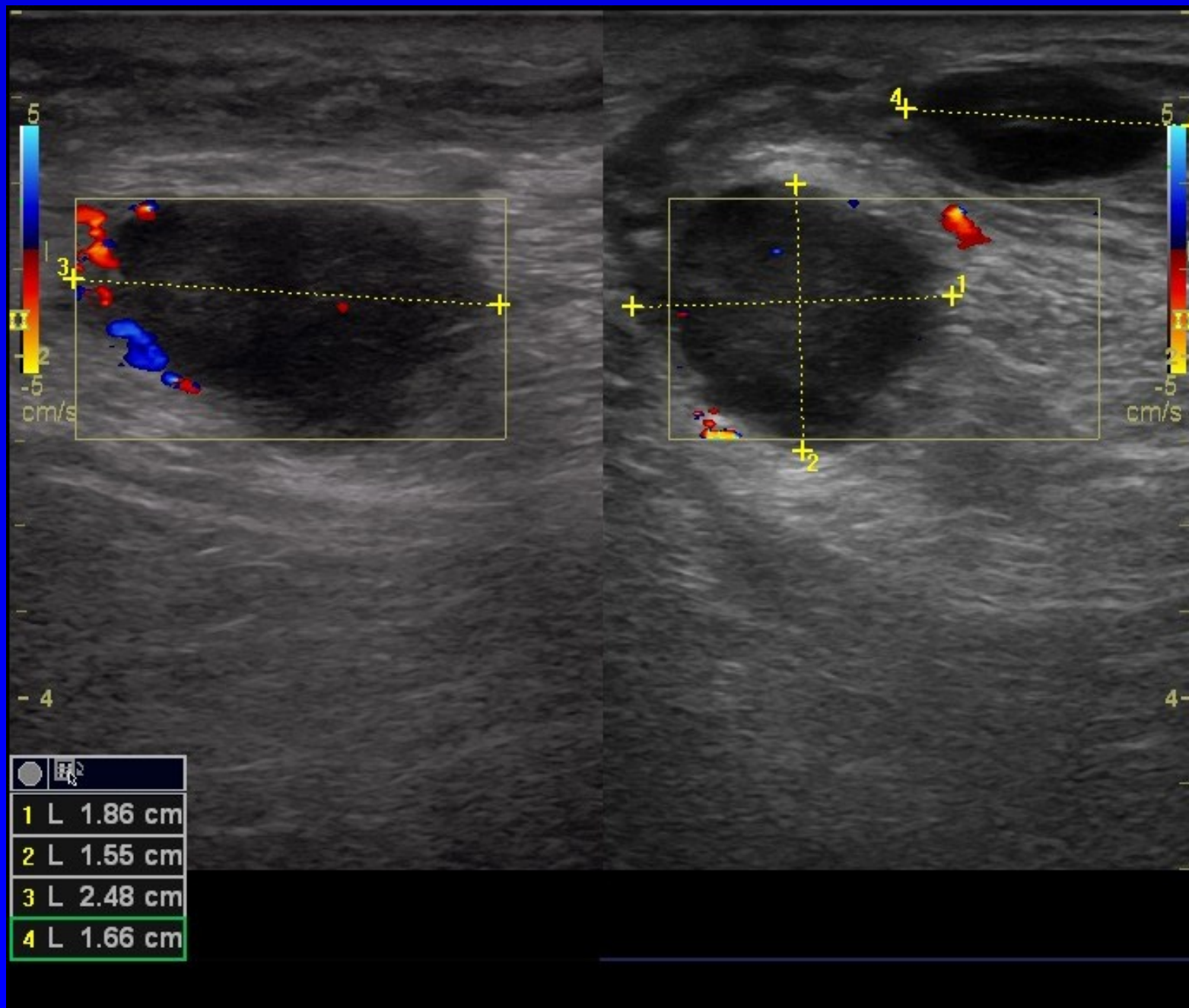
Tumors

DDH

Effusion in joints







CT scann

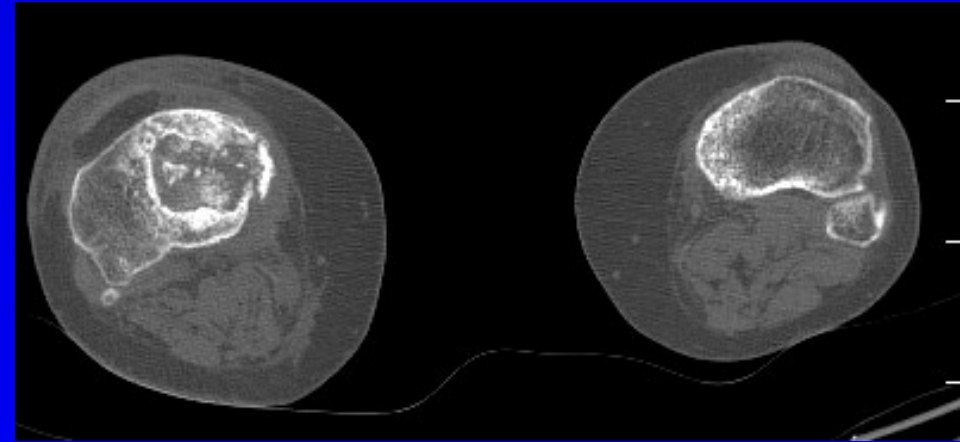
Absorption of X-ray beams

Air – 1000 H.U.

Water 0 H.U.

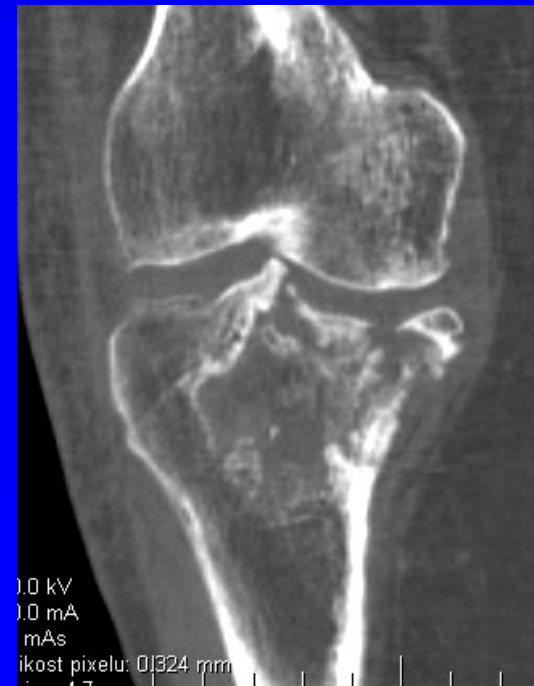Bone + 1000 H.U.

Enhancement with a dye

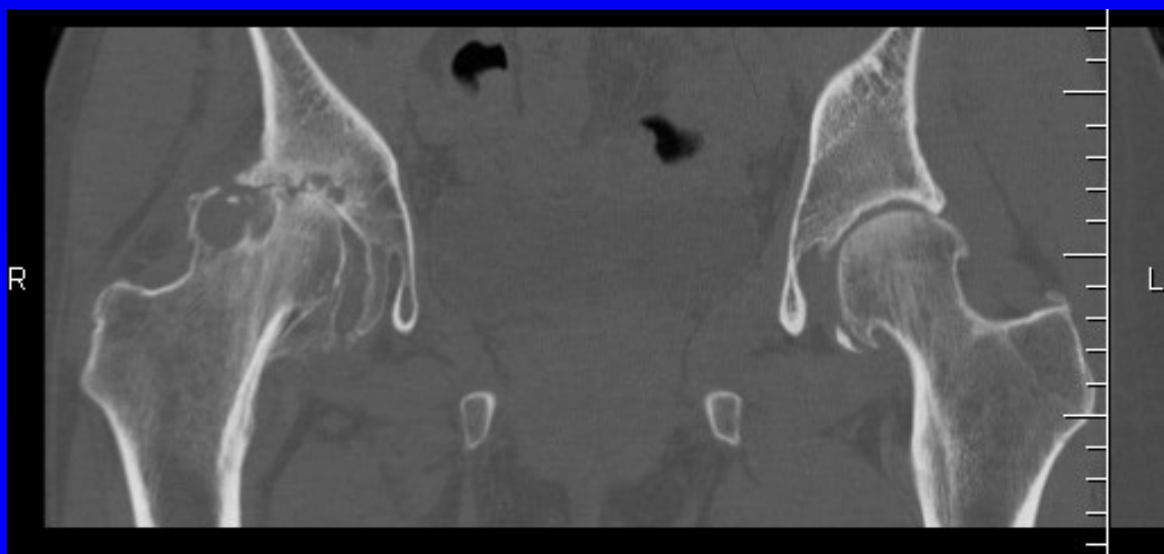
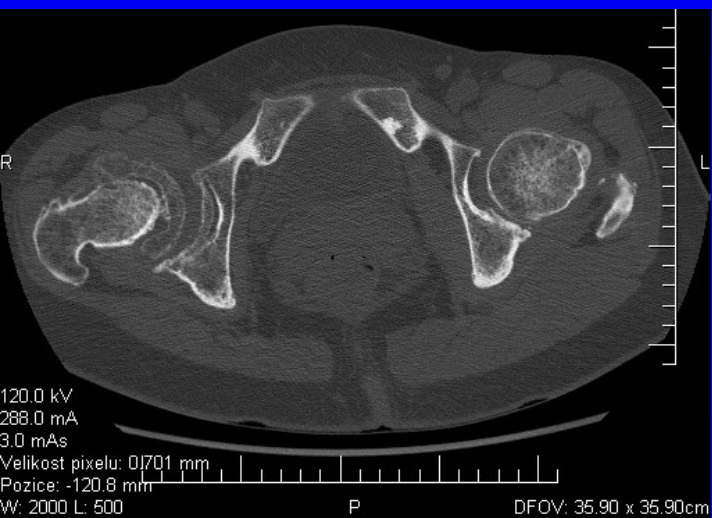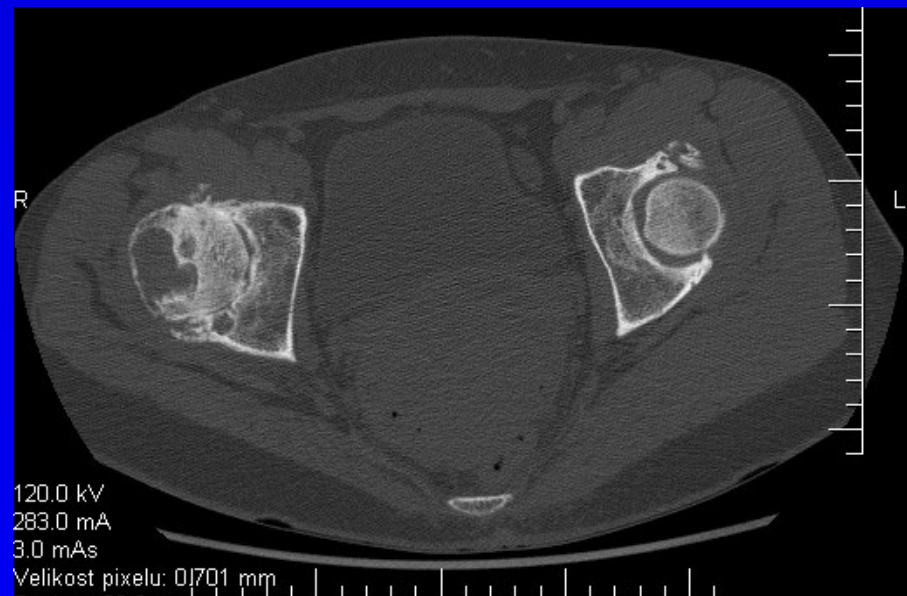
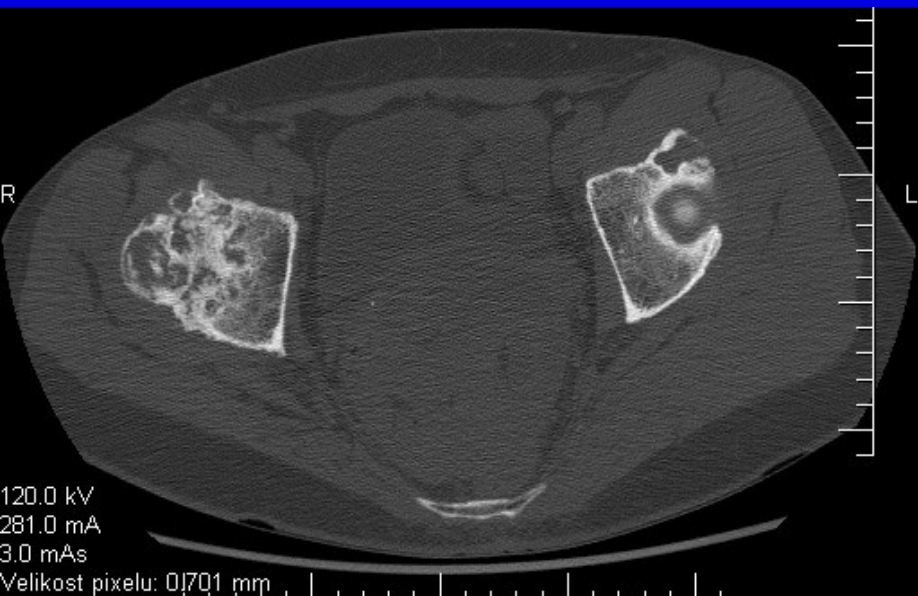


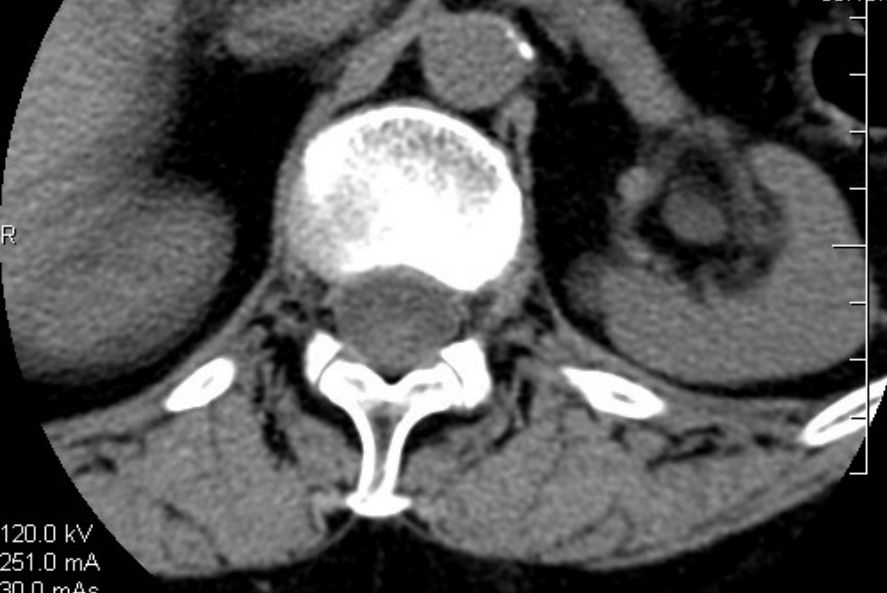Bone lesions

Bone tumors

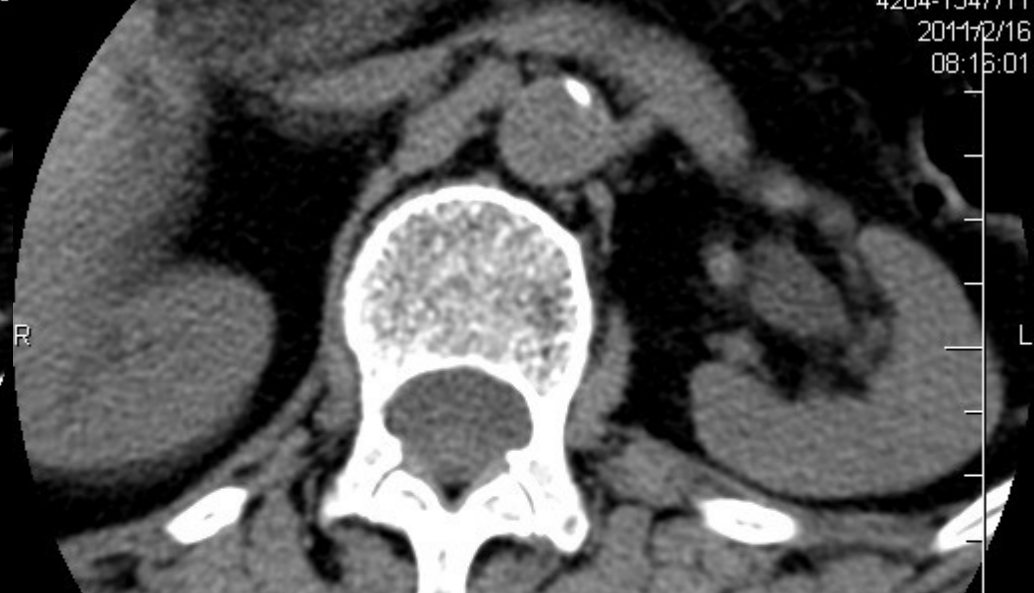


CT

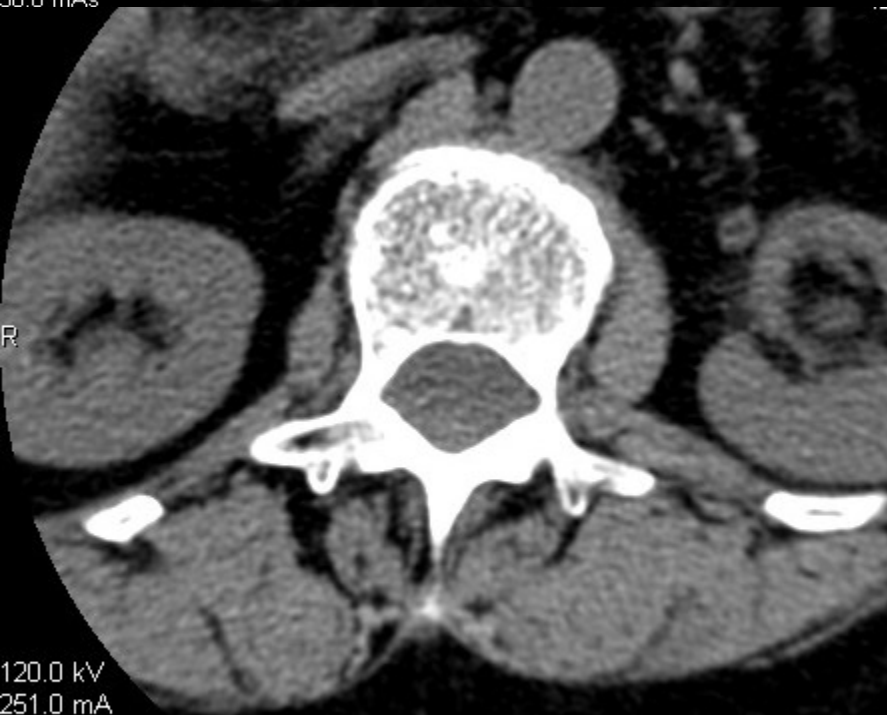




120.0 kV
251.0 mA
30.0 mAs

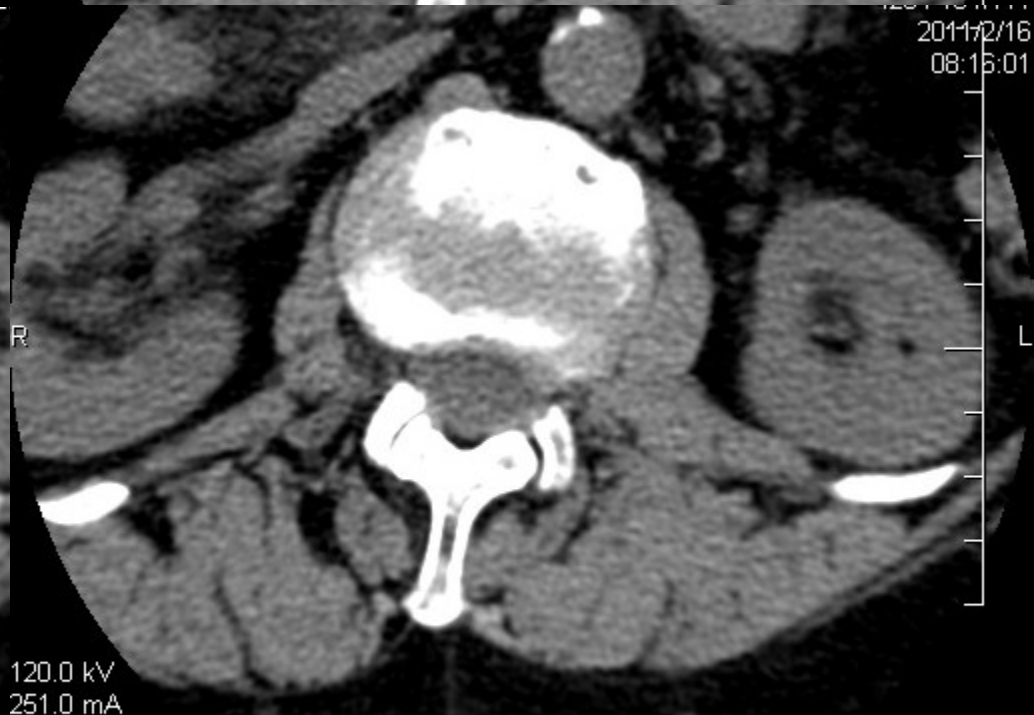

4204-134771
2011/2/16
08:15:01



120.0 kV
251.0 mA
30.0 mAs

Velikost pixelu: 0,313 mm
Pozice: 138.3 mm
W: 300 L: 60



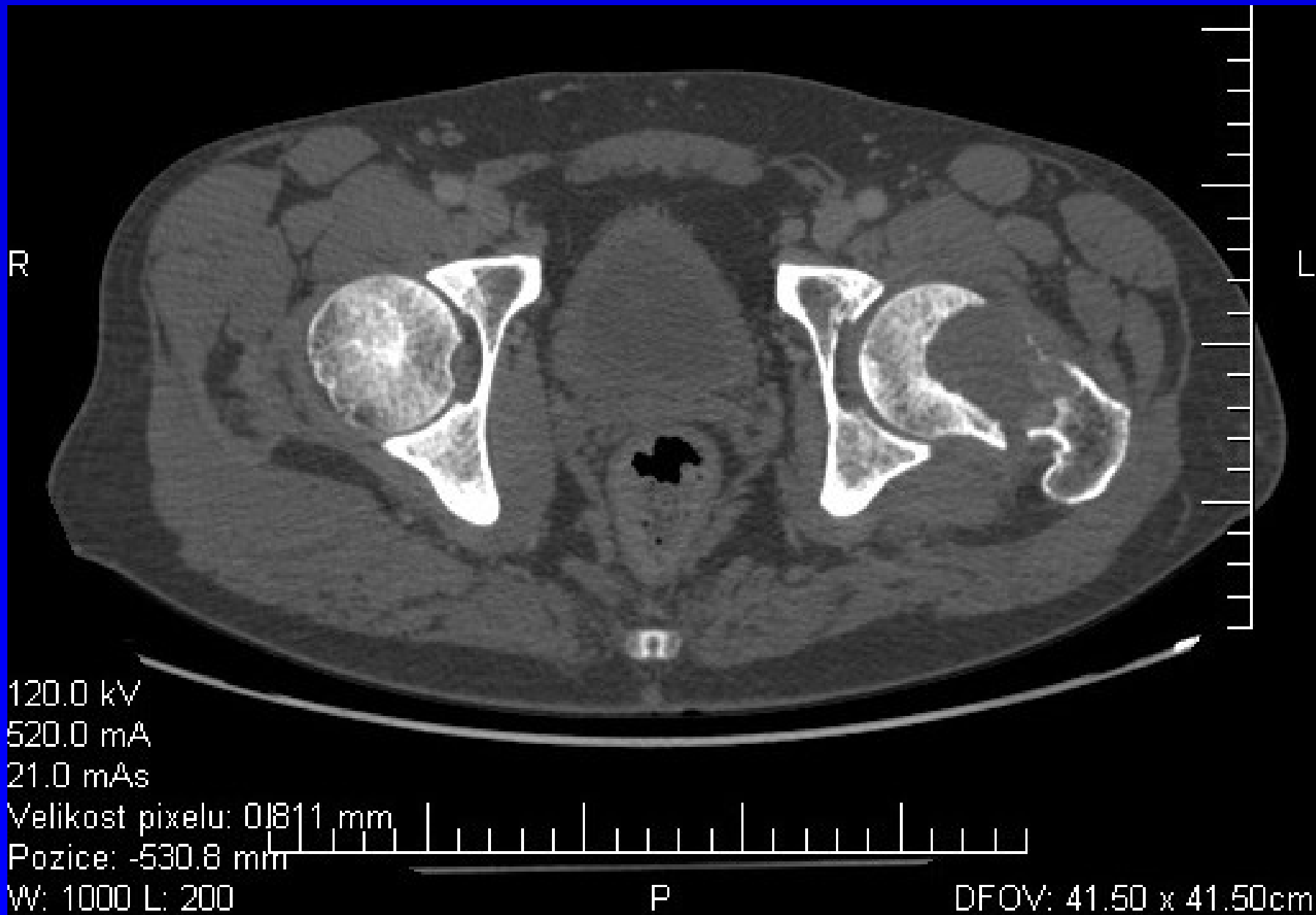2011/2/16
08:15:01

120.0 kV
251.0 mA
30.0 mAs

Velikost pixelu: 0,313 mm
Pozice: 128.3 mm

DFOV: 16.00 W: 300 L: 60

DFOV: 16.00 x 16.00 cm



MRI

Magnetic field

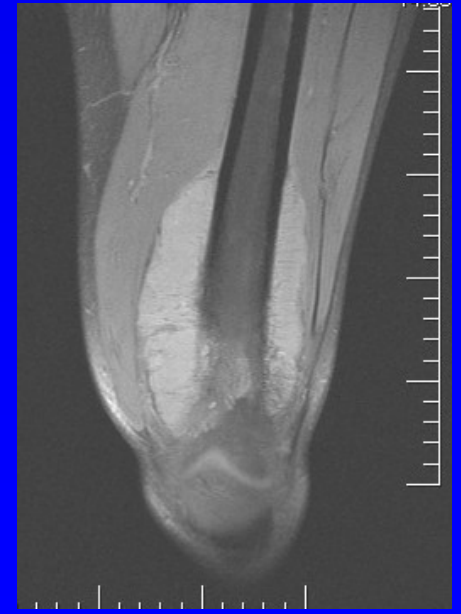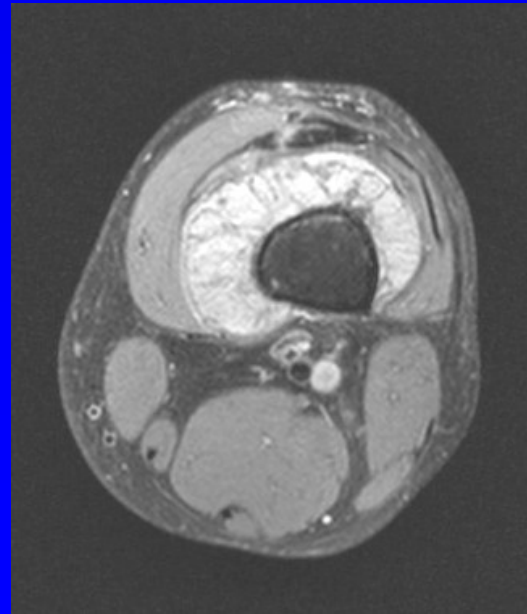
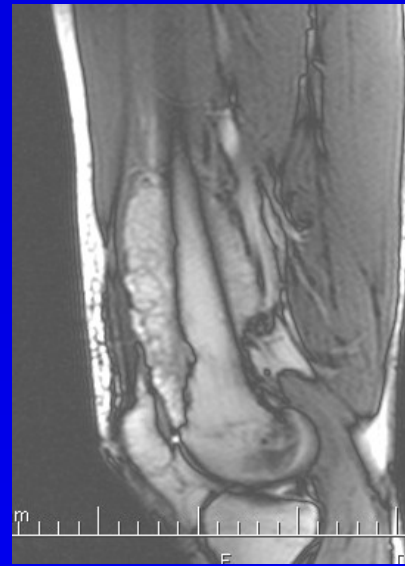
Hyposignal- dark

Hypersignal - white

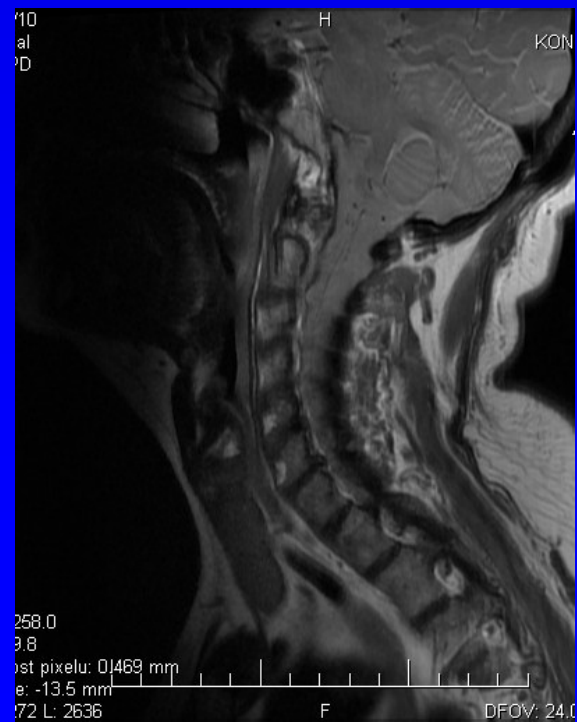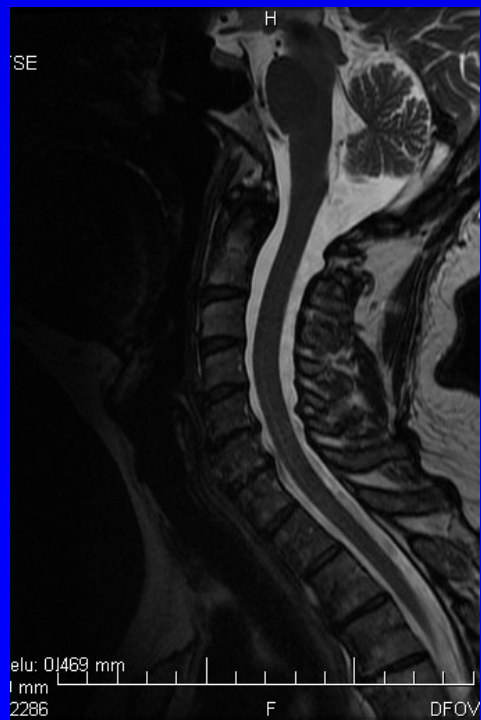
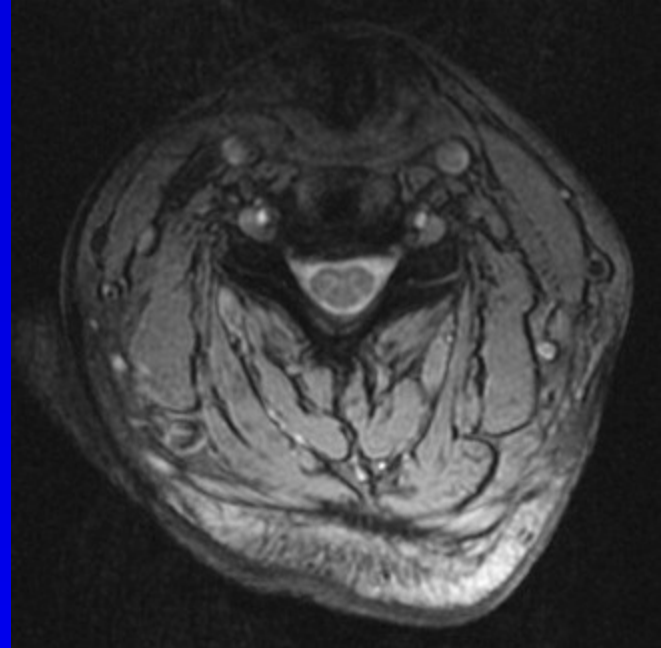
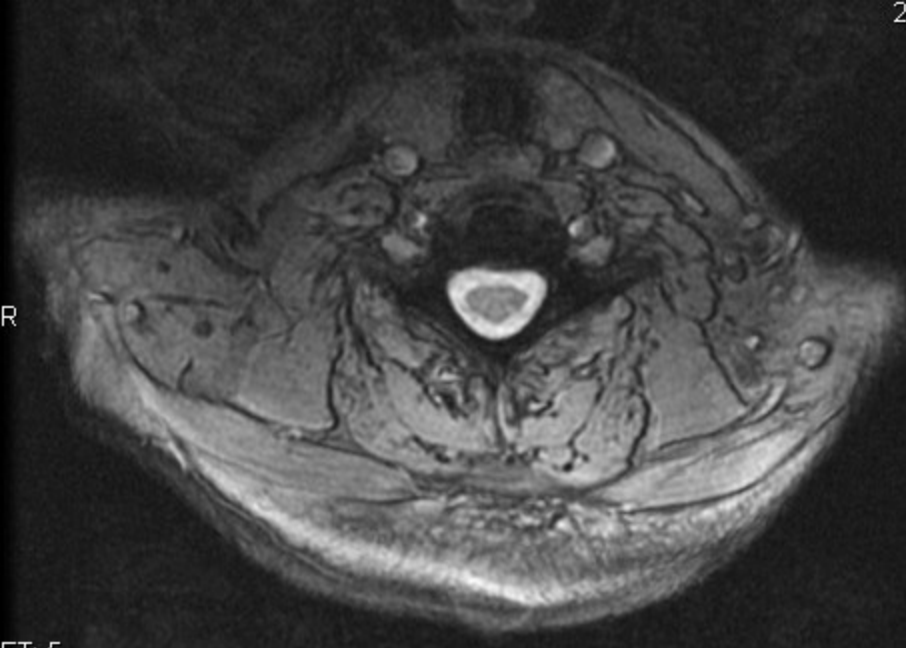
Soft tissue tumors

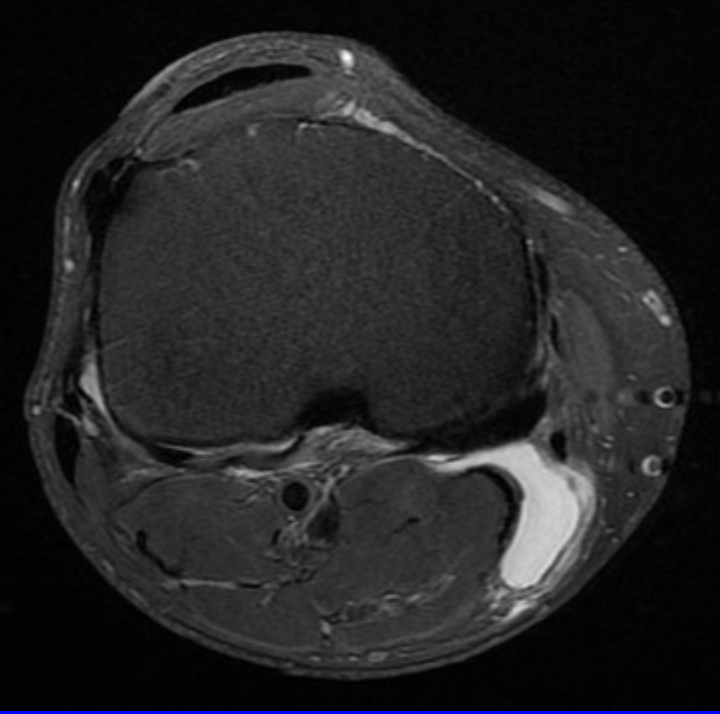
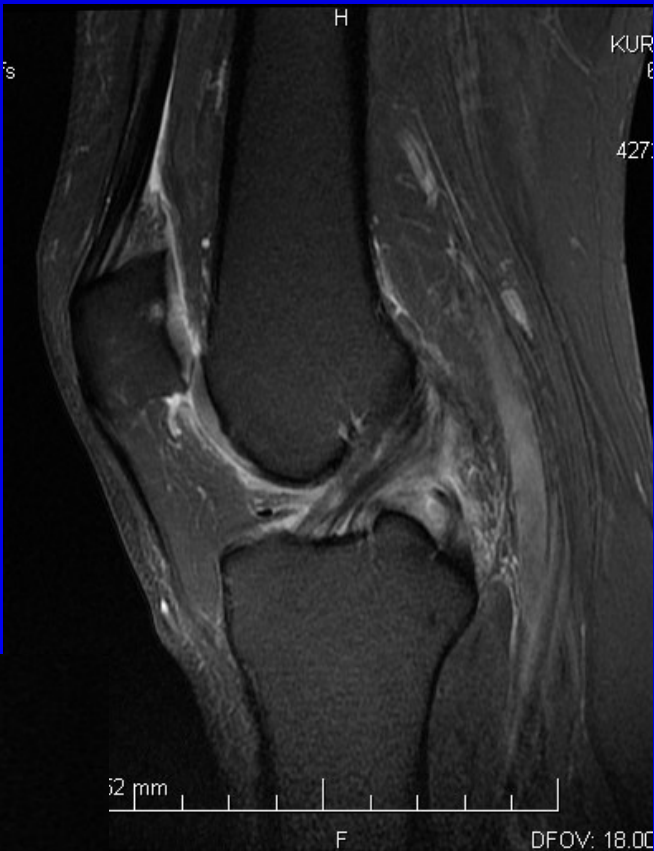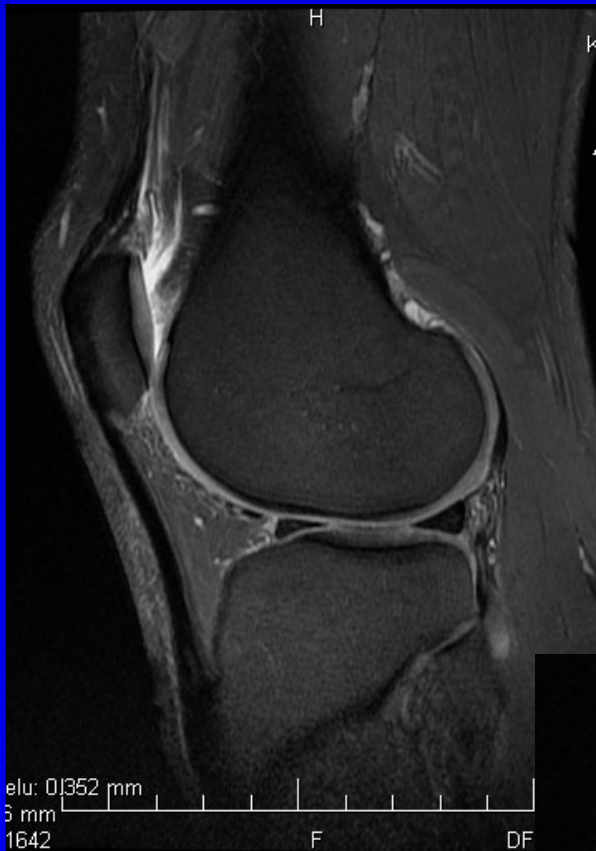Soft tissue mass

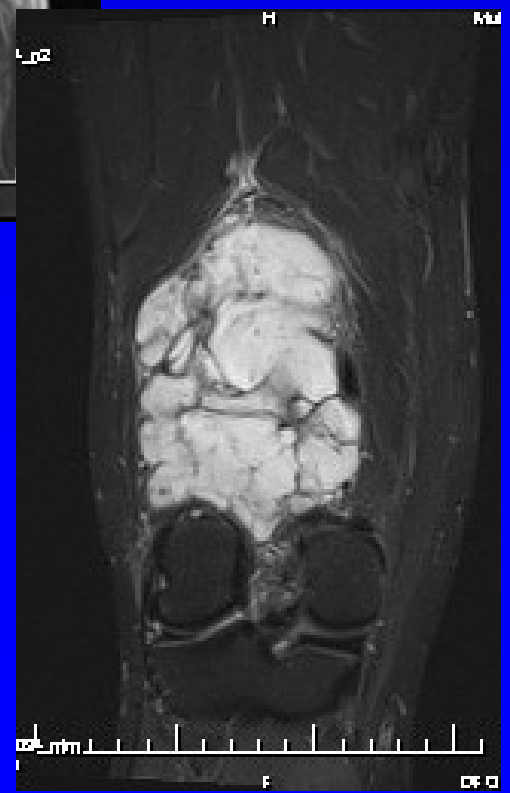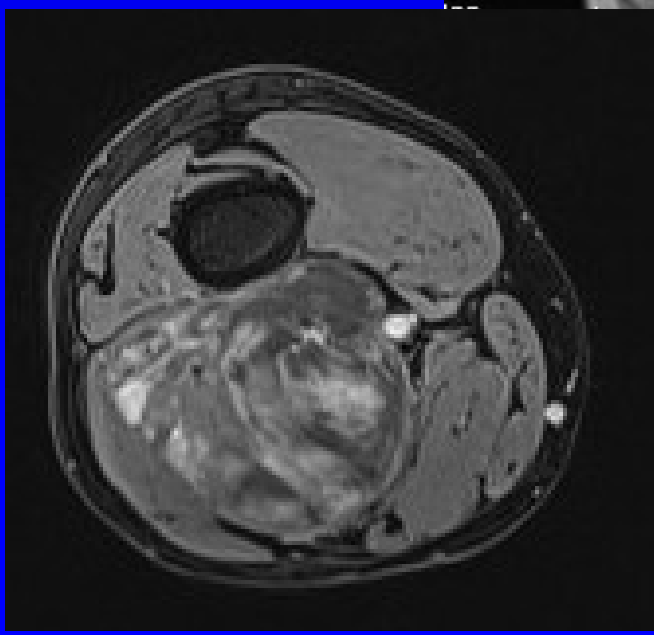
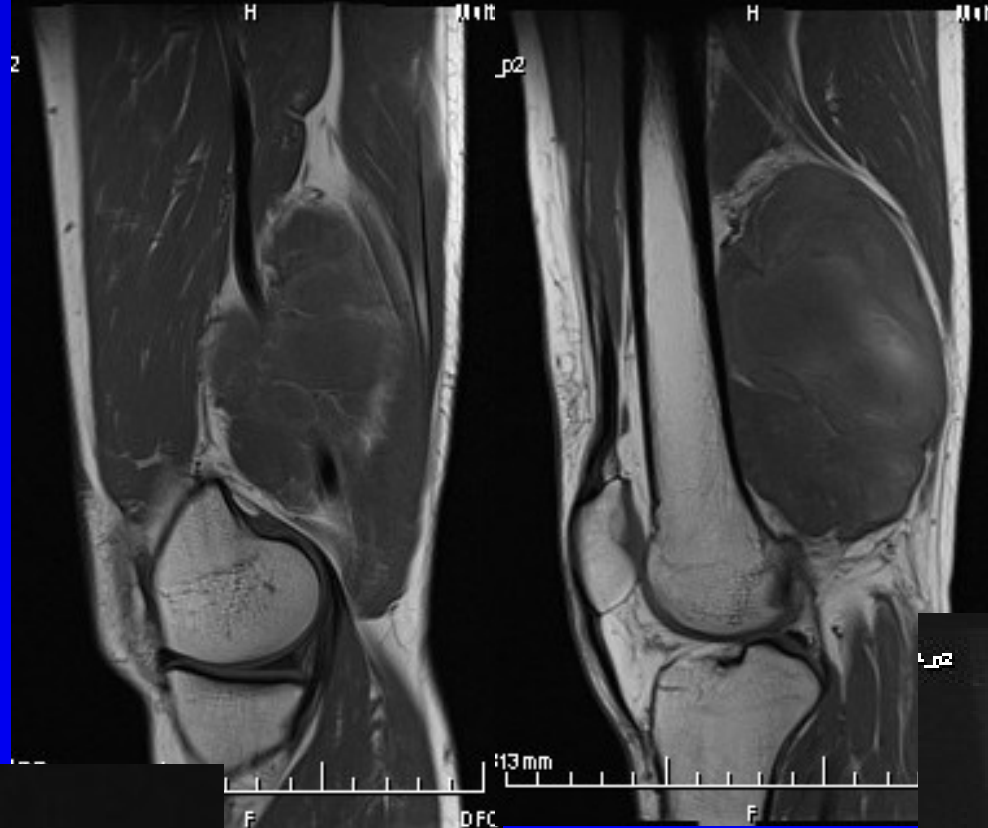
Spine



MRI

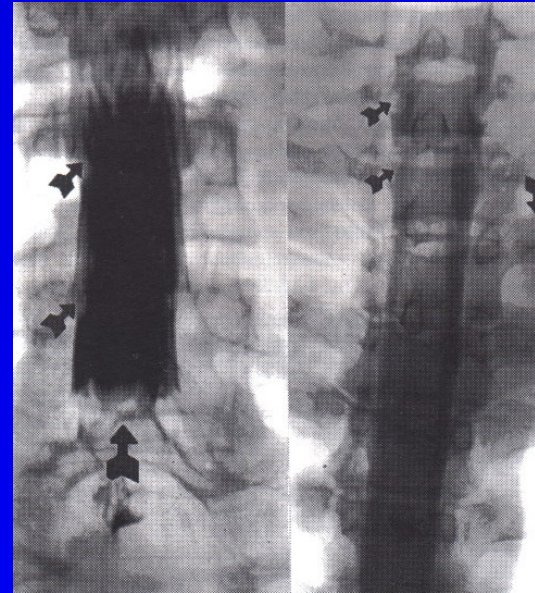




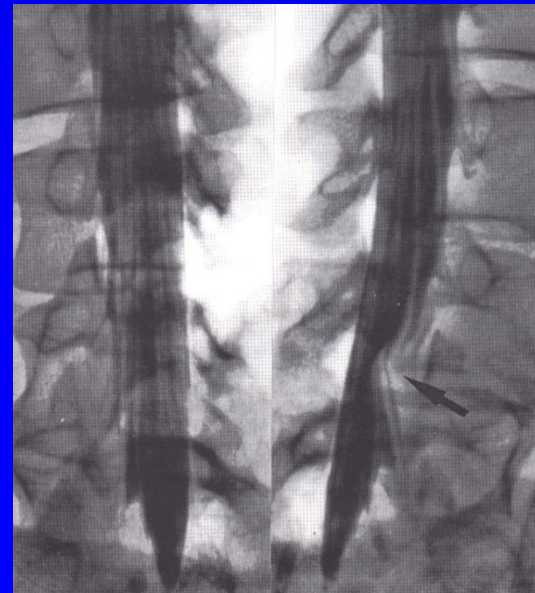


Perimyelography

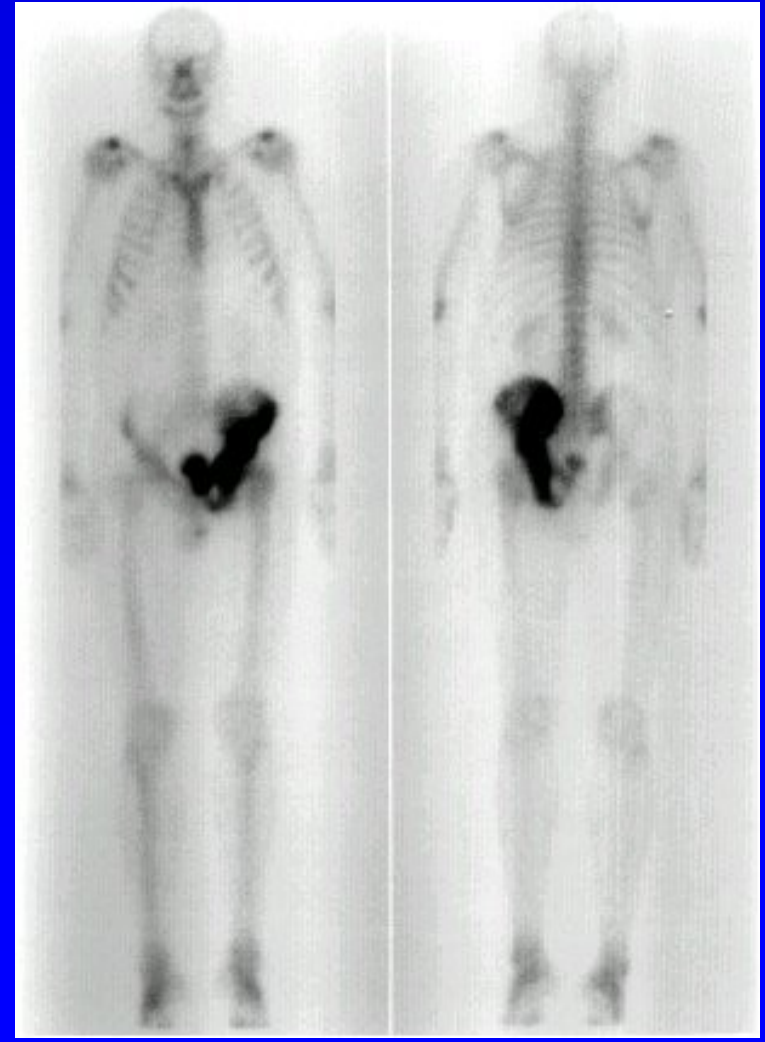
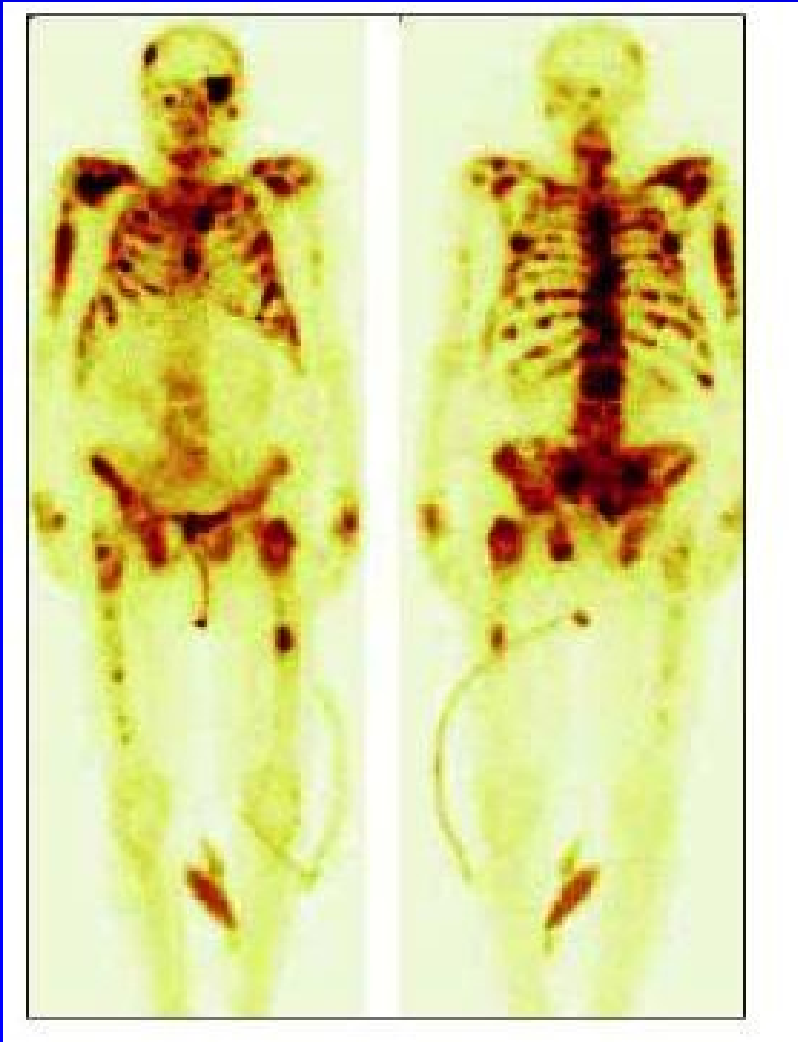
Myelography



Radiculography



Scintigraphy



Densitometry DEXA

Absorption of X-ray of two energies (70 and 140 kV)

BMD- bone mineral density in g/cm^2

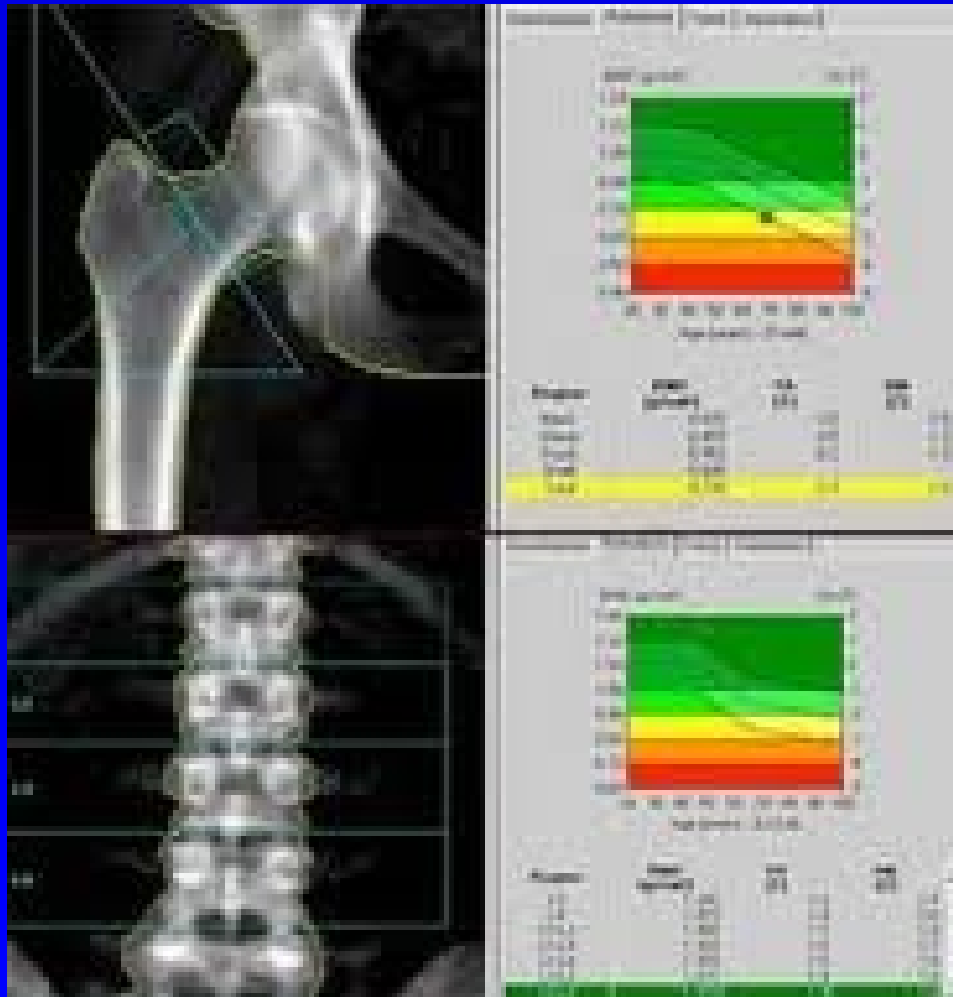T- score - difference from peak bone mass

Z- score - difference in the same age

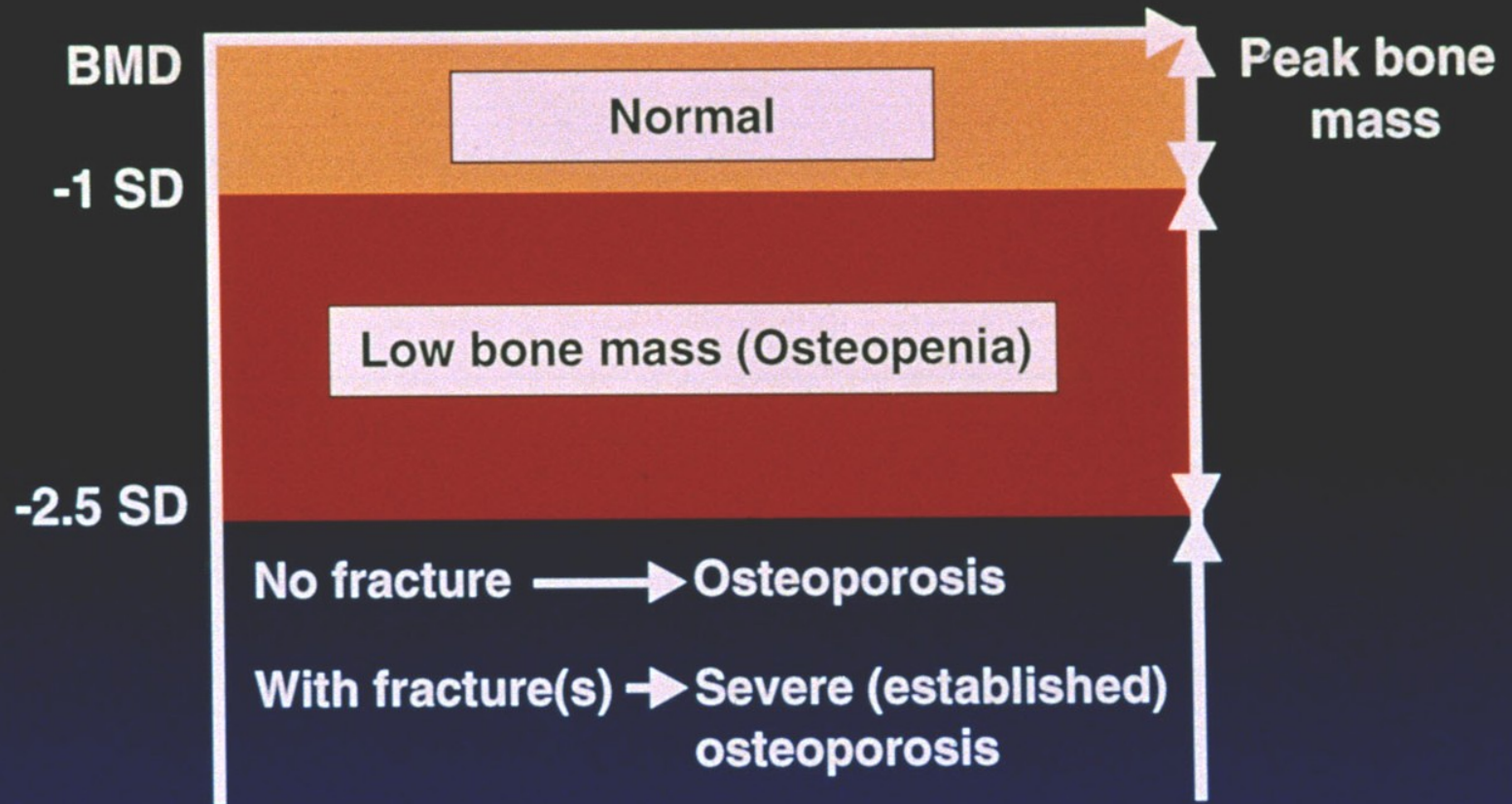
Change - difference from previous examination

1 SD = 10% of bone mass

DEXA



WHO definition of osteoporosis



Laboratory tests

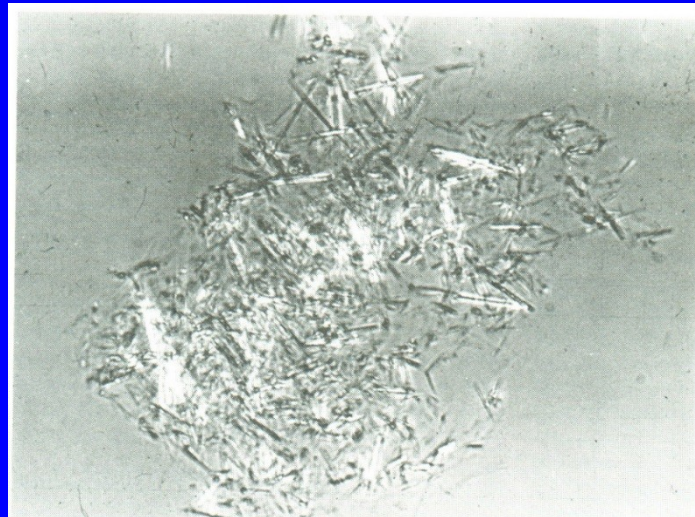

- Inflammation: ESR, leu, CRP, diferencial, ELFO
- Osteopathy: Ca, P, ALP, bone isoenzyme of ALP
osteocalcin, osteonectin, PTH, vitamin D
- Bone markers- PSA

Biochemistry

- Proteins
- Glucose
- Lactate
- Uric acid

Joint effusion

- Microscopic
- Biochemic
- Bacteriologic
- Immunologic
- Cytologic



Biopsy

Histological examination

Biopsy – CT, ultrasonography

