

Congenital disorders

Z. Rozkydal

P. Janíček

Congenital abnormalities

The child is born with them

1. Typical - genetic, chromosomes and genes abnormality, familiar occurrence
2. Atypical – not genetic
embryonal damage
during pregnancy

Gene mutation

Chromosomal disorders

Autosomal dominant transmission

Autosomal recessive transmission

X-linked disorders

Classification

1. Genetic disorders of cartilage and bone growth
(Achondroplasia, epiphyseal dysplasia..)

2. Collagen disorders

Osteogenesis imperfecta, Marfan syndrom
Neurofibromatosis ..

3. Enzyme defects

Mucopolysacharidosis, Gaucher disease..

4. Chromosome disorders

Down syndrom ..

Classification

1. Disturbance of a form (shape)
2. Disturbance of separation
3. Duplication
4. Gigantism
5. Hypoplasia
6. Congenital constrictions
7. General deformities

1. Disturbance of a form

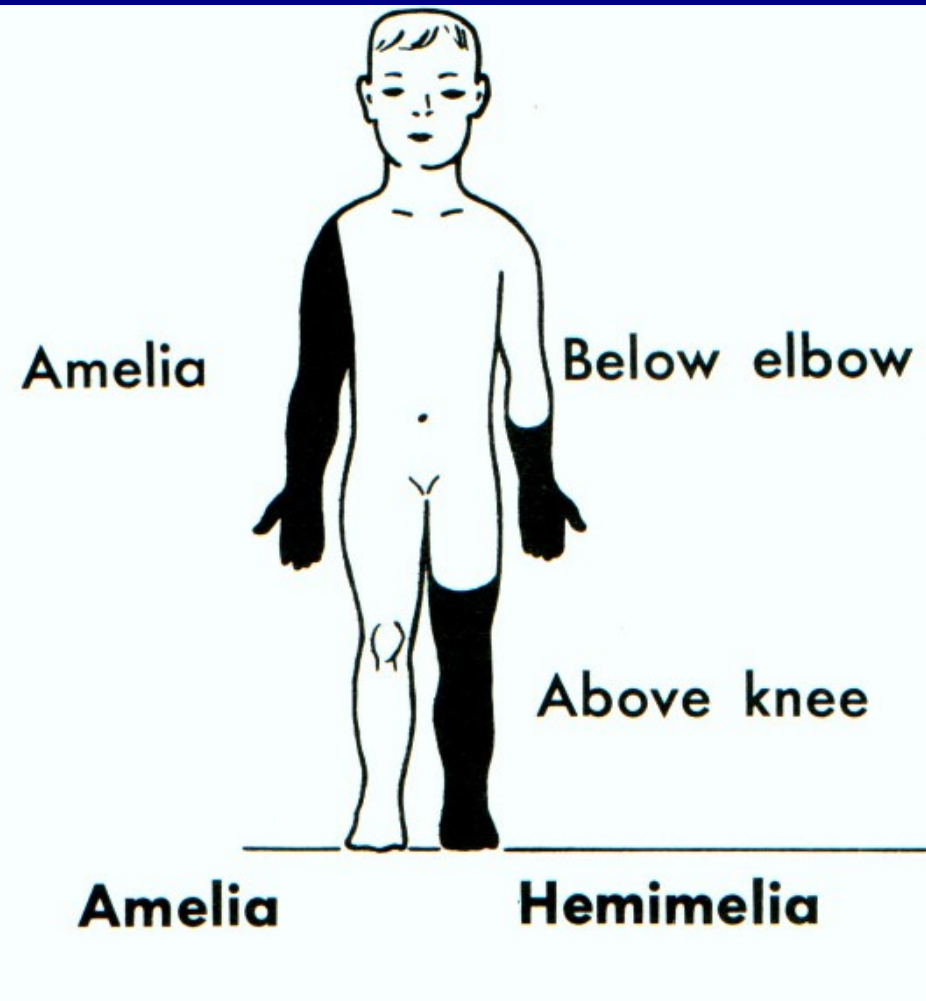
A. Transversal defects

- terminal
- intercalary

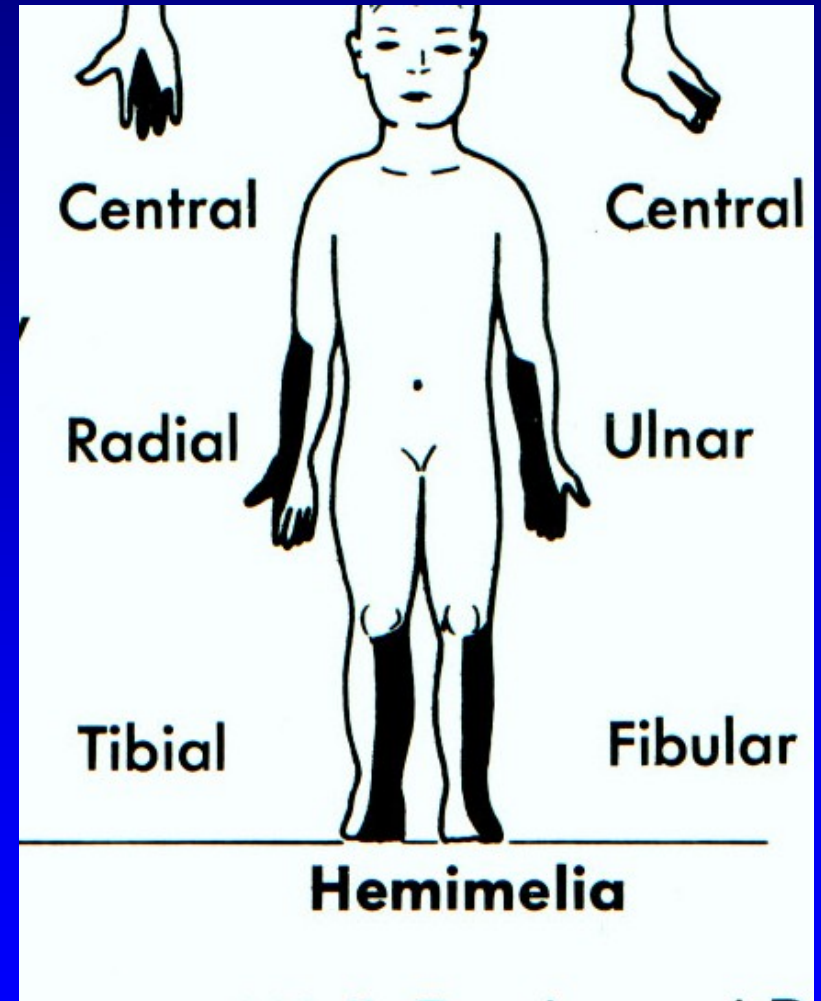
B. Longitudinal defects

- terminal
- intercalary

Terminal defects

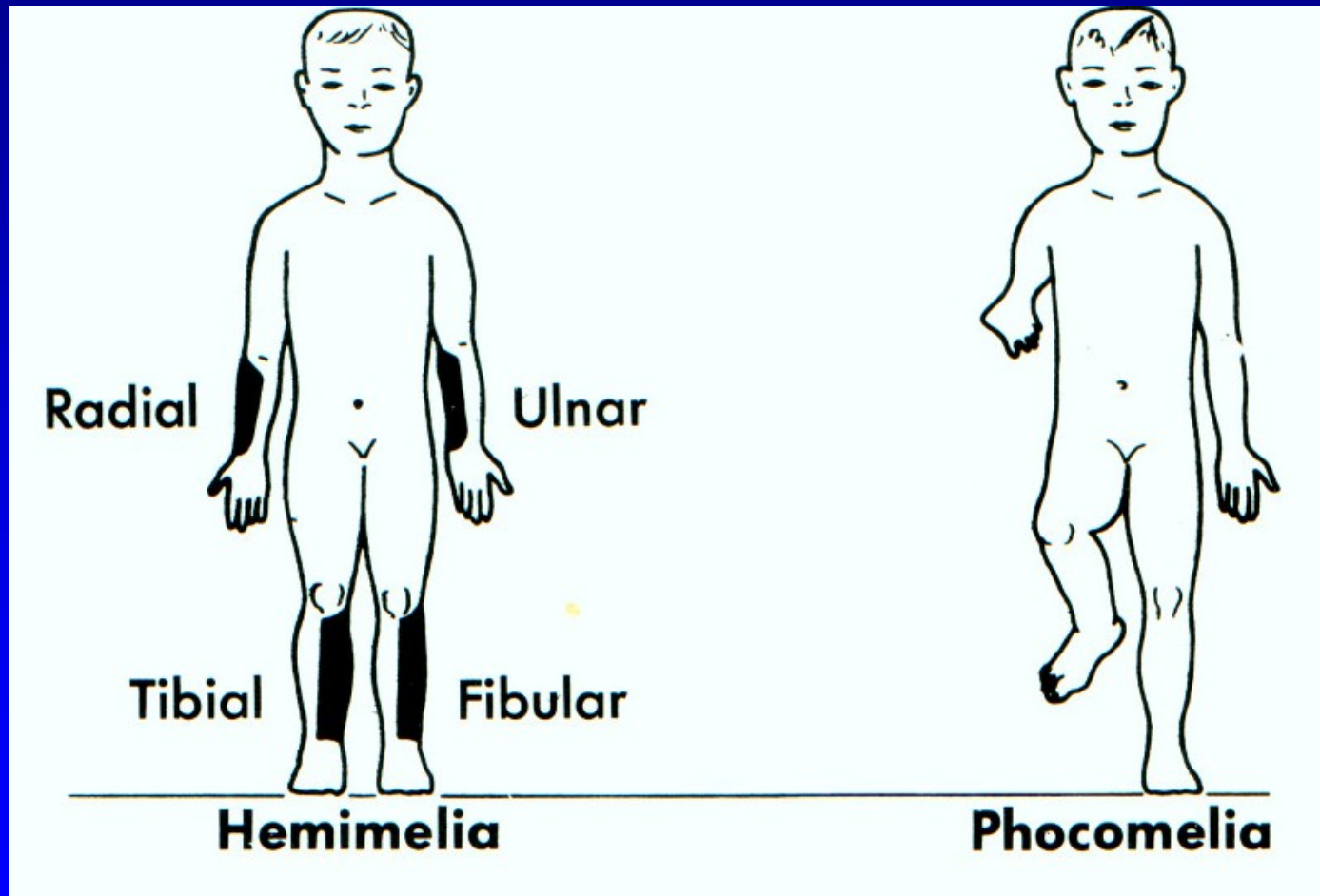


Obr. 1

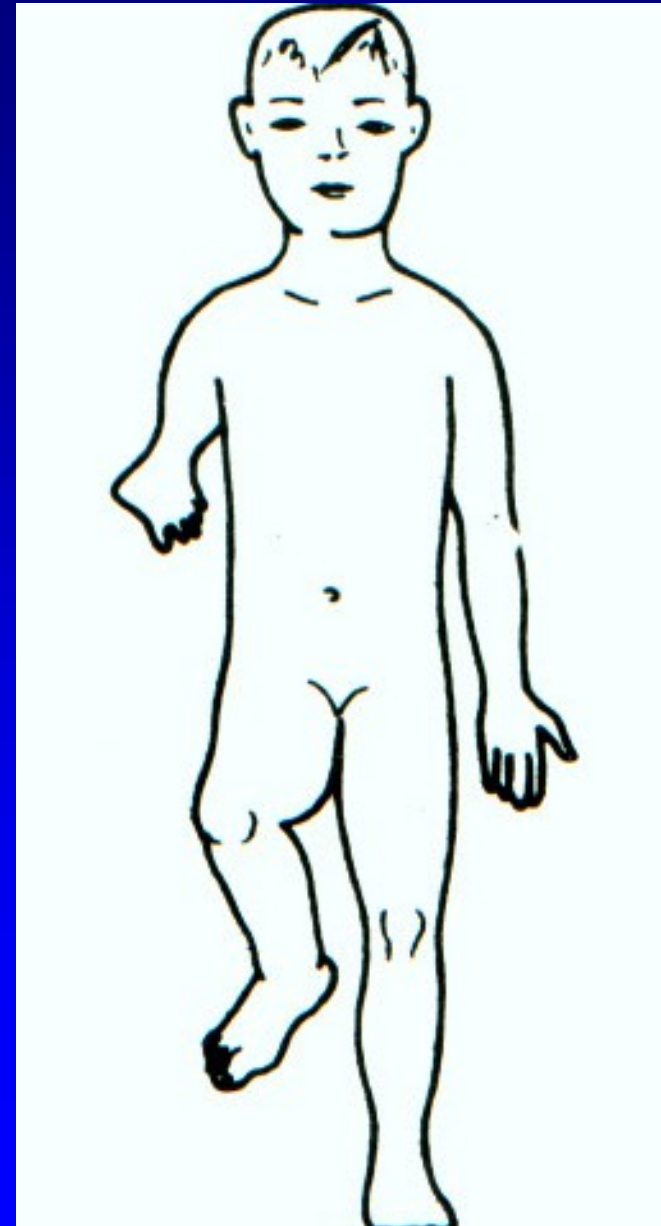


Obr. 2

Intercalary defects

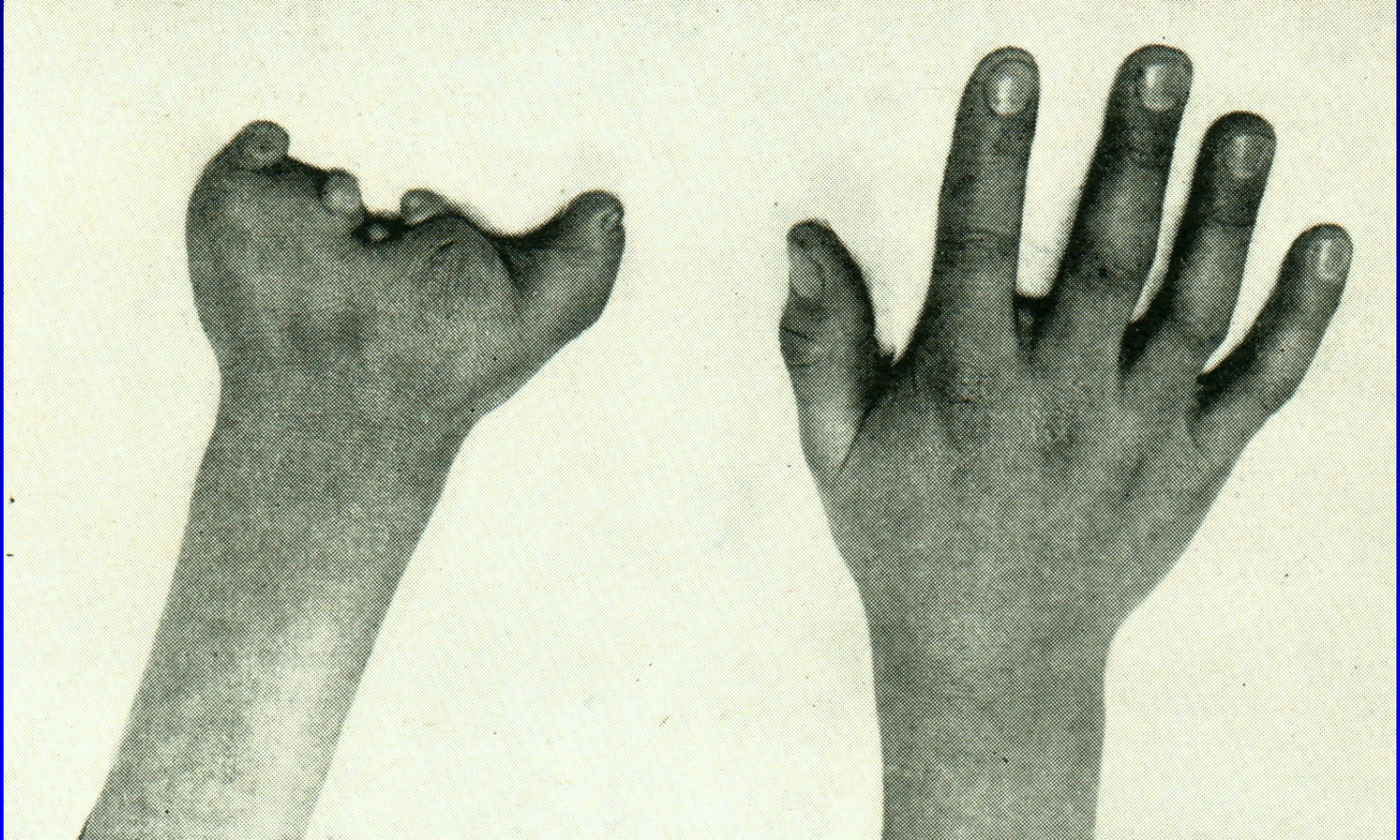


Focomelia



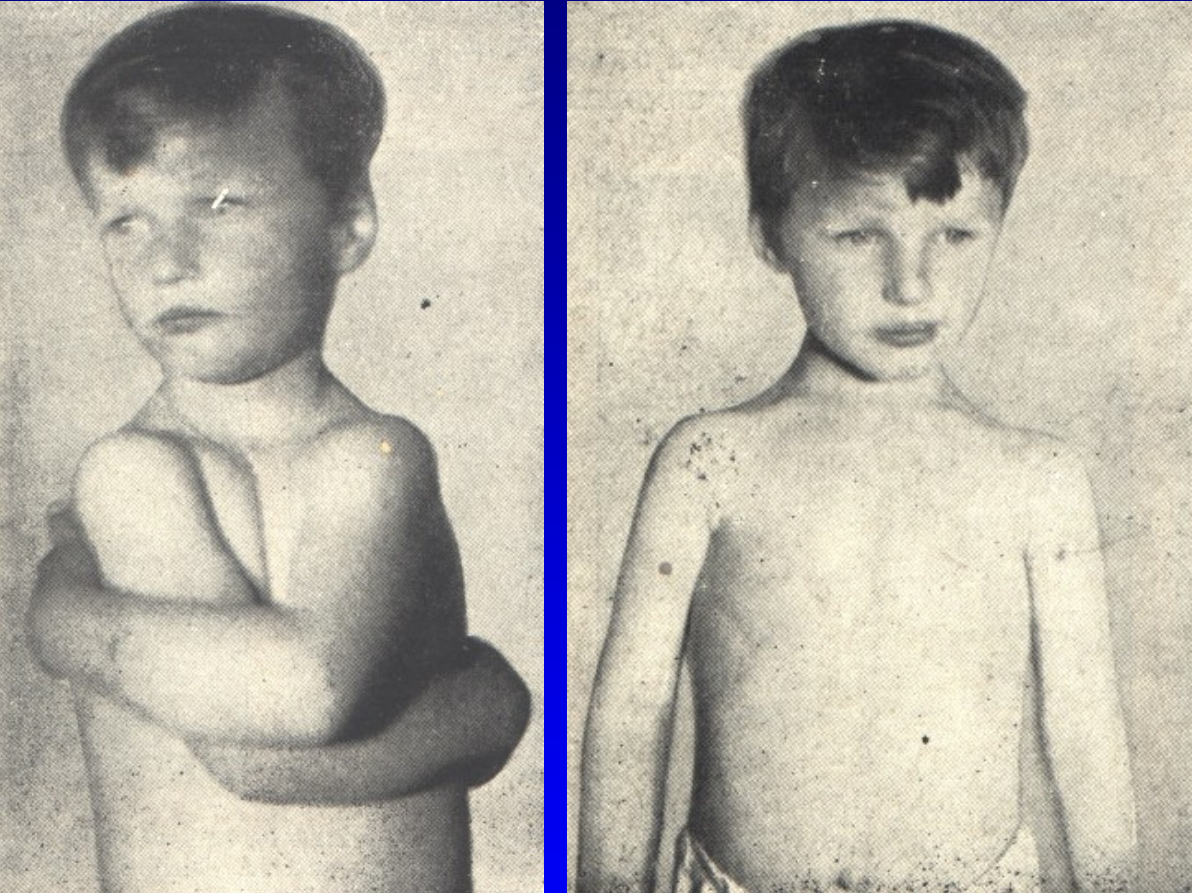
Obr. 4

Congenital aplasia of fingers



Obr. 5

Dysostosis cleidocranialis

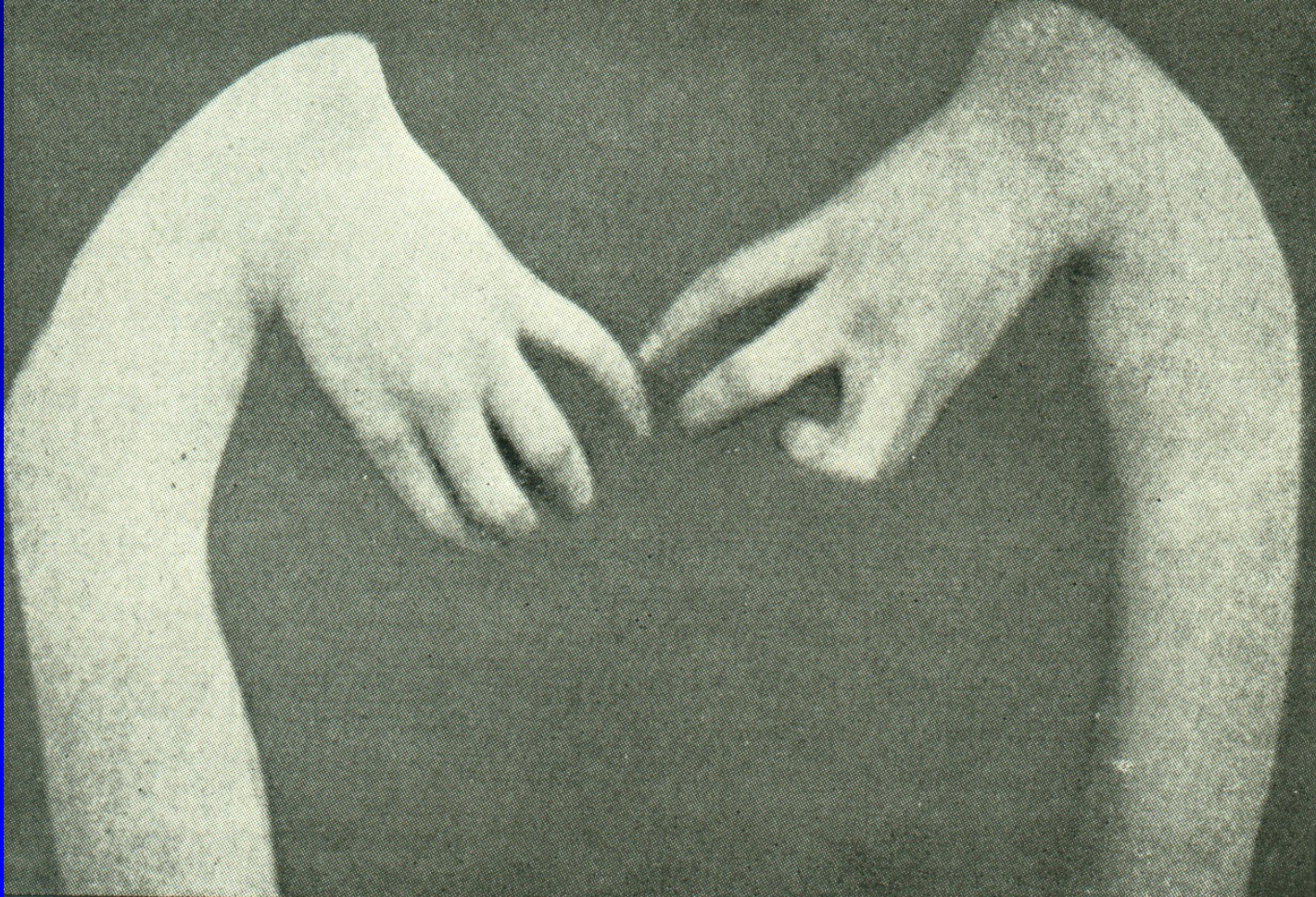

Absence of clavicle

Obr. 6

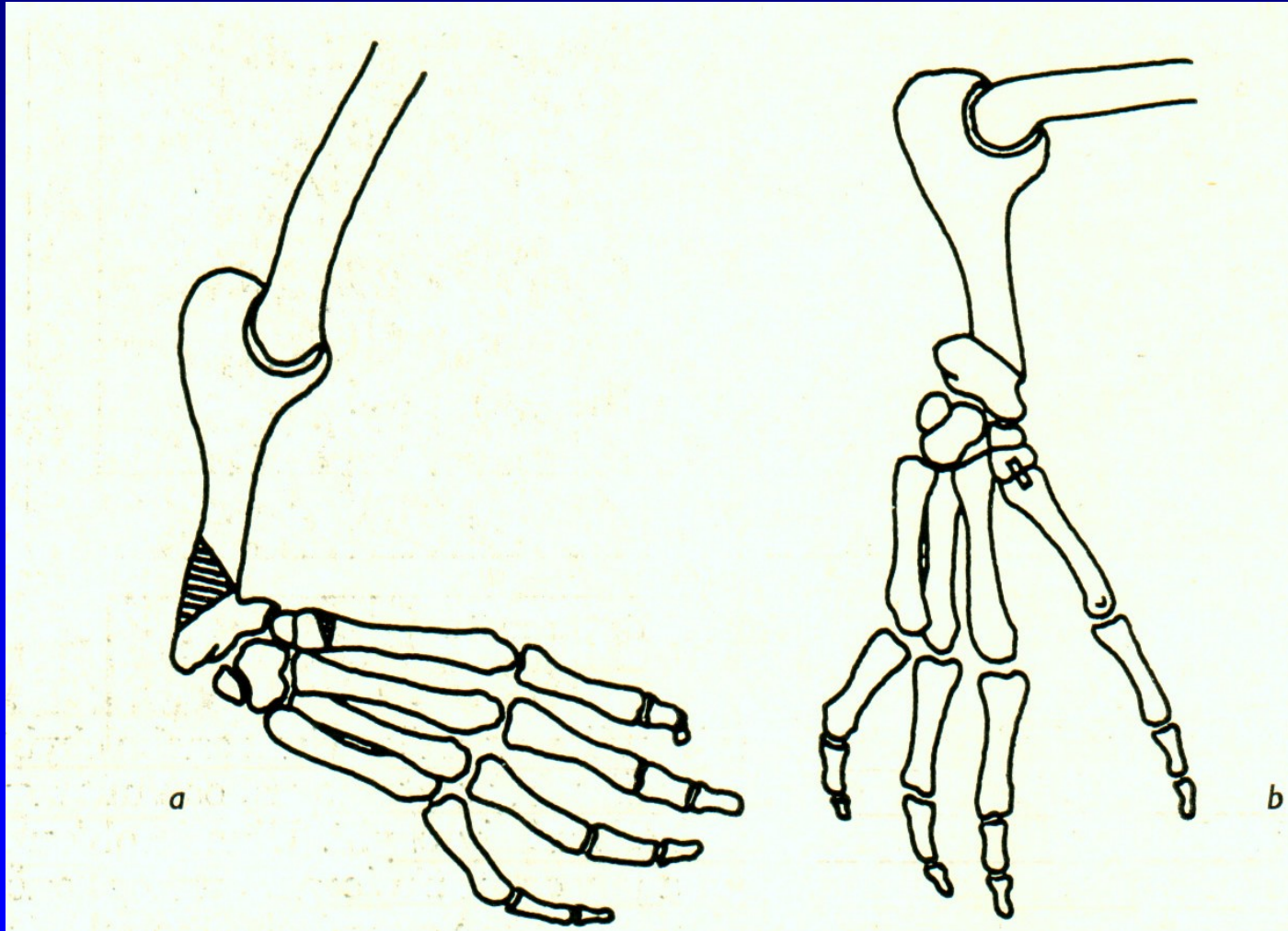
Congenital aplasia of radius

- manus vara



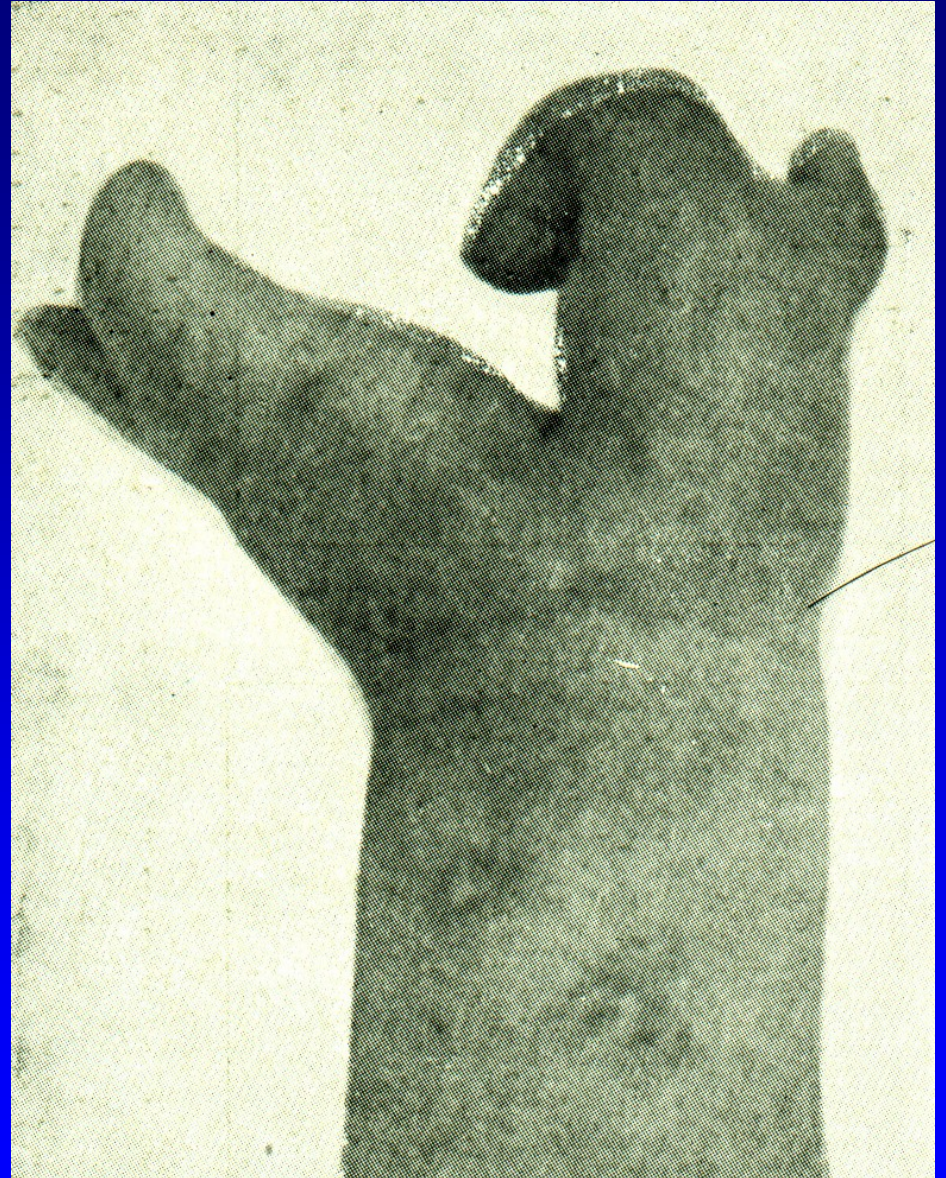Obr. 7

Correction surgery for manus vara




Obr. 8

Cleft hand

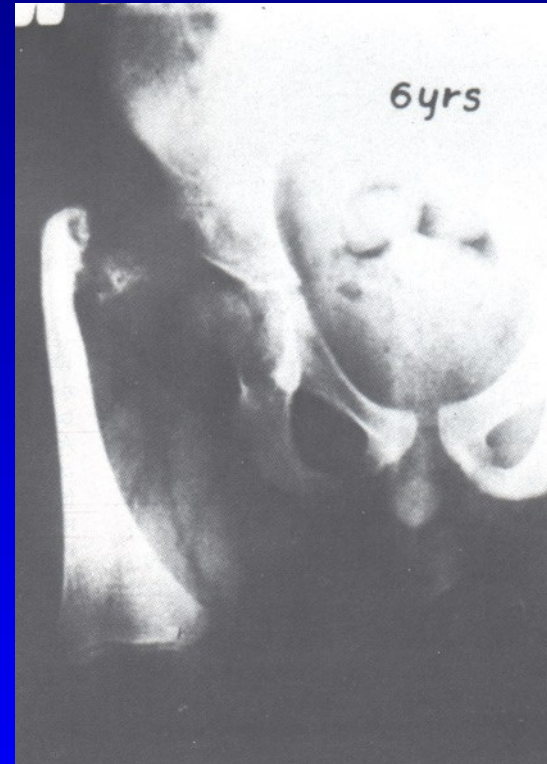


Obr. 9

Aplasia of the femur

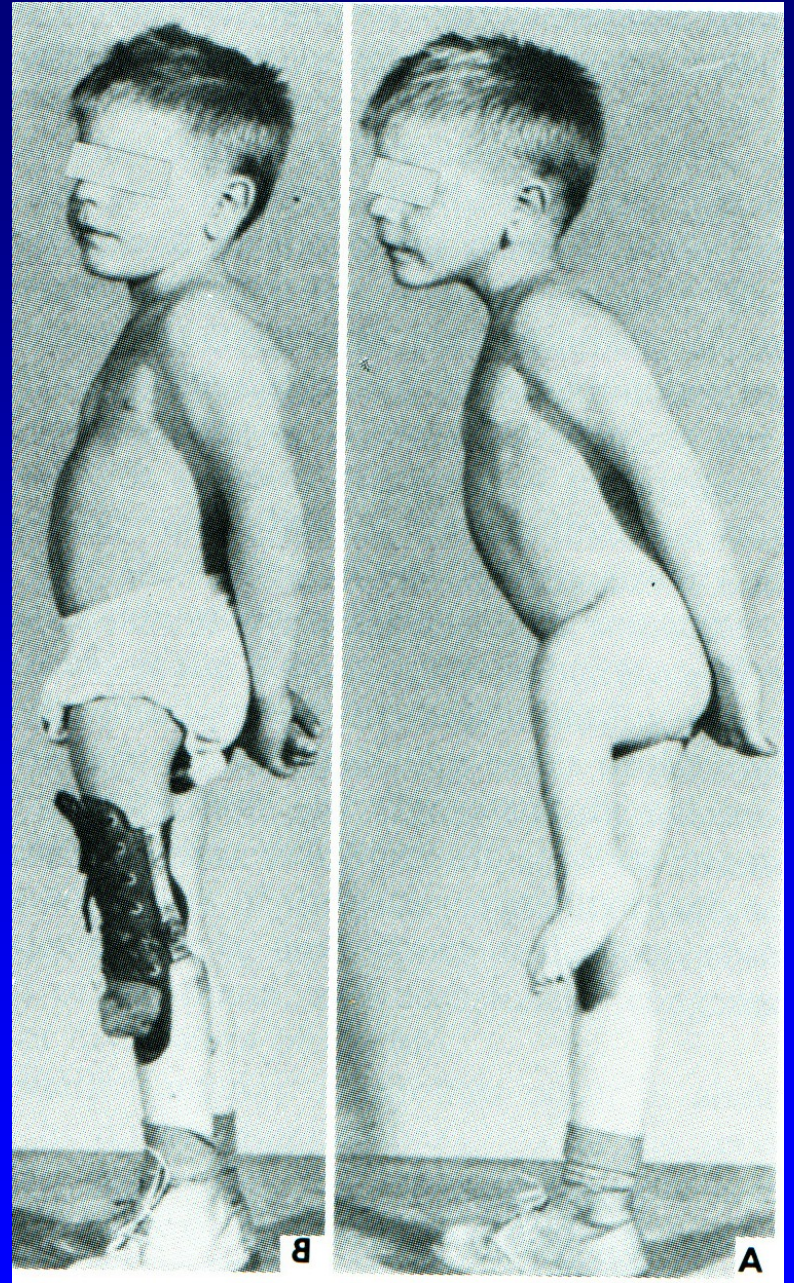


Obr. 10



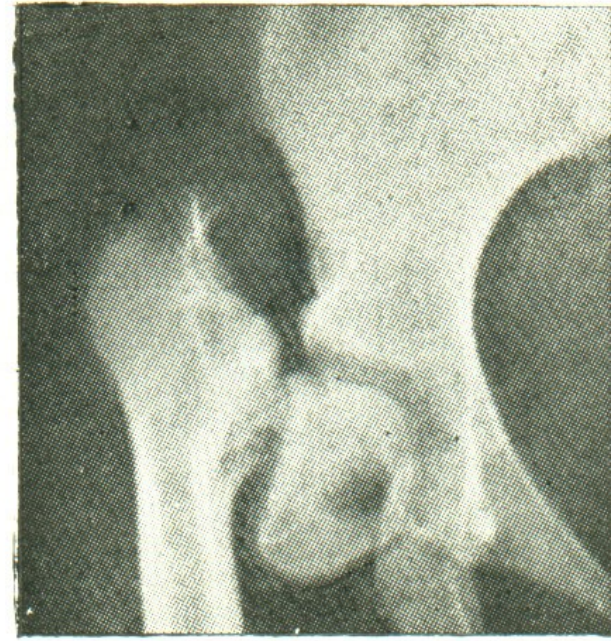
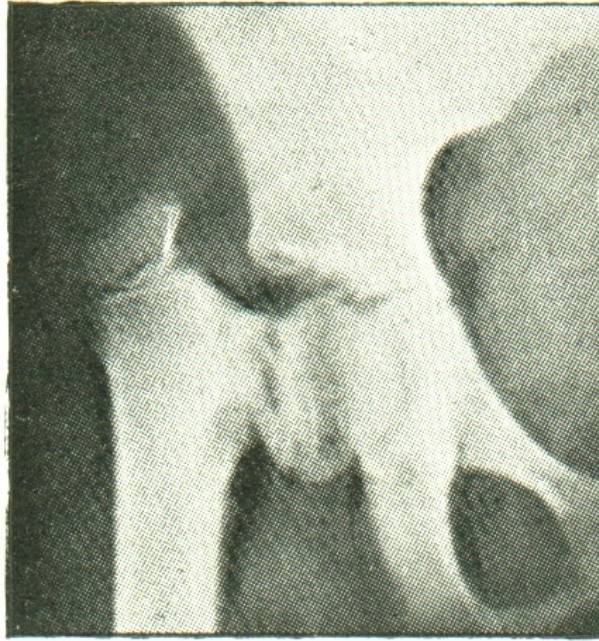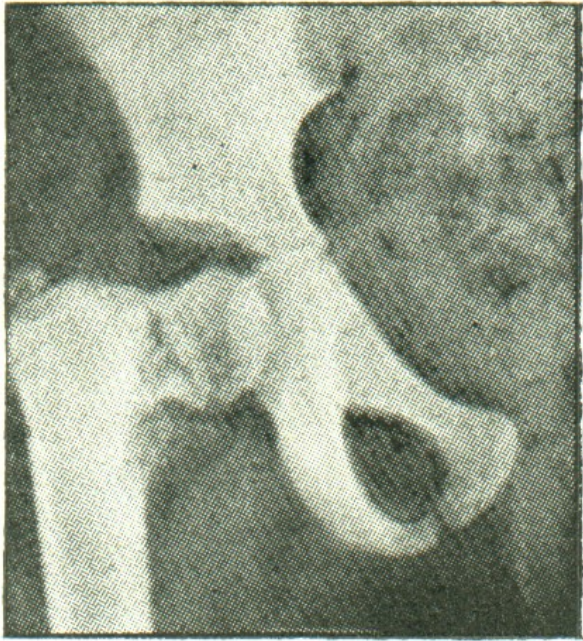
Obr. 11

Congenital aplasia of the femur



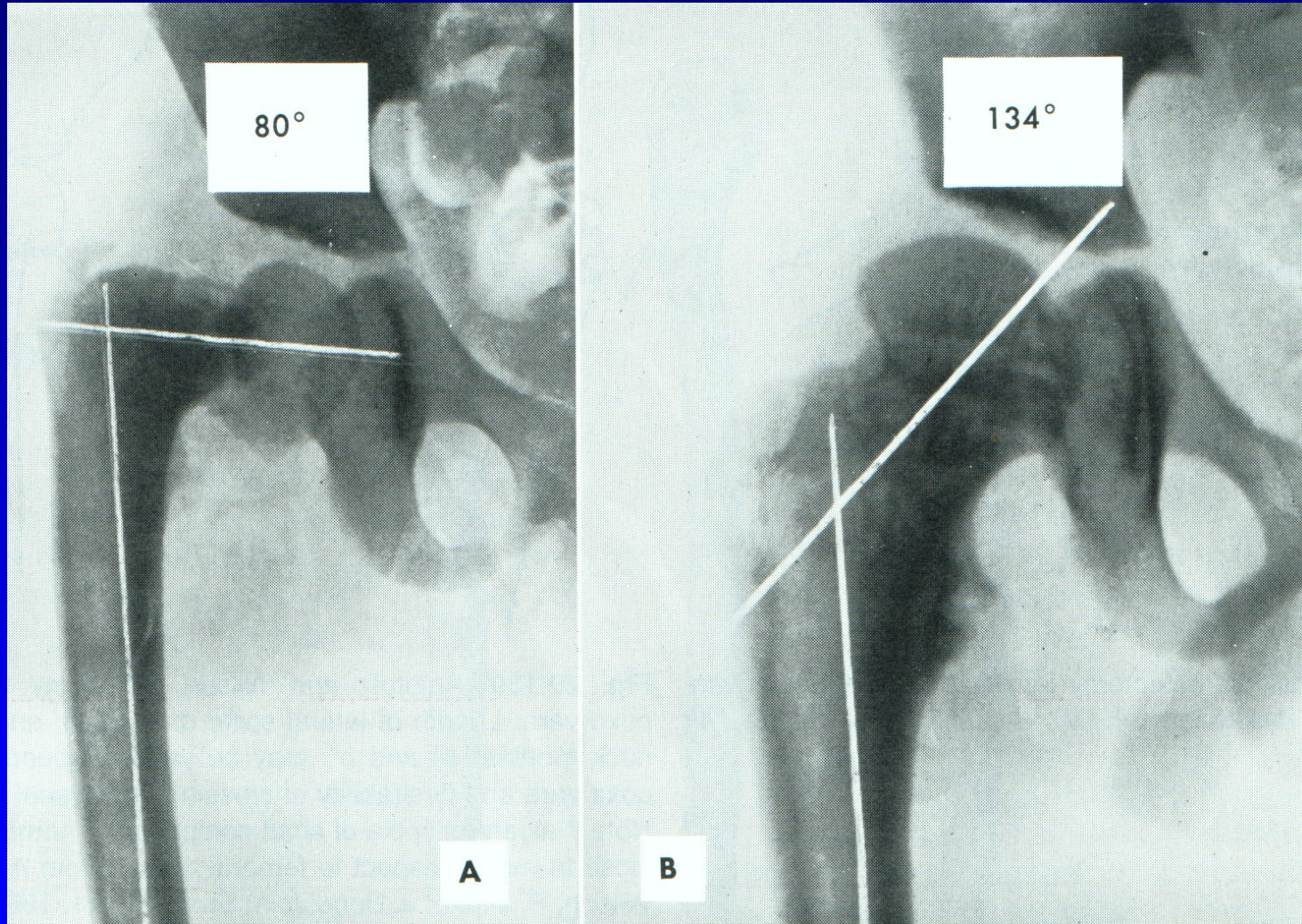
Obr. 12

Coxa vara congenita



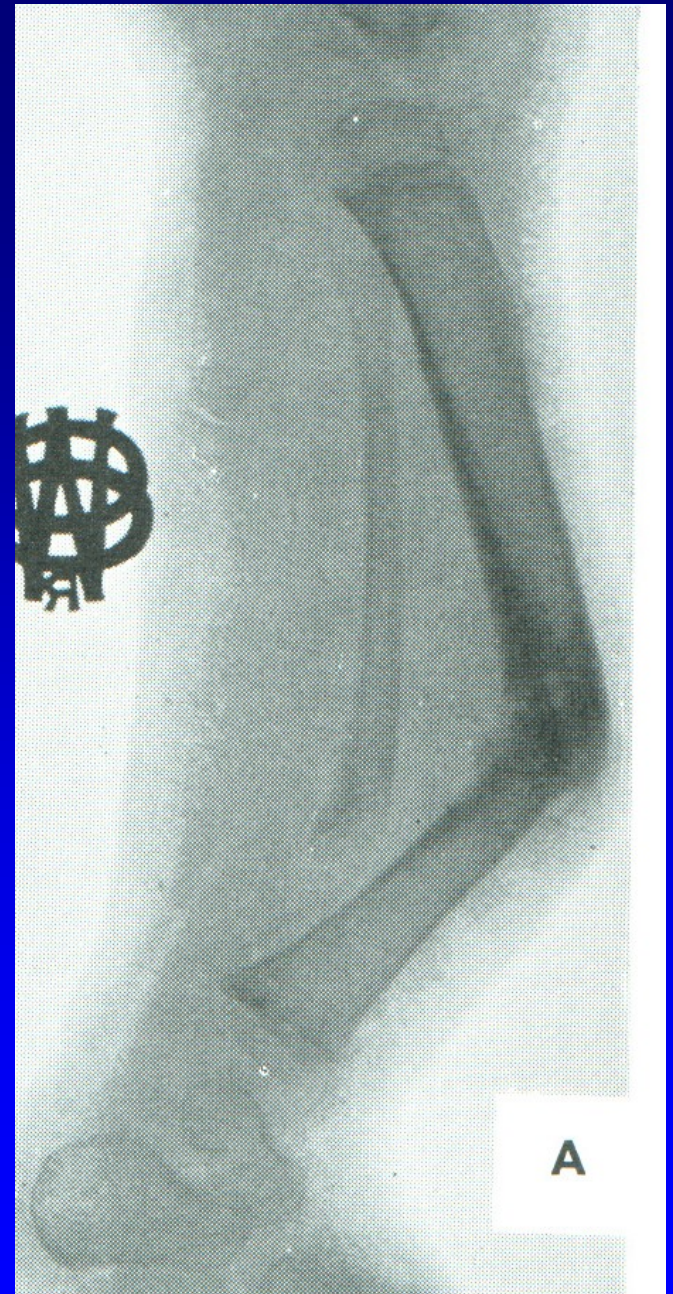
Obr. 13

Coxa vara congenita



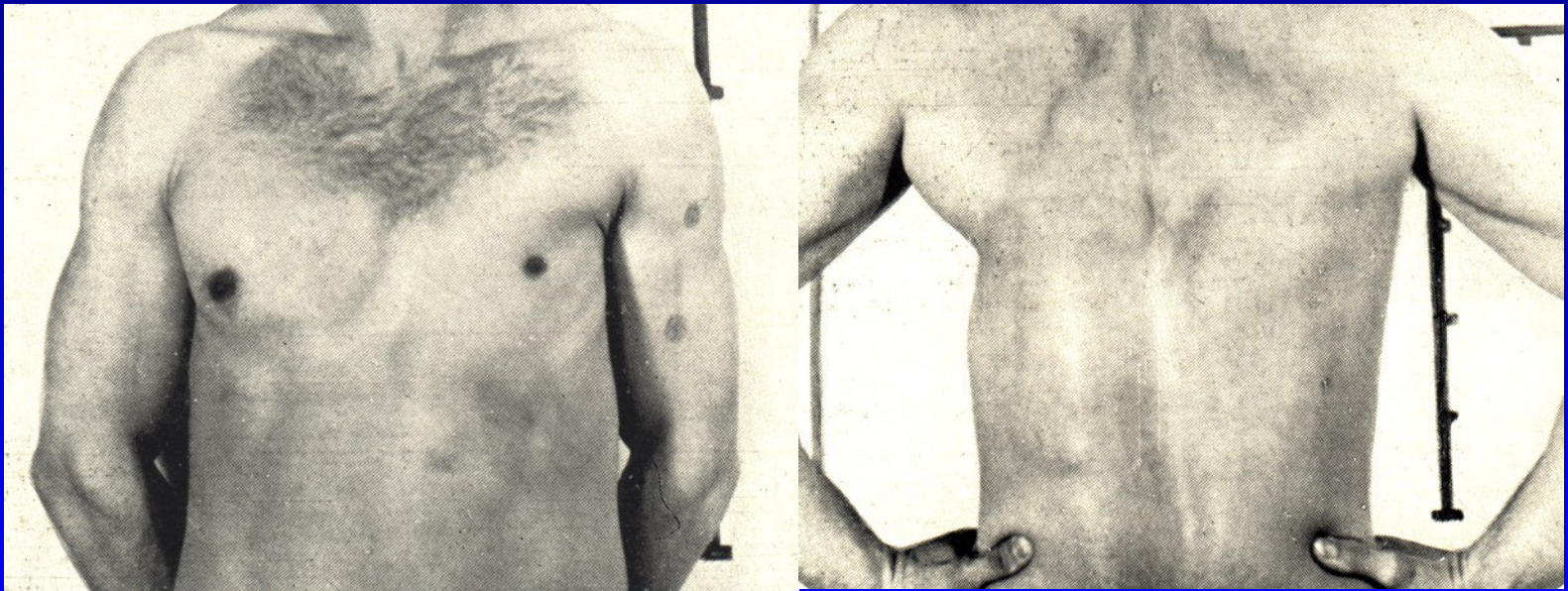
Obr. 14

Congenital nonunion of the tibia



Obr. 15

Aplasia of pectoral muscles



Obr. 16

2. Disorders of differentiation

Syndactylyia

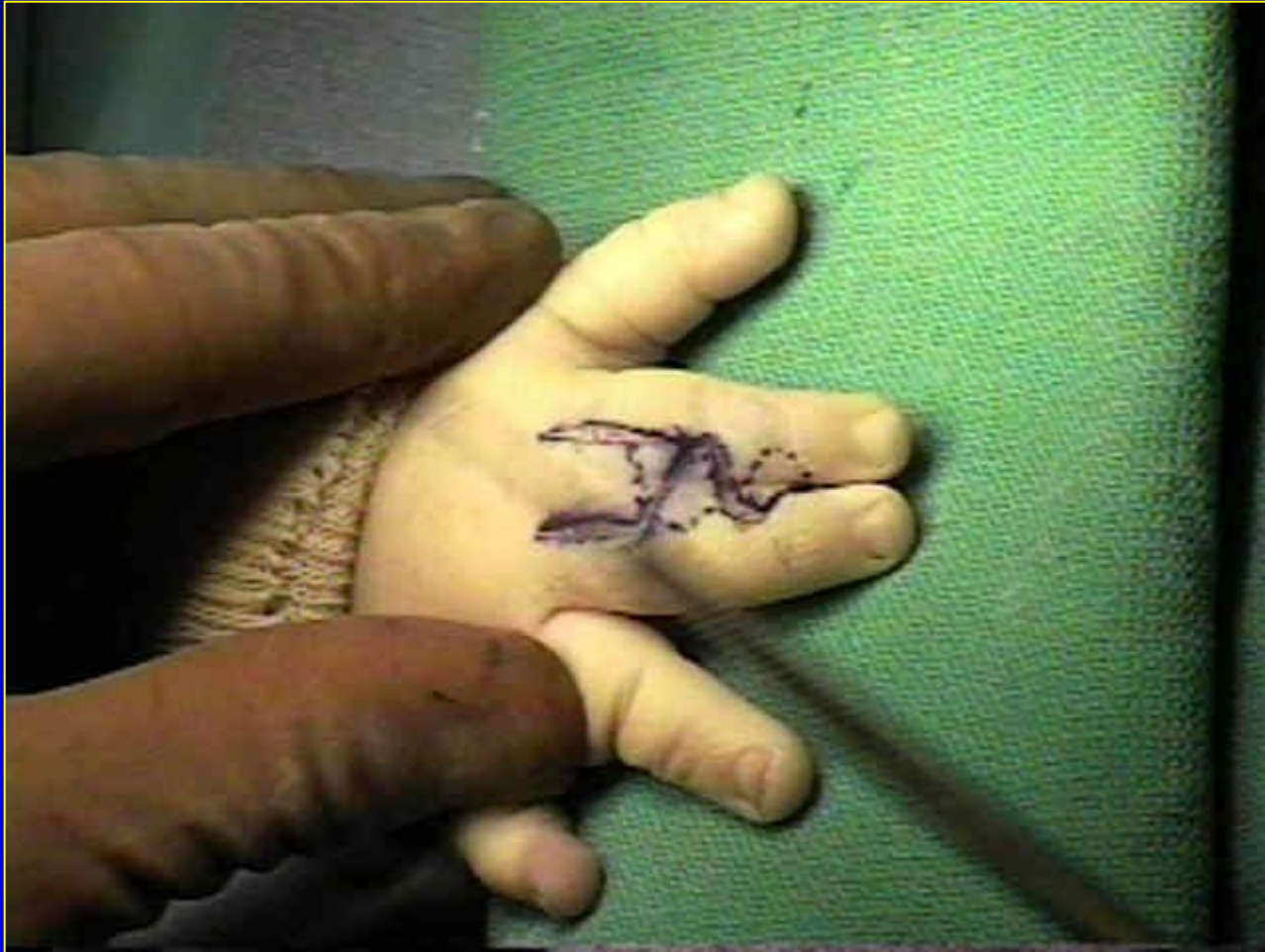Radioulnar synostosis

synostosis of carpal bones

Synostosis of vertebrae

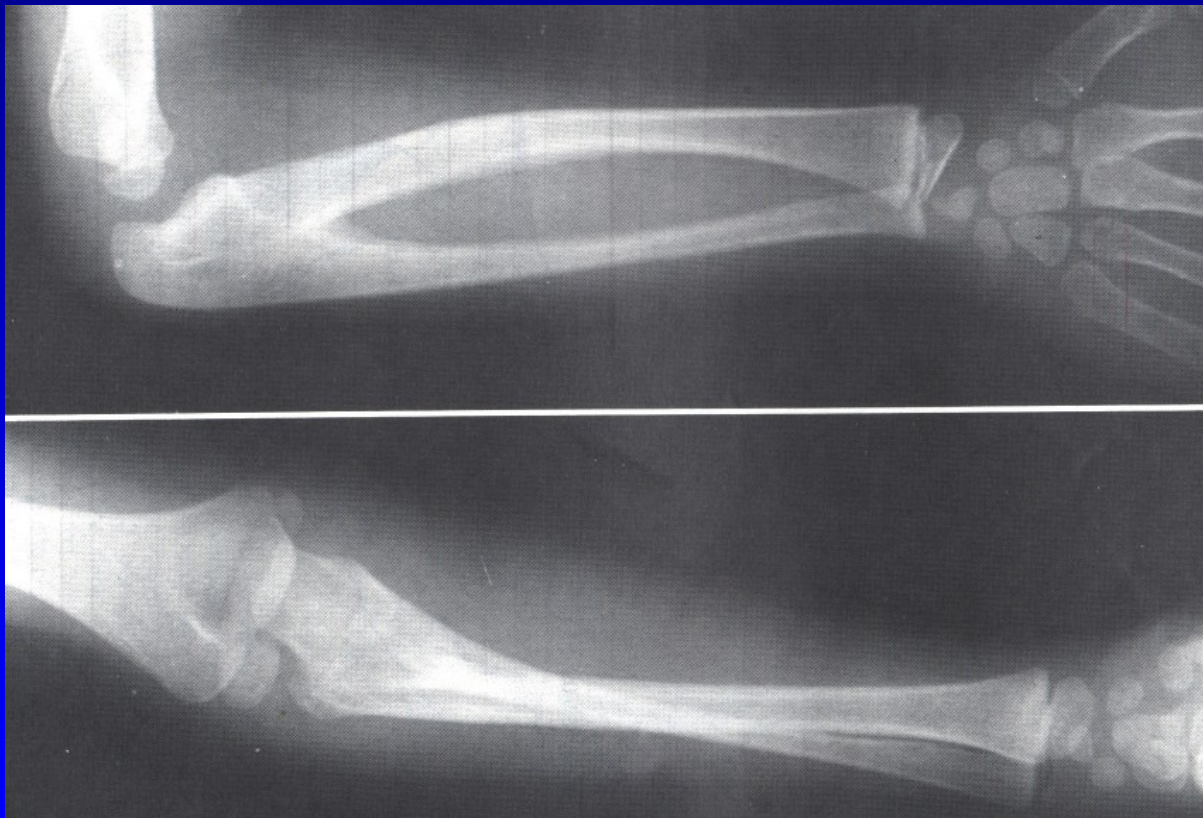
Tarsal coalition

Syndaktylia



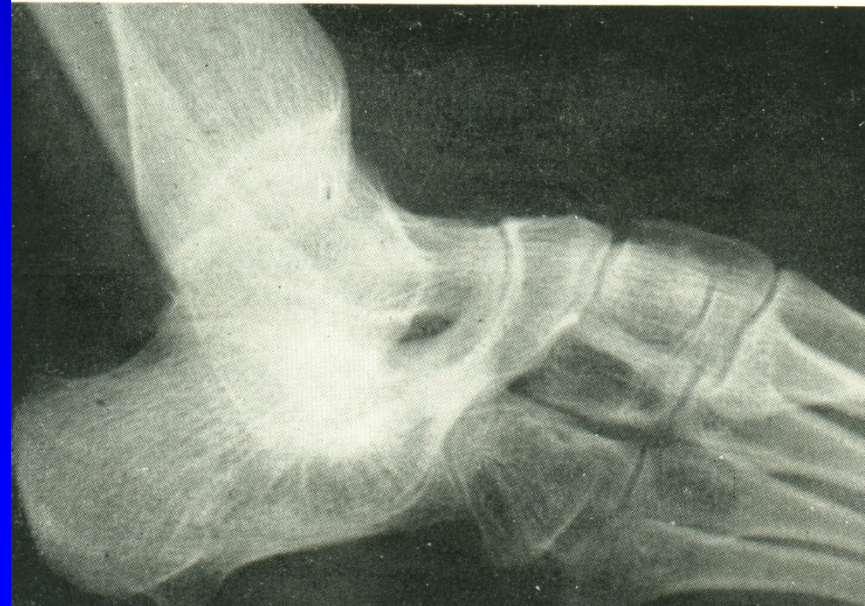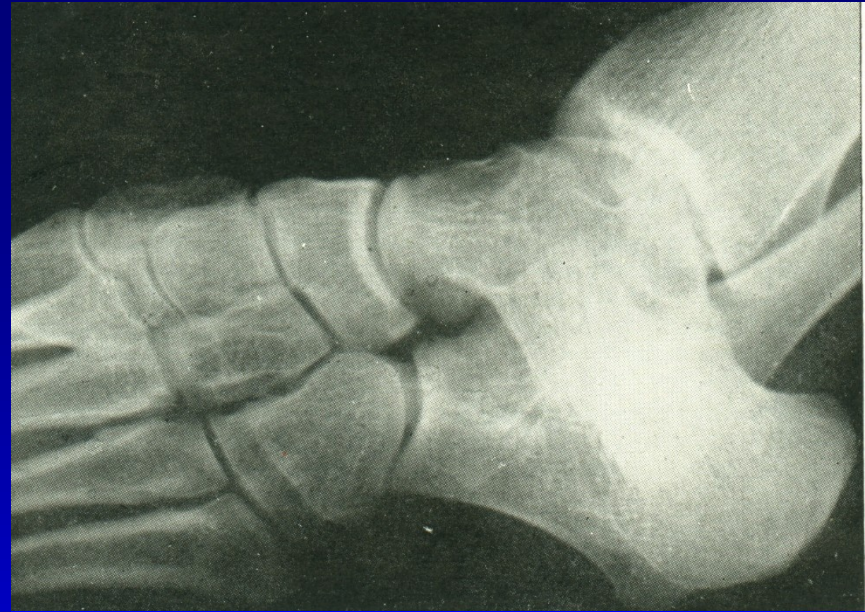Obr. 17

Radioulnar synostosis



Obr. 18


Tarsal coalition



Obr. 19

Sprengel's deformity

- high scapula



Small scapula

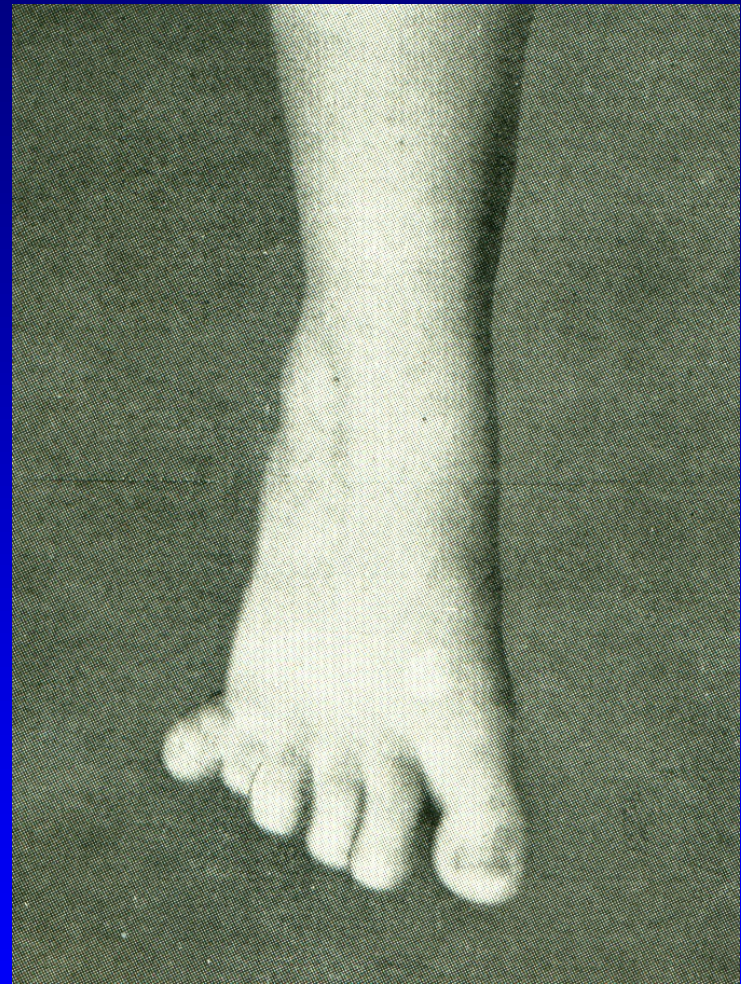Os omovertebrale

Fixed rotation of scapula

Limited movements

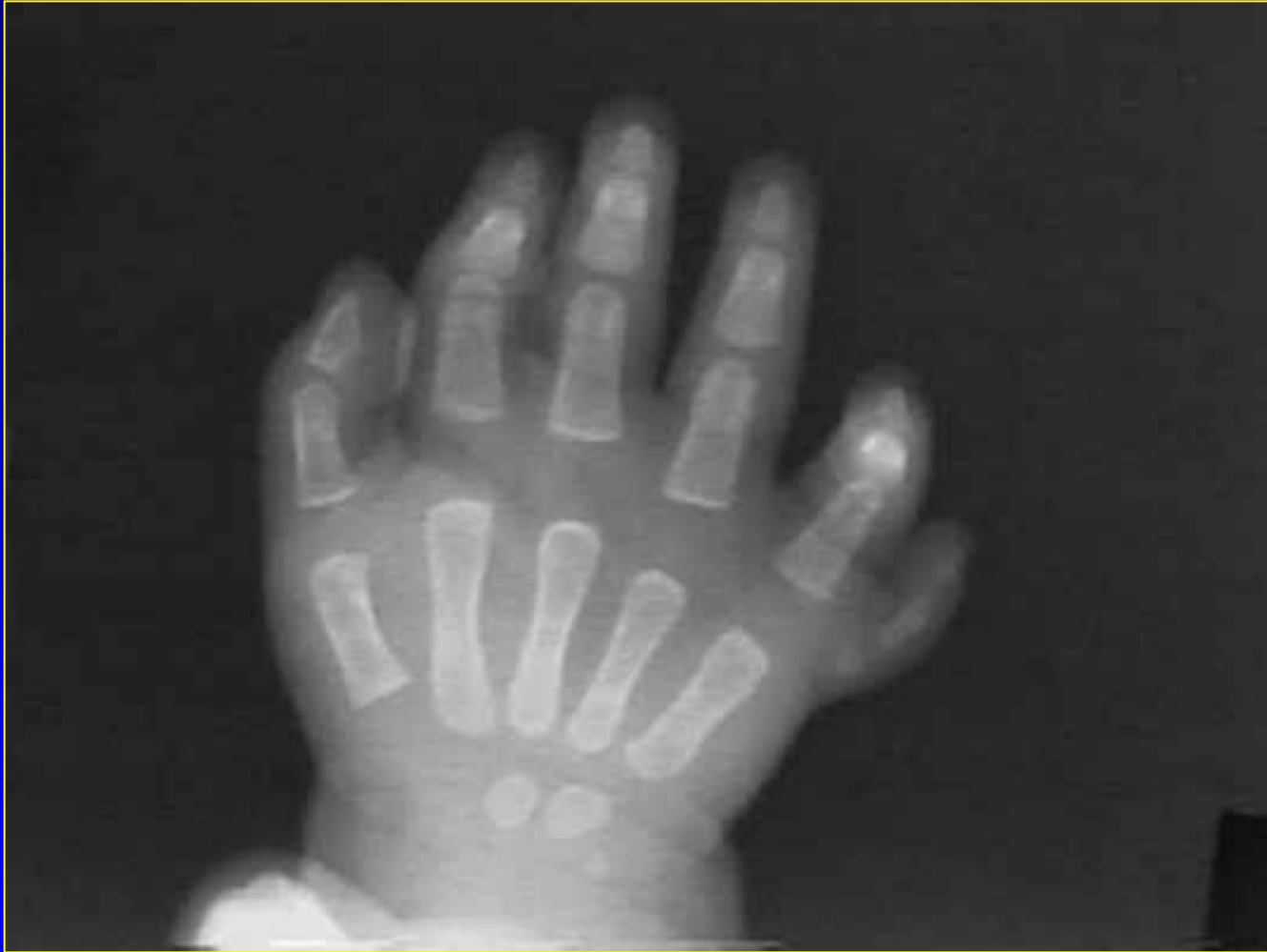Obr. 20

3. Polydactylyia



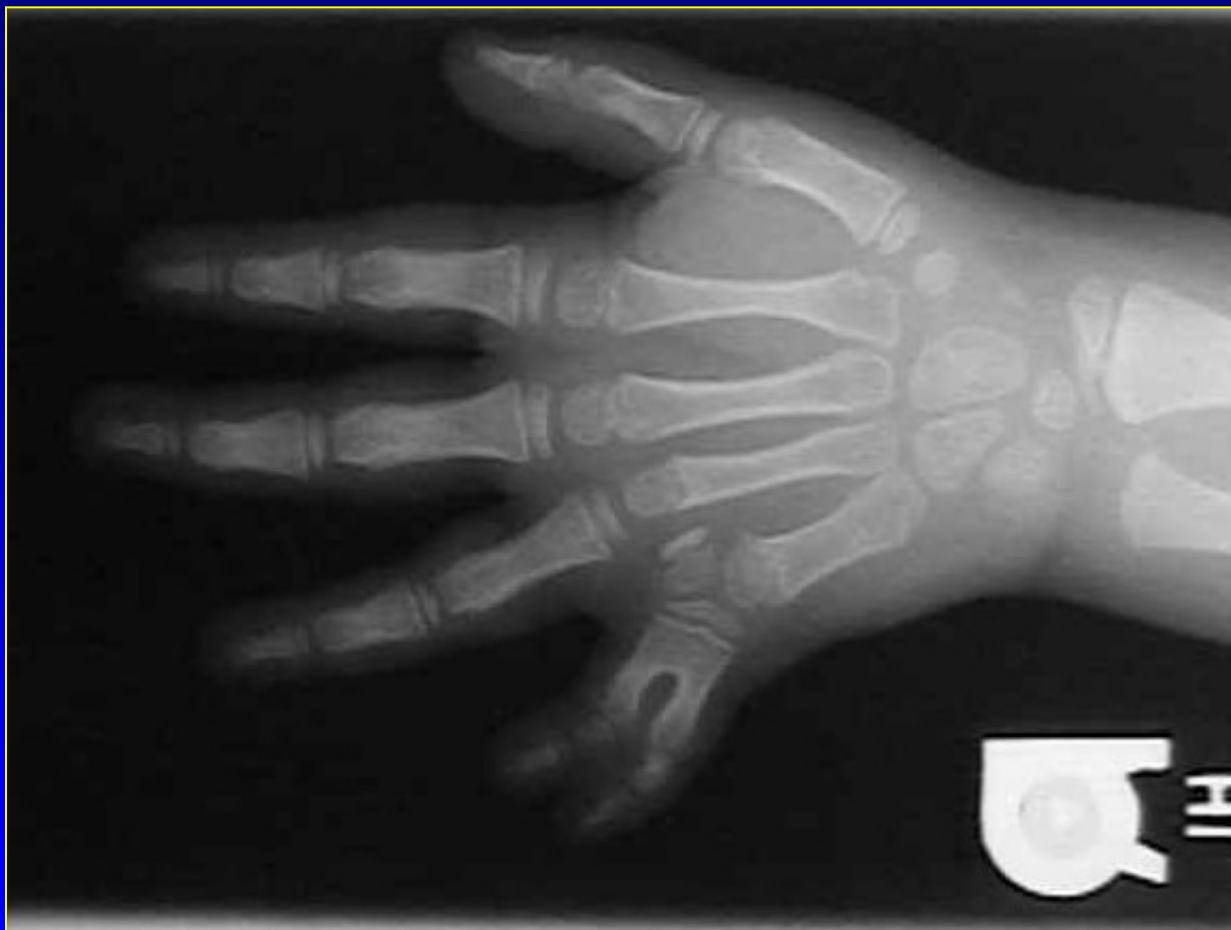Obr. 21

Polydaktylia



Obr. 22

Polydaktylia



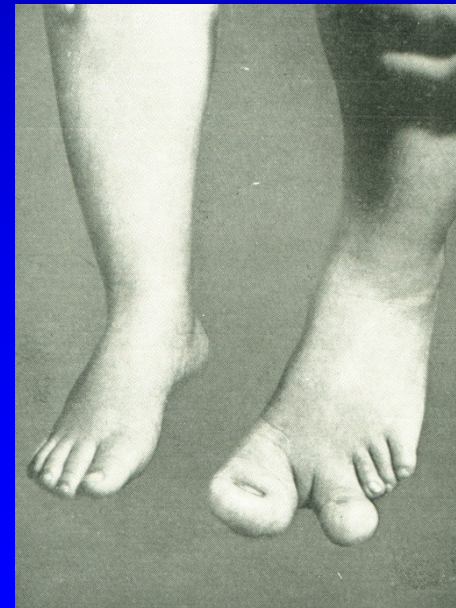
Obr. 23

4. Gigantisms

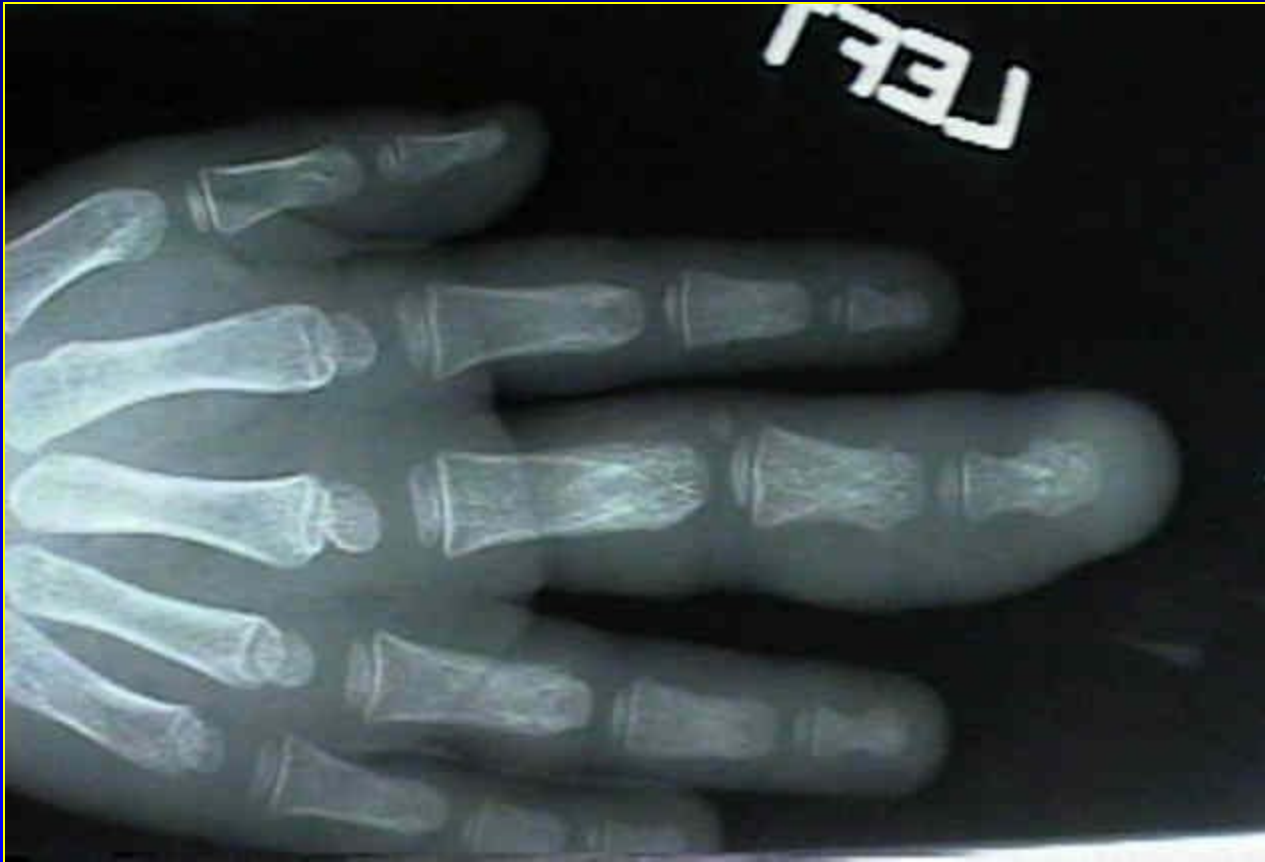Growth hormon disorders

A- high stature (over 2 m)
Gigantismus

B- hypertrophy of a part of body
macroductyilia



Makrodactylyia



Obr. 25

5. Hypoplasia

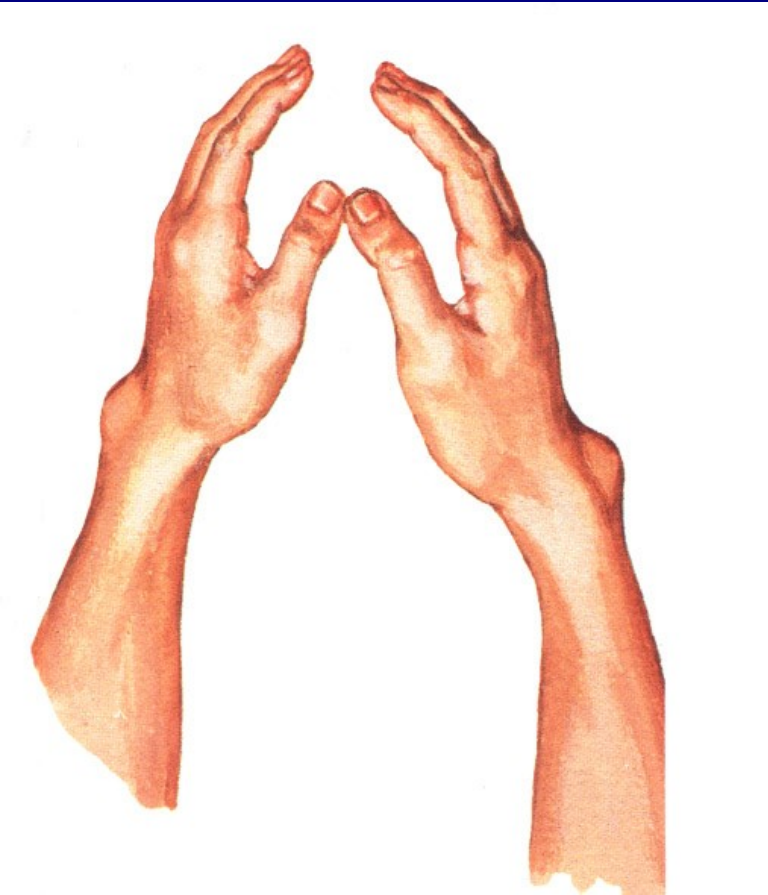
Brachydactyly

Brachyphalangia

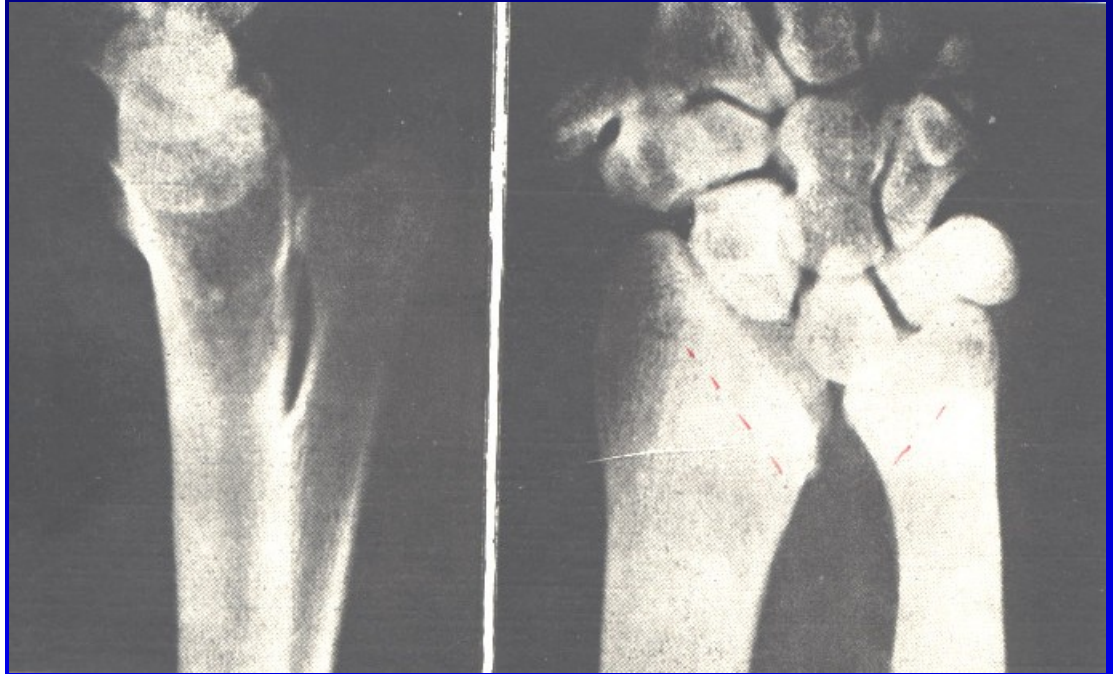
Madelung deformity

Talipes equinovarus

Madelung deformity



Obr. 26



Obr. 27

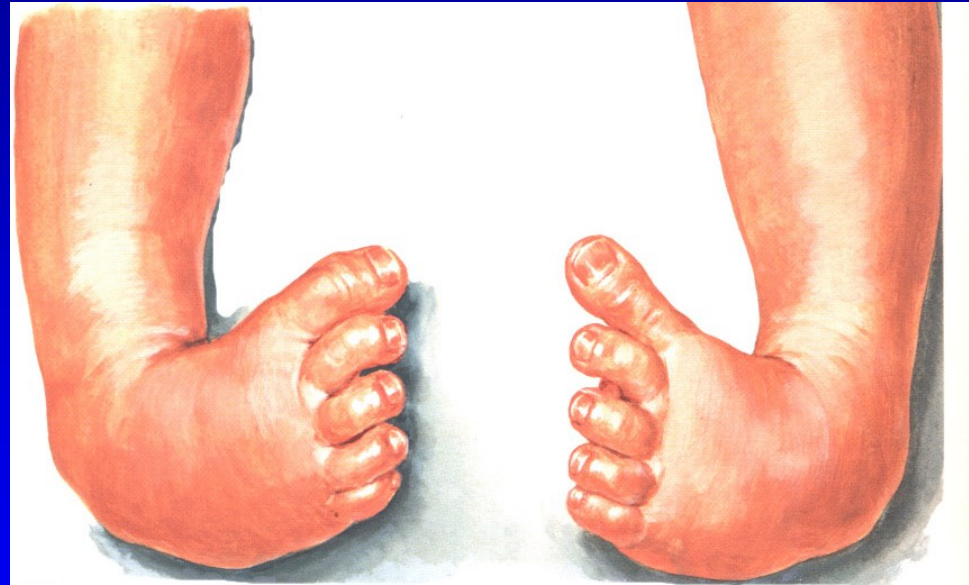Talipes equinovarus

Frequent disorder

Occurrence 1/1000

Boys more often affected

1. Equinus of the ankle
2. Varus of the heel
3. Adduction of forefoot
4. Supination of the foot
5. Excavation of dorsum of the foot



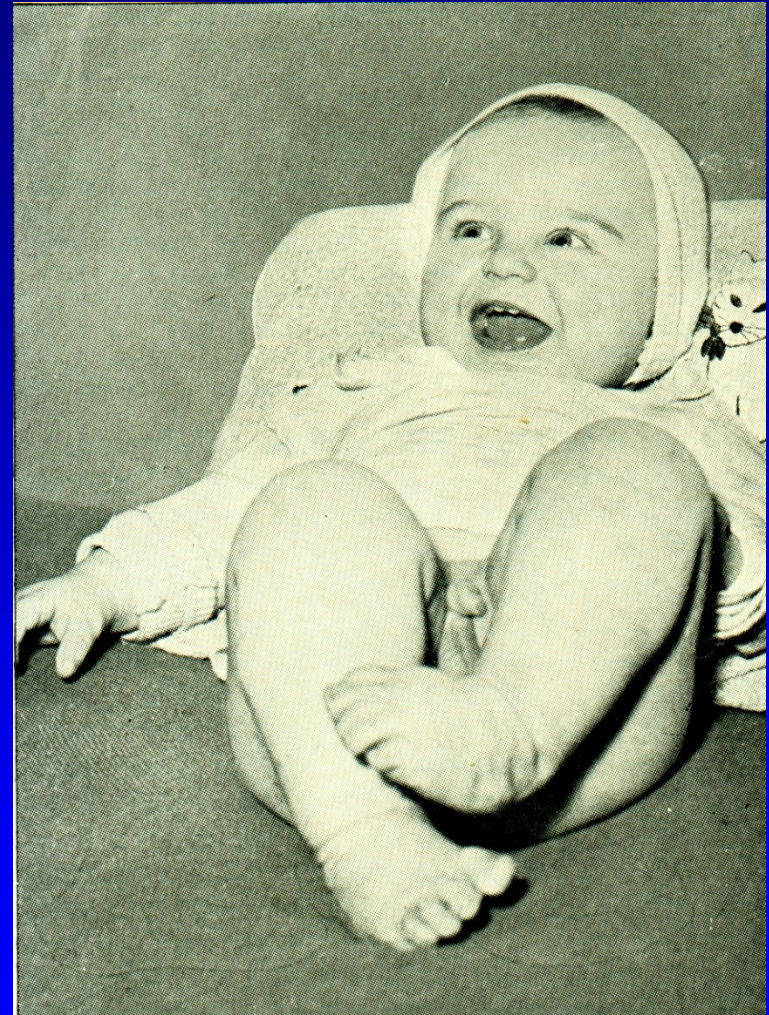
Obr. 28

Talipes equinovarus

Positional

Rigid

Rigid with other deformities



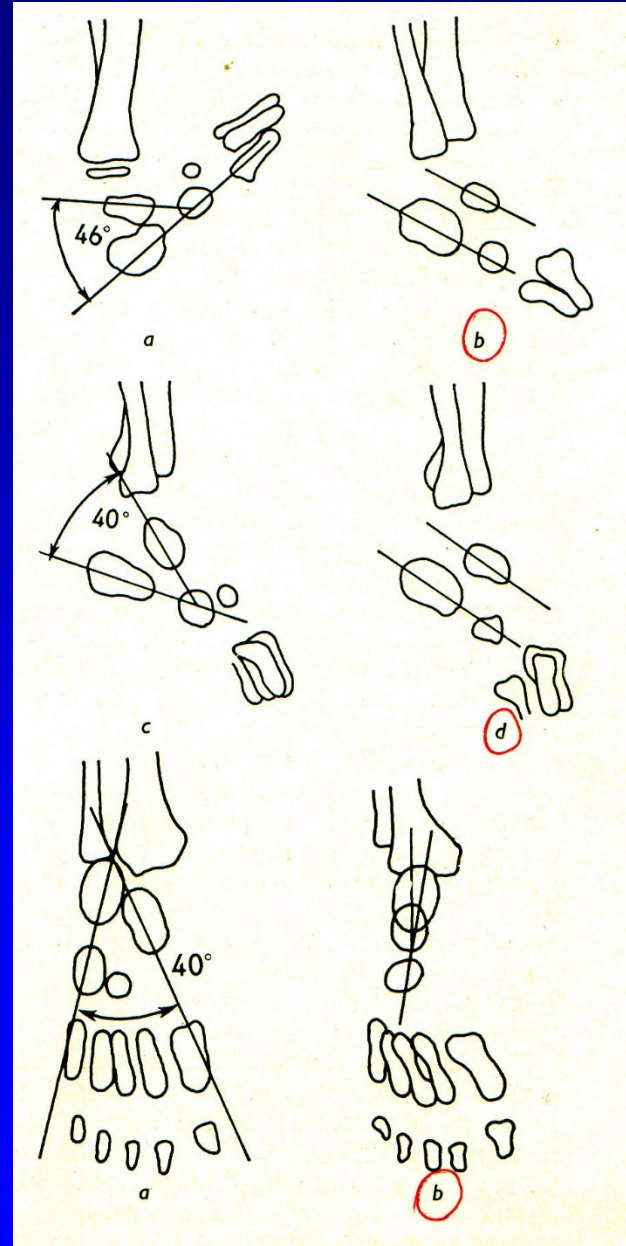
Obr. 28

Normal

PEC

Pes equinovarus congenitus

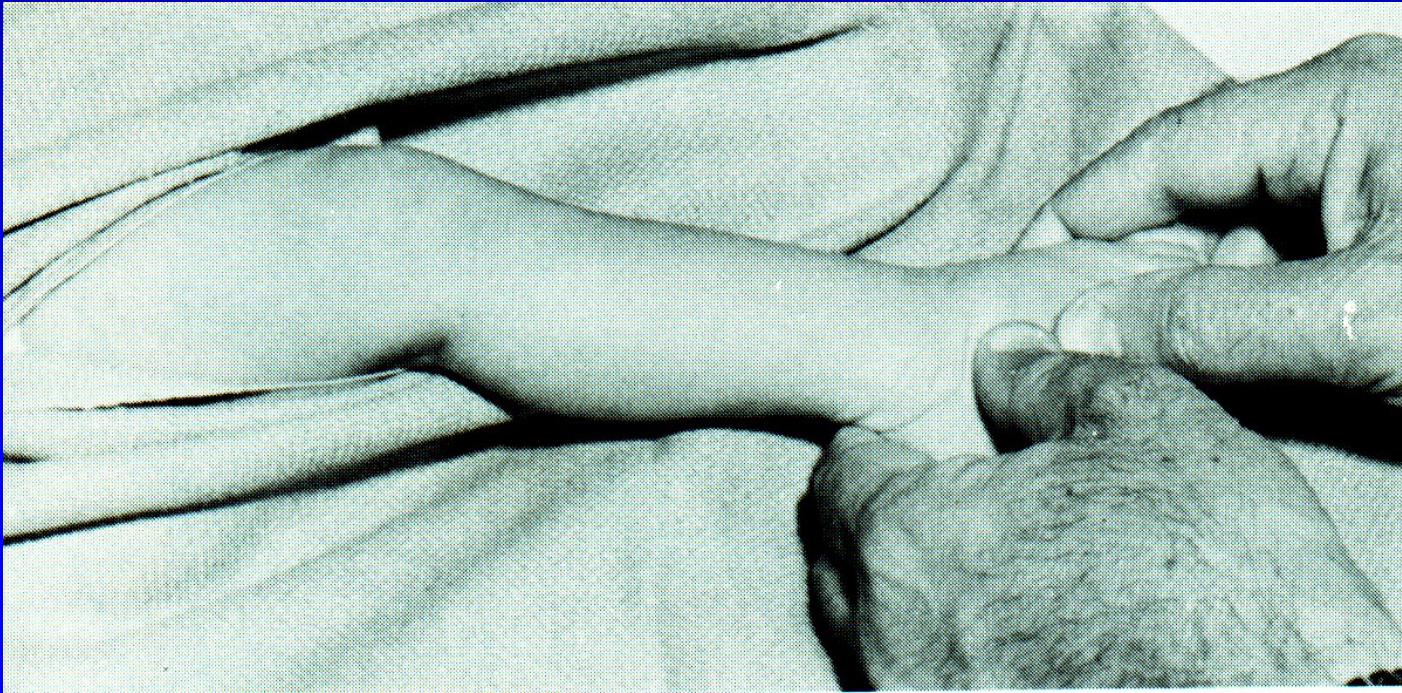
X ray



Obr. 30

Management

Fysiotherapy – first 2 days



Obr. 31

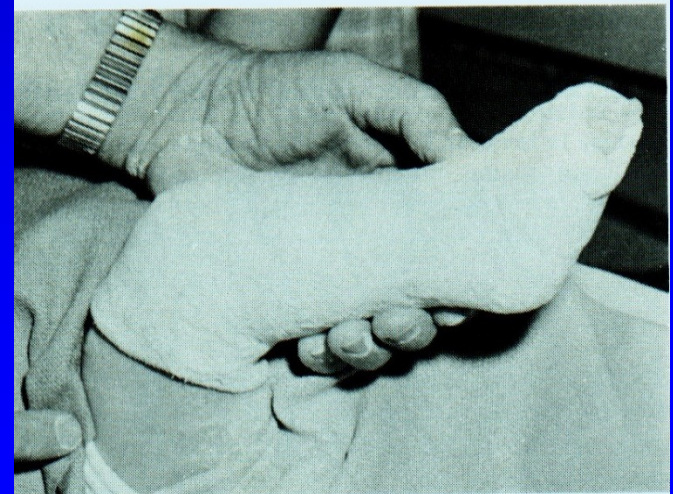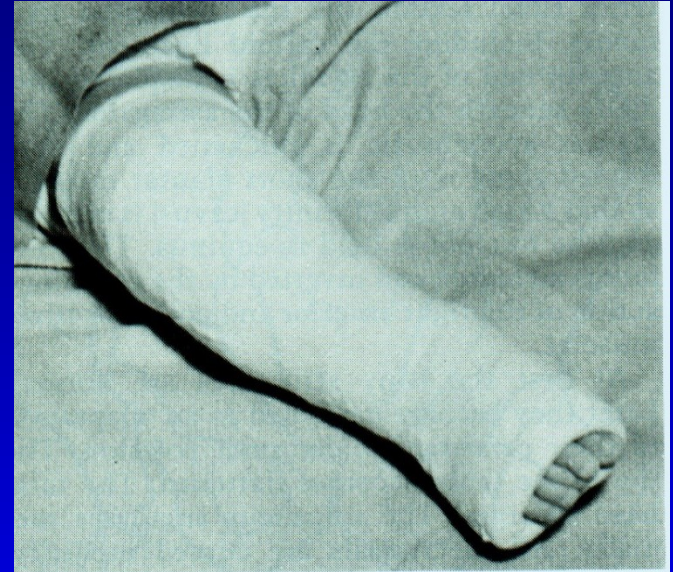Splinting

First days after a birth

Change- twice weekly

10 weeks- 3 months

Correction of all deformities



Ponseti method

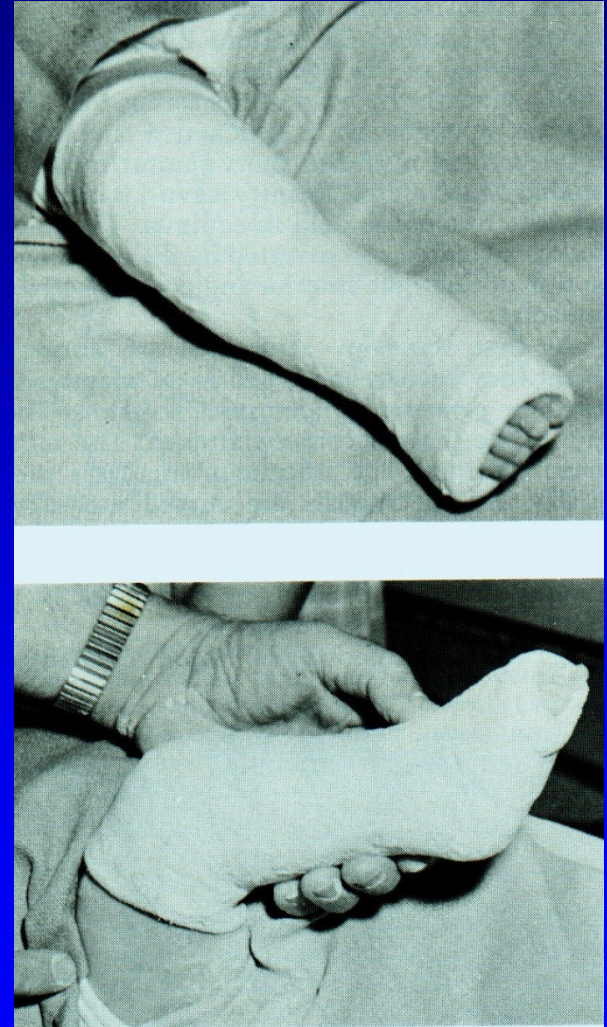Splinting 4 weeks +
correction of all deformities

Achilotomy + 6 weeks plaster

Denis- Brown splint

60 % succes

40 % surgery then necessary



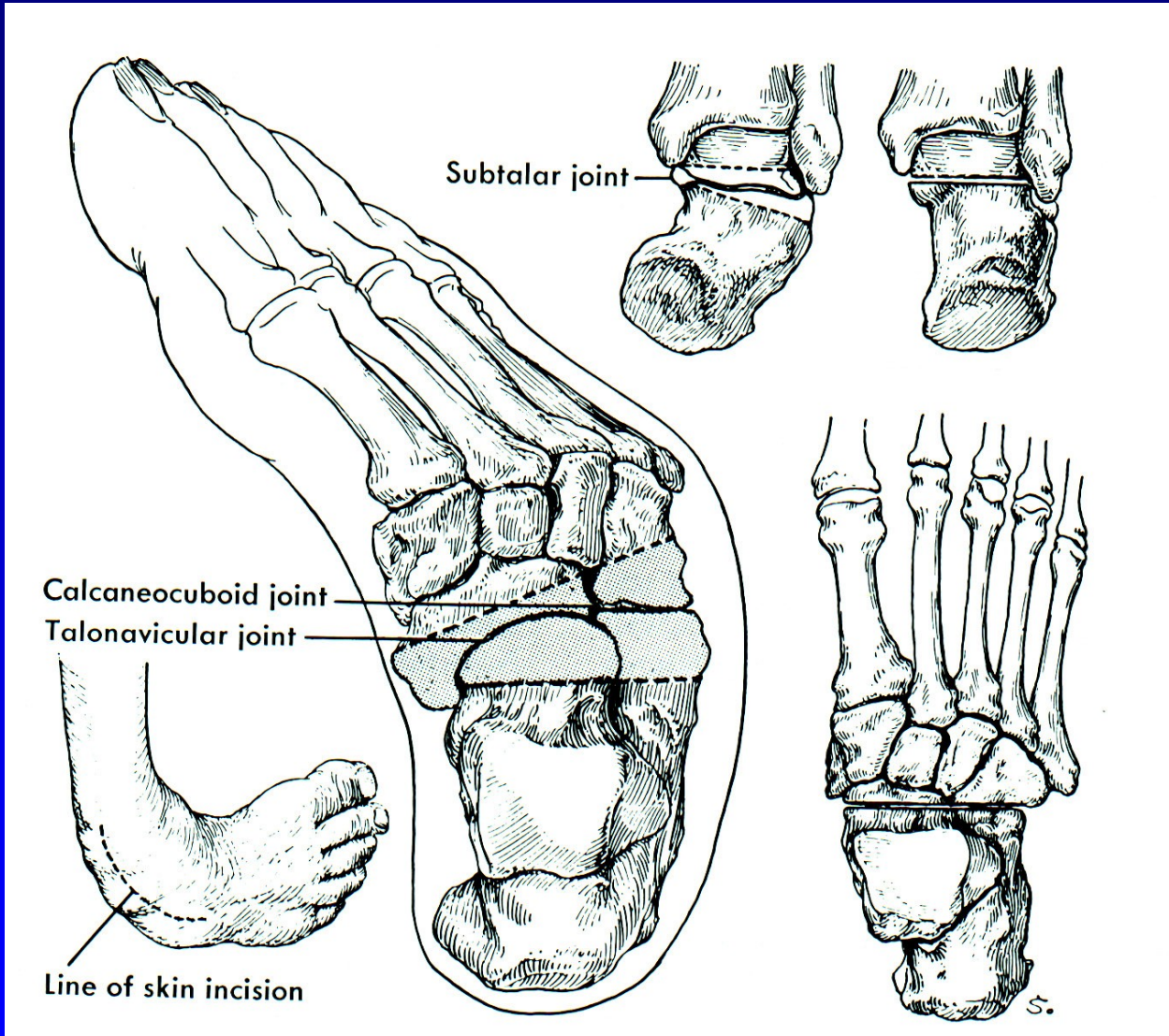
Surgery

Posterior capsulotomy +
lengthening of Achilles tendon

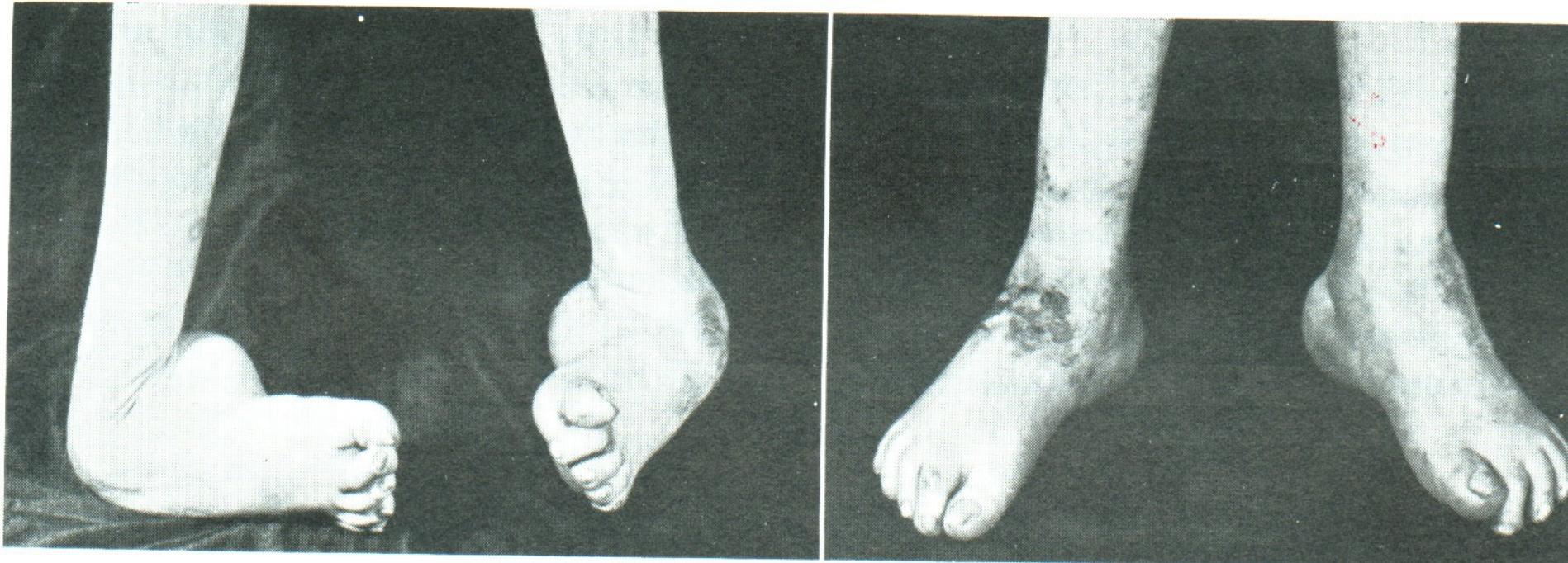Surgery- Turco, Mc Kay, Dwyer,
Heymann, Bermann + Gartland.

Aftertreatment- plaster, correction splints

Triple arthrodesis



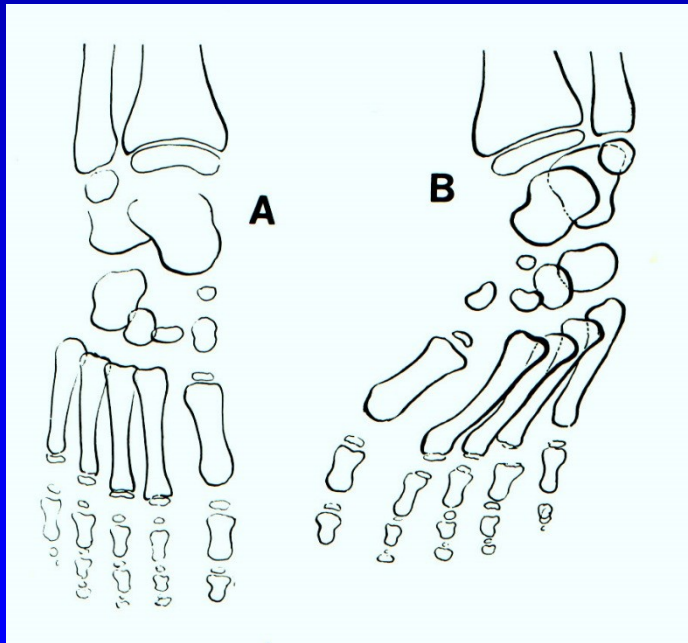
Neglected pes equinovarus congenitus



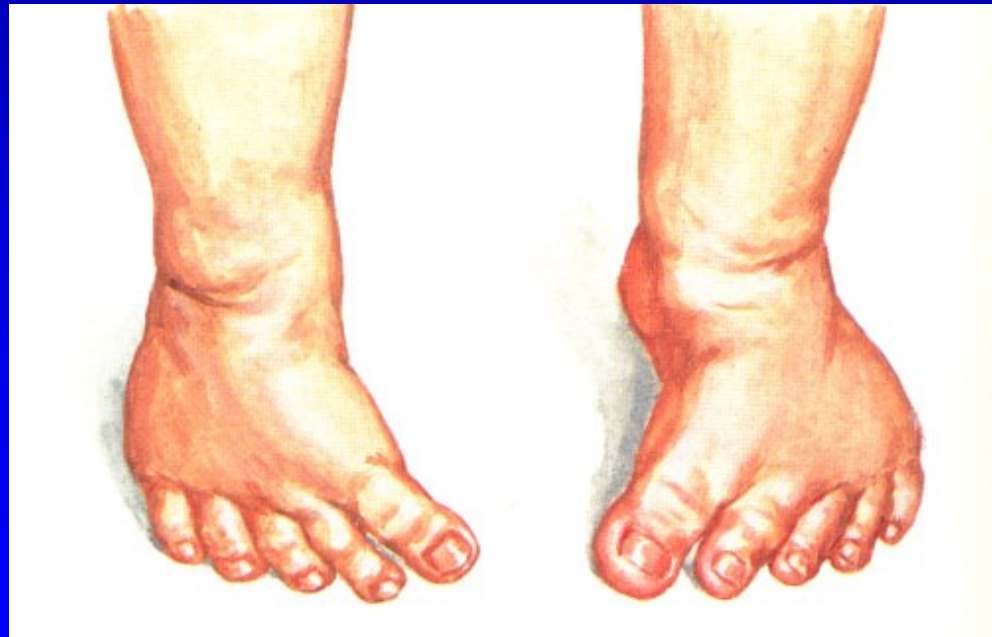Obr. 33

Metatarsus varus congenitus

Mild form of equinovarus deformity
- adduction and supination of the forefoot
Conservative and operative treatment

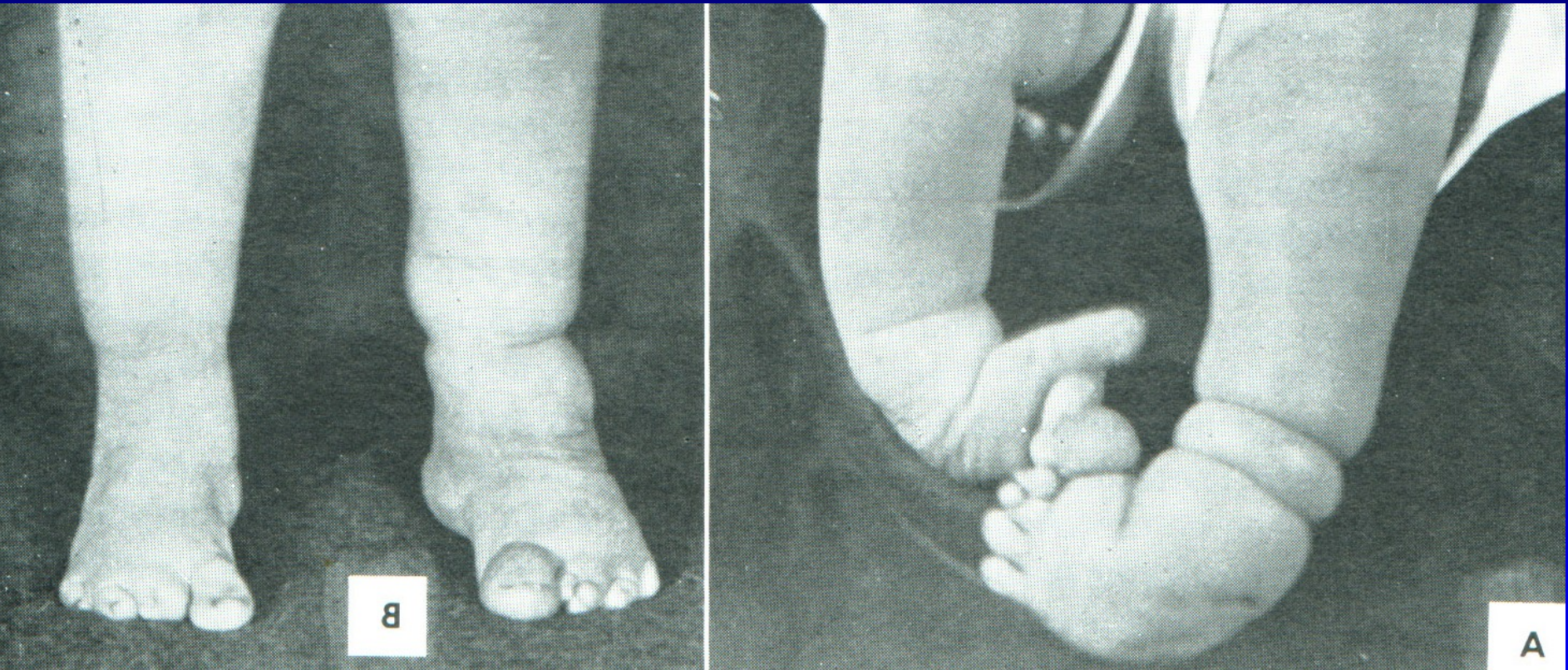


Obr. 35



Obr. 36

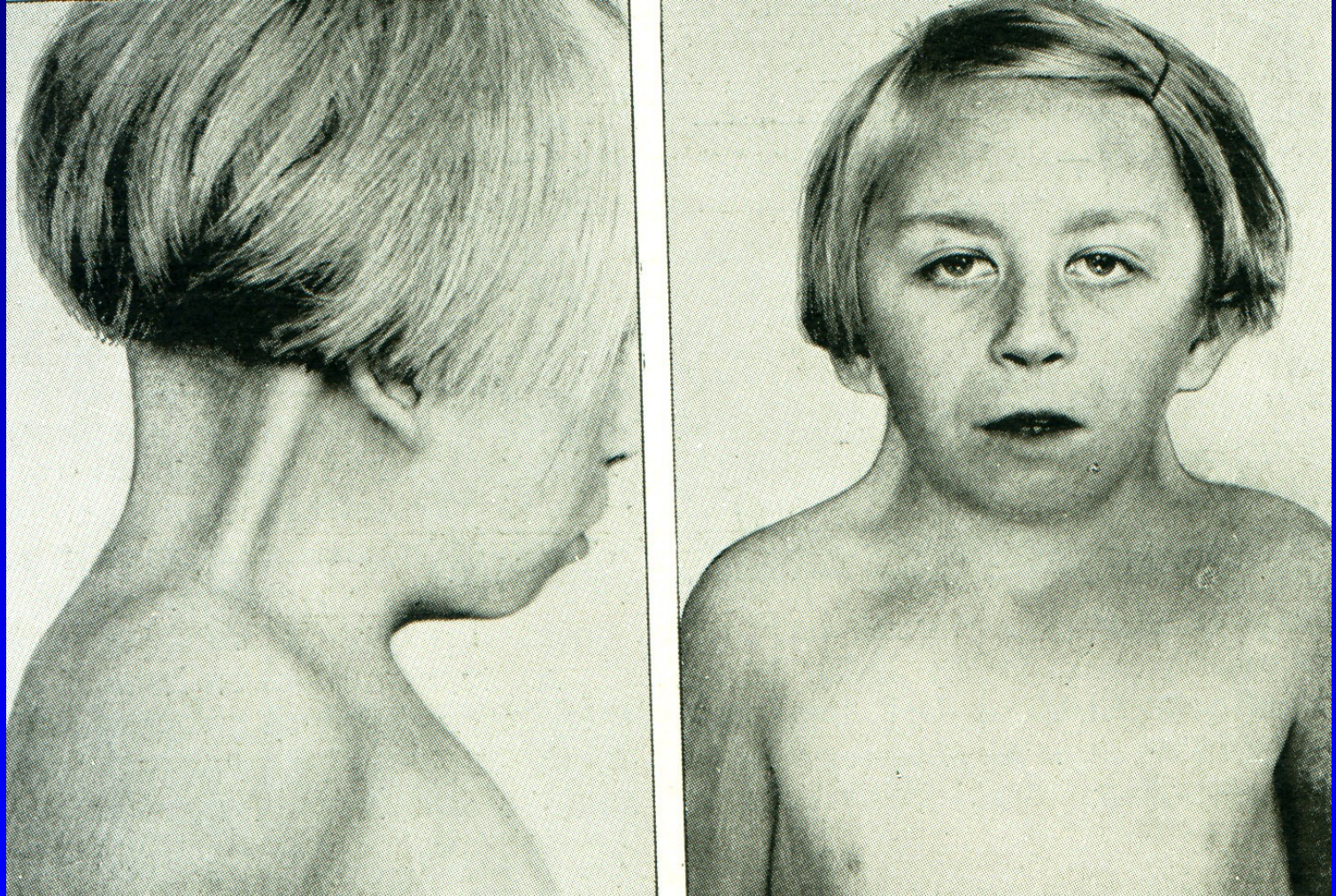
6. Congenital constrictions



Obr. 37

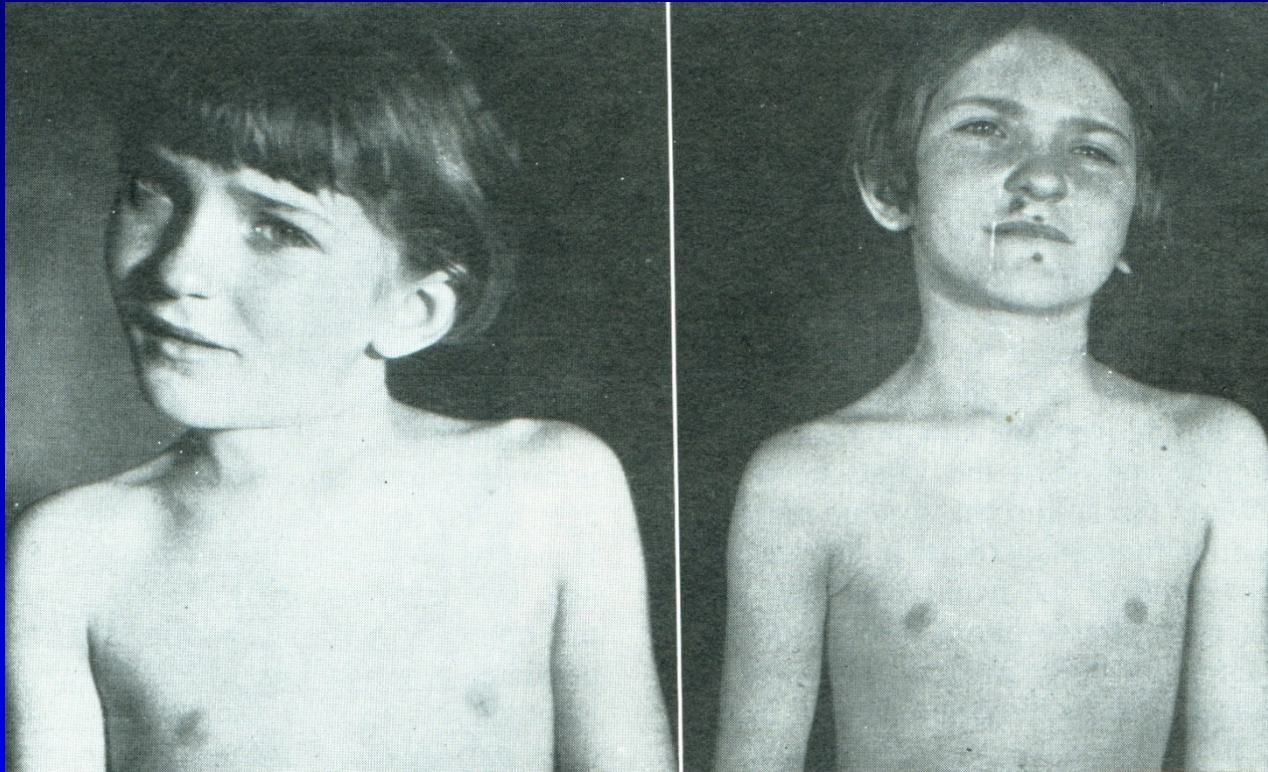
Intrauterine development

Pterygium colli



Obr. 38

Wry neck- torticollis muscularis congenita



Obr. 39

Trauma of sternocleidomastoideus muscle during delivery

Haematoma, tightening and fibrous shortening

The head – rotated to the healthy side

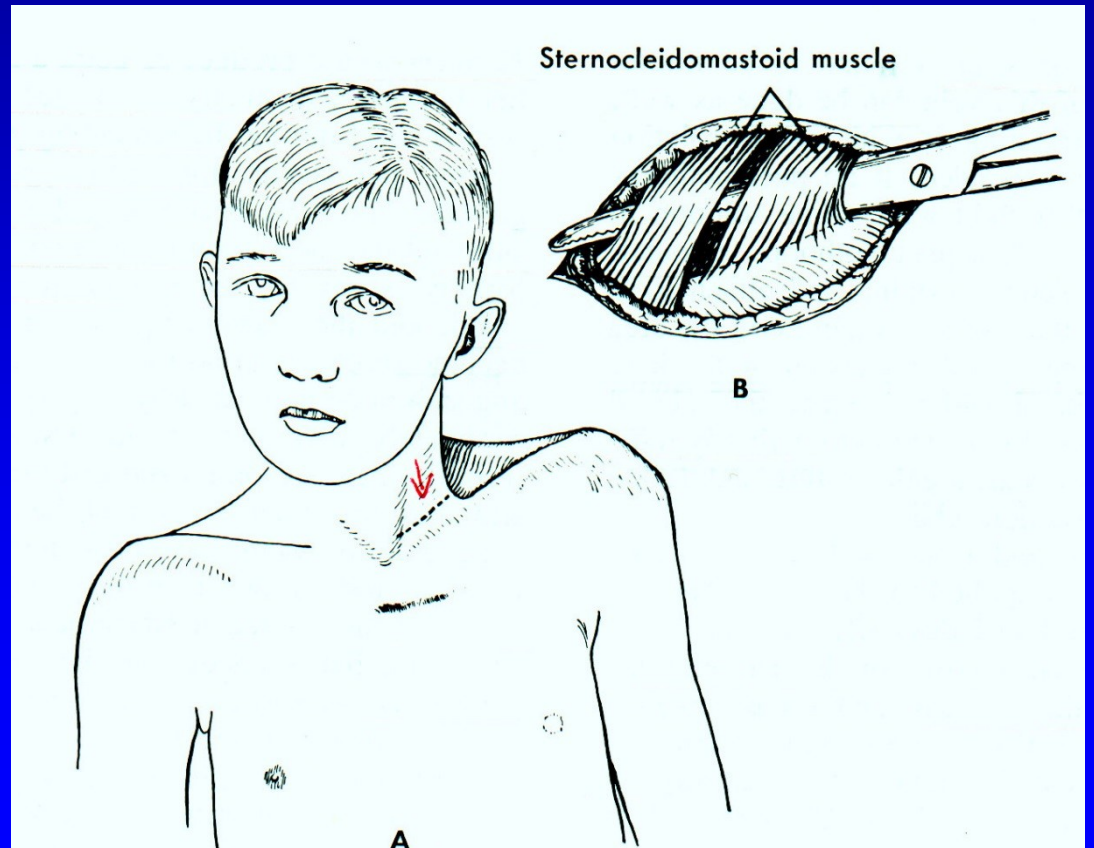
tilted to affected side

Asymetry of the face

Torticollis muscularis congenita

Positioning
Bandage

Surgery



General skeletal deformities

A. osseous

B. cartilage

C. mesenchymal

A. Osseous

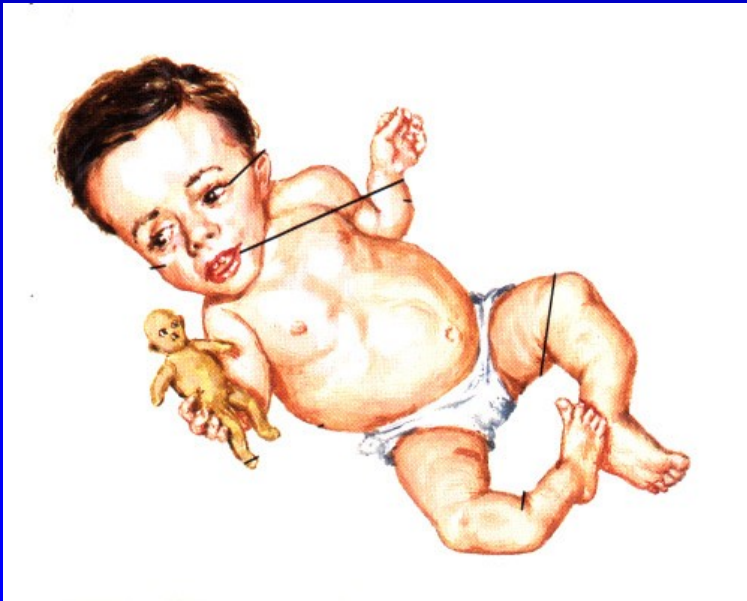Osteogenesis imperfecta

Osteopetrosis

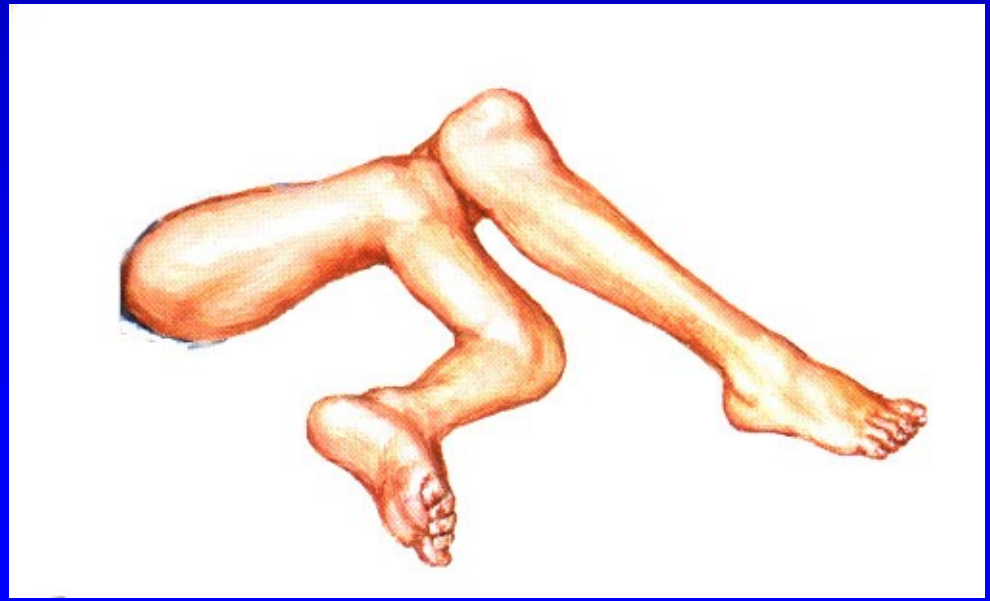
Osteogenesis imperfecta

I. – V. types

- letal (multiple fractures intrauterine)
- tarda (fractures, deformities, kyphosis, kyfoscoliosis, blue eyes, deafness (otosclerosis))

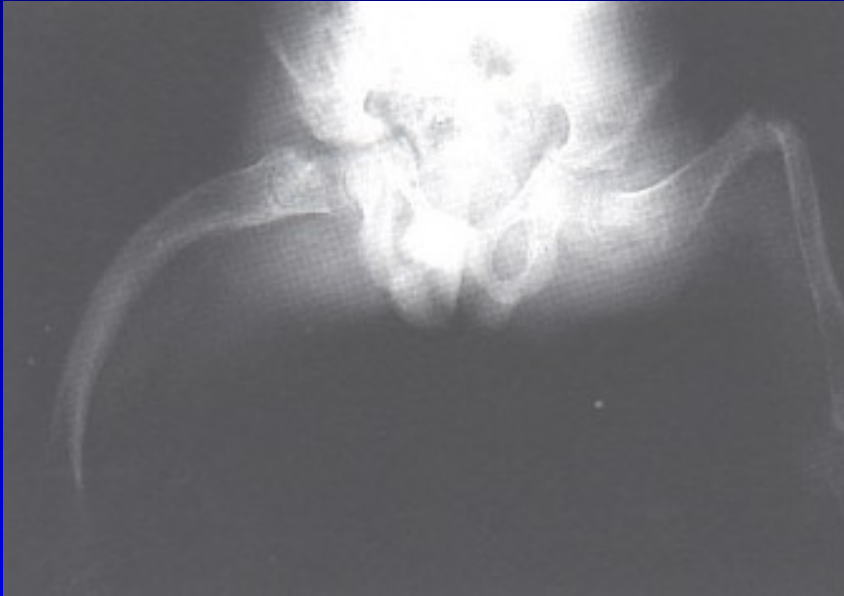

Obr. 41

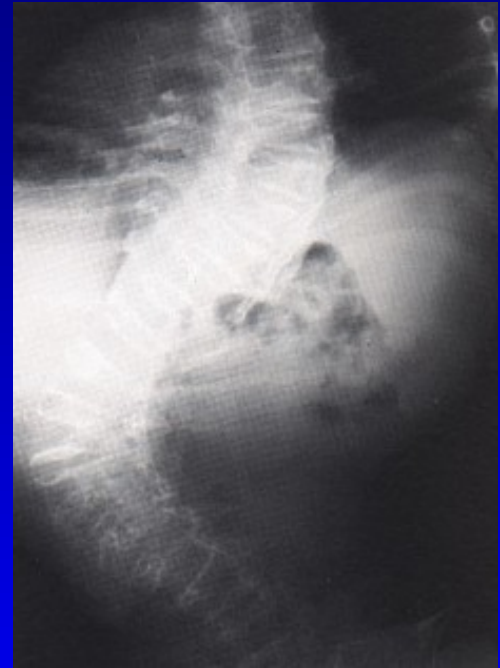

Obr. 42

Osteogenesis imperfecta

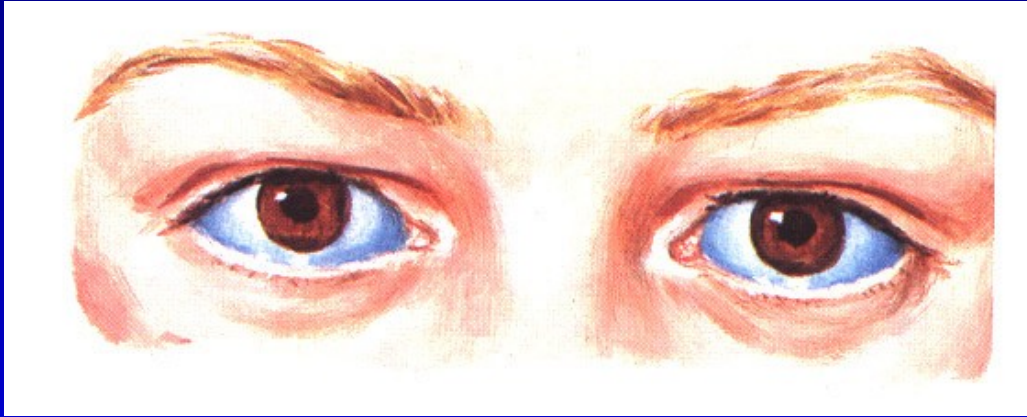


Obr. 43

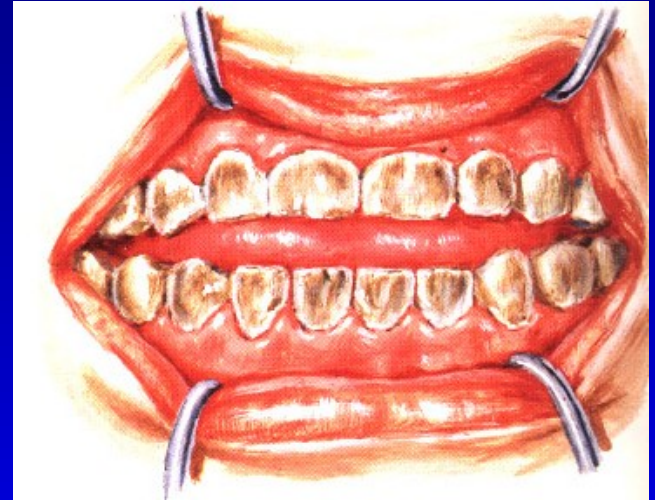


Obr. 44

Osteogenesis imperfecta

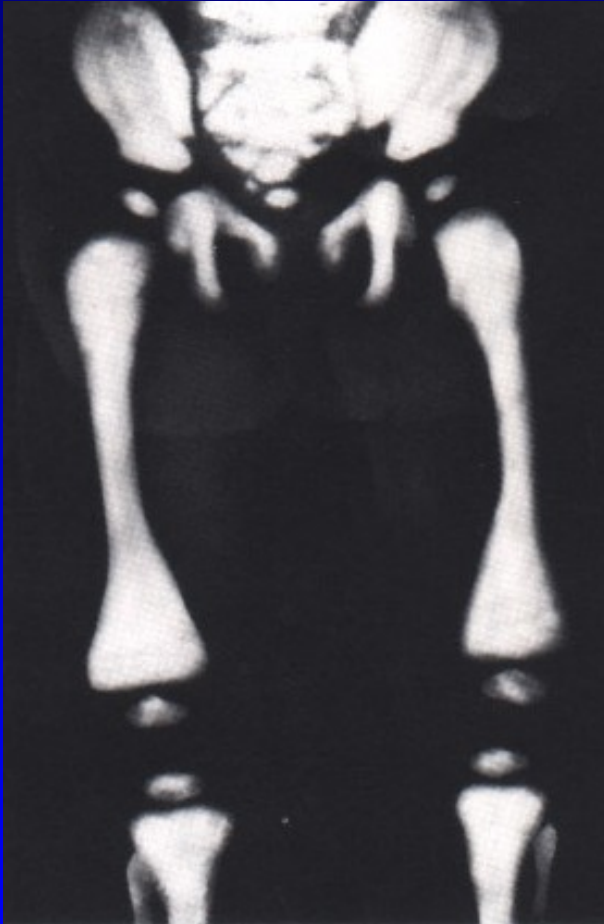

Obr. 45

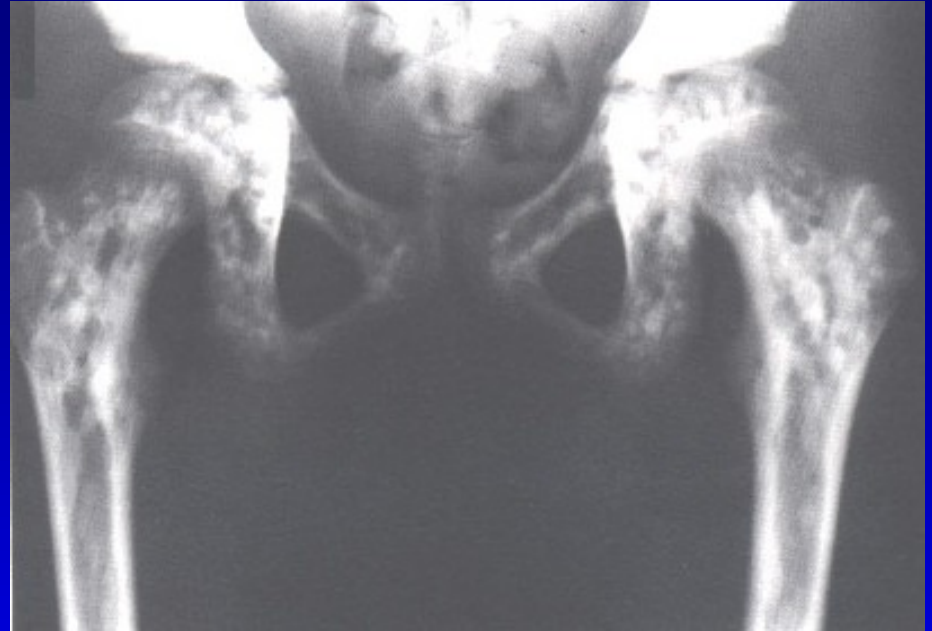


Obr. 46

Osteopetrosis



Obr. 47



Obr. 48

Osteopoikilosis

Osteopetrosis
Sclerotic and fragile bone

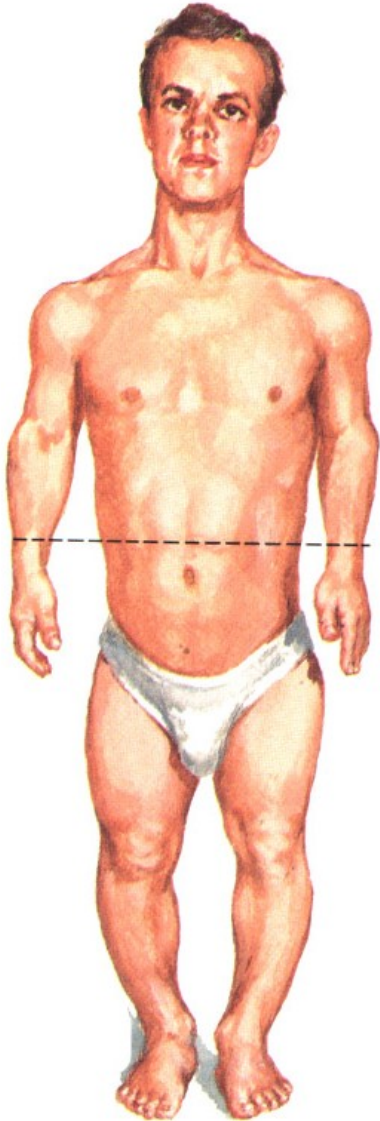
B. Cartilage

Achondroplasia

Multiple chondromatosis

Multiple epiphyseal dysplasia

Dwarfism- achondroplasia



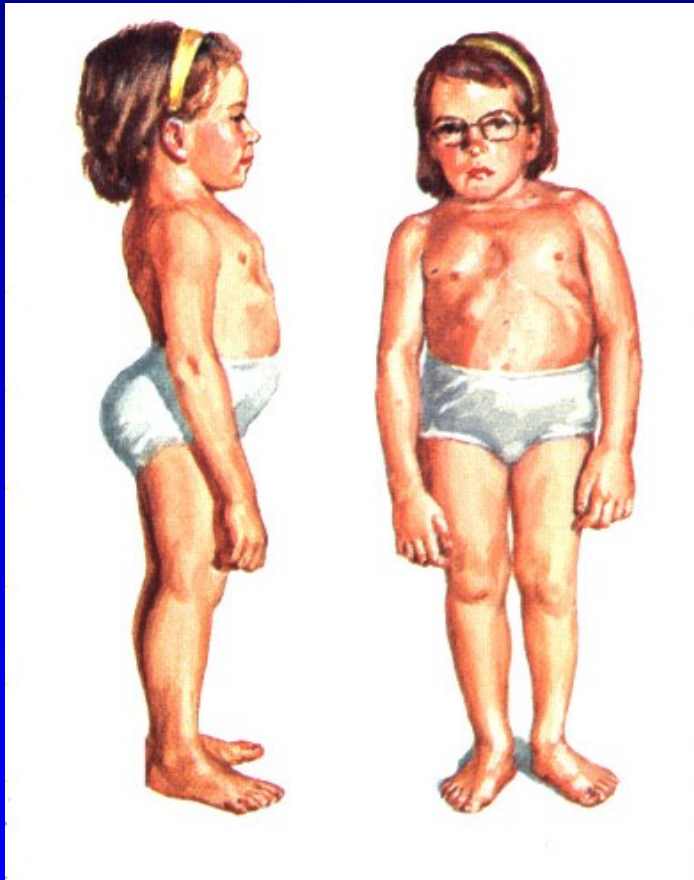Dysproportional short stature
Long trunk, short extremities

Normal mental condition

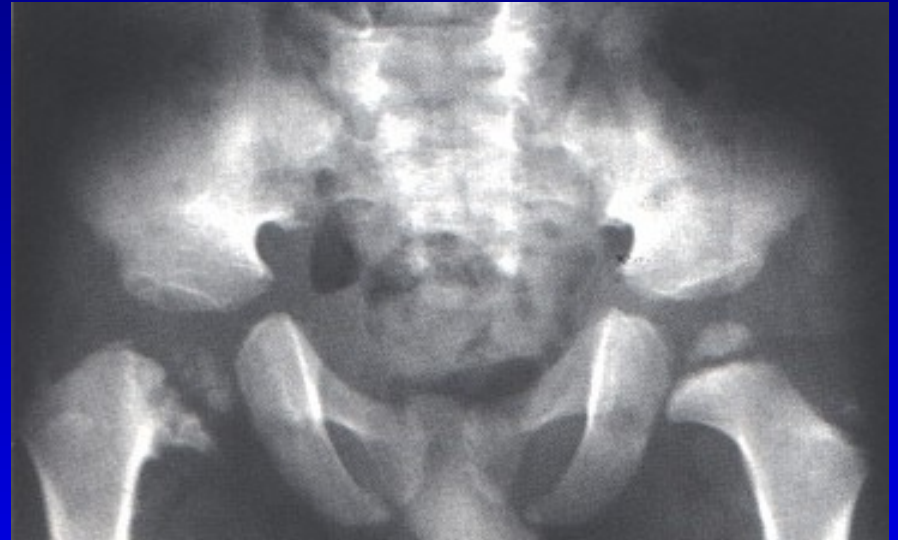Low function of growth plates
with their premature closure

Obr. 49

Spondyloepiphyseal dysplasia



Obr. 50



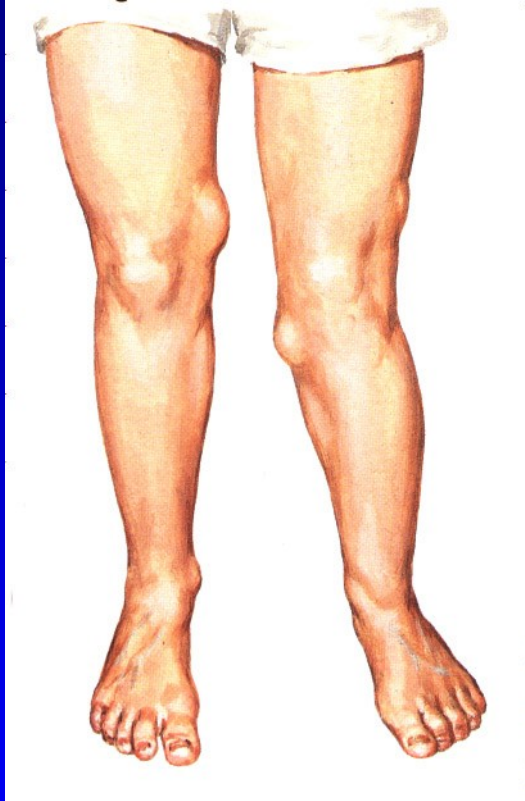Obr. 51

Disorder of enchondral growth
and ossifications

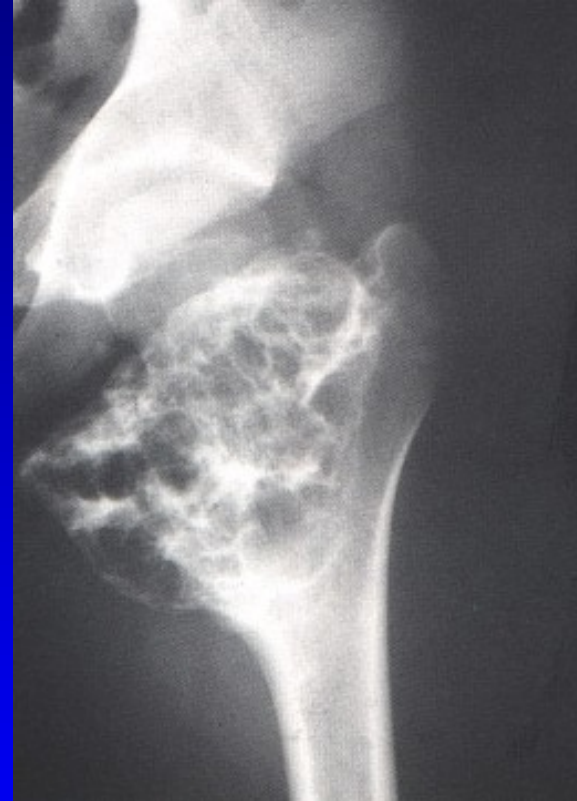Deformity of epiphyseal region

Affections of joints, platyspondylia

Multiple osteochondromatosis



Obr. 52



Obr. 53

Multiple osteochondroms

C. Mesenchymal

Arthrogryphosis congenita

Neurofibromatosis

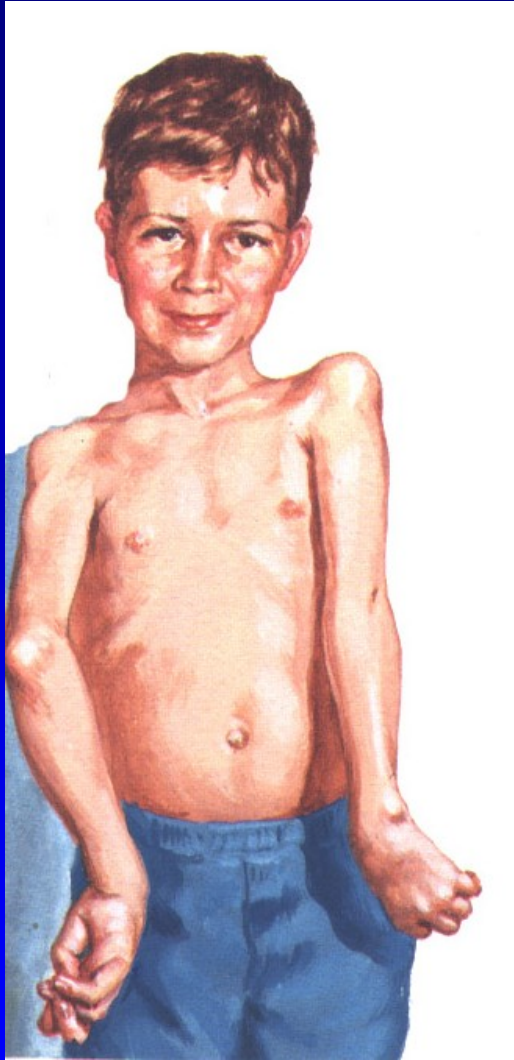Fibrous dysplasia

M. Ehlers-Danlos

Marfan syndrom

Mucopolysacharidosis

Arthrogryphosis congenita



Change of muscles into
fibrous and adiposis tissue

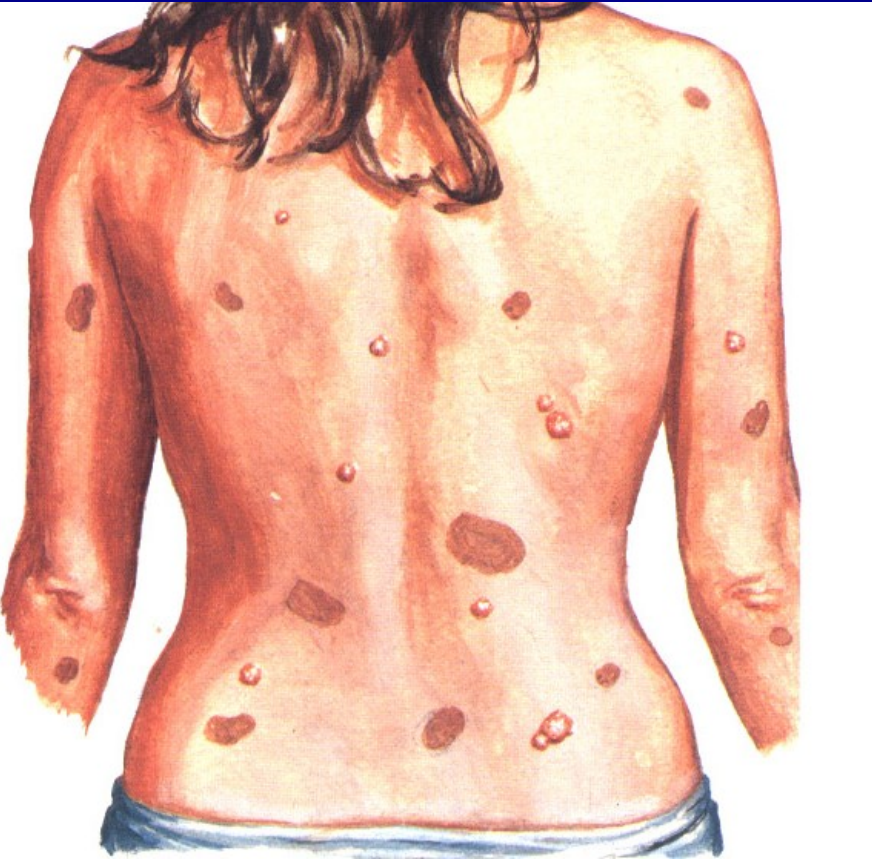Stiff joints

In flexion

In extension

Normal mental condition

Neurofibromatosis



Multiple neurofibroms

Café au lait patches

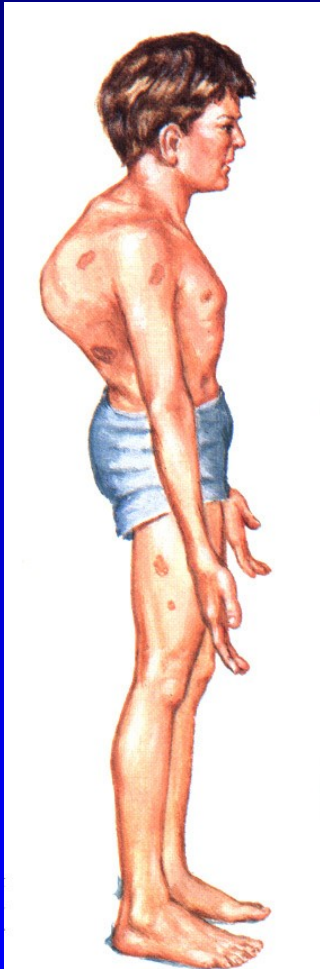Large naevus

Hyperplasia

Hypoplasia

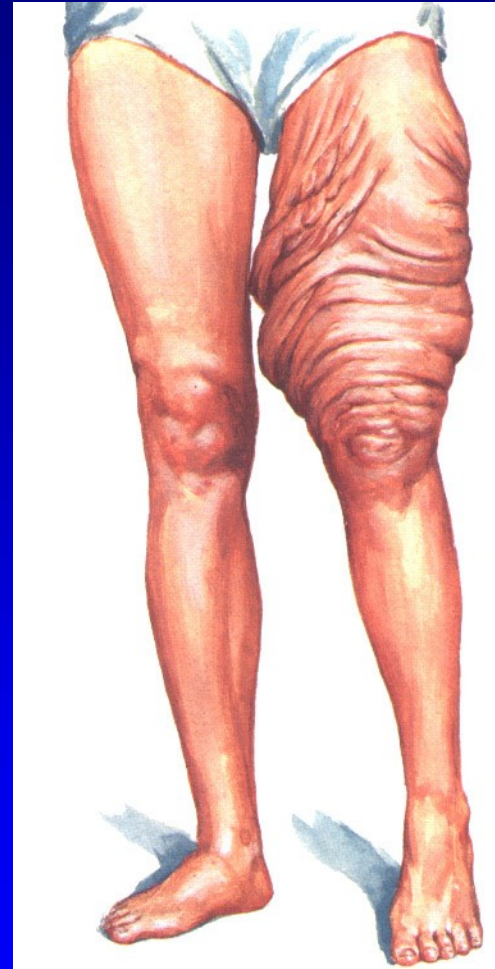Obr. 55

Neurofibromatosis



Obr. 56

Kyfoskoliosis



Obr. 57

Elefantiasis

Neurofibromatosis

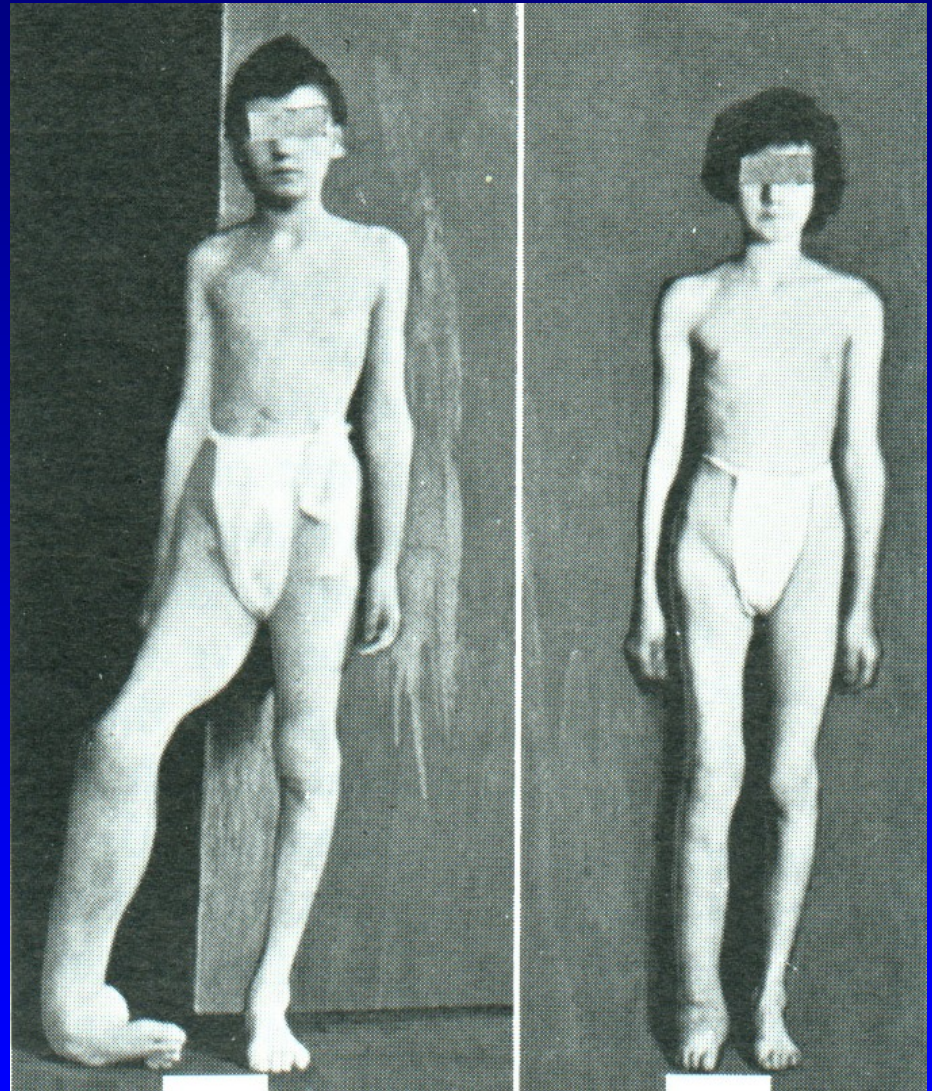
Oedema

Elefantiasis

Haemangiomas

Hyperplasia

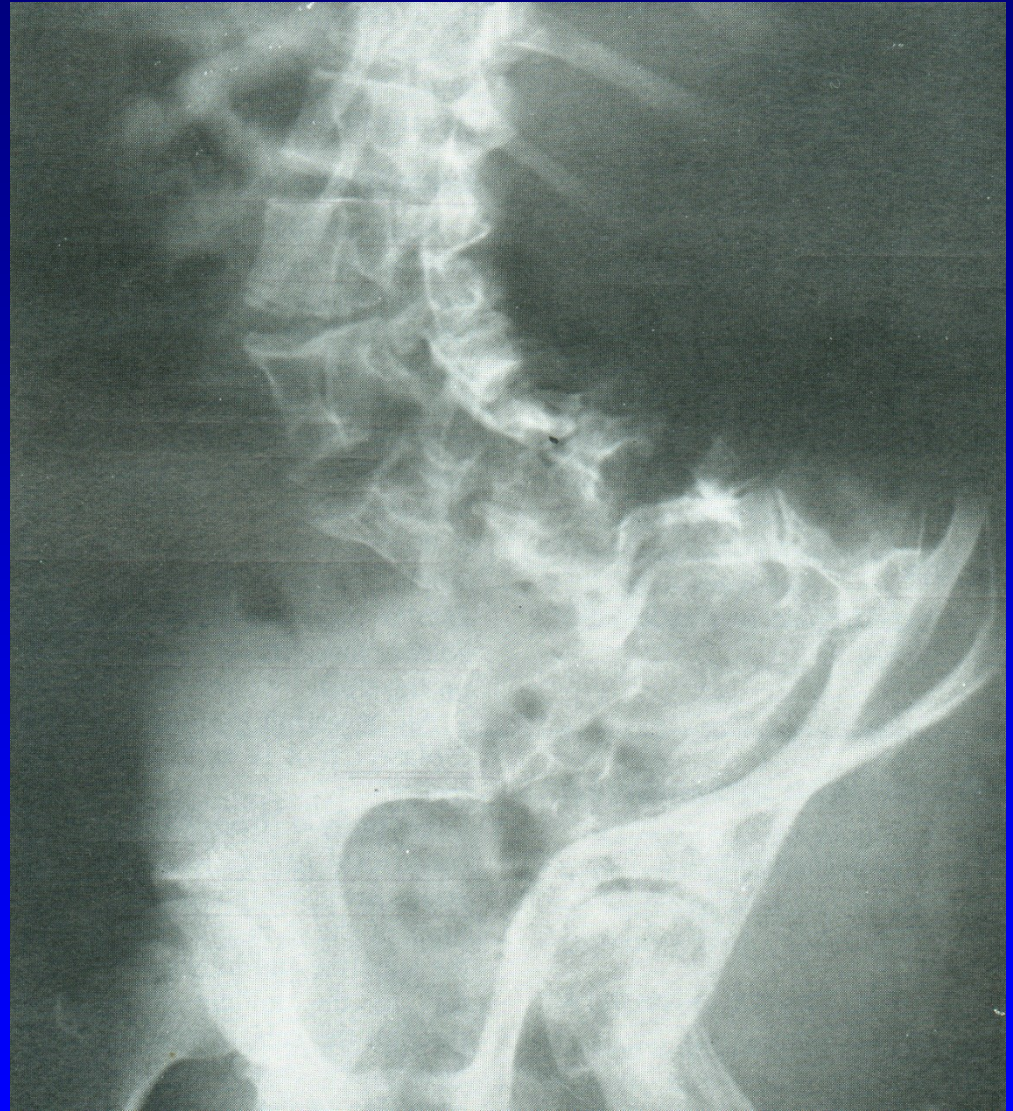Hypoplasia



Obr. 58

Neurofibromatosis

Scoliosis
Deformity of the pelvis

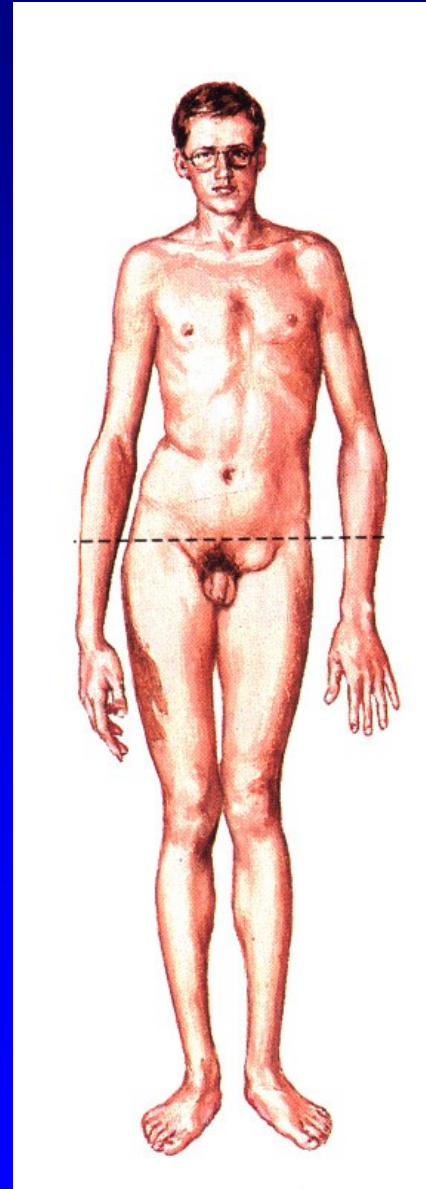


Obr. 59

Marfan syndrom

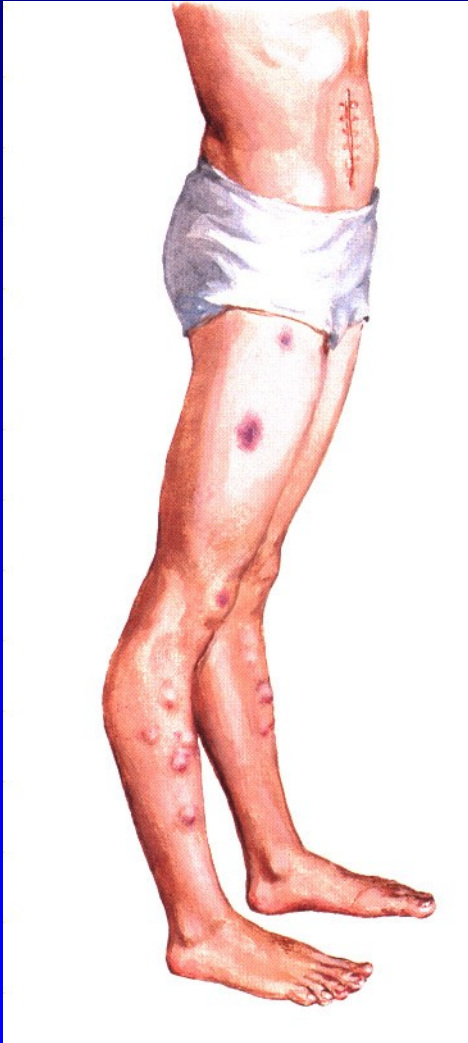Tall stature
Long extremities
Long fingers
Scoliosis
Deformity of the sternum

Aneurysma of the aorta
Hearth failure
Lens dystopy
Gothic patro

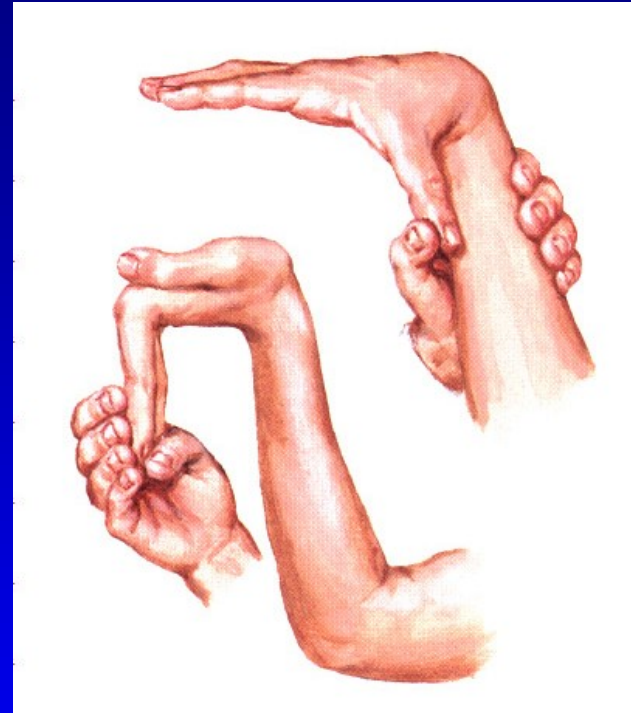


Obr. 60

Marfan syndrom



Obr. 61



Obr. 62

Mesenchymal general laxity
genu recurvatum

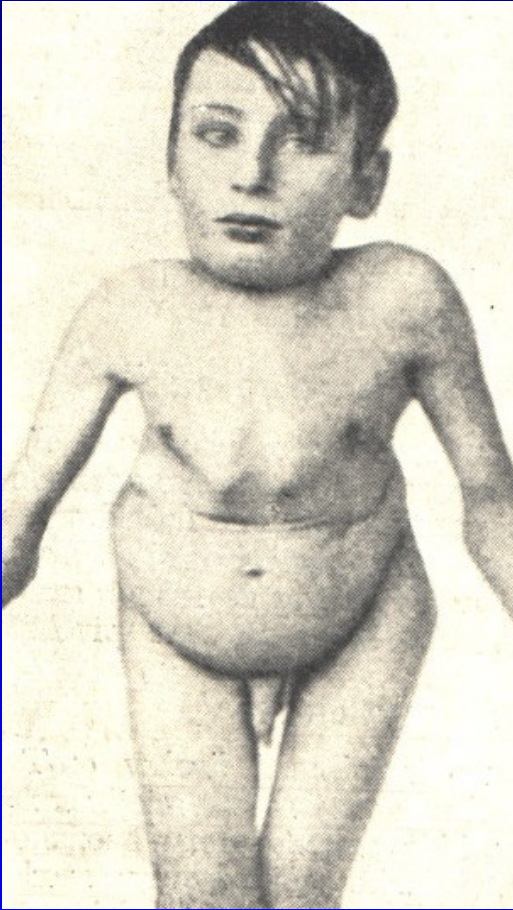Mucopolysacharidosis

Morquio- Brailsford syndrom

Hurler syndrom

Hunter syndrom

Morquio- Brailsford syndrom



Platyspondylia
hyperkyphosis
Short stature
Short neck
Pectus carinatum
Weaknes of muscles
Hip deformities

Obr. 63

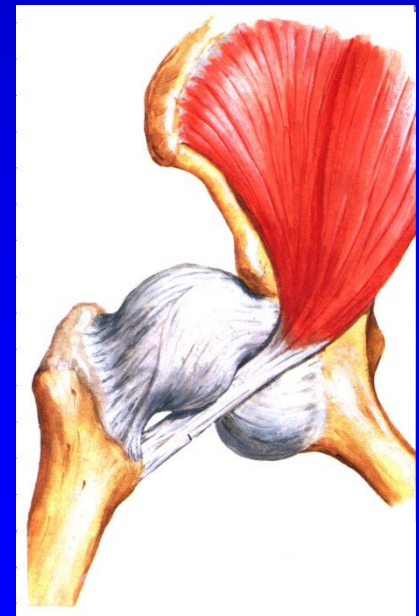
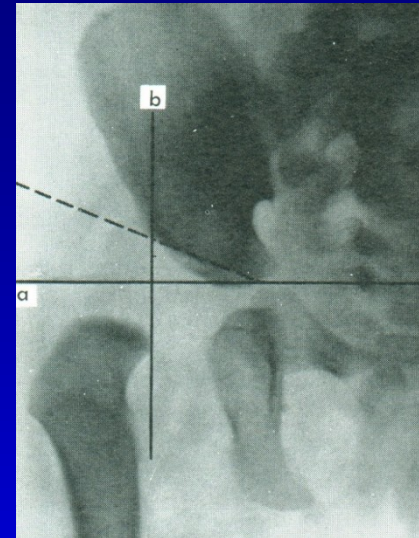
Developmental dysplasia of the hip

Occurrence: 5 % of all children

Czech republic: 80-120
diclocations/ year

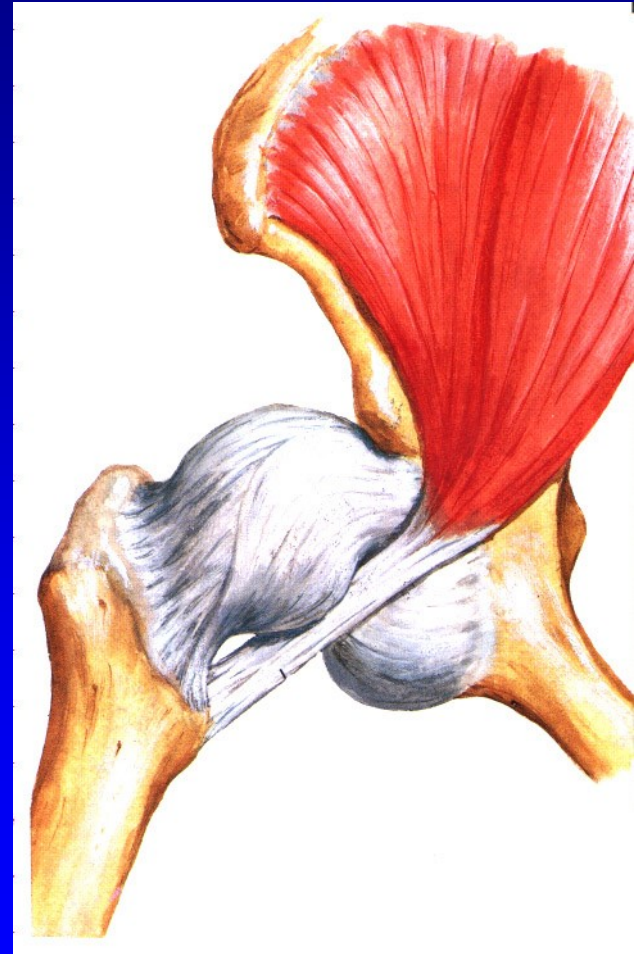
3-5 often girls

20 % of dysplastic O.A.



DDH

Perinatal and postnatal
Genes for acetabular dysplasia
Genes for joint capsule laxity
Increased laxity- relaxin
External forces
Birth- pelvis first

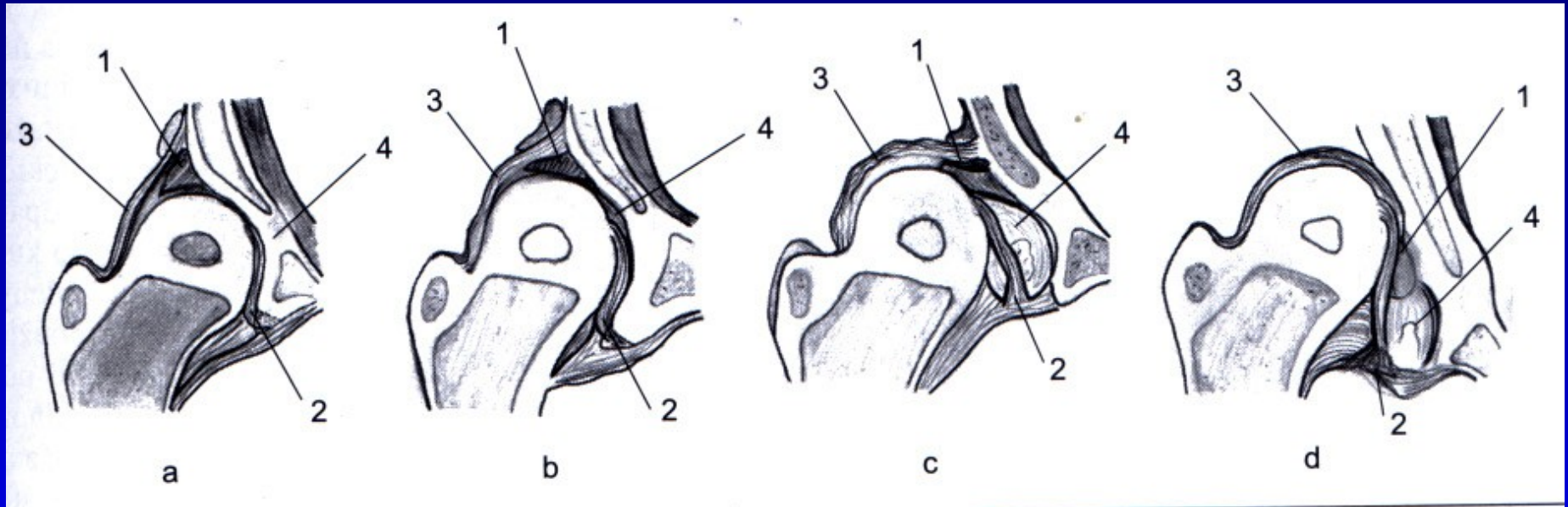


Obr. 64

DDH

1. Dysplasia
 - a- stable hip
 - b- unstable hip
 - steep osseous tectum
 - late ossification of femoral head
 - no decentration
2. Subluxation – head is subluxated
3. Dislocation- head is outside of the acetabulum

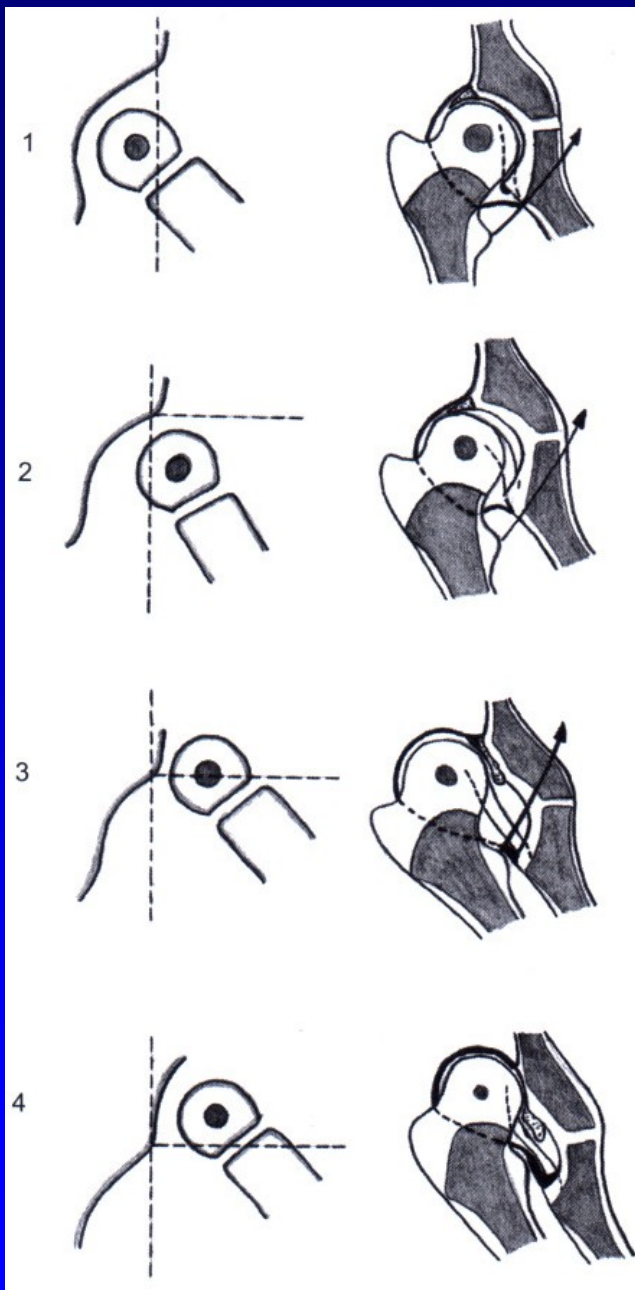
DDH



- a dysplasia, stable hip
- b dysplasia, unstable hip
- c subluxation
- d dislocation

AKH classification of DDH

- 1 preluxation
- 2 unstable dysplasia
- 3 subluxation
- 4 dislocation

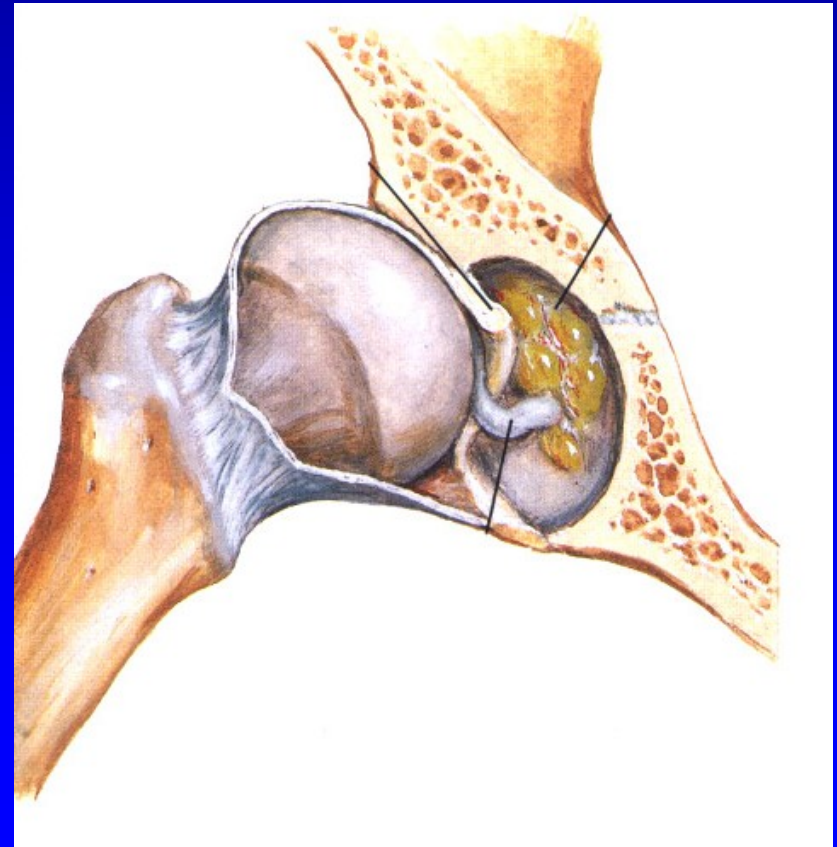


4. dislocation – head is outside of the acetabulum

luxatio marginalis

luxatio supracotyloidea

luxatio iliaca



Obr. 66

Symptoms in a newborn child- certain

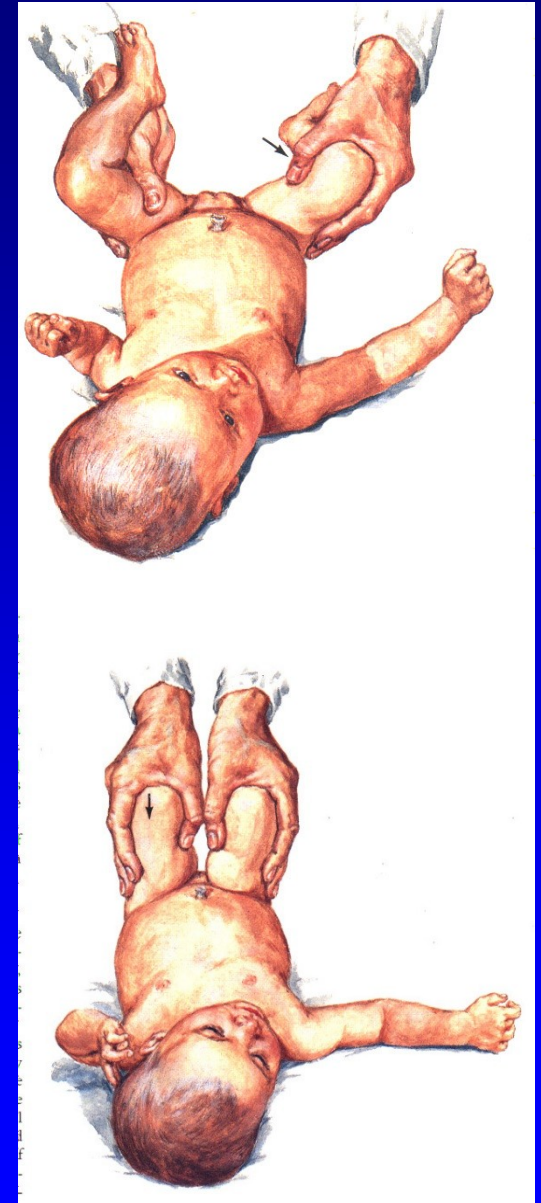
Ortolani abduction test (reduction)

Dislocation tests:

- Palmén test
- le Damany test
- Barlow test

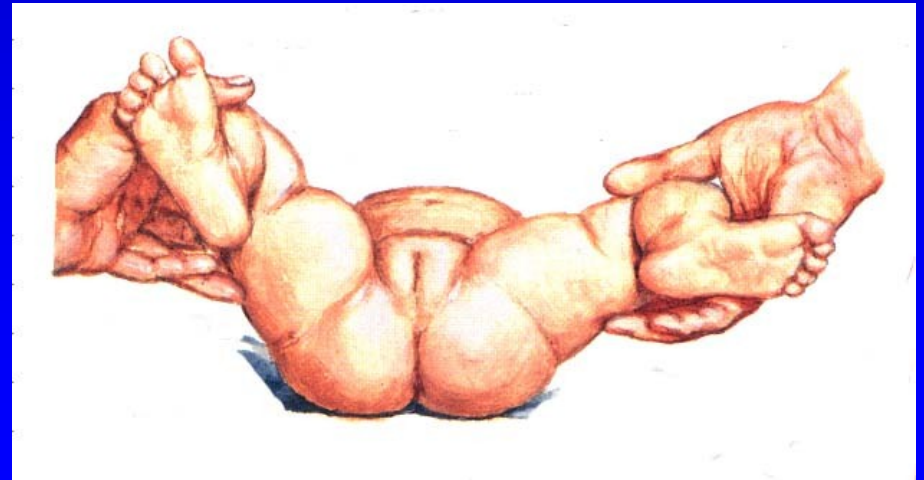
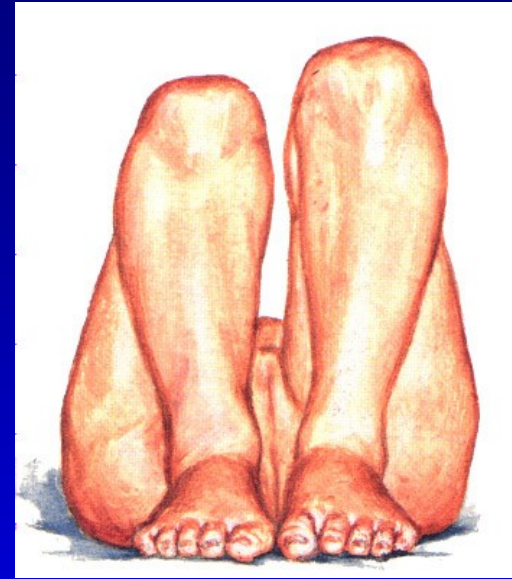
High position of greater trochanter

Femoral head is palpable
under abductors or in groin region



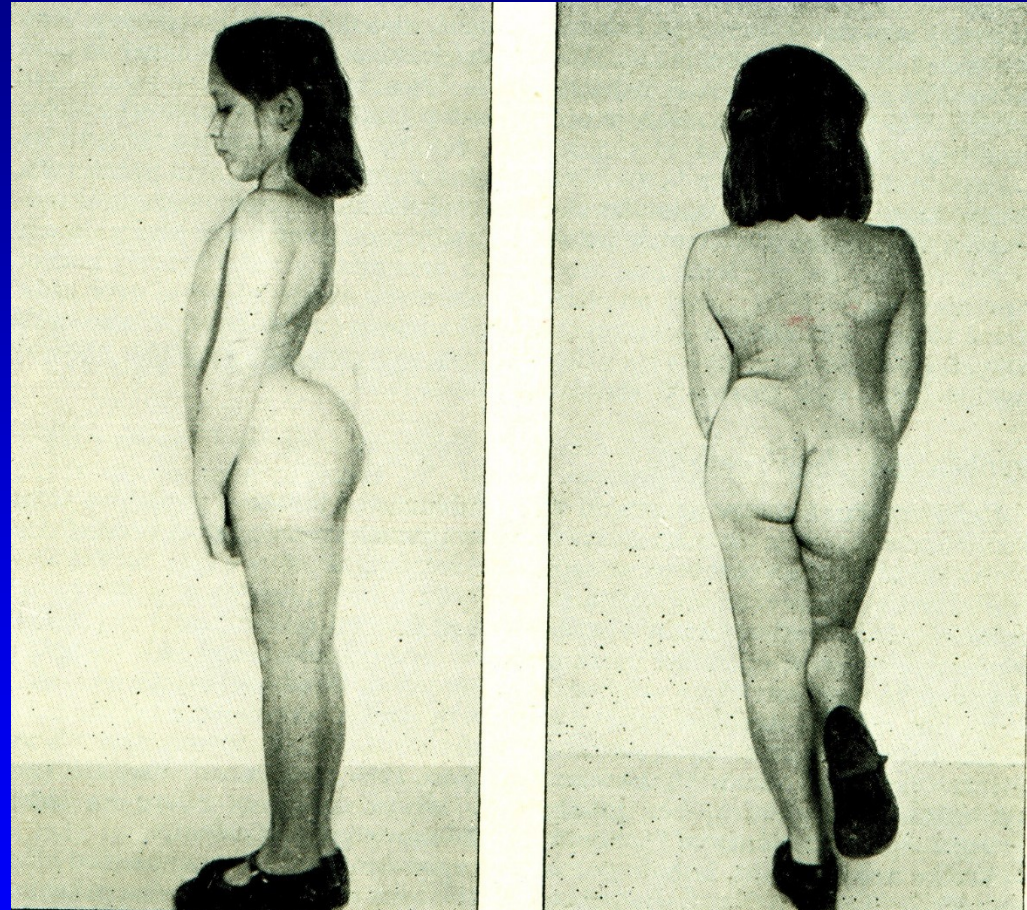
Symptoms in a newborn child - suspicion

- Shortening of the extremity
- Limited abduction
- Asymmetry of skin grooves
- Increased tonus of adductors



Symptoms in a older child

Limping
Shortening of the extremity
Trendelenburg sign
Lumbar hyperlordosis
Rocking child in
bilateral cases



Obr. 70 Trendeleburg sign

Ultrasonography

Graf classification

1a

1b

II a

II b

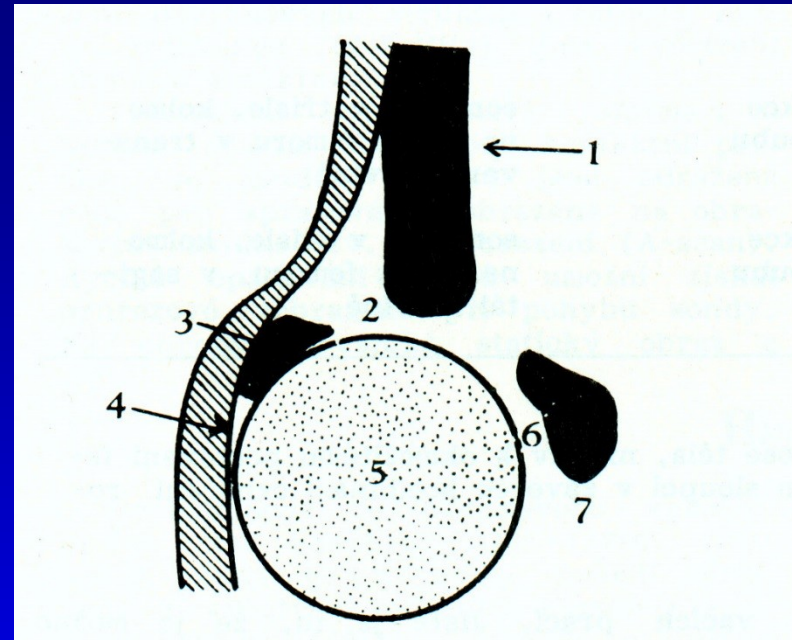
II c

II d

III a

III b

IV



Obr. 71

1- iliac bone

2- cartilago of lateral acetabulum

3- labrum acetabulare

4- joint capsule

5- femoral head

6- osseous tectum

7- inferior margin of the iliac bone

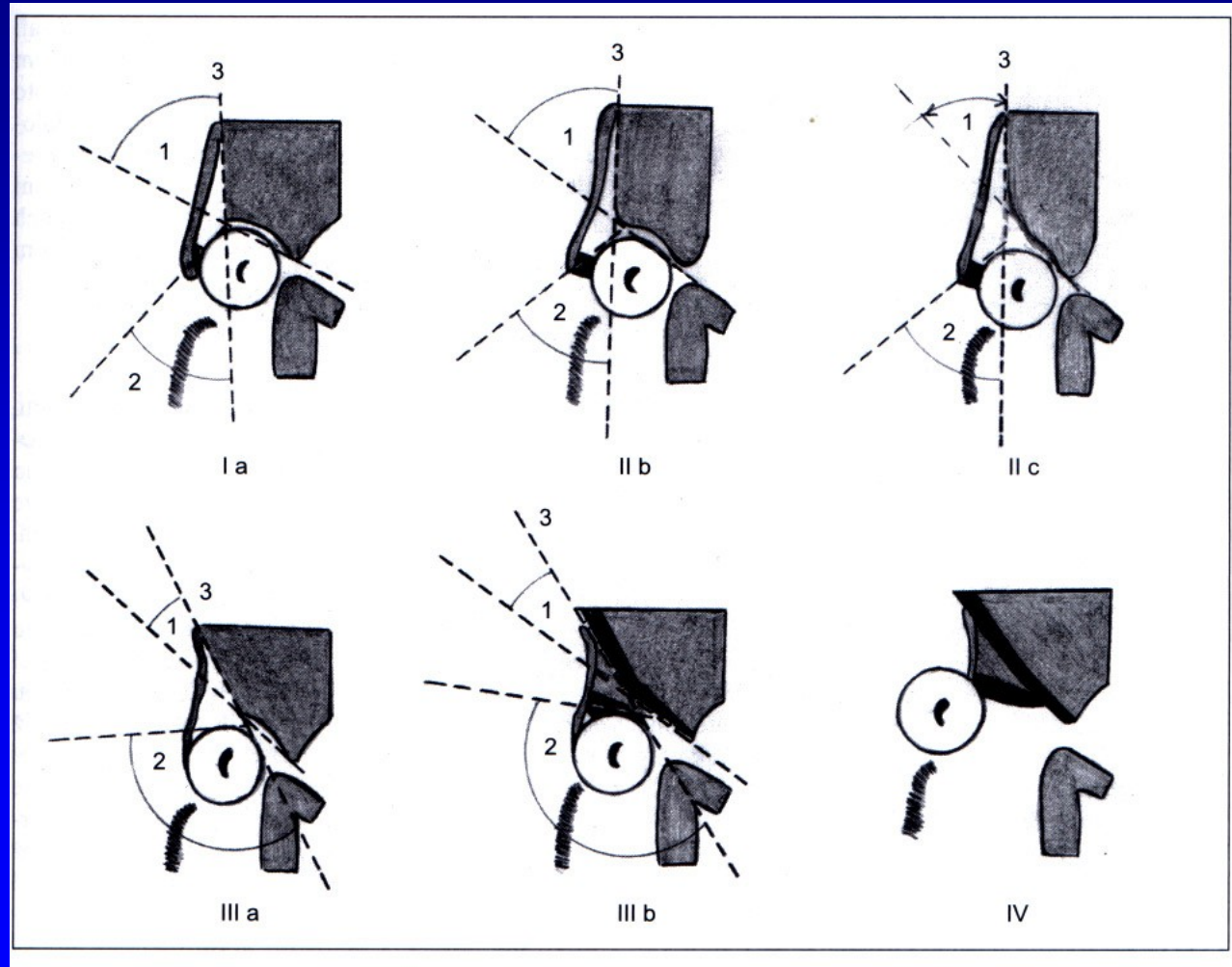
Graf classification- ultrasonography

Ia, Ib normal

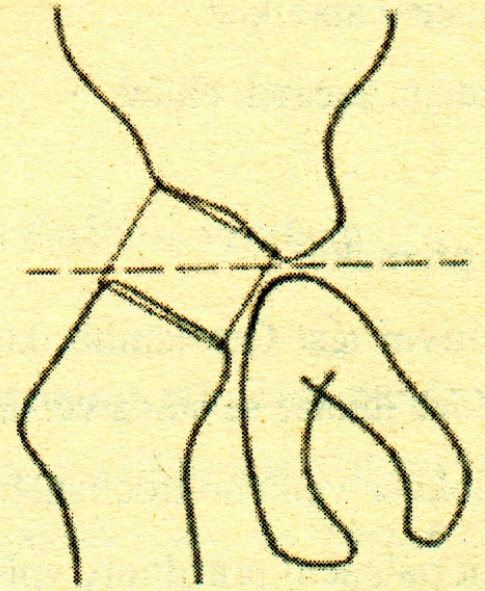
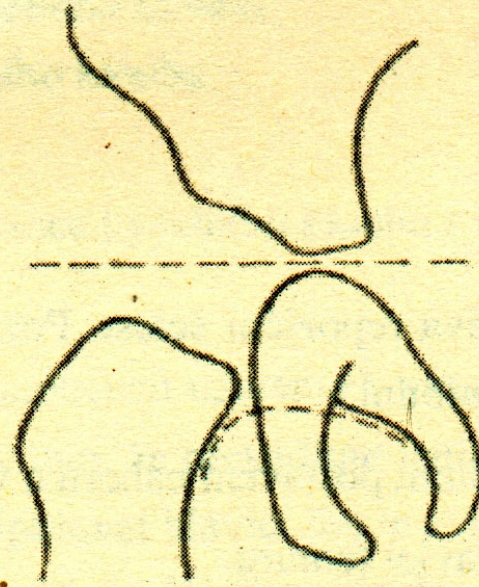
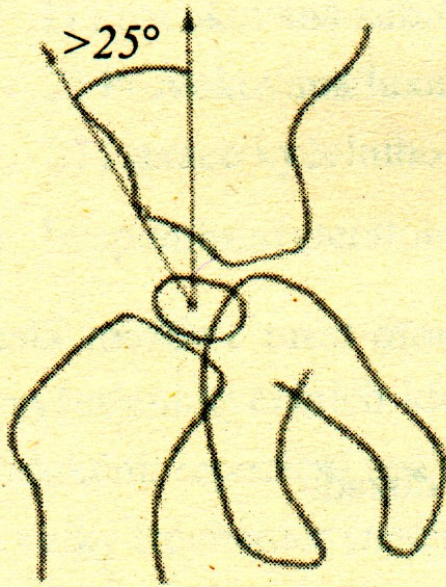
IIa,b,c,d dysplasia

IIIa,b subluxation

IV dislocation



X-ray



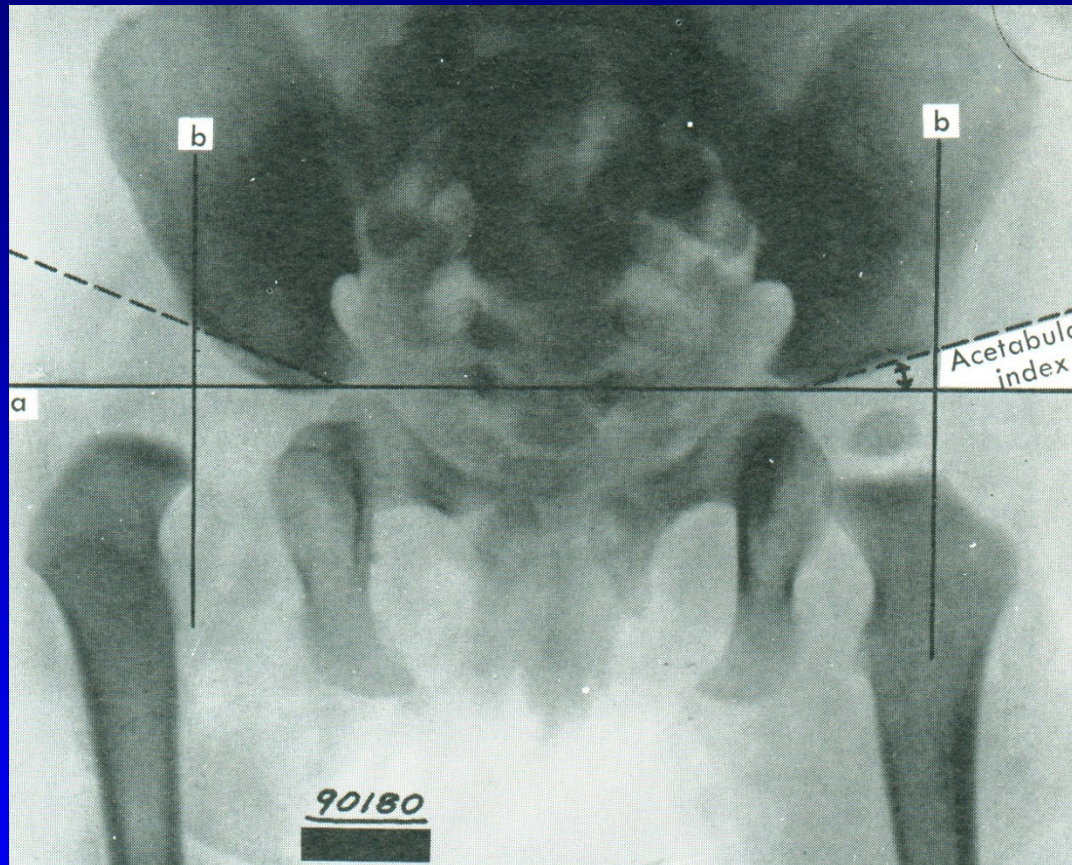
Obr. 72

Wiberg angle

Shenton line

Kopitz paralogram

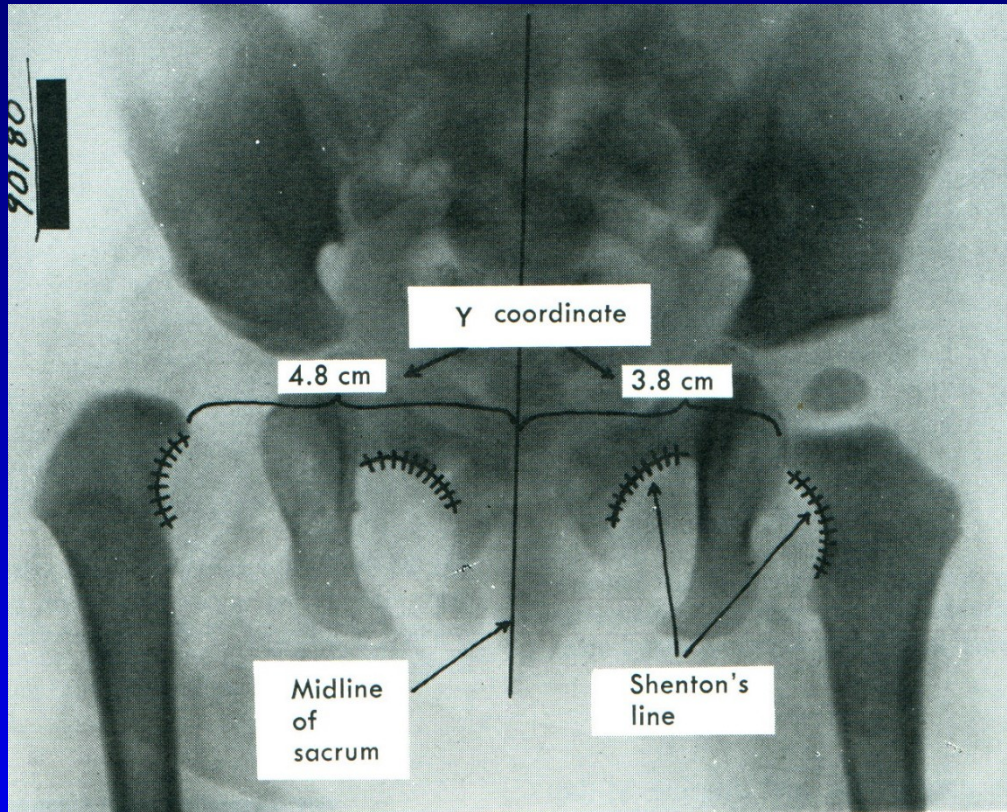
X-ray



Obr. 73

Dislocation of the right hip
Absent ossification of proximal epiphysis

X-ray



Obr. 74

Dislocation of the right hip
Femur is upwards and lateral
Shenton line is disrupted
No ossification of proximal epiphysis

Conservative management

- closed reduction

In the first month: reduction by gentle Ortolani manevuer- keep in abduction in Pavlik harness

Keep in safe zone: 90-120° flexion

50-70° abduction

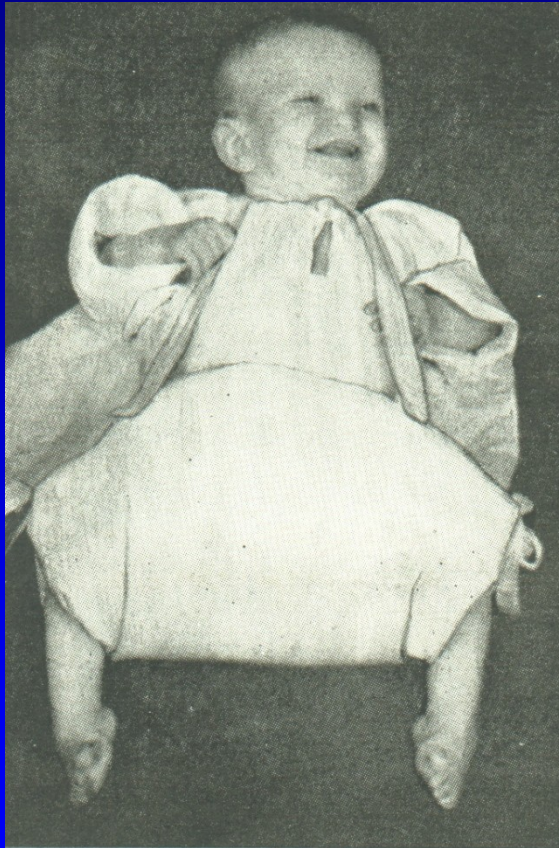Spontaneous reduction: up to 2- 3 months

- abduction positioning

- Frejka pillow

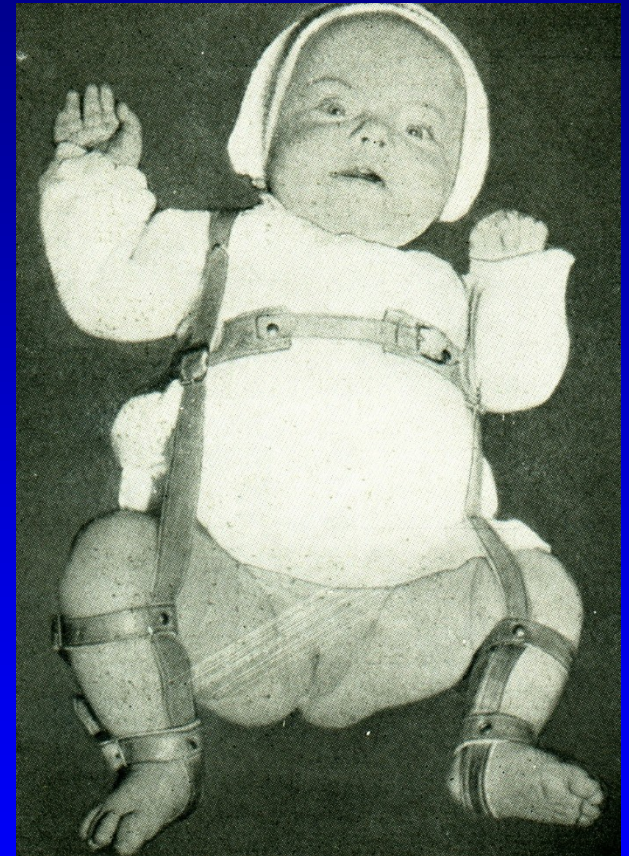- Pavlik harness

Functional treatment



Obr. 75

Frejka pillow

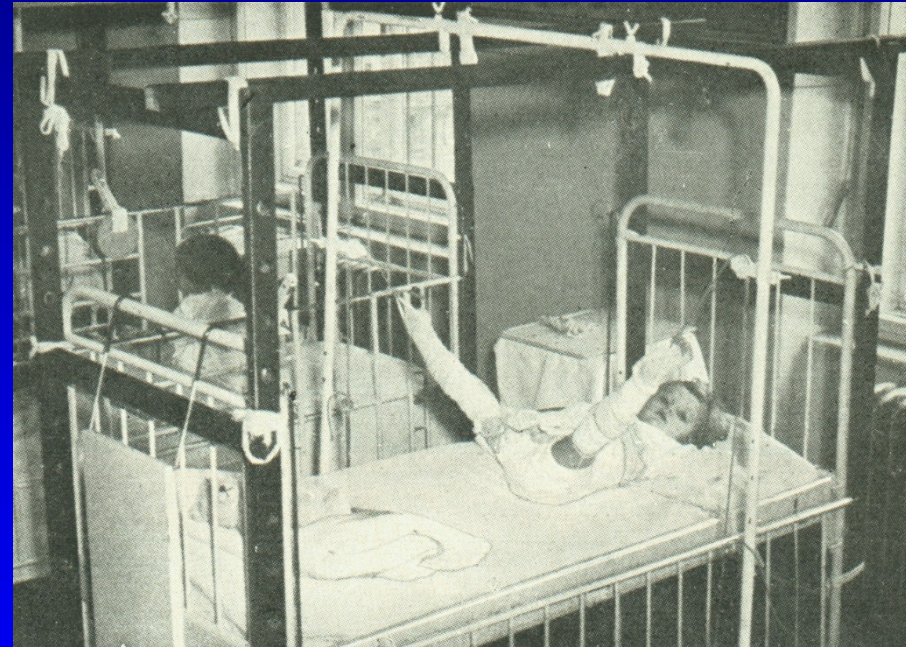


Obr. 76

Pavlik harness

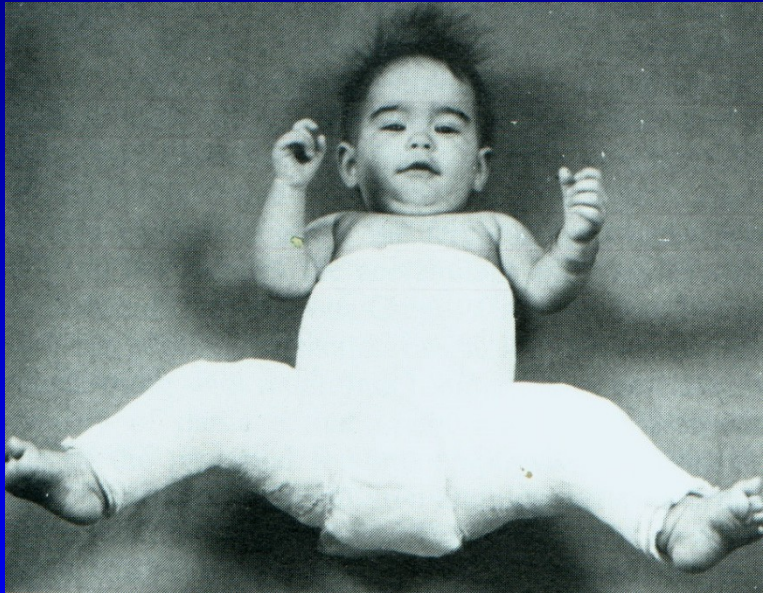
Over head traction

1. 2 weeks horizontal
2. 4 weeks in flexion of 100°
gradually increasing of abduction
up to 70°
buttock is slightly above the bed
3. Bilateral hip spica
flexion 100° , abduction 50°
for 6 weeks
4. Aftertreatment with Pavlik harness
of abduction apparatus



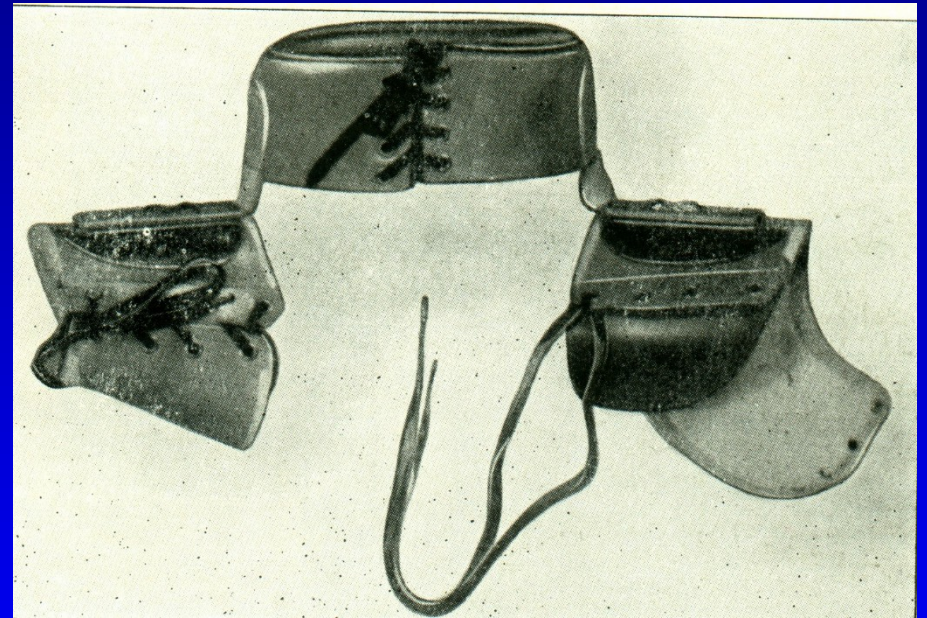
Obr. 77

Hip spica



Obr. 78

Abduction apparatus



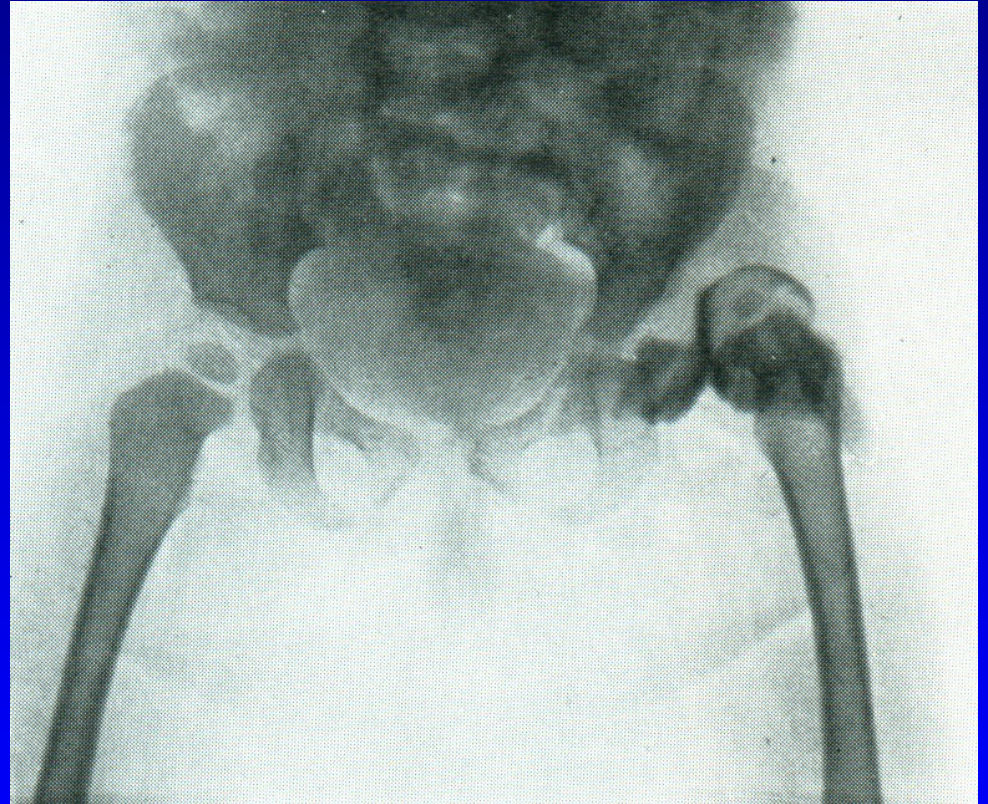Obr. 79

Arthrography or MRI

Left hip

Inverted limbus

Constriction of joint capsule

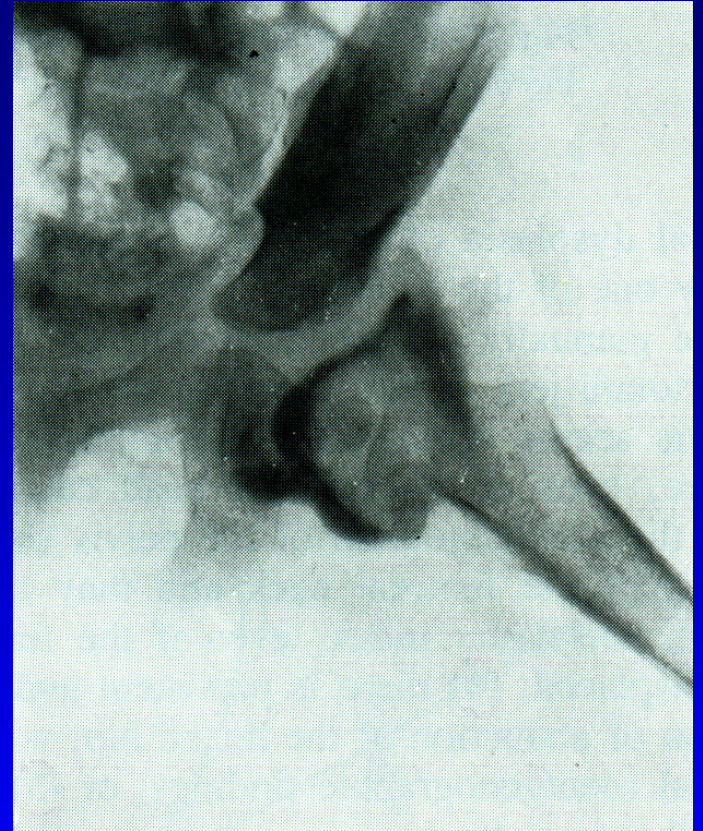


Obr. 80

Arthrography

Large inverted limbus

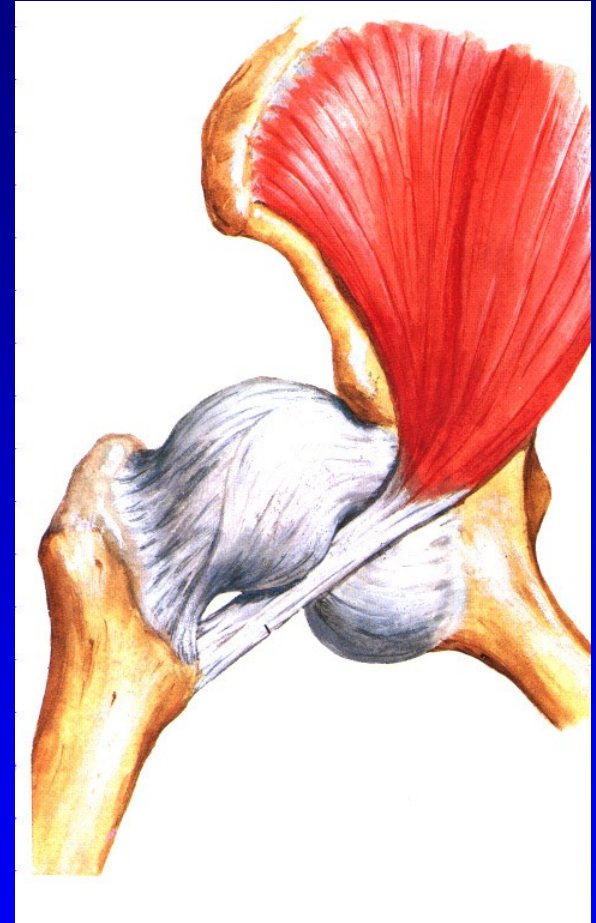
Dichotomy of femoral head



Obr. 81

Obstacles for reduction

1. Inverted limbus
2. Constriction of joint capsule
3. Hypertrophy of lig. capitis femoris
4. Iliopsoas tendon
5. Big anteversion of the femoral neck



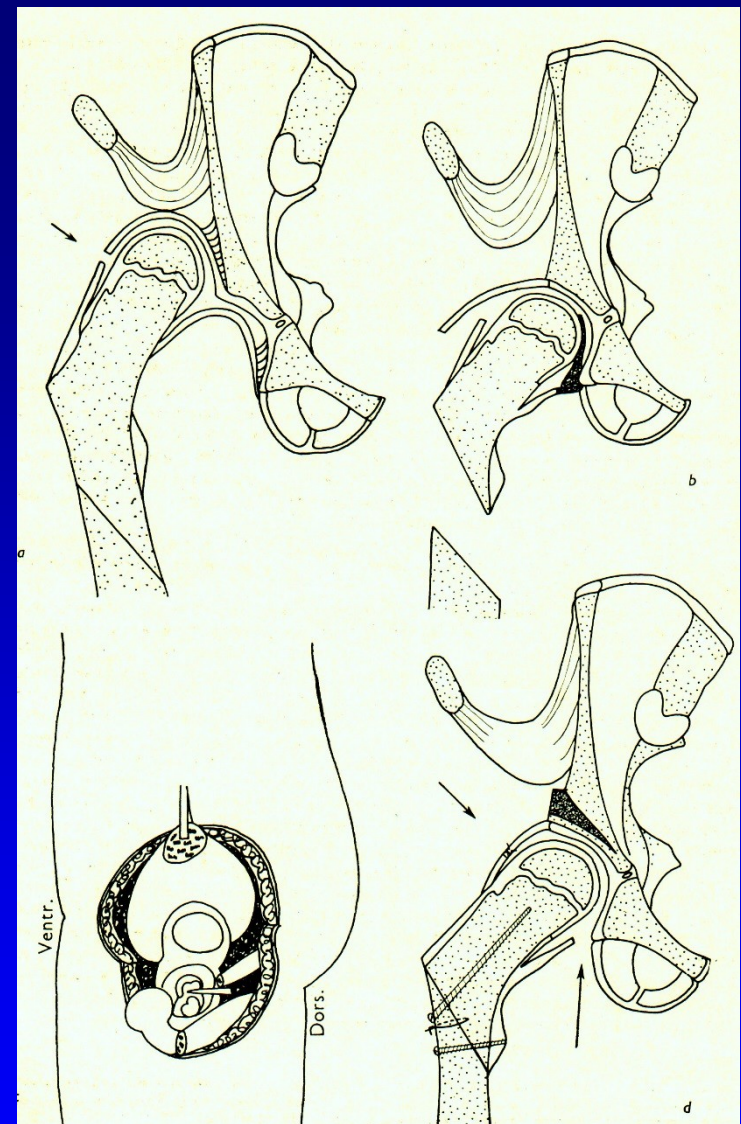
Obr. 82 Iliopsoas tendon

Operative treatment

Open reduction

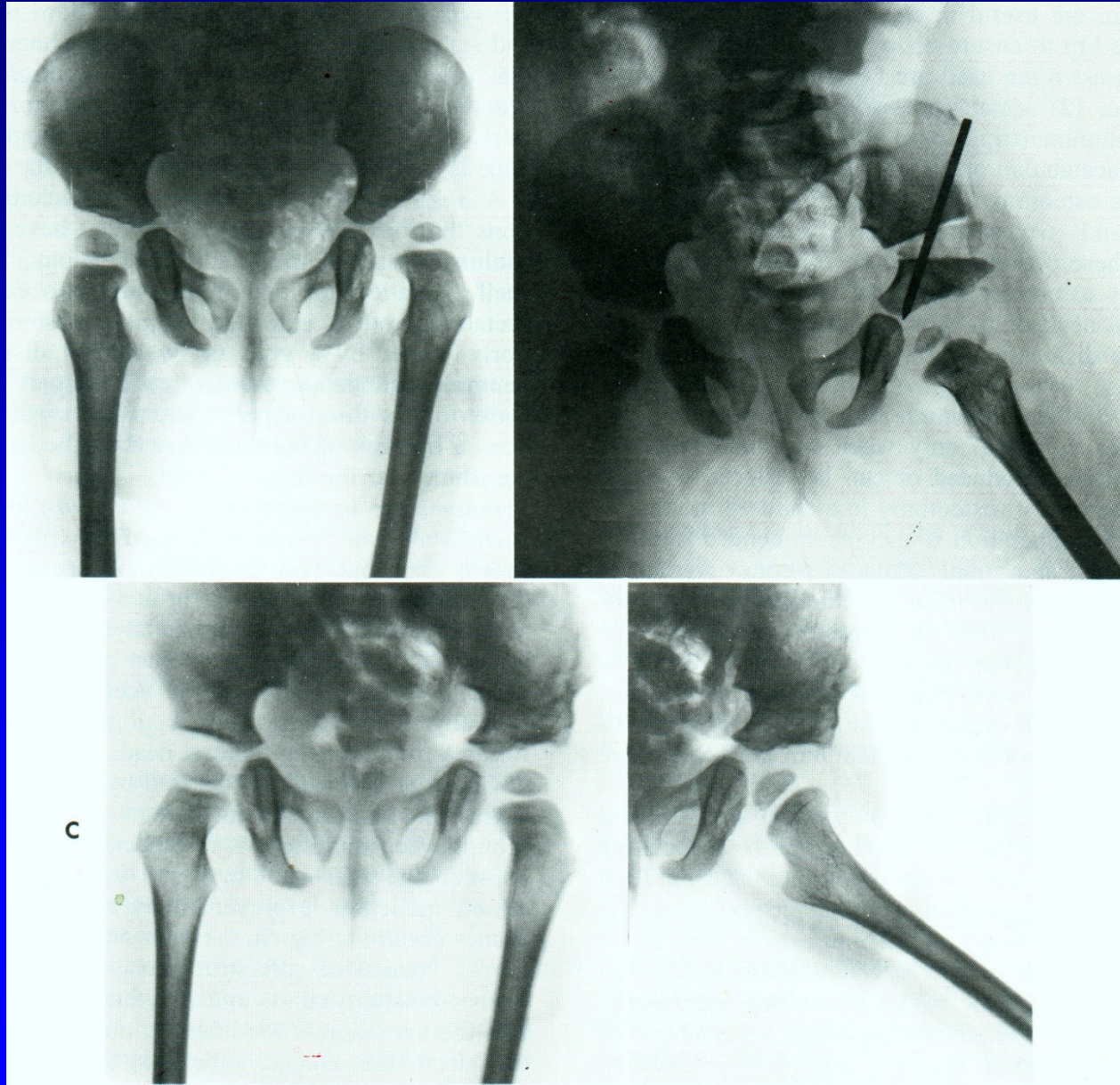
Removal of the obstacle
Shortening osteotomy of the femur
Reduction into the acetabulum
Pelvic osteotomy-
Salter, Dega, Pemberton

Osteotomy of proximal femur
- CCD angle and anteversion



Obr. 83 Open surgery- Zahradníček

Salter osteotomy



Obr. 84

Ischemic necrosis in DDH

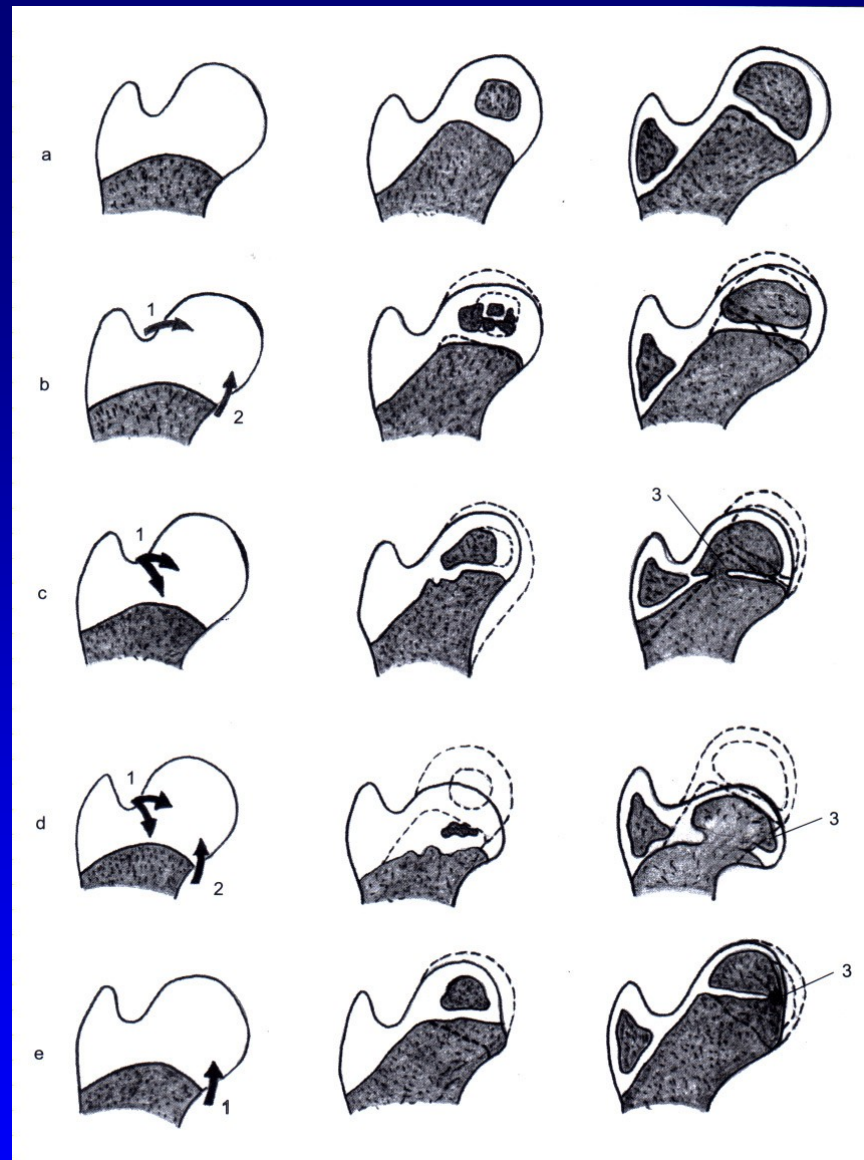
a normal

b type I slight flattening

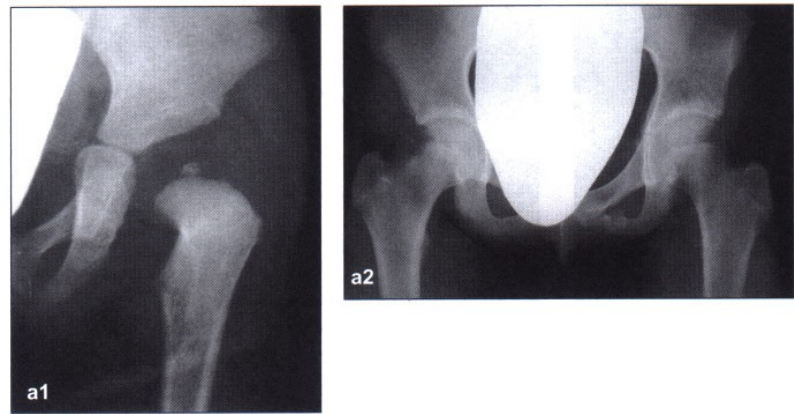
c type II valgus deformity

d type III severe flattening,
varus neck

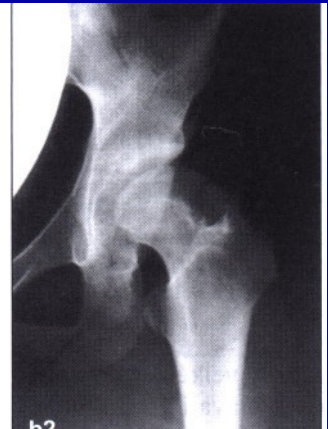
e type IV medial part of
epiphysis



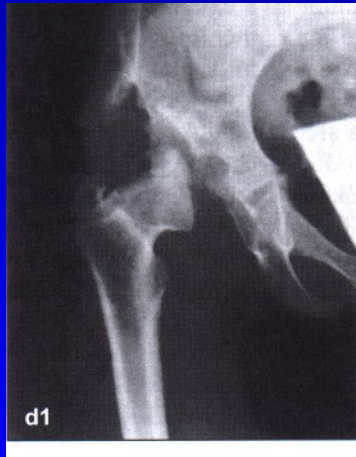Type I



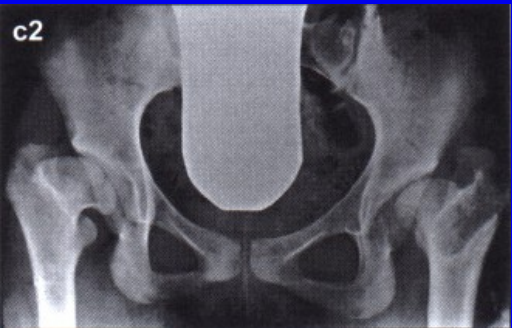Type II



Type IV.



Type III



Operative treatment

Shelf plasty

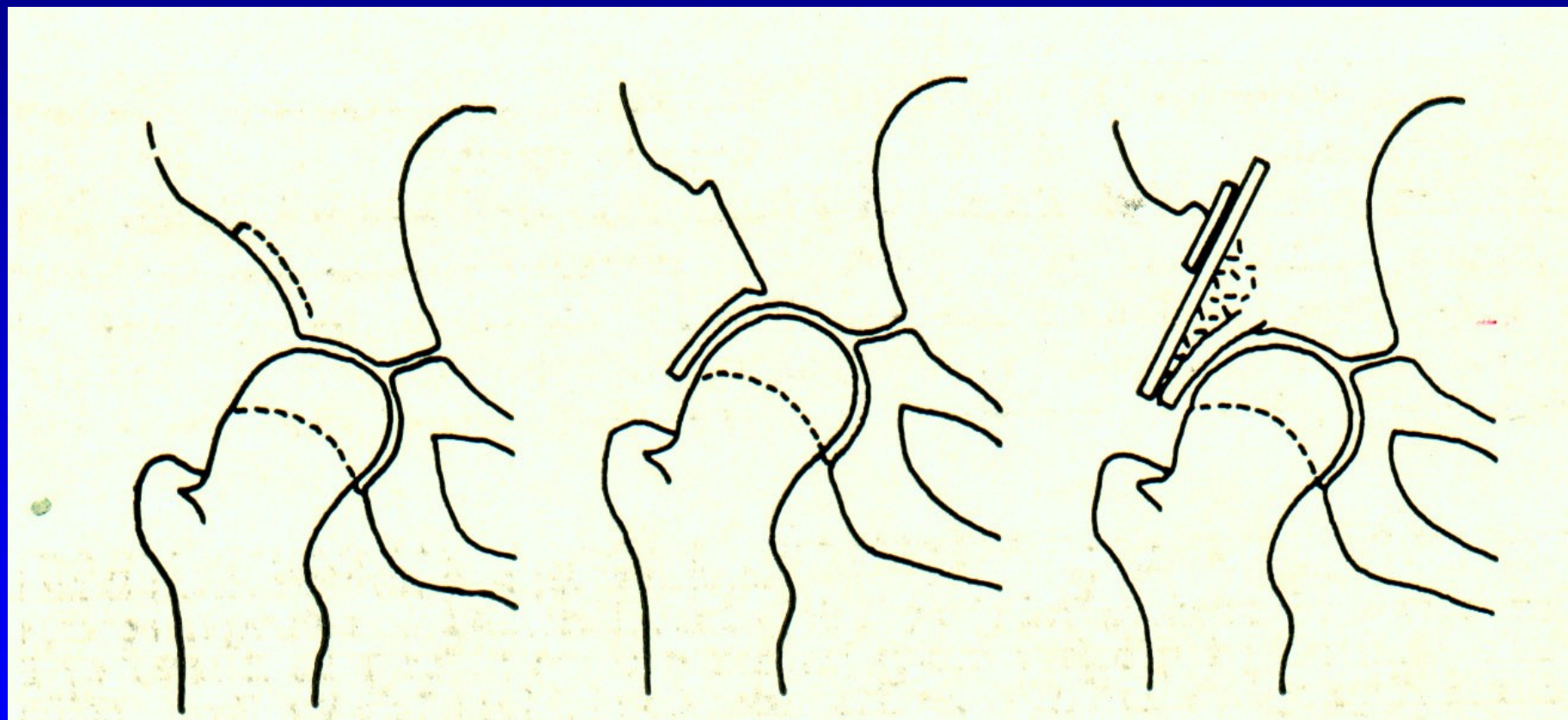
Osteotomy of the pelvis

Steel, Sutherland, Eppright, Chiari

Osteotomy of the femur

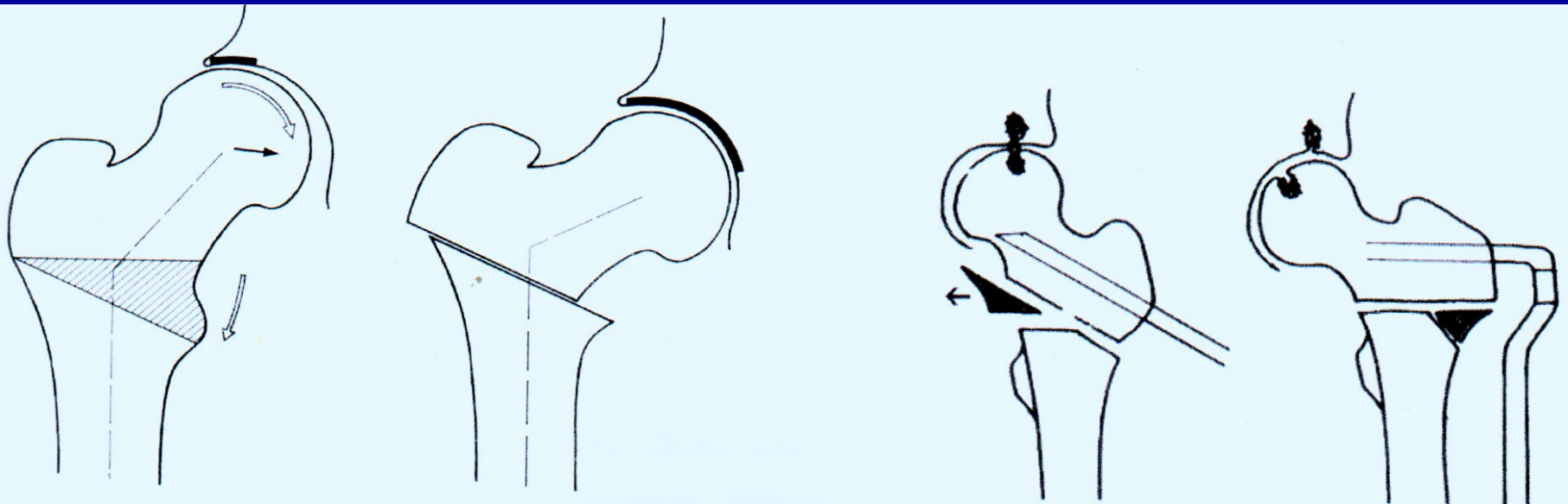
- varus
- valgus
- shortening
- derotation

Shelf plasty



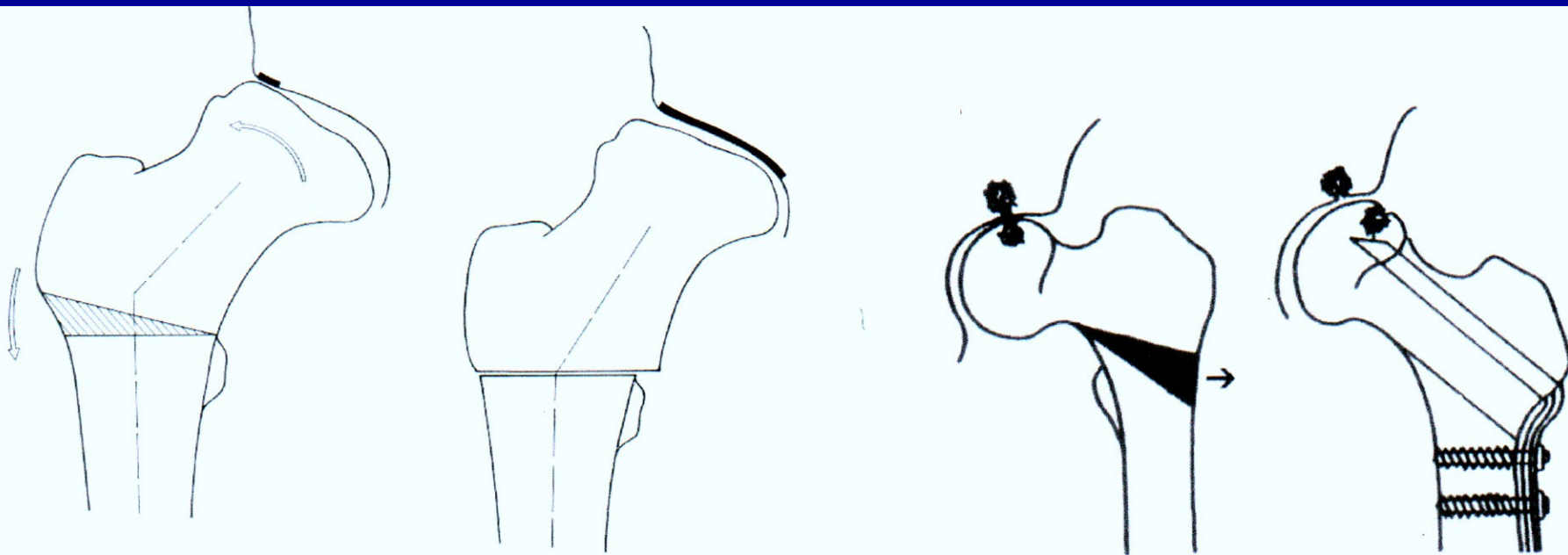
Obr. 87

Varus osteotomy



Obr. 85

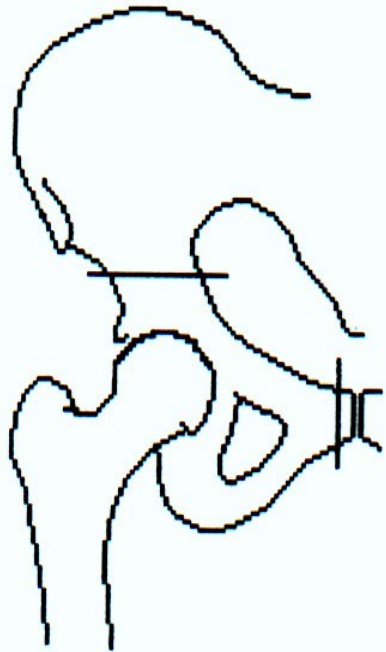
Valgus osteotomy




Obr. 86

Osteotomy of the pelvis


Sutherland



Steel

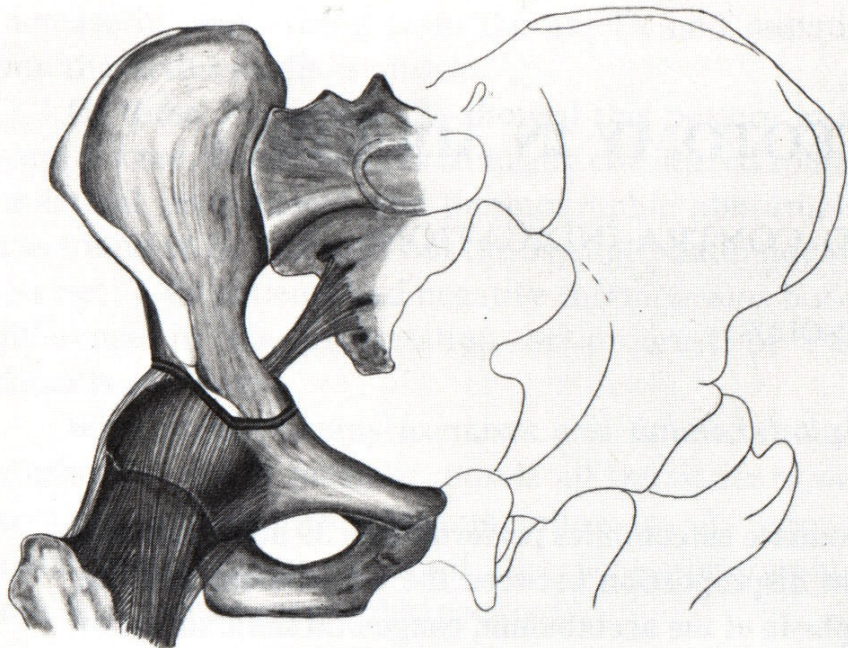


Eppright



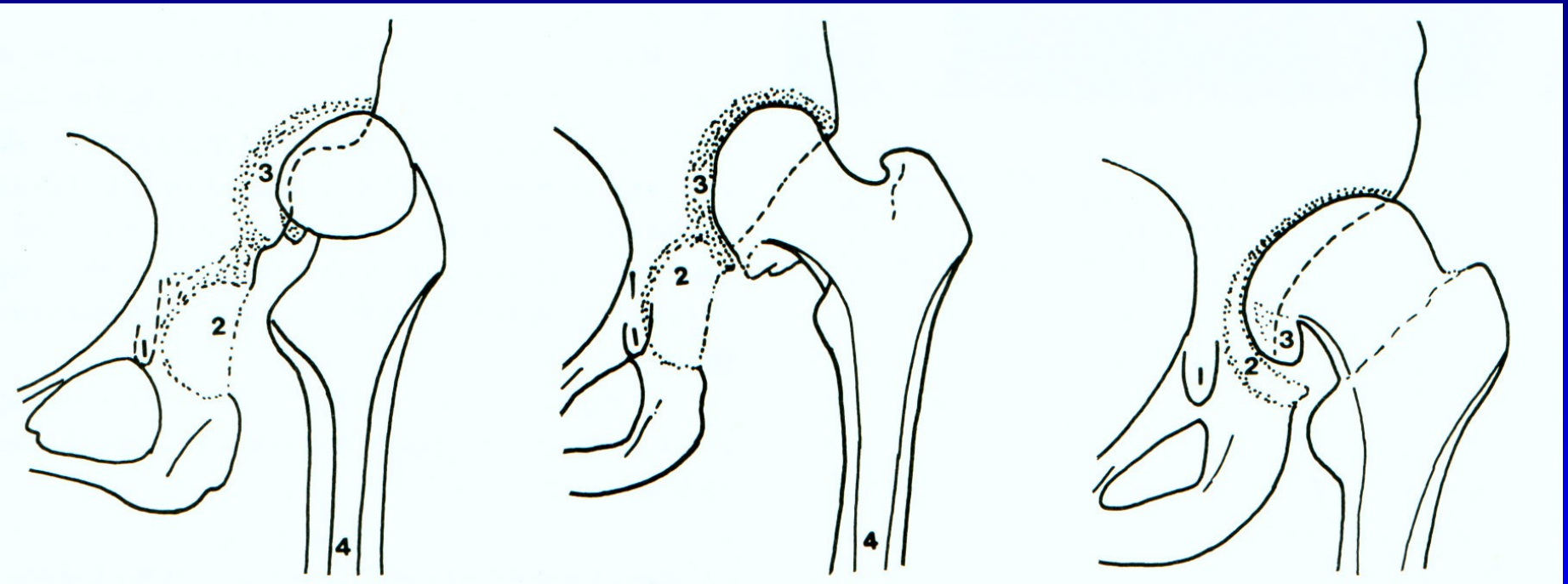
Obr. 88

Chiari osteotomy of the pelvis



Obr. 89

Consequences of DDH in adults



Obr. 65

Dislocation

Subluxation

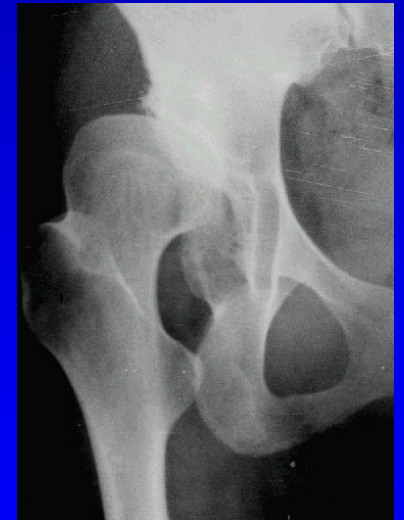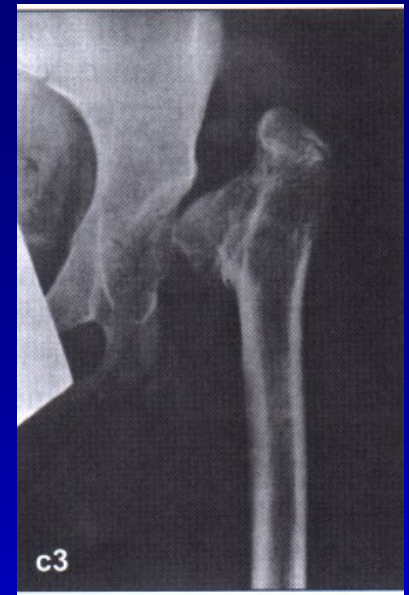Dysplasia

Consequences of DDH

Ischemic necrosis of femoral head

Residual deformity

Damage of the labrum



Consequences of DDH

Shortening of the extremity

Pain

Limited movements

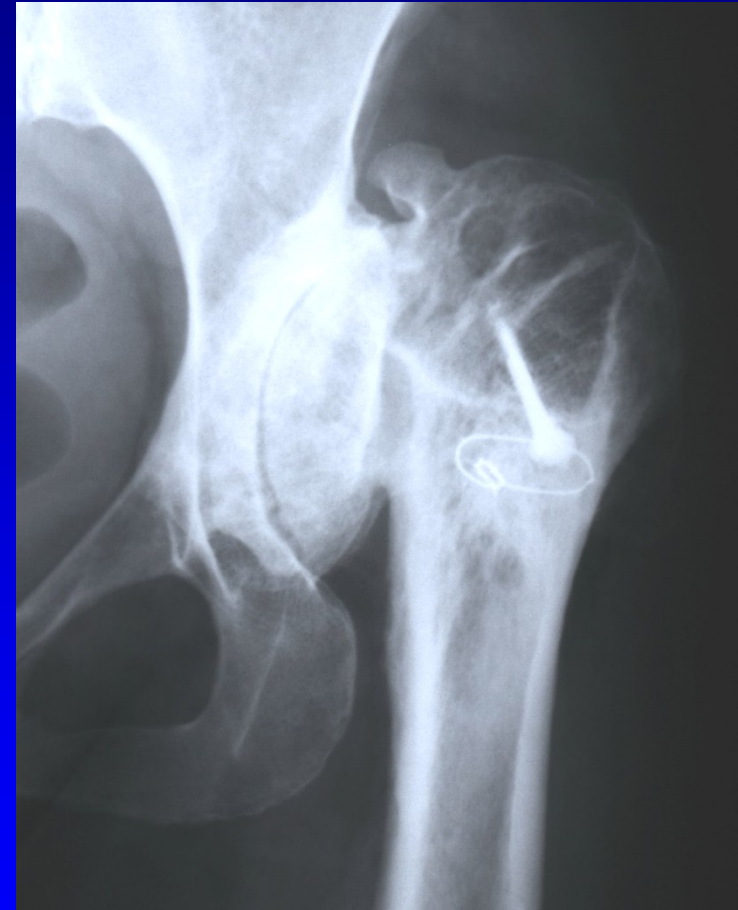Limping

Weak muscles around the hip

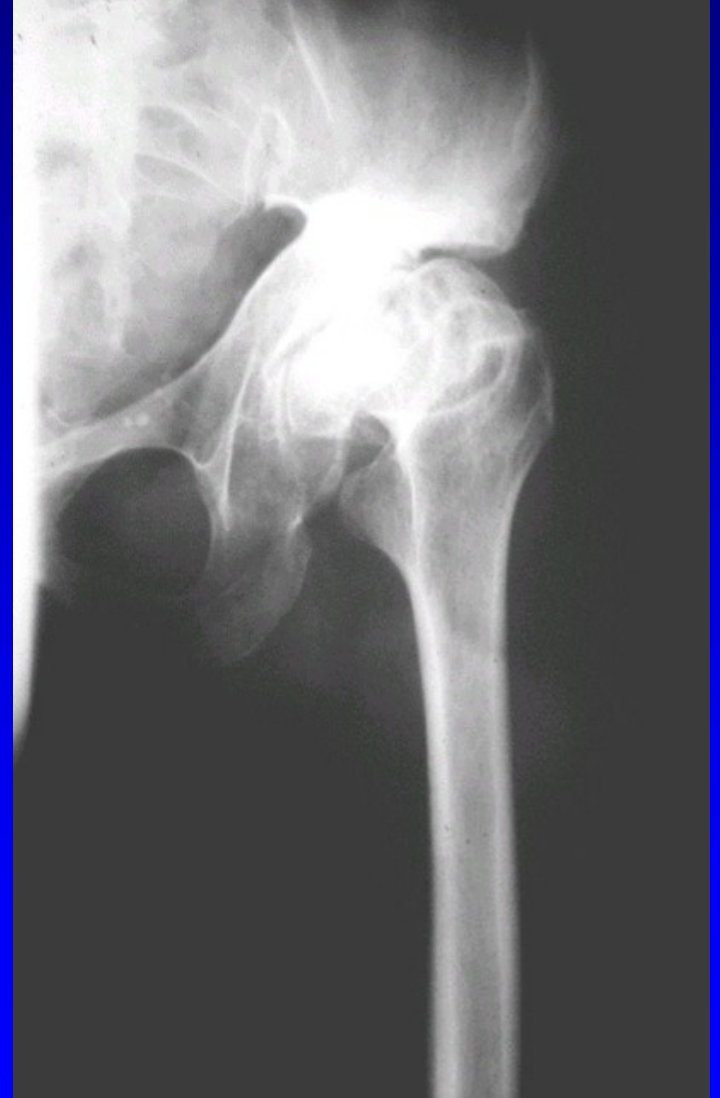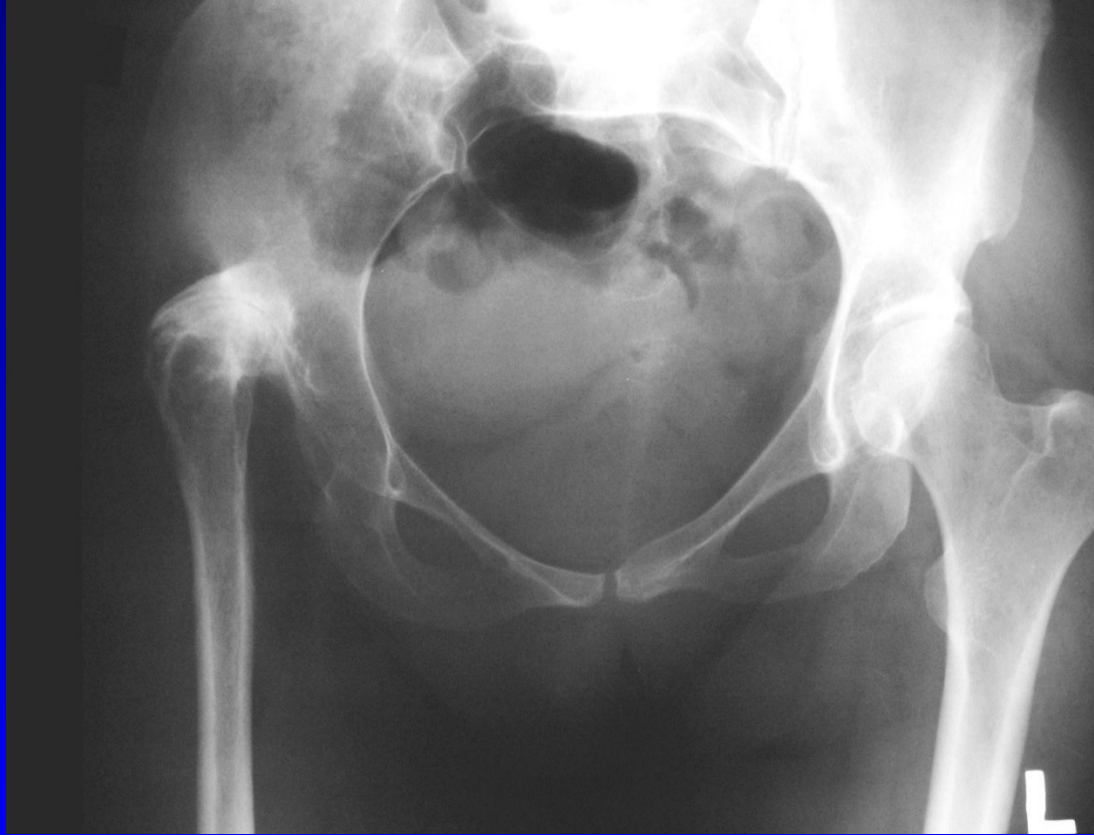Dysplastic O.A.

Dyscomfort

Walking aids



Consequences of DDH



Figures

Edmonson A.S., Crenshaw, A.H. : Campbell's Operative Orthopaedics. Sixth Edition, The C.V. Mosby Company, 1980.

Obr. 10,11,14,18,33,34,37,39,40,58,59,73,74,78,80,84.

Netter, F.: The CIBA collection of medical illustrations Vol. 8, part. I, II., Ciba- Geigy Corporation, 1990.

Obr. 20,26,28,35,36,41,42,43,44,45,46,47,48,49,50,51, 52,53,54,55,56,57,60,61,62,64,66,67,68,69,81,82.

Figures

Pauwels, F.: Atlas zur Biomechanik der gesunden und krankem Hufte. Springer Verlag, Berlin-Heidelberg-New York 1973.
Obr.85,86.

Reynolds, D.A.: Chiari innominate osteotomy in adults. Technique, indications and contraindications.
J Bone J Surg 1986;68-B:45-54.
Obr. 89.

Figures

Turek, S.: Orthopaedics. J.B. Lippincott Company,
Third Edition, 1977
Obr. 1,2,3,4,31,32.

Frejka, B.: Základy ortopedické chirurgie. Avicenum
Praha, 1970
Obr. 5,6,7,8,9,13,16,19,21,24,27,29,30,38,63,70,75,76,
77,79,83,87.

Janíček, P.: Ortopedie. Masarykova univerzita, 2001.
Obr. 72.

Figures

Hartofilakidis, G., Stamos, K. et al.: Congenital hip Disease in adults. Classifications of acetabular Deficiencies and operative treatment.
J Bone J Surg 1996; 78-A: 683- 692.
Obr. 65.