

Fractures

Z. Rozkydal

I.Orthopaedic department

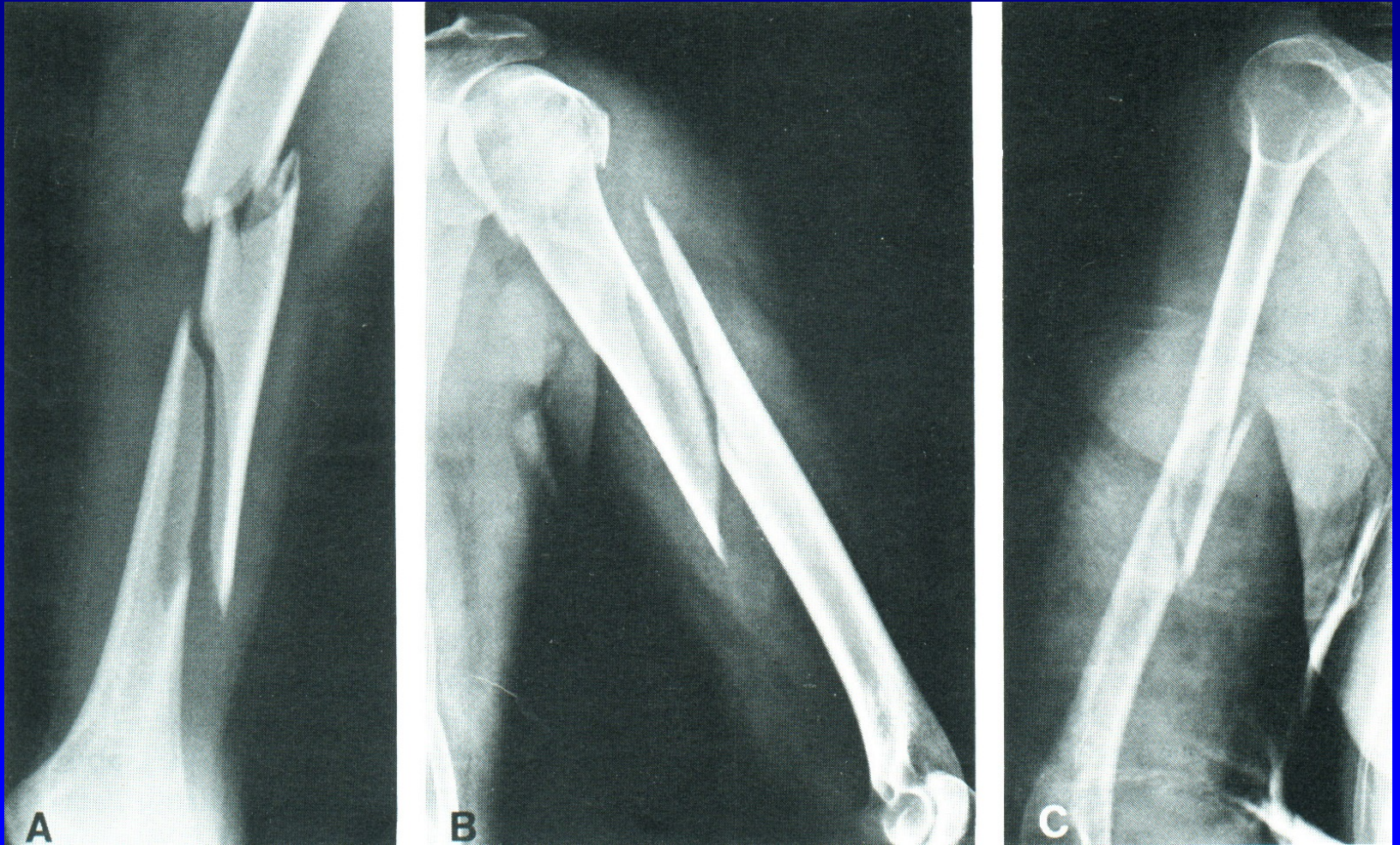
Medical faculty, Masaryk university

Brno

Fractures - etiology

- Traumatic (acute violence)
- Pathological (pathological lesion)
- Stress fractures

Traumatic fracture



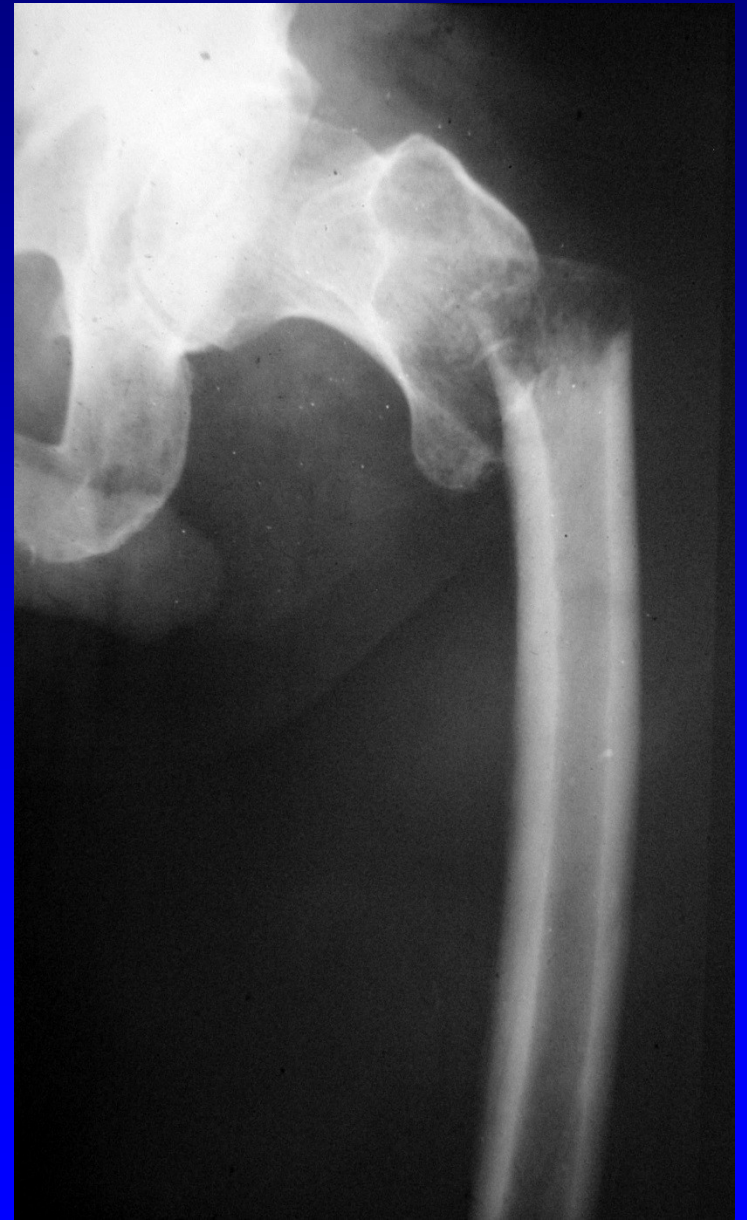Pathological fracture

Tumors

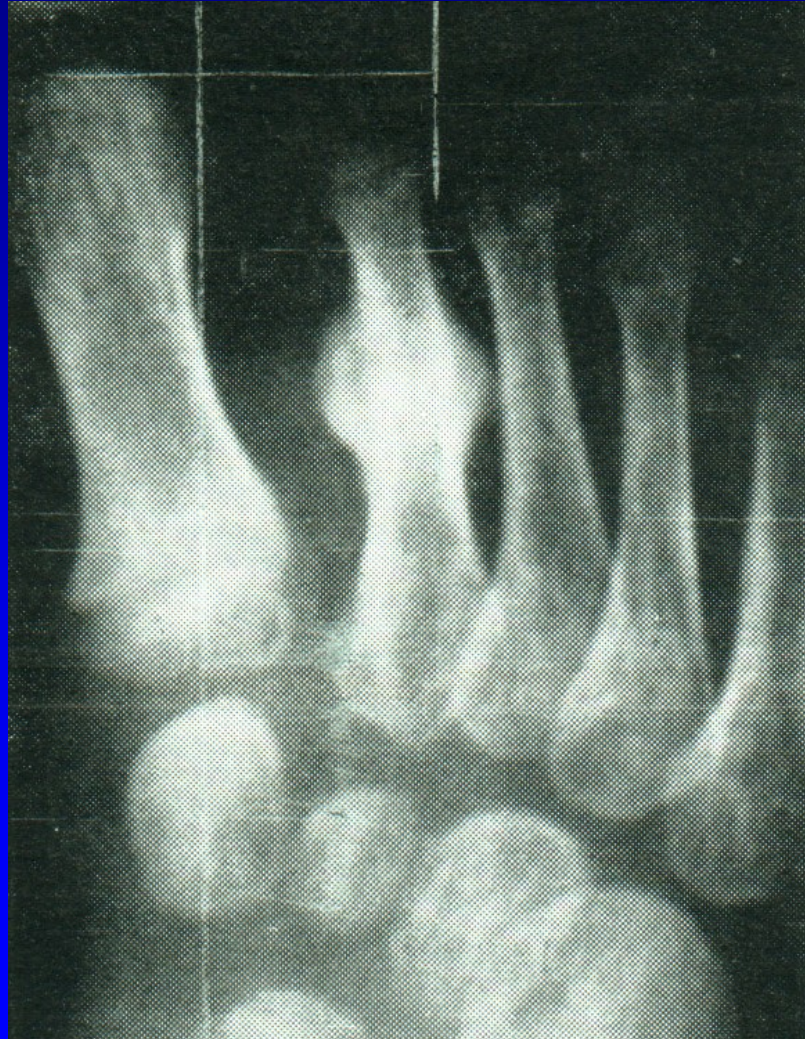Infections

Osteopatias

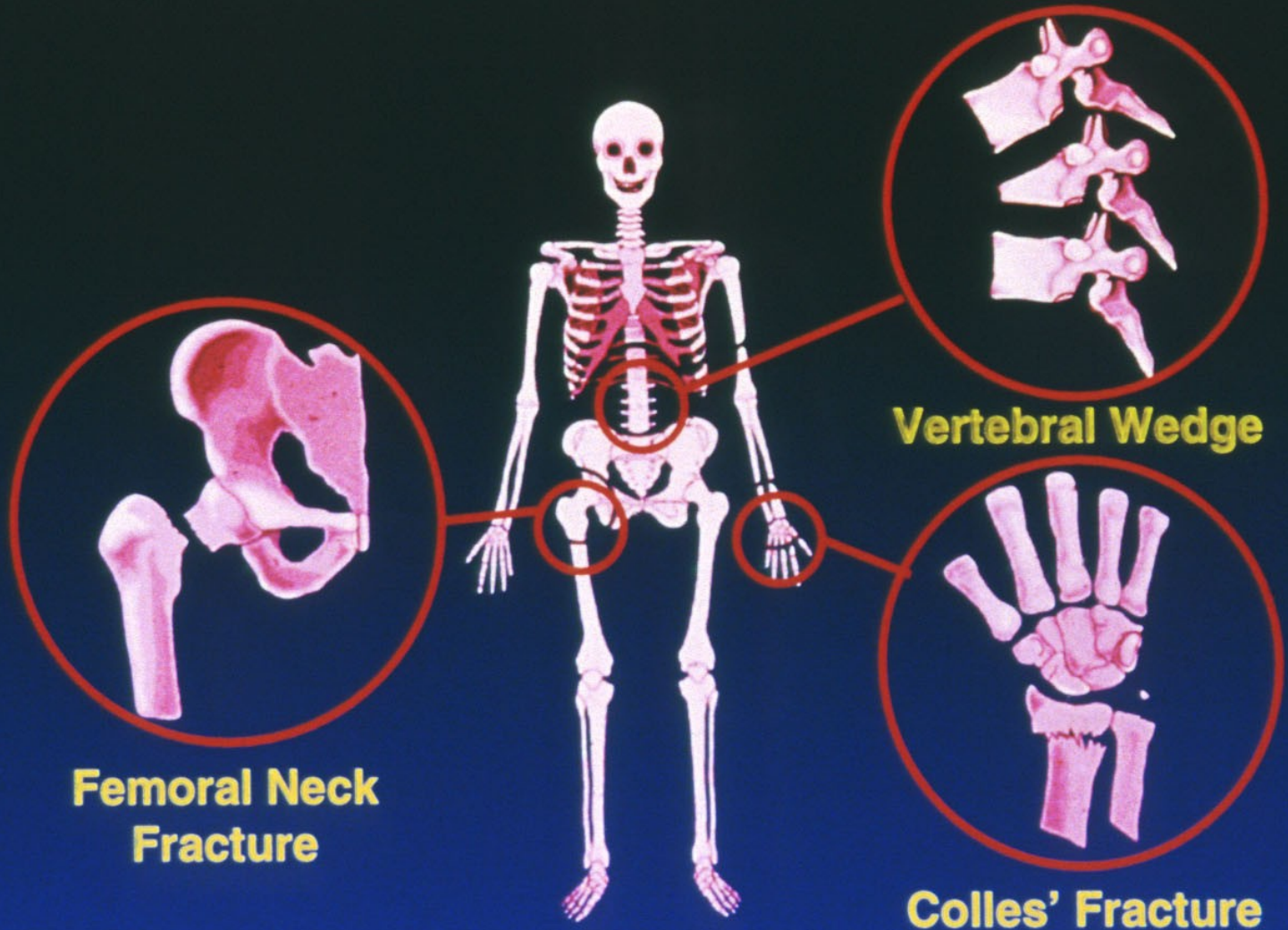
Congenital diseases



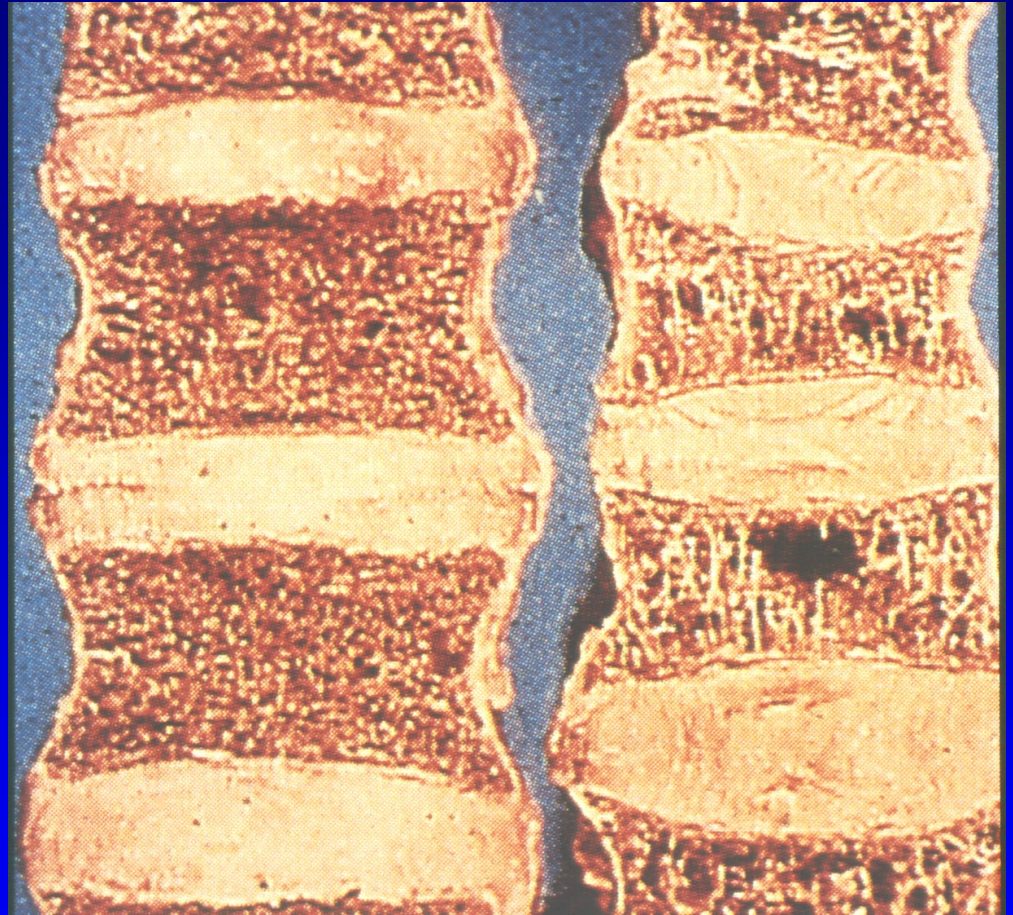
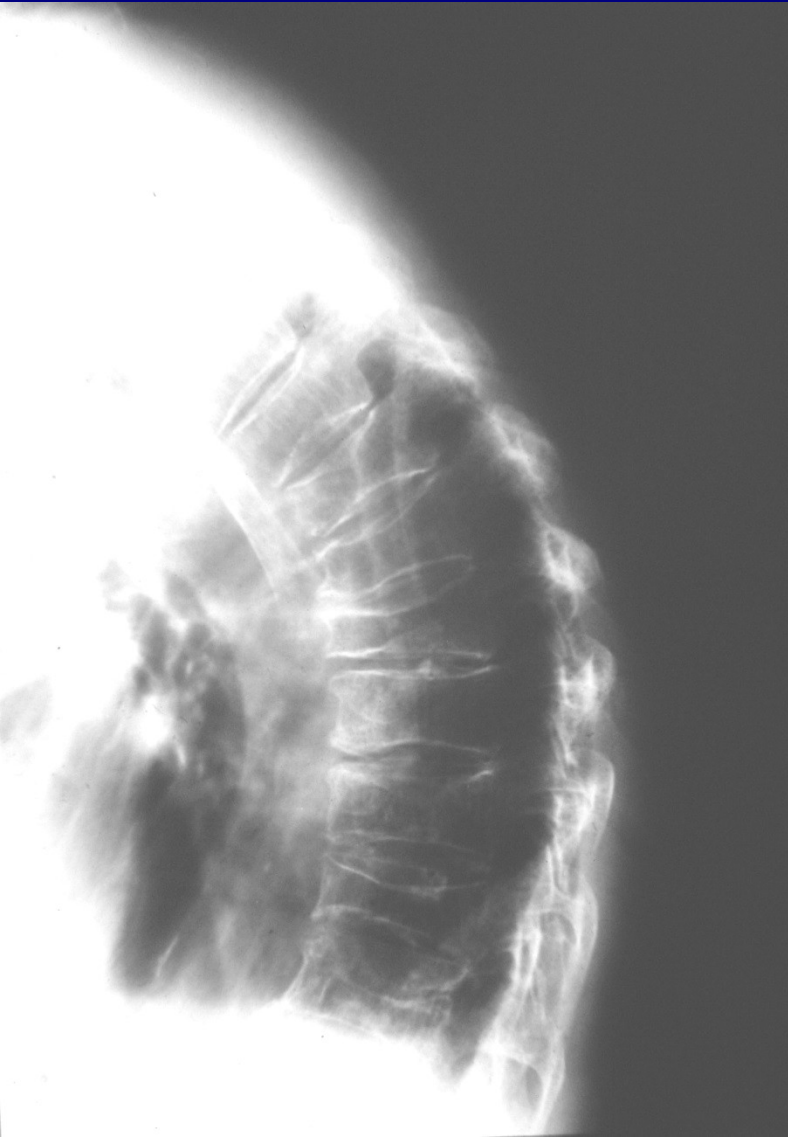
Stress fracture



THE COMMON FRACTURES OF OSTEOPOROSIS

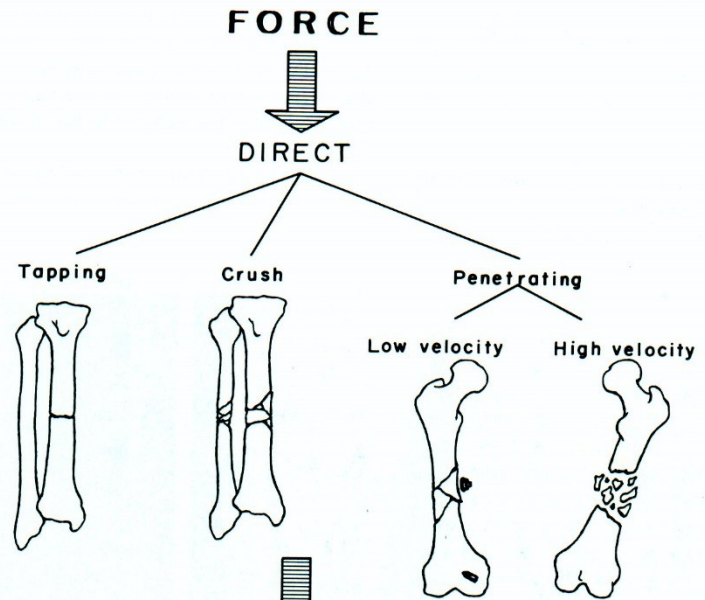


Osteoporosis of vertebrae

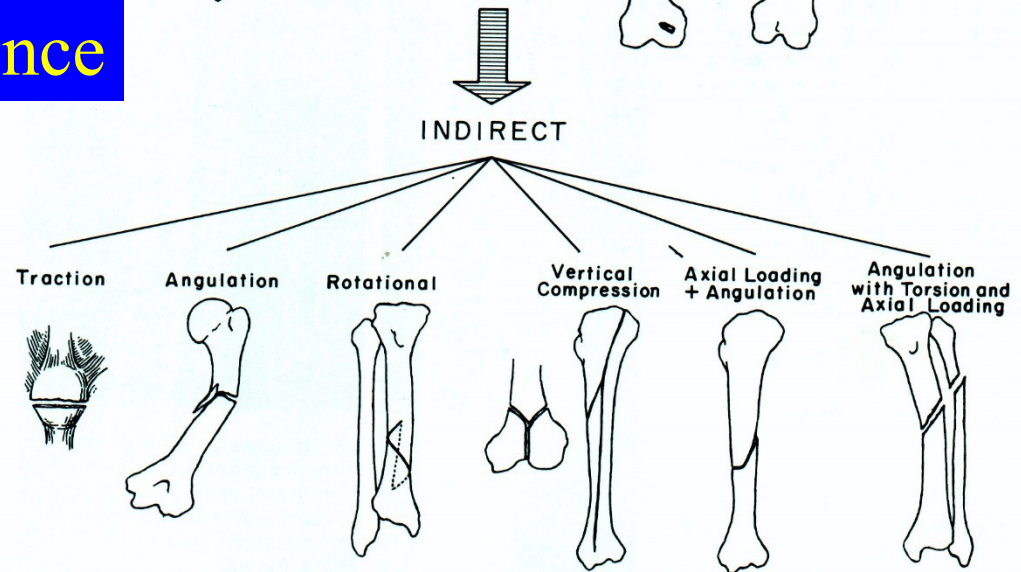


Mechanism of injury

Fractures from direct violence

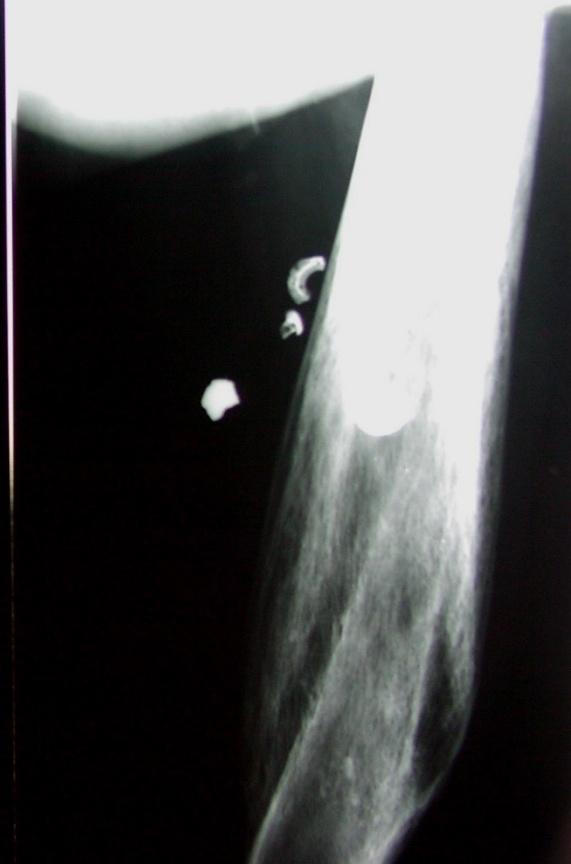
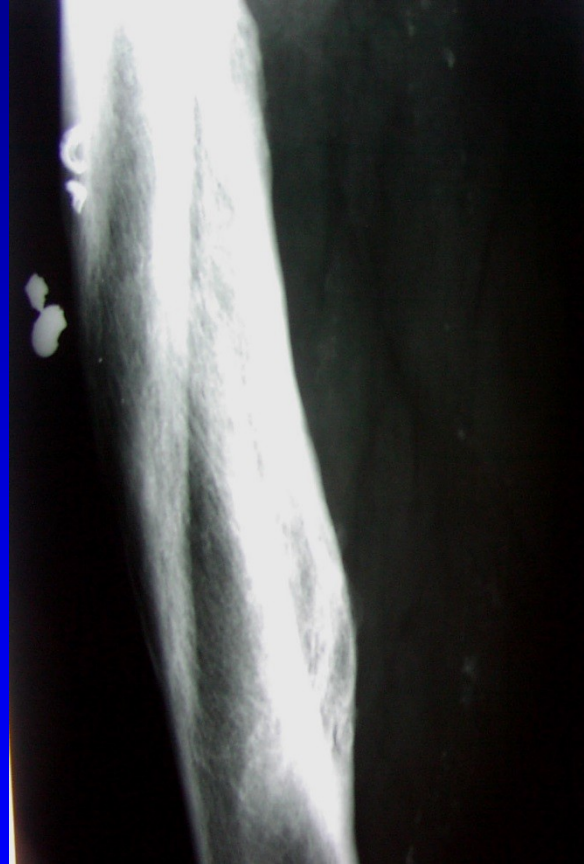
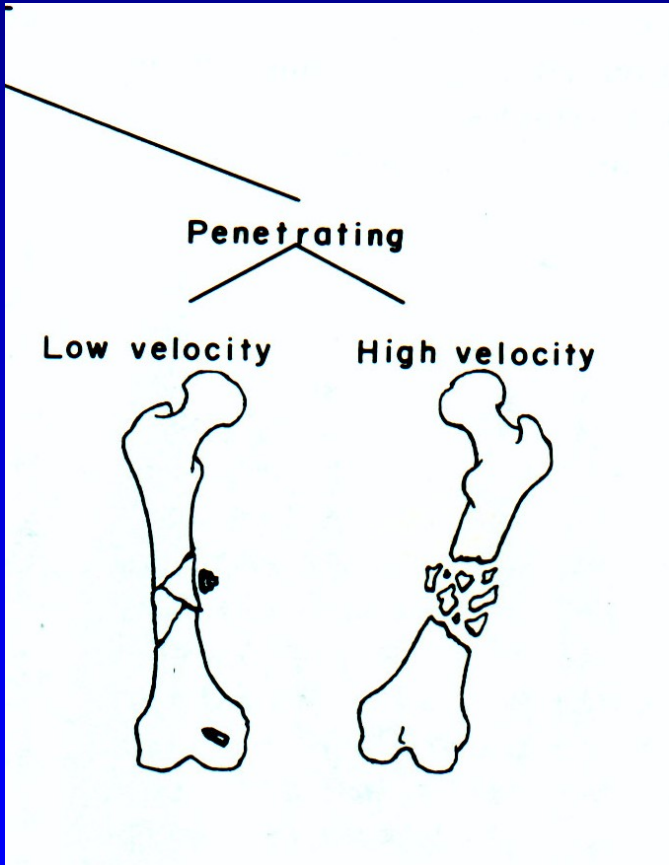


Fractures from indirect violence



- traction
- angulation
- rotation
- vertical compression
- torsion

Missile fractures

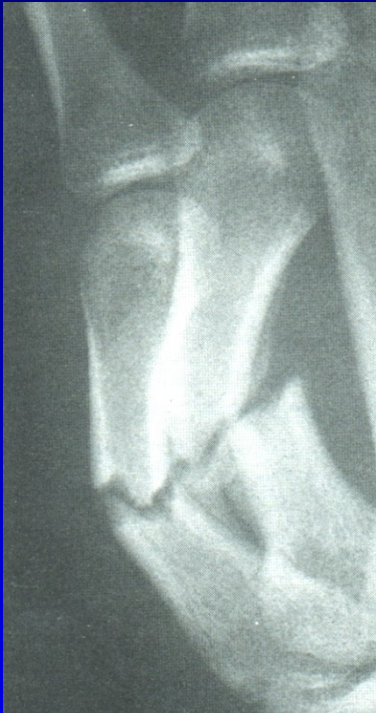

Mechanism of injury

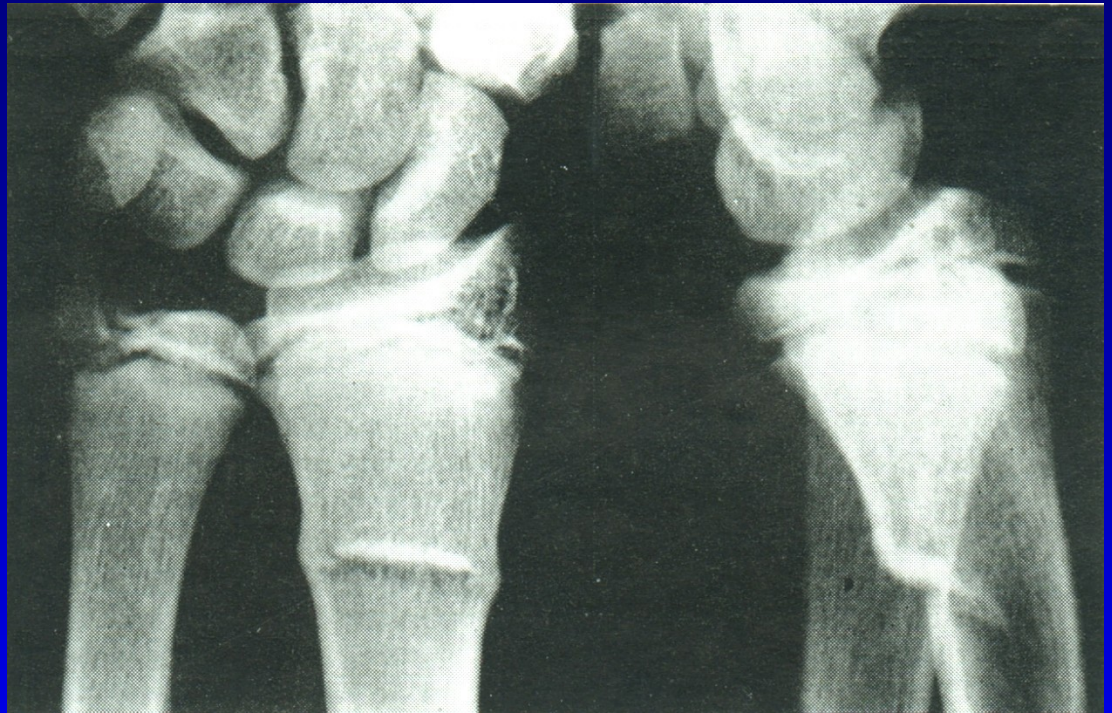High energy trauma – large lesion of soft tissue

Low energy trauma - small lesion of soft tissue

Classification of fractures



Complete




Incomplete:

- fissures
- infractions
- impressions
- subperiosteal

Localisation of fractures

- Epiphyseal
- Metaphyseal
- Diaphyseal

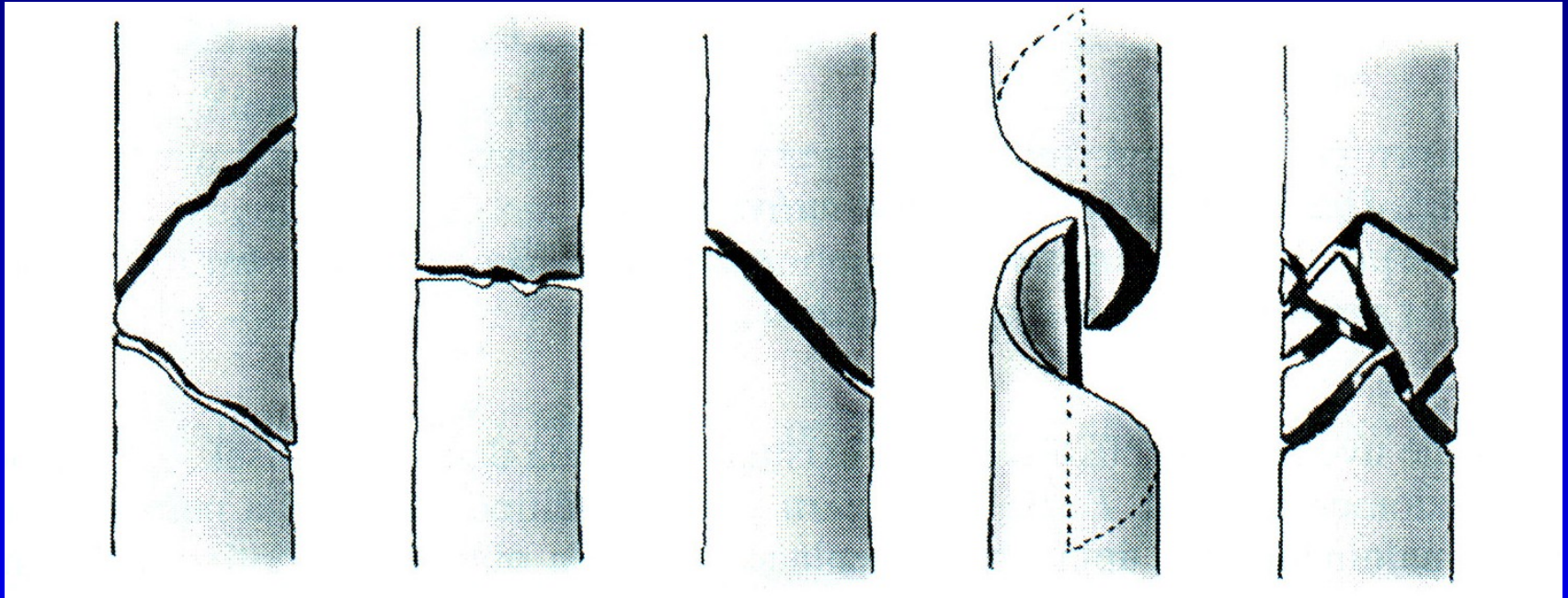


epiphysis
metaphysis

diaphysis

metaphysis
epiphysis

Fracture lines



interfragment

transverse

oblique

spiral

comminution

Dislocation

Dislocatio ad axim


Dislocatio ad latus

Dislocatio ad longitudinem cum contractione

Impactio

Dislocatio ad longitudinem cum distractione

Dislocatio ad peripheriam



Clinical symptoms of fractures

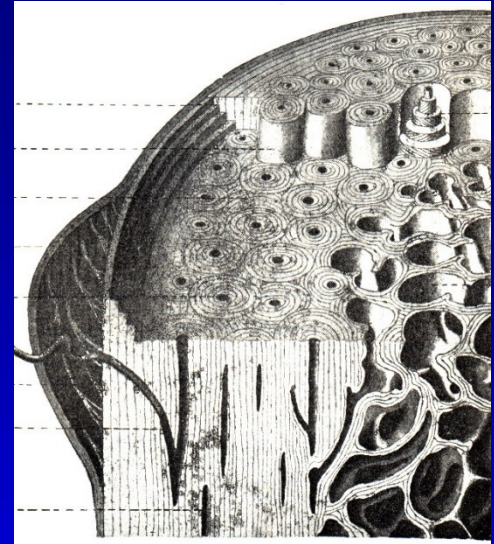
- Pain and tenderness
- Swelling, haematoma
- Impaired function
- Deformity
- Crepitation
- Pathological movements

Healing of fractures

Osteoblasts:

Cambian layer of periosteum and
endosteum

Trabeculae in metaphyseal
and epiphyseal region

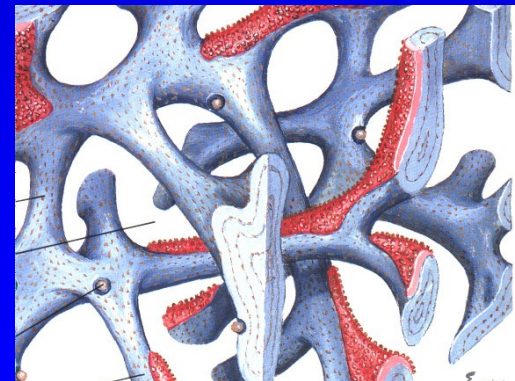


Osteoprogenitor cells:

reticular, perivascular cells, monocytes

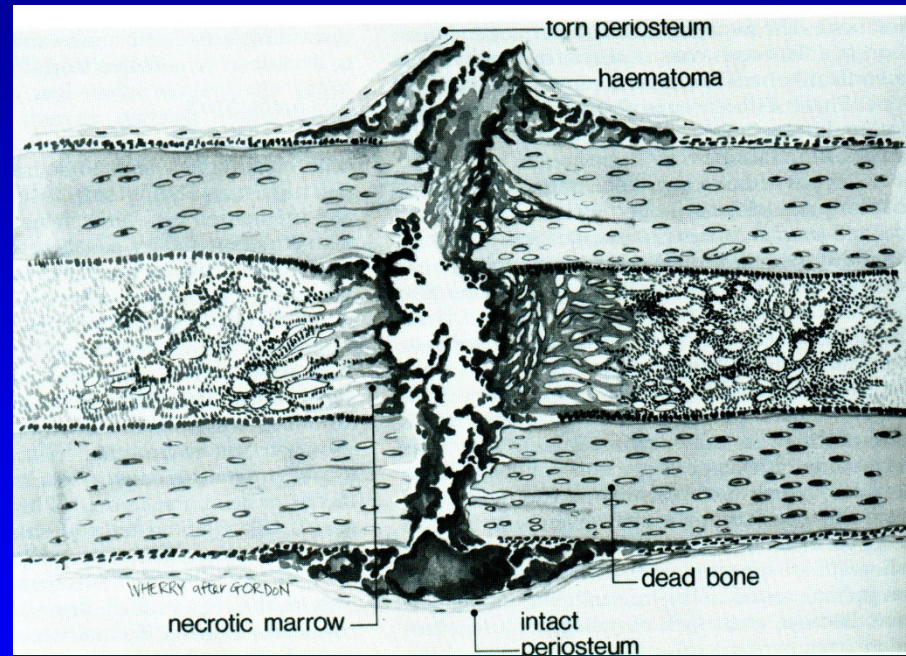
Diaphysis – longer period of healing

Epi and metaphysis – shorter period
of healing



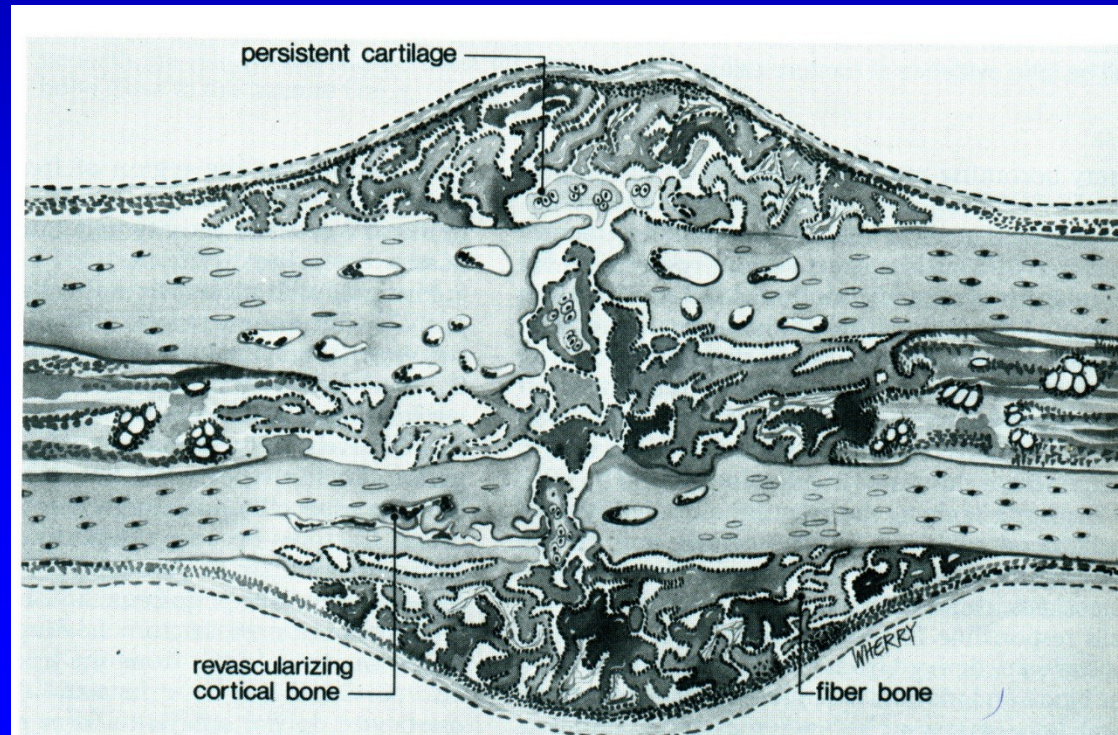
Secondary healing

1. Haematoma
2. Granulation tissue
3. Osteoid (since 5. day)
4. Primary callus formation
 - primary woven bone
 - fibrous tissue,
 - cartilage tissue
 - mineral layers after 6 days



Secondary healing

5. Secondary callus formation
 - woven bone is replaced by cortical and trabecular bone
6. Remodelation of callus



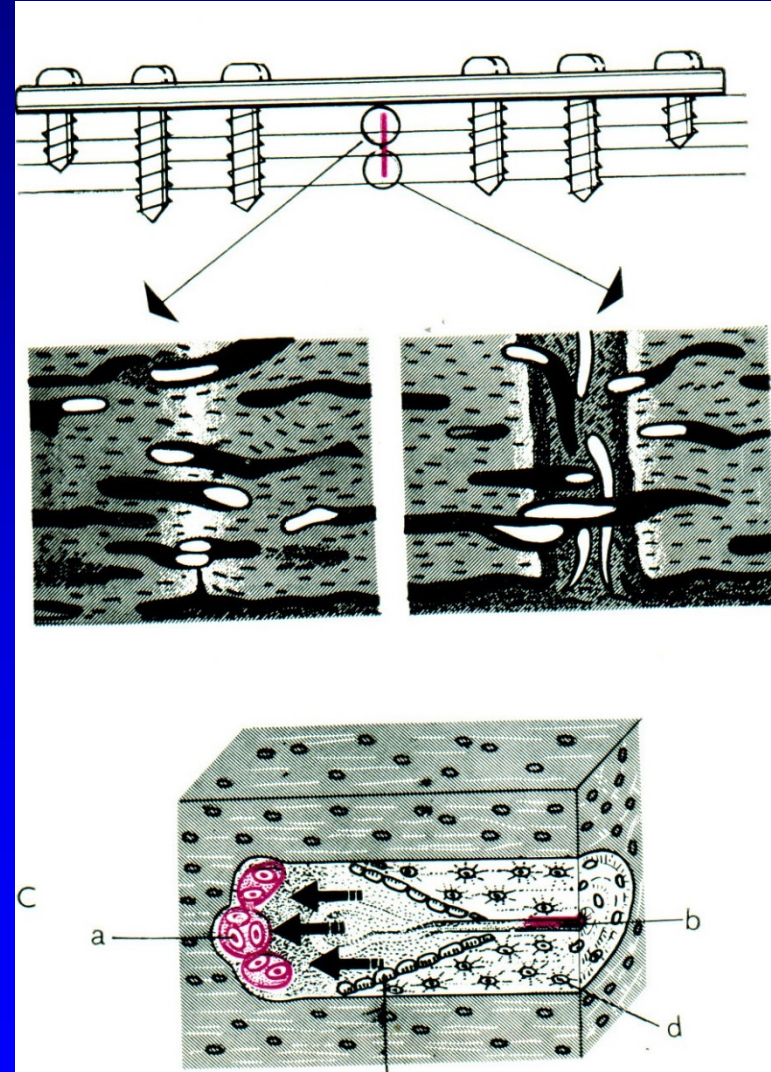
Primary healing

Prerequisite: stable fixation
It is intercortical healing
without callus formation

1. Contact

2. Gap

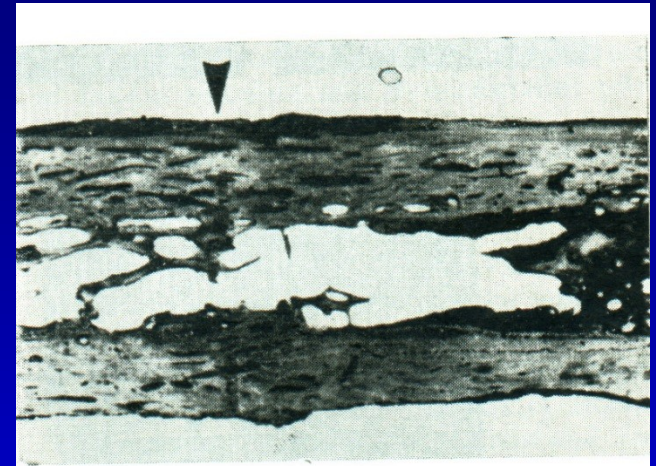
Osteon: osteoclasts, vessels,
osteoblasts



Primary healing

Functional unit: **Osteon**

Speed of osteons: 0,1 mm/day



5. Makropreparát osteotomie radia psa fixovaní kompresní dlahou (stav po 6 týdnech). Je vytvořen minimální periostální a endostální svalek



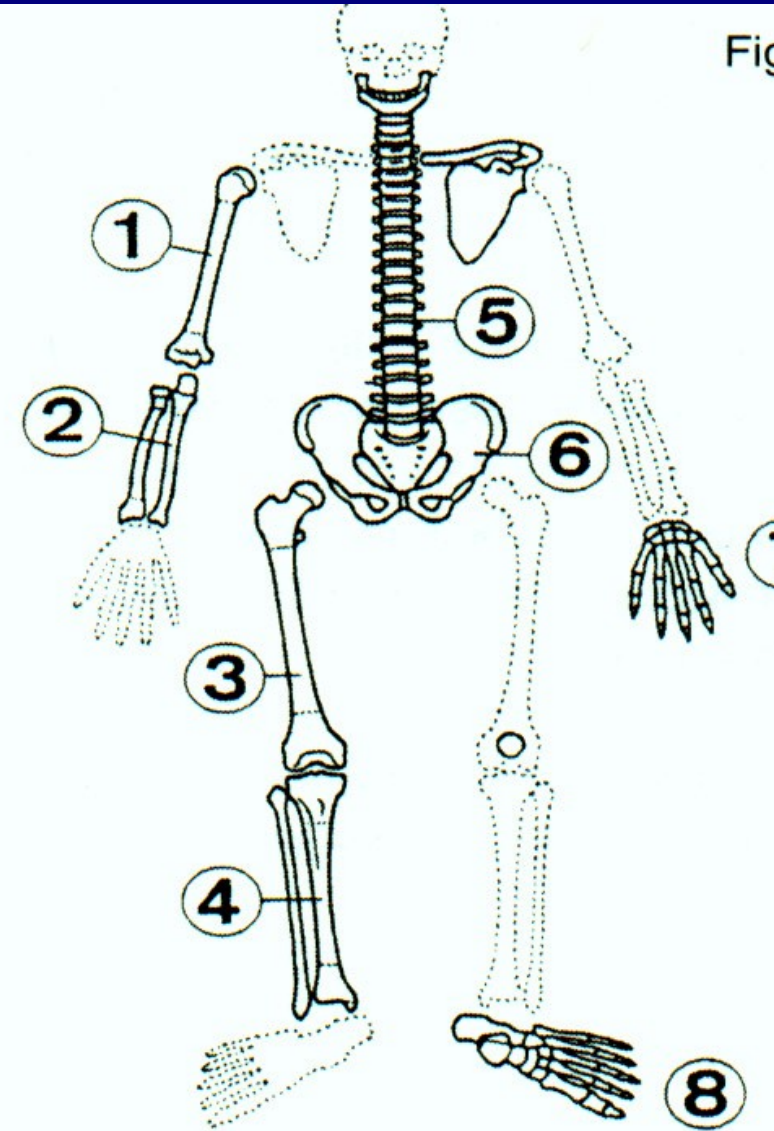
AO classification

Davos, 1958.

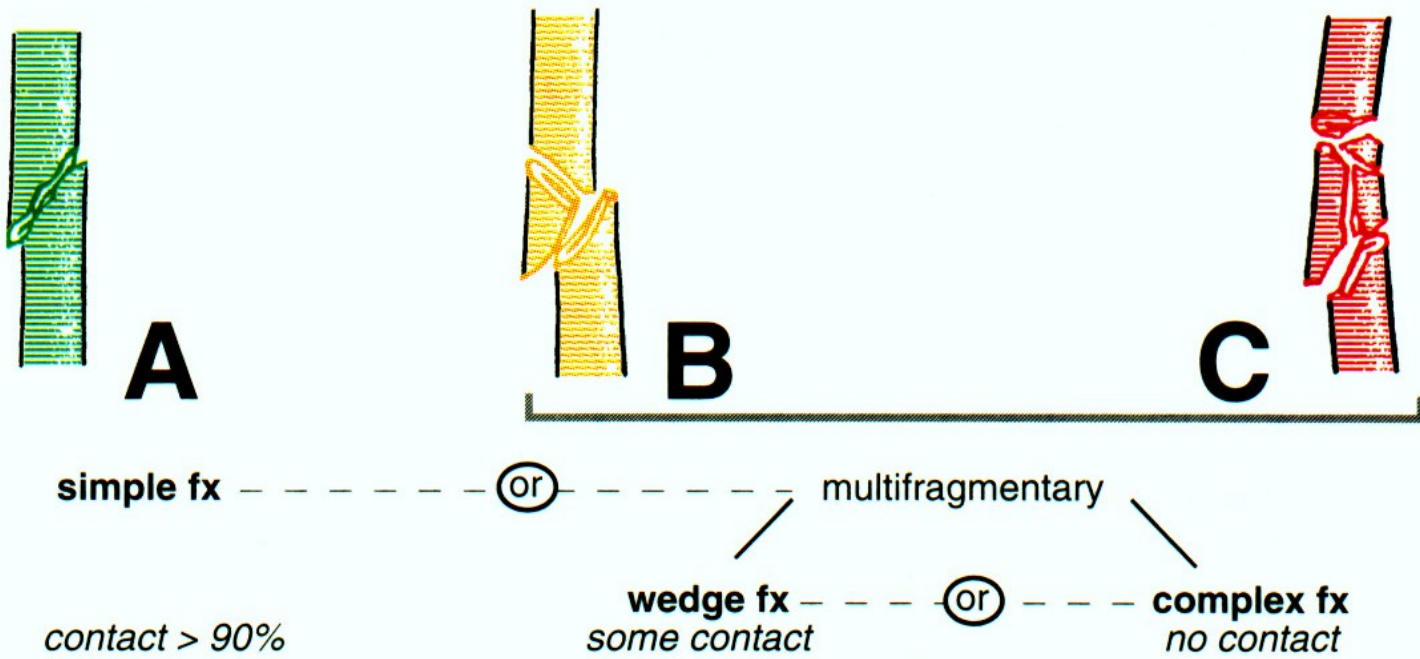
E. Müller

M. Allgöwer

H. Willenegger



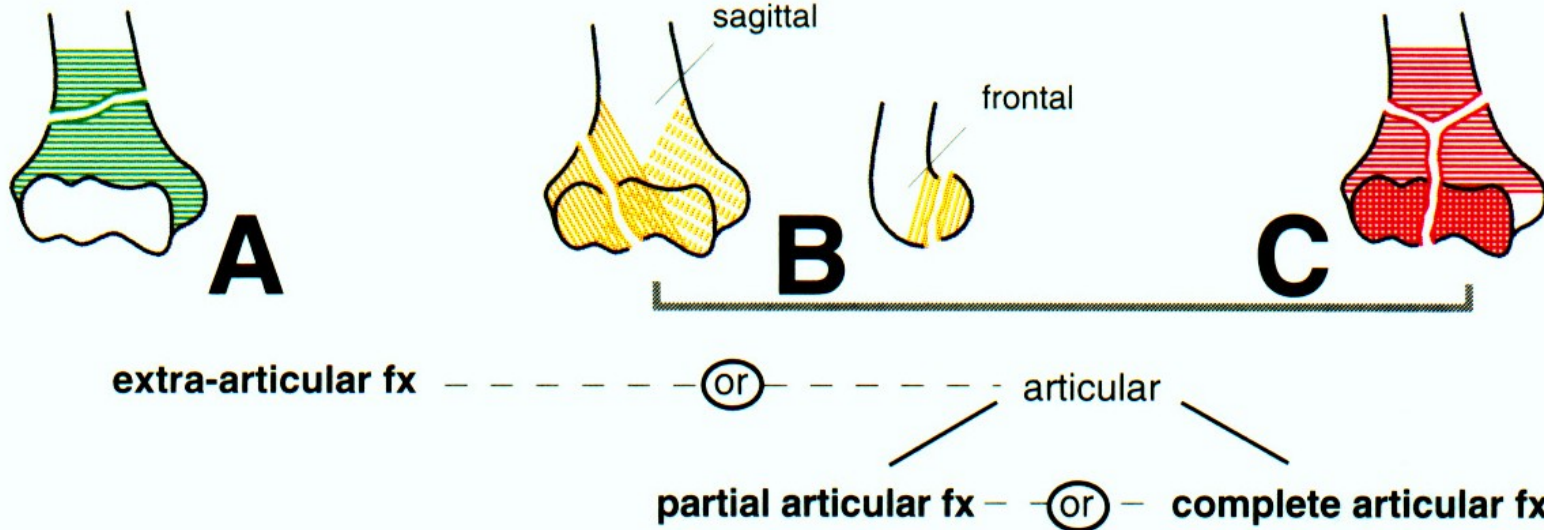
AO classification - diaphysis



Type

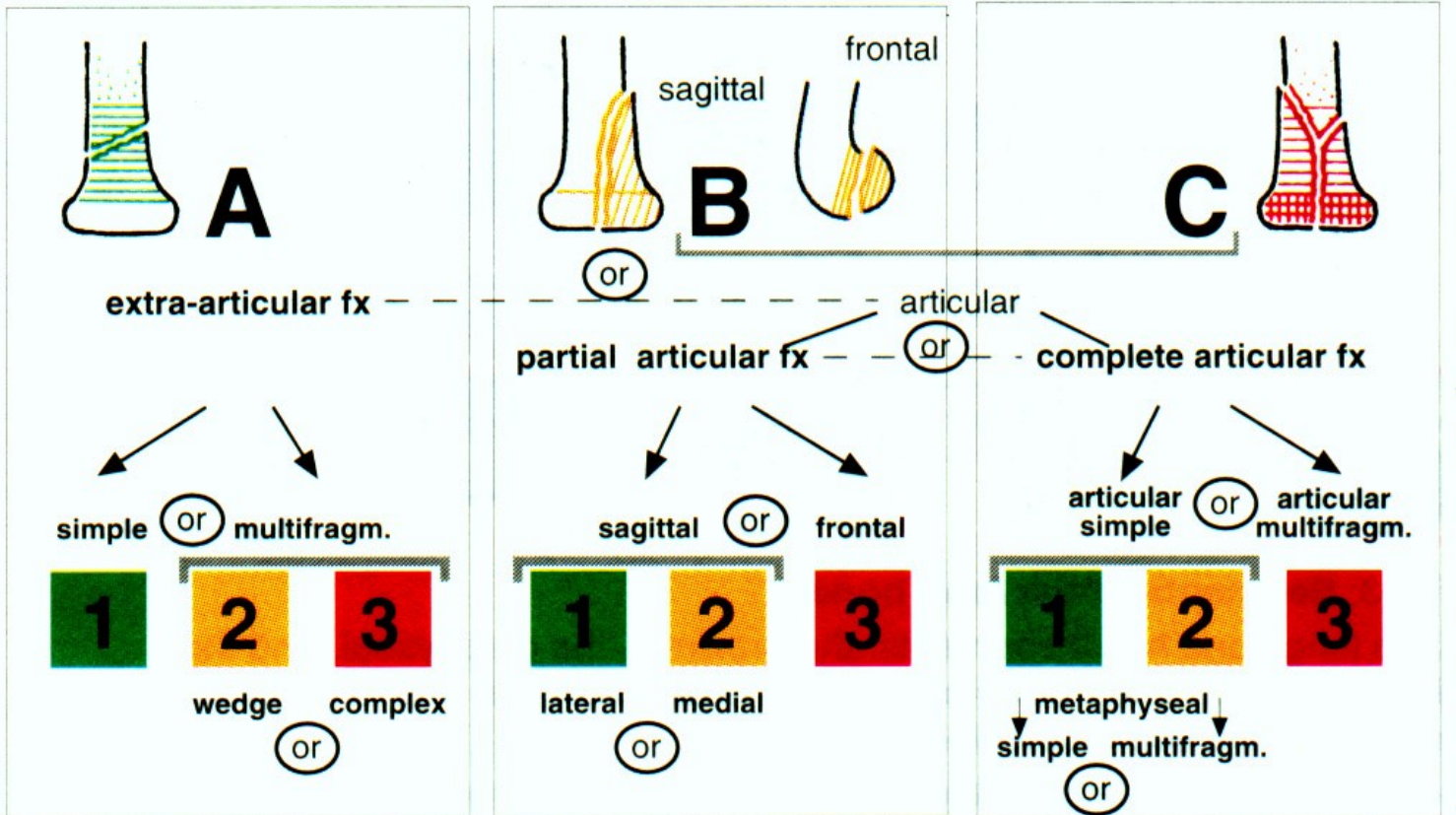
AO classification

- metaphysis, epiphysis



Type

AO classifications



Type

Group

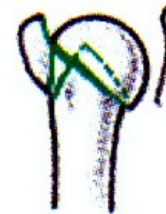AO classification – proximal humerus



A1
Extra-articular
unifocal fx,
tuberosity



B1
Extra-articular
bifocal fx,
with metaphyseal
impaction



C1
Articular fx,
with slight
displacement



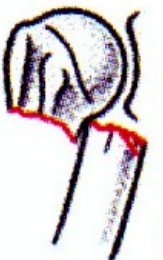A2
Extra-articular
unifocal fx,
metaphyseal
impacted



B2
Extra-articular
bifocal fx,
without
metaphyseal
impaction



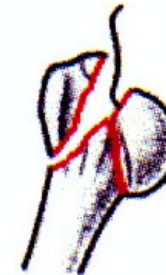C2
Articular fx,
impacted
with marked
displacement



A3
Extra-articular
unifocal fx,
metaphyseal
non-impacted



B3
Extra-articular
bifocal fx,
with glenohumeral
dislocation



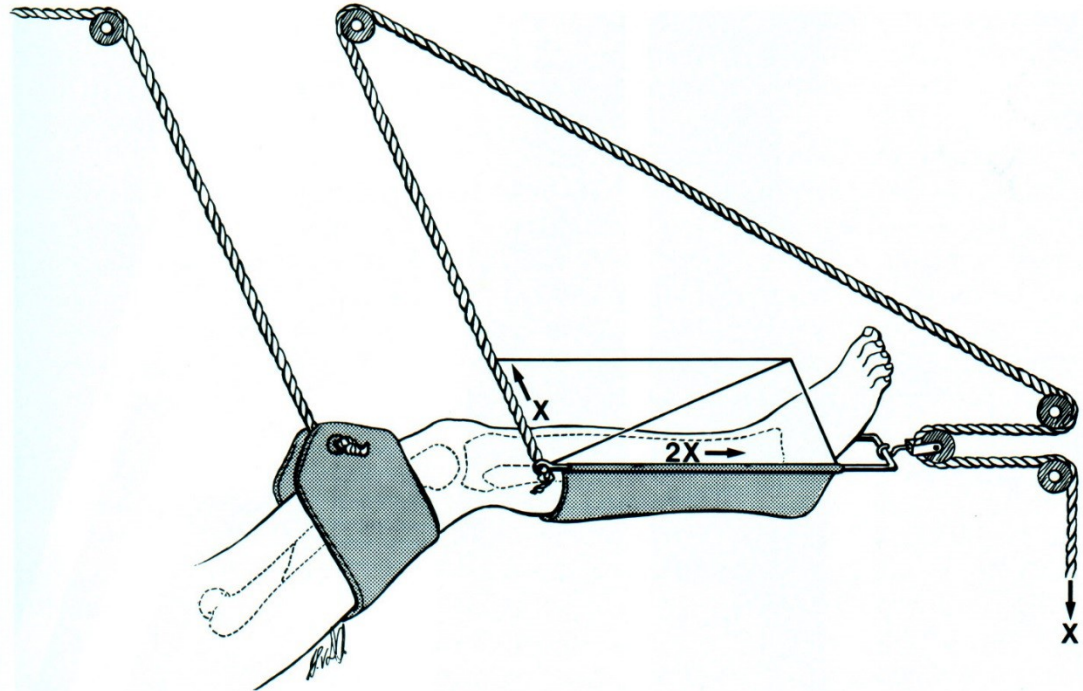
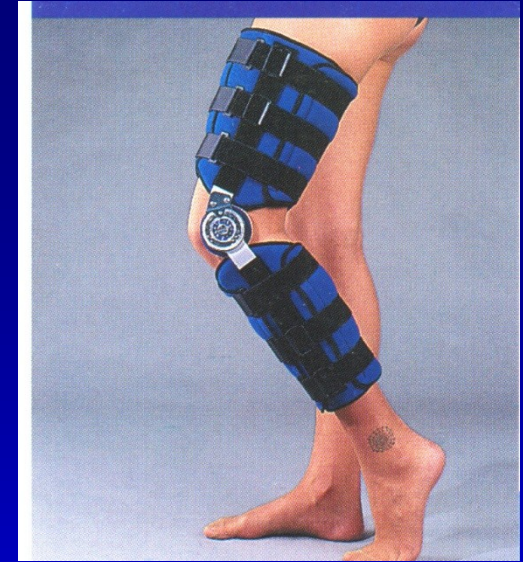
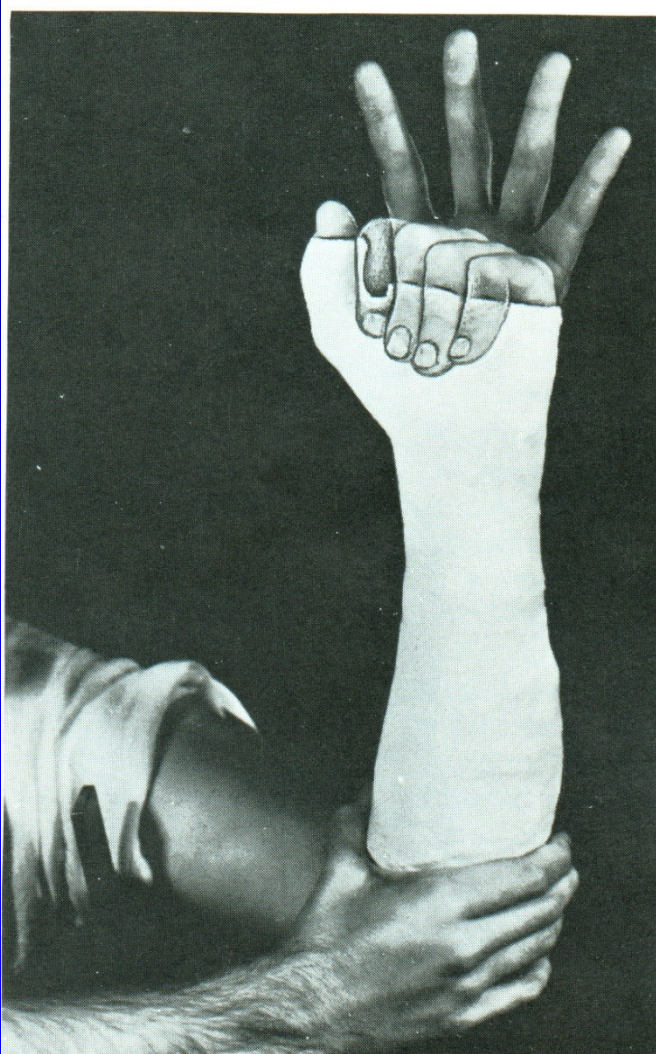C3
Articular fx,
dislocated

Management of fractures

Conservative:

- 1. Reduction
- 2. Retention (immobilisation)
- 3. Physiotherapy

Conservative management



Operative treatment

In all cases, in which we get advantage against conservative treatment

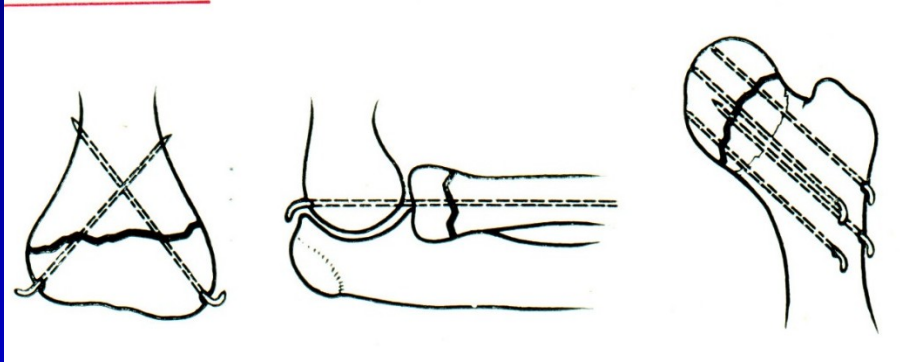
- Intraarticular fractures
- Dislocated fr. – not redusable by closed reduction
- Fr. of proximal femur
- Diaphyseal fr.
- Open fr.

Osteosynthesis

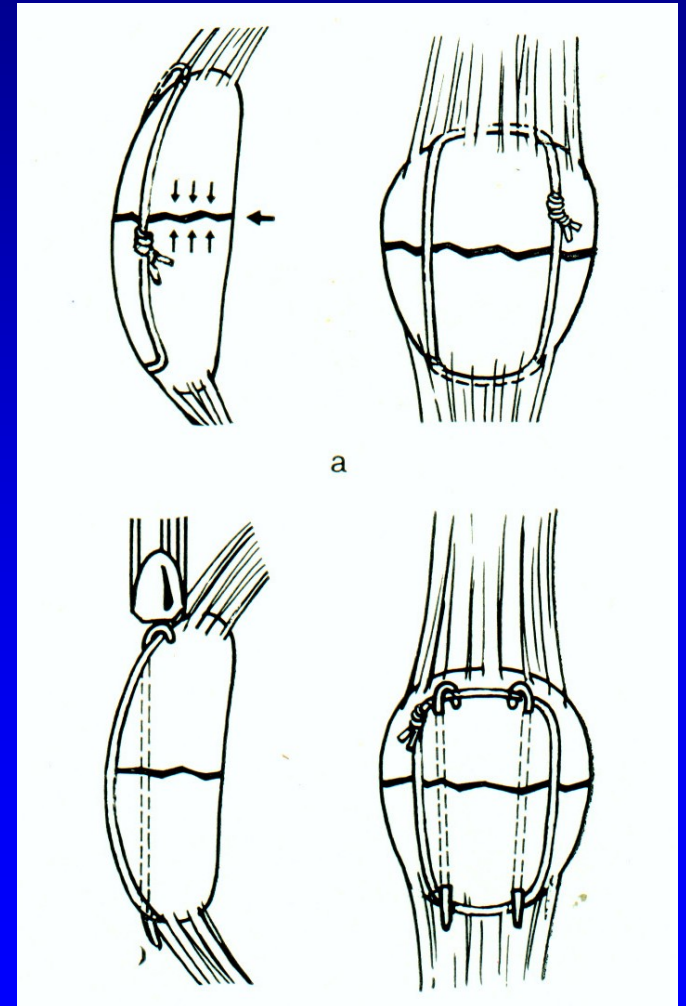
- Aim – anatomical reduction
- Absolute stability (AO plate)
- Relative stability
 - + secondary healing with periosteal and endosteal callus (intramedullary nails)

Osteosynthesis

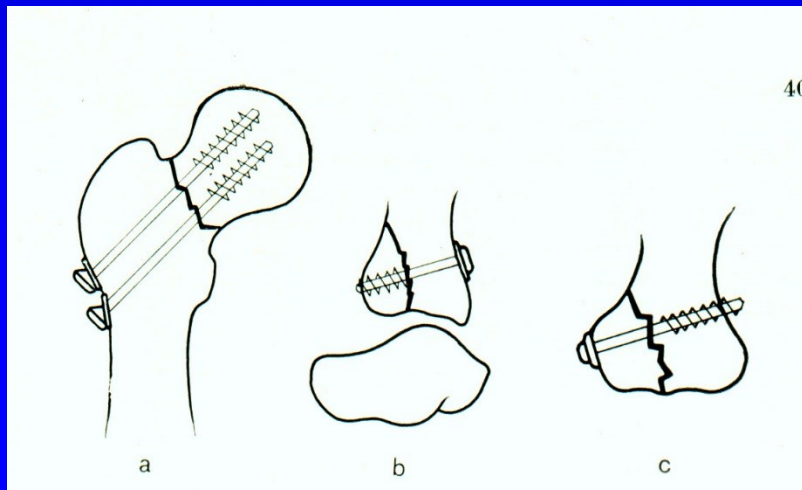
Kirschner wires



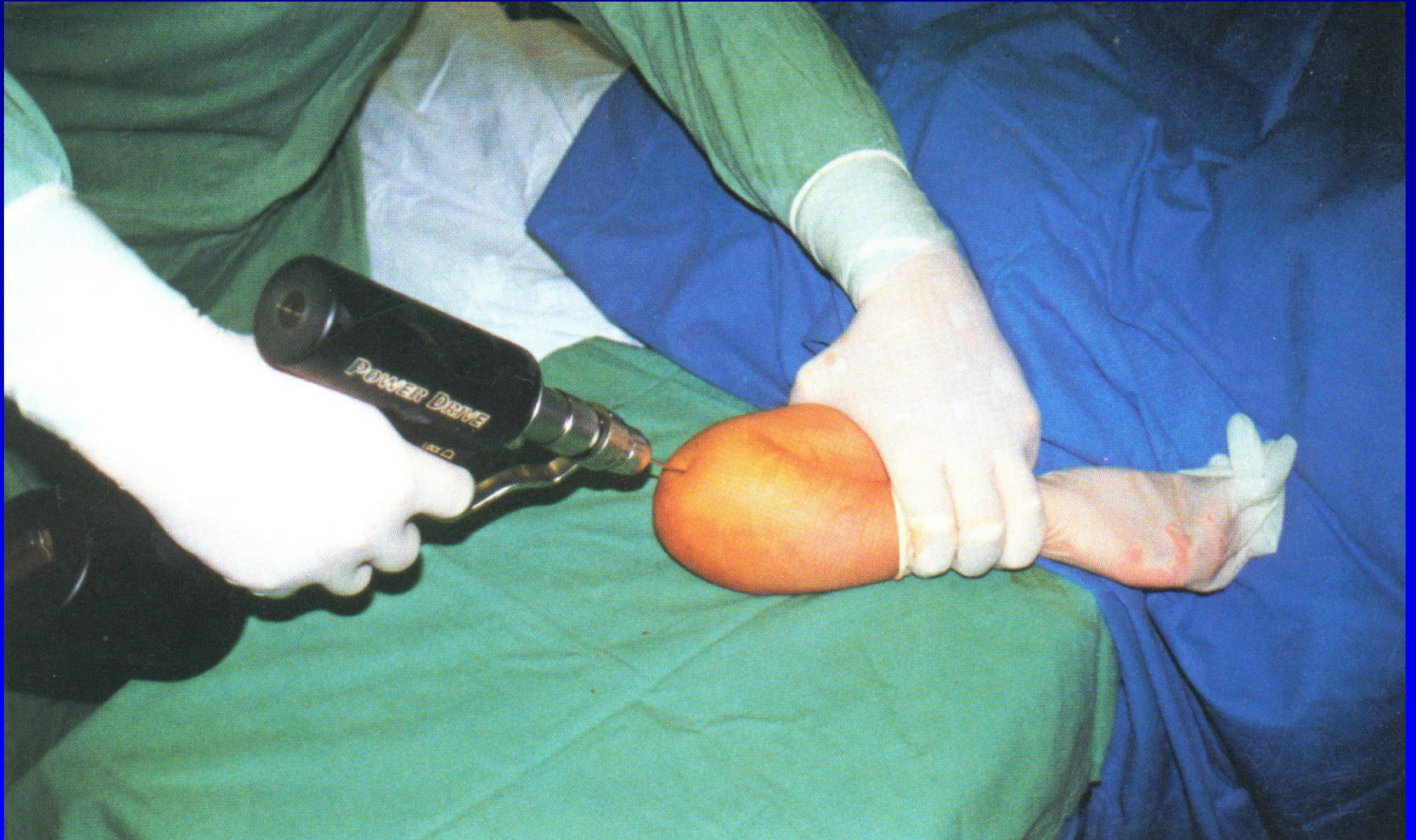
Tension band wiring



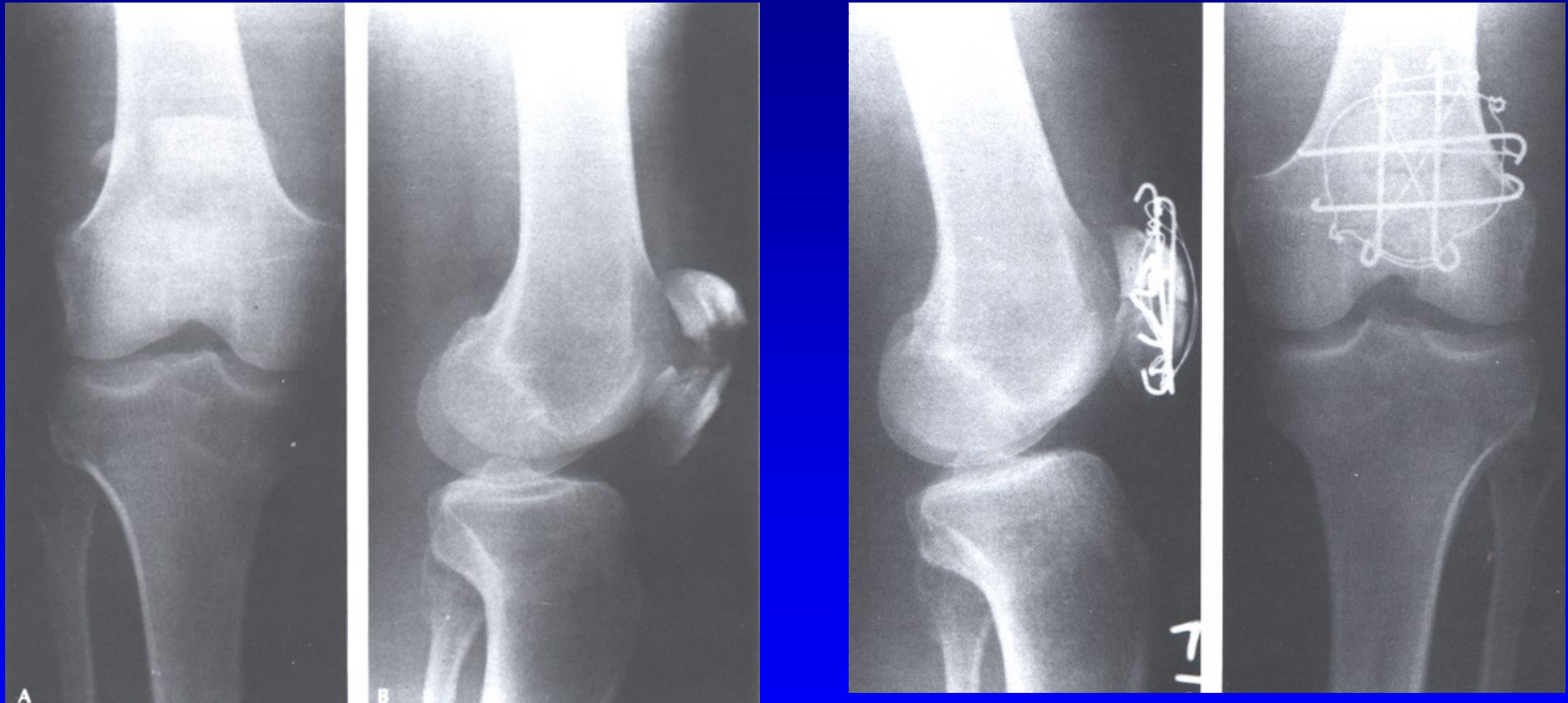
AO screws cortical cancellous



K- wires

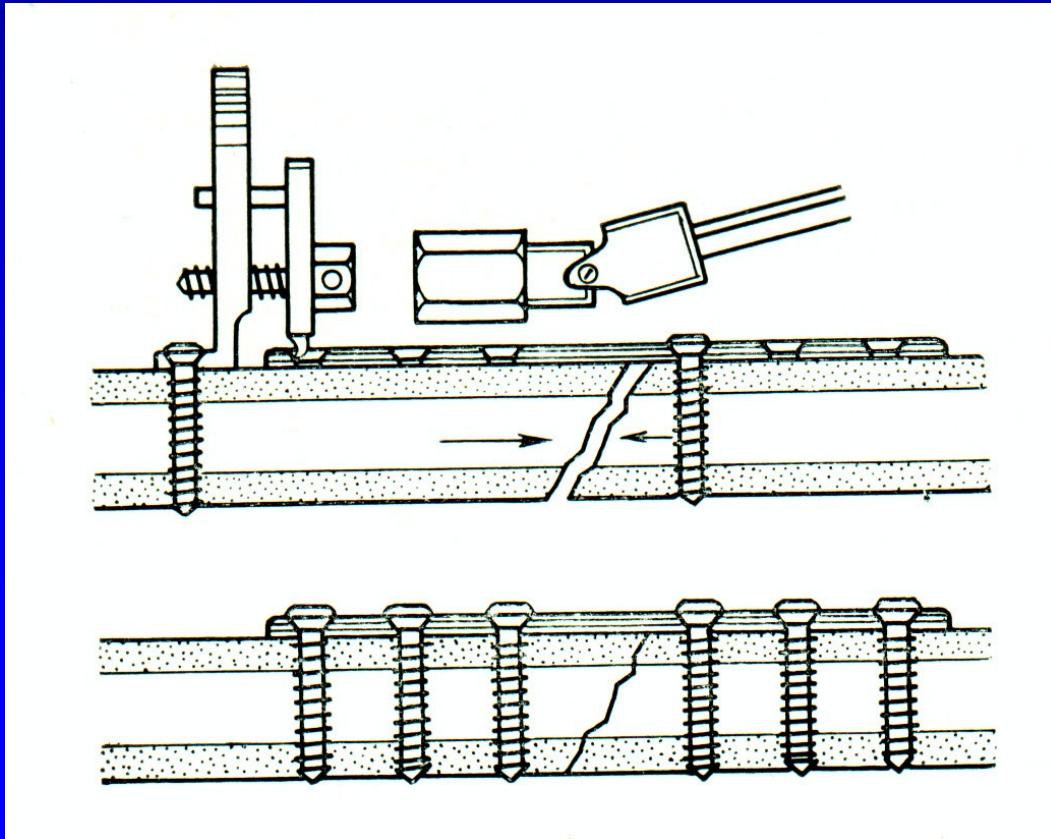


Tension band wiring of patella

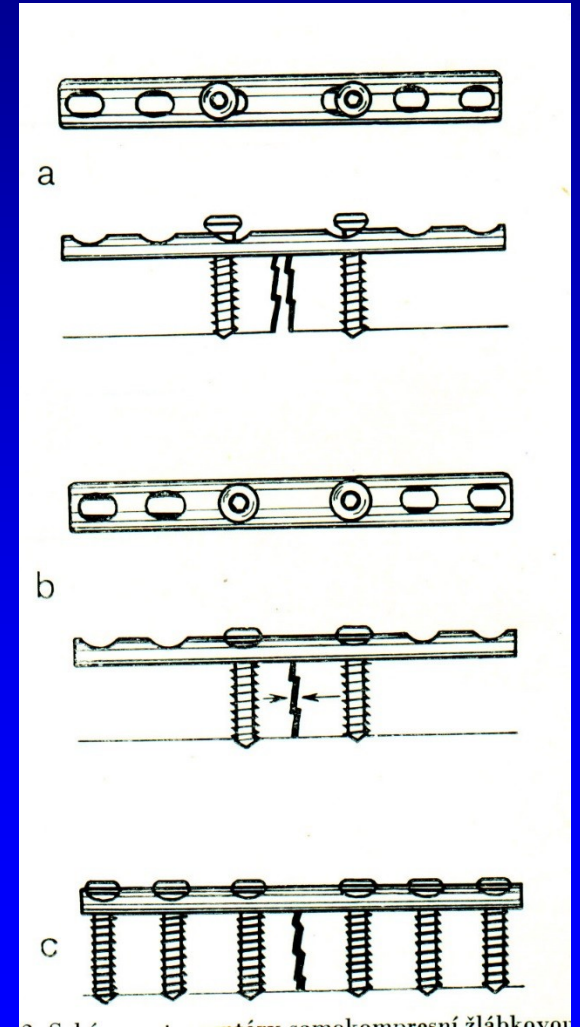


AO plates

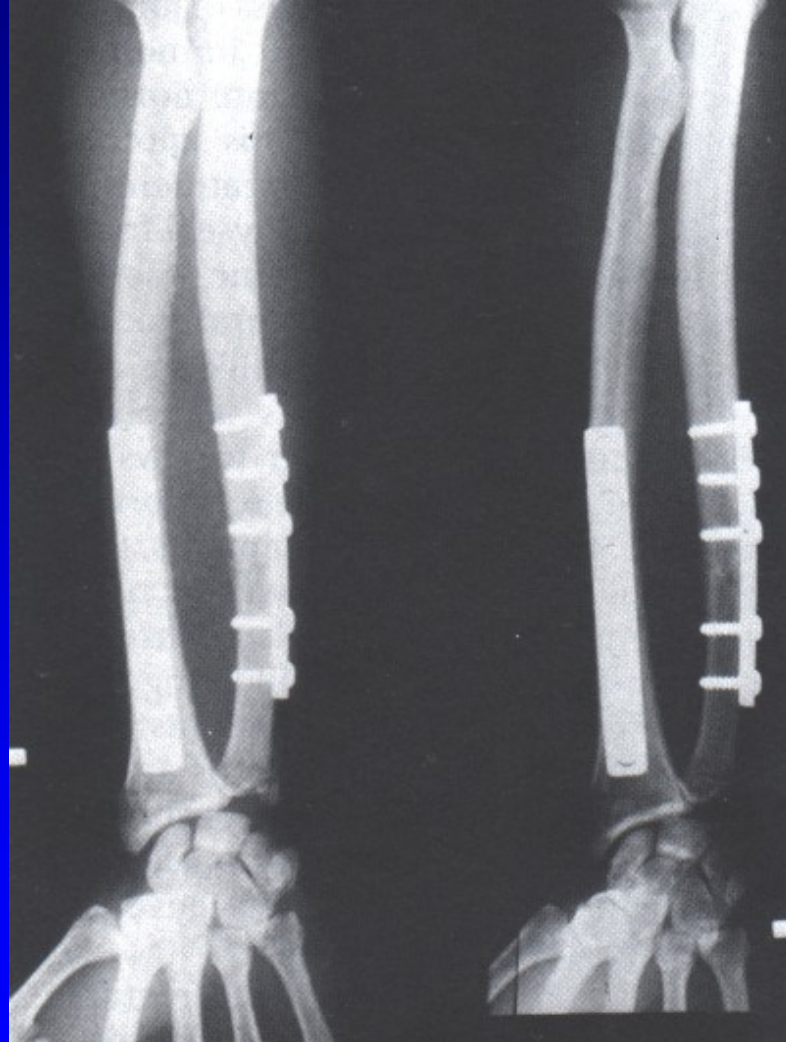
Compression AO plate



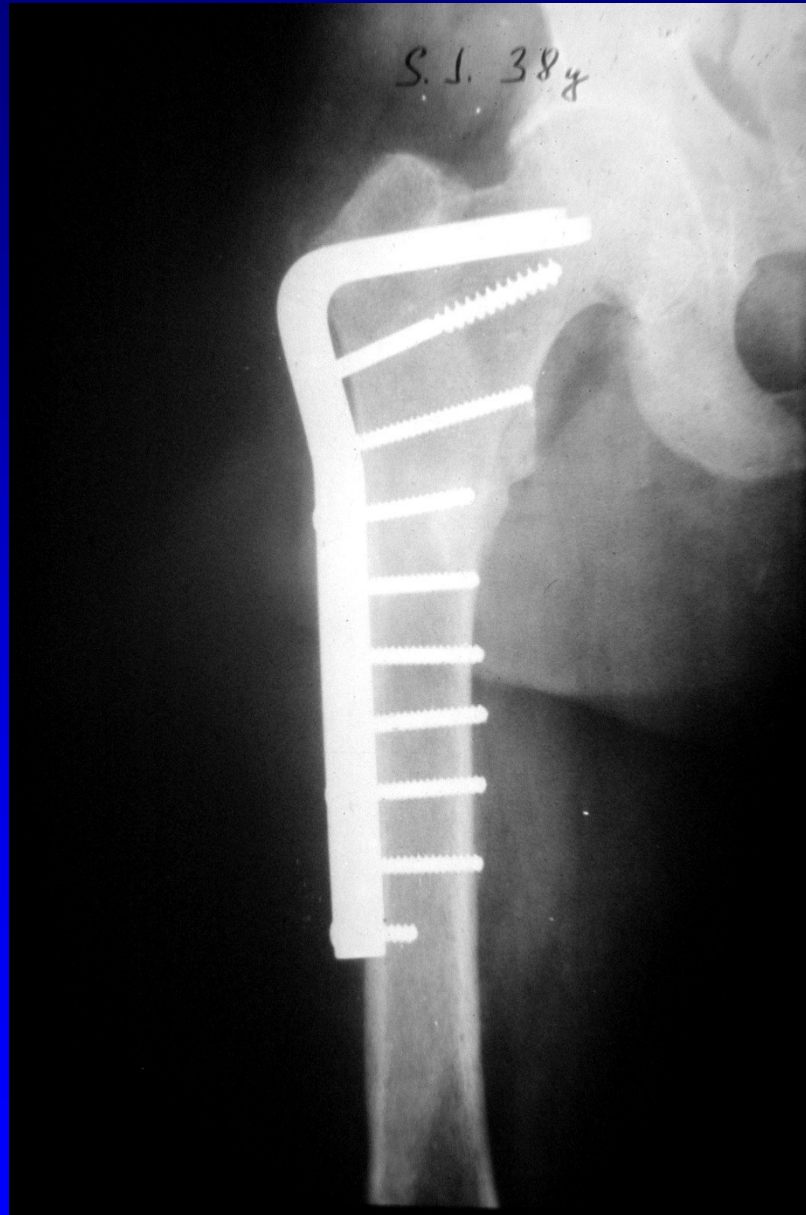
Self-compression AO plates



Osteosynthesis of radius and ulna



AO plate of proximal femur

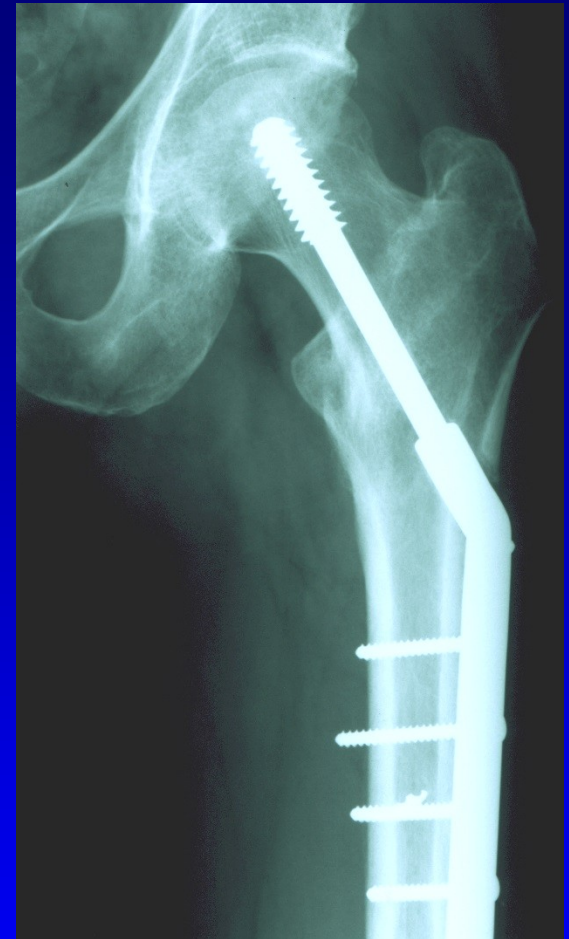


DHS

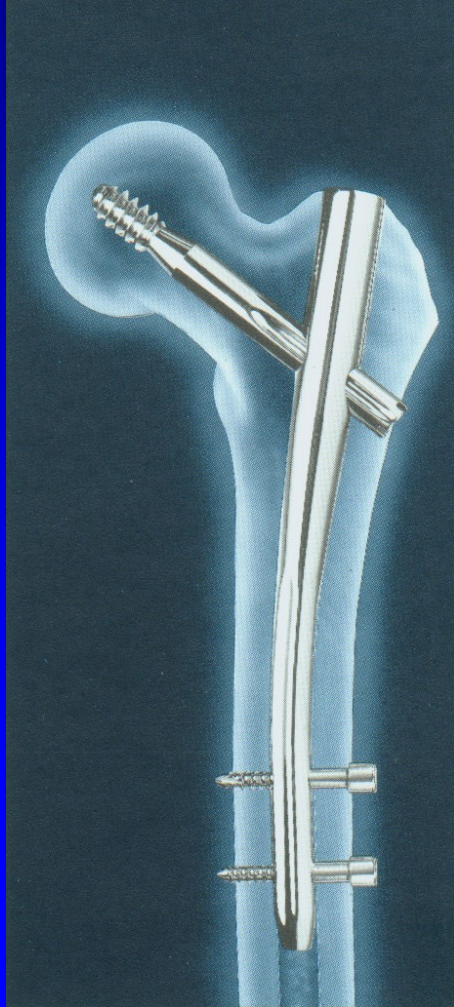
Dynamic hip screw

DCS

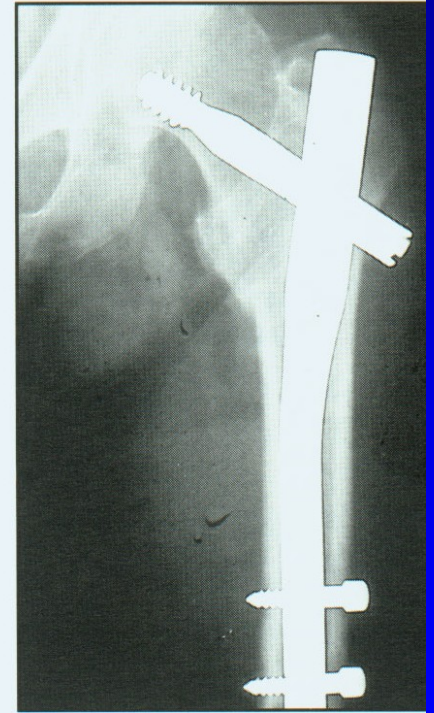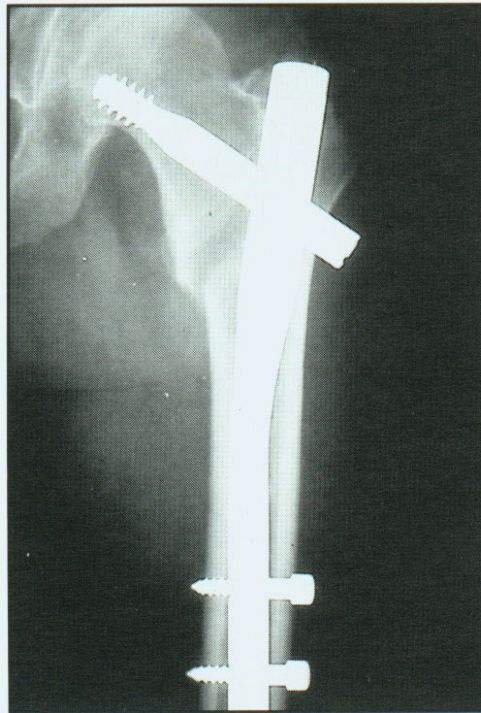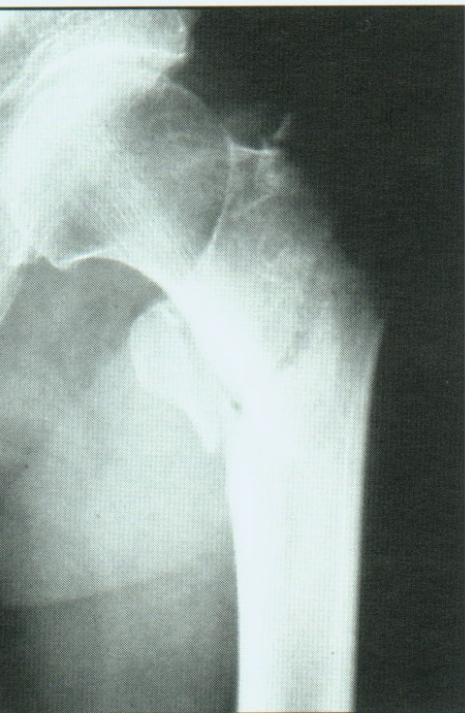Dynamic condylar screw



Gamma locking nail



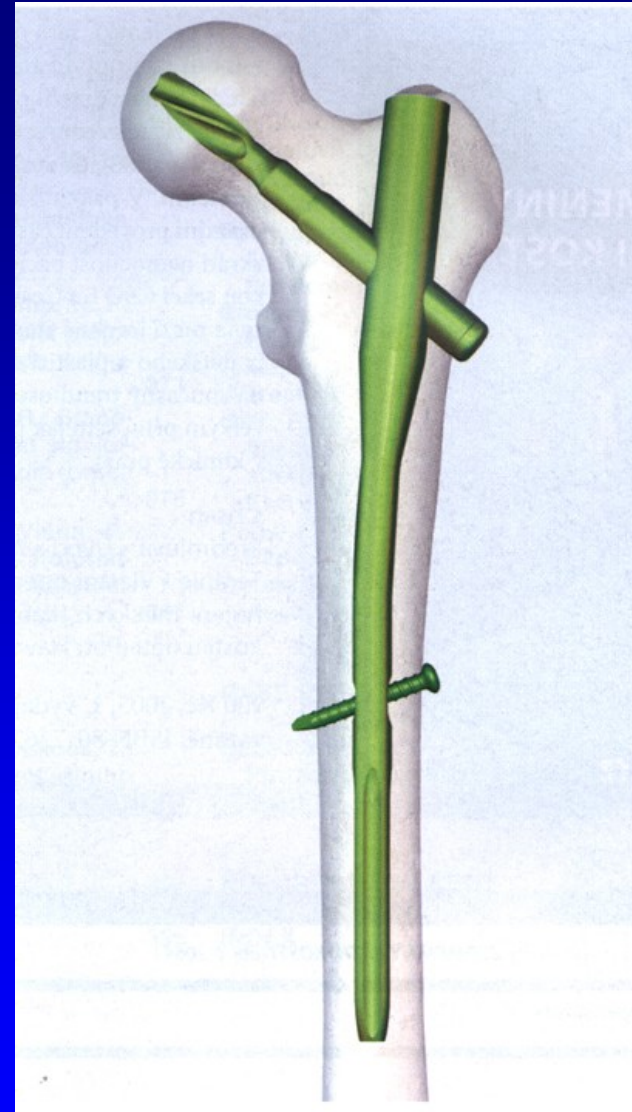
Gamma locking nail



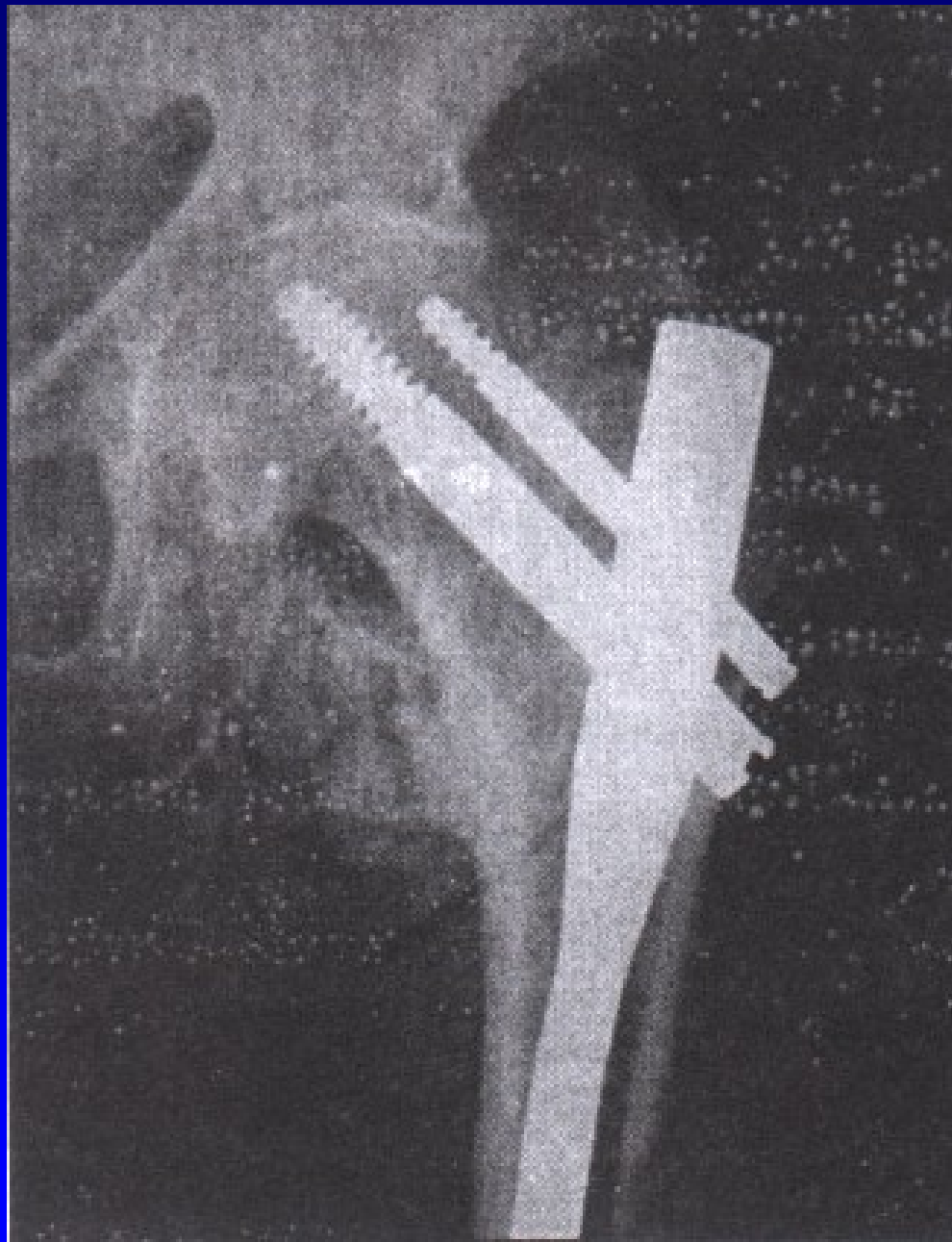
Nail PFNA

Rotation and angle stability

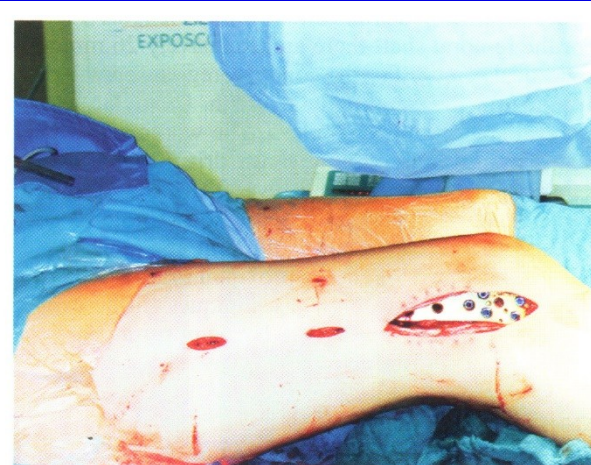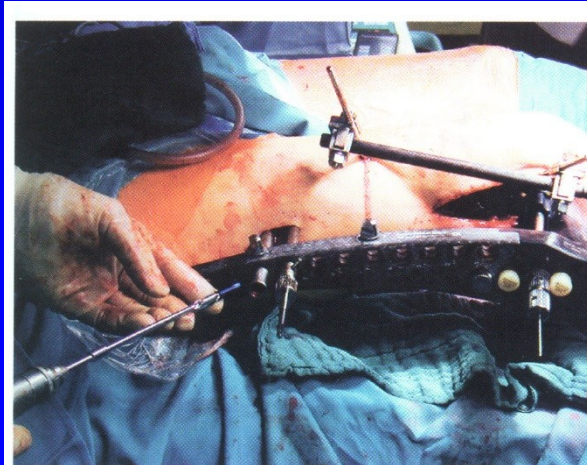
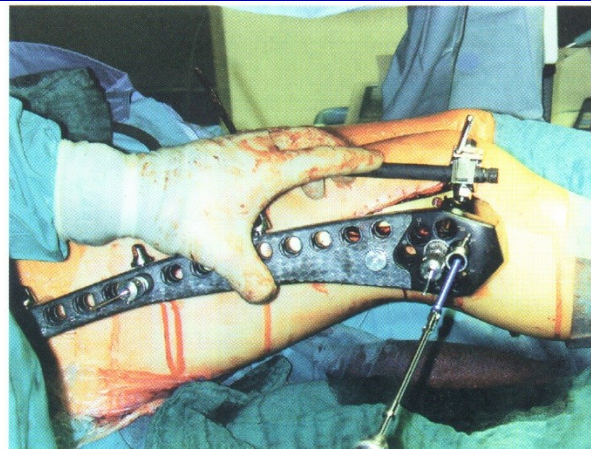
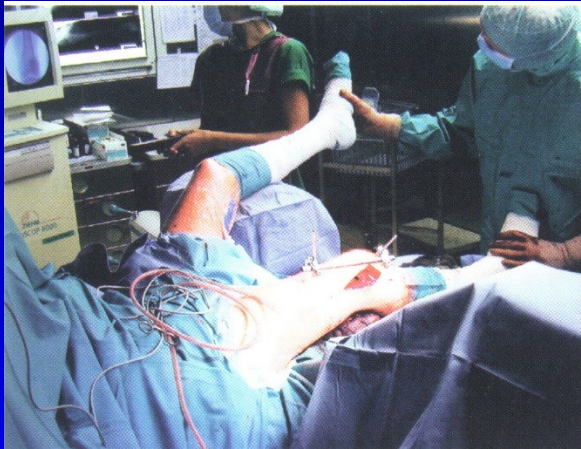
Static and dynamic locking mechanism



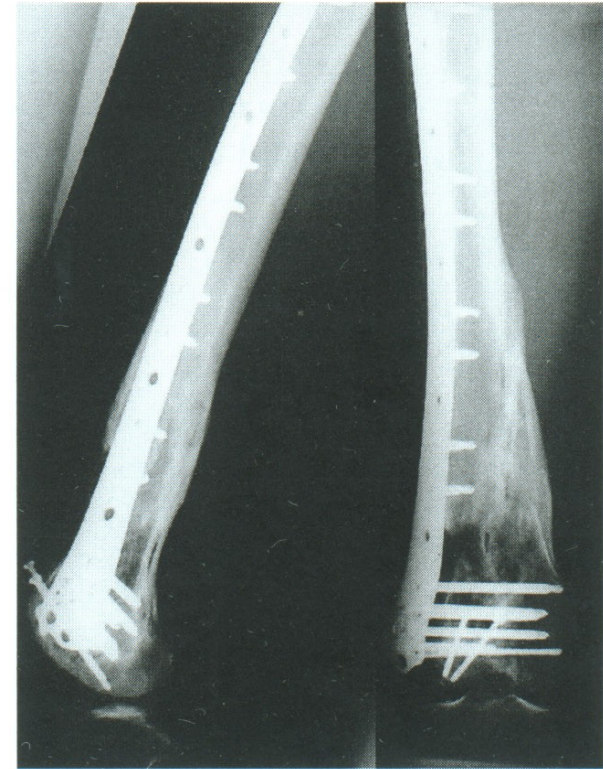
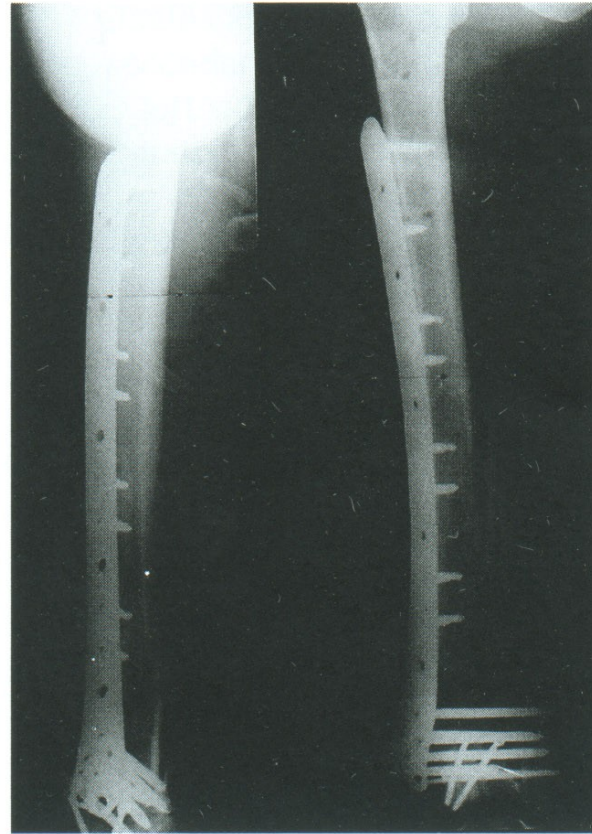
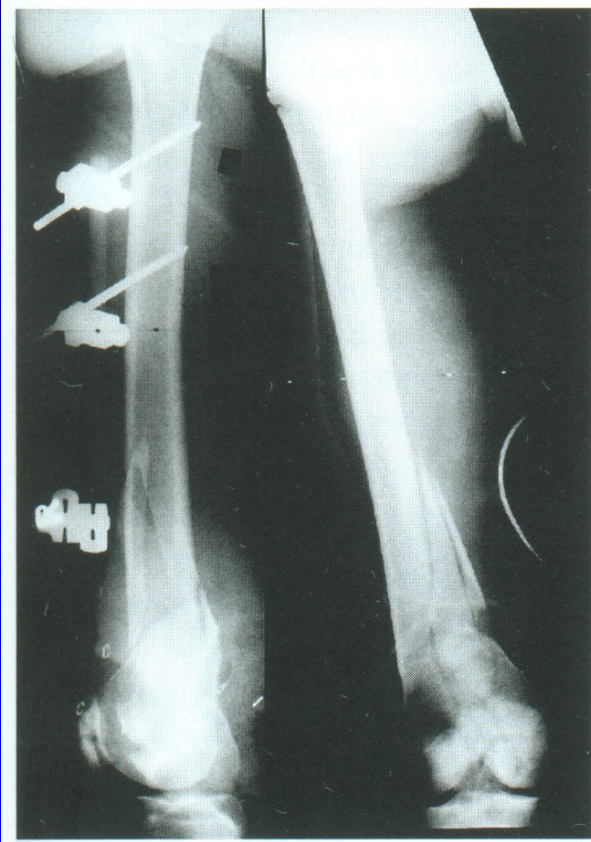PFNA Synthes



LISS – less invasive stabilisation system



Unicortical plates



Locking compression plate - LCP

Unicortical fixation – in diaphysis

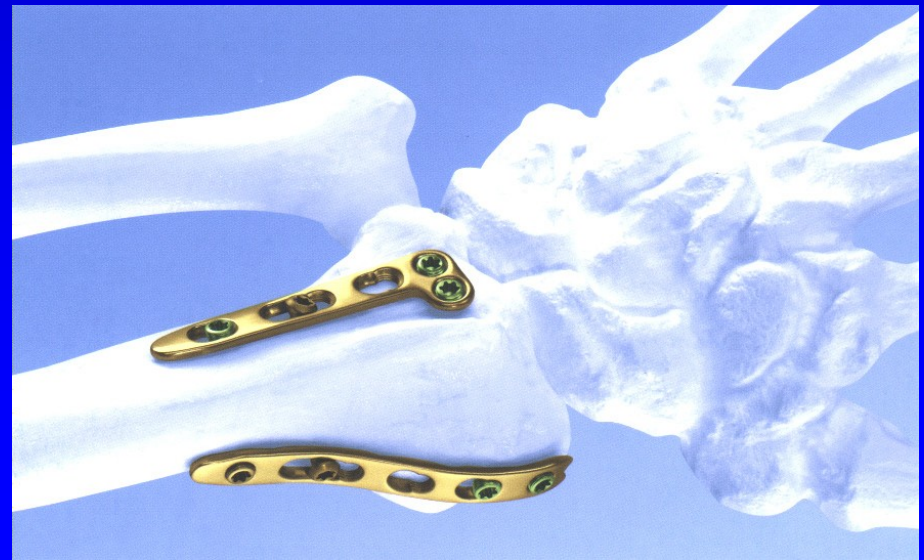Bicortical fixation - in epiphysis

Compression screws – oblique direction

Limited contact

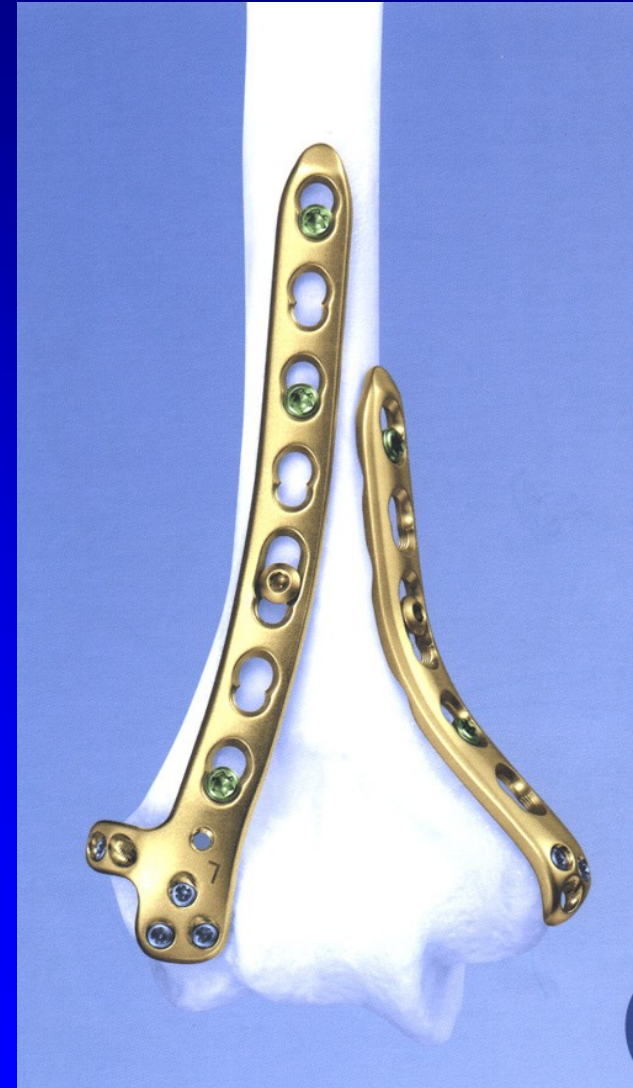
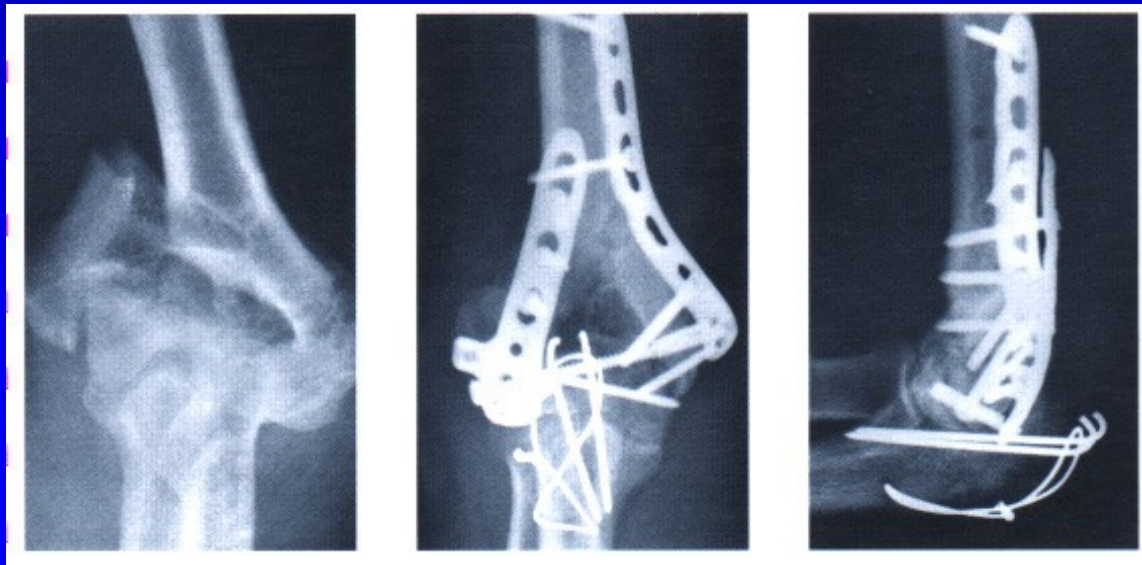
Adjusted to every anatomical region

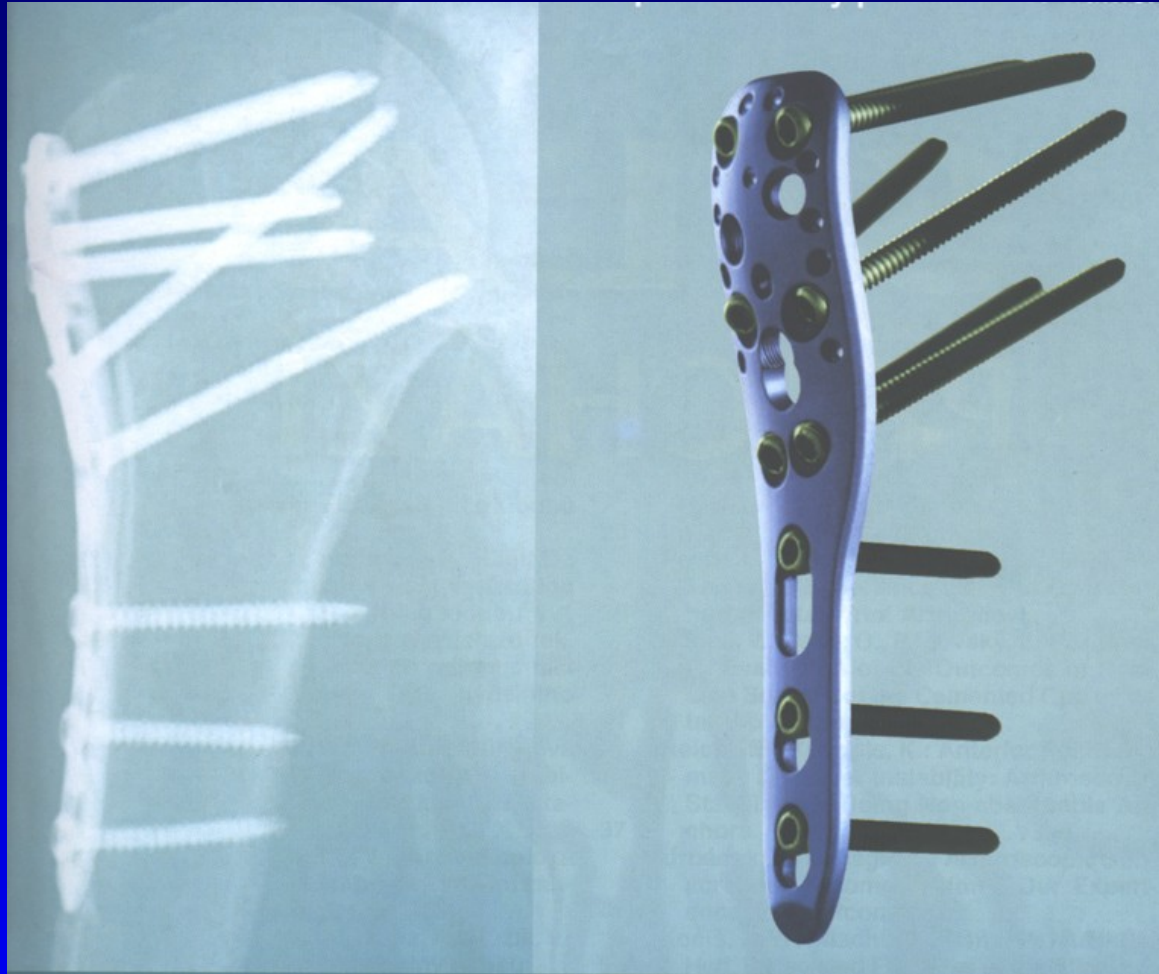
Titanium



Locking compression plate - LCP

In epiphysis bicortical fixation
In diaphysis unicortical fixation



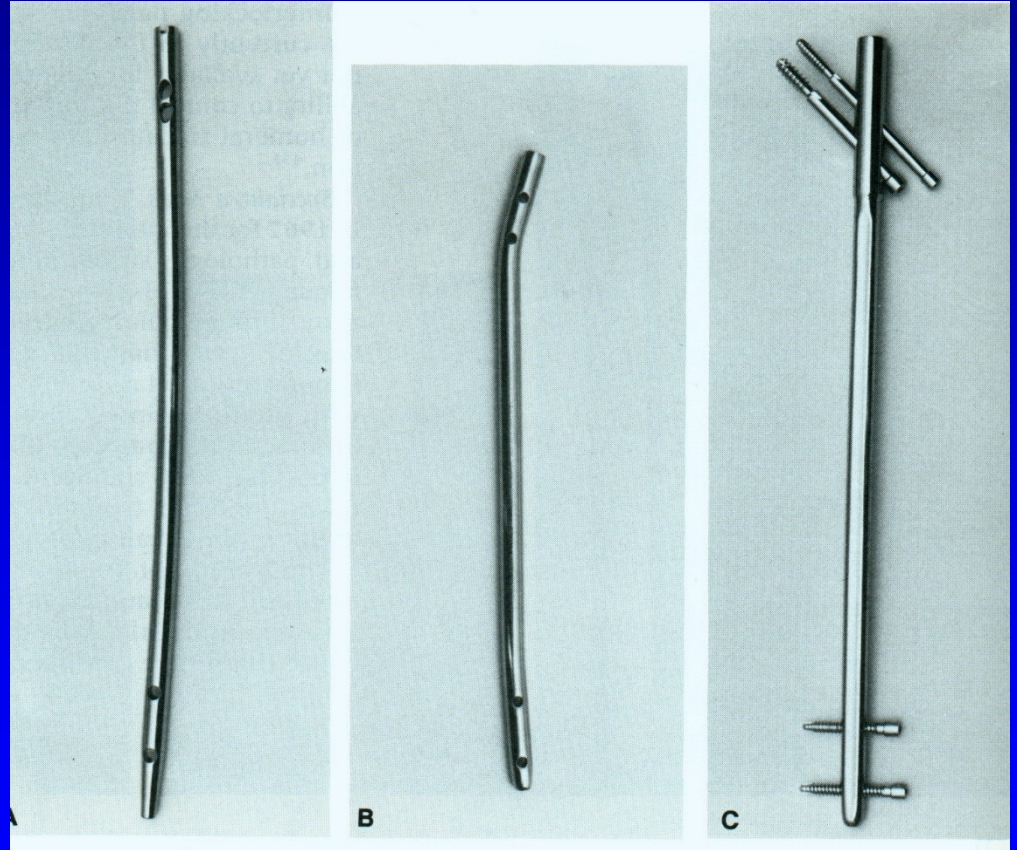


LCP - Philos
Anatomical shape

Locking intramedullary nails

Reamed

Unreamed



Locking intramedullar nails

Reamed:

Stronger

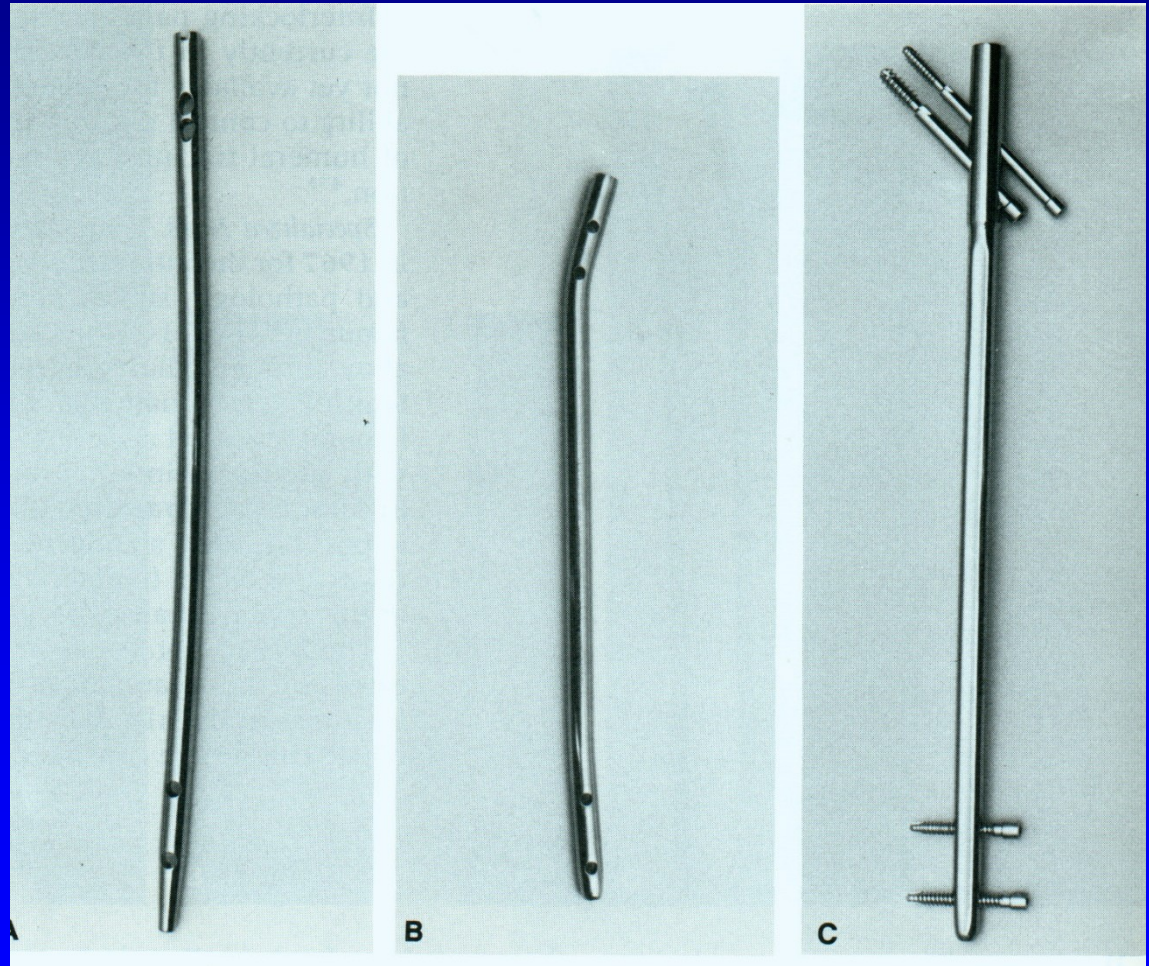
Flexible reamers

Hollow

Good stability

Risk of fat embolism

In type fx. A,B



Locking intramedullar nails

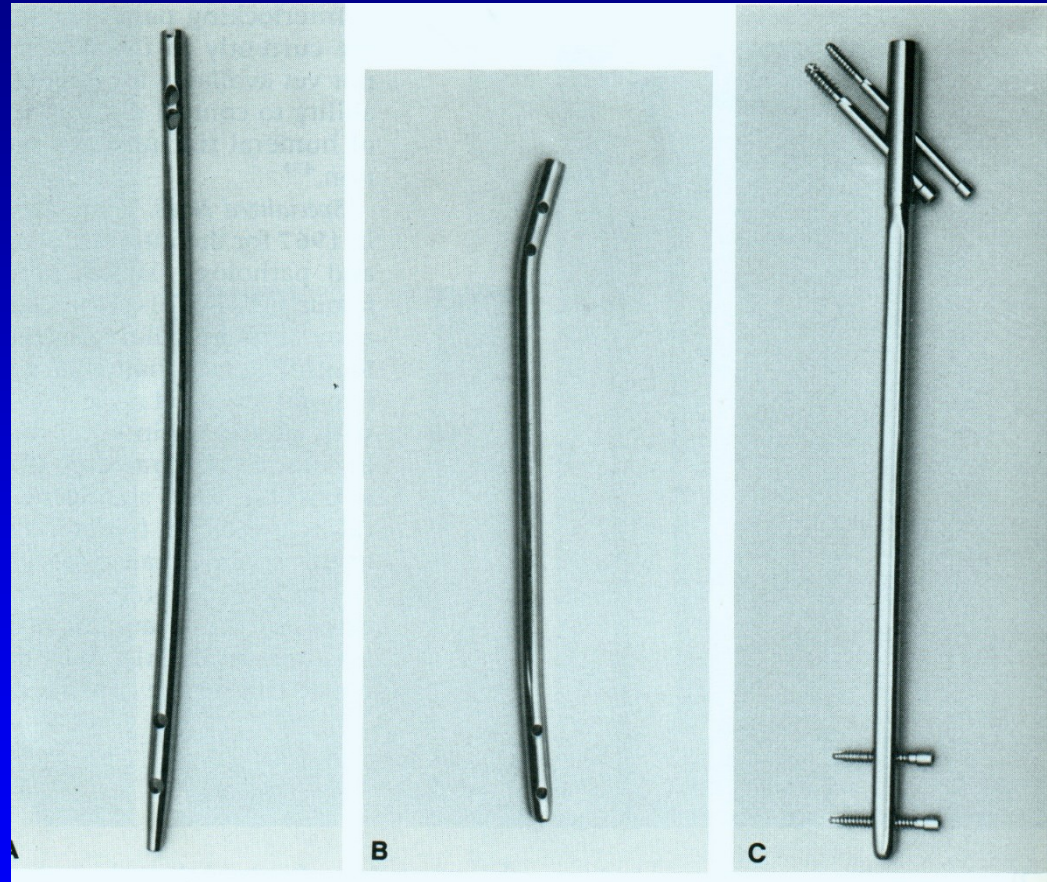
Unreamed:

Solid

Proximal and distal locking

Less stability

For fx. type C

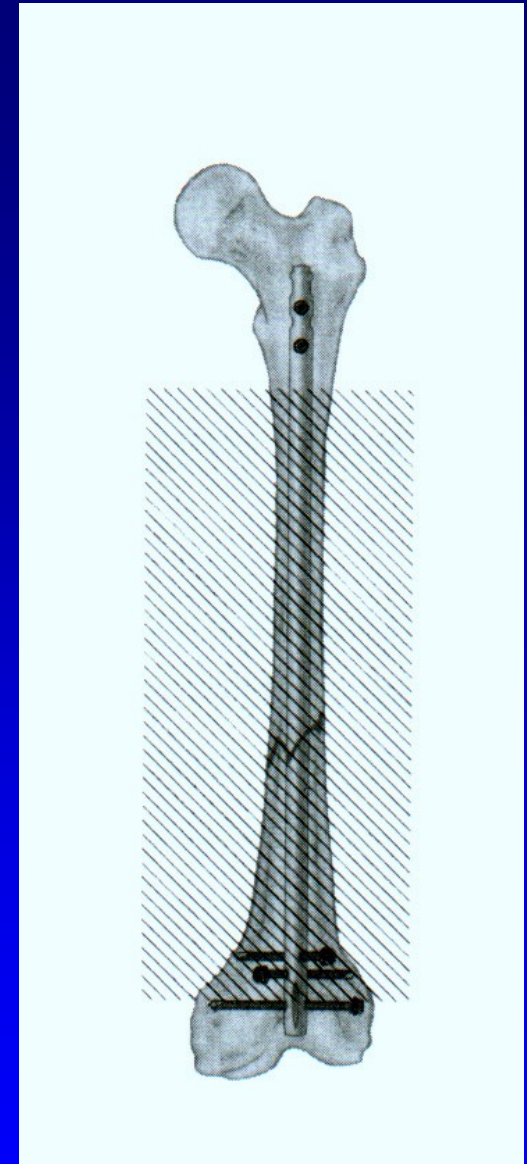


Intramedullar nail of femur

Rotation stability

Static - circle holes

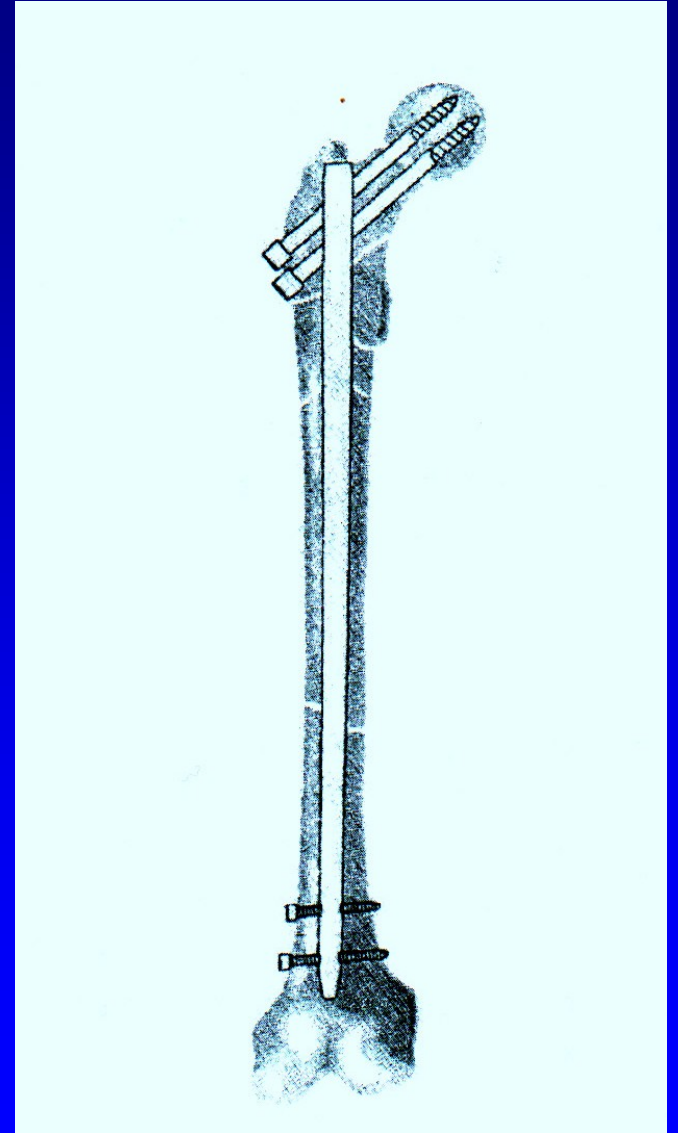
Dynamic - oval holes
with compression of fragments



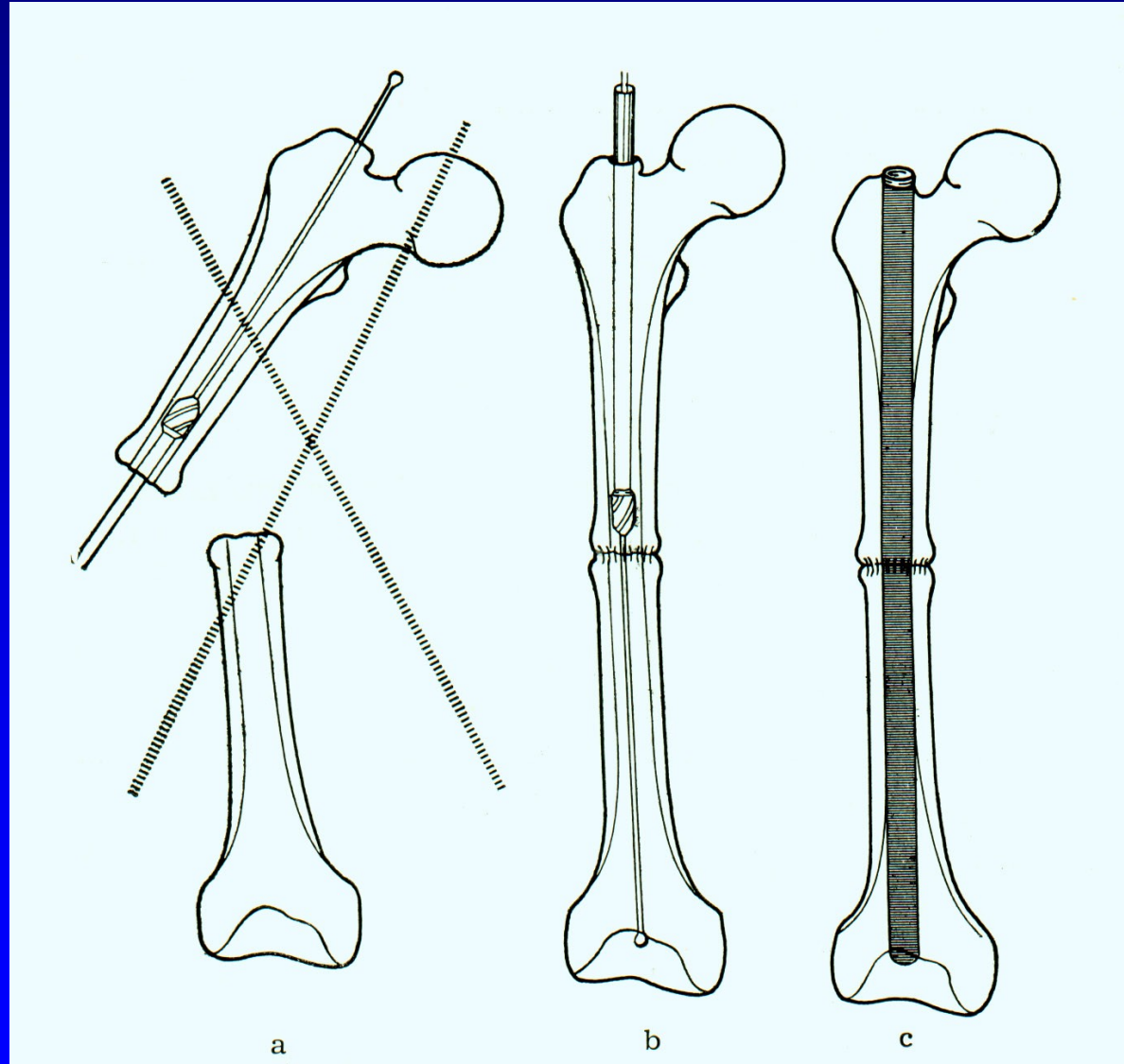
Middle 3/5 of diaphysis

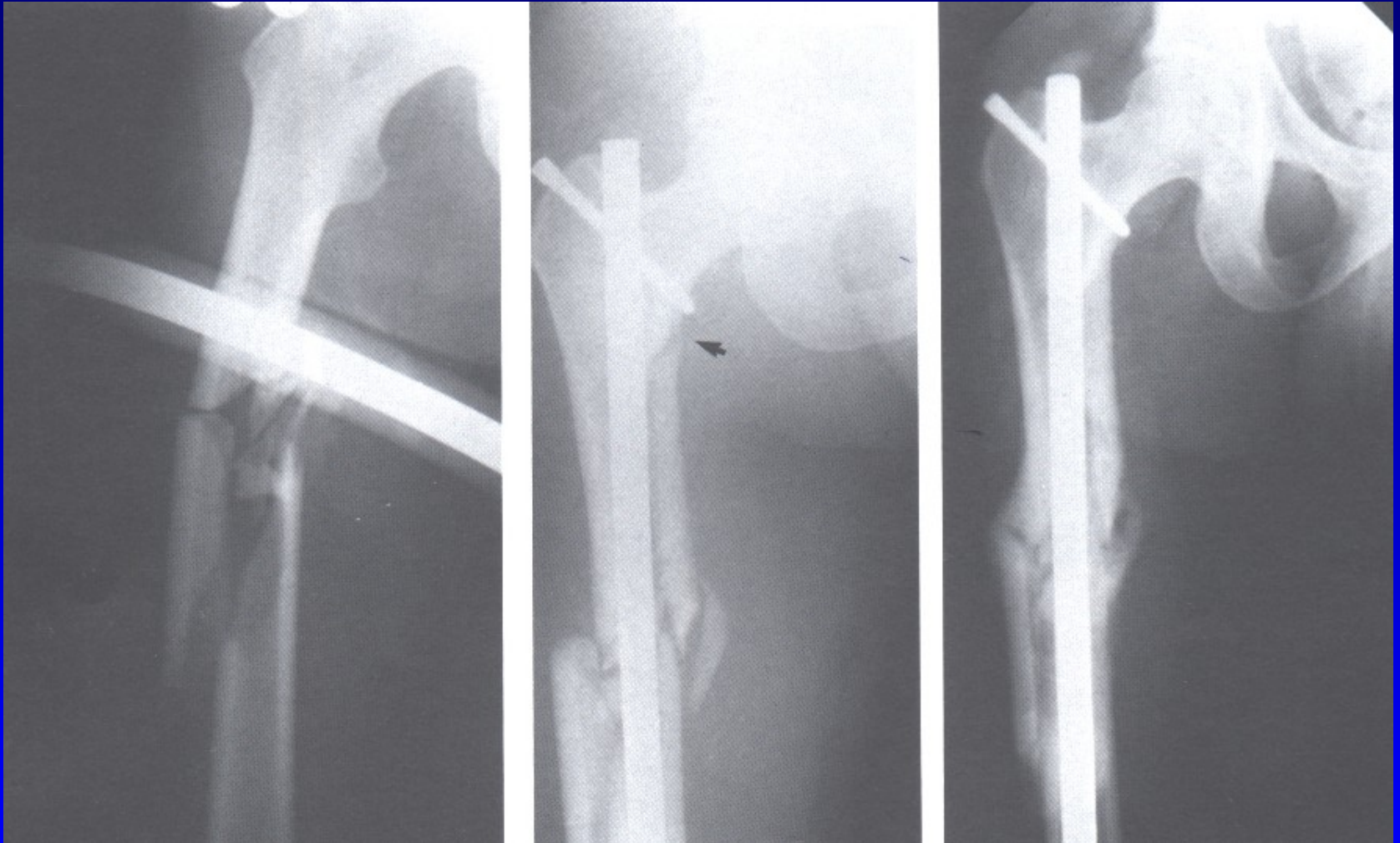
PFN - proximal femoral nail

Reconstructive nails



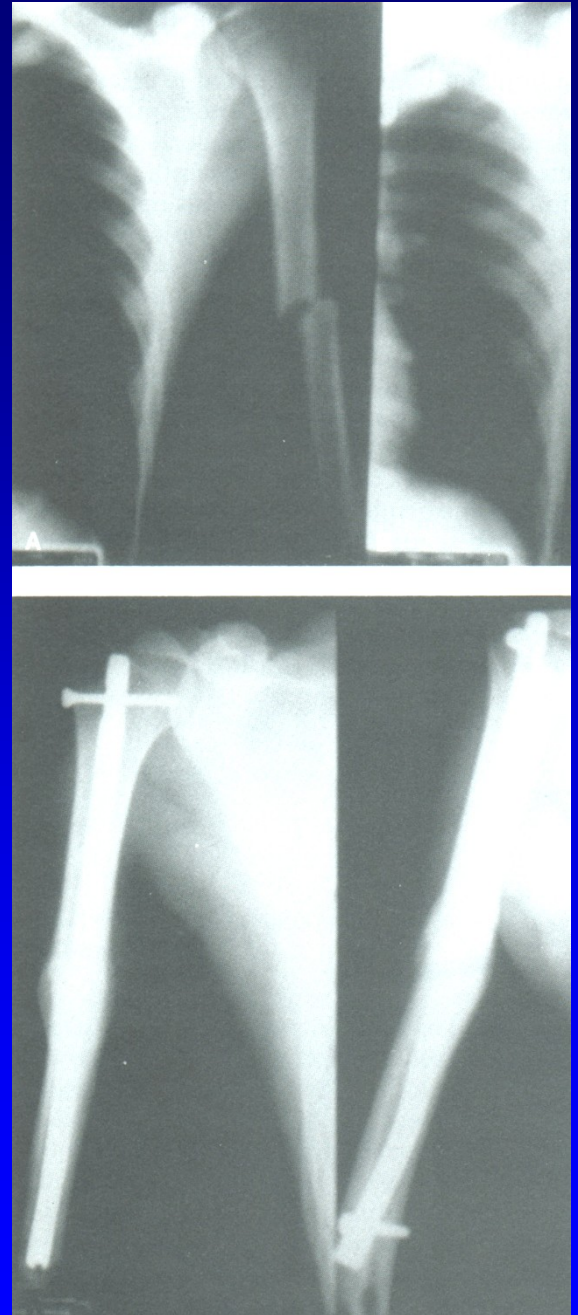
Küntscher intramedullar nail



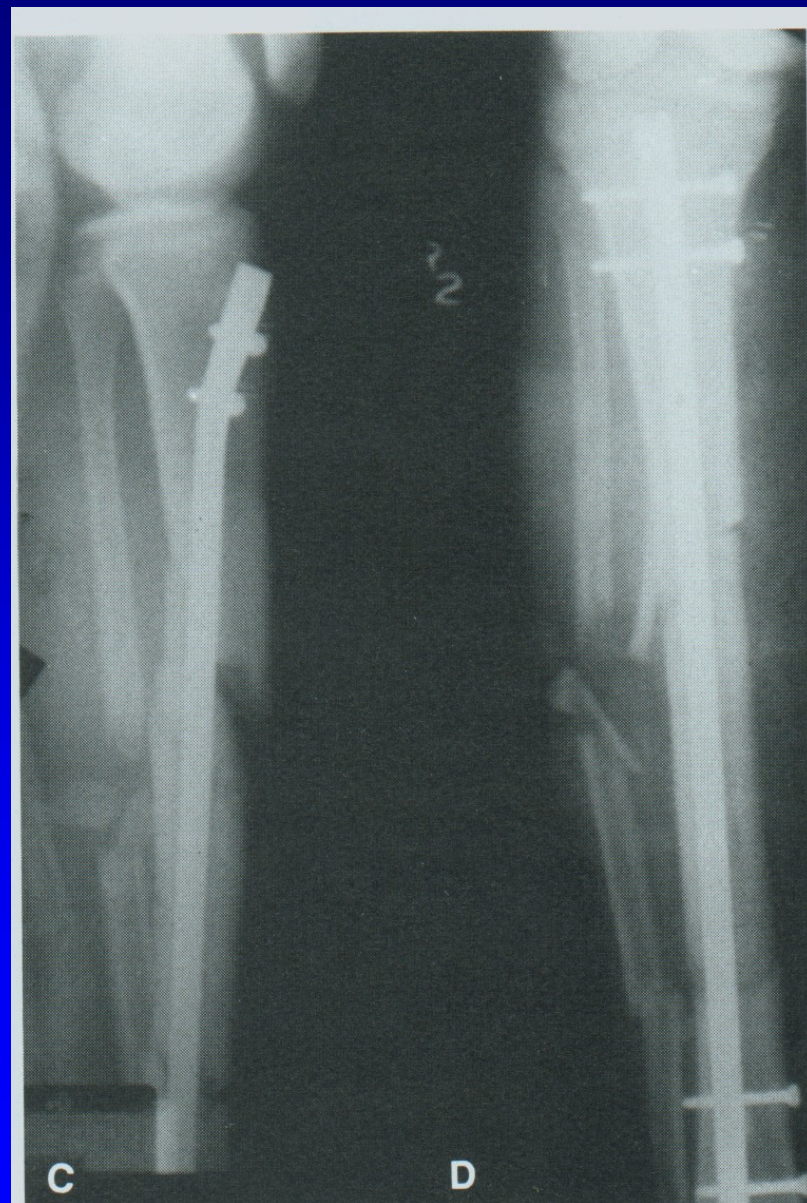


Intramedullar nailing of the femur

Locked nail in humerus



Locked nail in tibia




Tibial nail - Synthes

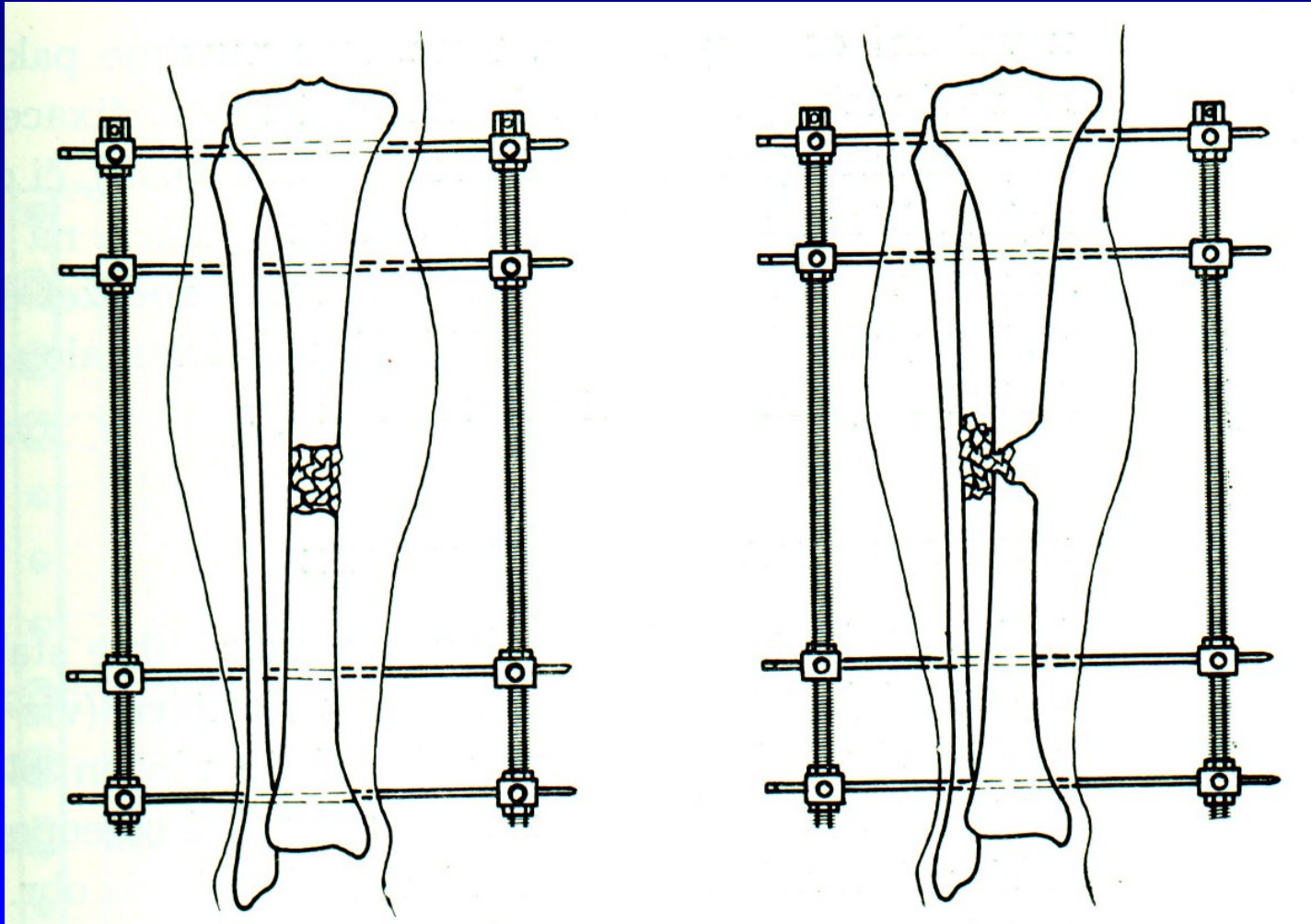
Steel

Titan

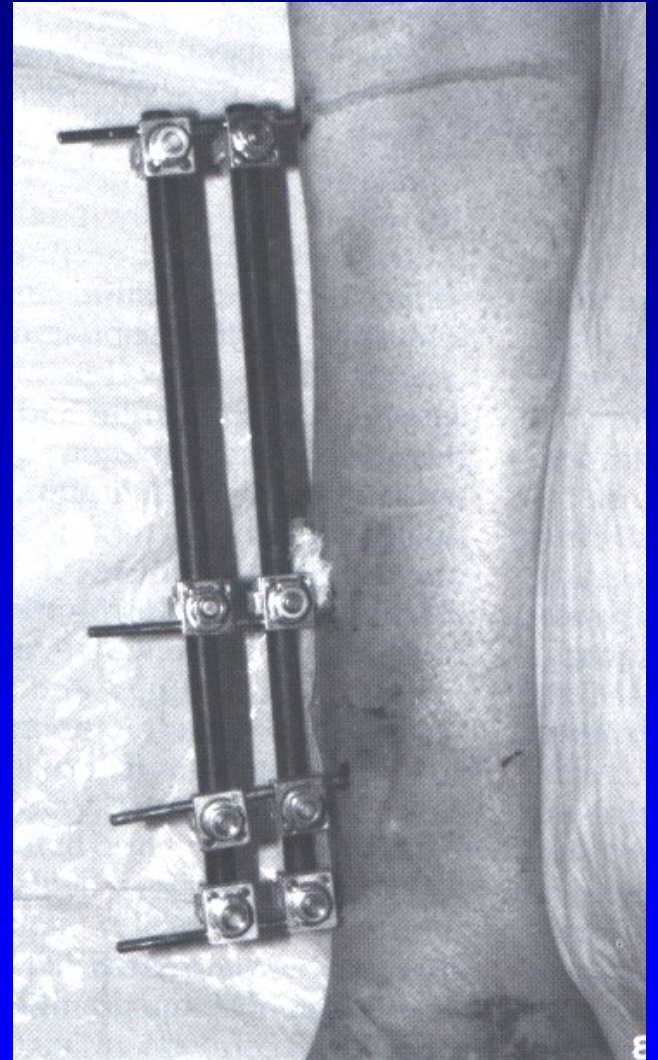
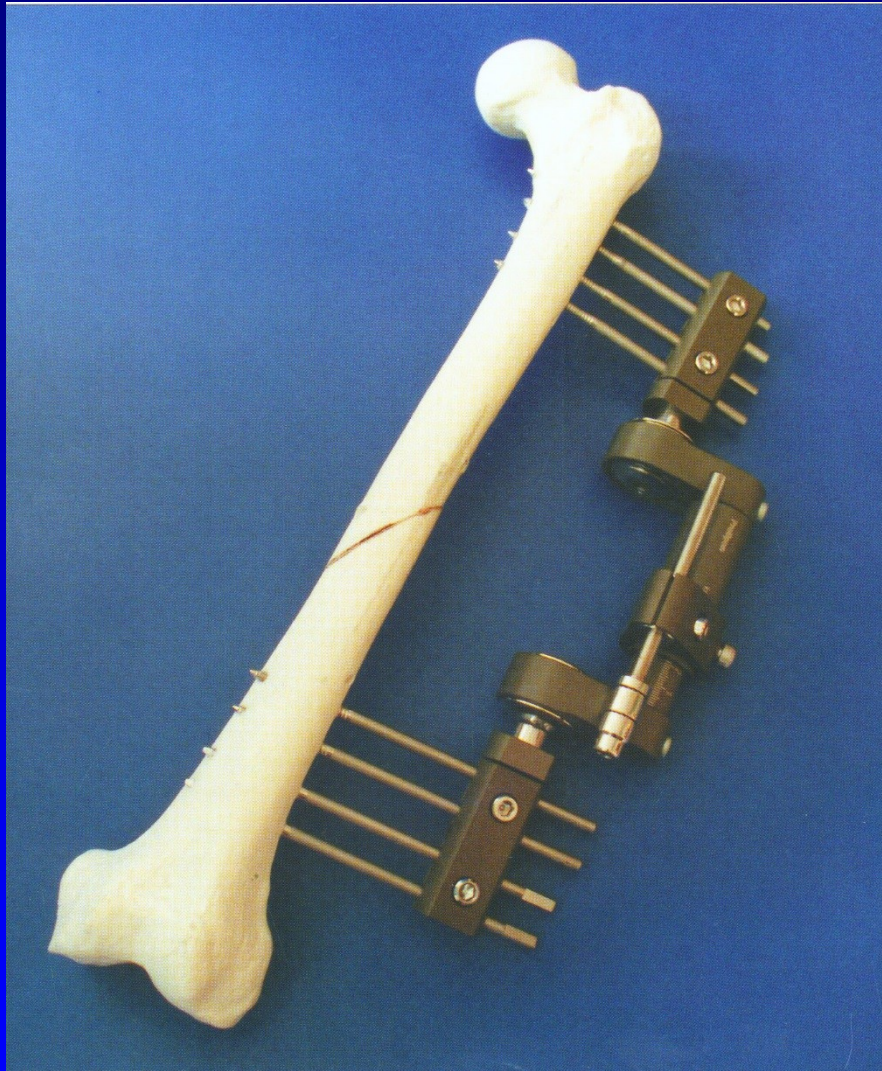
Anatomic curvature




External fixator - frame



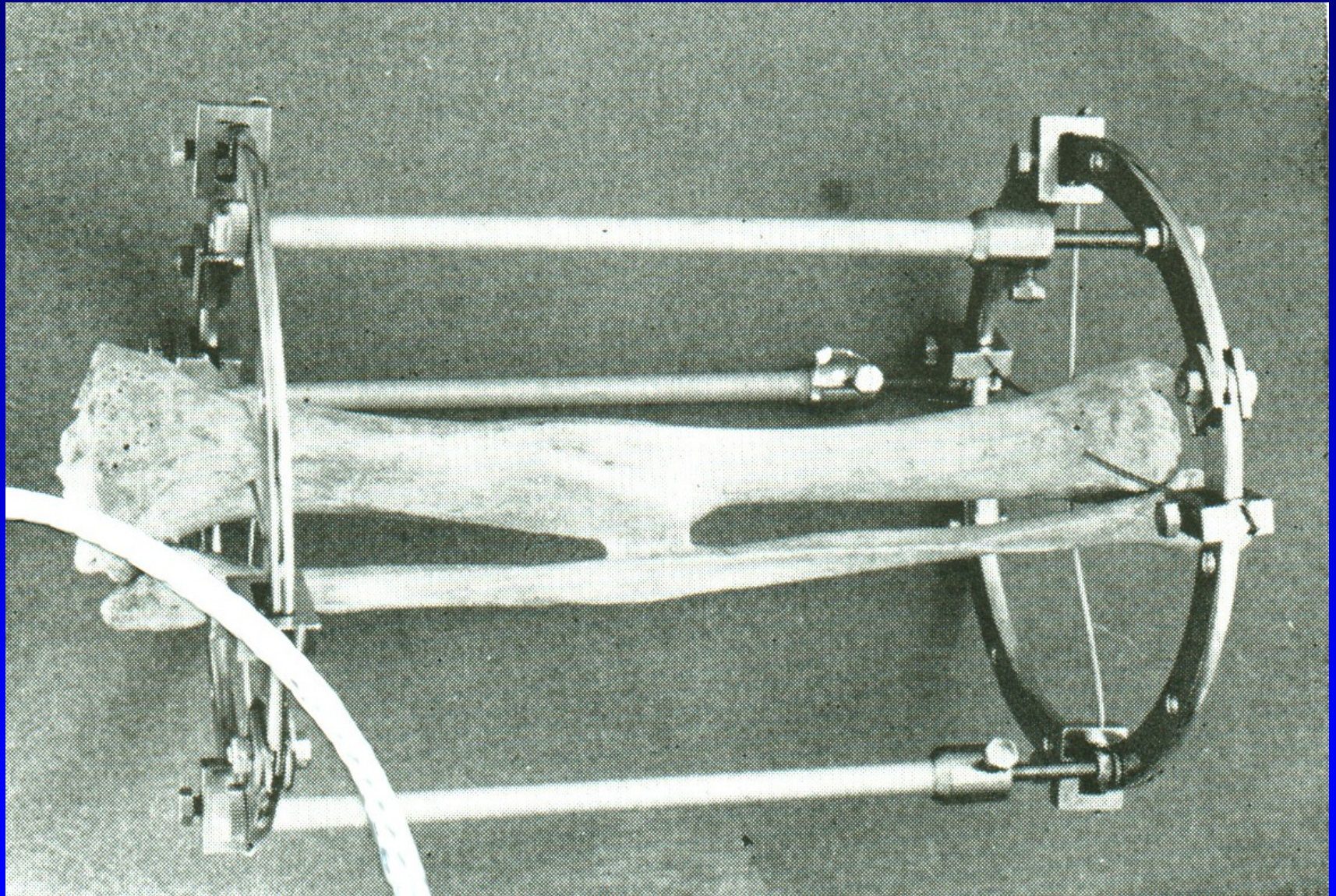
External fixator



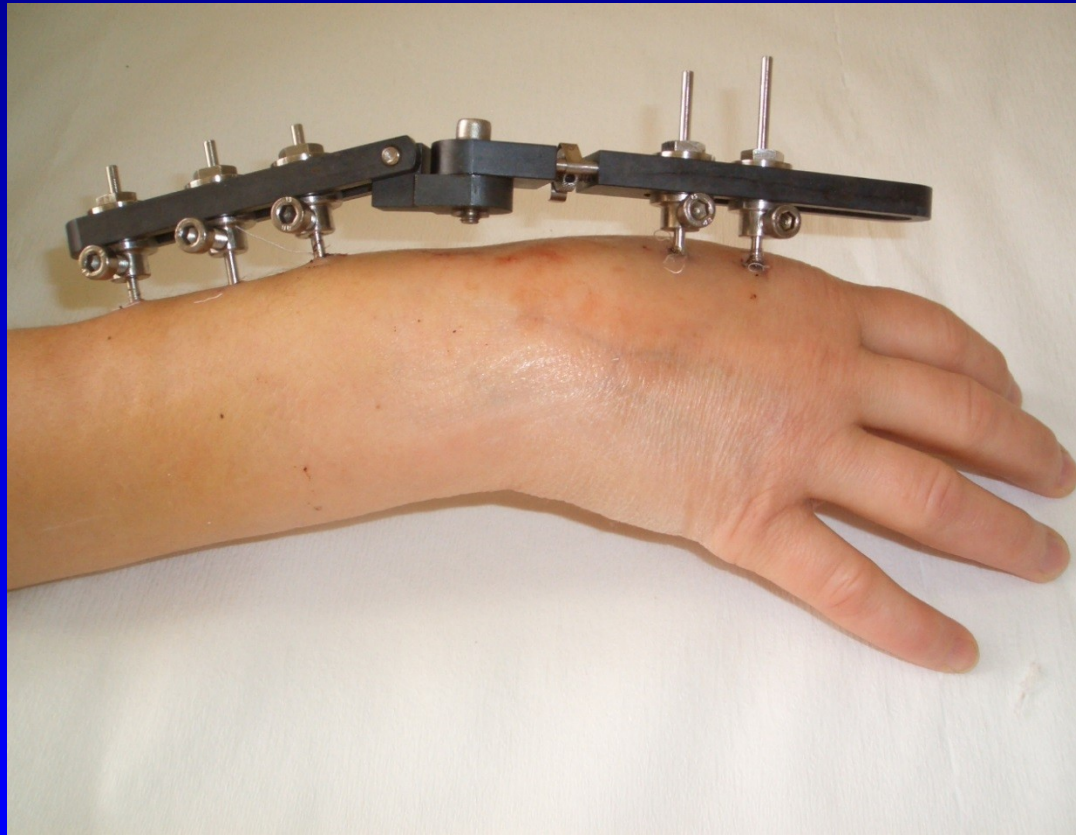External fixator



External fixator - Ilizarev



External fixator of the wrist



Fractures in children

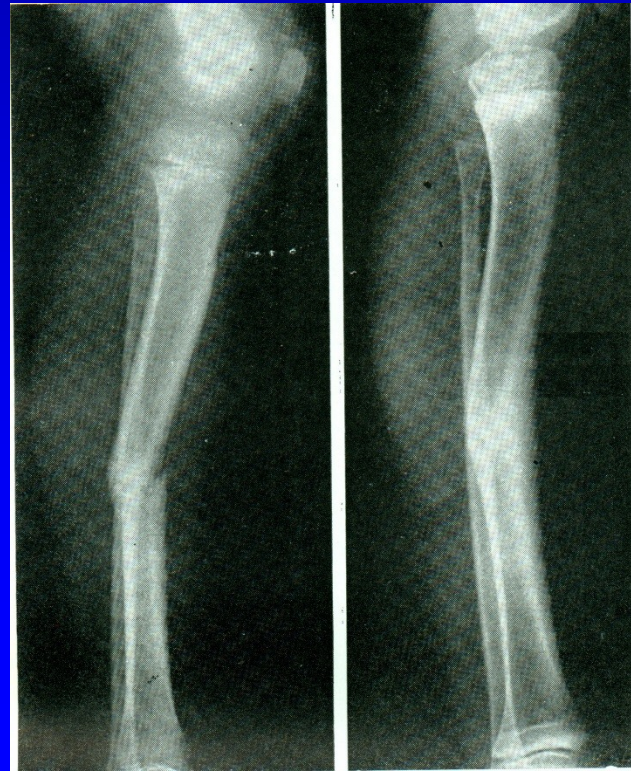
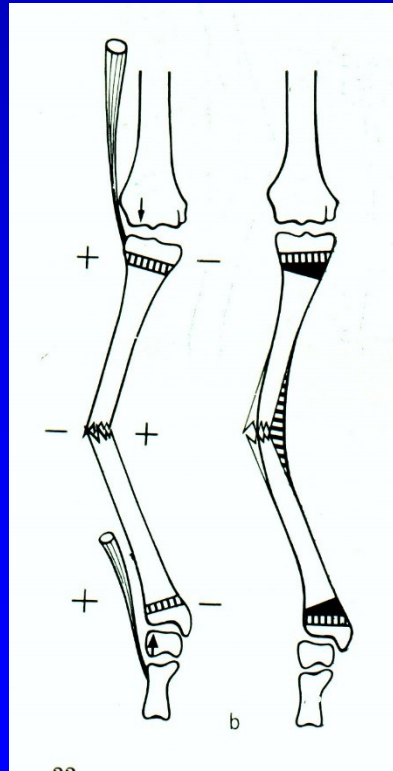
- Fast healing
- Many fx. healed by conservative methods
- Few complications

Remodelation

Remodelation (dislocation ad latus, ad axim, in antecurvation or recurvation) can heal properly.

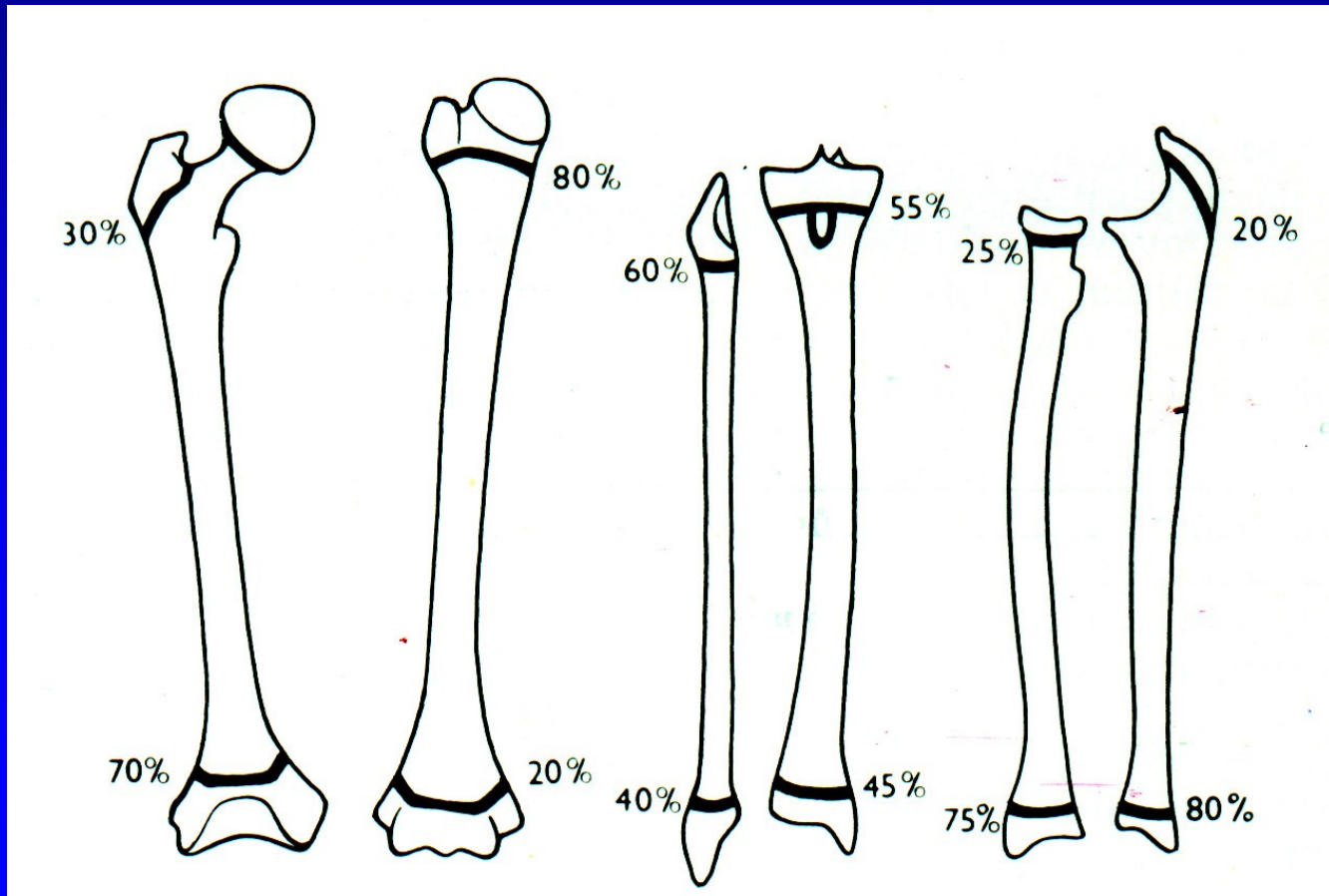
Depends on age and site to growth plate.

Dislocations ad peripheriam should be reduced.



Fractures in children

- growth plate – lengthening of long bones
- damage of growth plate – disturbance of growth



Fractures in children

- Strong periosteum, elasticity of bone (green stick fractures)
- Subperiosteal haematoma.
Ossifications of haematoma
- Ligaments are elastic
 - epiphyseolysis is common
 - fracture is less common

Epiphyseal injuries - Salter- Harris

- in 15 % of cases

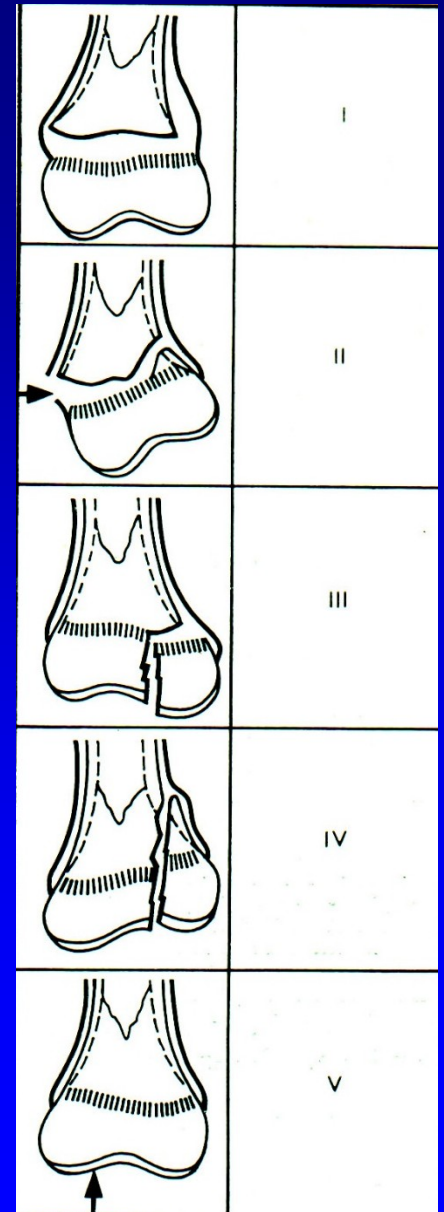
1. Epifyseolysis

2. Fx. of epiphysis- Holland triangle

3. Fx. of epiphysis

4. Fx. epiphyseometaphyseal

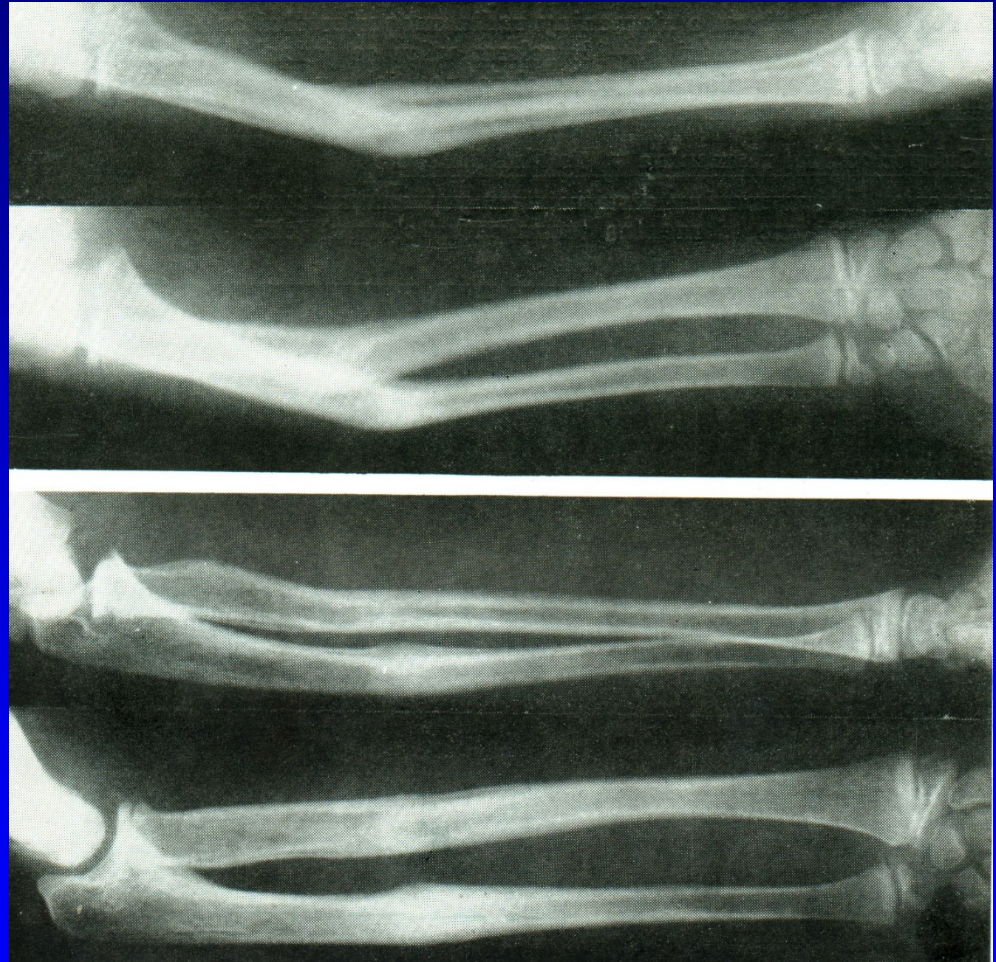
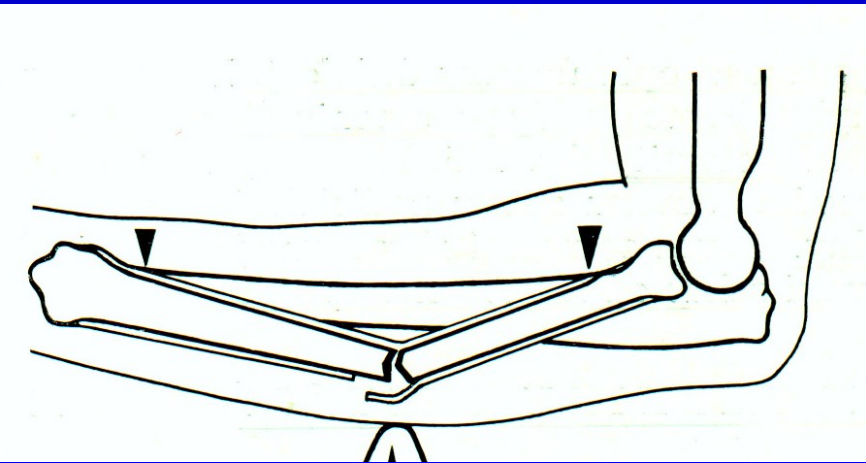
5. Contusion of epiphysis



Green stick fractures

Bone is broken
in a periosteal sleeve

Periosteum is not disrupted



Physiotherapy

- Physiotherapy in children is easier than in adults

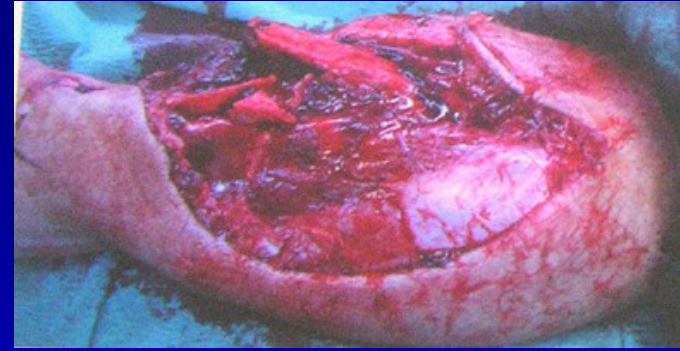
Componed (open) fractures

Damage of skin

Damage of soft tissues

Bacterial contamination

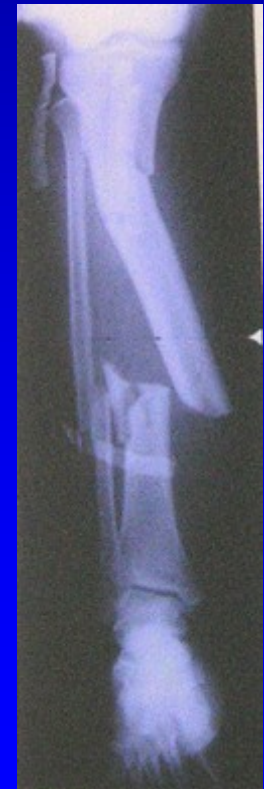Classification of Gustilo and Anderson



1 stage – puncture of skin from bone fragment
low energy trauma

2 stage – open fracture without defect of skin and
soft tissue

3 stage – wound with defect of skin and soft
tissue, high energy trauma



Tscherne clasification

Closed fr.

G0 no damage to soft tissues

G1 superficial excoriations

G2 deep excoriations

G3 contusion of the skin, decollement, damage of muscles

Open fr.

O1 puncture wound from bone fragment, small wound

O2 wound without loss of skin

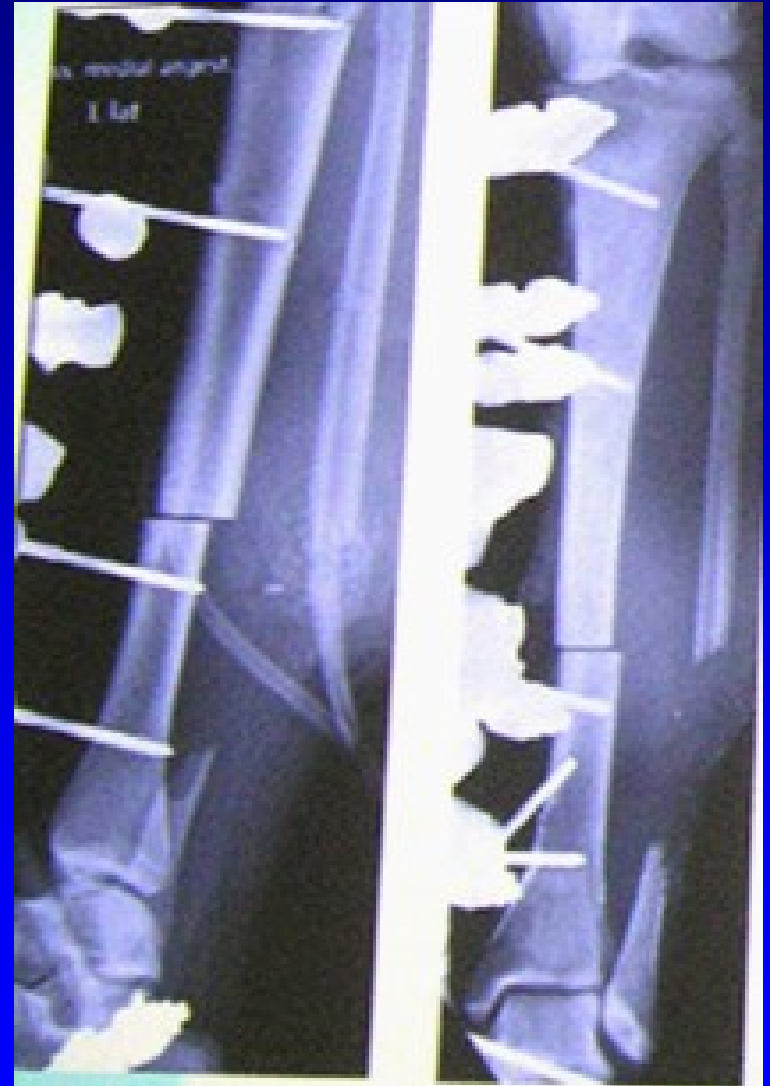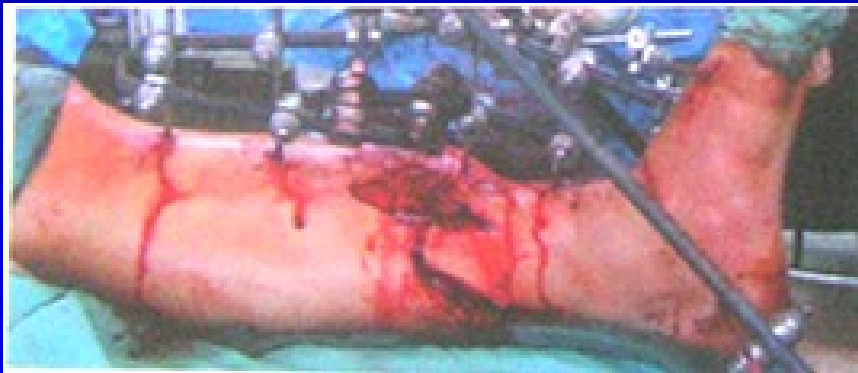
O3 large wound with loss of skin

O4 subtotal amputation

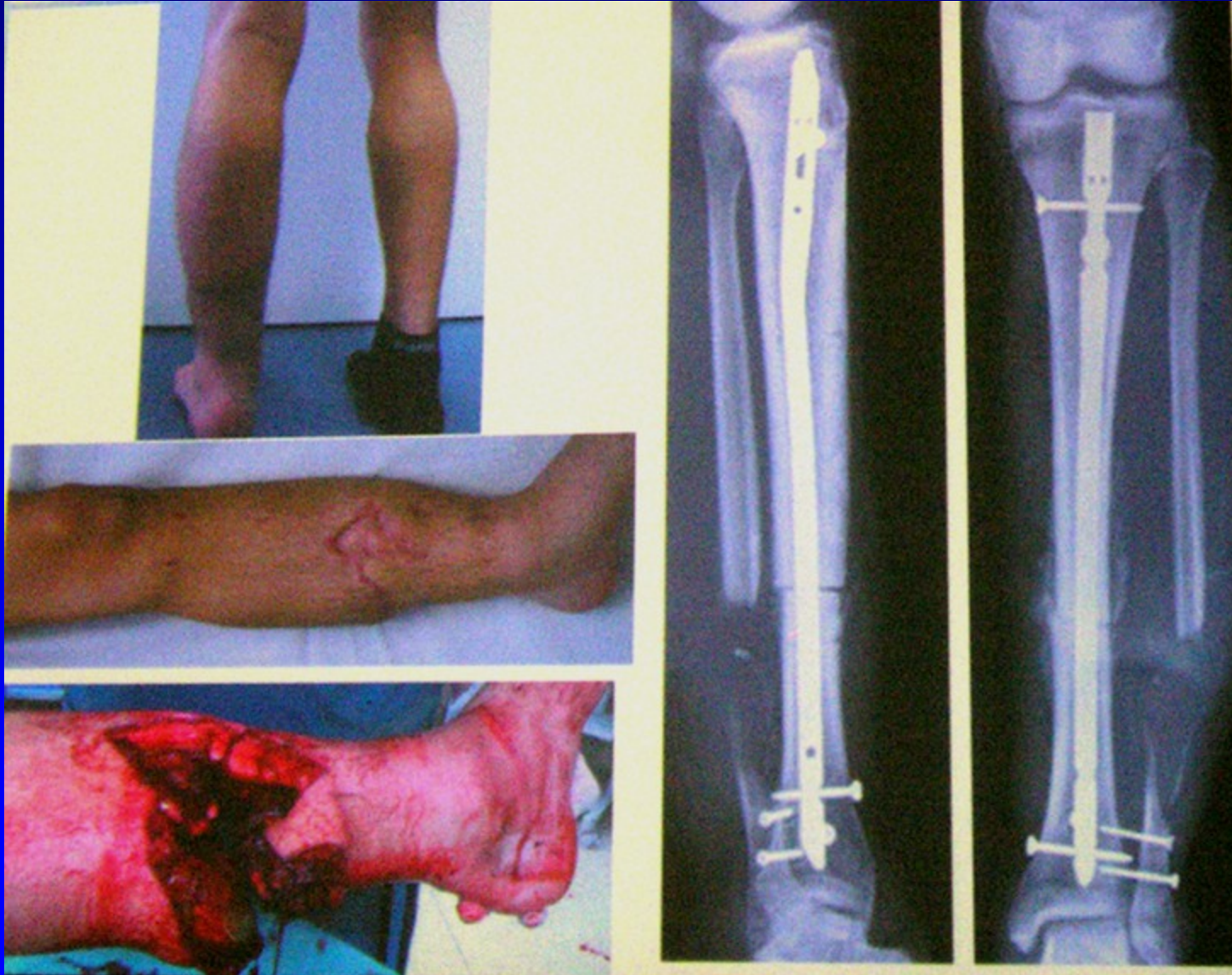
Management

- Surgery as soon as possible
- 1. Cleaning of skin
- 2. Debridement of wound (removal of foreign bodies, excision of dead parts, lavage)
- 3. Open reduction, stabilisation with external fixator, suction drainage, suture of skin without tension

Management

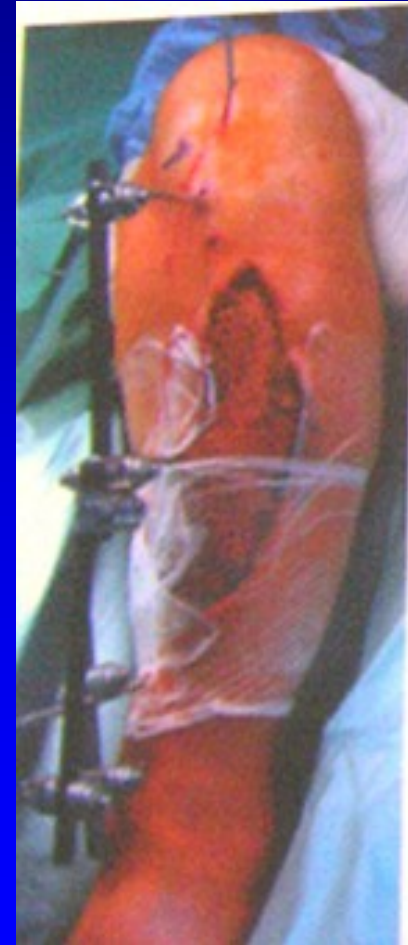

Conversion to the intramedullary nail



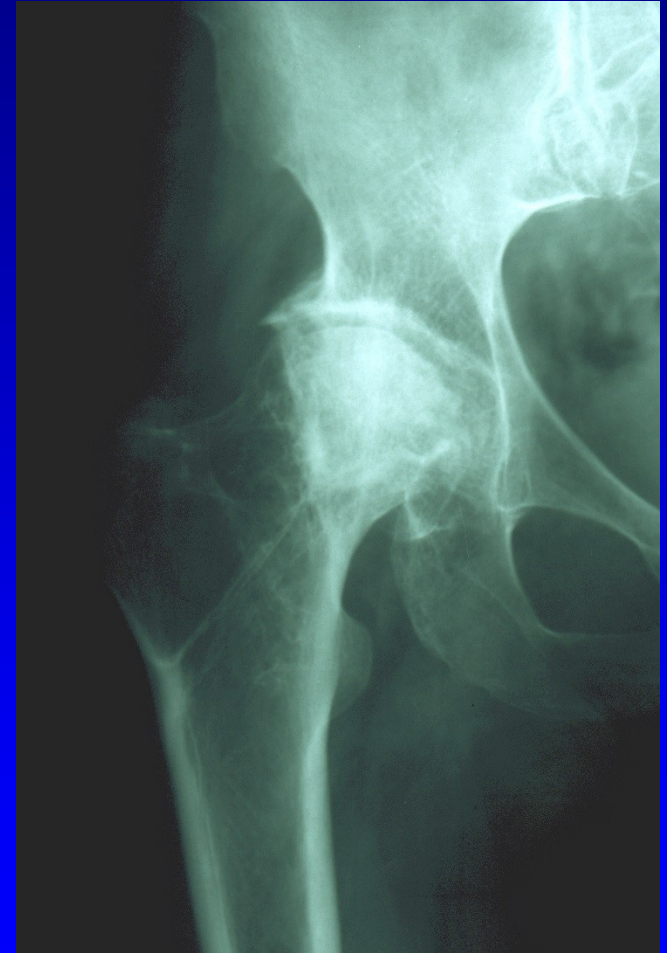Management

- Musculocutaneous flap
- Antibiotics
- Tetanus prevention
- Antigangrenous serum
- Prevention of phlebotrombosis



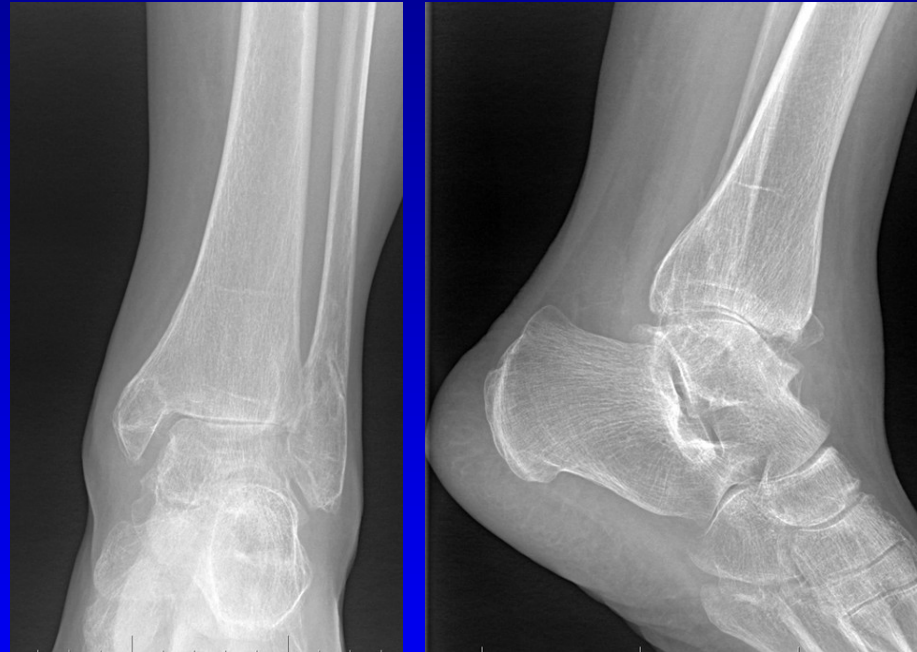Disturbance of fracture healing

- Malunion- fractura male sanata
- Hypertrophic callus
- Delayed union
- Avascular necrosis of epiphysis
- Nonunion: aseptic, septic
vital, nonvital
- Refracture

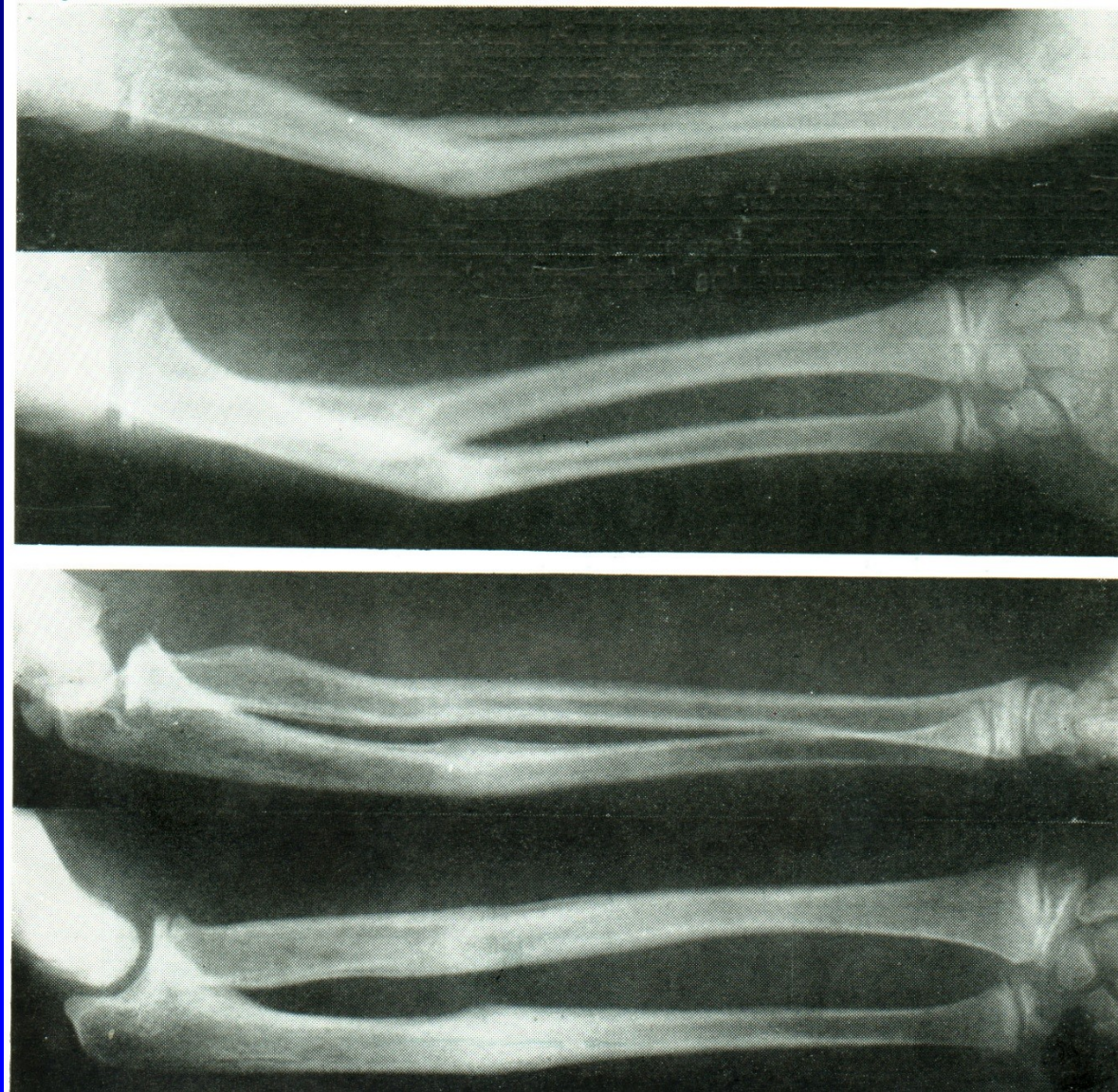


Consequences of fractures

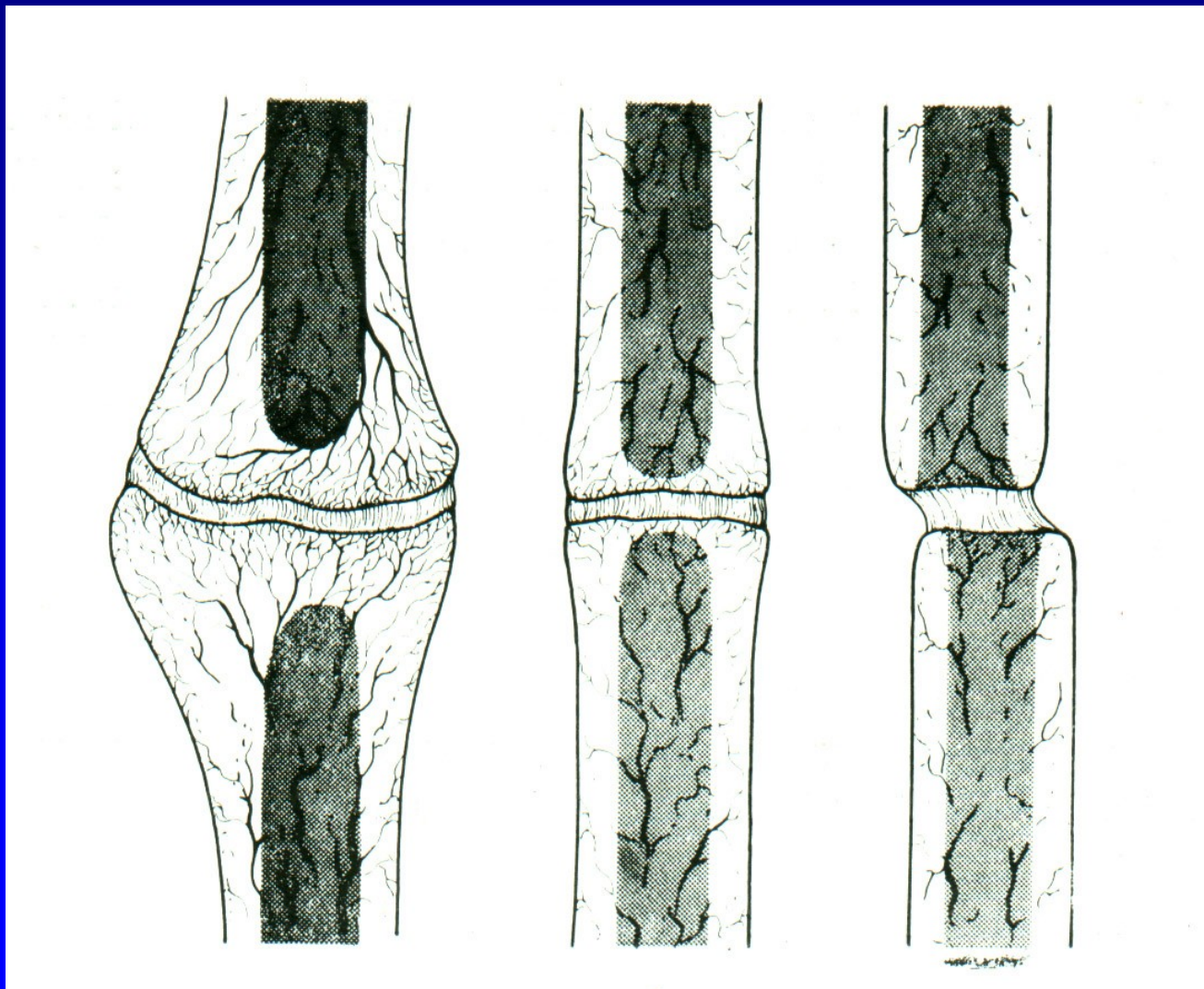
- Growth arrest
- Shortening of bone
- Paraarticular ossifications
- Osteoarthritis
- Limites movements in joint



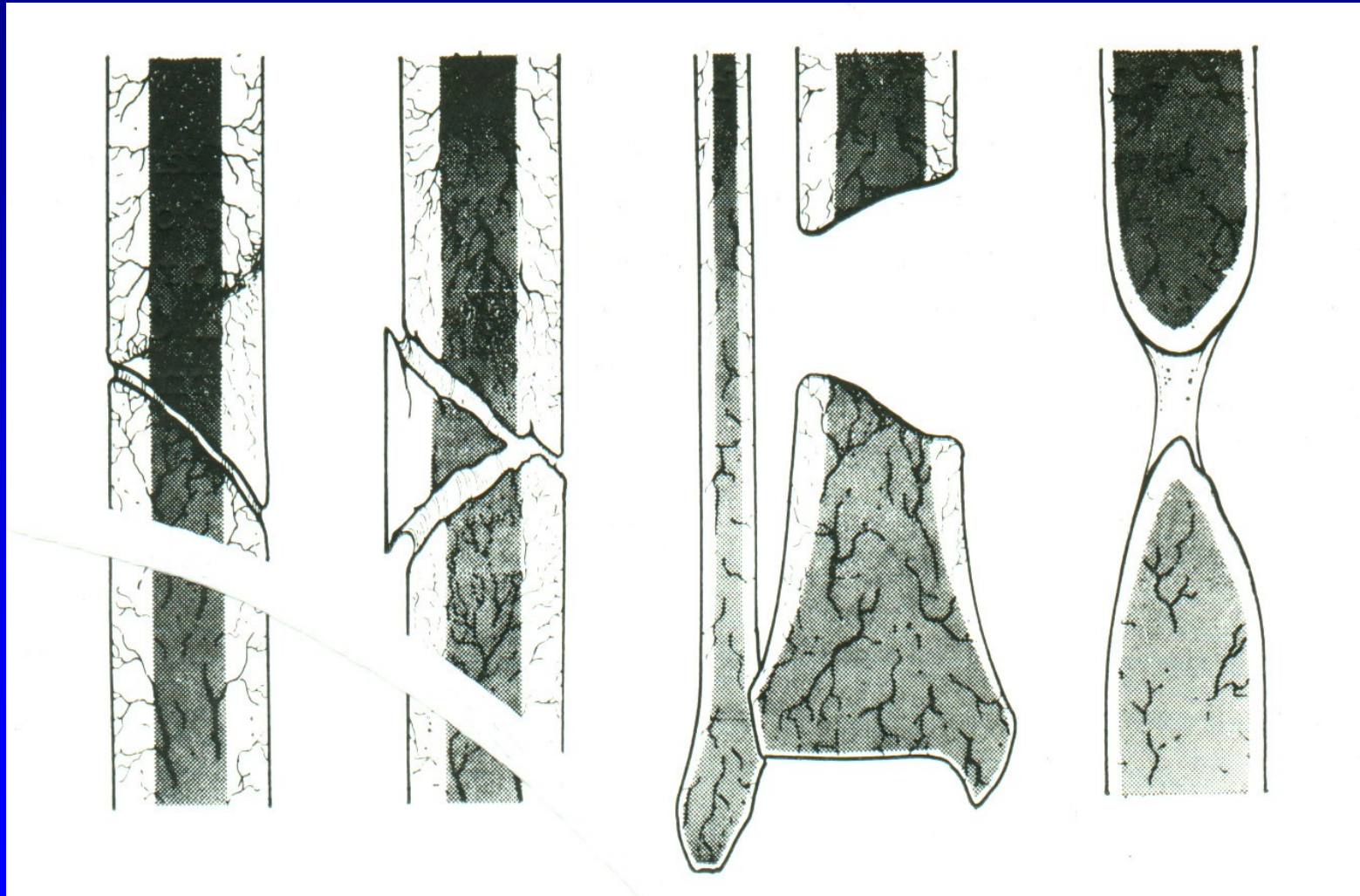
Malunion



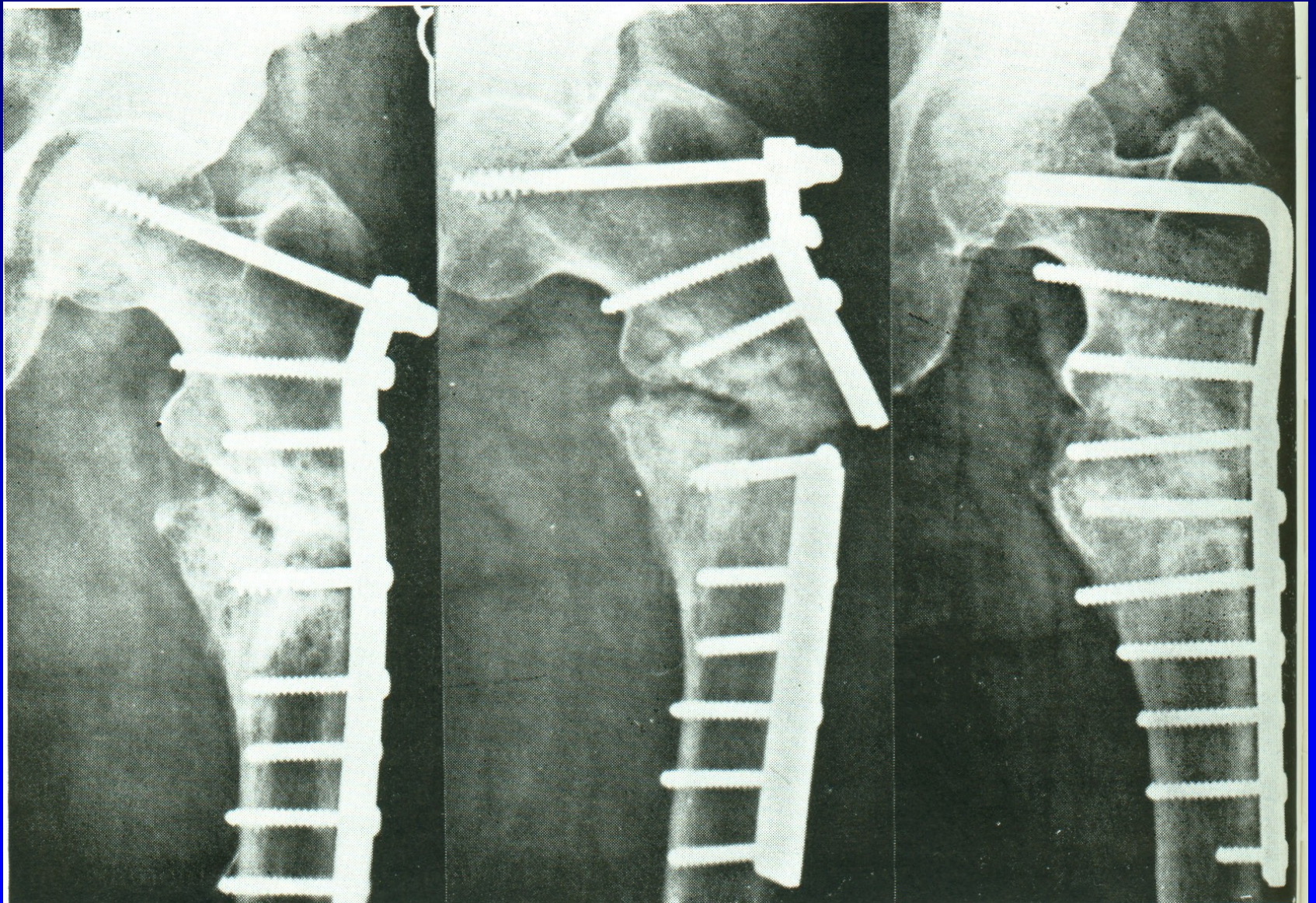
Vital nonunion



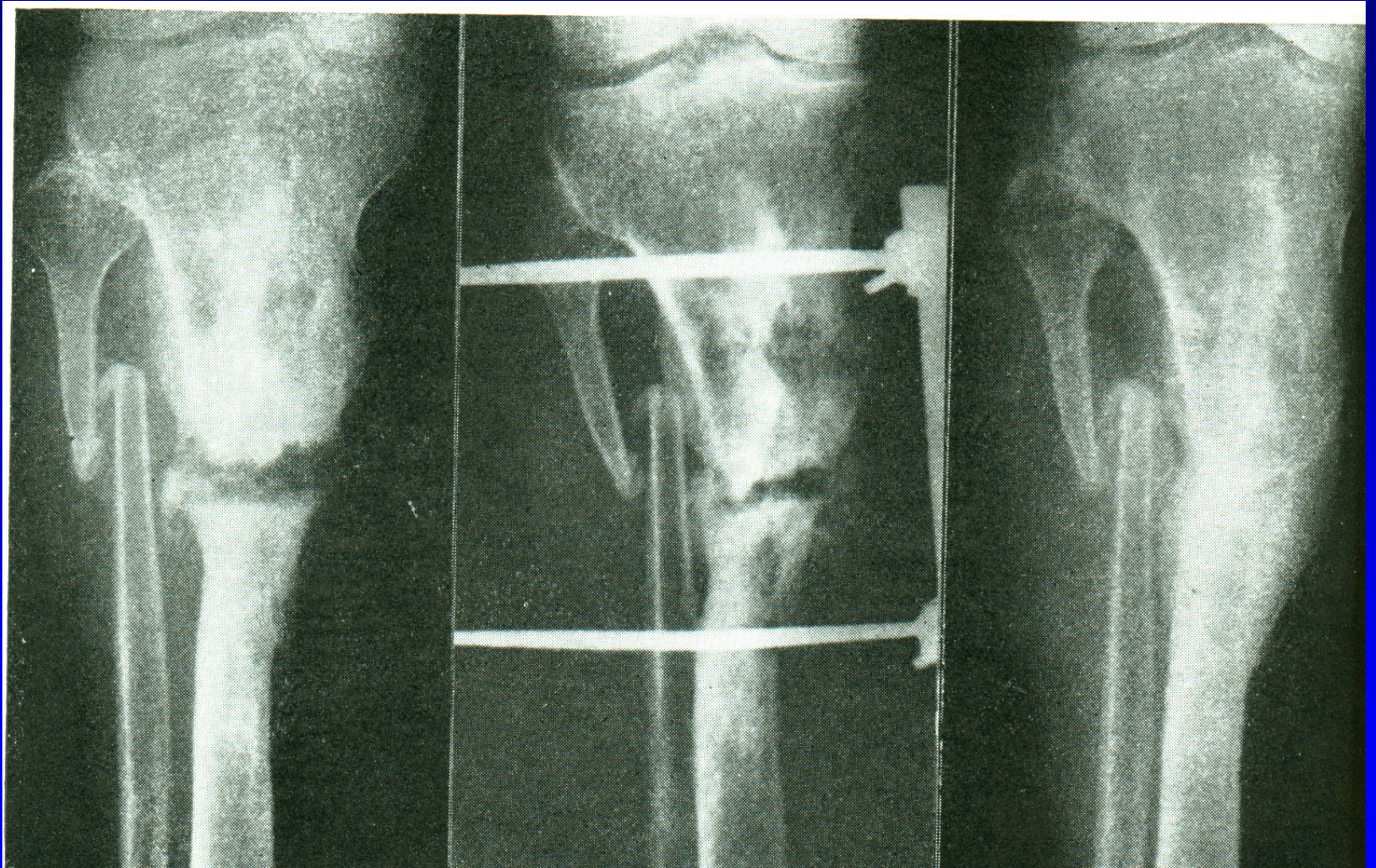
Avascular nonunions



Pseudoarthrosis of the femur



Pseudoarthrosis of the tibia



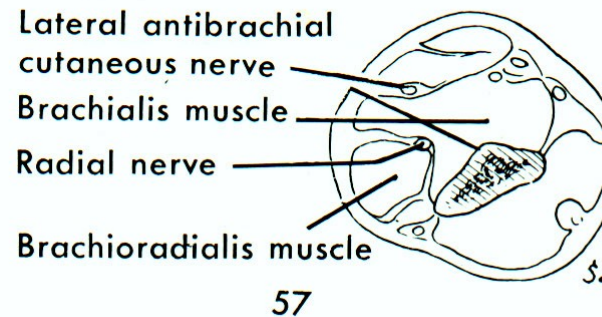
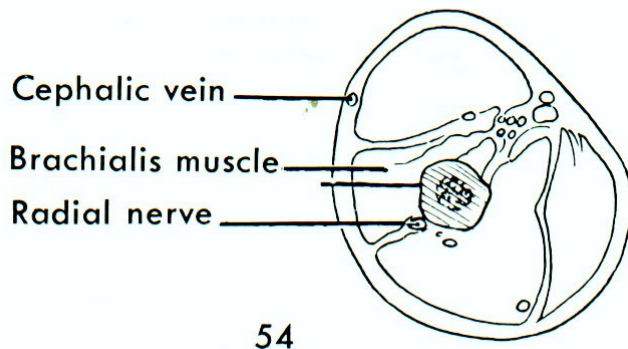
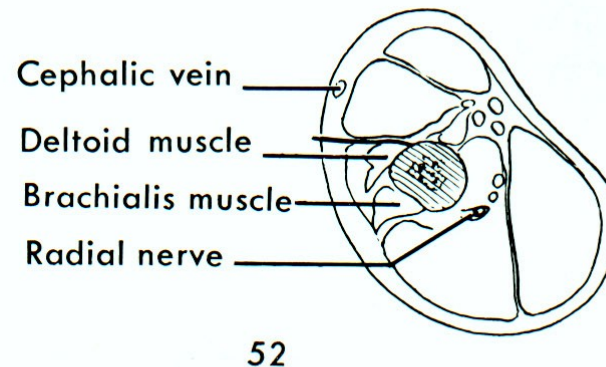
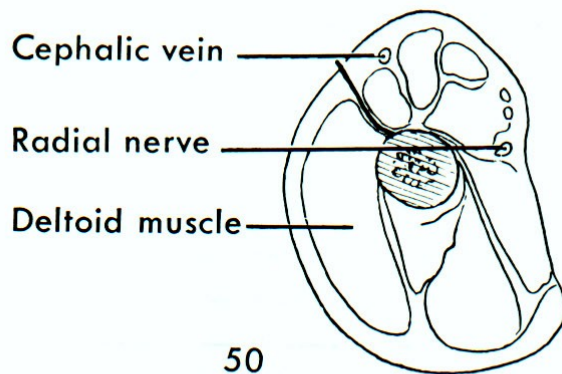
Complications of fractures - local

- Soft tissue damage:
vessels, peripheral nerves, muscles,
surrounding tissues
- Infection
- Compartment syndrom
- Algoneurodystrophy

Compartment syndrom- CS

Physiological pressure in tissue: 0 - 6 mm Hg

Pathological pressure in CS -tissue : 30- 40 mm Hg



Compartment syndrom

Hematoma

Swelling

Tight bandage ,tight plaster of Paris

Severe contusion

Tight suture of fascia

Compartment syndrom

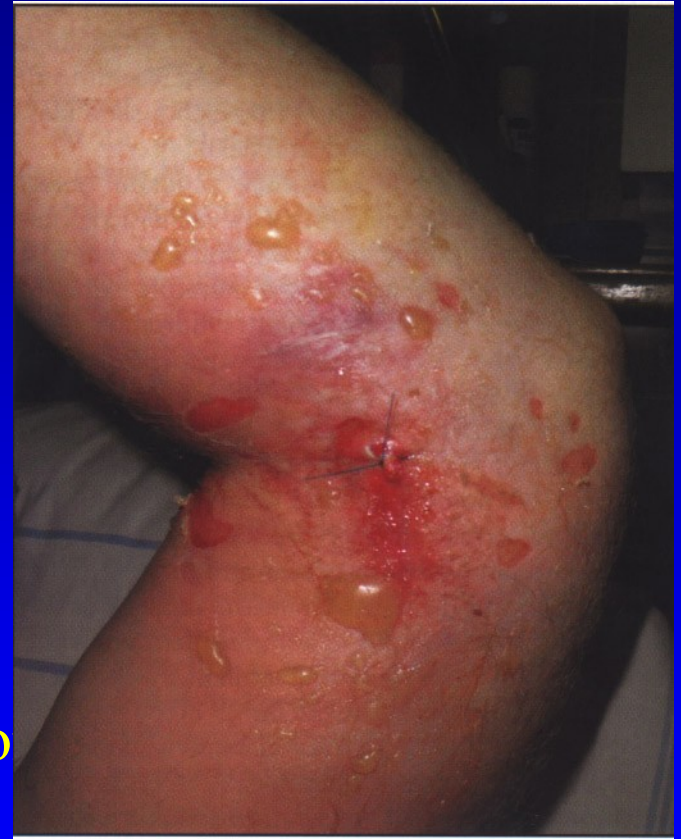Pain
Pallor
Paresthesia
Paralysis
pulselessness

Normal preasure 3-10 mm Hg

Above 30 mm slow doen od circulatio

Piesoelectric sensor

Indication for fasciotomy mpre than 30-45 mm Hg

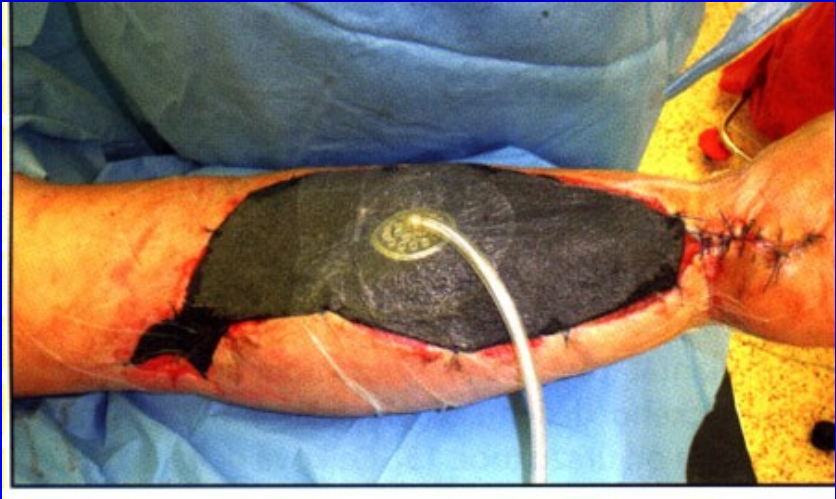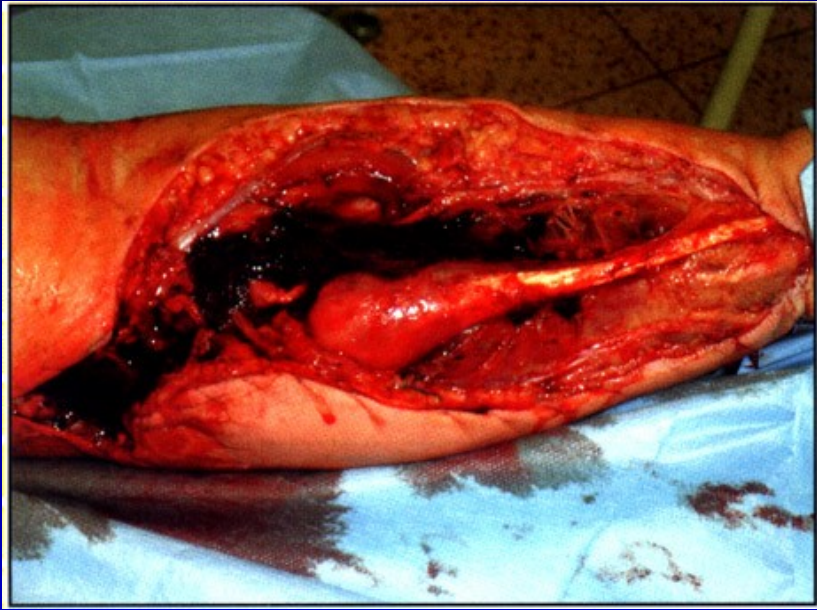


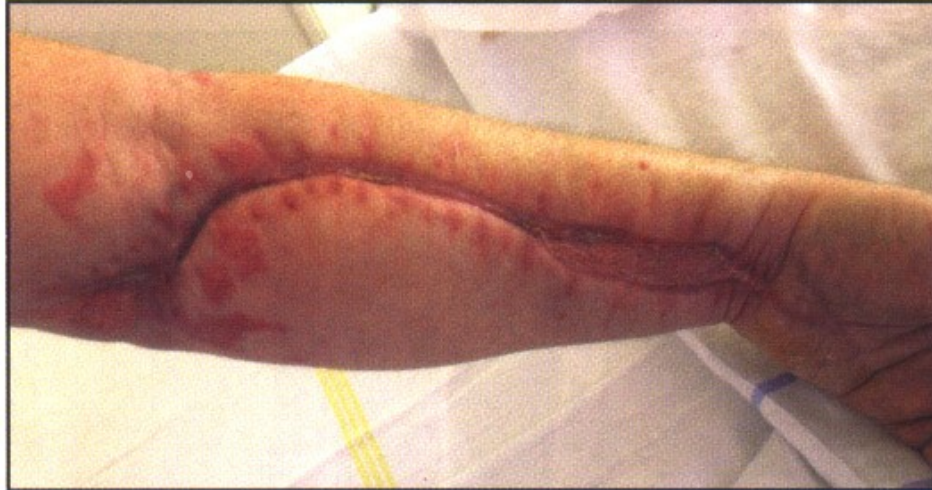Symptoms

- Pain – intensive and growing
- Swelling- increasing
- Cold periphery, cyanosis
- Parestesia, hyperestesi, numbness of toes
- Diminished motor function (from ischemia)
- Diminished puls in periphery

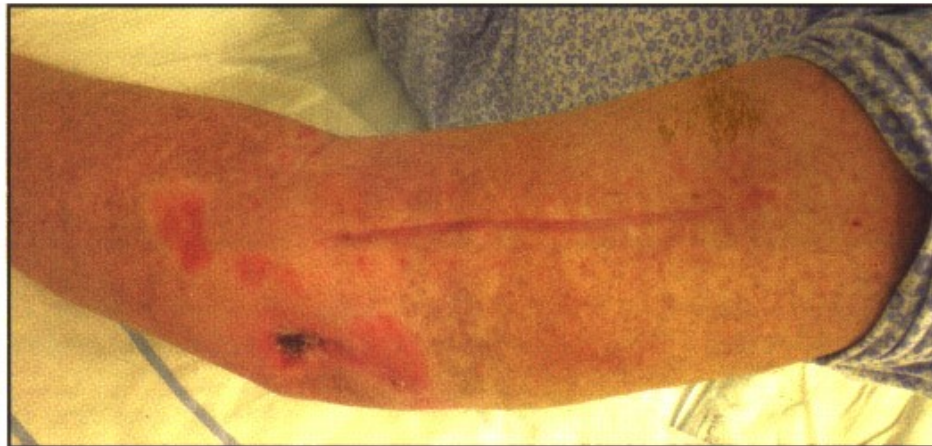Management of CS

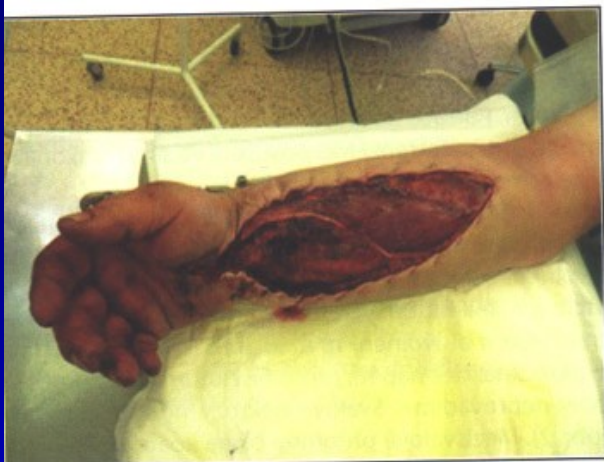Urgent fasciotomy



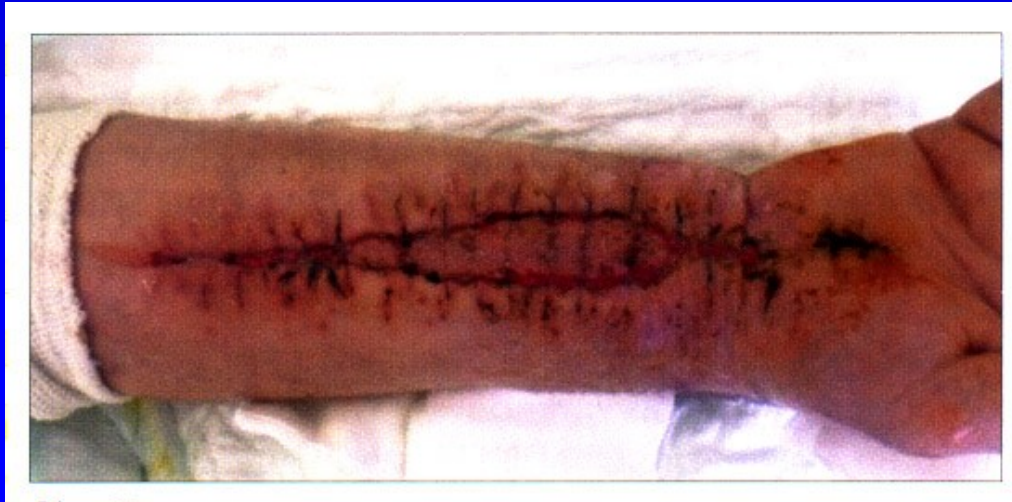
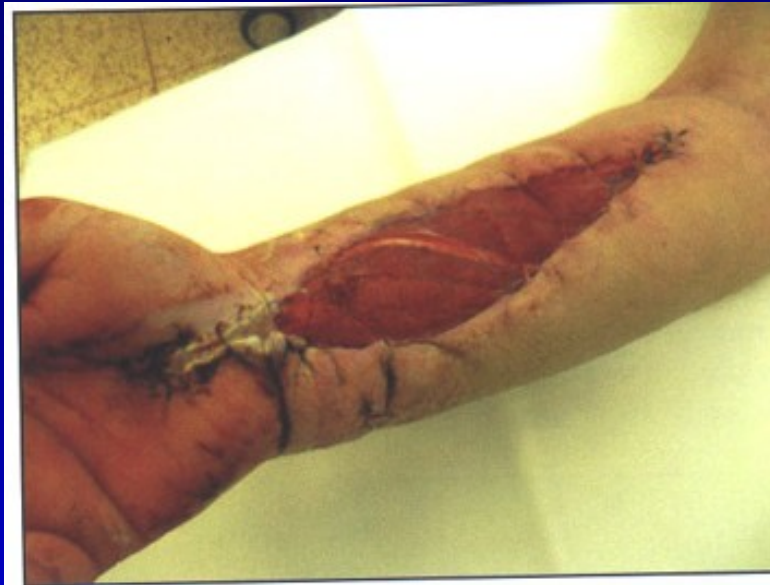
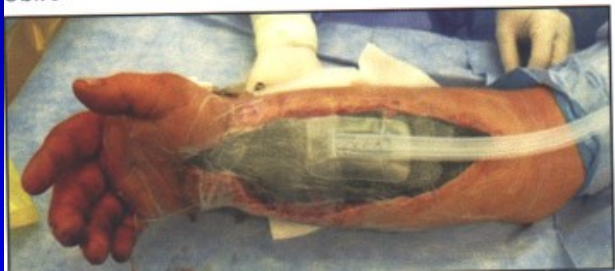Obr. 5





Obr. 9



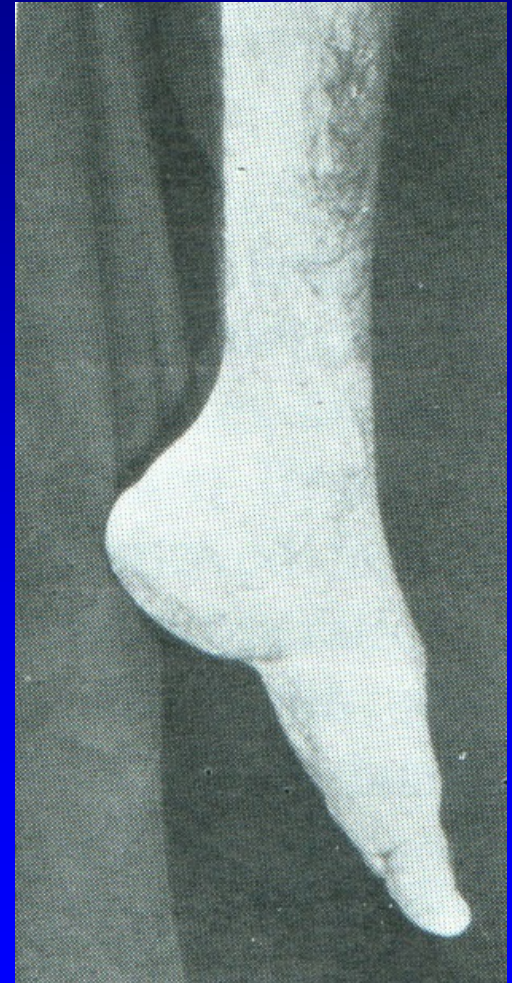Compartment syndrom - consequences

After 6 hours – irreversible damage to muscles

- Change to fibrous filaments
- contracture of muscles

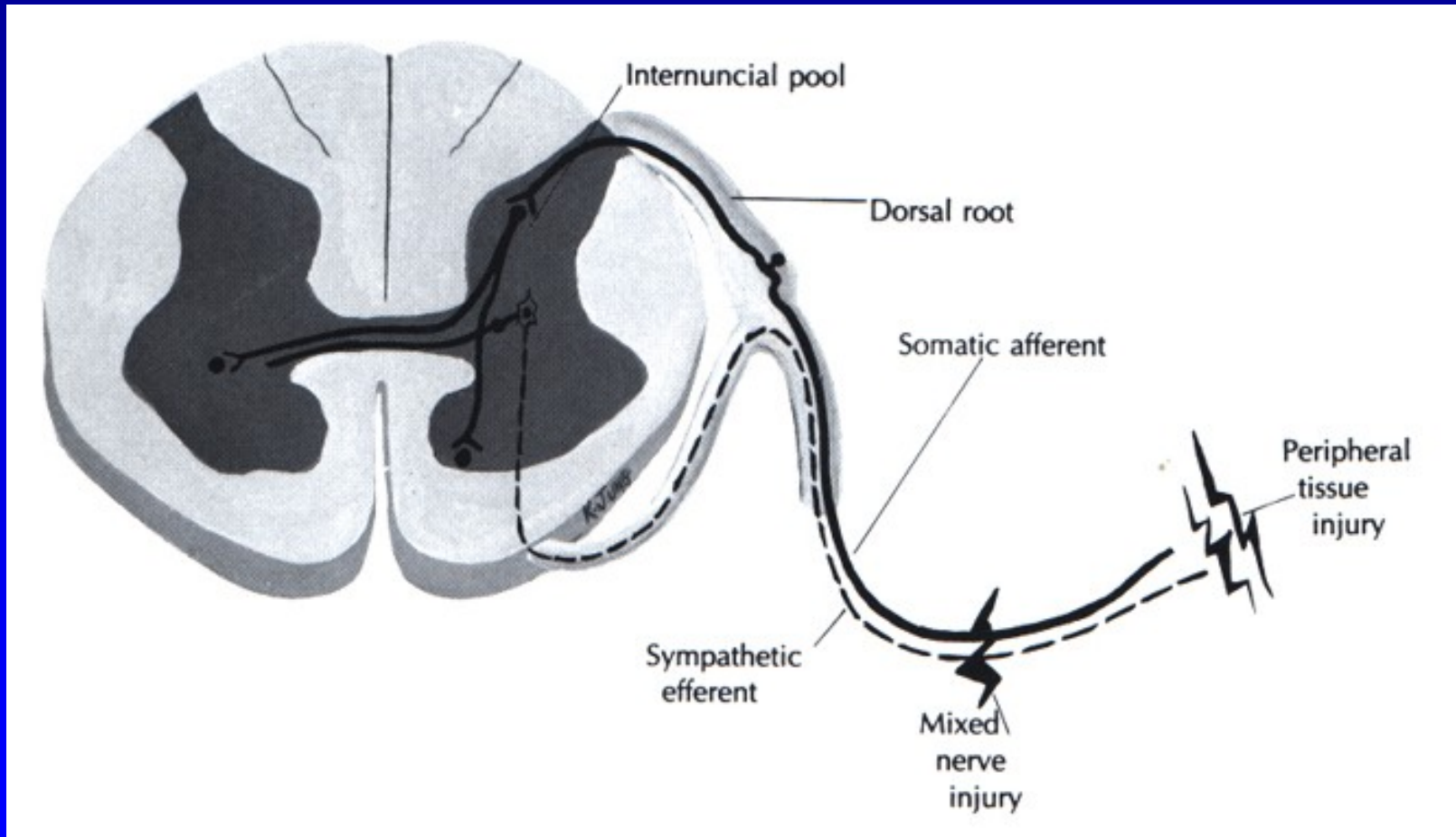
After 12 hours

- Irreversible damage to nerves



Algoneurodystrophy

Reaction of sympathetic nerves to the injury

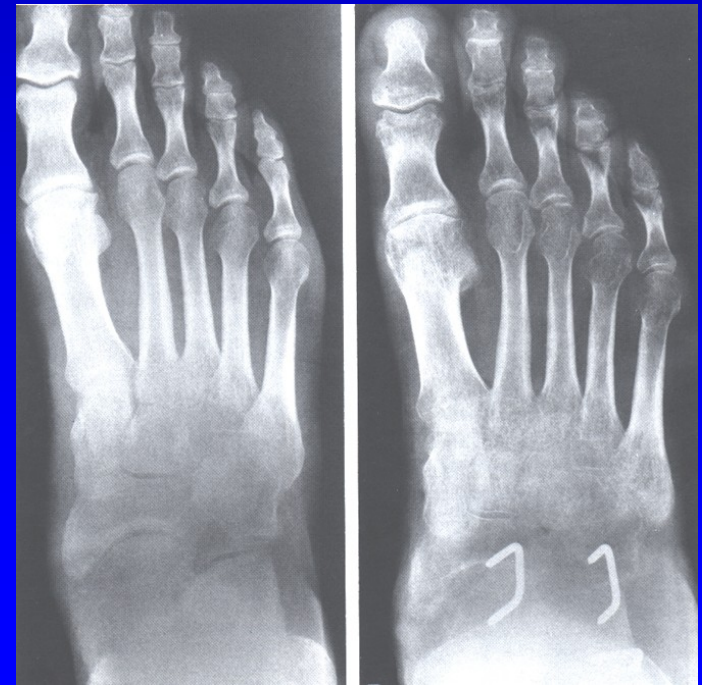
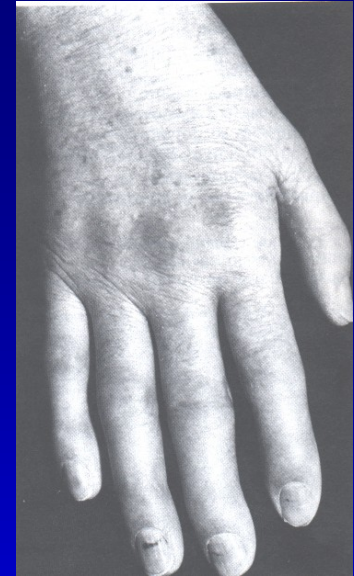
Algoneurodystrophy

1. Stage - hyperemia, 0- 3 months
pain, swelling, hyperesthesia

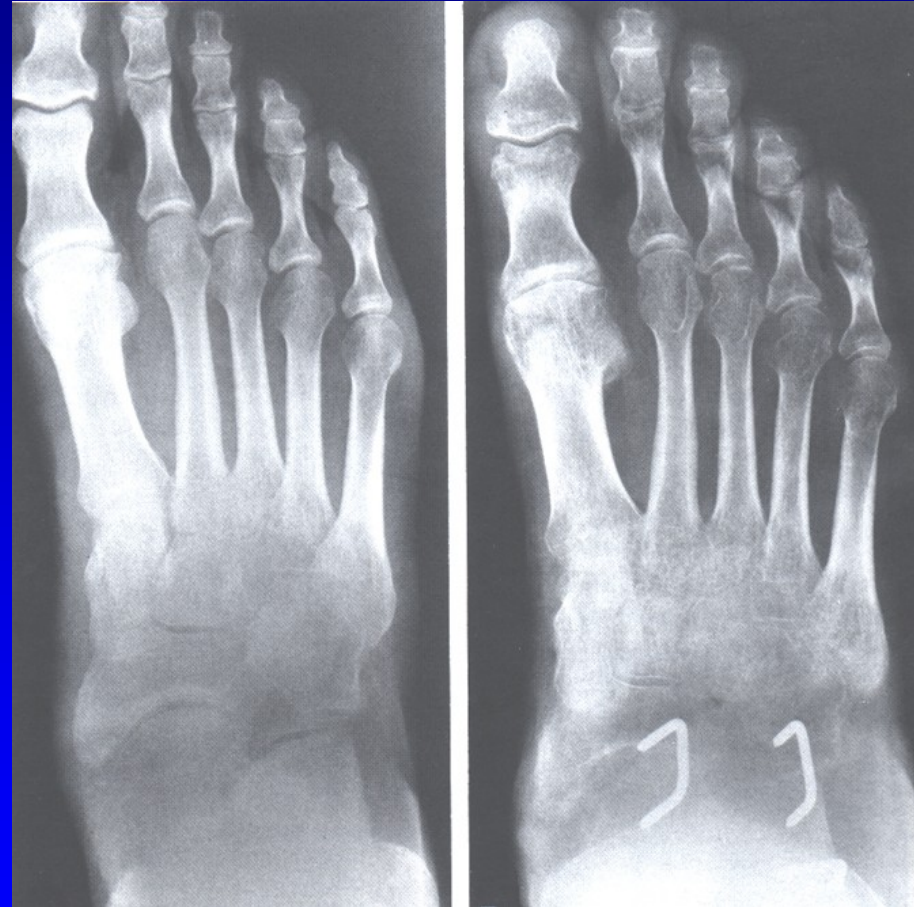2. Stage - dystrophy
plastic oedema, cold periphery,
thin skin, limited movements,
X-ray - osteoporosis

3. Stage - atrophic
atrophic skin, muscles, limited
movements



Algoneurodystrophy -management

Short immobilisation
Drugs against swelling
Analgetics, sedative drugs
physiotherapy
Sympaticolytics
Regional blocks
Corticoids
Calcitonin, alendronate
Physioterapy after removal of
bandage



Complication of fractures - general

Hypovolemic shock

Cardiopulmonar arrest

Fat embolism

Haemorrhagic complications


Disseminated intravascular coagulopathy

Trombembolism

Complication of fractures - general

- Fracture disease:
 - bronchopneumonia
 - Phlebotrombosis, pulmonary embolism
 - Pressure sores
 - Urinary tract infection
 - Weakness
 - Muscle atrophy and contractures

Garden classification



Head prosthesis

Over 80 years

Minimal blood loss

Immediate weightbearing

Disadvantage:

Erosion of the cartilage of the acetabulum







