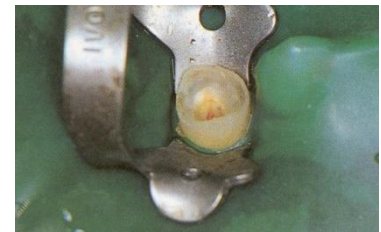

Endodontic treatment – from  
access to the working length

# Phases of the endodontic treatment

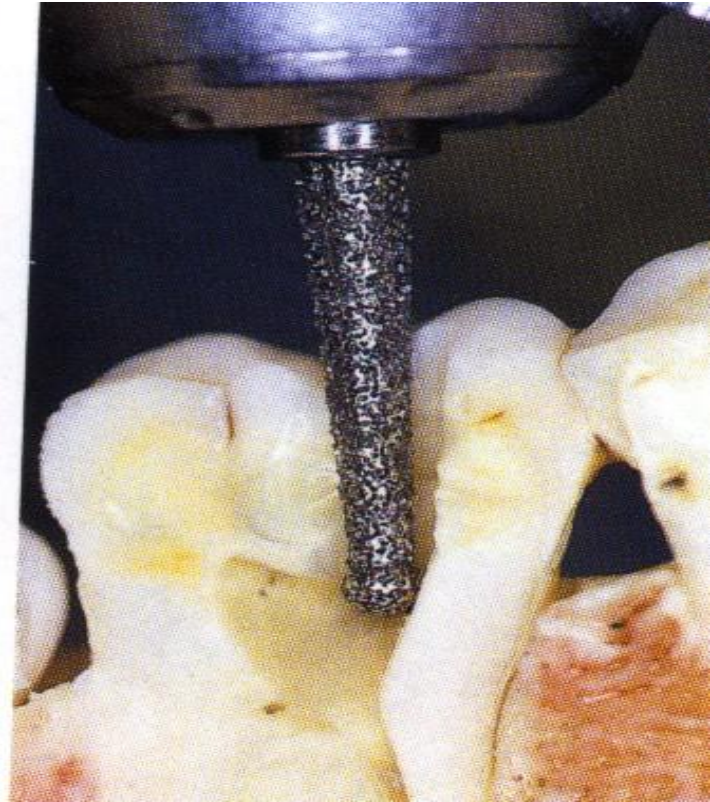
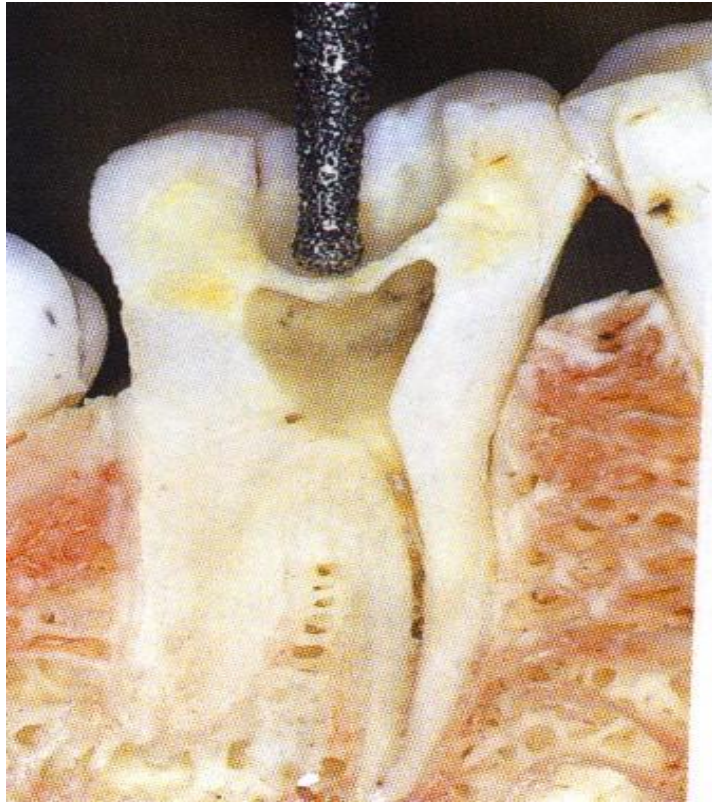
- **Investigation, diagnostic radiogram, consideration ( local, regional, systemic factors)**
- **Removal of old fillings, carious dentin, temporary restoration - contours of treated tooth.**
- **Dry operating field**
- **Preparation of the access (endodontic cavity)**



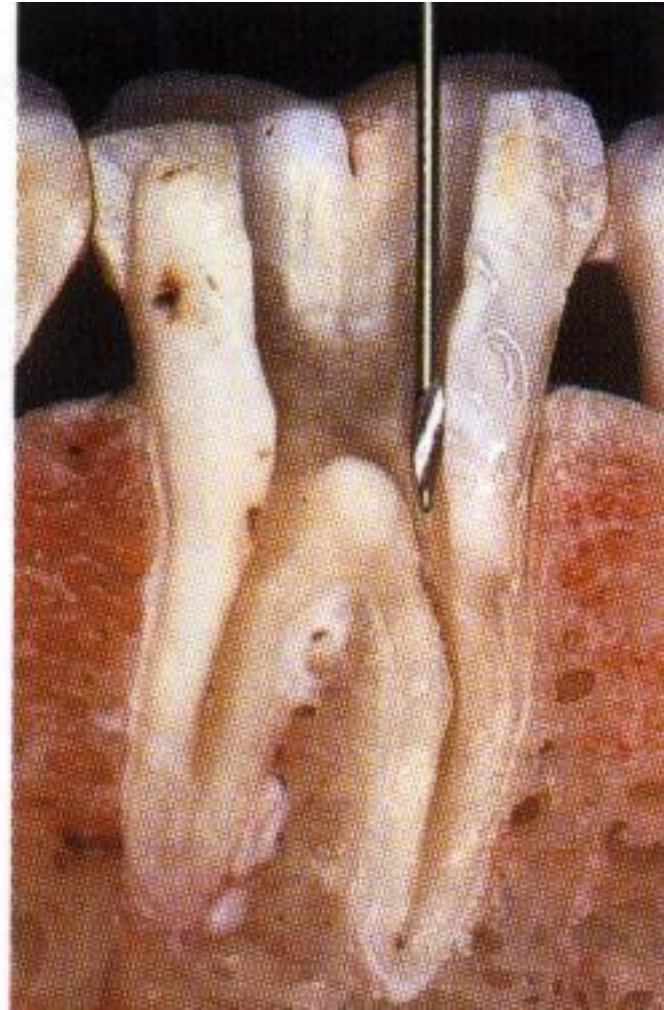
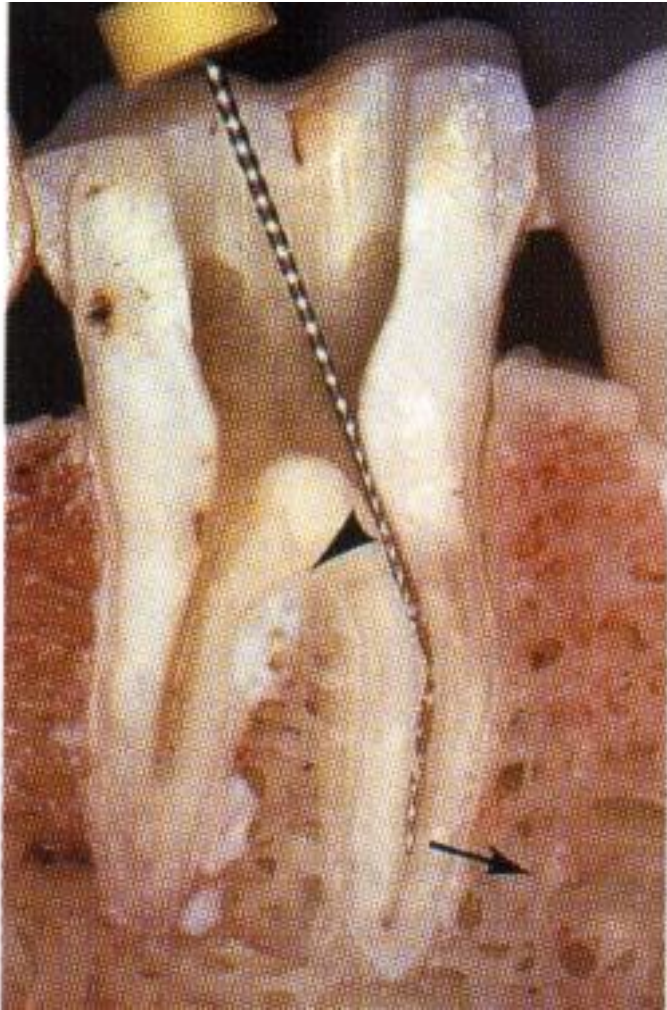
# Phases of the endodontic treatment

- **Opening of root canals**
- **Initial flaring and removal of content of root canal**
- **WL (working length)**
- **Root canal shaping and cleaning (irrigation)**
- **Rekapitulation**
- **Drying**
- **Filling**
- **Radiogram**
- **Postendodontic treatment**

# Access

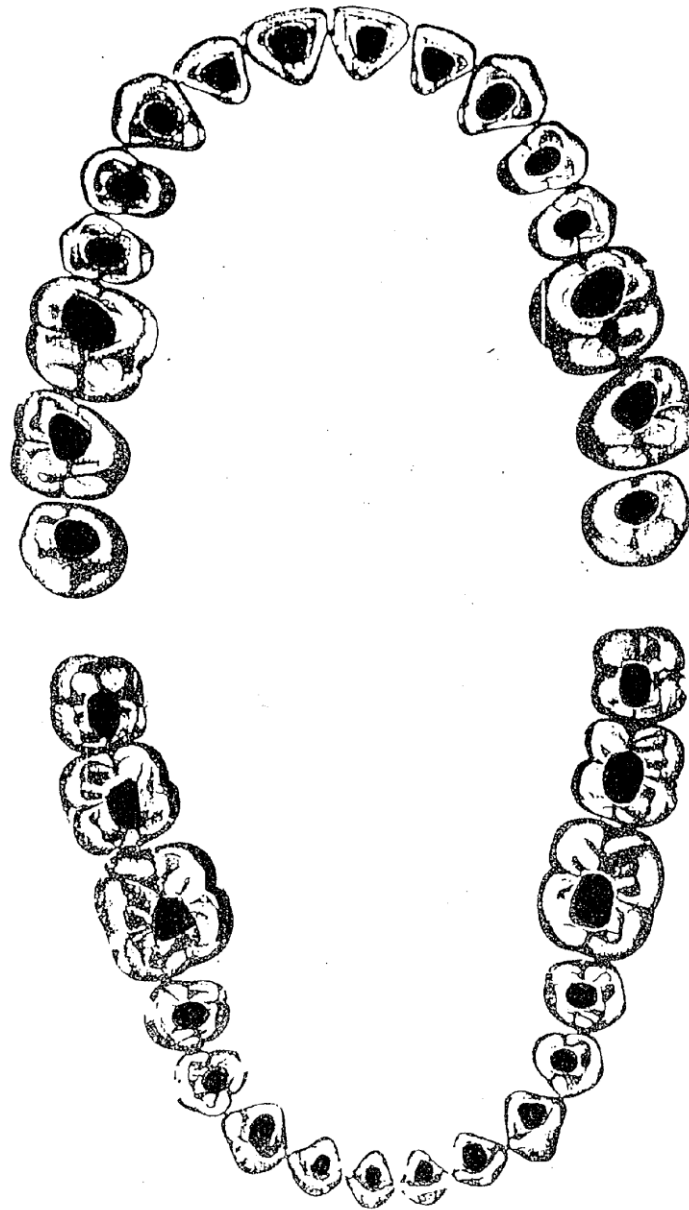


# Opening of root canal orificies

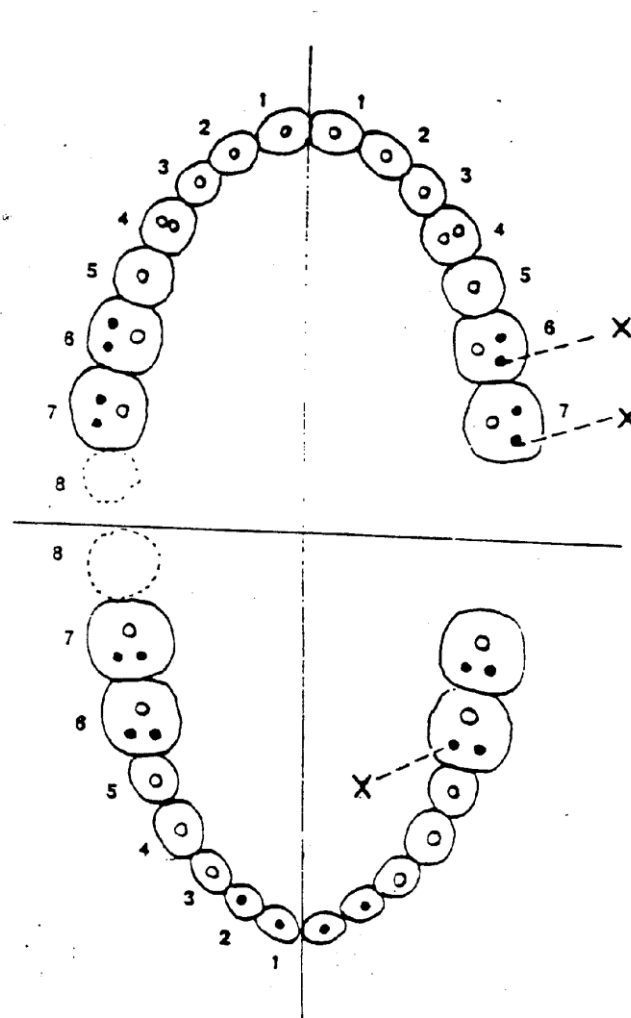


Shapes of endo cavities

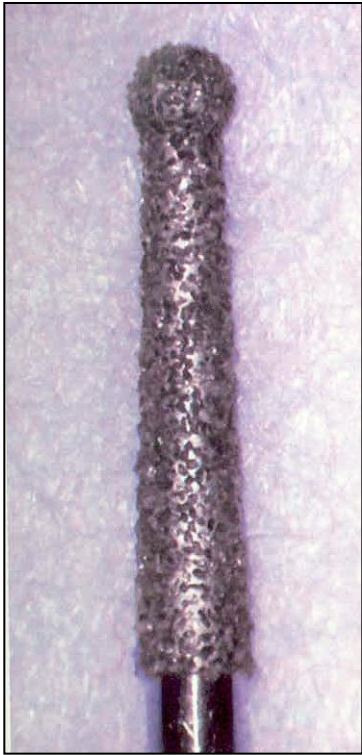
See special material on is



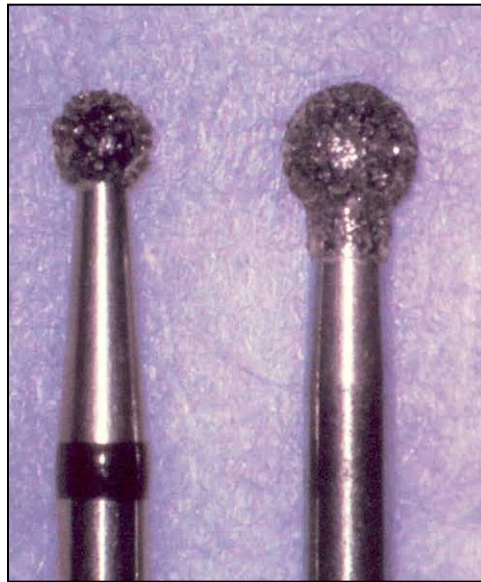Number of root canals  
First upper molar – 4 root canals



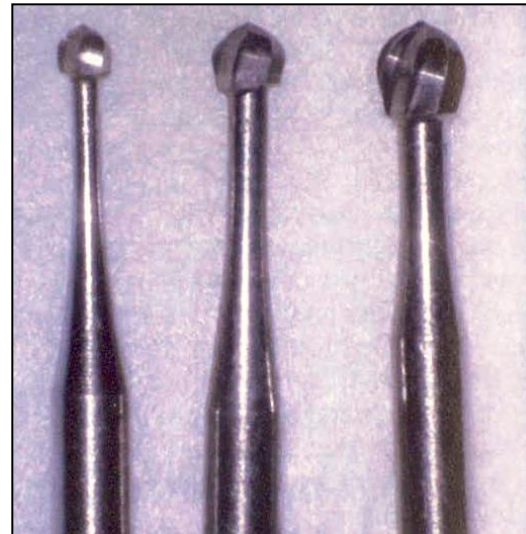# Instruments



Dia trepan



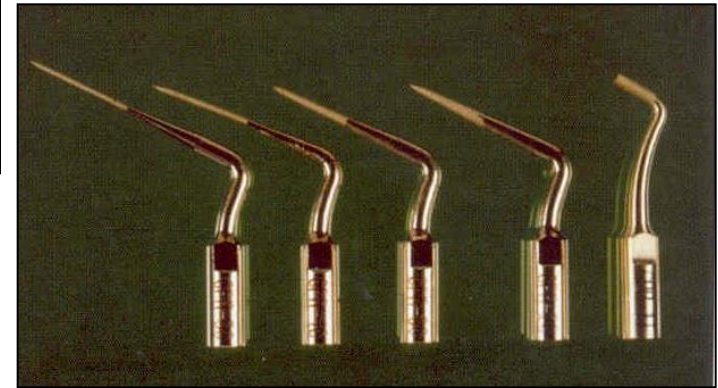
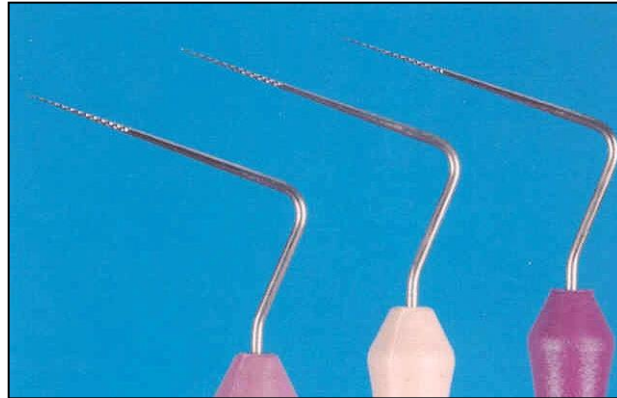
Dia balls



Ball burs



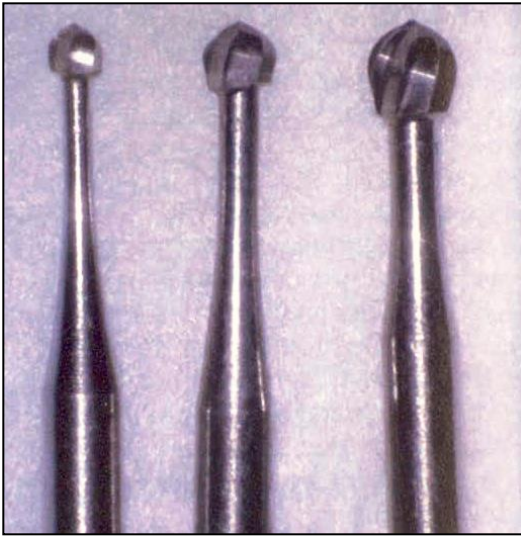# Find of root canals



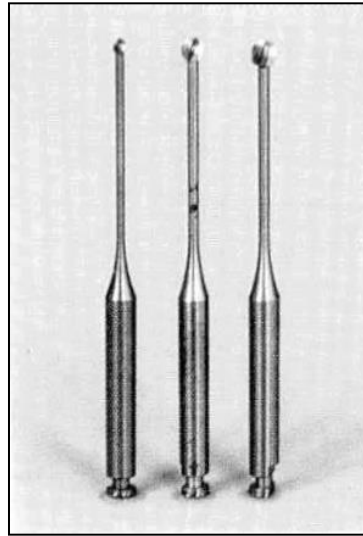
Endodontic probes, microopeners

Ultrasound tips

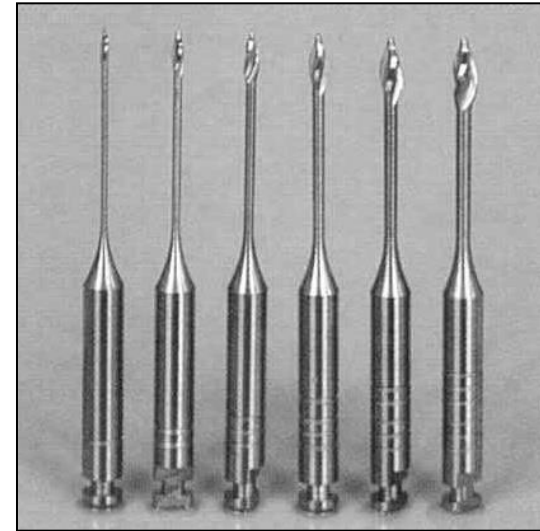
# Opening of root canals



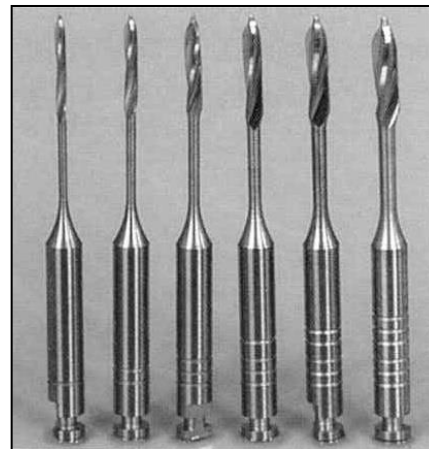
Ball burs



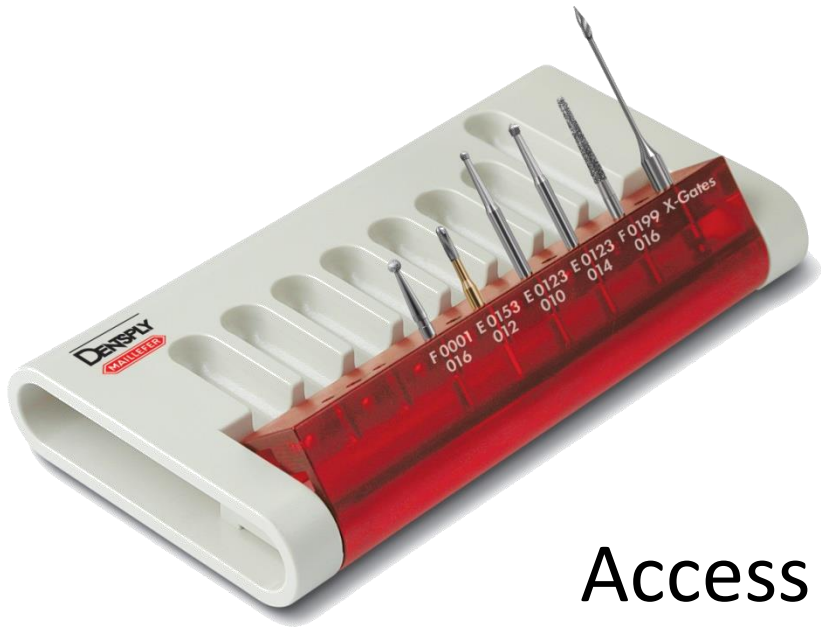Miller's  
burs



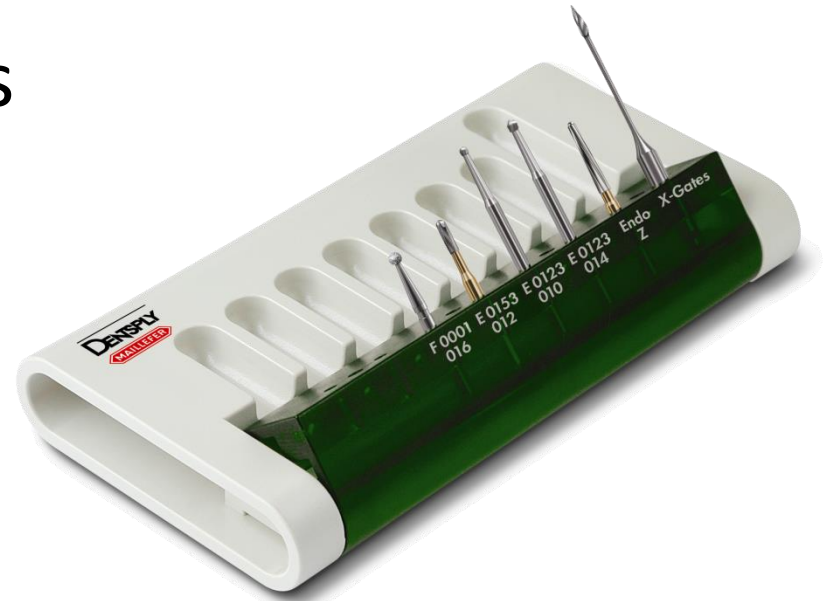Gates Glidden's burs



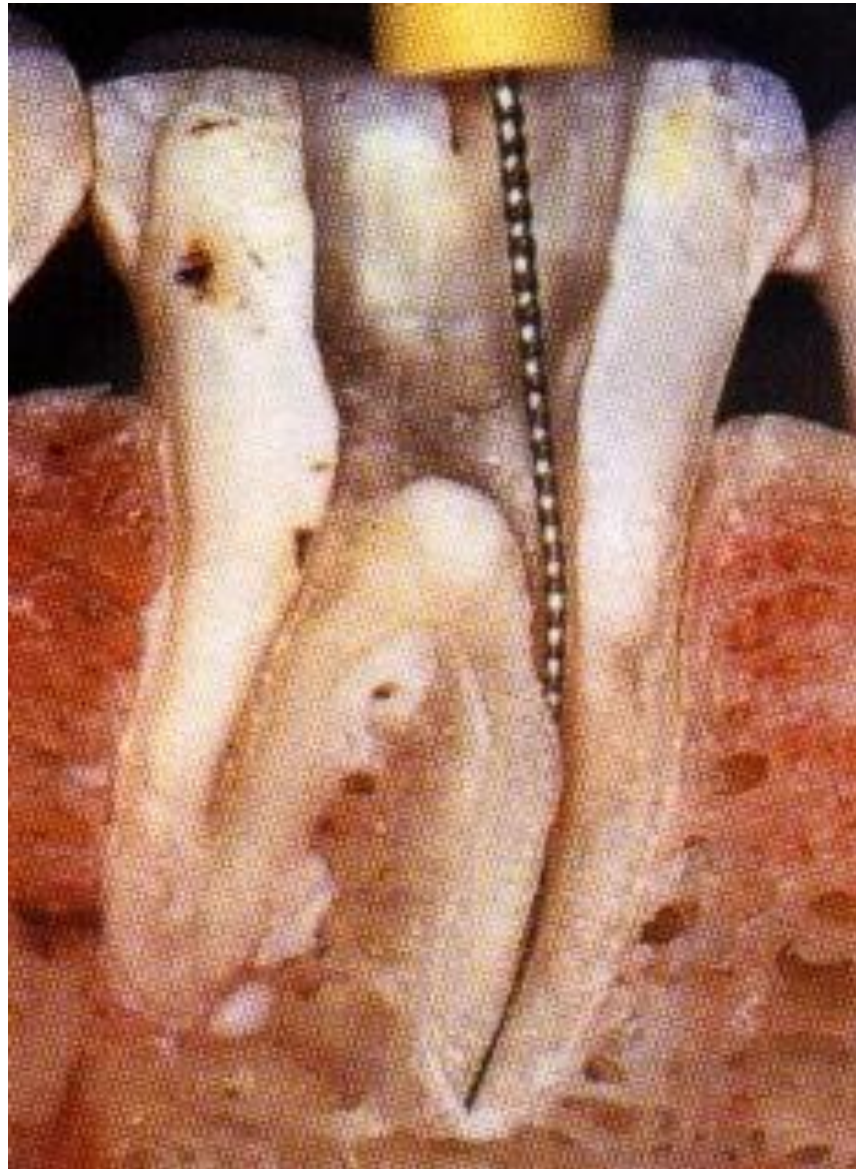
Peeso – Largo

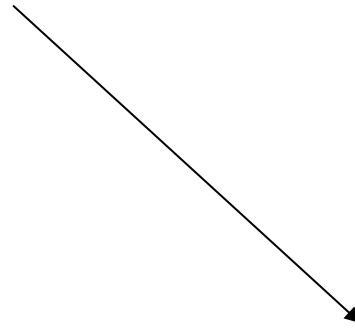
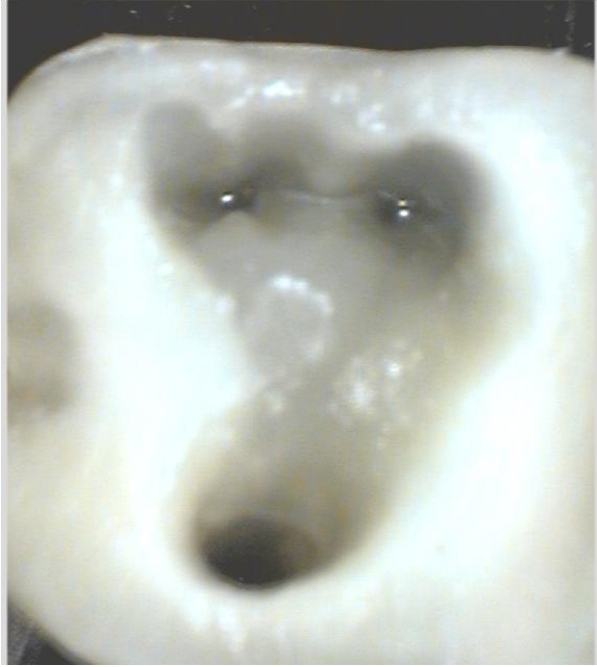

## Access kits



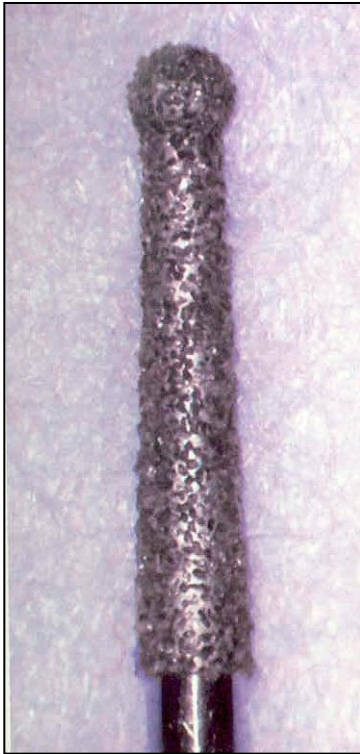
After opening of the access and shaping of the root canal orifice



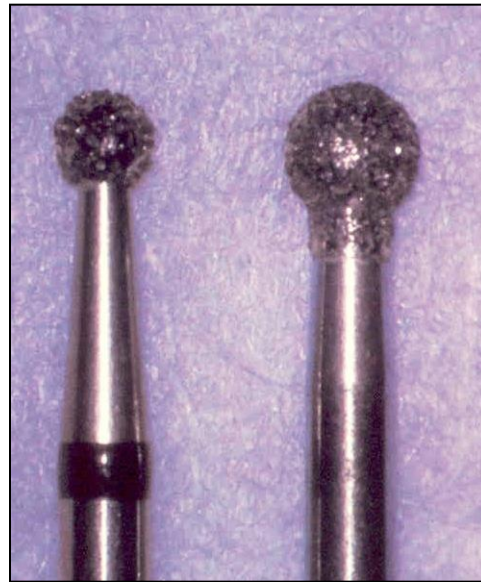

The pulp chamber correctly open

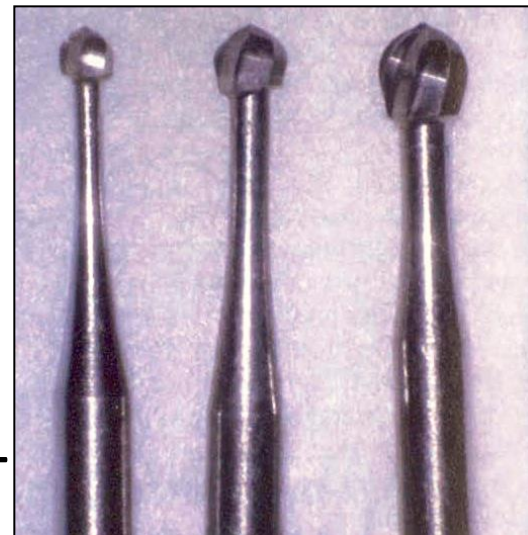
# Opening of the pulp chamber Access



Dia trepan



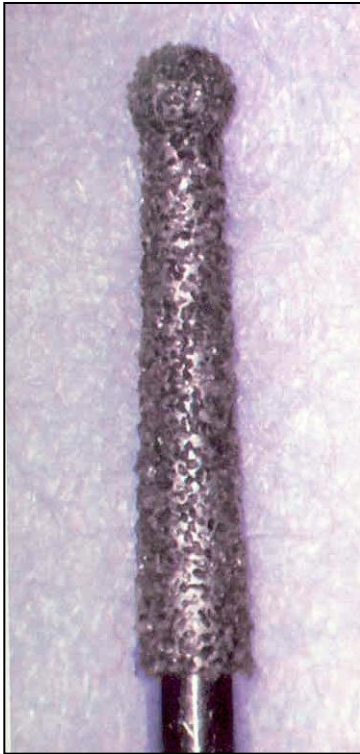
Dia round burs –  
balls



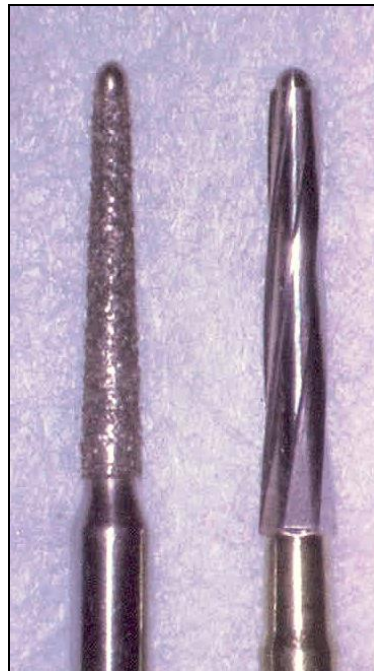Steel round burs



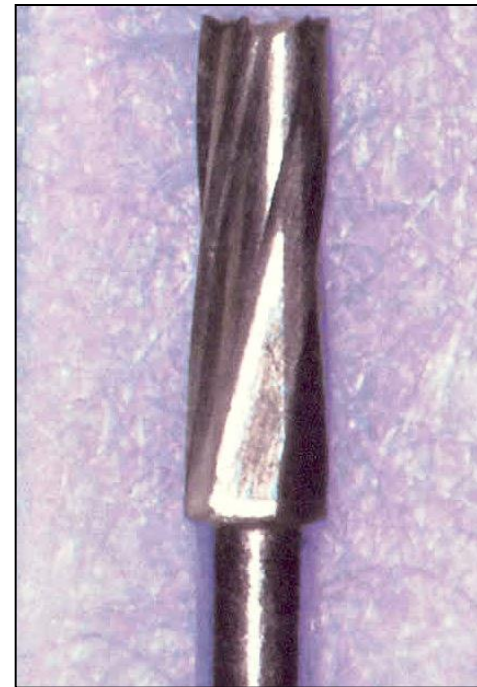# Preparation of the endodontic cavity



Dia trepan

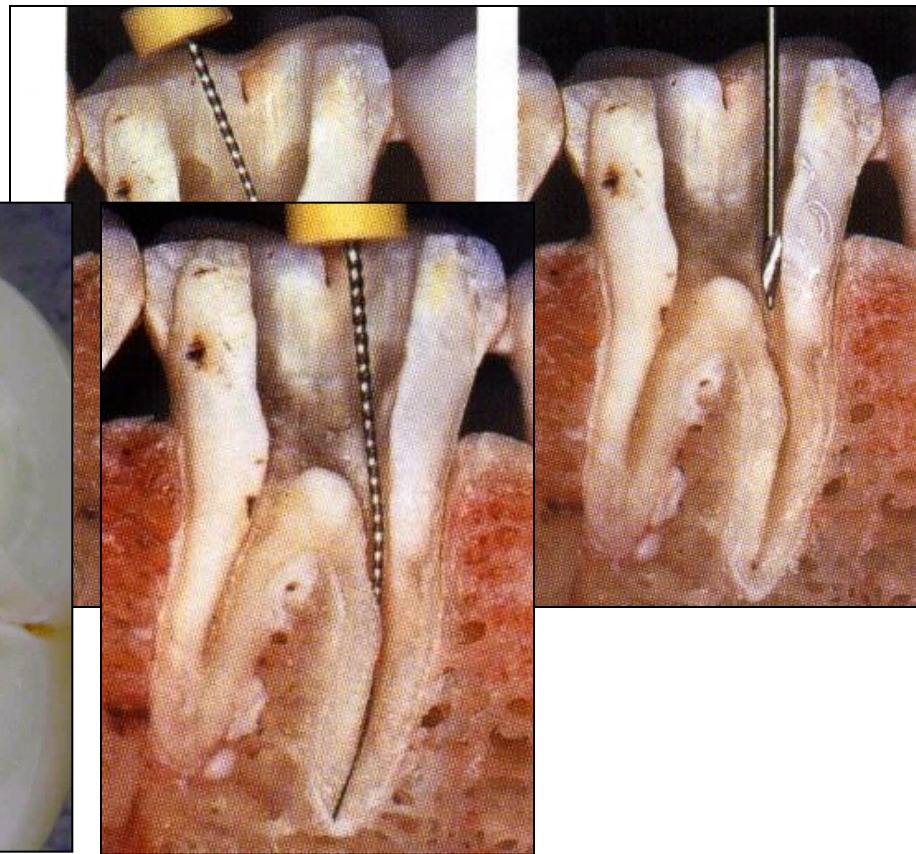
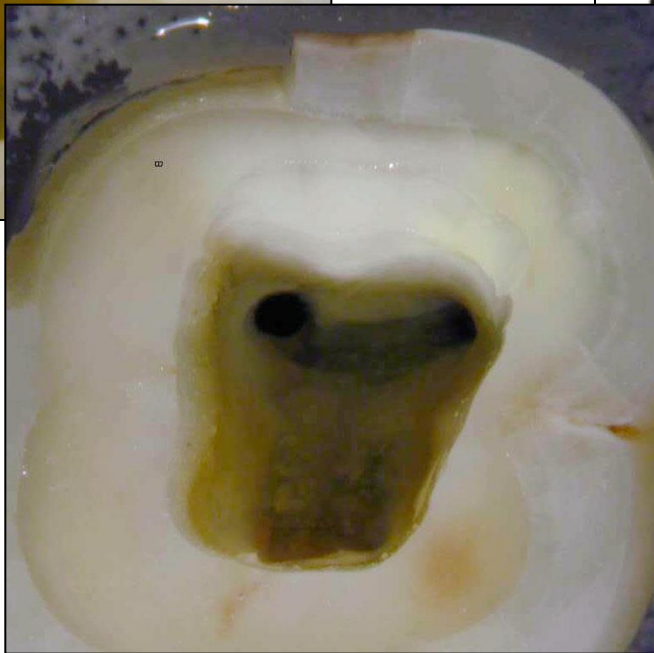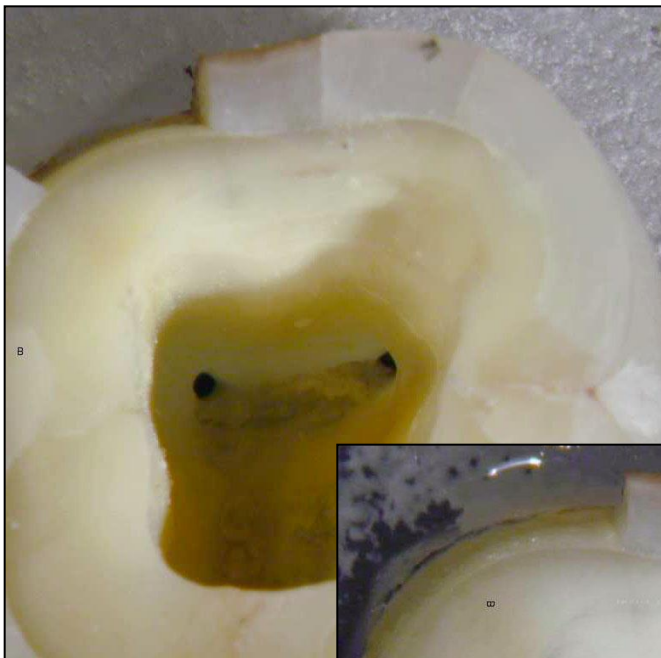


Safe ended tips  
Batt's instruments



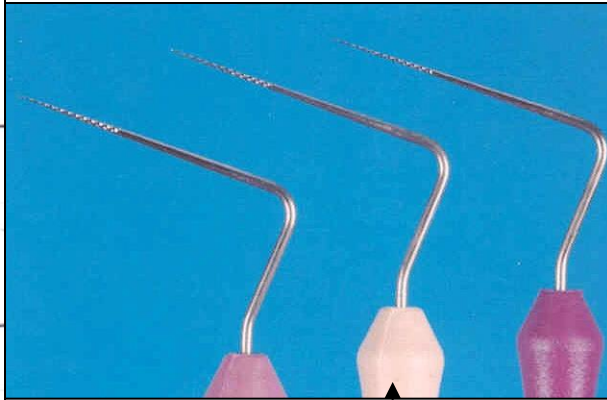
Fissur bur

# Finding of the root canal orifice

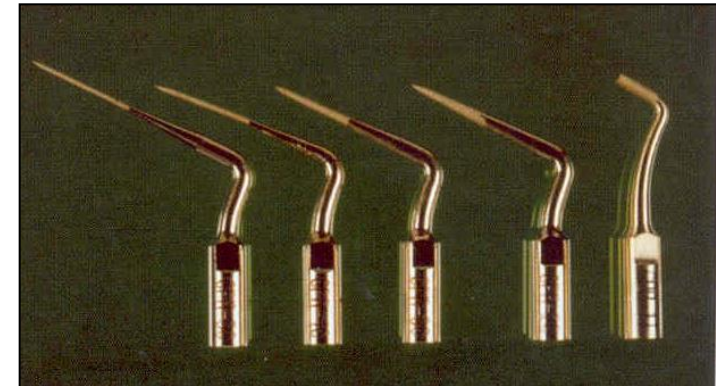




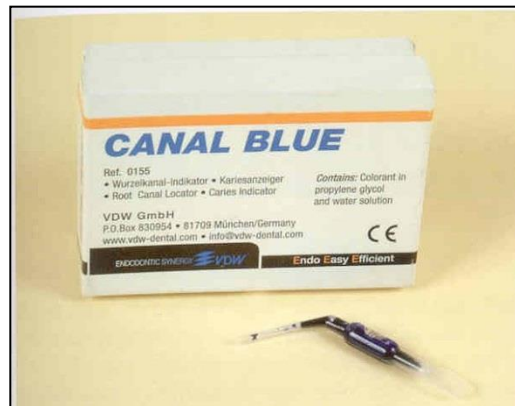# Finding and opening of rot canal orifices



Endodontic probes  
Microopeners

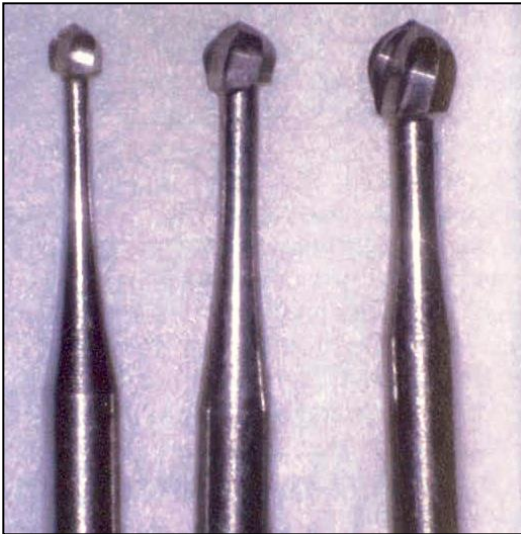

Ultrasound tips

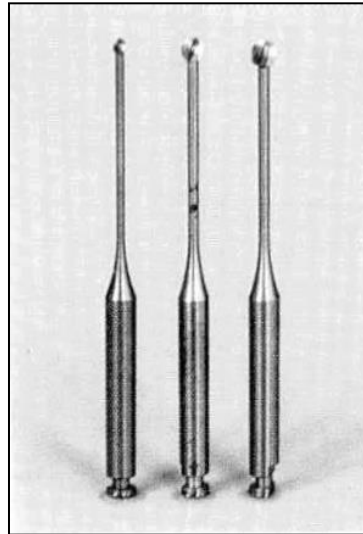


Dye

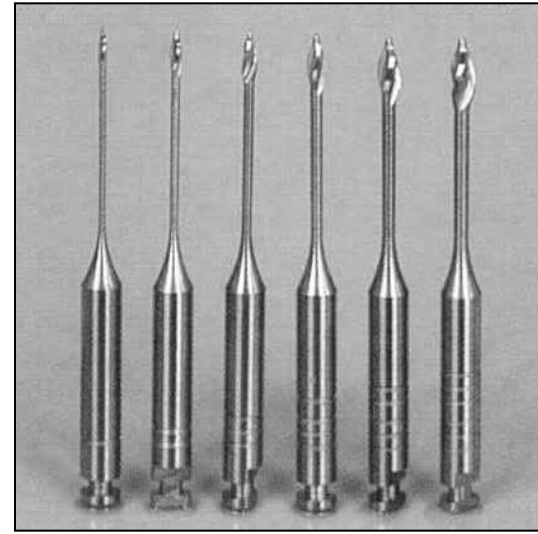
# Finding and opening of root canal orifices



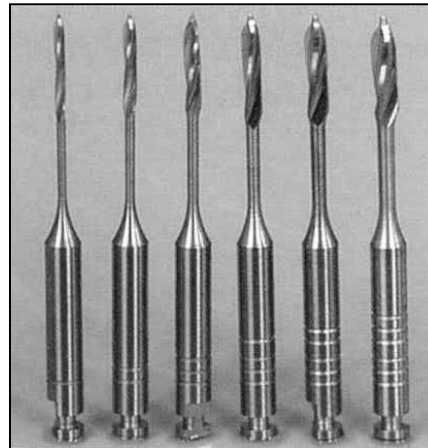
Rounded burs - balls



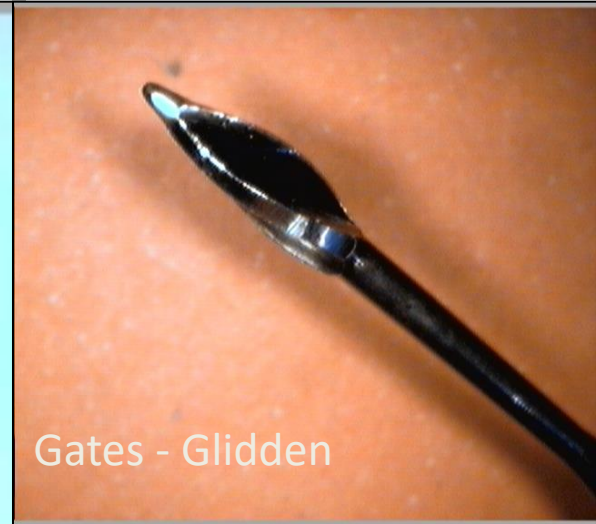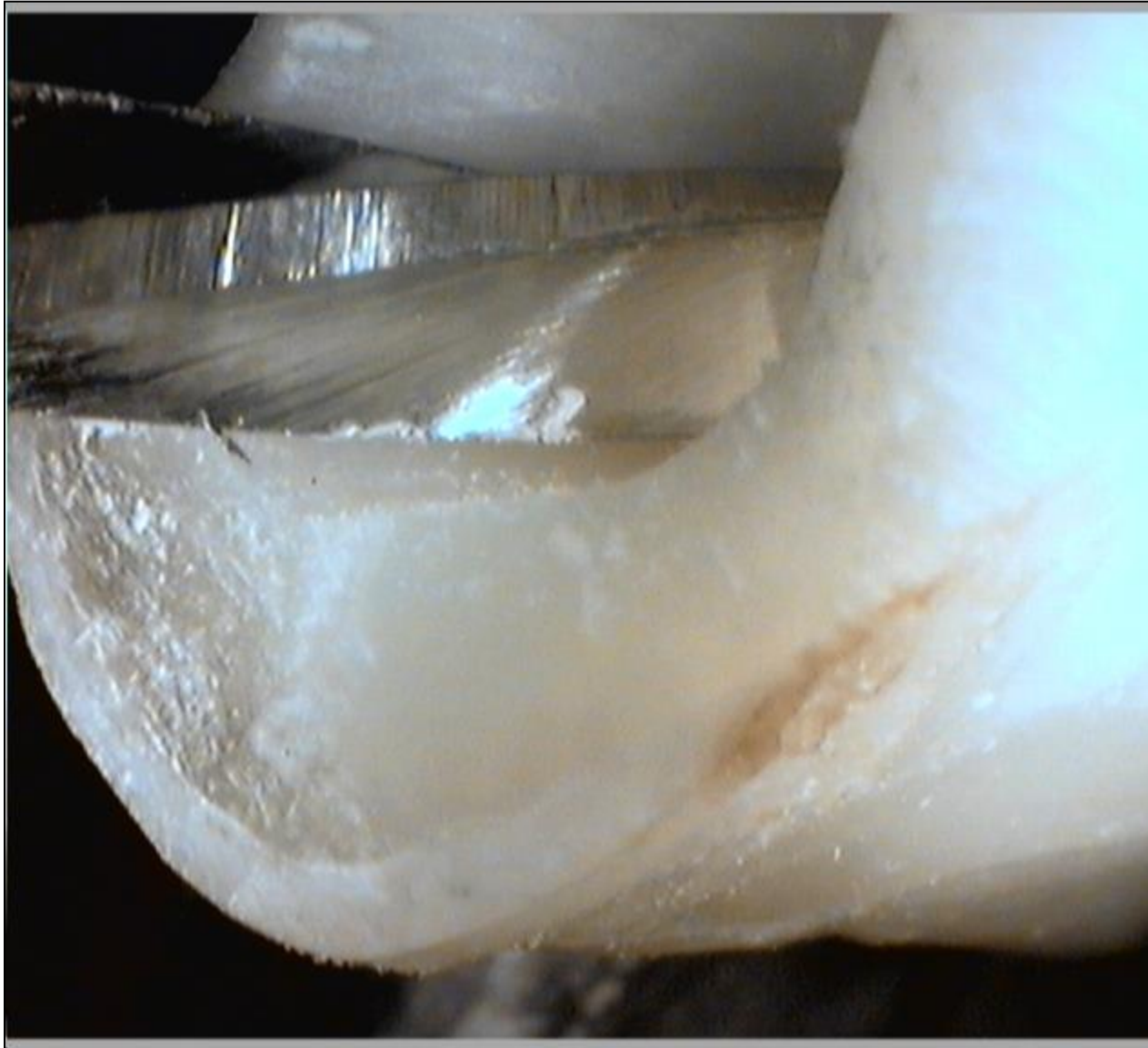Miller's burs

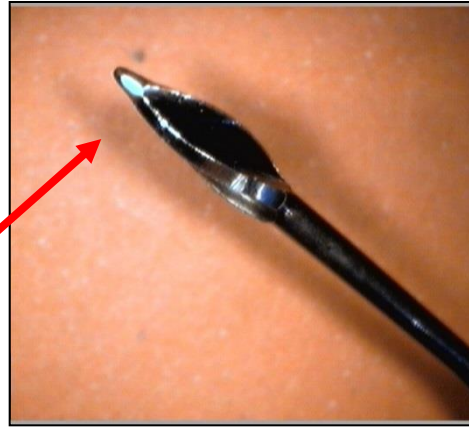


Gates Glidden's burs




Peeso T8 Largo

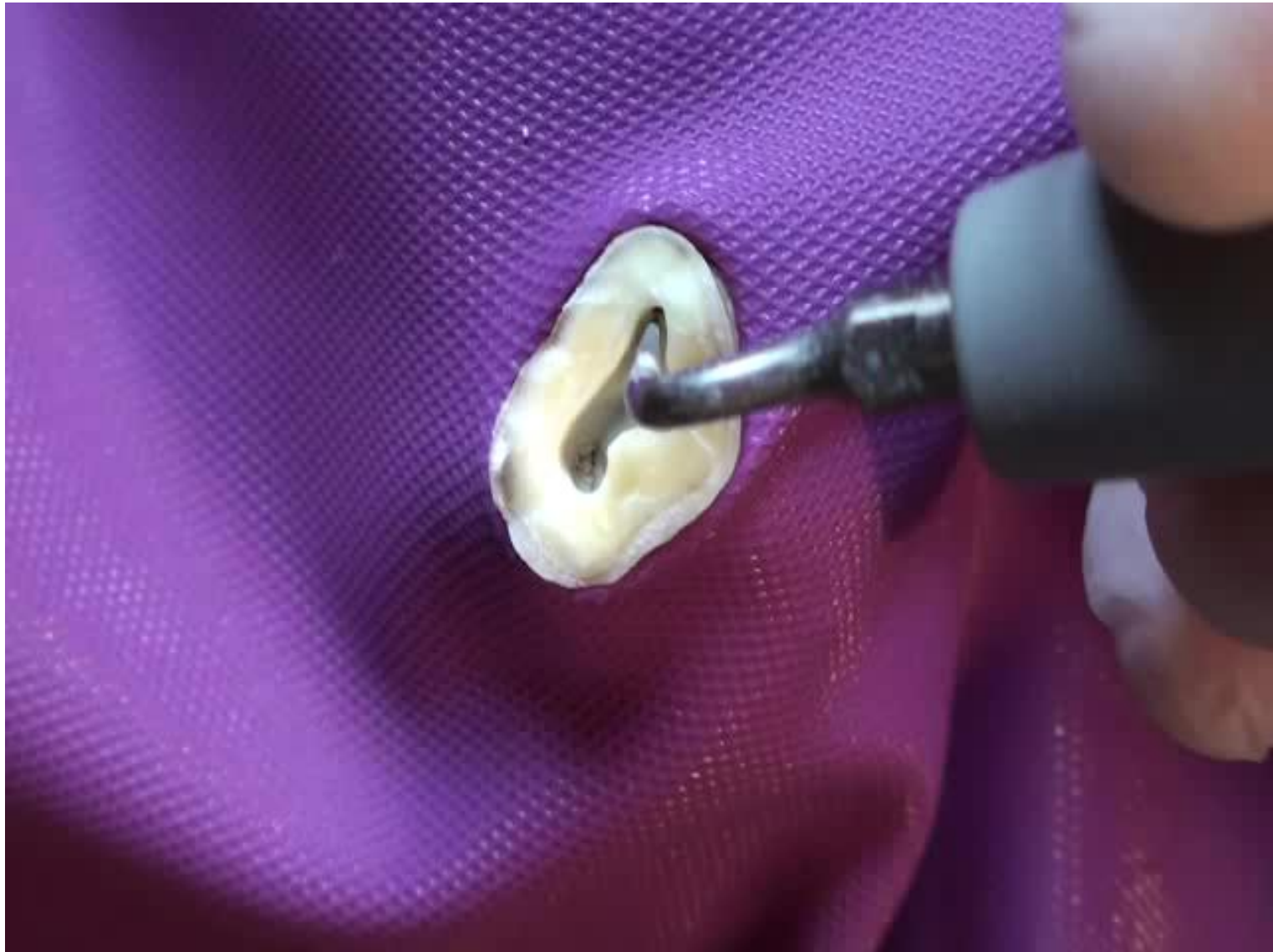



Gates – Glidden:  
Blunt, non active tip

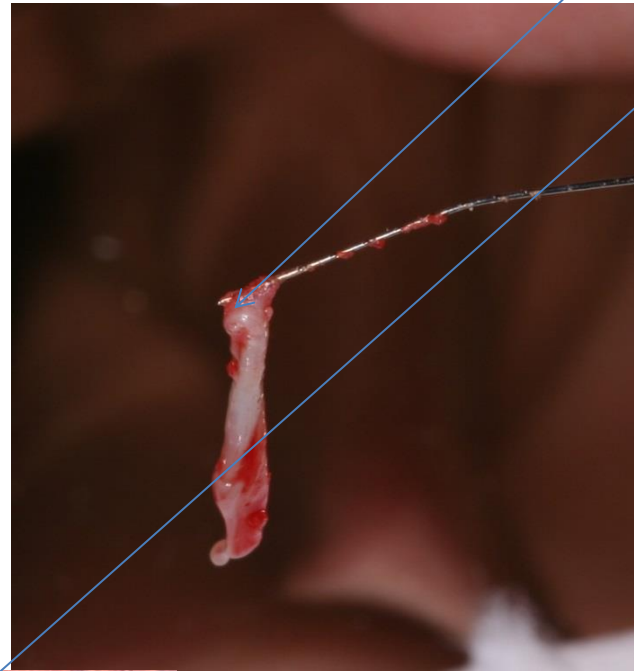


Program point of breakage

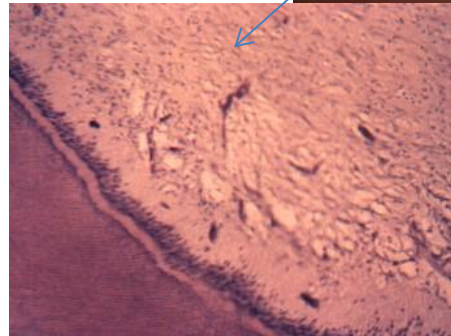


Ultrasound

# Pulpextractor



Dental pulp



Soft wire  
Prickles like harpune  
Insertion  
Rotation  
Exstirpation

# Canal shaping

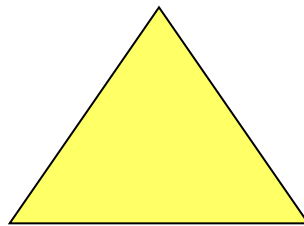
- Reamers (penetration)
- Files (shaping)

# Reamer

**K -reamer**


**Triangl or square wire spun**

**Symbol**





# Reamer

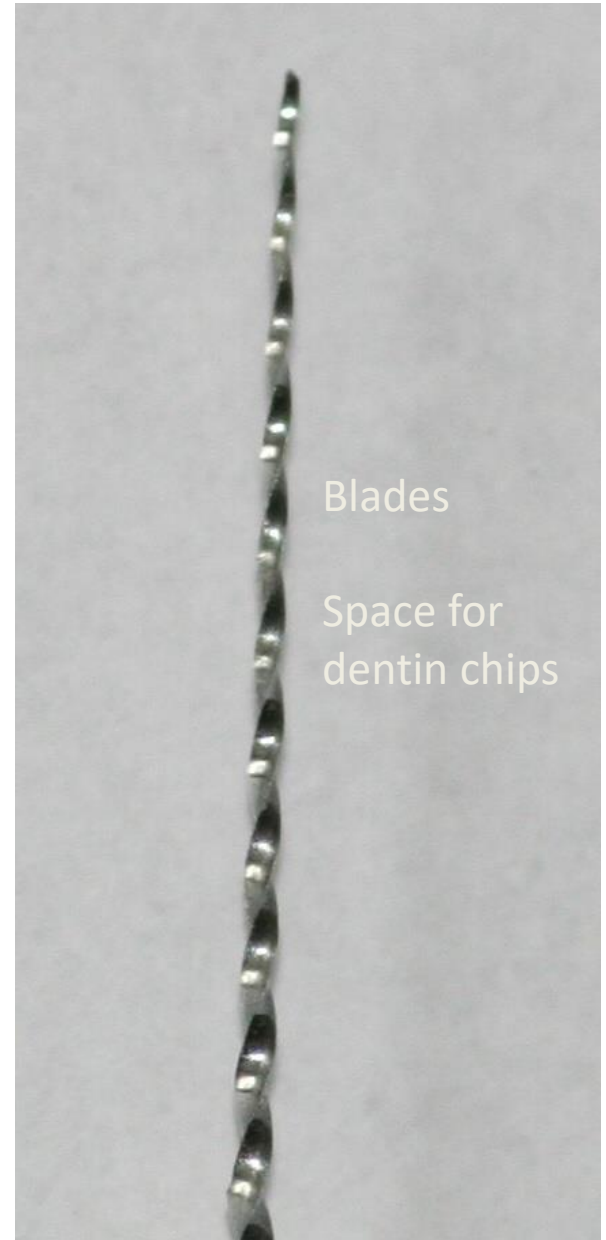


Bladed part

Shank

Stopper

Grip



Blades

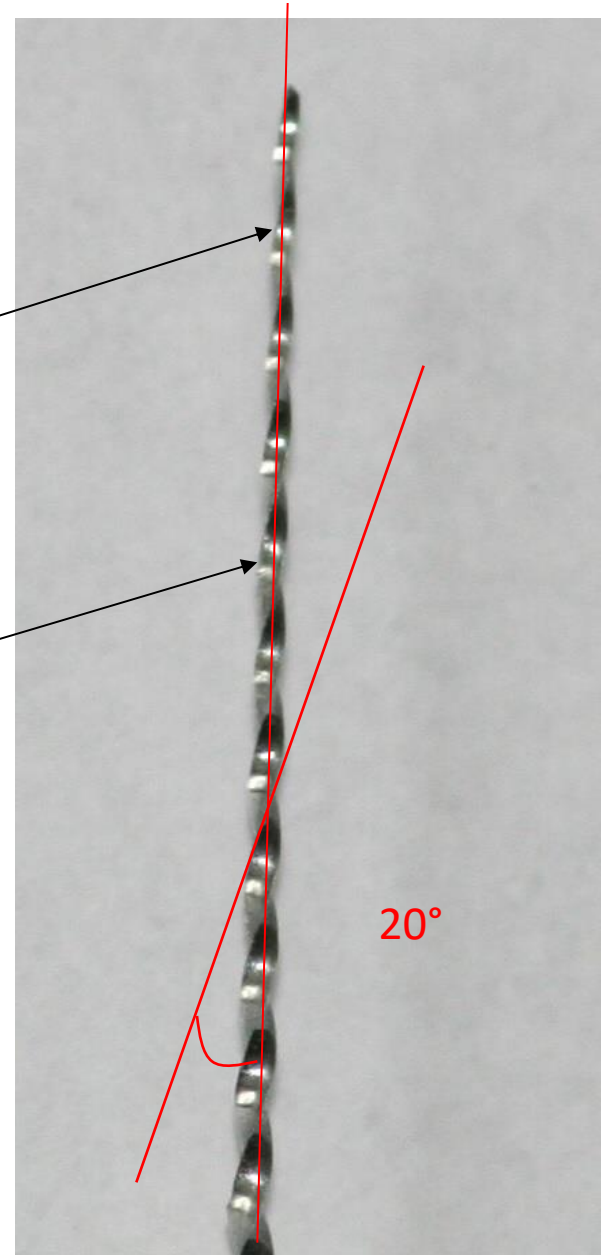
Space for dentin chips

# Reamer

Blades

Space for dentin chips

***Rotation – reaming action - penetration***



# Reamer

**Rotation (clockwise) – penetration**

**Application of plastic material  
(counterclockwise)**


# Files

- 1. K-file**
- 2. K-flexofile, flexicut, flex-R**
- 3. K-flex**
- 4. H-file, S-file**

# K file

Wire triangle or square

Symbol is always square




# K-file

***Filing***


***Also rotation***

***45° – 90°***



# K-flexofile, flexicut, flex-R

- Triangle wire always




Flexibility

K- flexofile a flex – R file: non cutting tip and first blades are blunt

Like K-file

# K- flex



Rhombus


Two blades in action

Enough space for dentin chips

Flexibility, efficacy





# K-file and reamer: the difference



# H-file

= Hedstroem file

Ring





# H- file

No rotation!!

Pull motion only!!

Risk of breakage in small sizes



# ISO

- Diameter of the tip
- Length of the cutting part
- Taper

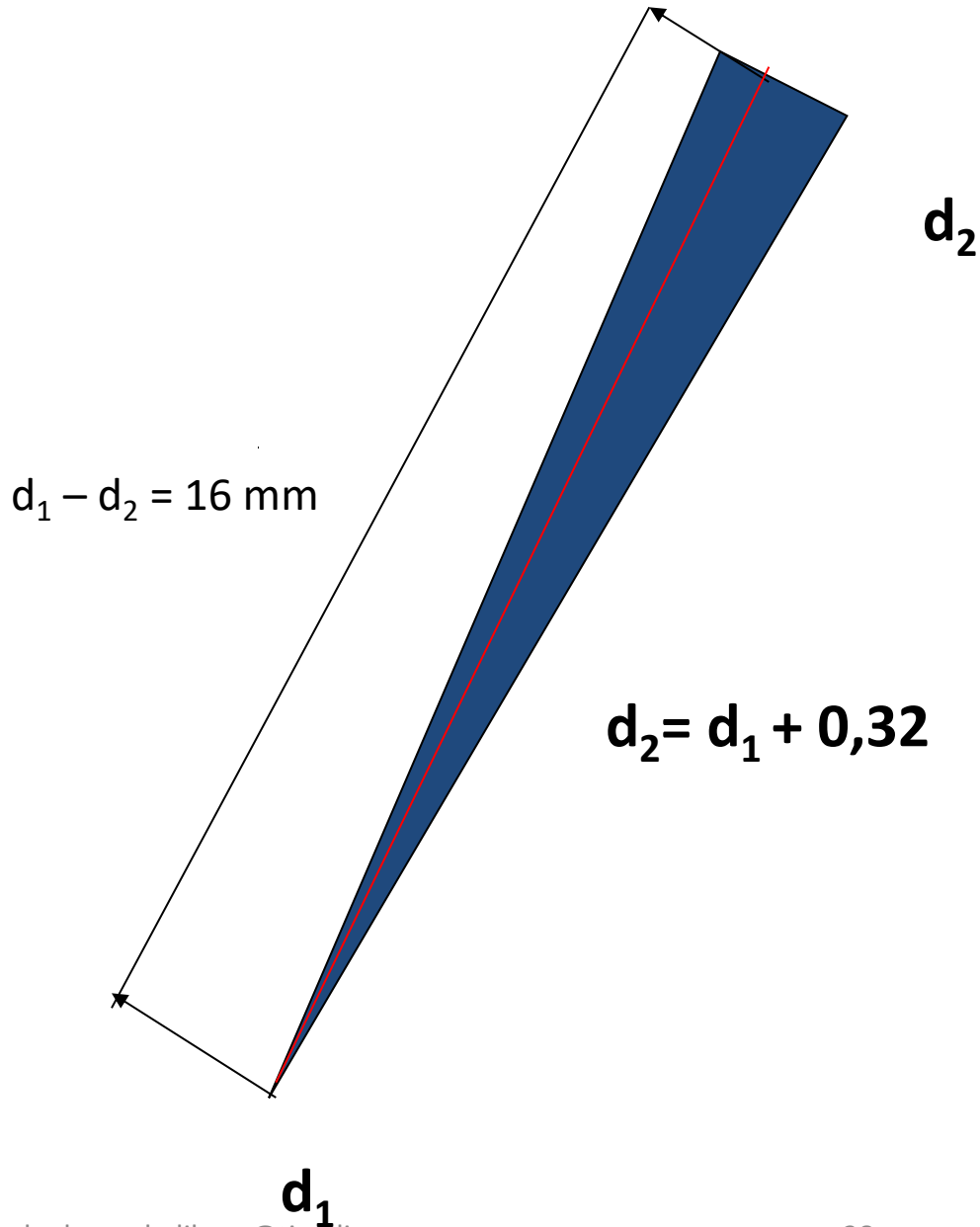


# ISO standard


06	
08	
10	
15	45
20	50
25	55
30	60
35	70
40	80

Size – diameter at the tip

**Taper 2%**



0,02 mm na 1mm



$d_2$

$d_2 + 0,64$

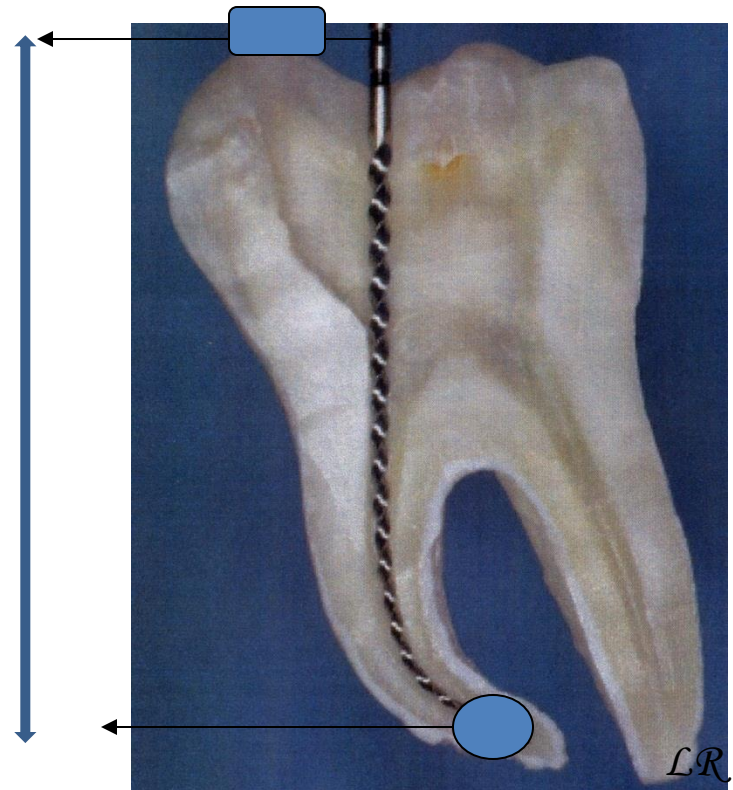
$d_1$

**Konus 4%**

0,04mm na 1 mm

# Working length

- Distance between the referential point and apical constriction
- Radiographically
- Apexlocators
- Combination





# Why apical constriction

- Small apical communication
- Minimal risk of damage of periodontium
- Prevention of overfilling
- Prevention of extrusion of infection
- Good decontamination
- Good condition for root canal filling

# Radiogram

X-ray with inserted root canal instrument

Safe length: average length of teeth reduced for  
2 – 3mm

Tooth with clinical crown

# Safe length

Average length of the tooth less 2 mm

- Maxilla:

I1 20

I2 18

C22-24

P20

M 18 mkk, 20 P

# Safe length

Average length of the tooth less 2 mm

- Mandible

I 18

C20 -22

P18

M18

# Procedure


- Instrument ISO 15 inserted into the root canal, stop at the referential point
- Estimation of location of apical constriction (1 – 1,5 mm distance from x-ray apex.

If difference in the radiogram more than 23 mm  
- repeat

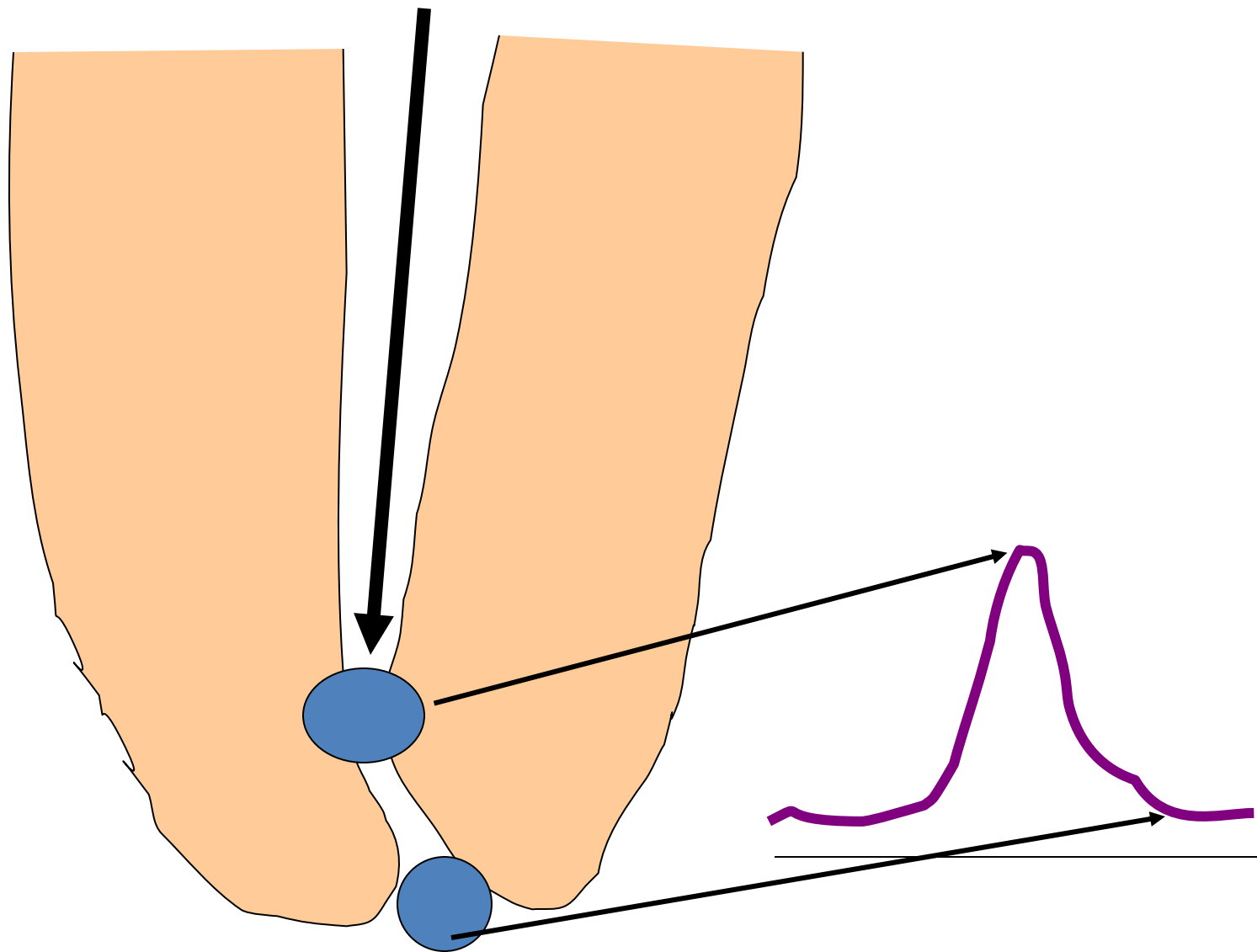
If 2 mm or less – add to the safe length

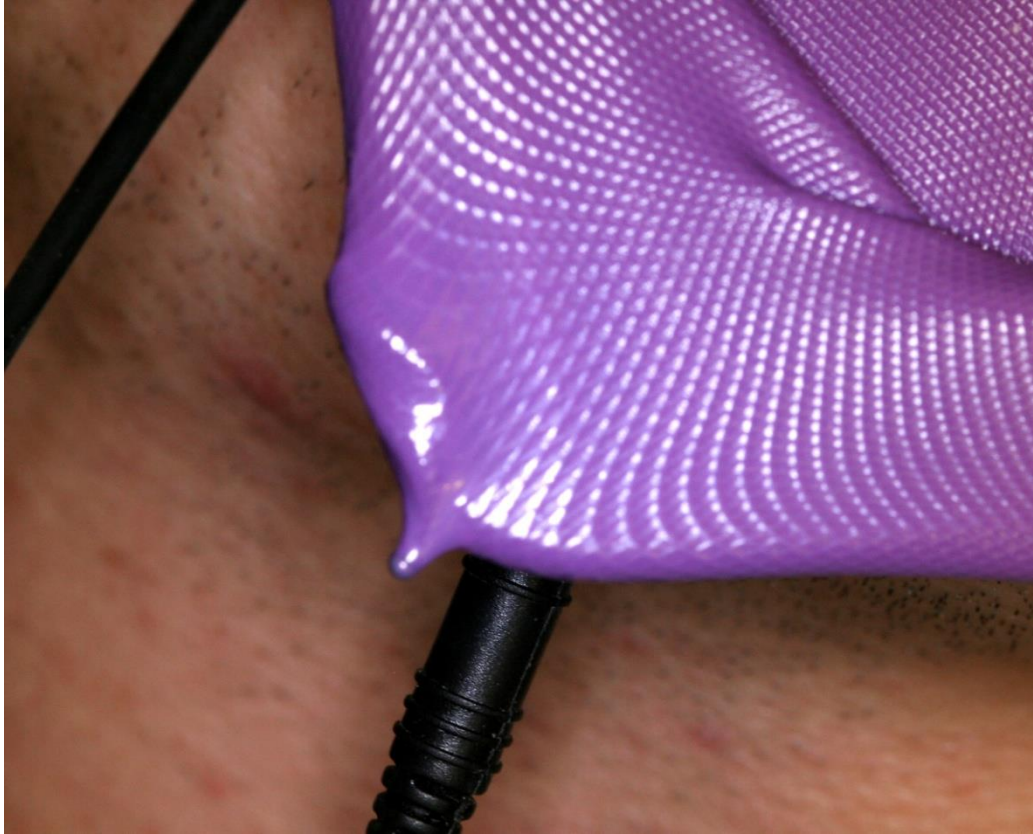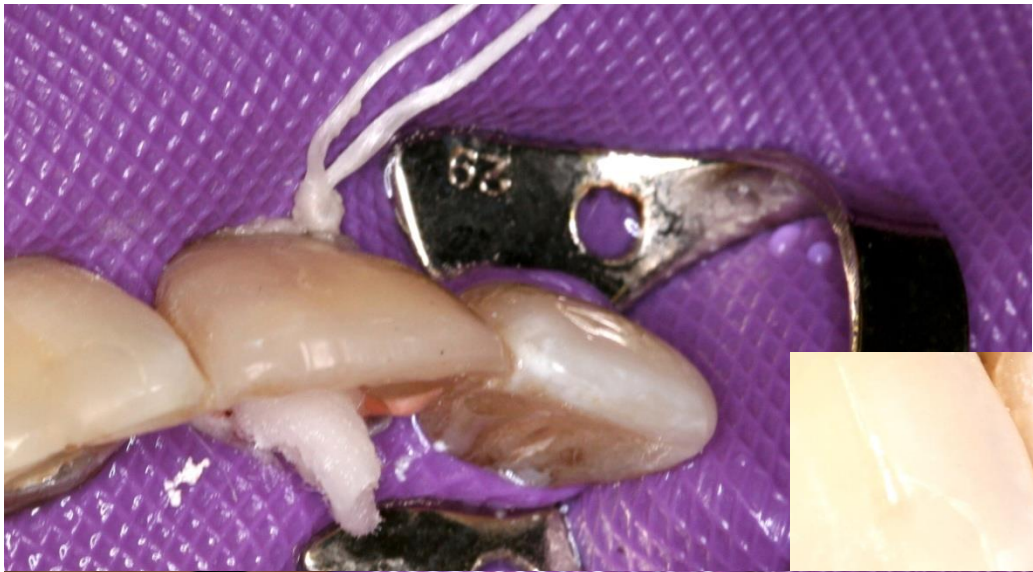
# Endometry, odontometry

- Endometry



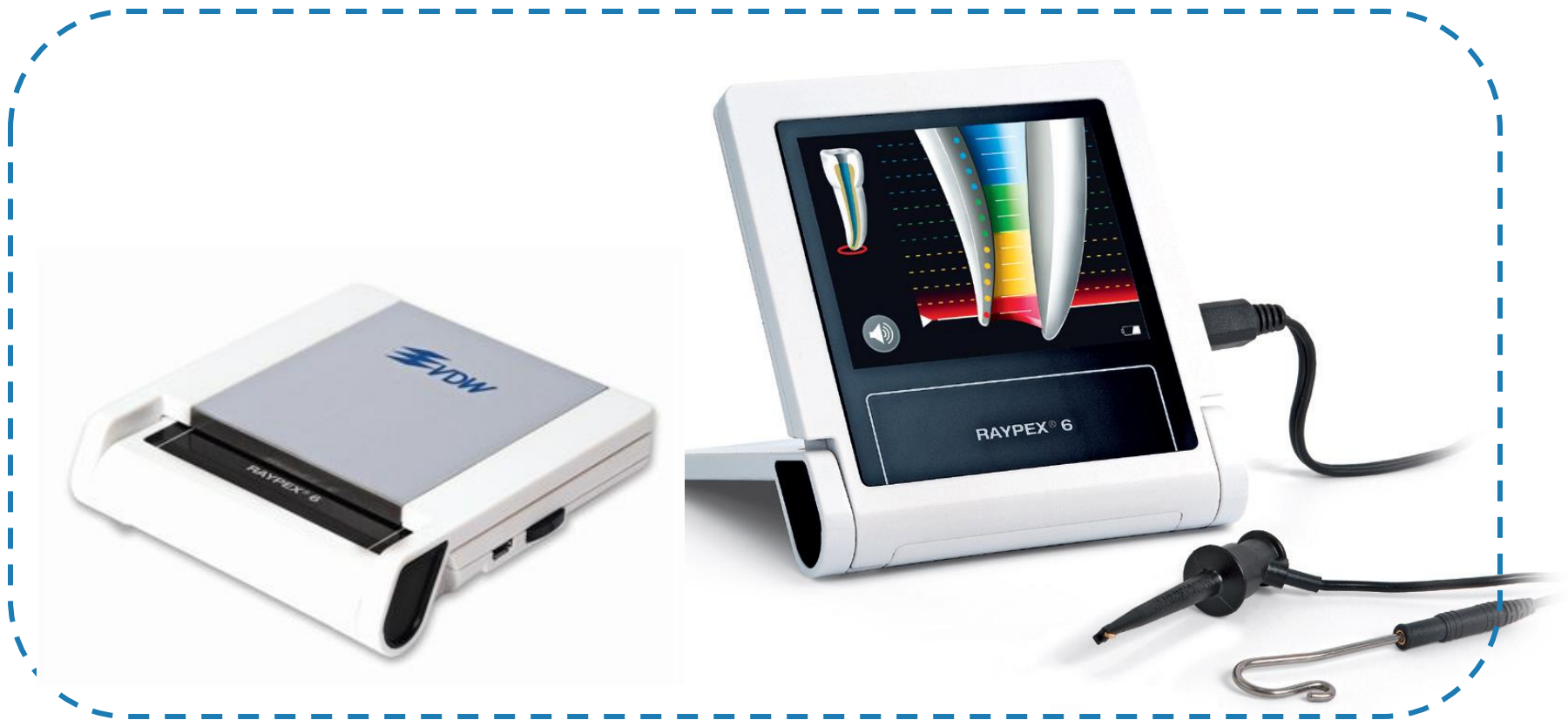**edevices based on measurement of electrical resistance**







# RAYPEX<sup>®</sup> 6



# Methods of shaping

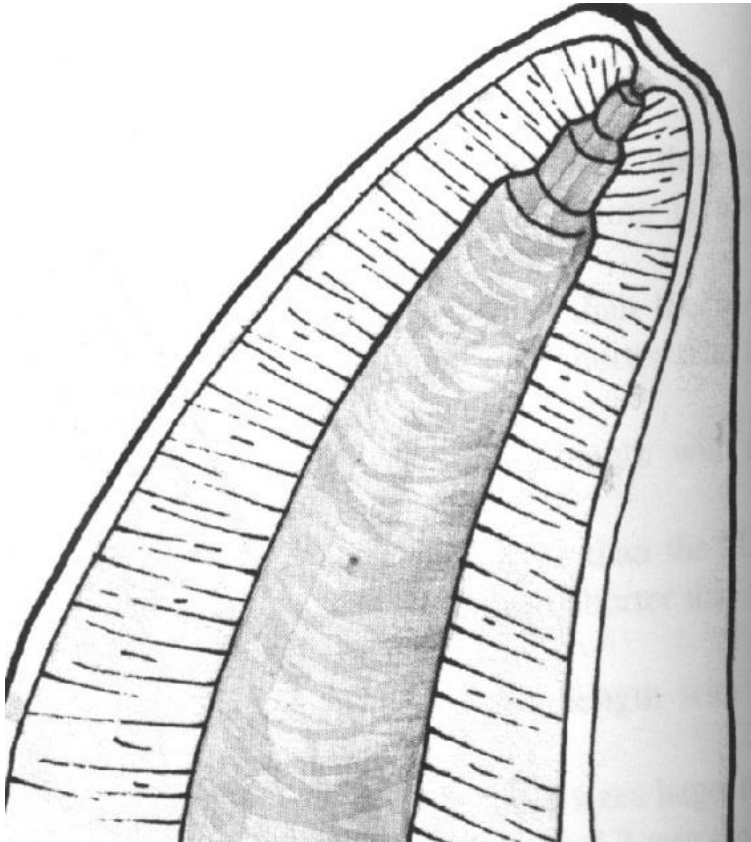
- Step back method

Increasing size with decreasing length.

Insertion of root canal instrument – WL

Next – 1 mm shorter

...



Taper  
Final flaring with  
the smallest instrument

H- File nebo K - Flexofile.

# Method modified double flared

- I. Opening of root canal

- Coronal third

- II. Apical preparation

Cathetrization, measurement, shaping till ISO 30 – 35 balanced force. Master file – MAF (till WL)

- III. Step back

- Final flaring (MAF)