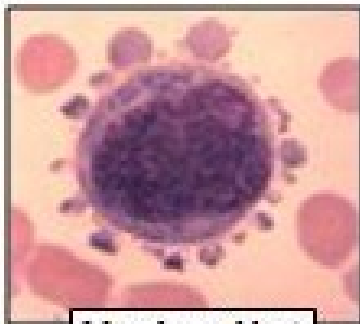
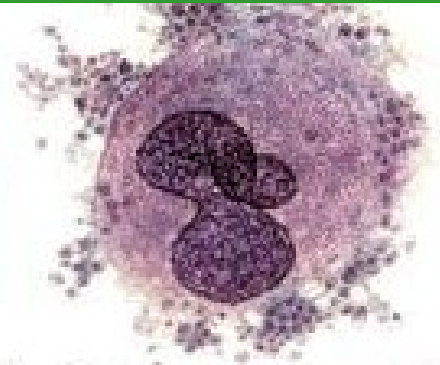
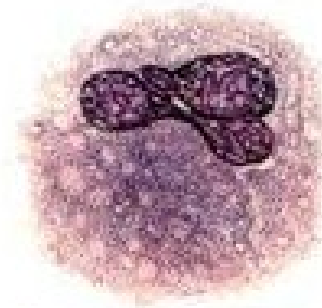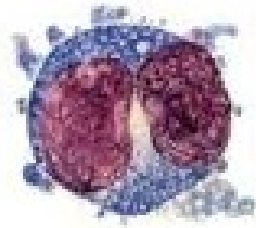
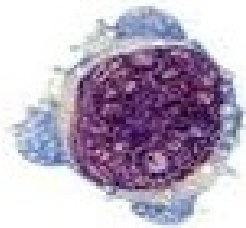


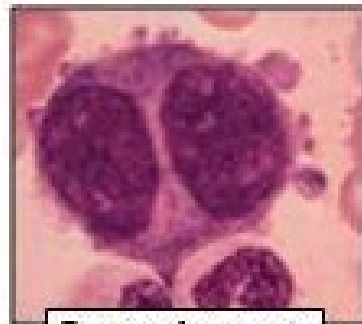
Morfologie trombocytů

Bourková L., OKH FN Brno

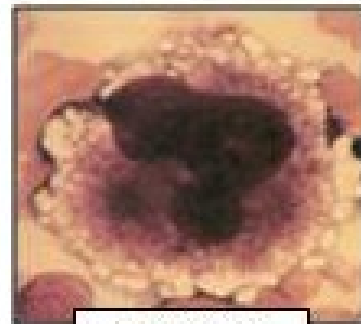
Příklad vývojových stádií megakaryocytů



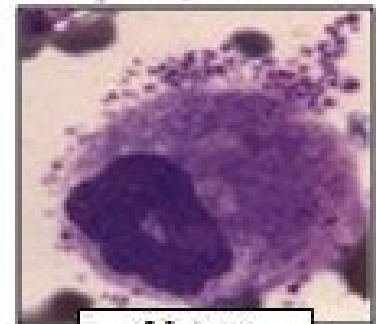
Megakaryoblast



Promegakaryocyte

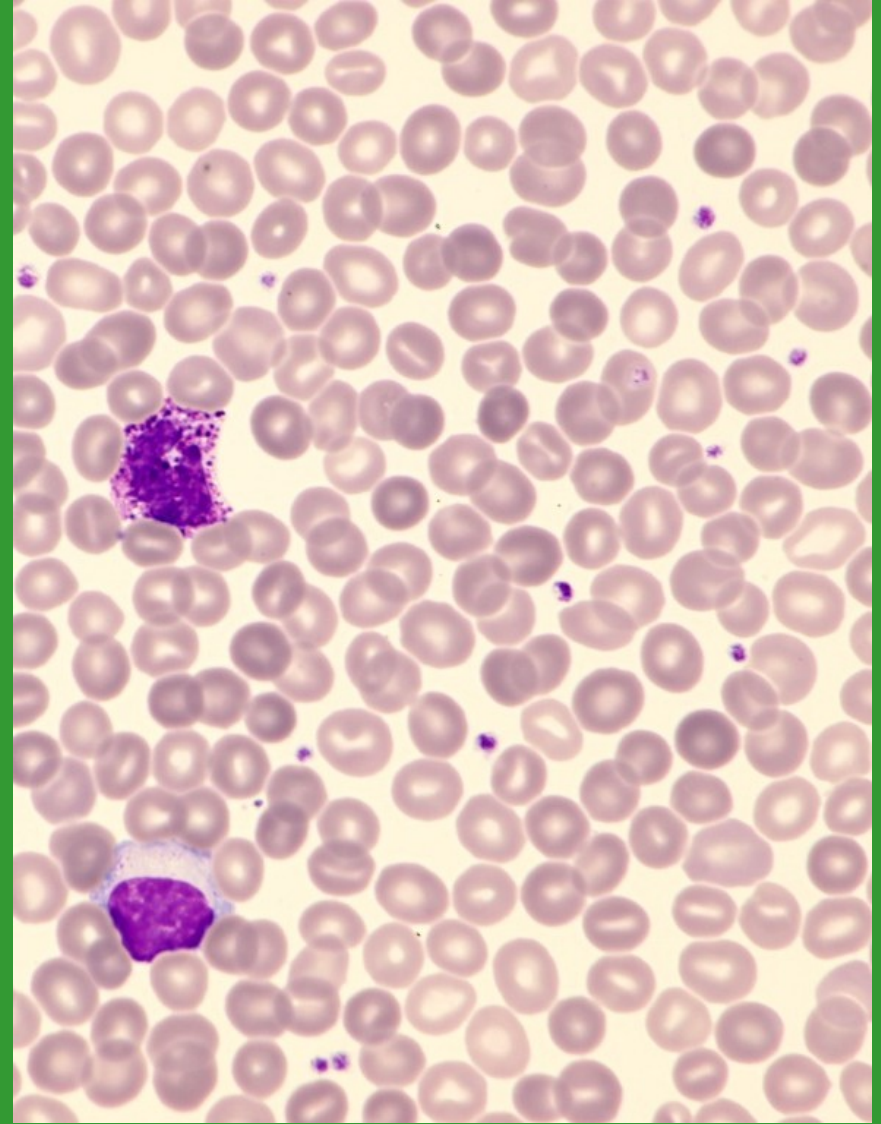
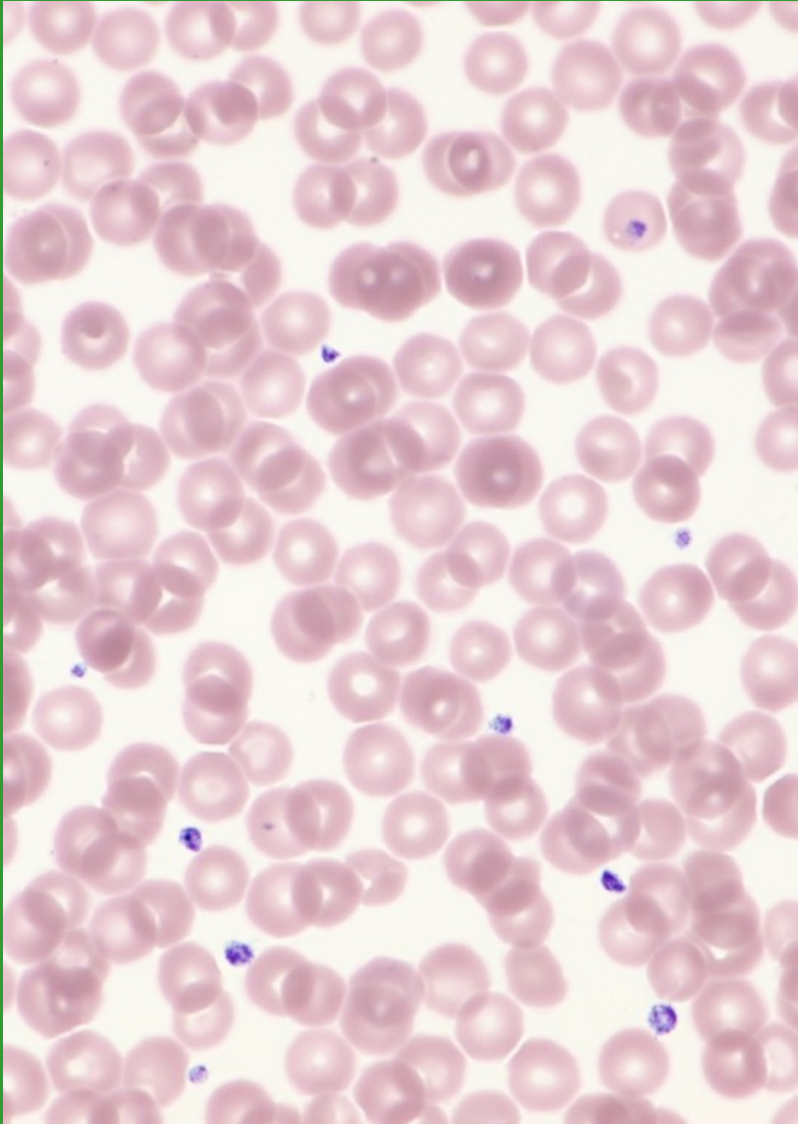


Immature
Megakaryocyte

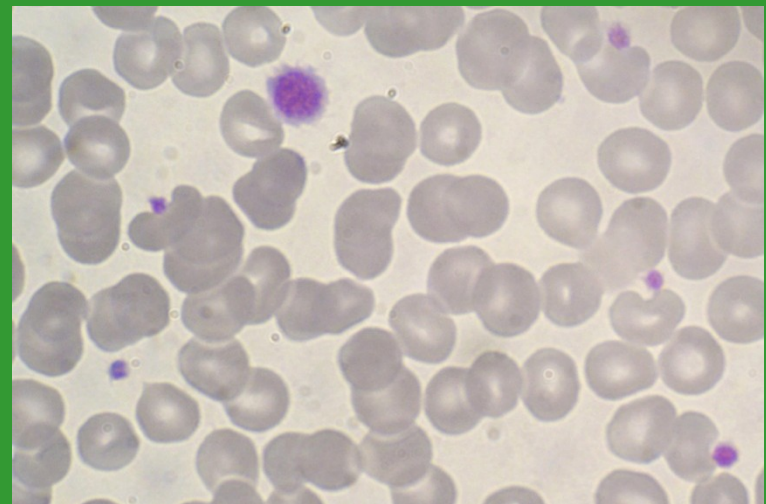
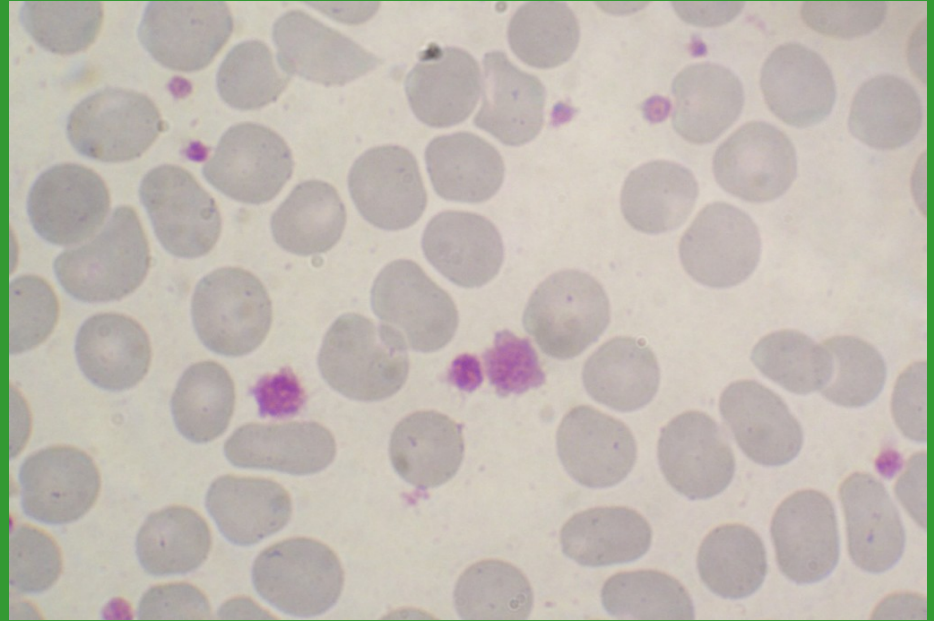
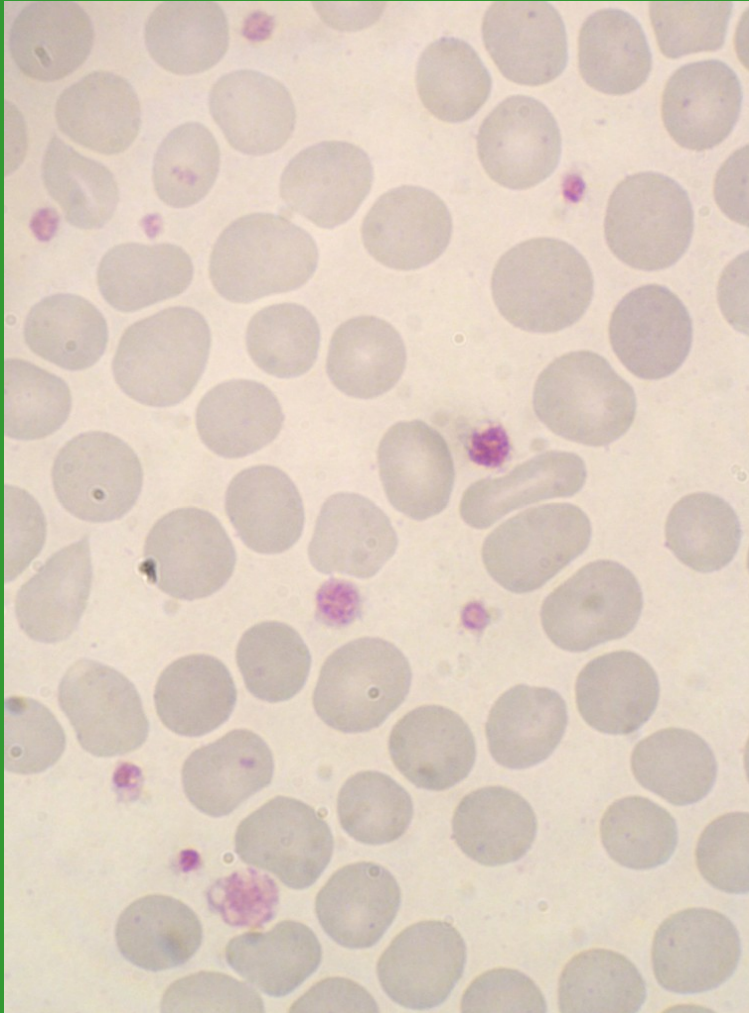


Mature
Megakaryocyte

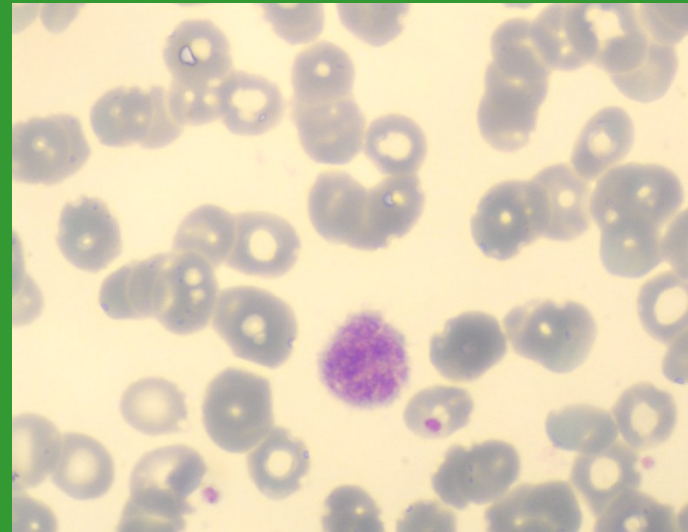
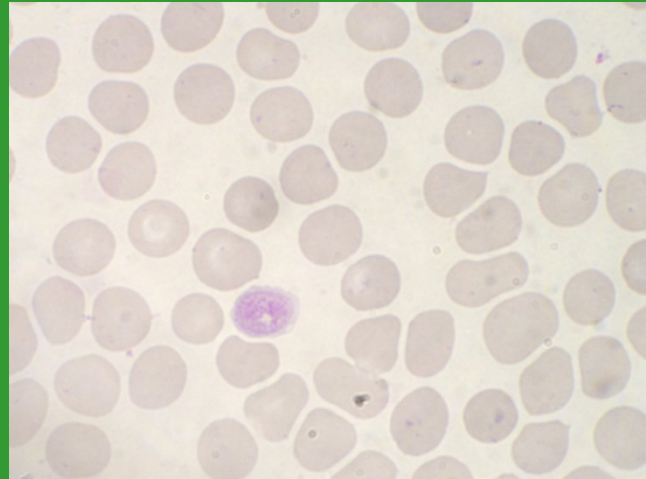
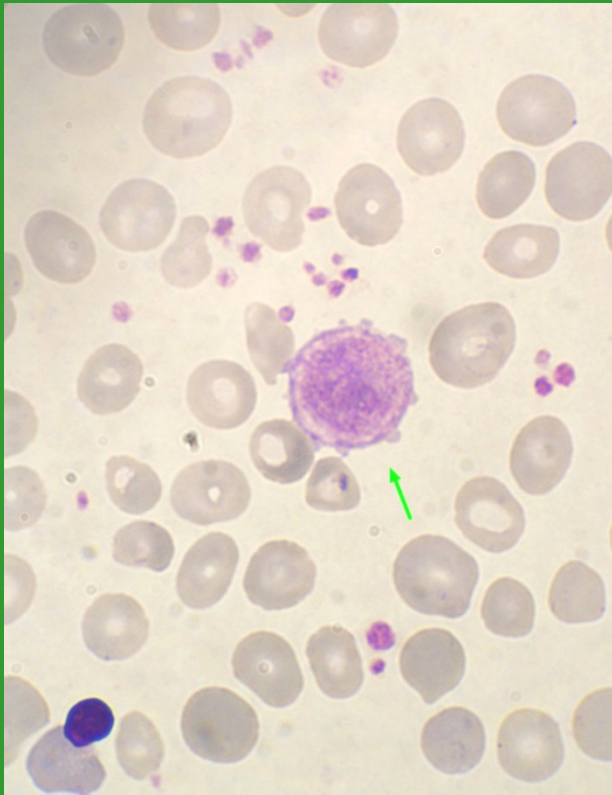
Fyziologické trombocyty



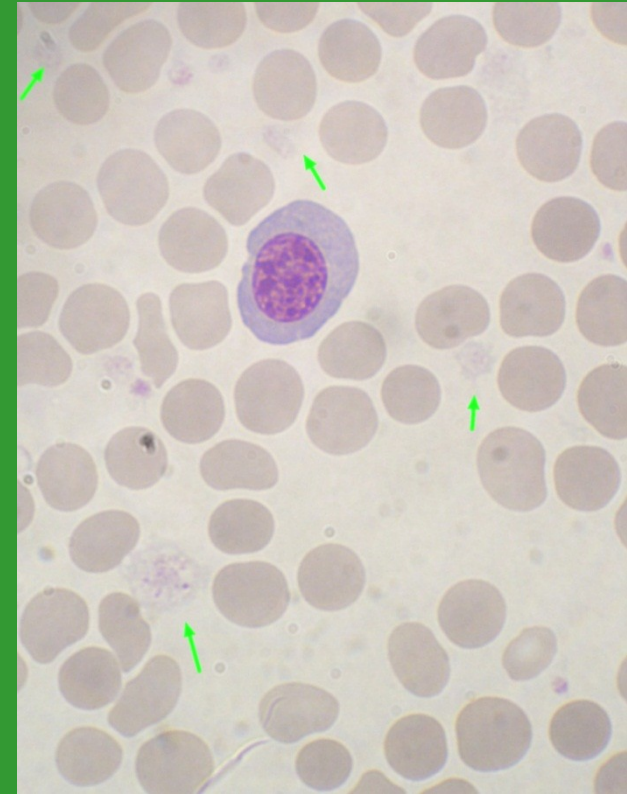
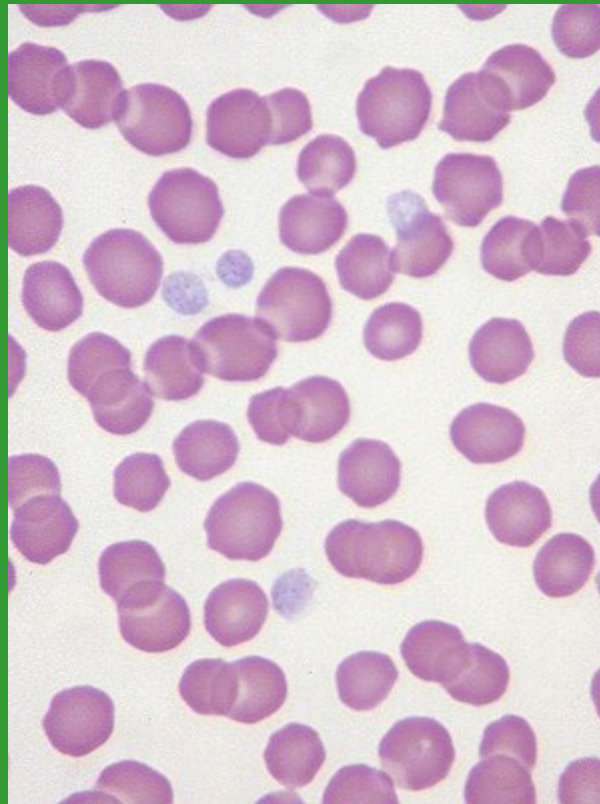
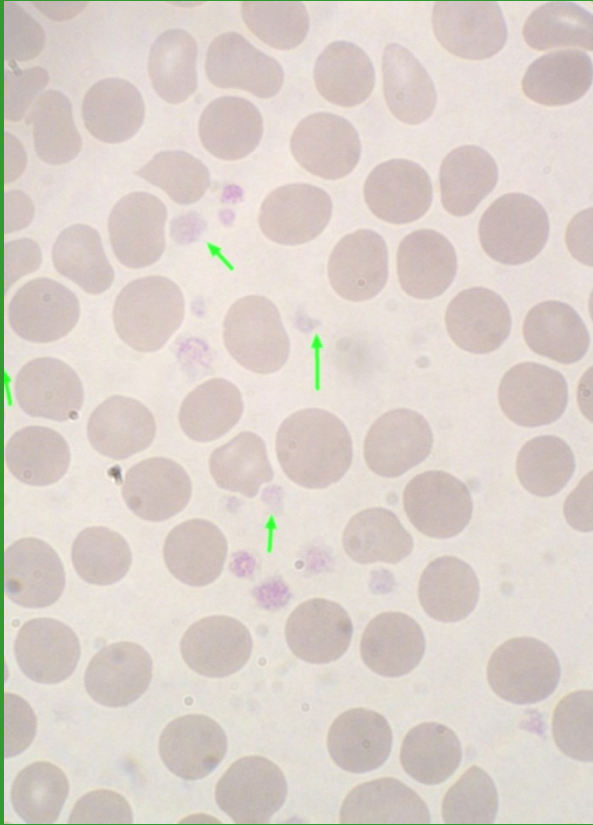
Anizocytóza trombocytů



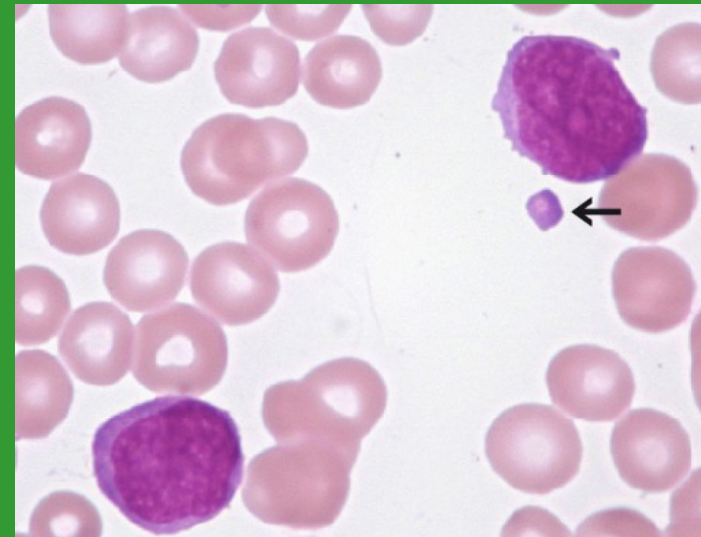
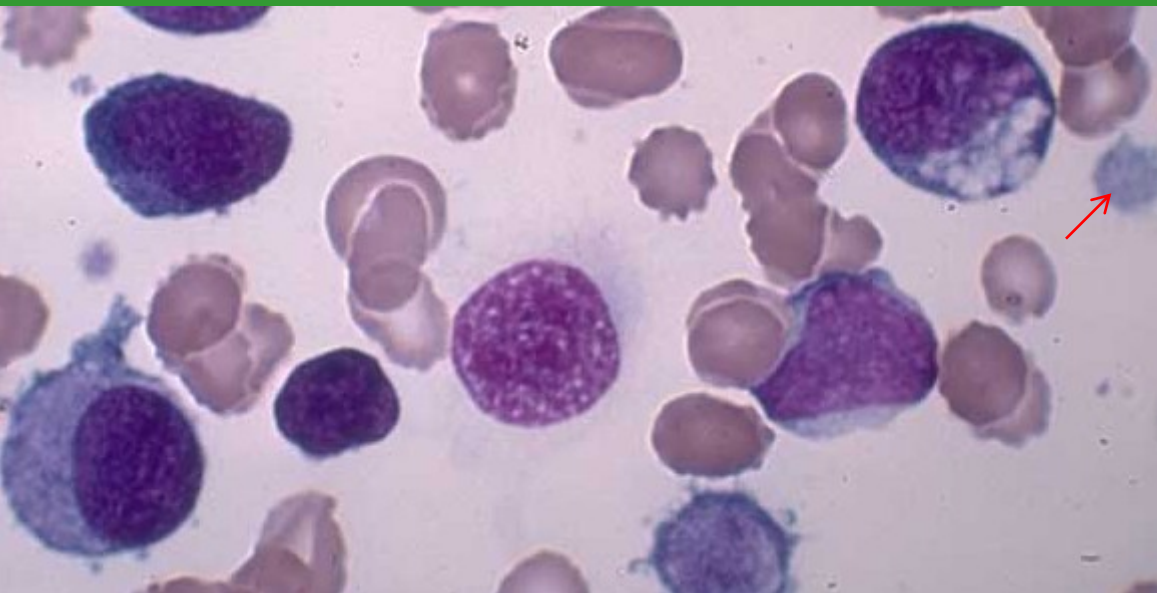
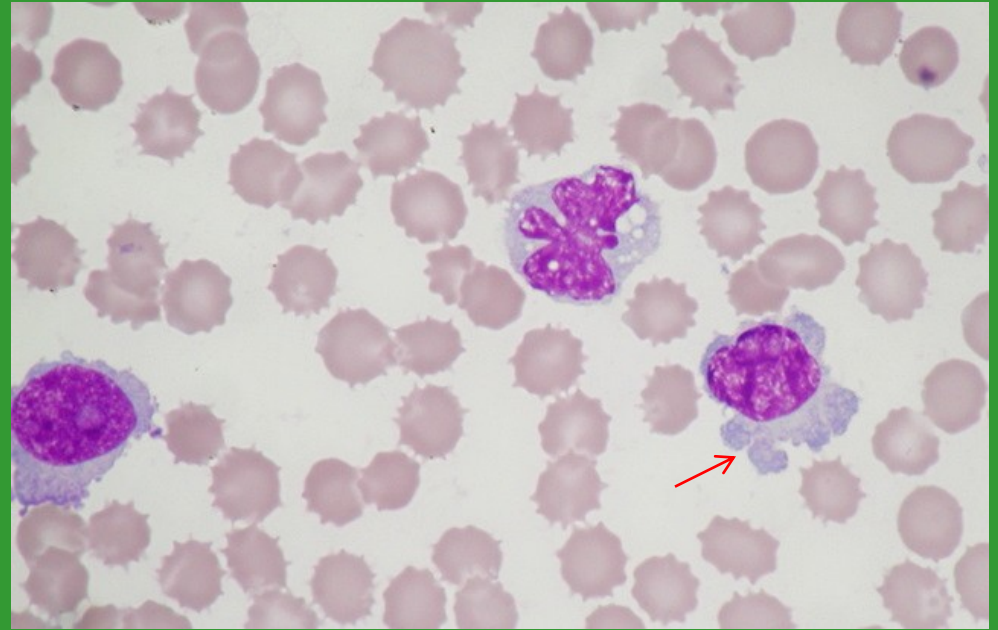
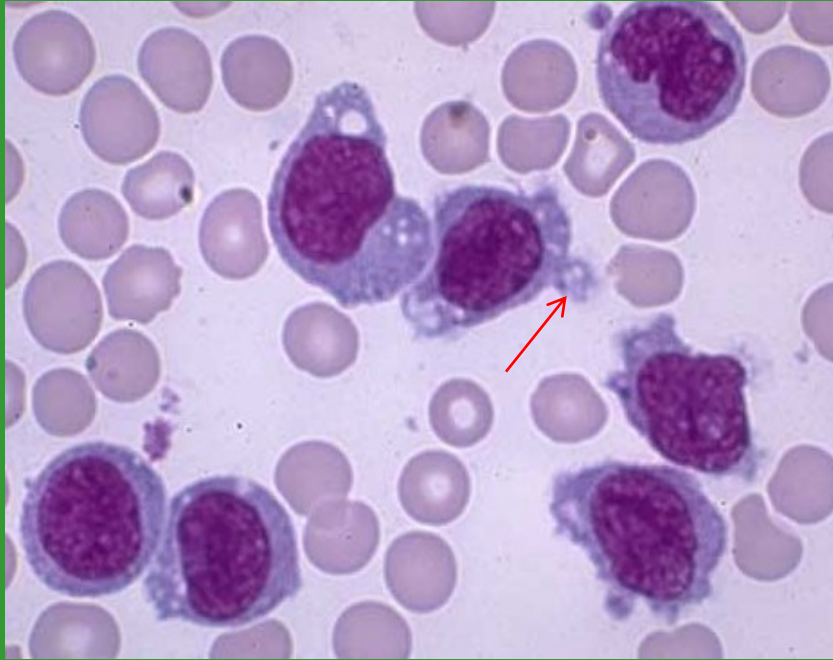
Makrotrombocyty – gigantické trombocyty



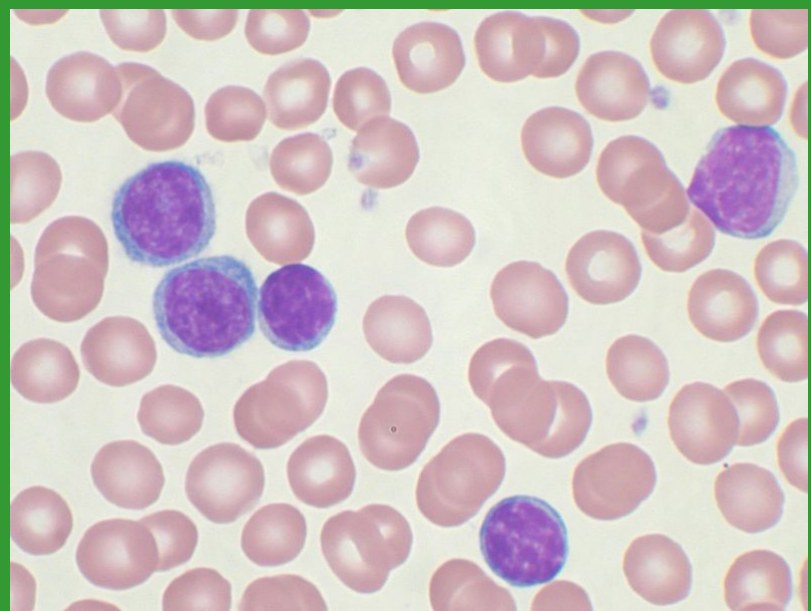
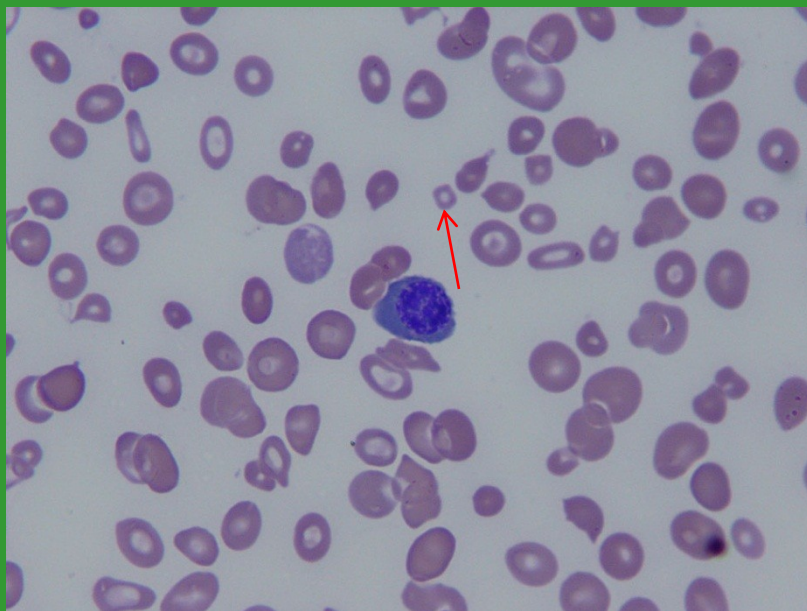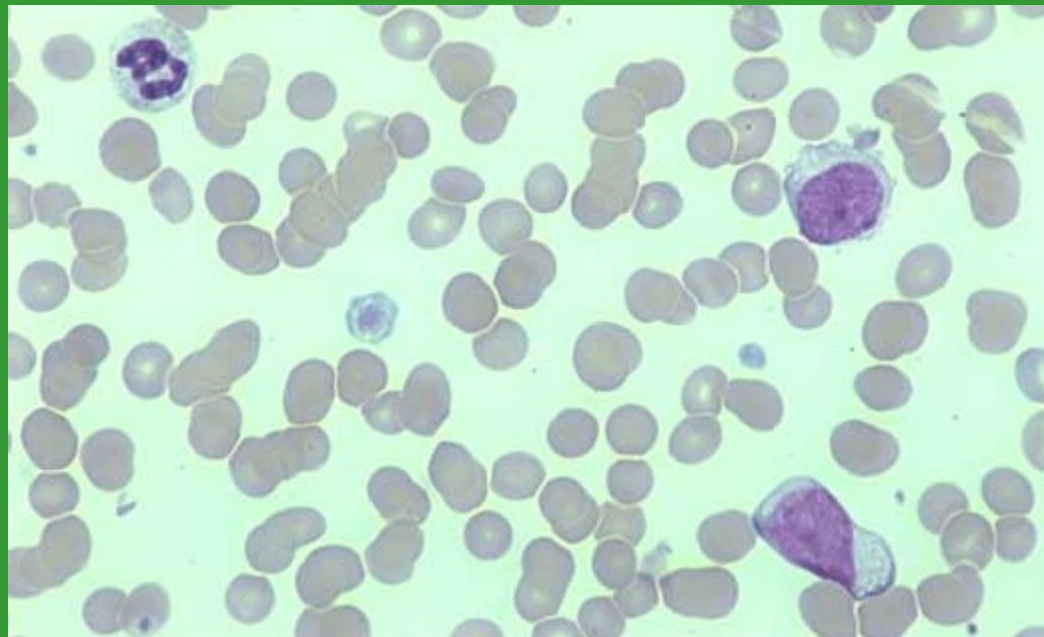
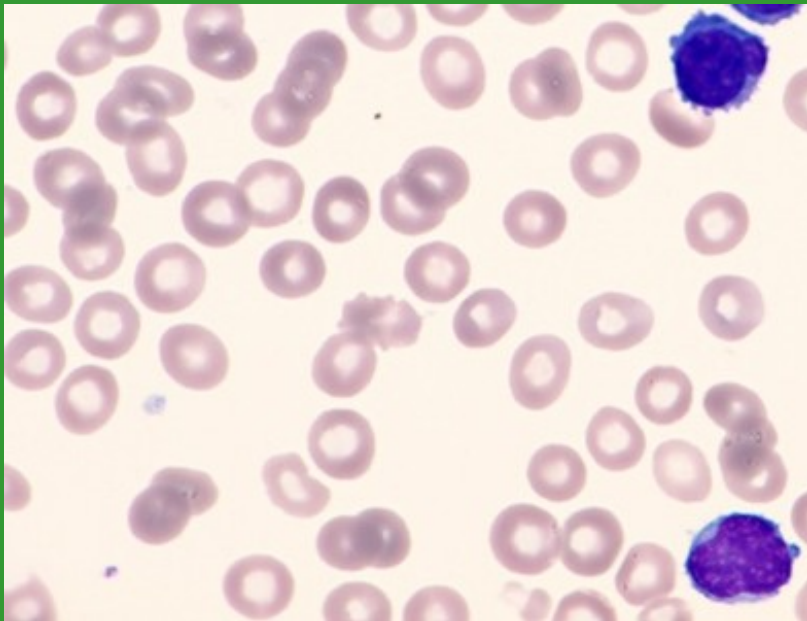
Hypogranulární trombocyty



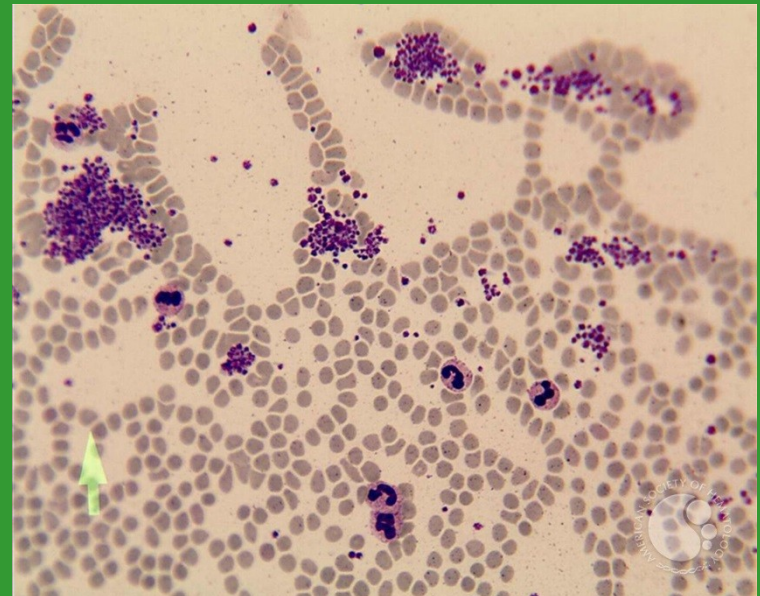
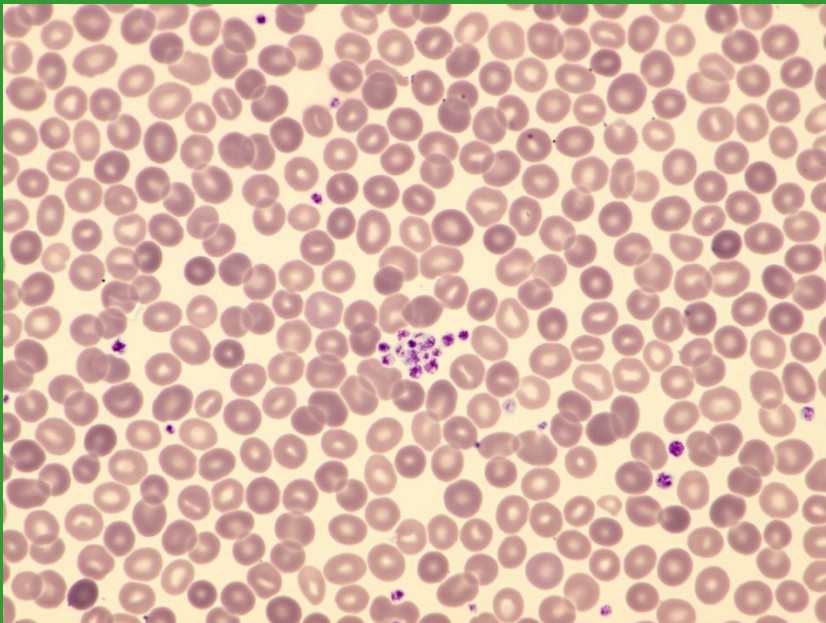
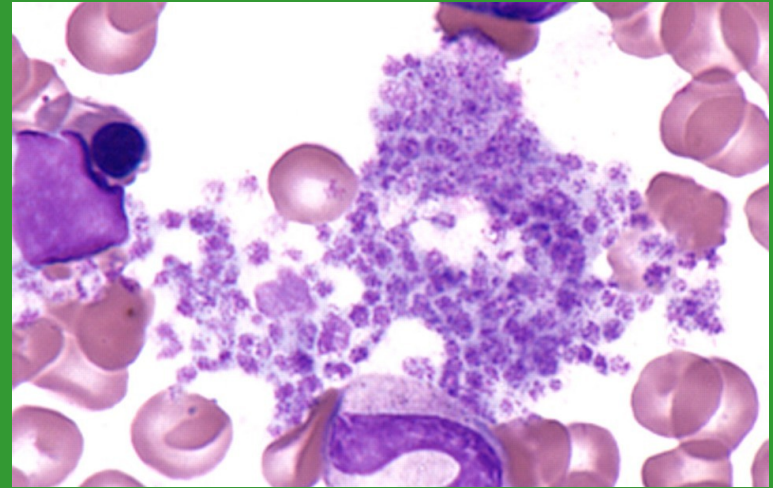
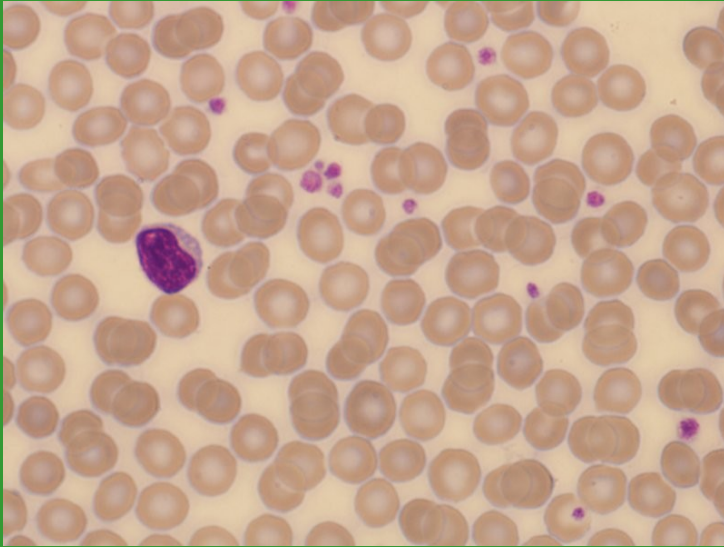
Fragmenty cytoplazmy (MGK x WBC)



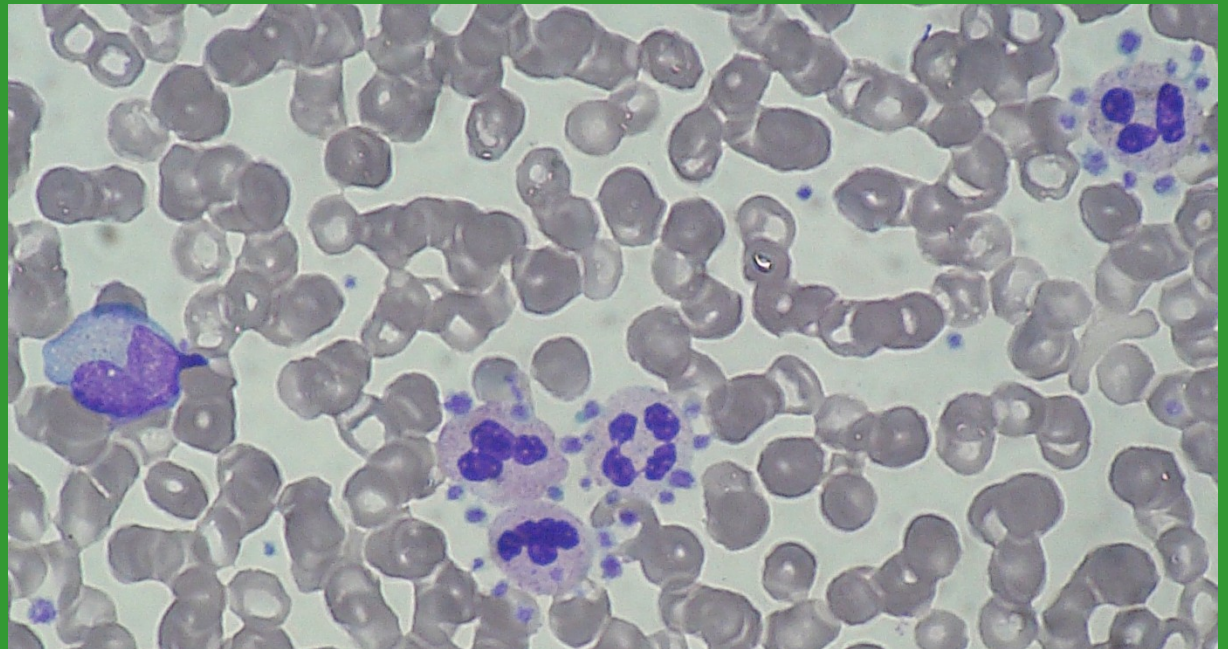
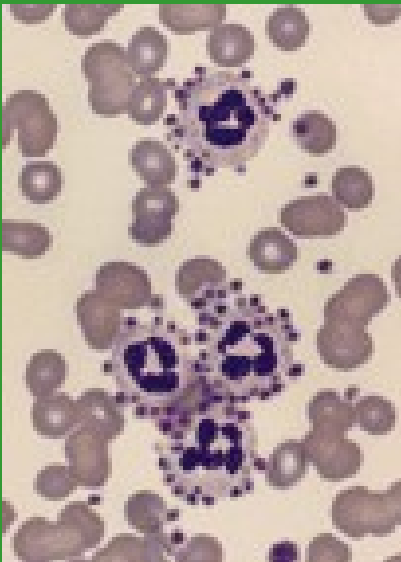
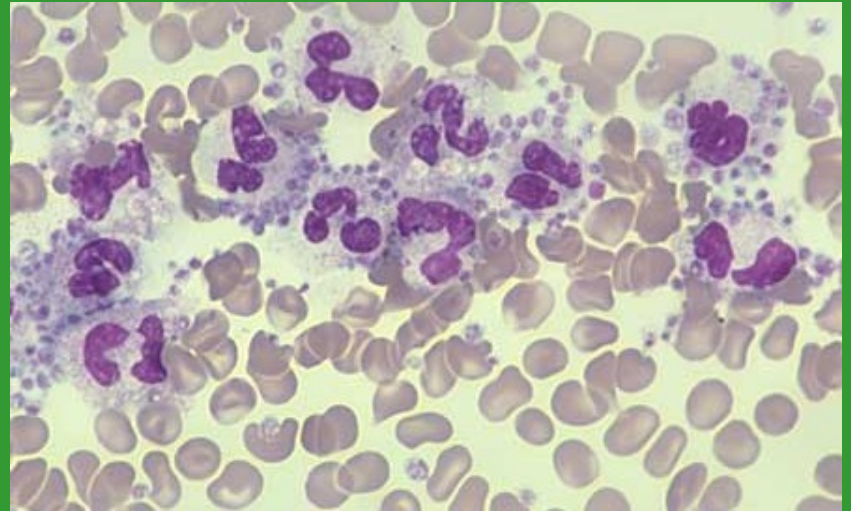
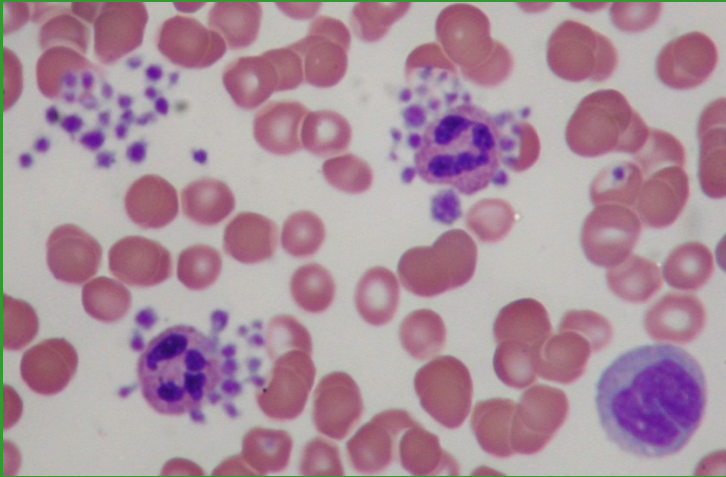
PLT – hypogranulace x buněčné fragmenty x mikrocyty



Shluky/sraženiny trombocytů

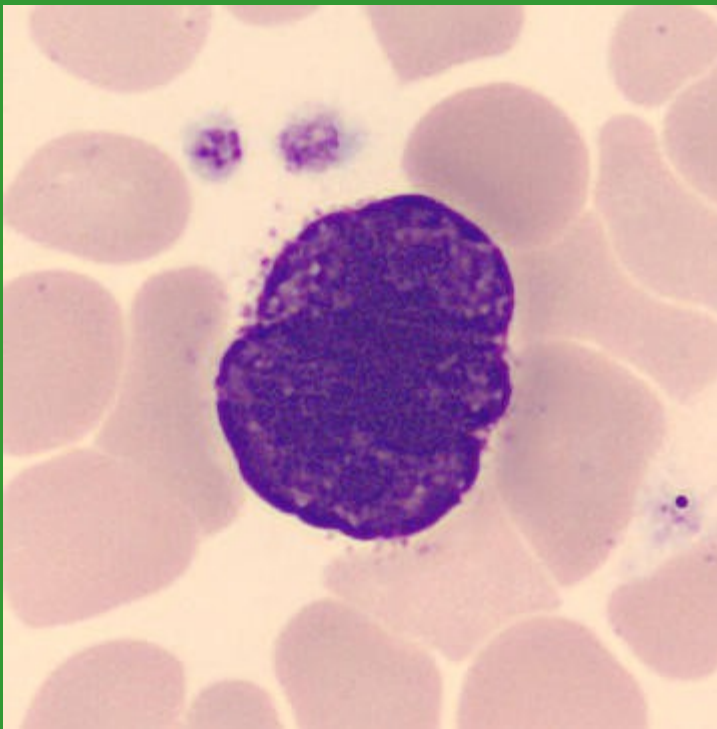


Satelitismus trombocytů



Megakaryocyty

holé jádro MGK v PK



MGK v KD

