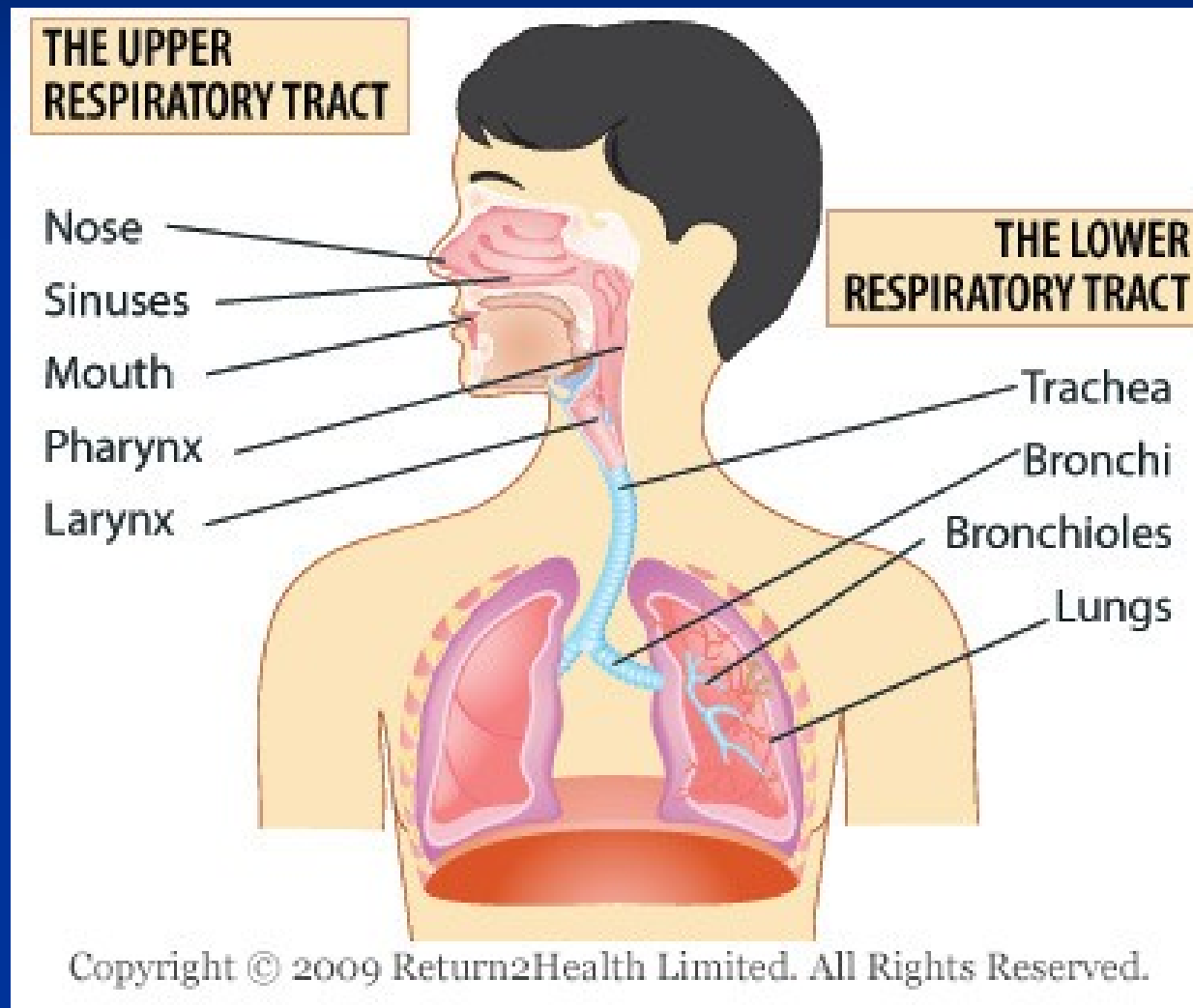


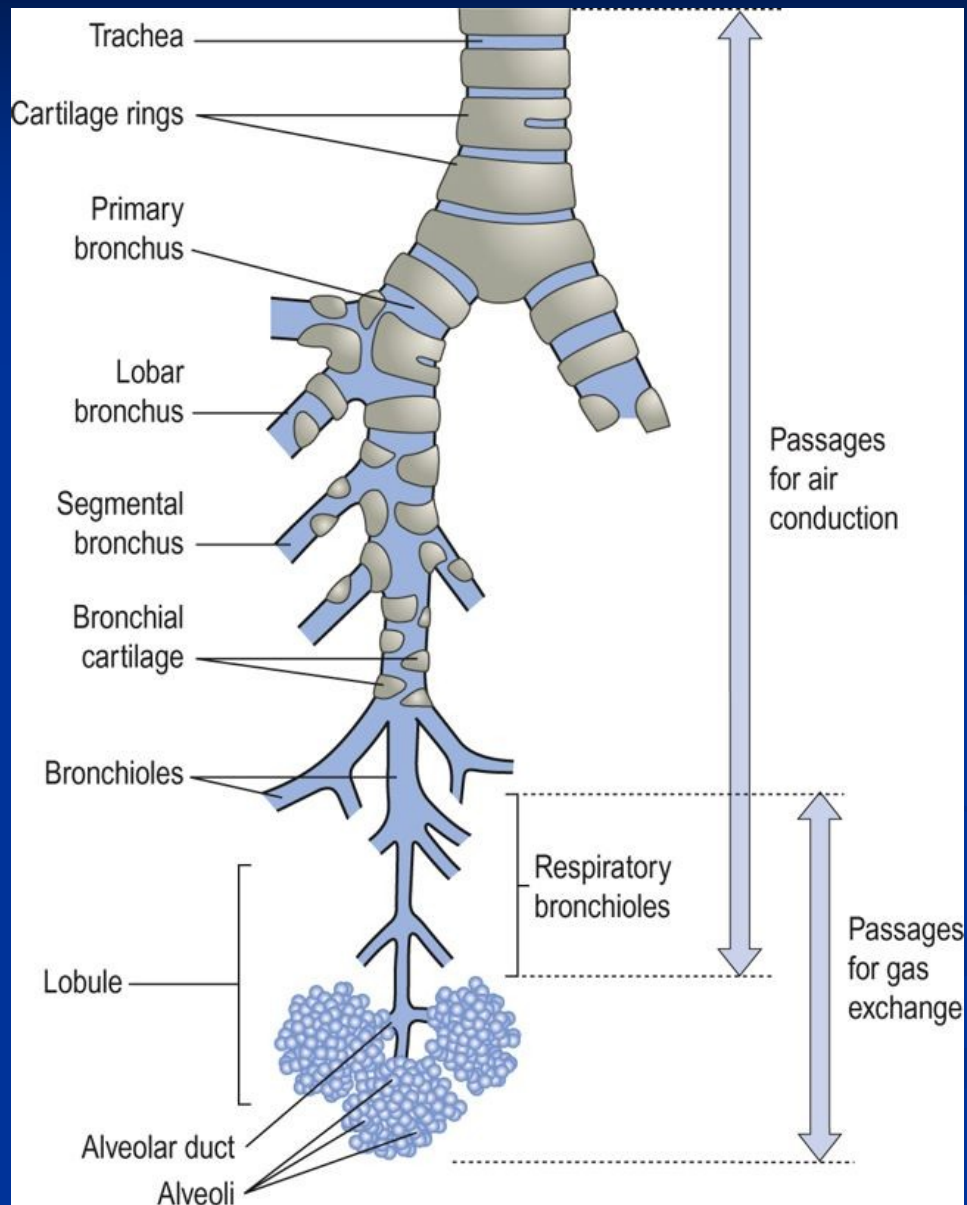
Pathology of the respiratory system

Markéta Hermanová

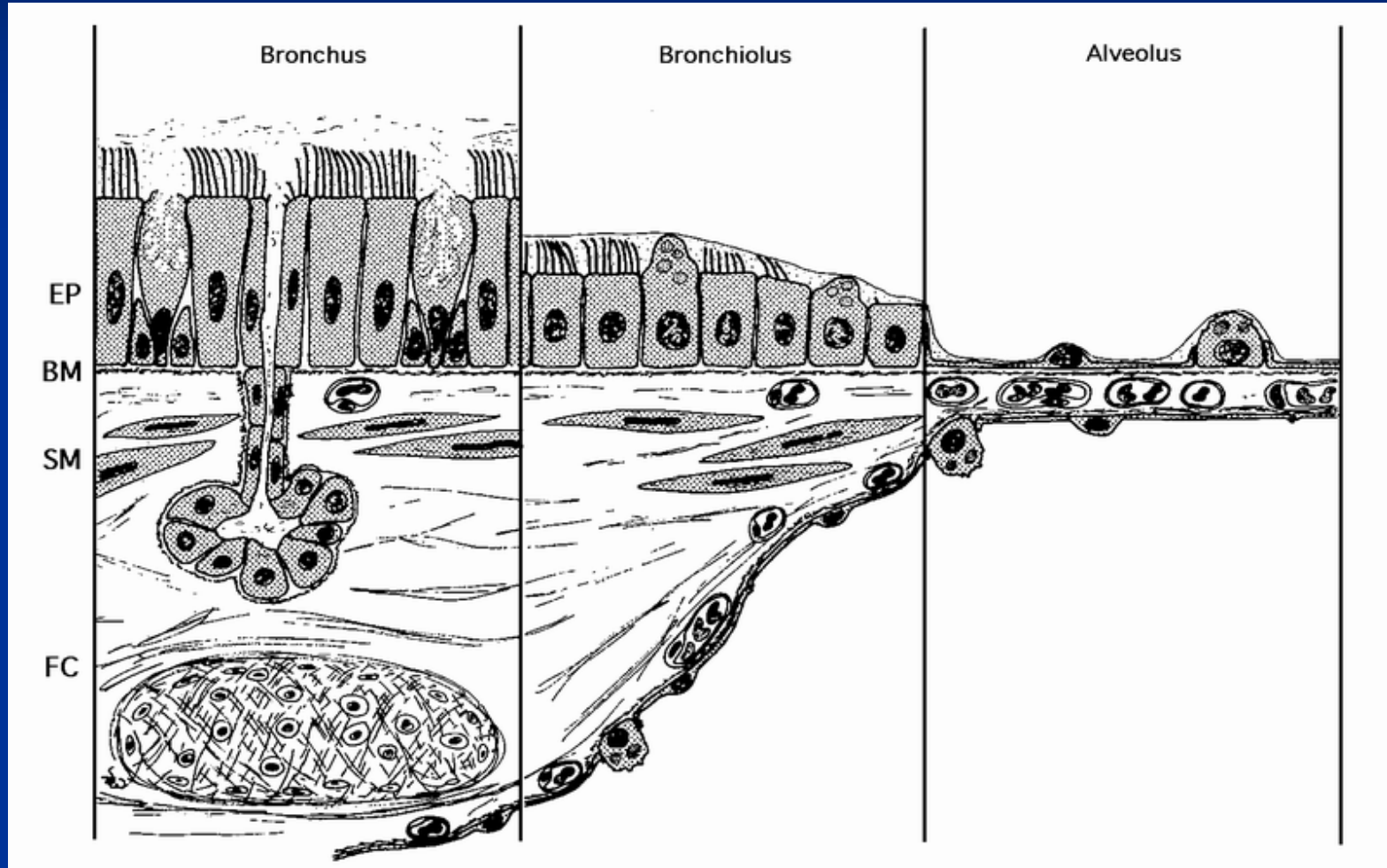
Structures of upper and lower respiratory tract



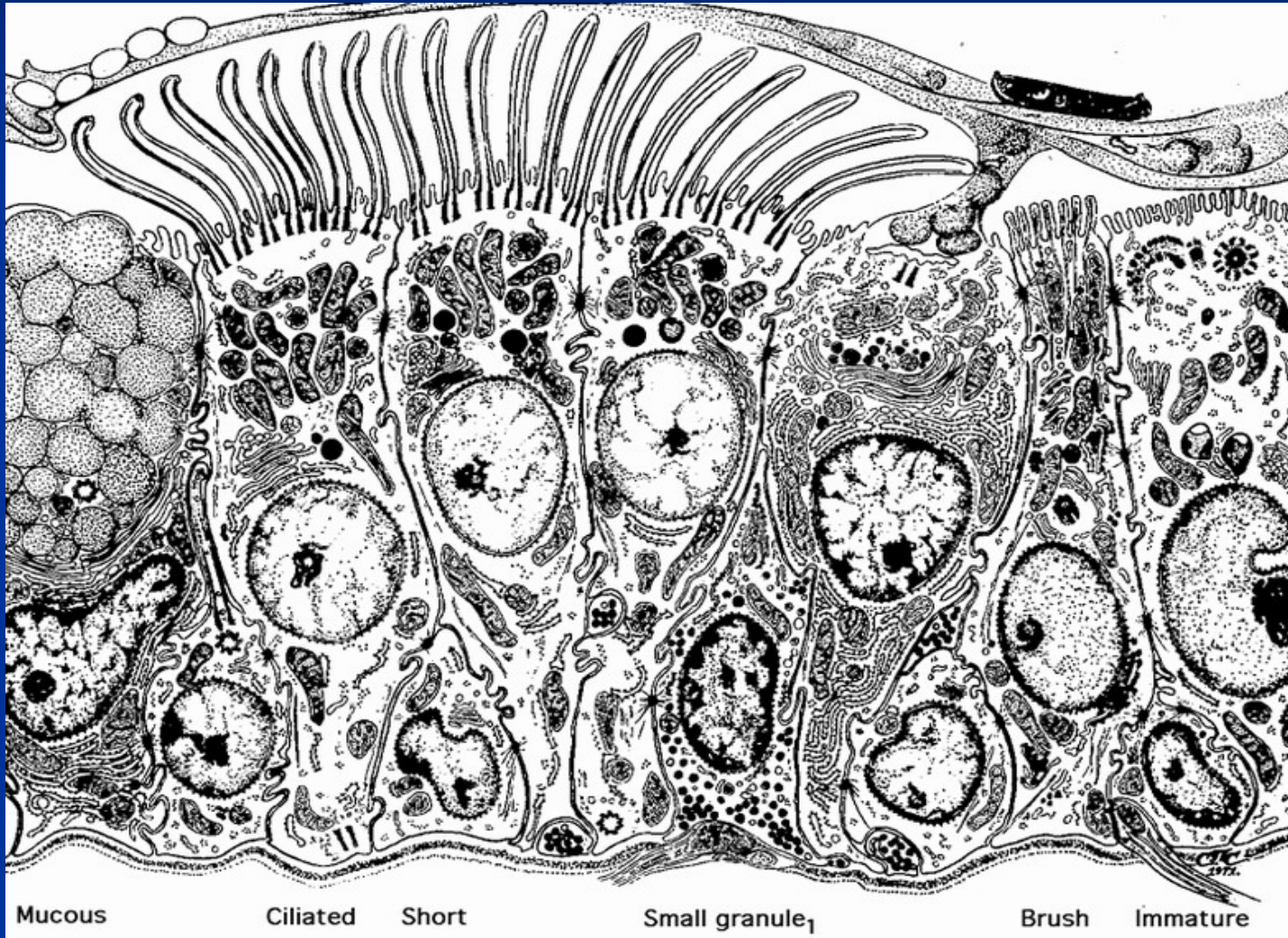
Structure and nomenclature of the lower RT



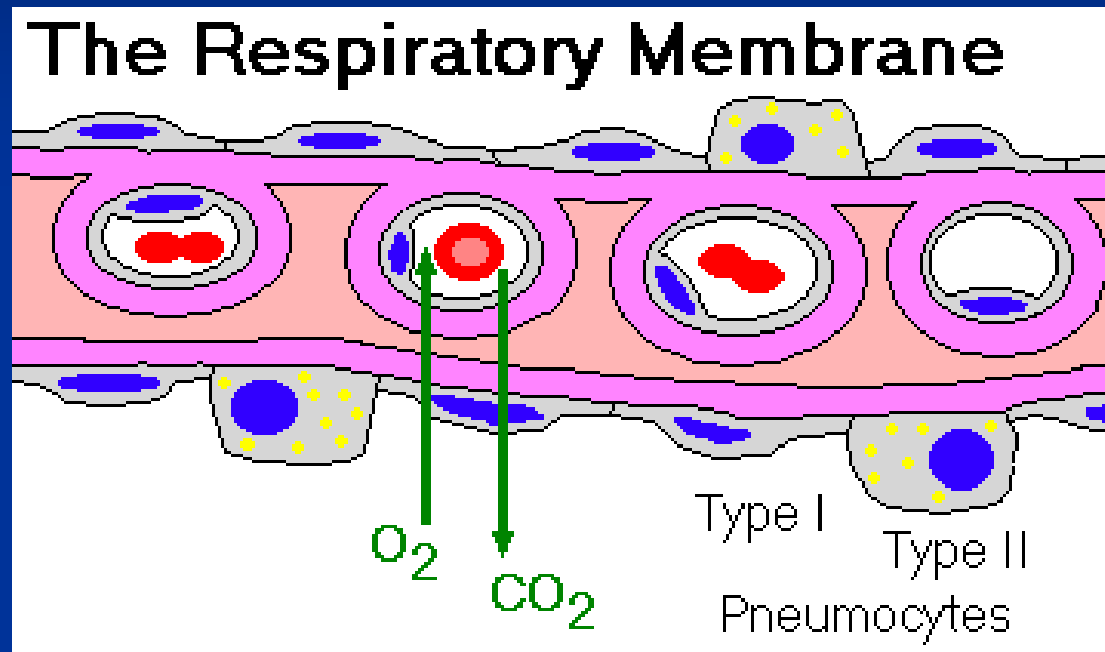
Histology of respiratory tract



Cellular components of bronchial mucosa



The respiratory membrane



Most common signs and symptoms of pulmonary diseases

- Cough
- Dyspnoea
- Abnormal sputum
- Chest pain
- Hemoptysis
- Cyanosis
- Digital clubbing
- Altered breathing patterns

Clinical problem	Respiratory tract (RT) disease
Sputum - Clear or mucoid - Purulent - With blood	Excess secretion of mucus in asthma, chronic bronchitis Inflammatory exudate from RT infection Cardiac failure, pulmonary infarction, ulceration of respiratory mucosa, tumor
Breathlessness	Asthma, chronic bronchitis, emphysema, pneumonia, pneumothorax, pulmonary embolism
Chest pain	Pleuritis, pulmonary embolism
Finger clubbing	Thickening and widening of terminal phalanges in lung cancer, bronchiectasias
Headache	Cerebral metastases from lung cancer
Hemoptysis	RT infection, pulmonary embolism, lung cancer, bronchiectases, tbc
Cough	Reflex response to presence of mucus, exudate, tumor or foreign material
Ankle swelling	Right heart failure due to pulmonary hypertension
Confusion	Hypoxaemia due to respiratory cause

Pathological basis of respiratory signs and symptoms

Sign or symptom	Pathological basis
Wheezing <ul style="list-style-type: none">- On inspiration- On expiration	Narrowing of the proximal airways (e.g. by tumor) Distal bronchial narrowing (e.g. In asthma)
Dyspnoea	Decreased oxygen in blood (impaired alveolar gas exchange, left heart failure, anaemia)
Cyanosis	Increased non-oxygenated haemoglobin (e.g. circulatory bypassing of lungs in congenital heart diseases, impaired alveolar gas Exchange)
Pleuritis pain	Pleural irritation due to inflammation, infarction, tumor
Pleural effusion <ul style="list-style-type: none">- Transudate (low protein)- Exudate (high protein)	Cardiac failure, hypoglobulinaemia (e.g. in cirrhosis, nephrotic syndrome) Pleural inflammation, tumors.
Clubbing	Lung carcinoma, pulmonary fibrosis, cirrhosis, inflammatory bowel diseases
Weight loss	Tbc, tumors

Major aetiological factors of respiratory diseases

Aetiological factor	Disease
Genetic	Cystic fibrosis Alpha-1 antitrypsin deficiency Some asthma
Environmental	
- Smoking	Lung cancer Chronic bronchitis Emphysema Susceptibility to infection
- Air pollution	Chronic bronchitis Susceptibility to infection
- Occupation	Pneumoconiosis Asbestosis Mesothelioma Lung cancer
- Infection	Influenza, measles, bacterial pneumonias, tbc.

Respiratory infections – upper respiratory tract (URT)

■ Rhinitis

- Common cold
- viral and bacterial infections, allergic reaction (hay fever)
- Nasal polyp = chronic hyperplastic rhinitis

■ Sinusitis

- Inflammation of paranasal sinuses; acute or chronic
- Complicated by cranial osteomyelitis, meningitis or cerebral abscess

■ Wegener granulomatosis

- autoimmune disease, vasculitis involving also URT (+ necrotising vasculitis in lungs and glomerulonephritis)

■ Otitis media

- Infection of middle ear, often assoc. with URT infection

Respiratory infections – upper respiratory tract (URT)

■ Laryngitis

- Viral or bacterial
- Diphtheria – was a common and most serious bacterial cause

■ Epiglottitis

- Cause by *Haemophilus influenzae*
- Swollen epiglottis causes airway obstruction (intubation necessary, tracheostomy)

Respiratory infections – lower respiratory tract (LRT)

■ Bronchitis

- Cough, dyspnoe, tachypnoe, sputum
- Acute or chronic (cough and sputum 3 months in 2 years, often in smokers)
- Viral or bacterial (*Haemophilus influenzae*, *Streptococcus pneumoniae*)

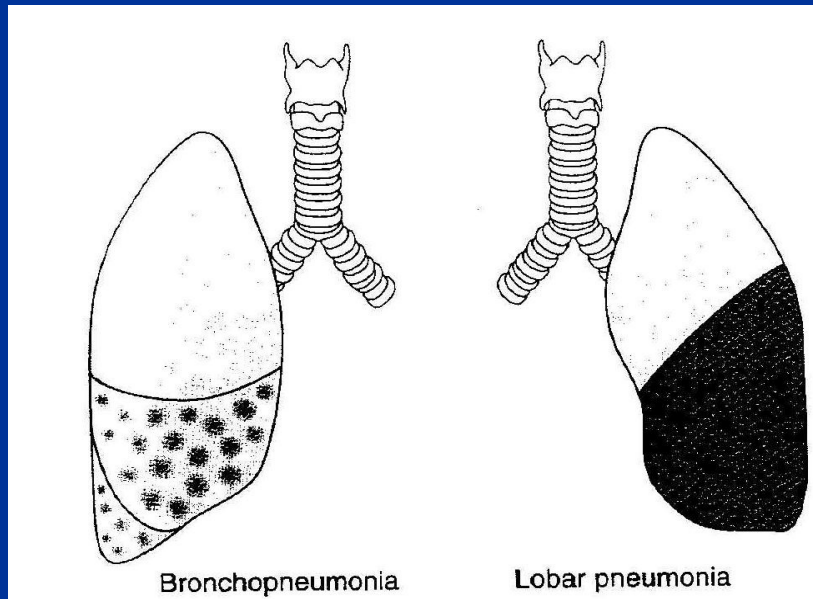
■ Bronchiolitis

- Usually primary viral infection in infants (RSV), causes dyspnoe and tachypnoe
- May be secondary to other inhaled irritants, also a part of systemic disease (by pathologic immune reaction)

Respiratory infections – lower respiratory tract (LRT): Pneumonia

- Alveolar inflammation
- Bronchopneumonia and lobar pneumonia

- Patchy consolidation
- Centred on bronchioles or bronchi
- Purulent inflammation
- Often in infancy or old age
- Often secondary



- Affects segments or whole lobe
- Uncommon in infancy and old age
- Males more than females
- 90 % due to *Streptococcus pneumoniae*
- Cough and fever with sputum
- Fibrinous inflammation
- Healing complicated by fibrotisation

Pulmonary infections

- **Factors which favor the pneumonia**
 - Chronic diseases
 - Immunologic deficiency, immunosuppressive treatment
 - Unusual virulent infections, nosocomial infections
 - Loss or suppression of the cough reflex (neuromuscular disorders, chest pain, drugs; could cause aspiration of gastric content,...)
 - Injury of mucociliary apparatus (smoking, viral disease, genetic disorders, inhalation of hot or corrosive gases,...)
 - Pulmonary congestion and edema
 - Accumulation of secretion (bronchial obstruction, mucoviscidosis,...)

Implications for therapists

- Careful hand hygiene
- Adequate hydration and airway clearance technique
(deep breathing, coughing and ventilation-perfusion
ventilatory support and supplemental oxygen)
- Proper positioning

Pneumonia syndromes

- **Community-acquired acute pneumonia**

(streptococcus pn., haemophilus inf., Moraxella cat., Staphylococcus a., Legionella pn., Klebsiella pn., Pseudomonas ae.,...)

- **Community-acquired atypical pneumonia**

(Mycoplasma pn., Chlamydia spp., Coxiella burnetti, viruses,...)

- **Nosocomial pneumonia**

(G- rods (Klebsiella spp., Serratia marcescens, E. coli, Pseudomonas spp.,...))

- **Aspiration pneumonia**

(mixture of anaerobic and aerobic flora)

- **Chronic pneumonia**

(Nocardia, Actinomyces, granulomatous (mycobacterium tbc, atypical mycobacteria, Histoplasma capsulatum, Coccidioides immitis, Blastomyces dermatidis)

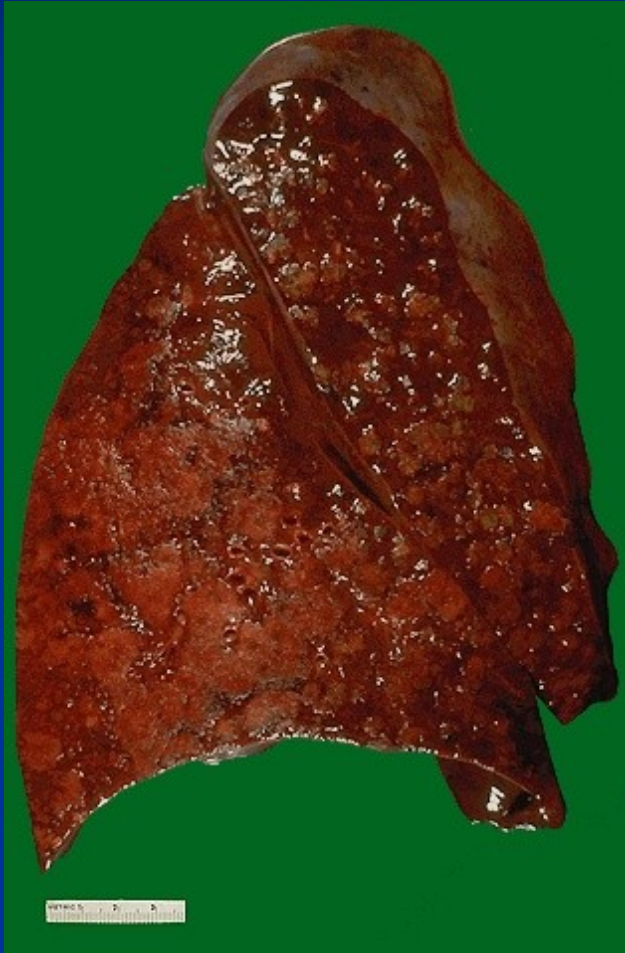- **Necrotizing pneumonia and lung abscess**

(mixture of aerobic and anaerobic flora, Staphylococcus a., Klebsiella pn., Streptococcus pyogenes and pneumoniae)

- **Pneumonia in the immunocompromised host**

(CMV, Pneumocystis c., Mycobacterium avium intracellulare, aspergillus, Candida a. and others listed above,...),

Bronchopneumonia



Atypical pneumonias (usually interstitial)

■ Infective

In non-immunosuppressed hosts

- Viral and mycoplasma pneumonia
- Legionnaires' disease (*Legionella pneumoniae*)

In immunosuppressed hosts

- *Pneumocystis carinii*
- Fungi (e.g. *Candida albicans*, *Aspergillus*)
- Viruses (CMV, HSV, varicella zoster)

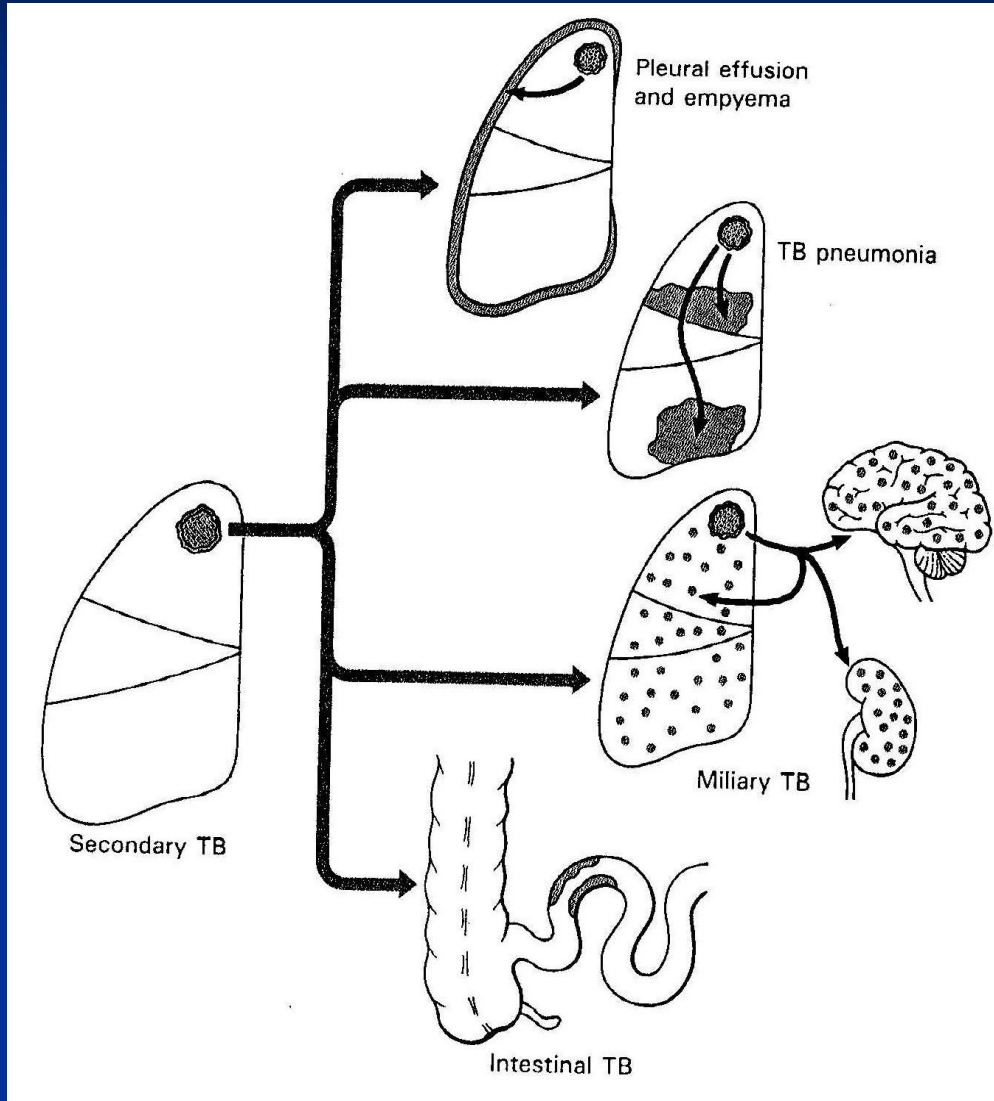
■ Non-infective

- Idiopathic interstitial pneumonitis and fibrosis (v.s. autoimmune)
- Cryptogenic organizing pneumonia = bronchiolitis obliterans
- Aspiration pneumonia (primarily non interstitial, often with lung abscess)
- Eosinophilic (v.s. allergic) and hypersensitivity pneumonitis
- Pulmonary involvement in collagen vascular diseases

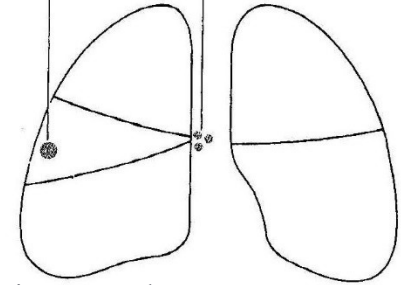
(systemic lupus erythematoses, rheumatoid arthritis, progressive systemic sclerosis (scleroderma), dermatomyositis-polymyositis, mixed connective tissue disease)

Alveolar walls = interstitium in lungs....in interstitial inflammation the inflammatory infiltrate within the alveolar walls...complication of alveolocapillary gas exchange

TBC of the lungs

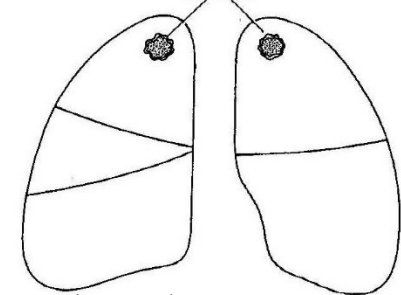


Small, mid-zone lesion Hilar lymph nodes involved



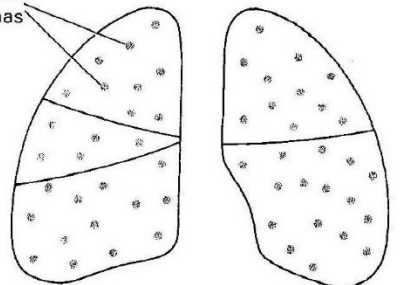
A primary tbc

Apical lesions, often bilateral



B secondary tbc

Small granulomas



c miliary tbc

■ Obstructive pulmonary diseases

(increase in resistance to airflow due to partial or complete obstruction at any level)

- Chronic bronchitis
- Emphysema
- Asthma
- Bronchiectasia

Chronic bronchitis + emphysema = chronic obstructive pulmonary disease (COPD)

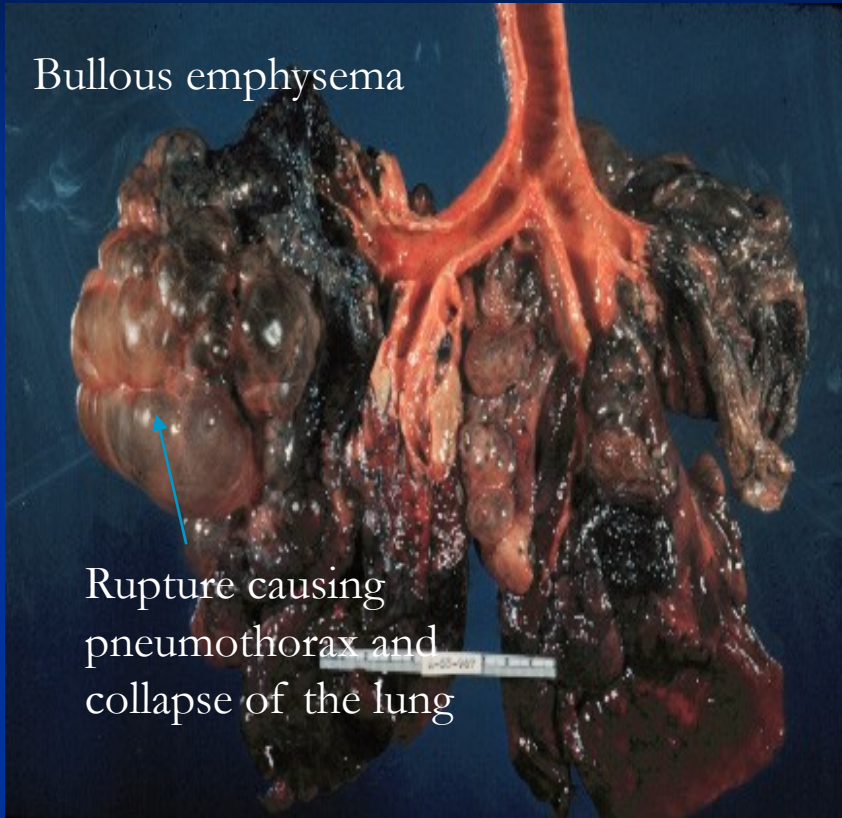
■ Restrictive pulmonary diseases

(reduced expansion of lung parenchyma with decreased total lung capacity)

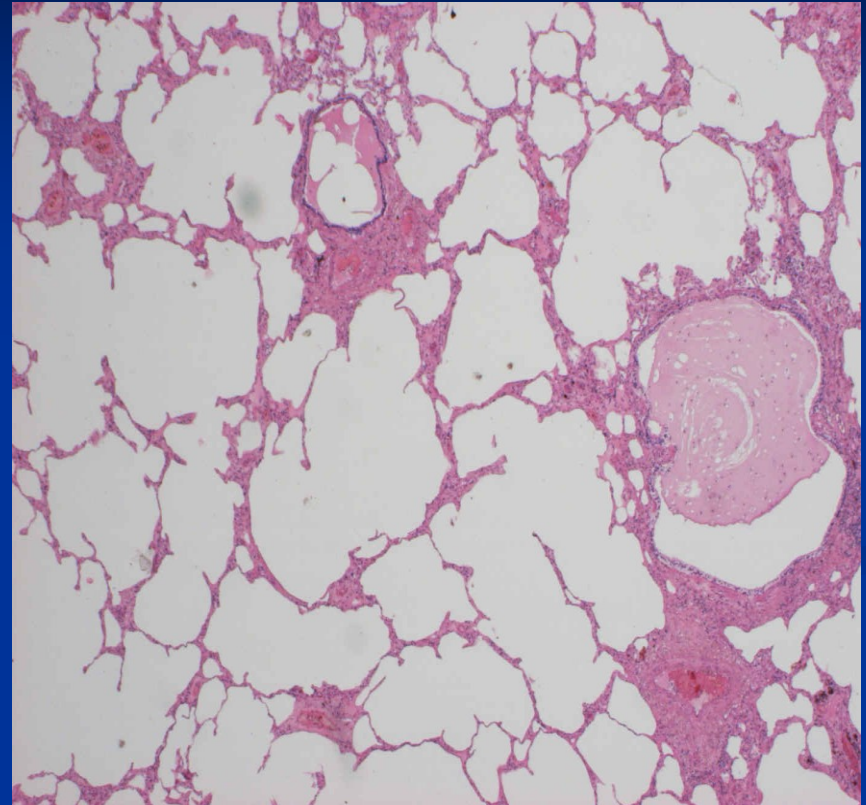
- Chest wall disorders in presence of normal lungs (kyphoscoliosis, pleural diseases, severe obesity, neuromuscular disorders such as poliomyelitis)
- Acute or chronic interstitial and infiltrative diseases

Emphysema

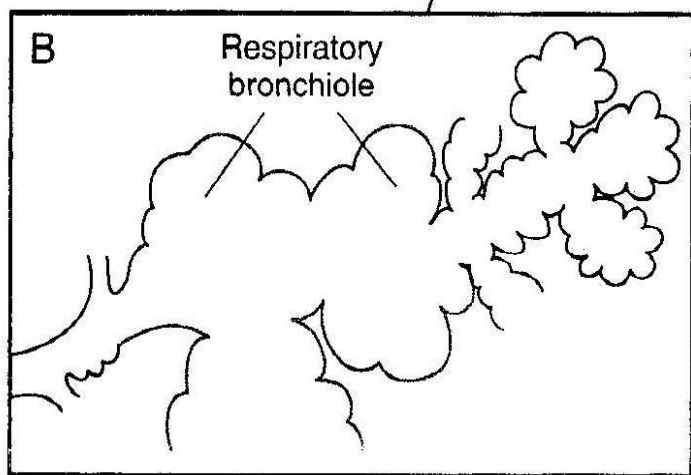
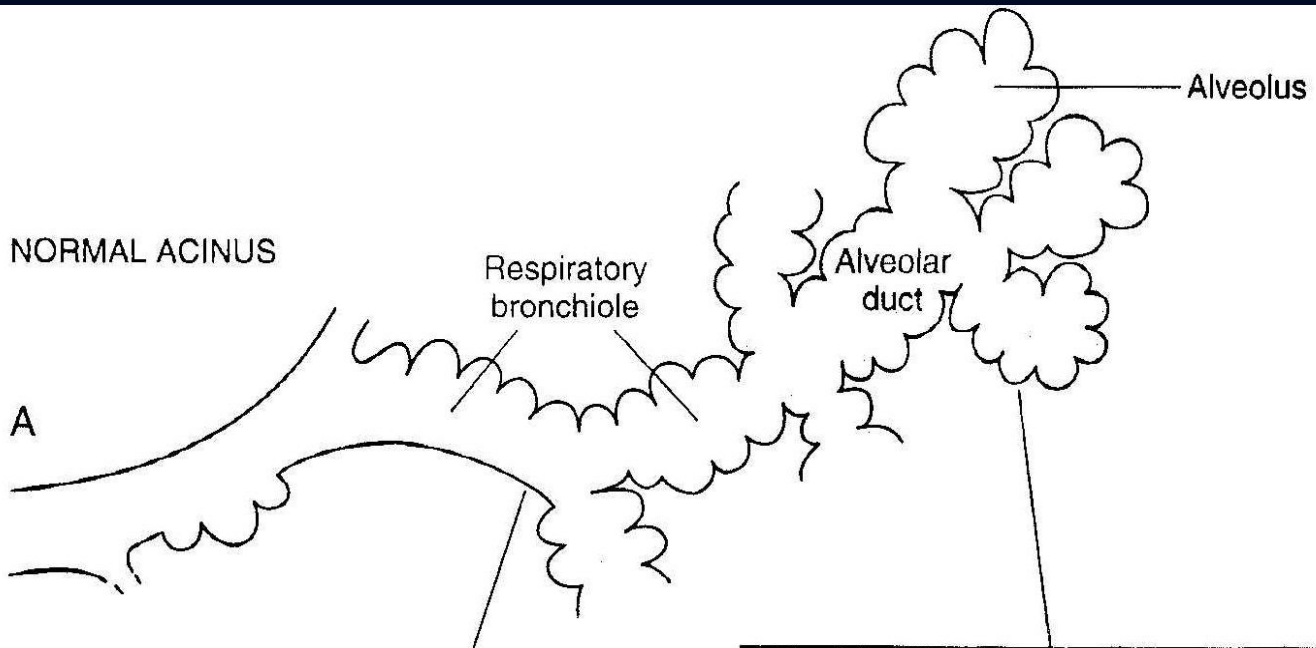
Bullous emphysema



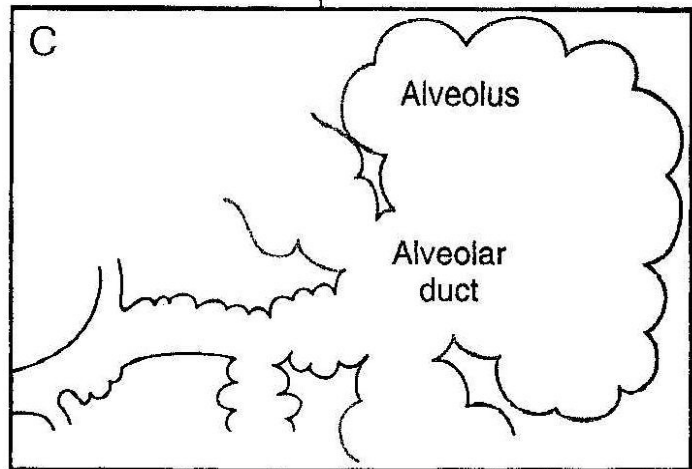
Rupture causing
pneumothorax and
collapse of the lung



- Abnormal enlargement of alveolar airspaces
- Usually seen in smokers in association with chronic bronchitis.
- Risk factors: smoking, alpha-1antitrypsin deficiency (inhibitor of proteases)



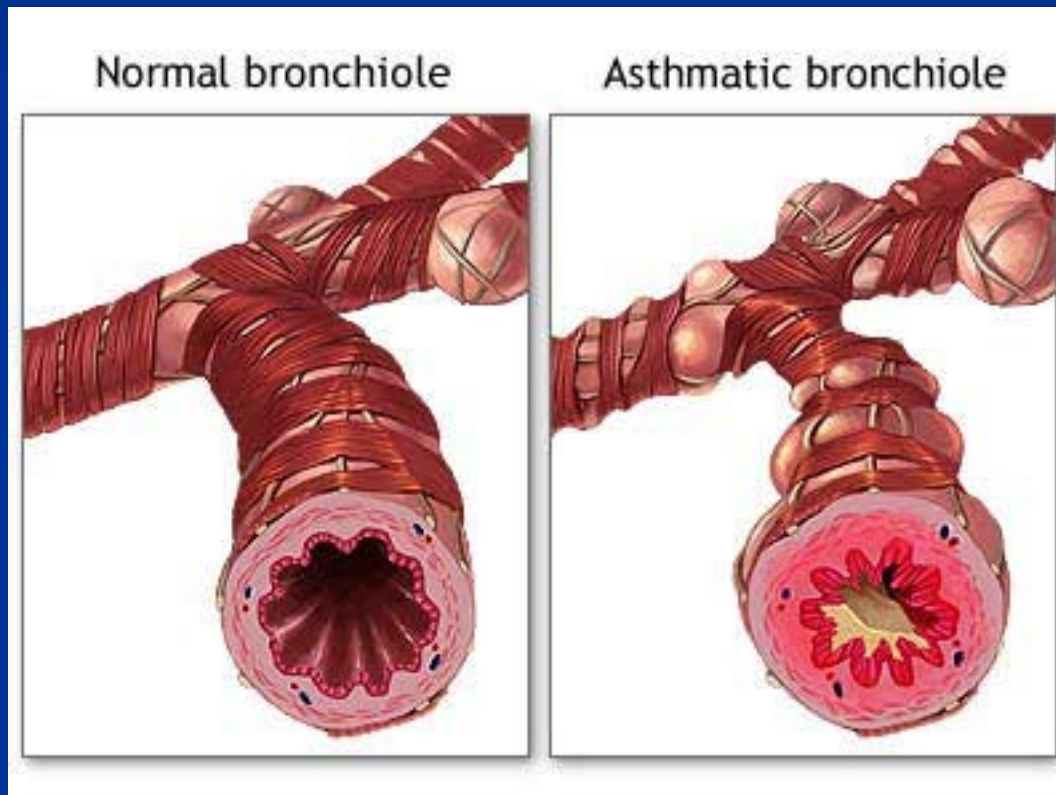
Centriacinar emphysema



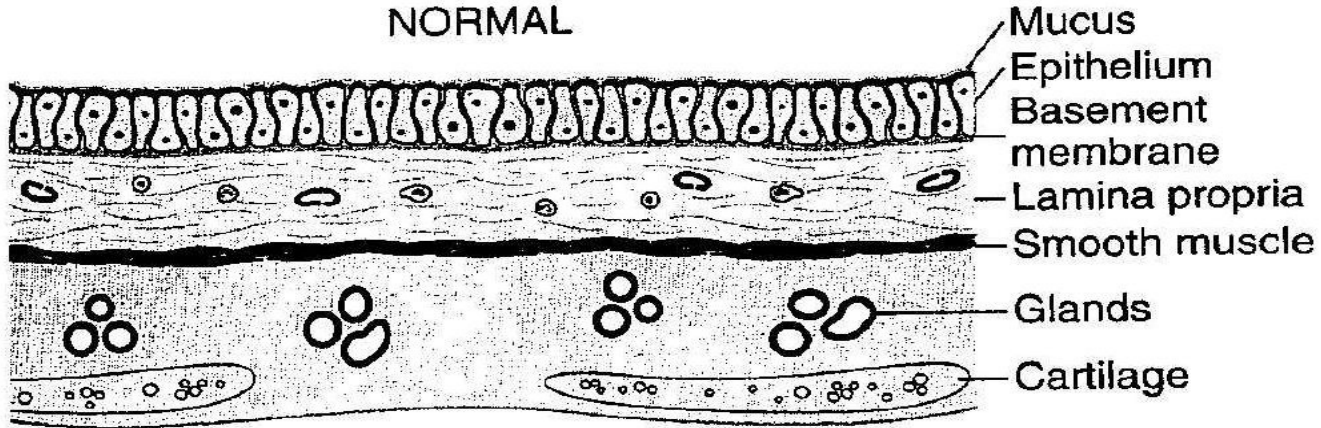
Panacinar emphysema

Asthma bronchiale

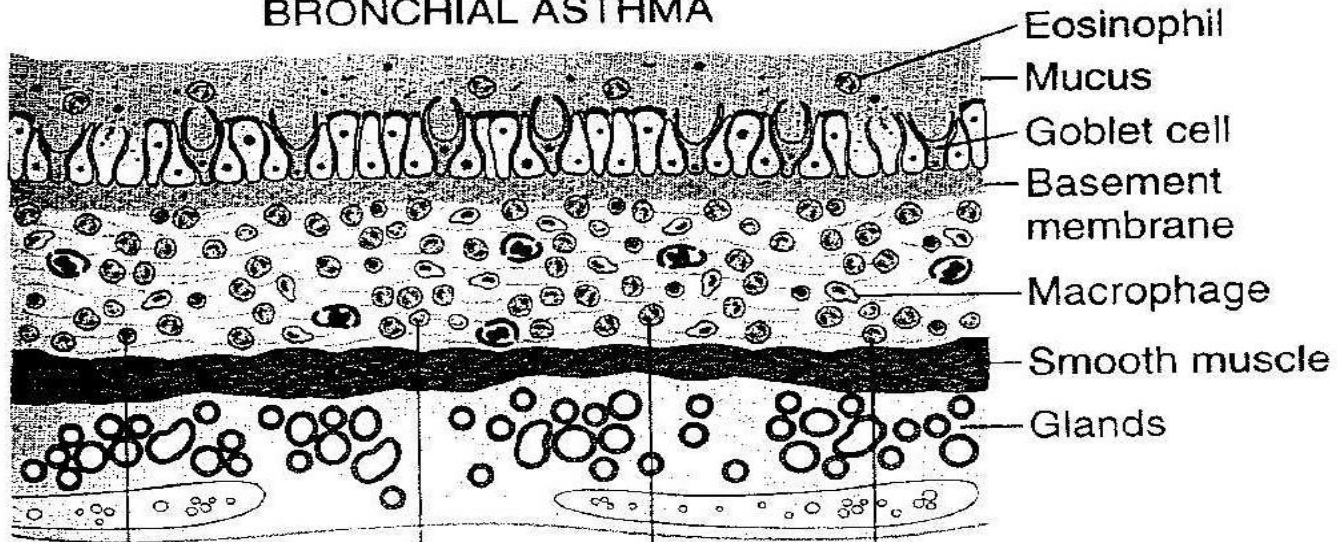
- Reversible small airways obstruction characterised by bronchospasm, inflammation and oedema. Paroxysmal attacks
- Overdistended lungs, mucous plugs in bronchi, mucous gland and smooth muscle hypertrophy



NORMAL



BRONCHIAL ASTHMA



Lymphocyte
(CD4+, T_H2)

Neutrophil

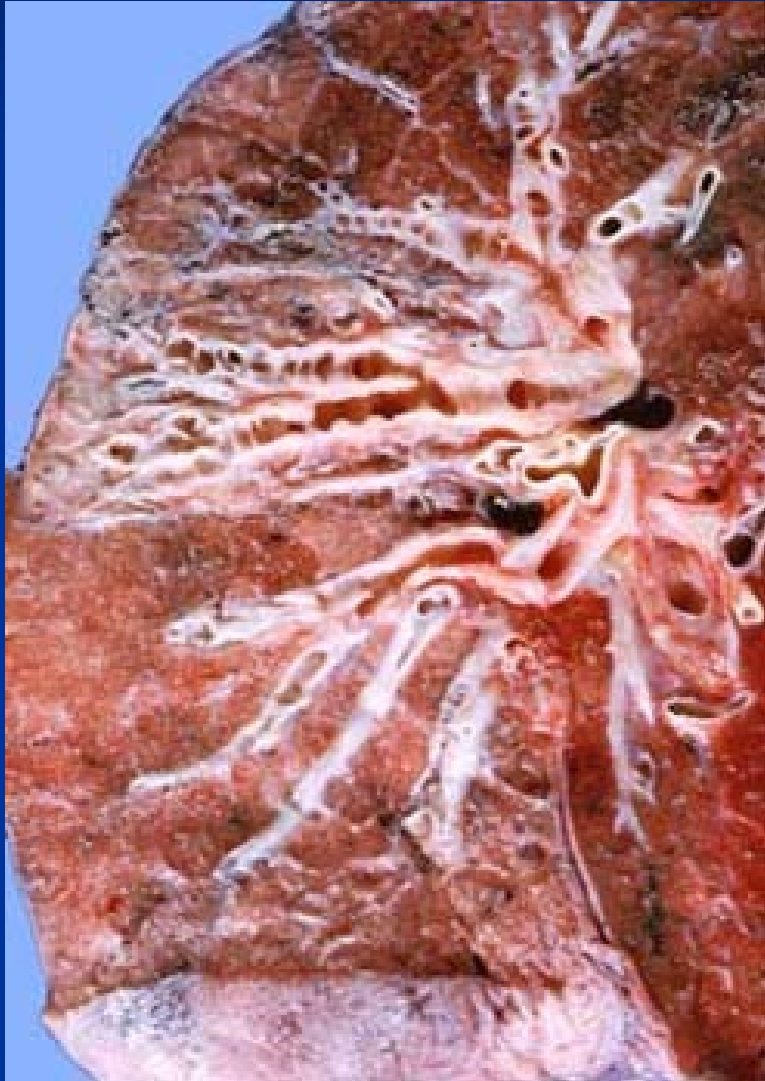Eosinophil

Mast cell

Asthma bronchiale

- **Extrinsic, atopic**
(IgE-mediated external allergens)
- **Intrinsic, non-atopic, idiopathic**
(secondary to infection?)
- **Aspirin – induced**
- **Allergic bronchopulmonary aspergillosis**
- **Occupational**
- **(Exercise – induced)**

Bronchiectasis: permanent dilatation of bronchi and bronchioles



- Results from pulmonary inflammation and scarring due to infection, bronchial obstruction or lung fibrosis (e.g. after radiotherapy)
- Secondary inflammation lead to further destruction of airways
- Chronic cough with dyspnoea and production of copious amount of foul-smelling sputum
- Complications: pneumonia, abscess, amyloid, pulmonary fibrosis, cor pulmonale
- Arise from: genetic conditions (cystic fibrosis), childhood infections, chronic lung infections (tbc), radiotherapy in lung and breast cancer, distal to bronchial obstruction, immunodeficiency, aspergillosis

Implications for the therapists

- **Pulmonary rehabilitation**
- **Smoking cessation, physical activity**

(breathing exercises, airway clearance techniques, physical training, program to improve posture and conditioning of respiratory musculature)

Pulmonary edema (congestion)

■ Hemodynamic

1. Increased pulmonary venous pressure – venostatic edema (left sided heart failure, mitral stenosis or incompetence, volume overload, pulmonary vein obstruction)
2. Decreased oncotic pressure (hypoalbuminemia, nephrotic syndrome, liver disease, protein losing enteropathies)
3. Lymphatic obstruction

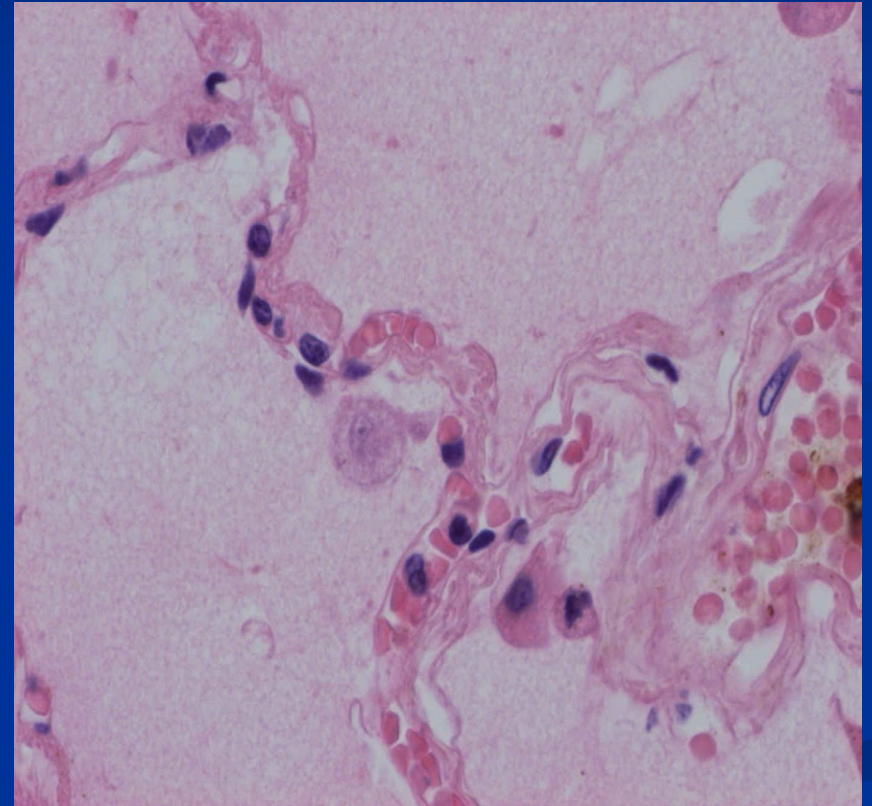
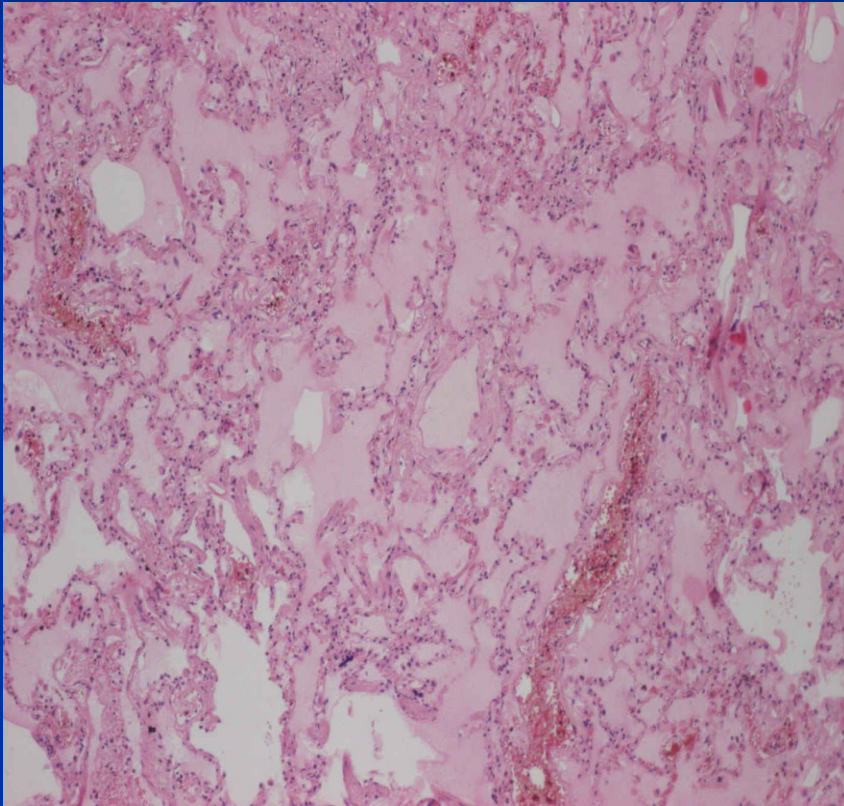
■ Due to microvascular injury (alveolar injury; leakage of fluids and proteins into interstitium and later into alveoli)

1. Infections (pneumonia, septicemia), shock, trauma
2. Inhalation of toxic gases
3. Liquid aspiration
4. Drugs, chemicals
5. Radiation

■ Undetermined origin

1. High altitude
2. CNS trauma

Pulmonary edema



- working with a client already diagnosed with PE – sitting position preferred..

Atelectasis; collapse

- **Atelectasis** (primary; neonatal; immature neonates, lack of surfactant)

- **Collapse** (secondary, previously inflated lungs) = acquired atelectasis
 1. **Obstruction** (resorption of the air after the blockage)
 2. **Compression** (hydrothorax, pneumothorax, pleural exsudate)
 3. **Contraction atelectasis** (fibrotic changes prevent full expansion)

**Acute respiratory distress syndrome (in adults - ARDS) –
diffuse alveolar damage (DAD) – shock lung:**

Acute respiratory failure after a systemic or pulmonary insult

- **Diffuse pulmonary infections, sepsis**
- **Gastric aspiration**
- **Chemical injury** (heroin, methadon, barbiturate overdose, acetylsalicylic acid)
- **Physical injury**
- **Hematologic conditions** (DIK, multiple trasfusions)
- **Pancreatitis**
- **Uremia**
- **Inhaled irritants** (oxygen toxicity, smoke, toxic gases)
- **Hypersenzitivity reaction** (organic solvents, drugs – anticancer treatment)
- **Cardiopulmonary bypass**

Pneumoconioses

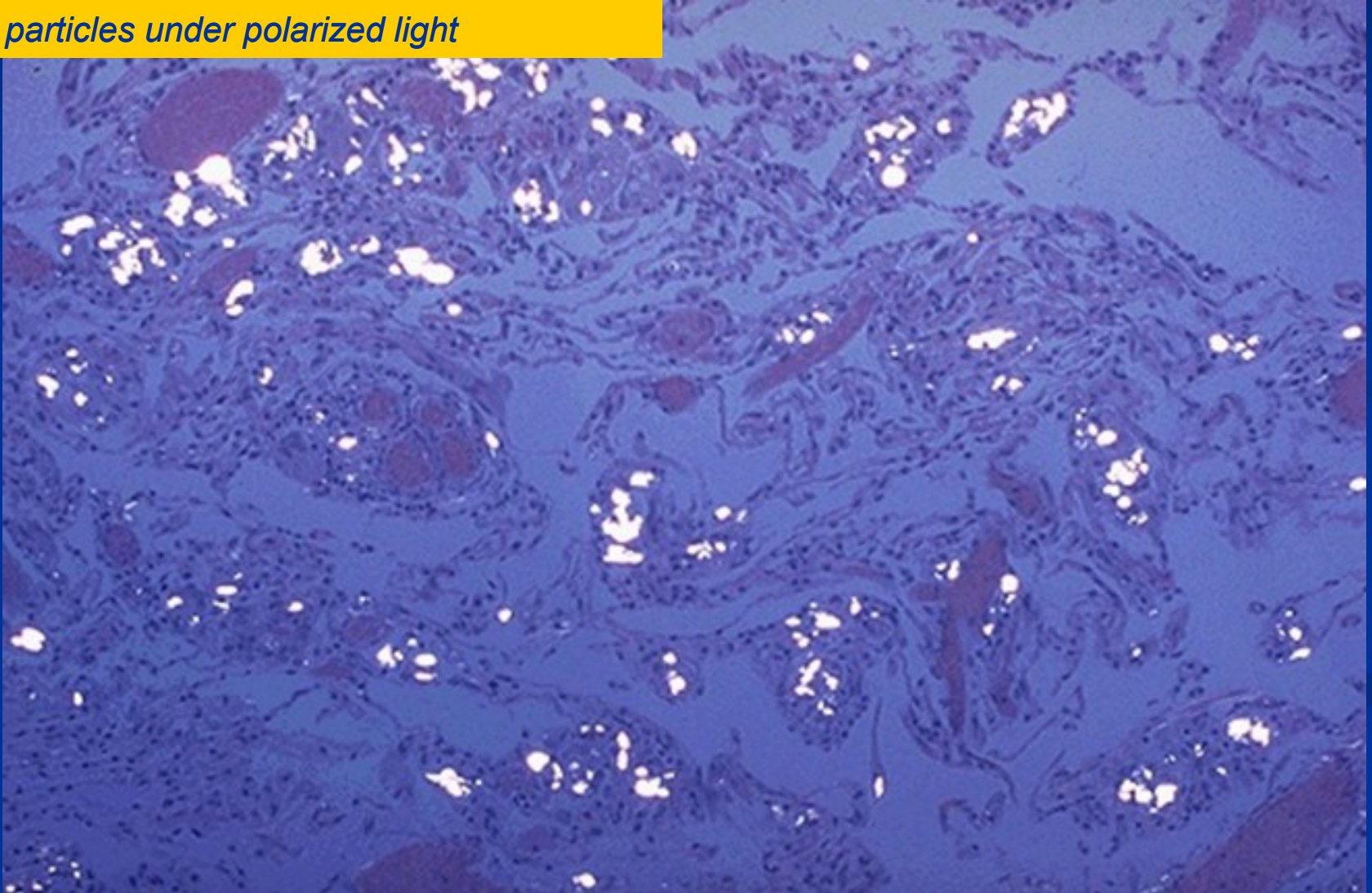
- Non-neoplastic lung reaction (usually occupational) to inhalation of organic (mineral dusts) as well as inorganic particulates and chemical fumes and vapors

Consequences of inhalation of different materials:

- **Inert** (does not induce fibrotisation), e.g. simple coal workers pneumoconiosis (inhalation of coal dust, anthracosis caused by inhaled carbon)
- **Fibrous**, e.g. silicosis (silica inhalation), asbestosis resulting in lung fibrosis, respiratory insufficiency and cor pulmonale
!!!increased risk of mesothelioma and lung cancer in asbestosis!!!
- **Allergic** (inhalation of organic dusts, e.g. Farmer's lung)

Pulmonary silicosis

Silica particles under polarized light

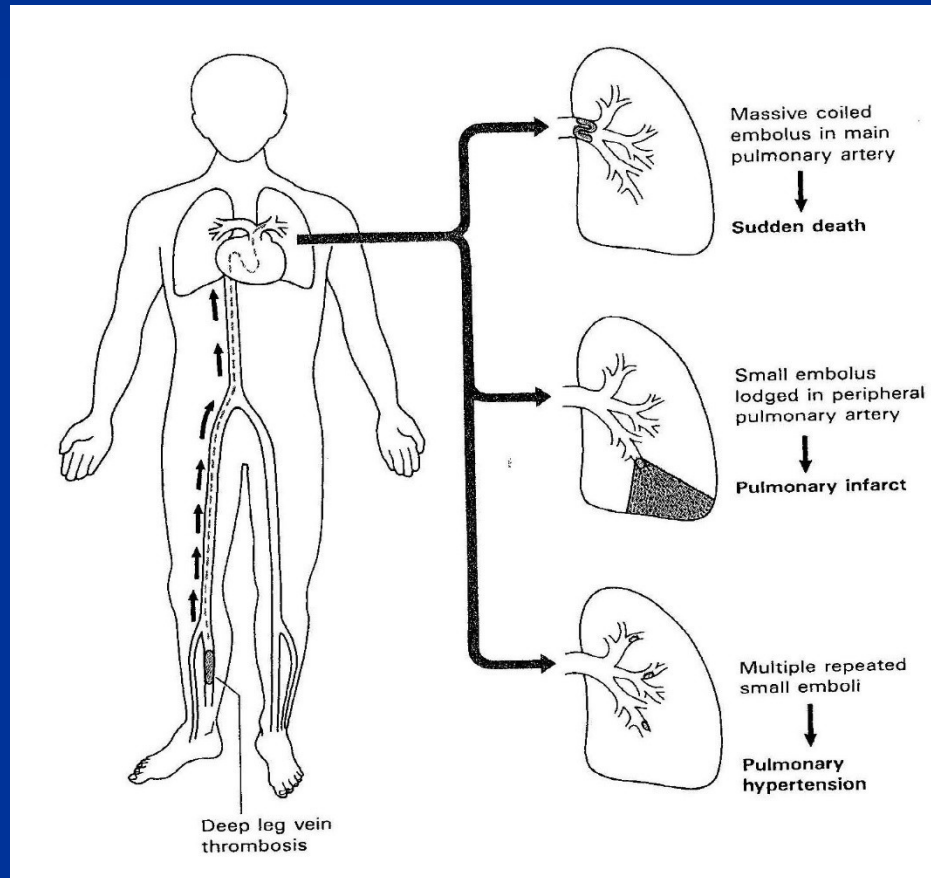


Sarcoidosis

- multisystem inflammatory disorder
- noncaseating granulomas; 90 % lung and hilar lymph nodes involvement
- idiopathic, unknown etiology; may represent a pathologic immune response in genetically predisposed individuals exposed to certain environmental agents(e.g. mycobacteria, *Rickettsia* species, *Propionibacterium acnes*)
- other organs affected: spleen, liver, bone marrow, skin, eye and associated glands, salivary glands, muscle

Pulmonary embolism

- Hypercoagulable state
 - Primary (factor V Leiden, antiphospholipid syndrome,...)
 - Secondary (obesity, surgery, oral contraceptives, pregnancy,...)



Pulmonary hypertension

- Pulmonary blood pressure = $1/8$ of systemic blood pressure
- Pulmonary hypertension → cor pulmonale

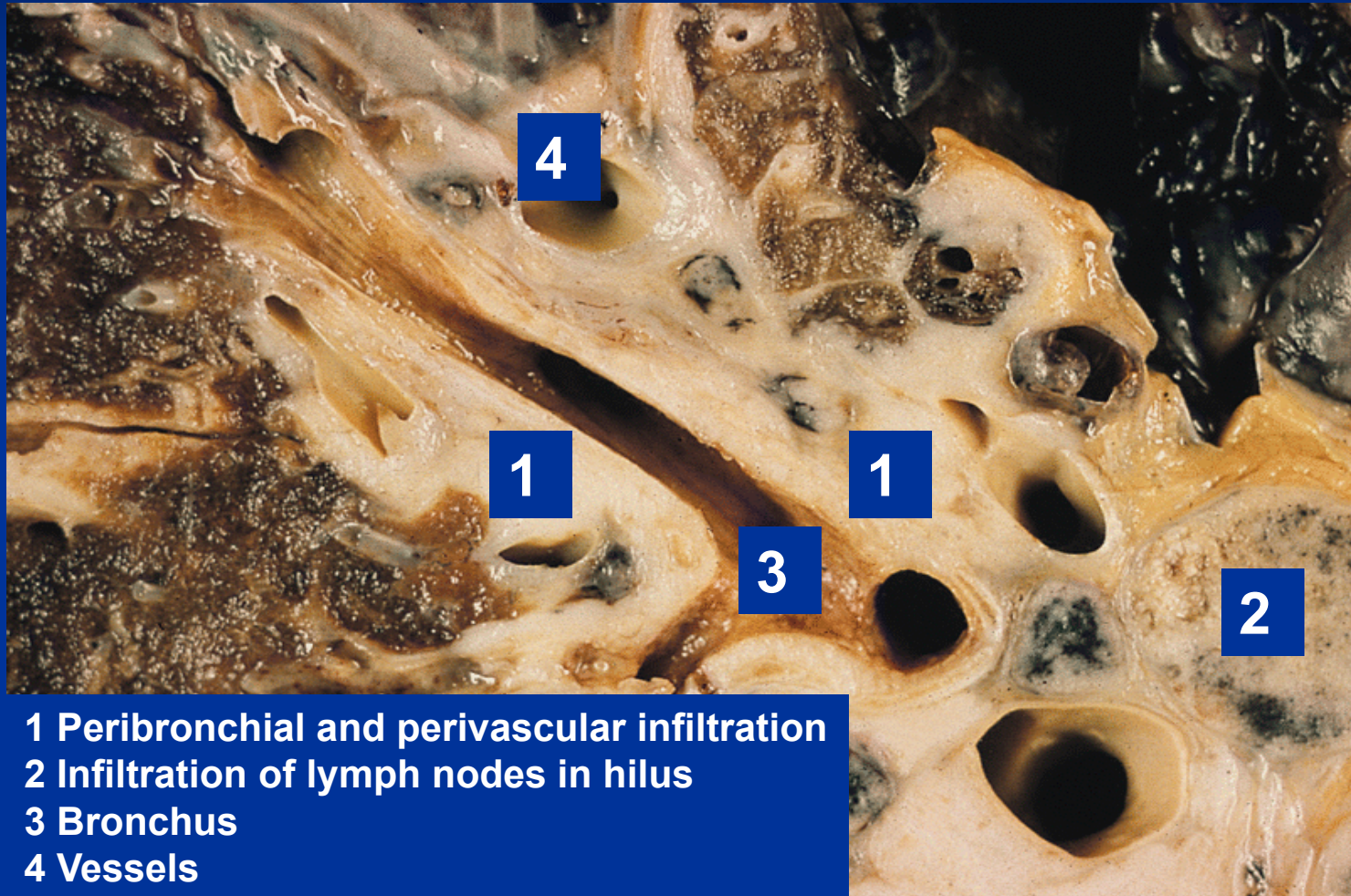
IN:

- Chronic obstructive and restrictive lung diseases
- Antecedent congenital or acquired heart disease (venostasis before left heart)
- Recurrent thrombemboli
- Autoimmune disorders involving pulmonary vasculature
- Venooclusive lung disease (musculoelastic thickening of subpleural and interlobular septal veins)
- Primary idiopathic pulmonary hypertension

Tumors of the lung

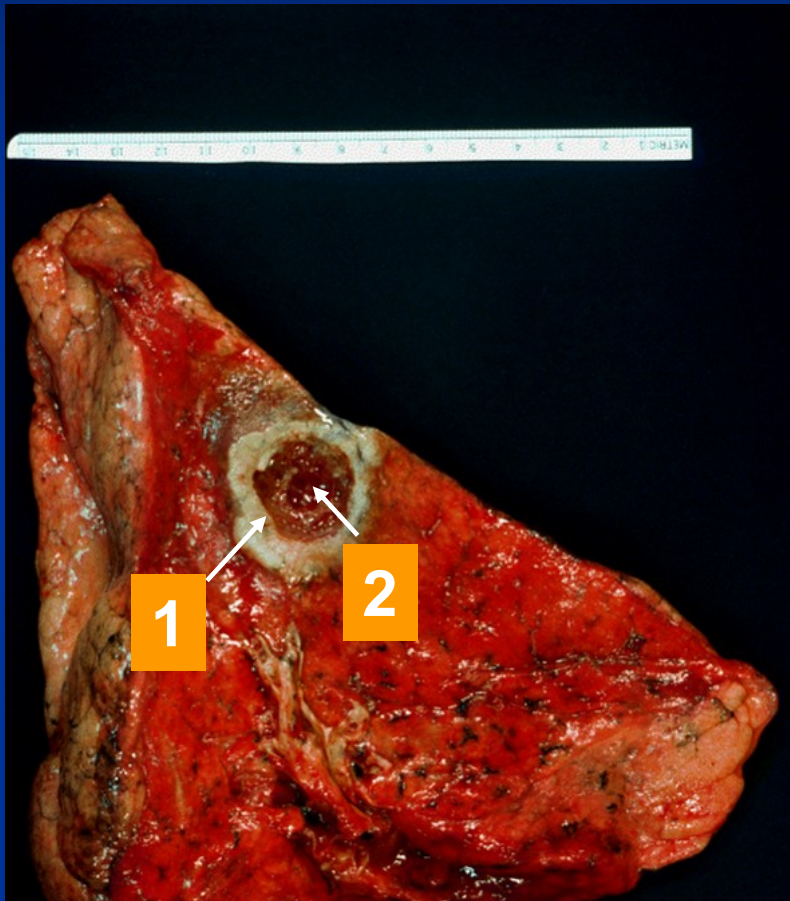
- Most common primary malignant tumor in the world; related to cigarette smoking, assoc. with occupational exposure to carcinogens, generally with poor prognosis
- **Epithelial**
 - Benign (adenomas)
 - Malignant
 - squamous cell carcinoma
 - adenocarcinoma
 - small cell (neuroendocrine) carcinoma
 - undifferentiated carcinomas-large cell)
- **Mesenchymal**
- **Others**
- **Secondary – metastatic tumors**

Small-cell lung carcinoma

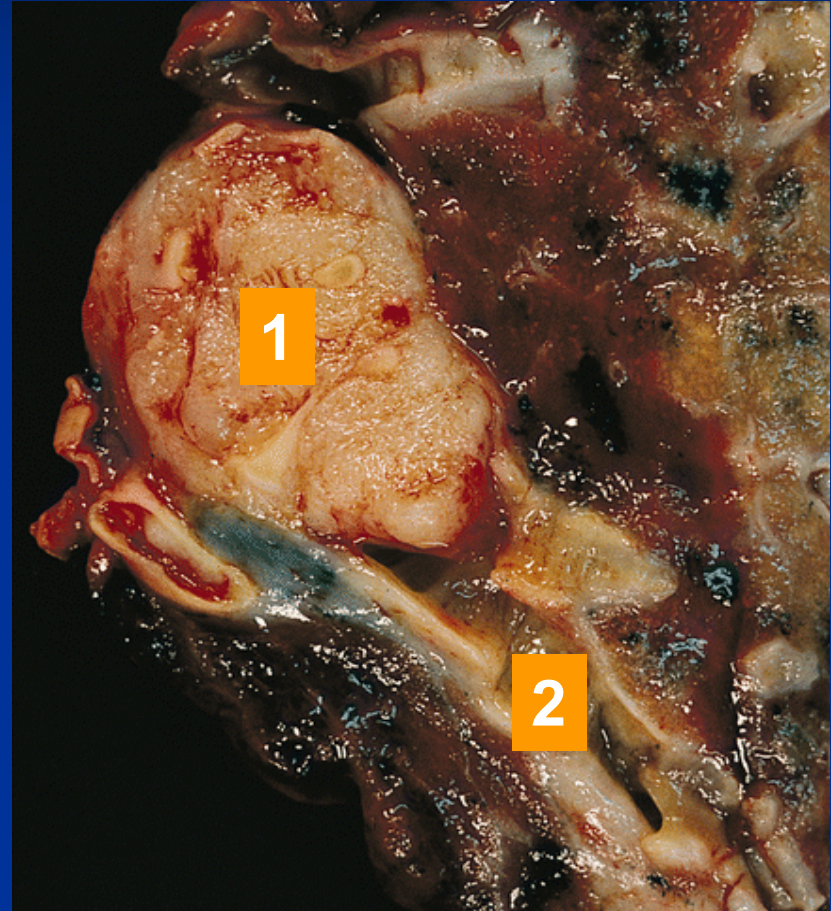


- 1 Peribronchial and perivascular infiltration
- 2 Infiltration of lymph nodes in hilus
- 3 Bronchus
- 4 Vessels

Squamous cell lung carcinoma



1. Tumor localized in the periphery
2. Central necrosis



1. Tumor in bronchus
2. Segmental bronchus

Complications of lung cancer

