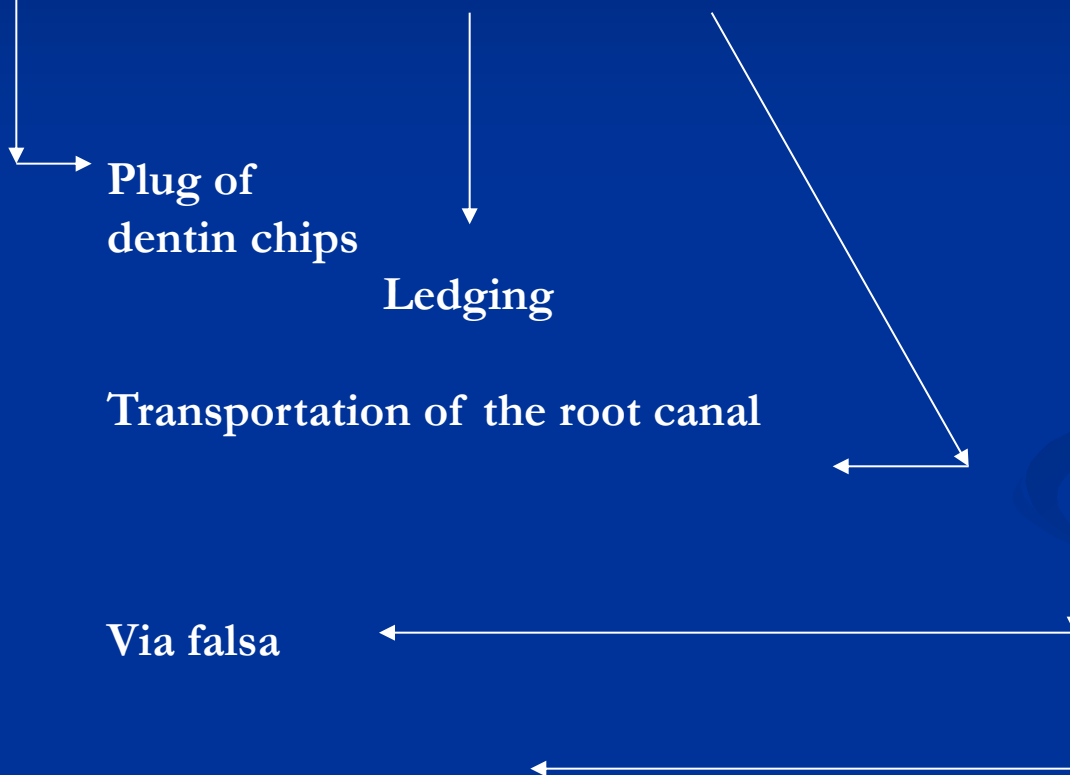
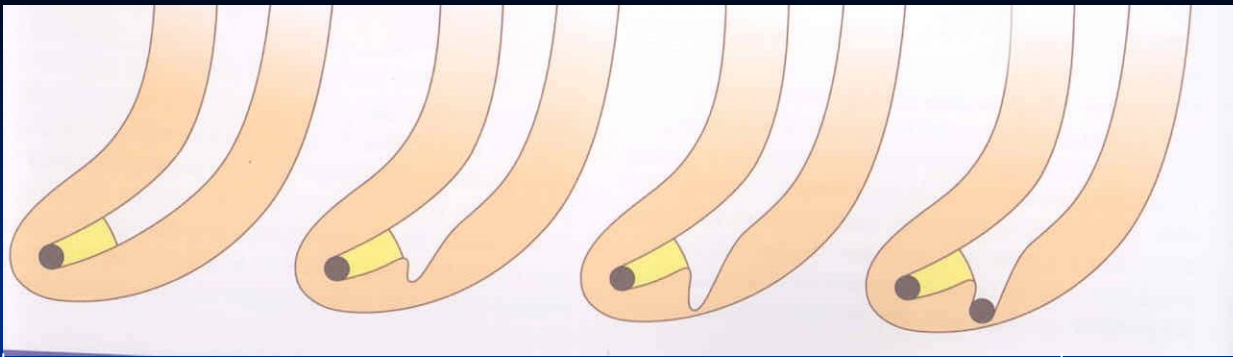


Complications of endodontic treatment

Local

Regional

Systemic



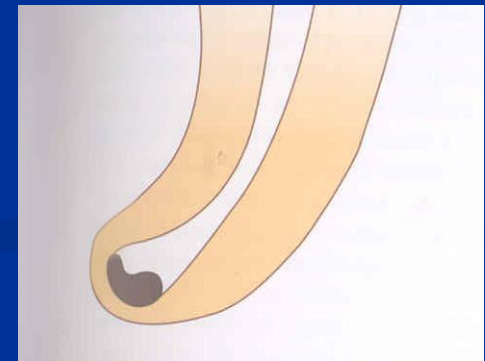
Plug of
dentin chips

Ledging

Transportation of the root canal

Via falsa

Zipping a elbow



Local complications

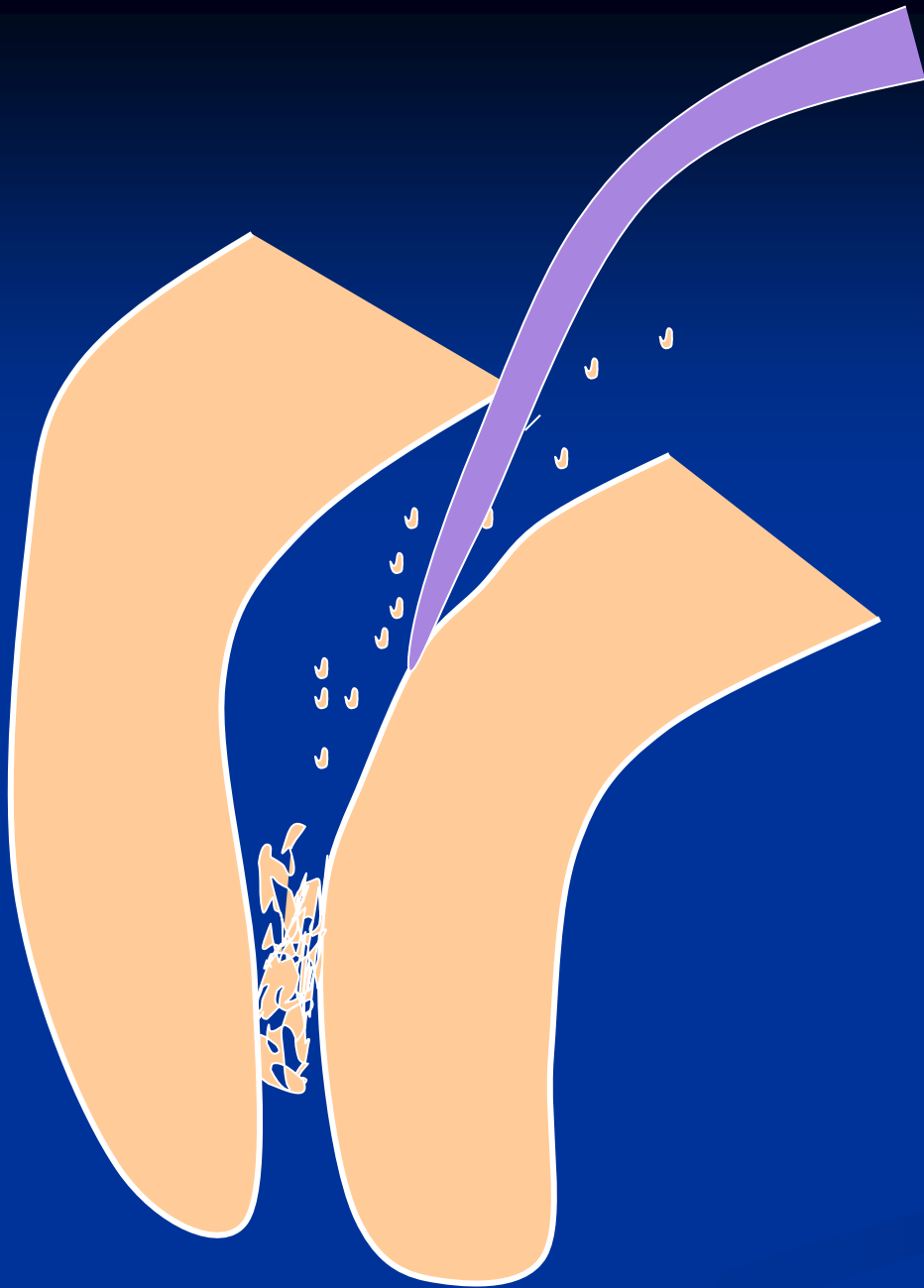
Plug



Reasons

**Insufficient irrigation and
recapitulation**

Loss of the working length



Solution

Repeated careful
instrumentation
with a thin
instrument

*Irrigation is not
effective in this
case!!!*

Ledging




Reasons

The instrument is not bended in advance!

No control of the WL

=

No recapitulation Loss of the WL



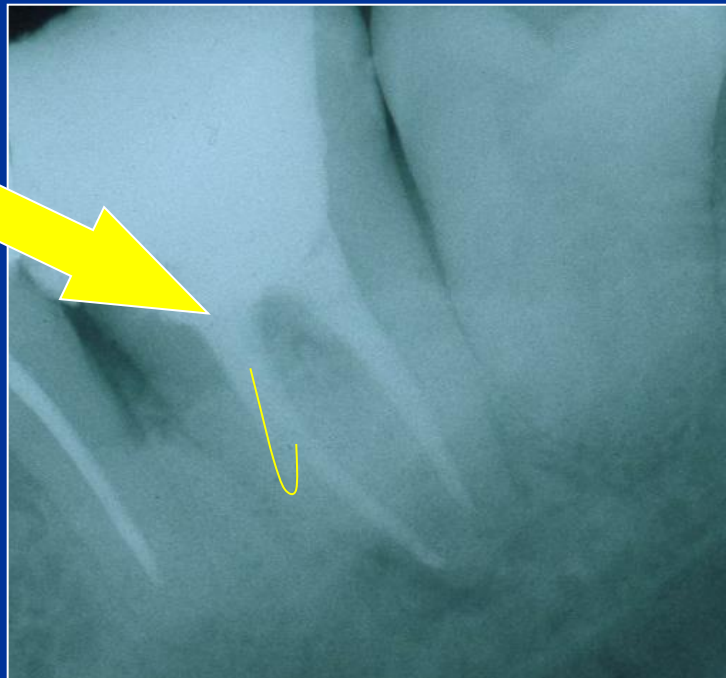
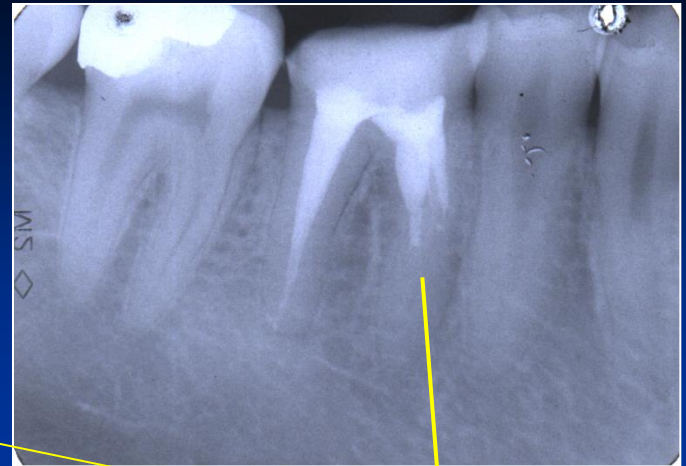
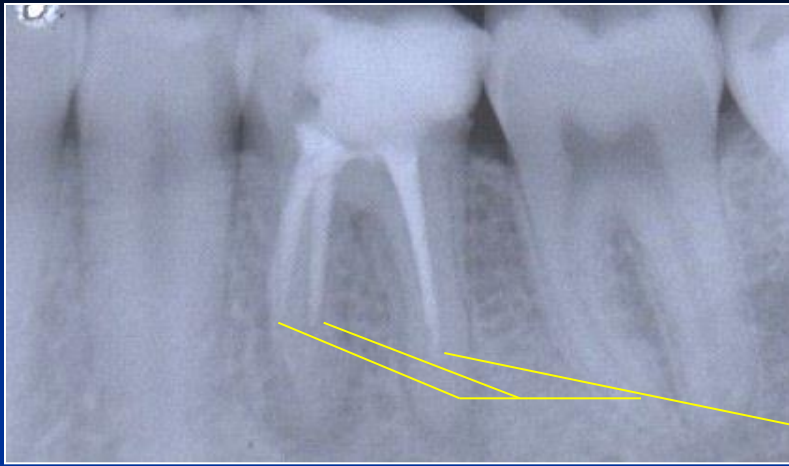
Solution

The instrument must be
bended in advance

Careful but complete rotation

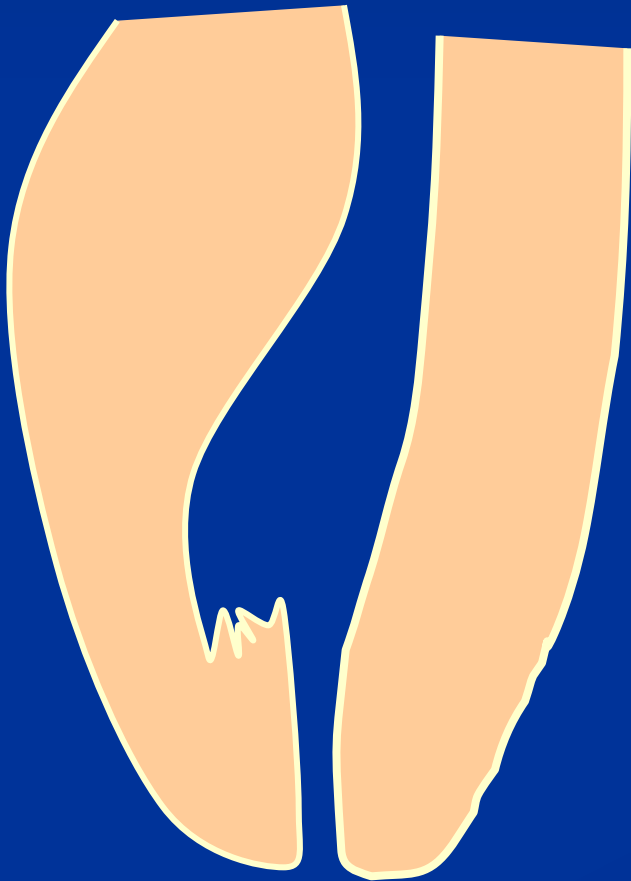Finishing with the fine filing

No NiTi!!!



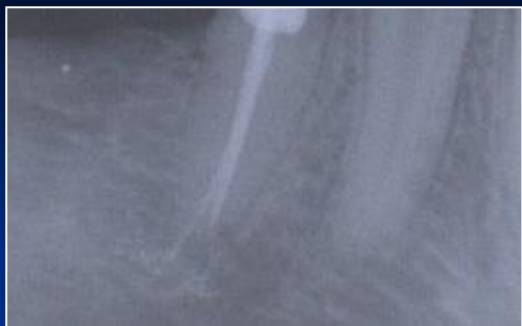

Ledging

Zippering a Elbow



The instrument is not bended in advance!

Rotation in curved canals



Stripping

Reasons

Bad orientation in morphology – no diagnostic x-
Instruments are not bended
Rotary NiTi with a big taper


Dangerous zones

Mandibular molars – mesial roots

Premolars, esp. maxillar

Mandibular incisors

Oblast isthmu




Stripping

Důkladný přehled!

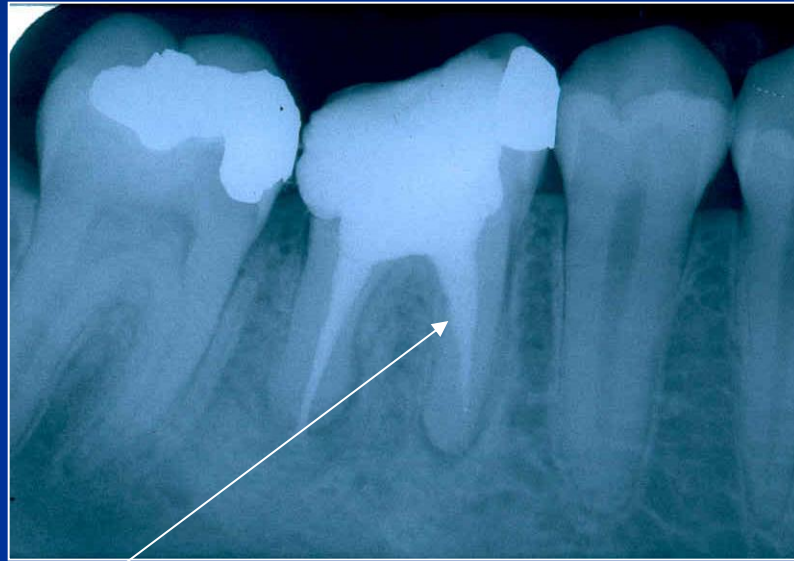
Šetřit oblast isthmu!

Ruční preparace!

Menší kónus NiTi !



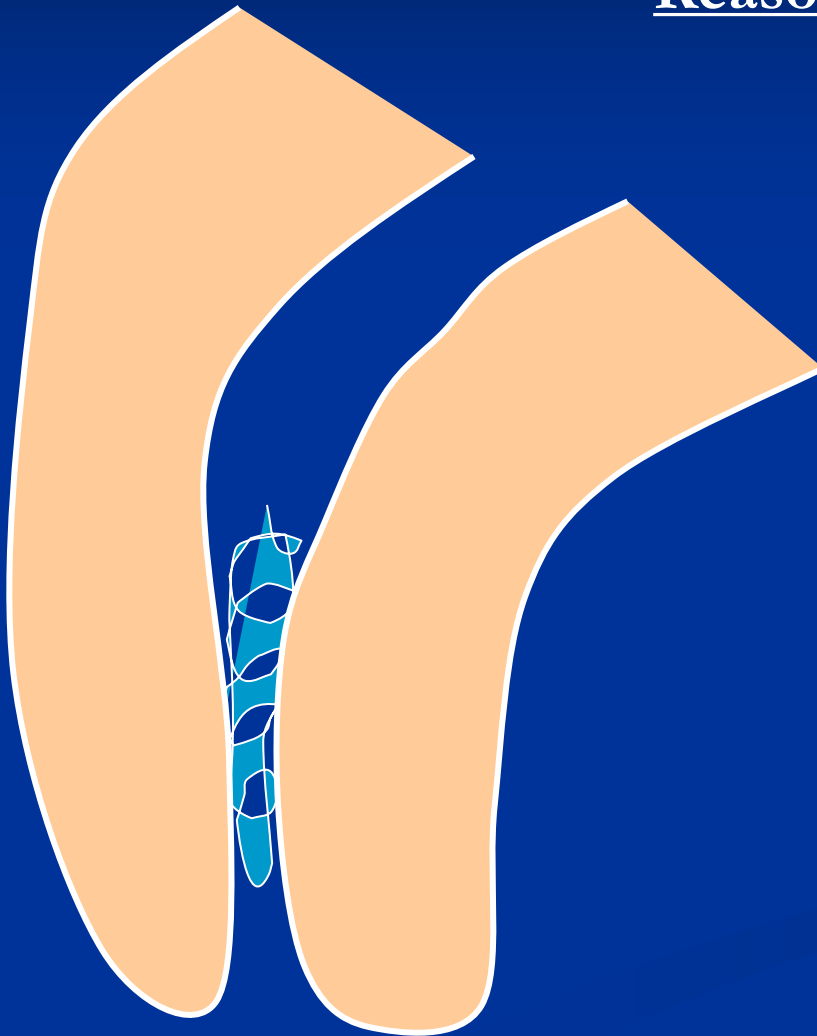
Stripping



Bend the instrument and eventually blunt it !

Fracture of the root canal instrument

Reasons



**Insufficient
coronal flaring**

**Old root canal
instrument**

Aggressive force

**Incorrect
movement of the
root canal
instrument**

Solution

Enlargement of the
root canal till the
instrument

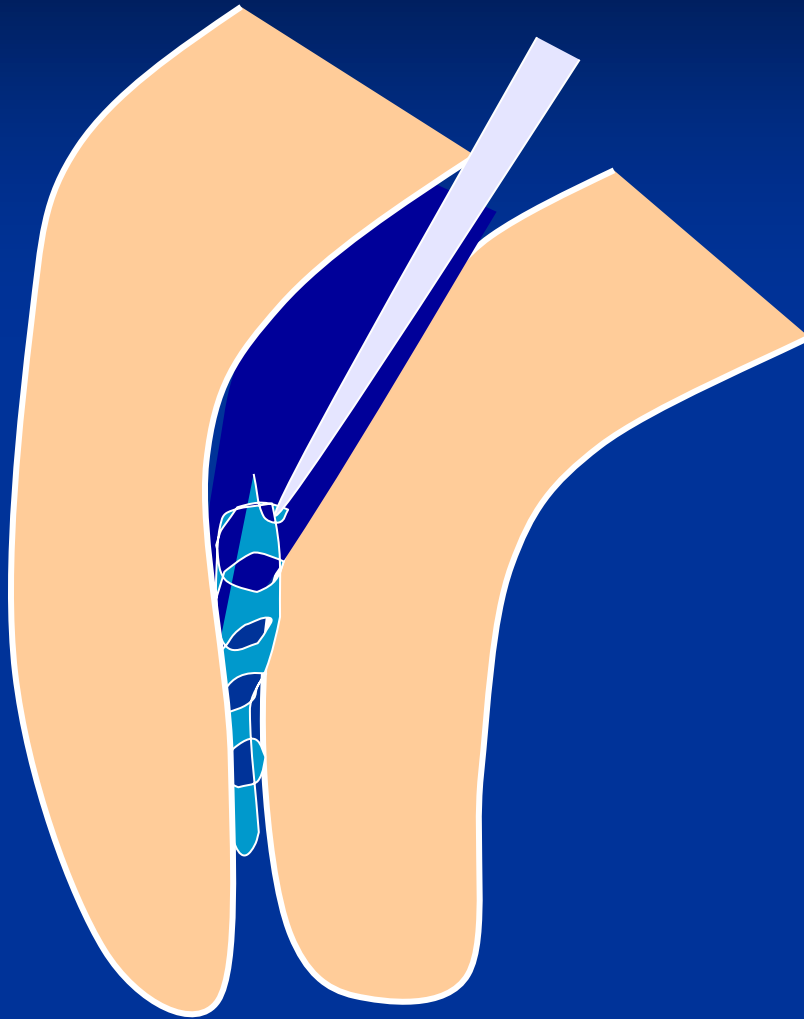
Ultrasound tips

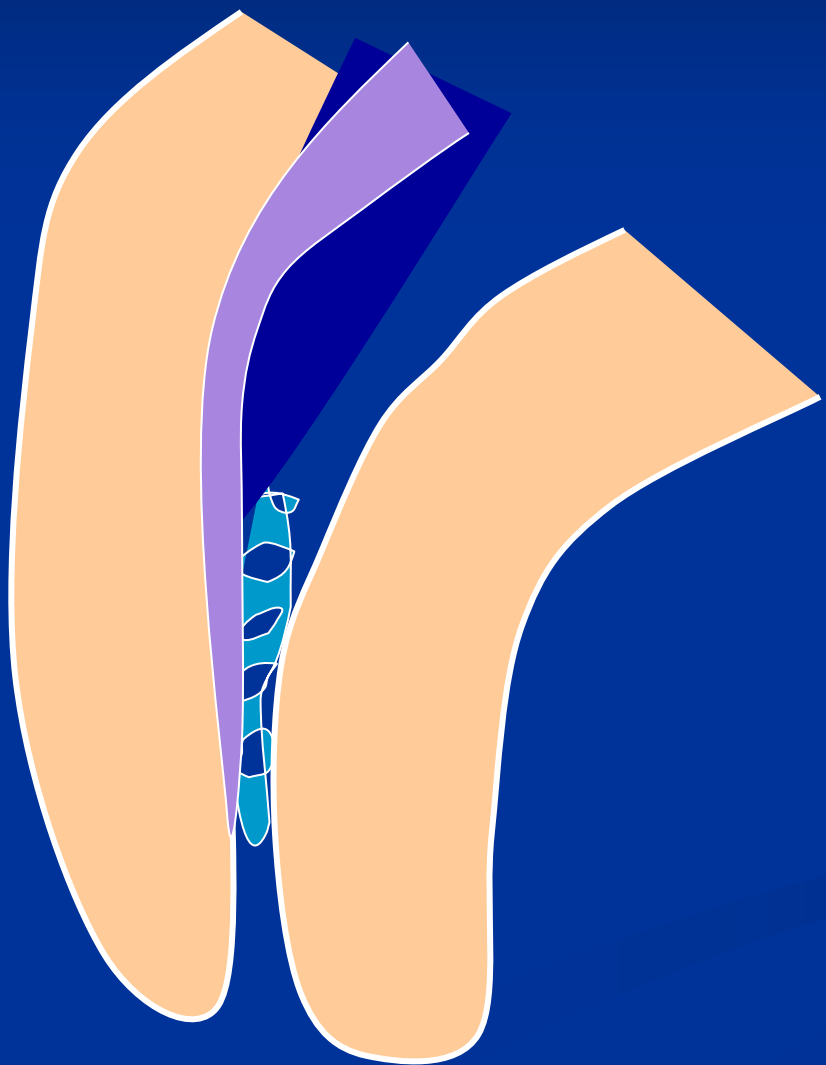
Rotating root canal
instrument – caution!

Bypass

Leaving in

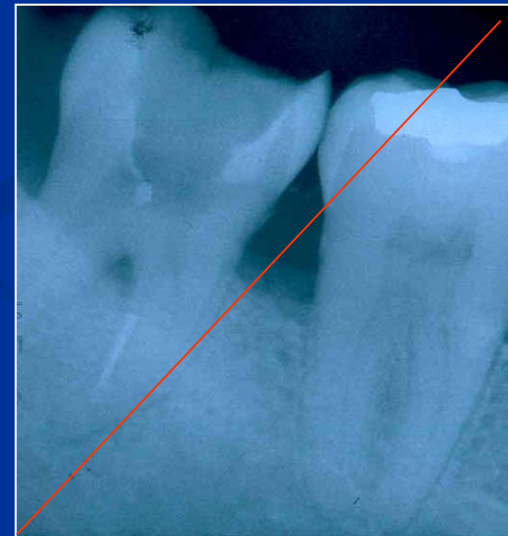
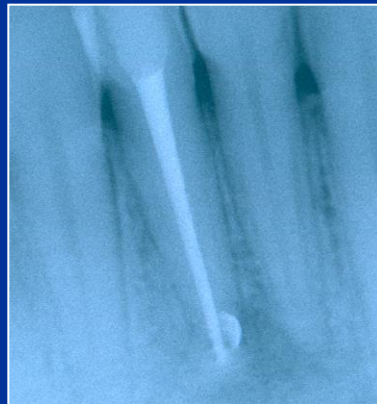
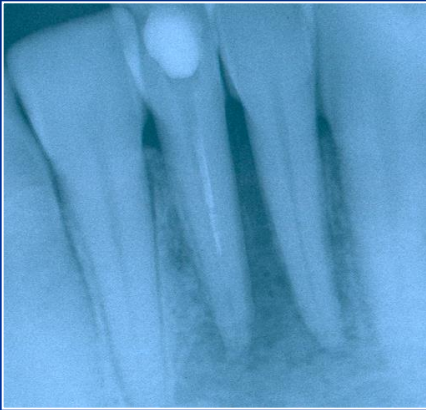Surgical treatment





Bypass

Fractured instrument



Obliteration



Partial

Obliterate



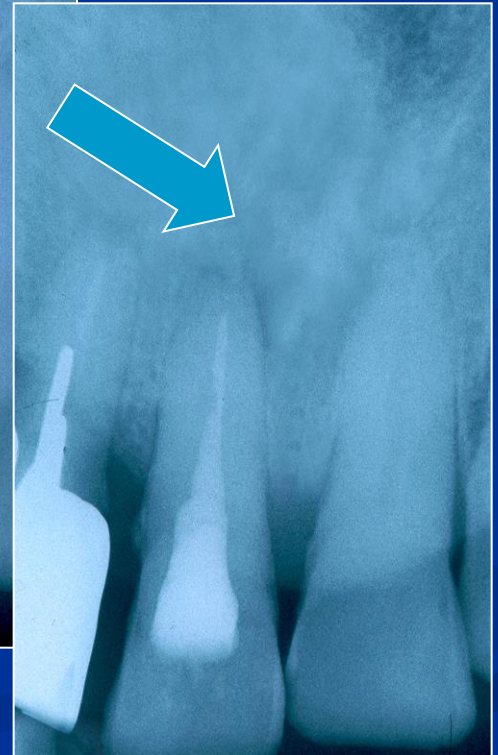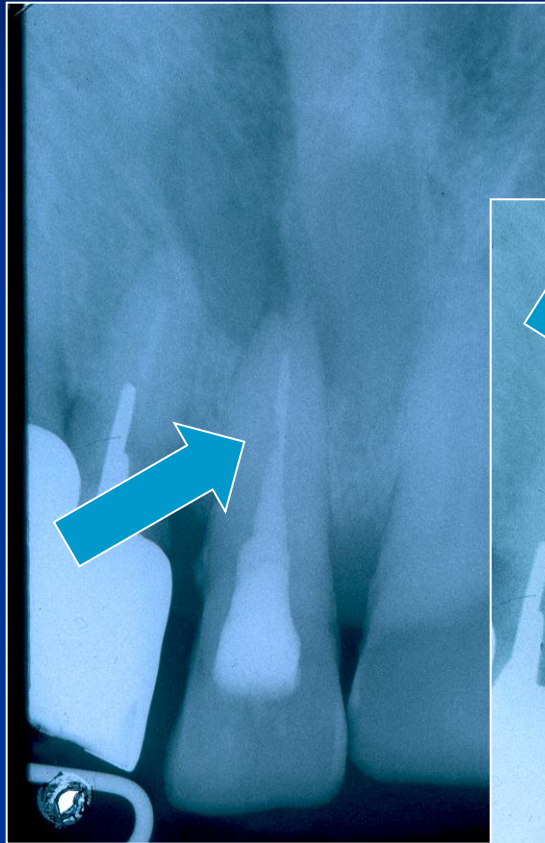
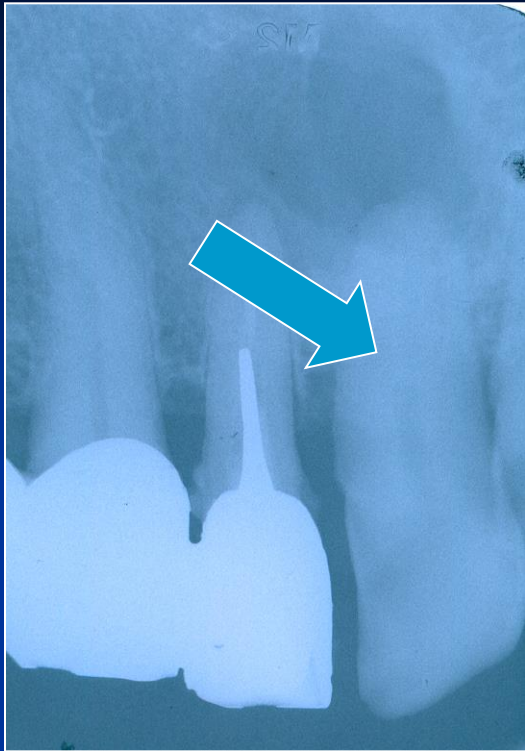
Access!!!

Hand thion
Instrument!

Steel or NiTi

EDTA

Patience

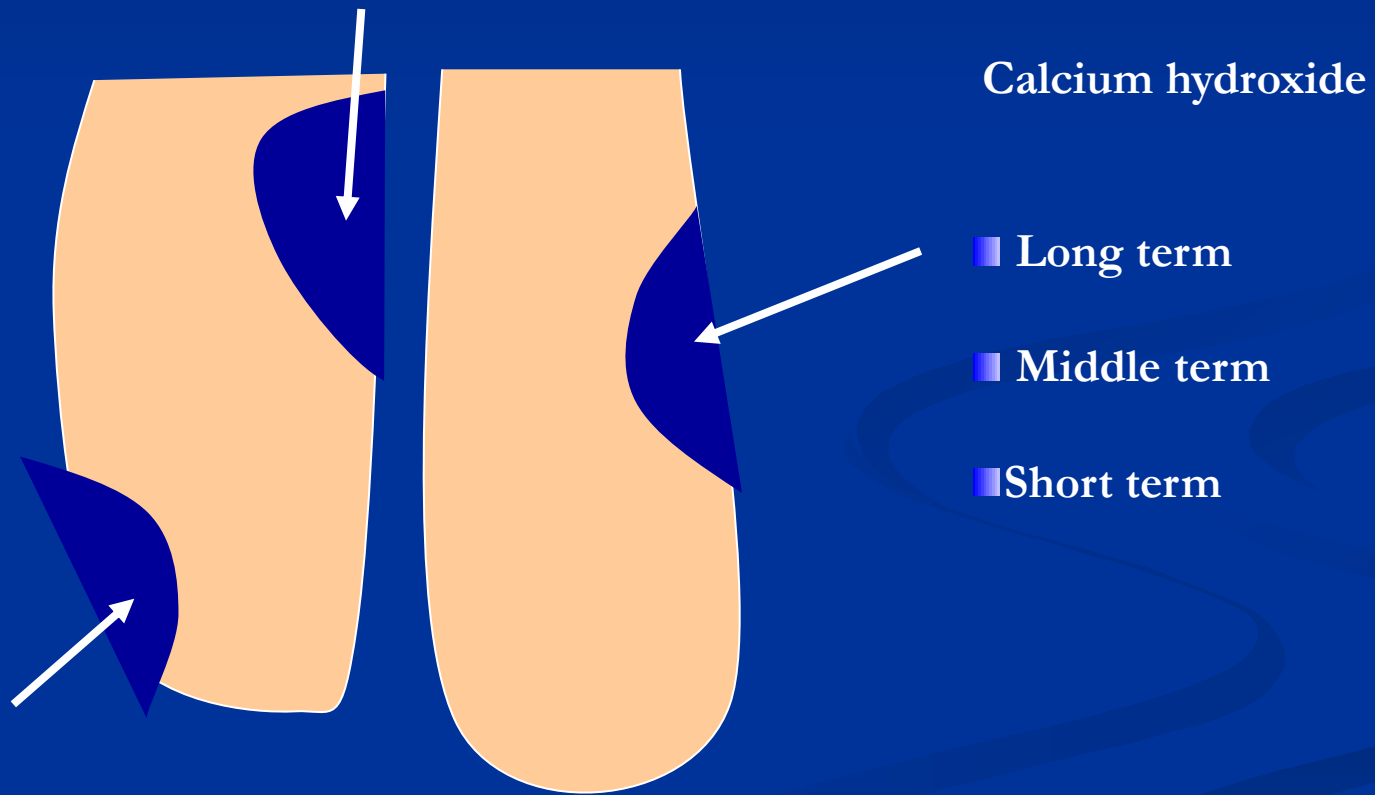


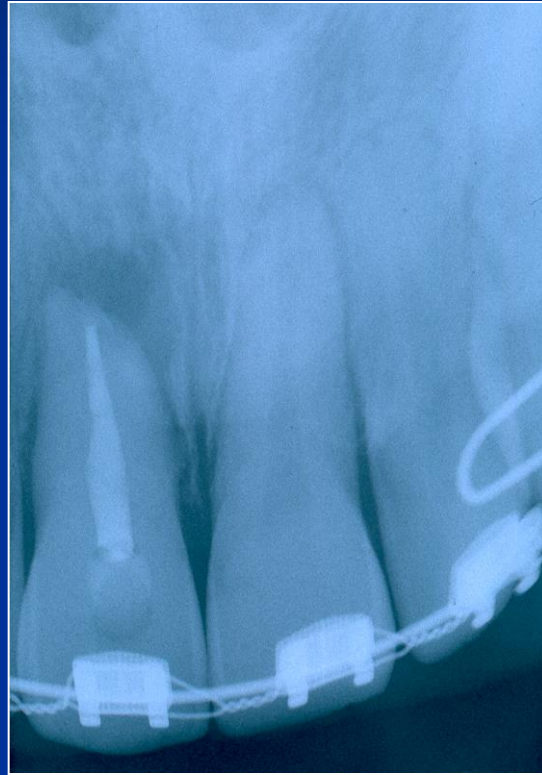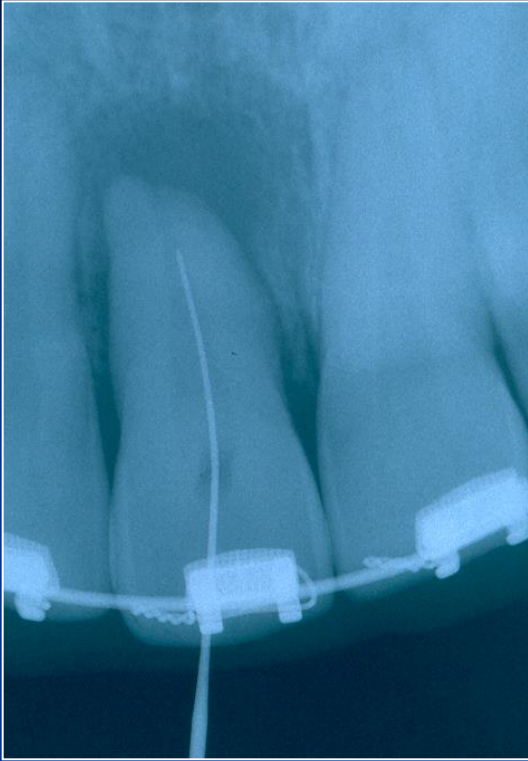
Obliterace

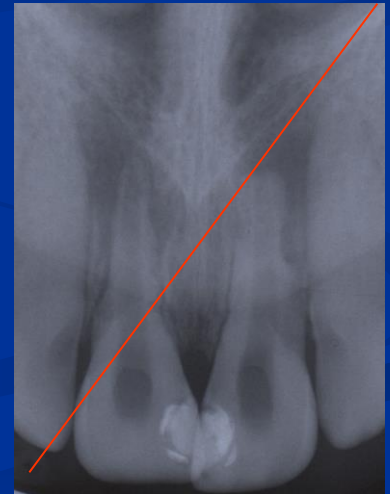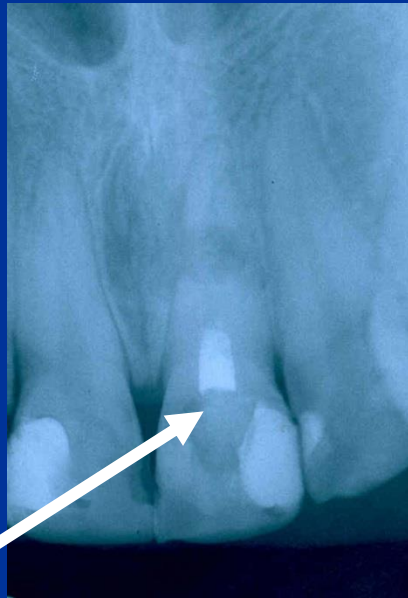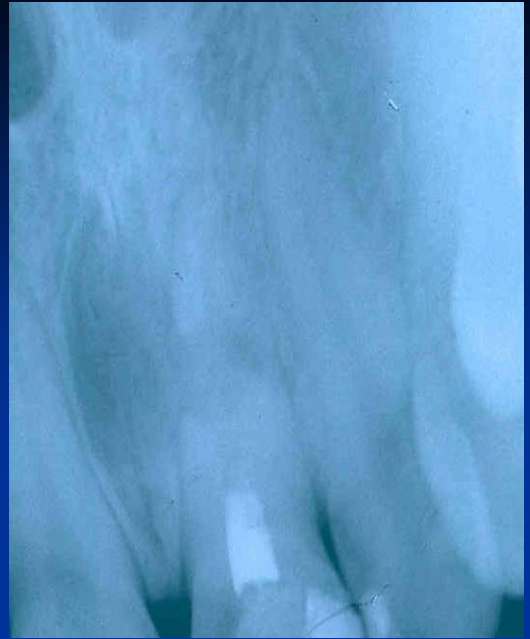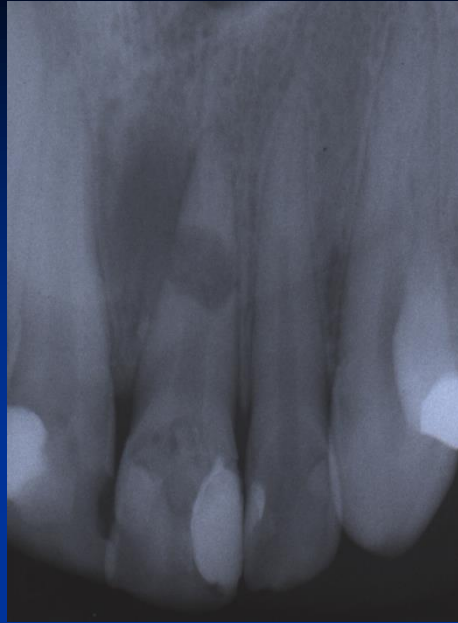


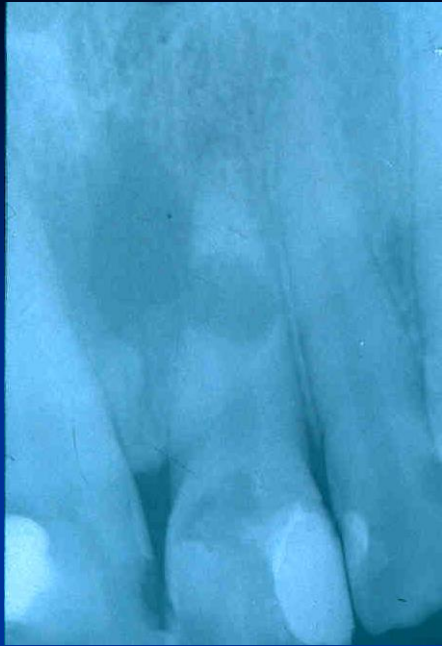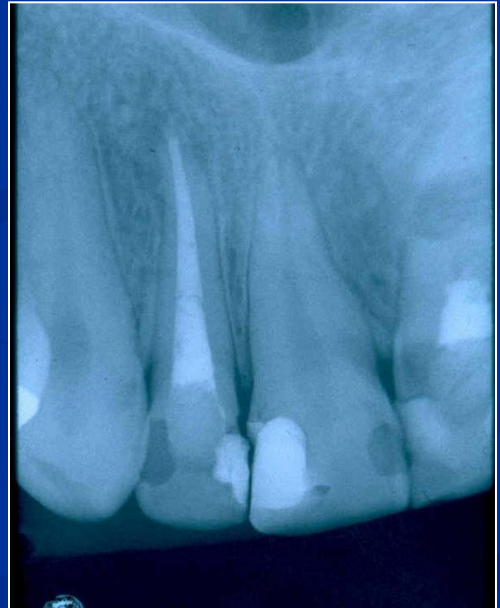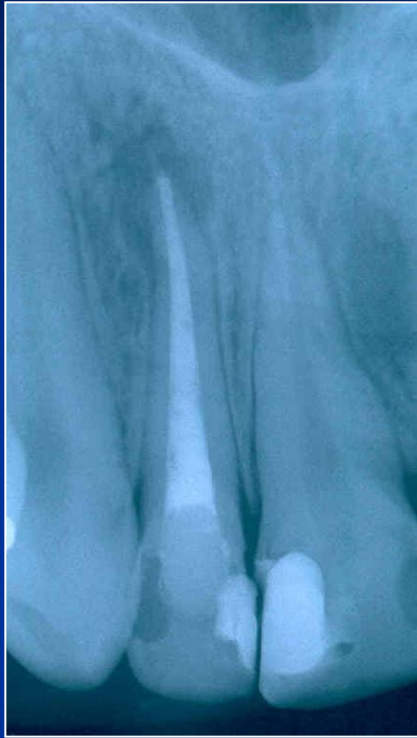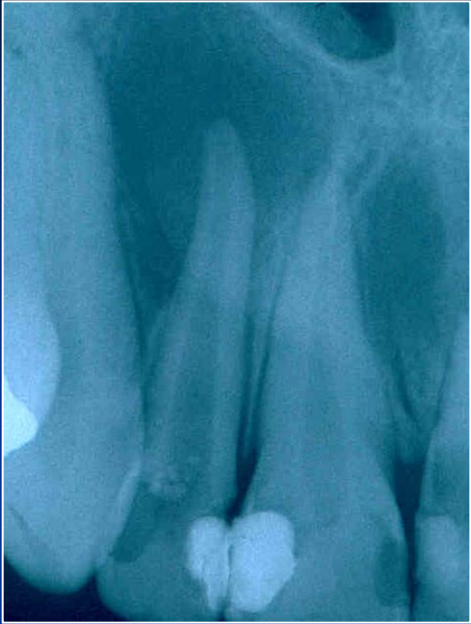Úplná -
ponechat.

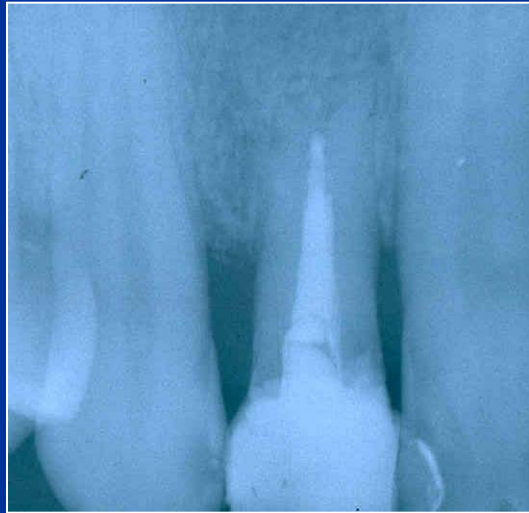
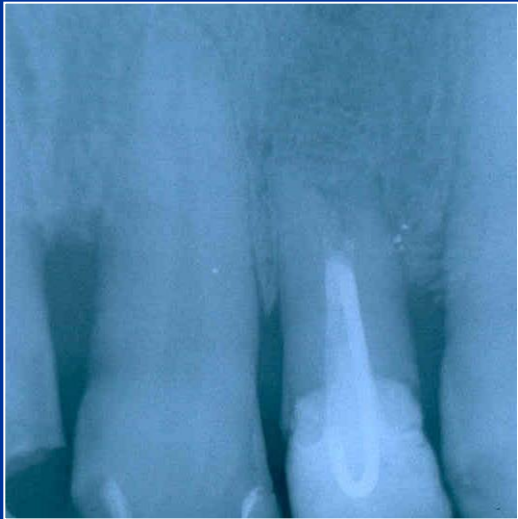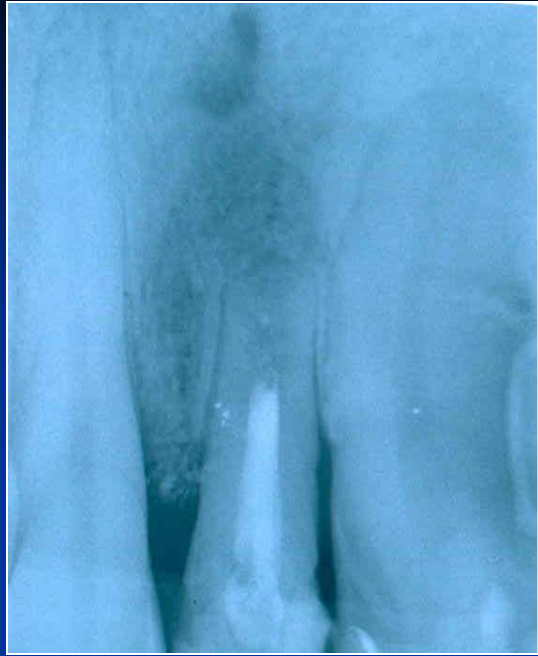
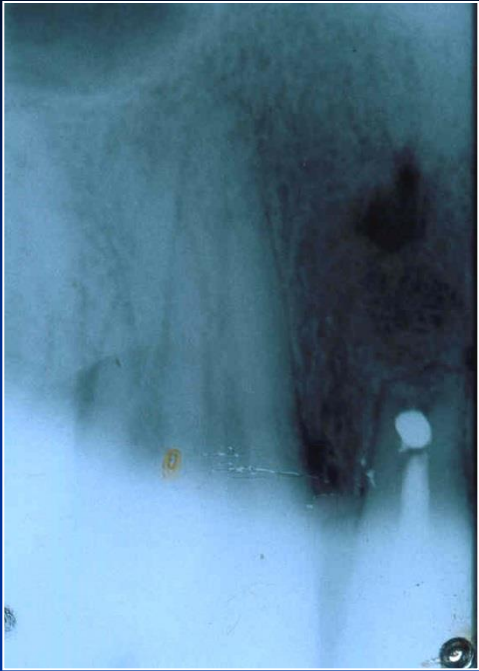Resorption











Via falsa

- Perforation of the bottom of the pulp chamber or the coronal part of the root canal
- Perforation in the middle part of the root canal
- Apical perforation

LOT 000724 EXP 0507

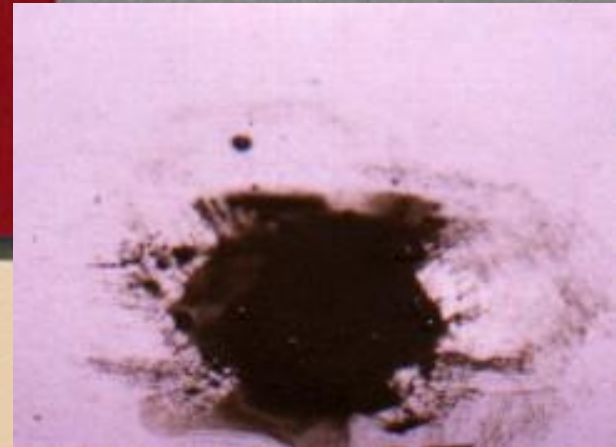
DENTSPLY

PRO ROOT™

*MTA (Mineral Trioxide Aggregate)
Root Canal Repair Material*

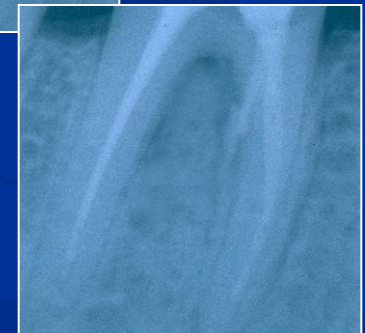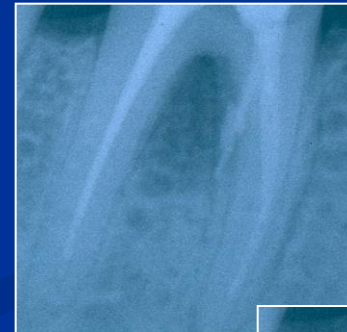Contents: 1 gram (1 treatment)

CE
0120



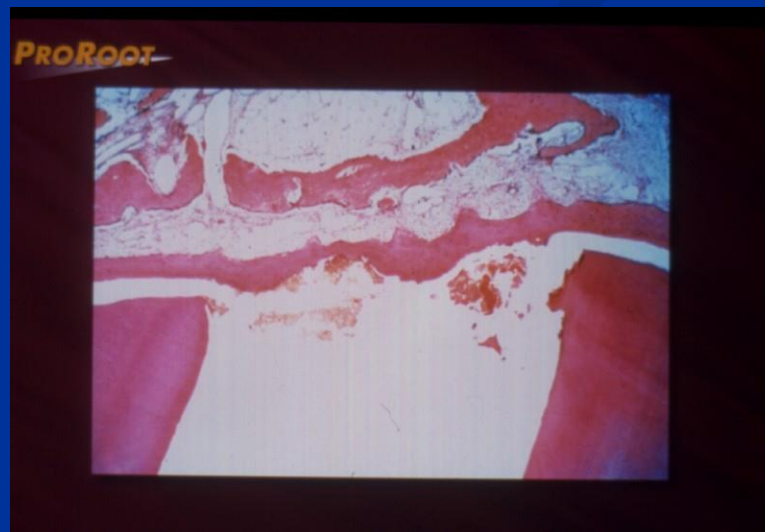MTA composition


- Dicalcium silicate
 - Trikalcium silicate
 - Trikalcium aluminate
 - Tetrakalcium aluminate
 - Cuprum sulphate
 - Bismuthum trioxide
- = Portland cement

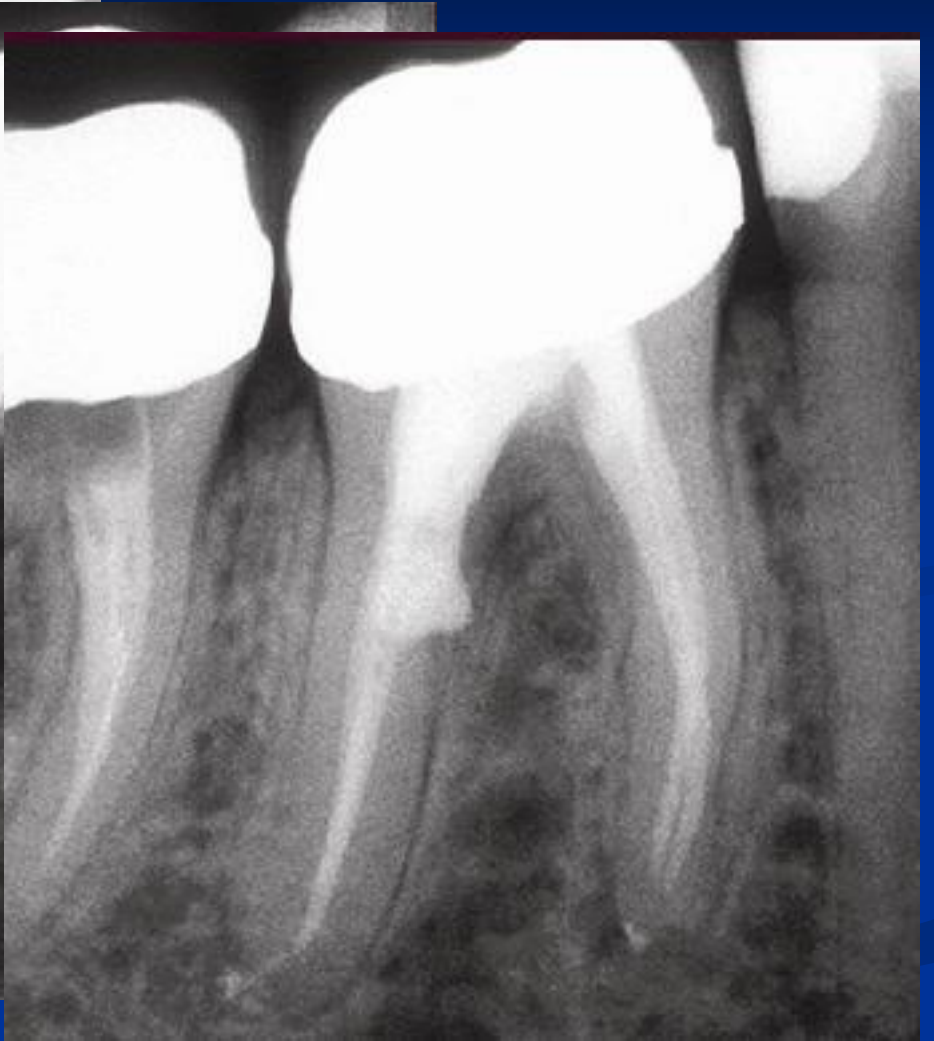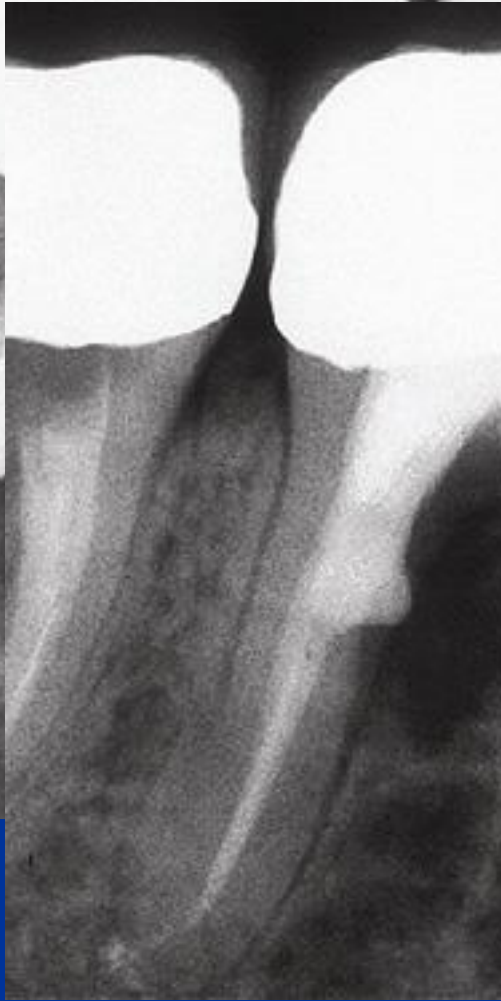

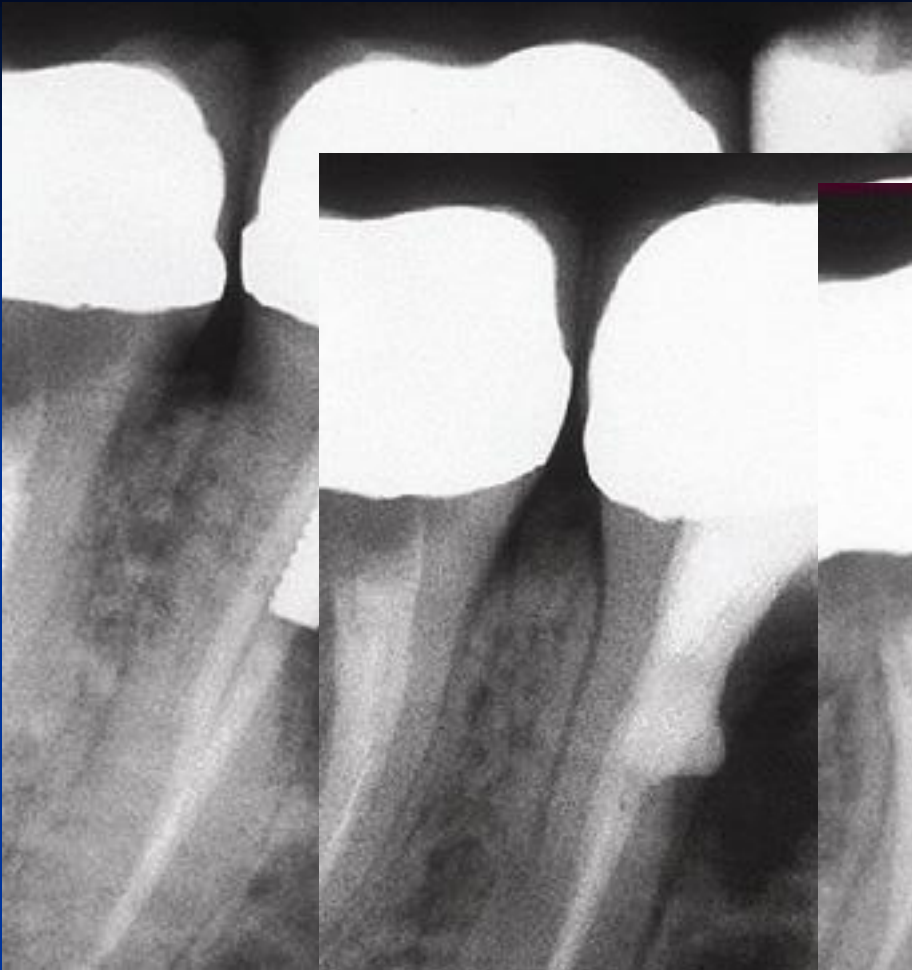
MTA

- Umožňuje hojení – dobrý okrajový uzávěr !
Zabraňuje přístupu mikroorganismům,
umožňuje hojení dřeně a periodoncia tvrdou tkání.

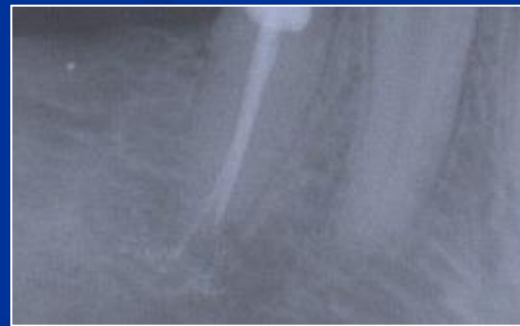


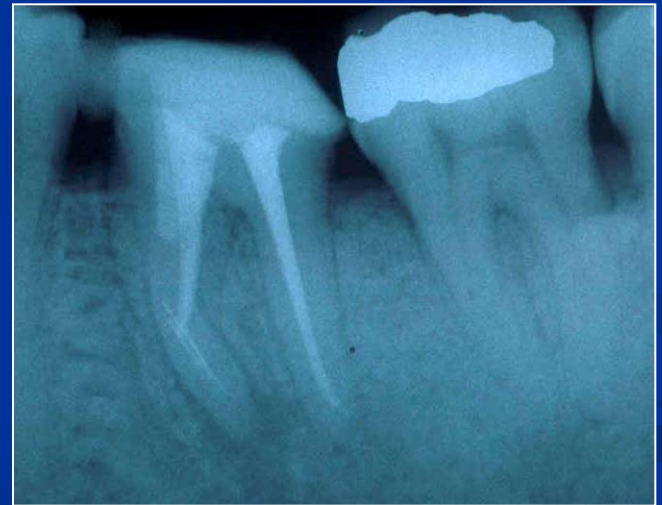
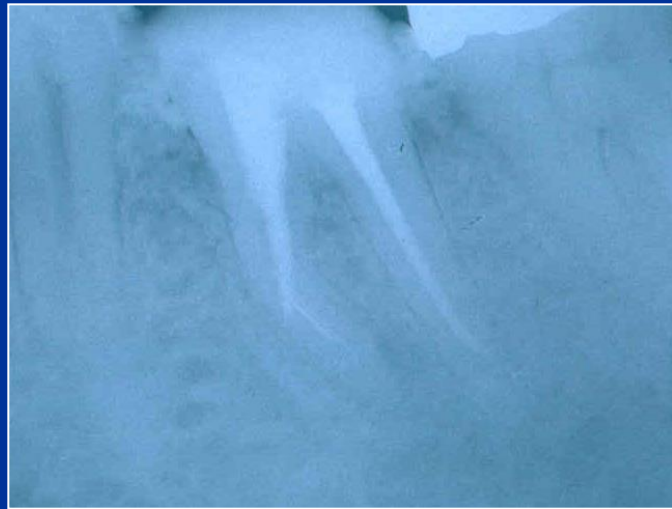
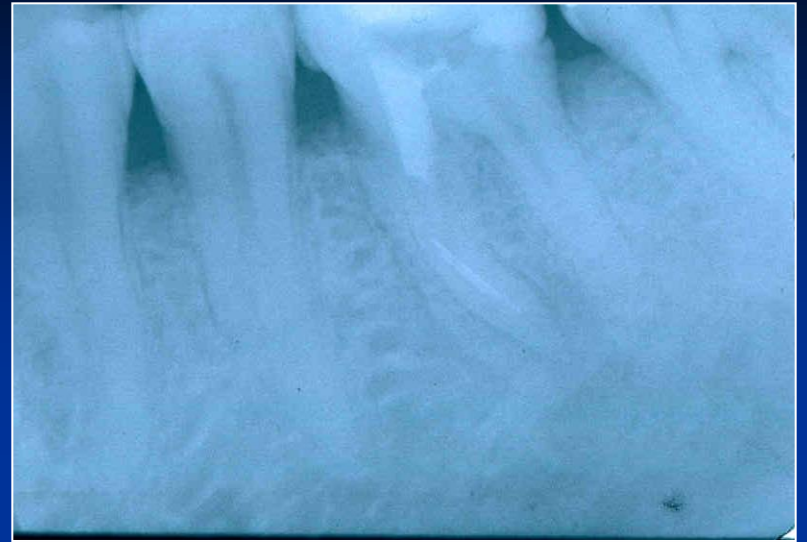
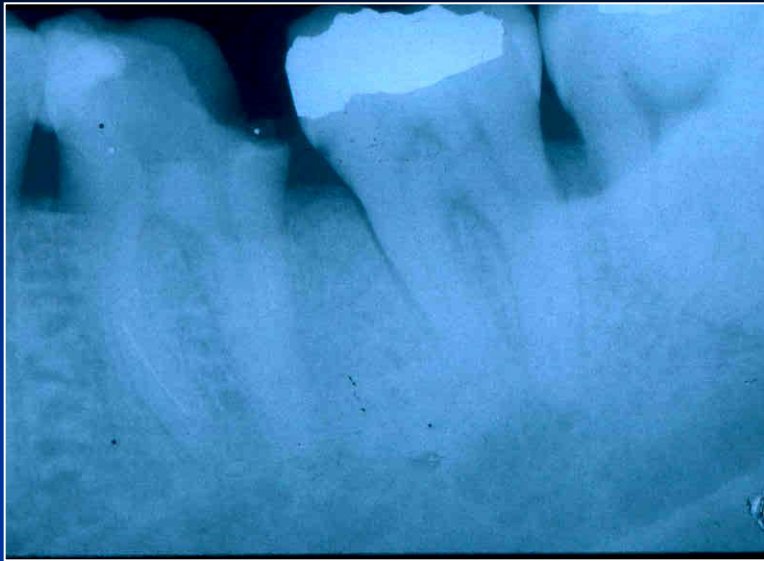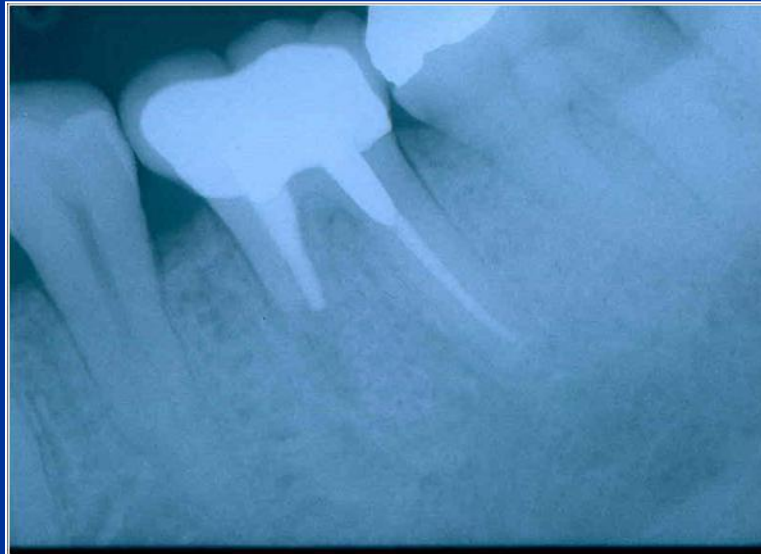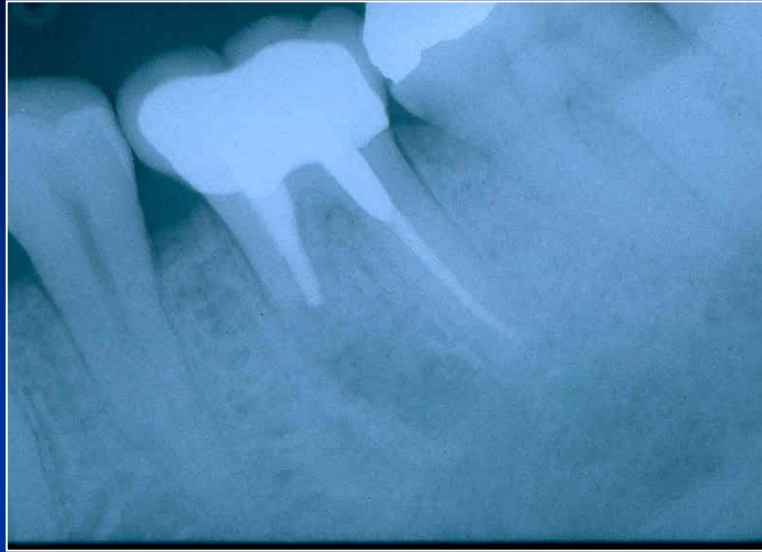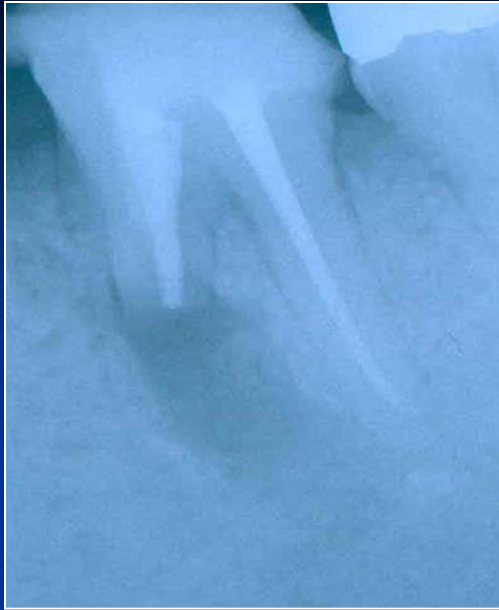Via falsa - treatment

- No bleeding
- Desinfection
- MTA – moisture (wet cotton pellet)
- Calcium hydroxide
- Filling



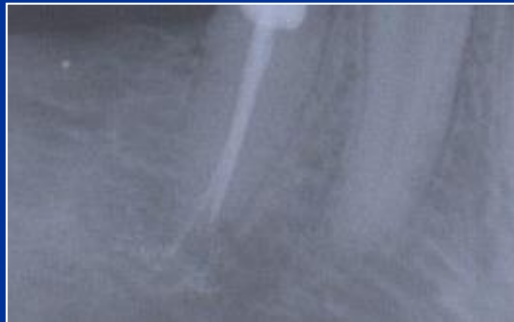



Via falsa

- Perforace apikálně


Hydroxid kalcia, kořenová výplň.



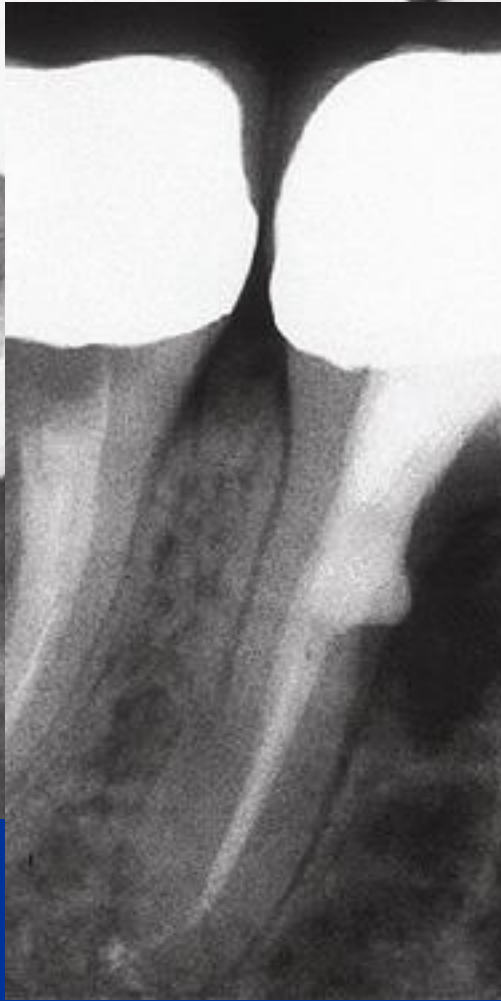
MTA

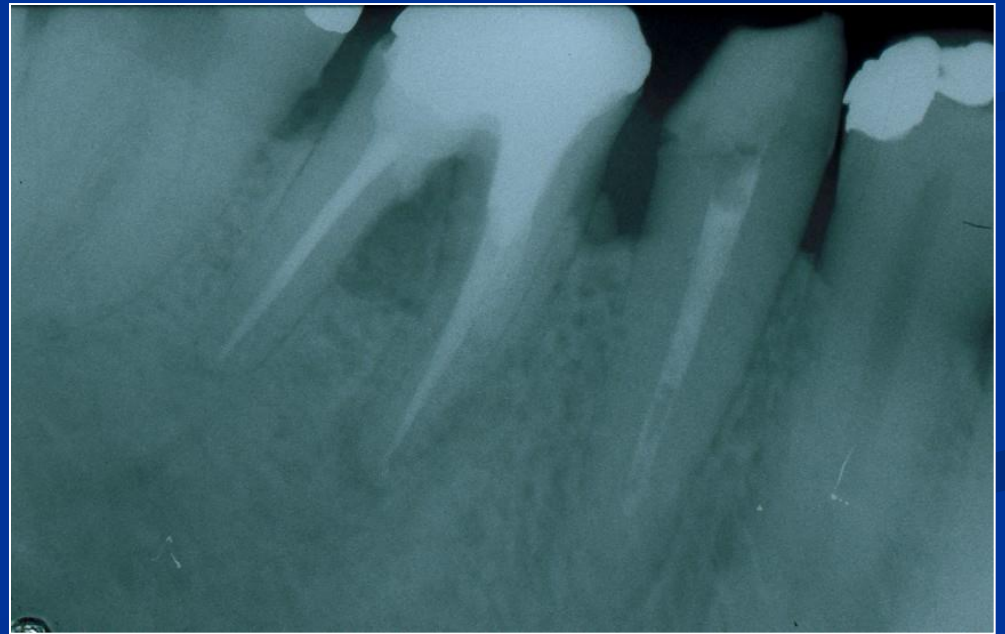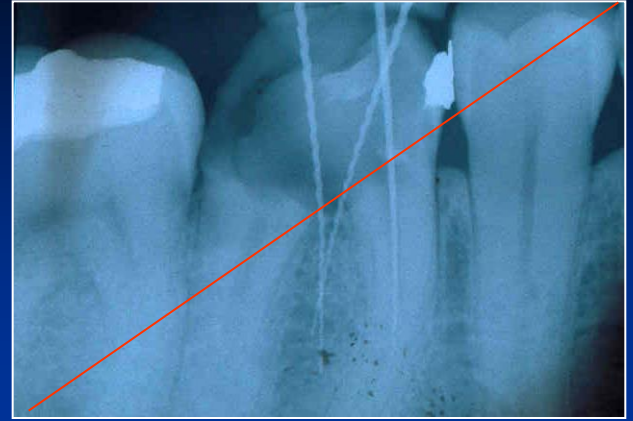
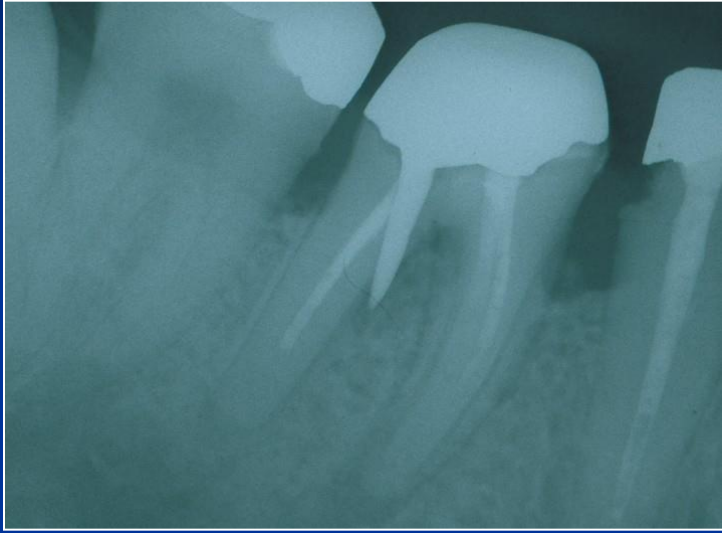- Umožňuje hojení – dobrý okrajový uzávěr !
Zabraňuje přístupu mikroorganismům,
umožňuje hojení dřeně a periodoncia tvrdou tkání.



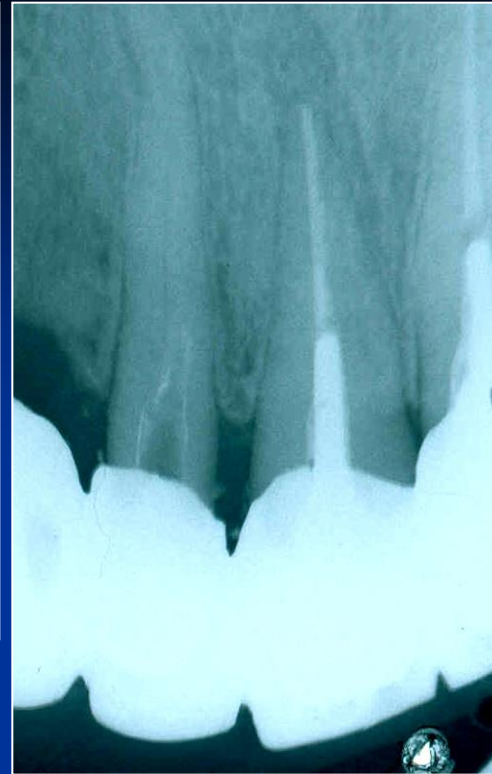
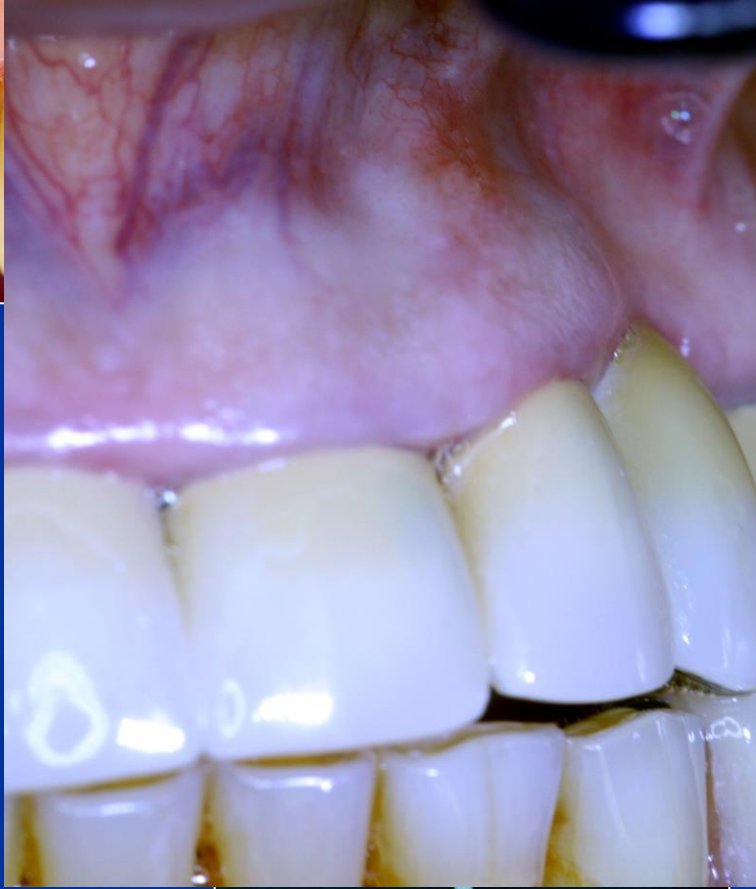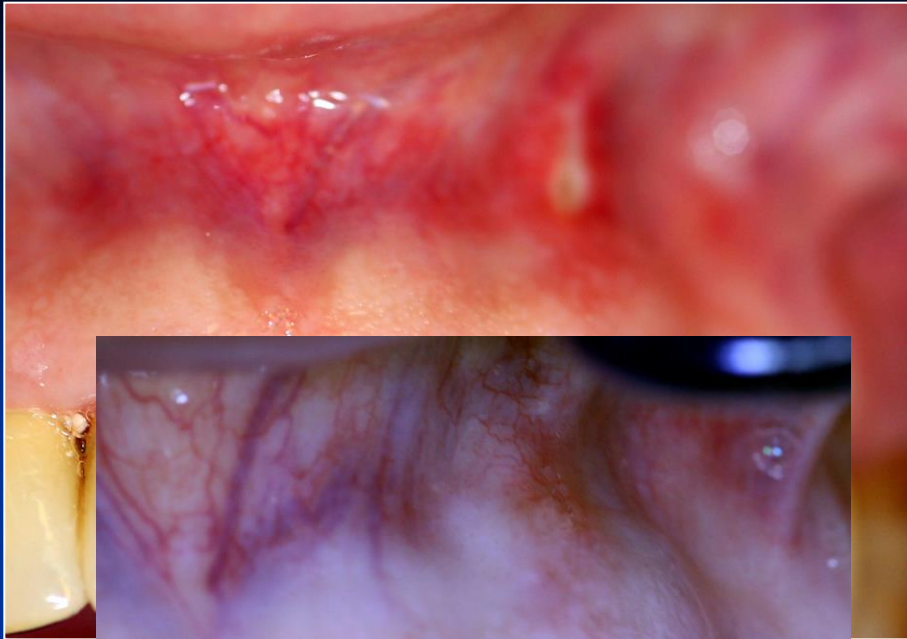


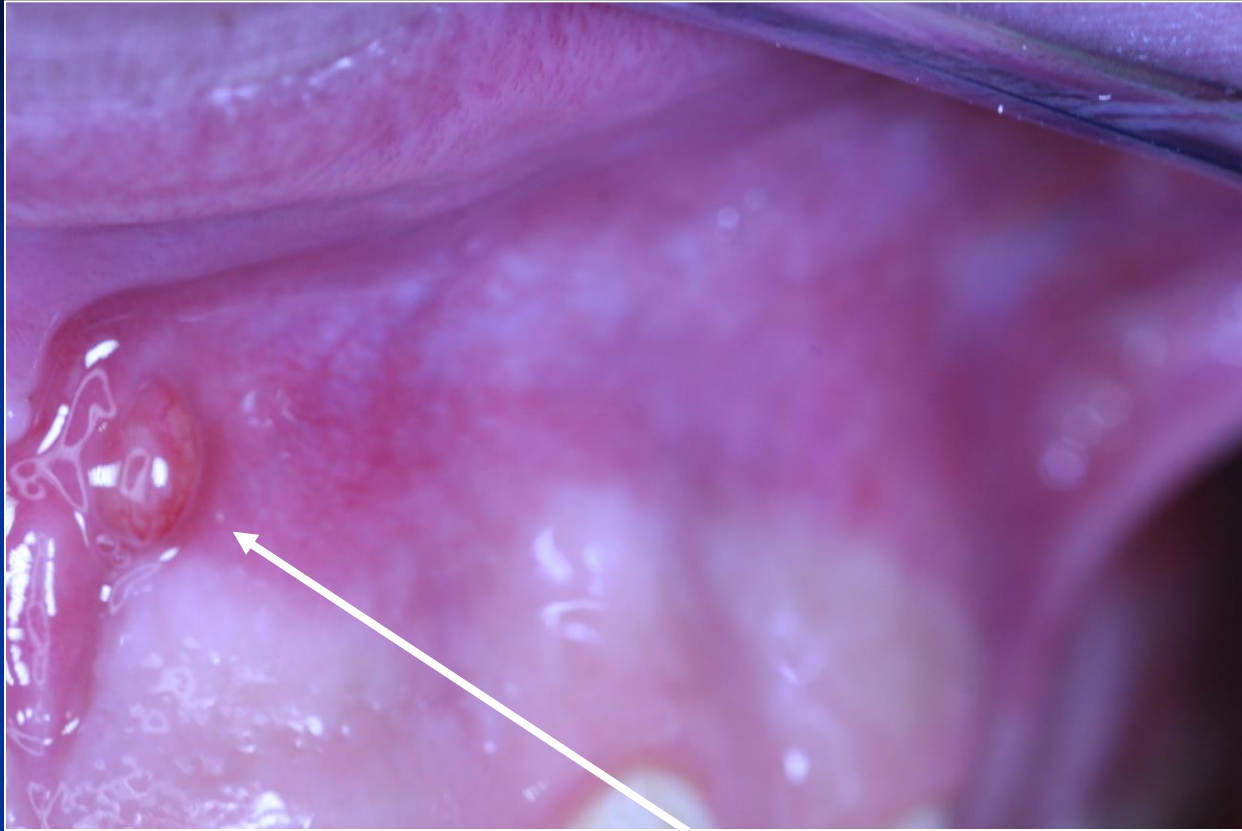
Zdroj: Manuál firmy Maillefer





Regional complications





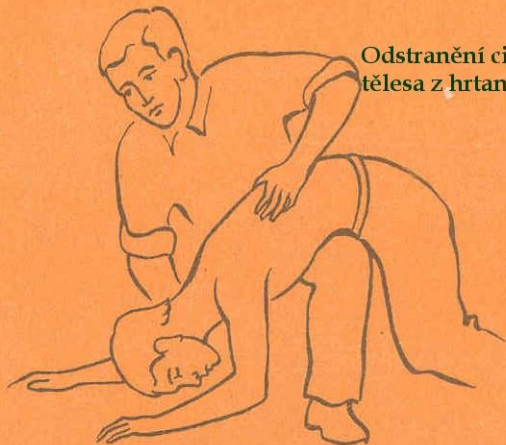
Píštěl

Systemic complications

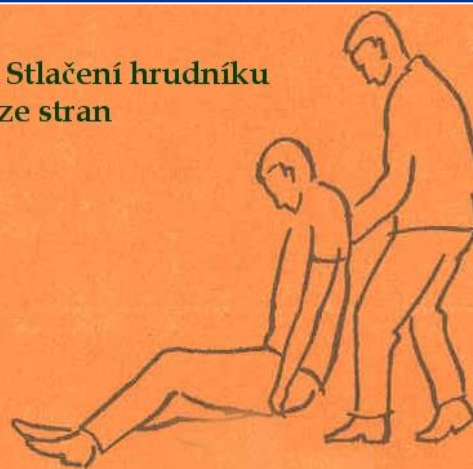Systemic complications

- Periostitis
- Inflammation of soft tissues (face, neck)
- Gulp of the instrument (X ray, remnant diet, information)- cough
- Aspiration of the instrument -emesis

**Odstranění cizího
tělesa z hrtanu**



**Stlačení hrudníku
ze stran**

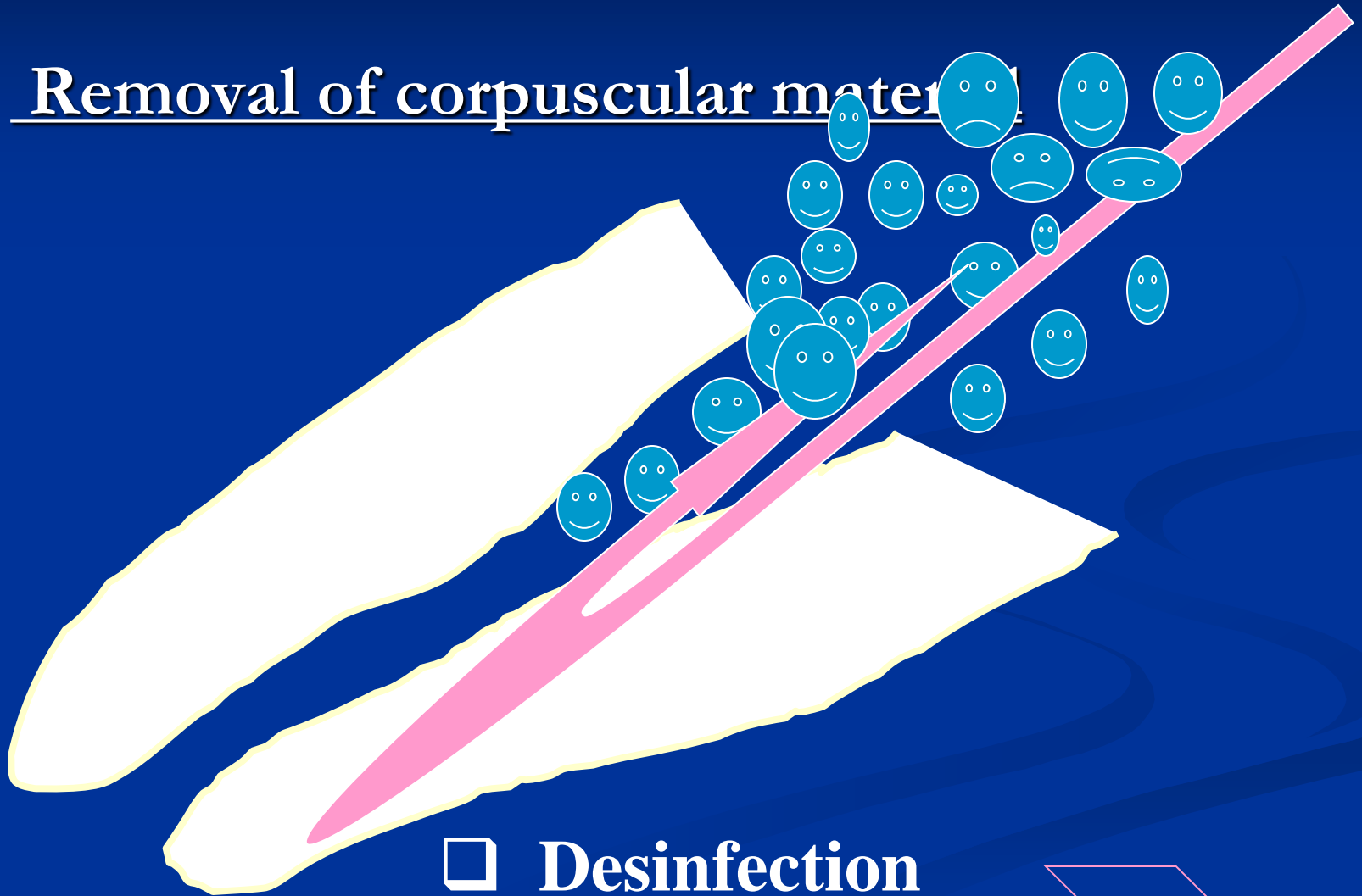


Caution!

Always find the loss instrument !!!!!

Irrigation of the root canal

□ Removal of corpuscular material



□ Desinfection

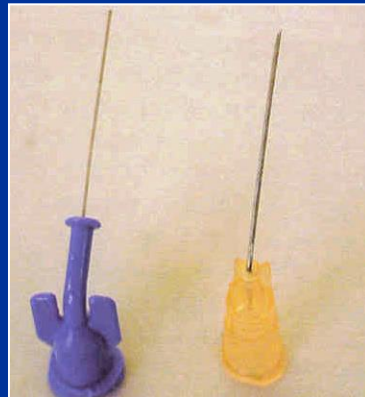



Výplachové roztoky

- ✓ Natrium hypochlorite – 0,5% – 5,25%
(1% - 2%)
- ✓ Chlorhexidin (0,12 – 0,2%)
- ✓ EDTA 17% solution or lubrication gel
- ~~✓ Hydrogen peroxide 3%~~
- ~~✓ Peracetic acid – 1%~~



■ Cannula



Activation of irrigation

- Hand
- Ultrasound
- Hydrodynamic
- Laser

Desinfection

- Calcium hydroxide
- Antibiotics and corticosteroids

Calcium hydroxide

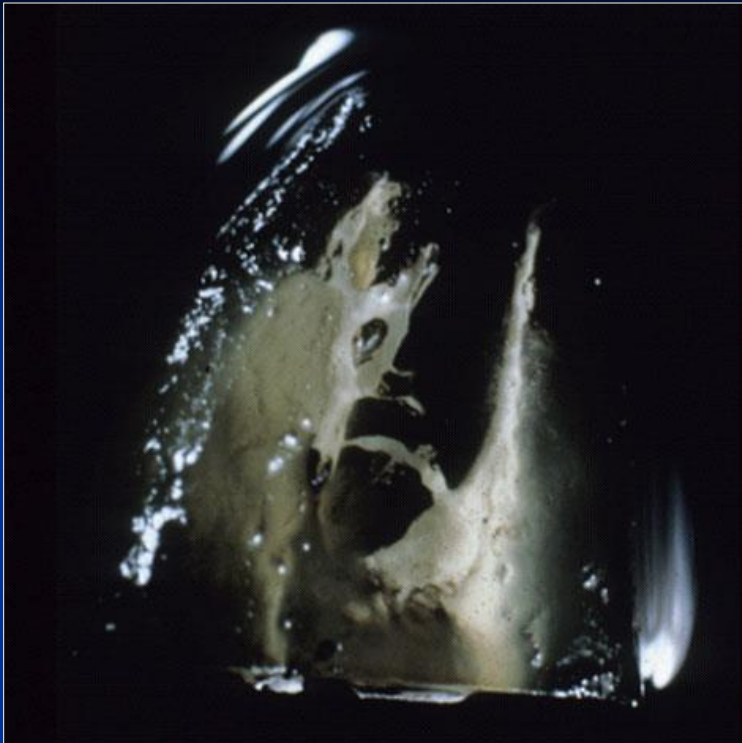- Alkaline
- Antibacterial
- Stimulation of hard tissue formation
- Haemostatic and antiphlogistic

Calcium hydroxide

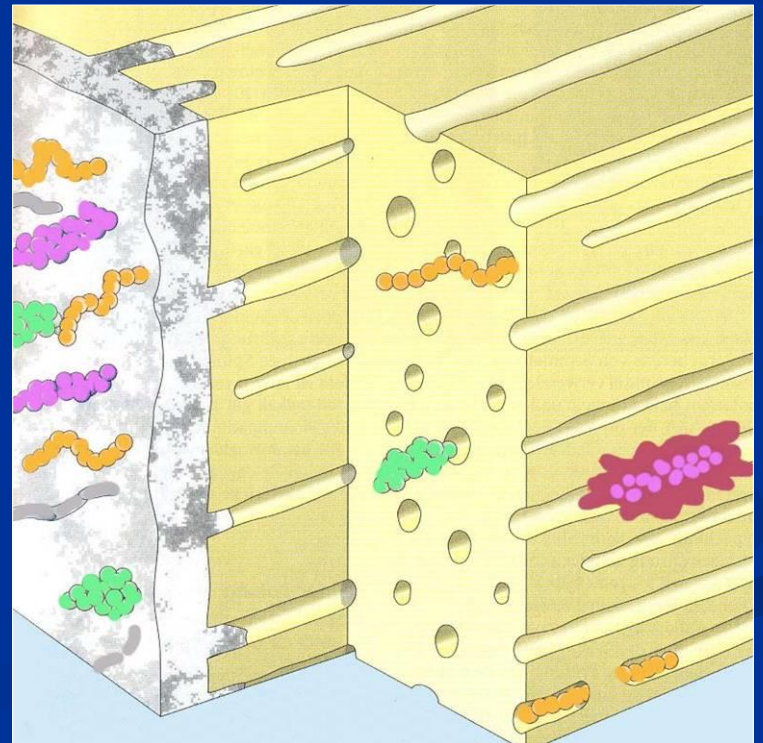
Temporary root canal filling

Subbase

Component of sealers



Dressing



Calcium hydroxide

- Short term action

1 – 2 weeks

Desinfection, haemostasis

Calcium hydroxide

- Middle term action

2 – 3 months

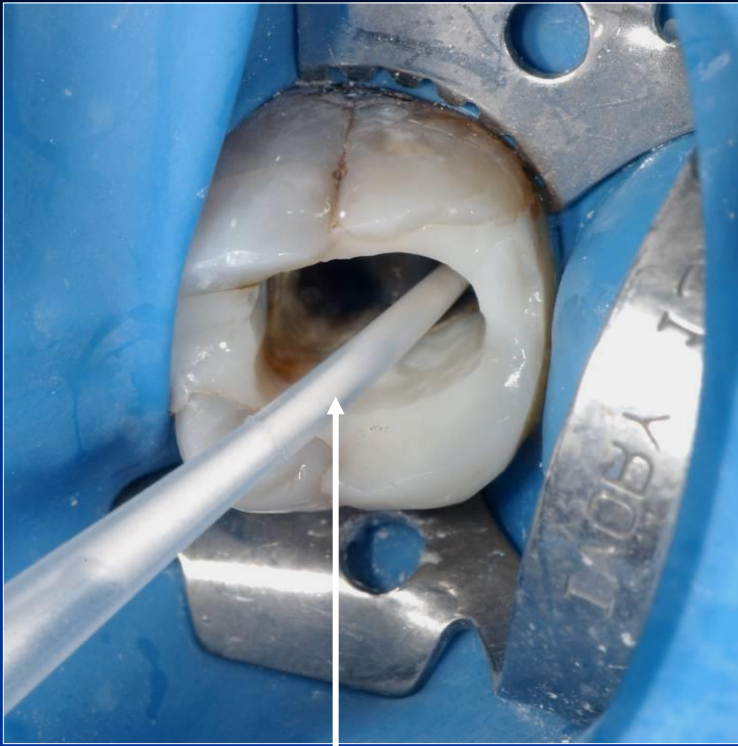
Apexification

Chronic form of apical periodontitis

Calcium hydroxide

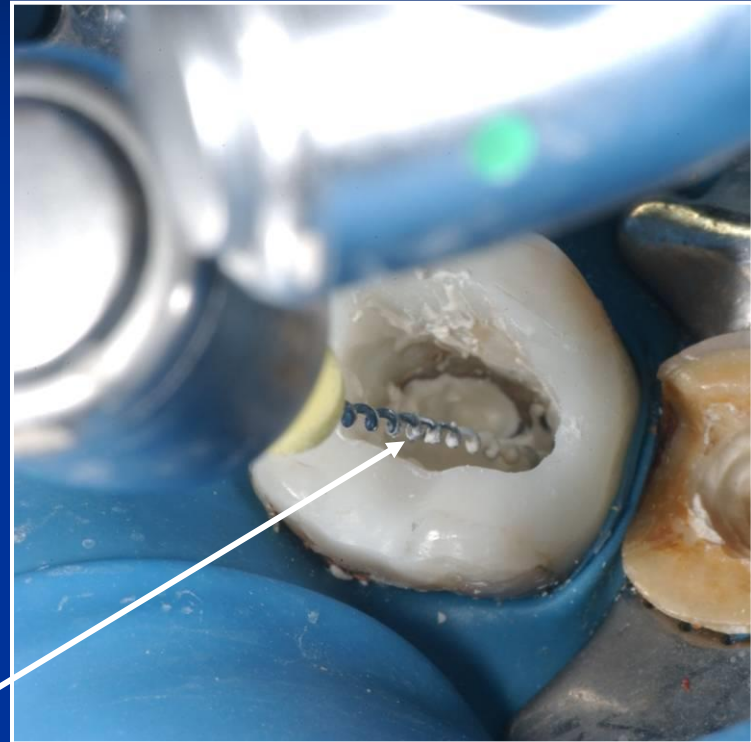- Long term action
3 months and more

Prevention of resorption

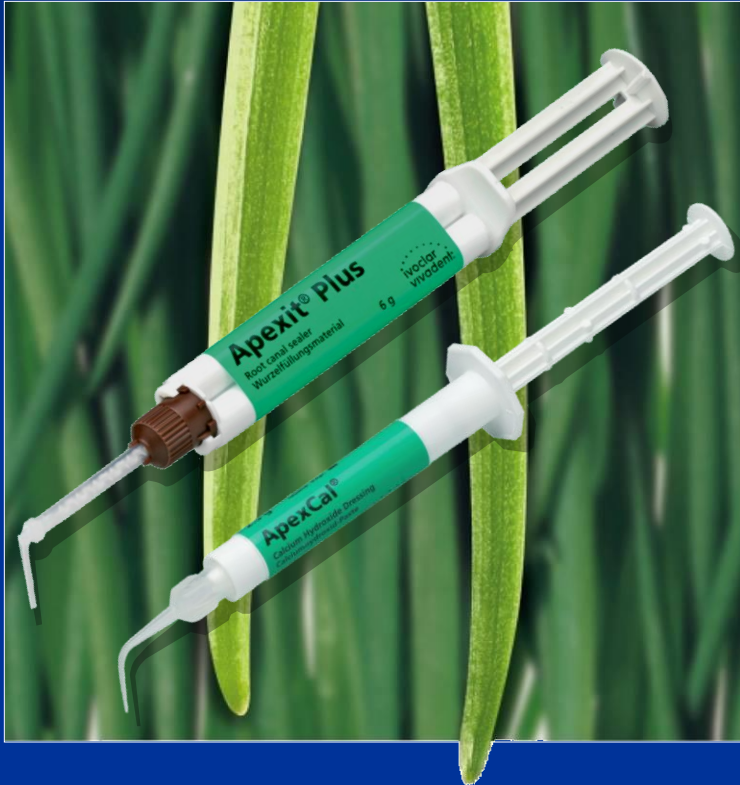

Magistraliter

The powder is mixed with distilled water



Lentule 2 mm less than WL !!!!!



Apexit® Plus

ApexCal®

Root canal filling

Ideal root canal filling (Grossman 1988)

1. Easy mixing
2. Sufficient working time
3. Good seal
4. X- ray contrast
5. Easy removal
6. No shrinkage
7. Long term volume stability
8. No bacterial growing
9. No permeability for fluids
10. Biocompatibility
11. No staining

Classification of root canal fillings

- Solid
- Semisolid
- Pastes

Guttapercha

Dried juice of the Taban tree (*Isonandra percha*)
(gutta)

1,4 - polyisoprene

Crystallin structure (60%)

Brittle

Guttapercha

■ Beta phase

■ Alpha phase 42 – 49 °C

- plastic

- **Gamma phase** 56 – 62° (amorfní)

Cooling process

very slowly (less than 0,5°C) – alpha phase

normal cooling– beta phase

Composition of guttapercha materials in endodontic

Guttapercha 19% – 22%

Zinc oxide 59 - 79%

Heavy metal salts 1% - 7%

Wax or resin 1% - 4%

Resilon

(Pentron)

- Thermoplastic synthetic polymer
- Points or material for injection

Composition:

Polyester polymers

Bioactive glass

Radioopaque fillers (bismuthum oxichlorid a and baryum sulphate)

Silver or titanium cones

- No good seal
- Silver cones - corrosion

Sealery

Chemically curing plastic materials

Good adhesion to root canal walls as well as solid cones

X- ray contrast

Biocompatibility

Sealers

Zinc Oxide-Eugenol

Chloropercha

Calciumhydroxide

Resins

Glasionomer

Silicone

Sealers

Importance

Filling of the spaces between the solid cones



Seal of the root canal filling

Zinc - Oxid Eugenol

Powder:

Zinc oxide

Liquid:

Eugenol

Acidic resins

Good adhesivity, antimicrobial effect, cytotoxic.
(resorbable)

Zink Oxid Eugenol sealers

Pulp Canal Sealer (Kerr, USA))

Tubuli- Seal (Kerr, USA)

Caryosan (Spofa Dental, ČR)

Chloropercha

Powder

Canadian balsam

Resins

Guttapercha

Zinc oxide

Liquid:

Chloroform

Resins

Chloroperča

Vlastnosti:

Good adhesivity

Shrinkage

Toxicity

Calciumhydroxide sealers

Base (powder)

Calcium hydroxide

Zinc oxide

Other components and vehicula

Kalciumhydroxidové sealery

Catalystr (paste)

Zinc stearat

Titanium dioxide

Baryum sulphate

or

Eugenol, Eukalypt

others

Kalciumhydroxide sealers

- Increase of the healing potential of periapical tissues
- Antibacterial effect
- Easy manipulation

But!

Resorbable if not homogeneous

Not suitable for the single cone technique

Resins

➤ Rezorcin formaldehyd

➤ Epoxide

➤ Polyketone

➤ Metacrylate

Rezorcín formaldehydové pryskyřice

Toxicity

N2, Endomethason, Riebler's paste, Foredent