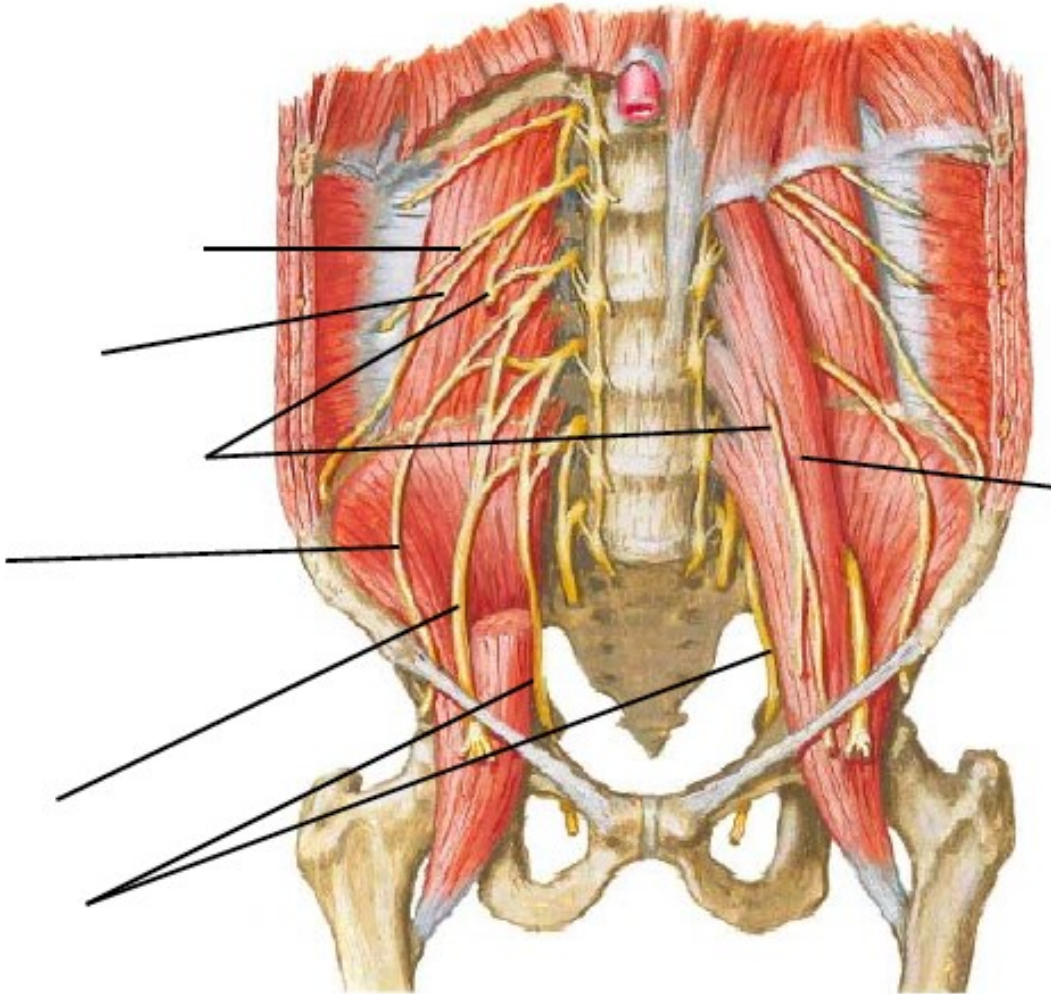


## PLEXUS SACRALIS ET PLEXUS LUMBALIS

1) Plexus lumbalis is distributed around m. \_\_\_\_\_.

2) Describe the picture:



3) Does n. ilioinguinalis pass through the inguinal canal? \_\_\_\_\_

4) N. cutaneus femoris lateralis is purely \_\_\_\_\_ nerve and it passes through \_\_\_\_\_ and innervates skin of \_\_\_\_\_

\_\_\_\_\_.

5) Which is the longest branch of n. femoralis? \_\_\_\_\_

Please draw its course.



6) Write all muscles (6), which are innervated by nervus obturatorius:

---

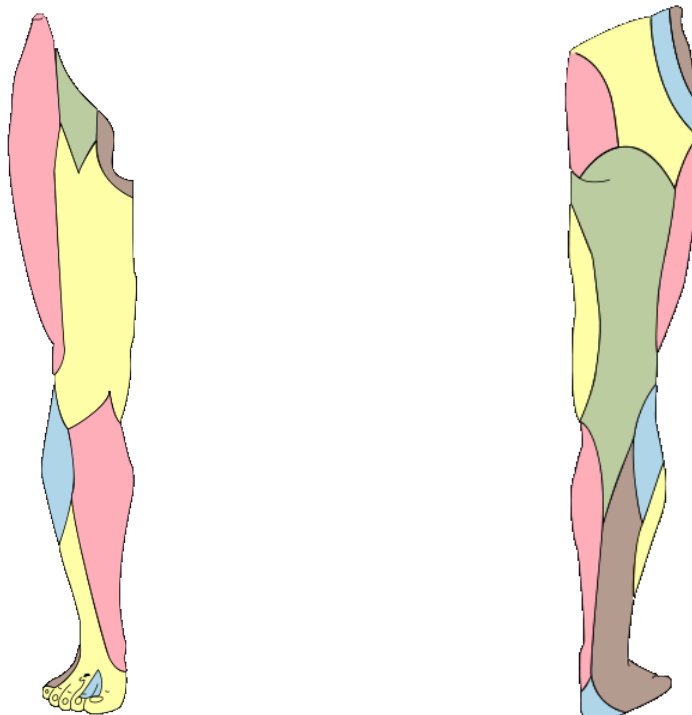
---

---

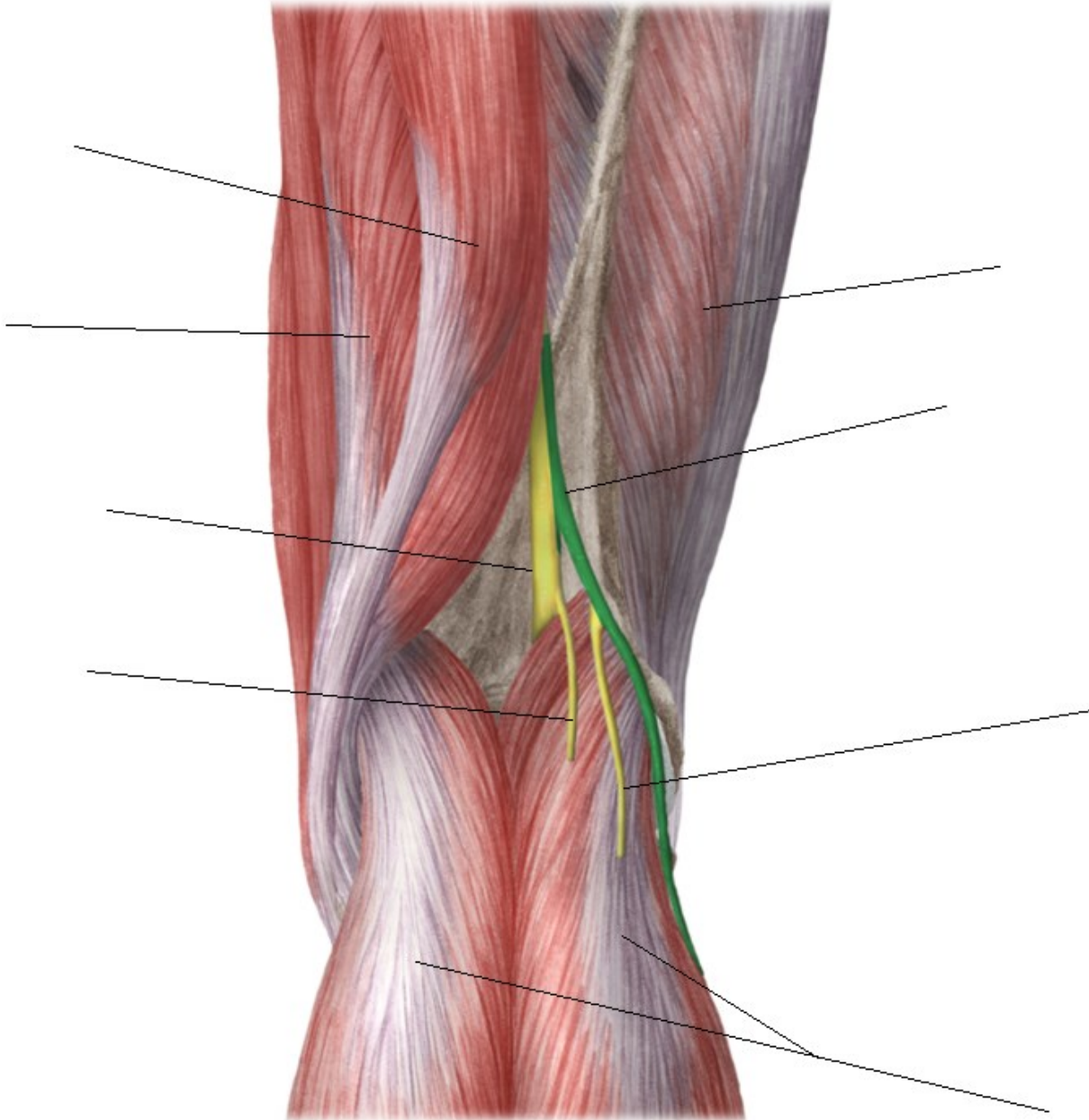
7) Which nerves (of sacral plexus) are passing through foramen suprapiriforme?

---

8) Which area is innervated by n. cutaneus femoris posterior and which one by n. cutaneus femoris lateralis?



9) Describe the picture.



10) Which nerve is the marked area innervated by:

