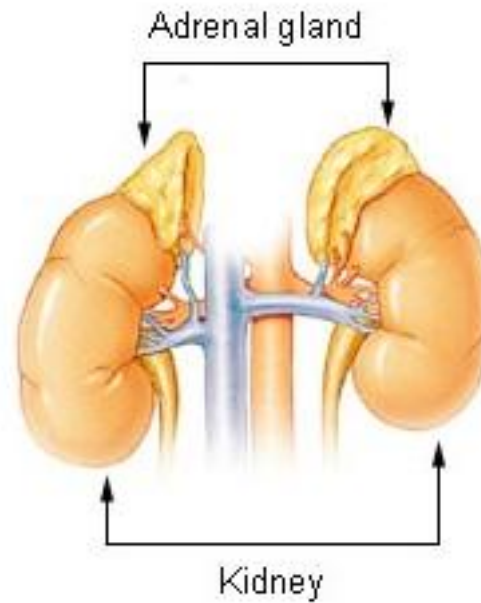

# Nemoci nadledvin

Seminář, Vnitřní lékařství 5.roční k LF MU  
MUDr. Dalibor Zeman

# Steroidní hormony

Metabolismus tuků , glycidů, bílkovin , regulace vnitřního prostředí ,minerálů vody , sek pohl. znaky

## Kůra nadledvin

zona glomeruloza - mineralokortikoidy- **aldosteron**/ RAAS, K

Na , K, angiotenzinu II

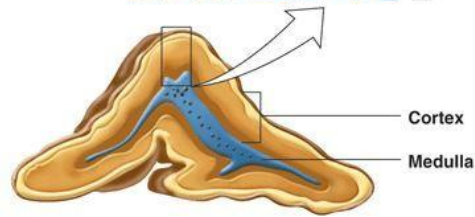
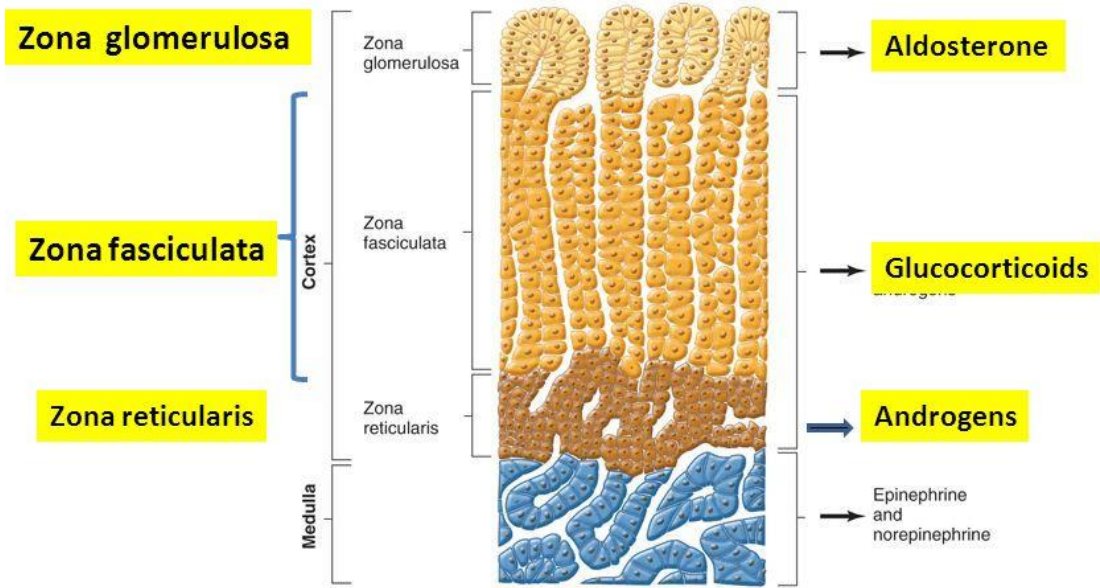
zona fascikulata – glukokortikoidy-**kortizol** / ACTH

zona retikularis - androgeny , **DHEA ,Testosteron, .....kortizol**/ ACTH

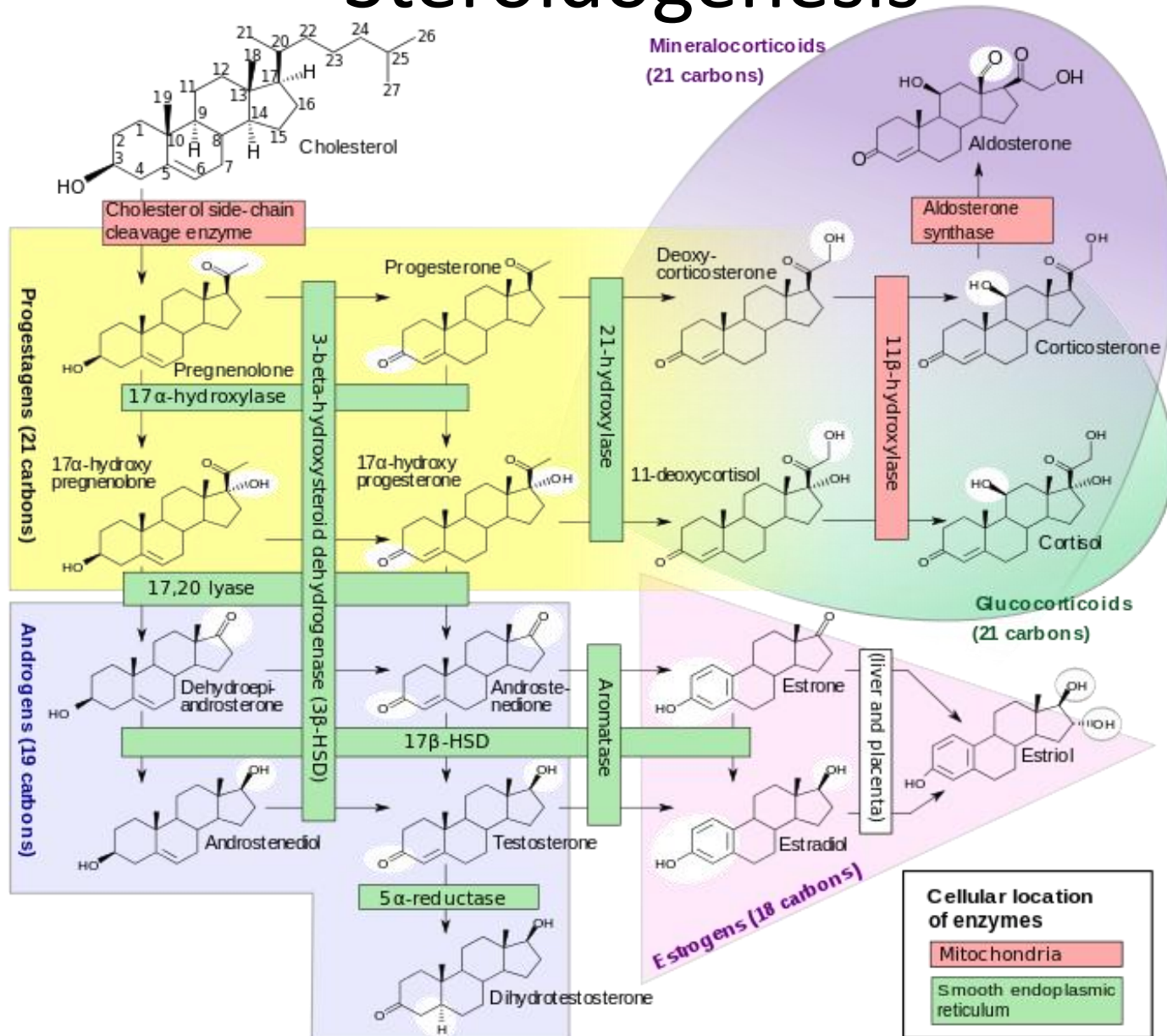
## Dřev nadledviny

katecholaminy, **NA , A , DOPA**

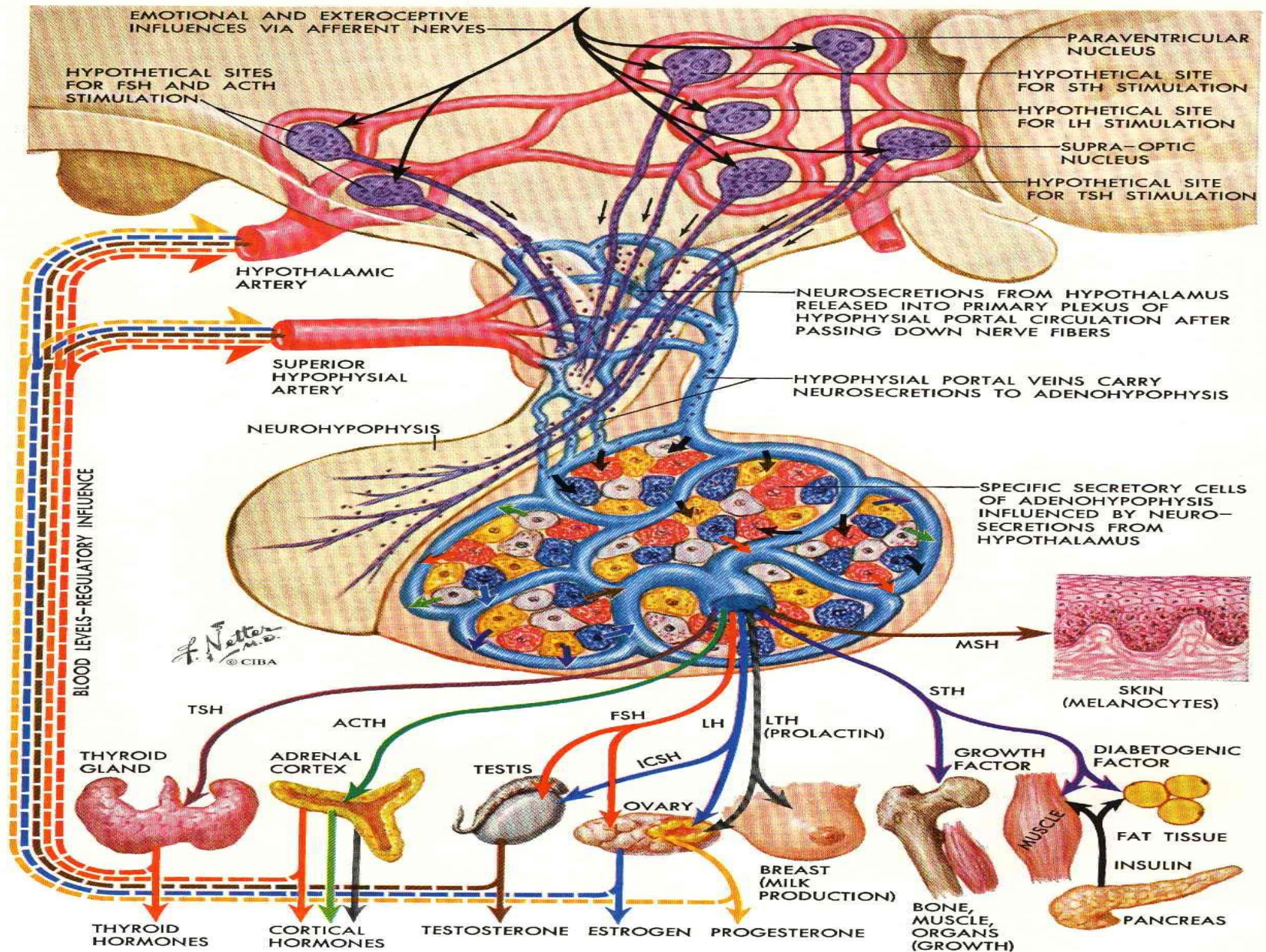
# Adrenal Morphology



# Steroidogenesis



# Hypophysial portal circulation, Neurosecretion, Portal veins transport



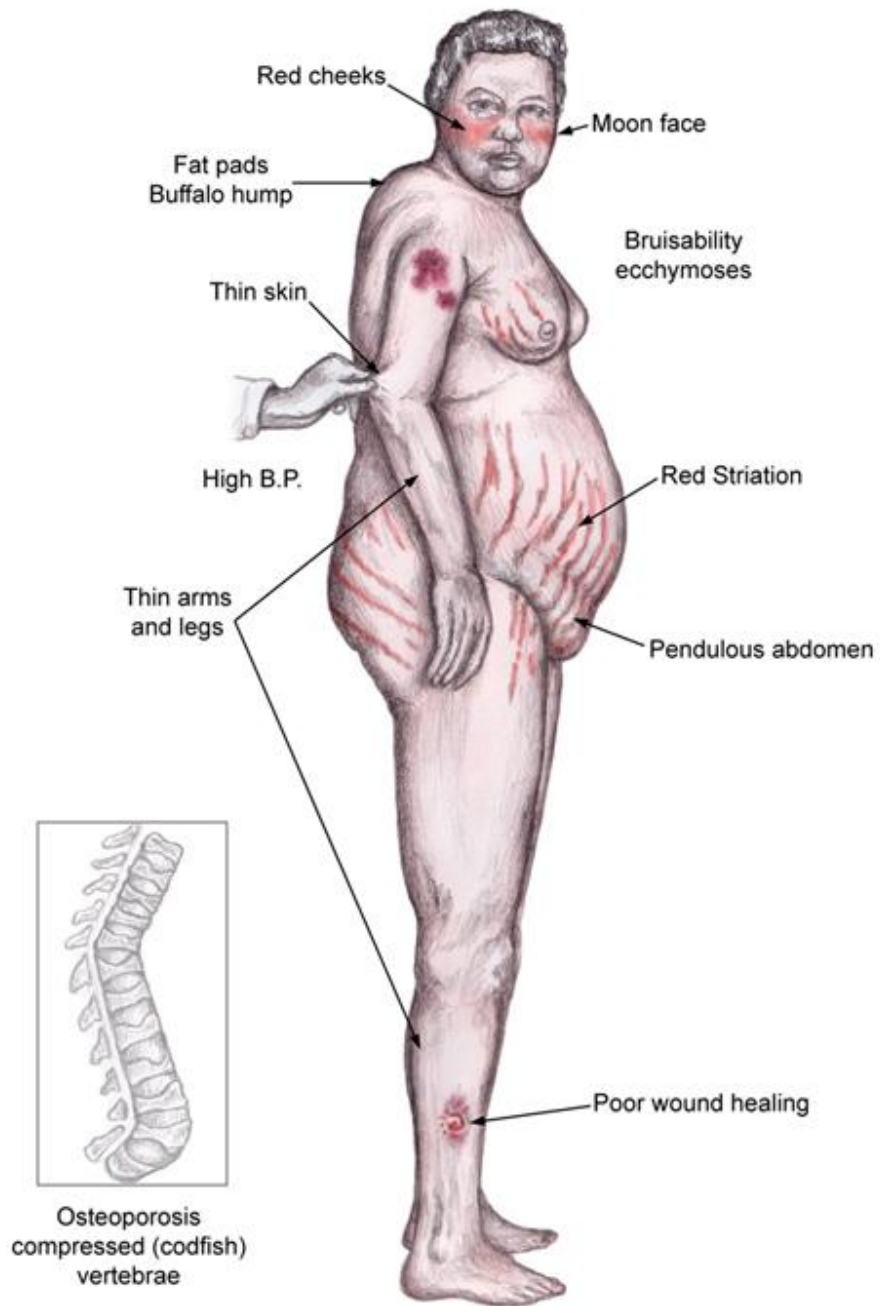
# Patofyziologie

- Primární,  
....Sekundární , .....Centrální , .....Periferní...  
... ektopická .....,
- Akutní a Chronické selhání
- Hyperfunkční a Hypofunkční syndromy

# Kortizol – Hyperkortizolismus

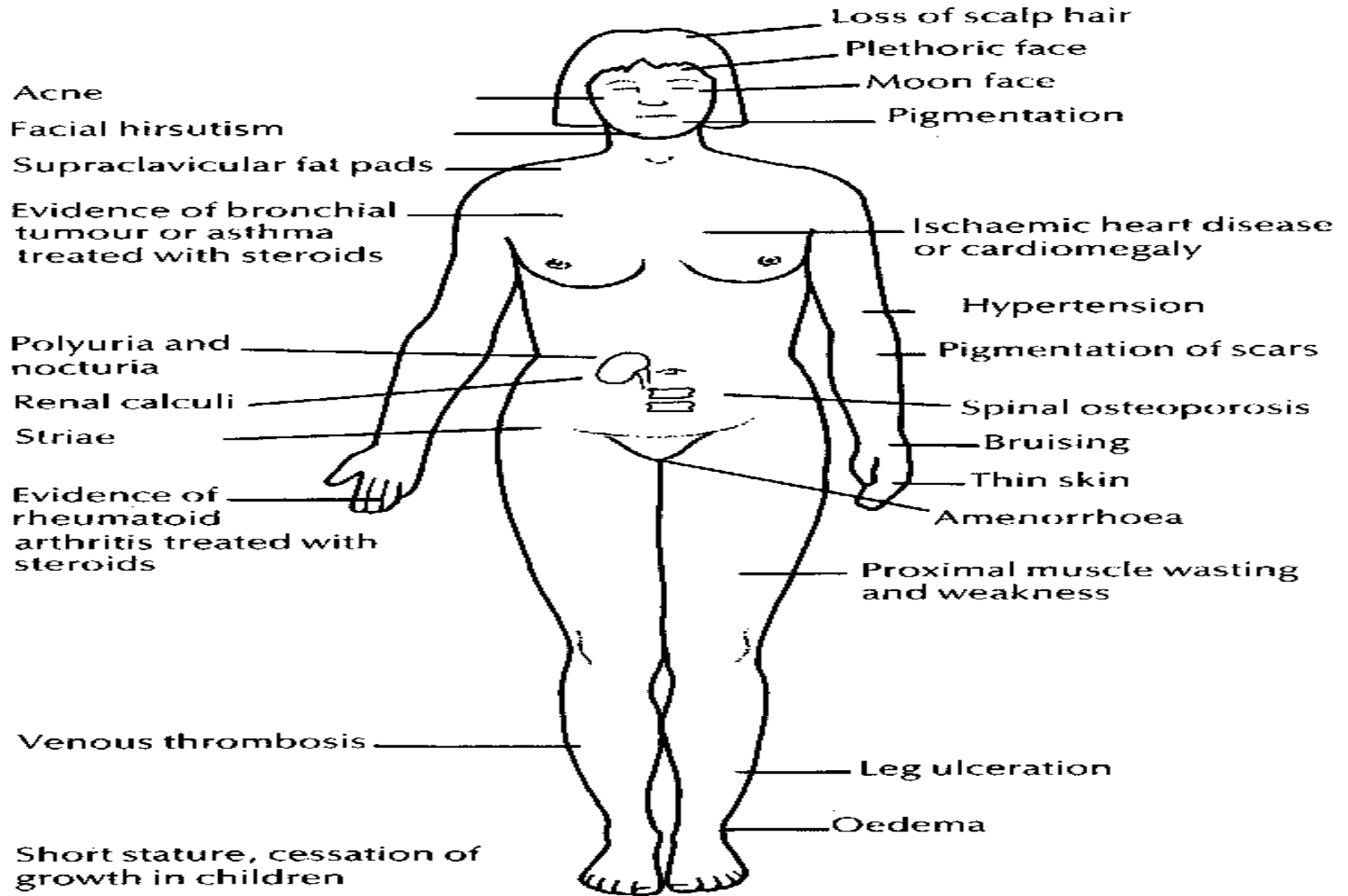
Fce.... Nadprodukce, hyperfunkce

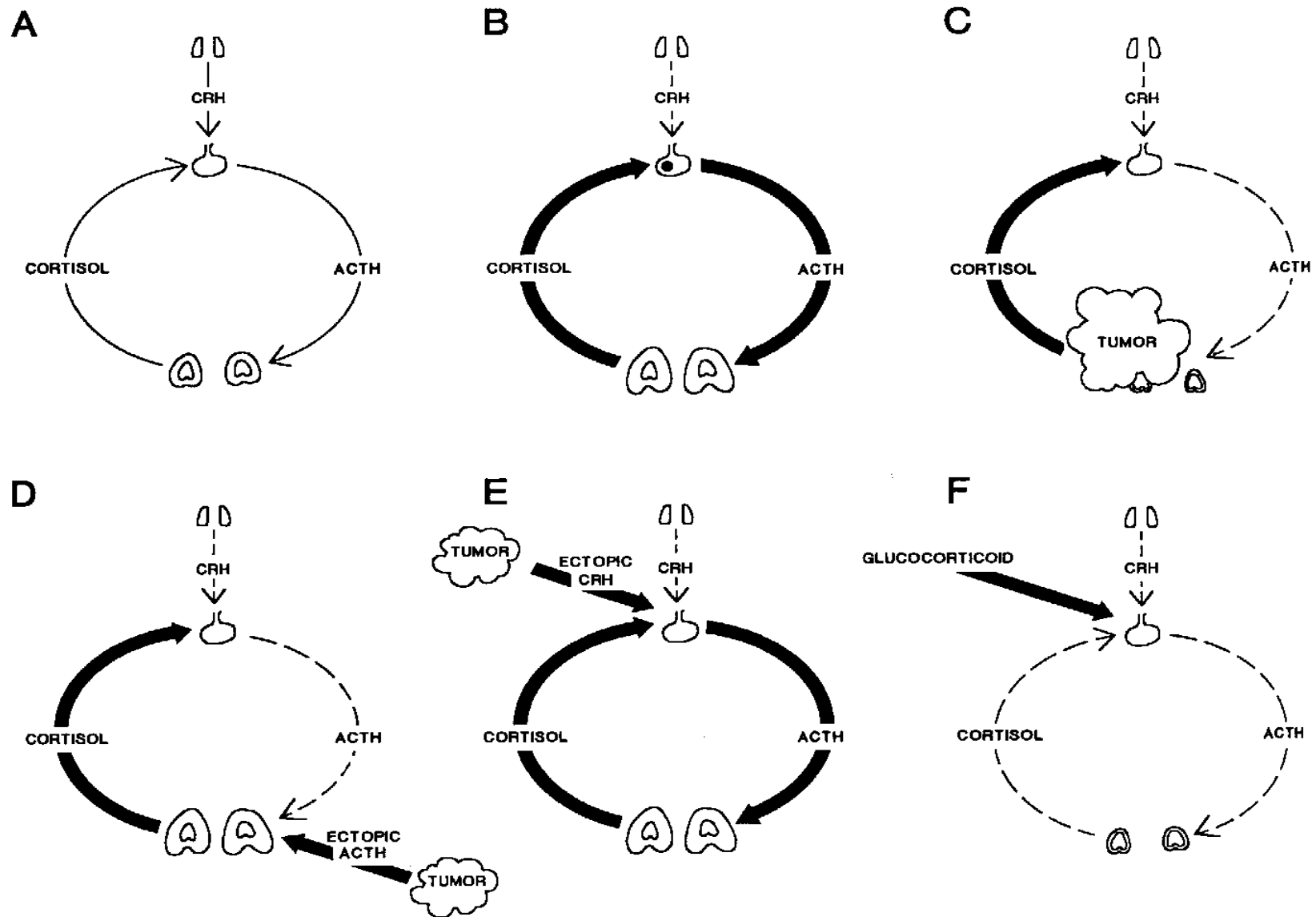
- **Cushingův syndrom**  
( primární adrenální hyperkortikalismus)
- **Morbus Cushing**  
(centrální hyperkortizolismus, ACTH dependntní hyperkortikalismus, hyperpituitarismus ...)
- **Paraneoplastický hyperkortizolismus** (malobb. Karcinom plic, Karcinoid)
- **Exogenní hyperkortizolismus CS**





# Cushing's syndrome





**Figure 12-38.** Hypothalamic-pituitary-adrenal function in normal individuals (A) and the pathophysiological aberrations in pituitary ACTH-dependent Cushing's disease (B), primary adrenocortical disease (i.e., cortisol-secreting adrenal tumor, bilateral micronodular dysplasia, and bilateral ACTH-independent macronodular hyperplasia) (C), ectopic ACTH syndrome (D), ectopic CRH syndrome (E), and iatrogenic Cushing's syndrome caused by pharmacologic dosage of glucocorticoids (F).

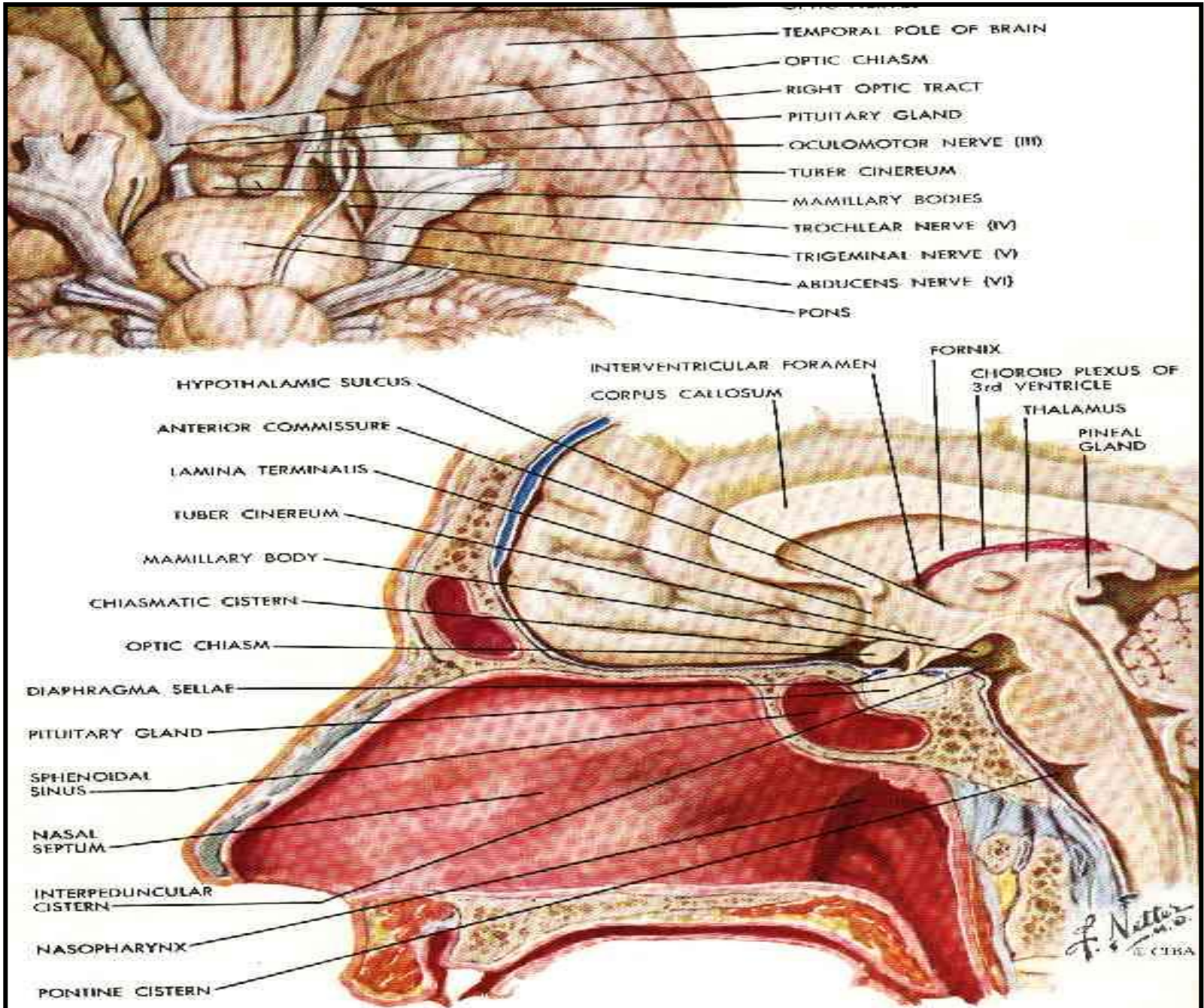
# Cushinguv syndrom -klasifikace

- **ACTH dependentní**
  - Chushingova nemoc 68%
  - Ektopický ACTH 15%
- **ACTH independentní**
  - Adenom nadledvin 9%
  - Karcinom nadledvin 8%

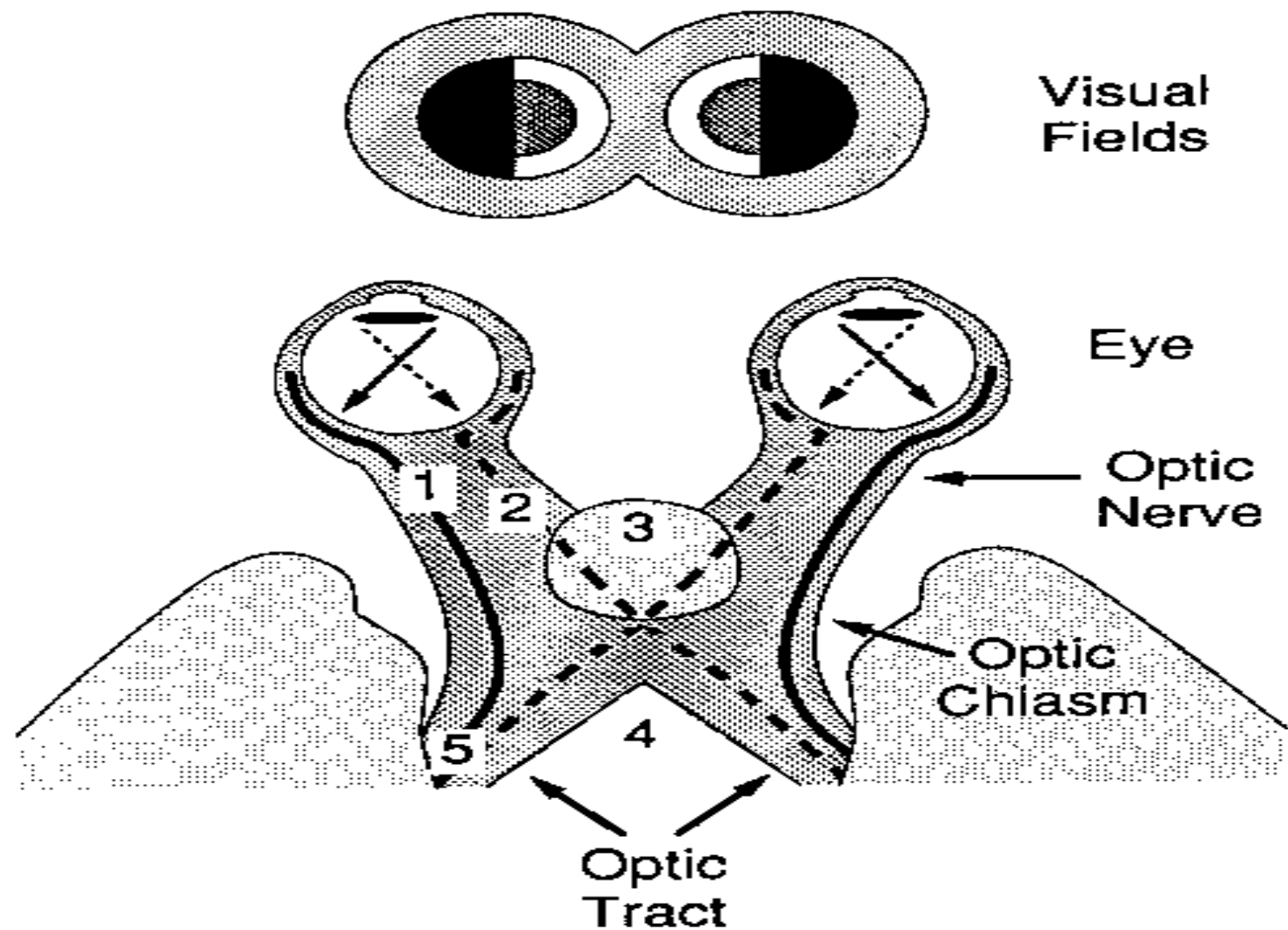
# Cushing's syndrome therapy

Pituitary dependent (central) Cushing's syndrome

- **Transphenoidal surgery**
- **Transcranial surgery**
- **Radiotherapy** (not recommended as a primary treatment)
- **Stereotactic Radiosurgery** non-surgical precisely-targeted radiation small tumors, preserve healthy tissue
- **Medical treatment** – metyrapone, aminoglutethimide, ketoconazole/kabergolin, mitotane (adrenolytic agent), pasireotide, somatostatin analogs – Signifor



# Hypophys



**Figure 9-29.** The most common visual field defect, bitemporal hemianopia (black areas of visual fields) is caused by compression of the posterior aspect of the chiasm (4) from below. Visual disturbances resulting from compression of the optic nerves, chiasm, and tracts are listed below. The site of lesion is indicated by number.

Pattern

Visual Field/Acuity

Anatomic Correlate

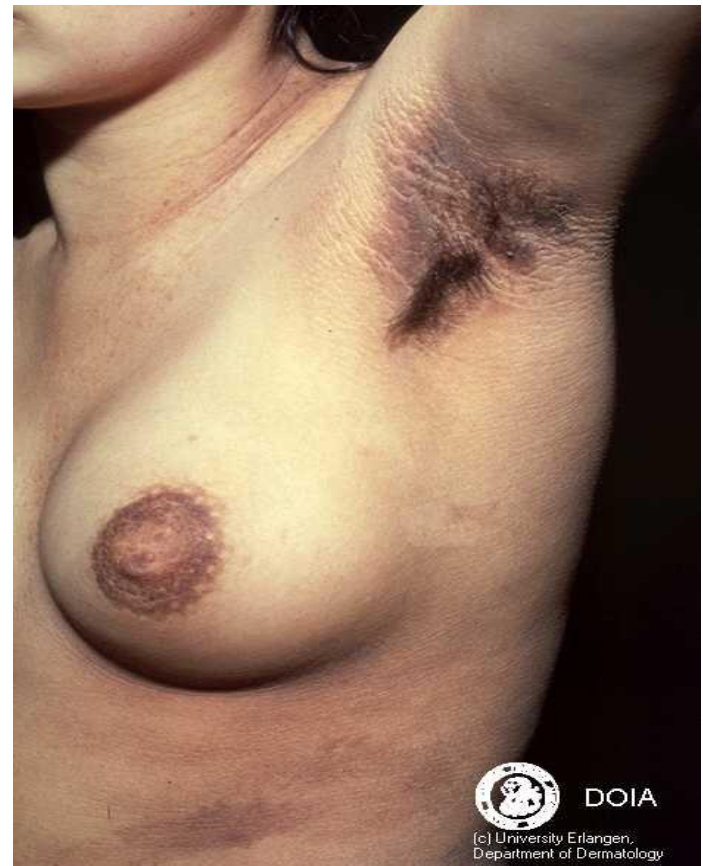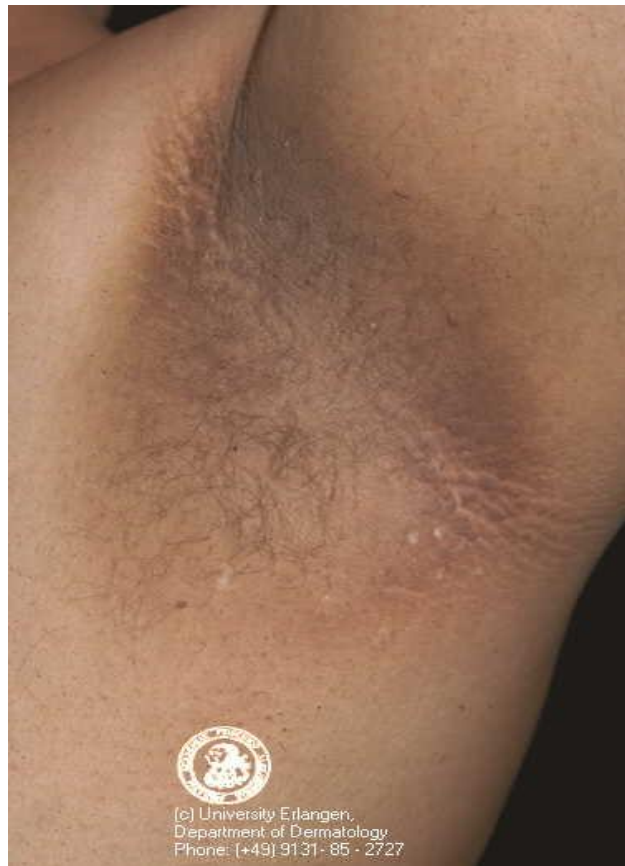# Kortizol

Fce .....nedostatečna funkce , hypofunkce

- **Addisonova choroba** - (primární adrenokortikální insuficience)
- **Hypopituitarismus**  
(centrální adrenální insuficience )

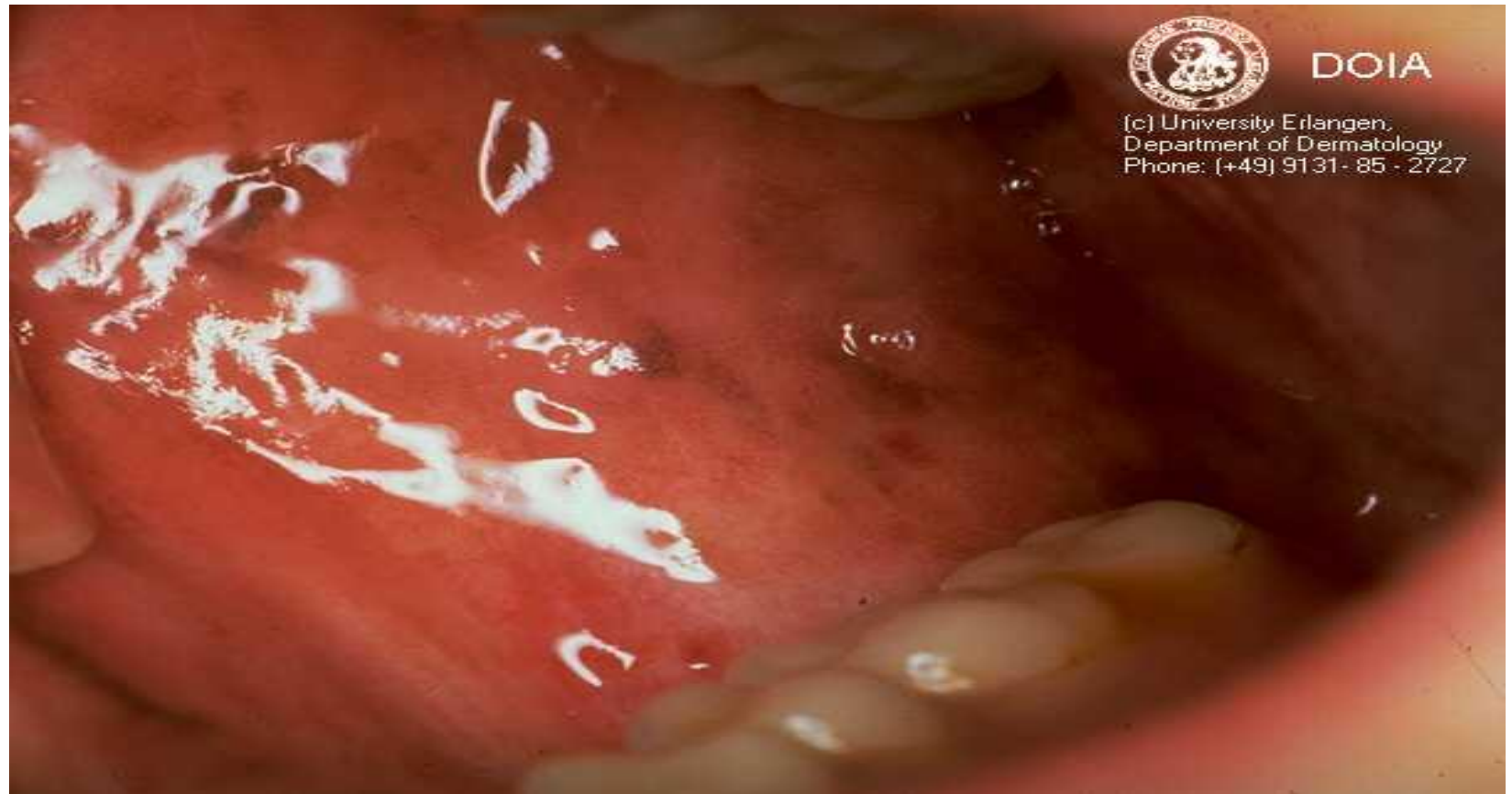.... Léčba substituční kortikoidy ale také  
mineralokortikoidní substituce ...  
(HCT,Fludrokortizon)

# APS 1.,2.- hyperpigmentace , addisonova choroba

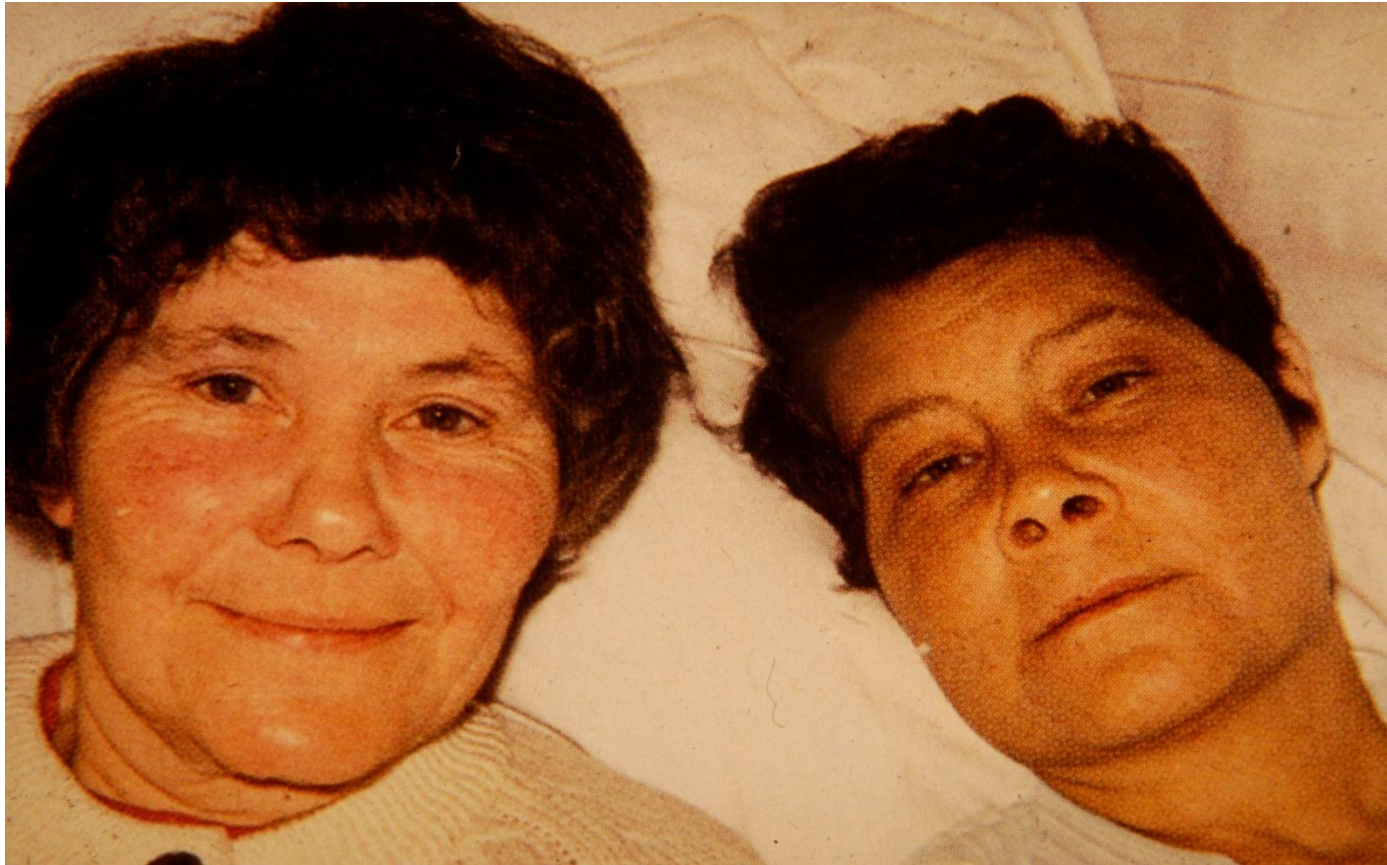



# APS 1.,2.- grafitové skvrny



# APS 1.,2.-addisonova choroba




# Adrenal failure

## Addison's Disease

Easy to diagnose and treat -- if you think of it.

normal adrenal




Addison's from TB



auto-immune Addison's




iron overload



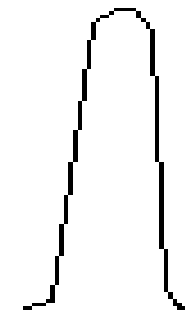
hypotension  
hyperkalemia

hyperpigmentation  
"mental illness"  
weakness



ACTH stimulation test

Blood cortisol level  
after ACTH injection



Normal



Adrenal  
insufficiency

Repeat: Improvement suggests pituitary disease ("secondary Addison's"); no improvement indicates primary adrenal disease.

# Aldosteron

... fce

(primární hyperaldosteronismus )

- AAA 45% **Connov syndrom**
- Idiopat. bilat. A. Hyperplasie 45%
- unilat. AH 5%
- familiární hypaldosteronismus (dex s) 1%

# Primární hyperaldosteronismus

20% výskyt u nemocných s těžkou farmakorezistentní hypertenzí

- bilaterální hyperplazie (tzv. idiopatický hyperaldosteronizmus – 65 %)
- unilaterálním adenom nadledviny (Connův syndrom – 30 %),
- další varianty jako kombinace hyperplazie a adenomu, unilaterální adrenální hyperplazie, familiární hyperaldosteronismus I. a II. typu či karcinom kůry nadledviny jsou méně časté

# Androgeny

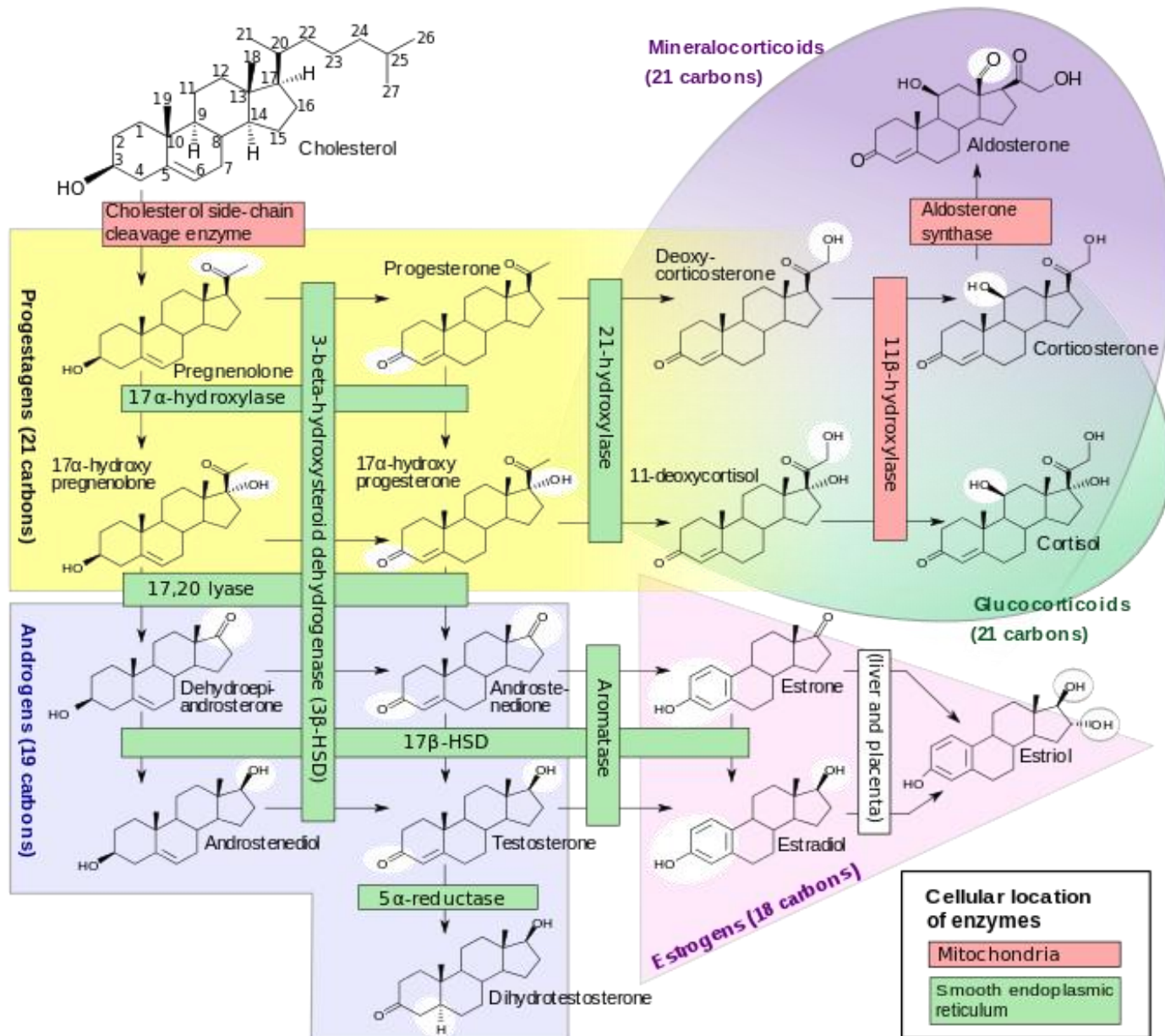
- **Adrenální virilizace** , hirsutismus, hypertrichoza  
( tumor, carcinom , congenitalní adrenální hyperplasie CAH –steroidní enzymopatie)

**CAH klasická**( časná) adrenogenitální sy

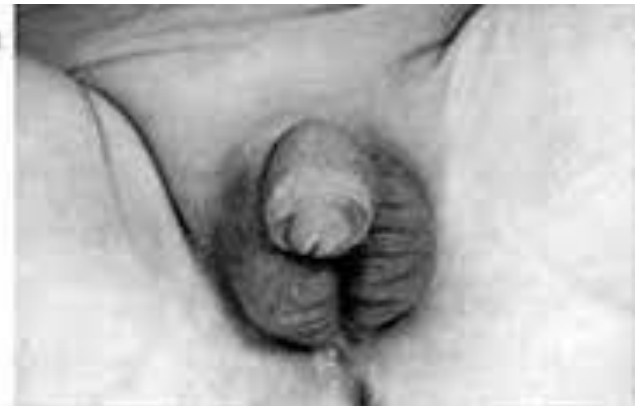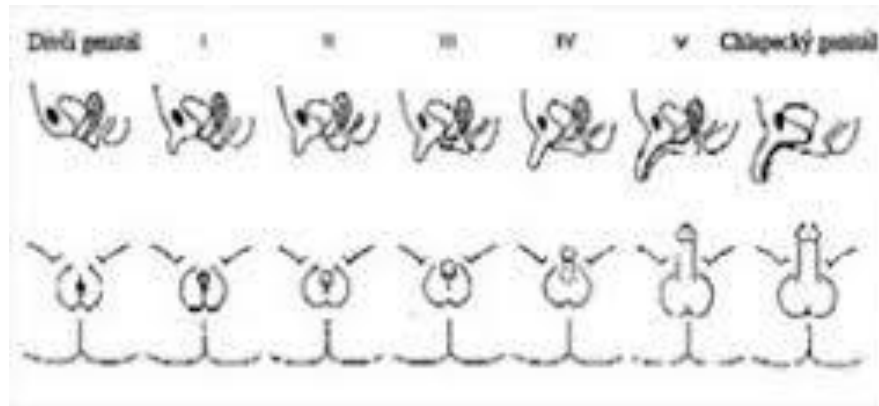
**CAH** neklasická tzv **Late Onset** (pozdní)

se solnou poruchou nebo bez ní

# Steroidogenesis



# Adrenogenitální sy.





# Katecholaminy

- Dřen nadledviny chromaffinní bb. **Feochromocytom**
- Sympatický, Parasympatický NS

## **Paragangliom**

(sympat. NS - hrudník břicho pánev )

(parasympat. NS krk )

Zarodečné mutace : 20 genů spoj s PPGL

Genetické syndromy PPGL : **VHL, MEN2, mnohočetná familiární paragangliomatoza, Recklinghausenova neurofibromatoza,**

# FEO , PGL

- **Diagnostika**

MN, NMN/pl , CT, MR, PET/CT , MIBG ,F-DOPa, ,  
Somatostatin analoga (Ga izotop ) FDG

- **Terapie**

Adrenalectomia Alfa1-adrenoreceptor block

Doxazosinum ( Zoxon tbl ) ,Prazosinum  
( Deprazolin tbl )

# Von Hippel–Lindau Syndrome

Autosomal dominant genetic condition

(mutation in the tumor suppressor gene on chromosome 3p25.3)

**characterized by** visceral cysts, benign masses, and the potential for malignant transformation in multiple organ systems

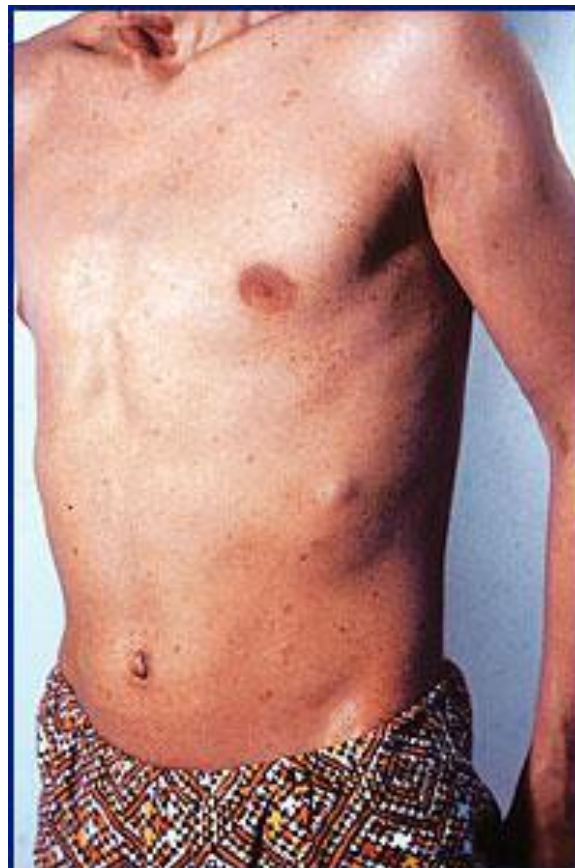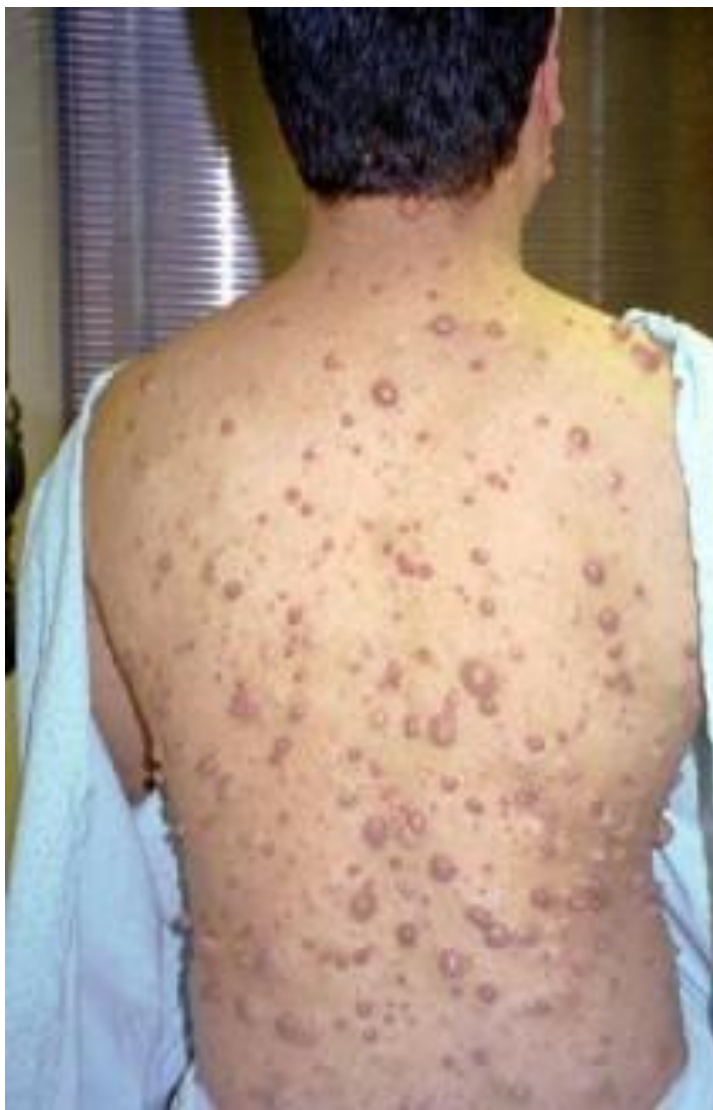## Clinical features:

- \* Eye tumor (retinal hemangioblastomas)
- \* Brain tumor (CNS hemangioblastomas)
- \* Kidney tumor (renal cell carcinoma)
- \* Adrenal gland tumor (pheochromocytoma)
- \* pancreatic tumors (pancreatic serous cystadenoma)
- \* Cafe au lait spots
- \* CVS (strokes, and heart attacks)





# VHL



Obr. 6 – Charakteristický nález skvrn bílé kávy a podkožních neurofibromů u pacienta s Recklinghausenovou chorobou

# Incidentalomy

- Dg., Metodiky, Obraz

- Addison nemoc – Morbus Addison
- Cushingova nemoc – Morbus Cushing
- Cushingův syndrom
- Connův syndrom
- CAH
- Feochromocytom
- Incidentalom