

# Chapter 5 Occlusion

## INTRODUCTION

Concepts of occlusion in the early twentieth century were based primarily on the rehabilitation of totally edentulous patients with complete dentures. At the time, a relatively large segment of the population was edentulous, in part because of the wide-spread acceptance of the focal infection theory (Goymerac and Woollard, 2004). Complete mouth extraction was commonly prescribed by physicians for patients with systemic diseases in an attempt to eliminate any oral infections that were assumed to act as focal infections and cause the systemic disease.

## CENTRIC RELATION AND CENTRIC OCCLUSION

Concepts of centric relation evolved as dentists refined their treatment methods for edentulous patients (Hanau, 1929). It was observed by many dentists that the mandible of an edentulous patient could be guided upward and backward to a stable, repeatable position. In this position, the mandible appeared to hinge or rotate about an axis (Figure 5.1). Because these dentists assumed that each condyle was centered in its respective glenoid fossa when the mandible reached this position, the position was referred to as centric relation (Hanau, 1929). Many dentists believed that the condyles were in the most retruded position when the mandible was in centric relation (Thompson, 1946), and by the latter half of the twentieth century, most definitions of centric relation described it as the most retruded mandibular position. It was also assumed, at the time, that the condyles were in centric relation when a dentate patient brought together the maxillary and mandibular opposing teeth (Niswonger, 1934); therefore, the position with the opposing teeth fitting together was referred to as centric occlusion. Posselt's (1952) research on mandibular movements clearly demonstrated that, with most patients, the condyles were not in centric relation when the teeth fit together best. He suggested the term intercuspal position (ICP) to designate the best fit of the teeth, rather than centric occlusion.

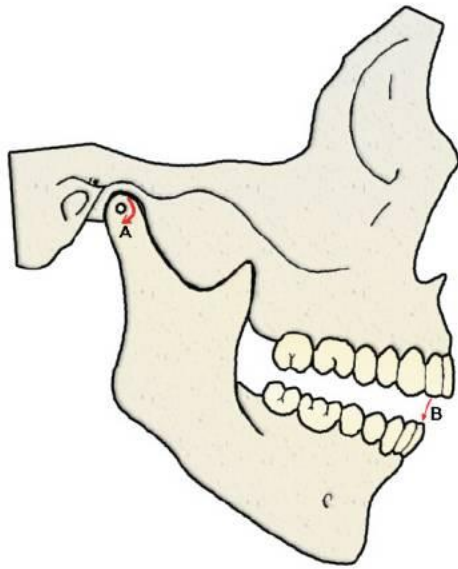
American dentists ignored Posselt's suggestion and continued to use the term centric occlusion to designate the ICP. Finally, in 1987, the *Glossary of Prosthodontic Terms*, fifth edition (Academy of Prosthodontics, 1987), introduced the term maximum intercuspal position (MIP) (later modified to maximal intercuspal position in a subsequent edition of the *Glossary*) as the designation for the best fit of the teeth.

The term centric occlusion was not abandoned but was redefined as "the occlusion of opposing teeth when the mandible is in centric relation" (Academy of Prosthodontics, 1987), a position that may or may not coincide with MIP. In that fifth edition of the *Glossary*, centric relation was also redefined as, "the maxillomandibular relationship in which the condyles articulate with the thinnest avascular portion of their respective disks with the complex in the anterior-superior position against the slopes of the articular eminences. This position is independent of tooth contact. This position is clinically discernible when the mandible is directed superiorly and anteriorly. It is restricted to a purely rotary movement about the transverse horizontal axis." This definition was based on a new understanding of the physiology of the temporomandibular joint (Figure 5.2). Centric relation was not relocated; it was redefined. In 1995, McDevitt et al. conducted a magnetic resonance imaging study of a group of patients and confirmed the validity of the new definition.

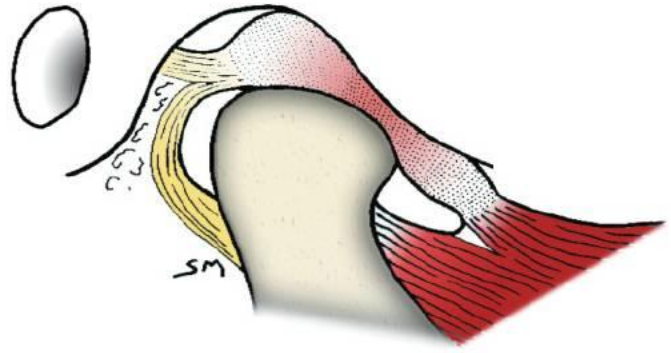
It has become universally accepted that the MIP for a totally edentulous patient should coincide with centric relation. This concept was later applied to patients with natural teeth. Many dentists believed that a natural MIP that did not coincide with the centric relation position was a malocclusion, while others disagreed.

## BALANCED ARTICULATION

Developing an MIP that coincides with centric relation provides denture stability in MIP; however, mastication is not restricted to pure hinge movement. Mastication involves lateral, protrusive, and retrusive three-dimensional movements. Arranging the artificial teeth of complete dentures to allow simultaneous contact of the teeth in eccentric positions can enhance denture stability, uniformly distribute the forces directed to the edentulous ridges, and improve masticatory performance and patient comfort (Ohguri et al., 1999; Khamis et al., 1998; Sutton and McCord, 2007) (Figure 5.3). Dentists noticed, empirically, that if the artificial teeth for complete dentures were set to balanced articulation (cross-arch, cross-tooth balance, whereby all teeth contact without interferences in all eccentric positions), there appeared to be less resorption of the edentulous ridges, and the dentures were more stable during mastication. Balanced articulation became the gold standard for complete denture occlusion.

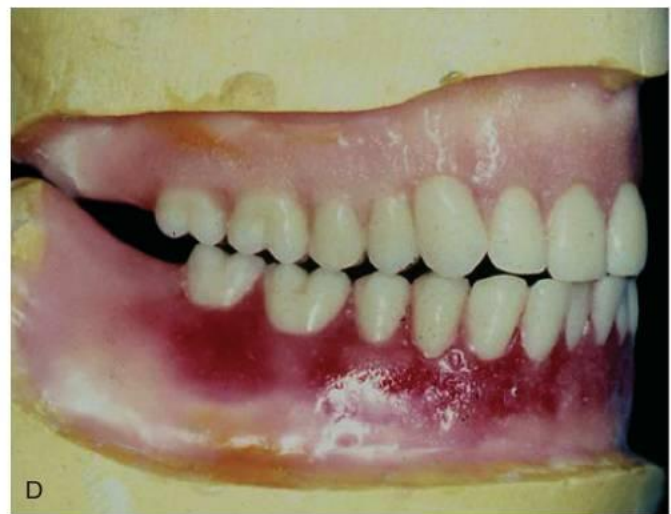
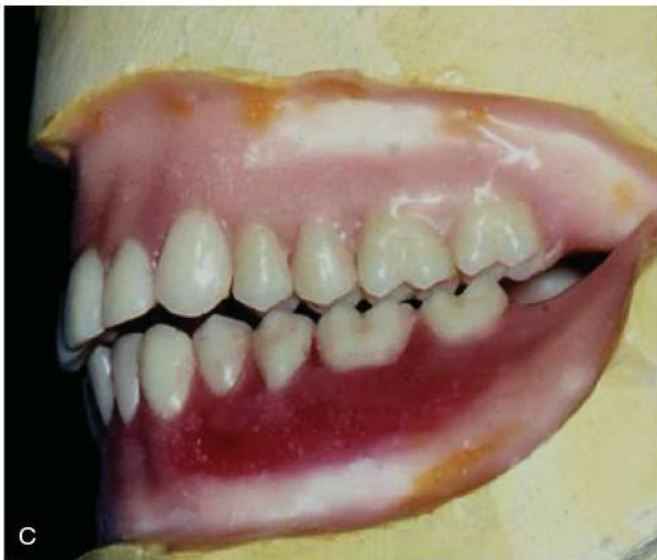
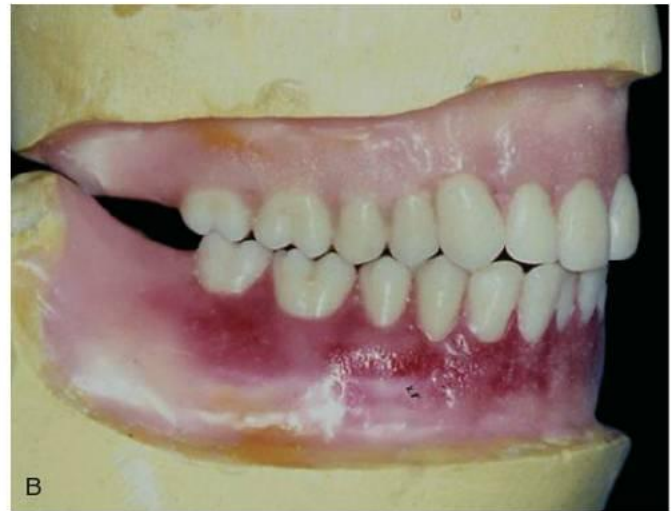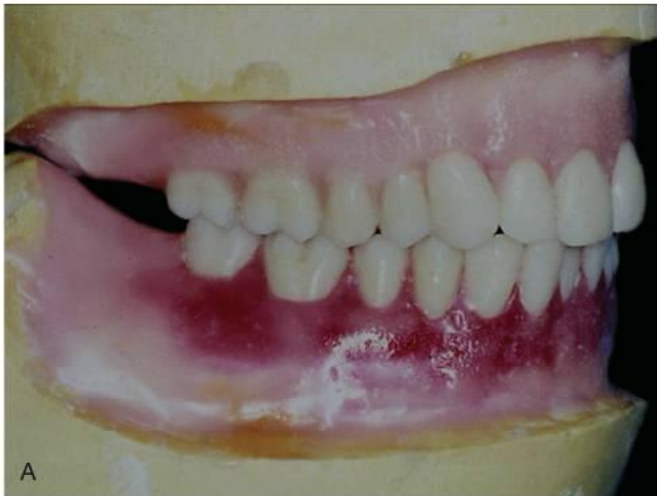**Figure 5.1.** When the mandible is in centric relation it rotates about an axis.



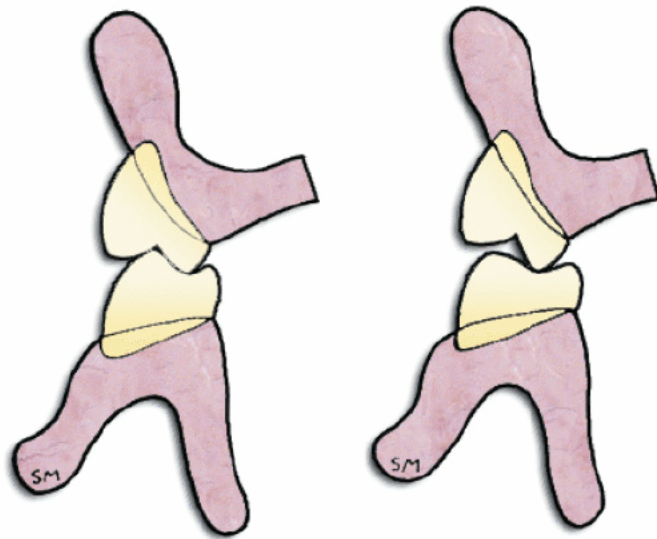
**Figure 5.2.** The current definition of centric relation describes condyles as articulating with the thinnest avascular portion of their respective disks with the complex in the anterior-superior position against the slopes of the articular eminences.

e55ee82b65b746a624a9148a5c720ea4  
ebruary

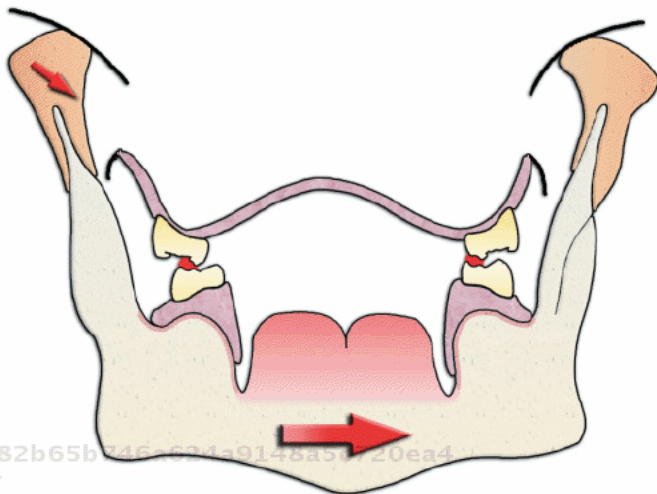


**Figure 5.3.** Thirty-degree anatomical teeth have been arranged in wax with balanced articulation. A, MIP; B, working side contacts; C, nonworking side (balancing-side) contacts; D, contacts in protrusion.

e55ee82b65b746a624a9148a5c720ea4  
ebruary

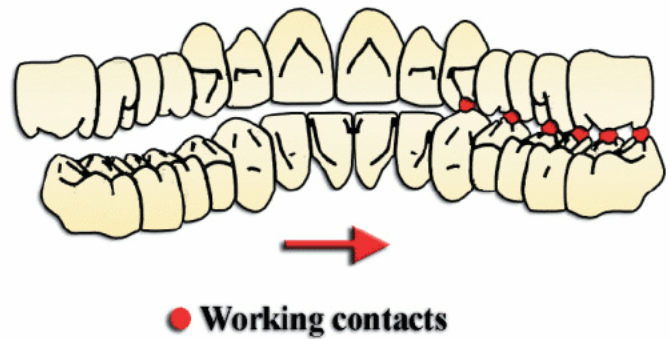


**Figure 5.4.** Left, classical balanced articulation; right, lingualized occlusion.



**Figure 5.5.** With lingualized occlusion, there is cross-arch balance but no cross-tooth balance.

A modified form of balanced articulation was described by Payne in 1941. Payne suggested an arrangement of the artificial teeth with cross-arch balance, but not cross-tooth balance (Figures 5.4, 5.5). The term lingualized occlusion was later used to describe this method of developing an artificial occlusion (Pound, 1970). This occlusal concept has become popular and is commonly advocated for implant-supported removable prosthodontics. Clinical and in vitro studies have shown that balanced lingualized occlusion can be as effective as classical balanced articulation (Ohguri et al., 1999; Khamis et al., 1988; Sutton and McCord, 2007).



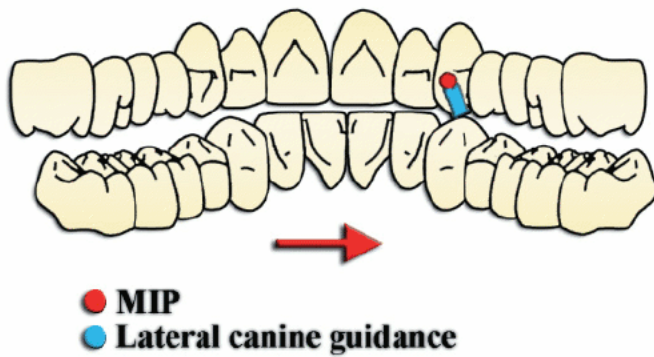
**Figure 5.6.** Group function or unilateral balance.

## OCCLUSAL CONCEPTS FOR CONVENTIONAL FIXED PROSTHODONTICS

With advances in materials and techniques in the 1930s and 1940s, it became possible to rehabilitate a natural dentition with fixed restorations. Early attempts to provide complete-mouth rehabilitation with fixed prosthodontics used occlusal concepts that were established for complete denture prosthodontics; i.e., balanced articulation was prescribed. It is understandable that dentists would attempt to mimic an occlusal scheme that was highly successful for edentulous patients. It was obvious that balanced articulation resulted in dentures that did not loosen; also, with occlusal balance, there appeared to be less bone resorption beneath the dentures. At the time, the cause of periodontal disease was obscure. The term dental plaque did not exist. Many dentists assumed that bone loss around natural teeth was the result of occlusal overload. Balancing the occlusion was assumed to be a method to uniformly distribute the forces of occlusion and avoid occlusal overload.

Developing balanced articulation with dentate patients required very sophisticated instrumentation. An articulator that could precisely mimic eccentric jaw movements (a fully adjustable instrument) was necessary, and much of the efforts of prosthodontists in the 1930s and 1940s were directed toward developing tracing devices and articulators that could transfer a patient's 3D jaw movements to an articulator that could be adjusted to reproduce these movements.

In the late 1950s and early 1960s the concept of developing balanced articulation for fixed prosthodontics was challenged. Two primary philosophical approaches were suggested. Unilateral balance, later referred to as group function, was advocated by Schuyler (1963) (Figure 5.6). Stuart (1964) suggested eliminating all posterior tooth contacts in eccentric positions. This occlusal scheme has been described as mutually protected occlusion because the posterior teeth act as vertical stops (closure stoppers) and prevent excessive



**Figure 5.7.** Mutually protected occlusion with lateral canine guidance.

contact of the anterior teeth in MIP, and the anterior teeth disengage the posterior teeth in eccentric positions to protect the posterior teeth from lateral forces (Figure 5.7). Another term that has been used to describe this occlusal scheme is anterior disclusion (anterior teeth discluding the posterior teeth in eccentric positions). If the canine alone (without involvement of the incisors) discludes the posterior teeth in lateral eccentric positions, the mutually protected occlusal scheme is described as canine disclusion.

### ANTERIOR DISCLUSION (CANINE DISCLUSION) AND GROUP FUNCTION

Throughout the 1960s and 1970s there was considerable controversy concerning the best eccentric occlusal scheme for a fixed prosthodontic oral rehabilitation. Group function was considered optimal by some dentists, primarily periodontists, because empirically it appeared that simultaneous contact of all teeth on the working side in a lateral occlusal position would uniformly distribute forces among all teeth. Nevertheless, most prosthodontists were advocating anterior disclusion or canine disclusion. Some periodontists felt that anterior disclusion or canine disclusion would cause occlusal overload of the anterior teeth, trauma from occlusion, and eventual hypermobility of the anterior teeth; however, prosthodontists were commonly prescribing this occlusal arrangement with good results.

Arguments ensued for at least two decades concerning the optimal eccentric occlusal scheme, but definitive research by Gibbs and Lundeen (1982) shed new light on the physiology of mastication and quelled the arguments. Gibbs and Lundeen reported three distinct adult chewing patterns. They described these as good occlusion, malocclusion, and worn occlusion.

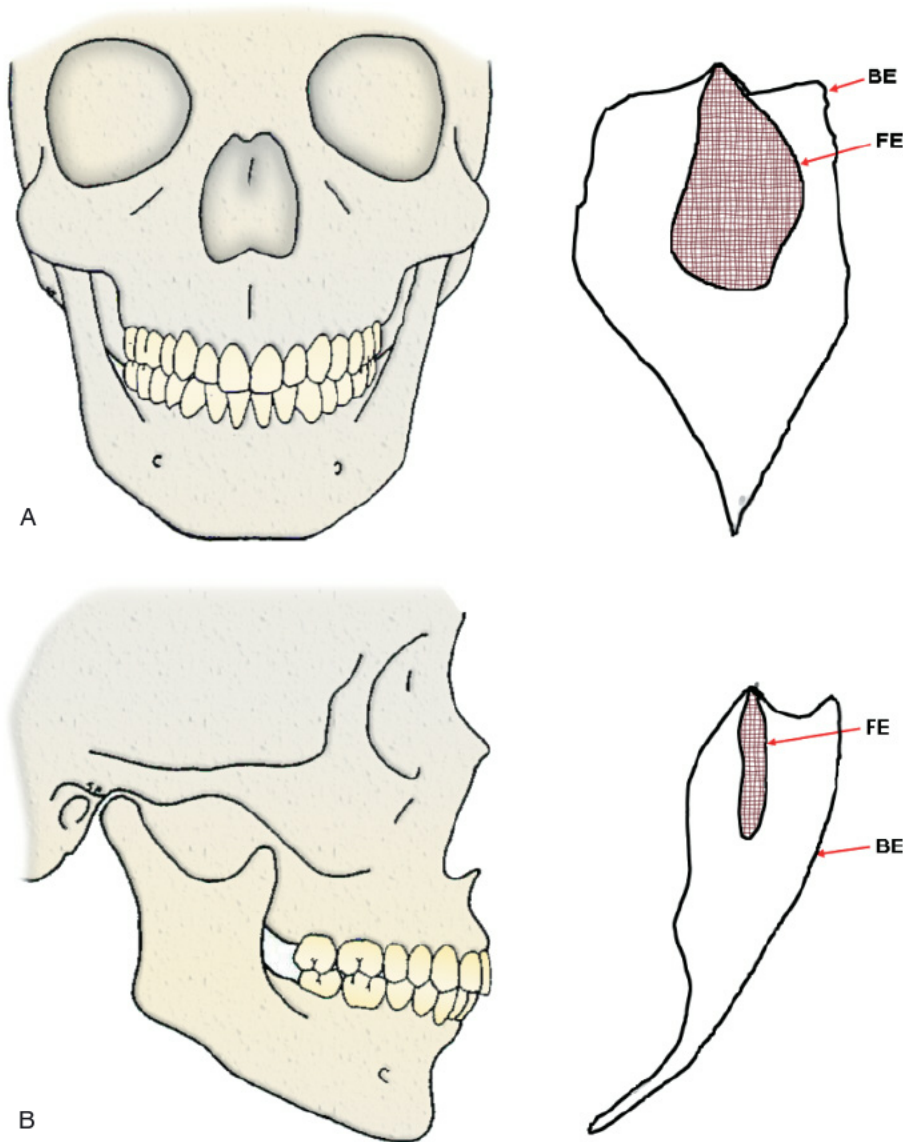
Patients with good occlusion had an arrangement of the dentition whereby the anterior teeth prevented contact of the

posterior teeth in eccentric positions. These patients chewed with smooth, repeatable strokes. During mastication, tooth gliding contacts occurred while the mandible was entering MIP. However, these contacts occurred at the very end of the closing stroke, and they were of short duration and low magnitude when compared with the forces generated in MIP. The investigators tracked the envelope of motion or border envelope (Posselt, 1952) and the envelope of function with superimposed tracings. It was clear from these tracings (Figure 5.8) that the maxillary and mandibular anterior teeth passed very close to each other during mastication, without contacting. It was the tactile sensation and tactile memory, or proprioception (Crum and Loiselle, 1972) of the teeth, as governed by the periodontal ligaments, that appeared to guide the chewing strokes for these patients with good occlusion, always returning to MIP without long gliding contacts on the anterior teeth.

A different chewing stroke was observed with patients whose anterior teeth did not prevent contact of the posterior teeth in eccentric positions. These patients lacked repeatable strokes. Chewing was erratic with long, gliding contacts. This group of patients was designated as having malocclusion.

A third type of chewing stroke was observed in patients with worn occlusal and incisal surfaces. These patients lacked overlap of the anterior teeth and chewed with broad side-to-side strokes. This group was described by the investigators as having a worn occlusion.

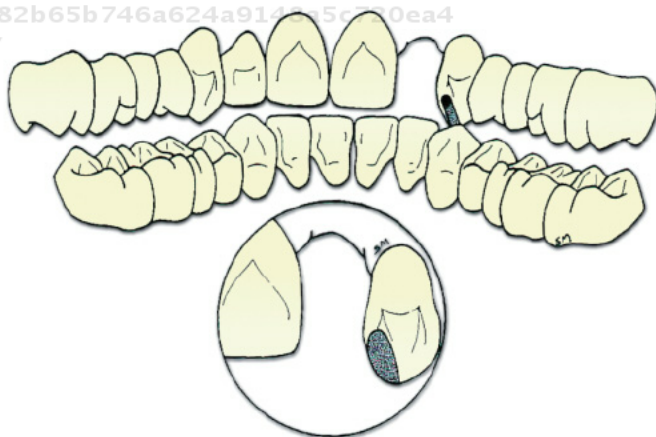
The results of these studies by Gibbs and Lundeen confirmed the desirability of anterior disclusion or canine disclusion for the restoration of a dentition with fixed prosthodontics (Figure 5.9.) The results also refuted the contention that a patient's natural MIP must coincide with centric relation. In Gibbs and Lundeen's studies, patients always returned to the MIP during mastication because of the tactile memory and tactile sensation of the teeth. Therefore, when a patient has a normal, healthy MIP and a functional anterior guidance (vertical and horizontal overlap of the anterior teeth), the dentist should preserve this occlusal relationship when placing several crowns or a short-span fixed partial denture (FPD). If the MIP is dysfunctional and cannot be preserved because it will be destroyed with crown preparations (as with complete-mouth oral rehabilitation), or does not exist (as with a patient edentulous in one or both jaws), centric relation would be the treatment position. It is interesting to note that Gibbs and Lundeen found only a small difference when condylar positions in MIP and centric relation were compared. The mean anterior-posterior difference was 0.13mm and the mean superior-inferior difference was less than 0.5mm. These findings suggest that restoring a dentition by developing an MIP coincidental with CR is physiologically sound



e55ee82b65b746a624a9148a5c720ea4  
ebruary

**Figure 5.8** Superimposition of tracing of the envelope of motion or border envelope (BE) and functional envelope (FE) clearly demonstrated that maxillary and mandibular anterior teeth passed very close to each other during mastication, without contacting. A, frontal view; B, sagittal view.

e55ee82b65b746a624a9148a5c720ea4  
ebruary



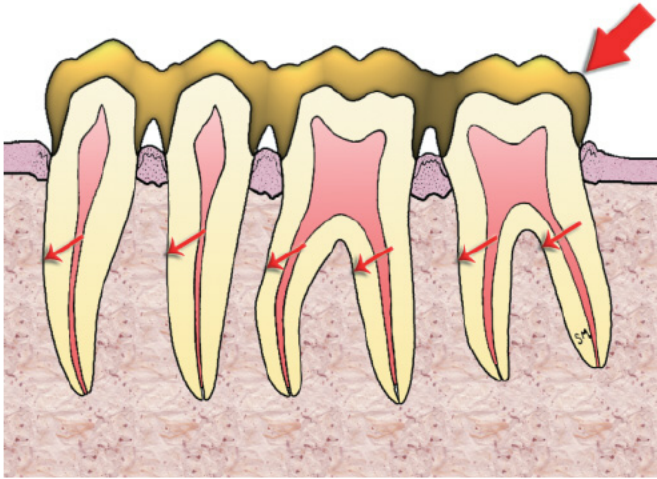
**Figure 5.9.** The patient will receive three-unit fixed partial denture to replace a missing lateral incisor. The canine relationship of natural teeth should be preserved in the final restoration to ensure canine disclusion.

because this position coincides very closely, but not precisely, with the condylar position of a healthy MIP.

### SPLINTING

With further improvements in materials and techniques in the 1960s, it became possible to accurately seat castings that were splinted together. Many prosthodontists would routinely splint crowns in series to protect the natural teeth from trauma from occlusion. Often a complete-mouth rehabilitation would be fabricated as maxillary and mandibular one-piece prostheses, each arch completely splinted together. Splinting of natural teeth is no longer advocated. Splinting makes it more difficult to fabricate the prosthesis. An occlusal interference on one splinted crown will be transmitted to all teeth and the interfering tooth cannot move away from the

interference (Figure 5.10). A problem with one tooth or one crown can jeopardize the prognosis of the entire prosthesis. Complete-arch splinting is especially undesirable in the mandible because of the phenomenon of mandibular flexure (Fischman, 1976) (Figure 5.11). Splinting of implant-supported crowns in series is often advocated and is discussed below.



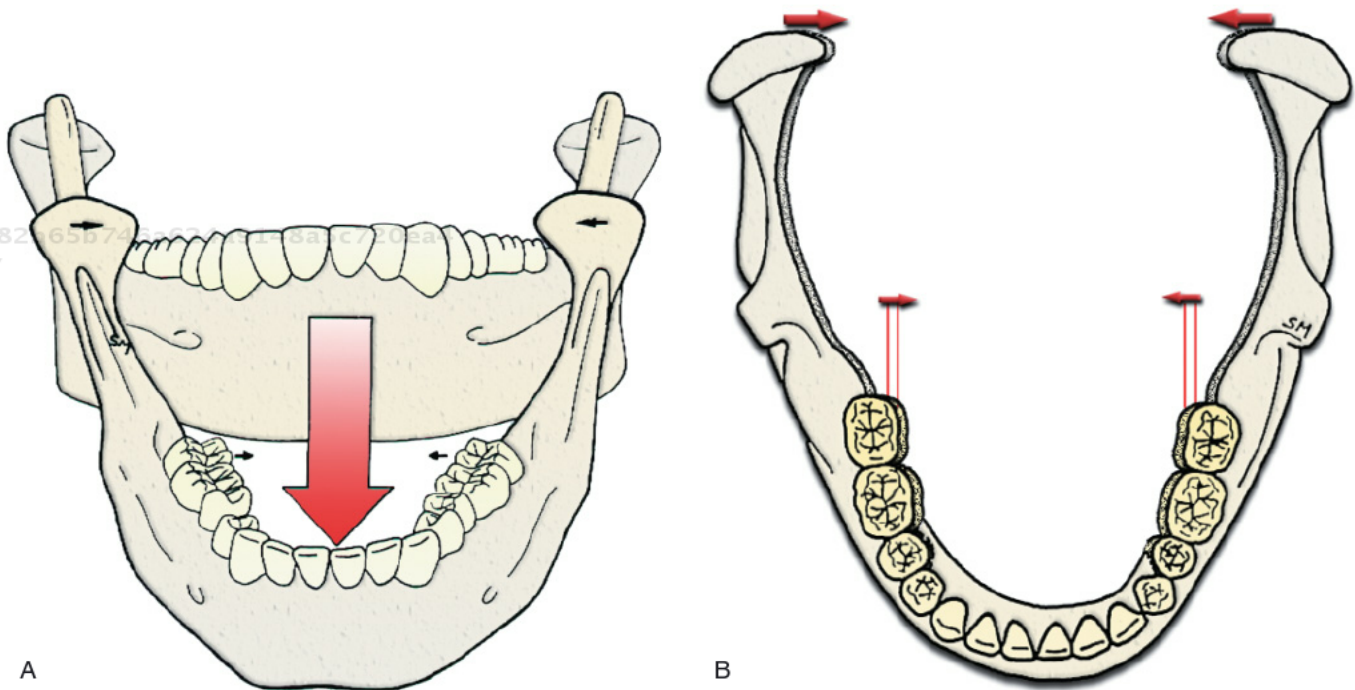
**Figure 5.10.** Occlusal interference on one splinted crown will be transmitted to all teeth and the interfering tooth cannot move away from the interference.

## IMPLANT-SUPPORTED ARTIFICIAL OCCLUSION

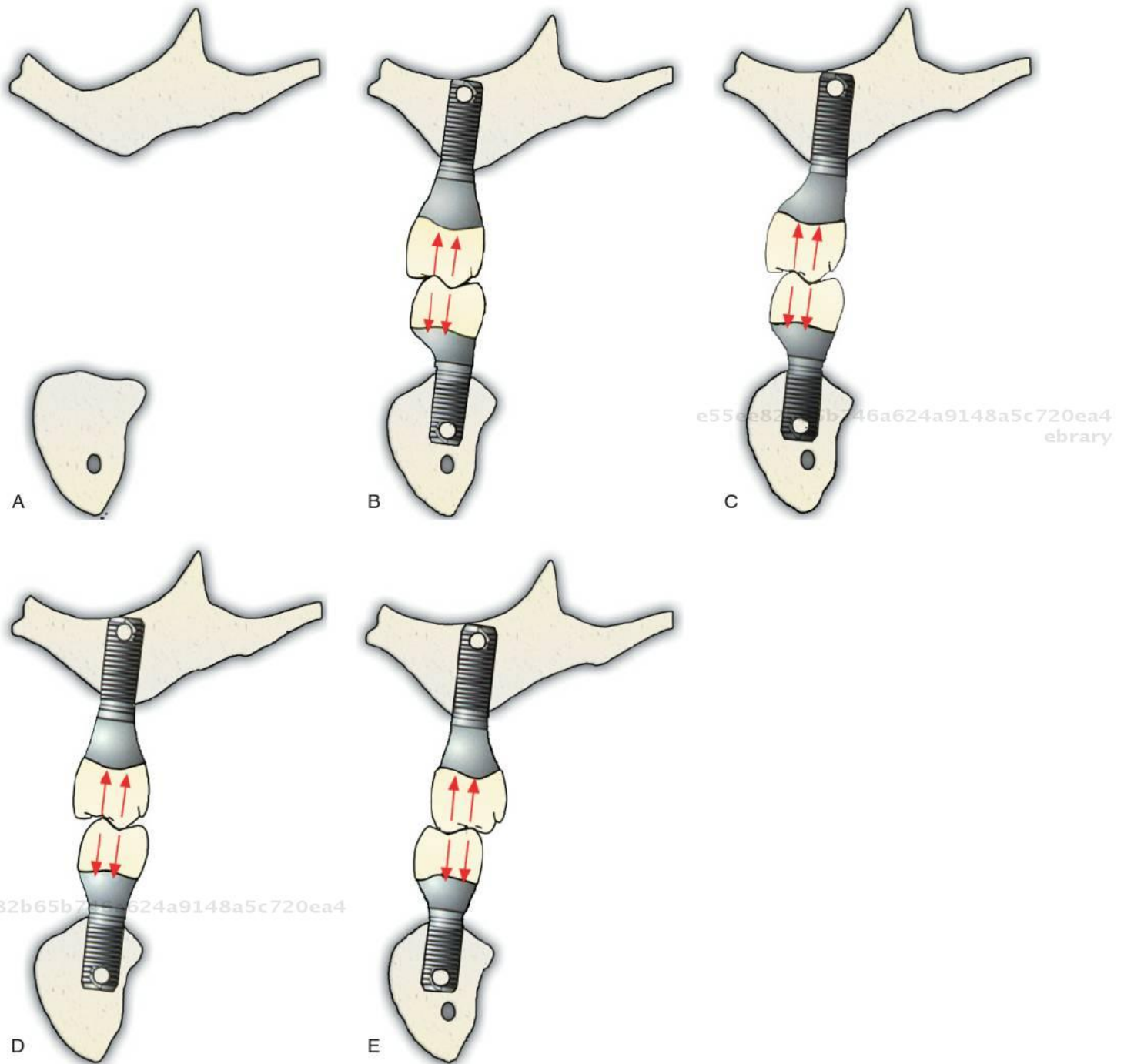
Perceptions of occlusion vary with different dental specialties. Orthodontists are interested in moving teeth to develop an Angle Class I occlusal relationship because the maxillary and mandibular teeth tend to fit together best with this arrangement. Prosthodontists are concerned with fabricating dental prostheses in a laboratory on an articulator, and then delivering the prostheses to restore esthetics, phonetics, and function with favorable biomechanics. Traditionally, periodontists were primarily concerned with controlling trauma from occlusion in the natural dentition; however, the contemporary periodontist devotes a considerable amount of time to surgically placing dental implants. Implant dentistry is planned from the crown down; i.e., the prosthodontist or restorative dentist determines the required location and contour of the planned artificial tooth or teeth with a wax trial arrangement of an artificial tooth or teeth, and the implant is then planned to permit this required position of the tooth or teeth (Figure 5.12). To do this effectively, the periodontist must have more background related to occlusal biomechanics.

### Fixed Implant-supported Restorations

Gibbs and Lundeen's research highlighted the importance of proprioceptive input from the periodontal ligaments for fine motor control of the masticatory stroke. Because osseointe-

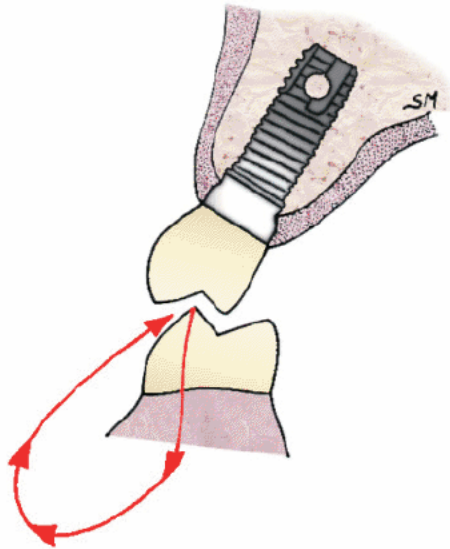


**Figure 5.11.** A, Because of the medial pull of the lateral pterygoid muscles, with maximal opening, the condyles are pulled medially. B, The result is flexure of the mandible and contraction of the mandibular arch. Splinting teeth from last molar to last molar in the mandible can create unfavorable stresses.



**Figure 5.12.** A, Resorbed maxillary and mandibular edentulous ridges. It is impossible to accurately place implants without prosthetic planning. B, Forces on the maxillary crown are compressive (favorable), but unfavorable torquing forces exist with the mandibular crown. C, Improved force distribution. D, Optimal force distribution. E, Sometimes optimal forces require a cross-bite occlusal relationship due to the pattern of bone resorption.

grated implants lack a periodontal ligament, the sensation generated from occlusal contacts is completely different from the sensation experienced with natural teeth (Figure 5.13). A clinical study by Jacobs and van Steenberghe (1993) on passive tactile sensation of natural teeth and implant-supported prostheses reported a threshold that is 50 times greater with implant-supported prostheses when compared with natural teeth. This marked difference in sensation suggests that a patient could easily, and without awareness, overload an implant-supported restoration.



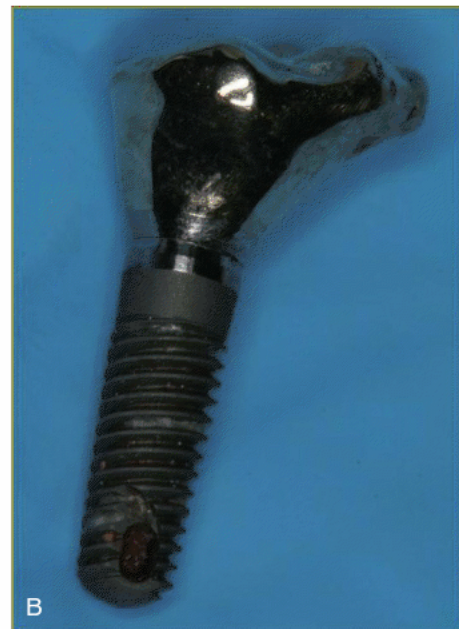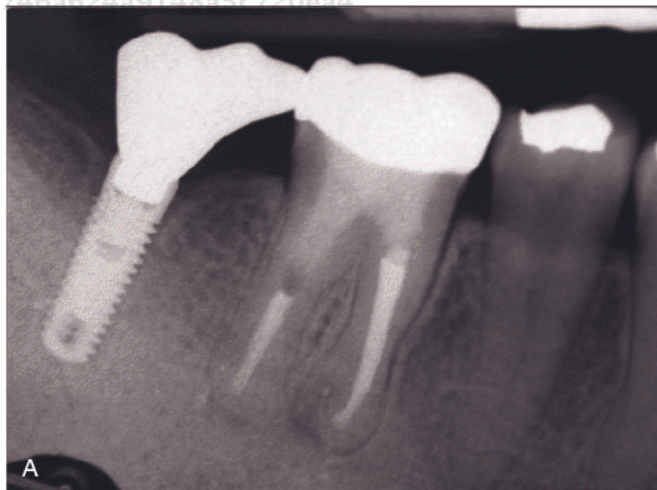
**Figure 5.13.** Fine motor control of the envelope of function depends on tactile sensation and tactile memory from receptors within periodontal ligaments of teeth; however, osseointegrated implants lack a periodontal ligament.

Careful control of biomechanics is essential to the long-term serviceability of implant-supported fixed prostheses. Poor placement can lead to biomechanical overload, which can manifest itself as chronic screw loosening, screw fracture, implant fracture, or loss of osseointegration (Figure 5.14). A retrospective study by Eckert et al. (2000) of fractured implants reported that screw loosening preceded implant fracture for the majority of the implants, suggesting that screw loosening can be a sign of occlusal overload.

When a single missing tooth is replaced with an implant-supported crown, the differences in displaceability of the natural teeth and single implant must be considered. The tooth can be displaced within its socket, but the implant is, for all practical purposes, non-displaceable (Figure 5.15). When the patient occludes lightly on a single implant-supported crown, shim stock (a Mylar strip, 8  $\mu$ m in thickness) should easily pass through the occlusal surfaces of the implant-supported crown and opposing natural tooth. When the patient occludes with heavy force, the implant-supported crown should not hold the shim stock any tighter than the adjacent teeth hold a shim stock (Figure 5.16).

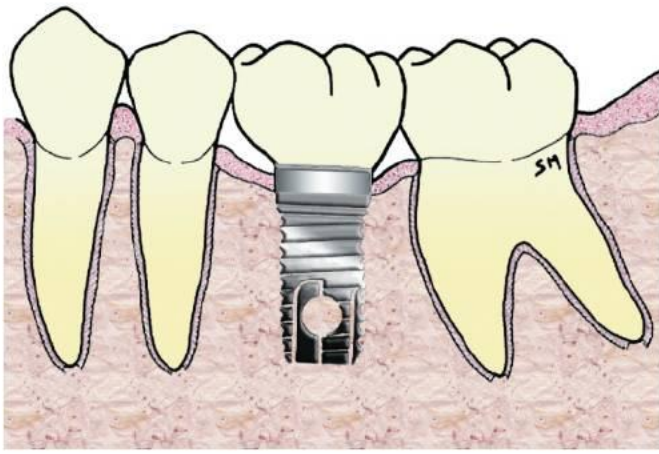
The method of implant support will also influence the biomechanics. A finite element analysis (Morgano and Geramy, 2004) of a mandibular single molar supported by a 3.75-mm diameter implant, a 5-mm diameter implant, and two implants reported a reduction of approximately 50% in micro-motion of the crown with the 5-mm diameter implant and the double implant support (Figure 5.17). Micro-motion is an important

e55ee82b65b746a624a9148a5c720ea4  
ebruary

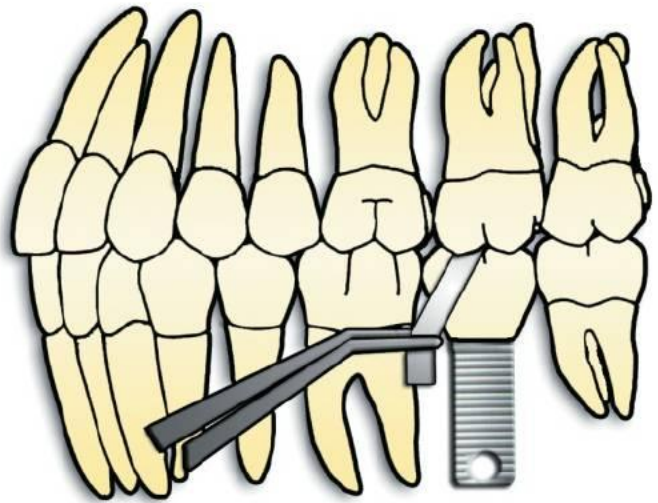


**Figure 5.14.** A, The implant was placed too far distally, resulting in an artificial crown with poor biomechanics. B, The result was loss of osseointegration.

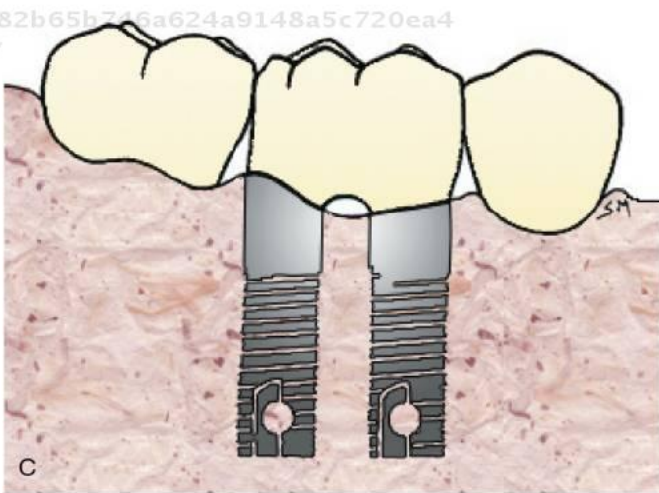
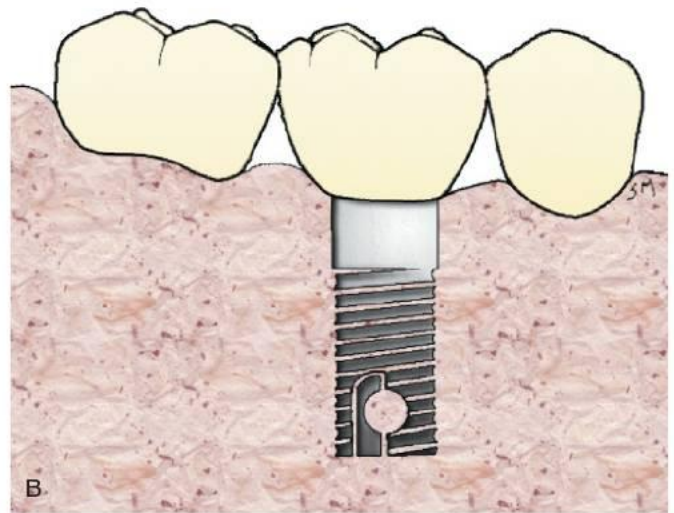
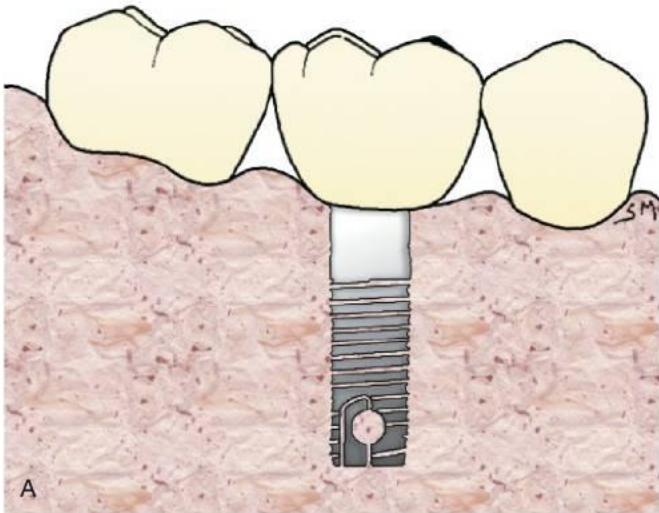




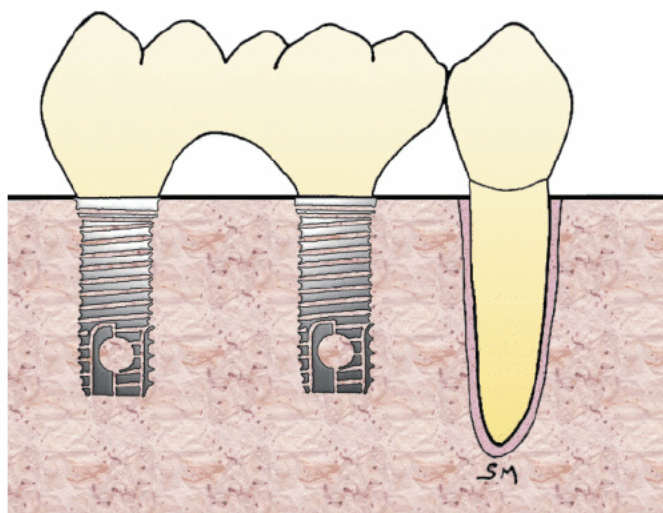
**Figure 5.15.** Differences in displaceability of natural teeth, which are surrounded by periodontal ligaments, and a single implant must be considered when adjusting occlusion.



**Figure 5.16.** A shim stock is used to adjust occlusion. e55ee82b65b746a624a9148a5c720ea4 ebrary



**Figure 5.17.** A finite element analysis by Morgano and Geramy (2004) of a mandibular single molar supported by A, a 3.75-mm diameter implant, B, a 5-mm diameter implant, and C, two implants reported approximately 50% reduction in micromotion of the crown with the 5-mm diameter implant and the double implant design.



**Figure 5.18.** In vitro evidence suggests that splinting implants together can distribute forces more uniformly and improve biomechanics.

consideration in implant prosthodontics because it has been reported to produce various clinical problems for implant-supported crowns, including soft tissue complications (Dixon et al., 1995), bone loss (Hermann et al., 2001), and mechanical problems, such as fracture and loosening of screws (Gratton, 2001). A strain gauge study (Seong et al., 2000) with a similar design to the study by Morgano and Geramy reported similar results. Also, when implants are in a series, splinting them together helps distribute forces more uniformly and improve the biomechanics (Guichet et al., 2002) (Figure 5.18).

### **Implant-supported Removable Prosthodontics (Overdentures)**

The application of osseointegrated implants to support and retain complete dentures has the potential to improve the quality of life for totally edentulous patients (Awad et al., 2003). However, it is important to appreciate that implant-supported restorations are not trouble free (Goodacre et al., 2003). One important consideration is occlusal stability (Kohavi, 1993). The acrylic resin teeth commonly used with conventional complete dentures tend to wear rapidly with implant-supported overdentures because of the amount of force the patient can generate. The use of porcelain artificial teeth or custom metal occlusal surfaces should be seriously considered, especially for patients with strong musculature.

With implant-supported overdentures, classical balanced articulation or balanced lingualized occlusion should be used to ensure favorable force distribution and masticatory efficiency. Lingualized occlusion has become very popular with implant-supported overdentures because of the improved lever balance. Lever balance was first described by Ortman

(1977), and relates to directing the forces of occlusion over the supporting area of a complete denture, thus reducing unfavorable leverage. Because the maxillary palatal cusp is the only intercusating cusp with lingualized occlusion, it is easier to centralize forces over the supporting implants with lingualized occlusion.

## **ARTICULATORS**

An articulator, which has several functions, is used when restoring a dentition. An articulator must serve as a holding instrument for the maxillary and mandibular casts and ensure a positive centric lock. It is desirable for an articulator to accept a face-bow to transfer the patient's opening and closing axis to the instrument. Adjustable condylar guidances are also important features.

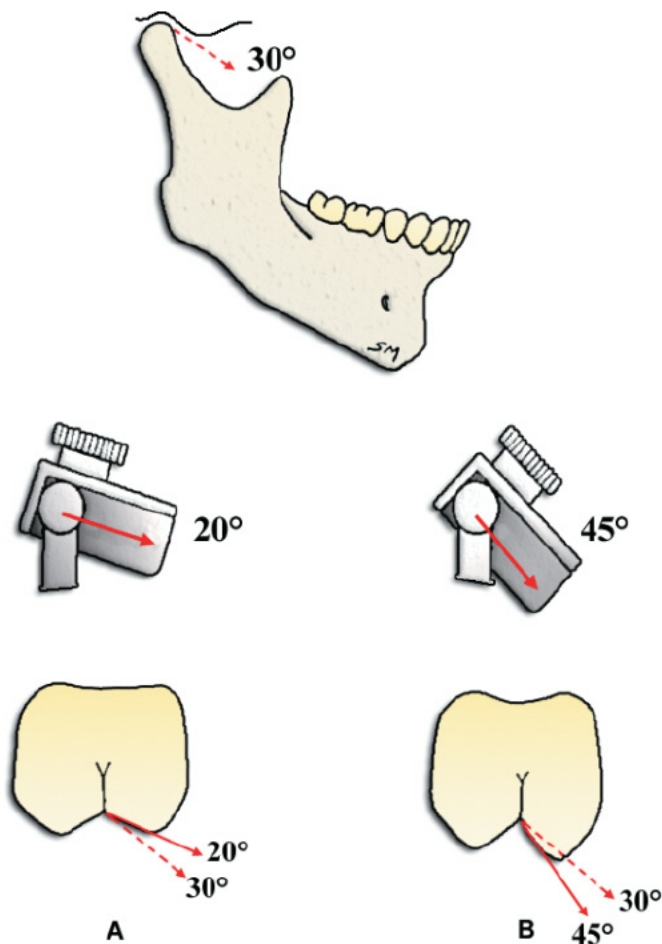
### **Rehabilitation with Fixed Prosthodontics**

Mutually protected occlusion is commonly prescribed when rehabilitating a dentition with conventional fixed prosthodontics. Because the goal of mutually protected occlusion is the disclusion of all posterior teeth in eccentric positions, this type of occlusal scheme can be achieved with the use of a semi-adjustable articulator (Lundeen, 1979). A semi-adjustable articulator can be programmed for positive or negative error. If an eccentric tooth contact on the articulator is an interference in the mouth, it is described as positive error. If an eccentric tooth contact on the articulator discludes in the mouth, it is negative error (Figure 5.19).

Setting the horizontal condylar guidance below the normal range found in clinical studies will result in negative error in protrusion and in a non-working (mediotrusive) movement because the separation of the posterior teeth on the articulator will be less than the separation that occurs in the mouth. Therefore, if the posterior teeth disclude in protrusion and non-working movements in the articulator, they will disclude by more in the mouth.

With a working-side movement, the setting of the Bennett angle (angle of the progressive side shift) on the articulator can be used to produce negative error. The amount of progressive lateral movement is determined by the Bennett angle (the wider the Bennett angle, the greater the progressive lateral movement). Therefore, setting the Bennett angle on the articulator wider than what has been reported in clinical studies will allow the articulator to move laterally a greater amount than can occur in the mouth. As a consequence, posterior teeth on the working side will disclude in the mouth with a separation greater than what occurred on the articulator.

The range of the protrusive angle has been reported as 25 degrees to 65 degrees, and the Bennett angle has been




**Figure 5.19.** An articulator can be programmed for negative or positive error. A patient's natural condylar guidance is 30 degrees (dotted line). A, The articulator has been set with a 20-degree condylar inclination. What contacted on the articulator (solid line) missed in mouth (dotted line)—negative error. B, The articulator has been set with a 45-degree condylar inclination. What contacted on the articulator (solid line) became interference in the mouth (dotted line)—positive error.

reported as 7 degrees to 8 degrees (Lundeen and Wirth, 1973; Lundeen, 1979). If a semi-adjustable articulator is set with a protrusive angle of 20 degrees and a Bennett angle of 15 degrees, it will be programmed for negative error (Figure 5.20).

**Rehabilitation with Complete Dentures**

With complete denture prosthodontics, balanced articulation is desired, whereby the posterior teeth contact simultaneously in the right and left lateral occlusal positions and in protrusion. Harmonious eccentric occlusal contacts firmly seat the denture(s) and distribute the occlusal load, promoting denture stability and masticatory efficiency (Figure 5.21). Because posterior eccentric contacts are desirable, the



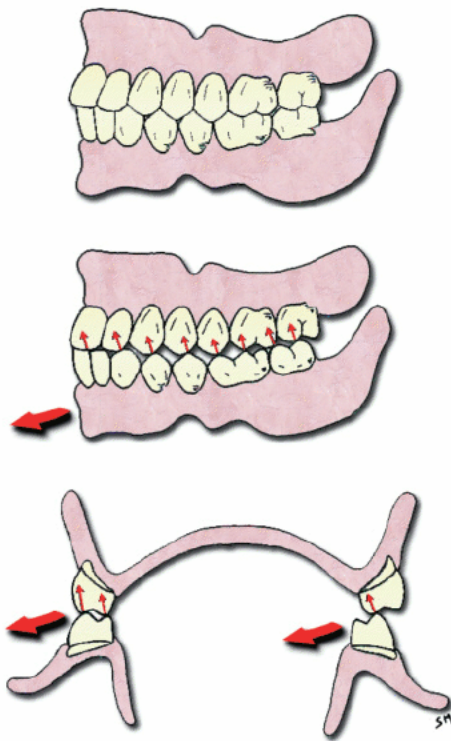
**Figure 5.20.** If a semi-adjustable articulator is set with A, a protrusive angle of 20 degrees and B, a Bennett angle of 15 degrees, it will be programmed for negative error, ensuring anterior disclusion.

concept of negative error cannot be used. A protrusive record is made to set the protrusive angle on the articulator. Lateral check records can be made to set the Bennett angles; however, the variability in the Bennett angles of edentulous patients is very small. Langer and Michman (1970) reported that the Bennett angle for edentulous patients was approximately twice the values reported for dentate patients  $\pm 2$  degrees. Therefore, commonly, the Bennett angle is set arbitrarily at 15 degrees for edentulous patients.

**AUTHORS' VIEWS/COMMENTS**

Early principles of occlusion were empiric concepts designed for complete dentures that were almost entirely mechanical. Centric relation was used as the treatment position for the MIP of the dentures, and the occlusion was designed with eccentric balance. This balanced arrangement of the teeth was used to promote denture stability and uniformly distribute forces. Dentists learned that a single interceptive occlusal contact could disturb the position of the denture bases on the mucosa, thus promoting instability, poor retention, tissue

Dibart, Serge. Practical Periodontal Diagnosis and Treatment Planning. : Wiley-Blackwell, . p 75 <http://site.ebrary.com/id/10341824?ppg=75> Copyright © Wiley-Blackwell. . All rights reserved. May not be reproduced in any form without permission from the publisher, except fair uses permitted under U.S. or applicable copyright law.

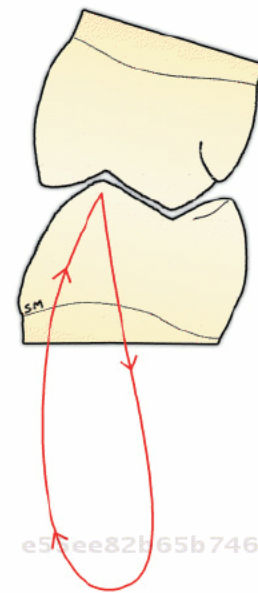


**Figure 5.21.** Balanced articulation firmly seats the dentures and distributes the occlusal load, promoting denture stability and masticatory efficiency.

trauma, soreness, and accelerated bone resorption. Several clinical studies have reported improved performance with complete dentures when classical balanced articulation or lingualized occlusion was used.

Attempts to apply this mechanical approach to complete mouth rehabilitation with fixed prosthodontics were unsuccessful. The concepts of occlusion for fixed prosthodontics gradually moved from a mechanical approach to a biomechanical approach. Current scientific knowledge suggests that mutually protected occlusion is a biomechanically sound approach to designing the occlusal scheme for a fixed prosthodontic rehabilitation. With a complete-mouth rehabilitation, the MIP will be destroyed because of the tooth preparations, so the treatment position for the newly created MIP would be centric relation.

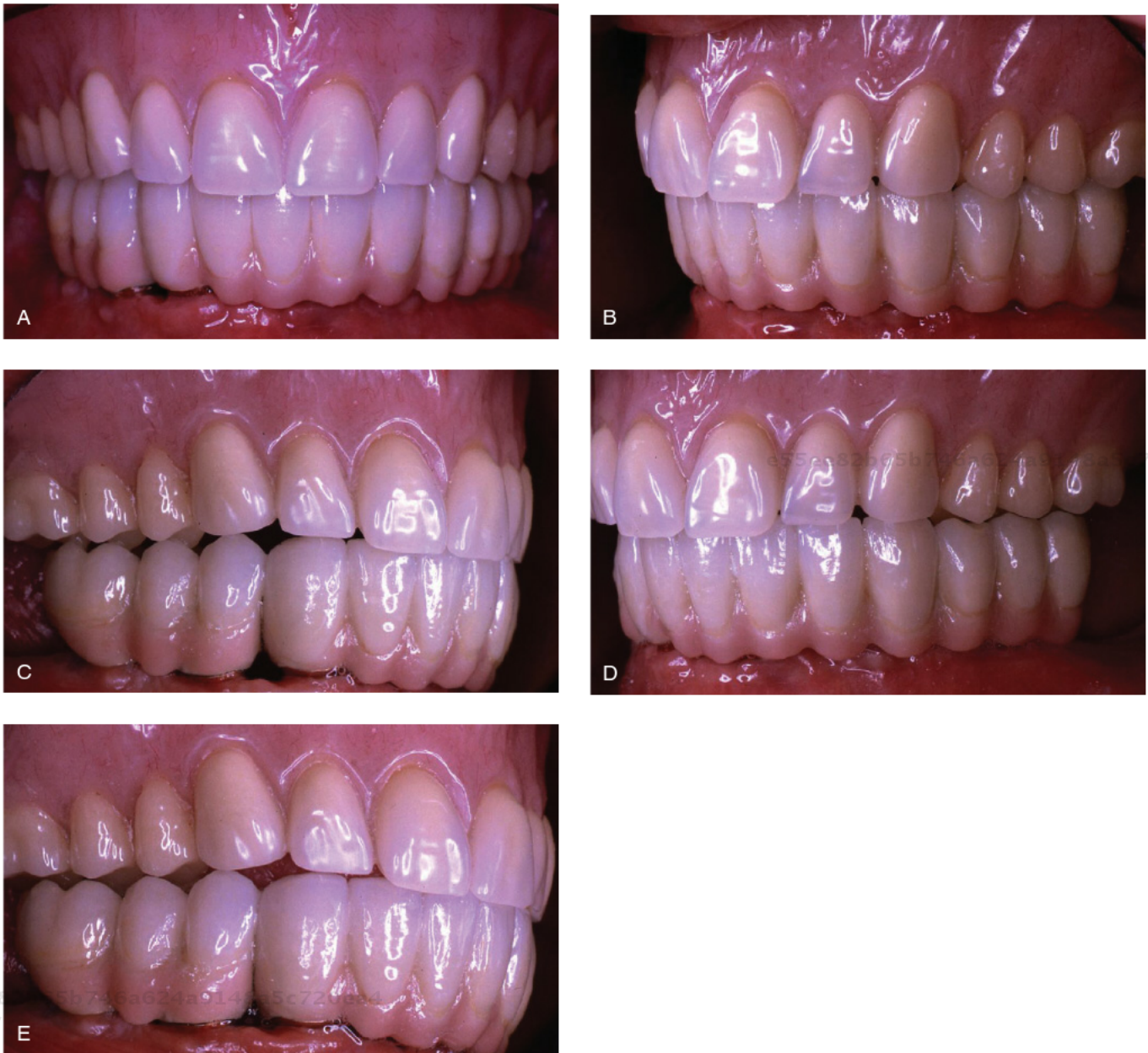There is no evidence to suggest that a stable, healthy MIP that does not coincide with centric relation should be altered. Most patients have a slight discrepancy between the condylar positions when the condyle is in centric relation and when the teeth are in MIP. Simple restorations that involve a few teeth should be made to harmonize with the existing MIP.



**Figure 5.22.** Relatively steep overlap of the anterior teeth (anterior guidance) produces a vertical chewing stroke, protecting posterior teeth from lateral forces.

The masticatory function of natural teeth depends on feedback from the receptors in the periodontal ligaments of the teeth. Because implants are not surrounded by periodontal ligaments, the sensation from implants is different from that of natural teeth. The dentist must be cognizant of this difference in the sensation when designing the occlusal scheme for implants. Steep vertical overlap of natural anterior teeth is considered desirable because the receptors in the periodontal ligaments of the anterior teeth will guide the mandible through the 3D space with a relatively vertical chewing stroke. This vertical stroke helps to protect the posterior teeth from lateral forces (mutually protected occlusion) (Figure 5.22). Because implant-supported anterior crowns lack periodontal ligaments, the sensation is also lacking. Steep anterior vertical overlap is likely to cause chipping of porcelain. An implant-supported fixed rehabilitation should be developed with very shallow anterior guidance, shallow cusps, and narrowed occlusal tables (for improved lever balance). Group function occlusion is also an option. A functionally generated path recording can be used to develop group function with the use of a semi-adjustable articulator (Meyer, 1959).

The occlusion for implant-supported overdentures should mimic the occlusion for conventional complete dentures—either classic balanced articulation or balanced lingualized occlusion. Special attention should be directed toward ensuring occlusal stability by preventing excessive wear of the occlusal surfaces of the posterior teeth (Figure 5.23).



**Figure 5.23.** Maxillary implant-supported overdenture that occludes with mandibular implant-supported fixed prostheses. Lingualized occlusion has been used, with porcelain posterior artificial teeth in overdenture and porcelain occlusal surfaces on mandibular metal-ceramic fixed partial dentures. A and B, MIP; C, right nonworking; D, left working (note the lack of contact of buccal cusps); E, protrusion. Courtesy of Dr. Dmitri Svirsky, Toronto, Ontario, Canada.

## REFERENCES

- Academy of Prosthodontics. 1987. Glossary of Prosthodontic Terms. 5th ed. *J. Prosthet. Dent.* 58, 725.
- Awad MA, Lund JP, Shapiro SH, Locker D, Klemetti E, Chehade A, Savard A, Feine JS. 2003. Oral health status and treatment satisfaction with mandibular implant overdentures and conventional dentures: a randomized clinical trial in a senior population. *Int. J. Prosthodont.* 16, 390-6.

- Crum RJ, Loisel RJ. 1972. Oral perception and proprioception: A review of the literature and its significance to prosthodontics. *J. Prosthet. Dent.* 28, 215-30.
- Dixon DL, Breeding LC, Sadler JP, McKay ML. 1995. Comparison of screw loosening, rotation, and deflection among three implant designs. *J. Prosthet. Dent.* 74, 270-8.
- Eckert SE, Meraw SJ, Cal E, Ow RK. 2000. Analysis of incidence and associated factors with fractured implants: a retrospective study. *Int. J. Oral Maxillofac. Implants.* 15, 662-7.

- Fischman BM. 1976. The influence of fixed splints on mandibular flexure. *J. Prosthet. Dent.* 35, 643–7.
- Gibbs CH, Lundeen HL. 1982. Jaw movements and forces during chewing and swallowing and their clinical significance. In Gibbs CH, Lundeen HL. eds. *Advances in Occlusion*. John Wright PSG, Inc., Boston. pp. 2–50.
- Goodacre CJ, Guillermo B, Rungcharassaeng K, Kan JYK. 2003. Clinical complications with implants and implant prostheses. *J. Prosthet. Dent.* 90, 121–32.
- Goymerac B, Woolard G. 2004. Focal infection: a new perspective on an old theory. *Gen. Dent.* 52, 357–61.
- Gratton DG, Aquilino SA, Stanford CM. 2001. Micro-motion and dynamic fatigue properties of the dental-implant interface. *J. Prosthet. Dent.* 85, 47–52.
- Guichet DL, Yoshinobu D, Caputo AA. 2002. Effect of splinting and interproximal contact tightness on load transfer by implant restorations. *J. Prosthet. Dent.* 87, 528–35.
- Hanau RH. 1929. Occlusal changes in centric relation. *J. Am. Dent. Assoc.* 16, 1903–15.
- Hermann JS, Schoolfield JD, Schenk RK, Buser D, Cochran DL. 2001. Influence of the size of the microgap on crestal bone changes around titanium implants. A histometric evaluation of unloaded non-submerged implants in the canine mandible. *J. Periodontol.* 72, 1372–83.
- Jacobs R, van Steenberghe D. 1993. Comparison between implant-supported prostheses and teeth regarding passive threshold level. *Int. J. Oral Maxillofac. Implants.* 8, 549–54.
- Khamis MM, Zaki HS, Rudy TE. 1998. A comparison of the effect of different occlusal forms in mandibular implant overdentures. *J. Prosthet. Dent.* 79, 422–9.
- Kohavi D. 1993. Complications in the tissue integrated prostheses components: clinical and mechanical evaluation. *J. Oral. Rehabil.* 20, 413–22.
- Langer A, Michman J. 1970. Evaluation of lateral tracings of edentulous subjects. *J. Prosthet. Dent.* 23, 381–6.
- Lundeen HC, Wirth CG. 1973. Condylar movement patterns engraved in plastic blocks. *J. Prosthet. Dent.* 30, 866–75.
- Lundeen HC. 1979. Mandibular movement recordings and articulator adjustments simplified. *Dent. Clin. North Am.* 23, 231–41.
- McDevitt WE, Brady AP, Stack JP, Hobdell MH. 1995. A magnetic resonance imaging study of centric maxillomandibular relation. *Int. J. Prosthodont.* 8, 377–91.
- Meyer FS. 1959. The generated path technique in reconstruction dentistry. Part II. Fixed partial dentures. *J. Prosthet. Dent.* 9, 432–40.
- Morgano SM, Geramy A. 2004. Finite element analysis of three designs of an implant-supported molar crown. *J. Prosthet. Dent.* 92, 434–40.
- Niswonger MF. 1934. The rest position of the mandible and centric relation. *J. Am. Dent. Assoc.* 21, 1572–82.
- Ohguri T, Kawano F, Ichikawa T, Matsumoto N. 1999. Influence of occlusal scheme on the pressure distribution under a complete denture. *Int. J. Prosthodont.* 12, 353–8.
- Ortman HR. 1977. Complete denture occlusion. *Dent. Clin. North Am.* 21, 299–320.
- Payne SH. 1941. A posterior set-up to meet individual requirements. *Dent. Digest.* 47, 20–2.
- Posselt U. 1952. Studies in the mobility of the human mandible, *Acta Odont. Scandinav.* 10, 19–160, Suppl. 10.
- Pound E. 1970. Utilizing speech to simplify a personalized denture service. *J. Prosthet. Dent.* 24, 586–600.
- Schuyler CH. 1963. The function and importance of incisal guidance in oral rehabilitation. *J. Prosthet. Dent.* 13, 1011–29.
- Seong WJ, Koriath TW, Hodges JS. 2000. Experimentally induced abutment strains in three types of single-molar implant restorations. *J. Prosthet. Dent.* 84, 318–26.
- Stuart CE. 1964. Good occlusion for natural teeth. *J. Prosthet. Dent.* 14, 716–724.
- Sutton AF, McCord JF. 2007. A randomized clinical trial comparing anatomic, lingualized, and zero-degree posterior occlusal forms for complete dentures. *J. Prosthet. Dent.* 97, 292–8.
- Thompson JR. 1946. The rest position of the mandible and its significance to dental science. *J. Am. Dent. Assoc.* 33, 151–80.