

HISTOLOGY

Physiotherapists

Tissues

Epithelial tissue

Connective tissue

 Connective tissue proper

 Cartilage

 Bone

Muscle tissue

Nervous tissue

Blood

Cardiovascular system

EPITHELIAL TISSUE (EPITHELIUM)

General characteristics of epithelium

- is avascular tissue (without blood supply – cells receive nourishment by diffusion from a highly vascular loose connective tissue just below the basement membrane called the **lamina propria**)
- is highly cellular tissue – cells are arranged to form layer(s) or groups of cells highly adhering together and with minimum of extracellular matrix
- epithelium displays a free surface – usually luminal surface (turned to the lumen of hollow organs)
- opposite (basal) surface adheres to extracellular **basement membrane** or **lamina basalis**
- epithelial cells display polarity – apical (luminal), lateral and basal surfaces with structural specialization
- epithelial cells are specialised for absorption, secretion or to act as barrier
- lateral surfaces display junctional complexes for intercellular adhesion and communication

One type of epithelium may change into another type – **metaplasia** (*examples: pseudostratified ep. of respiratory passages transforms into stratified squamous ep. on the surface of epiglottis and soft palate*)

Membrane specializations of epithelia

Lateral surface

Specialised structures are present in epithelia which link individual cells together. Two main adhesion types are distinguished:

1. Cell membrane proteins acting as specialised cell adhesion molecules (CAMs) fo
2. Specialised areas of the cell membrane incorporated into cell junctions.

Three types are recognized: occluding junctions, anchoring or adherence junctions and communicating junctions.

- Occluding junctions bind cell together to form an impermeable barrier
 - **Zonula occludens** or tight junction
- Anchoring junctions link the cytoskeleton of cells to each other and two underlying tissues
 - **Zonula adherens** provides mechanical strength
 - Macula adherens or **desmosomes** provides mechanical strength in tissues where there are tensile or shearing stresses, eg skin
- Communications junctions allow direct cell-cell communication
 - Gap junction or **nexus** allow rapid communication for coordinated action

Luminal (free, apical) surface

- **Microvilli** – short finger-like projection of the cell membrane to increased surface area (regularly arranged microvilli in intestines – **striated border**, in kidney tubules – **brush border**)
- **Cilia** – hair-like surface projections of cells involved in transport
- Glycocalyx – thin extracellular layer consisting of protein glycoprotein and sugar residues; stains PAS positive; can act as enzyme, CAM or for cell recognition

Basal surface

Basal invaginations or folds – greatly enhance surface area; folded membrane with ions pumps + mitochondria form **basal labyrinth** in kidney tubules.


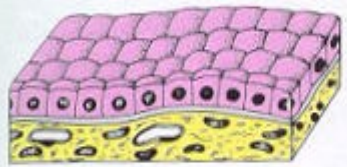
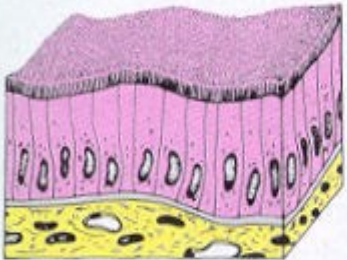
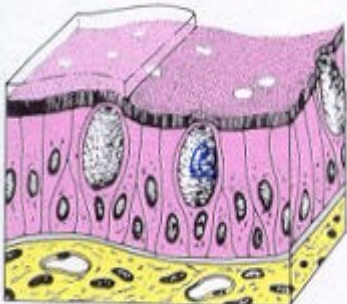
Epithelial tissues are physically separated from underlying connective tissues by a **basement membrane** or **basal lamina**. The portion of an epithelial cell attached to the basement membrane is called its basal surface. The opposite side - facing the external environment, or lumen of a body cavity, is its apical surface. Basement membranes are composed of a special type of collagen and a substance called laminin (see below). The basement membrane helps epithelial cells orient themselves in relation to other tissues. After epithelial injury (e.g., an abrasion), the basement membrane serves as a scaffolding upon which new cells attach themselves during healing.

Cassification of epithelia

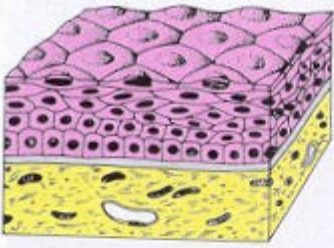
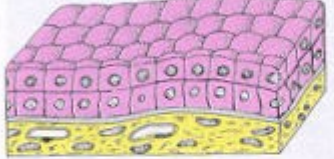
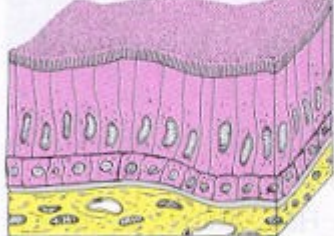
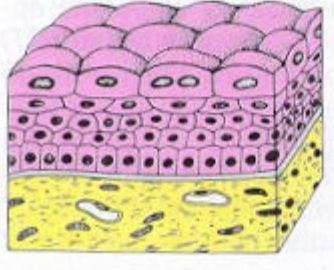
I. surface epithelium – is 1 or more layers of cells arranged into sheet;

	According to number of layers	According to shape of cells in the outermost layer
SURFACE EPITHELIUM	⇒ simple layerd	– squamous
		– cuboid
		– columnar
		– pseudostratified columnar
	⇒ stratified	– squamous non-cornified (non-keratinized)
		– squamous cornified (keratinized)
		– columnar
		– transitional

SIMPLE EPITHELIA – only 1 (single) layer on basement membrane

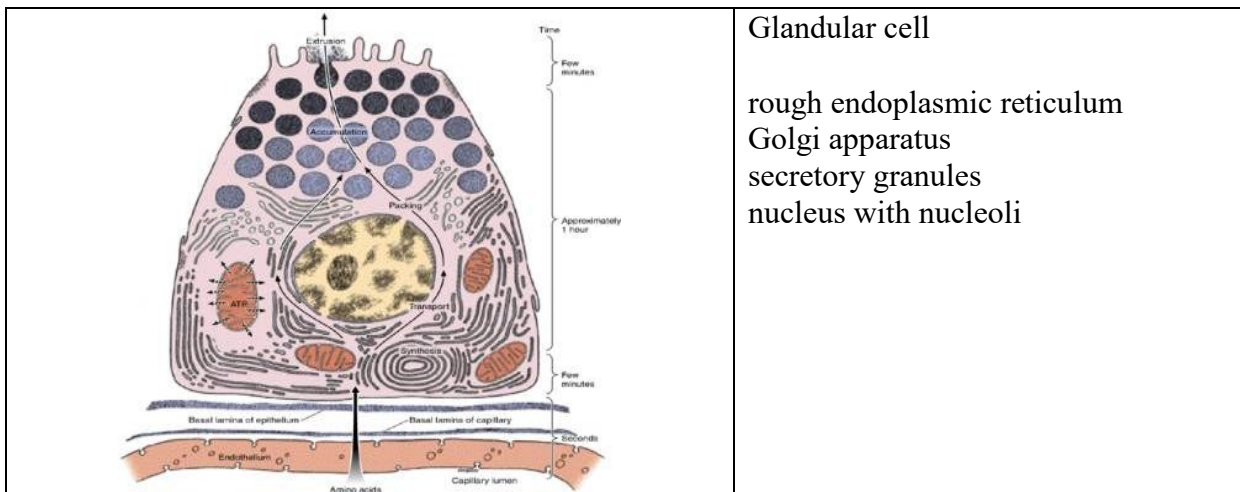
	Simple squamous	<p><u>Squamous</u> – single layer of flattened thin cells with little cytoplasm and prominent nucleus. (In the smallest tubules and ducts of different organs, Henle’s loop or Bowman’s capsule in kidney)</p>
	Simple cuboidal	<p><u>Endothelium</u> – squamous epithelium in cardiovascular system. <u>Mesothelium</u> - squamous epithelium of mesodermal origin lining serous membranes and cavities.</p>
	Simple columnar	<p><u>Cuboidal</u> - cell height, width and depth are the same, round centrally placed nucleus. (In renal tubules and small glandular ducts)</p>
	Pseudostratified	<p><u>Columnar</u> - cell height greater than width, nucleus elliptical or cigar shaped. (In the intestines, in the oviduct)</p> <p><u>Pseudostratified</u> – single layer but nuclei situated at <u>different levels in the cell</u>. <u>All cells are in contact with the basement membrane</u>, but not all cells reach the apical surface. Both conditions create the illusion of several cell layers. (In the respiratory passages – nasal cavity, larynx, trachea, bronchi)</p>

STRATIFIED EPITHELIUM – consists of basal layer on basement membrane, several layers of polyhedral cells and surface layer. According to the shape of cells in this layer the epithelium is named (squamous, columnar, transitional)

 <p>Stratified squamous</p>	<p><u>Stratified squamous</u> – resiting to mechanical influences (press) – non-keratinised (mouth cavity, vocal cords, vagina, anus) – keratinised (epidermis of the skin) – the cells are released continously from the surface</p>
 <p>Stratified cuboidal</p>	<p>Is not described in human organism</p>
 <p>Stratified columnar</p>	<p><u>Stratified columnar</u> – 2 or more layers of cells, columnar cells form the upper layer (two-layered in ductus epididymis and ductus deferens, more-layered male urethra, conjunctive)</p>
 <p>Transitional</p>	<p><u>Transitional</u> - stratified, top layer dome or umbrella shaped. (only in some urinary passages – renal pelvis, ureter and urinary bladder). Epithelium change the shape of cells and number of layers according to wall conditions of urinary passages – distansion or contraction.</p>

Epithelia with special functions:
 resorptive, sensory, respiratory, myoepithelial cells

II. glandular epithelium – multicellular epithelial structures that specialize in synthesizing and secreting complex molecules.



Glandular cell

rough endoplasmic reticulum
Golgi apparatus
secretory granules
nucleus with nucleoli

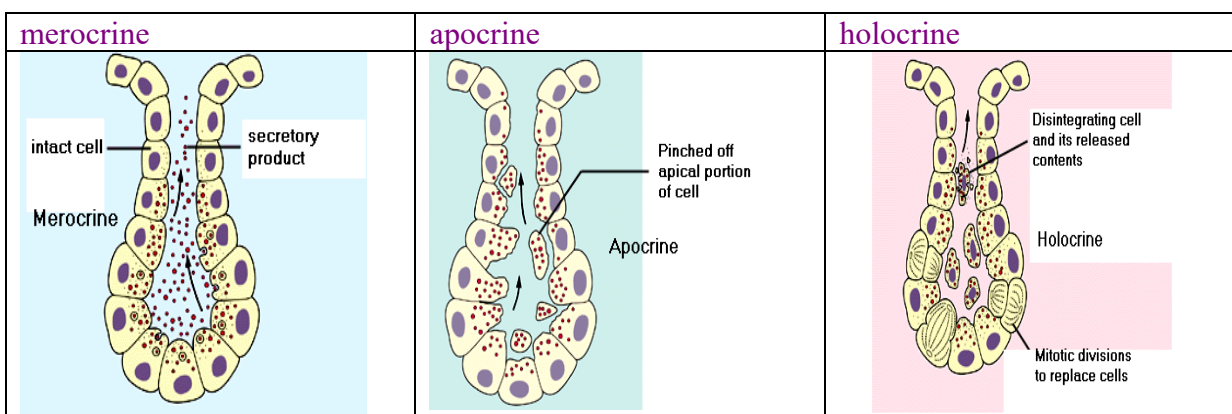
CLASSIFICATION OF GLANDS

GLANDULAR EPITHELIUM	⇒ unicellular	Single cells in covering epithelium – (Paneth cells, goblet cells, enteroendocrine cells, Leydig cells)
	⇒ multicellular	<p><u>According of mechanism of secretion</u></p> <p>endocrine</p> <p>exocrine – merocrine, apocrine, holocrine</p> <p><u>According to localization</u> intraepithelial</p> <p>⇔ extraepithelial</p> <p><u>According to arrangement of ducts</u></p> <p>simple ⇔ branched ⇔ compound</p> <p><u>According to type of secretory portions</u></p> <p>tubular ⇔ alveolar (acinar) ⇔ tuboalveolar</p> <p><u>According to product properties</u></p> <p>mucous ⇔ serous ⇔ mixed</p>

According of mechanism of secretion

endocrine – glands without ducts, product is released into the blood through the wall of capillaries

exocrine – secretory cells of exocrine glands release their products into ducts in three different ways:

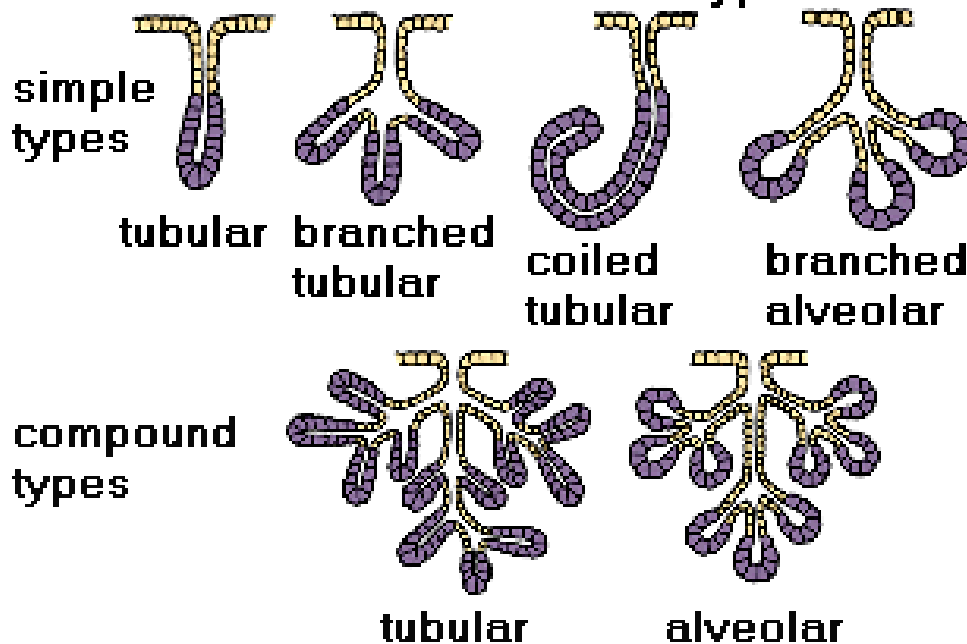


- membrane-bound secretory granules are moved to the apical surface where they coalesce with the membrane on to release the product.	- the apical portions of cells are pinched off and lost during the secretory process.	- secretory cell degenerates and as it breaks apart, the contents of the cell become the secretory product.
--	---	---

According to

type of secretory units	to product properties	simple	branched	compound
tubular	are usually mucous			
alveolar (acinar)	are usually serous			
tuboalveolar	mixed			

Exocrine Gland Types



Secretory units

Serous acinus (alveolus)	Mucous tubule	Serous demilune (Giannuzzi)

Functions of epithelia:

- **Barrier:** Epithelial tissue commonly functions as a covering or lining for organs and other tissues (e.g., skin, mucous membranes, pleural cavity, etc.). Epithelial cells serve as selective barriers between the environment and the internal structures of the body. They protect underlying tissues from drying, and from mechanical and chemical injury. Tight junctions between individual cells play an important role in the barrier function of epithelium. Some barrier epithelial cells have motile **cilia** that propel fluid or particulate matter over tissue surfaces (e.g., cells lining the bronchi).
- **Absorption:** Epithelial cells are found in those organs (e.g., intestine) which are involved in absorption of substances important for life. These cells often **microvilli** which increase cell surface area in order to facilitate absorption.
- **Secretion:** The secretory cells of endocrine and exocrine glands are epithelia.
- **Sensory:** Many of the more complex sensory receptors of the nervous system are derived from specialized epithelia called neuroepithelia (e.g., the rods and cones of the retina, olfactory receptors of the nose, taste receptors on the tongue, etc.). Sensory receptors function by converting mechanical, chemical, or electromagnetic signals from the environment into nerve impulses which can be processed by the nervous system.
- **Contractility:** Some very specialized epithelial cells (myoepithelia) contain the contractile proteins myosin and actin similar to muscle. Myoepithelia are associated with the ducts of sweat, salivary, lacrimal, and mammary glands and assist in the secretory process.

Origin: Epithelial tissues are derived from all three primary germ cell layers.

- **Ectoderm:** The epithelial cells of the skin and oral cavity (epidermis) are derived from ectoderm. Epithelial cells covering the cornea and lens, as well as sensory receptors of the eyes, ears, and nose, are also ectodermal in origin.
- **Mesoderm:** The epithelial lining of blood vessels (endothelium) is derived from mesoderm. The epithelial lining of the pleural and peritoneal cavities (mesothelium) also originate from mesodermal cells.
- **Endoderm:** The epithelial lining of the respiratory system and digestive tracts - as well as the functional cells (parenchyma) of the liver, pancreas, gallbladder, thyroid, and parathyroid, are derived from endoderm.

CONNECTIVE TISSUE (CT)

forms an extensive compartment in the body and can be considered as the "glue" that holds the body and organs together.

- the most diverse of the four tissue types with a wide variety of functions,
- 3 types of CT: connective tissue proper / cartilage / bone
- consistency is soft gel-like (areolar CT) to hard (bone),
- originate from embryonic CT = mesenchyme (derivate of mesoderm)
- function of CT: supporting, nutritive (diffusion of nutritives from blood vessels)

All types of CT consist of **cells** and **intercellular matrix** secreted by some of those cells. The

intercellular matrix consists of **fibres** and **ground substance** (interfibrillar substance).

Types of CT	Classification	Cells	intercellular matrix	
			Fibres	Ground substance
CT proper	Mesenchyme Mucose CT Loose CT Dense CT - regular - irregular Reticular CT Adipose CT - white fat - brown fat	<u>Fixed:</u> fibroblasts and fibrocytes, reticular cells, pigment cells, adipose cells, histiocytes, mast cells, plasma cells, <u>Free:</u> macrophages, leukocytes	collagen reticular elastic	
Cartilage	Hyaline Elastic Fibrocartilage	chondroblasts and chondrocytes	collagen elastic	
Bone	Fibrillar Lamellar - compact - spongy	osteoblasts, osteocytes	collagen	mineralized

Ground substance: occupies the space between the cells and fibres of CT,

- it is colorless, transparent, homogenous substance of mucose consistency,
- it has a high water content,
- in specially prepared sections, has an amorphous appearance. In routine preparations, it is lost during the fixation and dehydration process, and only cells and fibres can be seen.

Ground substance consists of:

- **glycosaminoglycans** – (*earlier called mucopolysaccharides*) – are polymers of hexosamines (glucosamine or galactosamine) and uronic acids. The main of them are **hyaluronic acid, chondroitinsulfate, dermatansulfate, keratansulfate, heparansulfate**. Sulfate and carboxyl groups makes glycosaminoglycans highly negatively charged. The high density of negative charges attracts water, forming a hydrated gel. This gel permits the rapid diffusion of water-soluble molecules but inhibits the movement of large molecules and bacteria. Hyaluronic acid is extremely long and rigid, consisting of a chain of several thousand sugars.
- **proteoglycans** – (**aggrecan, syndecan, fibroglycan**) are very large macro-molecules, consisting of a **core protein** to which many **glycosaminoglycan** molecules are covalently attached.
- **glycoproteins** – (**fibronectin, chondronectin, laminin, osteocalcin, osteonectin, osteopontin**) differ from proteoglycans: protein core is the main part of their molecule to which oligosaccharide chains are attached.

Fibres: There are three types of fibres secreted by connective tissue cells: **collagen fibres, reticular fibres,** and **elastic fibres**. The abundance and preponderance of different types of fibres varies in different CTs. Each type of fibre is formed by proteins made of long peptide chains.

Collagen fibres:

- the

most common type of fibres arranged into bundles

- flexible fibres with a high tensile strength;

- in LM: wavy lines of variable width and indeterminate length.

- in EM: fibres are seen to be made up of thread-like subunits called collagen fibrils. Each fibril is made up of **protein COLLAGEN**. The collagen molecule (called **tropocollagen**) is composed of three intertwined polypeptide chains that form a right-handed triple helix. Several types of collagen have been identified. Type I collagen is the most prevalent and is found in the dermis of the skin, bone, tendon, organ capsules and many other areas. The fibres found in cartilage are finer, they consist of type II collagen. Type IV collagen is found in the basal lamina (of basement membrane) of epithelia.

Reticular fibres:

- are closely related to collagen fibres.

- they

are made up of **protein COLLAGEN** (type III collagen fibrils).

- fibres do

not form bundles, and can be displayed with special silver preparations (impregnation) or with the periodic acid-Schiff (PAS) reaction because of their relatively high sugar content.

- fibres are arranged into network which provides a supporting framework for the cellular constituents of various tissues and organs (the lymphnodes, the spleen). They are also found around adipocytes, small blood vessels, nerves and muscle cells.

- in most locations, reticular

fibres are produced by fibroblasts. However, the reticular fibres that support the stroma of hemopoietic and lymphatic tissue are made by special cells called **reticular cells**. Each reticular cell maintains a unique relationship to its fibre, surrounding it with its cytoplasm and thereby isolating it from its environment. Other areas where reticular fibres are not produced by fibroblasts include the endoneurium of peripheral nerves (they are produced by Schwann cells), the tunica media of blood vessels and the muscularis externa of the alimentary canal (the smooth muscle cells secrete the fibres).

Elastic fibres:

- are thinner than collagen fibres and are arranged in a branching pattern to form a three dimensional network.

they give tissue the ability to cope with stretch and distension.

- are composed of two structural components: **protein ELASTIN** and **microfibrils**. Microfibrils consist of a fibrillar glycoprotein.

- are is found

in certain ligaments (elastic ligaments), some cartilage (elastic cartilage in auricle, epiglottis) and in large arteries (elastic arteries).

- in most cases, the

elastic fibres are produced by fibroblasts. In the case of elastic arteries, it is produced by the smooth muscle cells of the tunica media.

- they do not stain very well with eosin

and in routine preparations usually cannot be distinguished from collagen fibres. Elastic fibres are selectively stained with special dyes such as orcein and resorcin-fuchsin.

The cells of connective tissues:

As mentioned in the table, many different kinds of cells can be found in CTs. Some of the cells in CTs are **fixed**, that is, they are permanent residents in the CT. Other cells are **wandering (free)**, they are transient migrants who have entered the CT from the blood in response to specific stimuli.

Fixed cells:

Fibroblasts:

- the principal cells of connective tissue.

- they produce precursors of all types of fibres (collagen, reticular, elastin) and ground substance.

Reticular cell:

- stellate cells
- production of collagen III of reticular fibres

Pigment cells: (melanocytes)

- production of pigment melanin
- cells originate from neuroectoderm

Adipose (fat) cells:

- also called adipocytes, these cells are specialized to store neutral fat.
- white fat – univacuolar cells (one large lipid droplet)
- brown fat – multivacuolar cells (several small lipid droplets)

Mobile cells:

Histiocytes:

- are phagocytic cells (fixed macrophages), after activation transform into migrating form – free macrophages

Mast cells:

- with granules containing **histamine**, **heparin** and **anaphylactic factors**. When released in response to an antigen, they cause hypersensitivity reactions, allergy and anaphylaxis.

Plasma cell:

- with voluminous cytoplasm and typical appearance of nucleus („clock“). Plasma cells are derived from B-lymphocytes and produce antibodies against a specific antigen. They have a limited migratory ability and a short life.

Undifferentiated mesenchyme cells: These are cells that retain the multiple potentials of embryonic mesenchyme cells. They are found in the tunica adventitia (the outer layer of CT) of venules.

Wandering cells:

Neutrophils: Neutrophils are white blood cells that act as phagocytes in the early stages of acute inflammation.

Eosinophils: Eosinophils are white blood cells that are found in the lamina propria of the GI tract, and at sites of allergic reaction and parasitic infection.

Basophils: Basophils are white blood cells that are similar to mast cells in having vasoactive agents released in response to an allergen.

Lymphocytes: These are cells responsible for immune responses that circulate in the blood. Normally, only small numbers are found in the CTs throughout the body. The number increases dramatically at certain sites of tissue inflammation. They are also very numerous in the **lamina propria** of the respiratory and gastrointestinal tracts, where they are involved in immunosurveillance. The lamina propria is a layer of loose CT lying immediately beneath the epithelium.

Monocytes: Monocytes are white blood cells that will give rise to all the phagocytes of the mononuclear phagocytic system.

Classification of connective tissues: CTs are classified on the basis of types and relative abundance of cells, fibres and ground substance, and on the organization of fibres.

Mesenchyme:

Mesenchyme contains fairly uniform appearing, small spindle-shaped cells whose processes extend and contact those of other cells to form a three dimensional cellular network. A semi-fluid ground substance fills the intercellular spaces. Fibres are present, but are very fine and sparse.

Mucose CT

or **Wharton's jelly**, is present in the umbilical cord (Its adult counterpart is found in the iris of the eye and in dental pulp of deciduous teeth.) In mucous CT, the ground substance is more viscous or jelly-like than in mesenchyme. Fibroblasts are the predominant cell type, and the number of fibres increases with age.

Loose (areolar) CT:

- cellular type of CT – all types of cells
- abundant ground substance and thin and relatively sparse fibres (mainly collagenous)
- viscous gel-like consistency
- is important for the diffusion of oxygen and nutrients, phagocytosis; connective function

examples of occurrence: beneath epithelia as lamina propria, submucosa – distinct layer of the wall of hollow tubular organs

Dense irregular CT:

- collagenous fibres form a bundles running in various directions (hence irregular)
- fibroblasts are scarce and usually the only cell type present
- little ground substance is present.

examples of occurrence: is found on the outside of many organs as fibrous capsule, in the dermis of the skin and as a sclera.

Dense regular CT:

- collagenous fibres are packed in dense regular arrays, between which lie rows of cells.

examples of occurrence: in tendons, ligaments, (some also contain large amounts of elastic fibres and are called elastic ligaments), and aponeuroses.

Elastic CT:

- bundles of elastic fibres (elastin causes yellow colour of CT)
- cells and ground substance are scarce
- mechanical functions

examples of occurrence: ligamenta flava (spinal column), vocal ligaments; elastic fibres are present as elastic membranes in the wall of blood vessels

Reticular CT:

- consists of reticular cells and reticular fibres
- serves as supporting network for free cells (lymfocytes or hematopoietic cells)

examples of occurrence: some lymph organs, bone marrow.

Adipose CT:

Adipocytes, which are specialized to store fat, are found throughout loose connective tissue. When adipocytes are the predominant cell present, the tissue is called adipose tissue. In white or unilocular fat, adipocytes contain a single, large lipid droplet surrounded by a thin layer of cytoplasm. The lipid mass compresses the nucleus to an eccentric position, producing a "signet ring" appearance.

A different kind of adipose tissue is known as brown or multilocular fat. Brown fat contains fat droplets of varying sizes. The cells are smaller than those of white fat, with an eccentric round nucleus. Brown fat has a very limited distribution in adult humans, but is found in many animals. In hibernating animals, the oxidation of brown fat warms the blood flowing through it during arousal from hibernation. Human newborns, whose large surface to volume ratio can result in heat loss, also have a lot of brown fat. Most of it disappears during the first decade of life.

Cartilage

- type of connective tissue whose cells, called **chondrocytes**, secrete extracellular substances of ground mater and proteins of collagen or elsatc fibres

CARTILAGE: Consists of **chondrocytes (and chondroblasts)** in lacunae, in an extracellular matrix.

- **MATRIX**: Consists of FIBERS + GROUND SUBSTANCE
 - **Ground Substance**: Consists of **glycosaminoglycans - hyaluronic acid, keratan sulfate, chondroitin sulfate**.
 - Basophilia of matrix is due to the glycosaminoglycans
 - **AVASCULAR**: All cartilage does not contain blood vessels
 - nutrients are received, via passive diffusion, from blood vessels in the perichondrium.
- **PERICHONDRIUM**: Dense connective tissue (capsule) around the cartilage.
 - Perichondrium is not found on the articular surfaces of long bones and on the surface of fibrocartilage.
 - It contains blood vessels which provides nutrients to the cartilage.
- **CHONDROCYTES (and chondroblasts)**: they are located within little caves called **lacunae**, which they fill during life. However, during tissue preparation, chondrocytes shrink and frequently fall out, and lacuna appear only partially filled or empty.
 - **SYNTHESIS**: They are heavily synthetic. They have lots of ER. They secrete the extracellular matrix components .
 - They produce **matrix components**: 1) **glycosaminoglycans - hyaluronic acid, keratan sulfate, chondroitin sulfate**, 2) **chondronectin** (increases adhesiveness of chondrocytes to matrix) .
 - They produce **proteins of fibers (collagen II or elastin)**. Collagen fibers are not distinguishable in slides as their refractive index is almost identical to that of the ground substance.
- **DEVELOPMENT**: **Mesenchymal** cells aggregate to start formation. The Perichondrium is formed.
 - **INTERSTITIAL GROWTH**: Formation of isogenous groups leads to an expansion of the cartilage **from within the cartilage (isogenous groups** are mitotic clusters of chondrocytes in mature cartilage, formed by interstitial growth during cartilage development
 - **APPOSITIONAL GROWTH**: **Adding cells from the Perichondrium**. Layers from the perichondrium are added from the outside perimeter.
- **CARTILAGE REGENERATION**: Regeneration is limited because cartilage is avascular.
 - Some appositional regeneration can occur from chondroblasts around the periphery.

TYPES OF CARTILAGE:

- a) **HYALINE CARTILAGE**: Most common, basic type.
 - FIBERS: **Collagen Type II** (Cartilaginous Collagen)
 - Chondrocytes form **isogenic groups**, ground substance around them shows an intensive basophilia and so forms basophilic capsule – **isogenic group + basophilic capsule = chondron or teritorium**, ground substance among them = **interteritorium**
 - **DISTRIBUTION**:
 - Nasal cartilage
 - Trachea, bronchi, large cartilages of larynx
 - Articular ends of bones
- b) **ELASTIC CARTILAGE**:

- FIBERS: **Elastins** (proteins of elastic fibers)
- Chondrocytes (in lacunae) are dispersed diffusely, are not arranged in isogenic groups.
- MICROSCOPIC APPEARANCE: Under low light, when you focus in and out, you can see refraction of the elastic fibers under the microscope. Elastic fibers can be visualized by staining with orcein or resorcin fuchsin.
- DISTRIBUTION:
 - Auditory tube + auricle of ear
 - Epiglottis
 - Small laryngeal cartilages
- c) **FIBROCARILAGE**: Found in places where high stress occurs.
 - DISTRIBUTION: It never occurs alone. It is closely associated with either dense connective tissue or with hyaline cartilage.
 - Intervertebral Disks
 - Articular Disks
 - Pubic Symphysis
 - STRUCTURE: It has **no perichondrium**
 - GROWTH: It grows more like connective tissue (i.e. interstitial growth) due to the absence of a perichondrium.
 - FIBERS: **Collagen Type I**
 - Chondrocytes are not numerous, they are flattened and arranged in rows due to press of thick bundles of collagen fibers.

Bone

Bone is a connective tissue that is characterized by a mineralized extracellular matrix. The matrix is secreted by cells called osteocytes.

UNIQUE QUALITIES OF BONE

- **HYDROXYAPATITE**: Calcium Phosphate crystals.
 - It **prevents diffusion** of metabolites.
 - It **prevents interstitial growth** -- all bone growth occurs from the periosteum.
- **A CANALICULAR SYSTEM**: Tiny canals connect one **haversian system** to the other.
- **VASCULARITY**: All bone cells are in close proximity to vessels!
- **APPOSITIONAL GROWTH**: All growth occurs by appositional growth.
- **BONE RECONSTRUCTION**: Bone is dynamic tissue, constantly changing shape.
- **LONG-BONE GROSS STRUCTURE**:
 0. **DIAPHYSIS**: The shaft, with a medullary cavity on inside.
 1. **EPIPHYSIS**: The ends.
 2. **METAPHYSIS**: The site of ossification, between the diaphysis and epiphysis.
 3. **ARTICULAR CARTILAGE**: Hyaline cartilage covering compact bone at the ends of long bones. It lacks perichondrium.
 4. **PERIOSTEUM**: Osteogenic potential around the outside.
 5. **ENDOSTEUM**: Lines the marrow cavity and also has osteogenic potential.
 - In Skull, the endosteum is the **dura mater**, and it has limited osteogenic potential which is important in fracture healing.

GENERAL PROPERTIES OF BONE

BONE: Consists of **cells** in lacunae, in an extracellular matrix

BONE CELL TYPES

- **A) OSTEOPROGENITOR CELLS**: The Stem-Cells of bone.
 - **DISTRIBUTION**:
 - Found on the inner lining of the periosteum and endosteum.
 - Found lining vascular canals.
- **B) OSTEOBLASTS**: They are secretory cells.
 - **SECRETE**:
 - They secrete the bone matrix.
 - **ALKALINE PHOSPHATASE** which calcifies the matrix.
 - They have polarity and resemble other secretory cells.
- **C) OSTEOCYTES**: They are osteoblasts that have become trapped in their own matrix.
 - They are found **in lacunae**, between layers of **lamellae**, in the matrix of cortical bone.
 - **CANALICULI**: Fine **cytoplasmic extensions** of the osteocytes running perpendicular to the haversian canals.
- **D) OSTEOCLASTS**: Large, multinucleate cells derived from **monocytes**.
 - They have **acid hydrolases**.
 - Osteoclasts have many lysosomes and are eosinophilic.
 - **HOWSHIP'S LACUNAE**: The spaces for bone resorption, between the osteoclast and the bone resorption surface.

BONE-MATRIX

- **COLLAGEN**: Type I Collagen = 85% - 90% of total bone protein.
- **NON-COLLAGEN PROTEINS**: Small percentage but very important.
 - Cell Attachment Proteins: **Fibronectin, Osteopontin**
 - **Proteoglycans**
 - **OSTEOCALCIN**: important in bone turnover.
- **HYDROXYAPATITE**: Bone salts (Calcium Phosphate) composes the non-protein inorganic part.

TYPES OF BONE

- **WOVEN BONE** - collagen fibers are not arranged into lamellae and running in different directions, they form a network in ground substance. Osteocytes in lacunae are situated in this network.
- **COMPACT BONE** - is recognized as:
 1. **Lamellar bone**: Bone arranged in concentric layers called **lamellae**, with **Haversian Canals** containing blood vessels in the center. Often found around the outside of large bones.

Compact lamellar bone :

Lamellae: Lamellae around central **Haversian Canals**, which contain blood vessels and nerves. **Osteocytes** are within the lamellae, with **canaliculi** radiating toward the central haversian canal.

1.Haversian

Volkman's Canals: Run perpendicular (transverse) to the Haversian Canals, they **connect the haversian canals to each other, or to the marrow cavity.**

2. Interstitial Lamellae: Remnants of older haversian lamellae. They are not concentrically arranged, but lie in between the haversian systems.

3. Circumferential Lamellae: The external and internal borders of cortical bone. **Outer Circumferential Lamellae:** Occur adjacent to the periosteum. **Inner Circumferential Lamellae:** Occur adjacent to the endosteum.

Spongy bone: forms **trabeculae** inside of bone cavity with the bone-marrow. Lamellae are organized in parallel way to their surface.

Characteristics of Ossification

- **OSTEOID:** Unmineralized "pre-bone" matrix is the early matrix that is secreted by osteoblasts, before it is mineralized.
- **WOVEN BONE:** Osteocytes are uniformly distributed and randomly oriented throughout the bone. **All bone starts as woven bone.**
- Bone first appears as little spikes called **spicules**, which then form **trabeculae**
- The woven bone is reformed to make either **cortical bone or spongy bone.**

A) INTRAMEMBRANOUS OSSIFICATION

: Formation of bone directly from osteoblasts, with **no cartilage intermediate.**

- Mesenchymal cells --> osteoblasts
- **Osteoblasts** secrete the osteoid matrix.
- Osteoblasts then secrete alkaline phosphatase to calcify the matrix, trapping themselves in it, and thereby forming **Osteocytes.**
- Some flat bones are formed by intramembranous ossification.

B) ENDOCHONDRAL OSSIFICATION

: Long bones are formed on a cartilage model. **GENERAL PROCESS:**

- Cartilage matrix is laid down.
- **Perichondrium** then becomes **periosteum**, when a **vascular bud** invades the perichondrial space.
 - the vascular bud contains blood cells, bone marrow cells, macrophages, endothelial cells.
- **GROWTH IN LENGTH:** Occurs by proliferation of chondrocytes at the epiphyseal plates and at the primary ossification front.
- **GROWTH IN DIAMETER:** Occurs by deposition of new bone under the **periosteal collar along with simultaneous osteoclastic resorption, in order to maintain bone shape.** The osteoclastic resorption is necessary to enlarge the medullary cavity.
- **PRIMARY OSSIFICATION CENTER:** Occurs in the center of the diaphysis, and extends toward both epiphyses.
 - Thus there are **two fronts of primary ossification.**

- **Primary ossification centers** close around the time of birth. Thereafter, long-bone growth occurs from the secondary ossification centers.
- **SECONDARY OSSIFICATION CENTER:** Forms at the **epiphyseal plate**.
 - The orderly columns of chondrocytes are not seen here.
 - Growth occurs from the epiphysis downward, toward the epiphyseal plate.
- **EPIPHYSEAL CLOSURE:** The end of longitudinal growth in long bone, when the **primary ossification center overtakes (i.e. calcifies) the secondary ossification center**, and hence long-bone growth ceases.

OSSIFICATION ZONES

RESERVE ZONE: This is the zone of normal hyaline cartilage. Little cellular activity or cell division is occurring.

PROLIFERATIVE ZONE: Chondrocytes are multiplying and arrange themselves in long parallel isogenous columns: This is the main zone responsible for growth of the long axis of the bone.

ZONE of HYPERTROPHY: Chondrocytes are hypertrophying and secreting **alkaline phosphatase**.

CALCIFICATION ZONE: Matrix around the hypertrophied cells calcified, trapping the chondrocytes in the matrix. Chondrocytes are dying here (**due to no nutrients**).

„**LINE of erosion**“

OSSIFORM ZONE: **calcified cartilage matrix = spicules** are covered with osteoblasts are recruited from the blind end of vascular bud. **OSTEOBLASTS** produce bone matrix = **osteoid**, which is later calcified trapping osteoblasts in mineralized matrix - **ossein**

- **FORMATION OF THE MARROW CAVITY:** Develops from the early cavities in trabecular bone, formed by erosions in the trabeculae.
- **FORMATION OF HAVERSIAN SYSTEMS:** **Trabeculae** of the long bone appear as **stalactites**, hanging down from the epiphyses. These trabeculae enclose **tunnels** where chondrocytes once resided.
 - **The vascular bud enters through those tunnels, and haversian canals form around those tunnels.**
 - Bone builds up on either side of the vascular tunnel.
 - The two ridges then **fuse**, enclosing the vascular tunnel.
 - **What was periosteum forming on both sides has now become the endosteum of the tunnel.**
 - Ossification proceeds inward. Endosteal cells deposit bone until the vessel is completely enclosed.

: The process of **BONE-REMODELING**, which occurs during growth and in mature bone. It explains the **interdependence between osteoclastic and osteoblastic activity in bone-remodeling**, which explains why **Osteoporosis** is difficult to treat.

- **Activation:** Osteoclasts are activated and begin secreting acids to resorb bone.
- **Resorption:** Osteoclastic resorption occurs.
- **Reversal:** Resorption stops and osteoblasts take over.
- **Formation:** Osteoblasts form bone on the opposing surface to complete the bone reforming process.

PARATHYROID HORMONE: Enhances the rate of bone-turnover. Ultimately it takes Ca^{+2} from the bone and puts it into the blood.

- PTH indirectly stimulates Osteoclasts to resorb bone. **PTH stimulation of Osteoclasts is mediated by Osteoblasts.** Again this shows interdependence of the two cell types.
 - PTH stimulates the release of **soluble factors from osteoblasts.** Those factors stimulate the osteoclastic activity.
 - **Osteoclasts have no PTH-Receptors.**
 - PTH also stimulates the differentiation of monocytes into osteoclasts, and increases the amount of osteoclastic ruffled borders.
- PTH also directly stimulates Bone-Lining Cells to transfer Ca^{+2} .
- We need Parathyroid Hormone to survive and maintain Calcium homeostasis. We can live without Calcitonin.

VITAMIN-D: 1,25-Dihydroxy-Vit-D stim. osteoblasts to synthesis the bone matrix & alkaline phosphatase.

CALCITONIN: Takes Ca^{+2} from the blood and deposits it into the bone.

- Calcitonin inhibits osteoclastic activity **by binding directly to osteoclasts.**
 - **Osteoclasts do have Calcitonin receptors.**
- Calcitonin also directly stimulates osteoblastic activity.
- Although Calcitonin opposes PTH, it does not completely counteract PTH. The effect of PTH is more important.

TRANSFORMING GROWTH FACTOR (TGF-beta): One connection between osteoblasts and osteoclasts.

- TGF-beta is found in bone in its inactive form.
- Osteoclastic activity stimulates TGF-beta : increased acid production --> activation of TGF-beta in bone.
- TGF-beta, in turn, inhibits further osteoclastic activity (negative feedback) and promotes osteoblastic activity.
- TGF-beta, as well as other cytokines, (**IL-1, Tumor Necrosis Factor**), appear to be involved in differentiation of monocytes into osteoclasts.

MECHANISMS OF CALCIFICATION

- **MATRIX VESICLES:** Matrix vesicles are inside the osteoblasts. They accumulate the mineral and control the rate at which calcification proceeds.
 - **Intravesicular Calcium Accumulation:** Ca^{+2} binds to vesicle and combines with phosphates from the phospholipids to form the calcium salt.
 - **Extravesicular Calcium Accumulation:** The hydroxyapatite crystals get exposed to the extracellular space.
 - **Vesicular Alkaline Phosphatase** is required for external calcification to occur.

JOINTS

- **SYNARTHROSES:** Poorly moveable (fibrous) joints.
 - **Syndesmosis:** Bones linked by dense fibrous connective tissue, as in SKULL SUTURES
 - **Synchondrosis:** Bones linked by cartilage, as in the PUBIC SYMPHYSIS.
- **DIARTHROSES:** Movable joints
 - **Articular Cartilage** made of hyaline cartilage, **without perichondrium**, covers the moving bone-ends.
 - **Joint Capsule** is continuous with the periosteum.
 - **Synovial Membrane** lines the joint capsule. It secretes **synovial fluid** into the joint space.
 - Proprioception Nerve Receptors are located in the joint capsule.
- **ARTHRITIS:** Inflammation or degeneration of the joints, impairing joint mobility.
 - **Rheumatoid Arthritis:** Auto-immune attack. Swelling of synovial membrane, hypertrophy of articular cartilages.
 - **Osteoarthritis:** Non-inflammatory degeneration. Hypertrophy of articular cartilages occurs.

Nervous Tissue (NT)

- highly specialized tissue
- forms, receives and sorts signals (**irritability**)
- transmits electrical impulses (**conductivity**)

Functions of Nerve Tissue

- Nervous tissue *allows an organism to sense stimuli in both the internal and external environment.*
 - The stimuli are *analysed and integrated to provide appropriate, co-ordinated responses in various organs.*
 - The afferent or sensory neurons *conduct nerve impulses from the sense organs and receptors to the central nervous system.*
 - Internuncial or connector neurons *supply the connection* between the afferent and efferent neurons as well as different parts of the central nervous system.
 - Efferent or somatic motor neurons *transmit the impulse from the central nervous system to a muscle (the effector organ) which then react to the initial stimulus.*
 - Autonomic motor or efferent neurons *transmit impulses to the involuntary muscles and glands.*
- NT forms central and peripheral nerve system (CNS and PNS)
 - NT consists of nerve cells = **NEURONS** and associated supporting cells = **NEUROGLIA**; neurons are specifically designed to transmit electrical impulses and to receive and process information; neuroglial cells are non-conducting cells that are in intimate physical contact with neurons. They provide physical support, electrical insulation and metabolic exchange with the vascular system.
 - NT originates from ectoderm

NEURON

Nerve cells are very variable in appearance, shape and size, but all neurons have a cell body, also called soma or **perikarion**, and processes extending from the nerve cell to communicate with other cells. There are two types of processes: **dendrites** that receive impulses and **axons (neurites)** that transmit impulses. All nerve cells have one axon, which is usually the longest process that extends from the cell and one or more (hundreds) dendrites, these are generally shorter and thicker than the axon. The junction where a nerve cell communicates with another nerve cell or an effector cell (eg. muscle fibre) is called a **synapse**, which can be chemical or electric. The terminal part of the axon with chemical synapses releases substances called a **neurotransmitter** which acts on the membrane of the other cell.

Main parts of neuron

- Dendrites
- Cell body
- Axon (neurite)
- Axon terminal

Cell body – **PERIKARION**: contains nucleus and most cytoplasm with organelles:

- nucleus – round or oval, very light, with prominent nucleolus
- rough ER (called Nissl' substance) – involved in synthesis of proteins (neurotransmitters)
- other usual organelles (mitochondria, Golgi apparatus, lysosomes)
- neurofibrils – neurofilaments and neurotubules
- pigment lipofuscin

DENDRITES – input structure – receive signals; number of dendrites: one – several hundreds

- short, branched processes with structure similar to perikarion (cytoplasm + organelles + neurofibrils)
- incoming signals summate to initiate action potential highly branched tree structure

Classification of neurons according to number of processes (dendrites):

1. **Multipolar neuron** – several dendrites extend from body found in brain & spinal cord
2. **Bipolar neuron** – one dendrite and one axon (in retina of eye)
3. **Unipolar neuron** – one process only, link to axon (sensory neurons)
4. **Pseudounipolar neuron** – one short process divides later into dendrite and axon (spinal ganglia)

AXON – only one

- no protein synthesis here
- Trigger zone - where nerve impulses arise
- Axon hillock – the cone-shaped base of the axon, its cytoplasm is free of rER (Nissl substance)
- Axons terminal - end with fine branching with „terminal boutons“ – mitochondria and synaptic vesicles containing neurotransmitters
- Axon hillock and terminal are not covered with oligodendrocytes (in CNS) or Schwann cells (in PNS)
- Serves for impulses transmission and for axonal transport of neurotransmitters and nutrients

Classification of neurons according to length of axon:

1. Golgi type I – long axon (up to 1 m) – somatic motor neurons
2. Golgi type II - short axon (in μm)

Classification of neurons according to function:

1. sensitive neurons – (afferent) conduct informations from receptors to CNS
2. motor neurons – (efferent) conduct infirmations from CNS to effector cells: somatomotor to skeletal muscle and visceromotor to smooth muscle cells, cardiomyocytes or glandular cells
3. interneurons (97 %)

Sheaths of axons:

Schwann sheath (neurilemma) – Schwann cells surround the axon (gray fibers)

Myelin sheath – lipoprotein product of Schwann cells in PNS and oligodendrocytes in CNS
- electrically insulates axon - increases speed of nerve impulse
- wraps around one axon many times and has a lamellar appearance

Many axons are wrapped in a lipid-rich covering called **myelin**. This **myelin sheath** insulates the axon from the surrounding extracellular component and increases the rate of electrical conduction. The myelin sheath is discontinuous at intervals called the **nodes of Ranvier**. The area covered with myelin is called **internodal area (internodium)**. In myelinated axons, the voltage reversal (that is, the impulse propagation) can occur only at the nodes, and the impulse "jumps" from node to node. This is called **saltatory conduction**. In unmyelinated axons, the impulse is conducted more slowly, moving as a wave of voltage reversal along the axon.

Synapses

- NEURON – NEURON

- Presynaptic neuron - conducts signal to a synapse // synaptic vesicles with neurotransmitter
- Synaptic cleft (20-30 nm thick)
- Postsynaptic neuron - conducts signal from a synapse // receptors on cell membrane

- NEURON – EFFECTOR CELL

Effector cells – muscle cells (in smooth muscle = **neuromuscular spindle**, in skeletal muscle = **motor-end-plate**), cardiomyocytes, glandular cells

Chemical Synapses

- Presynaptic cell releases neurotransmitters from synaptic vesicles
- Act on the postsynaptic cell (help initiate AP)
- Neurotransmitters can excite or inhibit
- Neurotransmitters (acetylcholine, serotonin, norepinephrine and epinephrin, dopamine, GABA, ...)
- Neurotransmitter must be removed to prevent continual firing of neurons

- Enzymatically - acetylcholinesterase
- Many pharmaceuticals and drugs modulate this effect
- Cocaine block removal of dopamine

Electrical Synapses

- Without synaptic vesicles; synaptic cleft – only 2 nm thick
- Depolarizing wave continues from presynaptic to postsynaptic membrane
- Morphologically (in electron microscope) it looks like communicatin intercellular connection: gap junction (nexus)

SUPPORT CELLS PLAY A VITAL ROLE

Support cells are essential to the function and survival of nerve cells. The CNS and PNS each have their own specific types of support cells.

Support cells in the CNS:

The general term for support cells in the CNS is **glia** or **neuroglia** (glial cells, neuroglial cells). There are four types of neuroglial cells. (1) **Oligodendrocytes**, the myelin-secreting cells of the CNS. (2) **Astrocytes**, which provide physical and metabolic support for nerve cells. (3) **Microglia**, (microglial cells), which are the phagocytes of the CNS. (4) **Ependyma** (ependymal cells) lining brain cavities and central canal in spinal cord.

Oligodendrocytes. As their name implies, oligodendrocytes have few processes. They are often found in rows between axons. The myelin sheath around axons is formed by concentric layers of oligodendrocytes plasma membrane. Each oligodendrocyte gives off several tongue-like processes that find their way to the axon, where each process wraps itself around a portion of the axon, forming an internodal segment of myelin. Each process appears to spiral around its segment of the axon in a centripetal manner, with the continued insinuation of the leading edge between the inner surface of newly formed myelin and the axon. One oligodendrocyte may myelinate one axon or several. The nucleus-containing region may be at some distance from the axon(s) it is myelinating. In the CNS, nodes of Ranvier (between myelinated regions) are larger than those of the PNS, and the larger amount of exposed axolemma makes saltatory conduction more efficient.

Unmyelinated axons in the CNS are truly bare, that is they are not embedded in any glial cell process. (In contrast to the situation in the PNS, described below.)

Astrocytes. Astrocytes are the largest of the neuroglial cells. They have elaborate processes that extend between neurons and blood vessels. The ends of the processes expand to form end feet, which cover large areas of the outer surface of the blood vessel or axolemma. Astrocytes are believed to play a role in the movement of metabolites and wastes to and from neurons, and in regulating ionic concentrations within the neurons. They may be involved in regulating the tight junctions in the capillaries that form the blood-brain barrier. Astrocytes also cover the bare areas of neurons, at nodes of Ranvier and synapses. They may act to confine neurotransmitters to the synaptic cleft and to remove excess neurotransmitters.

Two kinds of astrocytes are identified, **protoplasmic** and **fibrous astrocytes**. Both types contain prominent bundles of intermediate filaments, but the filaments are more numerous in fibrous astrocytes. Fibrous astrocytes are more prevalent in white matter, protoplasmic ones in grey matter.

Microglia. These are the smallest of the glial cells, with short twisted processes. They are the phagocytes of the CNS, considered part of the mononuclear phagocytic system (see pg 110 in Ross et al.). They are believed to originate in bone marrow and enter the CNS from the blood. In the adult CNS, they are present only in small numbers, but proliferate and become actively phagocytic in disease and injury. Their alternate name, mesoglia, reflects their embryonic origin from mesoderm (the rest of the nervous system, including the other glial cells, is of neuroectodermal or neural crest origin).

Ependymal cells. Cuboidal to columnar cells in one layer lining the fluid-filled brain ventricles and central canal (canalis centralis) in spinal cord. Ependyma is involved in cerebrospinal fluid production in some regions (choroid plexus).

Support cells in the PNS:

The support cells of the PNS are called satellite cells and Schwann cells.

Satellite cells. Satellite cells surround the cell bodies of the neurons in ganglia (ganglion cells). These small cuboidal cells form a complete layer around the nerve cell body, but only their nuclei are visible in routine preparations. They help maintain a controlled microenvironment around the nerve cell body, providing electrical insulation and a pathway for metabolic exchange. In paravertebral and peripheral ganglia, nerve cell processes must penetrate between satellite cells to establish a synapse.

Schwann cells. Schwann cells are responsible for the myelination of axons in the PNS. A Schwann cell wraps itself, jelly roll-fashion, in a spiral around a short segment of an axon. During the wrapping, cytoplasm is squeezed out of the Schwann cell and the leaflets of plasma membrane of the concentric layers of the Schwann cell fuse, forming the layers of the myelin sheath. An axon's myelin sheath is segmented because it is formed by numerous Schwann cells arrayed in sequence along the axon. The junction where two Schwann cells meet has no myelin and is called the node of Ranvier (the areas covered by Schwann cells being the internodal regions).

The lack of Schwann cell cytoplasm in the concentric rings of the myelin sheath is what makes it lipid-rich. Schwann cell cytoplasm is however found in several locations. There is an inner collar of Schwann cell cytoplasm between the axon and the myelin, and an outer collar around the myelin. The outer collar is also called the sheath of Schwann or neurilemma, and contains the nucleus and most of the organelles of the Schwann cell. The node of Ranvier is also covered with Schwann cell cytoplasm, and this is the area where the plasma membranes of adjacent Schwann cells meet. (These adjacent plasma membranes are not tightly apposed at the node, so that extracellular fluid has free access to the neuronal plasma membrane.) Finally, small islands of Schwann cell cytoplasm persist within successive layers of the myelin sheath, these islands are called Schmidt-Lanterman clefts.

Myelination (development of myelin sheath):

Not all nerve fibres in the PNS are covered with myelin, some axons are unmyelinated. In contrast to the situation in the CNS, unmyelinated fibres in the PNS are not completely bare, but are enveloped in Schwann cell cytoplasm. The Schwann cells are elongated in parallel to the long axis of the axons, which fit into grooves on the surface of the Schwann cell. One axon or a group of axons may be enclosed in a single groove. Schwann cells may have only one or up to twenty grooves. Single grooves are more common in the autonomic nervous system.

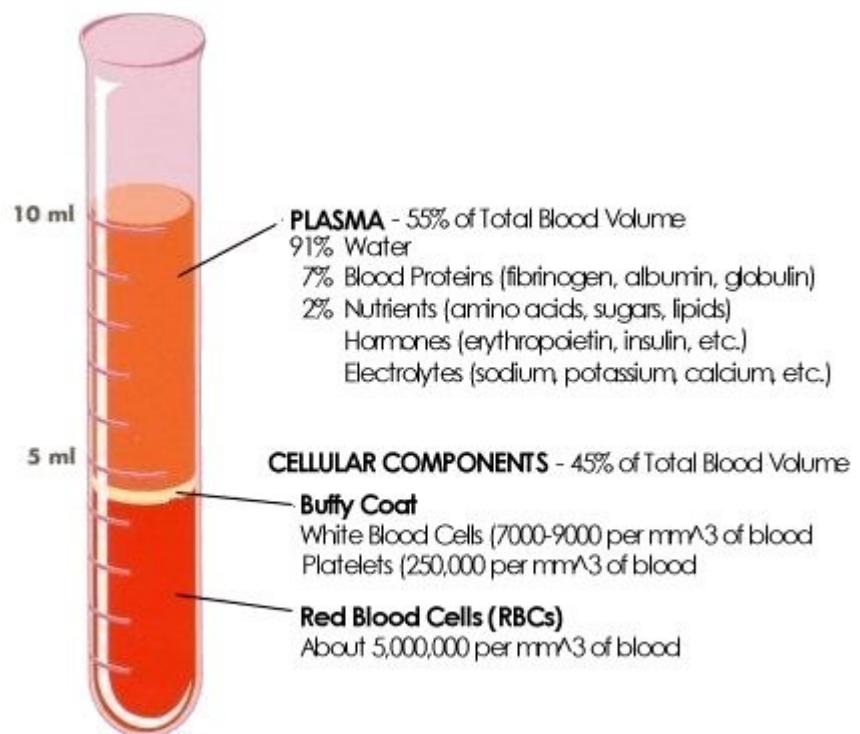
BLOOD

The blood consists of a suspension of special cells in a liquid called **plasma**. In an adult man, the blood is about 1/12th of the body weight and this corresponds to **5-6 litres**. Blood consists of 55 % **plasma**, and 45 % by cells called **formed elements**. The blood performs a lot of important **functions**. By means of the hemoglobin contained in the erythrocytes, it carries oxygen to the tissues and collects the carbon dioxide (CO₂). It also conveys nutritive substances (e.g. amino acids, sugars, mineral salts) and gathers the excreted material which will be eliminated through the renal filter. The blood also carries hormones, enzymes and vitamins. It performs the defense of the organism by mean of the phagocitic activity of the leukocytes, the bactericidal power of the serum and the immune response of which the lymphocytes are the protagonists.

THE PLASMA

Cells free serum or plasma, can be obtained by centrifugation. The plasma is a slightly alkaline fluid, with a typical yellowish color. It consists of **90 % water** and **10% dry matter**. Nine parts of it are made up by **organic substances**, whereas one part is made up by minerals. These organic substances are composed of glyicides (glucose), lipids (cholesterol, triglycerides, phospholipids, lecithin, fats), proteins (globulins, albumins, fibrinogen), glycoproteins, hormones (gonadotropins, erythropoietin, thrombopoietin), amino acids and vitamins. The **mineral substances** are dissolved in ionic form, that is dissociated into positive and negative ions.

Blood can be separated into its components in centrifuge. The parts separate according to their relative "weights." This test tube shows the components of blood in their relative ratios. It shows a **hematocrit** of 45 because the RBC layer together with the "buffy coat" layer make up 45% of the total volume of centrifuged blood (4.5 ml. out of 10 ml).



THE BLOOD CELLS

In the blood are present special cells, classified in: **erythrocytes** and **leukocytes**. There are also **platelets** (thrombocytes) which are not considered real cells.

ERYTHROCYTES (red cells)

The erythrocytes are the most numerous blood cells i.e. about **4-6 millions/ μl (mm^3)**

In man and in all mammals, erythrocytes are devoid of a nucleus and have the shape of a biconcave lens. The red cells are rich in **hemoglobin**, a protein able to bind to oxygen. These cells are responsible for **providing oxygen to tissues** and partly for **recovering carbon dioxide** produced as waste. However, most CO_2 is carried by plasma, in the form of soluble carbonates.

In the red cells of the mammals, the lack of nucleus allows more room for hemoglobin and the biconcave shape of these cells raises the surface and cytoplasmic volume ratio. These characteristics make more efficient the diffusion of oxygen by these cells. In so-called "sickle-cell anaemia", erythrocytes become typically sickle-shaped. In the electron microscope, the red cells can have different shapes: normal (biconcave), round (spherocyte) berry (crenated), burr (echinocyte), target (codocyte), oat, sickled, helmet, pinched, pointed, indented, poikilocyte, etc – **POIKILOCYTOSIS – except normal shaped cells different other shapes are found in blood smear**. Normal size of erythrocytes is **7.2 – 7.4 μm** (normocytes), smaller ery = microcytes, greater ery = macrocytes and meagocytes; **ANISOCYTOSIS – except normocytes also micro and macrocytes are found in blood smear**. The mean life of erythrocytes is about 120 days. When they come to the end of their life, they are retained by the spleen where they are phagocytosed by macrophages.

RETICULOCYTES are immature erythrocytes released from the bone marrow into the peripheral blood. They contain some rests of organelles (mainly ribosomes, but not nucleus) which are loosed during maturation (24 – 48 hours) and reticulocytes transform into mature erythrocytes. Reticulocytes represent 0.5 – 1.5 % of all erythrocytes in peripheral blood. **Reticulocytosis** – increased number of reticulocytes, a sign of increased releasing of these immature cells from bone marrow. **Anemia** – decreased number of erythrocytes, **polyglobulia** or polycythemia – increased number of erythrocytes.

PLATELETS

Cytoplasmic fragments of large cell – megakaryocyte in bone marrow.

Hyalomere – microtubules

Granulomere – mitochondria, glycogen and 3 kinds of granules: alpha (fibrinogen and other platelet proteins), delta (serotonin, pyrophosphate, ATP, ADP, Ca ions), lambda (like lysosomes – enzymes)

The main function of platelets, or **thrombocytes**, is **to stop the loss of blood from wounds** (hematostasis). To this purpose, they aggregate and release factors which promote the blood coagulation. Among them, there are the **serotonin** which reduces the diameter of lesioned vessels and slows down the hematic flux, the **fibrin** which trap cells and forms the clotting. Even if platelets appears roundish in shape, they are not real cells. In the smears stained by Giemsa, they have an intense purple color. Their diameter is 2-3 μm about, hence they are much smaller than erythrocytes. Their density in the blood is **150000-300000 / μl (mm^3)**.

LEUKOCYTES

Leukocytes, or **white cells**, are responsible for **the defense of the organism**. In the blood, they are much less numerous than red cells. The density of the leukocytes in the blood is **5000-9000 / μ l (mm^3)**. Leukocytes divide in two categories: **granulocytes** and **agranulocytes**.

Granulocytes contain **specific granules** in the cytoplasm. In the different types of granulocytes, the granules are different and help us to distinguish them. In fact, these granules have a different affinity towards neutral, acid or basic stains and give the cytoplasm different colors. **Granulocytes** distinguish themselves in **neutrophil**, **eosinophil** and **basophil**. **Agranulocytes** do not contain any specific granules, but azurophilic granules with lysosomal enzymes are present in their cytoplasm. Agranulocytes are divided into **lymphocytes** and **monocytes**.

GRANULOCYTES

-- NEUTROPHILS

The neutrophils are the most common leukocytes (72 %). They have a diameter of 12-14 μm . Their nucleus is divided into 2 - 5 lobes connected by a fine nuclear strand or filament. The cytoplasm is transparent because its granules are small and faintly pink colored (in LM usually invisible). Immature neutrophils have a band-shaped nucleus and are known as **band cells**. In the nucleus of the neutrophil from females, you may see an appendage like a little drumstick. It is the second X chromosome, inactivated (body of Baar).

Neutrophils are very active in phagocytosing bacteria and are present in large amount in the pus of wounds. Unfortunately, these cells are not able to renew the lysosomes used in digesting microbes and dead after having phagocytosed a few of them.

-- EOSINOPHILS

The eosinophils are quite rare in the blood (4 %). They have the same size as the neutrophils (14 μm). Generally their nucleus is bi-lobed. But even nuclei with three lobes have been observed. The cytoplasm is full of granules which assume a characteristic pink-orange color. As for the neutrophil, the nucleus is still easily visible.

Eosinophils attack parasites and phagocyte antigen-antibody complexes.

-- BASOPHILS

Basophils are the rarest leukocytes: less than 1 %. They are quite small: 9-10 μm in diameter. Cytoplasm is very rich in granules which take a dark purple color. The nucleus is bi- or tri-lobed or S-shaped, but it is hard to see because of the number of granules which hide it.

Basophils secrete anti-coagulant and vasodilatory substances as histamines and serotonin. Even if they have a phagocytory capability, their main function is secreting substances which mediate the hypersensitivity reaction.

AGRANULOCYTES (lymphoid cells)

-- LYMPHOCYTES

Lymphocytes are cells which, besides being present in the blood, populate the lymphoid tissues and organs too, as well as the lymph circulating in the lymphatic vessel. The lymphoid organs include thymus, bone marrow (in birds bursa with B-ly), spleen, lymphoid nodules, tonsils, Peyer's patches and lymphoid tissue of respiratory and gastrointestinal tracts.

Most lymphocytes circulating in the blood is in a resting state. They look like little cells with a compact round nucleus which occupies nearly all the cellular volume. As a consequence, the cytoplasm is very reduced. The lymphocytes of the lymphoid tissues and organs can be activated in a different amount following antigenic stimulation. In the blood, lymphocytes are 20 % (40 % in child) of all leukocytes and are slight larger (8 μm) than red blood cells.

Lymphocytes are quite common in the blood: 20-40%, 8-10 μm in diameter and generally they are smaller than the other leukocytes but they are still a few larger than red cells (fig. 11). The cytoplasm is transparent. The nucleus is round and large in comparison to the cell and it occupies most of it. In any case, some of the cytoplasm remains visible, generally in a lateral position. According to the quantity of cytoplasm, lymphocytes are divided into small, medium and large. With Giemsa stain, we cannot distinguish the different types of lymphocyte (B, T, NK), either in the blood because they are not activated, or because it would be necessary to perform special immunochemical staining.

The lymphocytes are the main constituents of the immune system which is a defense against the attack of pathogenic micro-organisms such as viruses, bacteria, fungi and protista. Lymphocytes yield **antibodies** and arrange them on their membrane. An antibody is a molecule able to bind itself to molecules of a complementary shape called **antigens**, and recognize them. As for all proteins, even the antibodies are coded by genes. On the basis of a recombination mechanism of some of these genes, every lymphocyte produces antibodies of a specific shape.

Hence, lymphocytes perform an action which is called **specific** in that each of them recognize the complementary antigen only. Even if every lymphocyte is so selective to recognize only one molecule, the number of circulating lymphocytes is so large that they are able to recognize practically all substances which are in the organism, both its own and foreign. It is a question of recognizing hundreds of millions of different molecules.

The cells of the immune system, chiefly lymphocytes, cooperate amongst themselves to activate, boost or make more precise the immune response. To attain this scope, there exist different types of lymphocytes, with different functions: **T and B lymphocytes**. When the **B – ly** are activated, they breed quickly (**clonal selection**) and they become **plasmacells** which secrete a great deal of antibodies in the blood stream (**humoral response**). When free antibodies meet micro-organisms with complementary shape (**epitopes**), they bind to them and form complexes which immobilize the micro-organisms. Later, other cells which are not specific, but which are able to recognize antibodies, phagocyte these complexes.

In their turn, the **T – ly** are divided into three categories: Tc (cytotoxic), Th (helpers), Ts (suppressors). Even the **Cytotoxic lymphocytes** breed quickly when they are activated. They do not release antibodies in the bloodstream, but they keep the antibodies on their membrane and use them to recognize cells mainly of its own organism infected by virus or tumoral cells. The cytotoxic lymphocytes kill cells by means of the release of perforins, substances which produces lesions in the membrane of the target cell and cause its death by osmotic lysis (**cell-mediated response**). The **helper lymphocytes** are needed to activate both B and Tc lymphocytes which, even though they recognize extraneous agents, seldom enter into direct action. **Suppressor lymphocytes** reduce the intensity of the immune response.

However, the immune system must not attack the cells of its body as the **autoimmune reaction** can damage the organism and lead to death. How does the immune system distinguish between self and not self? We have seen that B and Tc lymphocytes which have recognized an antigen, do not enter in action, but they need to be activated by a helper lymphocyte. A few times after the organism's birth, some of the new lymphocytes pass through the thymus where they become T lymphocytes. Here, these cells are compared with all antigens of the organism (autoantigens). It seems that lymphocytes which recognize an antigen, as they are still immature, will die. In this way, as the autoreactive Th lymphocytes are being killed, only the B and Tc lymphocytes which have recognized extraneous antigens can be activated. The system of cellular cytotoxicity mediated by Th cells is evolved as a defense against their own infected, modified or aberrant cells. In fact, B and Tc lymphocytes can activate themselves against bacteria even without the agreement of the helpers.

The B and Tc activated lymphocytes, besides to producing antibodies and killing foreign cells, multiply quickly. During the cellular division, rearrangements often occur in the sequence of the genes which code for the antibody. In this way, the antibody of the new cell takes a slightly different shape in comparison to that of its "mitotic parent". If the new shape matches the antigen better, this cell will be induced to divide more. The next generation of clones is therefore more efficient and, in its turn, can induce more selective varieties. This process and that of clonal selection make the immune response more effective. Finally, the immune system produces **memory cells**, i.e. deactivated lymphocytes ready to be reactivated on the occasion of further meeting with the same antigen.

Besides the Th and B cells, there is a third population of lymphocytes in the peripheral blood and lymphoid organs which do not have receptors for antigens. These lymphocytes have a non-specific defense function which is not activated by Th lymphocytes. These cells represent the more ancient component of the immune system and they are characterized by their cytotoxic activity. For these reasons, they are named **NK, Natural Killer**. Apart from killing viruses, bacteria, infected and neoplastic cells, these lymphocytes also regulate the production of other hematic cells such as erythrocytes and granulocytes.

-- MONOCYTES

Monocytes are the biggest leukocytes: 16-20 μm . They have a great reniform or horseshoe-shaped nucleus, in some cases even bi-lobed. The cytoplasm is transparent, but with an appearance of "ground glass" .

Monocytes are the precursors of **macrophages**. They are larger blood cells, which after attaining maturity in the bone marrow, enter the blood circulation where they stay for 24-36 hours. Then they migrate into the connective tissue, where they become macrophages and move within the tissues. In the presence of an inflammation site, monocytes quickly migrate from the blood vessel and start an intense phagocytory activity. The role of these cells is not solely in phagocytosis because they have also have an intense secretory activity. They produce substances which have defensive functions such as lysozyme, interferons and other substances which modulate the functionality of other cells. Macrophages cooperate in the immune defense. They expose molecules of digested bodies on the membrane and present them to more specialized cells, such as B and Th lymphocytes.

Each type of leukocyte is present in the blood in different proportions. Evaluation of their percentage is known as differential white cell count (DWCC) and its normal values are:

neutrophil S 68 % + R 4% (S = segmented nucleus, R – rod or band shaped, nonsegmented nucleus)

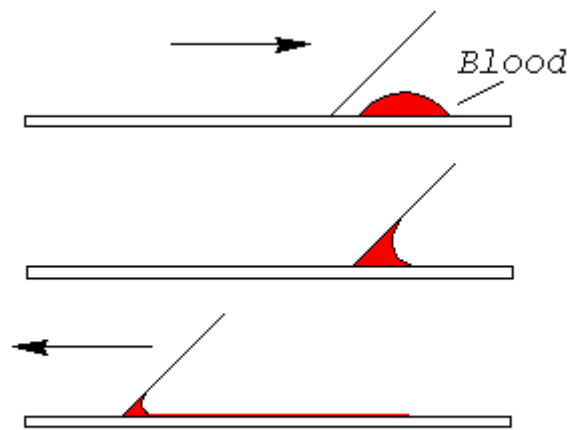
eosinophil 3 %

basophil 1 %
 lymphocyte 20 %
 monocyte 4 %

Blood smear preparation

1. apply a drop of blood on the glass;
2. put the other glass to the drop and spread it on the glass,
3. fixation of dry smear – methyl alcohol (3 – 5 minutes)
4. panoptic staining according to Pappenheim

Results of staining: **cytoplasm of erythrocytes** – orange, **cytoplasm of granulocytes** – pink, **specific granules** – red (eosinophilic) or blue (basophilic), **cytoplasm of agranulocytes** – light blue, **azurophilic granules** – orange-red, **thrombocytes** – violet bodies.



Differential white cell count (DWCC)

– an important examination of blood, which expresses percentage of all types of leukocytes (Table 1)

Table 1:

GRANULOCYTES		normal values
Neutrophilic granulocytes with non-segmented nucleus	Neu - bands	4 %
Neutrophilic granulocytes with segmented nucleus	Neu – segments	68 %
Eosinophilic granulocytes	Eos	3 %
Basophilic granulocytes	Baso	1 %
AGRANULOCYTES		
Lymphocytes	Ly	20 %
Monocytes	Mono	4 %

Method of leukocytes counting (in the light microscope): blood smear is viewed by regular movement (*) of the slide and 100 leukocytes of all types must be registered. Total number of each of leukocyte types represents values in % (percentage)

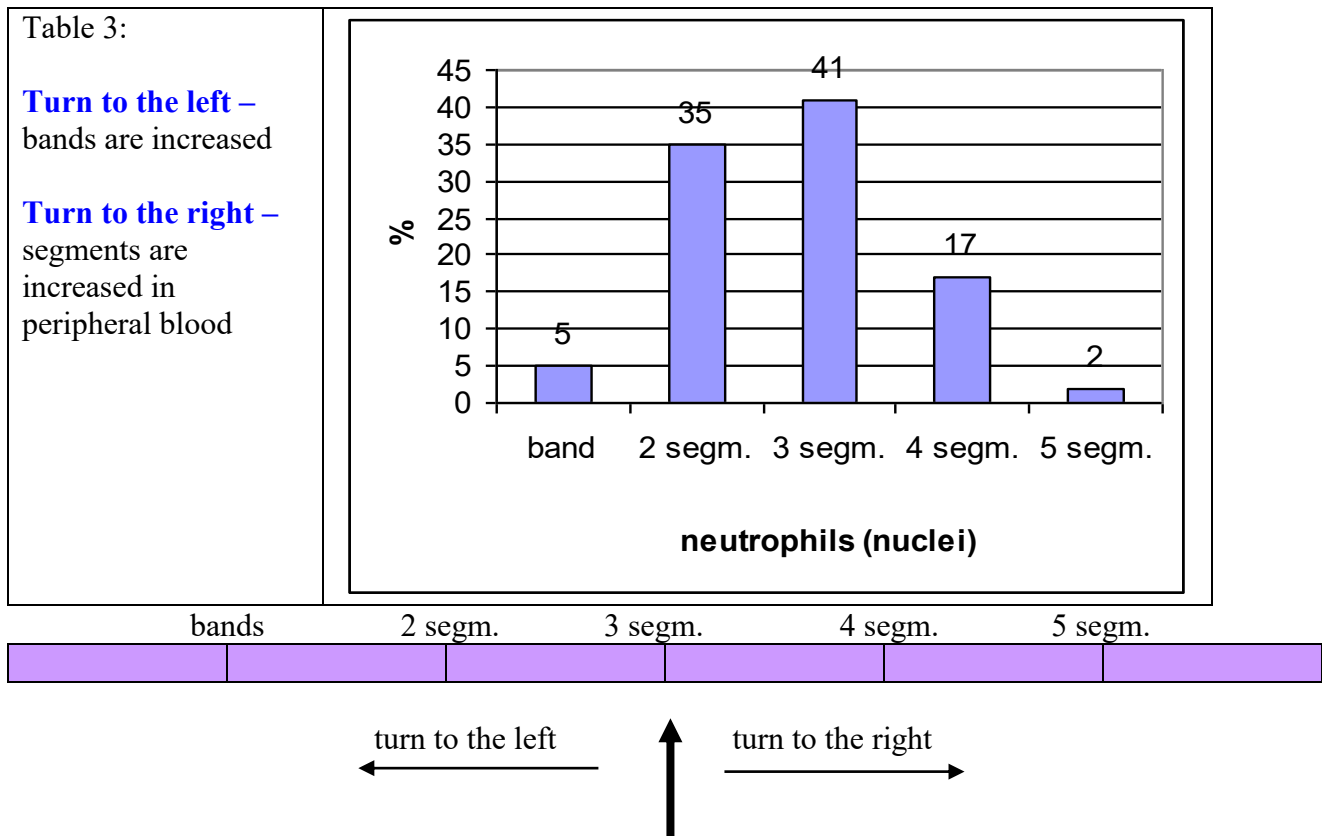
Deviation of DWCC:

Table 2:

	Increased number (↑) – cytosis	Decreased number (↓) – penia
Neutrophils *	Neutrophilic granulocytosis	Neutrophilic granulocytopenia
Eosinophils	Eosinophilic granulocytosis	Eosinophilic granulocytopenia
Basophils	Basophilic granulocytosis	Basophilic granulocytopenia
Lymphocytes	Lymphocytosis	Lymphocytopenia
Monocytes	Monocytosis	Monocytopenia

* see the table 3

Normal ratio of **neutrophil bands and segments** (B : S) is 4 % : 68 % = **1 : 17**.

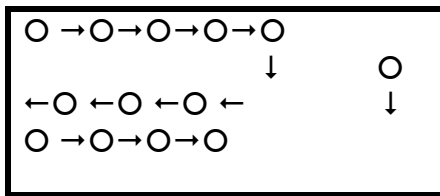


Differential white cell count (DWCC)

- percentage of leukocytes types in blood

- Counting: 100 leukocytes are counted in blood smear; their types are registered into the table:
neutrophil bands, neutrophil segments, eosinophils, basophils, lymphocytes, monocytes.

- Method: blood smear is viewed by regular movement (*) of slide and 100 leukocytes of all types must be registered. Total number of each of leukocyte types represents values in %



(*)

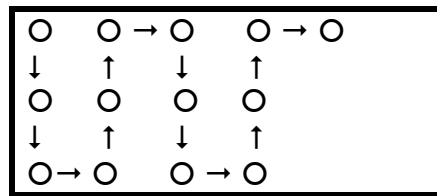


Table:

	1	2	3	4	5	6	7	8	9	10	%	%
B	/			/			//					4
S	////-/	////-	////-	////-	////	////	////-	////-	////-	////-		68
Eos		/			//							3
Ba									/			1
Ly	//		///	/	///	////-	////	/				20
Mo	/				/			/		/		4
cells	10	10	10	10	10	10	10	10	10	10	100	100

Development of the blood cells

Prenatal hematopoiesis

■ Mesoblastic period – the 1st – 2nd month

mesoblast of yolk sack and connecting stalk and mesenchyme of embryonic body:

INSULAE SANGUINAE (blood islets)

- *angioblasts*

- *hemoblasts* ⇒ *primitive erythrocytes with nucleus*

■ Hepatolienal period – the 2nd – 7th month

liver and spleen

■ Medullary period – from the ±4th month

bone marrow

Postnatal hematopoiesis

■ Bone marrow: *erythrocytes, leukocytes, thrombocytes*

■ Thymus: *T-lymphocytes*

■ Lymph organs: *B-lymphocytes*

Bone marrow

■ Red – reticular c.t. + hematopoietic cells

in adult – in flat and short bones (sternum, clavicle, skull bones, iliac bones, vertebrae) and proximal epiphyses of long bones

■ Yellow – reticular c.t. + fat cells

[possible reversion into hematogenous (red) marrow]

- Gray – reticular c.t. only

Bone marrow - structure

- reticular connective tissue – net of reticular cells and reticular fibers
- hematopoietic cells
- macrophages
- adipose cells
- blood sinusoids

Erythropoiesis

- Proerythroblast
- Basophilic erythroblast
- Polychromatophilic erythroblast
- Orthochromatic erythroblast
- Reticulocyte

Processes of erythropoiesis

During repeated mitoses:

- ☞ cell size decreases from 20 μm to 8 μm in diameter
- ☞ condensation of nuclear chromatin, nucleoli disappear, nucleus will be extruded - enucleation
- ☞ hemoglobin production
- ☞ transformation of cytoplasm staining – from basophilia (caused by ribosomes) to acidophilia (caused by hemoglobin production)

Proerythroblast

- \varnothing 15 – 20 μm
- basophilic cytoplasm forms irregular, „ear-shaped“ projections from the surface of the cell
- spherical nucleus contains 2 – 3 nucleoli

Basophilic erythroblast

- \varnothing 16 μm
- basophilic cytoplasm
- condensation of nuclear chromatin begins
- absence of nucleoli

Polychromatophilic erythroblast

- \varnothing 12 μm
- production of hemoglobin begins and causes irregular staining of cytoplasm – partly basophilic, partly acidophilic
- condensed chromatin

Orthochromatophilic erythroblast

- \varnothing 9 – 10 μm
- acidophilic cytoplasm with hemoglobin
- pyknotic nucleus in excentric position before enucleation

Reticulocyte

- \varnothing 8 μm
- acidophilic cytoplasm with hemoglobin
- without nucleus, but with the rests of some organelles – substantia reticulofilamentosa

Granulopoiesis

Myeloblast

- Promyelocyte
- Myelocyte – *neutrophilic - eosinophilic - basophilic*
- Metamyelocyte – *neutrophilic - eosinophilic - basophilic*

Processes of granulopoiesis

During repeated mitoses:

- ☞ cell size decreases from 20 μm to 10-14 μm in diameter (except promyelocyte)
- ☞ condensation of nuclear chromatin, transformation of nucleus shape (from spherical to band)
- ☞ production of specific granules
- ☞ transformation of cytoplasm staining – from basophilia (caused by ribosomes) to acidophilia (caused by production of specific granules)

Myeloblast

- \varnothing 20 μm
- light, basophilic cytoplasm
- round nucleus with fine chromatin structure and 2 – 5 nucleoli

Promyelocyte

- \varnothing 25 – 30 μm
- light, basophilic cytoplasm with azurophilic granules
- D-shaped nucleus with nucleoli

Myelocyte - neutrophilic, eosinophilic, basophilic

- \varnothing 15 – 20 μm
- light, acidophilic cytoplasm
- production of specific granules (*neutrophilic, eosinophilic, basophilic*)
- kidney-shaped nucleus – condensed chromatin, without nucleoli

Metamyelocyte - neutrophilic, eosinophilic, basophilic

- \varnothing 15 μm
- acidophilic cytoplasm with specific granules (*neutrophilic, eosinophilic, basophilic*)
- nucleus has shape of „thick band“ and condensed chromatin

Lymphocytopoiesis and monocytopoiesis

Lymphocytoblast

- Prolymphocyte

■ Monocytoblast

■ Promonocyte

Thrombopoiesis

- Megakaryoblast - \varnothing 20 μm
- Promegakaryocyte - \varnothing 40 - 50 μm
- Megakaryocyte - \varnothing 80 - 100 μm

Endomitosis – repeated mitoses without karyokinesis and cytokinesis give rise to the large, polyploid cell - megakaryocyte

Megakaryocyte

Cardiovascular system

The cardiovascular system consists of the heart and blood vessels. The heart acts as a pump to circulate the blood. The heart pumps blood by contracting and relaxing the muscles which line the heart walls, squeezing blood out and then letting new blood in.

The circulatory system consists of two distinct circuits which allow for oxygen transport to body cells, and CO₂ removal via the lungs. The cycle through the lungs, where blood is enriched with oxygen, is known as the **pulmonary cycle**; the cycle through the body, where blood supplies all the cells with oxygen and picks up carbon dioxide, is called the **systemic cycle**. It is crucial for the heart to keep the two cycles separate, so heart is divided into the right and the left halves, which have no direct connections whatsoever. The right half is responsible for the pulmonary cycle and the the left - for the systemic. The two halves are each divided into two chambers: the ventricle and the atrium. Blood comes into the heart through the atria and leaves through the ventricles.

Endothelium

The **endothelium** is the layer of thin, flat **cells** that lines the interior surface of **blood vessels** and heart, forming an interface between circulating **blood** in the **lumen** and the rest of the vessel wall. Endothelial cells line the entire **circulatory system**, from the **heart** to the smallest **capillary**. In small blood vessels and capillaries, endothelial cells are often the only cell-type present. Endothelial cells are involved in many aspects of vascular biology, including:

- **vasoconstriction & vasodilation**, and hence the control of **blood pressure**
- **blood clotting (thrombosis & fibrinolysis)**
- **atherosclerosis**
- formation of new blood vessels (**angiogenesis**)
- **inflammation** and swelling (**edema**)

Endothelial cells also control the passage of materials — and the transit of **white blood cells** — into and out of the bloodstream. In some organs, there are highly differentiated endothelial cells to perform specialized 'filtering' functions. Examples of such unique endothelial structures include the **renal glomerulus** and the **blood-brain barrier**. Endothelial tissue is a specialized type of **epithelium** tissue – specialized type of **simple squamous epithelium**.

Passage and transport of substances through the endothelium is realized by pinocytosis and an occurrence of numerous pinocytic vesicles in the cytoplasm of endothelial cells is a morphological picture of this process.

Blood vessels

Blood vessels are divided into three groups: **arteries**, **veins**, and **capillaries**. Arteries and veins are further divided, according to size, into **large**, **medium**, and **small** blood vessels. The smallest arteries and veins are named **arterioles** and **venules** and the atypical capillaries are named **sinusoidal capillaries** or **sinusoids**. The vascular system is subjected to varying degrees of hydrostatic pressure, and the structure of vessels varies in an adaptive fashion. Blood vessels are thickest and their walls more complex in the immediate vicinity of the heart, where hydrostatic pressure is greatest. As blood vessels decrease in size their wall becomes thinner and less complex.

Capillaries

Capillaries are very small vessels. Their diameter ranges from 4-15 μm and their wall is composed primarily of endothelium and the basement membrane upon which the endothelium rests. The wall of capillary may be formed by a single endothelial cell. The low rate of blood flow and large surface area facilitate the functions of capillaries:

- providing nutrients and oxygen to the surrounding tissue,
- the absorption of nutrients, waste products and carbon dioxide,
- the excretion of waste products from the body.

These functions are also facilitated by a very simple organisation of the wall of capillaries. **Only the tunica intima is present**, which typically only consists of the endothelium, its basal lamina and an incomplete layer of cells surrounding the capillary, the **pericytes**.

Capillaries may be of three types: **continuous**, **fenestrated** and discontinuous (**sinusoidal capillaries**).

Continuous capillaries

- are the most common type
- are formed by "continuous" endothelial cells and basal lamina. The endothelial cell and the basal lamina do not form openings, which would allow substances to pass the capillary wall without passing through both the endothelial cell and the basal lamina. Both endothelial cells and the basal lamina can act as selective filters in continuous capillaries.

The examples of continuous capillaries: in muscle tissue

Pericytes may be found in association with the endothelium of certain continuous capillaries. They have thin cytoplasmic processes enveloping the capillary. The pericyte when present is enclosed by a basal lamina that is continuous with the endothelium. It is a relatively unspecialized cell that is derived from the same precursor cells that form endothelial cells in new vessels and can give rise to smooth muscle cells during vessel growth. Pericytes have contractile properties and can regulate blood flow in capillaries. In the course of vascular remodelling and repair, they can also differentiate into endothelial and smooth muscle cells.

Function of pericytes:

- synthesize components of vascular basal lamina
- regulate microvascular angiogenesis
- provide mechanical support for capillarie

by contraction: modulate blood flow and pressure and regulate permeability of capillary wall

Fenestrated capillaries

The endothelial cell forms **small** openings called fenestrations, which allow components of the blood and interstitial fluid to bypass the endothelial cells on their way to or from the tissue surrounding the capillary. The extent of the fenestration may depend on the physiological state of the surrounding tissue, i.e. fenestration may increase or decrease as a function of the need to absorb or secrete. The endothelial cells are surrounded by a continuous basal lamina, which can act as a selective filter.

The examples of fenestrated capillaries: in the gastrointestinal mucosa, in certain endocrine glands, and in the renal glomeruli.

Discontinuous capillaries (sinusoidal capillaries or sinusoids)

are larger and more irregularly shaped than other capillaries. They are thin-walled blood vessels lined by endothelial cells. The lumen is irregular in shape and up to about 40 µm in diameter. The specialized phagocytic cells (e.g. Kupffer cells of the liver) belong to the reticuloendothelial system (RES) or monocyte-macrophage system of the body. Unusually wide gaps are present between the endothelial cells that permit leakage of material into and out of these vessels. There may be partial or complete absence of the basal lamina underlying the endothelium.

The examples of fenestrated capillaries: they are found where a very free exchange of substances or even cells between bloodstream and organ is advantageous (e.g. in the liver, spleen, and red bone marrow).

Arteries and veins

The wall of arteries and veins of large or medium caliber have three tunics: **tunica intima (interna)**, **tunica media**, and **tunica adventitia (externa)**.

General structure of tunics

- **tunica intima** – the endothelial lining with its basal lamina and subendothelial layer with longitudinally oriented elastic fibers
- **tunica media**
 - in artery more than in veins: spirally and circularly oriented connective tissue fibers organized into elastic fenestrated membranes and smooth muscle cells, the ratio of smooth muscle cells and elastic membranes depends on the type of blood artery
- **tunica adventitia** – contains collagen and elastic fibers, scattered fibroblasts.
 - in vein more than in arteries: longitudinally oriented bundles of smooth muscle cells, surrounded with connective tissue

The tunica adventitia contains small blood vessels (**vasa vasorum**), which supply nutrients to tissues in the outer one-half of the wall of the blood vessel. Small nerves (**nervi vasorum**), representing fibers of the autonomic nervous system, are also present in the tunica adventitia and they innervate the smooth muscle of the vessel. Elastic laminae – inner and outer – separate tunics in the vessel wall. These laminae (membrana elastica interna et externa) are made up of elastic fibers. Inner membrane separates intima from media and outer one separate media from adventitia. Outer membrane is not usually distinct in all veins and small arteries.

Generally, the wall of artery is thicker than the wall of the vein of the same calibre and the thickest layer is tunica media in artery and tunica adventitia in vein.

Arterioles and venules

(the smallest arteries and veins)

Arterioles

Arterioles are the smallest part of the arterial tree. These vessels regulate the flow of blood into capillaries, which in turn, drain into venules, the first component of the venous system. Histologically, **tunica intima** of an arteriole is composed of endothelial cells lying on a basal lamina. **Tunica media** has either scattered smooth muscle cells or a single complete layer of smooth muscle (in 1-5 layers) around the endothelial tube. The elastic tissue forms an elastic net rather than an internal elastic membrane. Reticular fibers and collagenous fibers surround individual smooth muscle fibers and condense externally to form the **tunica adventitia**. Arterioles can be distinguished from small arteries by the number of smooth muscle layers in the tunica media layer and the tunica intima of a small artery has an internal elastic membrane.

Venules

Capillaries drain into postcapillary venules, which are the smallest venules (~10 - 25µm in diameter). They resemble capillaries in structure, but contain more pericytes. Postcapillary venules drain into large collecting venules (~20-50µm in diameter). Here the pericyte layer becomes more continuous and is surrounded by collagen fibers. As the venules increase in diameter, smooth muscle cells replace the pericytes and form a layer that is 1 to 2 cells in thickness. The lumen is usually larger and the wall is thinner in the venule than in the arteriole. The wall of the venule lacks distinct layers.

Small arteries and small veins

The arteries possess three tunics, which vary in thickness, but there must be at least two layers of smooth muscle for it to be classified as a small artery. Intimal, medial and adventitial layers are present in veins but they are not as clearly demarcated as in arteries. The veins contain an elastic net and some smooth muscle fibers separated by connective tissue. In comparison to arteries, veins have a larger lumen and a relatively thinner wall. Therefore, they appear collapsed in histologic sections.

Medium arteries and medium veins

Medium sized arteries are often referred to as **muscular arteries** because they have more smooth muscle in their tunica media than so the small and large arteries. These arteries contain a prominent internal elastic membrane that separates intima from the smooth muscle layer of the media. The tunica media consists of smooth muscle cells and collagen fibers. The smooth muscle cells are arranged in a spiral fashion such that when they contract, they assist in maintaining blood pressure. The media layer is separated from the adventitial layer by an external elastic membrane.

Medium-sized veins are 1-10mm in diameter and they have an endothelial layer that sits on a basal lamina. An indistinct condensation of elastic fibers that produce a thin, discontinuous internal elastic lamina is separated from the endothelial layer by a narrow zone of collagen fibers. Together these three components comprise the inner layer of a small vein. The outer layers, the tunica media and adventitia, vary considerably in thickness due to the proportions of collagen fibers, elastic fibers and smooth muscle present within them.

Large arteries and large veins

Large arteries = Elastic arteries (examples: **aorta** and pulmonary arteries, the immediate branches of these arteries are also considered to be elastic arteries – brachiocephalic, common carotids, etc.). have sheets of elastic tissue in their walls and are the largest diameter arteries. They are subjected to high systolic pressures. These large vessels are also adapted to smooth out the

surges in blood flow since blood only flows through them during systole. The elastic tissue in their tunica media provides the resilience to smooth out this pressure wave.

The tunica intima is relatively thick and consists of an endothelial layer with its basal lamina, a subendothelial layer of connective tissue and an internal elastic membrane. The internal elastic membrane is not as conspicuous because it is one of the many elastic membranes in the wall of the arteries. It is usually only identified because it is the innermost of the elastic layers of the arterial wall. The tunica media is the thickest of the three layers. The numerous, thick, fenestrated elastic membranes are the predominant substance of the media. They are interconnected by fine elastic fibers and also by smooth muscle cells, which spirals at a slight angle to the transverse axis of the vessel. The smooth muscle cells is surrounded by reticular fibers and a few collagenous fibers. In elastic arteries, the tunica adventitia is relatively thin – half the thickness of the media – and contains collagen fibers, elastic fibers and connective tissue cells (fibroblasts and macrophages). The tunica adventitia contains blood vessels (*vasa vasorum*) and nerves (*nervi vasorum*) that supply the blood vessel wall.

Large veins (examples: **vena cava**, subclavian veins)

In large veins, the tunica media is relatively thin and consists of an endothelial lining with its basal lamina, a small amount of subendothelial tissue and some smooth muscle cells. Thin tunica media contains sparse, circularly arranged smooth muscle. Also present are collagen fibers and some fibroblasts. The most obvious feature is the thickness of the tunica adventitia. In large veins, large bundles of longitudinal disposed smooth muscle cells are found with the usual collagen and elastic fibers.

HEART

The heart is a pump with four chambers and valves that maintain a one-way flow of blood. The wall of the heart includes: (1) cardiac musculature for contraction to propel the blood out of each chamber and into the major vessels, (2) a fibrous skeleton for attachment of the valves and (3) an internal conducting system for synchronization of muscle contraction.

○ **Endocardium**

- Endothelium – simple squamous epithelium on basal lamina
- Subendothelial layer – connective tissue fibers (elastic, fine collagenous)
- Subendocardial layer – connective tissue with Purkinje fibers

Purkinje Fibers – conducting cardiomyocytes

Purkinje fibers are modified cardiac muscle fibers **found in the subendocardium** of the ventricles. They constitute part of the **specialized impulse conducting system**, which connects to the right and left bundle branches and regulates the heartbeat. These are **large muscular fibers** with a vacuolated cytoplasm due to the **high glycogen content**. Other characteristics that help distinguish Purkinje fibers from typical cardiac muscle fibers are that they contain fewer myofibrils, and more sarcoplasm.

○ **Myocardium**

- **Epicardium** – visceral layer pericardium
- **Pericardium** – parietal layer pericardium
- **Pericardial space** between epi- and pericardium
- **Cardiac (fibrous) skeleton**
 - anuli fibrosi
 - trigona fibrosa

- septum membranaceum

The fibrous skeleton is comprised of **dense connective tissue** that encircles the base of the two arteries leaving the heart and the openings between the chambers. It serves as an attachment for cardiac muscle and the cuspid valves of the atria and ventricles. It also serves as an attachment site for the semilunar valves of the aorta and the pulmonary artery. The atrioventricular (A-V) bundle passes from the right atrium to the ventricular septum via the fibrous skeleton. See Figure 36 below.