

Female genital tract

V. Žampachová
I. ÚP LF MU



FLORA of the REPRODUCTIVE SYSTEM

- *Lactobacillus, Streptococcus, Corynebacterium, Mycobacterium.*
- *Candida albicans*
- The flora occupies the external genitalia. Internal reproductive structures normally remain sterile.



Genital tract infections

- Genital tract – open to the outside, barriers necessary
- **Barrier function** - vaginal flora, endocervical mucus
- **Predisposing factors** – nonexistent barrier (age), barrier defect (loss of protective vaginal flora, menstruation, abortion, delivery + residua, instrumentation and other mucosal microtraumata, systemic diseases, drugs,...)



Genital tract infections

- **Ascending infection** most usual (STD, G- fecal bacteria – E. coli, Proteus,...)
- Lower genital tract (**STD** – HSV, molluscum contagiosum, HPV, trichomonas, chancroid, granuloma inguinale; **endogenous** – candida)
- Entire genital tract (**STD** – gonorrhea, chlamydia, mycoplasma, syphilis; **endogenous** – enteric bacteria), may end in PID



The Female Reproductive System

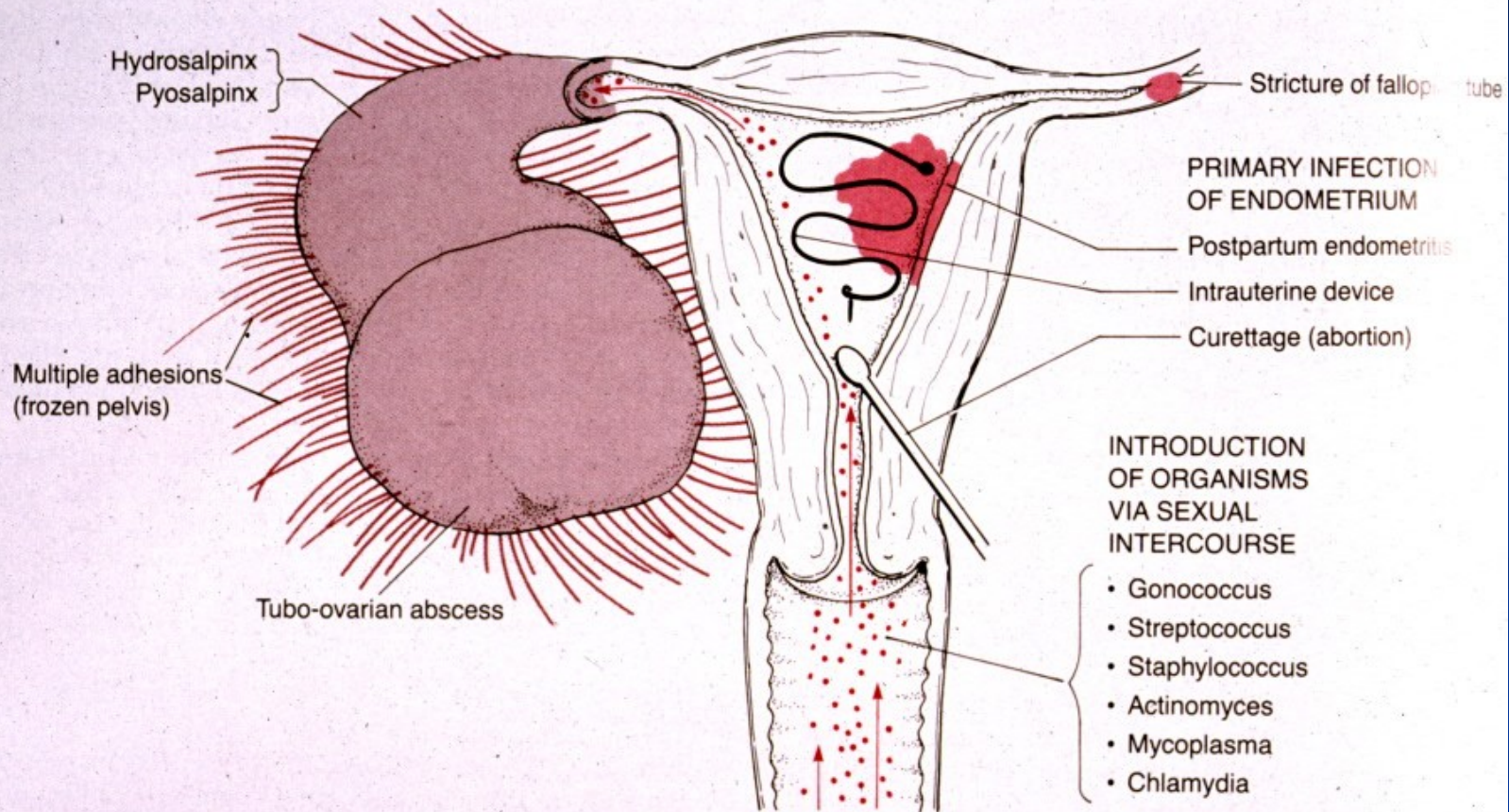
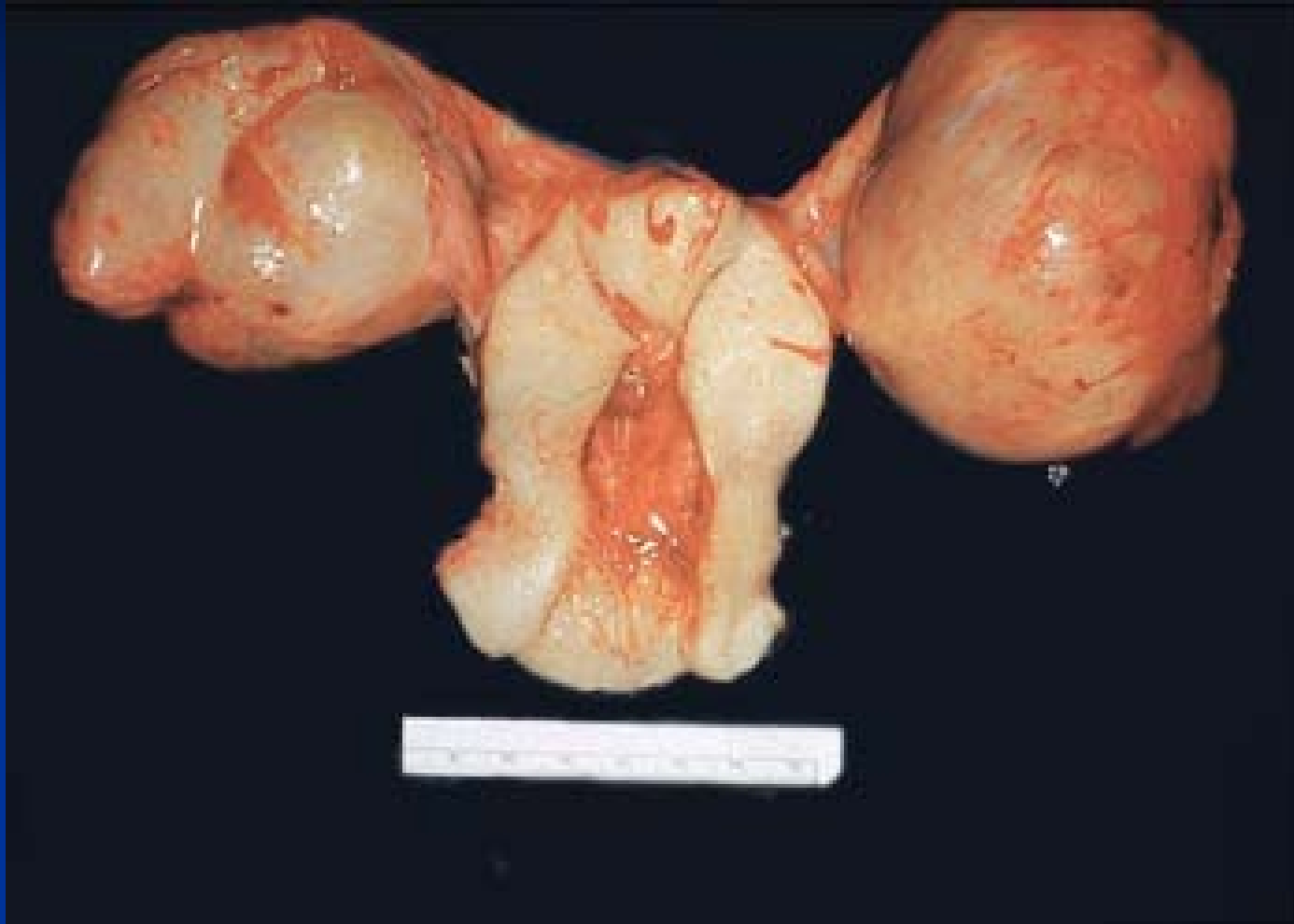

FIGURE 18-2
Pelvic inflammatory disease.

Robbin's Pathologic Basis of
Disease



Acute endometritis and salpingoophoritis



Sexually Transmitted Infections

- Sexually Transmitted Disease – **STD/STI**
- Infection transmitted through vaginal, anal or oral sex
- Every sexually active individual is at risk
- Women acquire infections from men more than men from women
- 2/3 of STD occur in people under 25 yrs of age
- Infection by multiple agents common (↑ risk)
- Fetus or infants – vertical transplacental or perinatal transmission of STD → abortus, inborn defects, neonatal infection. Diagnosis + treatment!!



STI

ascending inf.: endometritis, salpingitis, PID



■ sexual partner → horizontal transmission → STI



vertical transmission: placenta (fetus, neonate)

STD

- **Viruses:** HSV, HPV, HIV, hepatitis B, C
- **Chlamydiae:** Ch. trachomatis
- **Mycoplasmas:** M. urealyticum (urethritis)
- **Bacteria:** Neisseria gonorrhoeae, Treponema pallidum, Haemophilus ducreyi (chancroid), Klebsiella granulomatis (granuloma inguinale)
- **Protozoa:** Trichomonas vaginalis (urethritis, balanitis, vaginitis)

Genital herpes

- About a week after exposure, painful red, fluid-filled blisters in the genital area (vagina, labia, cervix, penis, anus)
- Blisters filled with clear fluid containing the virus, highly contagious
- Rupture → ulcers may last up to 6 weeks
- The first outbreak - the first episode infection
- Subsequent episodes (recurrent infections) usually less severe



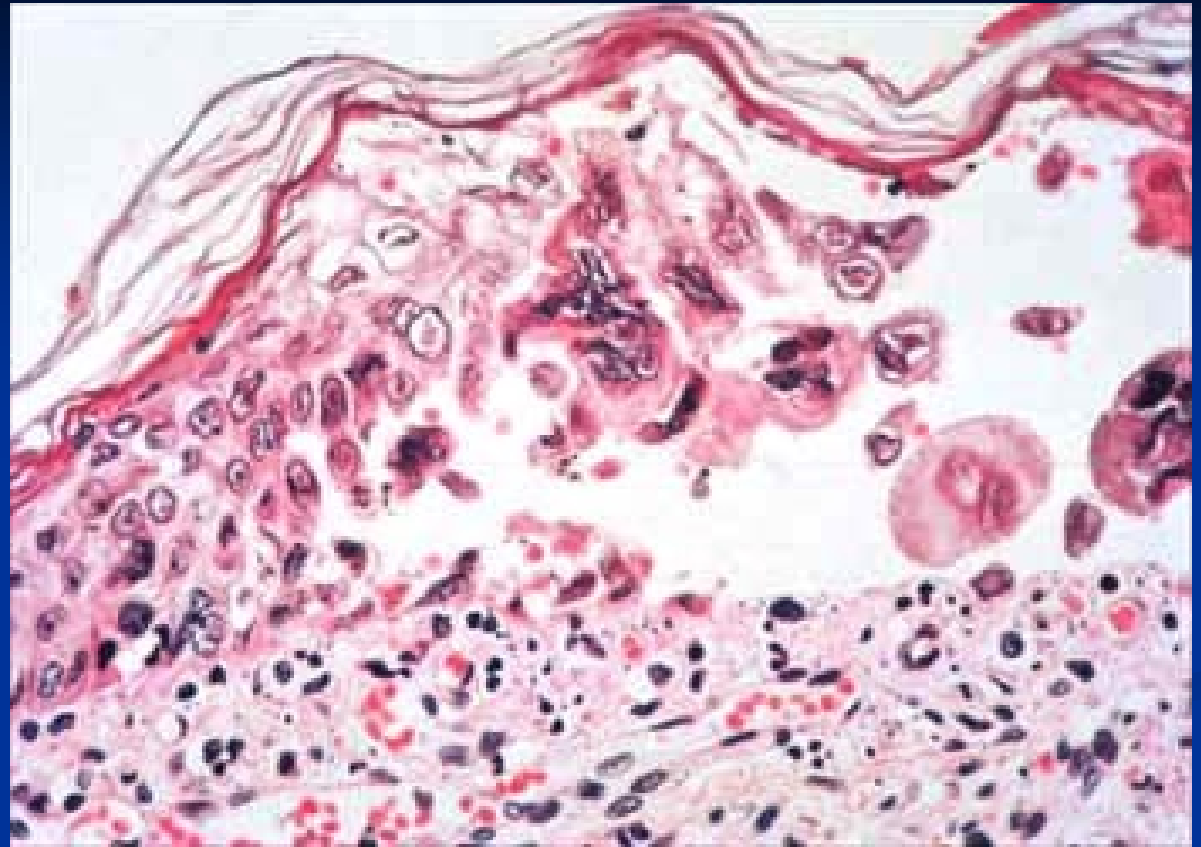
Genital herpes

- Latency period, no symptoms, the virus may be shed, patient infectious
- The virus dormant in nerve fibers in the spinal cord in between outbreaks
- In active stage, mostly in primoinfection → high risk of the newborn infection during delivery → haemorrhagic herpetic encephalitis

Genital herpes

- Prodromal symptoms: burning, itching, tingling or throbbing
- Pain may radiate to the legs, thighs, groin or buttocks; patient may be more infectious during the prodromal period
- Recurrent infections- herpetic lesions reappear, general malaise, headache, fever, dysuria, urinary retention, vaginal/urethral discharge may occur

HSV

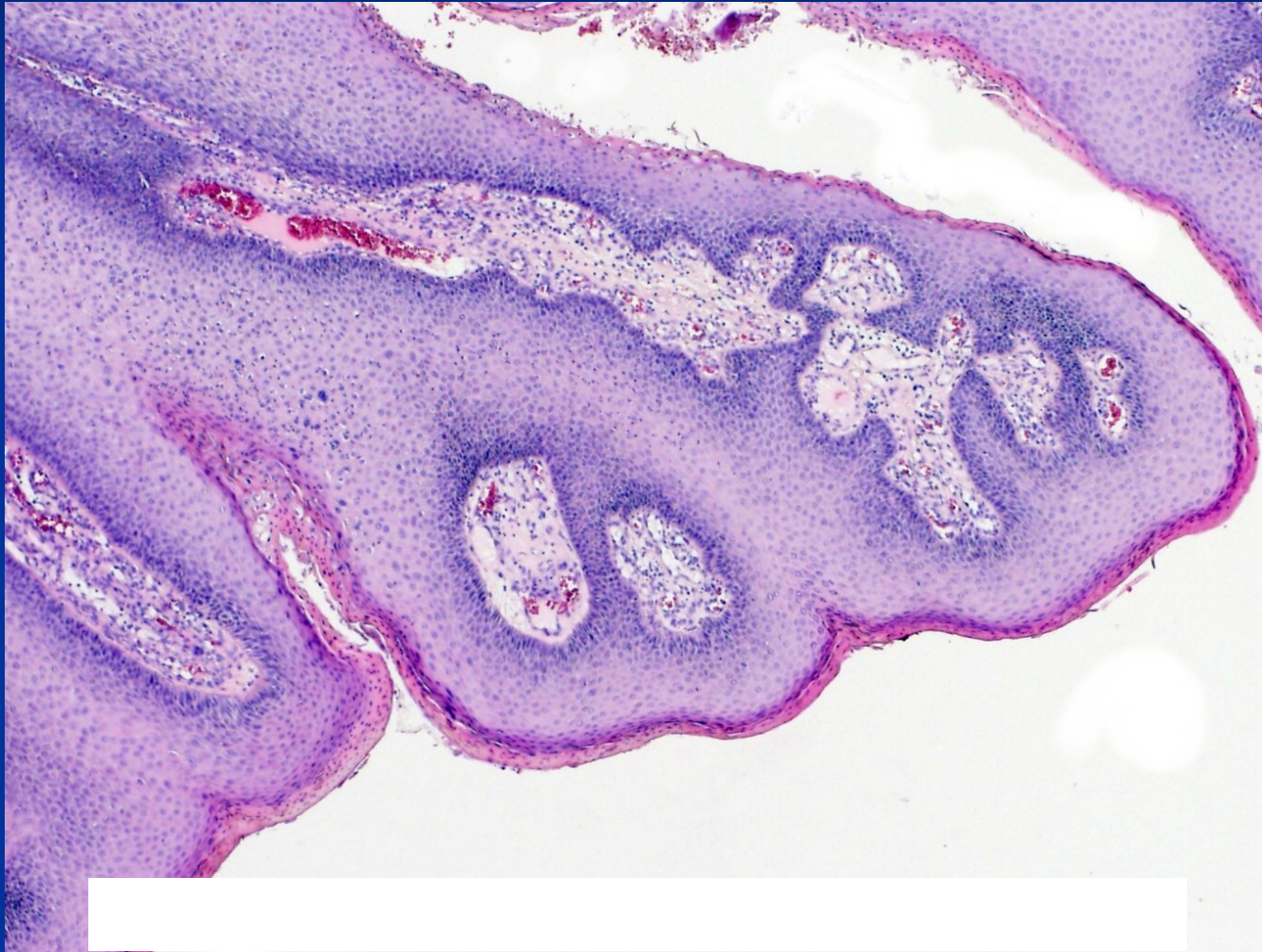


Genital warts

- Condyloma acuminatum - HPV
- Most HPV infections asymptomatic or unrecognized
- Mostly found in young, sexually active; associated with early onset of sexual activity, multiple sexual partners
- Transmitted by all types of sexual contact
- Usually cleared from host's organism
- Vaccination (already ↓ in low risk types manifestations – LSIL)



Condyloma acuminatum



Genital warts

- May be asymptomatic; single or multiple painless cauliflower-like growths on the vulva, vagina, perineum, urethra, cervix, anus
- Productive infection – low risk types (6, 11)
- Other subtypes of HPV (i.e. 16, 18) strongly associated with cervical dysplasia and/or carcinoma
- HPV - higher risk of vaginal, vulvar, penile, anal dysplasia/carcinoma
- Some types in oral/laryngeal carcinoma

Genital warts: complications

- Possible urethral obstruction or destruction of normal tissue
- Can be transferred to fetus during pregnancy or delivery
- Large warts may obstruct the birth canal; cesarean section may be necessary
- Infants infected may develop a chronic respiratory condition – laryngeal papillomatosis

Chlamydia: manifestations

- In females often asymptomatic until uterus and tubes infected; may present with dysuria, urinary frequency, vaginal discharge
- (1/3 of males may be asymptomatic; dysuria, urethral discharge, testicular pain)
- Patient infectious even if asymptomatic

Chlamydia: complications

- May result in PID (pelvic inflammatory disease)
- Major cause of infertility, ectopic pregnancy in women; may cause stillbirth or spontaneous abortion (miscarriage)
- (In males may result in epididymitis, prostatitis, sterility, Reiter's syndrome)
- In neonates may cause blindness, pneumonia

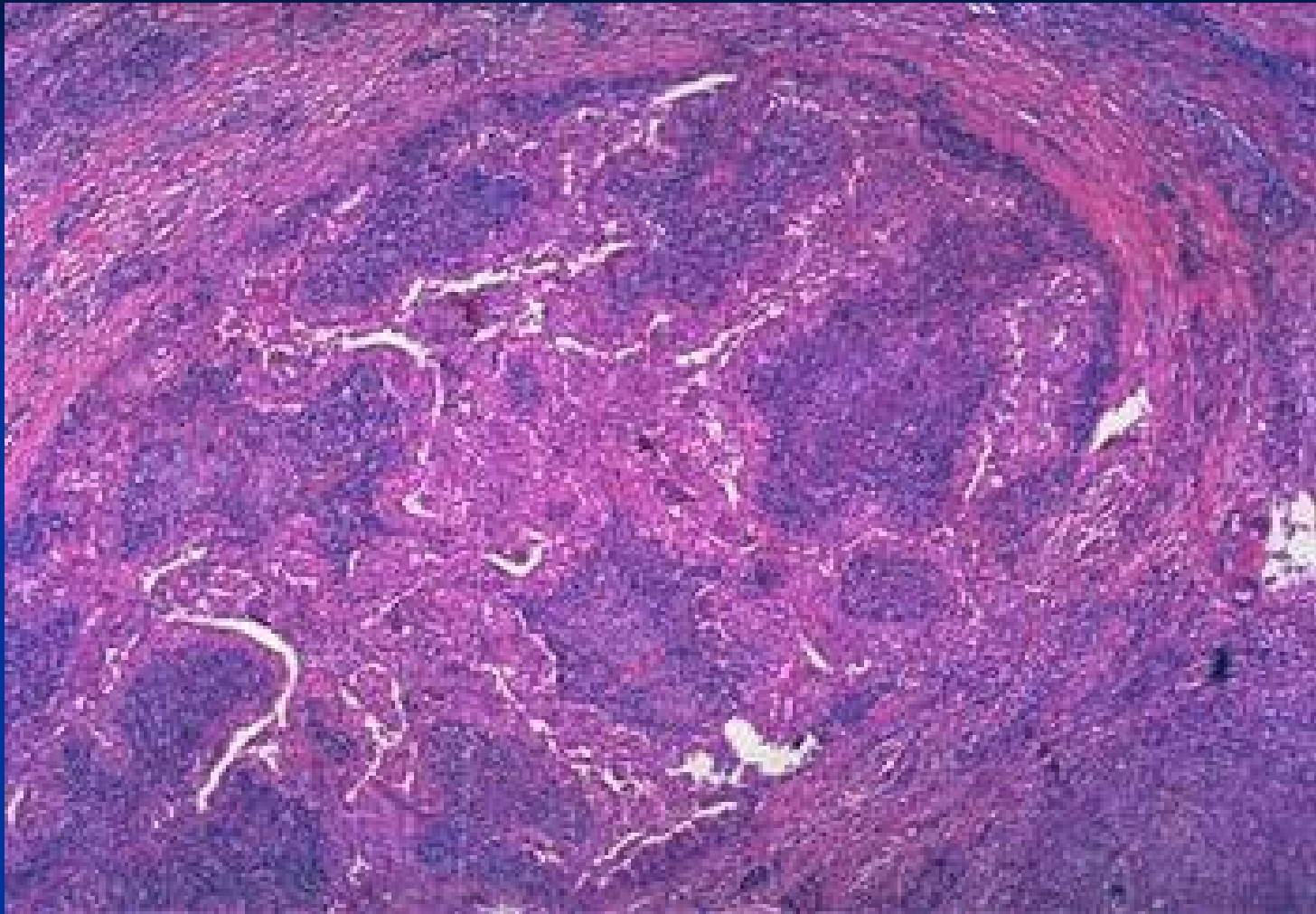
Gonorrhoea

- ‘clap’; one of the most common STDs (second only to Chlamydia)
- Caused by *Neisseria gonorrhoeae*; incubation period is 2-8 days
- Transmitted by sexual contact, during passage through the birth canal
- Usually targets the cervix, (male urethra)



Gonorrhoea

- Female: mostly asymptomatic until advanced disease; dysuria, urinary frequency or abnormal vaginal discharge
- (Male: dysuria, serous, milky or purulent urethral discharge; regional lymphadenopathy)
- Complications: (prostatitis, epididymitis, sterility); PID, endometritis, salpingitis, peritonitis; in neonates gonorrhoea can infect the eyes, nose or anorectal region



Purulent salpingitis - gonorrhoea

Syphilis

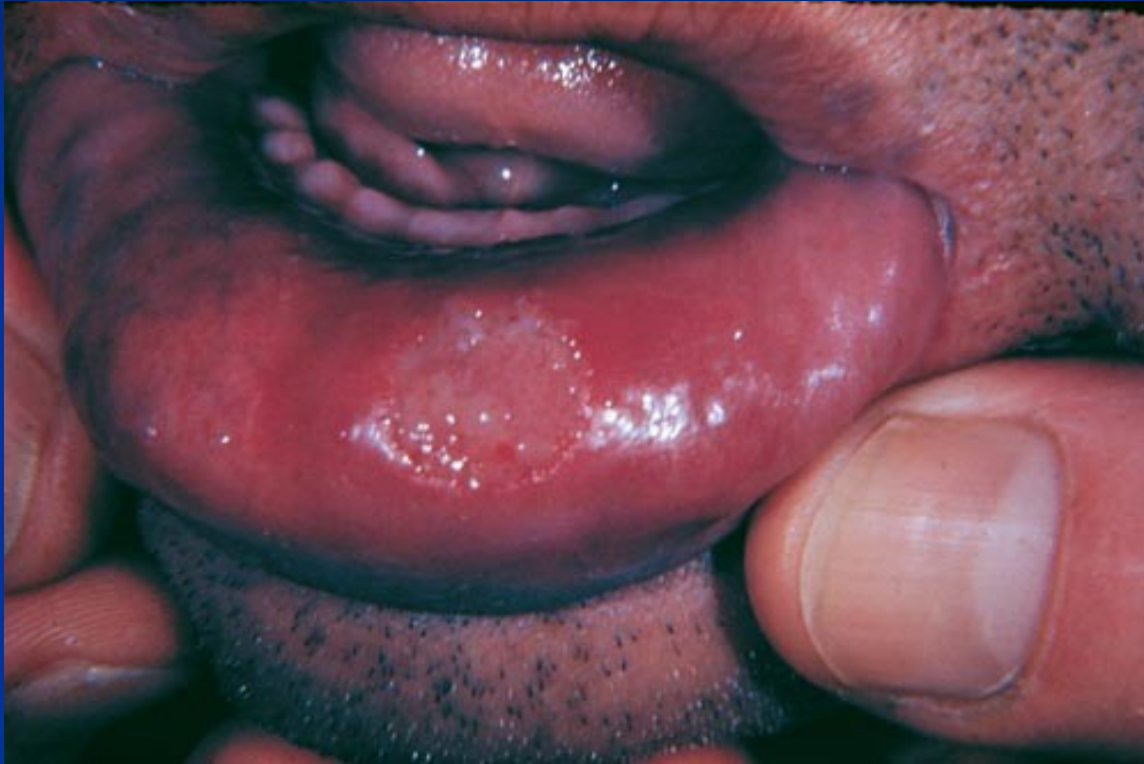- Spirochete *Treponema pallidum*
- Transmitted from open lesions during sexual contact
- Organism can survive days in fluids
- May also be transmitted by infected blood, body fluids, including saliva
- Average incubation is 20-30 days
- Spreads through blood, lymphatic system
- Congenital syphilis - transplacental

Syphilis: primary stage

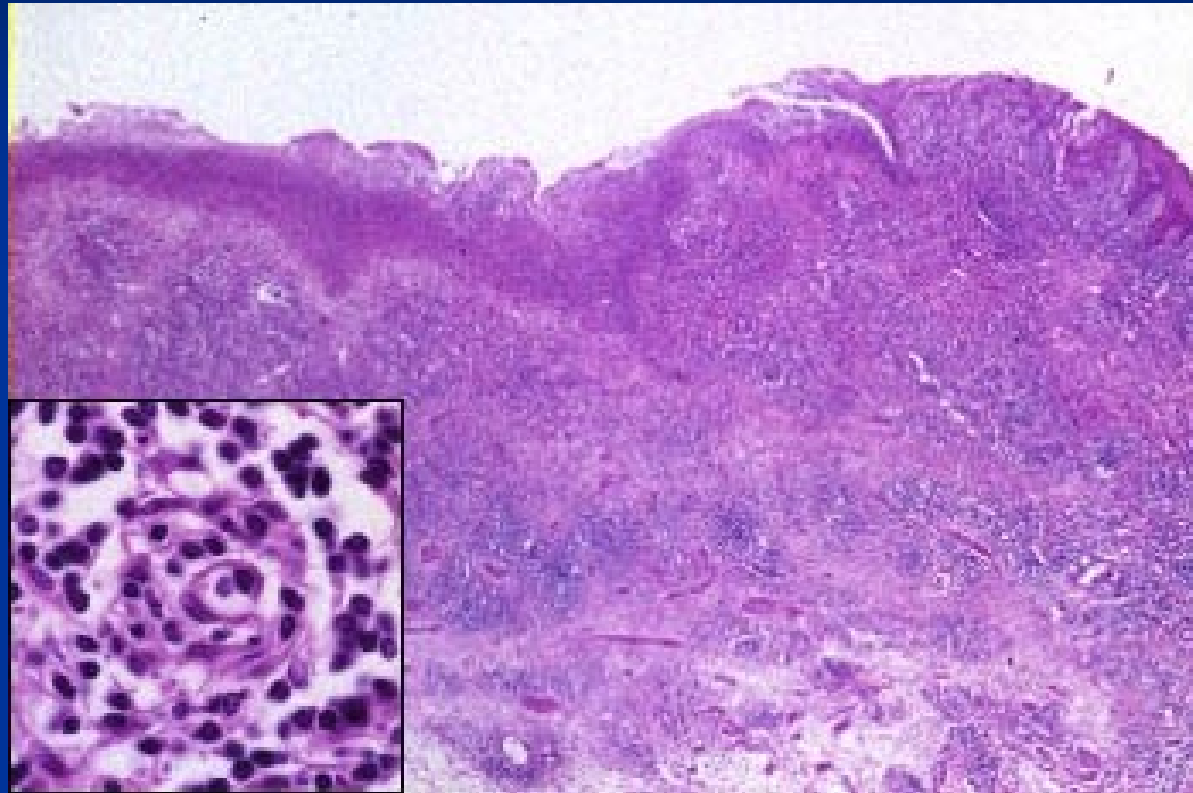
- **Chancre:** painless ulcer in the site of inoculation; regional lymphadenopathy
- chancre appears 3-4 weeks after infectious contact, disappears within 4-6 weeks
- Chancre may go unnoticed in women
- Highly infectious during primary stage even if no symptoms are present
- Micro: nonspecific, high amount of plasma cells in inflammatory infiltrate



Syphilis – primary



Syphilitic chancre – plasma cells in infiltrate

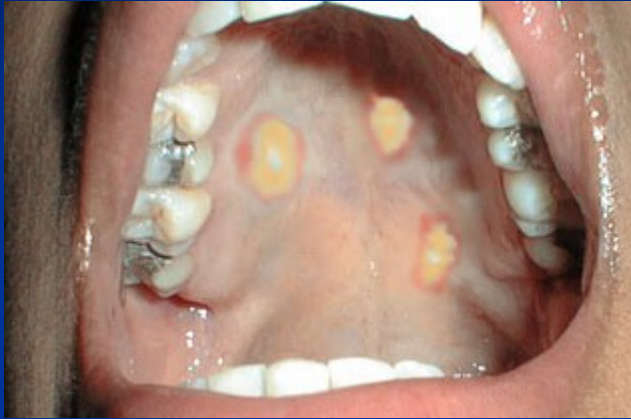

Syphilis: secondary stage

- Symptoms of secondary syphilis appear any time from 2 weeks to 6 months after initial chancre disappears, in 75% of untreated people
- **Primary generalisation**, flu-like symptoms, sore throat; generalized lymphadenopathy
- **Skin rash** (especially on palms of hands and soles of feet) maculopapular, pustular;
- **condylomata lata** - mucus patches + erosions in oral cavity; flat, broad-based wart-like papules on labia, anus or corner of mouth, **highly infectious**; secondary alopecia
- Disappears within 2-6 weeks

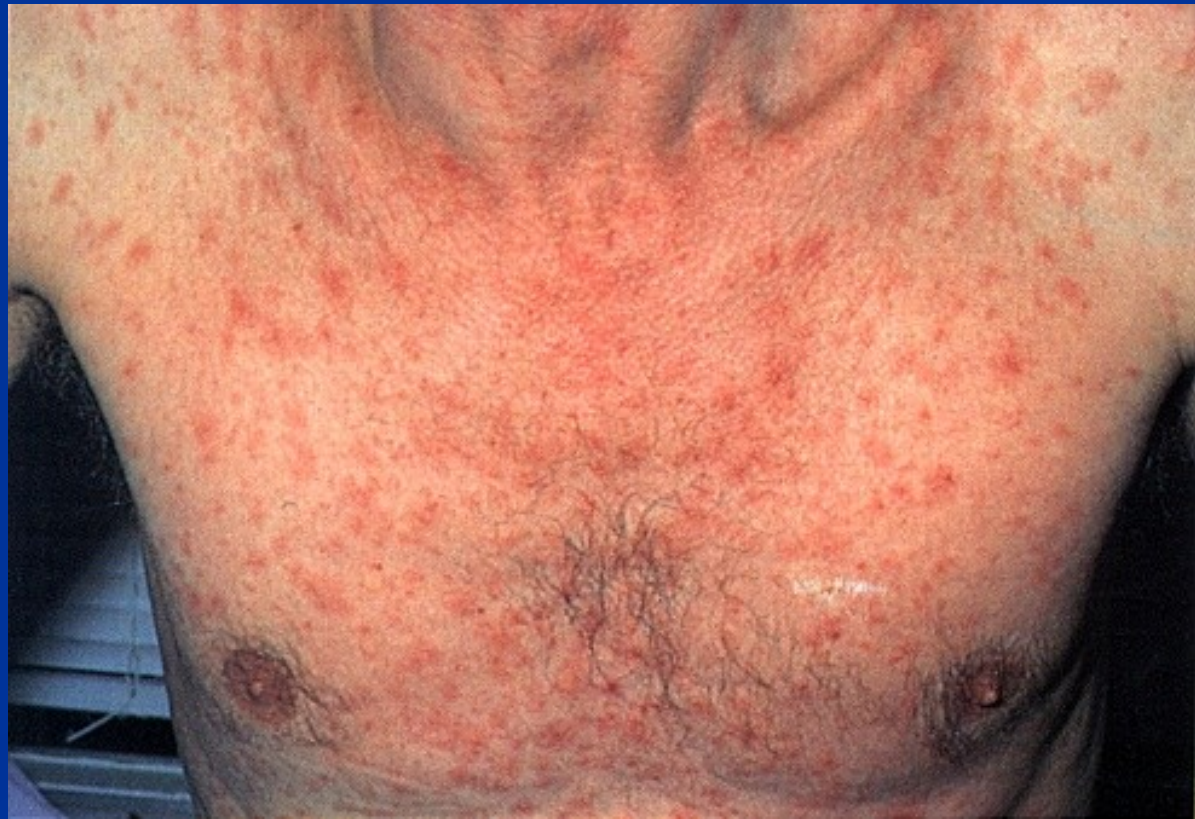

Syphilis - secondary



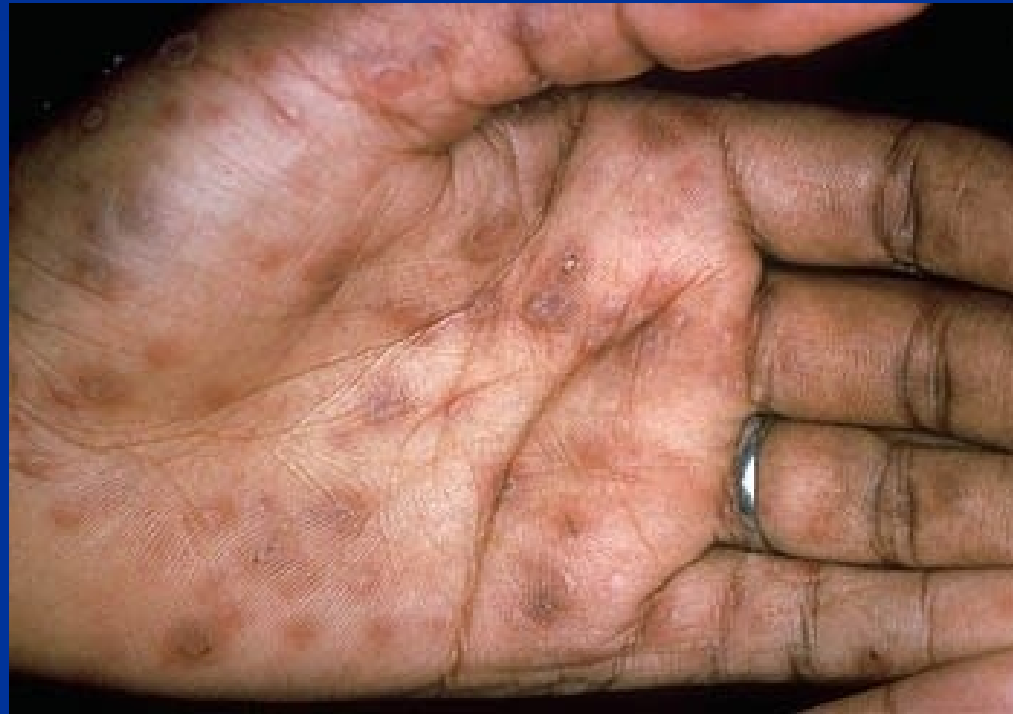Condylomata lata

Syphilitic rash



Syphilis

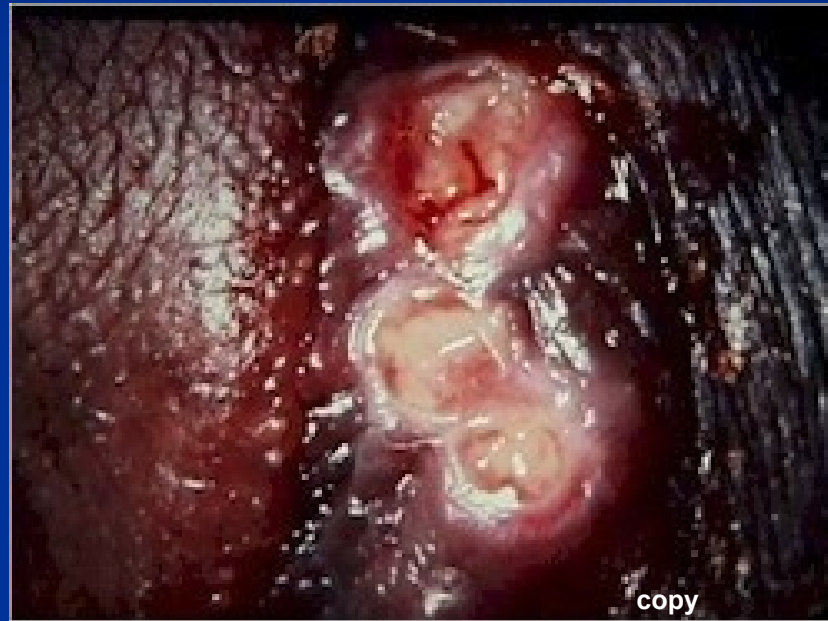- secondary stage – early generalisation



Chancroid (Soft chancre)

- *Hemophilus ducreyi*
- Mostly tropical and subtropical areas
- HIV co-transmission
- Four to seven days after infection: tender, erythematous papule → irregular ulcer
 - More painful in males; not indurated; multiple; on external genitalia
 - Inguinal lymph nodes are enlarged and tender (buboes)
- Micro: nonspecific ulcer, superficial zone of neutrophilic debris and fibrin, underlying zone of granulation tissue, lymphoplasmacytic infiltrate

Chancroid



Granuloma inguinale (Donovanosis)

Klebsiella granulomatis (*Calymmatobacterium donovani*)

tropical and subtropical areas

Gross: papular lesion (on genitalia) → ulcer

Ulcer : protuberant, soft, painless mass; borders raised and indurated; abundant granulation tissue; mimicking carcinoma
(**pseudoepitheliomatous hyperplasia**)

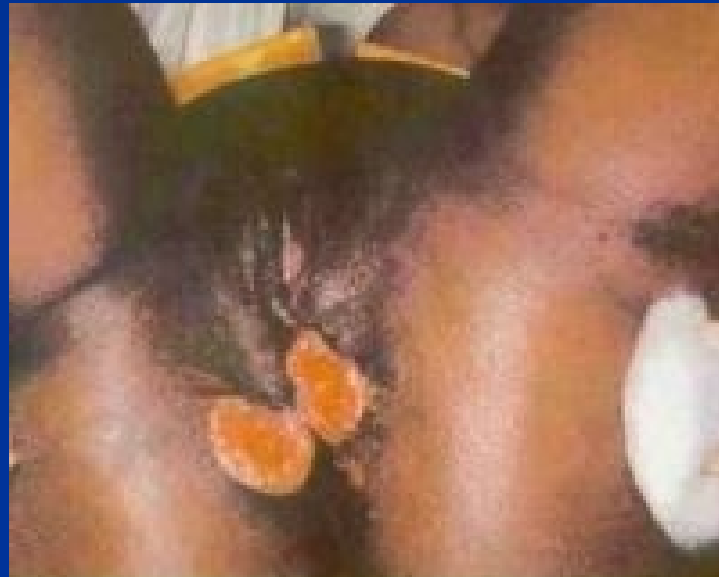Micro: silver stains (e.g., the Warthin-Starry stain): encapsulated coccobacilli (Donovan bodies) in macrophages

lymph nodes typically spared (unlike chancroid)

Complications: extensive scarring + lymphatic obstruction, possible lymphedema (elephantiasis)

Scars in untreated cases → urethral, vulvar, or anal strictures

Donovanosis (granuloma inguinale)



Granuloma Inguinale
(GI) copy

Pathology of ovaries

- Pathological lesions: morphological, functional, commonly both
- Signs: commonly late, nonspecific (menstruation cycle and/or fertility disturbances, pelvic pain, abdominal distention) → late diagnosis



Pathology of ovaries

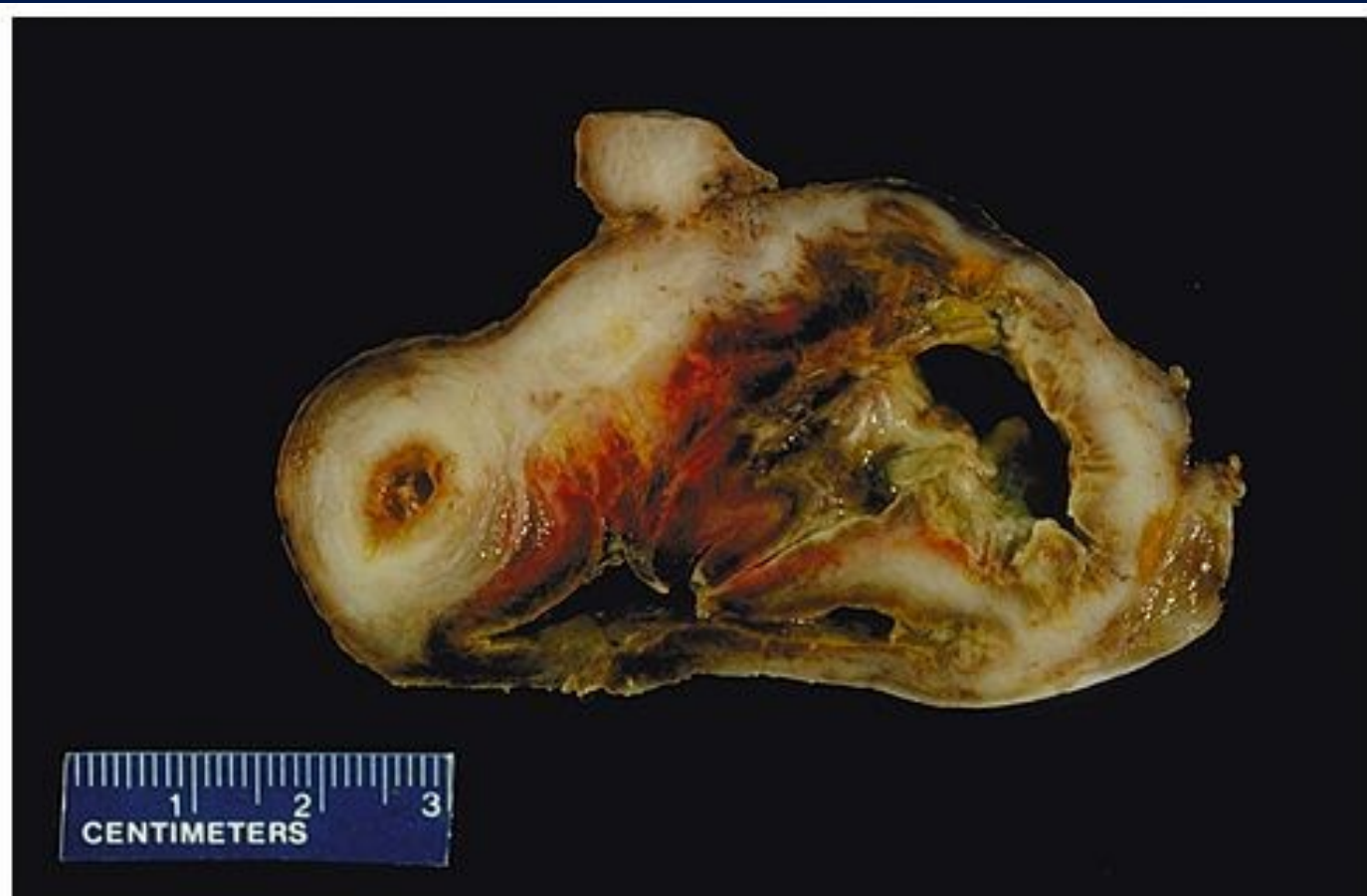- **Inborn defects:** commonly a part of complex chromosomal disturbances (X0 Turner syndrome, gonadal dysgenesis), intrauterine infections, ...
- **Inflammation:** usually chronic, part of nonspecific pelvic inflammatory disease
- **Cysts:** common, variable causes
- **Tumors:** variable origin, commonly cystic form



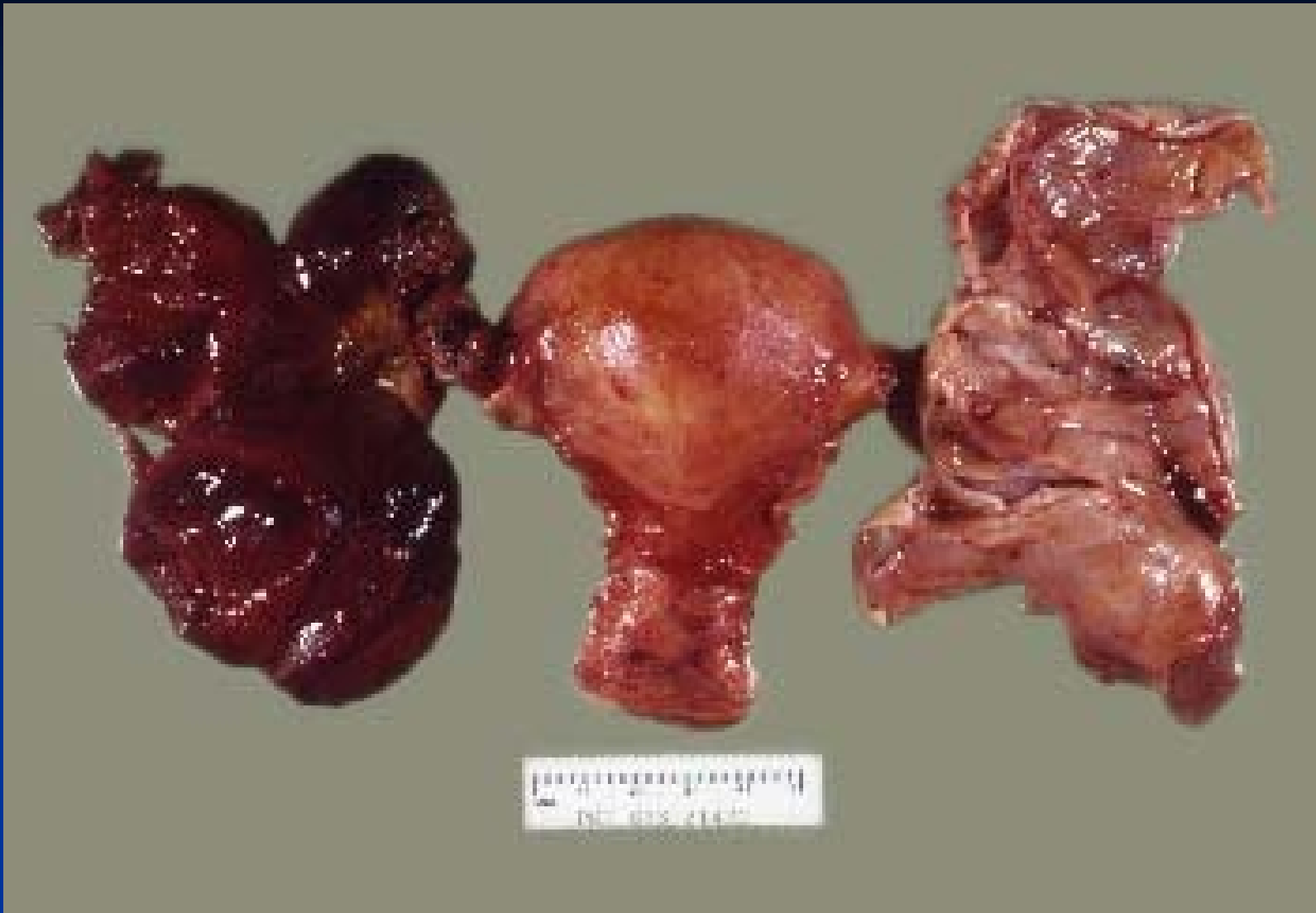Chronic inflammation

- „tuboovarian abscess“ – mixture of chronic abscesses, proliferation of granulation and fibrotic tissue, multiple adhesions, stenoses
- Fecal bacteria, str., staph., actinomycetes
- Pelvic pain, fever in acute exacerbation, may → peritonitis, sepsis
- Risk of infertility, GEU





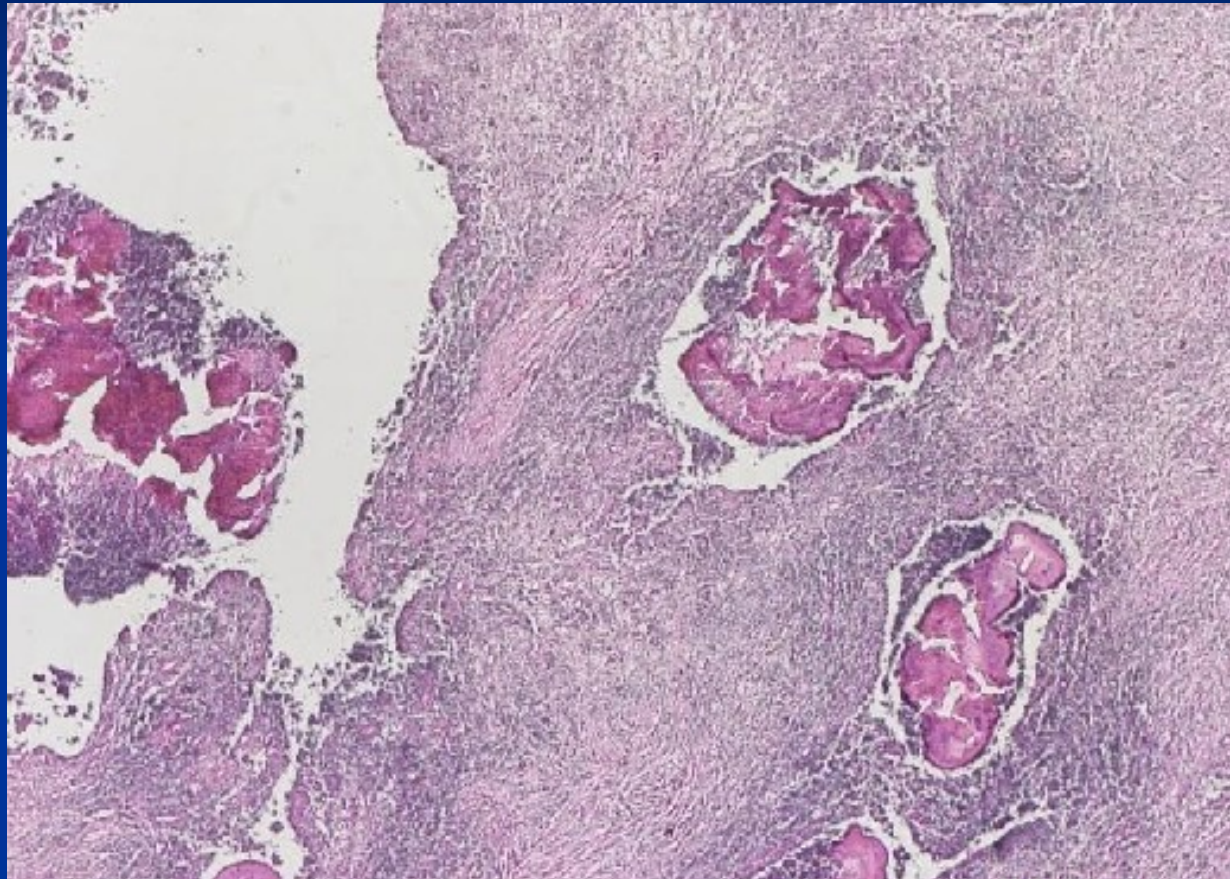
Copyright © 2002, Elsevier Science (USA). All rights reserved.



PID - torsion



Actinomycosis – sulphur granules



Ovarian cysts

- **non-neoplastic** – *inclusion c.* (mesothelial, epithelial)

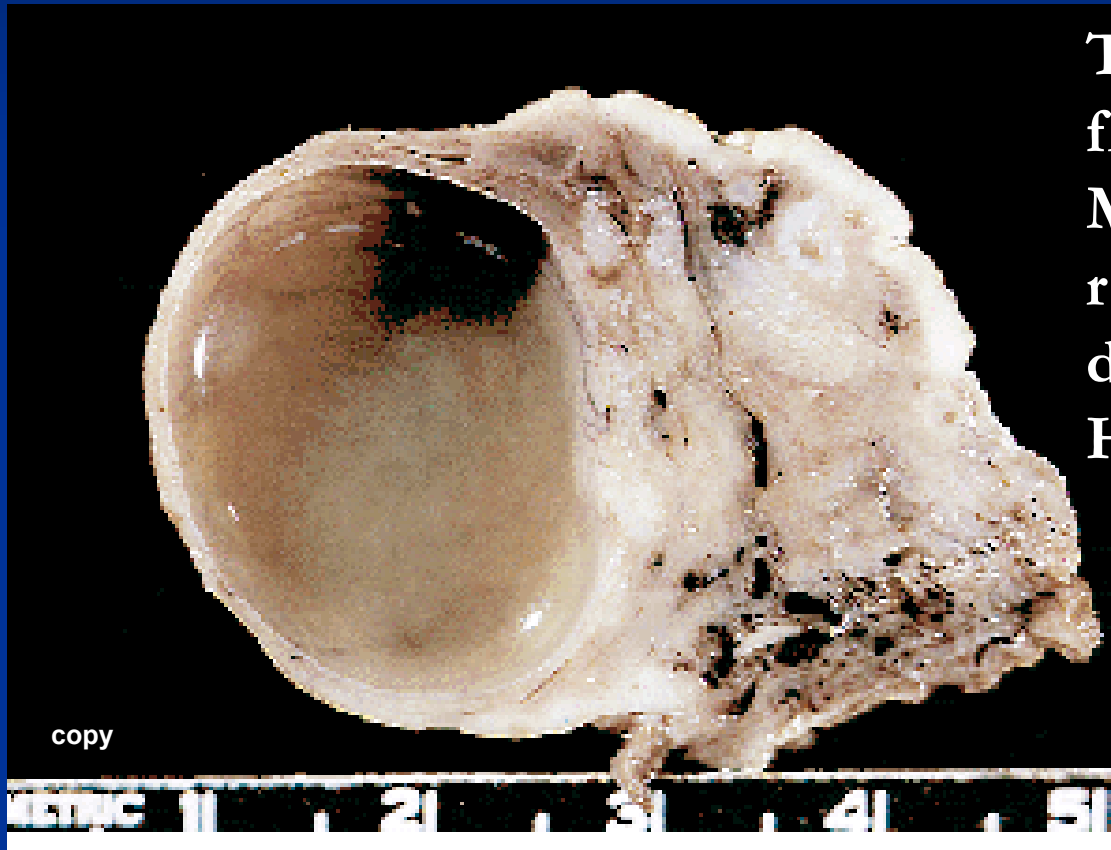
functional c. (follicular, luteal, polycystic ovary syndrome, ovarian hyperstimulation syndrome)

endometriosis

- **neoplastic** (*surface epithelial tumors, germ cell tu, sex-cord stromal tu, metastatic tu, etc.*)



Follicle cyst



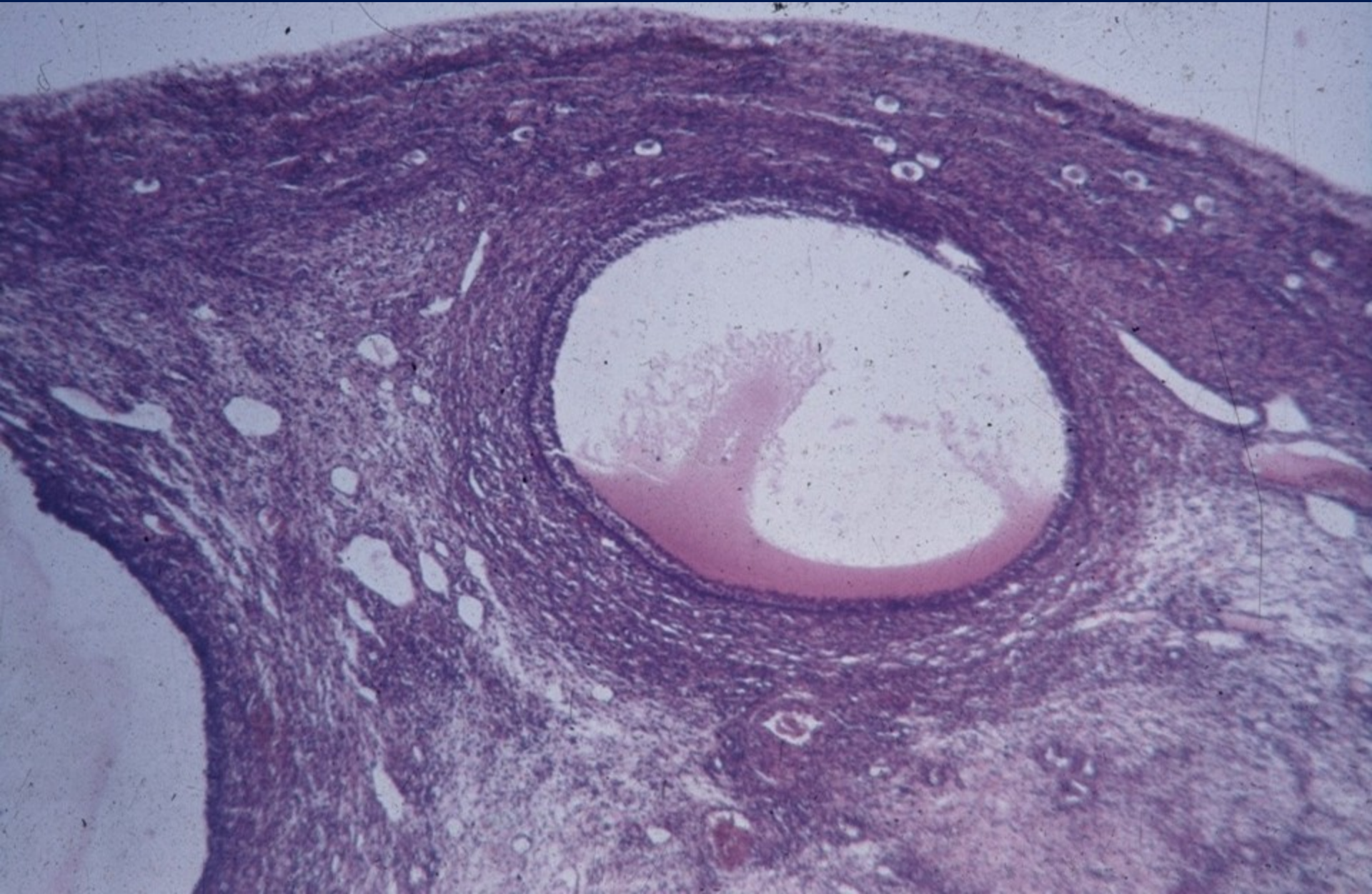
Thin walled, contains clear fluid, diameter ≥ 2 cm

Micro: enlarged non-ruptured follicle, longer duration

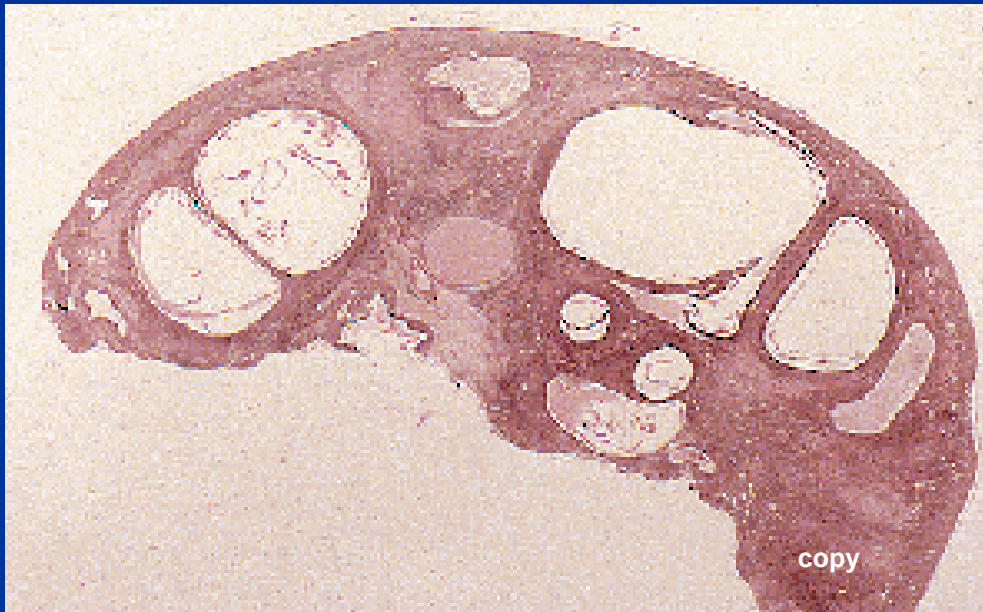
Hyperestrinism possible



Follicle cyst



Polycystic ovarian disease



Complex etiology, stopped normal follicular maturation, enlarged ovaries with smooth surface, multiple thin-walled cysts

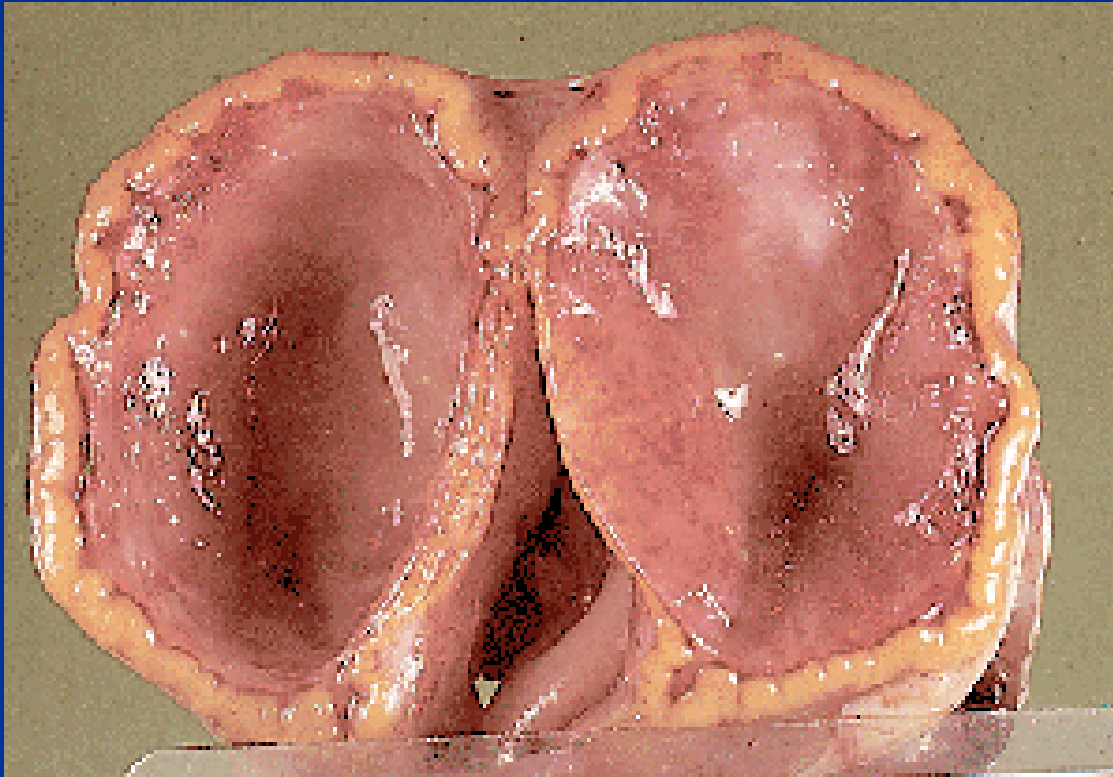
Profound hormonal + metabolic

(insulin)disturbances

Infertility (amenorrhea), obesity, hirsutism



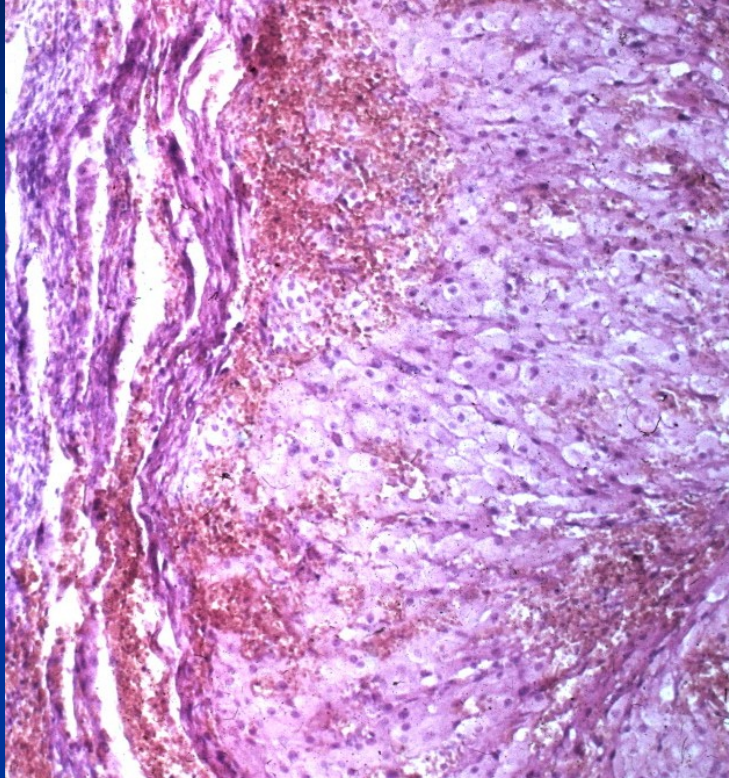
Corpus luteum cyst

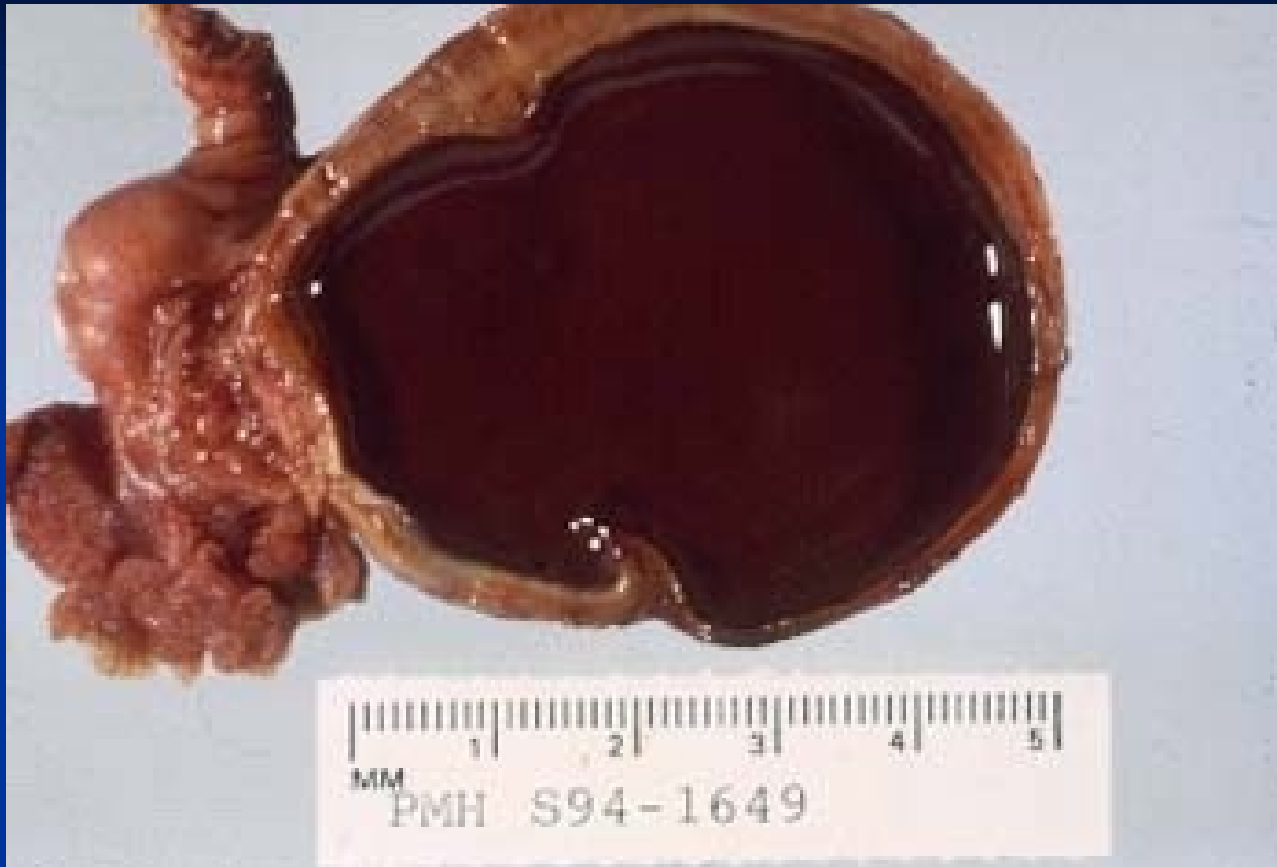

Yellow convoluted wall,
smooth lining, may
contain bloody fluid
Not regressed corpus
luteum, typical cells
with foamy cytoplasm



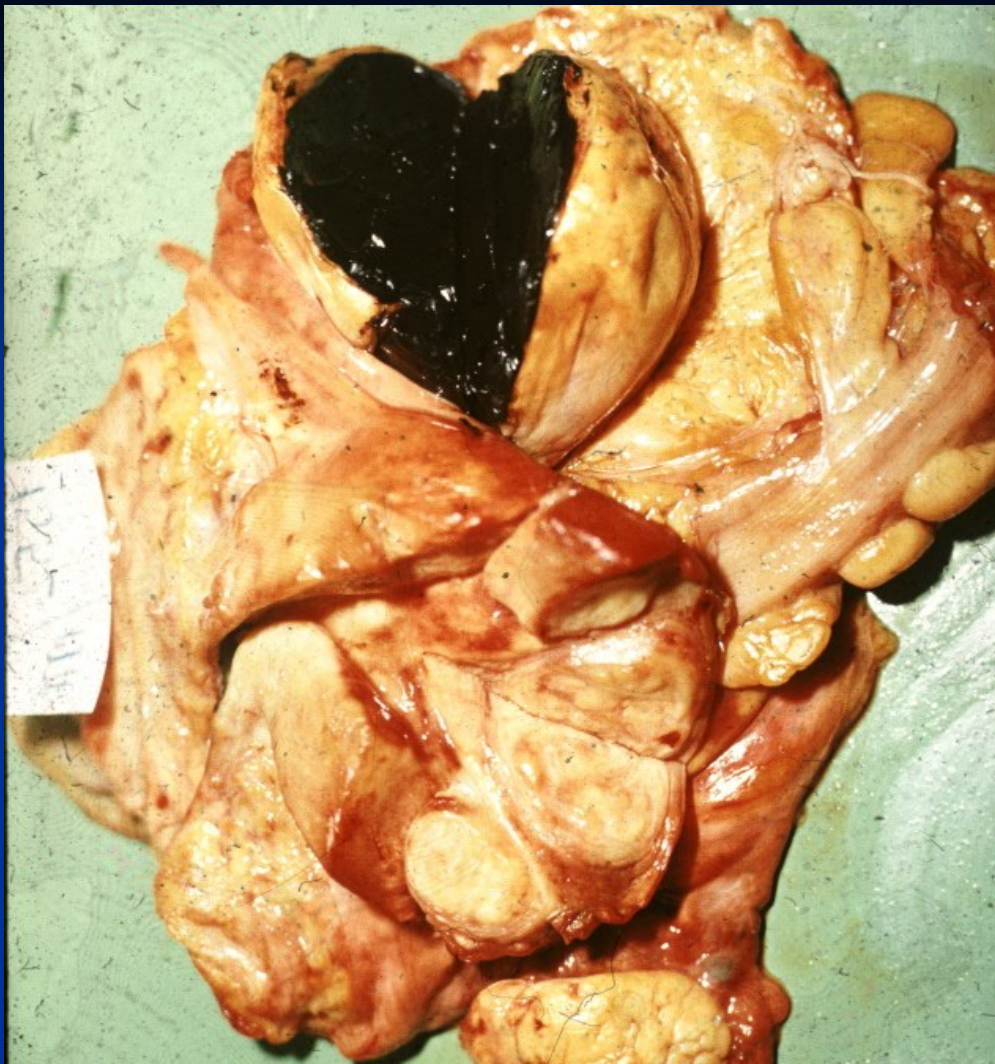Corpus luteum cyst



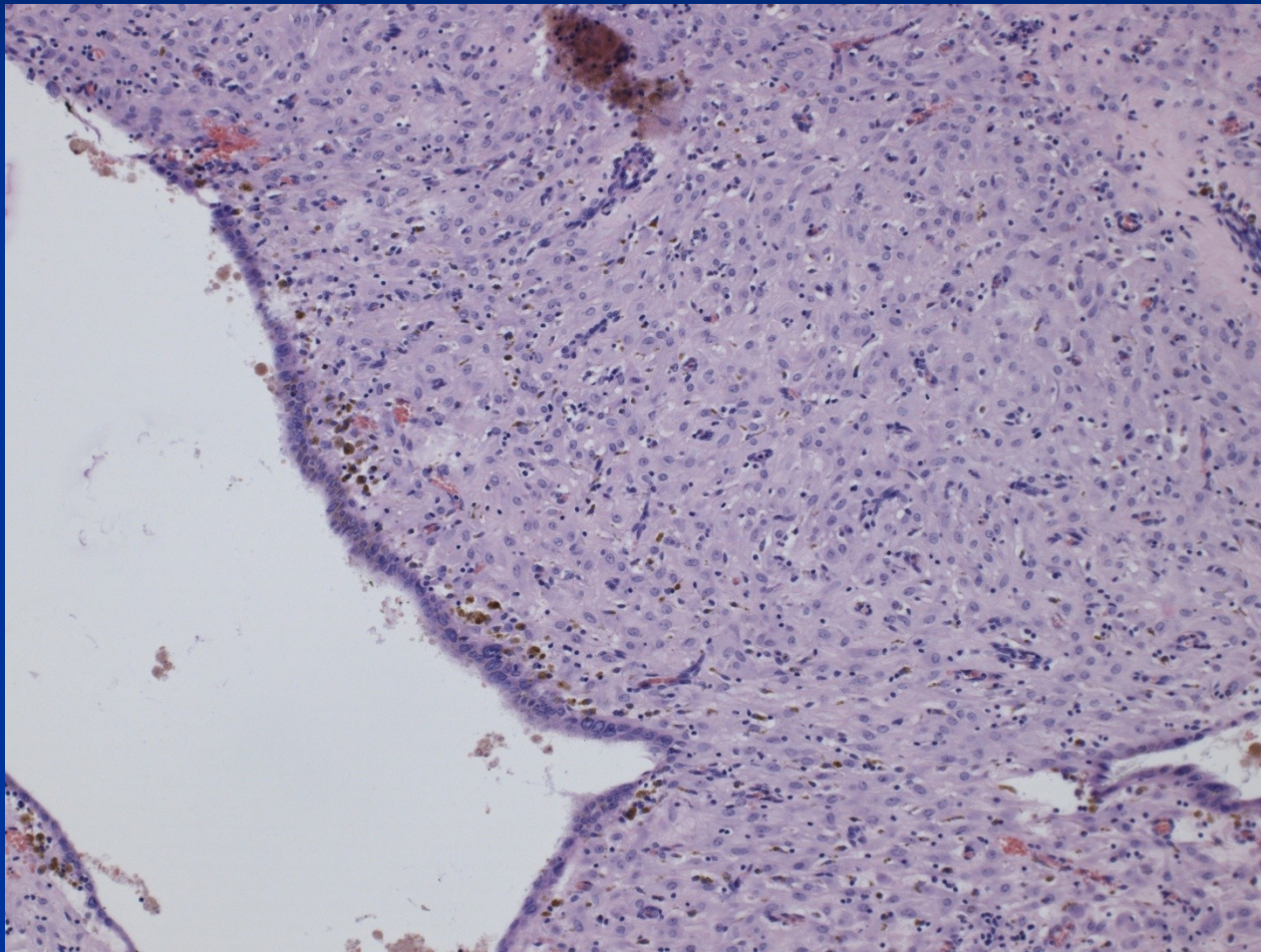


Endometriosis – „chocolate cyst“

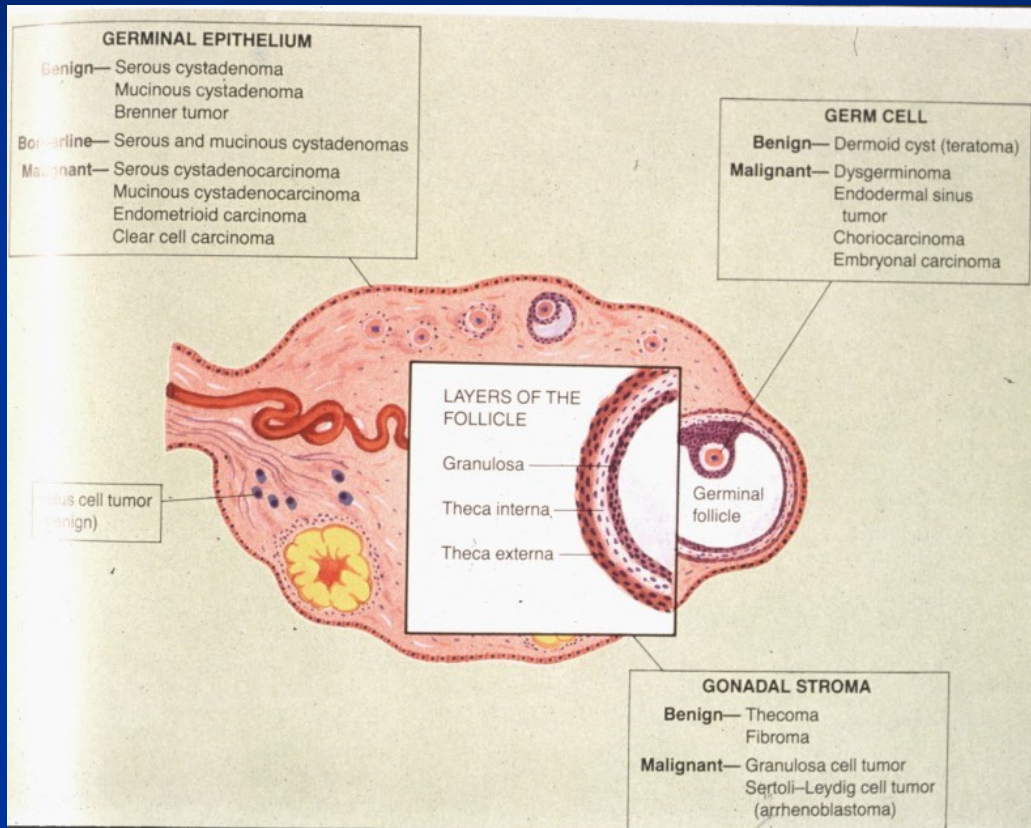




Endometriosis



Ovarian tumors



Ovarian tumors

- Surface epithelial tumors
 - most common, 70 %
 - adults
- Germ cell tumors
 - 15-20 %
 - children, adults
- Sex cord-stromal tumors
 - 5-10 %, any age
- Metastasis
 - 5 %, variable

Classification/nomenclature

1. Surface epithelial-stromal tumors

Epithelial type

- Serous
- Mucinous, endocervical-like and intestinal-type
- Endometrioid
- Clear cell tumors
- Transitional cell tumors
- Mixed tumors of müllerian epithelium



Classification/nomenclature

Surface epithelial-stromal tumors

Form of growth

- Cystic
- Papillary incl. inverted
- Solid
- Increased amount of neoplastic stroma, mixed tumor (adenofibroma, adenosarcoma, etc.)



Classification/nomenclature

■ Surface epithelial-stromal tumors

Biologic potential

- **benign** (commonly in form of cystadenoma)
- **Low malignant potential** (borderline malignancy)
 - moderate atypias, mitotic activity, architectonic changes (multilayering, irregular papillary budding), ! no invasion, but non-invasive peritoneal implants possible
- **Malignant**



Classification/nomenclature

■ Surface epithelial-stromal tumors

Names: combination, i. e.:

Mucinous cystadenoma

Serous papillary tumor of low malignant potential

Clear cell carcinoma of ovary



Classification

■ 2. Sex cord-stromal tumors

■ Granulosa-stromal cell tumors

Granulosa cell tumors

Tumors of the thecoma-fibroma group

■ Sertoli-stromal cell tumors, androblastomas (Sertoli-Leydig cells tumors)

■ (Sex-cord tumor with annular tubules)

■ (Gynandroblastoma)

■ Steroid (lipid) cell tumors



Classification

■ 3. Germ cell tumors

■ Teratoma

■ Immature

■ Mature (adult): solid; cystic - dermoid cyst; monodermal - struma ovarii, carcinoid

■ Dysgerminoma

■ Yolk sac tumor

■ Mixed germ cell tumor

■ 4. Malignant, NOS (not otherwise specified)

■ 5. Metastatic tumors

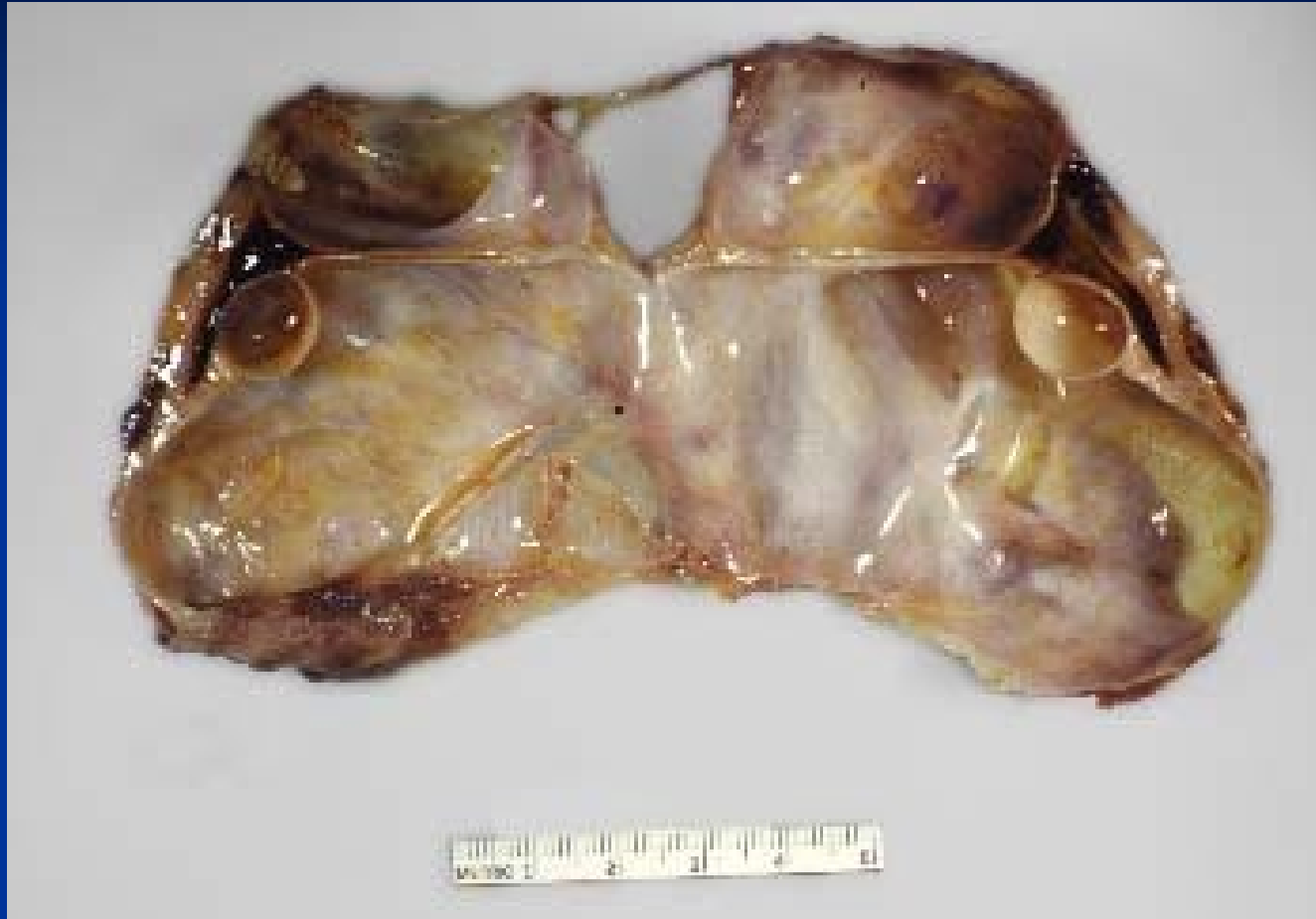

Serous cystadenoma

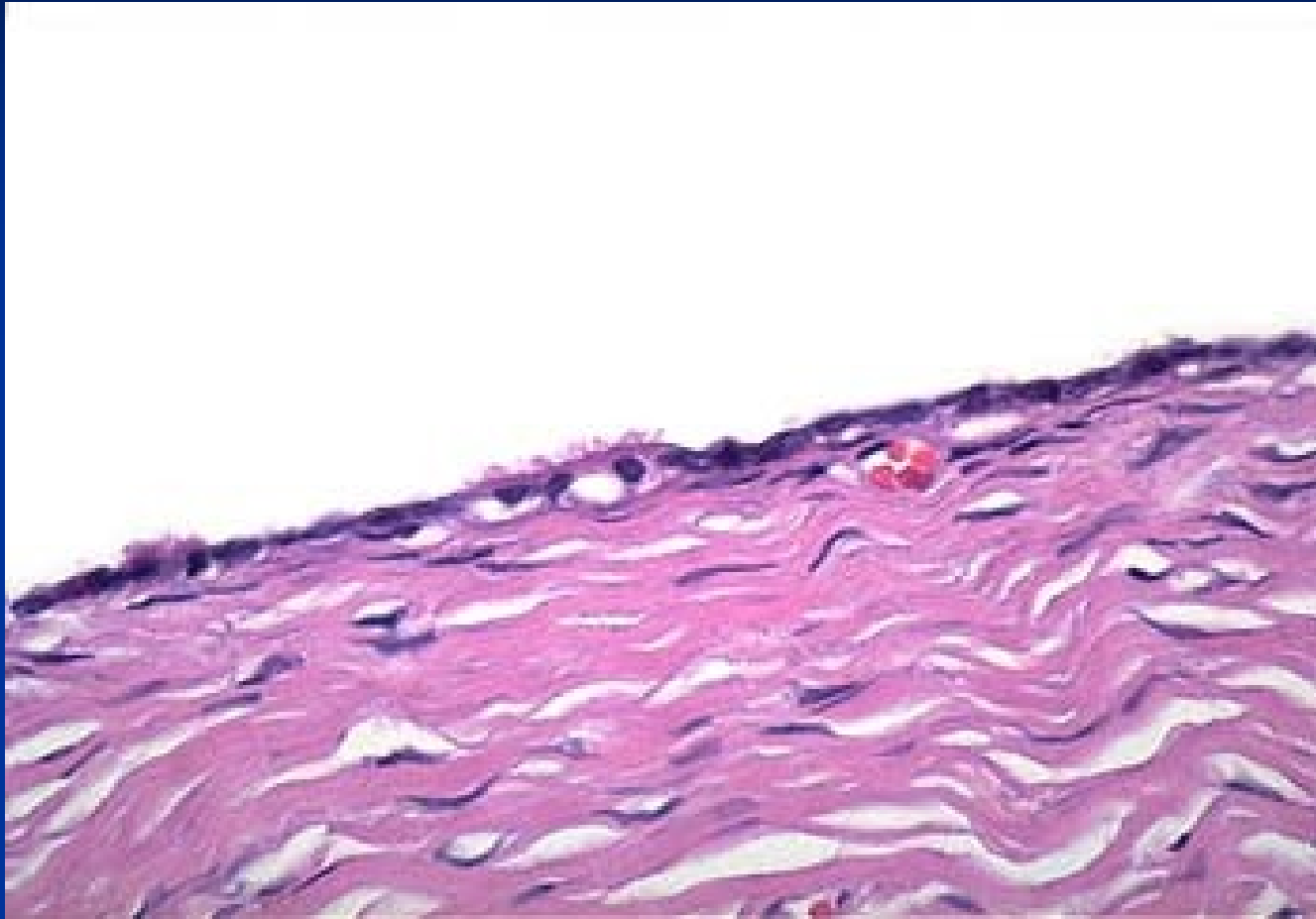
- Thin-walled multilocular cyst, variable size
- Clear fluid
- Lining smooth or papillary, micro ~ tubal epithelium, may be ciliated
- Possible non-cystic superficial papillary form on ovary



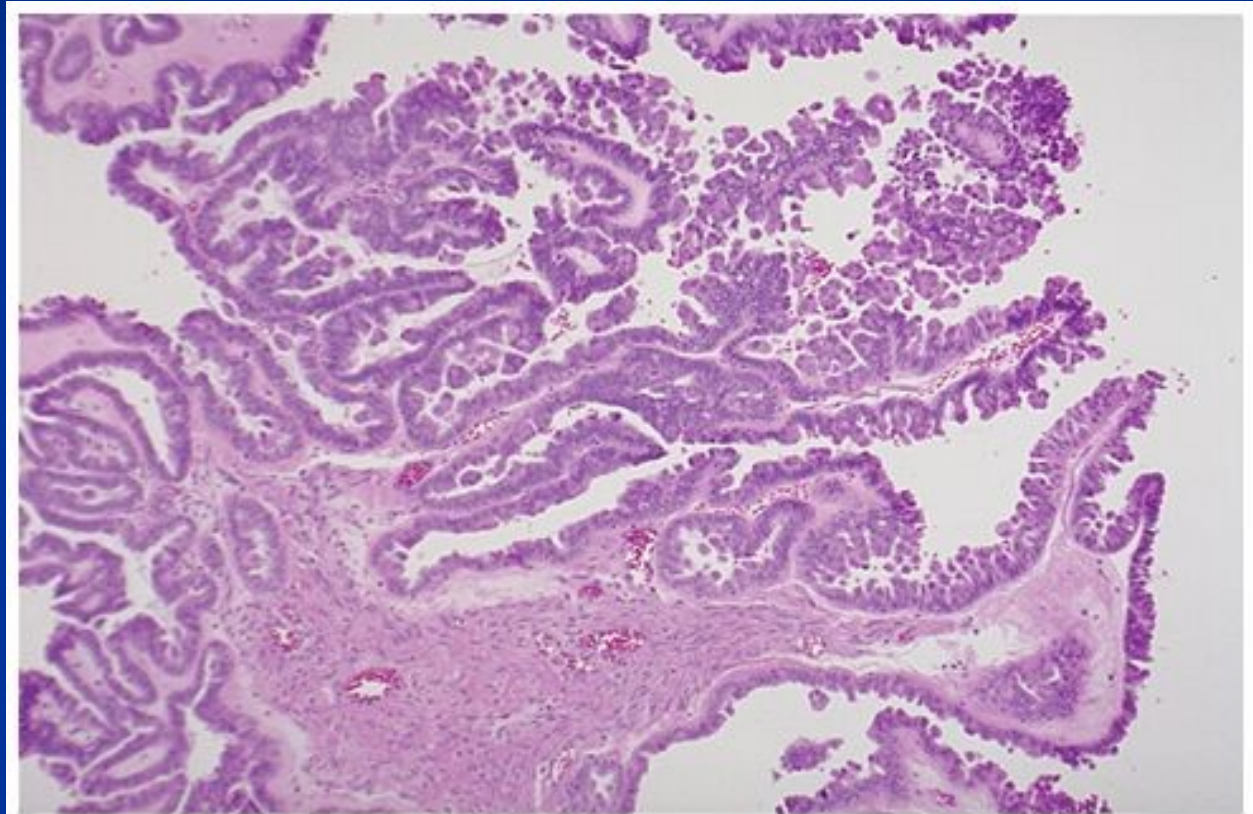
Serous cystadenoma



Serous cystadenoma

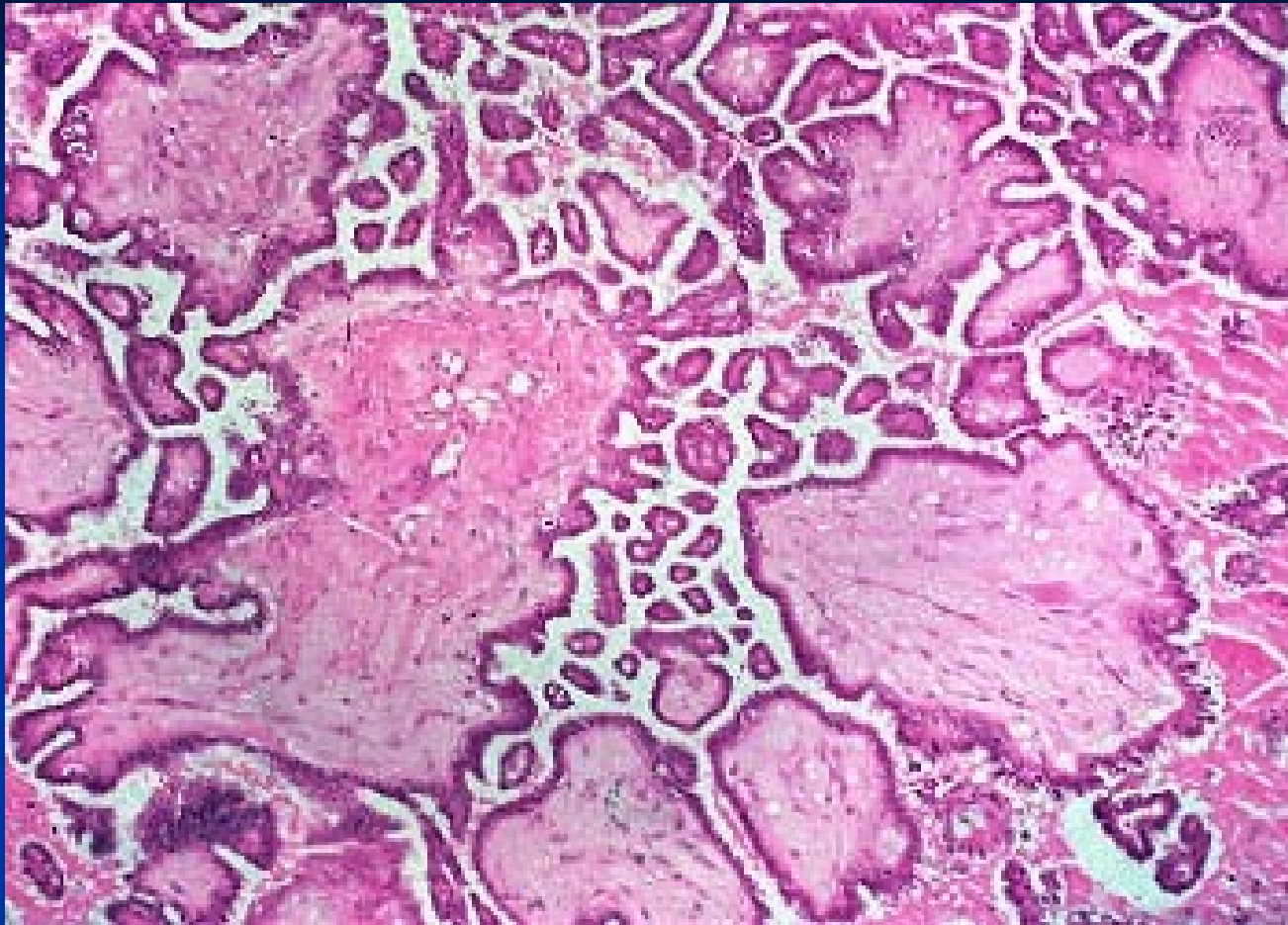


Serous papillary tumor of low malignant potential (papillary cystadenoma of borderline malignancy)



Copyright © 2002, Elsevier Science (USA). All rights reserved.

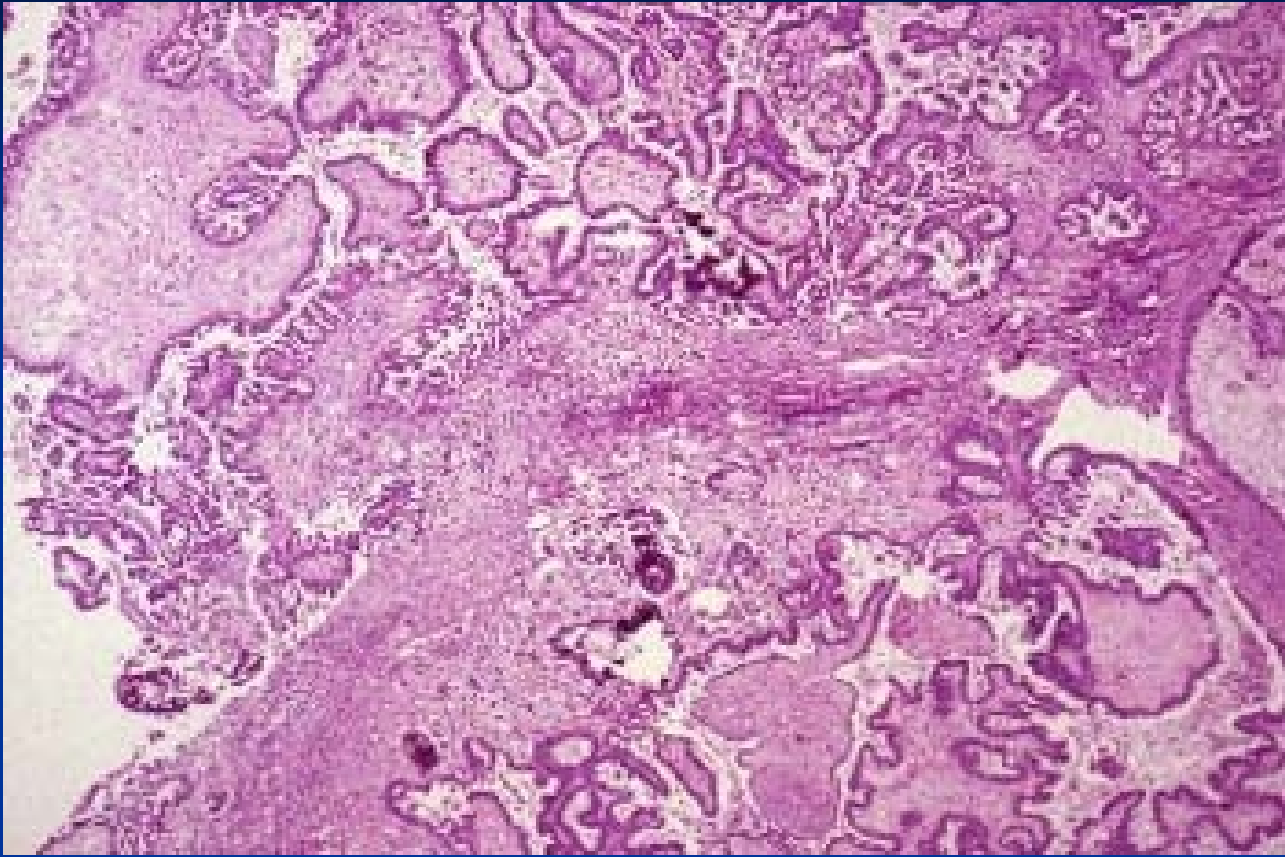




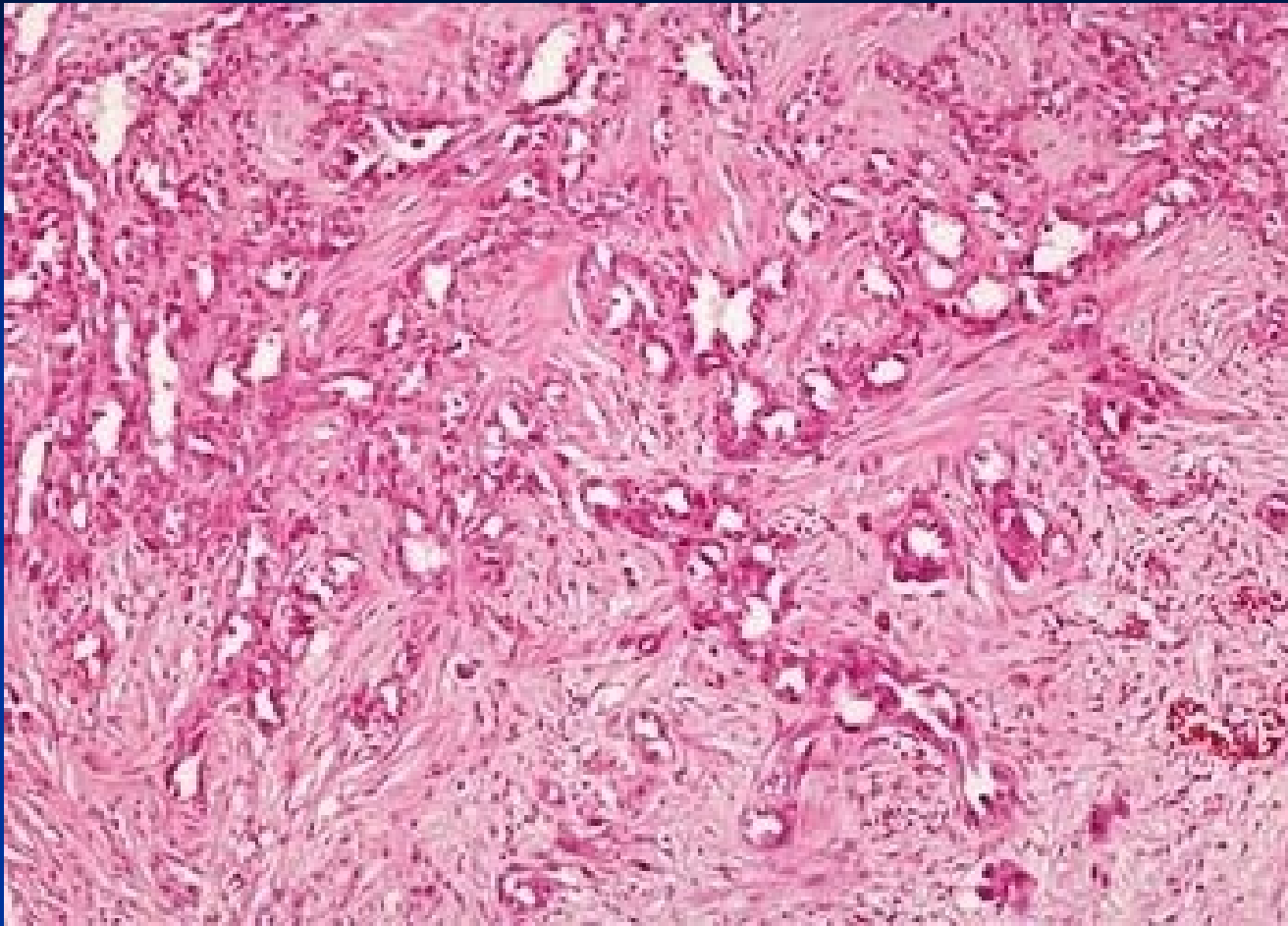
Serous adenocarcinoma

- Stromal invasion
- Confluent wide papillae
- Possible microcalcifications (psammomata)
- Commonly partially solid
- Growth into surrounding tissues
- Metastatic spread in abdominal cavity

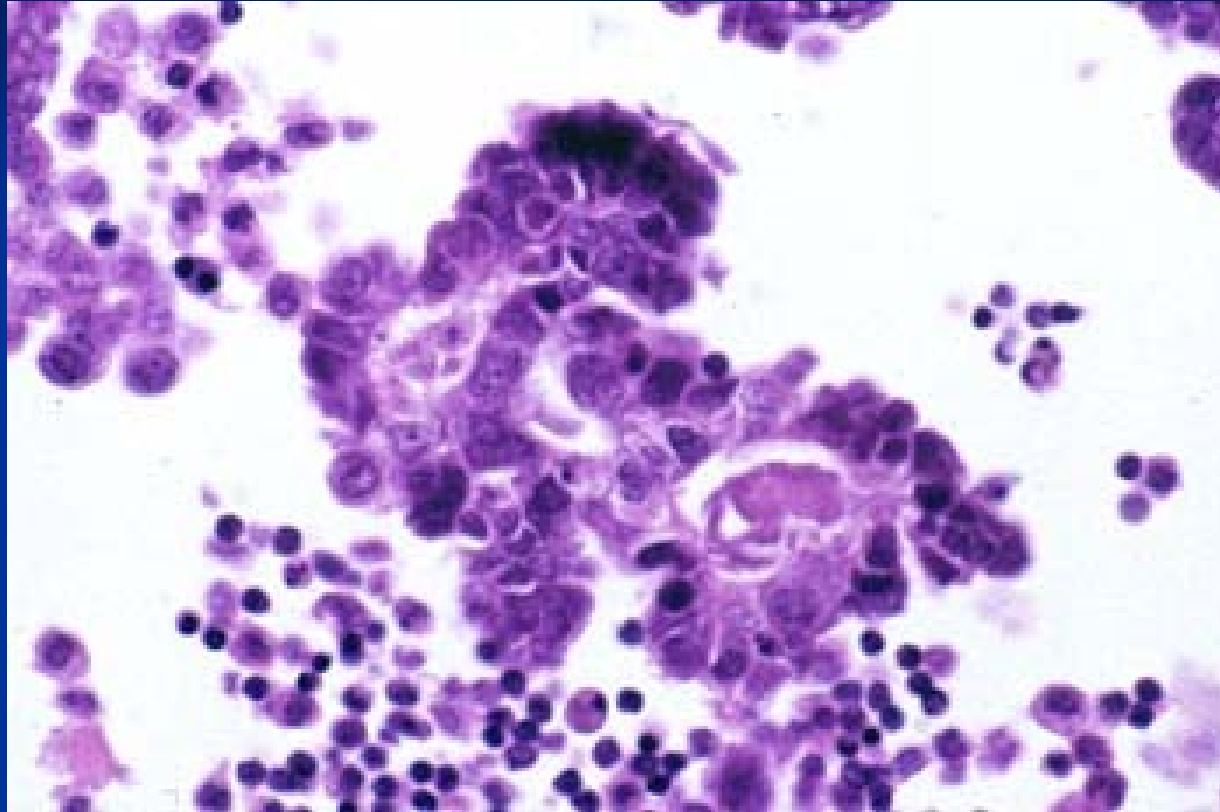




serous cystadenocarcinoma



ovarian adenocarcinoma – stromal invasion



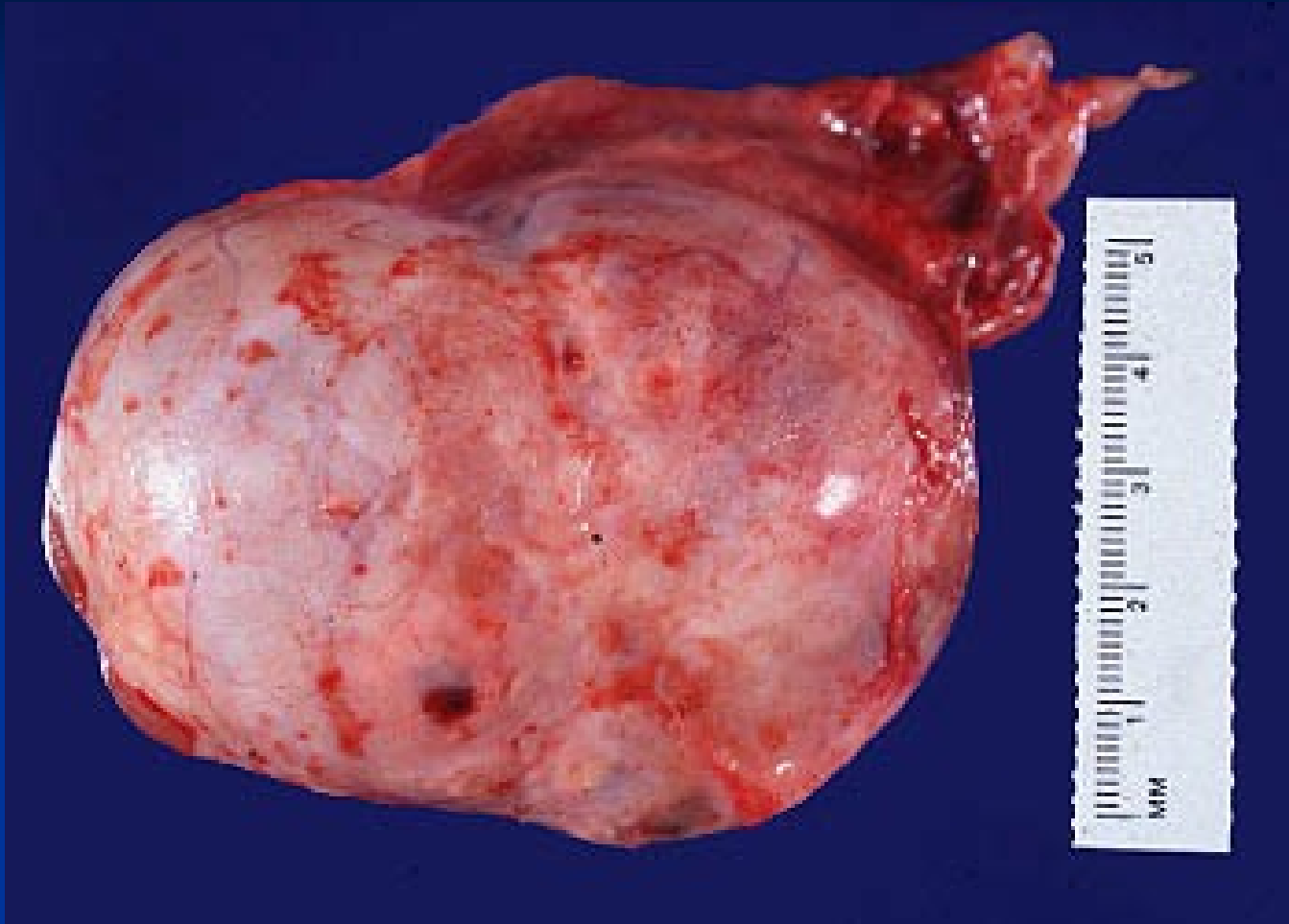
Malignant cell clusters in ascites



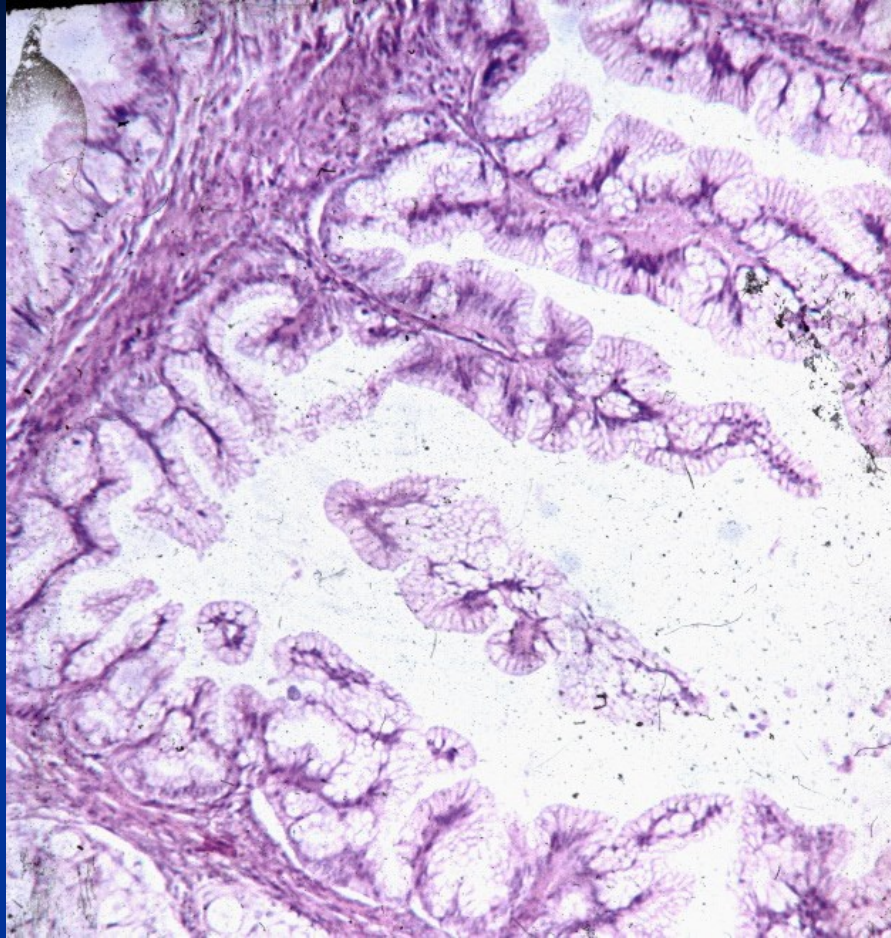
Mucinous cystadenoma

- large cysts with a smooth outer surface
- usually multilocular
- contain clear mucous material
- Micro: tall mucin-secreting columnar cells, mostly endocervical type, may be intestinal type
- Complications: huge size, abdominal distention, possible torsion, cyst rupture.

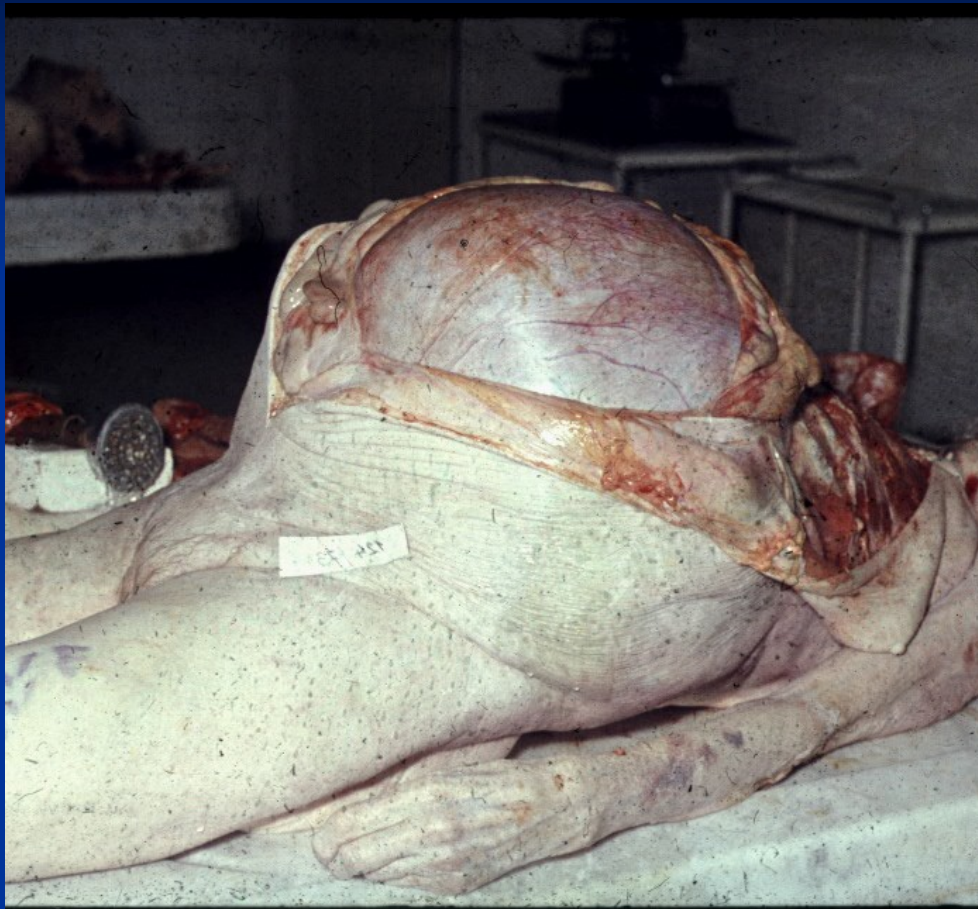




Mucinous cystadenoma



Mucinous papillary cystadenoma



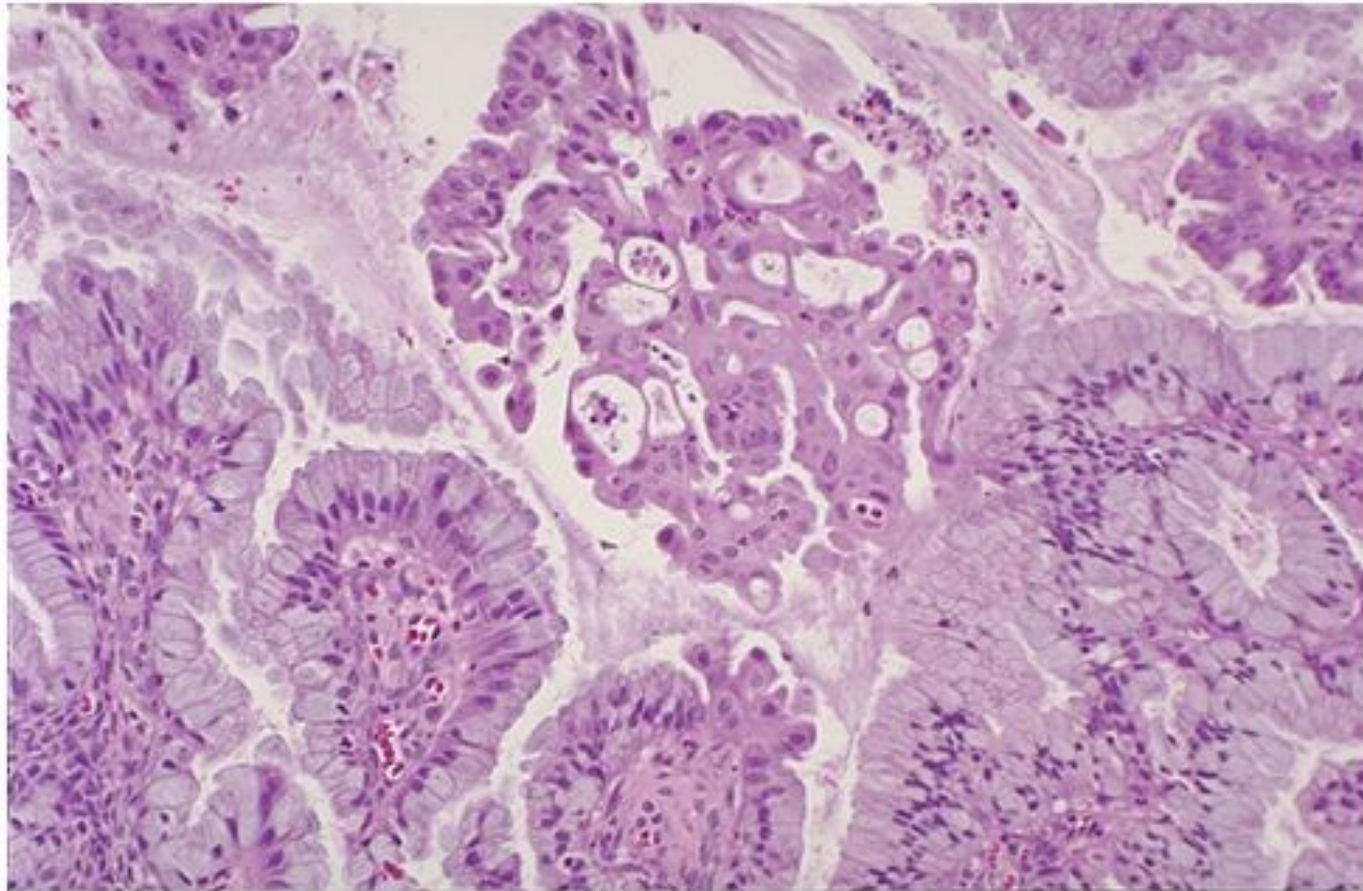
Mucinous cystic tumor of low malignant potential



Mucinous cystadenocarcinoma

- Commonly partially solid
- Metastatic spread into abdominal cavity – „pseudomyxoma peritonei“, organisation of mucinous material → adhesions, fibrosis, stenosis (tumor origin usually in appendix)
- Diff. dg. x other mucinous carcinomas (GIT)





Copyright © 2002, Elsevier Science (USA). All rights reserved.

Endometrioid tumors

- usually malignant
- histologically mostly identical with endometrial adenocarcinomas (!diff. dg. primary x metastatic, may be concurrent primary ca in endometrium and ovary)
- Possible start from foci of pre-existing ovarian endometriosis

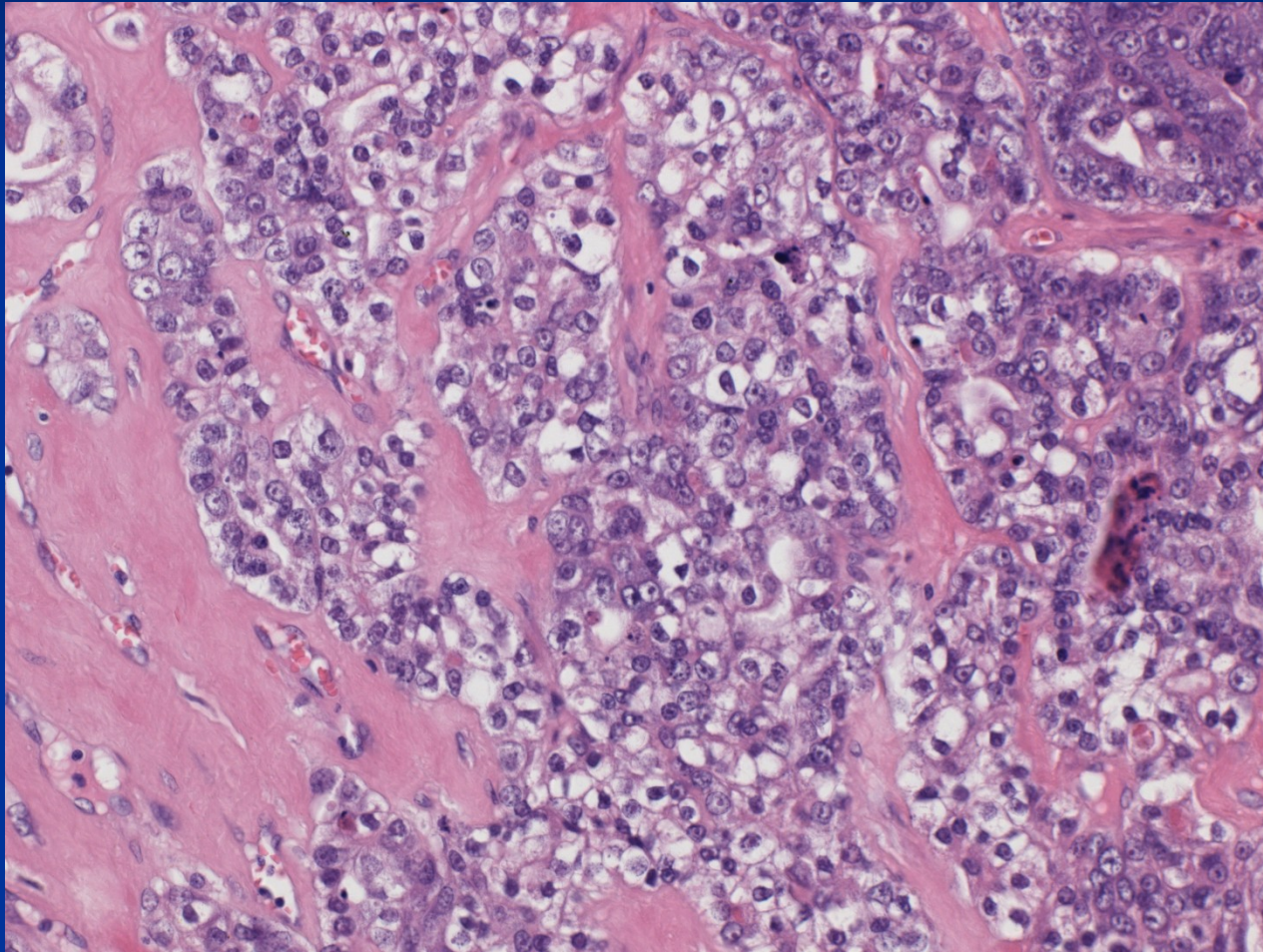


Clear cell tumors

- Almost always malignant
- Complex papillary and tubular pattern intermingled with sheets of highly atypical clear cells
- diff. dg. x other clear cell tumors (renal, vaginal)

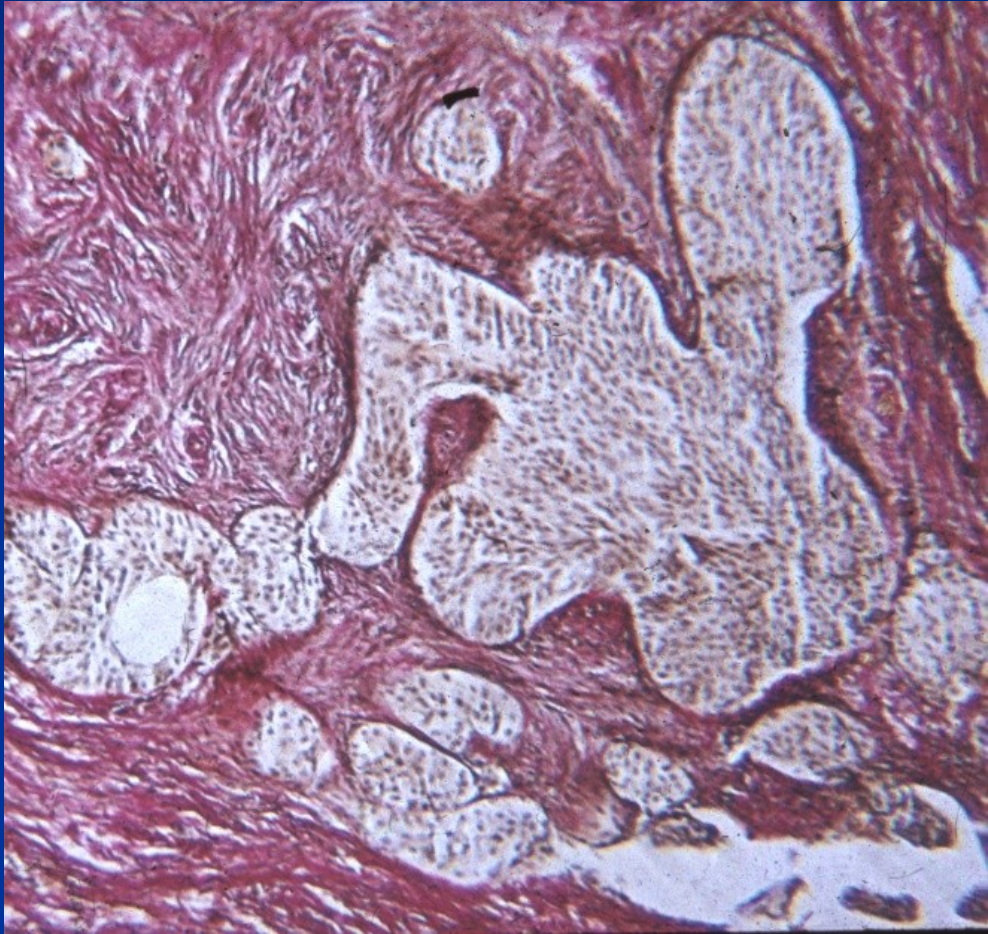


Clear cell carcinoma



Transitional cell tumors

- Mostly in form of Brenner tumors
- usually small, solid and benign
- Micro: rounded islands of transitional-type epithelium embedded in a dense fibrous stroma.
- Malignant forms rare.



Germ cell tumors

- **dysgerminoma** (ovarian counterpart of seminoma)
- **embryonal carcinoma** (similar to testis)
- **yolk sac tumor** (similar to testis)
- **choriocarcinoma** (similar to testis)
- **teratoma** (mature – benign: dermoid cyst, immature – malignant, malignisation in a mature teratoma)



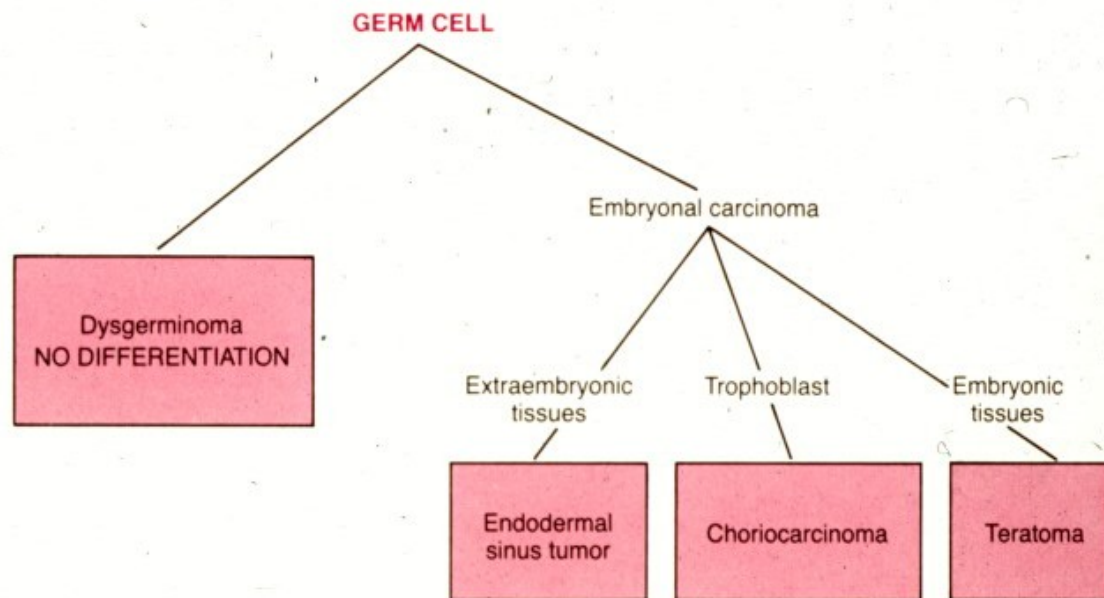
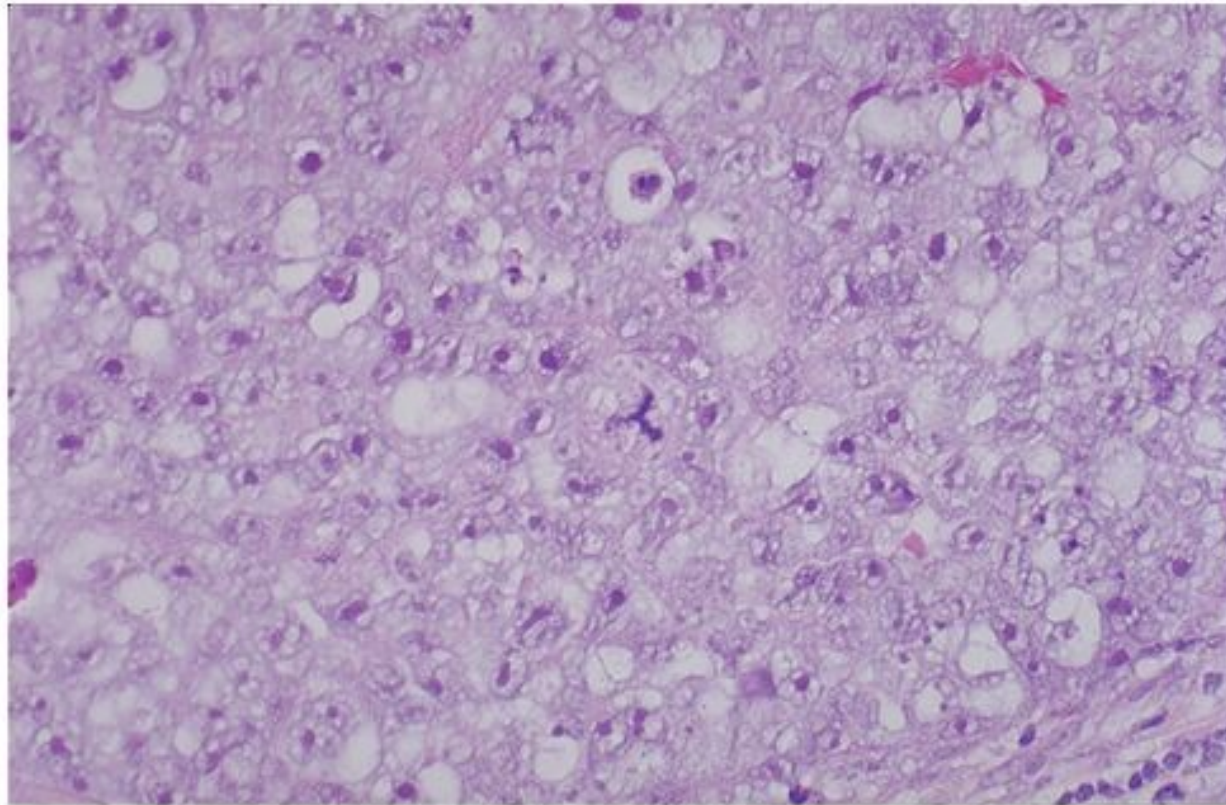


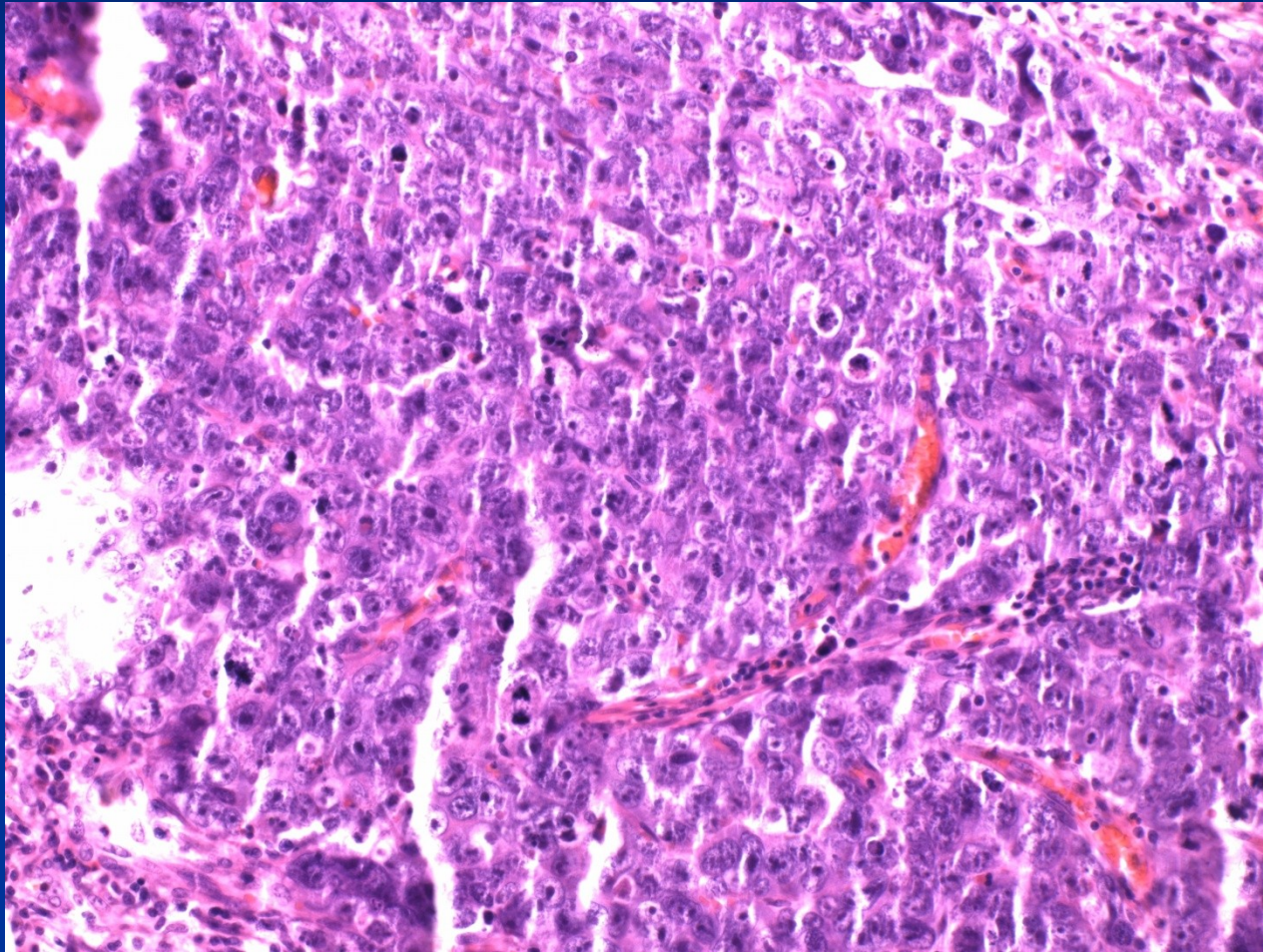
Figure 23-48. Histogenesis and interrelationships of tumors of germ cell origin.

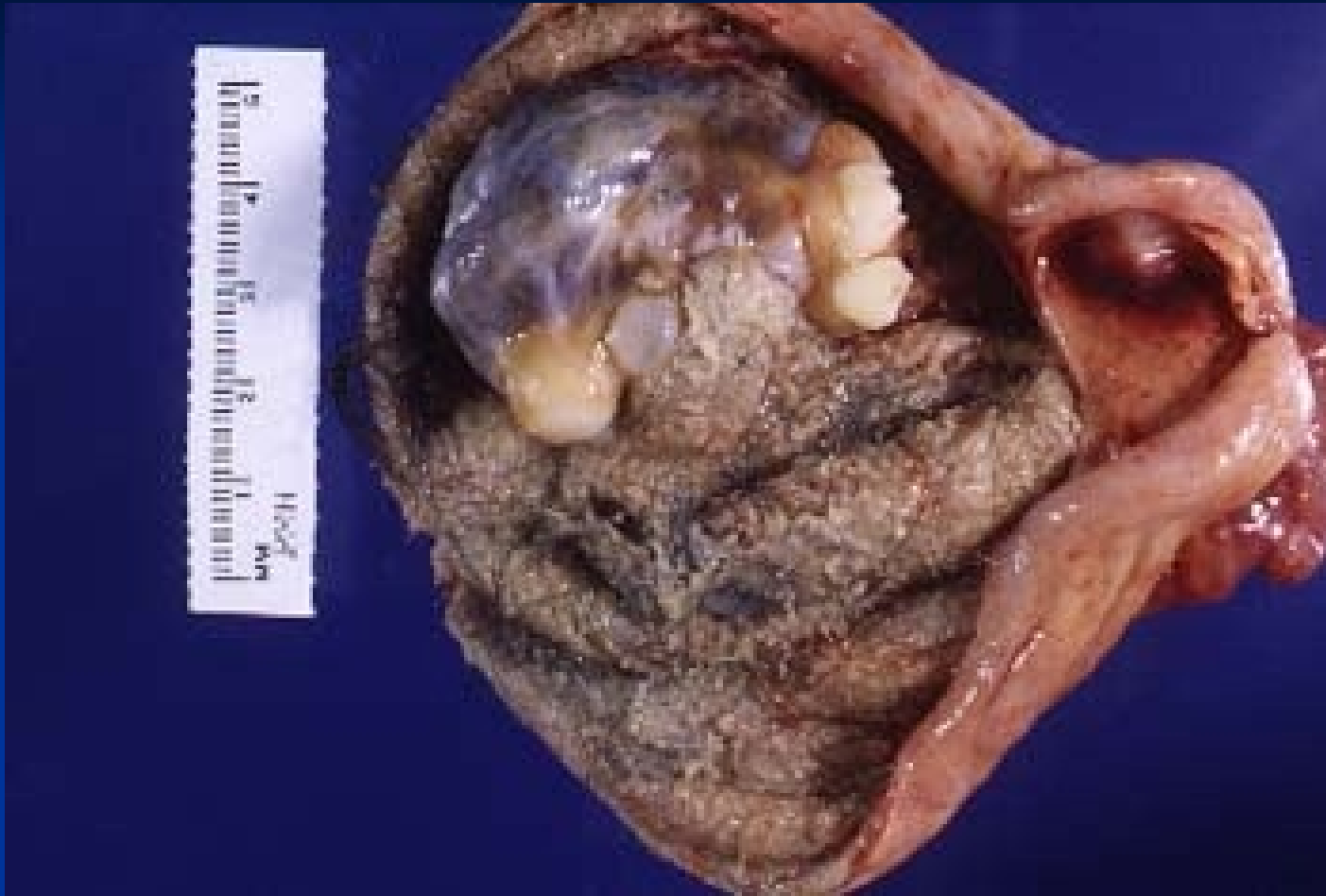

Copyright © 2002, Elsevier Science (USA). All rights reserved.

Dysgerminoma – clear cytoplasm

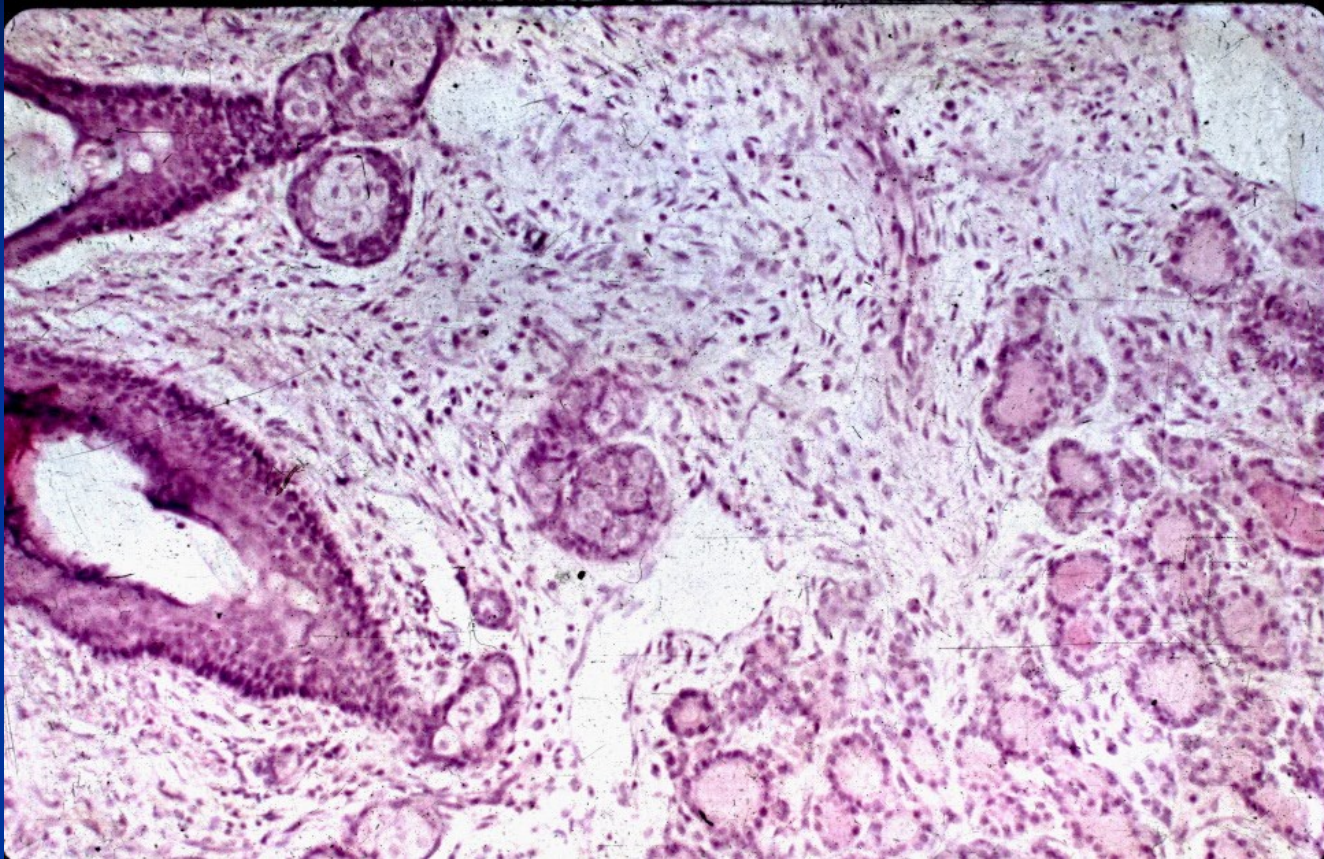
Embryonal carcinoma





Dermoid cyst – mature cystic teratoma

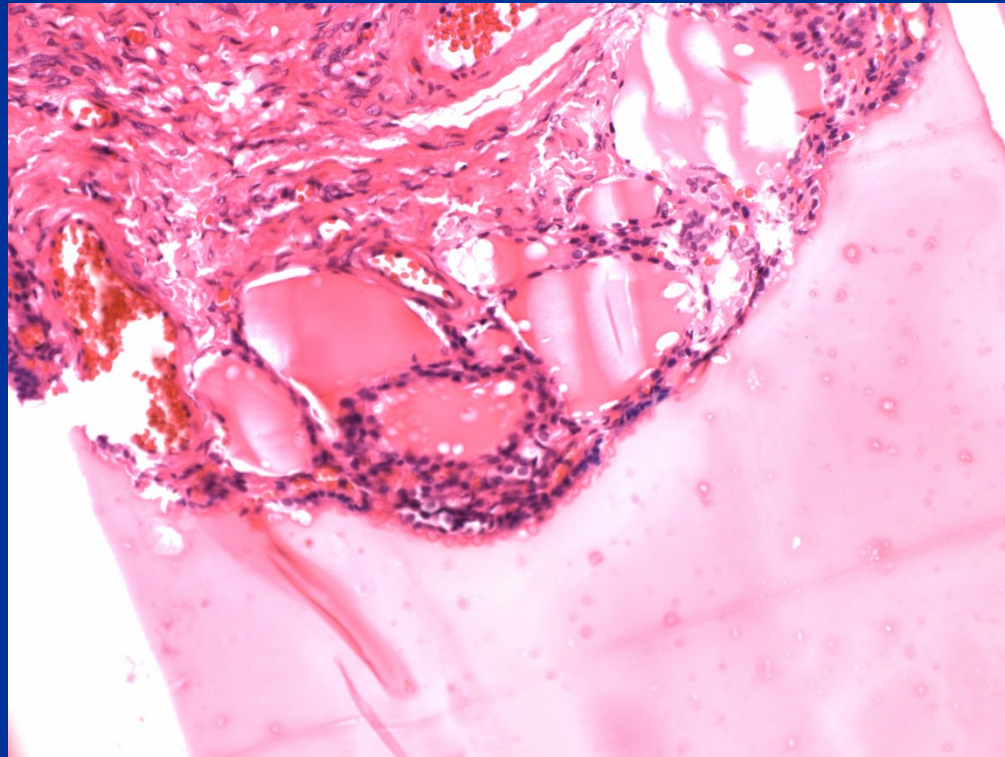




Dermoid cyst – mature cystic teratoma

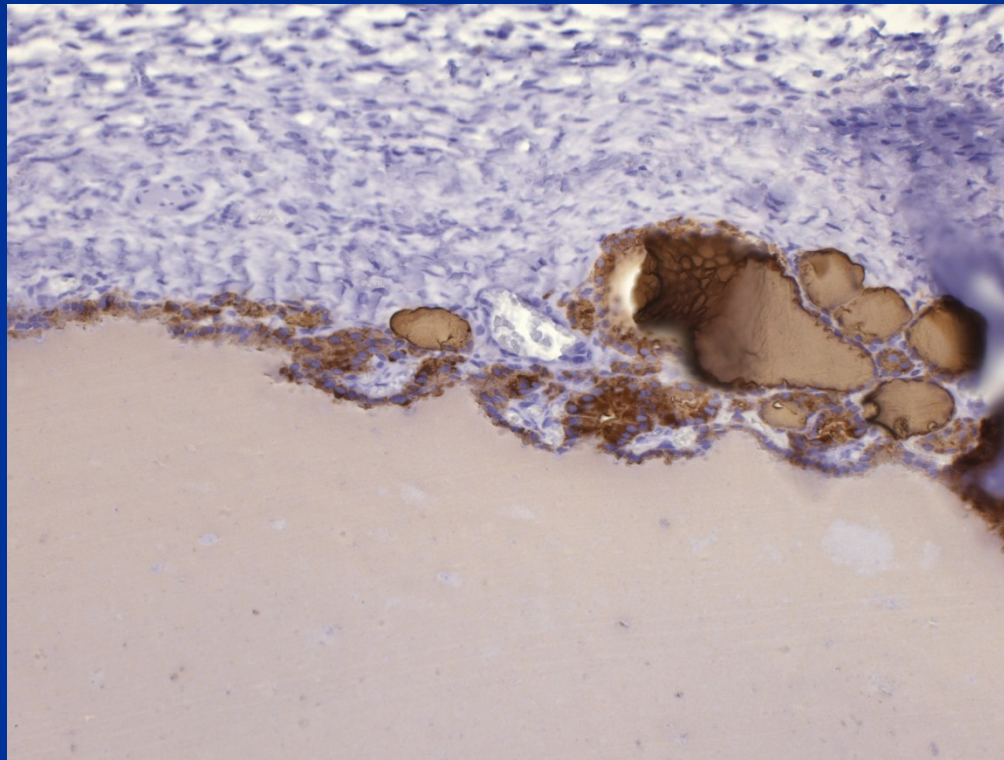


Struma ovarii



Struma ovarii

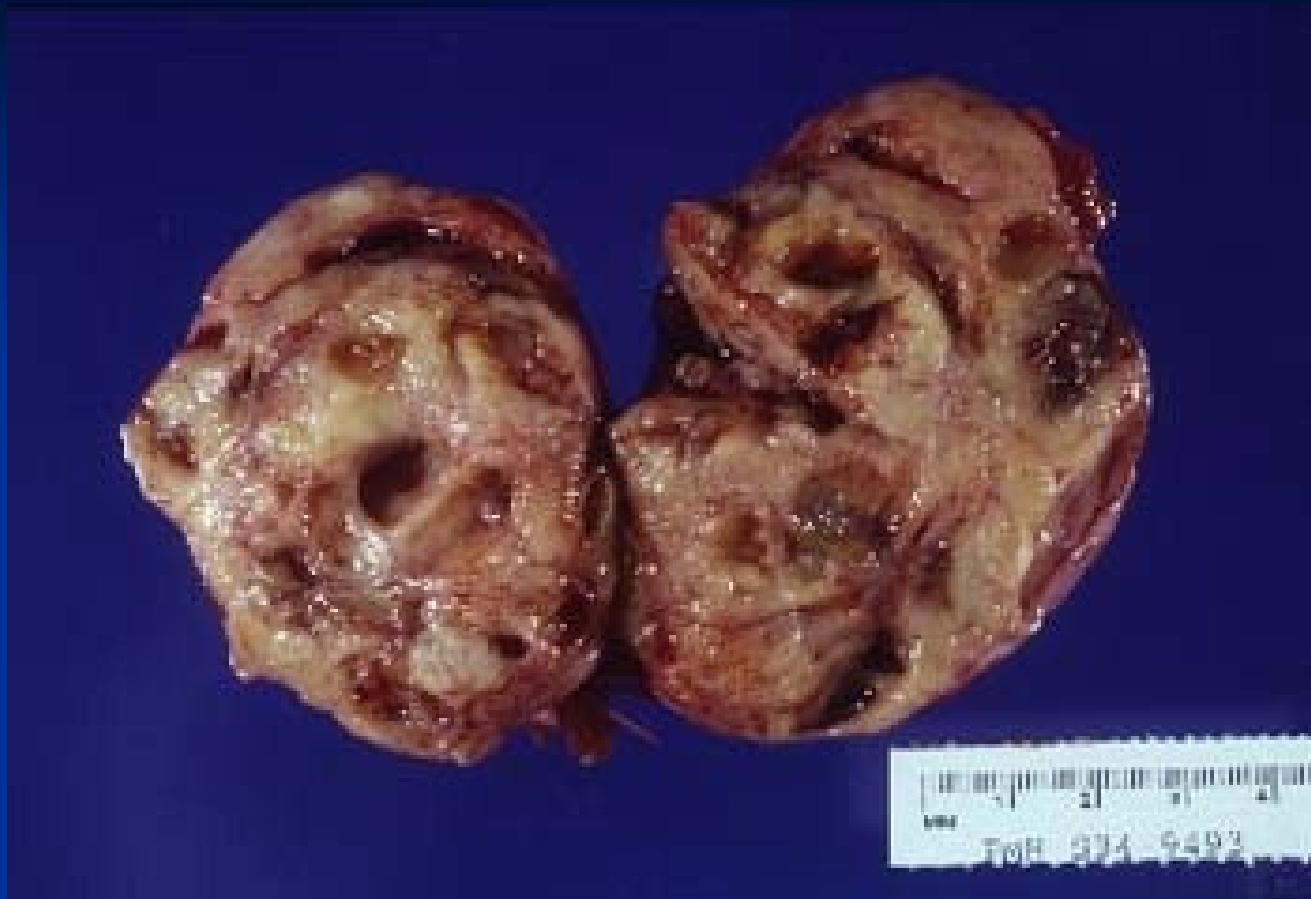- IHC thyreoglobulin



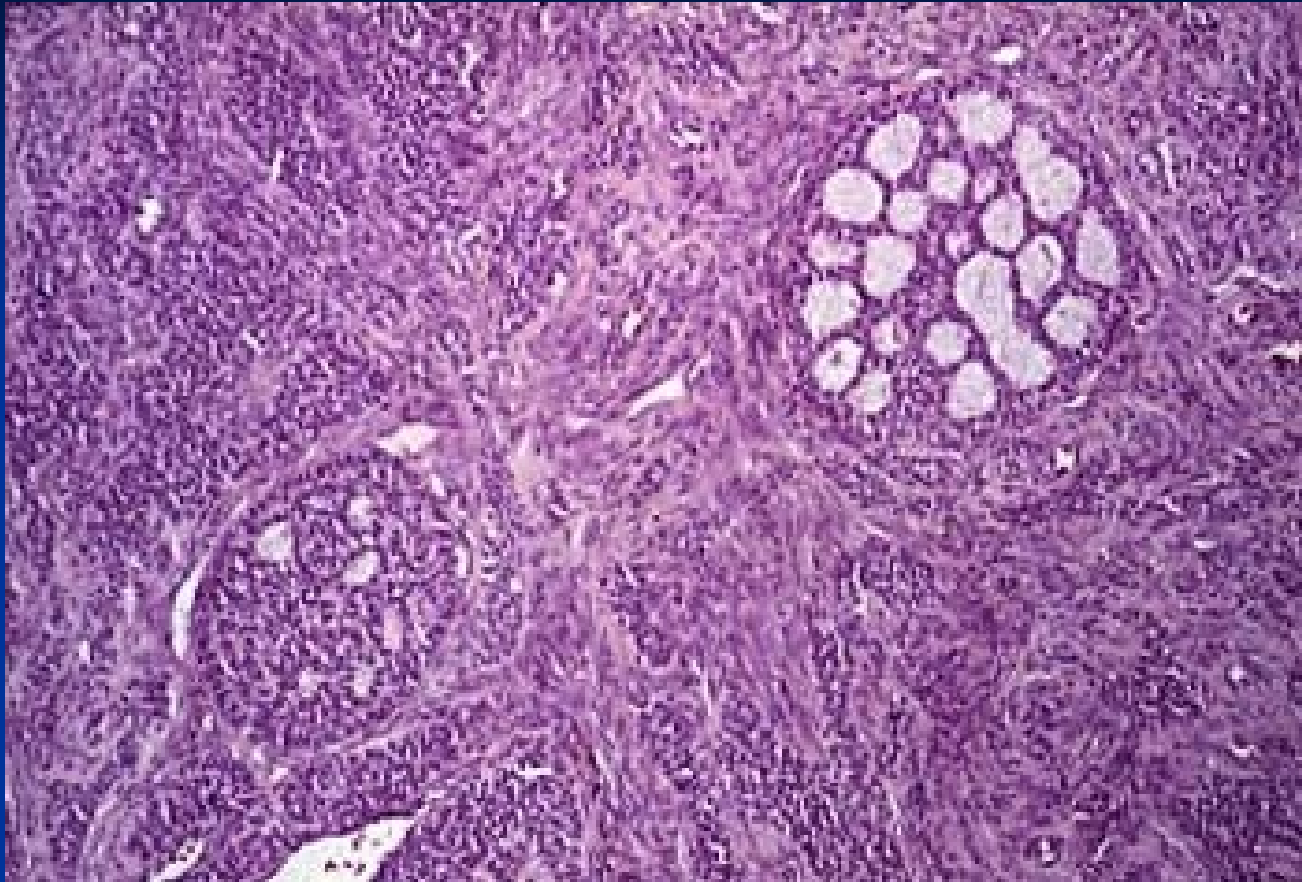
Sex-cord stromal tumors

- **Granulosa cell tumors** (potentially malignant, possible estrogen production – precocious puberty, risk of abnormal uterine bleeding, endometrial hyperplasia or ca)
- **Thecoma-fibroma** (most common, usually benign, possible association with ascites, rarely estrogen production)
- **Sertoli-Leydig cell tumors** (possible masculinisation)



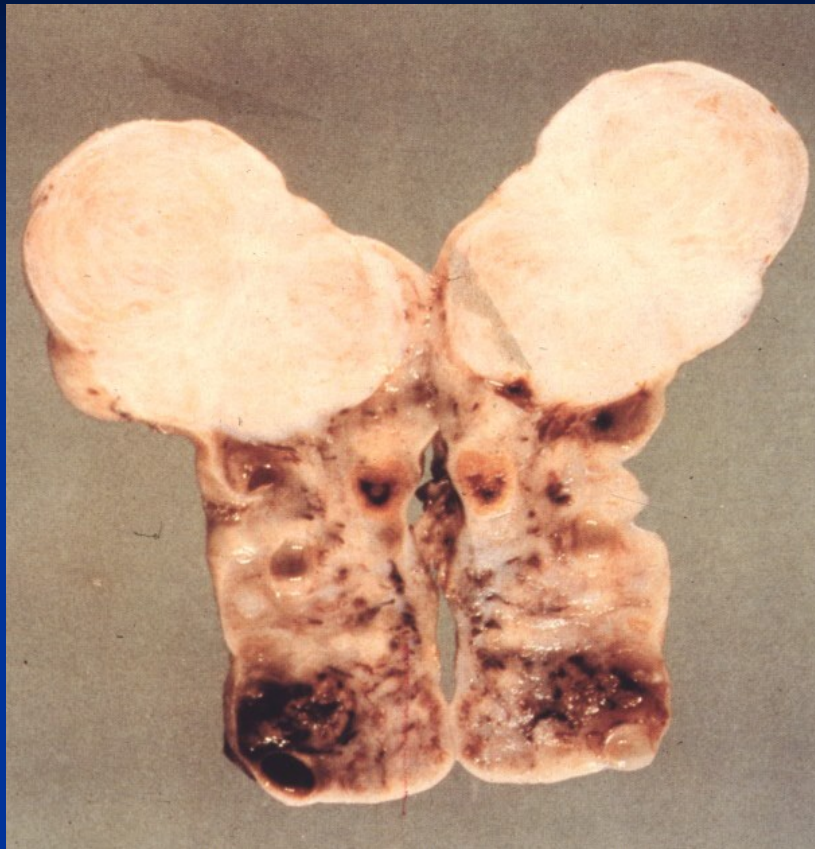


Granulosa cell tumor



Granulosa cell tumor

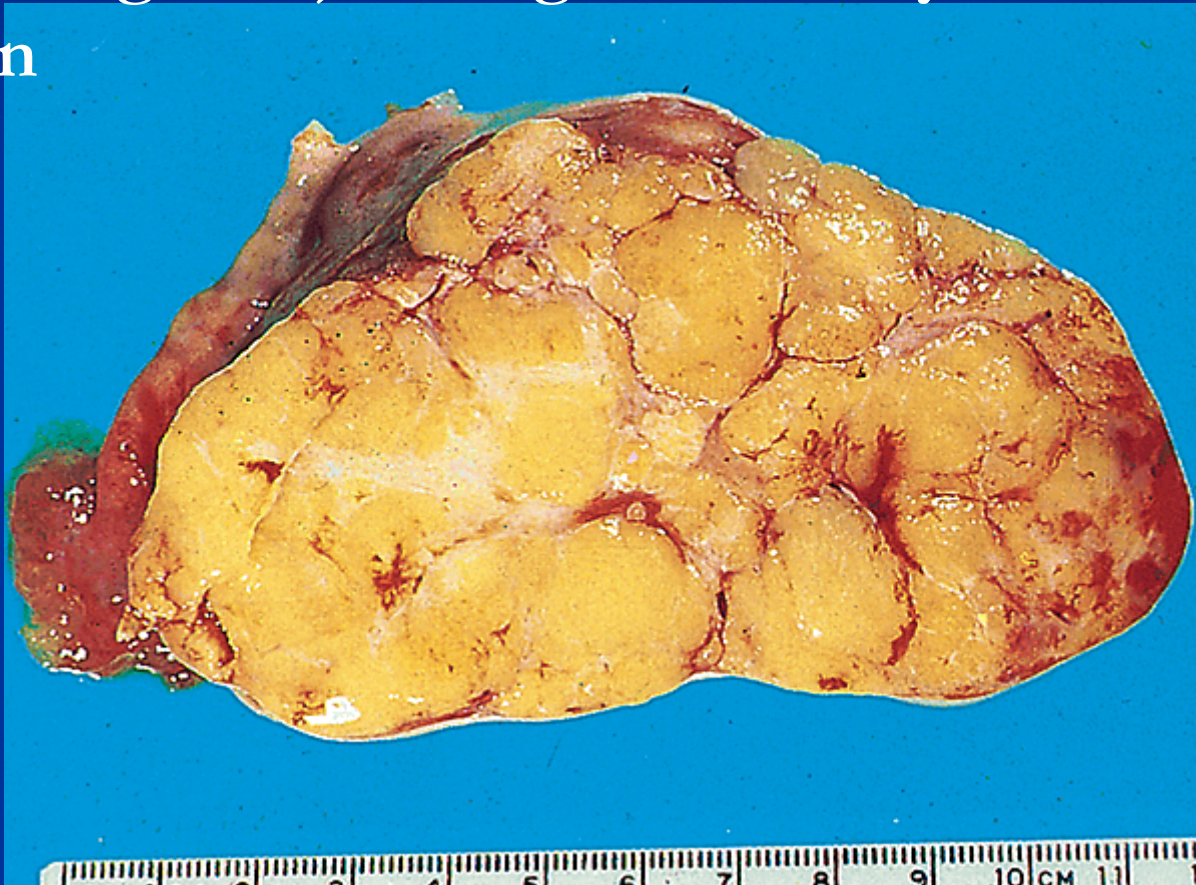


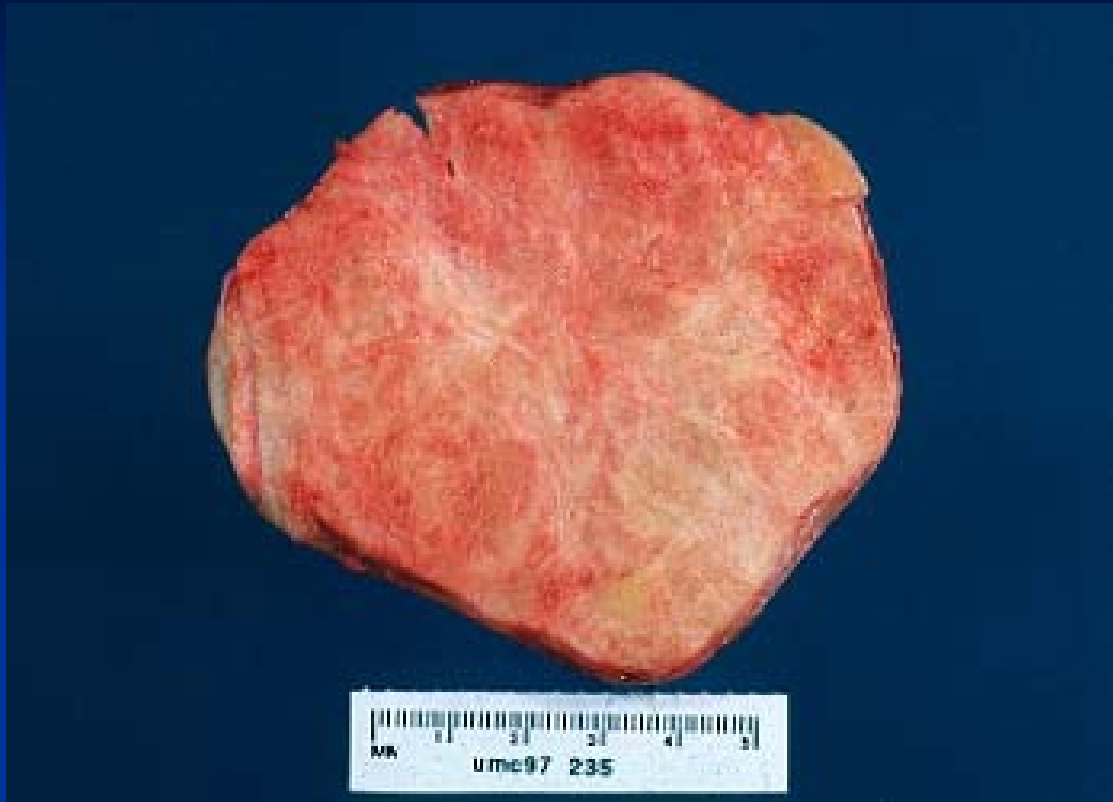

Ovarian fibroma – white-yellowish, solid, firm



Thecoma - solid, lobulated, yellow (lipid containing cells), estrogenic activity common; usually benign





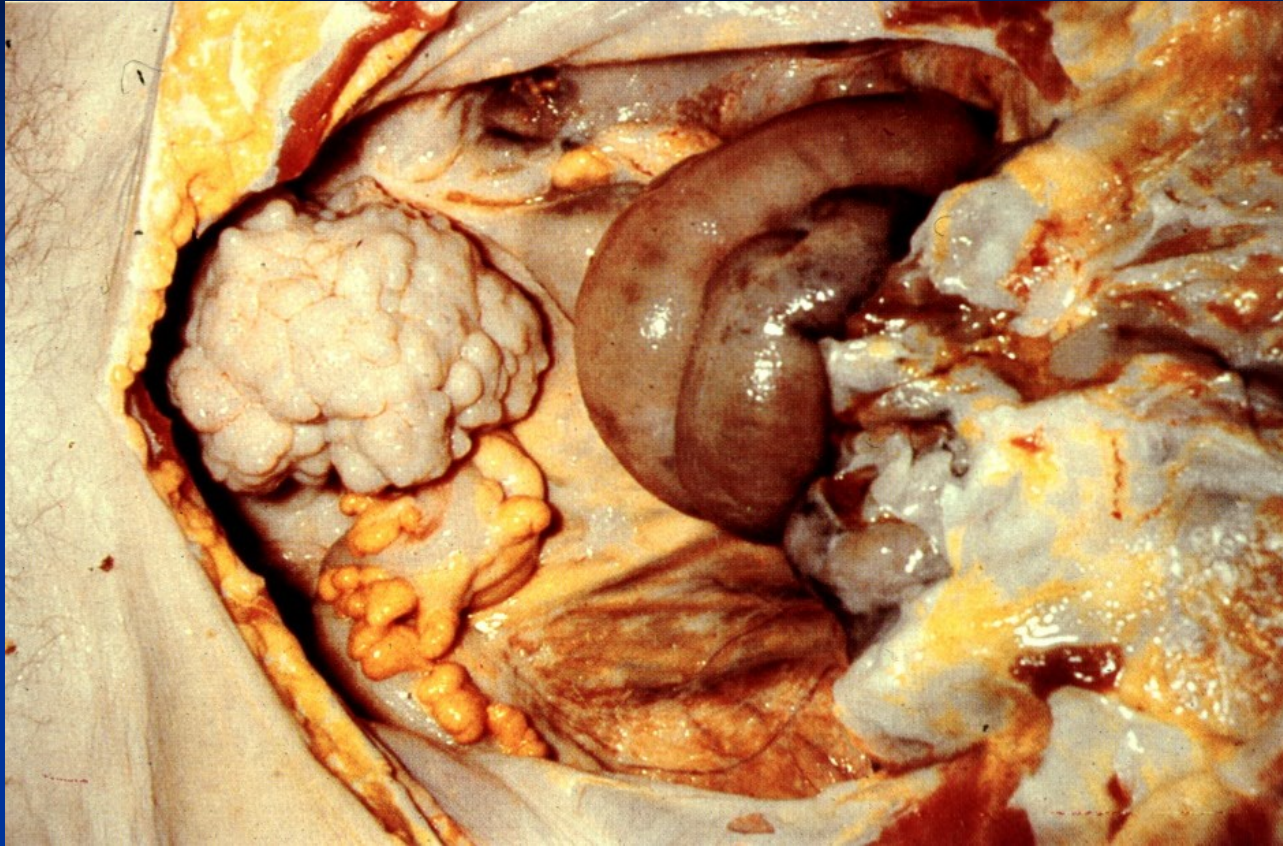
Sertoli-Leydig cell tumor



Metastatic tumors

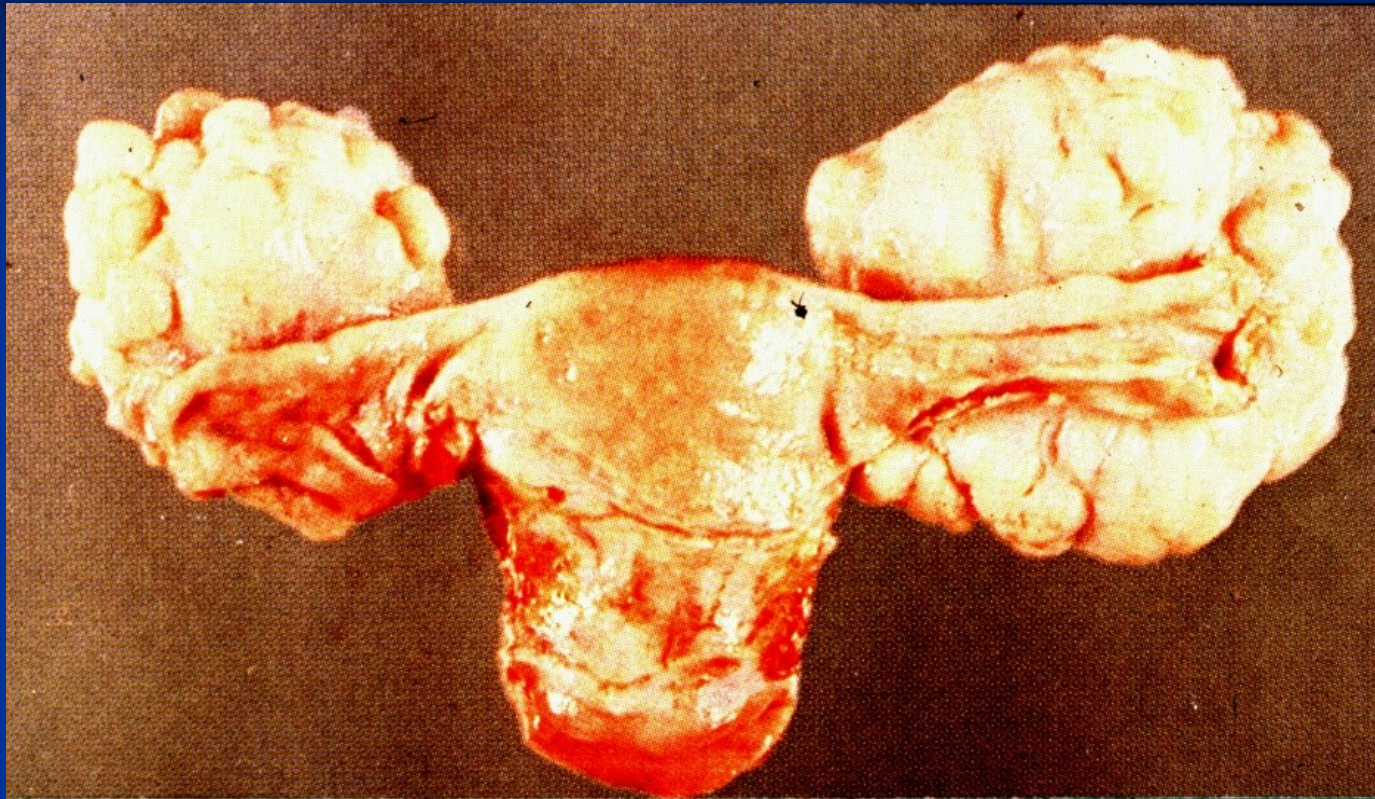
- **GIT** (stomach, colorectal, commonly mucinous adenocarcinoma)
- **breast**
- **! synchronnous primary endometrial ca + primary endometroid ovarian ca**





Krukenberg tumor



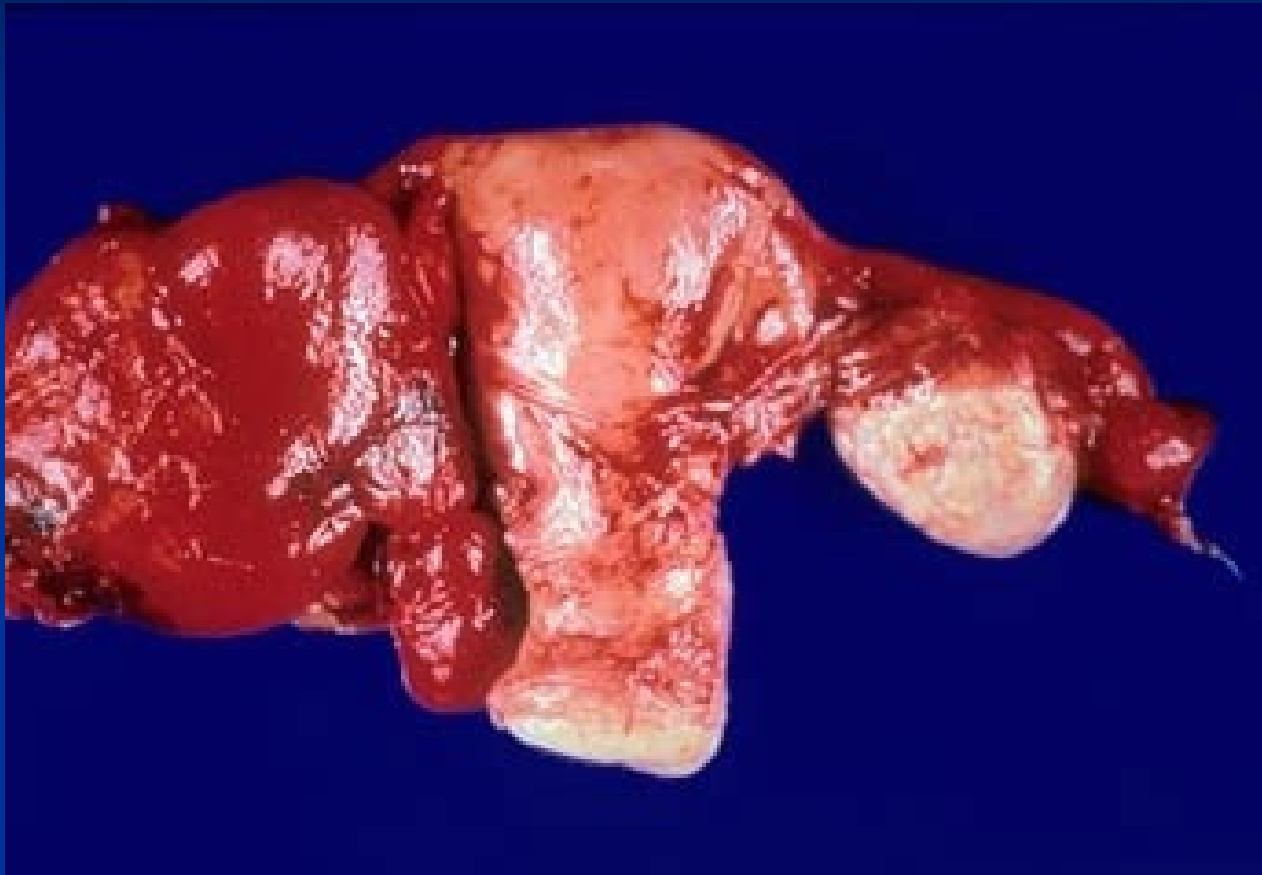


Krukenberg tumor

Fallopian tubes diseases

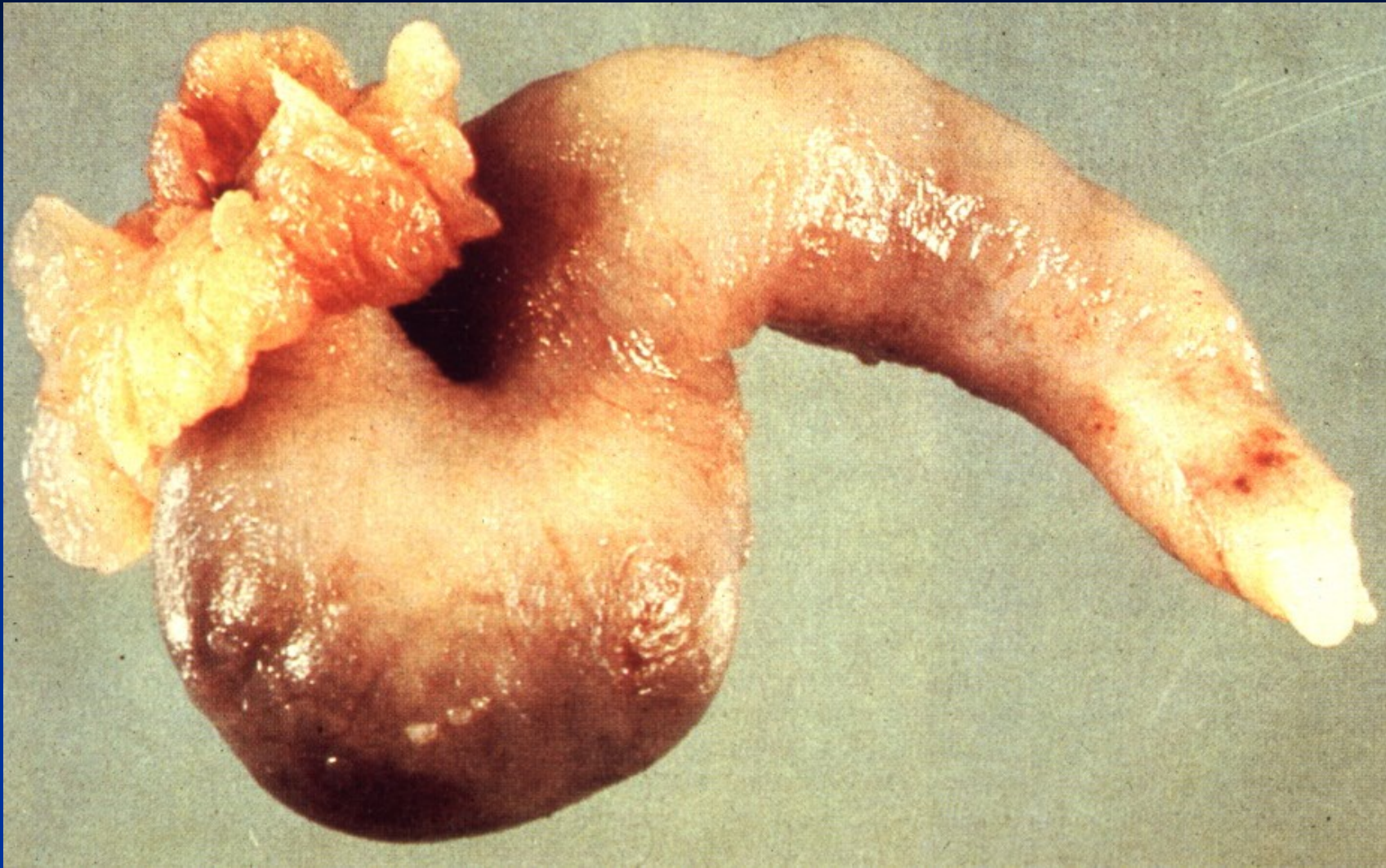
- Inflammation
- Cyst
- Visible tumors confined to fallopian tube rare (serous adenoma), possible focus of dysplasia or in situ carcinoma – most common source of serous ovarian ca
- GEU (ectopic pregnancy)





Acute salpingitis + tuboovarian abscess

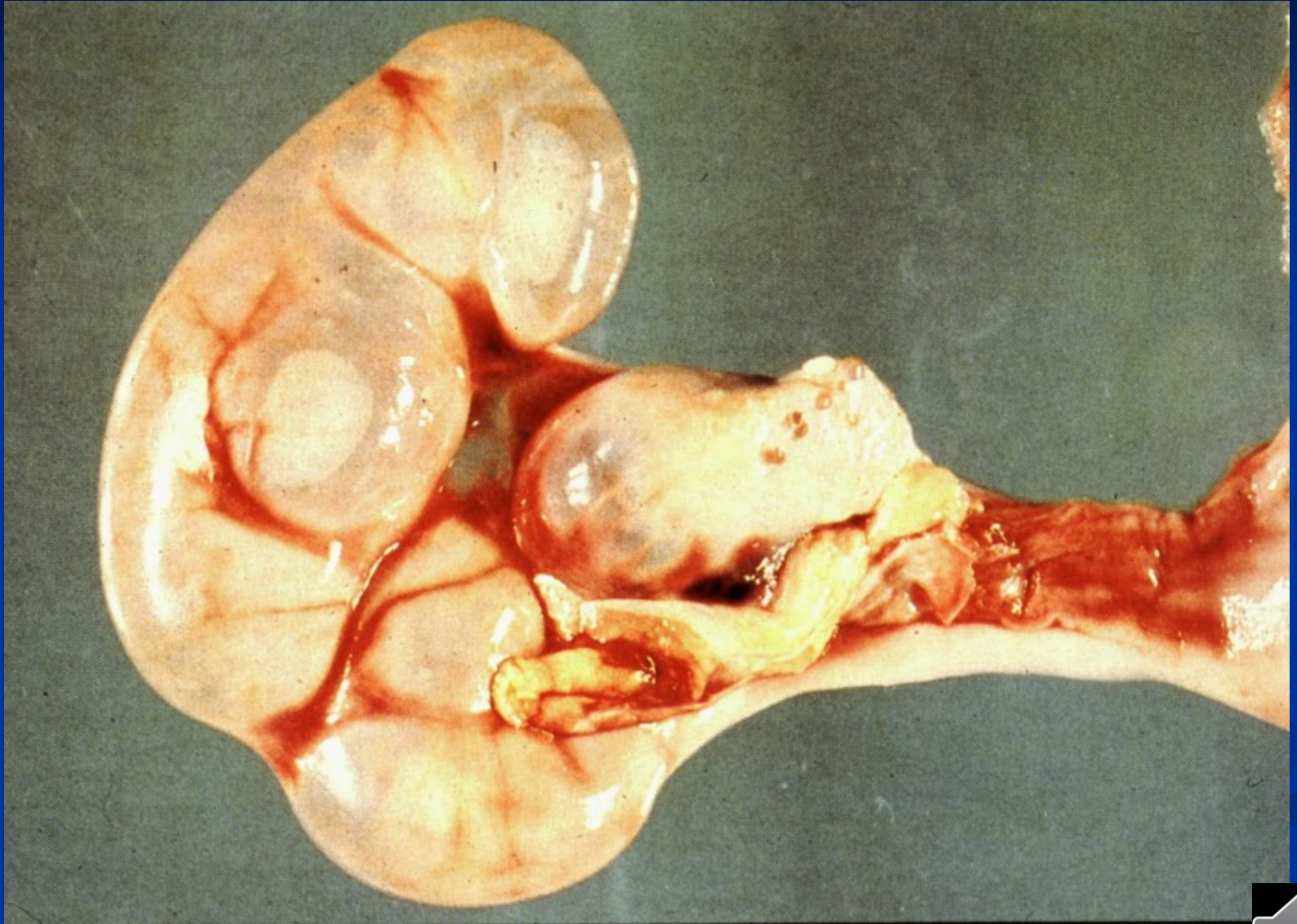




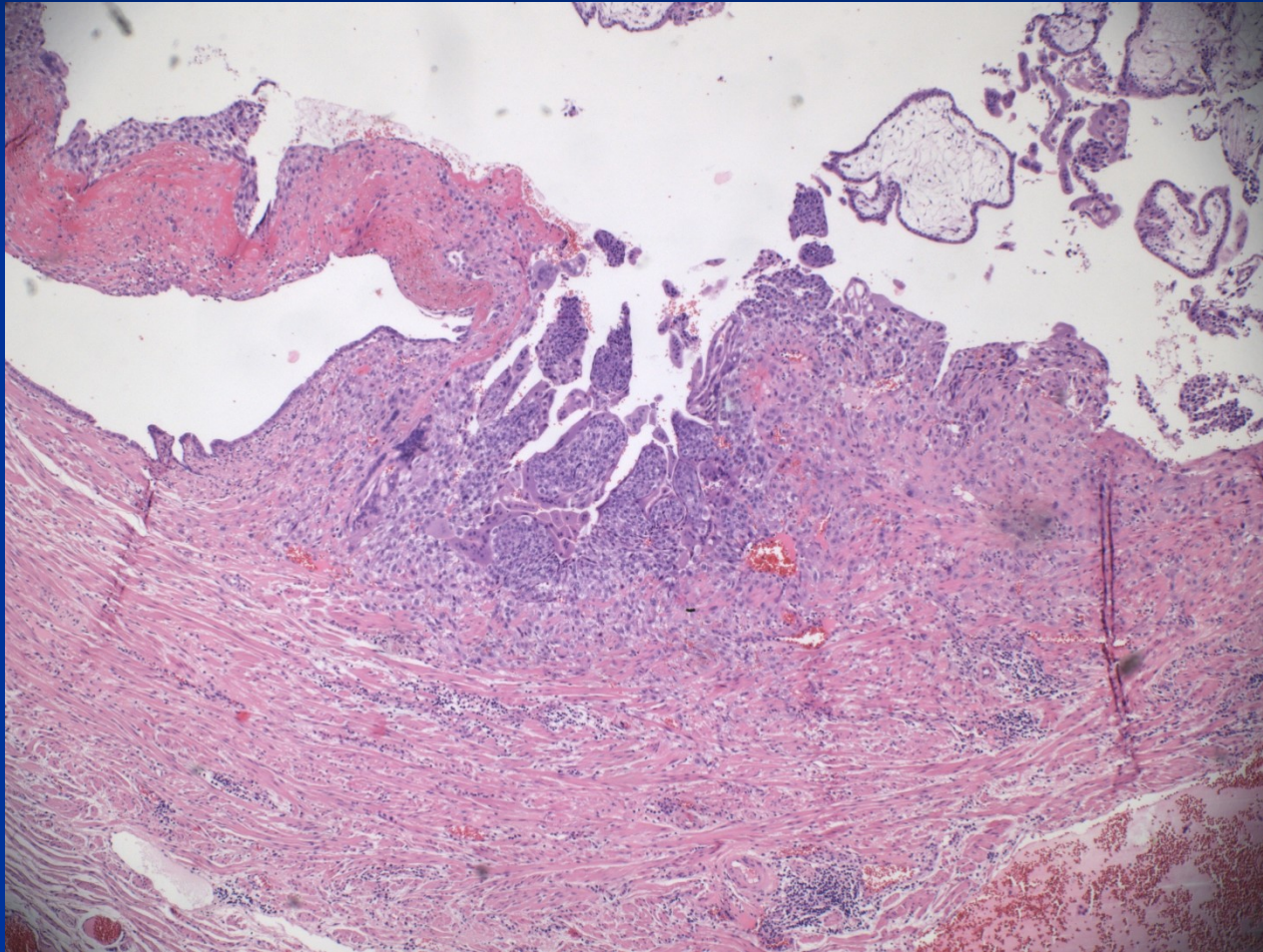
Chronic salpingitis



Hydrosalpinx



Tubal GEU – chorionic villi



Tubal intraepithelial neoplasia

- Most common source of ovarian serous adenocarcinoma

Pathology of uterine corpus

- congenital anomalies
- inflammation
- functional endometrial disorders
- polyps (endometrial etc.)
- adenomyosis
- endometrial hyperplasia
- tumors



Clinical signs

- **Disordered puberty** (praecox, tarda)
- **Sterility, infertility** (incl. repeated abortions)
- **Climacteric disorders**

- **Abnormal bleeding**
- **Pain** (localization, type)
- **Abdominal distention**
- **Systemic signs**



Clinical signs

Abnormal bleeding:

- **Amenorrhea:** no bleeding
- **Oligomenorrhea:** cycle > 35 d.
- **Polymenorrhea:** cycle < 21 d.
- **Hypomenorrhea:** regular cycle , \downarrow bleeding
- **Menorrhagia:** regular cycle, \uparrow bleeding
- **Metrorrhagia:** irregular bleeding outside of the cycle, incl. prepuberty and postmenopause
- **Menometrorrhagia**



Abnormal bleeding

- Newborn: maternal estrogen
- Childhood: trauma!!, infection, tumor
- Adolescence: hormonal imbalance, incl. anovulatory cycle, psychogenic/nutritional problems
- Fertile age: anovulatory cycle, pathologic pregnancy, hormonal imbalance/response, inflammation, polyp, neoplasia
- Post/menopause: hyperplasia, polyp, neoplasia; atrophy



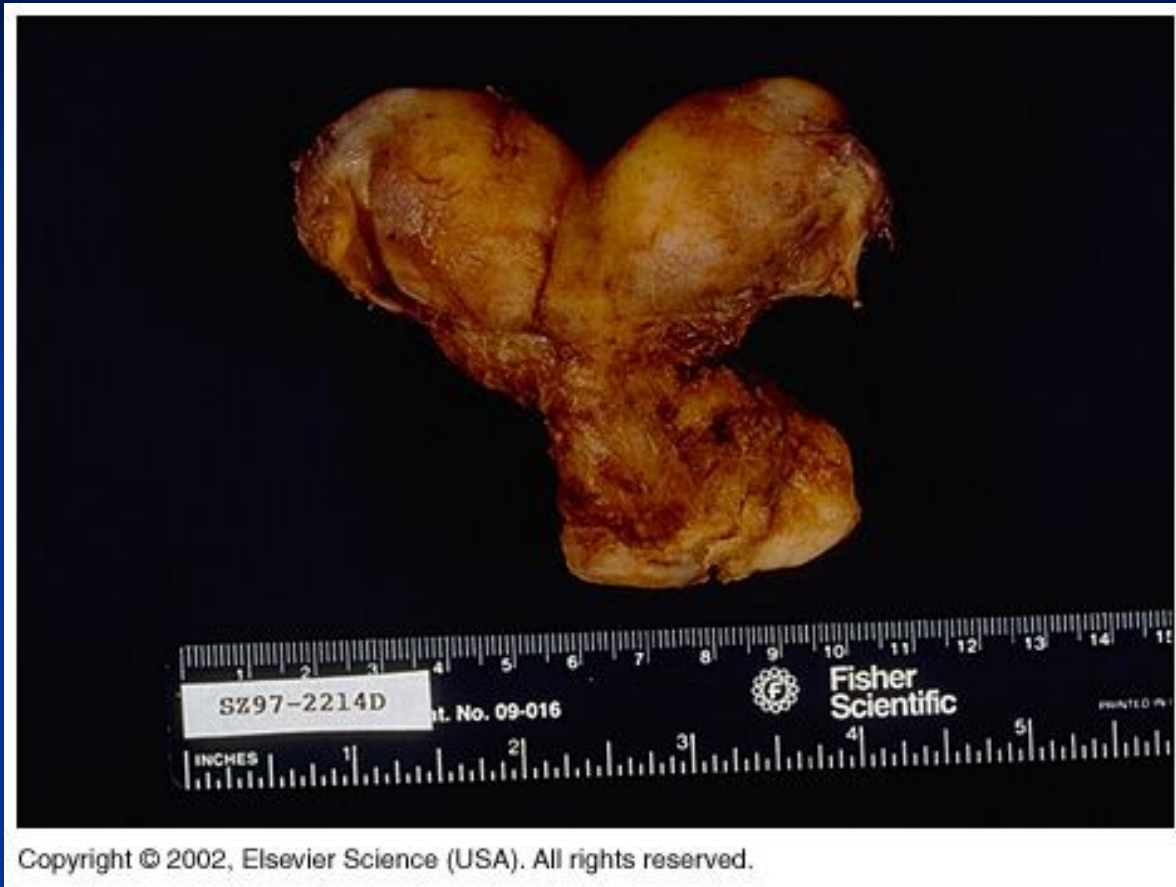Inborn defects

- Complicated embryogenesis, different original tissues (mesoderm → gonads;
paramesonephros → müllerian ducts → ovarian tubes, uterus, upper part of vagina
urogenital sinus → lower part of vagina, vestibulum
mesothelium → ovarian surface, tubal epithelium, endometrium

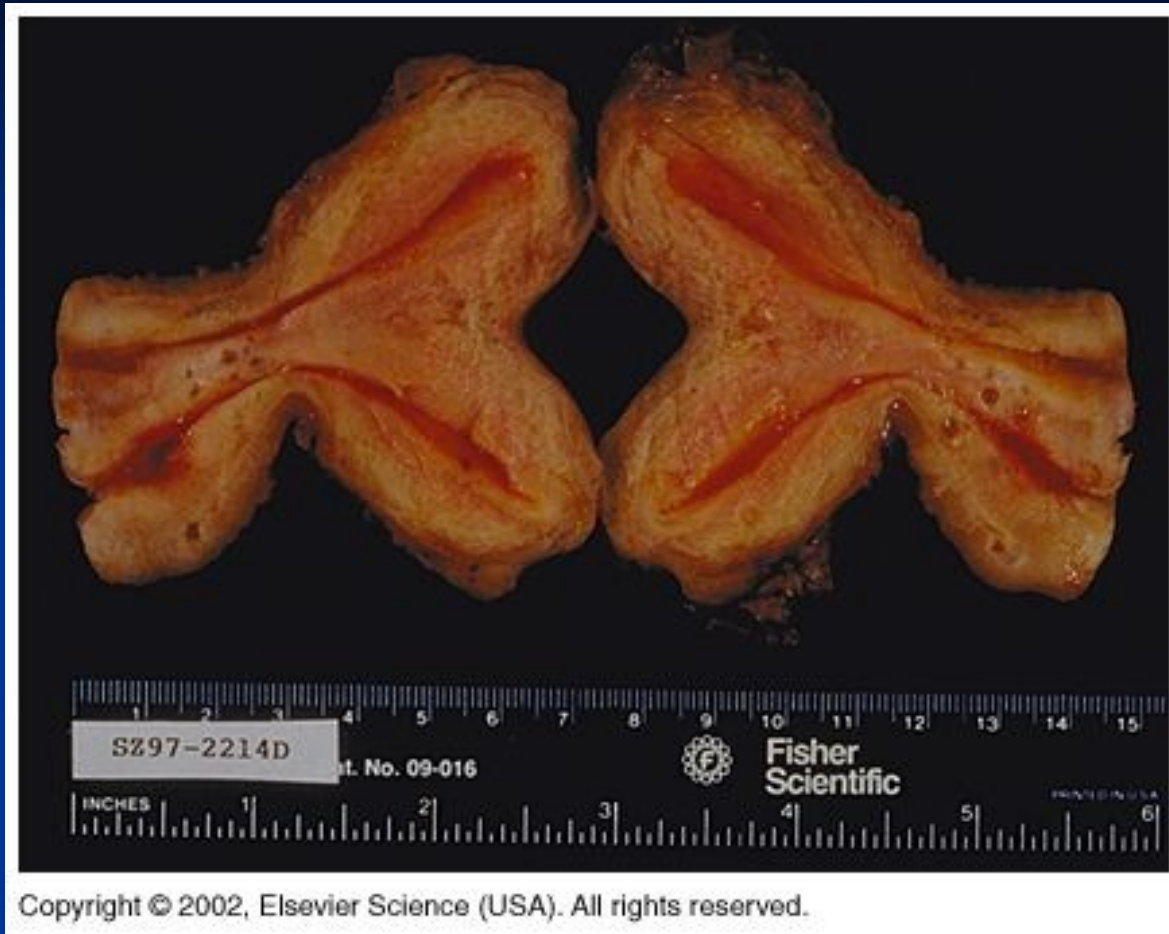


Inborn defects

- Temporary uterine septum → if persistent, uterus didelphys, uterus bicornis.
- Müllerian ducts atresia → complete aplasia of uterus etc.

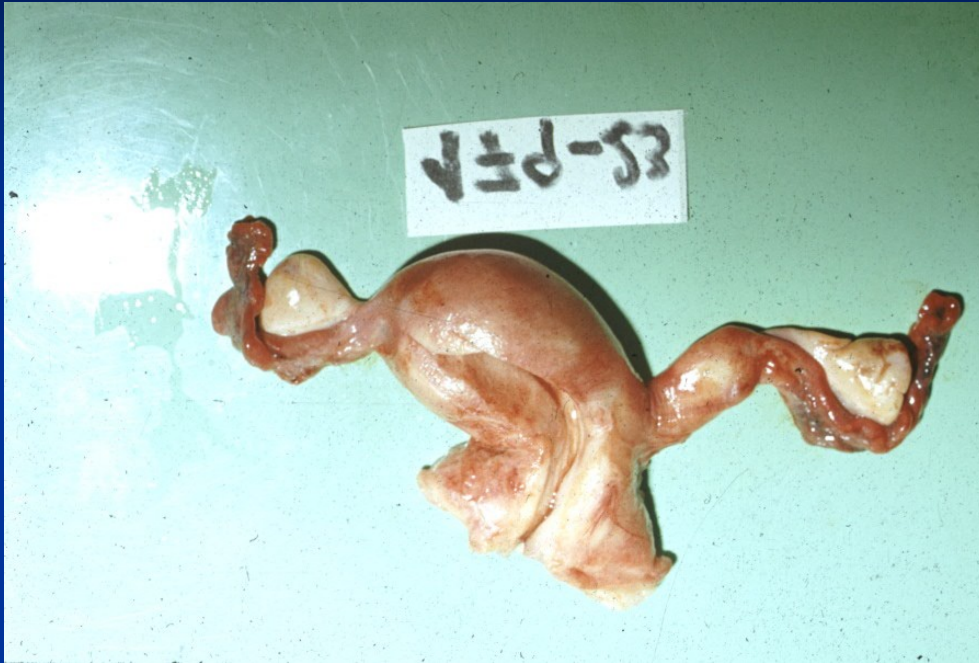

Uterus bicornis – persistence of temporary embryonal septum



Uterus didelphys





Uterus unicornis with rudimentary horn

Disorders of menstruation cycle

- Psychogenic – sec. amenorrhea, psychogenic sterility
- Hypothalamic
- Pituitary – idiopathic, sec. (infl., tumors,...)
- Gonadal
- Uterine
- Metabolic – endocrine (thyr., adrenals), hepatic
- Nutritional



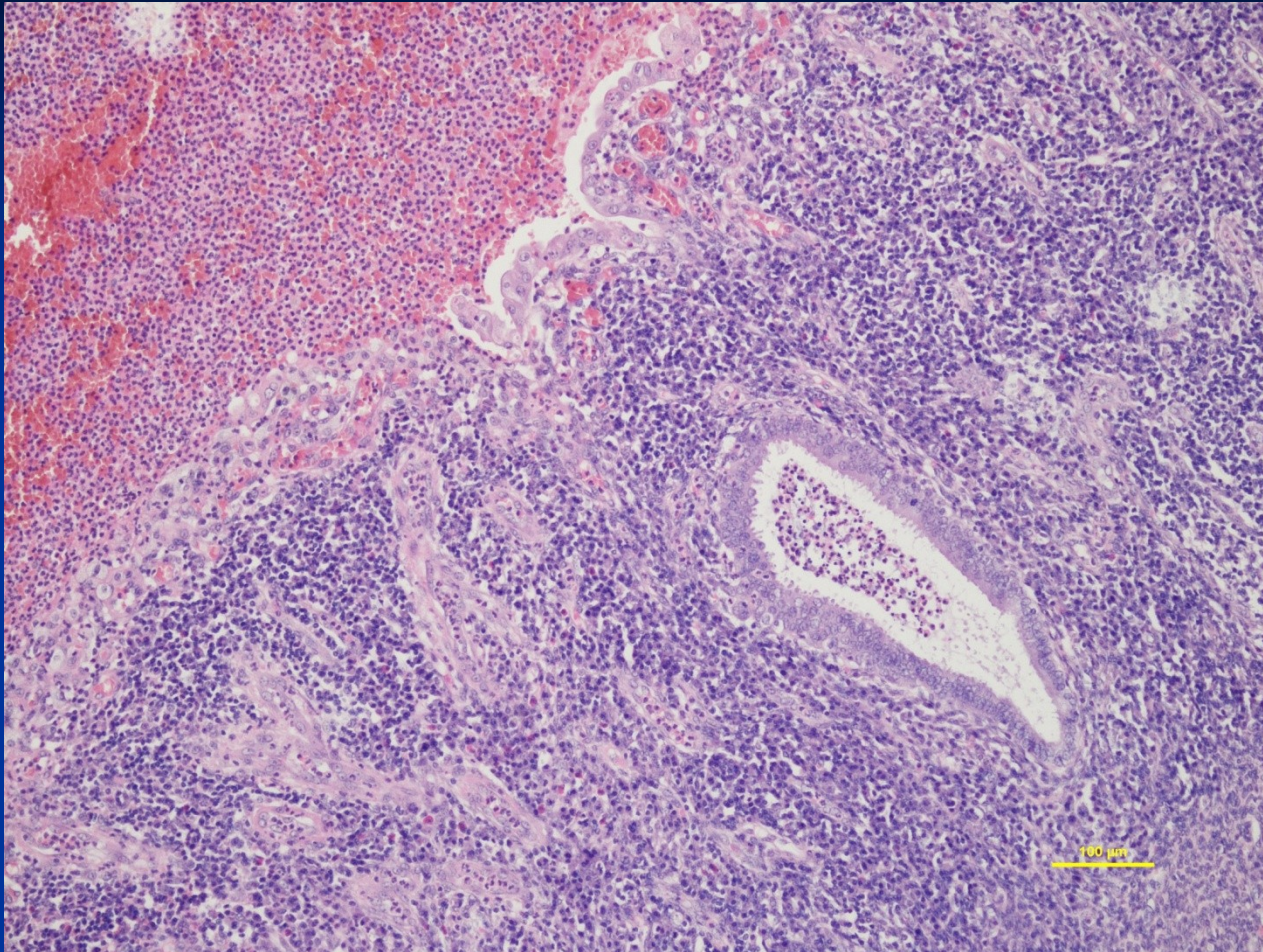
Acute nonspecif. endometritis

- mixed pyogenic flora (endogenous) Clostridium welchii; STD – Neisseria gonorrhoeae, Chlamydia trachomatis, mycoplasma – commonly into chronicity
- **signs** - fluor, metrorrhagia, local pain, systemic signs, sepsis possible (puerperal)
- **gross** – hyperemia, petechiae, endometrial ulcerations; gangrena
- **micro** – mixed inflammatory infiltrate in intersticium and glands, abscess, necrosis, thrombosis, haemorrhagia



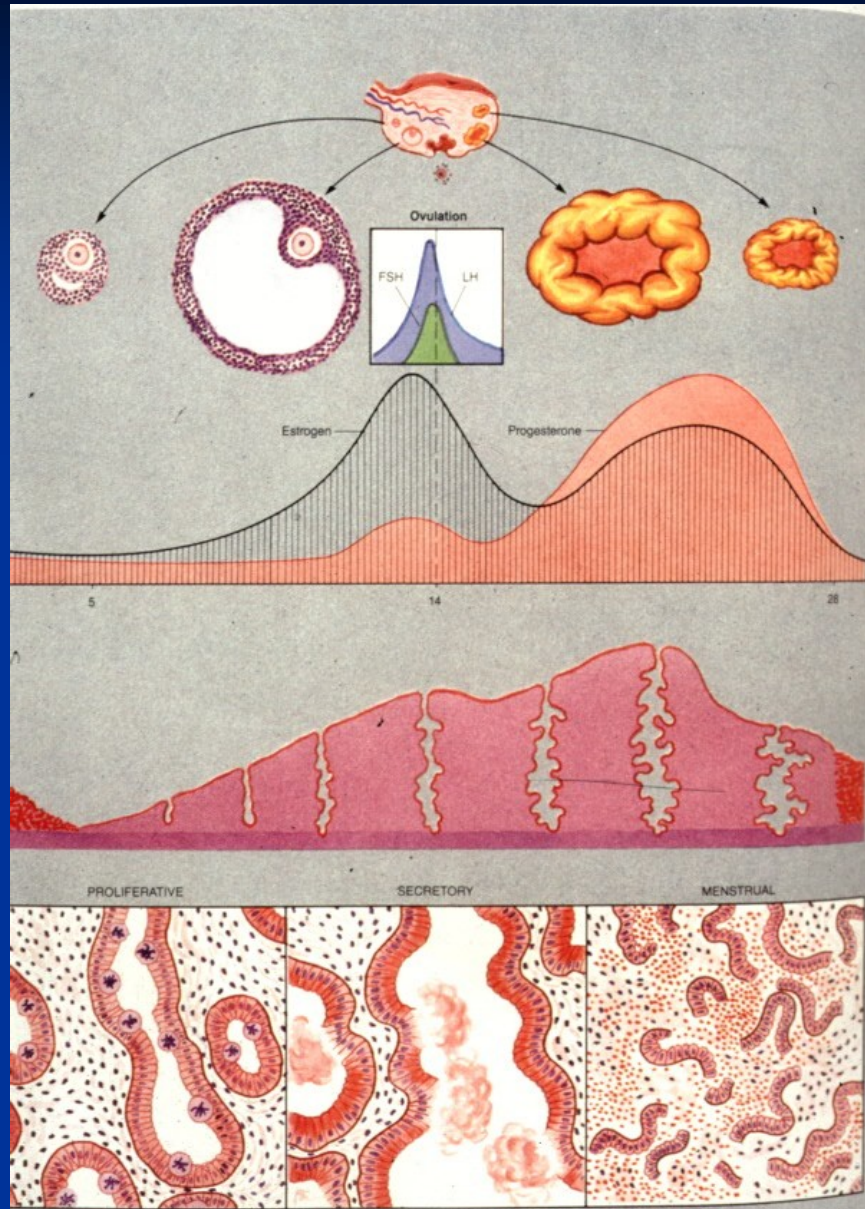
Acute nonspecific endometritis

- **ac. complications:** ac. myometritis, parametritis (→ pelvic veins thrombosis), salpingitis (→ peritonitis), sepsis
- **chron. complications:** chron. endometritis (→ irregular bleeding, infertility; plasma cells in infiltrate, stromal changes, irreg. glands)
tubal stenosis, adhesions (→ infertility, GEU);
pelvic inflammatory disease (local + systemic symptoms)



Acute endometritis





Functional endometrial changes

- **anovulatory cycle** – estrogenic stimulation (proliferation) without progestins
- **luteal insufficiency** – insufficient secretory transformation
- **irregular shedding** – irreg. response on hormone level drop
- **hypersecretion, Arias-Stella phenomenon** – ↑ progestins + stimulation; clear cells, reactive atypias

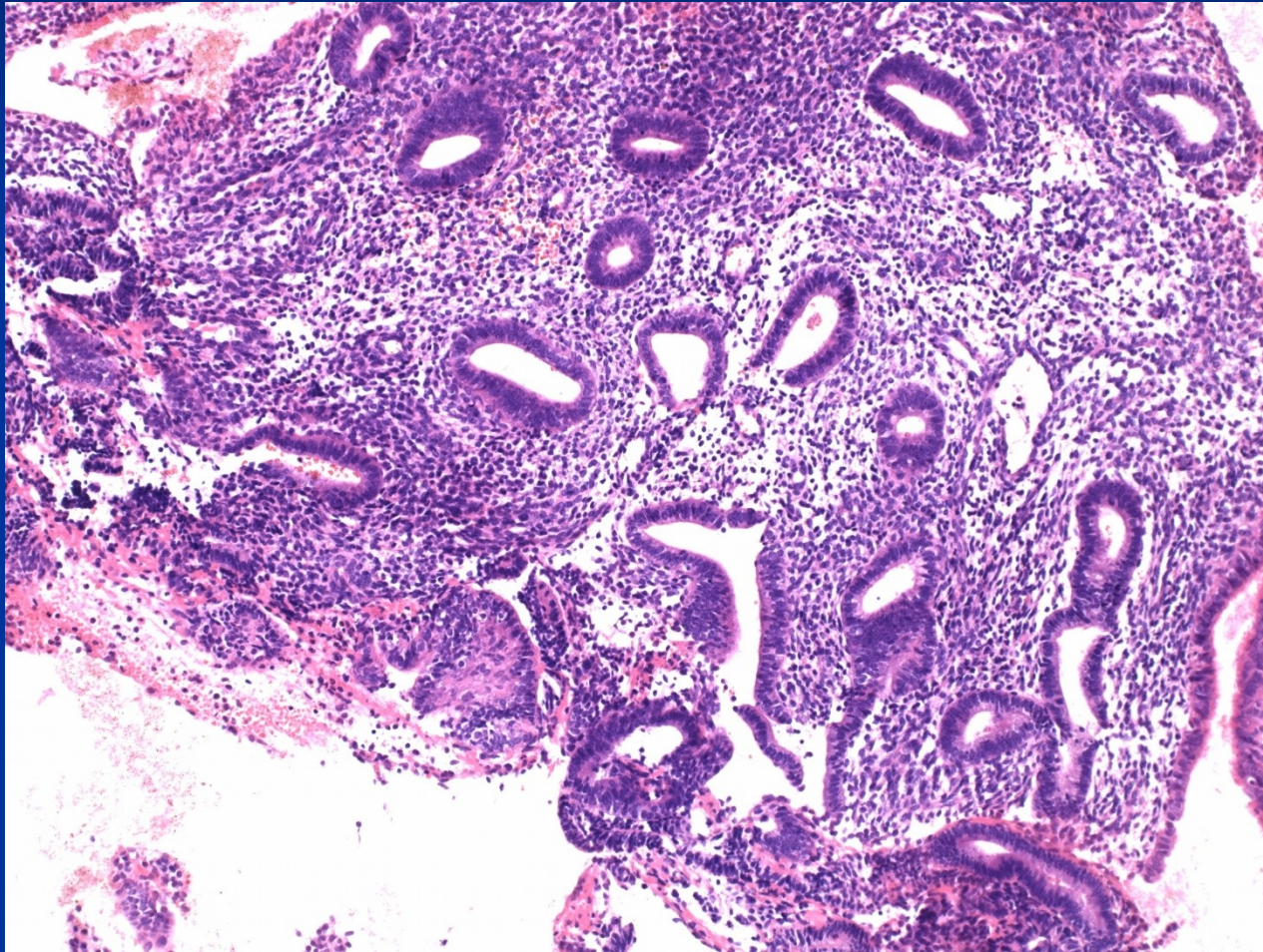


Iatrogenic endometrial changes

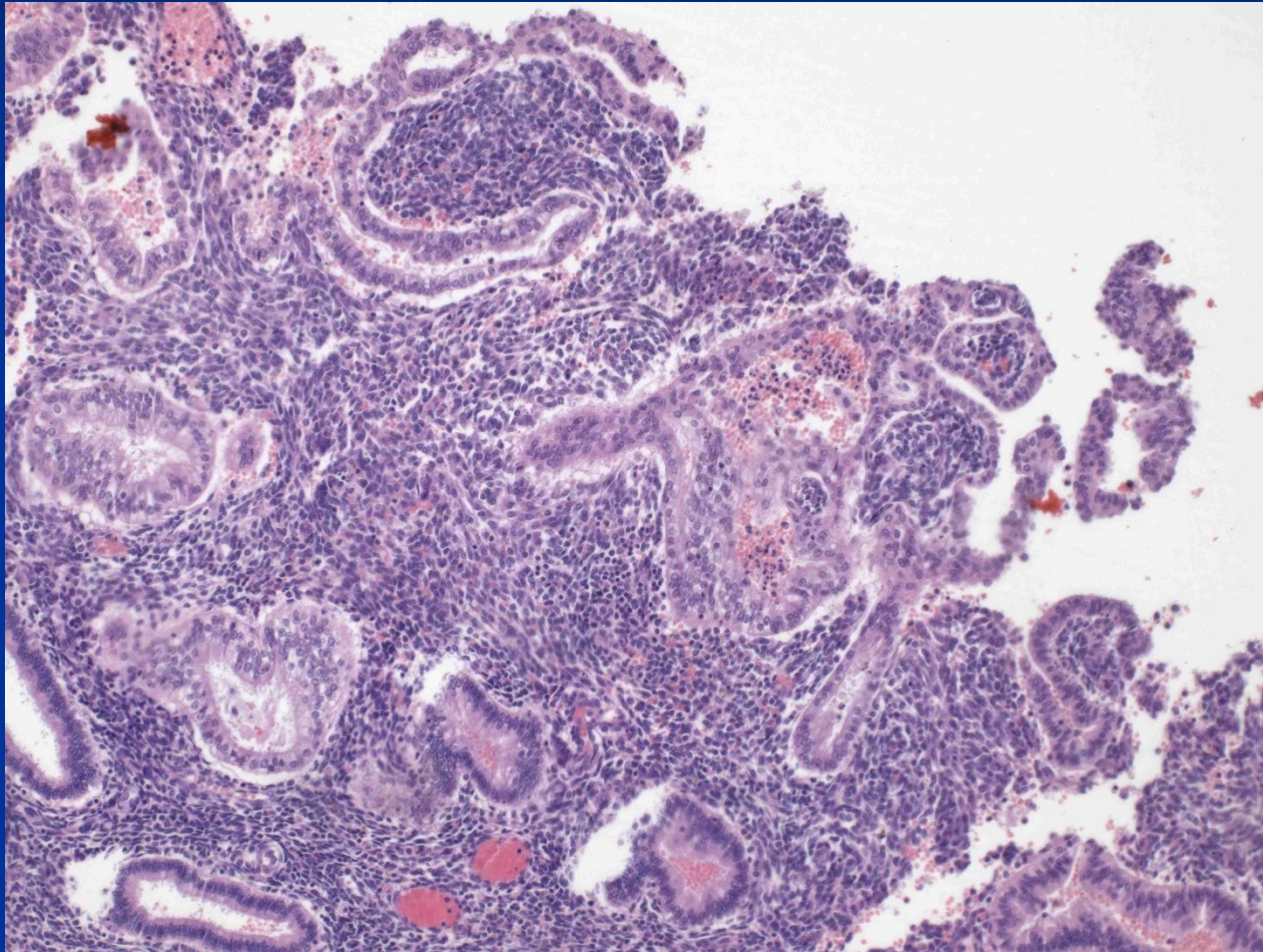
- **exogenous hormones – contraception:** variable appearance, combination → inactive to atrophic endometrium, progestins → stromogland. dissociation etc.
- **hormonal substitution therapy:** without HYE, combination prep. (risk of hyperplasia, ca)
- **IUD long-standing:** inflammation(focal. ac., chron. – actinomyces), ulceration, irreg. endometrium, metaplasia, thrombosis
- **tamoxifen:** endom. polyps, hyperplasia, ca
- **surgery, radiotherapy**



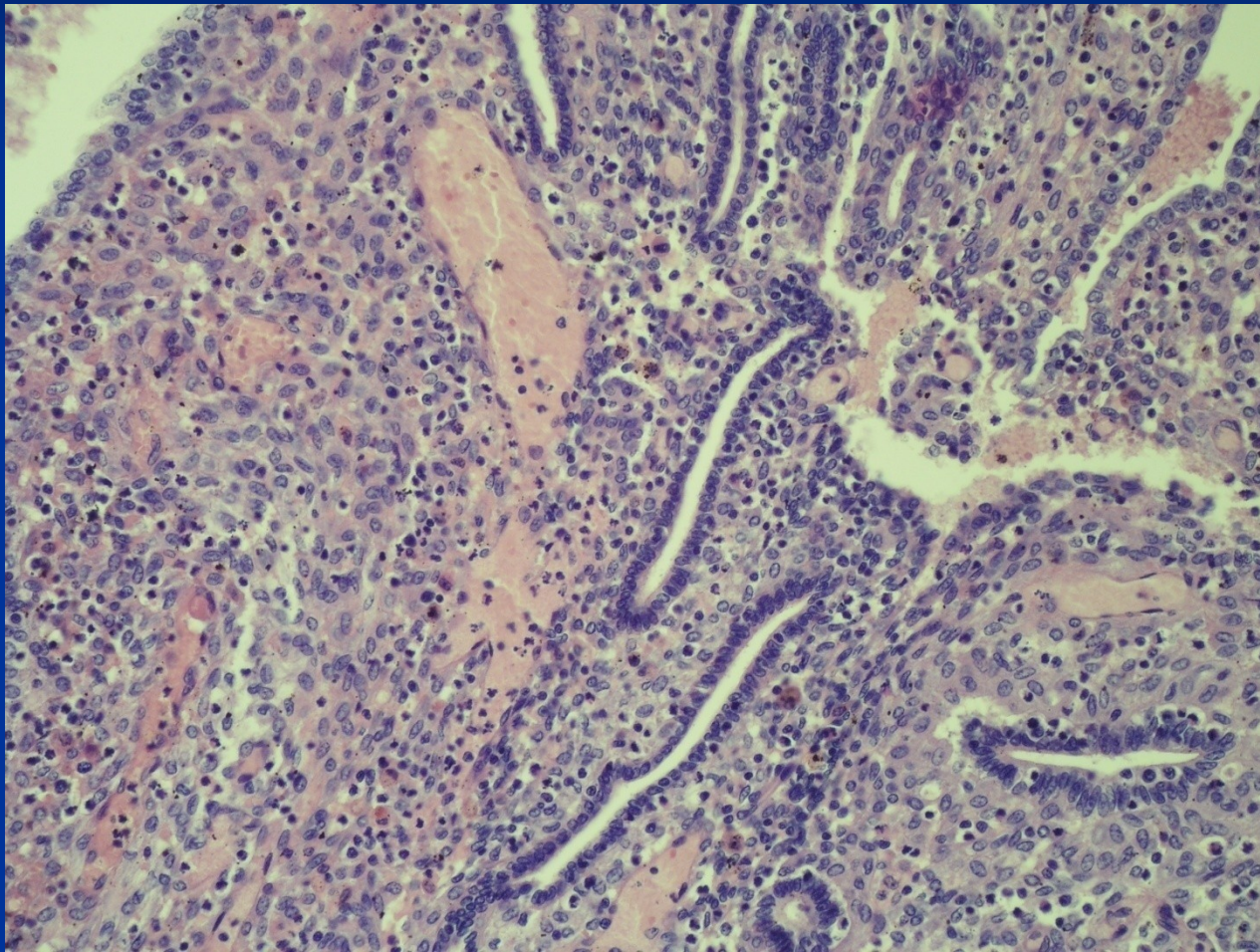
Irregular proliferation



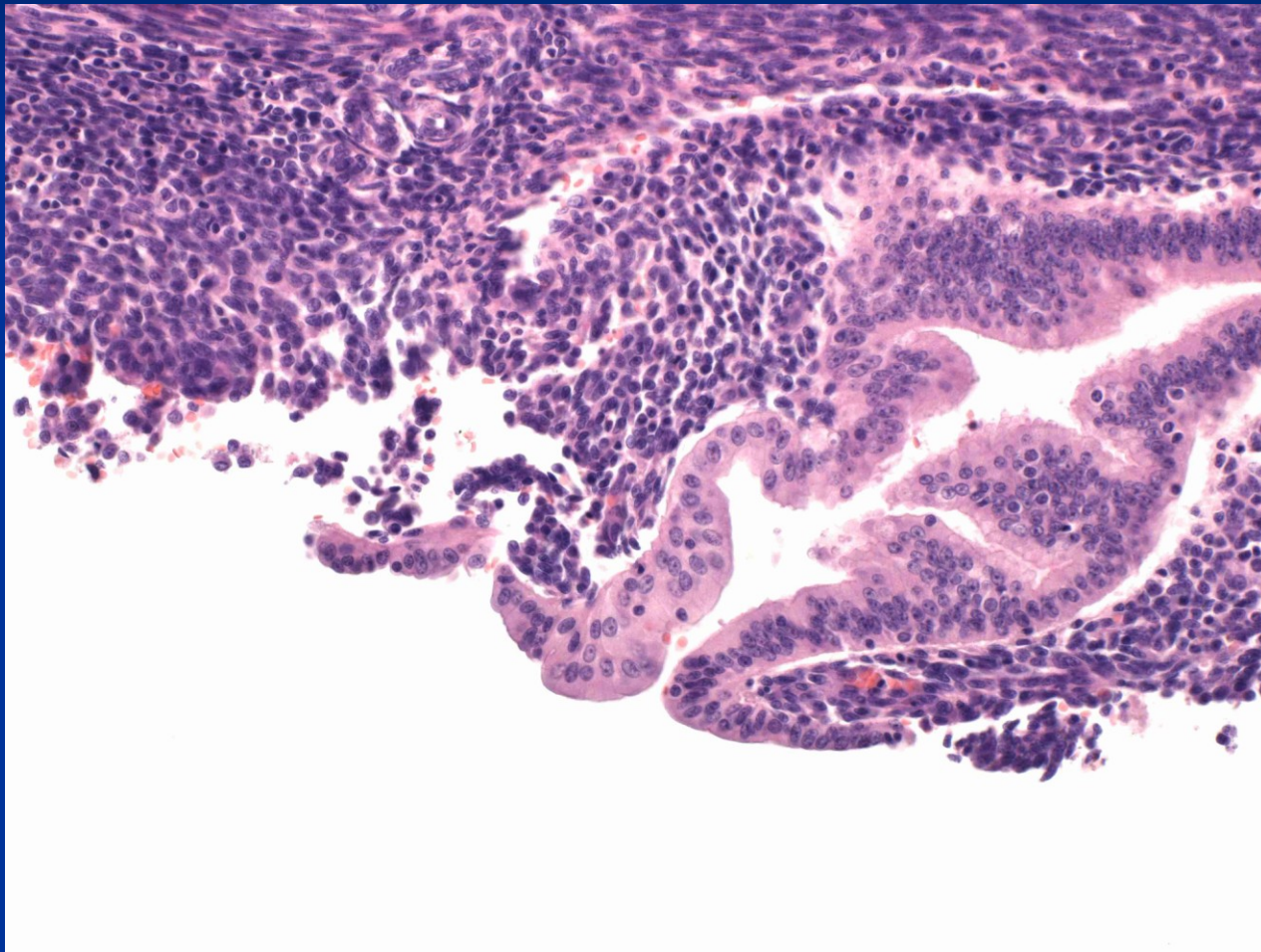
Disordered early secretion - ovulation



Stromoglandular dissociation



Epithelial changes - eosinophilic



Polyps

- Endometrial polyp
- Polypoid hyperplasia
- Hyperplasia and polyps in tamoxifen ther.
- Polypoid tumors – adenomyoma, carcinoma, submucosal leiomyoma, stromal tumors, etc.
- Pathological pregnancy (trofoblastic lesions, decidua etc.)
- Pseudotumors – pathol. material accumulation etc.

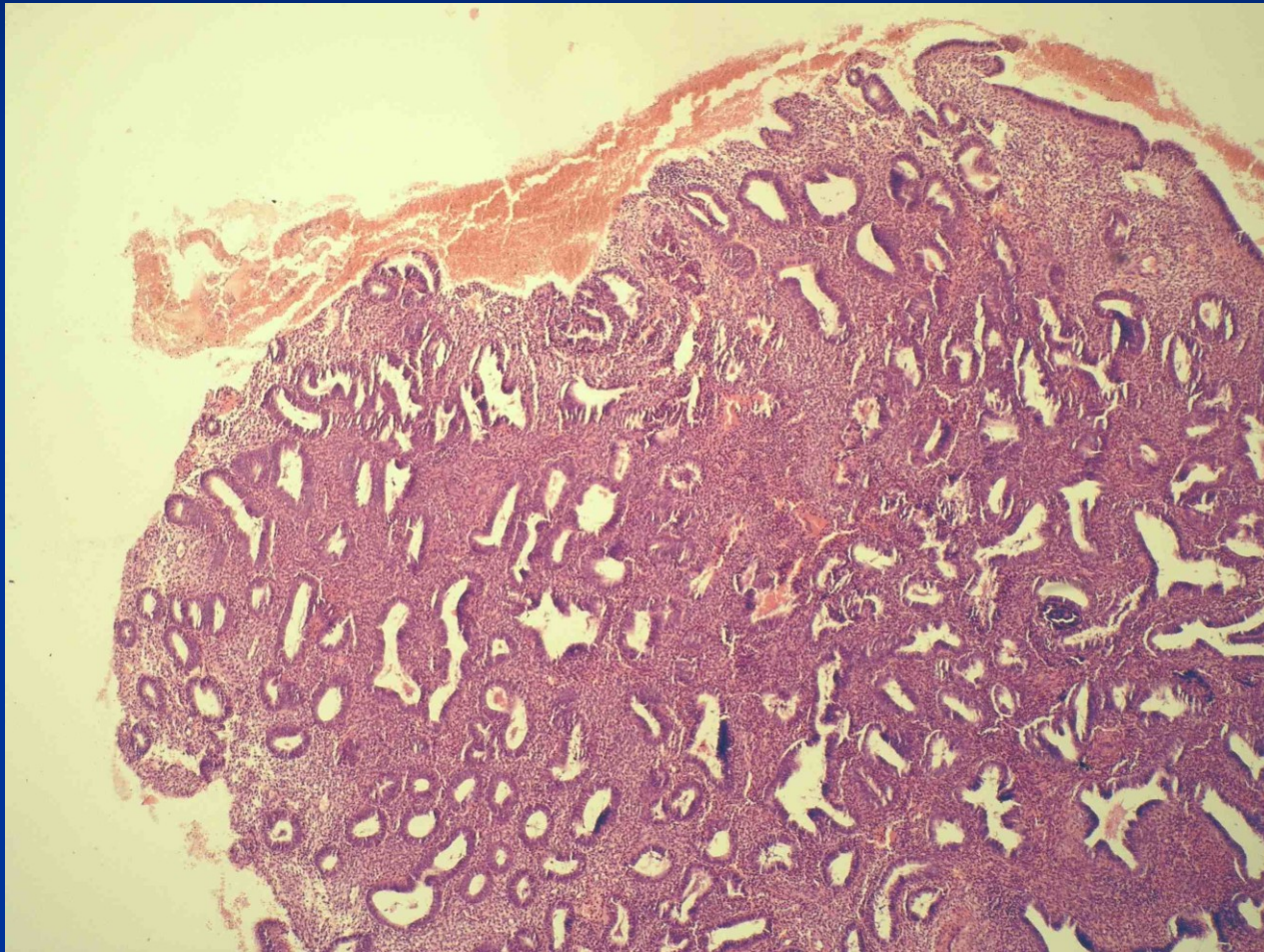


Endometrial polyp

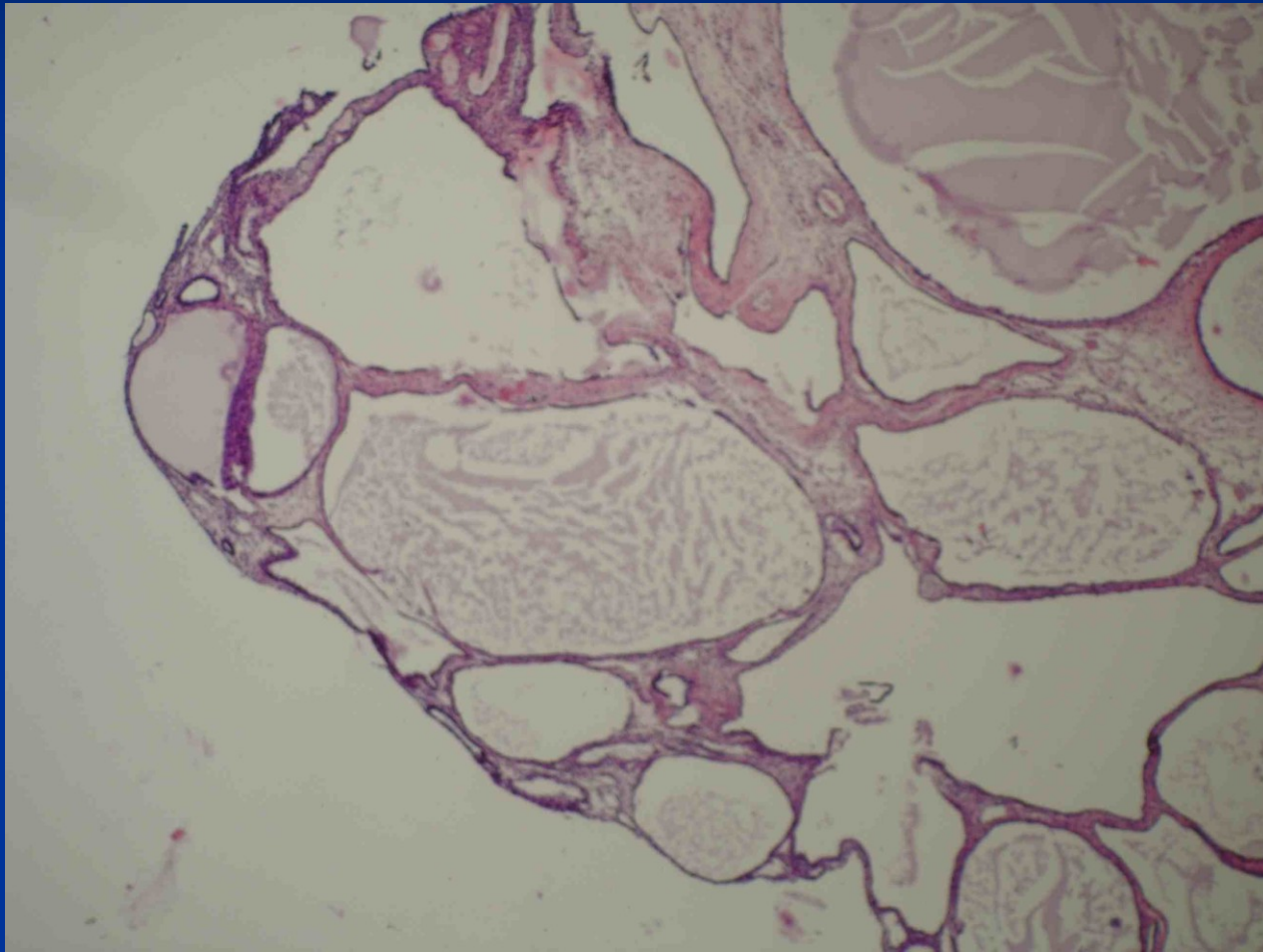
- Possible iatrogenic origin (tamoxiphen)
- up to $\frac{1}{4}$ women during fertile life
- common in climacterium
- dysfunctional bleeding
- possible cause of infertility
- possible start/localisation of endometrial ca



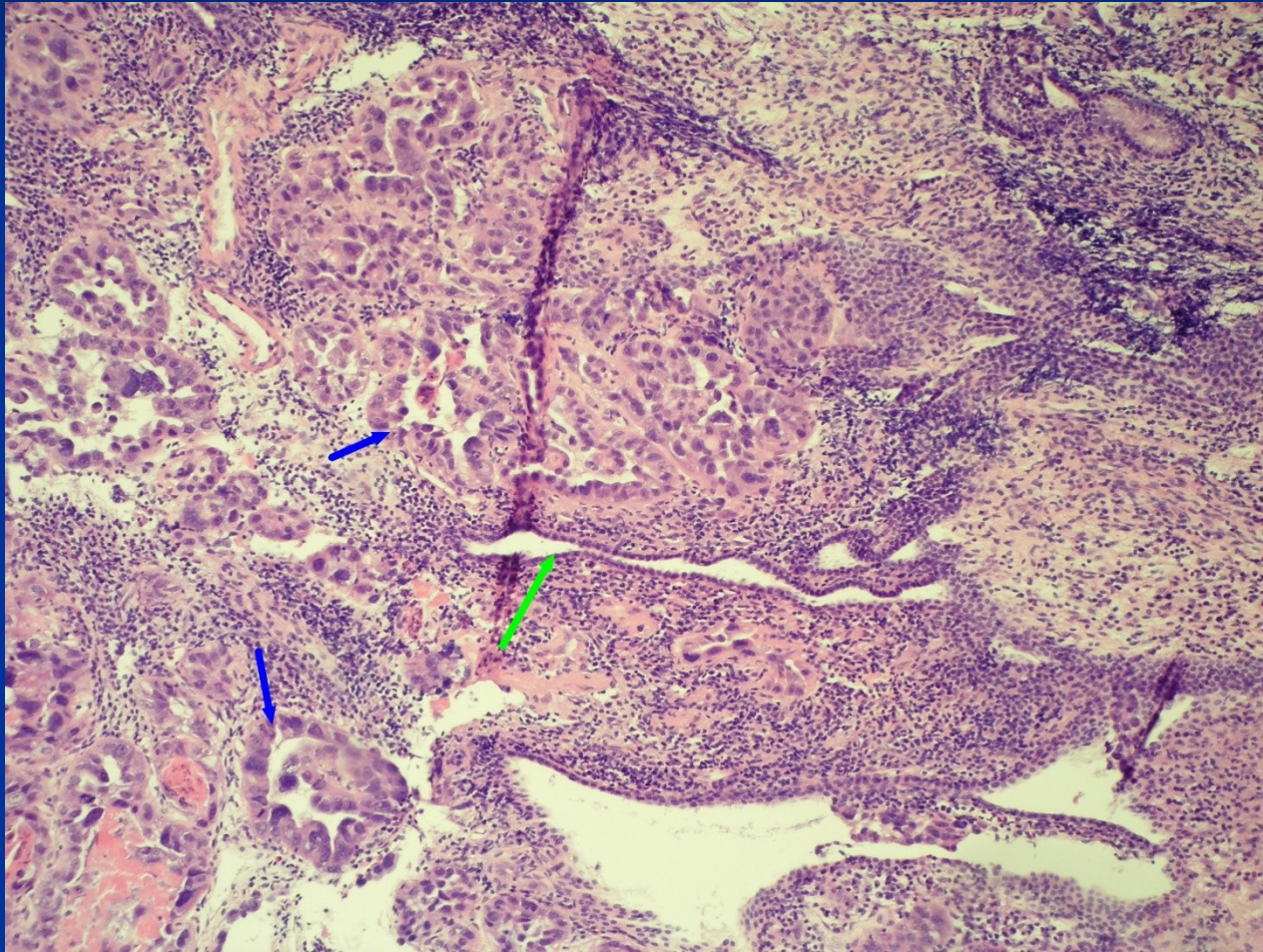
Endometrial polyp



Endometrial polyp



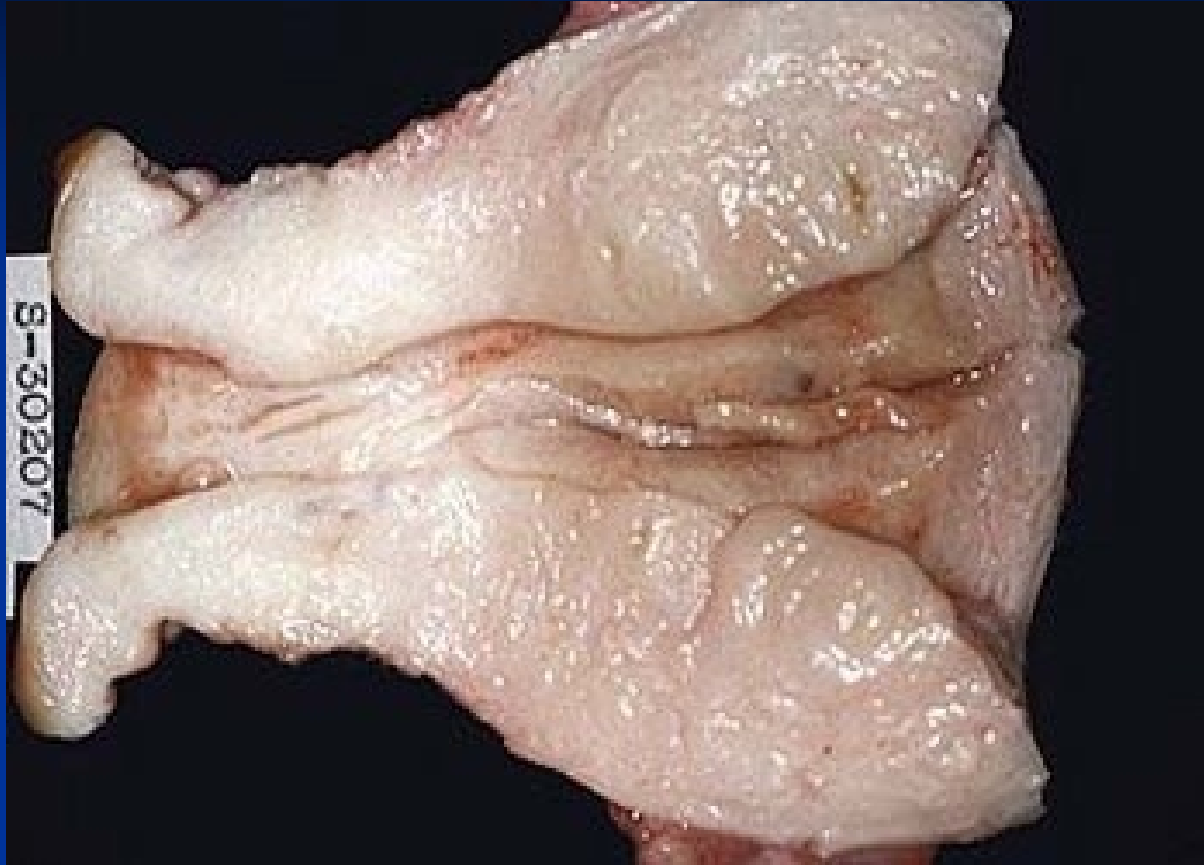
Endometrial ca in a polyp



Adenomyosis

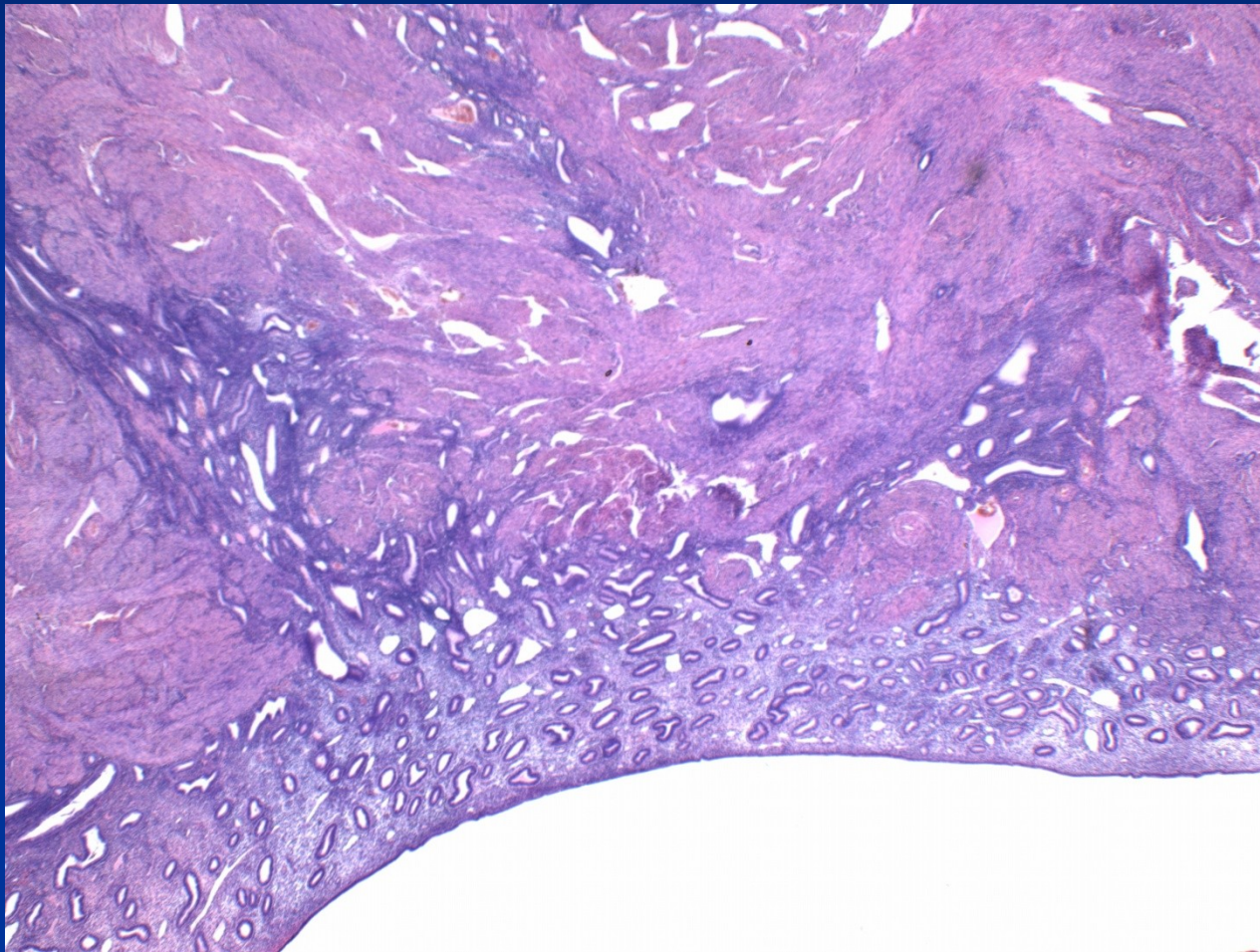
- irregular bleeding, dysmenorrhea, pelvialgia
- more common in perimenopause after repeated births („diverticulosis“)
- may predispose to uterine prolaps into vagina
- myometrial reaction incl. hyperplasia
- possible origo of endometrial tu in myometrium (! x ca invasion into myometrium)



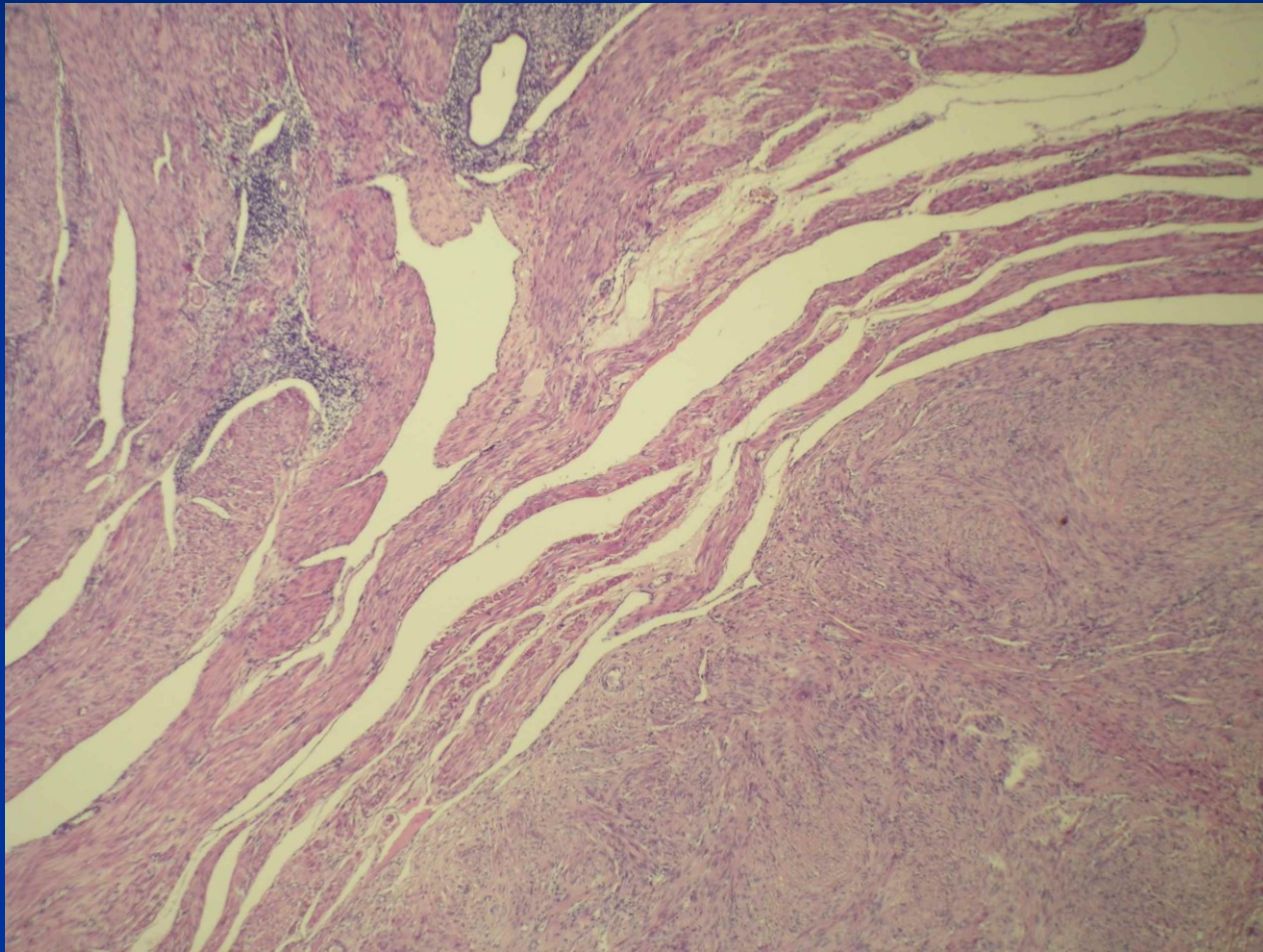


Adenomyosis

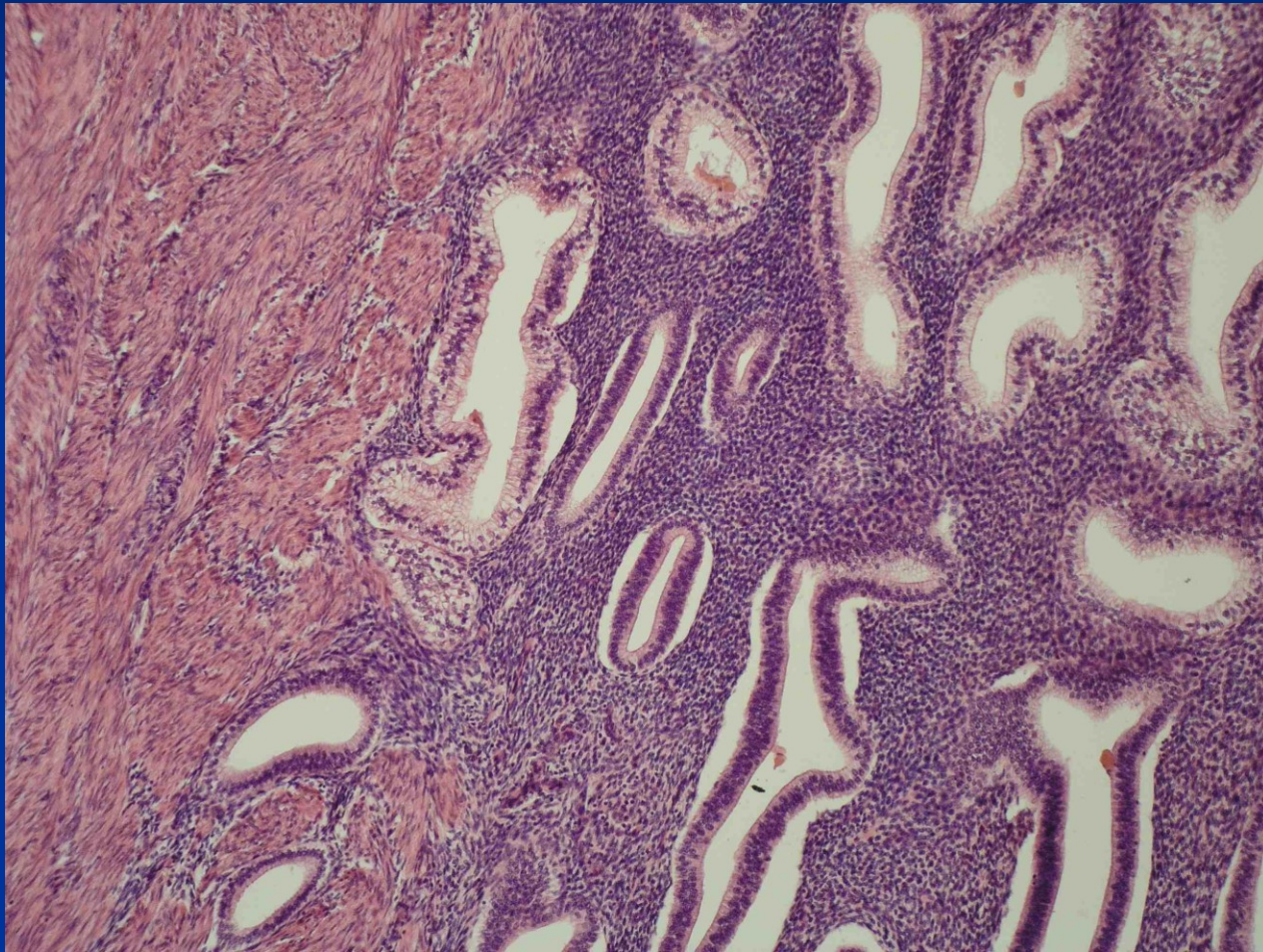
Adenomyosis



Adenomyosis + leiomyoma



Adenomyosis

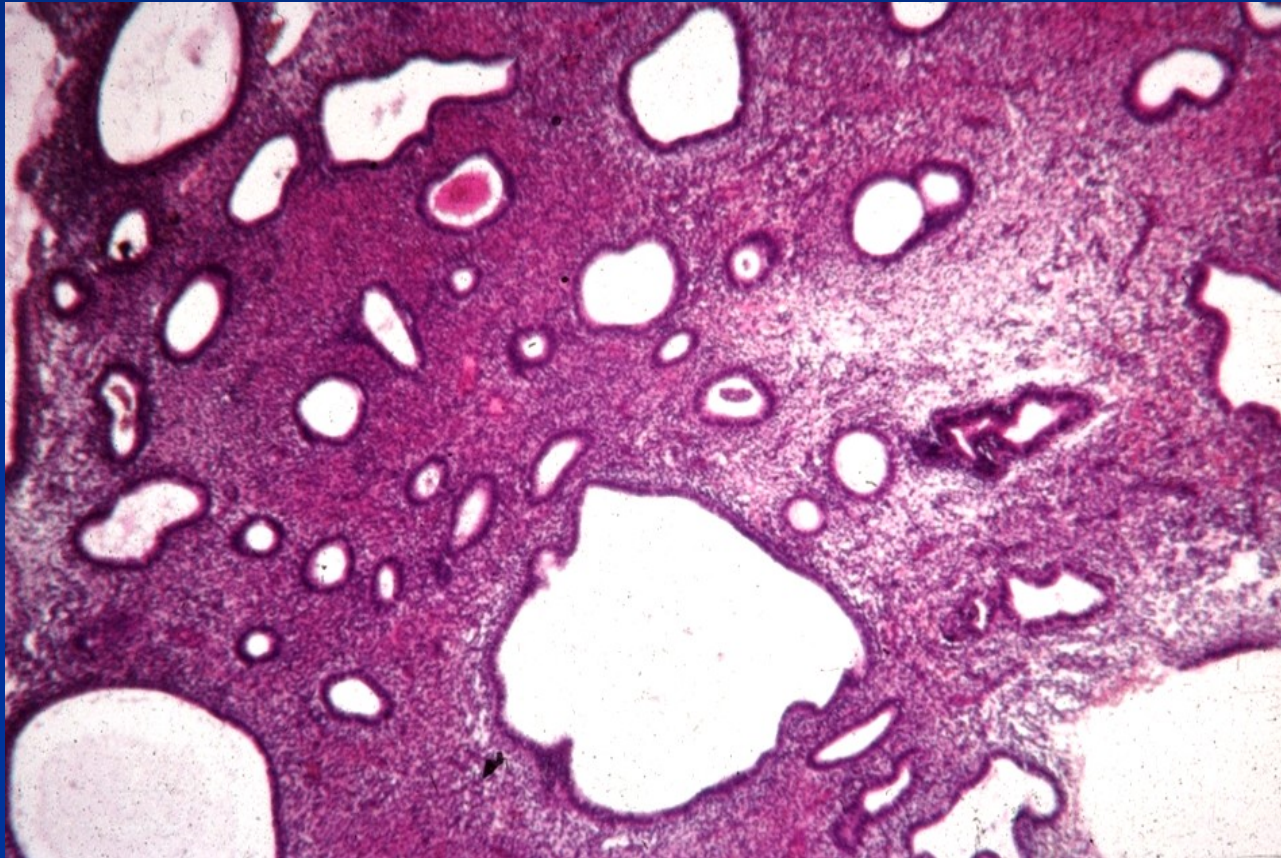


Hyperplasia, intraepithelial neoplasia

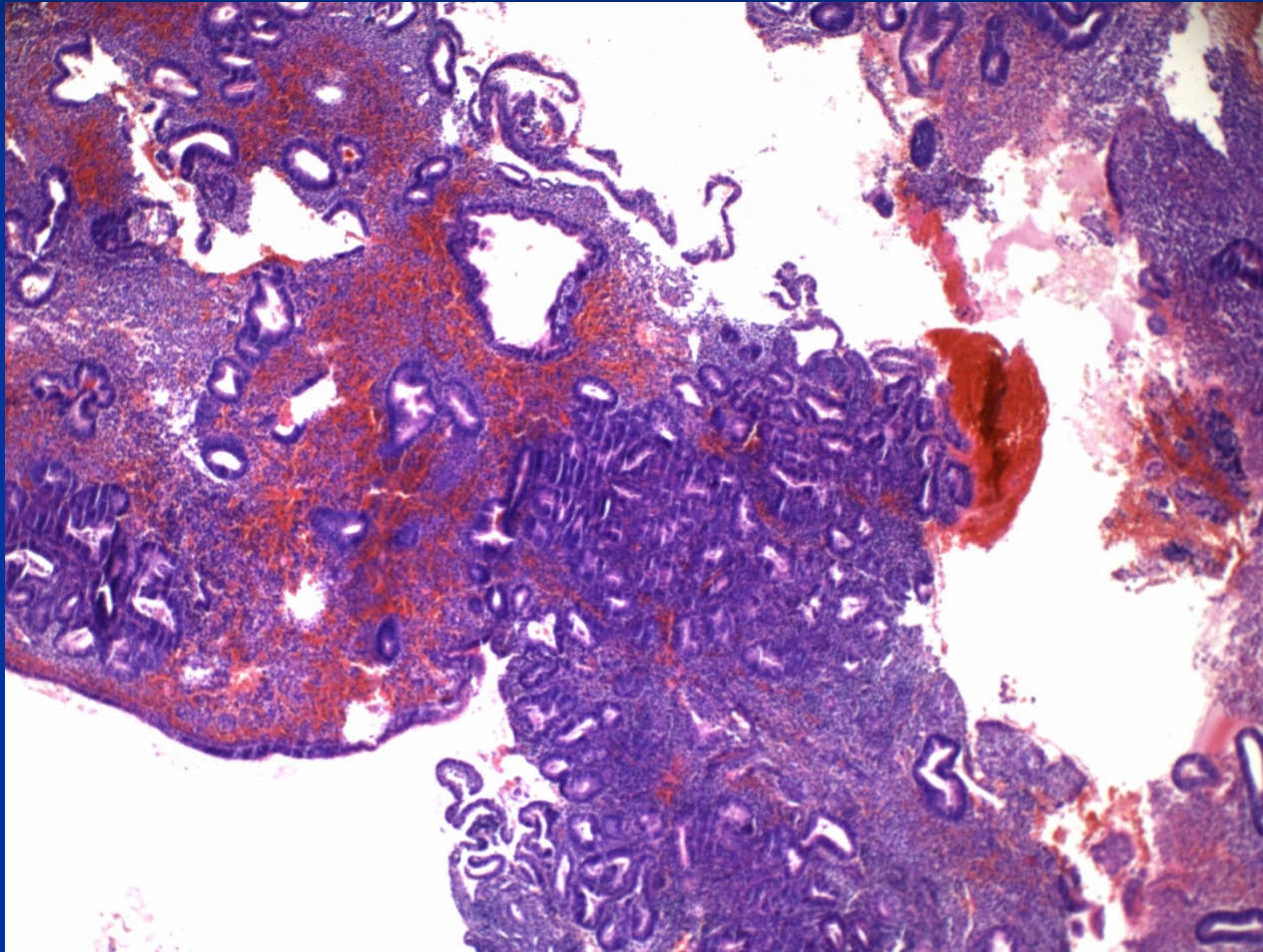
- Non-physiological non-invasive proliferation of endometrium, benign lesion (reactive) → premalignant condition (monoclonal)
- **Hormone dysbalance** - persistent estrog. stimulation without secretory transformation, incl. relative (progesterin insuff.). ~ endometr. ca type 1.
- **endogenous**: path. ovarian regulation, polycystic ovaries, hormon. active processes (tu), obesity with hyperestrinism etc.
- **exogenous**: hormon. therapy (pure estrogens)



Non-atypical simple hyperplasia



Complex hyperplasia

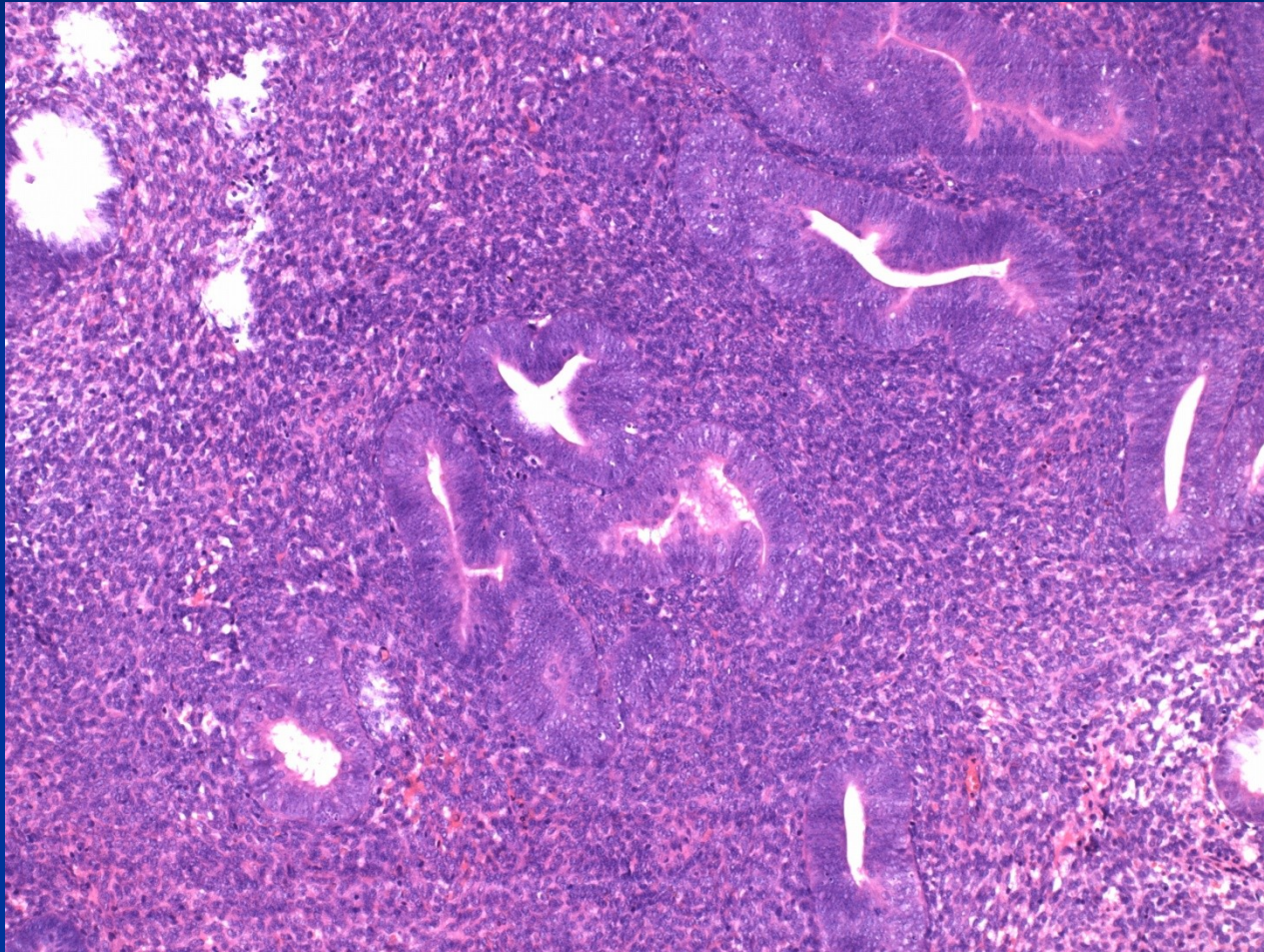


■ **Endometrial intraepithelial neoplasia (EIN)**

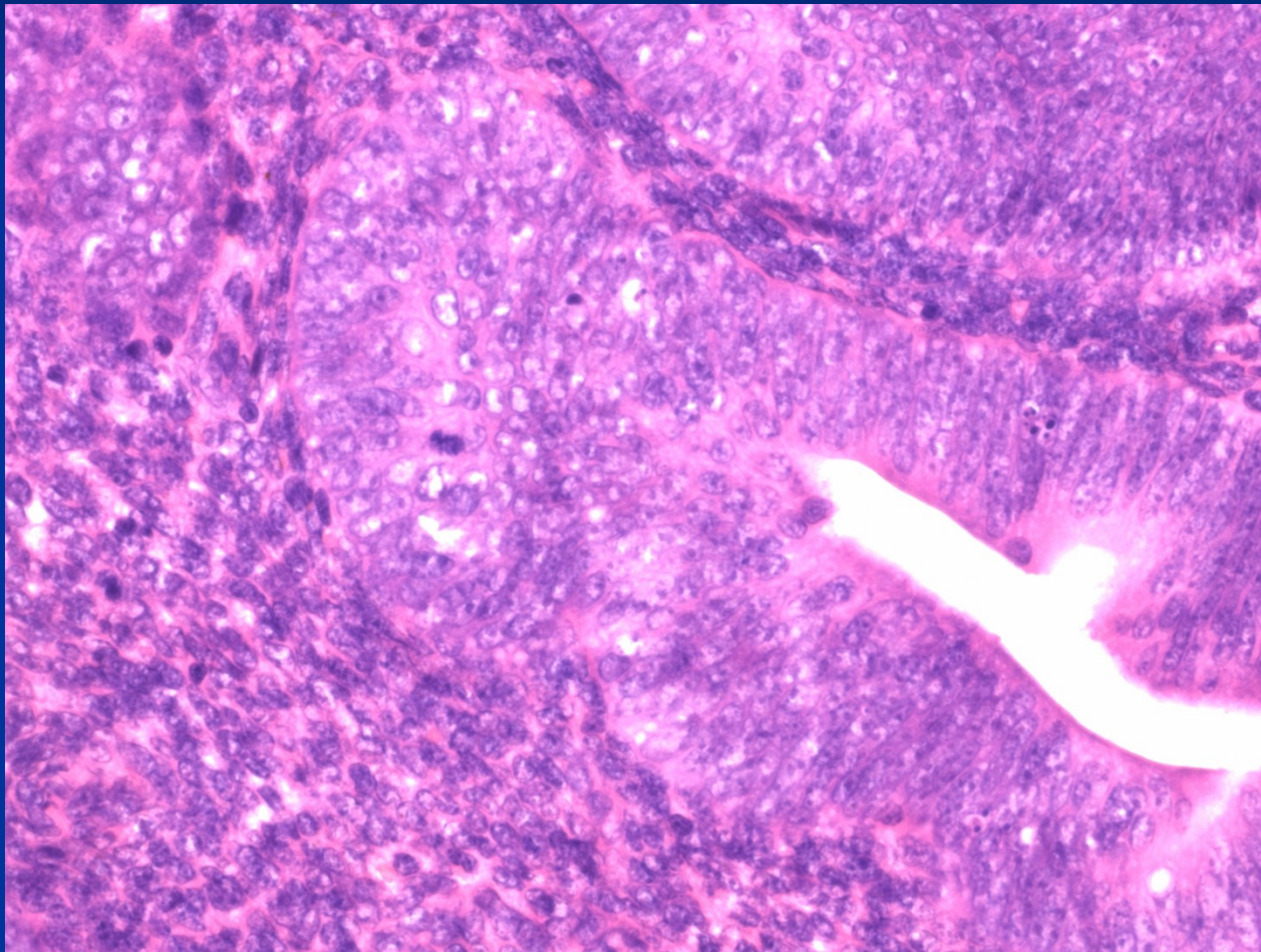
~ to complex atyp. hyperplasia > 1 mm,
different from surrounding tissue

intraglandular or superficial

Atypical hyperplasia/EIN



Atypical hyperplasia/EIN



Uterine corpus tumors – WHO

■ Epithelial tu and related lesions:

Endometrial carcinoma – endometrioid (type 1, estrogen-dependent; type 2 -non estrogen-dependent) mucinous, serous, clear cell, squamous cell, metaplastic (carcinosarcoma = malignant mixed müllerian tumor), others

Endometrial hyperplasia (+ endometrial intraepithelial neoplasia)

Endometrial polyps

Tamoxifen related lesions



Uterine corpus tumors – WHO

■ Mesenchymal tumors:

endometrial stromal lesions: endom. stromal nodule (benign), low grade endom. stromal sarcoma, undifferentiated endom. stromal sarcoma

smooth muscle tumors: leiomyoma (+ variants), tu of uncertain malignant potential, leiomyosarcoma (+ variants)

tumors from perivascular epitheloid cells (PECom)

other mesenchymal tumors

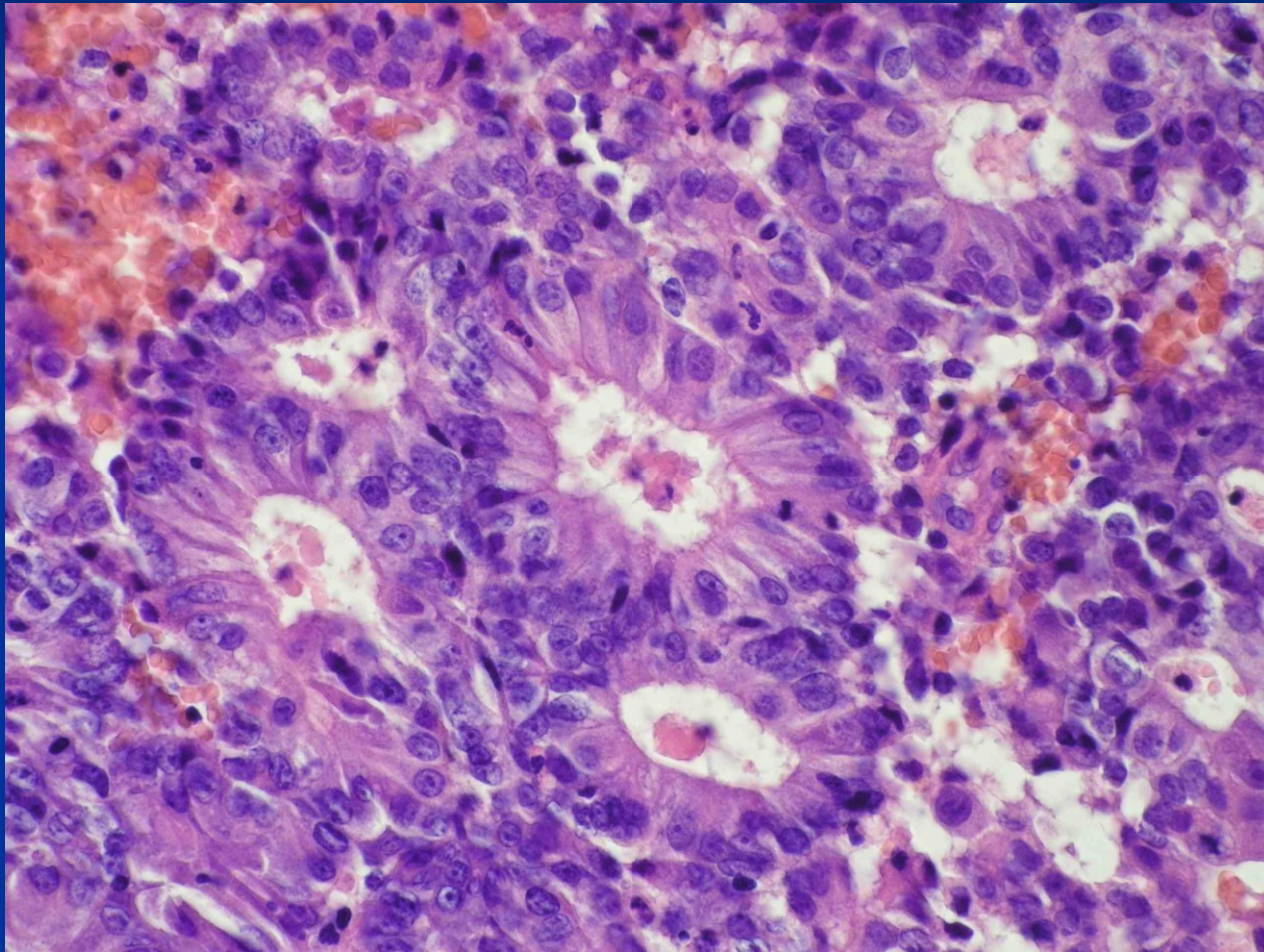


Uterine corpus tumors – WHO

- **Mixed epithelial and mesenchymal tumors:**
adenomyoma, adenofibroma, adenosarcoma etc.
- **Gestational trophoblastic disease**
- **Other tumors:** adenomatoid tumor (mesothelial), ...
- **Secondary tumors**



Endometrioid carcinoma



Endometrioid carcinoma

- **type 1** – cca 80%, estrogen-dependent, commonly in complex atyp. hyperplasia, endometrioid type, low grade, 55-65 yrs, better prognosis

risk factors – ↑ **estrogenous stimulation** (obesity, diabetes, hypertension, infertility incl. nulliparity, long fertile age, horm. active tu, horm. substitution)



Endometrioid carcinoma

- **type 2** – cca 15-20%, not directly connected with permanent oestrogenous stimulation, in later postmenopause, precursor: flat intraepithelial neoplasia, serous and clear-cell type, high grade, p53 mutation, aggressive, worse prognosis
- **Staging** – according to invasion into the uterine wall, cervix, surrounding structures



Endometrioid carcinoma

- **Signs:** abnormal bleeding – menometroragia in pre- and perimenopause, metrorrhagia in postmenopause;
uncommonly accidental finding
rarely - generalisation
- **Gross:** exophytic, ulcerated, whitish

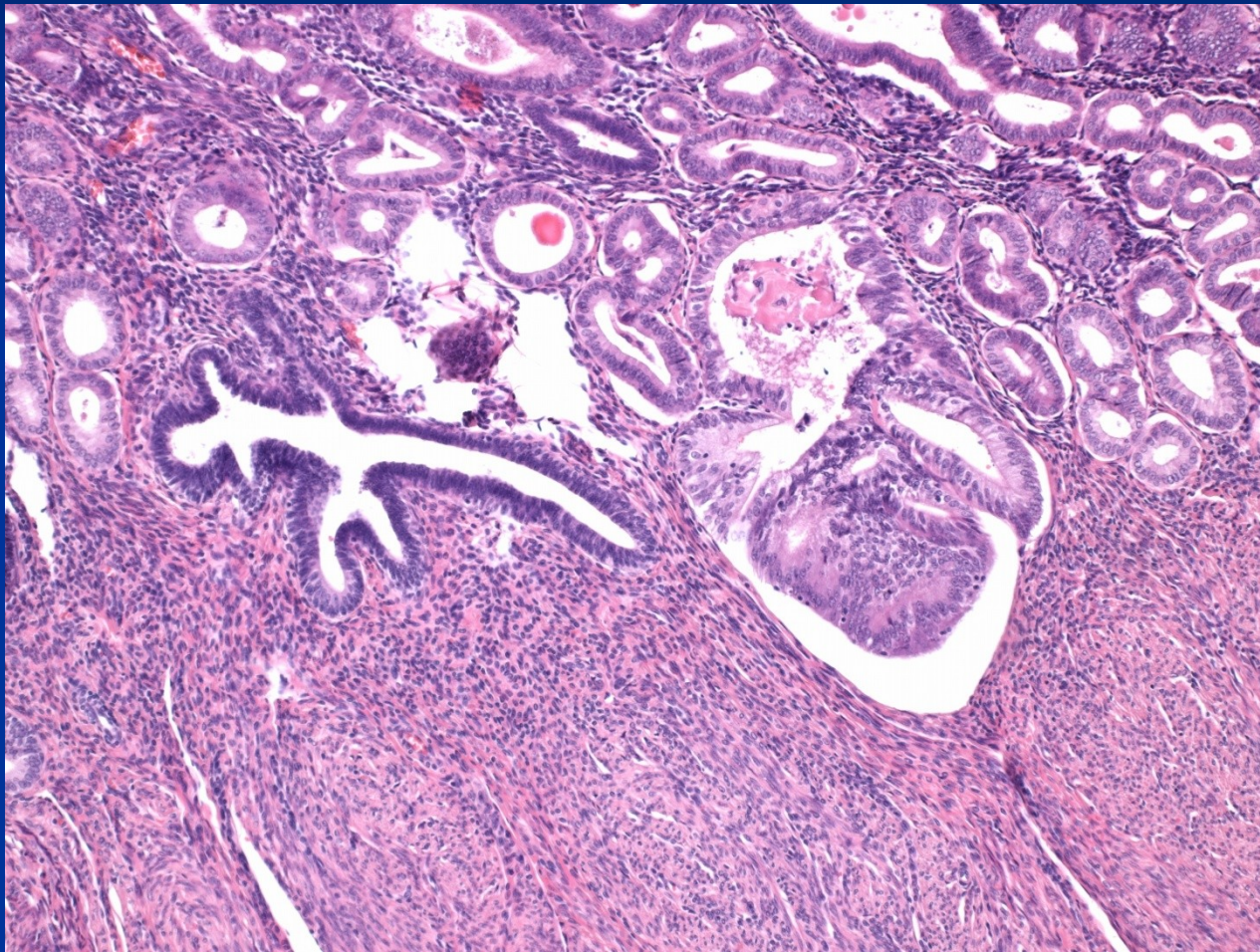


Endometrioid carcinoma

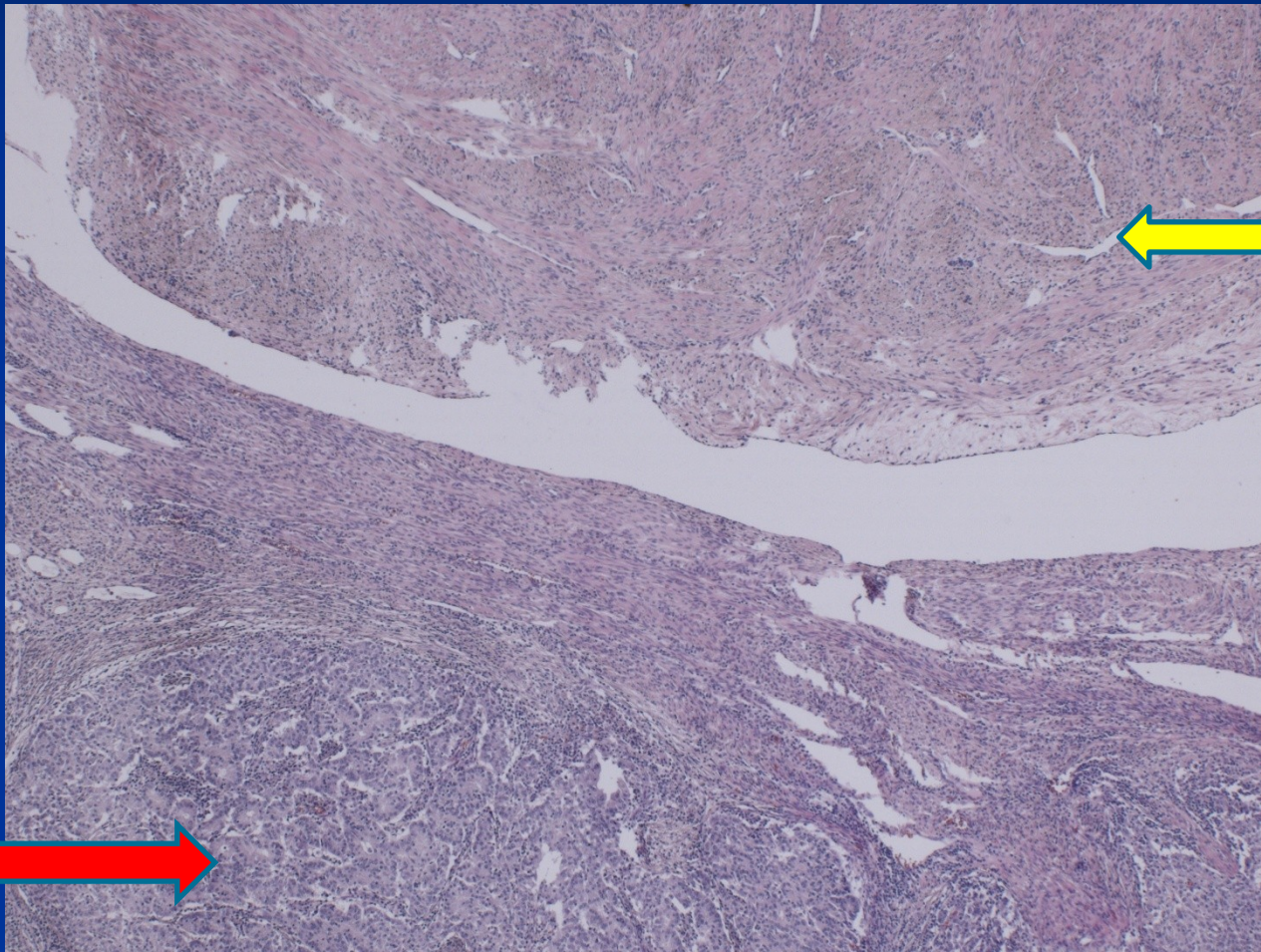
- Micro: endometrioid adenocarcinoma
- serous adenocarcinoma –papillary
- clear-cell

squamous ca,

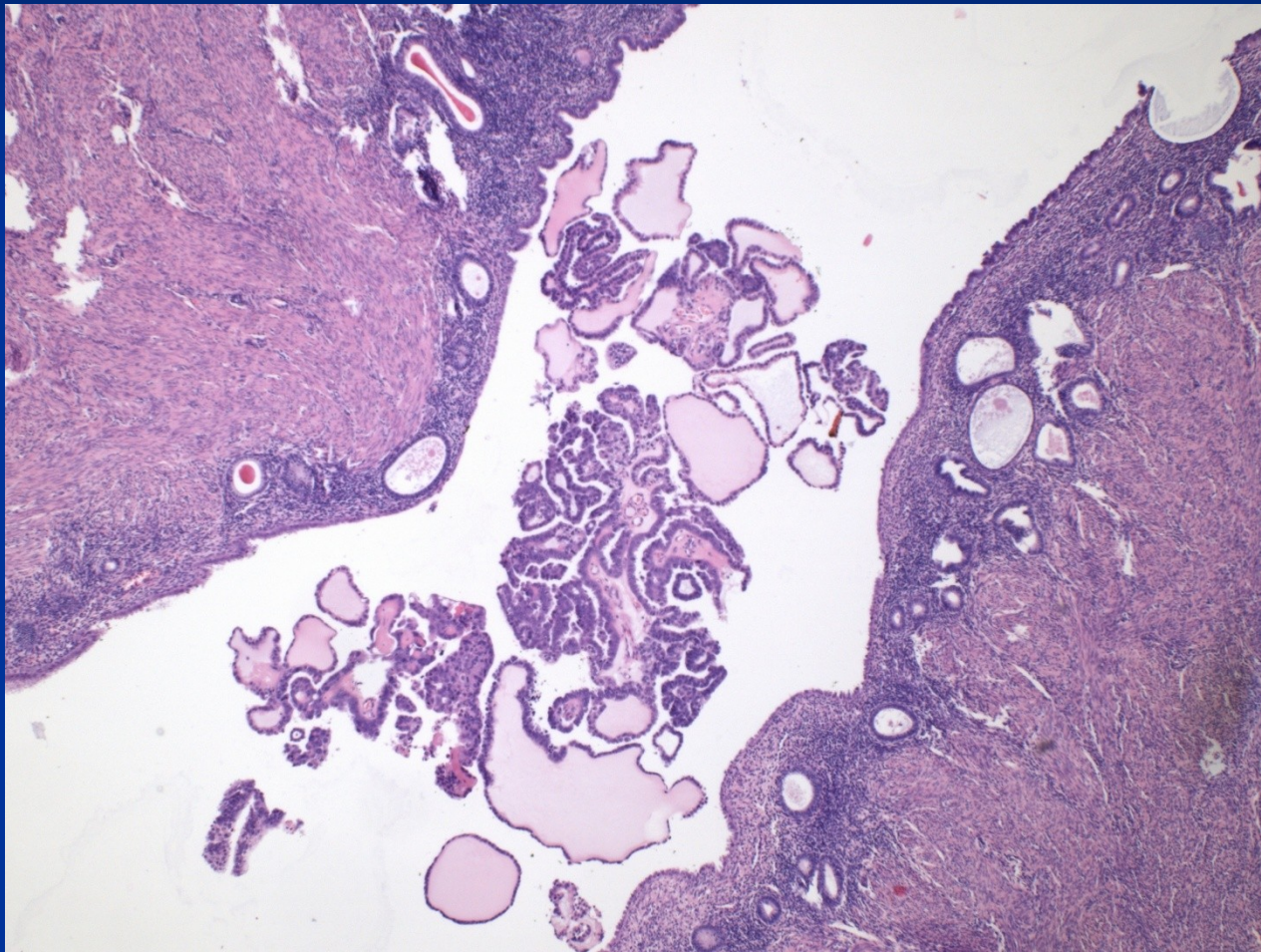
Endometrioid ca in adenomyosis



Endometrioid ca + leiomyoma

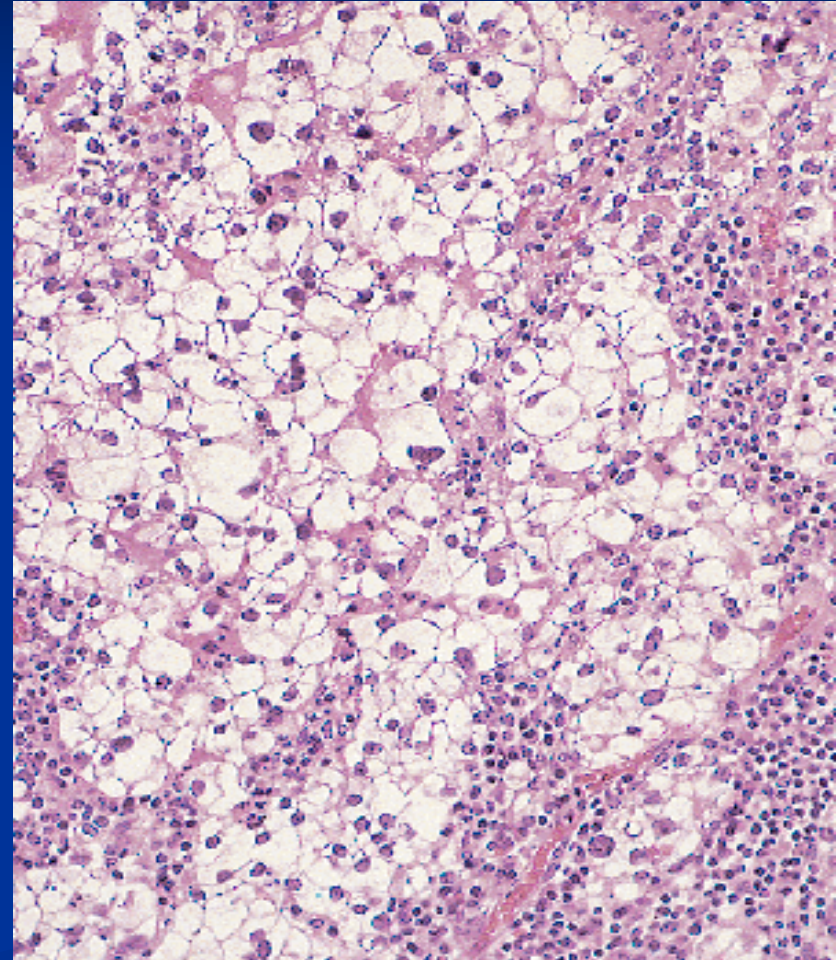


Serous adenocarcinoma

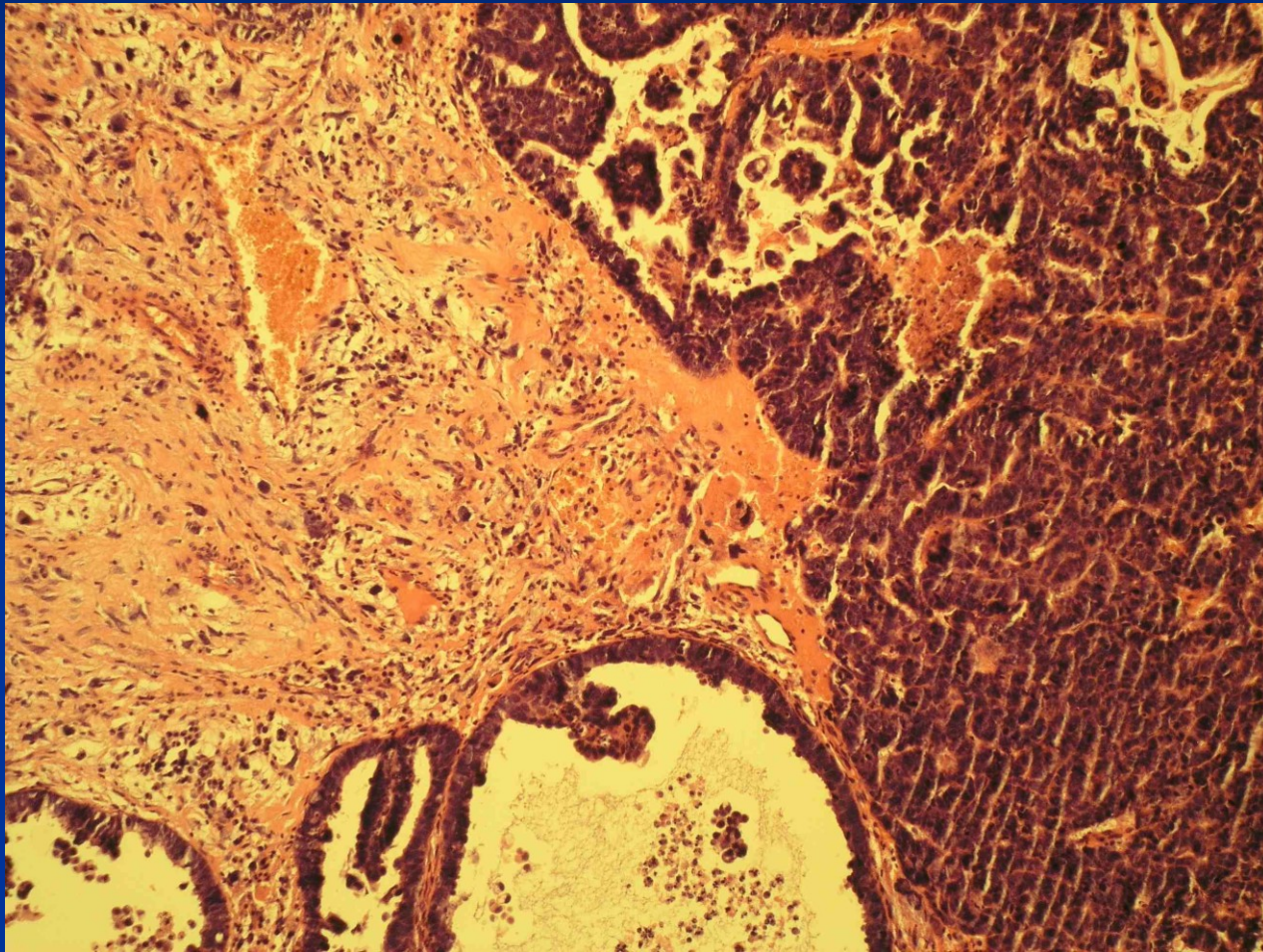


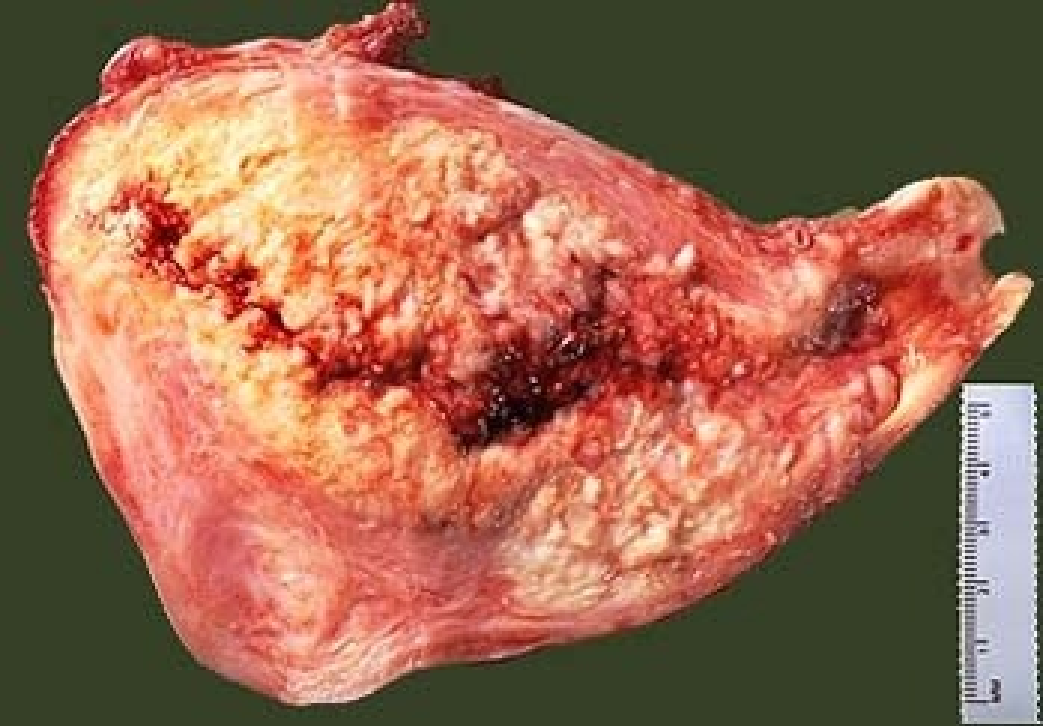
Clear cell adenocarcinoma

.Diff. dg. x renal cell clear cell
ca,
• vaginal clear cell ca,
atypical cell,



Metaplastic carcinoma





Mesenchymal tumors

endometrial stromal lesions: cells similar to stroma in prolif. endometrium

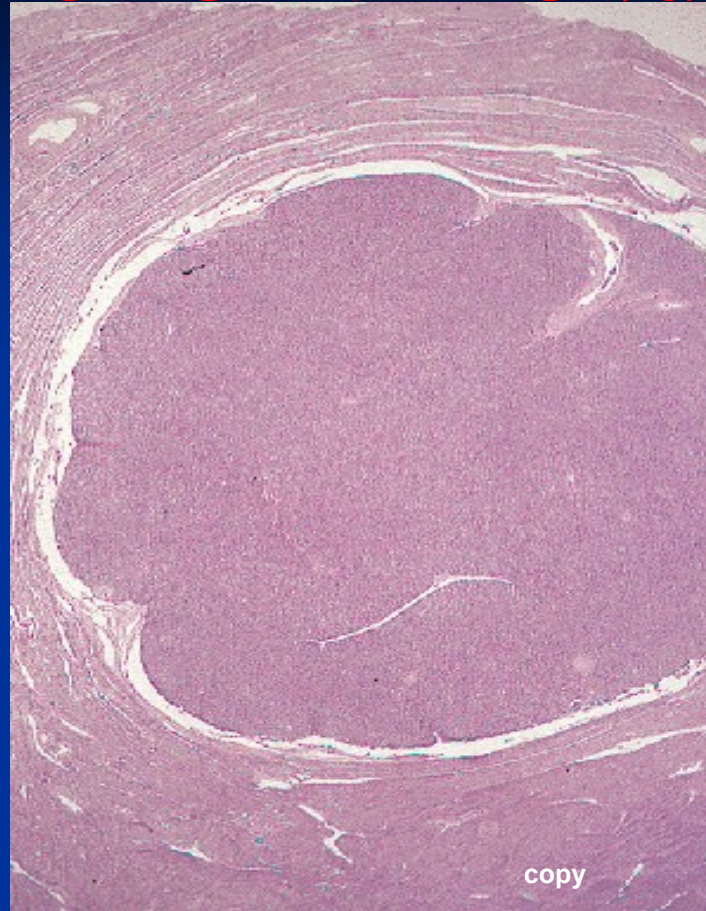
endom. stromal nodule: demarcated, benign

low grade endom. stromal sarcoma (LG ESS): well differ., invasion into surrounding myometrium and vessels, slow growth, usually good prognosis

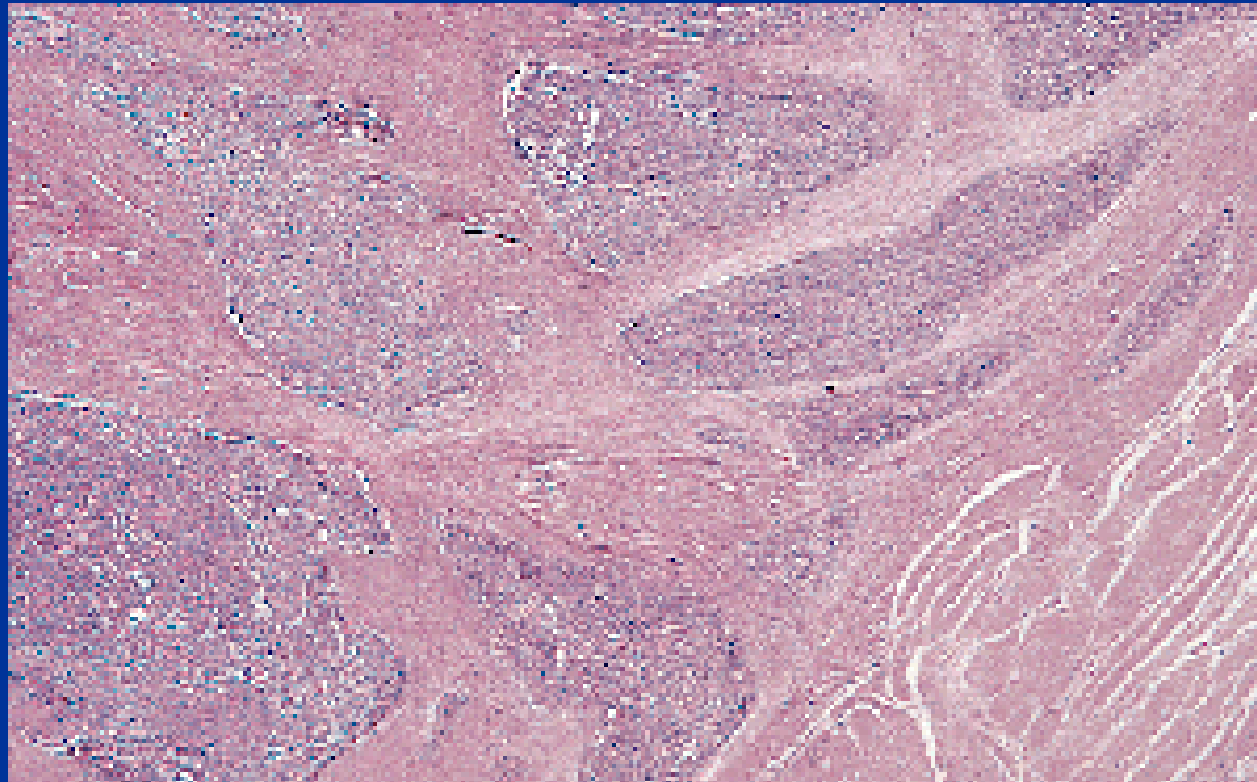
undifferentiated endom. stromal sarcoma (HG ESS): aggressive with dissemination, highly atypical cells, high MI



Stromal nodule



LG ESS



Leiomyoma

- enlarging focus in pelvic region
- pain, irregular bleeding
- possible infertility
- pressure on surrounding organs (ureters, bladder)
- in pregnancy ↑ risk of abortion, possible barrier of normal delivery



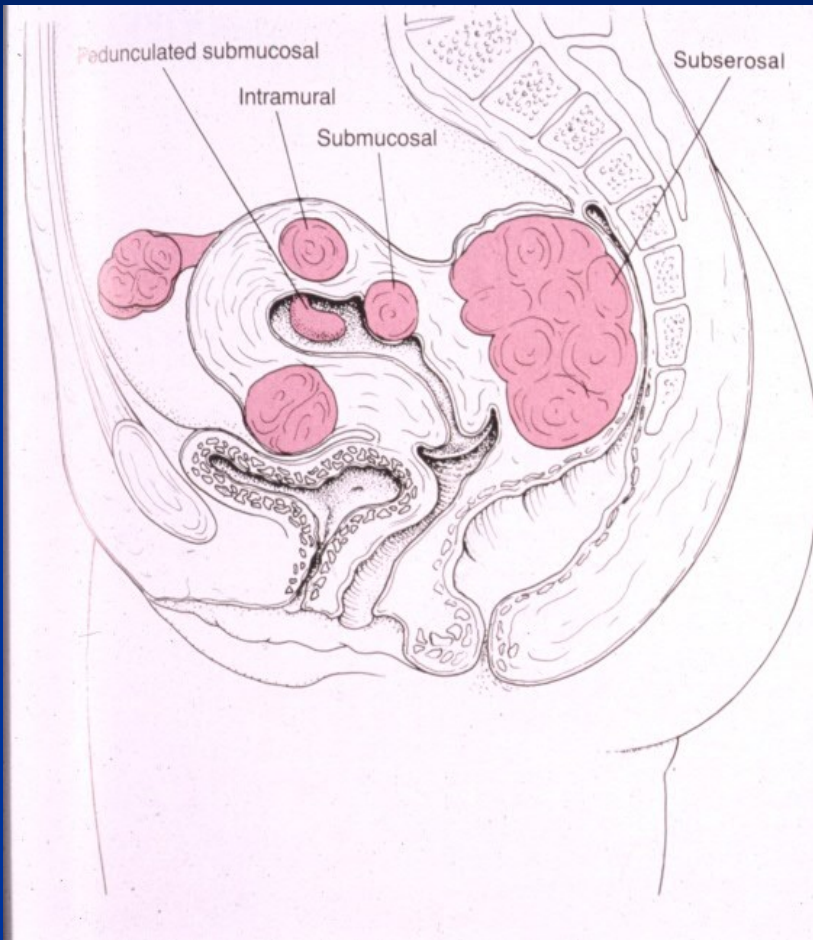
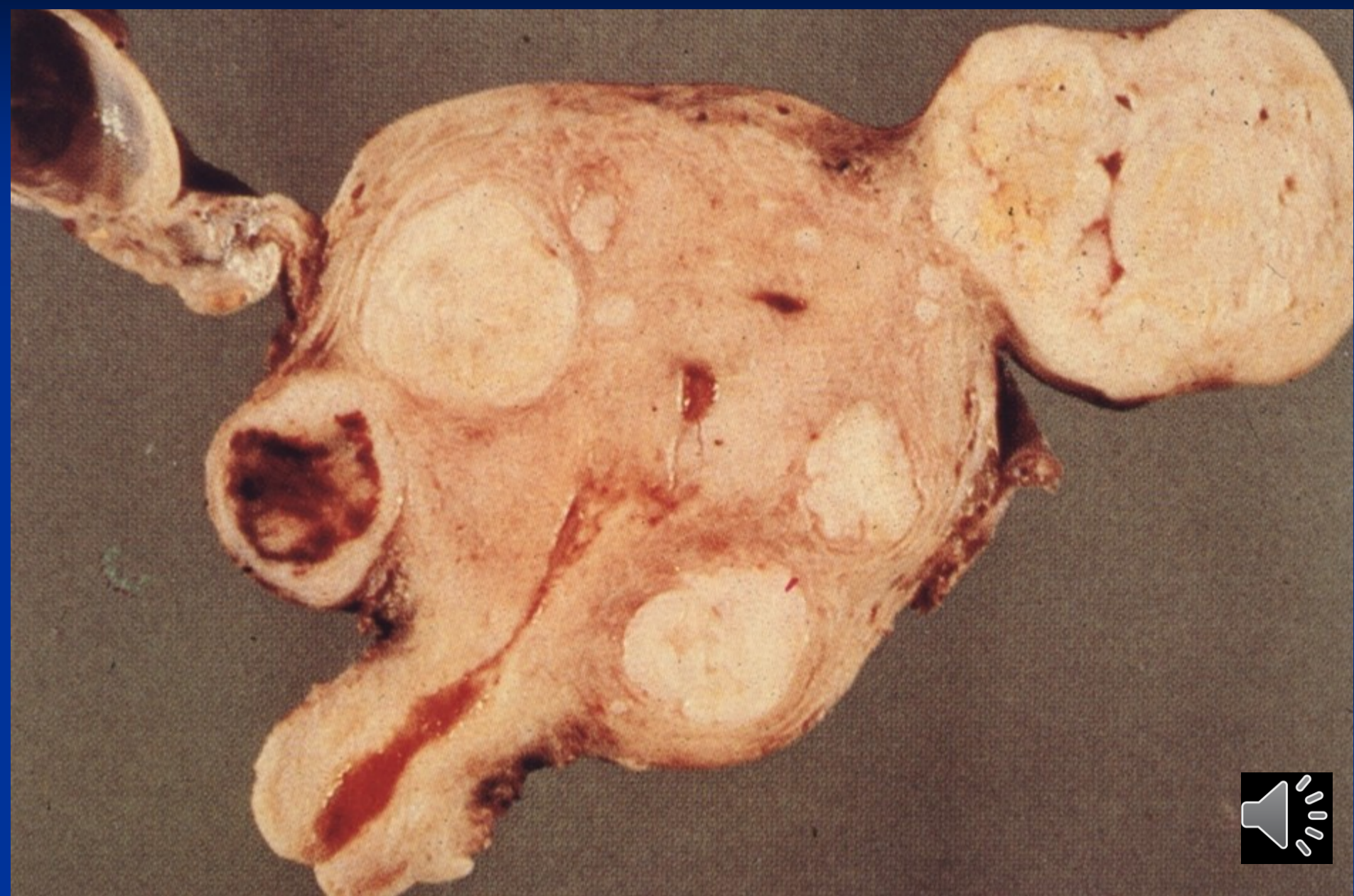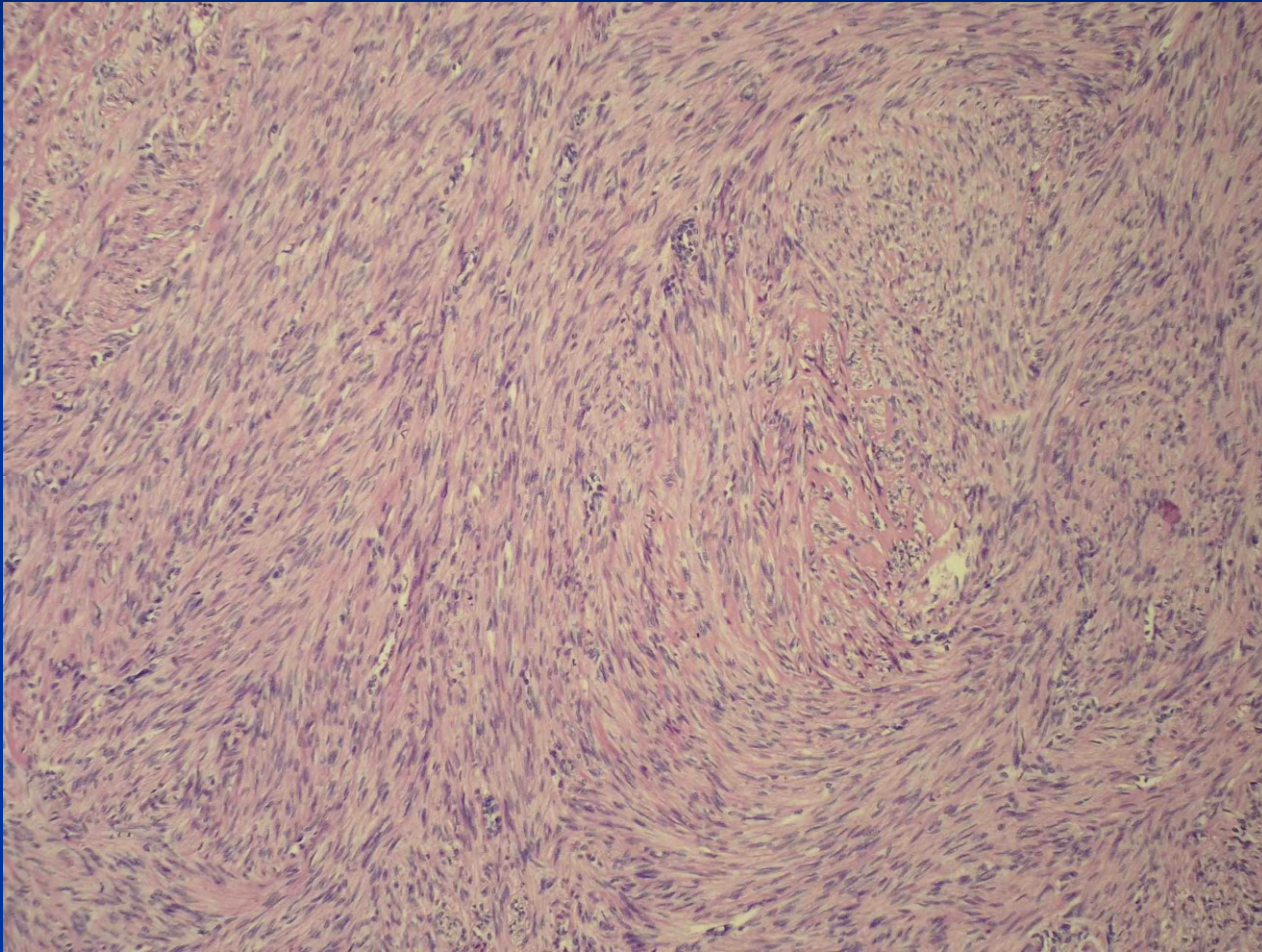


FIGURE 18-36
Leiomyomas of the uterus. The leiomyomas are intramural; submucosal, with a pedunculated one appearing in the form of an endometrial polyp; subserosal, with one compressing the bladder and the other the rectum.

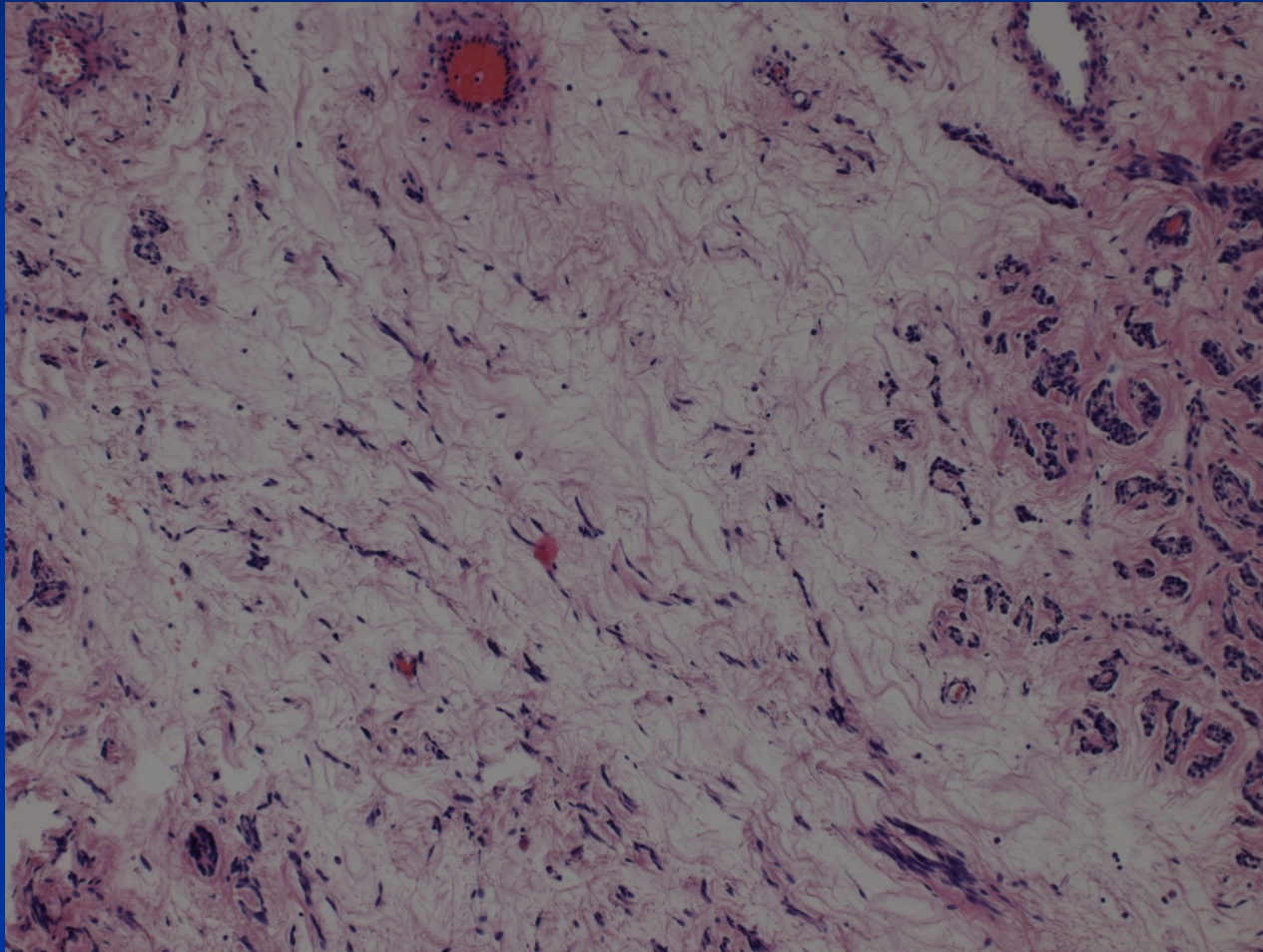
Leiomyomas



Leiomyoma



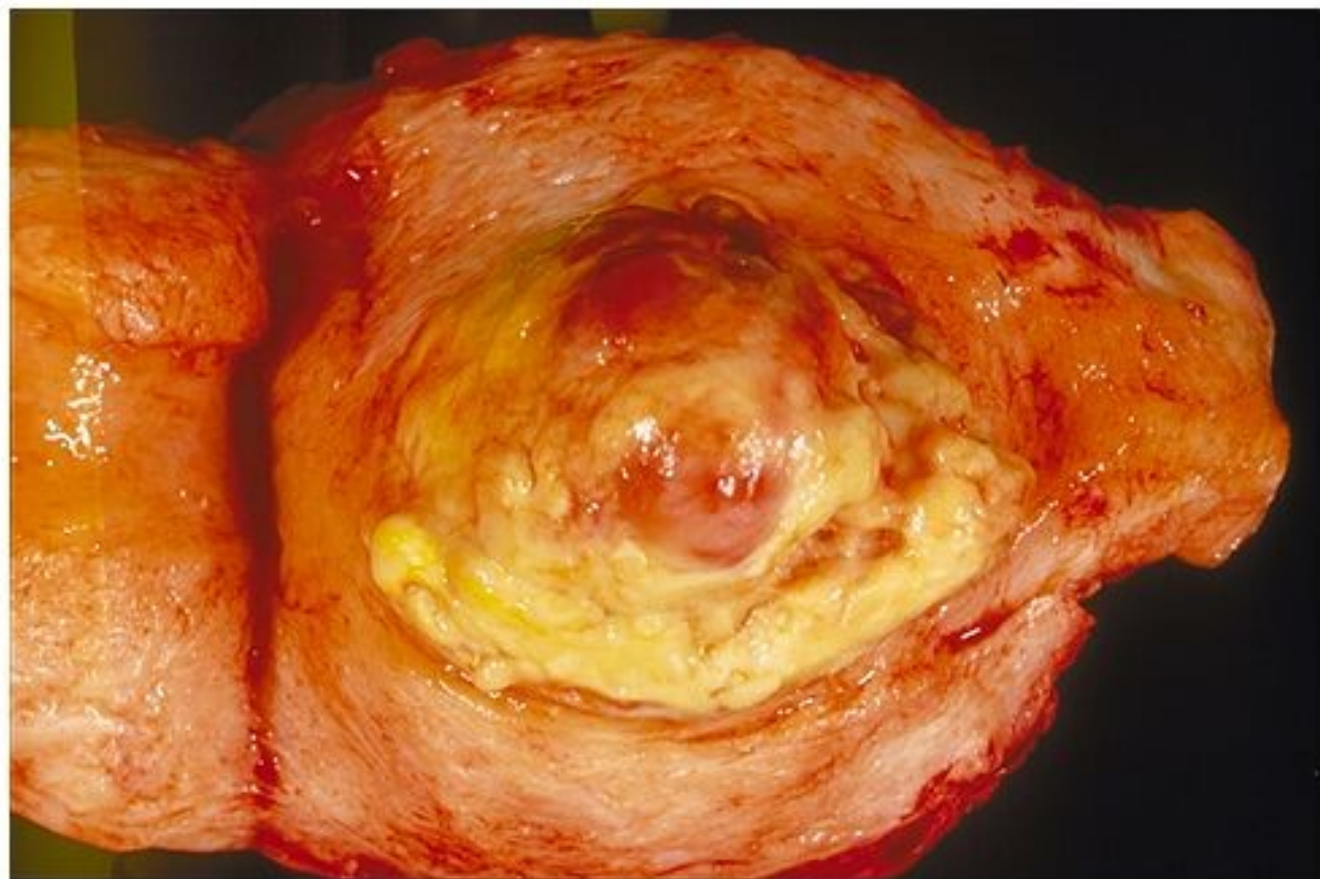
Leiomyoma – regressive changes



Leiomyosarcoma

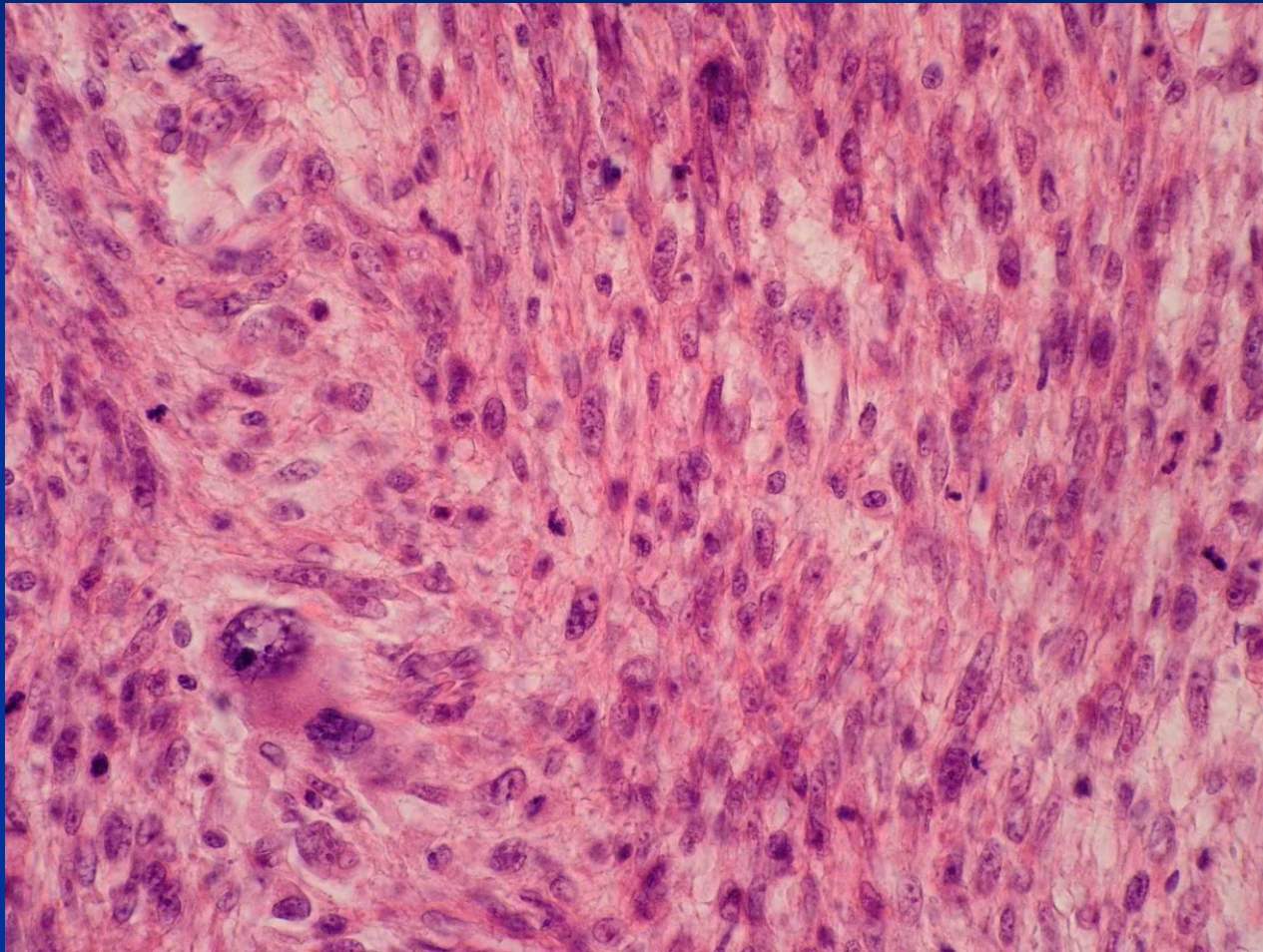
- rare, de novo from myometrium
- mostly in age of 40-60
- recurrence common, haematogenous meta (lungs, bones, brain), abdominal dissemination
- solitary, rose-grey, soft, haemorrhagia, necrosis
- micro – variable differentiation





Copyright © 2002, Elsevier Science (USA). All rights reserved.

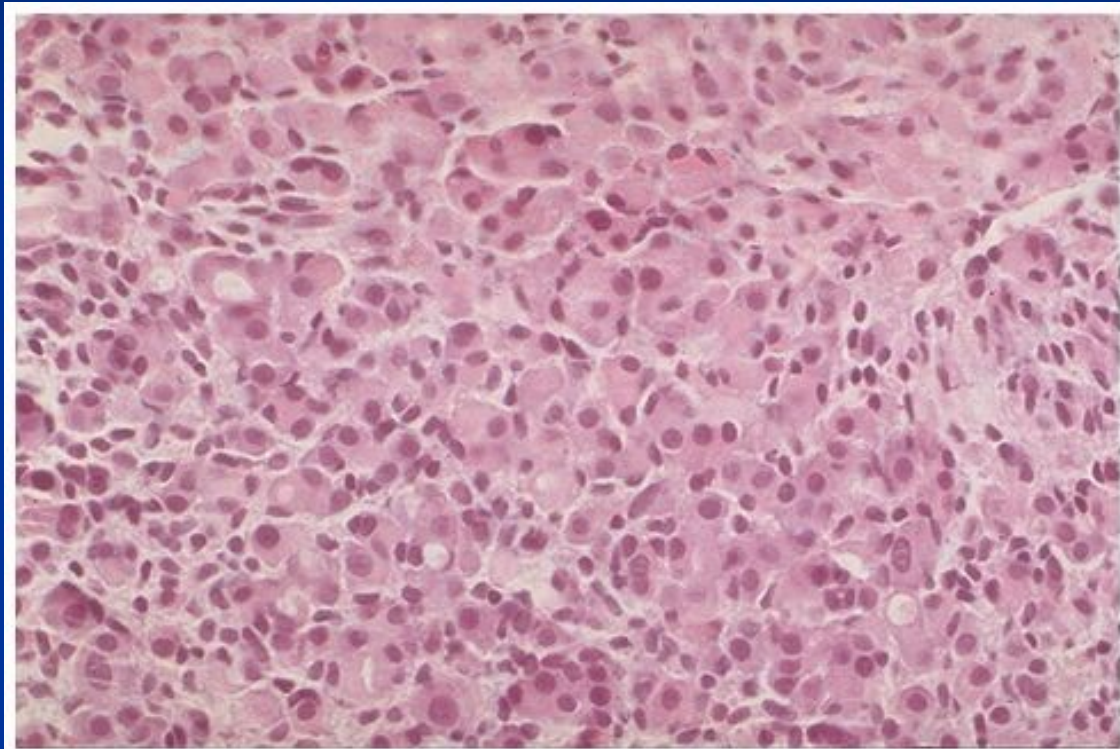
Leiomyosarcoma



Mixed epithelial and mesenchymal tumors

- adenomyoma (atypical polypoid)
- adenofibroma
- adenosarcoma

Breast ca metastasis



Copyright © 2002, Elsevier Science (USA). All rights reserved.

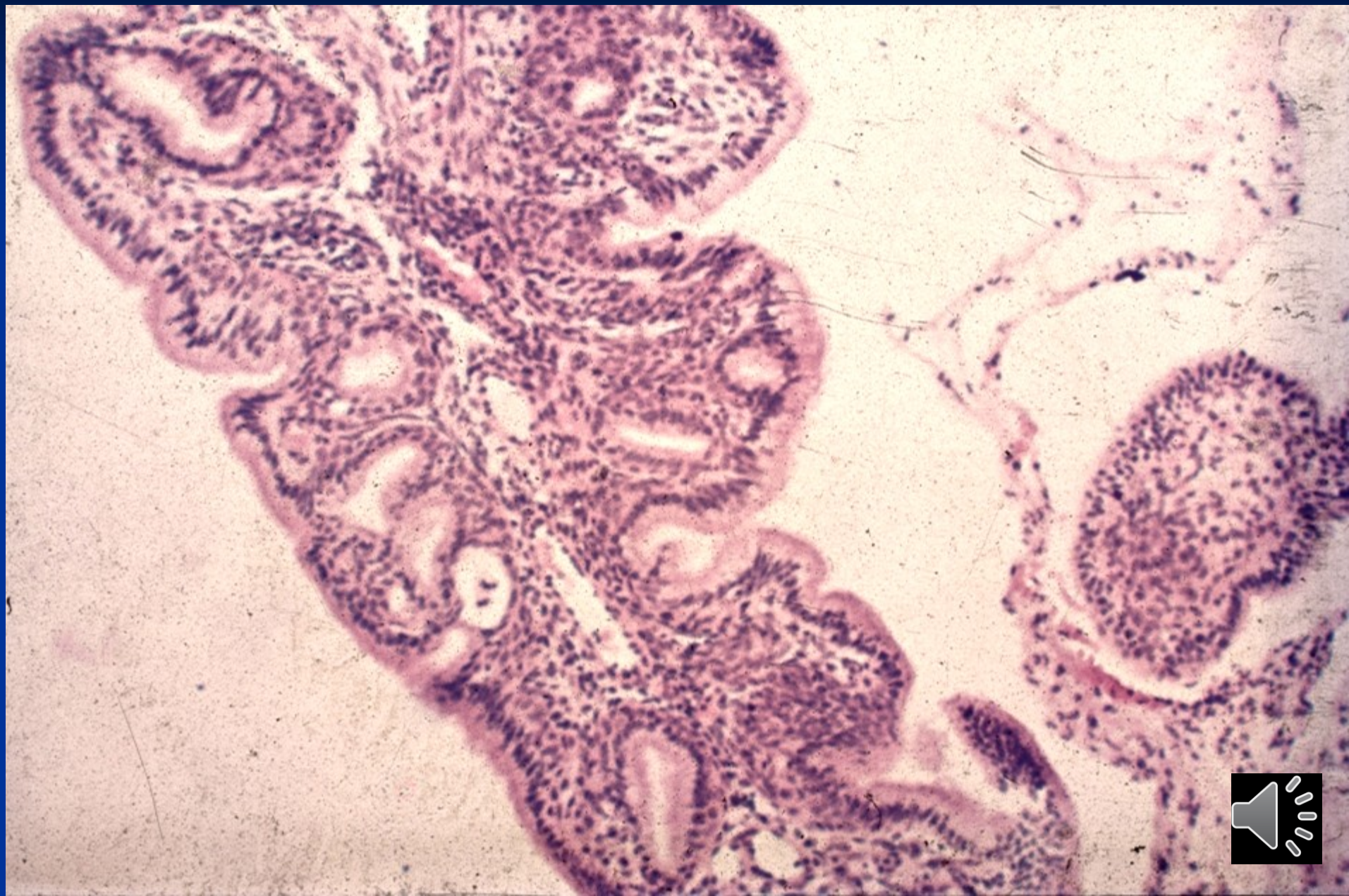


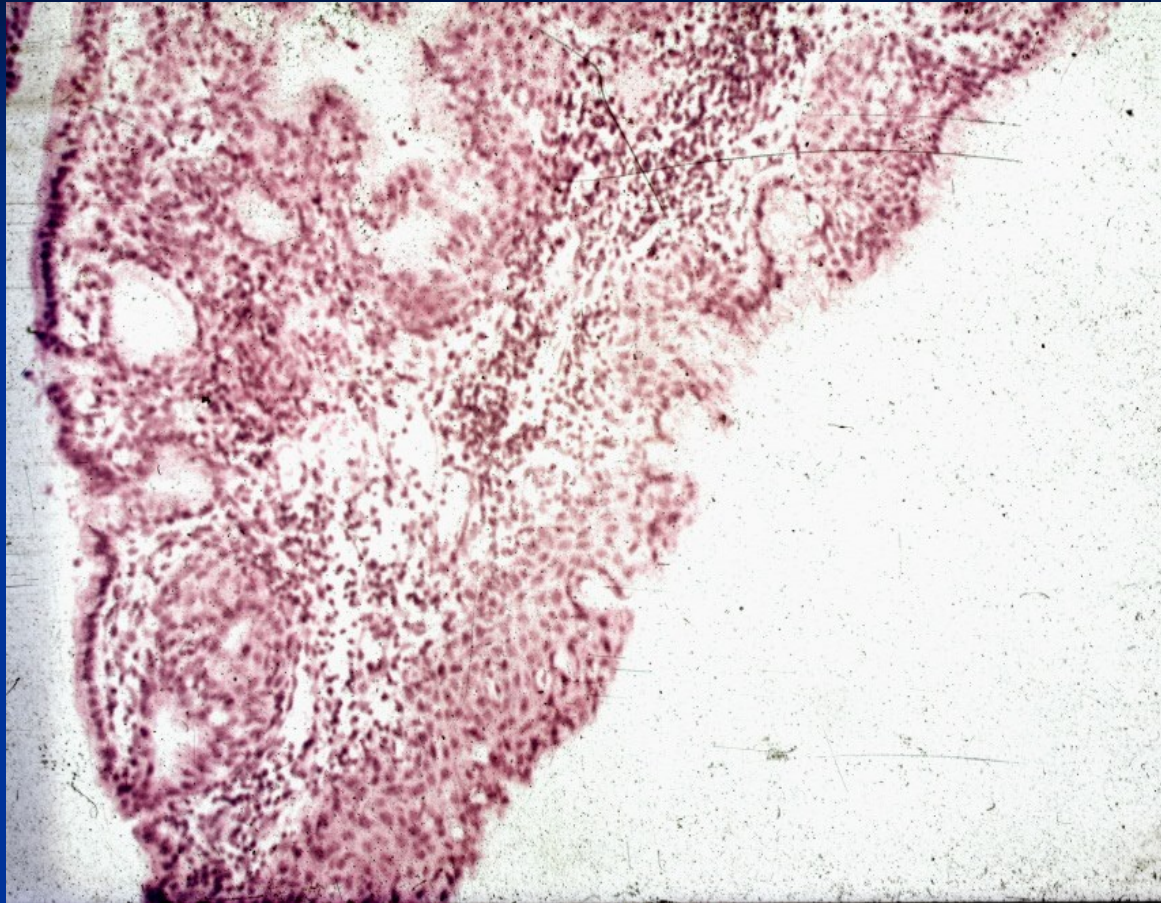
Pathology of the cervix

- cervicitis
- polyps
- physiological and pre-neoplastic epithelial changes – metaplasia, dysplasia (CIN)
- tumors



Endocervical polyp





Endocervical polyp with squamous metaplasia

Cervical intraepithelial neoplasia

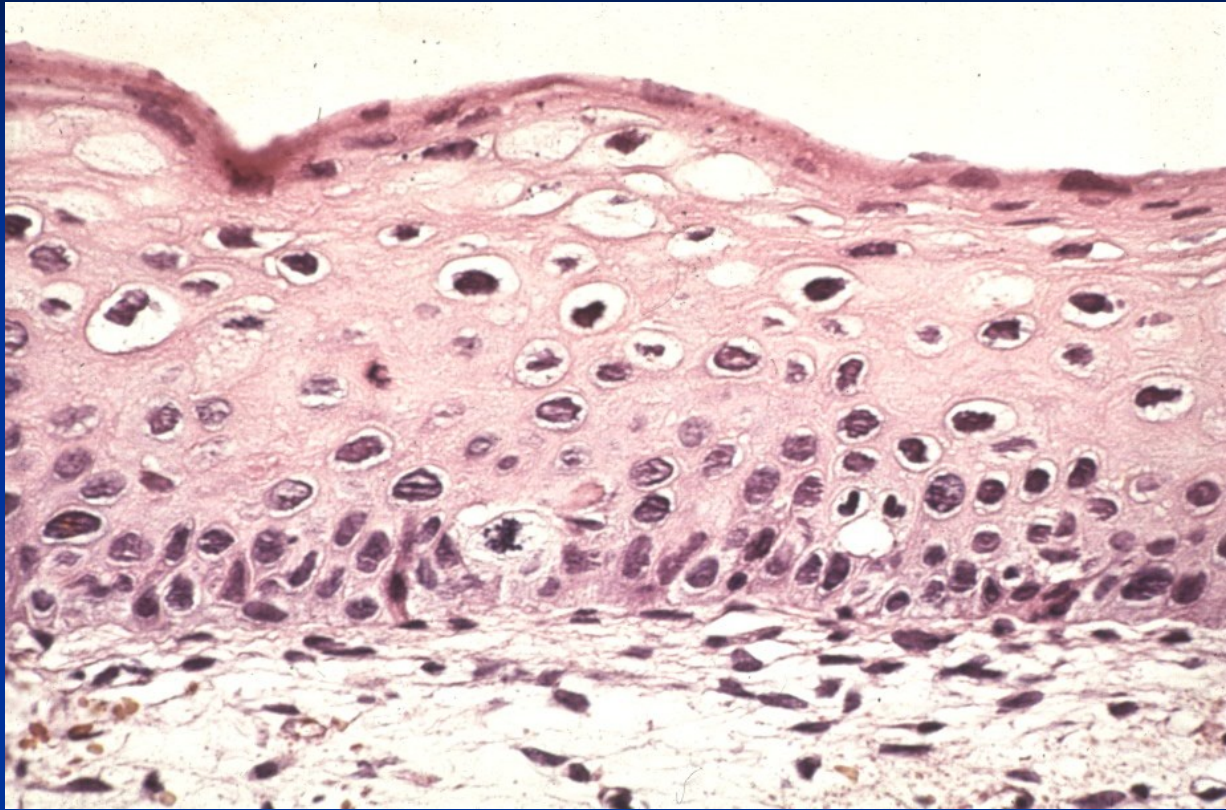
- flat HPV condyloma (without dysplasia)
- mild dysplasia (CIN I)
- moderate dysplasia (CIN II)
- severe dysplasia (CIN IIIa)
- carcinoma in situ (CIS, CIN IIIb)

Cytology:

Low grade squamous intraepithelial lesion (LSIL):
condyloma + CIN I

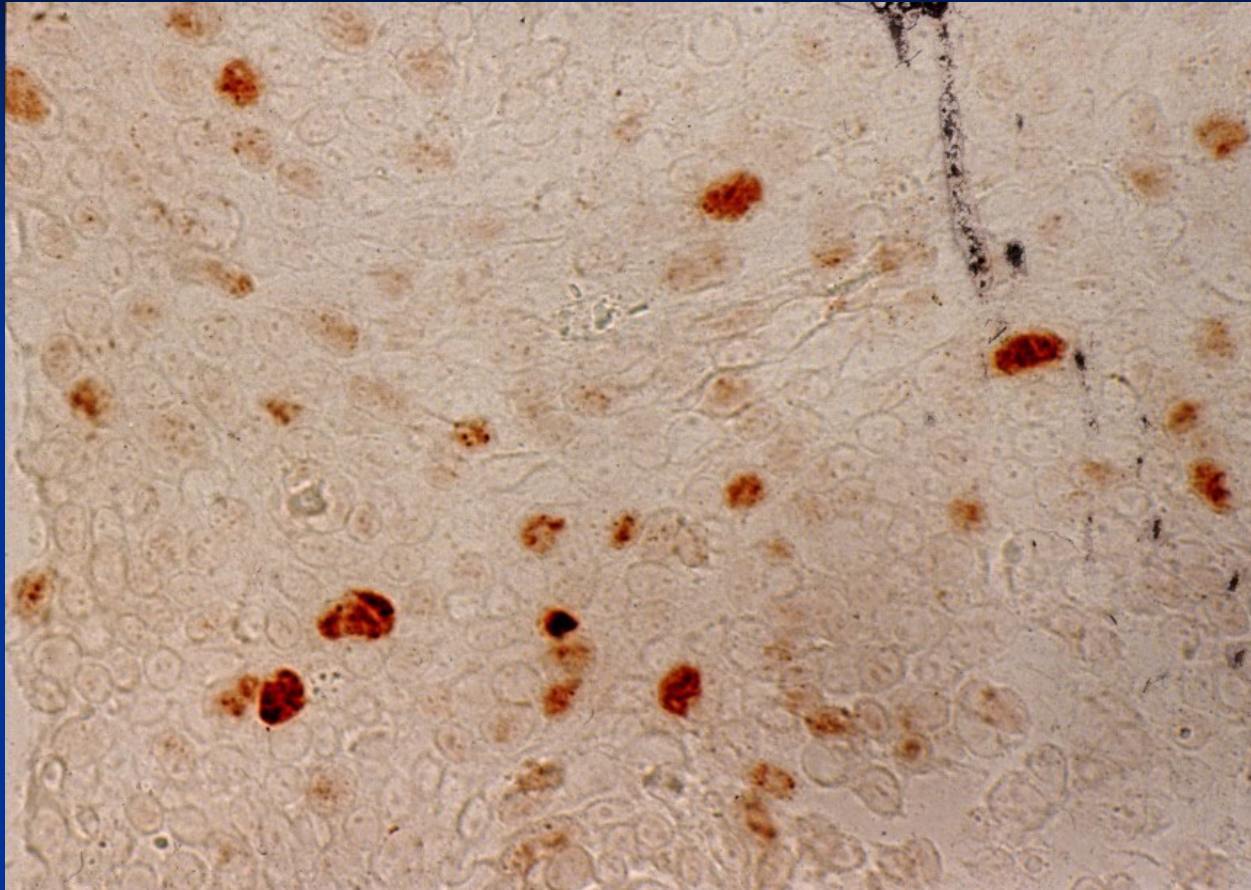
High grade SIL (HSIL): CIN II + CIN III





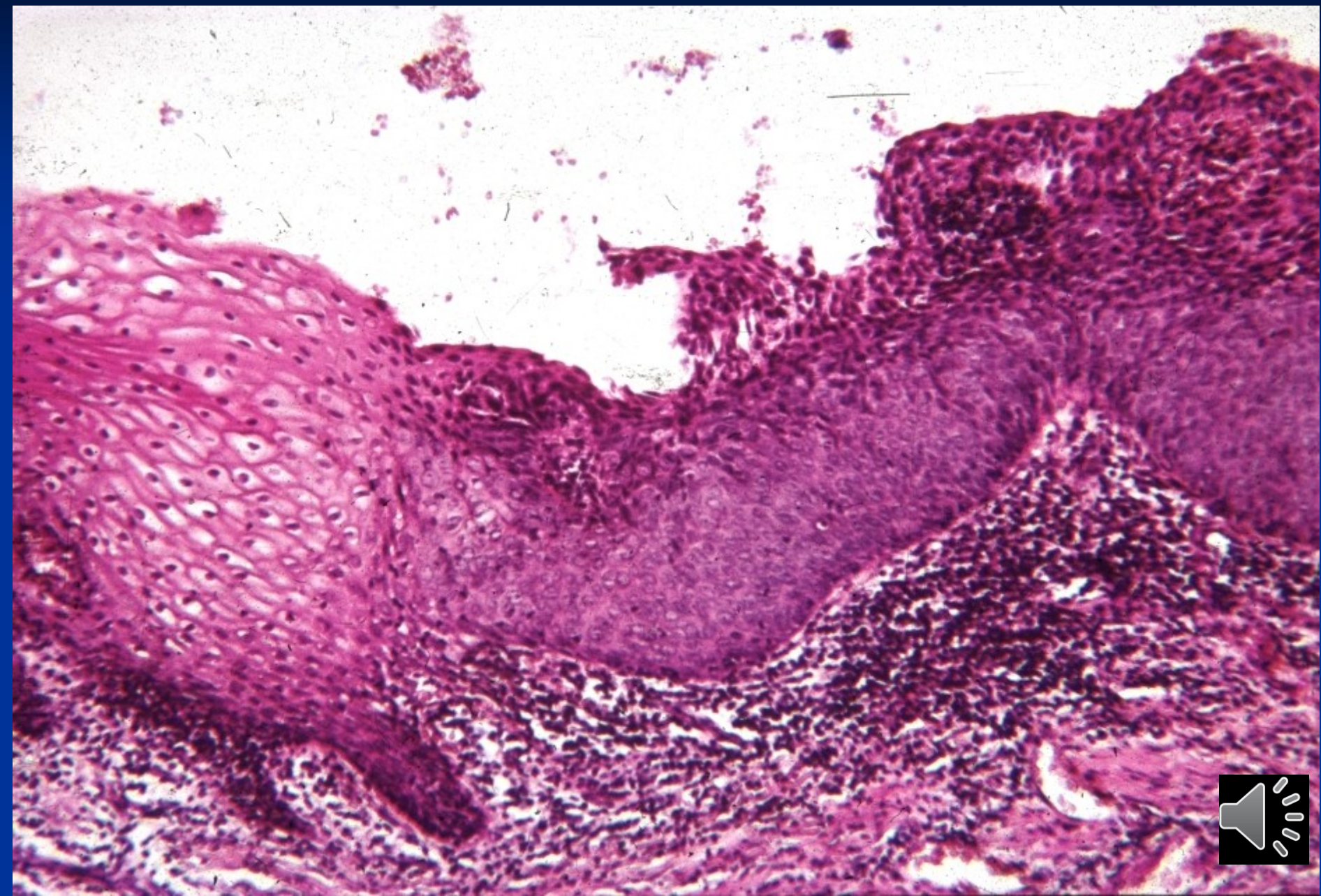
HPV – koilocytosis - LSIL

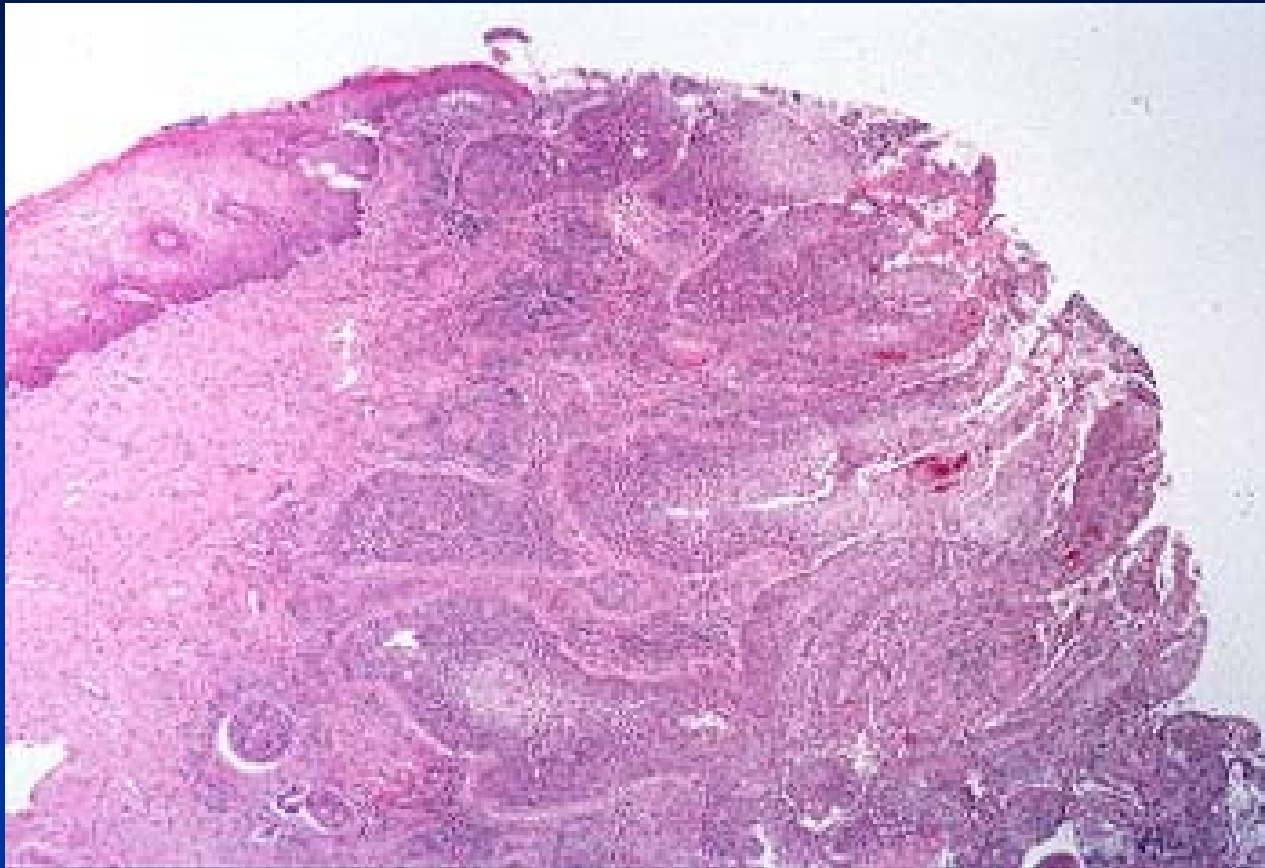




HPV - immunohistochemistry

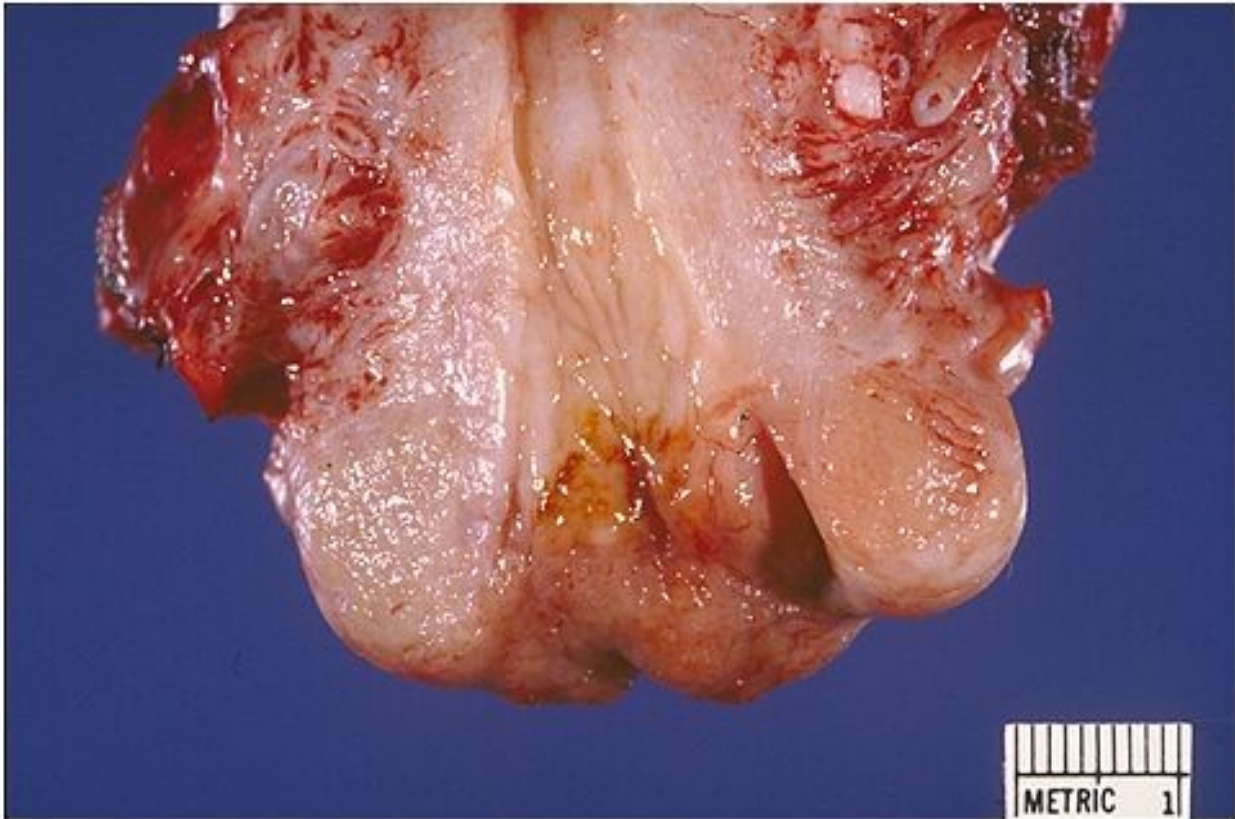
HPV CIN II.





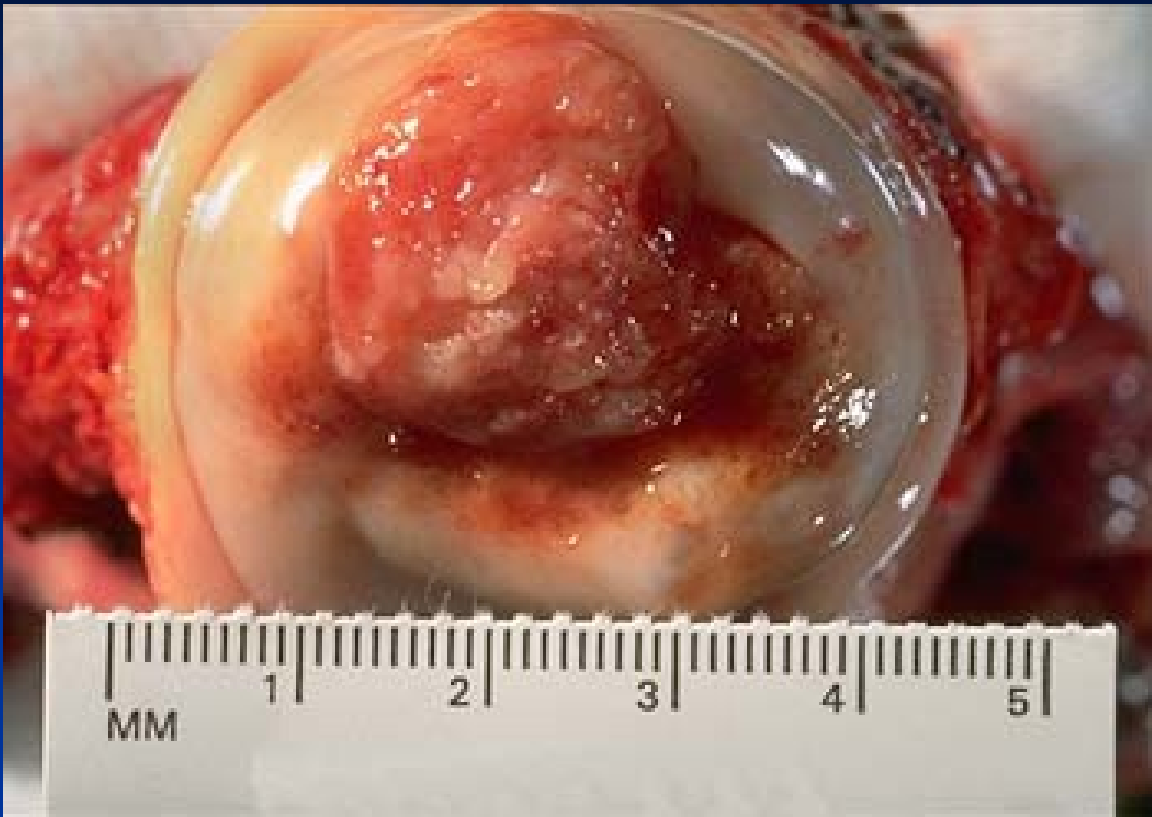Invasive squamous cell carcinoma

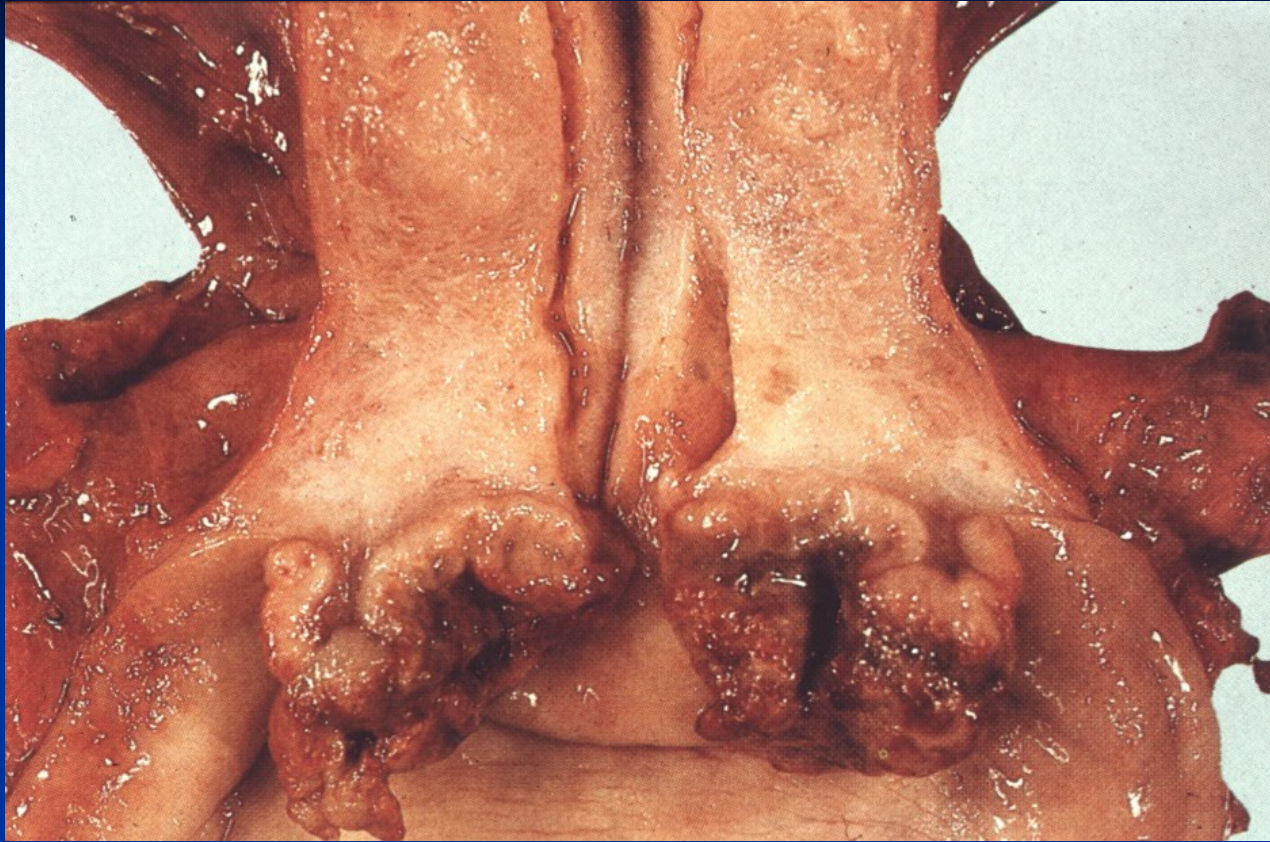



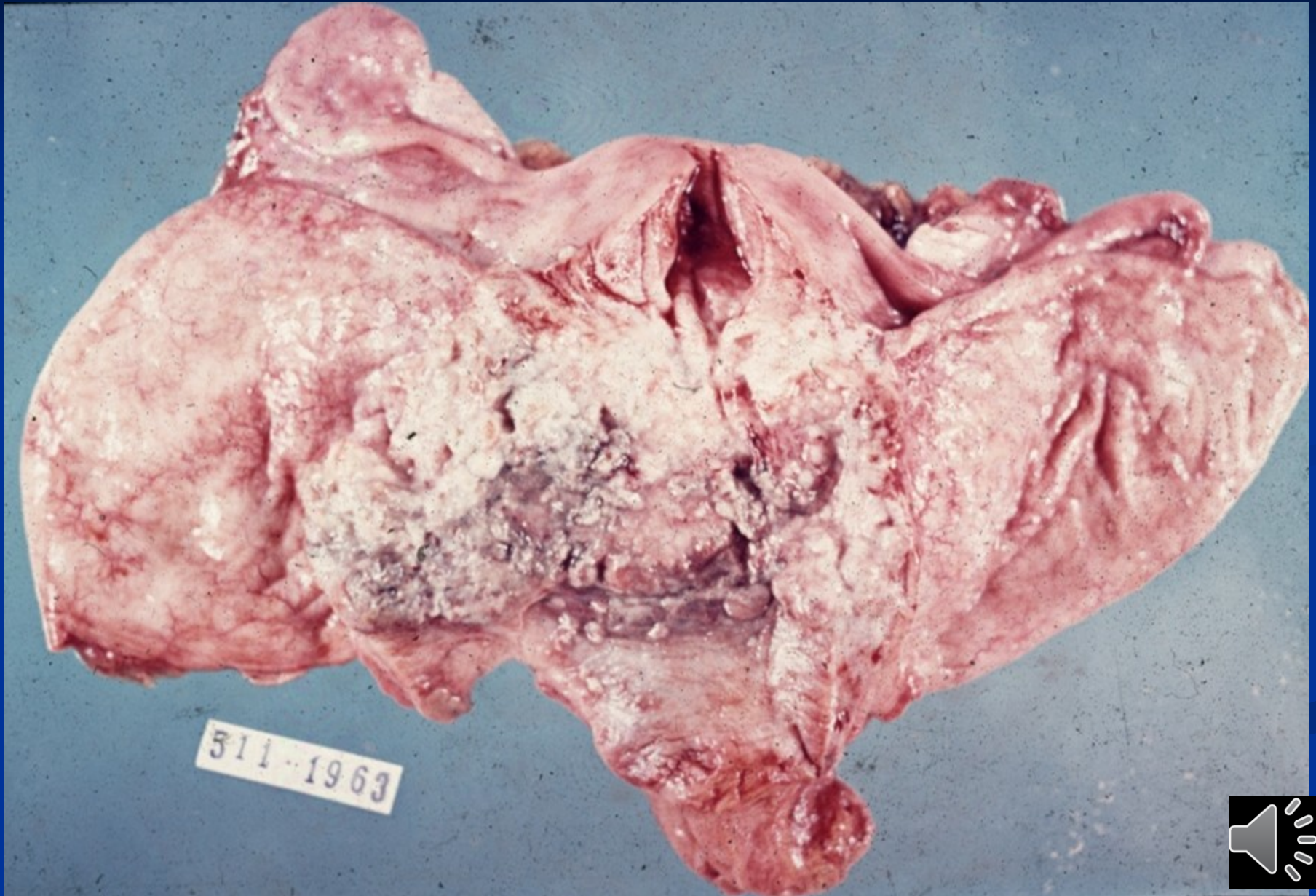
Copyright © 2002, Elsevier Science (USA). All rights reserved.

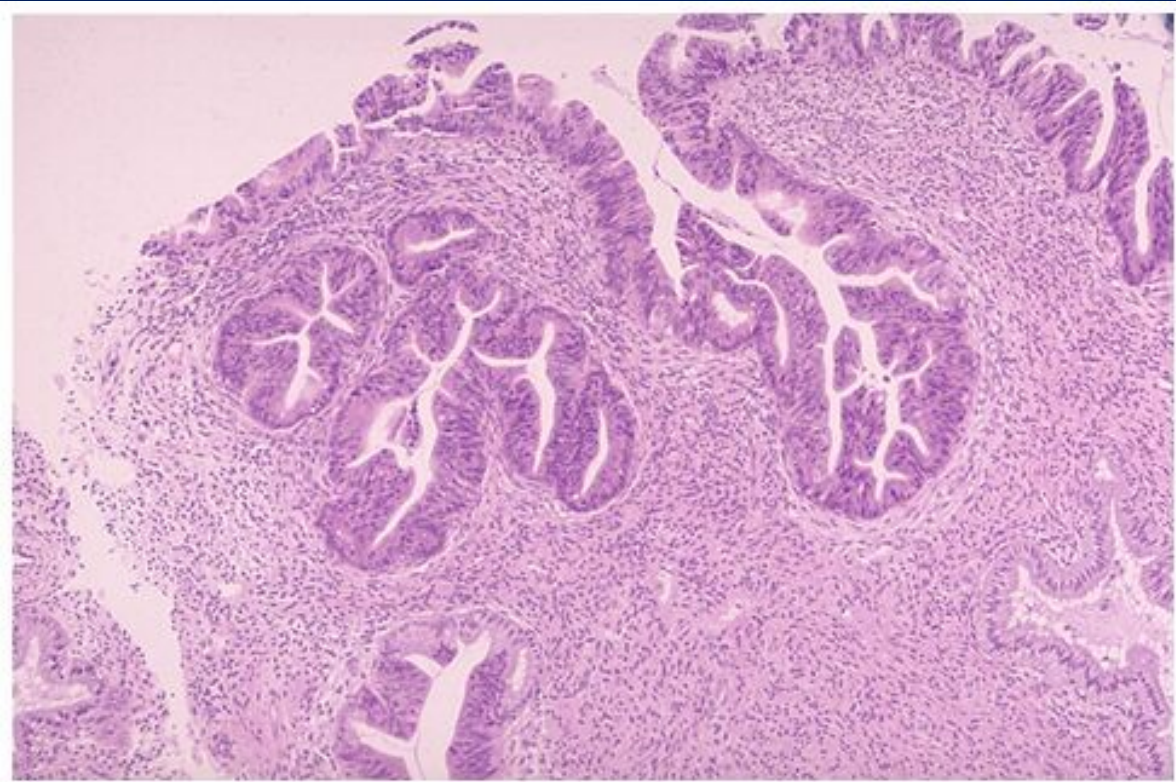






Cervical squamous cell carcinoma

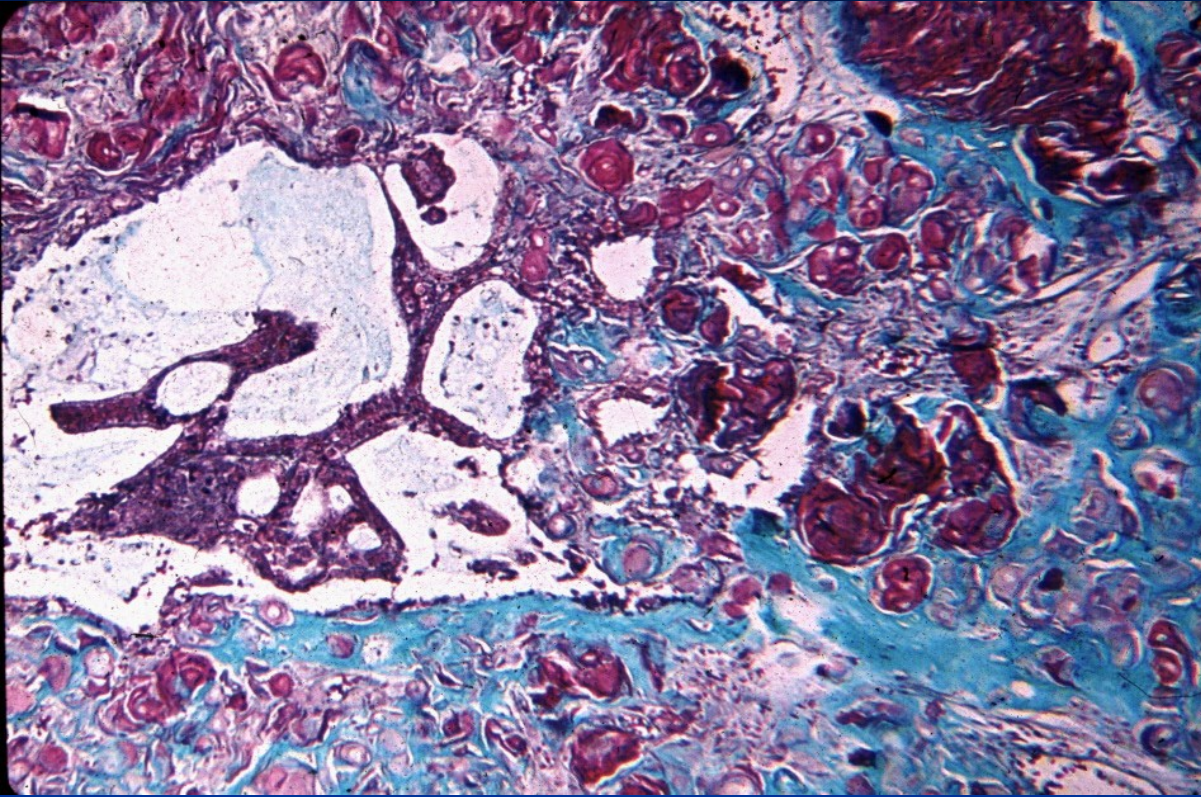




Copyright © 2002, Elsevier Science (USA). All rights reserved.

Cervical glandular intraepithelial neoplasia – CGIN





Adenosquamous carcinoma – alcian blue staining



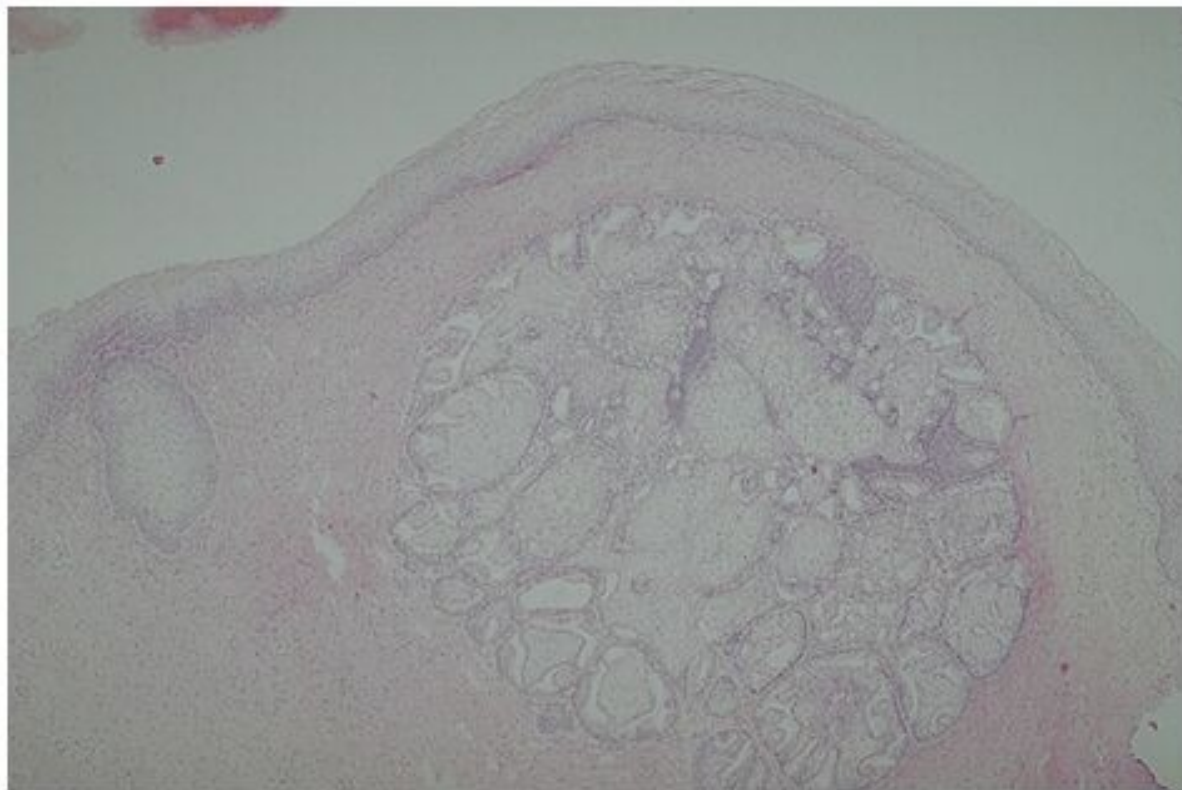
Vaginal pathology

- inflammation
- polyps, cysts
- vaginal squamous intraepithelial neoplasia (VaIN)
- vaginal adenosis (glands)
- tumors



Vaginal tumors and pseudotumors

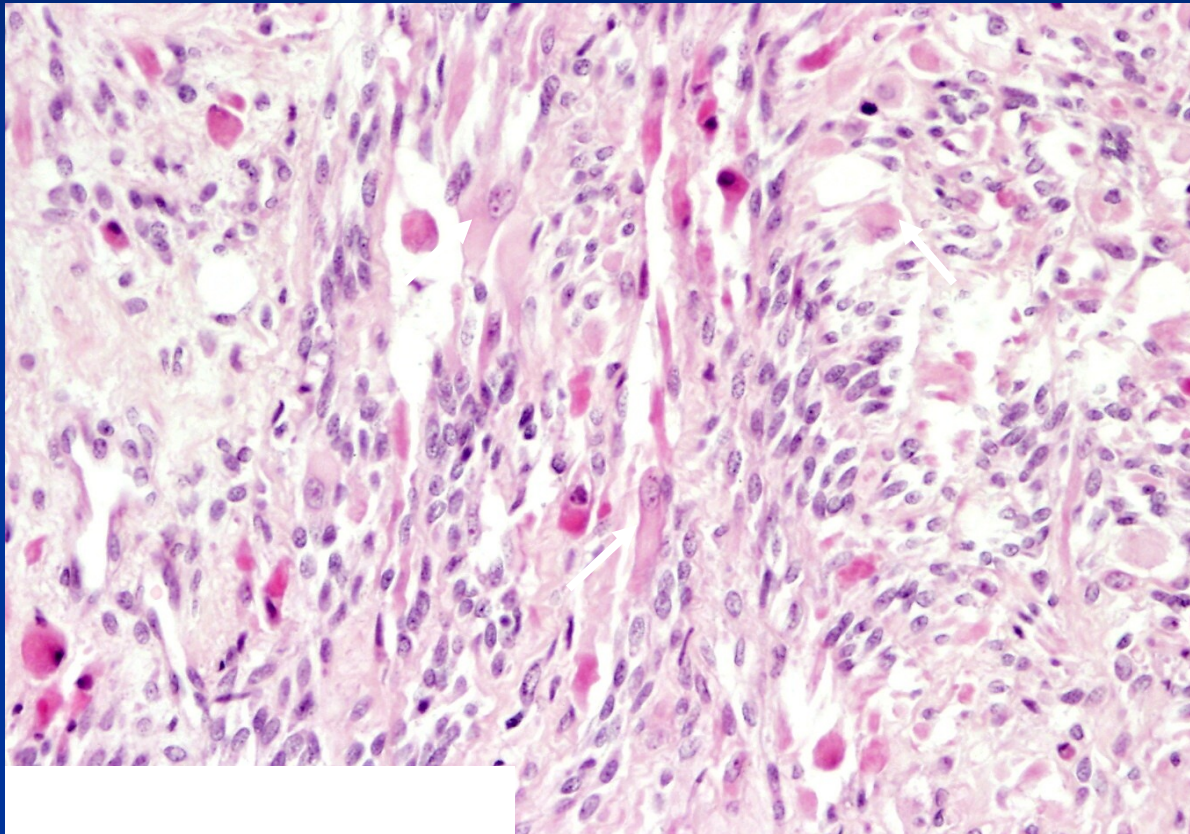
- fibroepithelial polyps, glandular cysts
- HPV lesions concurrent with cervical/vulvar
 - condyloma accuminatum, vaginal intraepithelial neoplasia (VaIN I-III) → **squamous carcinoma**
- embryonal rhabdomyosarcoma (sarcoma botryoides)
 - gross – soft polypoid tumor protruding into vaginal lumen
 - girls <5 years



Copyright © 2002, Elsevier Science (USA). All rights reserved.

vaginal adenosis

Embryonal rhabdomyosarcoma

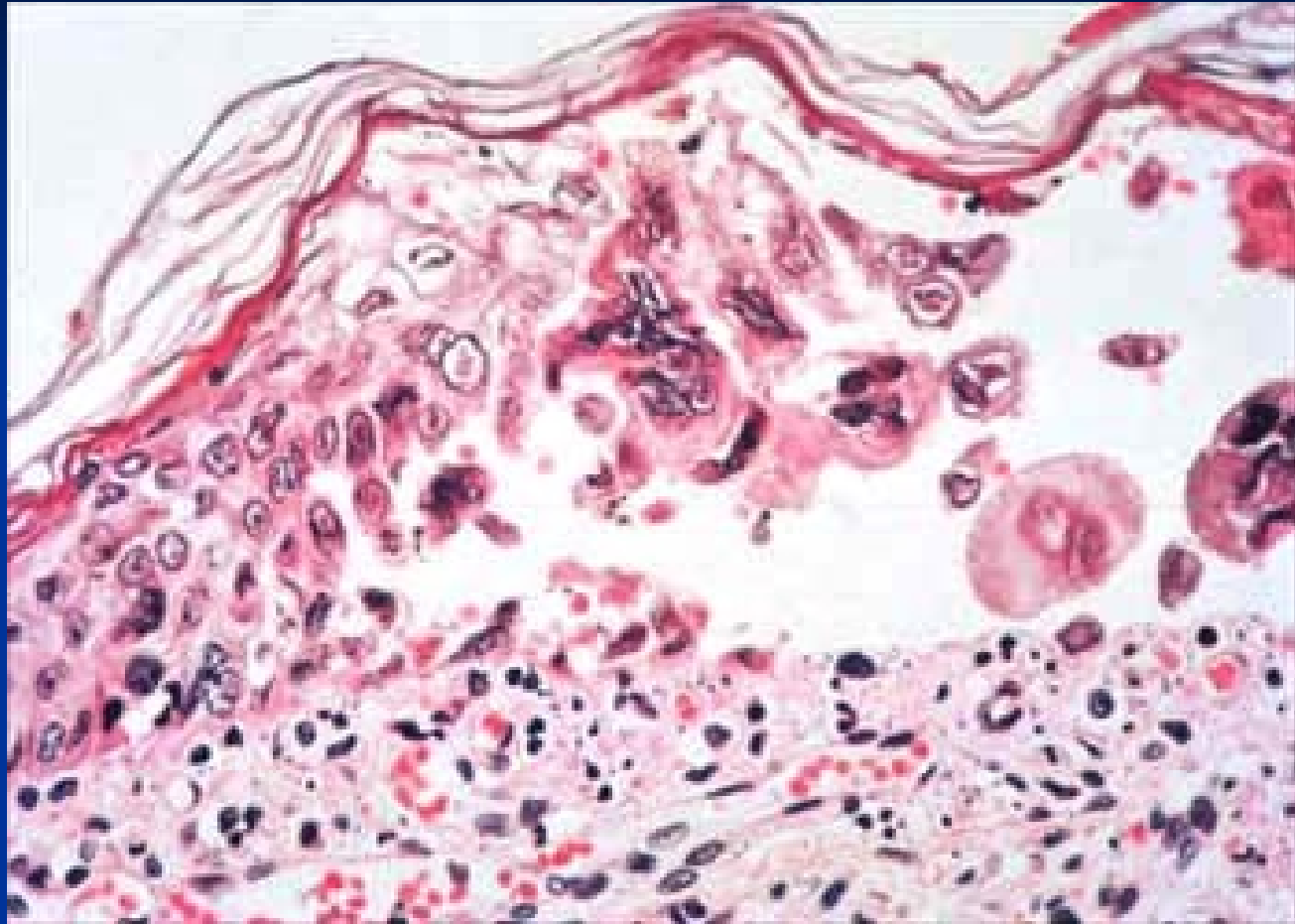


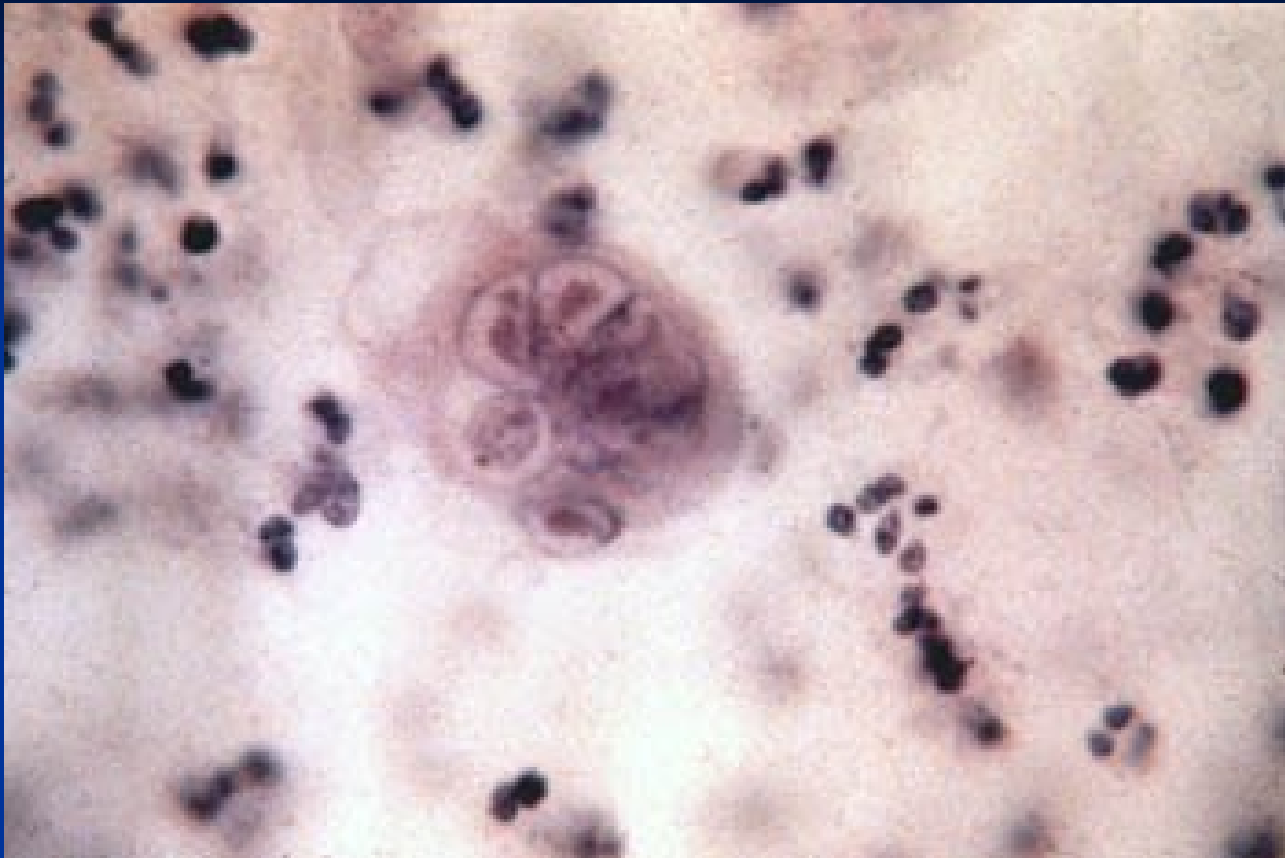(100x)

Vulvar pathology

- inflammatory disorders (infectious, noninfectious)
- cysts
- vulvar intraepithelial neoplasia (VIN)
- tumors







Non-neoplastic epithelial disorders

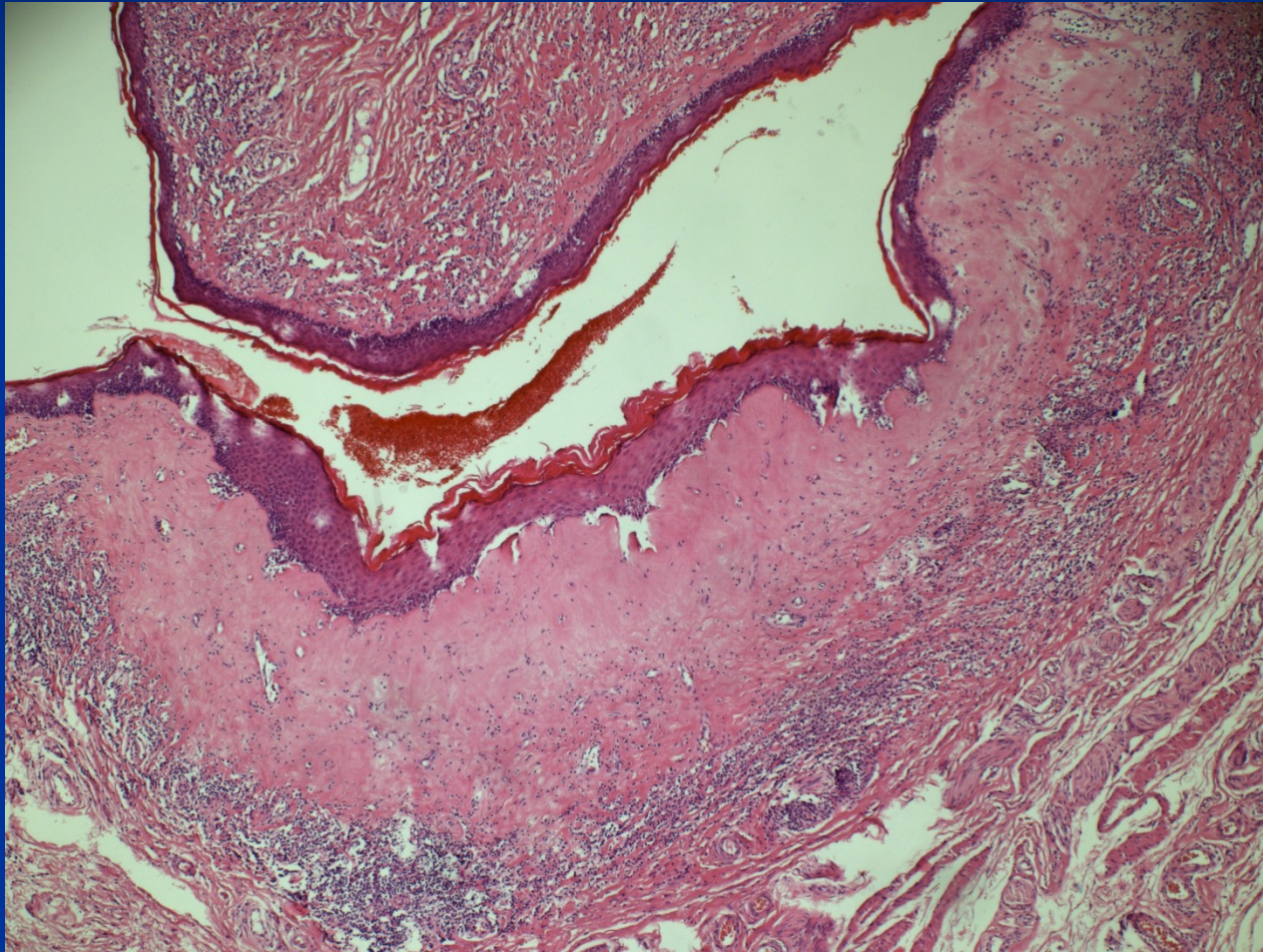
- gross appearance of leukoplakia – white plaque
- mostly in peri-, postmenopausal women
- inflammatory dermatoses (psoriasis, chronic dermatitis), pre- malignant lesions (VIN, ca), disorders of unknown etiology

- Lichen sclerosis
 - epithelial atrophy + hyperkeratosis
 - superficial dermis – band of oedema + hyalinisation
 - perivascular mononuclear inflammatory cell infiltrate
 - → → stenosis of vaginal orifice (craurosis vulvae)

- Lichen simplex chronicus – squamous cell hyperplasia
 - epithelial hyperplasia + marked hyperkeratosis
 - not a precancerosis



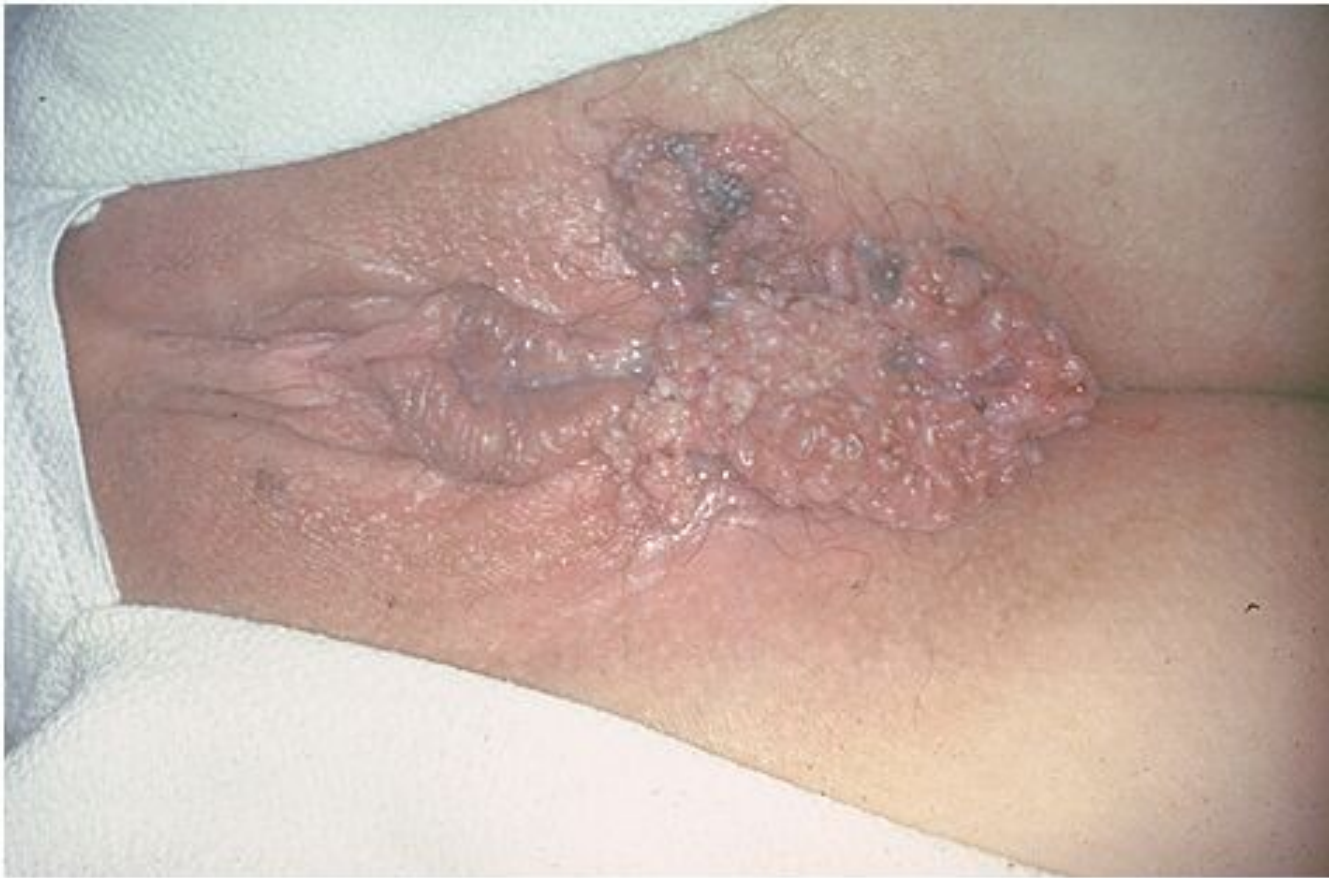Lichen sclerosus



Vulvar neoplasia

- **condyloma accuminatum**
 - low-risk HPV (6, 11)
 - squamous cell papilloma with koilocytor epithelial transformation
- **vulvar intraepithelial neoplasia - VIN**
 - high-risk HPV (16)
 - VIN II , III –high risk of progression into SCC
- **carcinoma**
 - squamous ca (90 %)
 - precursor lesions:
 - VIN II, III
 - lichen sclerosus (in older females)
 - adenocarcinoma, basal cell carcinoma
- **malignant melanoma**





Copyright © 2002, Elsevier Science (USA). All rights reserved.

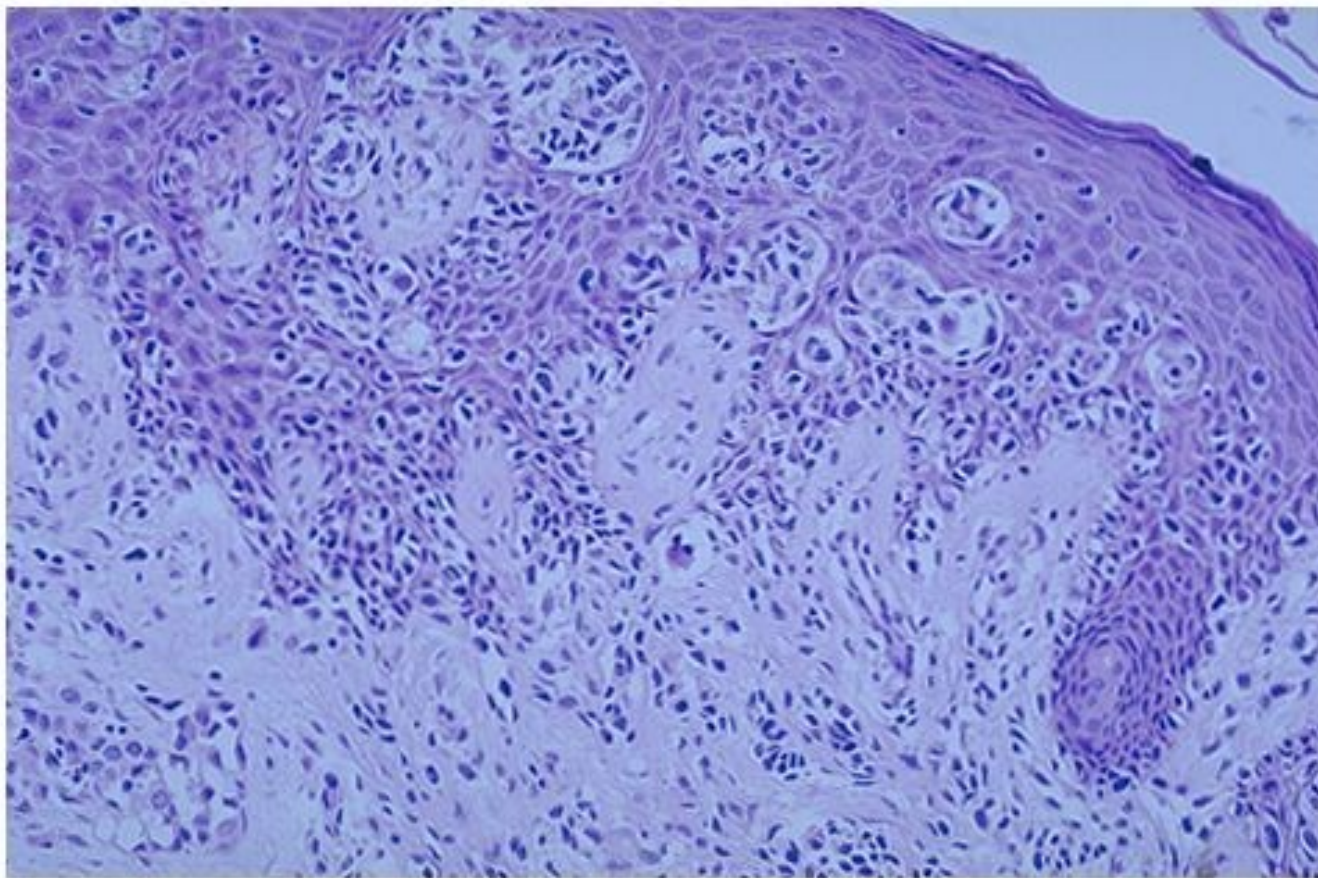
Extensive HPV condylomatosis

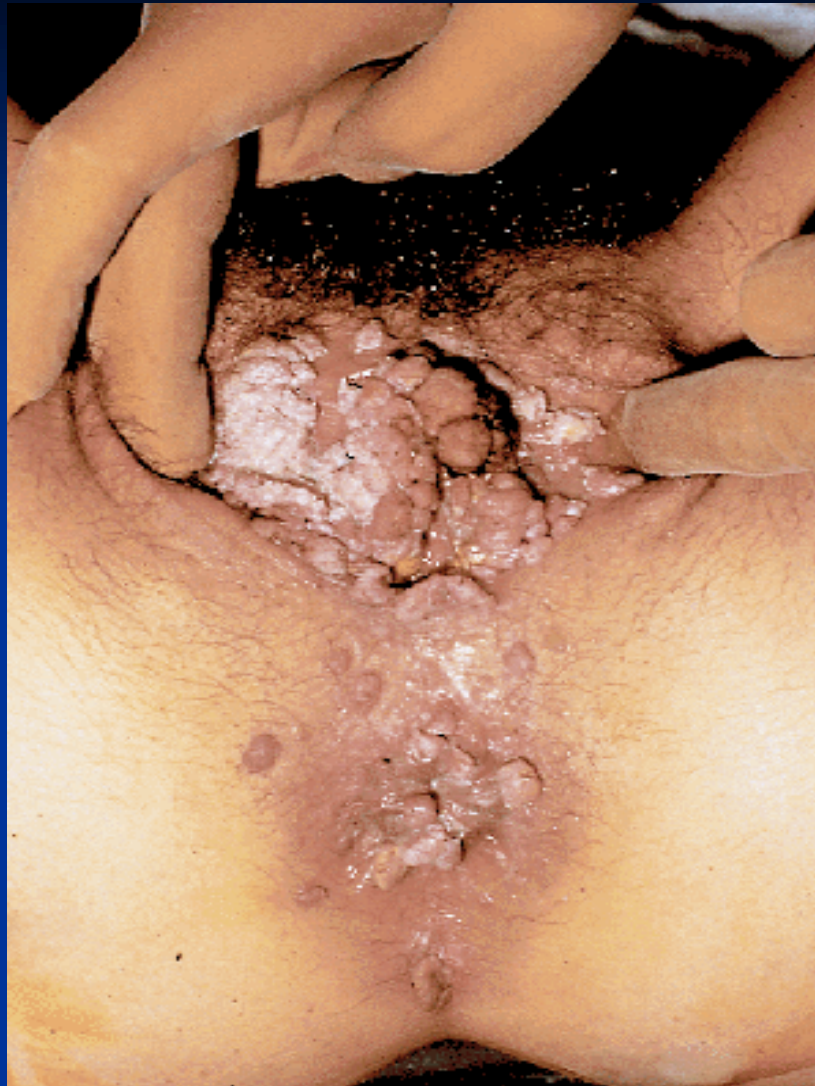
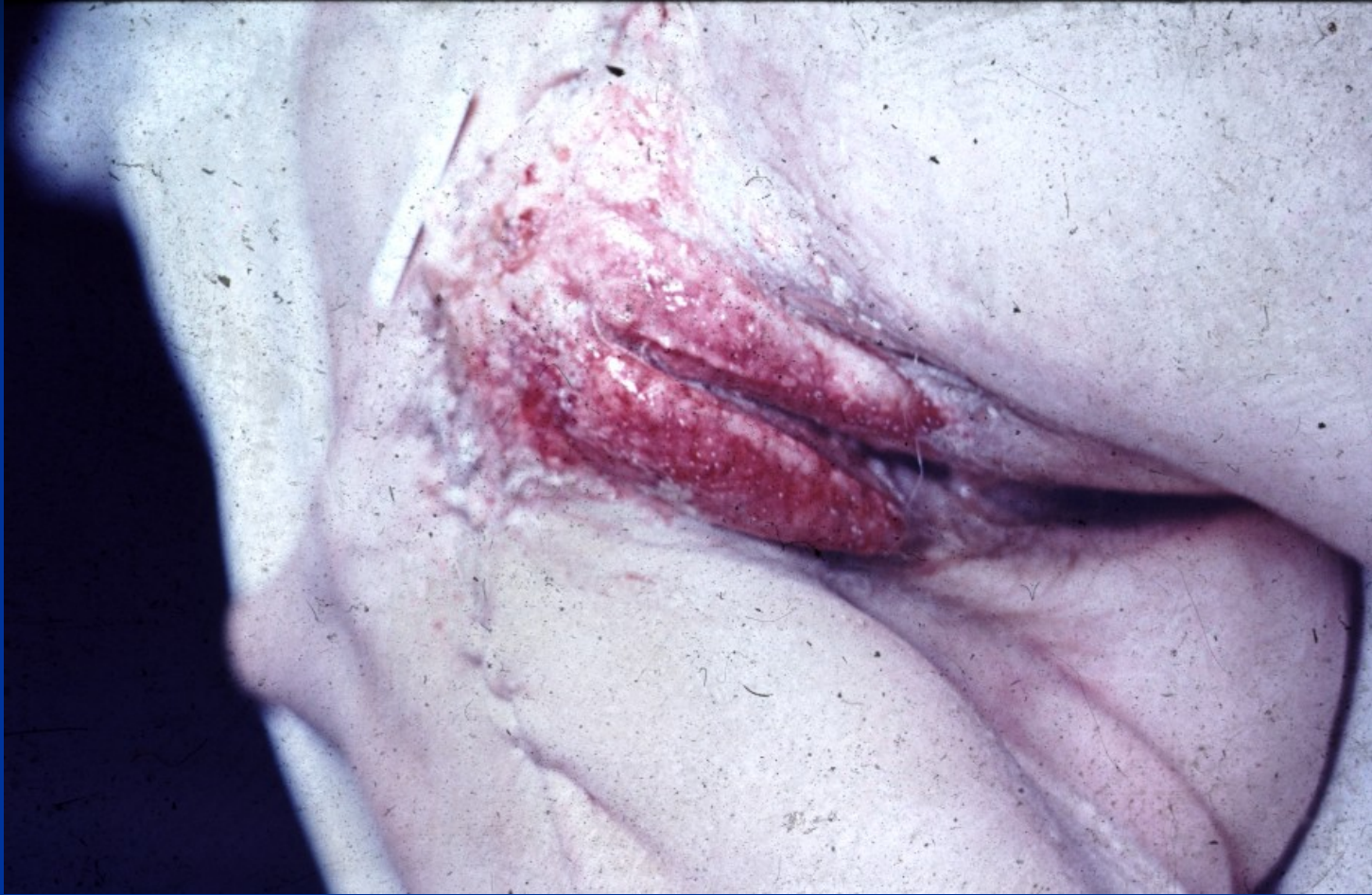
FIG. 5. Condyloma acuminatum. Genital warts may be discrete or confluent. Perianal involvement is common.



Vulvar squamous carcinoma



Copyright © 2002, Elsevier Science (USA). All rights reserved.



