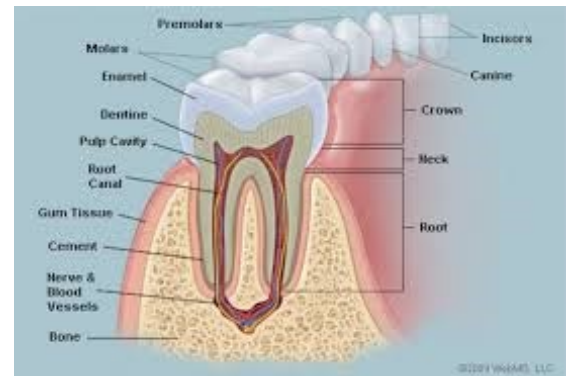


Endodontics I Final exam

01. Characterization and morphology of the endodont. (Abtin M.)

Endodontics is a part of dentistry that is focusing on the disease of dental pulp and periodontal tissues, their diagnosis, therapy and prevention. There are two therapeutic approaches in endodontics – vital pulp therapy (VPT) and root canal treatment (RCT). VPT – the dental pulp remains vital, RCT – the dental pulp or necrotic tissues must be removed and the treatment is based on removal bacteria from the root canal system and regeneration of damaged periodontal tissues. (Canal shaping, cleaning and filling).

The dental pulp is the most inner structure of the tooth and it is what provides nutrition and maintains the vitality of the whole tooth without the pulp chamber the tooth will be non-vital. Without vitality of the dental pulp the dentin loses its mechanical properties (elasticity) because the dentin tubules do not contain liquids and additionally the collagen can be destroyed during the time. Therefore the postendo treatment is very important.

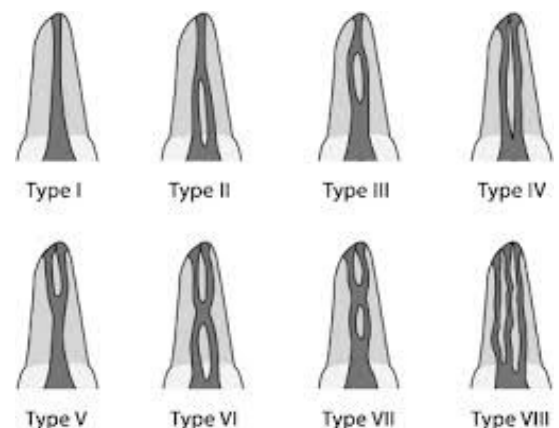


According to Meyer's conclusion the root canals are:

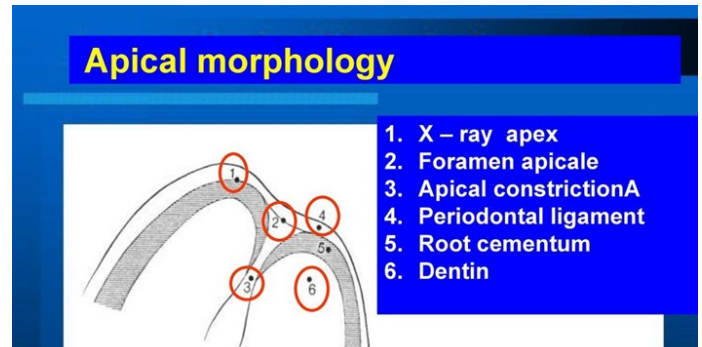
1. The root canal is not round but oval (long axis mesiodistal)
2. The root canal does not go straight but it deflects distally.
3. The outfall is not on the top of the root but below. (distal or distodorsal side of the root)
4. The form of the outfall is funnel – shaped.
5. The root canal system has usually more outfalls. (ramifications)
6. The ramifications are situated mostly in apical area. (first apical mm)
7. All outfalls are situated in cementum.

There are varieties of the morphology of the root canals system below are some of the basic shapes.

Each tooth may have different number of canals, but usually maxillary and mandibular anterior teeth all have one canal, Maxillary first premolar is the only premolar that usually has 2 canals the rest of the premolars including mandibular premolars have 1 root canal usually. Two root canals can be seen quite often in lower premolars (type III). The first mandibular molar has 4 root canals, two buccal (the first maxillary molar has usually 4 root canals MB1, MB2, DB, P) – see presentation on is, (mandibular molars all usually have 3 canals, 4 or 2 root canal can be also seen quite often.



1. This is the apex that is seen in radiogram. If the angulation is correct we can take in account that this is a picture of the real apex of the tooth.
2. The **apical foramen** is the opening at the apex of the root of a tooth, through which the nerve and blood vessels that supply the dental pulp pass. Thus it represents the junction of the pulp and the periodontal tissue.
3. Apical constriction is the tightest part of the canal before opening to the apex and it is where the endodontic treatment should end.

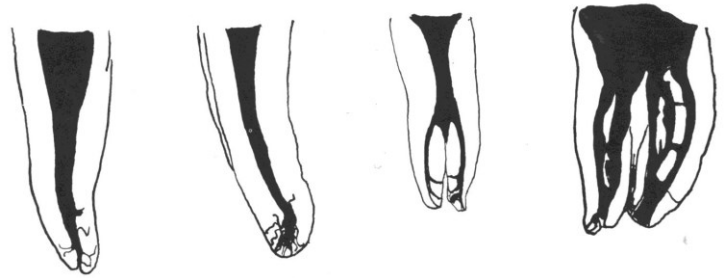


The average distances: Apex (x-ray apex) and apical foramen: 0,75 – 1 mm

Apical constriction – apical foramen: 0,5 – 0,75 mm

Apical constriction – Apex: 1,5 – 2 mm

These distances are average distances and we take them in account by establishment of the working length.



The periodontal space is a space between the root and the alveolar bone – in this space the periodontal tissue (periodontal ligament) lies. There are collagen fibers, blood vessels, lymphatic vessels, cells, nerve endings.

where the structures that surrounds the tooth and supports it lies.

The structures there are the following:

- Periodontal ligament
- Gingiva
- Alveolar bone
- Cementum

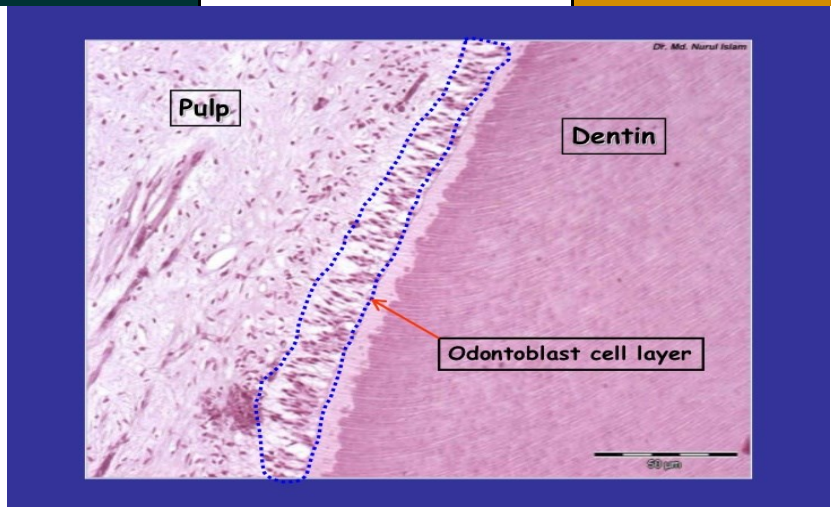
It is important to perform the endodontic treatment well and not to overfill as to not have this aseptic area become septic and cause periodontitis.

Ramifications of the root canal are accessory root canals **mostly next to** the apical constriction which is important to be eliminated during canal shaping as it is too small to be filled properly and bacteria may reside in them leading to a failed endodontic treatment. Apicectomy can also be considered up to 3mm to eliminate the majority of the root canal ramifications.

weight % (volume%)	lamellar bone	email	dentin	cementum
colour	yellow-brownish	blue-whitish	yellowish (ivory)	brown-yellowish

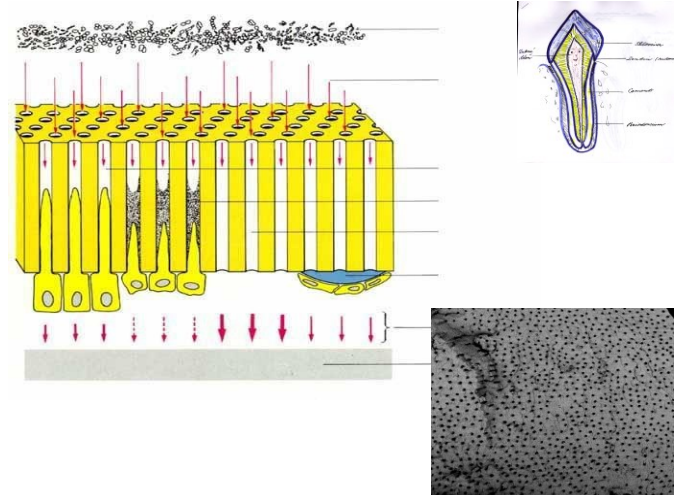
inorganic component	45 (23)	96 (86)	70 (45)	61 (33)
organic component	30 (37)	1 (2)	20 (30)	27 (31)
H₂O	25 (40)	3 (11)	10 (25)	12 (36)
collagen fibres	yes /in each lamella they run in the same direction/	no fibres	yes /rectangle to the dentinal tubules/	yes /felt/
cells	osteoblasts osteocytes	ameloblasts lack	odontoblasts (located on the pulpal side of dentinal matrix)	cementoblasts (cementocytes)
blood vessels	yes (in haversian canals)	no	no	no
nerves	yes (in haversian canals)	no	yes (on pulpal ends of dentinal	no

Odontoblasts - are not scattered within the ECM (dentinal matrix) - but are placed at junction dentin-pulp.



Macrocanal system is the main canal within the root but microcanal **asre dentin tubules** that lead to the pulp chamber. The pulp has some healing effects to protect the macrocanal from disease coming through from the microcanal system the following healing effects by the use of odontoblasts lying on the dental-pulp junction are:

- Formation of secondary dentin which is dentin but with less microtubules compared to primary dentin and not as straight.
- Tertiary dentin which is formed when the disease is close to the pulp chamber and it has very few microtubules and very irregular tubular pattern. **This dentin is less permeable**



-
- Intratubular dentin is a deposit of hard material in dentin tubules. Sclerotic dentin is dentin with closed dentin tubules. Calcification inside the dentin tubules is a prevention of the disease travelling to the pulp chamber.
- Dentin bridge is the dentin formed when exposed dental pulp is covered with bioactive material (e.g. calcium hydroxide or calcium silicate cements). These materials initiate formation of new odontoblasts. (Explanation of formation of dentin bridge in the other question). This healing can be observed when direct pulp capping or pulpotomy are performed.

Reference

Yu-Wen, Huang. "Dentin Pulp Complex." *LinkedIn SlideShare*, 6 Jan. 2012, www.slideshare.net/pen22cute/dentin-pulp-complex.

"Lectures." *Google Drive*, Google, drive.google.com/drive/folders/1mSd1PeDRZ1HZfAiUdySuFiB2qdxfhZba.

Doc. MUDr. Roubalíková, Ph.D., Lenka. "Endodontics I.1a." 7 Mar. 2020, Brno, Czech Republic.

02. Dental pulp and its healing potential, importance of calcium hydroxide. (Alan O.)

The dental pulp is a tissue of mesenchymal origin. It lies in the pulp chamber and root canals. The function of dental pulp and dentin can be seen as a morphological and functional unit (endodont) where odontoblasts take an important part of this system. Odontoblasts are the cells with the highest differentiation, they do not multiply. We find odontoblasts in the pulp-dentine junction where the body is found in the periphery of the pulp chamber and the process which is called odontoblast process or Tomes fibers run throughout the dentine by dentinal tubules.

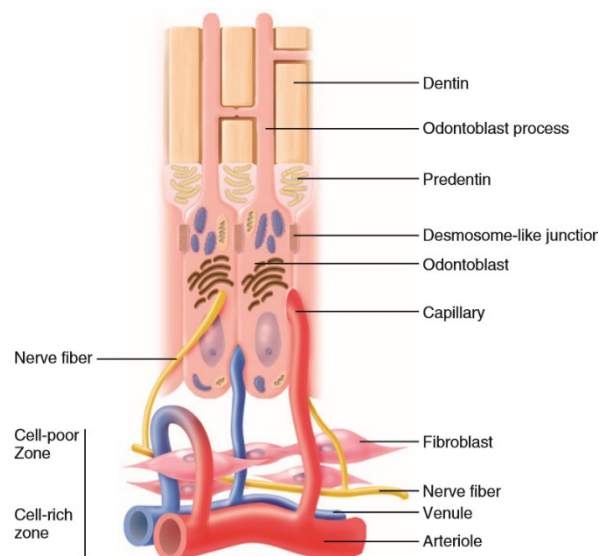
The dental pulp serves 4 functions:

1. Formative function of dental pulp in mediating metabolism of dentinal matrix and are active throughout life of healthy teeth
2. Nutritive function of the pulp to maintain the vitality of teeth by supply nutrients and moisture to dentine by odontoblasts their processes.
3. Sensory function provides nerve fibers within the pulp to mediate sensation of pain. Dentine receptors produce only pain as a response.
4. Defensive function is related to response to irritation by deposition of reparative dentine as protective barrier or by an inflammatory reaction

ZONES OF THE PULP

The zone of the pulp can be divided in 4 layers from outermost to inner zone.

1. Odontoblast layer is as mentioned earlier found in pulp-dentinal junction and are composed of one layer of odontoblast cell bodies with its nuclei found in basal region and the odontoblast processes tapered coronally into dentine. **The odontoblast are connected by tight and gap junctional complexes** for cell to cell communication and signaling to synchronizing. **There are differences between odontoblasts in the coronal and radicular pulp (columnar in the coronal pulp, cuboidal in the middle part of the radicular pulp and flat cells in apical portion of the radicular pulp. Fewer dentinal tubules per unit are present in the root than in the crown of the tooth. So the cell can spread out laterally.**
2. Cell-Poor Zone is around 40µm with and is found immediately under odontoblast layer. Here is no cell found and therefore called for *cell-free layer of Weil*, but blood capillaries, unmyelinated nerve fibers and the slender cytoplasmic processes of fibroblast is going through it. In young pulp this layer might not be found because the dentine is formed rapidly or in old pulp when reparative dentine is formed.
3. Cell-Rich Zone is the third layer of pulp and here as the name indicate rich in cells. Here we can find fibroblasts and number of immune cells like macrophages and dendritic cells, but also undifferentiated mesenchymal stem cells. The vascular system is more extensive here.
4. Pulp Proper is the central zone of the pulp which consist of loose connective tissues, larger blood vessels and nerves. The most prominent cell here is fibroblast.



TYPES OF DENTINE

By time of secretion and deposition of dentinal matrix, we can distinguish 3 types of dentine.

- Primary dentine is the first type of dentine and is secreted during tooth development. This can type has regular dentinal tubules and can be subdivided into two other layers. The first one is mantle dentine, which is the first secreted dentine at dentinoenamel junction of the tooth. The second is called circumpulpar dentine and is 9/10 of dentine thickness.

- Secondary dentine is produced when teeth have reached the occlusal plane and development of their roots are completed. This type of dentine secretes and deposit slowly on pulpal aspect of primary dentine during the life. Here is the dentinal tubules fewer and less regular than primary dentine and still communicate with each other. Secondary dentine can be separated from primary dentine by marked incremental line.
- Tertiary dentine is the last type of dentine and is laid down at sites of direct action of some external stimuli on odontoblast on the wall of pulp as a protective barrier. The dentinal tubules are much less and more irregular than the previous dentine types and have no communication.

We can subdivide tertiary dentine into reparative dentine which is formed by new odontoblasts without processes and reactionary dentine which is formed by still alive odontoblasts.

Sclerosis of dentin is a phenomenon characterized by degeneration of Tomes fibers and by obliteration of dentinal tubules by calcified materials progressing towards the pulp. This occurrence in tooth is a sign of aging which is called physiological dentin sclerosis or by mild irritation which is called reactive dentine sclerosis and can be seen by radiography as more radiopaque.

HEALING POTENTIALS

As all other connective tissues, the healing of dental pulp is as following; It begins with removal of debris by macrophages, followed by proliferation of fibroblast with nutrition for collagen synthesis and adequate blood supply to transport immune cells to the side of injury and removal agent from area.

Unlike most tissues the pulp does not have collateral circulation and thus theoretically higher risk of impair healing after a severe injury. This make it reasonable to think that pulp of young teeth with big opening of apical foramen and high blood supply has better healing potential then older teeth.

Unmineralized predentine contain some soluble and insoluble of growth factors such as TGF- β , BMPs and VEGF which cause proliferation and differentiation of mesenchymal stem cells to form reparative dentine and new blood vessels. When bacterial acids due to caries progression releases these from mineralized dentine to diffuse them to the pulp where the stimulate these processes.

This is also thought to be the mechanism of cation of calcium hydroxide. Even with high pH, calcium hydroxide has a demineralization effect to manage to stimulate reparative dentinogenesis. **It could be to the inhibition of oxygen consumption?**

Healing potential see also formation of tertiary and reparative dentin, dentin bridge, intratubular dentine – see above.

Reference

Sturdevant, John R. "Chapter 1." *Sturdevant's Art and Science of Operative Dentistry*, 6th ed., Elsevier, 2012, pp. 6–9.

Fristad, Inge, and Ellen Berggreen. "Chapter 12." *Cohen's Pathways of the Pulp*, 11th ed., Mosby, 2016, pp. 532–535.

Fristad, Inge, and Ellen Berggreen. "Chapter 12." *Cohen's Pathways of the Pulp*, 11th ed., Mosby, 2016, pp. 560–563.

03. Pulpal response to irritation, pulpitis (Christopher G.)

Dental caries (when cavitated lesion) is a destructive process of dentine, it can have if no treated response in dental pulp. Bacterial products as well as products from the dissolution of organic and inorganic part of dentin irritate the dental pulp.

Three basic reactions tend to protect the pulp against caries:

1. A decrease in dentin permeability
2. Tertiary dentin formation
3. Inflammatory and immune response

Dentin permeability decreases: dentinal sclerosis – deposits of minerals in dentin tubules, partly due to stimulation still vital odontoblasts partly due to the precipitation of mineral salts during demineralization.

Tertiary dentin occurs over a longer period and its resultant character depends on the stimulus. Mild stimuli activate resident quiescent odontoblasts, they elaborate the organic matrix of dentin. This type of tertiary dentine is referred to as reactionary dentin and can be observed when initial dentin demineralization occurs beneath the noncavitated enamel lesion. This dentin is similar in morphology to physiologic dentin and there can be a difference in the direction of new dentinal tubules.

When the stimuli are more aggressive, the carious process is cytotoxic to subjacent odontoblasts and require repopulation of the disrupted odontoblasts layer with differentiating progenitors. The resultant dentin matrix reflects the differentiation state of the secretory cells. This is reparative dentin it is more heterogeneous – from organized tubular dentin to more disorganized irregular fibrodentin. Thus fibrodentine is more permeable than physiologic dentin.

The pulp immune response provides humoral and cellular challenges to invading pathogens. In the progressing carious lesion the host immune response increases in intensity as the infection advances. The early inflammatory response to caries is characterized by the focal accumulation of chronic inflammatory cells. This is mediated by odontoblasts and dendritic cells. As the carious lesion progresses, the density of chronic inflammatory infiltrate as well as dendritic cells increases. Pulpal dendritic cells are responsible for antigen presentation and stimulation of T-lymphocytes. Odontoblasts play a role in humoral immune response. The immunoglobulins are present in their cytoplasm and these antibodies are transported to the infection front. At the beginning of dental caries these antibodies can be found in the odontoblastic layer, later also in dentin tubules. In the most advanced carious lesion the humoral immune response is accompanied by immunopathologic destruction of pulpal tissue. As carious lesion approaches the dental pulp there is an acute exacerbation of the precedent chronic inflammation characterized by an influx of neutrophils. In the presence of severe pulpal inflammation, focal microabscesses form and eventually coalesce, leading to progressive pulpal necrosis.

Dental pulp can be damaged also for other reasons:

Restorative procedures

- In dental pulp can be changes without any symptoms. In this case a simple restorative procedure can cause the irritation – inflammation even necrosis.
 - Heat during preparation (lack of water cooling)
 - Dessication
 - Chemical irritation as well as biological irritation (biological irritation occurs when the filling fails in its seal)
 - Proximity of restorative procedures to dental pulp (pulpal inflammation increases with the reduction of remaining dentin thickness)
 - Permeability of dentine – sclerotic dentine could be left

Pulpal reactions to restorative materials

- Some components of restorative materials can penetrate to dentin and dental pulp: some resin monomers (triethylene glycol dimethacrylate, 2-hydroxyethyl-methacrylate, eugenol etc. Effects of these chemicals is short and reversible if absence of bacteria.

The other factors that can irritate dental pulp

Bleaching

Laser and air abrasion preparation

Periodontal procedures (dentine tubules can be exposed and open, opening of accessory canals) - rare

Orthodontic movement (blood flow changes – transient)

Biomechanical irritants- parafunctions (dentinal cracks and invasion of infection)

Inflammation is a non specific, physiological reaction to tissue injury, infection or irritants.

Cardinal signs of inflammation:

Redness

Swelling

Pain

Heat

Loss of function

There are several ways micro-organisms are able to reach the dental pulp:

-Via the cariogenic process of decay

- Trauma e.g a fracture/cracks can create a direct path to the pulp
- Accessory root canals
- Retrograde movement from periodontal pockets into the pulp
- Anachoresis (microorganisms travel via lymphatic or blood circulation to the pulp and establishes infection)
- Neurogenic pulpitis

Substance P is released by afferent fibers, resulting in neurogenic inflammation of the dental pulp by causing vasodilatation and endothelial cell contraction, which allows plasma extravasation and mast cell degranulation. Releasing histamine, which in turn further amplifies vascular processes and activates nociceptors, resulting in pain.

Lymphocytes, granulocytes, and macrophages have receptors for Substance P, and these cells can be stimulated to produce cytokines. Macrophages stimulated by Substance P produce the inflammatory mediators PGE2 and thromboxane, as well as the pro-inflammatory cytokines IL-1, IL-6, and TNF furthering the inflammatory process.

Acute and chronic Response:

Acute response signifies the initial reaction of the pulp irritants (including Mechanical, chemical, thermal and bacterial)

Two major things happen:

Due to pro-inflammatory mediators vasodilation of pulpal vessels occurs increasing blood volume and hydrostatic pressure. There is a subsequent increase in vessel permeability due to endothelial contraction mediated by cytokines (Histamine, LT and bradykinin) resulting in edema. Fluid exudate (protein rich) leaks from vessels into the extracellular region of the pulp. This aims to dilute and detoxify the irritant.

Secondly due to increased Vascular permeability WBC/ Leukocytes are able to migrate to the site of infection where neutralisation of the irritant takes place. Neutrophils are able to engulf certain pathogens bacteria

Chronic/Proliferative response

Granulation tissue is composed of an extracellular matrix of fibrin, fibronectin, GAGs, proliferating endothelial cells, angiogenesis, and fibroblasts mixed with inflammatory macrophages, lymphocytes and plasma cells. Epithelial cells also are active during this phase and are responsible for initial wound closure. It is primarily formed to replace and repair the damaged tissue during inflammation. Normally an absence of pain.

Factors responsible for inflammation:

Neurogenic factor

TIF (tissue injury factor)

Both have the same effect, differing by their activation.

Neurogenic factor:

Irritants (such as mechanical, chemical and microbial) activate the neural response. Tissue injury factor is due to the release of mediators by damaged odontoblasts.

They both commonly result in vasodilation, increase in permeability, fluid exudation and leukocyte infiltration. Increase in intrapulpal pressure as a result of increased blood volume

and exudate. This can consequently result in pain as the build up of pressure remains localised and is unable to diffuse to surrounding soft tissue since the pulp is surrounded by hard dentine tissue.

Secondary pain response is mediated by unmyelinated C fibers and have a low conduction velocity, a smaller diameter, and a higher excitation threshold.

Types of pulpitis:

Reversible

Irrversible - Painful

Acute

Subacute - not painful

Chronic ulcerative pulpitis (caries)

Chronic pulpitis (no caries)

Chronic hyperplastic pulpitis

See the other question.

Additional Changes of the pulp

Regressive changes:

Atrophy

Fibrosis

Vacuolisation of odontoblasts

Hyalinisation

Dystrophic calcification: Involves the formation of calcification spots frequently found in the aging pulp, usually in perivascular or perineural locations. They contain no dentinal tubules.

Pulpal stones/denticles: Dentinal calcifications are localised masses of calcifications (dental tubules lined by odontoblasts). Often associated with aging, tooth injury, abrasion, erosion and dental conditions such as dental dysplasia. Initial resorption usually after persistent chronic inflammation. Its presence can hinder RCT as it can occupy the whole of the root chamber. Hence ultrasonic instruments with sodium hypochlorite should be used during end treatment.

Necrosis

Persistent infection leads to edema and increased intrapulpal pressure, causing tissue destruction, acute phase protein production, and cell death, leading to tissue necrosis.

Necrosis is a subsequent step to chronic inflammation.

Types of necrosis:

Liquefaction necrosis: tissue is transformed into a liquid mass. Affected cells are digested by [hydrolytic enzymes](#), resulting in a soft lesion consisting of pus and the fluid remains of necrotic tissue.

Coagulation necrosis: Due to poor blood flow to a part of the body. If blood flow is reduced then cells of the pulp will not receive enough oxygen and nutrients, which results in the cell death.

Products of necrosis are toxic to periodical tissue, hence can trigger an inflammatory response, access formation without the presence of bacteria. Pulp necrosis occurs, the radiographic manifestation may be an apical radiolucency.

Gangrene

Dental gangrene is a complete death and infection of the pulp tissue inside the tooth root. Intermediate proteolytic products of pulpal tissue result in a foul odour. Compounds responsible for the foul smell include the following: Indol, scatol, utrescin, cadaverin and indican. Also end products such as hydrogen sulphide and ammonia results in foul smell. Endotoxins from bacteria and foreign bacterial proteins mediate this process.

References

Nanci A Tencate's Oral Histology. Development, Structure and Fiction. 8th ed. Elsevier;20123

Kukletova, Prof. MUDr M. "Histology and Physiology of the Dental Pulp: Inflammation ." 8 Mar. 2020, Brno.

Hargreaves, Kenneth M., et al. Cohen's Pathways of the Pulp. Elsevier, 2016.

04. Classification of pulpitis, reasons (Luka Ž.)

Additional classification 2015 & 2018 will be added as soon as uploaded on IS.

Pulpitis, which is the inflammation of the dental pulp can be classified **histopathologically** into: **Description of changes in dental pulp must students know basically. .**

- hyperaemia pulpaе

- pulpitis acuta serosa partialis
- pulpitis acuta serosa totalis
- pulpitis acuta purulenta partialis
- pulpitis acuta purulenta totalis

- subacute pulpitis – nonpainful pulpitis

- pulpitis chronica clausa
- pulpitis chronica aperta
- pulpitis chronica ulcerosa – due to caries
- pulpitis chronica polyposa – pulp polyp

Clinically pulpal diseases can be divided into reversible and irreversible:

Reversible pulpitis can be recognized by: **no spontaneous pain is present**

- sharp pain and difficult to localize
- stimulation being uncomfortable
- pain on stimulus – especially cold stimulus can cause an attack of pain
- pain does not linger after the stimulus was removed
- normal peri-radicular appearance
- teeth are not tender to percussion

In **irreversible pulpal** diseases which are symptomatic:

- pain during the night
- during the time the attacks are longer
- the stimuli are less sensitive on cold, but more on hot
- patient is able to recognise the causative tooth
- x-ray is negative or widened periodontal ligament space – thickening of periodontal membrane

It is difficult to find the correlation between histological changes in dental pulp and symptoms. Today we can see a new way of thinking about the inflamed pulp. In majority of mature teeth diagnosed with irreversible pulpitis or apical periodontitis the root canal treatment is the only therapy for saving these teeth. Many of endodontically (after RCT) treated teeth are associated with apical radiolucency (appr. 40%), also endodontically treated teeth without visible radiographic signs of apical periodontitis can still be infected. The endodontic treatment (RCT) is lengthy and costly. As new insights in pulp biology have been gained, recent clinical research on vital pulp therapy now provides options for developing new biologically driven treatment protocols. Today is the trend to save dental pulp: if pulp tissue is preserved, thus maintaining its physiological and defensive functions. Also less hard dental tissue is removed, the tooth is not so weakened as in the case of RCT. Today modern endodontics is avoiding full pulpectomies if possible because a biological immune response from even a partially retained pulp could improve the treatment outcome by preventing infection of the apical area. Today's research has shown that results of vital pulp treatments are comparable to conventional root canal therapy. Aseptic approach is mandatory.

Pulpal defence mechanism is described in the previous questions. Apart from sclerosis and formation of tertiary dentine a host of growth factors including TGF- β , ADFM and IGF-1/-2 are released from the pulpodentinal complex when dentine dentin is demineralized during the progression of carious lesion. These growth factors can have a positive effect on pulpal responses by enhancing the processes involved in pulp repair and regeneration. Teeth that have a diagnosis irreversible pulpitis can be treated with vital methods very often. This is a reason for new classification of pulpitis.

Classification based on clinical symptoms:

(Hashem 2015)

- Mild reversible pulpitis

Sensitivity to hot, cold and sweet lasting up to 12 – 20 s and settling spontaneously

- Severe reversible pulpitis

Increased pain for more than several minutes and needing oral analgesics

- Irreversible pulpitis

Persistent dull throbbing pain, sharp spontaneous pain and tenderness to percussion or pain exacerbated by lying down.

New classification (2018)

- Initial pulpitis

Heightened but not lengthened response to cold, warm and sweet stimuli, not sensitive to percussion

And no spontaneous pain.

Therapy: IDP (indirect pulp capping)

- Mild pulpitis

Heightened and lengthened reaction to cold, warmth and sweet stimuli that can last up to 20 s but then subsides. According to the histological situation that fits these findings, it would be implied that there is limited local inflammation confined to the crown pulp.

Therapy: IPT or intermittent excavation.

- Moderate pulpitis

Clear symptoms, strong, heightened and prolonged reaction to cold, which can last for minutes, possibly percussion sensitive and spontaneous dull pain that can be more or less suppressed with pain medication. According to the histological situation that fits these findings, it would be implied that there is an extensive local inflammation confined to the crown pulp.

Therapy: Coronal pulpotomy – partly/completely

- Severe pulpitis

Severe spontaneous pain and clear reaction to warmth and cold stimuli, often, sharp to dull throbbing pain, patients have trouble sleeping because of the pain (get worse when lying down). Tooth is sensitive to touch and percussion. According to the histological situation that fits these findings, it would be implied that there is extensive inflammation of the crown pulp with extension into the root canals.

Therapy: Coronal pulpotomy (completely) or if bleeding does not stop using 2,5% NaOCl, deep pulpotomy is indicated (inflamed tissue is removed from the canal up to 3-4 mm from the radiographic apex. After stopping of bleeding the filling of the root canal follows up to the vital pulp tissue. If bleeding persists a full pulpectomy needs to be performed in order to remove all inflamed tissue from the canal.

But irreversible pulpitis can also be asymptomatic in quite a large number of patients and result after a period of time in symptomatic pulpitis or the pulp may become necrotic or/and lead to apical periodontitis

Necrosis, which is a sequel of acute and chronic inflammation, results in an inflammatory response, abscess formation without the presence of microbes. Products of necrosis are toxic to the periapical tissues and necrotic pulp may become very often gangrenous. Necrotic pulp can be recognised by:

- no symptoms
- no response on vitality tests
- pain on hot stimulus **no, it is a sign of gangraena because of expansion of gas by increasing of temperature. This symptom is present only when there is not any communication between the pulp chamber with gangreneous pulp and oral cavity.**
- no radiographic finding or widening of periodontal ligament space. **It is not typical, widening is a sign of inflammation in periodontal space.**

Gangrene, which can occur additionally, can be recognized by its typical smell **when open** and can be open or closed.

Reasons for any form of pulpitis and their way of entry may be very complex. Most common the causes are:

- dental caries
- mechanical irritants – trauma, over-instrumentation,
- chemical irritants – intracanal medicaments, overfilling, irrigants
- infection from the surroundings
- accessory root canals
- retrograde movement of infection – from periodontal pocket
- anachoresis – attraction of microorganisms to a focus of inflammation
- neurogenic pulpitis

Reference

Prof. MUDr. Kukletová, CSc., Martina. "Inflammation - Pulpitis." 7 Mar. 2020, Brno, Czech Republic.

Doc. MUDr. Roubalíková, Ph.D., Lenka. "Endodontics I.1a." 7 Mar. 2020, Brno, Czech Republic.

Doc. MUDr. Roubalíková, Ph.D., Lenka. "Endodontics I." 7 Mar. 2020, Brno, Czech Republic.

05. Symptomatology of pulpitis, principles of the treatment (Mareen A.).

Pulpitis is inflammation of dental pulp tissue. It can be divided into acute and chronic pulpitis.

Acute Pulpitis

1. **Acute reversible(hyperaemia) pulpitis²**: First stage of pulpitis where the inflammation is mild and the pulp is capable of healing.

Symptoms^{1,2}:

- Mild to moderate pain initiated by stimuli (cold, biting, sweet, sour and sometime heat)
- The pain evoked is of short duration. The pain is due to fluid movement within dentinal tubules can stimulate the odontoblasts and associated fast- conducting A-delta nerve fibers in the pulp
- There is no sponataneous pain and pain is difficult to localise
- Pain does not persist after stimulus is removed
- Sleep is usually not affected
- Teeth are not tender to percussion

Treatment²:

Removing the cause. If cause is fracture/cracked teeth, stabilise and seal the pulp temporarily using Calcium hydroxide. If the cause is caries then remove the caries and perform pulp capping. Pulpotomy in deciduous teeth.

Usually indirect pulp capping or intermittent excavation if there If larger portion of carious dentin – intermittent excavation. Consider pulpotomy – see previous question.

2. **Acute asymptomatic irreversible pulpitis²**: This is a clinical diagnosis based on subjective and objective findings indicating that the vital inflamed pulp is incapable of healing.⁶ The patient, however, does not complain of any symptoms. On occasion, deep caries will not produce any symptoms, even though clinically or radiographically the caries may extend well into the pulp. Left untreated, the tooth may become symptomatic or the pulp will become necrotic. In cases of *asymptomatic irreversible pulpitis*, endodontic treatment should be performed as soon as possible so that symptomatic irreversible pulpitis or necrosis does not develop and cause the patient severe pain and distress.

3. **Acute symptomatic irreversible pulpitis²**: It refers to instances where the inflammation is severe and the pulp is not capable of healing.

Symptoms^{1,2}:

- Severe Pain may develop spontaneously or from a stimuli (hot or cold). In later stages heat is more significant
- Pain lasts from minutes to hours .The pain is due to
- Pain continues even after stimulus is removed
- Sometimes the pain may be accentuated by lying down or bending over
- When the periodontal ligament is involved, the pain is localized
- A widened periodontal ligament may be seen in later stages
- Sleep is affected

Treatment²:

Root canal treatment where the pulp is removed and replaced by gutta-percha
A tooth that has had previous endodontic therapy (such as pulpectomy, pulpotomy) but has remained infected or has become infected again will require endodontic re-treatment or extraction.

Chronic Irreversible Pulpitis³

1. **Closed Pulpitis**: The pulp cavity is not connected to the oral cavity.

Symptoms:

- Pain: absent or mild to moderate, dull ache which is irregular

- Reaction to thermal changes is reduced in comparison to acute pulpitis.
- Manipulation with small instruments often causes bleeding but little pain.
- May be symptom less in some cases

Treatment:

Root canal therapy followed by crown restoration.

2. **Polypous open (hyperplastic) Pulpitis:** A granulation tissue slowly grows out of the pulp cavity as the increasing tissue mass through the opening of the pulp roof,

Symptoms:

- It is usually asymptomatic.
- Red pinkish nodule protruding out of the carious tooth.
- Direct pressure during mastication may cause mild to moderate tenderness
- Localised bleeding may occur when the soft tissue is manipulated or traumatized.
- Mobility of the tooth and sensitivity to percussion are usually absent.
- Mostly in young people with an abundant blood supply and a large carious lesion.

Treatment:

This condition is usually treated by root canal treatment, unless coronal damage does not permit restoration, in which case extraction is indicated

3. **Ulcerative open pulpitis:** located in the region of the opening of ulcerating pulp surface.

Symptoms:

- Symptoms and treatment similar to polypous pulpitis

4. **Pulpitis chronica granulosa interna - internal resorption**
Usually asymptomatic, there is enlargement of the root canal typical oval or spheric, because of a resorption of the tooth. If the resorption is big – a pink spot on dental crown can be seen. Typical finding on radiogram – well limited.
Therapy: RCT.

Reference:

1. Dent, IAU. "Pulpitis." *LinkedIn SlideShare*, 20 Jan. 2014, www.slideshare.net/UDDent/pulpitis-30231708.
2. Roubalíková, Lenka. "Endodontics I." IS MUNI

<https://is.muni.cz/auth/el/med/jaro2020/aZLED061p/Endodontics1.pdf?lang=en>

3. Kassem, Menna. "The Disease of the Dental Pulp." *LinkedIn SlideShare*, 23 Oct. 2015, www.slideshare.net/mennakassem31/the-disease-of-the-dental-pulp.

06. Differential diagnosis of pulpitis, papillitis, apical periodontitis, headache.
(Haneen T.)

The purpose of a diagnosis is to determine what problem the patient is having and why the patient is having that problem¹.

The basic steps in diagnostic procedures are²:

- Chief complaint of the patient
- Medical and dental history
- Intraoral and extraoral examination
- Clinical tests
- Data analysis and differential diagnosis
- Treatment plan

Chief complaint²

It is the first information given by the patient and must be recorded in the exact formula. It helps in both diagnosis and treatment plan.

Medical and dental history

This includes the medical history of diseases present and medications taken, allergies and injuries. Dental history includes history of previous treatments (restorative, periodontal², endodontic, TMJ dysfunction²), trauma², pain history³ (location, type, intensity and duration of pain, what makes the pain worse/better).

The dentist should ask the patient about symptoms he has. The patient may complain from²:

- Pain
- Swelling
- Sinus tract
- Broken tooth
- Loose tooth
- Tooth discoloration
- Bad taste

Intraoral and extraoral examination

Extraoral examination²:

- The dentist should look and analyze the patient as soon as he enters the room.
- Look for general appearance, skin tone, facial asymmetry, **swelling**, discoloration, **redness**, extraoral scars, sinus tracts and lymphadenopathy.
- Palpation of the face and neck is also important to check for swelling or tenderness. Many times the swelling is not clearly visible and requires palpation to identify.
- Degree of mouth opening.

Intraoral examination²:

- Oral tissue is dried and examination begins with lips, oral mucosa, cheek, tongue, periodontium, gingiva, palate and muscles.
- Look for signs of discoloration, inflammation, ulceration and sinus tract formation.
- Sinus tract can be traced to its source using gutta-percha points size 25 or 30 and inserted into the opening until resistance is felt. It may cause slight discomfort to the patient.
- Examine teeth with mirror and explorer and look for discoloration, fracture, abrasion, attrition, erosion, caries, defective restoration or other abnormalities.
- A discolored crown can be an indication of pulp pathosis.
- Periodontal examination: teeth with wide periodontal pocket are usually periodontal in origin, while teeth with narrow localized pocket are usually endodontic, or could be vertical root fracture. Furcation bone loss could be periodontal or endodontic.

Clinical tests

These could be divided to 3 categories:

- Pressure tests (palpation, percussion and bite test)
- Pulp sensitivity tests
- Radiographic examination
- Transillumination

Pressure tests

Palpation²:

- Firm digital pressure with index finger is applied to the apical area of the tooth and adjacent teeth

- Any soft tissue swelling, bony expansion, pain or tenderness should be noted and recorded
- This may indicate an active periapical inflammation, however it does not determine whether it is endodontic or periodontal in origin.

Percussion²:

- This test is performed when the patient complains from pain during biting.
- Pressure is applied with index finger on incisal/occlusal surface of the tooth vertically or horizontally.
- The adjacent teeth should be tested first to serve as control and to know the normal responses of the patient.
- If the patient doesn't report any pain after this test, then a blunt instrument is used to tap the tooth.
- This test doesn't indicate the status of the pulp, rather it indicates the presence of inflammation of the PDL.

Bite test²:

- It begins by applying firm pressure using a cotton tip applicator, toothpick or tooth sloth to each cusp of the tooth.
- Patient will report pain where there is apical pathology or root fracture.
- Sometimes patient feel pain when the instrument is removed, which may indicate fractured tooth or root.

Pulp sensitivity tests

Cold and hot tests²

- Cold test can be performed with ice sticks, dry ice (CO₂) or refrigerant spray.
- If patient response to the test and pain subside after removal of the instrument then the pulp is normal.
- If the pain does not diminish or rather increase after removal of instrument then this tooth most likely has a pulpal pathosis
- Heat test can be applied using heated water in syringe (after isolation with rubber dam), heated gutta-percha or use of rotatory rubber cup (not recommended).

Electric pulp test²

- This test does not indicate the presence of vascular supply to the pulp (a sign of vitality) but rather indicate the presence of intact nerve fibers.
- Electric pulp testing is most accurate when detecting necrotic teeth.

Radiographic examinations²

Periapical pathology can be presented radiographically with:

- Lamina dura is absent apically: it is the most consistent radiographic finding when tooth is not vital. If lamina dura is widened or intermitted then it can be an indication of pulpal or periodontal pathosis.
- Radiolucency at the apex: absence of radiolucency does not mean there is no pathology, other clinical tests should be performed.

Not all apical pathosis are seen on radiographs, especially early lesions. The root apices of most anterior teeth and premolars are close to the cortical bone, therefore seen early. While molar teeth are found in cancellous bone, therefore not seen early in the radiograph.

Transillumination and staining²

- Stains can be used to determine the presence of fracture in the root
- Transillumination with strong fiberoptic light can determine the fracture site
- Area close to the light source will appear bright, while area beyond the fracture will appear dim.

Other methods like Test Cavity may also be used, where a bur in high speed with water coolant is used to drill the tooth, when dentin is reached the patient will feel pain with indicate vital pulp tissue. It is only used when the other tests failed to determine the condition of the pulp. This test is not recommended because it is an invasive procedure².

Data analysis and differential diagnosis

Normal pulp²

The tooth responds normally to pulp tests. It responds to pain from the other tests and the pain disappears after removal of the stimuli

Pulpitis

According to histopathological classification

Acute Inflammation:

1. Hyperaemia: first stage of pulp inflammation, which is usually reversible. Lymphocytes and plasma cells migrate into the subodontoblastic area, combined with an expansion of the arterioles and a significant increase in the flow rate of the blood.³
2. Acute pulpitis serosa (partial or total): After the stage of hyperemia, serous exudate is released . A distinction is made between partial and total pulpitis. In the case of **pulpitis acuta serosa partialis**, it is limited to a small part of the crown pulp. If the entire pulp is affected, one speaks of **pulpitis acuta serosa totalis** , which is irreversible, but can change into chronic pulpitis.³
3. Acute pulpitis purulent (partial or total): If leukodiapedesis is added to pulpitis acuta serosa, the serous one becomes a purulent inflammation. In the case of infected necrosis, the dead pulp is decomposed by a mixed bacterial infection. It represents the final stage of all pulpitis.³

Chronic Inflammation:³

1. Closed: the pulp cavity is not connected to the oral cavity
2. Opened: the expansion of carious lesion or trauma can create a connection between oral cavity and pulp chamber.
3. Ulcerous: located in the region of the opening of ulcerating pulp surface.
4. Polypous: A granulation tissue slowly grows out of the pulp cavity as the increasing tissue mass through the opening of the pulp roof, in adequate blood supply.

(refer to Prof. M. Kukletová's lecture – Apical periodontitis)

According to clinical classification⁴

1. Reversible pulpitis:

- Pain does not persist after stimulus is removed
- Pain is difficult to localize
- Normal periradicular appearance
- Teeth are not tender to percussion

2. Irreversible pulpitis

- Pain may develop spontaneously or from stimuli
- In later stages heat is more significant
- Response lasts from minutes to hours
- When the periodontal ligament is involved, pain is localized
- A widened periodontal ligament may be seen in later stages

Papillitis

Is the inflammation of interdental papilla. ??**Percussion is positive in transverse direction.**

Apical periodontitis

Inflammation of the periodontal area of the infected tooth

- 1st phase (periodont): hyperemia in the apical periodontium, increase in pressure - elevates slightly, the tooth nerve endings are stimulated slight pressure - mild pain.⁵
- 2nd phase (enosseal): as the process advances - the tooth becomes increasingly tender, lymph nodes sensitive, alteration of the patient, starts pus formation, pain more intense and steady soft vestibular tissue - painful to palpation, patient may be febrile.⁵
- 3rd phase (periost): the most intense pain - throbbing, steady, radiating - pus penetrates the outer plate of the bone - raises the periosteum, swelling in the apical region, great mobility, face asymmetry, swelling. the symptoms are greater in horizontal position, patient – febrile.⁵
- 4th phase (submucous): periosteum and mucosa – ruptured, RELIEF, pain subsides - but swelling, fluctuation, great asymmetry.⁵

Symptomatic apical periodontitis:³

- The tooth responds to biting, percussion or palpation tests
- The tooth may or may not respond to vitality tests
- Radiographically the tooth presented at least with widened PDL. Apical radiolucency may or may not be seen.

Asymptomatic apical periodontitis:³

- The tooth usually does not respond to vitality tests, and does not respond to biting tests but ‘feels different’
- The tooth usually exhibits apical radiolucency
- However the patient does not complain of any symptoms

(refer to Prof. M. Kukletová’s lecture – Apical periodontitis)

Acute pulpitis – difference between reversible and irreversible see also previous questions.

Pulpitis X Periodontitis

Pulpitis: spontaneous pain, at the beginning it is not localized, the pain irradiates along nerve branches, see referred pain, the attacks come during the night. At earliest stages of pulpitis cold stimuli elicit pain, in later stages hot stimuli elicit pain, cold stimuli decrease pain. Dental caries, new filling or crown can be often found.

X ray negative, or when also dental pulp in the root affected the periodontal space can be widened due to hyperaemia there.

Periodontitis: pain is well localized, heavy pain on bite or percussion, vitality test negative, hot causes pain, cold stimuli decrease pain, the patient has a feeling of elevated tooth, vitality negative, usually slight mobility can be found, pain on palpation in apical area, fistula can be present, x ray: widening of periodontal space or periapical radiolucency.

Pulpitis X otitis media

Otitis media No suspicious finding in oral cavity, cold and rhinitis can be in patient's history.

Pulpitis X papillitis

Papillitis: the pain could be similar to pulpitis but there is pain on percussion in the transverse direction.

Pulpitis x Headache – migraine

Migraine: There is a pain limited on half of head, usually vomiting and photosensitivity.

Pulpitis x neuralgia n. trigemini

Neuralgia: Sharp pain, very short, there is trigger zone, tic douloureux, no finding of teeth.

Pulpitis x herpes zoster

Herpes zoster: pain along the nerve, small blisters along the nerve. No suspicious findings on teeth.

Treatment plan

*Vital methods*⁴

Dental pulp remains vital. Pulp capping (direct/indirect), pulpotomy (partial/total)

*Non-vital methods*⁴

Dental pulp does not remain vital. Root canal treatment

(refer to Prof. L. Roubalíková's lecture – Endodontics I)

Citations:

¹ Hargreaves, Kenneth M., et al. *Cohen's Pathways of the Pulp*. Elsevier, 2016.

² Academy, Iraqi Dental. "Endodontic Diagnosis and Treatment Planning Slides." *LinkedIn SlideShare*, 16 Dec. 2016, www.slideshare.net/AsadiUsama/endodontic-diagnosis-and-treatment-planning-slides.

³ "Pulpitis." *Wikipedia*, Wikimedia Foundation, de.wikipedia.org/wiki/Pulpitis#Pulpitis_acuta_serosa.

⁴ Roubalíková, Lenka. "Endodontics I." *IS MUNI* <https://is.muni.cz/auth/el/med/jaro2020/aZLED061p/Endodontics1.pdf?lang=en>

⁵ Prof. MUDr. M. Kukletová. *Apical periodontitis*.

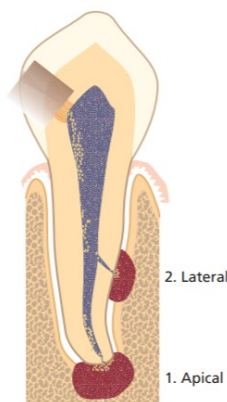
07. Apical periodontitis – reasons, classification Mostly infection and chemical irritation, classification acc. to course and pathology.(Garima K.)

Apical periodontitis – Inflammation of the periodontium surrounding the apex of the root canal system. (This is essentially at the root tips, the communication between the root canal system and the periodontium; the apical foramen).

Apical periodontitis is a type of inflammation; therefore it is a protective mechanism. The process attempts to isolate bacteria coming from the root canal space, to prevent spreading along the deeper areas (especially to avoid spreading systemically to the blood).

Reasons:

- Defensive response to a primary infection in a necrotic pulp.
- Post-treatment apical periodontitis is most commonly due to either unsuccessful control of primary root canal infection by endodontic treatment measures
- Reinfection of the root canal system due to inadequate obturation and/or inadequate coronal seal that allowed bacterial leakage to take place.
- Tissue toxic effects extrusion of certain medicaments and root filling materials into the periapical tissue – chemical irritation
- Exogenous forces become hyperactive- **explanation?**
- Increase in intraperiapical pressure - **explanation**
- Mediators released by the injured cells



This picture illustrates “Apical or periapical lesions “ which generally refer to lesions in the periodontium that are of endodontic origin.

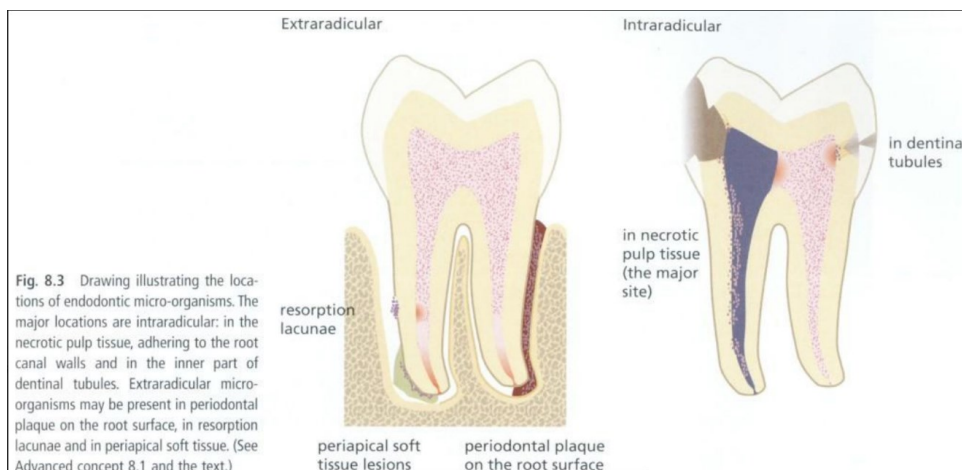


Fig. 8.3 Drawing illustrating the locations of endodontic micro-organisms. The major locations are intraradicular: in the necrotic pulp tissue, adhering to the root canal walls and in the inner part of dentinal tubules. Extraradicular micro-organisms may be present in periodontal plaque on the root surface, in resorption lacunae and in periapical soft tissue. (See Advanced concept 8.1 and the text.)

Classifications of apical periodontitis

Depending on different stages of their development we can find:

- Asymptomatic – most cases. Bone loss is the major indicator for apical periodontitis, especially because most cases are without symptoms.
- Symptomatic or ACUTE - Happens when the host defense vs the bacterial infection equilibrium is disturbed. Also as a response to an *initial* exposure of the periapical periodontium to bacteria or their products emerging from the infected root canal (*biting pressure sensitivity, percussion or palpation are symptoms*)

“Acute apical periodontitis

- *mild symptomatic (exudative) response*
- *contaminants from the pulp, vasodilatation, fluid exudation,*
- *white cells infiltration*
- *periodontal phase - abscess in the periodontal space*
- *enosseal phase - localized ostitis*
- *periosteal phase - severely symptomatic*
- *pain - throbbing character, radiating*
- *submucous phase - periosteal inflammation – relief,”*

1. Phase (periodont)	hyperemia in the apical periodontium increase in pressure - elevates slightly the tooth nerve endings are stimulated slight pressure - mild pain	3. phase (periost)	the most intense pain - throbbing, steady radiating - pus penetrates the outer plate of the bone - raises the periosteum swelling in the apical region great mobility face asymmetry, swelling the symptoms greater in horizontal position patient - febrile
2. phase (enosseal)	as the process advances - the tooth becomes increasingly tender, lymph nodes sensitive, alteration of the patient, starts pus formation, pain more intense and steady soft vestibular tissue - painful to palpation, patient may be febrile	4. phase (submucous)	periosteum and mucosa - ruptured RELIEF pain subsides - but swelling fluctuation great asymmetry

On a microscopic level:

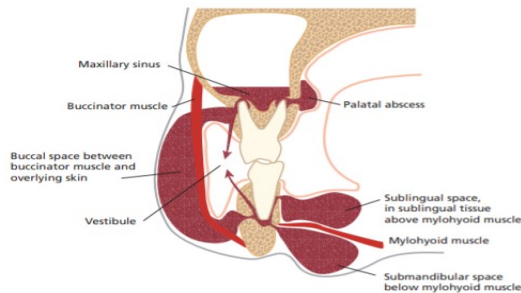
- **Apical granuloma** - inflammatory lesion dominated by lymphocytes, macrophages and plasma cells
- Periapical granuloma
- more advanced form
- granulation tissue + chronic inflammatory
- cells
- (granulomatous tissue)
- peripheral collagenous fiber capsule

- **Apical abscess** - Apical abscess denotes the presence of pus within the lesion. Rapid onset, pain, tenderness of the tooth to pressure, pus formation and eventual swelling of associated tissues. At the initial stages of its formation, the process may be extremely painful, as pressure builds up in the restricted periapical bony crypt or

periodontal space. The overlying cortical bone can perforate and pus will accumulate under the periosteum (extremely painful).

Acute periapical abscess

- Advanced exudative, severely symptomatic*
- steadily increasing amount of inflammatory exudate, leucocytic infiltration*



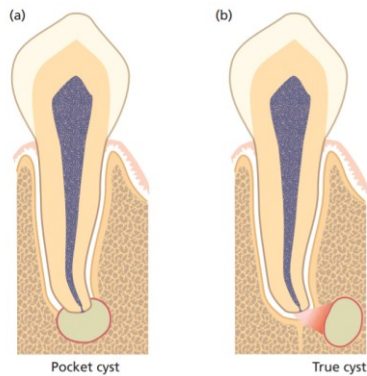
- suppuration*

Recrudescence abscess

(phoenix abscess)

- previously - chronic (granulomatous lesions)*
- contaminated (infected)*
- decrease in immunity*
- Symptoms: acute symptoms + periapical radiolucency*
- Subacute periapical abscess*
- chronic periapical abscess cycle*
- drainage through the stoma = the sinus tract (fistula)*
- parulis (gumboil) on the mucosa = swelling (gingiva, oral mucosa)*

- **Apical cyst** - epithelium-lined cavity that contains fluid or semi-solid material. Divided into pocket cysts and true cysts. A **pocket cyst** is an apical inflammatory cyst that contains a sac-like, epithelium lined cavity that is open to *and continuous with the root canal space*. **True apical cysts**, on the other hand, are **located within the periapical granuloma with no apparent connection** between their cavity and that of the root canal space



OTHER CLASSIFICATIONS

Pulpoperiapical osteosclerosis

- (condensing osteitis, sclerosing osteitis)
- increase in the density of the periapical bone
- osteoblastic hyperactivity - bony trabeculae thicker
- in young persons - mandibular teeth
- (caries lesion, chronically inflamed pulp)
- After root canal therapy - return to normal

Non painful pulpoperiodontal pathoses

- inflammatory response to pulpal irritant -
- proliferative components
- (granulomatous)
- Pain is absent

Incipient chronic apical periodontitis

- slightly widened apical periodontal space
- dilated blood vessels, mild inflammatory response
- chronic inflammatory cells (plasma cells, lymphocyte)

Apical periodontitis: inflammation in periodontal space of pulpal origin see previous text.

Reasons : infection

mechanical irritation (e.g. overtinstrumentation)

chemical irritation (e.g. irrigants)

trauma (interruption of blood vessels)

Histopathology see the text above.

From clinical point of view:

Acute periodontitis – symptomatic, radiogram: widened periodontal space,

Chronic periodontitis – asymptomatic, radiogram: radiolucency usu periapical – well limited:
Periodontitis chronica circumscripta, non limited: periodontitis chronica diffusa. Big non limited lesion: periodontitis chronica granulomatosa progressiva.

Chronic periodontitis can become acute – periodontitis chronica acute exacerbans. It is symptomatic, the only difference in comparison to acute periodontitis is radiolucency at the apex.

Development of radicular cyst: Mallasez cells (rests of Hertwig epithelial sheath) -chronic irritation – development of the cyst. See text above

Reference

Endodontics 1 “Apical Periodontitis” lecture – Professor Kukletova

Endodontics 1 “Apical Periodontitis” lecture – Professor Kukletova

Endontics lecture – page 6/32 - Professor Kukletova

08. Symptomatology of acute periodontitis, principles of treatment. (Maria L.)

Periodontitis- serious gum infection that without proper treatment can cause future complications involving whole periodontal apparatus (cementum, periodontal ligaments, alveolar bone) and can even result in teeth loss. If bacteria responsible for periodontitis will enter and spread in the bloodstream some diseases like rheumatoid arthritis, respiratory disease, coronary artery disease and problems controlling blood sugar in diabetes can occur.

Stages of development of periodontitis:

1. **Accumulation of the plaque-** improper brushing, bad oral hygiene, excessive consumption of sugars between meals.
2. **Hardening of the plaque into tartar-** filled with bacteria, difficult to remove, we need professional dental cleaning.
3. **Plaque can cause gingivitis-** the mildest form of gum disease. It is irritation and inflammation of the part of your gum tissue around the base of your teeth (gingiva). Gingivitis can be reversed with professional treatment and good home oral care.
4. **Ongoing gum inflammation can cause periodontitis-** arising of pockets filled with bacteria between gums and teeth. Not treated become deeper causing loss of the attachment which in worst case can cause teeth loss.

This text does not belong to apical periodontitis.

Apical periodontitis is an inflammation in periodontal space of pulpal origin (dental pulp become necrotic for various reasons), the other reasons see previous questions.

Phases of acute periodontitis:

1st Phase (periodont)

hyperemia in the apical periodontium
increase in pressure - elevates slightly
the tooth nerve endings are stimulated slight
pressure - mild pain

2nd Phase (enosseal)

as the process advances - the tooth becomes increasingly tender, lymph nodes sensitive, alteration
of the patient, pus formation, pain more intense and steady
soft vestibular tissue - painful to palpation, patient may be febrile

3rd Phase (periost)

the most intense pain - throbbing, steady
radiating - pus penetrates the outer plate of the bone- raises the periosteum
swelling in the apical region
great mobility
face asymmetry, swelling
the symptoms greater in horizontal position
patient – febrile

4th Phase (submucous)

periosteum and mucosa - ruptured
RELIEF
pain subsides - but swelling
fluctuation
great asymmetry

Principles of therapy:

Local – decompression – opening of pulp chamber, the pus is evacuated. If periodontal phase we can consider endodontic treatment in one visit.

In enosseal phase – decompression, the pus must be evacuated, the tooth can remain open for 24 hours, endodontic treatment follows afterwards. If we do not manage to evacuate pus, antibiotics therapy can be necessary.

In periosteal phase: decompression, incision of abscess, after decreasing of pain endodontic treatment.

Submucous phase: incision, evacuation of pus, opening of pulp chamber and root canal and irrigation, RCT in next session.

It is necessary always consider : local, regional and systemic factors when consider endotreatment. Extraction can be an option.

Acute periodontitis is characterized by: **this is differential diagnosis: It is important for correct diagnosis but I will not examine the therapy of 3-5.**

1. Gingival abscess;
2. Periodontal abscess;
3. Necrotizing periodontal diseases;
4. Herpetic gingivostomatitis;
5. Pericoronal abscess (pericoronitis);
6. Combined periodontal-endodontic lesions.

GINGIVAL ABSCESS

A localized purulent painful infection that involves the marginal gingiva or interdental papilla. It may be accompanied by increased sensitivity to hot or cold food and drinks, swelling, purulent exudate and red, shiny, smooth surface.

Treatment: draining the abscess to relieve the acute symptoms.

PERIODONTAL ABSCESS

A localized purulent infection within the tissues adjacent to the periodontal pocket that may lead to the destruction of periodontal ligament and alveolar bone. May include smooth, shiny swelling of the gingiva; pain, with the area of swelling tender to touch; a purulent exudate, and/or increase in probing depth. Rapid loss of periodontal attachment may occur causing mobility of the tooth. A periodontal abscess may be associated with endodontic pathosis.

Treatment: drainage by debriding the pocket and removing plaque, calculus, and other irritants and/or incising the abscess. We can also use x-ray to see if there is any bone loss. If the dental pulp is affected we may need a root canal treatment. In some circumstances extraction of the tooth may be necessary. **In typical case the tooth is vital.**

NECROTIZING PERIODONTAL DISEASES

When Necrotizing ulcerative gingivitis (NUG) include attachment loss, it is referred to as necrotizing ulcerative periodontitis (NUP). It may include necrosis and ulceration of the tips of the interdental papillae or gingival margins with pain, redness and bleeding under slight manipulation. The mouth may have a malodor and systemic manifestations may be present. Both NUG and NUP may be associated with increased levels of stress, heavy smoking, poor nutrition, HIV/AIDS and other diseases in immunocompromised patients.

Treatment: Irrigation and debridement of the necrotic areas and tooth surfaces; oral hygiene instructions and the use of oral rinses, pain control, and management of systemic manifestations, including appropriate antibiotic therapy, as necessary. Patient counseling

should include instruction on proper nutrition, oral care, appropriate fluid intake, and smoking cessation.

HERPETIC GINGIVOSTOMATITIS

Viral infection (herpes simplex) of the oral mucosa. Includes generalized pain in the gingiva and oral mucous membranes, inflammation, vesiculation, and ulceration of the gingiva and/or oral mucosa, lymphadenopathy, fever, and malaise

Treatment: Debridement and the relief of pain (e.g., topical anesthetic rinses). Patient counseling should include instruction in proper nutrition, oral care, appropriate fluid intake, and reassurance that the condition is self-limiting. The use of antiviral medications may be considered. The patient should be informed that the disease is contagious at certain stages.

PERICORONAL ABSCESS (PERICORONITIS)

A localized purulent infection within the tissue surrounding the crown of a partially or fully erupted tooth. Accompanied by localized red, swollen, lesions that are painful to touch. Also evident may be a purulent exudate, trismus, lymphadenopathy, fever, and malaise.

Treatment: Debridement and irrigation of the undersurface of the pericoronal flap, use of antimicrobials and tissue recontouring, or extraction of the involved and/or opposing tooth. Patients should be instructed in home care.

COMBINED PERIODONTAL/ENDODONTIC LESIONS (ABSCESSSES)

Localized, circumscribed areas of infection originating in the periodontal and/or pulpal tissues in the form of abscesses. Can originate from either or both locations; may arise primarily from pulpal inflammatory disease and spread itself through the periodontal ligament/the alveolar bone to the oral cavity (Endo-Perio) or from a periodontal pocket communicating through accessory canals of the tooth and or apical communication and secondarily infect the pulp (Perio-Endo) In addition, they may arise as a sequela of a fractured tooth. Symptoms are: smooth, shiny swelling of the gingiva or mucosa; pain with a purulent exudate. The tooth may be sensitive to percussion and mobile. A fistulous track may be present. Rapid loss of the periodontal attachment and periradicular tissues may occur. Facial swelling and/or cellulitis may be present.

Treatment: Establishing drainage by debriding the pocket and/or by incising the abscess. Other treatments may include endodontic therapy, irrigation of the pocket, limited occlusal adjustment, the administration of antimicrobials, and management of patient comfort. A surgical procedure for access for debridement may be considered. In some circumstances, an endodontic consultation may be required. In other circumstances, extraction of the tooth may be necessary. In any case, a comprehensive periodontal and endodontic examination should follow resolution of the acute condition

09.Symptomatology of chronic periodontitis,principle of treatment (Almost no symptoms, in case of acute exacerbation the same symptoms like in acute periodontitis. X-ray picture) (Aiike N.)

Periodontal disease is an inflammatory process that affects the protective and supportive tissues around the tooth. Bacterial plaque accumulation on the tooth surface leads to marginal tissue inflammation, known as gingivitis. If left untreated, gingivitis may progress to periodontitis, which is characterized by loss of periodontal attachment support and bone resorption, eventually resulting in tooth mobility and loss.²

Chronic periodontitis is a common disease characterized by a painless, slow progression. It may occur in most age groups, but is most prevalent among adults and seniors worldwide.²

Symptoms:¹

Healthy gums are firm and pale pink and fit snugly around teeth. Signs and symptoms of periodontitis can include:

- Swollen or puffy gums
- Bright red, dusky red or purplish gums
- Gums that feel tender when touched
- Gums that bleed easily
- Pink-tinged toothbrush after brushing
- Spitting out blood when brushing or flossing your teeth
- Bad breath
- Pus between your teeth and gums
- Loose teeth or loss of teeth
- Painful chewing
- New spaces developing between your teeth
- Gums that pull away from your teeth (recede), making your teeth look longer than normal
- A change in the way your teeth fit together when you bite

Risk factors:¹

Factors that can increase your risk of periodontitis include:

- Gingivitis
- Poor oral health habits

- Smoking or chewing tobacco
- Hormonal changes, such as those related to pregnancy or menopause
- Recreational drug use, such as smoking marijuana or vaping
- Obesity
- Inadequate nutrition, including vitamin C deficiency
- Genetics
- Certain medications that cause dry mouth or gum changes
- Conditions that cause decreased immunity, such as leukemia, HIV/AIDS and cancer treatment
- Certain diseases, such as diabetes, rheumatoid arthritis and Crohn's disease

Complications:¹

Periodontitis can cause tooth loss. The bacteria responsible for periodontitis can enter your bloodstream through gum tissue, possibly affecting other parts of your body. For example, periodontitis is linked with respiratory disease, rheumatoid arthritis, coronary artery disease and problems controlling blood sugar in diabetes.

Prevention:¹

The best way to prevent periodontitis is to follow a program of good oral hygiene, one that you begin early and practice consistently throughout life.

- **Good oral hygiene.** That means brushing your teeth for two minutes at least twice daily — in the morning and before going to bed — and flossing at least once a day. Flossing before you brush allows you to clean away the loosened food particles and bacteria. Good oral hygiene prevents the development of an environment around your teeth that is favorable to specific bacteria that cause periodontal disease.
- **Regular dental visits.** See your dentist or dental hygienist regularly for cleanings, usually every six to 12 months. If you have risk factors that increase your chance of developing periodontitis — such as having dry mouth, taking certain medications or smoking — you may need professional cleaning more often.

Treatment:³

The main aim of treatment is to clean out bacteria from the pockets around the teeth and prevent further destruction of bone and tissue.

1. Scaling and cleaning:

It is important to remove plaque and calculus to restore periodontal health.

A healthcare professional will carry out scaling and debridement to clean below the gumline. This may be done using hand tools or an ultrasonic device that breaks up the plaque and calculus. Root planing is done to smooth the rough areas on the roots of the teeth.

Cleaning is normally recommended twice a year, and possibly more often, depending on how much plaque accumulates.

2. Medications:

A number of medicated mouthwashes and other treatments are available.

Prescription antimicrobial mouth rinse, such as chlorhexidine: This is used to control bacteria when treating gum disease and after surgery. Patients use it as they would a regular mouthwash.

Antiseptic chip: This is a small piece of gelatin that is filled with chlorhexidine. It controls bacteria and reduces periodontal pocket size. It is placed in the pockets after root planing. The medication is slowly resealed over time.

Antibiotic gel: This gel contains doxycycline, an [antibiotic](#). It helps control bacteria and shrink periodontal pockets. It is placed in the pockets after scaling and root planing. It is a slow-release medication.

Antibiotic microspheres: Very small particles containing minocycline, an antibiotic, are placed into pockets after scaling and root planing. This slow-release medication is also used to control bacteria and reduce periodontal pocket size..

Advanced periodontitis

If good oral hygiene and non-surgical treatments are not effective, surgical intervention may be needed.

Options include:

Flap surgery: The healthcare professional performs flap surgery to remove calculus in deep pockets, or to reduce the pocket so that keeping it clean is easier. The gums are lifted back, and the tartar is removed. The gums are then sutured back into place, so they fit closely to the tooth. After surgery, the gums will heal and fit tightly around the tooth. In some cases, the teeth may appear longer than before.

Bone and tissue grafts: This procedure helps regenerate bone or gum tissue that has been destroyed. New natural or synthetic bone is placed where the bone was lost, promoting bone growth.

Guided tissue regeneration (GTR) is a surgical procedure that uses barrier membranes to direct growth of new bone and gum tissue at sites where one or both of these are lacking. It aims to regenerate tissue and repair defects that have resulted from periodontitis.

In this procedure, a small piece of mesh-like material is inserted between the gum tissue and bone. This stops the gum from growing into bone space, giving the bone and connective tissue a chance to regrow. The dentist may also use special proteins, or growth factors, that help the body regrow bone naturally.

The dental professional may suggest a soft tissue graft. This involves taking tissue from another part of the mouth, or using synthetic material to cover exposed tooth roots.

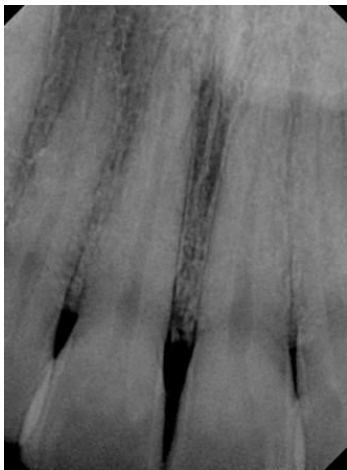
Success depends on how advanced the disease is, how well the patient adheres to a good oral hygiene program, and other factors, such as smoking status.

X-ray pictures: ⁴

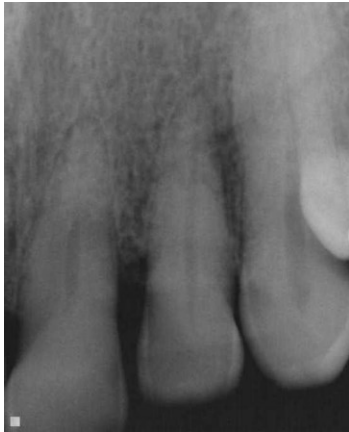Early periodontal stage:

Typical gum pocket depths would be 4-5mm and early horizontal bone loss around the teeth can be seen on the x-rays below.

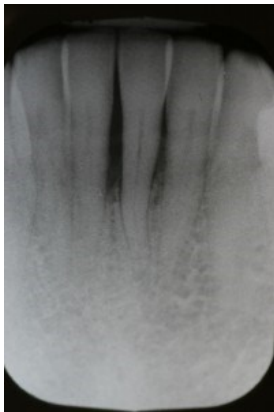Bleeding when measuring (probing) may be present.



Moderate periodontal stage: are typically characterized by moderate loss of bone (see x-ray below) around the teeth – either vertical or horizontal. Pockets can measure between 5-7mm, and there may also be associated tissue loss, or gum recession.



Advanced Periodontal stage: is characterized by more advanced bone loss around the teeth. There is 50% bone loss or more. Pockets typically measure 7-9mm or more, and there may or may not be tissue loss (recession of the gums) and mobility.



References:

1. "Periodontitis." *Mayo Clinic*, Mayo Foundation for Medical Education and Research, 14 Feb. 2020, www.mayoclinic.org/diseases-conditions/periodontitis/symptoms-causes/syc-20354473.
2. Shaddox, Luciana M, and Clay B Walker. "Treating Chronic Periodontitis: Current Status, Challenges, and Future Directions." *Clinical, Cosmetic and Investigational Dentistry*, Dove Medical Press, 11 Aug. 2010, www.ncbi.nlm.nih.gov/pmc/articles/PMC3645457/.
3. Brazier, Yvette. "Periodontitis: Treatment, Home Remedies, and Symptoms." *Medical News Today*, MediLexicon International, 18 Jan. 2018, www.medicalnewstoday.com/articles/242321#treatment.
4. Carroll, Judy. "Stages of Periodontal Disease." *Perio Peak*, 5 Oct. 2019, periopeak.com/stages-of-periodontal-disease/.

THIS QUESTION IS COMPLETELY OUT OF THE TOPIC. The topic is: chronic apical periodontitis

10. Diagnosis and differential diagnosis of acute periodontitis (Mariyam. D.)

Periodontitis is an inflammatory disease of the gums and the tooth's surrounding structure

FOCUS ON APICAL PERIODONTITIS .- IT MEANS PERIODONTITIS OF PULPAL ORIGIN.

Acute periodontitis is a clinical condition of rapid onset that involves the periodontium associated structures

- Can be localised or generalised
- Can present with possible systemic manifestations (pregnancy, hyperglycemia, diabetes, hormonal changes , etc)

This is mainly due to a build up of bacteria which cause an inflammatory response and can lead to erythema of the gums , pain / discomfort and bleeding sometimes upon brushing or probing.

This is out of topic.

Following text is ok.

PHASE 1- PERIODONT⁴

- Hyperemia
- Increase in pressure (intrapulpal pressure due to swelling) elevates slightly the tooth
- Nerve endings are stimulated due to slight pressure causing mild pain

PHASE 2- ENOSSEAL⁴

- Tooth becomes increasingly tender as the process advances
- Sensitive lymph nodes
- Pus formation
- Pain more intense and painful upon palpation
- Patient may be febrile

PHASE 3- PERIOST⁴

- Intense pain – throbbing , steady
- Radiating
- Swelling in the apical region
- Patient is febrile
- Symptoms intensify in the horizontal position

PHASE 4- SUBMUCOUS⁴

- Periosteum and mucosa can become ruptured
- Relief
- Pain subsides eventually but swelling present

DIAGNOSIS –

- Erythema
- Swelling
- Bleeding upon probing or brushing
- Discomfort

Acute Pulpitis – is the inflammation of pulp²

- Can be due to trauma
- Can be caused by a Retrograde infection (travels from apex deeper into the periodontal tissue)
- Some kind of Irritation (grinding of teeth can lead to horizontal crack in the tooth- chronic bruxism eliciting pain in the pulp leading to inflammation)

IRREVERSIBLE

- Pain : severe / spontaneous and continuous
- Pain increases when patient lies down
- Sharp pain upon applying the stimulus (hot , cold, sweet)
- Can get sharp pain throughout the night
- Bad breath

Pulp Necrosis and gangrene ²

- - o no symptoms
 - o no response to vitality tests
 - o if gangrene-- typical smell (can be open or closed)
 - o no radiographic finding or widened PDL space
 - o Gangrene has foul odour
 - o Necrosis usually has no odour

REVERSIBLE

- We get Pulp hyperemia (dilation of blood vessels)
- Exudation of material
- Inflammatory cell infiltration (neutrophils)
- Reactions usually remain localised adjacent to the cause
- Patient feels Pain during eating

Symptoms =

- Severe pain elicited due to thermal changes (cold and warm)
- Pain can persist even after thermal stimulus has been removed
- Pressure increases because of lack of escape of inflammatory exudate (intrapulpal pressure)
- Rapid spread of inflammation through pulp with pain and can lead to necrosis

Chronic pulpitis: (subacute)

- A mild exacerbation of a chronic pulpitis

- Intermittent episodes
- Transient pressure elevation

- Clinical manifestation is similar to acute pulpitis
- Diffuse, more difficult to localise
- Pain is more moderate
- Patient tolerates the discomfort for months
- Frequently – caries (recurrent)
- Localisation of both types – facilitated in case of extension to periapex – contains both pressure and pain receptors
- Can be felt on percussion

Pain may be felt in remote areas (referred pain)

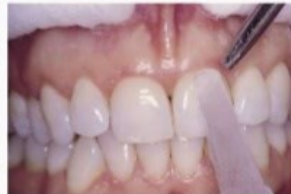Cold Test

Apply **ice** on the cervical third of the tooth where enamel is thin.

Normal Pulp: response, last for 1-3 seconds

Pulpitis: response, last for minutes

Necrotic pulp: No response



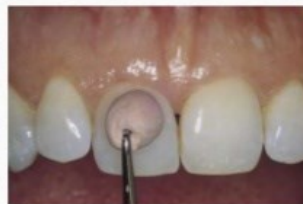Heat Test

Heat **Gutta-percha** and place it on cervical third of the tooth where enamel is thinnest.

Normal Pulp: response, last for 1-3 seconds

Pulpitis: response, last for minutes

Necrotic pulp: No response



PAPILLITIS:

Inflammation of the interdental papilla (located between teeth)

- caused by interproximal food impaction ²

-Papilla is red or edema can occur and lead to bleeding upon probing

- is not normally associated with pulpitis

- tooth is painful upon percussion perpendicularly rather than tapping it on long axis of tooth (like we do when checking for differential diagnosis in pulpitis)

PERIODONTAL ABSCESS

Localised collection of pus within the tissues of the periodontium³

The periodontal abscess is an acute destructive process in the periodontium resulting in localized collections of pus communicating with the oral cavity through the gingival sulcus or other periodontal sites and not arising from the tooth pulp

(prevalent group of bacteria: P. gingivalis, P. intermedia, B. forsythus, F. nucleatum and P. micros.)

- Usually associated with vital teeth
- Abscess forms normally on the sides of the root rather than apically
- Starts in the deeper periodontal pockets

- ACUTE periodontitis can lead to formation of acute periapical abscess
 - Symptomatic (responds to percussion and palpation)
 - Acutely painful response to biting pressure or percussion
 - May or may not respond to pulp vitality tests
 - Apical radiolucency and widened periodontal ligament space on Radiograph
 - Swelling intraorally and can be present on the facial tissues adjacent
 - Cervical and submandibular lymph nodes will exhibit tenderness to palpation ⁴

- CHRONIC periodontitis can lead to formation of granuloma (not a true cyst)

This granuloma can lead to abscess formation also if there is any acute exudate formation (pus)

- This type normally forms around teeth with non-vital pulp (damaged by caries or trauma)
- Asymptomatic – not sensitive generally to biting pressure but may feel different to patient on percussion / apical Radiolucency on Radiograph
- Will respond to pulp vitality test
- It can exhibit intermittent drainage through an associated sinus tract (parulis) or fistula
- When pus forms the pressure increases -> Tries to find the pathway of least resistance and spontaneously drains by forming a tract , relieving the pain
- Mild painful symptoms when stoma is blocked ⁴
- Patient feels as though the tooth is coming out
- They can localise the pain more especially upon biting , this comes as a sharp pain

1 - <https://aap.onlinelibrary.wiley.com/doi/pdf/10.1902/jop.2000.71.5-S.863>

2 - BERMAN, LOUIS H.. HARGREAVES, KENNETH M. *COHEN'S PATHWAYS OF THE PULP*. ELSEVIER - HEALTH SCIENCE, 2020.

3 - <https://www.ncbi.nlm.nih.gov/pubmed/15495540>

4 - KUKLETOVÁ, Prof. MUDR. M. "Histology and Physiology of the Dental Pulp Inflammation." 18 Feb. 2020, BRNO, CZECH REPUBLIC .

11. Necrosis and gangraena of dental pulp, their reasons, symptoms and principles of the treatment. (Aiike N.)

Pulp necrosis is a clinical diagnostic category indicating the death of cells and tissues in the pulp chamber of a tooth with or without bacterial invasion. It is often the end result of many cases of dental trauma, caries and irreversible pulpitis.¹ **do not mix necrosis and other diagnosis when the teeth are non vital. This question must be focused on necrosis and gangraena only.**

In the initial stage of the infection, the pulp chamber is partially necrosed for a period of time and if left untreated, the area of cell death expands until the entire pulp necroses. The most common clinical signs present in a tooth with a necrosed pulp would be a grey discoloration of the crown and/or periapical radiolucency. This altered translucency in the tooth is due to disruption and cutting off of the apical neurovascular blood supply.¹

Complications of a necrotic pulp include acute apical periodontitis, dental abscess or radicular cyst and discolouration of the tooth.¹

Causes¹

- Dental Caries
- Dental Trauma
- Dental Treatment
- Pulpitis
- Infection

Dental Caries

The influx of bacteria and growth of a carious lesion (if gross and left untreated) inevitably leads to the centre of the tooth – the pulp chamber. Once this tissue damaging process reaches the pulp it results in irreversible changes – necrosis and pulpal infection.

Dental Trauma

When a tooth is displaced from its normal position as a result of dental trauma, it can result in pulp necrosis due to the apical blood supply being compromised. This might be due to displacement of the tooth through avulsion or luxation. Furthermore, if the tooth is severely damaged, it could lead to inflammation of the apical periodontal ligament, and subsequently pulp necrosis.

Dental Treatment

Pulpal necrosis can also occur as a result of dental treatments such as iatrogenic damage due to interfering crown preparation – this may be due to excessive thermal insult and close

proximity to the pulp during tooth preparation – or rapid orthodontic work causing excessive force.

Irreversible Pulpitis

In irreversible pulpitis where the inflammation of pulpal tissues are not reversible, pulpal blood supply will become compromised and therefore necrosis of pulpal tissues will occur.

Symptoms:¹

Pulp necrosis may or may not arise with symptoms.

Signs and symptoms of pulpal necrosis include:

Pain

The pain associated with pulp necrosis is often described as spontaneous. Pain occurs on hot temperatures, and cold temperatures are said to soothe this pain. In some cases, the pain presents as a persistent pain as this is due to necrosis of the apical nerves being the last part of the pulp to necrose. **There cannot be pain when necrosis. !!!!**

Crown discoloration

In some cases of pulp necrosis there is a yellow, grey or brown crown discolouration. Dark coronal discoloration is believed to be an early sign of pulp degeneration. **When pure necrosis, we can see less translucency, discoloration is moetylly in teeth with gangraena.**

Internal root resorption

Internal root resorption may be an indication of pulpal necrosis though it is not possible to diagnose accurately with radiographic presentation of this alone. This is because the pulp tissue apical to the resorptive lesion will still be vital to allow active resorption to take place, it provides the clastic cells with nutrients via a viable blood supply. **This is not necrosis, this is a form of chronic pulpitis !!!!**

Diagnosis:

There are a plethora of ways to diagnose pulp necrosis in a tooth. The diagnosis of pulp necrosis can be based on the following observations: negative vitality, a periapical radiolucency, a grey tooth discoloration and even peri-apical lesions. This altered translucency in the tooth is due to disruption and cutting off of the apical neurovascular blood supply.¹ **non vital teeth is not the same as necrosis! Non vital teeth: necrosis, gangraena, periodontitis.**

Thermal Tests I

Thermal testing is a common and traditional way used to detect pulp necrosis. These tests can exist in the form of a cold or hot test, which aims to stimulate nerves in the pulp by the flow of dentine liquid at changes in temperature. The liquid flow leads to movement of the odontoblast processes and mechanical stimulation of pulpal nerves.

Pulse Oximeter Test I

The pulse oximeter test is a more accurate way to test for necrotic pulps as it primarily tests for vascular health of the pulp as compared to its nervous response. This method involves taking measurements of blood oxygen saturation levels, making it non-invasive and an objective way to record patient response regarding pulpal diagnosis. In a study conducted in primary and immature permanent teeth, results clearly reflected that pulse oximetry can readily differentiate between vital and non-vital, necrosed teeth.

Treatment:²

The most basic treatment for teeth with pulpal necrosis is root canal treatment. This involves the use of biologically accepted mechanical and chemical treatment of the root system, followed by the placement of a root filling, allowing healing of the periradicular tissues to occur.

If tooth is discoloured yellowish discoloration can then be improved with internal bleaching. Or veneers or full coverage crowns can be done for more esthetic treatment .

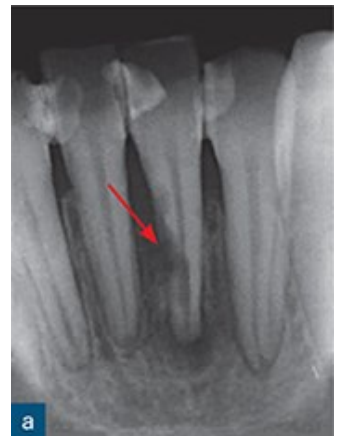In severe case is **tooth replacement**. Depending on the severity of pulp necrosis, your dentist may remove the entire tooth. You can choose from a number of tooth replacement options depending on your budget and preferences.

References:

1. "Pulp Necrosis." *Wikipedia, Wikimedia Foundation*, 4 Mar. 2020, en.wikipedia.org/wiki/Pulp_necrosis.
2. Cherney, Kristeen. "Pulp Necrosis: Symptoms, Tests, Causes, Risks, and Treatments." *Healthline, Healthline Media*, 16 Sept. 2018, www.healthline.com/health/pulp-necrosis#treatment.

12. Internal and external resorption – reasons, principles of treatment(Luka Ž.)

Dental resorption is the loss of dental hard tissues as a result of clastic (osteoclasts, odontoclasts) activities. It may occur as a physiologic or pathologic phenomenon. Root resorption in the primary dentition is a normal physiologic process except when the resorption occurs prematurely. Unlike bone, which undergoes continuous physiologic remodeling throughout life, root resorption of permanent teeth does not occur naturally and is inflammatory in nature. Thus, root resorption in the permanent dentition is a pathologic event and if left untreated, it may result in premature loss of the affected teeth.



Root resorption may be broadly classified into two types **external** and **internal**.

External inflammatory resorption (EIR) affects the surface of the root and is a relatively frequent sequel to dental luxation and avulsion injuries. It is a progressive condition with a potentially precipitous onset, and it is capable of advancing rapidly, such that an entire root surface may be resorbed within a few months if the tooth is left untreated. It also affects teeth diagnosed with chronic periapical periodontitis.

Clinical treatment of EIR is based on effective removal of the causal agent; namely, infected necrotic pulpal tissue in the root canal space. Treatment should be carried out as soon as the resorptive process has been diagnosed. The earlier EIR is diagnosed and treated, the better the prognosis is for the affected tooth. The diagnosis of EIR in clinical situations is based solely on the radiographic demonstration of the process. Traumatic dental injuries (e.g.,

intrusion, lateral luxation and avulsion) often result in contusion injuries to the periodontal ligament (PDL).

The **pathogenesis** of EIR can be explained as follows. Contusion injuries to the PDL, after a traumatic injury involving the periodontal structures, initiate wound healing, during which osteoclasts and macrophages are attracted to the site of the injury to remove the damaged tissue. The osteoclastic activity then slowly reduces the thickness of the dental tissue by its action.

Clinical Features

The tooth may look normal, but it will not respond positively to vitality testing. In advanced cases, signs of pulpal and/or periapical periodontitis may be present (e.g., discolored tooth, sinus present, and/or tenderness to percussion and/or palpation).

EIR is characterized radiographically by radiolucent, concave excavations along the root surface, with corresponding and associated radiolucency in the adjacent alveolar bone. EIR can have a rapid onset and aggressive progression, such that complete resorption of an entire root can occur within 3 months.

Clinical treatment of EIR is based on effective removal of the causal agent, the infected necrotic pulpal tissue in the root canal space. This arrests the resorption process and creates an environment conducive to hard tissue repair of the damaged root surface.

The earlier the resorption is diagnosed and treated, the better the prognosis is for the affected tooth. Failure to diagnose and treat the condition may result in tooth loss. Long term dressing of the root canal with calcium hydroxide may be beneficial in the treatment of established EIR. In many cases the EIR is extensive, rendering the tooth unsalvageable and requiring extraction.

Healing of EIR is characterized radiographically by cessation of the resorption process, resolution of the radiolucency in the adjacent bone, and reestablishment of the PDL space.

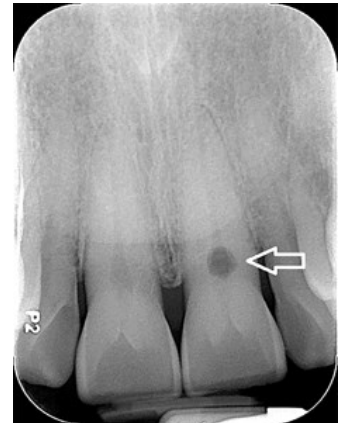Please add also the resorption with osseous replacement.

External cervical resorption (ECR) is a form of root resorption that originates on the external root surface but may invade root dentin in any direction. ECR generally develops immediately apical to the epithelial attachment of the tooth. In healthy teeth with a normal periodontal attachment, this is in the tooth's cervical region. The clinical features of ECR are variable.

The process is very often asymptomatic, especially in the earlier stages, and absence of clinical signs and symptoms is very common. The diagnosis is commonly made as a result of a chance radiographic finding.

A pink or red discoloration (fibrovascular granulation tissue occupying the resorptive defect) may develop at the cervical region of the tooth.

The **radiographic appearance** of ECR depends on the location, the extent of invasion. Although lesions with irregular margins are more common, some ECR defects may have smooth and/or well-defined margins. The radiographic features of ECR are very similar to those of internal root resorption.

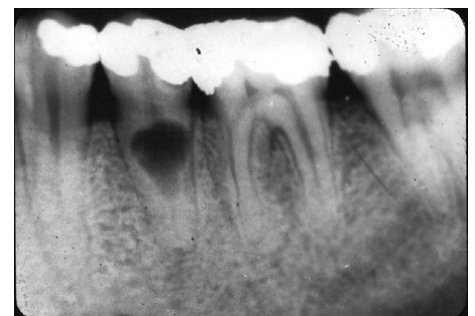


The fundamental **treatment** objectives in ECR are to excavate the resorptive defect, halt the resorptive process, restore the hard tissue defect with an aesthetic filling material, and prevent and monitor the tooth for recurrence. Endodontic treatment of the affected tooth is necessary when the resorptive process has perforated the root canal wall.

Internal root resorption (IRR) is a form of root resorption that originates in and affects the root canal wall. Various etiologic factors have been proposed including trauma, caries and periodontal infections, excessive heat generated during restorative procedures on vital teeth, calcium hydroxide procedures, vital root resections, anachoresis, orthodontic treatment, cracked teeth.

Bacteria may enter the pulp canal through dentinal tubules, carious cavities, cracks, fractures, and lateral canals.

In the absence of a bacterial stimulus, the resorption is transient and may not advance to the stage that can be diagnosed clinically and radiographically. If left untreated, internal resorption may continue until the inflamed connective tissue degenerates, advancing the lesion in an apical direction.



Ultimately, if left untreated, the pulp tissue apical to the resorptive lesion undergoes necrosis and the bacteria infect the entire root canal system, resulting in apical periodontitis.

The **clinical features** of IRR largely depend on the histologic status of the affected pulp and the extent of the hard tissue destruction caused by the resorptive process. Bacterial contamination of vital pulpal tissue may cause an acute inflammatory response, leading to clinical symptoms of pulpitis. With the onset of pulpal necrosis and an established bacterial colonization of the root canal space, clinical signs and symptoms associated with acute or chronic apical periodontitis may develop.

Extensive resorption of the coronal pulp may result in a pink or red discoloration visible through the crown of the affected tooth. This is caused by granulomatous tissue extending into and occupying the resorptive defect.

The diagnosis of any type of root resorption depends on **radiographic demonstration** of its presence.

Once a diagnosis of IRR has been made, the extent of the hard tissue destruction must be assessed, and a clinical decision must be made about the prognosis of the affected tooth. If the affected tooth is salvageable and has a reasonable prognosis, root canal treatment is necessary. As with any infected tooth, the main purpose of the root canal treatment is to remove the intraradicular bacteria and disinfect the root canal space.

The complex anatomic and morphologic features of root canal systems provide unique recesses that may harbor microorganisms in infected teeth. Endodontic instruments and passively delivered irrigants fail to penetrate into these spaces. The use of ultrasonic instruments to aid the penetration of endodontic irrigants has been shown to improve the removal of organic debris and biofilms from the root canal space. As such, an intracanal antibacterial medicament should be used to further reduce the microbial load and improve the disinfection of the root canal space. Calcium hydroxide is an antibacterial, endodontic medicament that has been shown to eradicate bacteria persisting in the root canal space after root canal treatment

Reference

Patel, Shanon, et al. "Root Resorption." *Cohen's Pathways of the Pulp*, by Kenneth M. Hargreaves et al., Elsevier, 2016, pp. 660–683.

13. Calcium hydroxide and medicaments in endodontics. (M.ahmad)

Calcium Hydroxide is an odorless white powder.

Purpose

Temporary canal filling¹: Used with vital pulp therapy, Pure calcium hydroxide powder is mixed with sterile saline to a powdery consistency. The calcium hydroxide is packed against the apical soft tissue with a plugger to initiate hard tissue formation. This step is followed by backfilling with calcium hydroxide to completely fill the canal. The temporary restoration is placed directly onto the calcium hydroxide in the access cavity. Calcium hydroxide should be removed from the walls of the access cavity before the temporary restoration is placed because calcium hydroxide is soluble and washes out when it comes into contact with saliva, leaving a defective temporary restoration.

As disinfectant¹: Mostly for non-vital teeth. A creamy mix of calcium hydroxide spun into the canal using lentulo. For short term use

Calcium hydroxide sealers¹: It contains catalyst, zinc stearate, titanium dioxide and eugenol. It seals the root canal filling and it is easy manipulation but not suitable for single cone technique (why?)

For Apexification¹: Root end closure that involves cleaning and filling the canal with a Ca(OH)₂, which was replaced at intervals over several months to stimulate the formation of an apical calcified barrier.

Direct Pulp Capping¹: Used as capping material

Effect

1. Short term (1-2 weeks)²

- It is antimicrobial so kills the bacteria in the canal
- Stops the bleeding
- It participates in mineralized tissue formation
- Capacity to dissolve necrotic material.
- It stimulates mineralization because of its dissociation into hydroxyl and calcium ions.

2. Middle term (2-3 months)²

- It increases the healing potential of periapical tissue so used to treat chronic form of apical periodontitis (calcium hydroxide sealer)
- Apexification.
- Produces an inflammatory response that stimulates dentinal bridge formation

3. Long term(more than 3 months)²

- Prevention of resorption:
Calcium hydroxide also has the capacity to penetrate into the dentinal tubules increasing the pH on the root periphery. This property contributes to the regression of resorption processes because the alkalinization of regions with acidic pH creates unfavorable conditions to the action of osteoclast.

4. **Other medicaments¹**

Chlorohexidine: It has good antimicrobial action both when used as an irrigant and as a medicament used in conjunction with calcium hydroxide. On its own it is unable to dissolve necrotic tissue, and are less effective against gram-negative bacteria than gram-positive bacteria

Sodium hypochlorite: commonly known as *bleach*, is frequently used as a disinfectant or a bleaching agent. It is the medicament of choice during root canal treatments following its efficacy against pathogenic organisms and pulp digestion. But it is toxic, has unpleasant odor and is ineffective in removing smear layer

EDTA: it dissolves inorganic material and smear layer so helps with root canal cleaning but it has no antimicrobial effect

Reference:

1. Hargreaves, Kenneth M., et al. "Chapter 1". *Cohen's Pathways of the Pulp*. Elsevier, 2016, pp. 17-18
2. Cohenca, Nestor. "Chapter 13". *Disinfection of Root Canal Systems: the Treatment of Apical Periodontitis*. Wiley Blackwell, 2014, pp.252-253

14. Diagnosis in endodontics, case selection and treatment planning

(Garima K.)

Common medical findings that may influence endodontic treatment planning

- Pregnancy
- Cardiovascular disease
- Cancer
- HIV and acquired immunodeficiency syndrome
- End stage renal disease
- Dialysis
- Diabetes
- Prosthetic implants
- Patients with anticoagulation therapy
- Behavioral and psychiatric disorders

Pregnancy is not a contraindication to endodontics but it does modify treatment planning. Consult a physician if you are not sure.

- Radiography If possible NO Lead apron and thyroid collar
- Drugs Antibiotics (penicilin, cephalosporin, clarithromycin – all with caution !)
- Analgetics (paracetamol – with caution!)
- Local anaesthetics (first if possible no in emergency with caution yes, second trimesters YES, third trimester with caution – a risk of contractions).
- Cardiovascular disease - Vulnerability to emotional and physical or stress during dental treatment including endodontics. - Consultation with the patient's physician is mandatory before the initiation of endodontic treatment if within 6 month after the attack.

- Patients who have had myocardial infarction within 6 months should not have elective dental care. Medication can potentially interact with vasoconstrictors in LA. Increased susceptibility to repeat the heart attack.
- Risk of vasoconstrictors

No administration:

- Patients with non-stable angina pectoris
- Uncontrolled hypertension
- Refractory arrhythmia
- Recent myocardial infarction (less than 6 months)
- Recent stroke (less than 6 months)
- Recent coronary bypass graft (less than 3 months)
- Uncontrolled congestive heart failure
- Uncontrolled hyperthyroidism

Risk of bacterial endocarditis

Caused by a bacteremia – can be associated with endodontic treatment.

It is potentially fatal.

- Patients who have a history
- of murmur or mitral valve prolapse with regurgitation
- Rheumatic fever
- Congenital heart defect
- Artificial heart valves

Risk of bacterial endocarditis must be minimized using ANTIBIOTIC PROPHYLAXIS

Short-term administration of antibiotic in high dosage – according to recent recommendation.

Cancer

- Risk of metastasis in jaws. Careful examination, OPG.
- Cancer in orofacial region - all potential foci must be removed, no endodontic treatment during and after radiotherapy. Risk of radionecrosis – radioosteomyelitis.
- Radiotherapy - decreasing number of osteoblasts, osteocytes, endothelial cells and blood flow.
- Routine dental procedures can be done if granulocyte counts are greater than 2000/mm³ and platelet count greater than

50,000/mm³

Consultation with responsible specialist.

HIV and acquired immunodeficiency syndrome

- HIV patients do not have an increased risk of postoperative pain or inflammation. Precautions of infection of dental team.

Generally – number of CD4 lymphocytes is important (less than 200/mm³ higher risk of opportunistic infections).

Renal disease and dialysis

- End stage renal disease – best way hospital setting.
- Dialysis – consultation with the specialist
- (some drugs are eliminated by dialysis, the treatment is best scheduled a day after dialysis since on the day of dialysis patients are generally fatigued and have a bleeding tendency)

Diabetes

- Patients with well medically controlled diabetes and free of serious complications (renal disease, hypertension, coronary atherosclerotic disease) is a candidate for endodontic treatment.
- Non insulin patient may require insulin
- Insulin patient may require higher dose of insulin
- Source of glucose should be available
- Appointments should be scheduled with consideration given to the patient's normal meal and insulin schedule. Especially when surgical endodontics is indicated – consultation with specialist is useful.

Prosthetic implant

- Can require antibiotics prophylaxis depending on time after implantation and other patient's diseases.

Consultation with patient's physician. Endodontic is an unlikely cause of bacteremia in comparison with extractions, scaling, periodontal surgery.

Patients with anticoagulation therapy

- Risk of bleeding from dental pulp and root canal
- Risk of hematoma when nerve blocking anesthesia is used.
- Treatment depending on laboratory tests, consultation with specialist.

Behavioral and psychiatric disorders

- Patient's ability of cooperation and drug interaction (local anesthetics)

Consultation of physician useful and sometime necessary.

Regional factors that influence endodontic case selection

- Position of the tooth and its importance for function The tooth must be valuable for the function (dystopic teeth, third molars etc..)

Local factors that may influence endodontic case selection

- Periodontal consideration (poor periodontal prognosis – no endodontic treatment)
- Surgical consideration (some lesions are nonodontogenic)
- Restorative consideration (root intraosseous caries, poor crown/root ratio, extensive periodontal defects)
- Others (calcification, obliteration, root resorption, dilaceration etc.)
- Biological width - Distance between free gingiva and alveolar bone

16. Access to the pulp chamber – instruments, step by step procedure, location and form of endodontic cavities. (Alan O.)

The first and most important phase in any nonsurgical root canal procedures is access to the root canal system. The aims of access cavity preparation are to (1) remove all caries when present, (2) conserve sound tooth structure, (3) unroof the pulp chamber completely, (4) remove all coronal pulp tissue (vital or necrotic), (5) locate all root canal orifices, and (6) achieve straight- or direct-line access to the apical foramen or to the initial curvature of the canal.

STEPS

1. Visualization of position of the pulp space is important during access to cavity. This is done by periapical radiograph and examination of the tooth anatomy at coronal, cervical and root levels. This examination is helpful for estimate position of pulp chamber, degree of calcification, number of roots and canals and canal length. All this information together gives us an understanding for the direction of the bur to access the cavity.
2. before entering the root canal system, we must remove all defective restorations and caries. This is essential to find hidden caries or fractures and the ability to determine the restorability of tooth is increased. Also, with an open preparation, canals are much easier to locate. It's also important to remove unsupported hard dental tissues to avoid tooth fracture during or between procedures.
3. Sufficient tooth structure must be removed to allow instrument to be placed into each canal orifice without any resistance from canal walls, especially when the canals are curved. Therefore, access of root canal depends not only on the orifice location, but also on the position and curvature of the entire canal. Failure to follow this guideline result in complications and treatment errors.

4. A proper access cavity generally has tapering walls, with its widest dimension at the occlusal surface. In such a preparation, occlusal forces do not push the temporary restoration into the cavity and disrupt the seal.

INSTRUMENTS

Good tactile awareness is essential to perform most phases of access preparation with a high-speed handpiece. In many cases, the use of a slow-speed handpiece is indicated, which is especially helpful in the careful excavation of caries located in the area of the anticipated access opening.

Numerous burs have been developed for access cavity preparation and every clinician have their own preferred type of burs. The most important thing is that access to cavity meets the previously steps than what type of burs are used in the process. Some of the more common access burs are:

1. Round carbide burs are used often in the preparation of access cavities. They are used to excavate caries and to create initial external outline shape. They also are useful for penetrating through the roof of the pulp chamber and for removing the roof.
2. Fissure carbide bur or a diamond bur with rounded cutting end are preferred by other clinicians. The advantage of the fissure carbide and diamond round-end burs is that they also can be used for some of the axial wall extensions of the access cavity preparation.
3. Batt's instrument which are fissure carbide or diamond burs but with noncutting ends are safer choices for axial wall extensions. They can be used to extend and favorably orient the axial walls of the pulp chamber.
4. Round diamond burs are needed when the access must be made through porcelain or metaloceramic restorations. Diamond burs are less traumatic to porcelain than carbide burs and are more likely to penetrate the porcelain without cracking or fracturing it. They should always be used with water spray to control heat buildup in porcelain restorations. After penetrating the porcelain with a diamond bur, a carbide bur, such as a transmetal bur is used for metal or dentin penetration because of this bur's greater cutting efficiency.
5. Extended shank round burs, such as the Mueller bur are indicated when receded pulp chamber and calcified orifice are identified, or to locate and identify the canal orifice.

ACCESS CAVITY PREPARATIONS

Anterior teeth

- Once caries and restorations have been removed as necessary to establish sound tooth margins, an external outline opening is cut on the lingual surface of anterior tooth. A round or a tapered fissure bur may be used to penetrate the enamel and slightly the dentine (ca 1mm). The outline form is similar to an ideal access shape for the particular tooth and is up to $\frac{3}{4}$ of final size of the access cavity. The bur is directed perpendicular to the lingual surface and the external outline opening is created.
- Penetration of the pulp chamber roof is done by the same bur with the angle rotated from perpendicular to the lingual/palatal surface to parallel to long access of the tooth. When the roof is penetrated, a drop into the chamber effect is felt.

- Once the pulp chamber has been penetrated, the remaining roof is removed by catching the end of a round bur under the lip of the dentin roof and cutting on the bur's withdrawal stroke. Because each tooth has a unique pulp chamber anatomy, working in this manner enables the internal pulp anatomy to dictate the external outline form of the access opening.
- Once the openings have been found and confirmed, the lingual shoulder is removed. Its removal improves straight line access and allows for intimate contact of files with canal walls. A rotatory orifice opener is used for flaring the opening and removal of lingual shoulder with minimal removal of dentin. Either safety-tip diamond or carbide bur or a Gates – Glidden bur can be used for this.
- After removal of the lingual shoulder and flaring of the orifice, straight-line access must be determined. Ideally, a small intracanal file can reach the apical foramen or the first point of canal curvature with no deflections.
- The final step in the preparation of an access cavity is to refine and smooth the cavosurface margins. Rough or irregular margins can contribute to coronal leakage through a permanent or temporary restoration

Posterior teeth

Preparation of access cavity on posterior teeth is similar to anterior teeth, but with some differences. Posterior teeth requiring root canal procedures typically have been heavily restored or the carious process was extensive. Such conditions, along with the complex pulp anatomy and position of posterior teeth in the oral cavity, can make the access process challenging.

- Removal of caries and existing restorations from a posterior tooth requiring a root canal procedure often results in the development of an acceptable access outline form. However, if the tooth is intact, the access starting location must be determined for an intact tooth. The pulp chamber of posterior teeth is positioned in the center of the tooth at the level of the CEJ.

In maxillary premolars the point of entry is in central groove between cusp tips. For mandibular first premolar the point of entry is halfway up the lingual incline of the buccal cusp on a line connecting the cusp and for mandibular second premolar the point of entry is on 1/3 of lingual incline.

To determine the starting location for molar access cavity preparations, the mesial-distal and apical-coronal boundary limitations for this outline must be determined. The mesial boundary for both the maxillary and mandibular molars is a line connecting the mesial cusp tips. Pulp chambers are rarely found mesial to this imaginary line. A good initial distal boundary for maxillary molars is the oblique ridge. For mandibular molars, the initial distal boundary is a line connecting the buccal and lingual grooves. For molars the correct starting location is on the central groove halfway between the mesial and distal boundaries.

- Penetration through the enamel into the dentin (approximately 1 mm) is achieved with a round bur or a tapered fissure bur. The bur is directed perpendicular to the occlusal table, and an initial outline shape is created at about half to three fourths its projected final size. The premolar shape is oval and widest in the buccolingual dimension. The molar shape is also oval initially; it is widest in a buccolingual dimension for

maxillary molars and in a mesiodistal direction for mandibular molars. The final outline shape for molars is approximately triangular (for three canals) or rhomboid (for four canals); however, the canal orifices dictate the position of the corners of these geometric shapes. Therefore, until the orifices have been located, the initial outline form should be left as roughly oval.

- Once initial penetration into the pulp chamber has been achieved, the angle of penetration changes from perpendicular to the occlusal table to an angle appropriate for penetration through the roof of the pulp chamber. In premolars the angle is parallel to the long axis of the root or roots, both in the mesiodistal and buccolingual directions. While in molars the penetration angle should be toward the largest canal because the pulp chamber space usually is largest just occlusal to the orifice of this canal. Therefore, in maxillary molars, the penetration angle is toward the palatal orifice, and in mandibular molars, it is toward the distal orifice.
- The bur of choice is used to remove the roof of the pulp chamber completely, including all pulp horns. The goal is to funnel the corners of the access cavity directly into the orifices, and a safety-tip diamond or carbide performs this task nicely. These burs are passed between the orifices along the axial walls to remove the roof, taper the internal walls, and create the desired external outline shape simultaneously.
- The multiple canals in posterior teeth plays an important role in determining the final extension of external outline form. Ideally the openings are located at the corners of the final preparation to enable all of the root canal procedures.
- In posterior teeth the internal barriers to an ideal access opening are the cervical dentin ledges or bulges and the natural coronal canal constriction.⁸⁴ The cervical bulges are shelves of dentin that frequently overhang orifices in posterior teeth, restricting access into root canals and accentuating existing. These bulges can be removed safely with burs or ultrasonic instruments. The removal instruments should be placed at the orifice level, and light pressure should be used to cut laterally toward the dentin bulge to remove the overhanging ledge. After removal of the ledge, the orifice and constricted coronal portion of the canal can be flared with Gates-Glidden burs, or large, tapered rotary instruments. As the orifice is enlarged, it should be tapered and blended into the axial wall so that an explorer can slide down the corner of the external outline form, down the axial wall, and into the orifice without encountering any obstructions.

Reference

Gutmann, James J, and Bing Fann Berggreen. "Chapter 05." *Cohen's Pathways of the Pulp*, 11th ed., Mosby, 2016, pp. 145–157.

17. Root canal shaping- instruments, techniques of instrumentation. (Maria L.)

Root canal shaping is one of the most important steps in the endodontic treatment. The major goals are the prevention of occurrence of periradicular disease and in cases where disease already exists healing of the infected tissues by:

- Removal of vital and necrotic content from the main root canal(s): complete debride the pulp from microorganisms, dentinal debris, endotoxins and pulp tissue.
- Creation of sufficient space for irrigation and medication.
- Preservation of the integrity and location of the apical canal anatomy: preparation must enlarge the canal while maintaining general shape (no extra root)
- Avoidance of iatrogenic damage to the canal system and root structure: once working length is determined instruments should be kept within proper confines, while preparation the environment should be wet
- Facilitation of canal filling.
- Avoidance of further irritation and/or infection of the periradicular tissues.
- Preservation of sound root dentine to allow longterm function of the tooth.

Herbert Schilder's Five Mechanical Objectives:

- Develop a continuously tapering conical form in the root canal preparation
- Make the canal narrower apically, with the narrowest cross-sectional diameter at its terminus.
- Make the preparation in multiple planes.
- Never transport the foramen
- Keep the apical foramen as small as is practical

Techniques of root canal preparation include manual preparation, automated root canal preparation, sonic and ultrasonic preparation, use of laser systems, and NITs.

Instruments:

We have two main one instruments:

Reamers (penetration): K- reamer, triangle/square shape, symbol: triange, 20 degrees

- motion: penetration-clockwise rotation, application-contraclockwise
- for penetration to the canal after drilling
- cylindrical or conical shape, made of high- carbon steel
- used for enlarging the holes
- provided with flutes or grooves (cutting is done between those)
- two classes: machine/chucking reamers or hand reamers

Files (shaping)

- C-file:
 - Stiffer than K-file
 - For calcified, curved and canals
- K-file:
 - trianl or square wire
 - symbol: square
 - Filing and rotation
 - 45° – 90°
- K-flexofile, flexicut, flex-R
 - Triangle wire
 - Higher flexibility
 - It has non-cutting tip and its first blades are blunt
- K- flex
 - Symbol: rhombus
 - Two blades in action
 - Enough space for dentin chips
 - Flexibility, effifacy
- H-file (Hedstroem file)
 - Symbol: Ring
 - Pull motions only
 - Risk of breakage

She will send it separately I do not have it until now.

19. Irrigation of the root canal. (Mariyam D.)

Irrigants are solutions used to clean/ rinse out the root canals of teeth

We have chemical or natural agents

The Main purpose of irrigants are to remove

1. The smear layer
2. Kill the bacteria present (antimicrobial activity)
3. For the dissolving of dental shavings (to prevent blockage of the canal apex)
4. For lubrication of the canal and flushing out of debris attached to wall.

Properties of an irrigant should include=²

- Removal of damaged or necrotic pulp tissue
- Removal of smear layer formed by instrumentation
- Dissolving the biofilm
- Dentin debris removal
- Removal of microorganisms and their products (by trying inactivate their exotoxins)
- Mechanical detachment of the dental shavings
- Low surface tension (to move into inaccessible places in the canal)
- Low toxicity
- Non-causative (unable to cause anaphylactic shock)
- Lubrication of canal (less likely to break instruments in lubricated canal)

COMMON IRRIGANTS THAT ARE USED INCLUDE NaOCL , EDTA , CITRIC ACID , SALINE sol.

SALINE (0.9% conc. Can be used)²

Functions:

1. Debridement and lubrication (Allowing easier gliding of the instruments)
2. Flushing action
3. Mild in action – less caustic
4. No adverse reaction if extruded periapically as it has similar osmotic pressure to that of blood

ITS DISADVANTAGES :

- little antimicrobial activity (does not remove biofilm as effectively as sodium hypochlorite would)
- Does not remove smear layer
- Action is Too mild to remove all debris / clean canal

SODIUM HYPOCHLORITE (2.5 – 4 % conc. Normally used) 6%

Functions:

1. Wide spectrum, sporicidal, tissue dissolving properties
2. High antimicrobial activity
3. Removes smear layer but NOT INORGANIC PARTS (must use chelating solution for that)
4. Antimicrobial effectiveness of NaOCL is directly related to its contact time with the canal
5. When used with EDTA after it can remove all of the smear layer
6. Lubricates canals effectively
7. Dissolves organic tissue

Dissolving of the organic tissue is important when removing debris from the canal , as the organic tissue can form a coagulate with the intracanal medicaments that can be placed after prep of root canal . This coagulum can then occlude the canal preventing further penetration of the medicaments.

ITS DISADVANTAGES INCLUDE :

- Toxic – can cause hemolysis , epithelial ulceration and necrosis-> hence is painful for the patient
- Only removes organic part of smear layer (inorganic part still present)
- Unpleasant odor
- If sodium hypochlorite gets extruded into periapical tissues can cause excruciating pain , periapical bleeding and swelling due to its tissue dissolving capability -> can lead to tissue necrosis

Extrusion can happen if injection beyond apical foramen -> when apical constriction has been destroyed during root canal prep or resorption or can occur in teeth with wide apical foramen

EDTA (used with other irrigation solutions) – 15-17%²

Ethyelene Diamine Tetra Acetic Acid

- It Is a decalcifying solution
- Used for cleaning and widening the canal
- Is Non-toxic / has ow toxicity
- Chelated with metallic ions so can be used to remove the inorganic portion of the smear layer
- Forms stable bonds with calcium and dissolves dentin
- Contributes to elimination of bacteria in the root canal
- Lubrication during usage of rotary root canal prep

Liquid forms =

1. REDTA
2. EDTAT
3. EDTAC
4. LARGAL ULTRA (15% , HAS CENTIMIDE WHICH HAS BACTERICIDAL EFFECT AND DECREASES SURFACE TENSION ALLOWING FOR EFFECTIVE DENTIN PENETRATION)

NOTE= A chelator is necessary as it prevents the tissue from re-adhering to itself and blocking the canals

Using EDTA and Sodium hypochlorite together has disadvantages as EDTA causes NaOCL to lose its tissue dissolving capacity and virtually no chlorine is available thus decreasing its antimicrobial effect.

MTAD and TETRACLEAN¹

- MTAD- Is a Mixture of Tetracyclin (doxycycline), citric acid and detergent
 1. It can remove the Smear layer
 2. Has effective Antibacterial properties
- TETRACLEAN- Is a mixture of citric acid, doxycycline and polypropylene glycol as detergent

Cleans dentinal tubules better than EDTA in the removal of debris and removing the smear layer in the apical third of root canals

CITRIC ACID²

Ranges from 1- 50% but 10% sol. Is the most common

- Irrigant
- Removes smear layer more effectively from the apical root end cavities than ultrasound
- Demineralizes dentin
- Non-toxic and cheap

HYDROGEN PEROXIDE (3-5%)¹

- Oxidising agent
- It is odorless
- Clear
- Effervescence action capable of removing loose debris from inside canal
- Release of nascent oxygen works against removal of anaerobic bacteria
Antimicrobial spectrum is not optimal, there is risk of emphysema.

DISADVANTAGE

- Tissue emphysema if it passes to the periapical tissue
- Post-operative pain
- CANNOT USE ALONE OR AS FINAL IRRIGANT
- Does not remove smear layer effectively

CALCIUM HYDROXIDE²

Calcium hydroxide [Ca(OH)₂] is used frequently as an endodontic intracanal medication because of its biological properties, antimicrobial activity, and capacity to inactivate bacterial endotoxins

BRAND= CALCIMOL

1. Light curing
 2. Radio-opaque hydroxide
 3. USES= Linings and indirect pulp capping
 4. Acid resistant
- Strong base
 - Destroys remaining bacteria by limiting space for multiplication
 - Acts as a physical barrier
 - Can use for open apex, root fracture, perio-endo lesion, root resorption
 - Antiseptic- high pH and leaching action on necrotic pulp tissues
 - Used in WEEPING CANAL (bleeding exudate cystic fluid)

After root canal treatment the canal still continues to fill with pus/ serous exudates and blood

Can be due to open apex, large cyst, perforation, pulp remnant

DRY THE CANAL, PLACE CALCIUM HYDROXIDE, AT NEXT APPOINTMENT THE CANAL CAN BE FOUND DRY AND READY FOR

OBTURATION (pH of periapical tissue is acidic and addition of calcium hydroxide turns it more basic)

ADVANTAGE:

- Stimulates healing
- Encourages mineralization

DISADVANTAGE :

- Difficult to remove from canal
- Decreases setting time of zinc-oxide eugenol based cements
- it may interfere with the seal of the root filling and compromise the quality of treatment

INSTRUMENTS

Irrigation to clean and disinfect a canal is an important part of a root canal, and the different endodontic irrigation instruments accomplish this task in different ways. These instruments and systems are used following the shaping of the canals and prior to obturation

Irrigants can be delivered using endodontic irrigation syringe or ultrasonic devices

Syringe and needle- the needle has a gauge which has different sizes from 22 to finer 30

Irrigation of the apical third requires the needle to be in close proximity for adequate flushing of the canal ³

Irrigation of larger canals require the tip of the syringe to be placed in the canal until resistance is felt, the tip is withdrawn a few millimeters and the solution is expressed very slowly until the chamber is full ³

The solution must be introduced slowly and the needle must never be wedged in the canal

Different designs of needles=³

1. Open ended blunt needle
2. Beveled needle
3. Blunt ended side venting needle
4. Notched tip
5. Perforated needle

Stropko NI-TI irrigation needles (flexible and resistant to clogging)

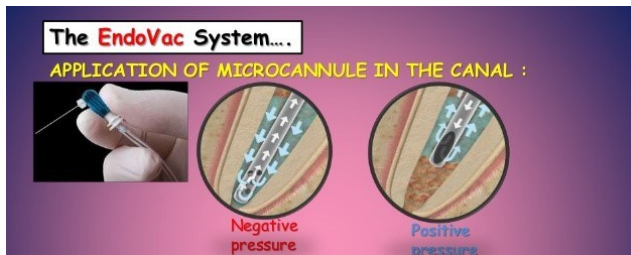Monojet endodontic needles (longer needles, blunted, open ended , able to insert the irrigant into the full canal)

MAX-1-PROBE (produce upwards flushing motion for complete canal irrigation , side port dispersal prevents solution and debris from being expressed through closed apex , rounded end reduces the risk of apical damage , close ended needle eliminates possible puncture of apical foramen)

EndoVac system- machine operated⁴

combined irrigation/evacuation system

1. Safer- less apical extrusion risk
2. Better debridement 1 mm from working length
3. Negative apical pressure irrigation system results in less post-operative pain
4. Pressure alteration device



Macro cannula can be used to wash the coronal portion of the canal and microcannula for the apical portion

The microcannula is stainless steel, laterally positioned and is used at the working length up to the apical part of the canal

Delivery/evacuation tip is attached to a syringe. The irrigant is delivered to the pulp chamber by a metal needle and any excess is immediately suctioned off through the plastic tubing surrounding the metal that is attached to the suction (vacuum pressure applied at the same time)

High-volume suction from the dental unit results in negative apical pressure and thus passively sucks the irrigant from the orifice to the apical part of the root canal, which is passively evacuated from the canal space.

Apical extrusion of the irrigant will probably be reduced

Activation of irrigation:

Hand

Hydrodynamic – the irrigant is delivered into the root canal using pressure

Sonic – activator – vibration in thousands HZ

Ultrasinic activation – special tips for ultrasound device see text below.

Lase activation.

Activation: vibration, heating and decomposition of NaOCl.

Vacuum suction -Endovac.

THERE ARE DIFF. TYPES OF DELIVERY METHODS OF THE IRRIGANT INTO THE CANAL, THESE INCLUDE :³

1. PASSIVE ULTRASONIC = Delivering using syringe is passive where there is no operating of instruments simultaneously (no cutting occurs and no instrumentation occurs)

Irrigant of choice is flooded into the chamber and the ultrasonic file is moved passively up and down the canal , irrigant is constantly freshened , improving effectivity

2. ULTRASONIC INSTRUMENTATION= this is continuous as it provides a continuous flow of an irrigant in the canal and prevents accumulation of debris in the canal. Also has better transfer of the irrigant into the canal.

Files are driven to oscillate at ultrasonic frequencies of about 25-30 kHz in a transverse vibration

1 <https://www.slideshare.net/marwa909055/endodontic-irrigating-solutions>

2 Garg, Nisha, and Amit Garg. *Textbook of Endodontics*. Jaypee Brothers Medical Publishers, 2019.

3 <https://www.slideshare.net/ankitpatel14473/root-canal-irrigants-and-devices>

4 BERMAN, LOUIS H.. HARGREAVES, KENNETH M. COHEN'S PATHWAYS OF THE PULP. ELSEVIER - HEALTH SCIENCE, 2020.

20. Root canal filling – materials (Abtin M.)

Root canal filling is the process of filling the root canals with bio active materials after trying your best to make the canal aseptic and dry.

Ideal root canal filling needs:

1. Easy mixing
2. Sufficient working time
3. Good seal
4. X- ray contrast
5. Easy removal
6. No shrinkage

7. Long term volume stability
8. No bacterial growing
9. No permeability for fluids
10. Biocompatibility
11. No staining

There are three classifications of root canal fillings:

- Solid
- Semi-solid
- Pastes

Gutta-percha which is a semi-solid filling (dried juice of taban tree) composition:

1. Gutta-percha 19% – 22%
2. Zinc oxide 59 - 79%
3. Heavy metal salts 1% - 7%
4. Wax or resin 1% - 4%

Resilon is a solid filling that is a thermoplastic synthetic polymer that is available in two forms points or injectable material composition:

- Polyester polymers
- Bioactive glass
- Radiopaque fillers (bismuthum oxychloride and barium sulphate)

Solid silver or titanium cones are contradicted as they don't have good seal and are prone to corrosion.

Sealers are chemically curing plastic materials and have to follow three requirements:

1. Good adhesion to root canal walls as well as solid cones
2. X- ray contrast
3. Biocompatibility

There are many sealers ex.:

1. Zinc Oxide-Eugenol
2. Chloropercha
3. Calcium hydroxide
4. Resins
5. Glass ionomer
6. Silicone

Instruments that are used to fill the root canals are:

- Lentulo to put in the paste filler
- Finger spreader used to condense gutta-percha into canal
- A plugger to remove excess gutta-percha and to condense it

Calcium hydroxide is a very good sealer with healing potential of the periapical tissue, has antibacterial effects and easy manipulation but is resorbable if it is not homogenous and contraindicated for the single cone technique.

Resin based sealers:

- Resilion: contains primer, sealer and synthetic polymer points. It is highly toxic.

- Epoxide (bismuth oxide, titanium oxide and hexamethylenetetramine powder with bisphenoldiglycidylether liquid): Advantages of this is long working time, hydrophilic, good adhesion to root canal walls, volume stability, no dissolution and it is antibacterial. Disadvantages are difficult to remove, stains and very toxic before setting. Contraindicated for single cone technique.
- Polyketone (Zinc oxide, Bismuth phosphate and Hexamethylenetetramine powder with Bisphenolglycidylether liquid) the advantages are good adhesion, no contraction and no dissolution while the disadvantages are high stickiness and not removable. Products: Diaket, Diaket A (3M ESPE)
- Methacrylate resins:
 1. Endo ReZ (Ultra dent) – UDMA:
For injection – single cone technique
 2. Epiphany (Pentron):
Bis- GMA, epoxy bis- GMA, hydrophilic bifunctional methacrylate's,
Calcium hydroxide, barium sulphate, barium glass silica.

Glass ionomer sealers (Aluminum silicate glass powder with polyacrylic acid liquid):

- Advantages are: Curing under wet conditions, chemical bonding to hard dental tissues, no staining.
- Disadvantages are: Short working time, difficult removal, porous.
- Different products: Ketac Endo (3M ESPE), Endion (VOCO).

Reference

Doc. MUDr. Roubalíková, Ph.D., Lenka. "Preclinical_endo_angl." 7 Mar. 2020, Brno, Czech Republic.

21. Root canal filling – preconditions for the filling, methods, instruments. (Garrick L.)

Preconditions of Filling

We must file the root canal to the appropriate size based on what tooth we are drilling. We should begin with a file that correctly fits the canal and then from there use files that slowly increase the size until we reach the optimal size. (I will ask her the theory behind why only 3 sizes) I'll add to this.

After filing the tooth we should clean it out with solutions that will clean the canal of

any debris and kill any bacteria. Common solutions used in the clinic are:

Sodium Hypochlorite (2-6%)

Chlorhexidine (.12-.2%)

ETDA (17%)

Once these solutions have been applied we must dry the tooth to prepare it for final filling. Most common way to dry the canals is by paper points. Sterilized, prefabricated points that are placed into the canals until dry. When using these we should still take into account the working length so we don't over press the point and cause any further damage to the apical area.

The patient should be free of any pain from that tooth once we are ready to fill.

Cold Filling Methods

After finishing canal shaping we need to seal the canal(s) with guttapercha. Guttapercha is a filling material used in endodontics to hermetically seal the canals after treatment. We have two categories of techniques, warm and cold.

Cold technique involves that the guttapercha points are not heated before being placed into the canal. The two ways of cold technique are, *single cone* and *lateral compaction*.

Single cone technique is when we use the same guttapercha cone size as the last ISO file size we used. If we finished filing with the 35, we would use a 35 size guttapercha cone. Before placement of the cone we must coat the cone with sealer. Sealers are important for the adhesion to the canal walls, and help give us x-ray contrast when taking x-rays of the tooth. But their main importance is to fill the spaces between the cones to give a tight filling. Common sealers are zinc oxide-eugenol, calcium hydroxide, resins and glass ionomers. This technique is good because it is easy, fast and gives us good control of the working length. When placing the cone we first must deliver the paste/sealer into the canal. This can be done by use of a lentulo, which is a small spiral burr we used at low speed to deliver paste on all sides of the canal. After this we can place the cone inside of the canal. After placement of the cone we seal the cone at the beginning of the canal.

Lateral compaction is the other common cold technique used in root canal fillings. This method involves choosing a master cone then using a spreader to laterally push the master cone to the side and create more room for other cones. Like before the lentulo should be used to apply sealer onto the canal walls. After we can place the master cone into the canal and by use of a hand spreader we can create a small gap. We then choose a guttapercha cone, *accessory cone*, 10 sizes smaller than the master cone and place this into the canal. We repeat the process with different size spreaders and cones until the canal is sealed. The cones are removed with heat and the cones inside the canal are compacted down into the canal.

Warm Filling Techniques

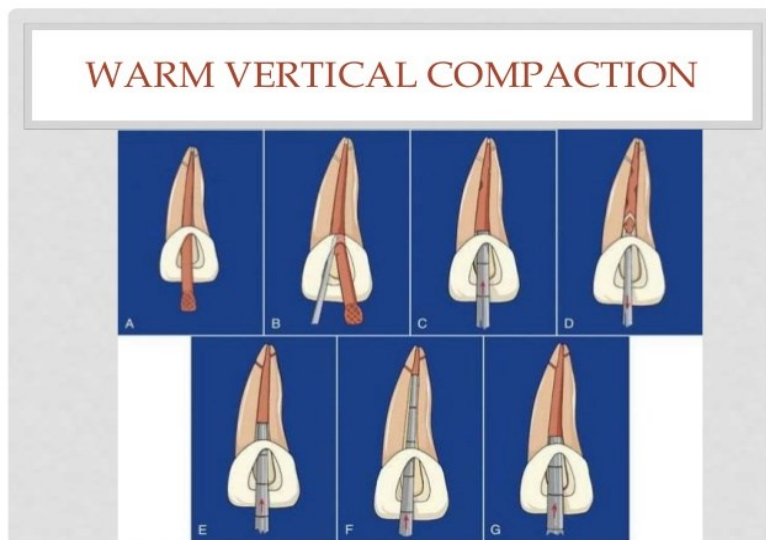
Warm vertical condensation is a warm technique which involves heat during the active filling process. By use of heated pluggers, pressure is applied in a vertical direction to the heat softened guttapercha. This allows and causes the guttapercha to slowly flow and fill the lumen of the canal, creating a seal.

Warm lateral compaction is similar to cold lateral compaction. We place a master cone in the canal and use special tips, Endotec II and EndoTwinn tips, to laterally compact the cones. Accessory cones are placed until the canal is filled.

Injection technique is a quick way to fill the canals. A device that heats the guttapercha is placed inside of the canal and slowly releases guttapercha in the canals.

Thermafil techniques are carrier based gutta percha. Carriers are plastic cores surrounded by guttapercha. These points are heated in a special device that heats them to the proper temperature. The files are then placed into the canal and the tip is cut off.

McSpadden Thermomechanical Compaction Method, is a method that uses heat to decrease the viscosity of the guttapercha and increase its plasticity. The heat is achieved by slowly rotating a specific file that is inside of the cone. The flutes on the file forces the guttapercha to move laterally and apically.



Resources

Roubalikova, Lenka. "Preclinical_endo_angl" IS MUNI
https://is.muni.cz/auth/el/med/jaro2020/aZLED061p/preclinical_endo_angl_pptm.pdf?lang=

[en](#)

Sheth, Maulee. "Obturation Techniques." *LinkedIn SlideShare*, 14 Feb. 2017, www.slideshare.net/MauleeSheth1/obturation-techniques-72119596.

22. *Complication of endodontic treatment (Christopher G.)*

Local complications

Plug formation

This is when you get accumulation of debris obdurating the canal due to insufficient irrigation and recapitulation.

Recapitulation: After each successively larger file you irrigate and return to a smaller file then the file used to prepare the apical portion of the canal.

Irrigation is the removal of debris after the use of a file.

Solution

Repeated instrumentation with a thinner instrument previously used with proper irrigate use. Irrigation alone cannot be used for the removal of the plug.

Fractured instruments

Reasons for fracture:

-Due to incorrect implementation of root shaping files techniques. e.g not carrying out balanced force technique correctly.

-Using aggressive force, or prolonged force when faced with resistance apically.

- Insufficient coronal flaring, you need sufficient space coronally.
- Lack of a straight line access.
- Old (/blunt) root canal shaping instruments
- Forgetting to pre bend the file
- Non sequential increase in file size. e.g go from 15 to 30 to save time.
- Too high rotary speed and radicular pressure

Common in NiTi rotatory instruments, they are more flexible but fracture prone. Most common in the apical third of mandibular molars, curvature of roots and lack of accessibility and vision.

For removal High magnification and illumination is required!

The ease of removal depends on the location of fracture within the root canal

If the fracture is before the apical bend (mid-root) and hence a straight line access available there is a chance of removal. Exposing about 2mm of the coronal portion followed by an extractor.

On the contrary, if the fracture is after the curvature of the root removal becomes increasingly difficult and surgery may be needed.

Solutions

The first possibility is with the use of an ultra sonic tip with EDTA. The tip is positioned around the between the coronal tip and the canal wall and rotated in a counterclockwise motion = unscrewing force. This will aid in loosening of the file from the canal.

Enlargement of the root canal around the fractured file

Or a smaller file can be used ignorer to bypass the fracture and dislodge it from the canal. If the fragment is lodged linguallly, a file can be placed ducally to bypass and remove the fractured file fragment without forcing the fragment deeper apically.

Surgical treatment may be needed or Leave the file in, particularly in the apical regions of the root canal, therefore, leaving the fragment in situ, if its attempt at removal has a high potential of further damage.

Ledge Formation

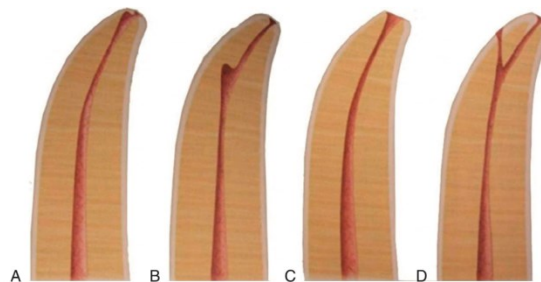


FIG. 19-12 Schematic diagrams showing the most common preparation errors. A, Radicular zip. B, Ledge. C, Radicular zip with perforation. D, Ledge with perforation.

Defined as; an artificial irregularity created on the surface of the root canal wall that impedes the placement of an instrument to the apex of an otherwise patent canal. The ledge prevents sufficient shaping and cleaning of the canal.

An exaggerated ledge is known as Zipping a Elbow, where again the file is not pre bent.

Reasons

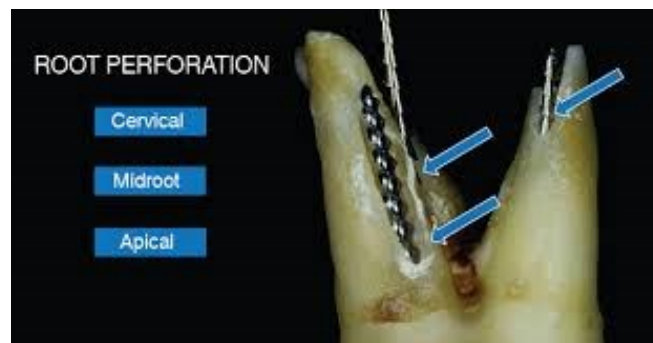
Due to not pre bending the hand instruments when root canal curvature is present.
Lack of working length control. Via rubber stopper not used/ moved during treatment
Clinical experience insufficient
Forcing of a large instrument into the canal

Solutions

Bending the instruments in advance.
Small hand instrument (number 10 file) to bypass the ledge

Stripping

Lateral perforation caused by over instrumentation through a thin wall.
Most likely to happen to the inside or concave wall of a curved root such as the distal wall of



the medial roots on a mandibular first molar.

Reasons

Poor orientation in morphology with the lack of a diagnostic Xray
No pre bending of instruments

Teeth to be handled with care:

Mandibular molars, medial root
Maxillary premolars
Mandibular incisors

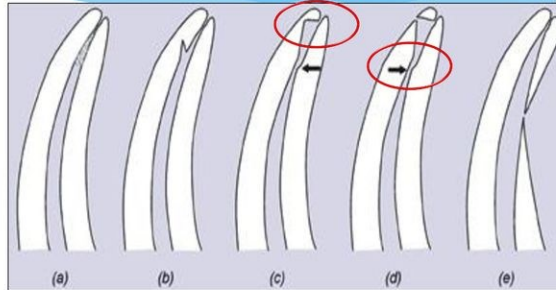
Solution

Bend the instrument

Via false:Perforation

Procedural Errors during instrumentation

- a. Canal blockage and Loss of working length.
- b. Ledge formation.
- c. Zipping
- d. Elbow formation
- e. Perforation
- f. Canal transportation (e)
- g. Separated instrument
- h. Over-instrumentation



Perforation can occur at either the coronal part of the root canal, middle or apically.

Solutions

Use of MTA (Mineral Trioxide Aggregates) as an endodontic cement sealing filling of perforations of the pulp chamber and of the root.

It allows for good edge closure/sealing, prevents access of micro-organisms. In addition it allows healing of the pulp and periodontium.

Composition (of Portland Cement): Dicalcium Silicate, Tricalcium Silicate, Tricalcium aluminate, Tetracalcium aluminate, Cuprum sulphate, Bismus trioxide

Prior treatment there must be no bleeding, sufficient use of disinfectant. Use of Calcium hydroxide.

Regional Complications

Mucosal Damage

NaOCl 1.5-5.5% is a common irrigation solution used in root canal treatment. It has strong antibacterial and tissue dissolving properties. It can cause severe chemical burns of the skin and irritation to the oral mucosa to partial necrosis. Several precautions must be taken during NaOCl use to prevent the spread of the solution into surrounding tissues with the use of Rubber Dam.

Early recognition of NaOCl accident and proper immediate management are important to obtain to minimise damage.

Sinus Perforation

This can occur with treatment of your upper premolars and molars. The palatal root of your molars are in close proximity (less than 2 mm in some circumstances) to the floor of the maxillary sinus.

Perforation of the maxillary sinus and introduction of canal filling materials can result in sinusitis.

Reasons

Loss of working length, as a result of overextension passing the apical constriction.

Solutions

-For prevention Diagnostic Xray taken to see proximity of sinus to palatal apical foramen in addition to the working length being controlled throughout the treatment.

-Surgical intervention may be needed for removing extruded root canal filling material and allowing for adequate healing.

Systemic Complications

Periostitis: Inflammation of the periosteum resulting in puss formation.

Inflammation of soft tissues (face, neck)

Gulp of the instrument (X ray, remnant diet, information)-cough for removal(Heimlich manoeuvre). Aspiration of instruments -emesis (vomiting) for removal. The use of Rubber dam would protect the patient from such scenarios. The lost instrument must be retrieved to make sure the instrument has been removed from the patient.

Latex Allergy - Due to use rubber dam required for Endodontic treatment.

Type I hypersensitivity reactions (with itching of the skin and eyes, sneezing and bronchospasm or anaphylaxis) occurs immediately after exposure to latex and can be life-threatening requiring appropriate medical management. Appropriate preventive measures should be used in all patients with known latex allergy including the use of non-latex products such as nitrile gloves and latex-free rubber dam.

References

↵American Association of Endodontists. Position paper: glossary of endodontic terms. 2015. At: www.nxtbook.com/nxtbooks/aae/endodonticglossary2015/. Accessed 21 Feb. 2016.

Faras, Fatemah, et al. "Complication of Improper Management of Sodium Hypochlorite Accident during Root Canal Treatment." Journal of International Society of Preventive & Community Dentistry, Medknow Publications & Media Pvt Ltd, 2016, www.ncbi.nlm.nih.gov/pmc/articles/PMC5109866/.

Latex allergy. American Academy of Allergy, Asthma & Immunology. <http://www.aaaai.org/conditions-and-treatments/Library/At-a-Glance/Latex-Allergy>

Hargreaves, Kenneth M., et al. Cohen's Pathways of the Pulp. Elsevier, 2016.