

Endodontic surgery

Classification

- Preendo – gingivectomy, elongation of the cinical crown
- Emergency - incision
- Apical surgery
- Hemiextraction

Apical surgery

Apicoectomy

- Removal of the pathological tissues in the periodontal space, and the end of the root, a tergo filling

Curretage - periapical

- Removal of granulation tissue

Indication

- Failure of the endo treatment
- Blocked root canal
 - Rigid root canal filling (sealer)
 - Root canal post
 - Fractured root canal instrument
 - Calcification of root canal - obliteration
- Perforation in apical part of the root

Contraindication

- All situations when the root canal treatment is possible
- All contraindications of apical surgery
- Risk of metastatic infection
- Vertical root fracture or stripping
- Primary periodontal lesion – resorption of alveolar bone, mobility
- External resorption of the root (cervical or middle third of the root)
- Pulpal and periodontal lesions (combination)
- Big lost of the vestibular bone – risk of big posttraumatic defect

Factors for consideration

- Clinical crown/root ratio
- Restorability of the tooth
- Size of periapical lesion and surrounding structures (Maxillary sinus, mandibular canal)
- Approach to the lesion
- Status of general health
- Compliance

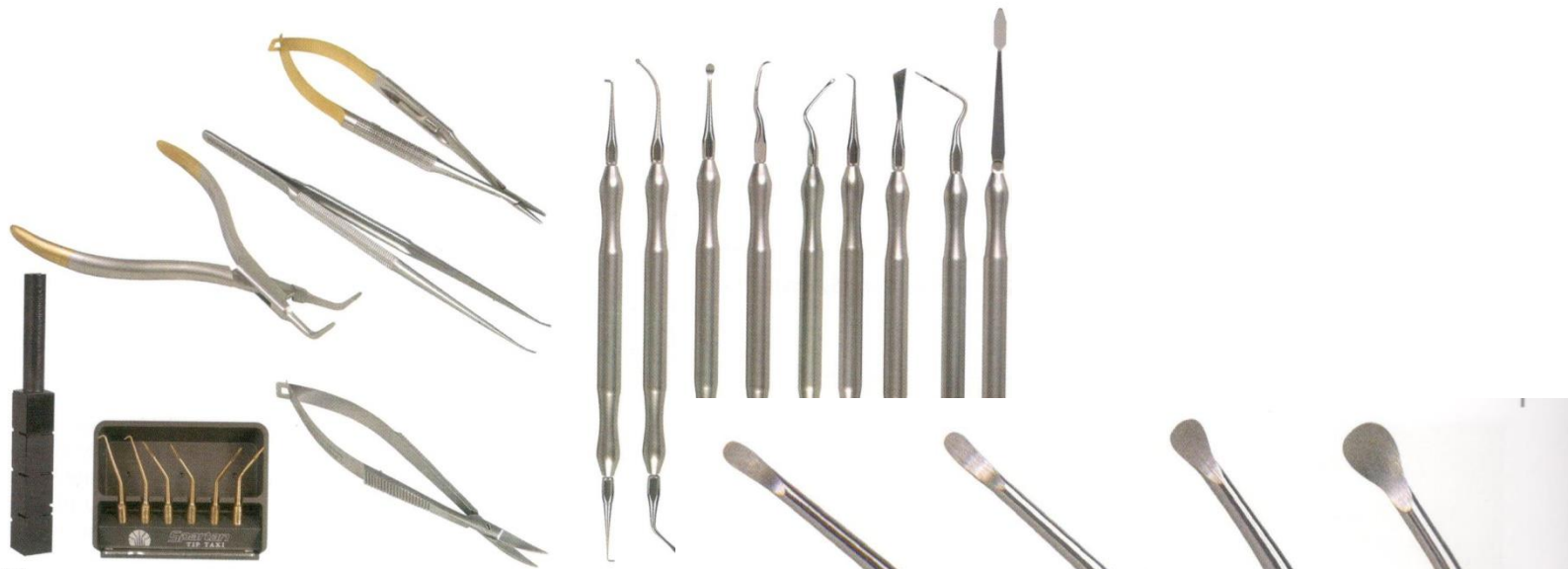Sutgical procedures

- Apicoectomy, curretage
- **Endodontic microsurgery**

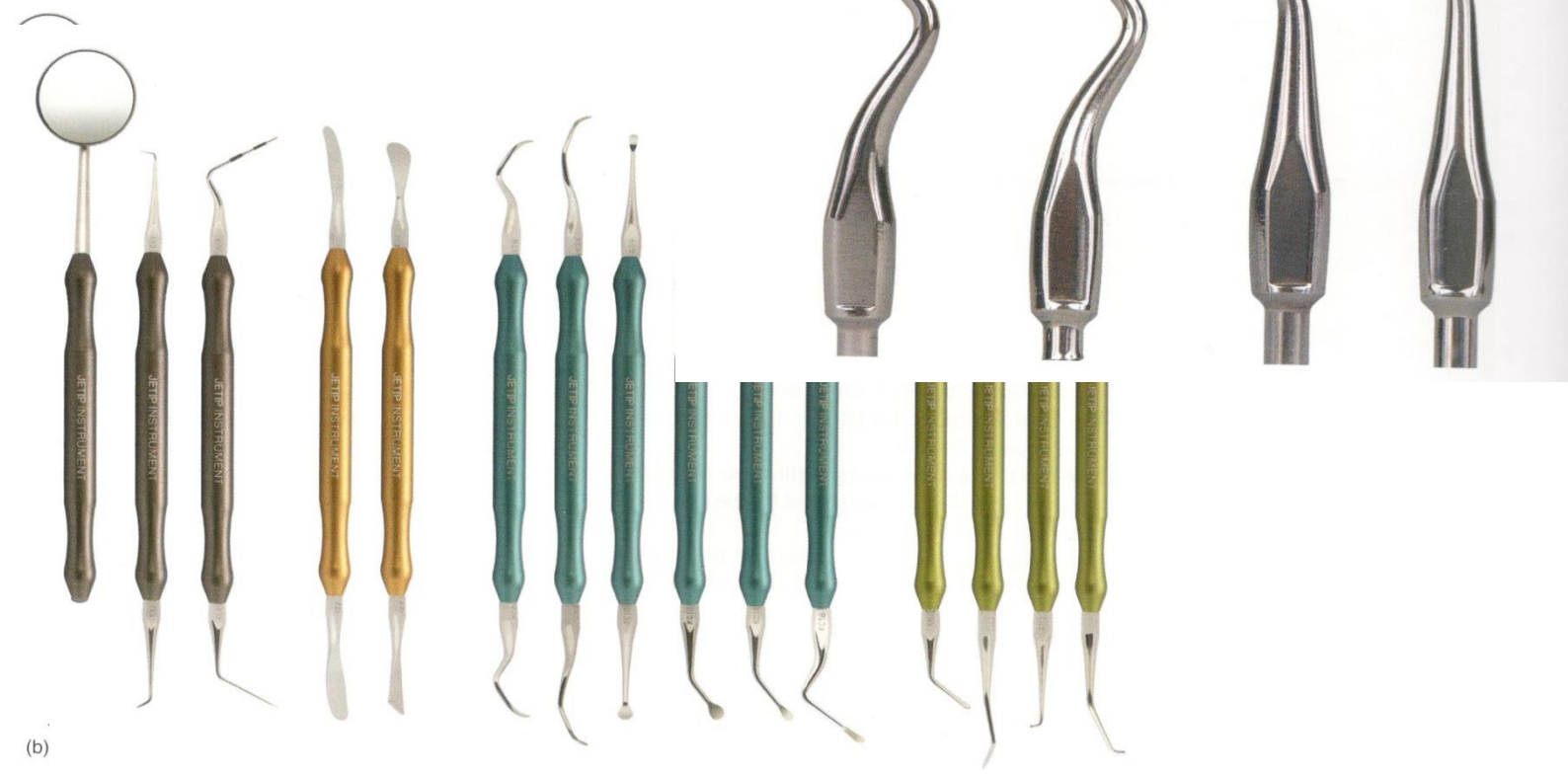Armamentarium

- Common surgical instruments
- Special instruments for microsurgery
 - Stainless steel. Titanium, small size, special shape
- Ultrasound tips
- Bone burs
- Special handpieces

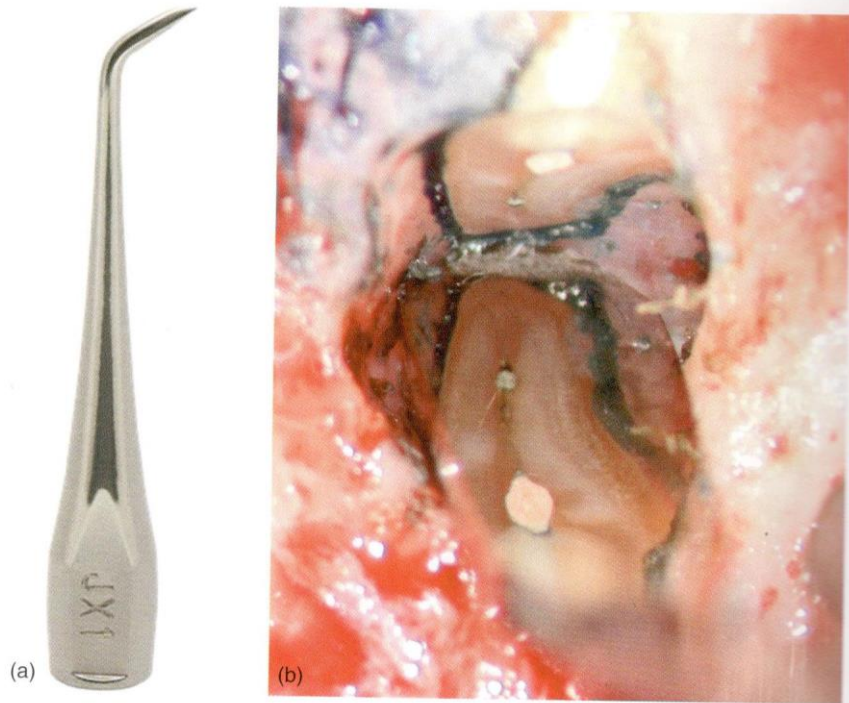
in 1/2 in 1/4 in 3/8 in 1/2 in 5/8 in 3/4 in 7/8 in 1 in 1 1/8 in 1 1/4 in 1 1/2 in 1 3/4 in 2 in 2 1/4 in 2 1/2 in 2 3/4 in 3 in 3 1/4 in 3 1/2 in 3 3/4 in 4 in 4 1/4 in 4 1/2 in 4 3/4 in 5 in 5 1/4 in 5 1/2 in 5 3/4 in 6 in 6 1/4 in 6 1/2 in 6 3/4 in 7 in 7 1/4 in 7 1/2 in 7 3/4 in 8 in 8 1/4 in 8 1/2 in 8 3/4 in 9 in 9 1/4 in 9 1/2 in 9 3/4 in 10 in



(a)




(b)



(a) (b)
A probe for investigation of the root canal filling

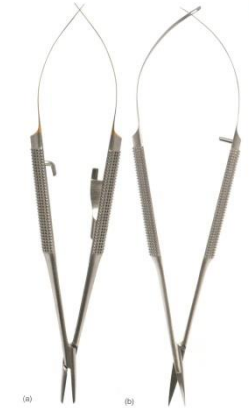Special handpiece



Needle holders

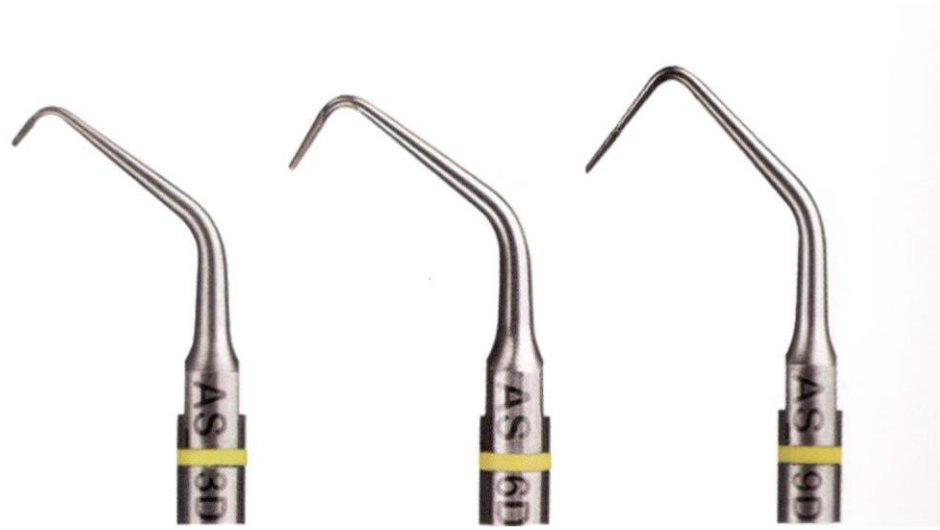

Mirrors – common and microsurgical

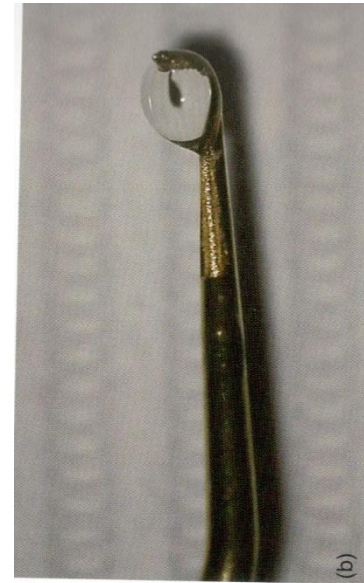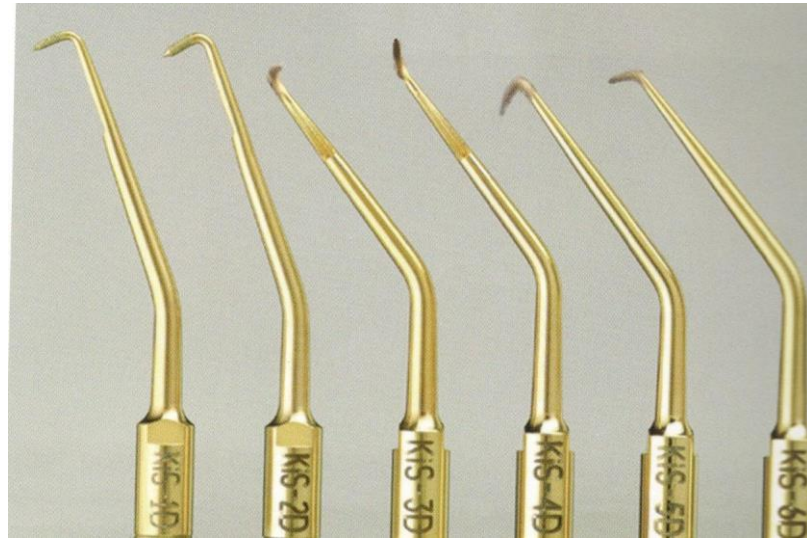


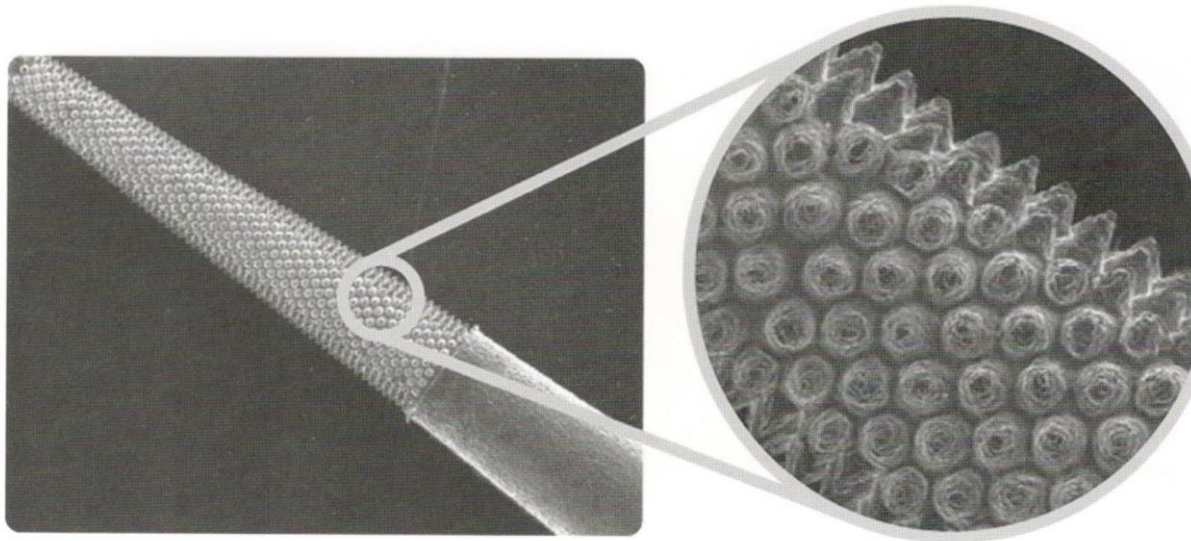
Ultrasound for apical surgery

- Piezoelectric devices (30 – 40kHz)
- Special uz tips for preparation of the root canal in long axis of tooth
 - Stainless, diamond coated, titanium nitride coated
 - Smooth
 - Rough

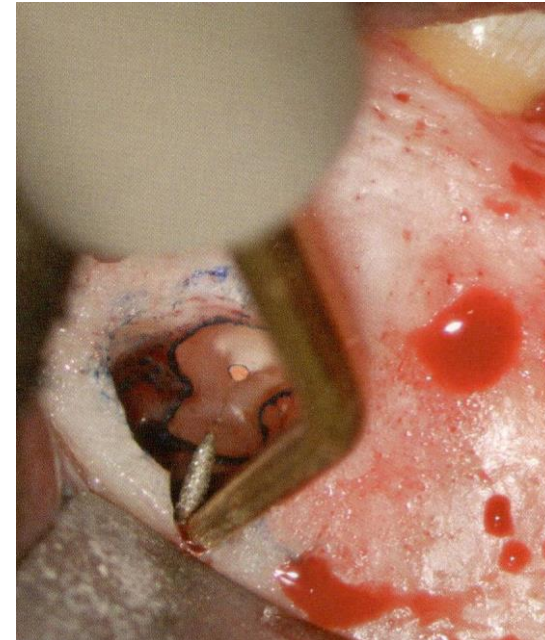


Ultrasound tips



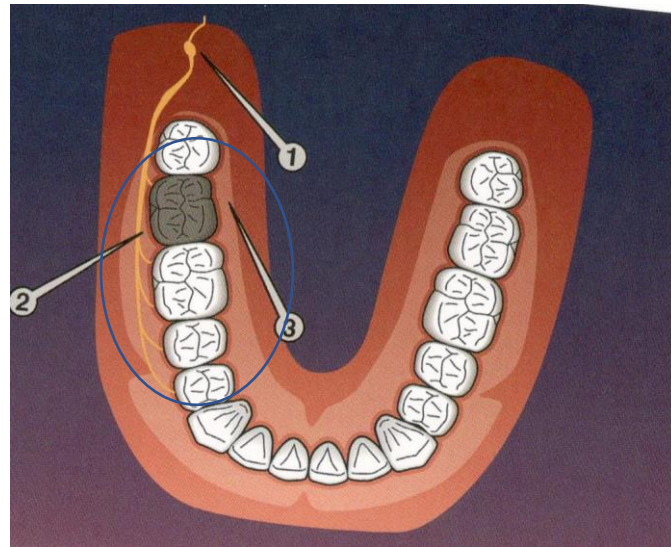
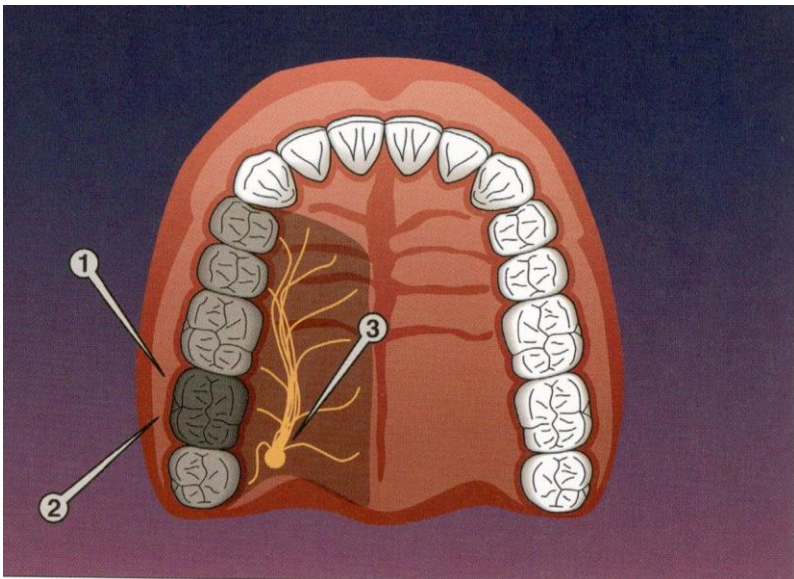
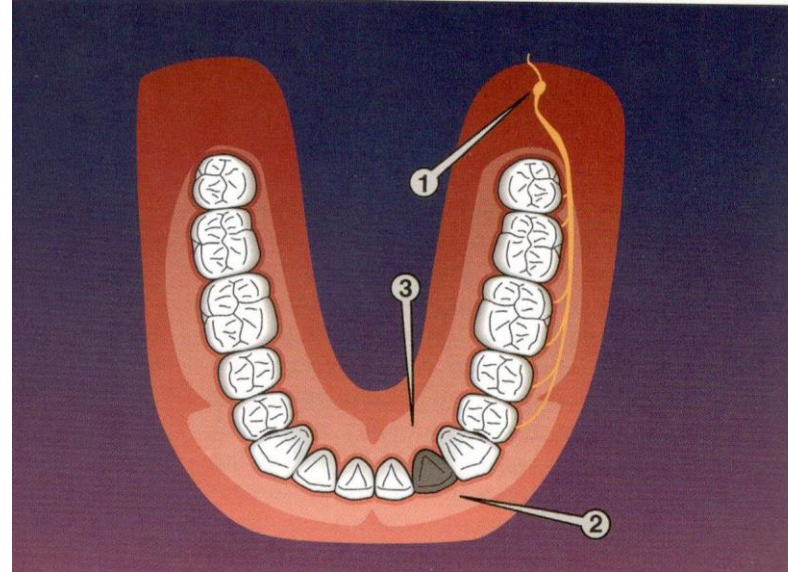
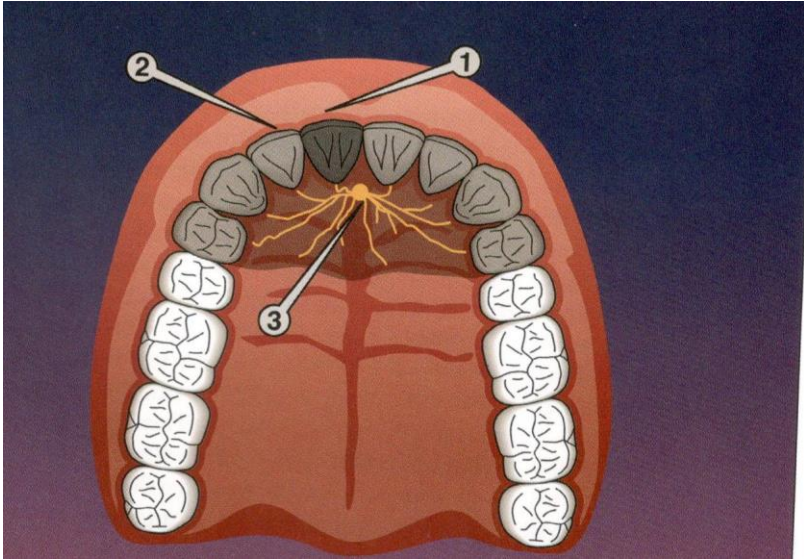


Special surface treatment, possibility of bending



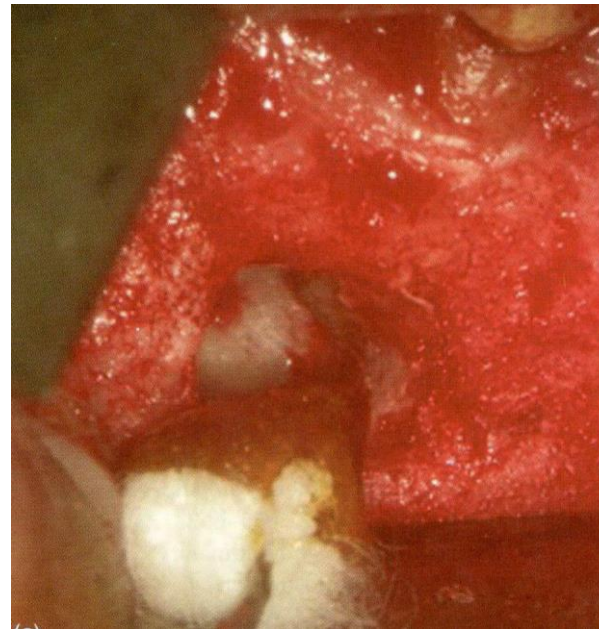
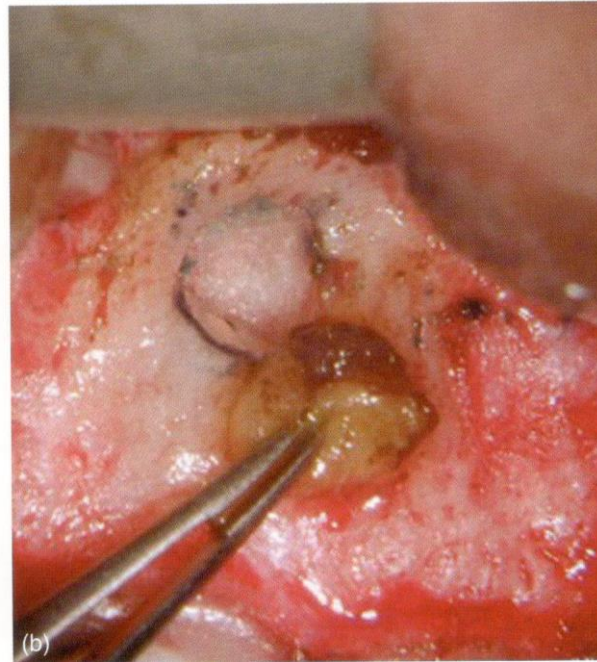
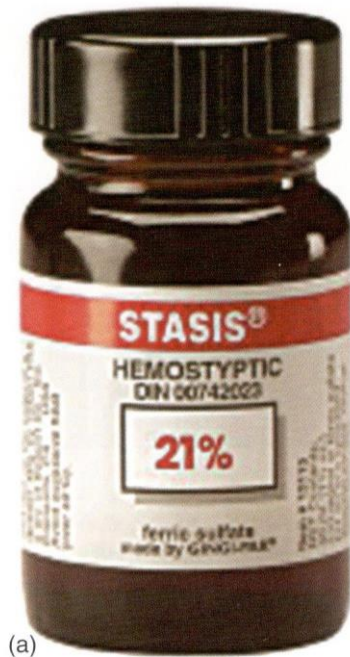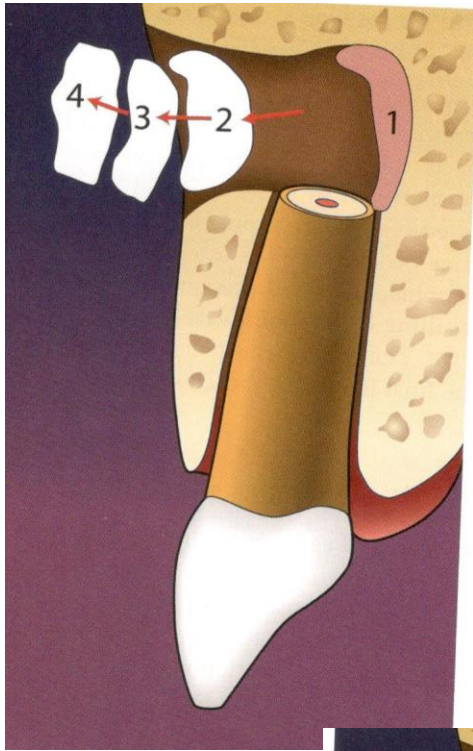
Anaesthesia

- Local – infiltration, nerve blocks



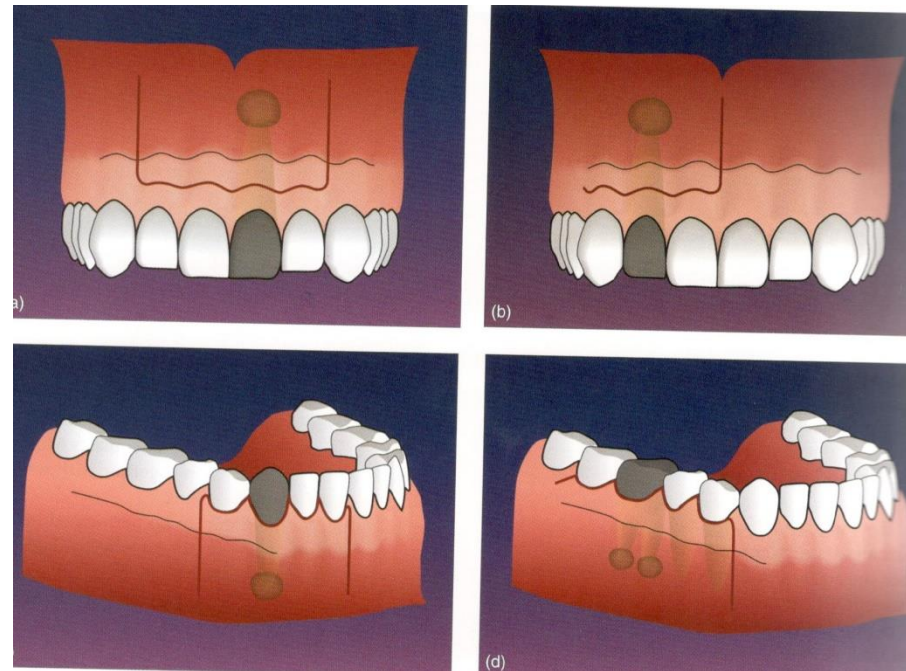
Hemostasis

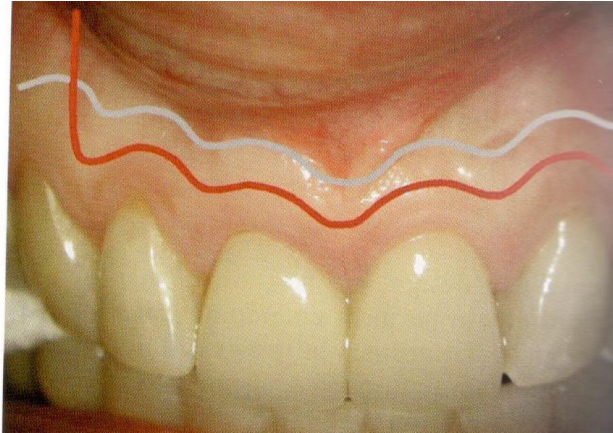- Mechanically
 - Ethicon
- Chemically
 - Adrenalin
 - Ferric sulfate
- Biologically
 - Thrombin
- Absorbable materials
 - Fibrin foam
 - Collagen



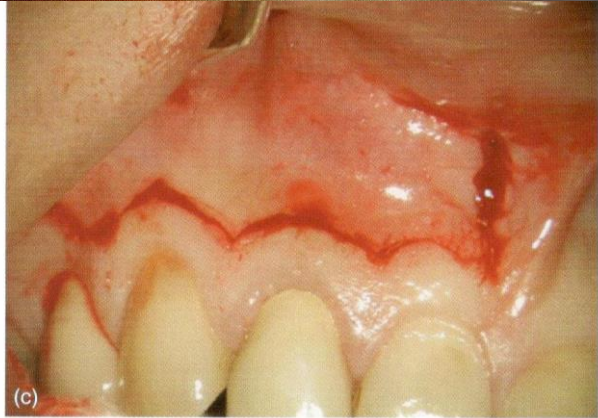Incision

- Submarginal
- Sulcular (preservation of interdental papilla)

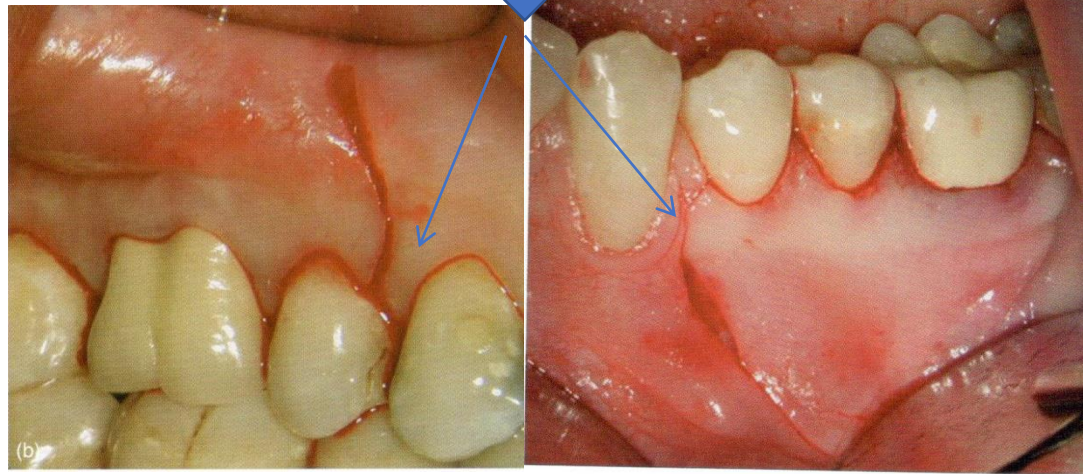




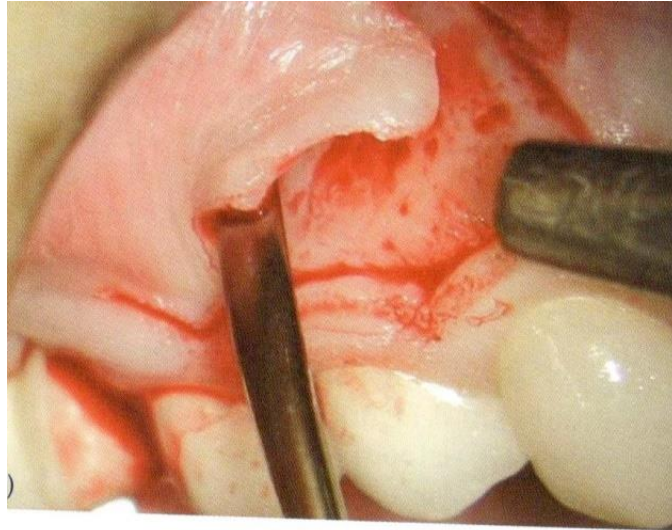
Submarginal



Sulcular

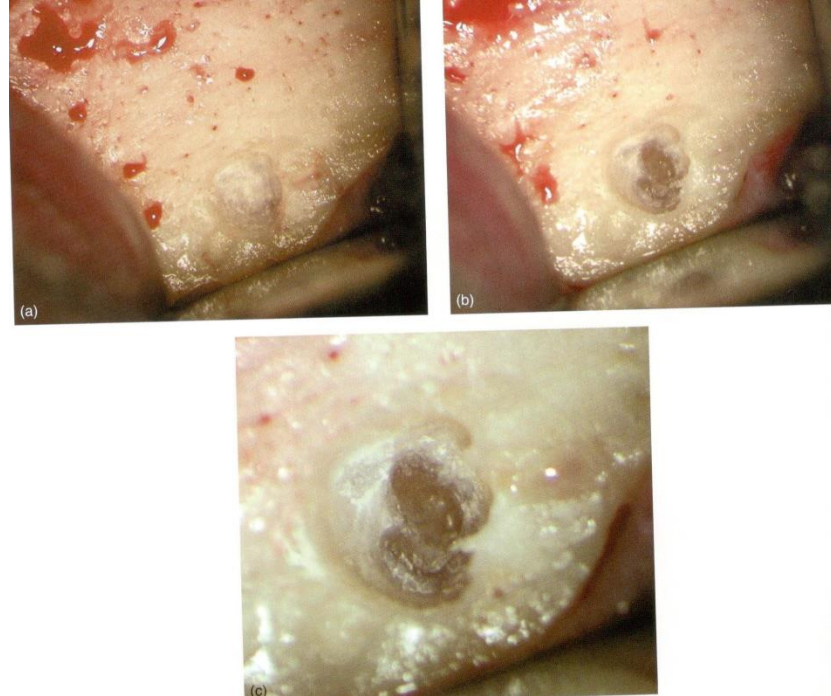




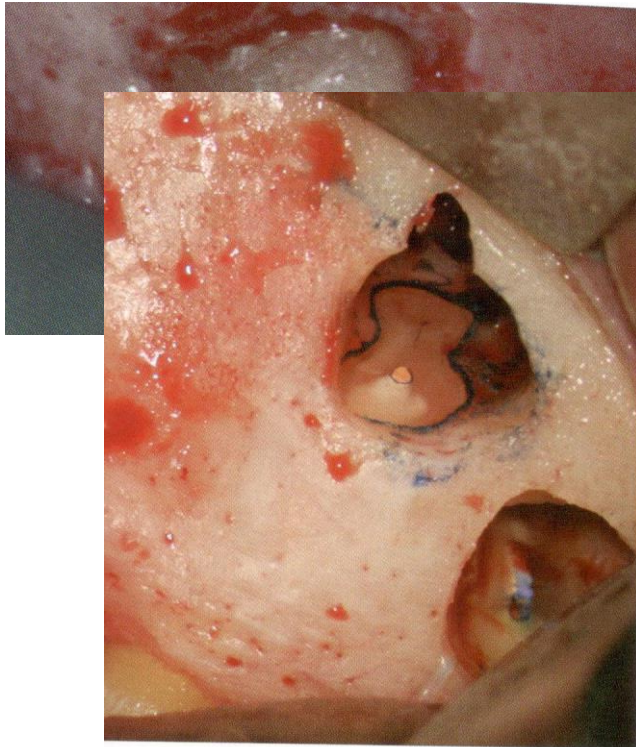
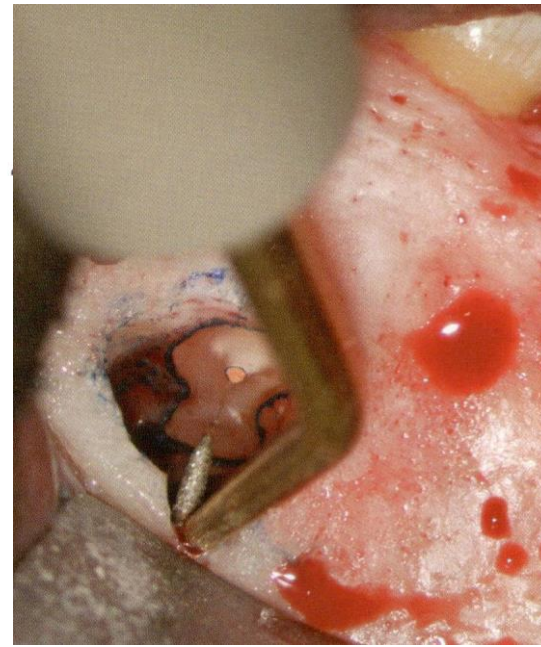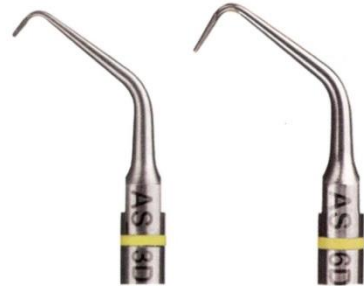
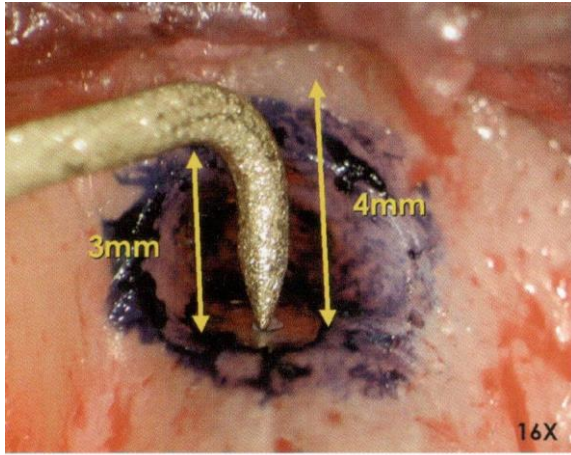
Raise of the flap



Approach to the lesion

- CBCT in advance
- Special instruments



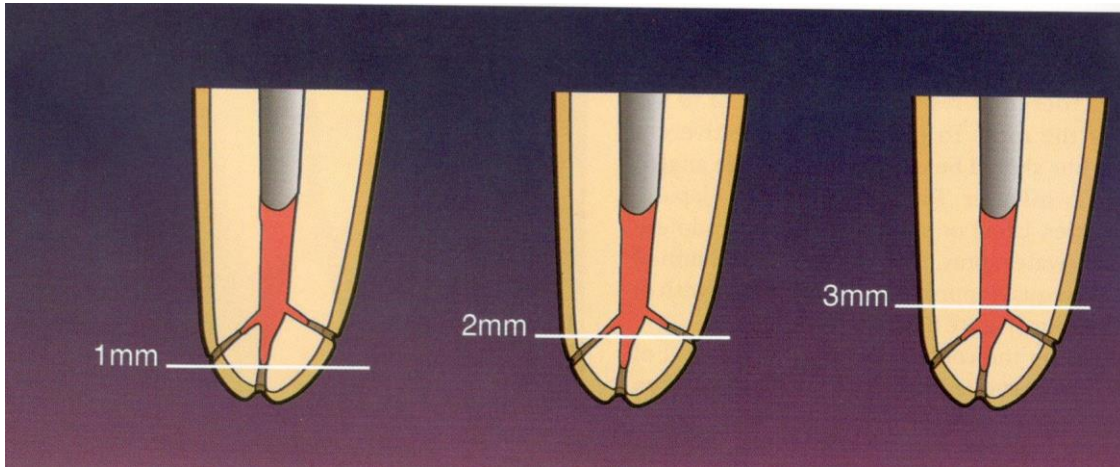
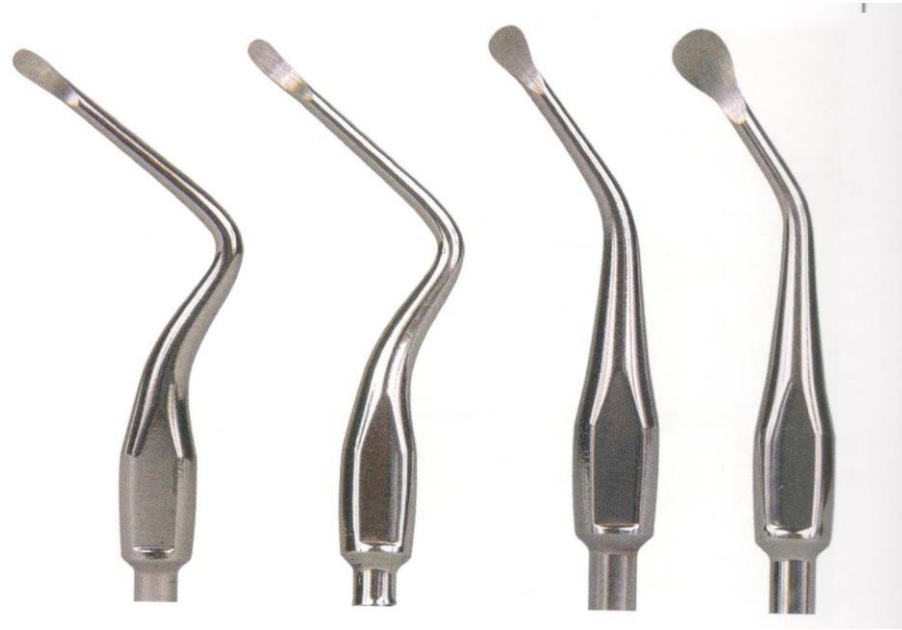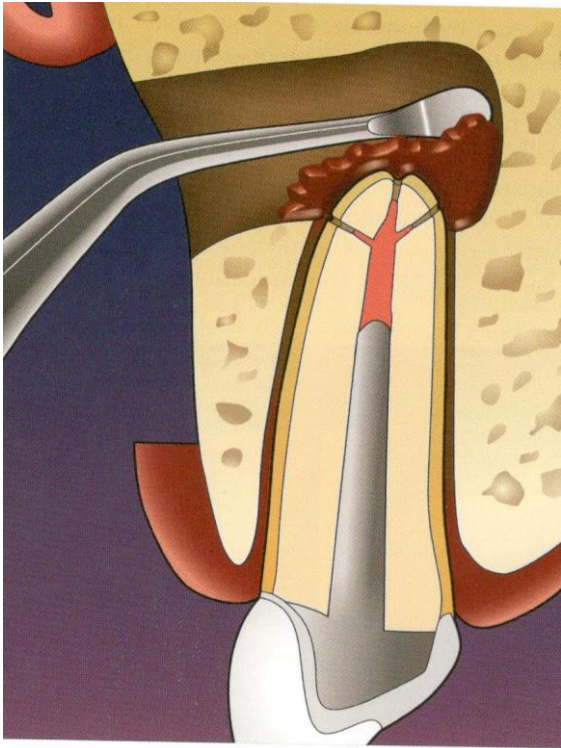


Root end resection

- Excochelation of the granulation tissue
- Removal of apical 3 mm

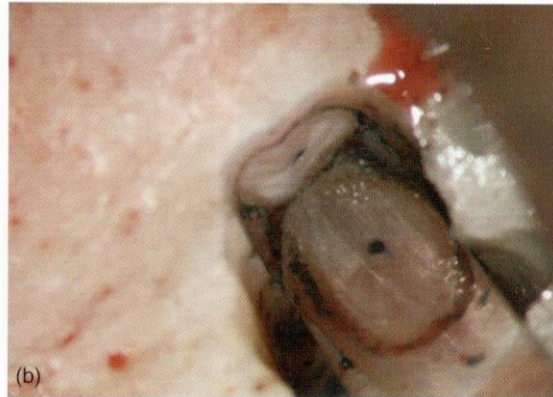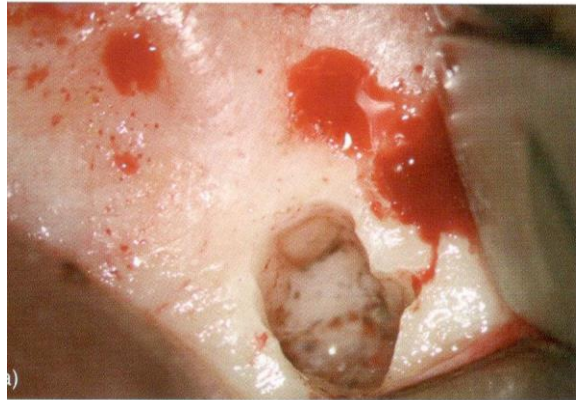
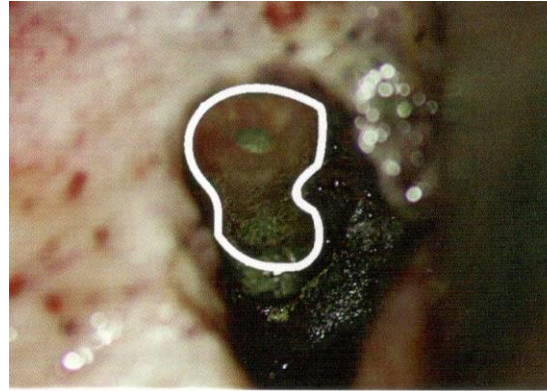
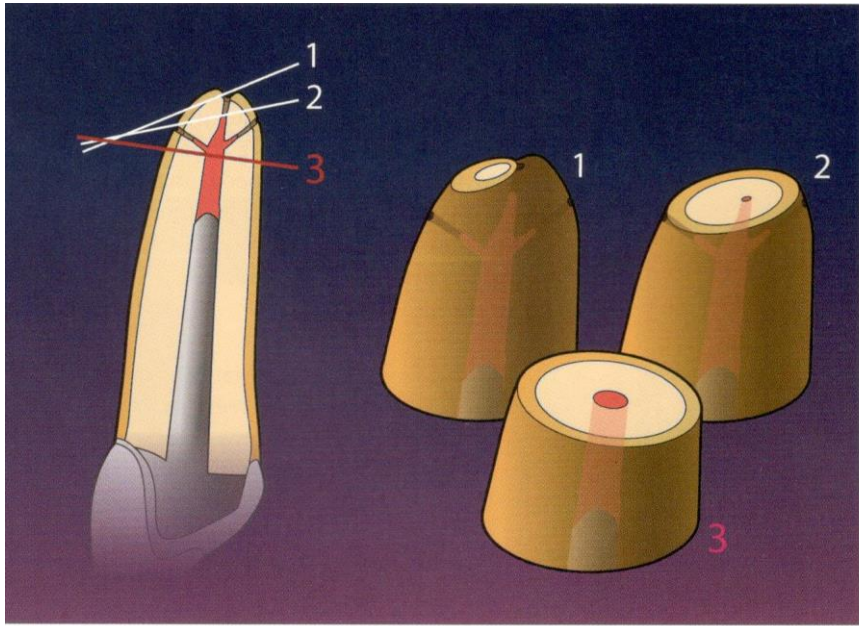
Reasons:

- Removal of pathologic proceses (apical deltas, accessor root canals, ramifications, severe curves)
- Removal of iatrogenic misshapes (ledging,stripping, separated instruments)
- Enhanced removal of granulation tissues
- Access to the canal systém when coronal aces is blocked
- Check of root canal filling
- Creation of apical seal
- Better conditions for investigation of the root and discovering of fractures
- Reduction of fenestrating root apices



3 mm

- 98% reduction of ramifications
- 93% reduction of the lateral canals



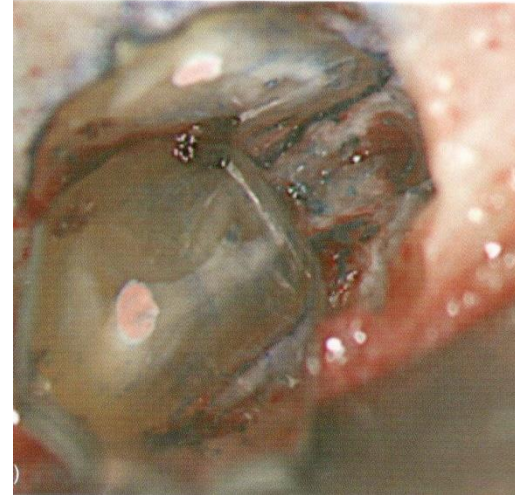
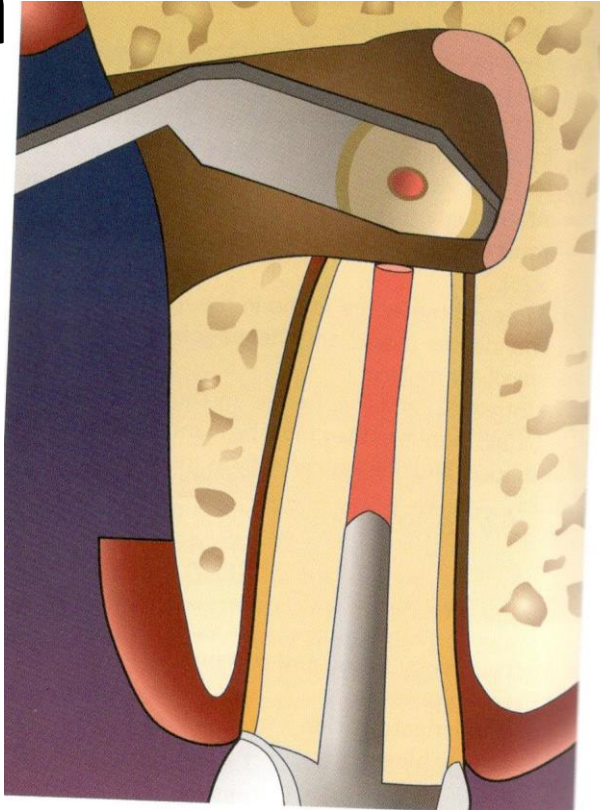
Root end resection

Bevel of cut

40° - 60°: risk of incomplete root end removal, leaving of lateral root canals and ramifications, bigger exposure of dentin tubules , higher risk of reinfection

90°: preservation of root length, less chance to miss multiple root canals esp in oral part of the root. Less exposed dentin tubules.

Kontrola



Preparace a tergo

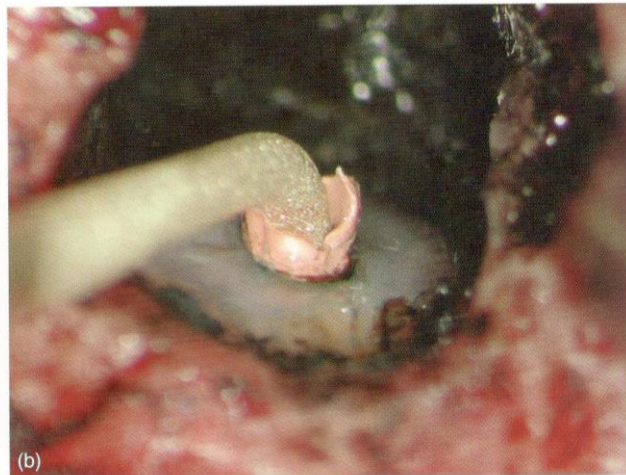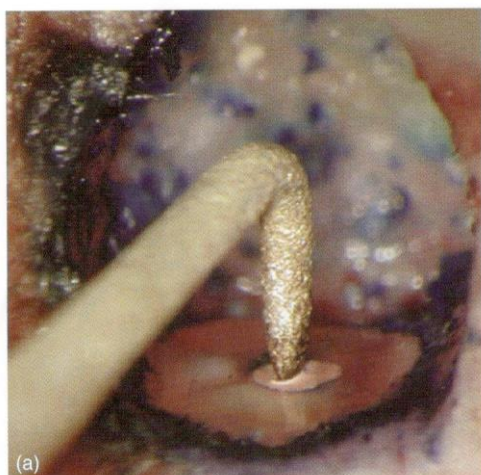
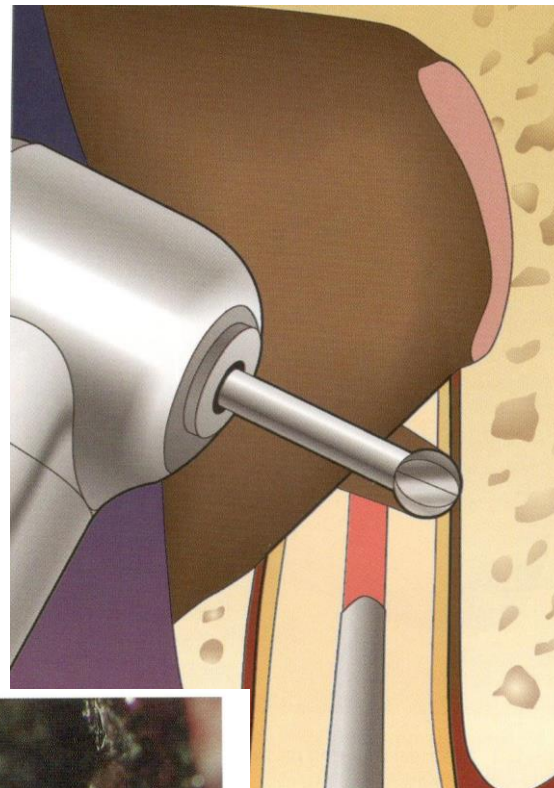
- Vrtáčky

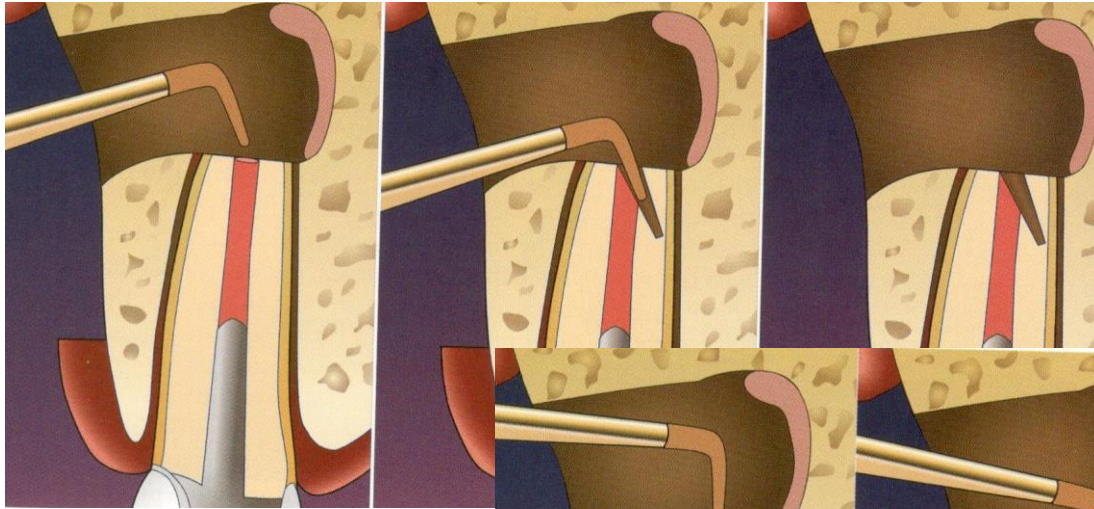


úskalí vedení nástroje

- Ultrazvuk

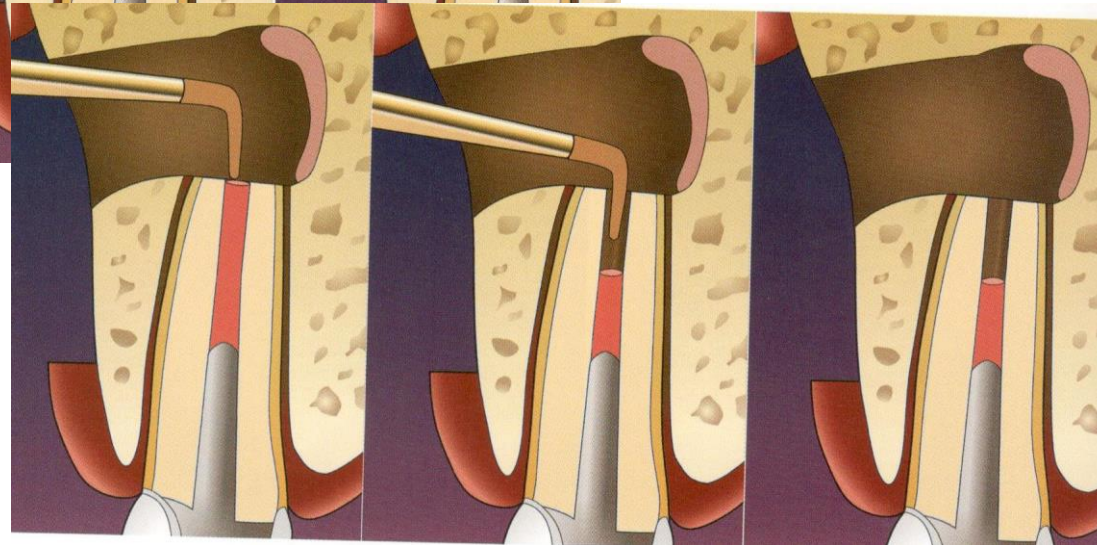
snazší vedení nástroje v dlouhé ose



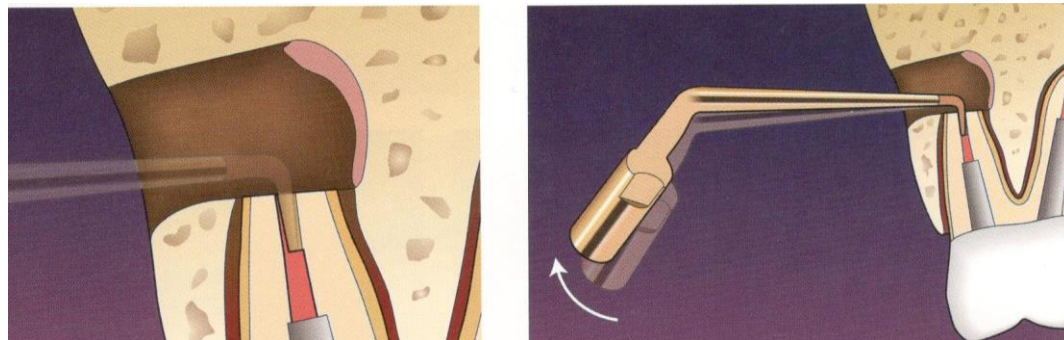


Incorrect leading of instruments

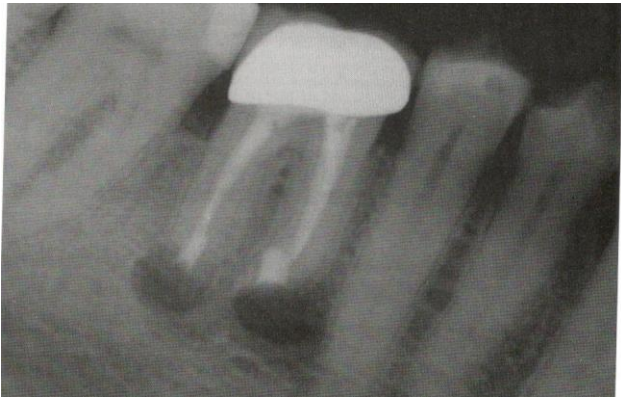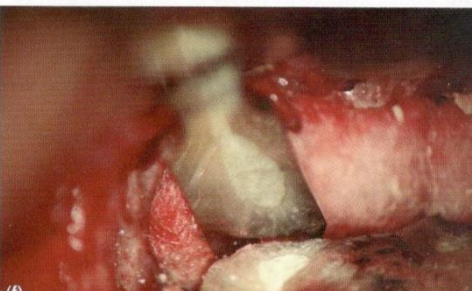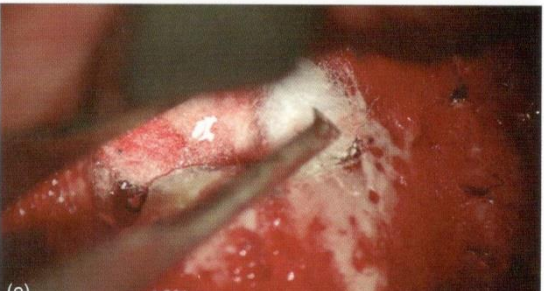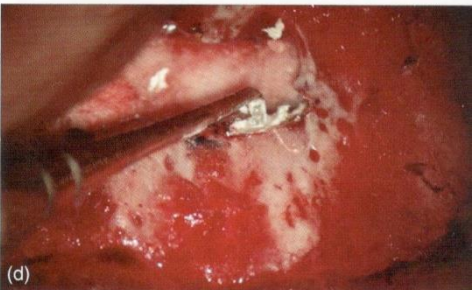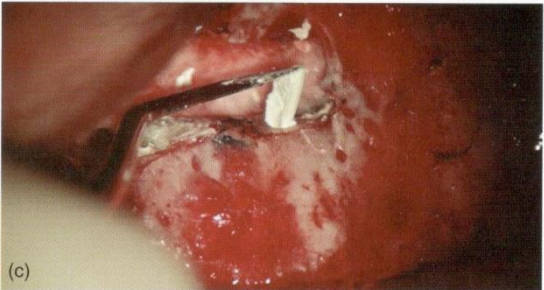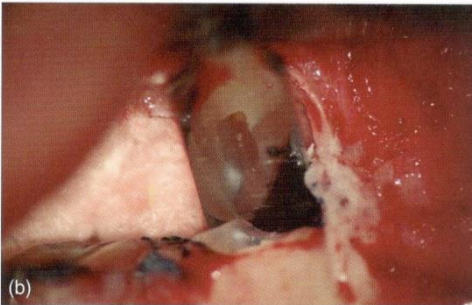
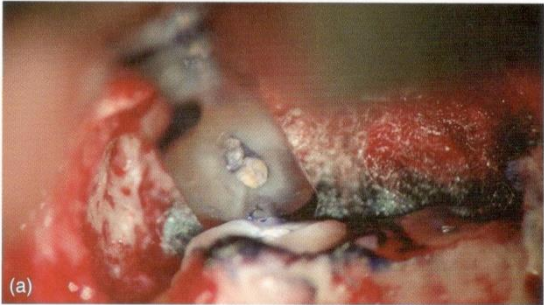
Correct leading of the instrument



3 – 4 mm



A tergo filling



Materials

- MTA

Benefits

- Excellent marginal seal
- Biocompatibility and bioactivity

Disadvantages:

- Difficult manipulation
- Content of metals
- Discoloration
- Longer setting (today modification)

Materials

- Other bioactive materials

Tricalcium silicate and phosphate (RRM – root canal repair material)

Other materials

- Amalgám
 - ✓ Toxicity, corrosion, tetoo, microfractures
- IRM (Intermediate restorative material)
 - ✓ Modified ZOE cement reinforced with polymethylmetacrylate resin
 - ✓ good tolerance

Othe materials

- SuperEBA (Super etoxybenzoic acid)
✓ Modification of the ZOE cement – etoxybenzoic acid (EBA)

EBA - partly replaces eugenol in the liquid

Powder:

60% ZNO, 34% SiO₂ % , natural resins

Liquid:

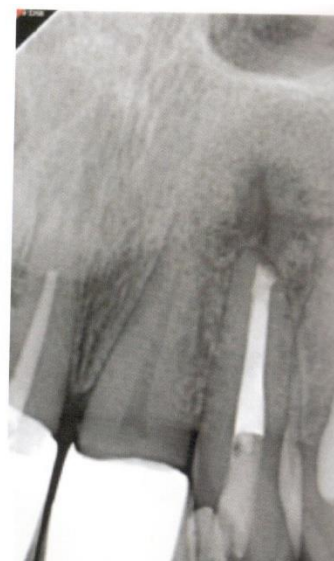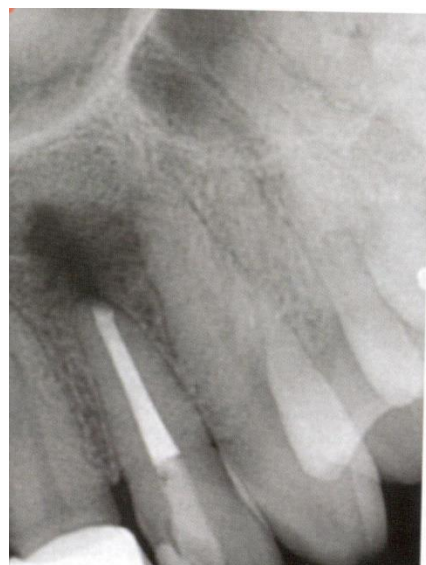
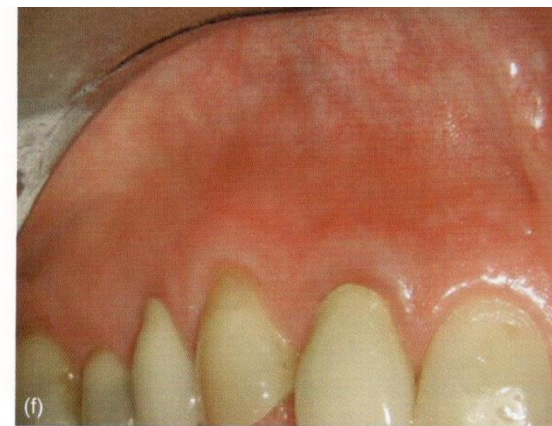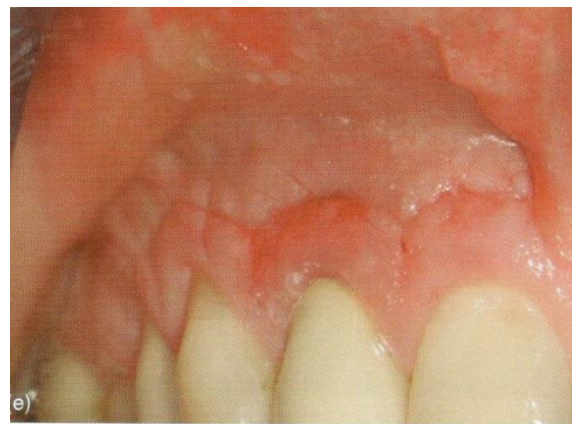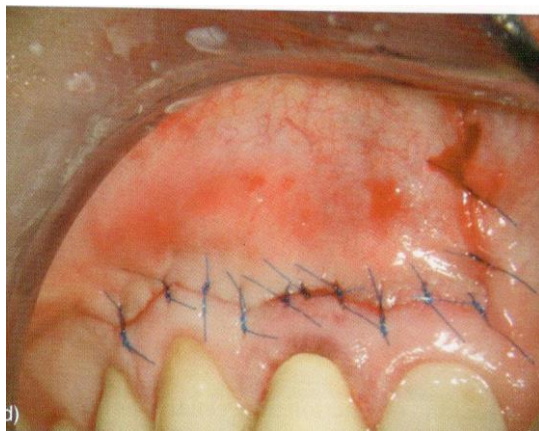
62,5% etoxybenzoic acid

37,5% eugenol

Other materials

- SuperEBA
 - ✓ Good tolerance
 - ✓ Fast setting
 - ✓ Volume stability
 - ✓ Easy surface treatment - polishing
 - ✓ Excellent marginal seal
 - ✓ Difficult manipulation
 - ✓ Sensitivity to moisture and temperature
 - ✓ Less rtg contrast

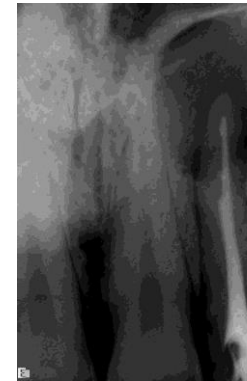
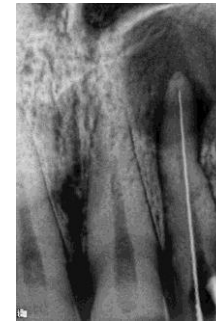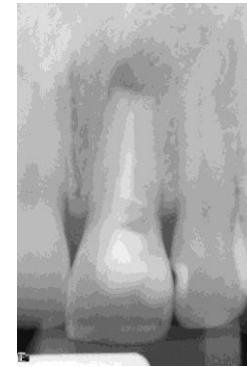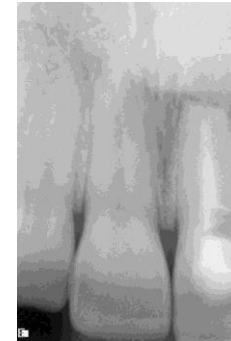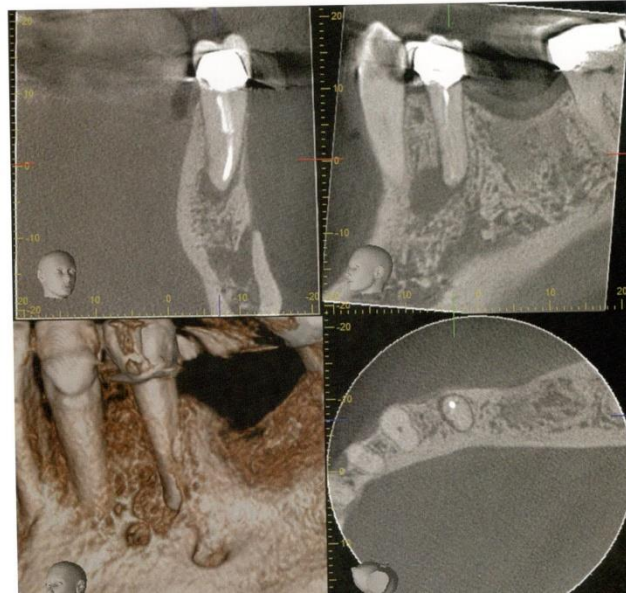
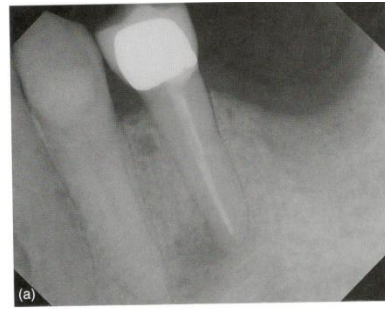Reposition of the flap, suture



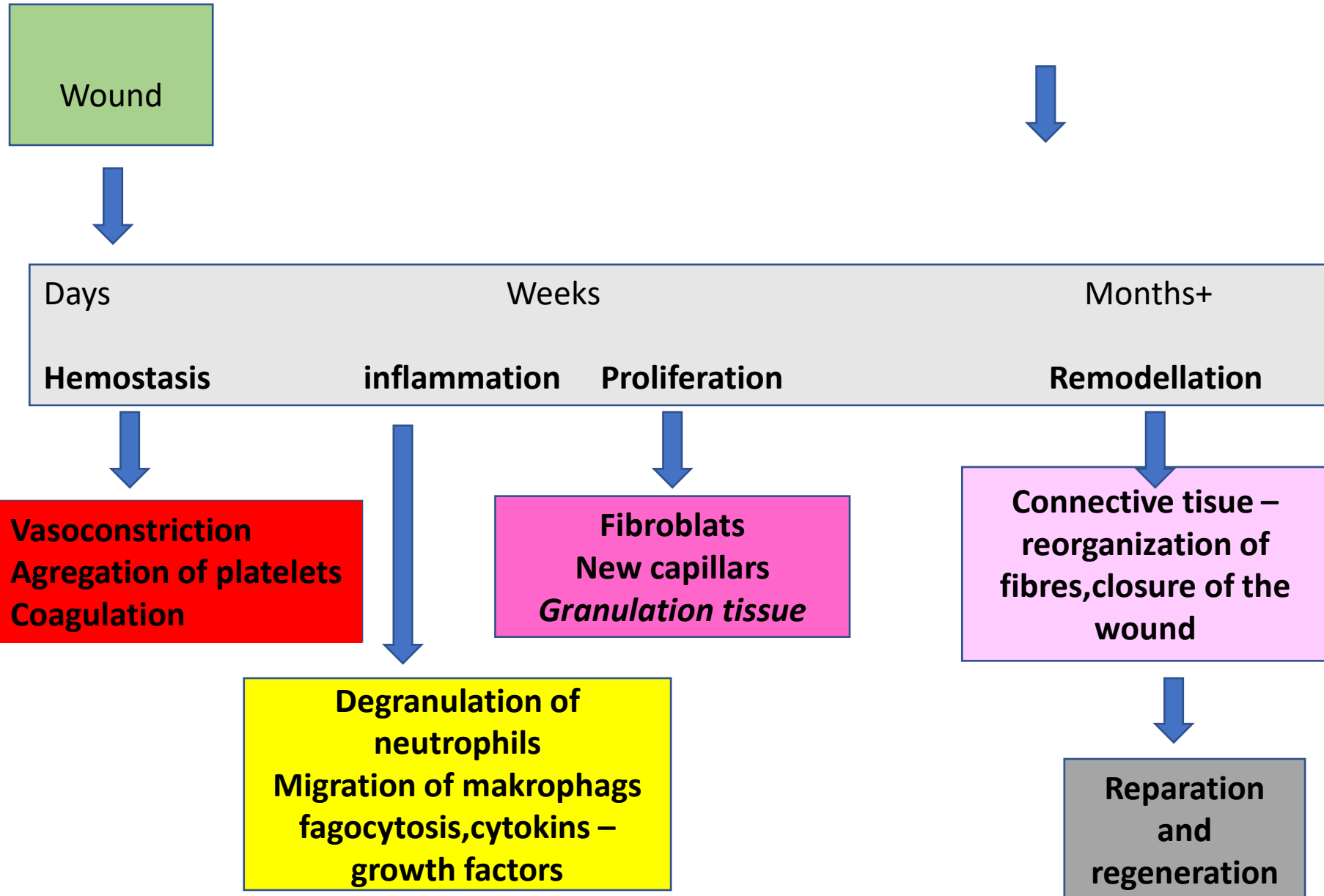
Evaluation rtg

CBCT

CBCT



Healing



Other surgical procedures

- Hemiextraction – removal of a part of the tooth
- Root amputation - removal of the root

