

# DEVELOPMENTAL NEUROLOGY



Department of Paediatric Neurology,  
Masaryk University Hospital Brno

# Infant Neurologic Assessment



- **Infant Neurologic Assessment reflects the ongoing maturation of the central nervous system (CNS).**
- **This maturation is demonstrated by the infant's appropriate acquisition of developmental milestones.**

# Embryology





- **Formation of the CNS begins at 3-4 weeks postconception with the appearance of the neural plate.**
- **A neural groove appears and a formation of the brain and spinal cord begins.**
  - **Once the basic structures are in place, neural cells proliferate at approx. 3 months postconception and then migrate to their final locations by 6 months of fetal life.**


- **At the end of this process all neurons are present. Interference in either phase can lead to a number of abnormalities such as neural tube defects (e.g. spina bifida, meningocele), microcephaly, lissencephaly etc.**
  - **Development of the white matter (myelination) begins at early stages of fetal life and continues, in the case of oligodendrocytes, to many years postnatal until myelination is complete.**

# Developmental Screening

- **At 4 months of age the infant should be able to hold the head up and push up on the arms when prone. A social smile, laughter, and vowel sounds should be present.**
- **Flaccidity or decreased muscle tone (hypotonia) is evidenced by an outward rotation at the hips with the legs externally rotated in a frog leg position**


- 
- A decorative graphic consisting of a horizontal bar with a color gradient from dark purple to bright yellow, and a teardrop-shaped shadow or glow extending to the right from the end of the bar.
- **Assessment of the axial and neck muscle tone** is accomplished by the **traction maneuver** – the infant lying supine is pulled to a sitting position.
  - Even in the full-term neonate the **extensor and flexor tone are balanced**, and the head is maintained briefly in the axis of the trunk.

- 
- **At 4-5 months of age the infant should be able to maintain the head in a neutral position. Abnormal tone (hypotonia) is indicated by the head falling backward or requiring support**

- 
- **Shoulder tone** is assessed by holding the infant in vertical suspension with the examiner's hands under the arms at the armpits. The infant should hold in that position with the arms remaining flexed and no rise in the shoulders.
  - Inability to maintain that position is known as „**slipping through**“ and is a mark of hypotonia



- **Leg tone** is assessed by placing the infant in the vertical position with feet on an examining surface.
- The 4-month old infant should be at least momentarily able to support his or her weight.
- Inability to support any weight is a mark of **hypotonia**
- Extensor posture with crossing or scissoring of the legs is a mark of **hypertonia (spasticity)**

- 
- **The Denver II Developmental Screening Test (DDST)**
    - **the most widely used developmental screening tool for this assessment.**

# The Denver II Developmental Screening Test (DDST)

## 1) Cognitive Milestones

- A. Month 3-5: Attends to and Reaches for objects
- B. Month 4-8: Pulls string to secure a ring
- C. Month 8-15: Imitates patting doll
- D. Month 14-20: Finds Hidden Object
- E. Month 18-28: Completes simple puzzles

# The Denver II Developmental Screening Test (DDST)

## 2) Language Milestones

- A. Month 1.5-3: Squeals
- B. Month 3.5-8: Turns to locate a voice
- C. Month 9-13: Says Mama or Dada
- D. Month 14-24: Combines two different words
- E. Month 21-36: Uses plurals

# The Denver II Developmental Screening Test (DDST)

## 3) Social and Emotional Milestones

- A. Month 1.5-4: Smiles at others
- B. Month 4-9: Seeks primary caregiver
- C. Month 8-15: Stranger anxiety
- D. Month 10-15: Displays 2 or more recognizable emotions
- E. Month 11-20: Exploratory play by self
- F. Month 21-36: Cooperative play in small groups

## **4) Gross Motor Milestones**

- A. Month 2-4.5: Rolls Over**
- B. Month 5-8: Sits without support**
- C. Month 10-14: Stands Alone**
- D. Month 14-20: Walks up steps**
- E. Month 21-28: Pedals tricycle**
- F. Month 30-44: Balances on one foot**
- G. By age 6: Rhythmic skipping**
- H. By age 8.5: Alternates foot-hop in place**
- I. By age 10: Holds tandem stance for 10 sec (eyes closed)**

## **5) Fine Motor Milestones**

- A. Month 2.5-4: Grasps rattle**
- B. Month 4.5-7: Transfers cube hand to hand**
- C. Month 8-12: Has neat pincer grasp**
- D. Month 15-20: Builds tower of four cubes**
- E. Month 18-24: Imitates vertical line**
- F. Month 28-36: Copies circle**
- G. By age 5 years: Draws a square**
- H. By age 5.5 years: Tripod pencil grasp**
- I. By age 7 years: Draws diagonal line**
- J. By age 9: Draws cross with same dimensions**
- K. By age 12: Draws three dimensional cube**

## 6) Self Help Milestones

- A. Month 4.5-8: Feeds self crackers
- B. Month 10-14: Drinks from cup
- C. Month 13-19: Removes clothes
- D. Month 18-28: Washes and dries hands
- E. Month 30-42: Dresses without supervision
- F. **Attained on average by age 4.5 years**
  - 1. Rides a bicycle with training wheels
  - 2. Cuts paper with scissors
  - 3. Colors inside lines
- A. **Attained on average by age 5.5 years**
  - 1. Ties shoelaces
  - 2. Prints first and last names
- A. **Attained on average by age 6 years**
  - 1. Rides a bicycle without training wheels





**The neurologic examination  
of an infant younger than 1 year of age  
can be divided into 3 parts**

**1) Evaluation of posture and muscle tone**

**2) Evaluation of primitive reflexes**

**3) Age-Invariable tests**

**Step 1. Lying supine**

**Step 2. Traction**

**Step 3. Rolling and prone position**

**Step 4. Suspensions (horizontal and vertical)**

# 1) Evaluation of posture and muscle tone

- Examination of the resting posture
  - Examination of passive tone - resistance to passive movements („the scarf sign“ in the upper extremities = hypotonia)
  - Examination of active tone („the traction response“)

## 2) Evaluation of primitive reflexes


- The evaluation of various primitive reflexes is an integral part of the neurologic examination of the infant. With progressive maturation (= **myelinization**) of the CNS some of these primitive reflexes disappear = they are gradually suppressed as the higher cortical centers become functional.

# Moro reflex

- The Moro reflex is best elicited by a sudden dropping of the baby's head backwards as he or she is held in the examiner's hands (or hitting the infant's pillow with both hands)
- Normally, there is an abduction and extension of the upper extremities, followed by an adduction and flexion
- It begins to disappear at 4 months of age
- Its absence during the first weeks of life or persistence beyond 6 months of age, indicates neurologic dysfunction

# Other primitive reflexes

- **Tonic Neck Response** - the fencing posture is assumed by the infant when his head is turned quickly to one side in the supine position.
- A positive response is extension of the arm and leg on the side toward which the face is rotated and flexion of the limbs on the opposite side.
- The 4-month old infant should be able to overcome this position.

- 
- **Babinski reflex** – is elicited by stroking the outside edge of the foot. Extensor response of a great toe with fanning of other toes is normal up to 1 year of age
  - Beyond this age it is a mark of the upper motor neuron dysfunction

- **Palmar and Plantar Grasp reflexes** – symetrically positive in first 2-3 months of age – later are covered up by voluntary activity.
- **Vertical Suspension (spasticity)**
- **Landau Reflex (hypotonia)** – the examiner lifts the infant with one hand under the trunk, face downward. Normally the infant lifts the head slightly below the horizontal. In the hypotonic infant the head falls down and the body tends to collapse.

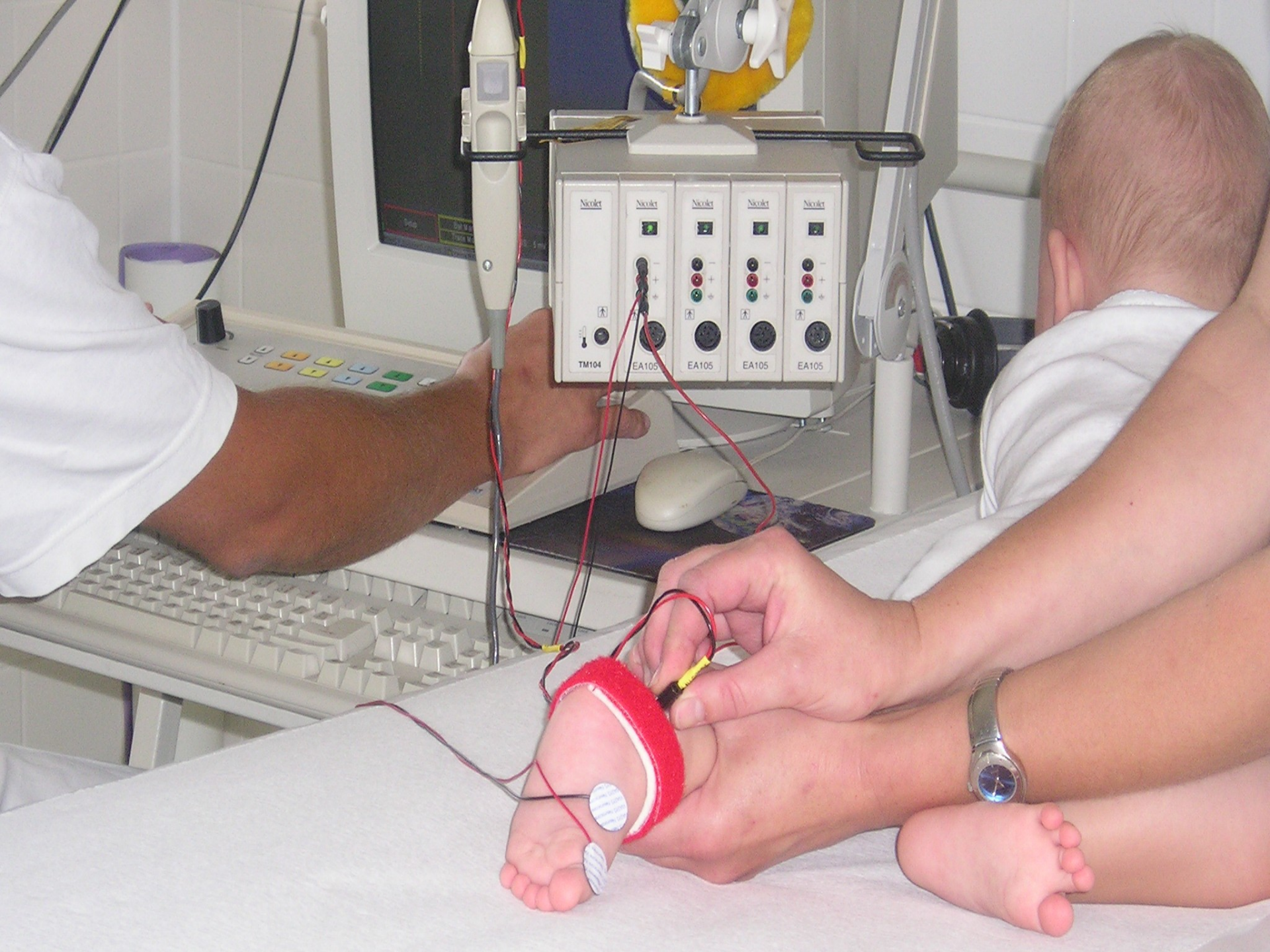

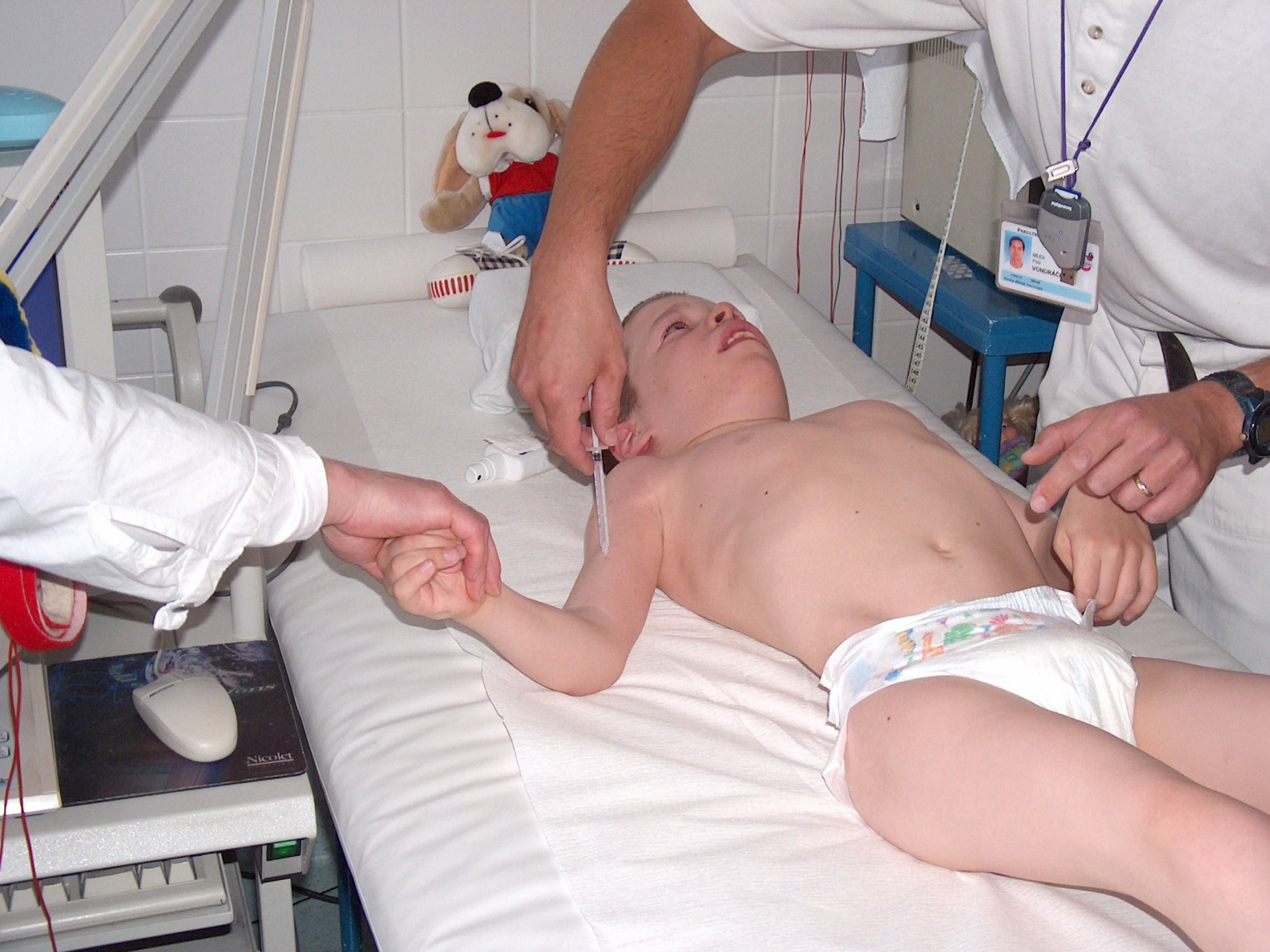- **Parachute Response**
- **The infant is suspended horizontally around the waist, face down, and suddenly projected toward the examining surface**
  - **He or she extends the arms to protect the face – it appears between 4-6 months of age and persists**

### **3) Age-Invariable tests**



- **Similar to those performed in older children and adults**
  - **Deep tendon reflexes**





FAMILIA  
MEDI  
PEDI  
VONDRAČEK  
MUDr.  
Vondraček  
MUDr.

Nicolet

# The main concerns of Child and Developmental Neurology



- 1) Age-related epileptic syndromes of childhood**
- 2) Cerebral palsy**
- 3) Disorders of mental development**
- 4) Neuromuscular disorders**

# 1) Age-related epileptic syndromes of childhood

- **Early Infantile Epileptic Encephalopathy (EIEE - Ohtahara syndrome).** The disorder affects newborns within the first three months of life (most often within the first 10 days). Infants have primarily tonic seizures, but may also experience partial seizures, and rarely, myoclonic seizures. Ohtahara syndrome is most commonly caused by metabolic disorders or structural damage of the brain. The EEGs of infants with Ohtahara syndrome reveal a characteristic pattern of high voltage spike wave discharge followed by little activity. This pattern is known as **“burst suppression.”**

# West Syndrome (infantile spasms)

- Infantile spasms constitute a unique and frequently malignant epilepsy syndrome confined to infants. The usual characteristic features of this syndrome are:
  - **tonic or myoclonic seizures**
    - **hypsarrhythmic EEGs**
    - **mental retardation**
- Infantile spasms are an age-specific disorder beginning during the first 2 years of life. The peak age of onset is between 4 and 6 months. Clusters of repetitive flexor spasms (salams), head nods, often on awakening
- 15% to 30% unknown etiology (cryptogenic) Tuberos Sclerosis or any brain abnormality
- EEG: **Hypsarhythmia**, high voltage slowing with chaotic multifocal spike wave
- Treatment: ACTH, Oral steroids (Europe Vigabatrin)

# Lennox-Gastaut syndrome (LGS)

- **Characterized by a mixed seizure disorder. tonic seizures and a slow spike-and-wave EEG pattern.**
- **The syndrome begins in children aged 1- 3 years . Mental retardation is considered a component.**
- **The child with LGS typically has a mixture of seizure types. The most frequently occurring are:**
  - **tonic**
  - **tonic-clonic**
  - **myoclonic**
  - **atypical absences**
- **"drop attacks"- a form of atonic, tonic, or myoclonic seizures. The identifying EEG pattern in LGS is a slow spike-and-wave discharge superimposed on an abnormal, slow background, occurring at a frequency of 1.5 to 2.5 Hz.**



# Landau-Kleffner syndrome

- The Landau-Kleffner syndrome is a childhood disorder consisting of **acquired aphasia and epileptiform discharges** involving the temporal or parietal regions of the brain.
  - The typical sequence is as follows:
    1. A seizure disorder develops in the child, but it is usually well controlled with antiepileptic drugs.
    2. Aphasia develops; its onset may be abrupt or insidious. Unlike typical acquired childhood aphasia, receptive dysfunction usually is the dominant feature early in the course of the disorder.
    3. Spontaneous verbal expression slowly becomes reduced, and the child may use stereotypies, perseverations, and paraphasias.

# Childhood absence (pyknolepsy)

- A syndrome of typical **absence seizures** (both simple and complex) in otherwise normal, prepubertal children older than about 3 to 5 years. There is a strong genetic predisposition, and girls are more frequently affected. The absences are very frequent (occurring at least several times daily), and tend to cluster.
- The absences may remit during adolescence, but generalized tonic - clonic seizures may develop.
  - The EEG reveals a bilateral, synchronous, symmetric 3-Hz spike-and-wave discharge with normal interictal background activity.

# Juvenile myoclonic epilepsy (JME)

- Juvenile myoclonic epilepsy (JME), also known as Janz syndrome, is a familial disorder that typically begins in the second decade of life and is characterized by mild **myoclonic seizures**, generalized tonic-clonic (GTC), and occasionally absence seizures. The average age of seizure onset is 14 years.
- Janz described a familial disorder of myoclonic epilepsy associated with an excellent prognosis in patients who were otherwise mentally and neurologically normal.

## 2) Cerebral palsy

- **Cerebral palsy refers to a group of disorders that affect a child's ability to move and to maintain balance and posture. It is due to a nonprogressive brain abnormality, occurred perinatally, which means that it does not get worse over time, though the exact symptoms can change over a person's lifetime.**
- **Children with cerebral palsy have damage to the part of the brain that controls muscle tone and coordination of movements. Initial central hypotonic syndrome in a newborn usually changes and spasticity develops**

# Types of cerebral palsy

- **Spastic**
- **Spastic cerebral palsy is usually described further by what parts of the body are affected. In spastic diplegia, the main effect is found in both legs. In spastic hemiplegia, one side of the person's body is affected. Spastic quadriplegia affects a person's whole body (arms, legs, and trunk).**
  - **Athetoid or dyskinetic**
    - **Ataxic**
    - **Mixed**

### **3) Disorders of mental development**



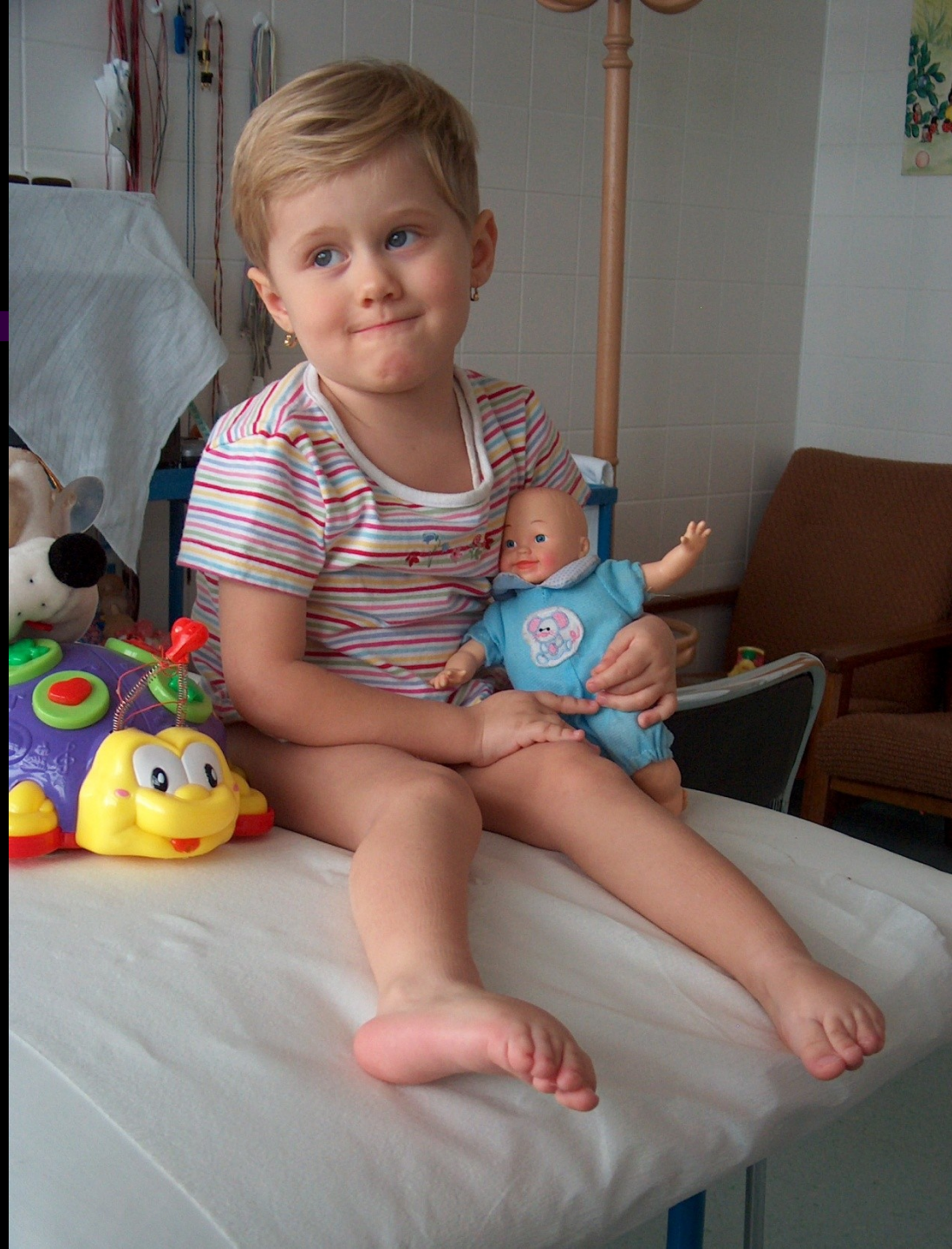- **ADHD - attention deficit-hyperactivity disorder**
- **specific learning disabilities**
- **autistic spectrum disorders**

## 4) Neuromuscular disorders





- **Muscular dystrophies**  
(congenital – CMD, Duchenne/Becker – DMD/BMD, limb-girdle – LGMD)
- **Spinal muscular atrophies (SMA)**
  - **Hereditary neuropathies**  
Charcot – Marie – Tooth (CMT)

# Case Report






- 
- Ester was a 4-month old female with presenting complaints of **muscle weakness and failure to gain developmental milestones.**
    - Family history was unremarkable, and no peri- or postnatal problems were noted.

- 
- **Her parents became concerned when the girl was not rolling over by 4 months of age.**
  - **At the time of the paediatric visit, she had no sucking or swallowing difficulties.**
  - **She had no history of respiratory problems or pneumonia.**

- She was noted to be hypotonic and was referred to neurology for further evaluation.
- She had markedly decreased muscle tone, strength and deep tendon reflexes – peripheral hypotonic syndrome was evident.
- In the resting position she maintained a frog leg posture.
- She had no head control on the traction maneuver.
- She had no weight bearing in vertical suspension, and an inability to support her weight at the shoulders.

- 
- **The Moro and tonic neck responses were absent.**
  - **In summary, the girl had a normal mental development, normal sensory functions, and abnormal motor development with peripheral hypotonia and inability to perform gross and fine motor skills.**

- **EMG showed a profound denervation and loss of motor unit potentials (MUPS), consistent with Motor Neuron Disease (MND).**
- **DNA analysis revealed deletion of exons 7 and 8 of the Survival Motor Neuron 1 (SMN1) gene on the 5q chromosome and verified the diagnosis of Spinal Muscular Atrophy (SMA) – Werdnig-Hoffmann Disease.**

# Summary 1



- **The neurological examination changes as the infant develops. The most marked changes occur during the first year of life. The gross and fine motor assessments are the most affected because myelin formation and cognitive development are essential to the development of these skills.**

## Summary 2

- **Age-related epileptic syndromes (e.g. West or Lennox-Gastaut syndrome) are a typical example of how affections of the brain during different stages of its development result in different clinical syndromes in paediatric patients.**