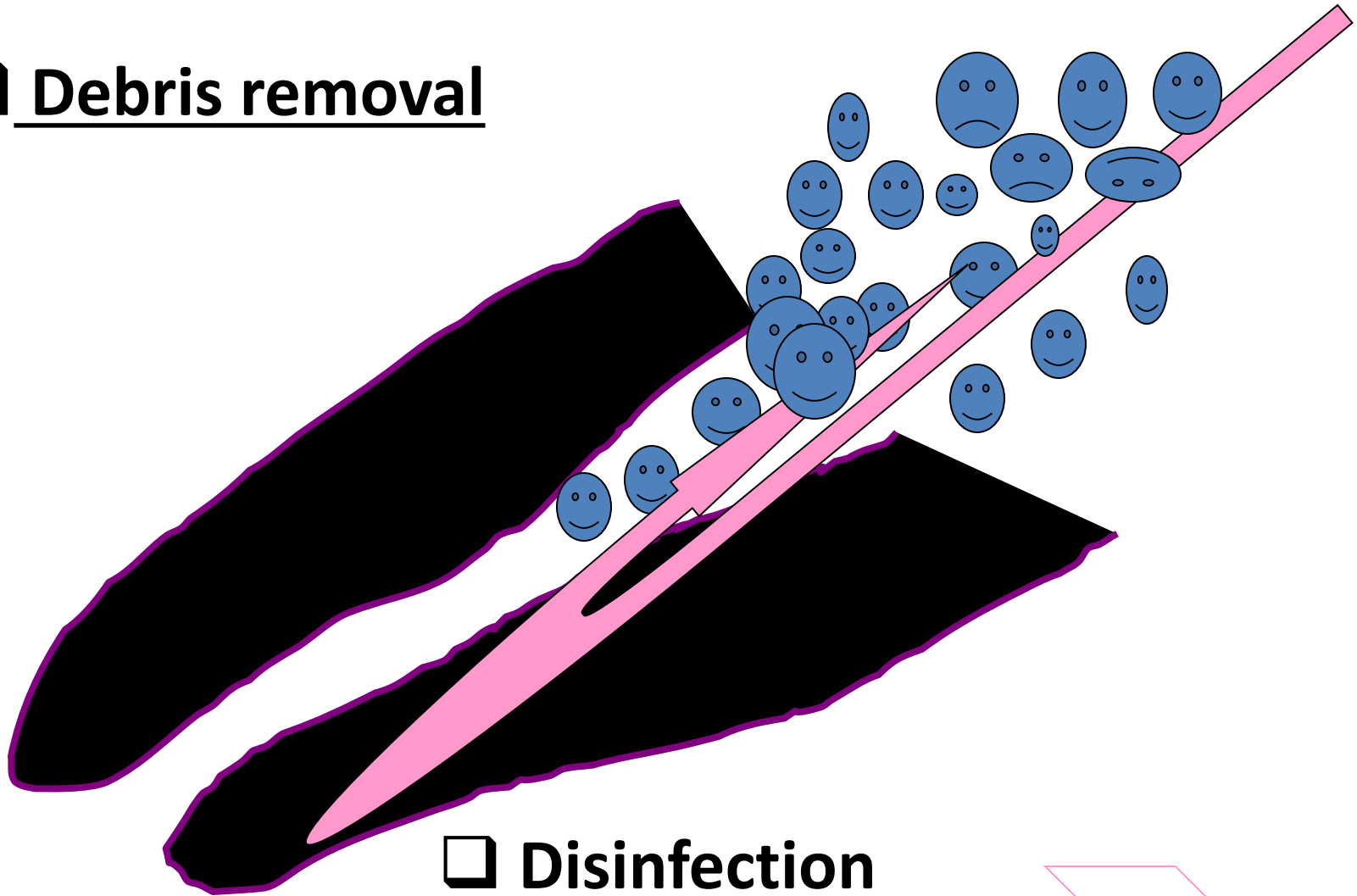


# Irrigation

Debris removal



Disinfection



# Irrigants

- Sodium hypochlorite (2 – 6%)
- Chlorhexidin (0,12% - 0,2%)
- Physiological solution
- EDTA – 17% (ethylendiaminotetraacetic acid)



# Root canal filling


- Power driven - lentulo  
Slow rpm (do 1000/min), in action when pulling out
- Hand – cold and warm techniques using guttapercha and sealer

Cold techniques:


- Single cone technique
- Lateral compaction

Warm techniques: warm lateral compaction, vertical compaction, injection and others.

Spreader

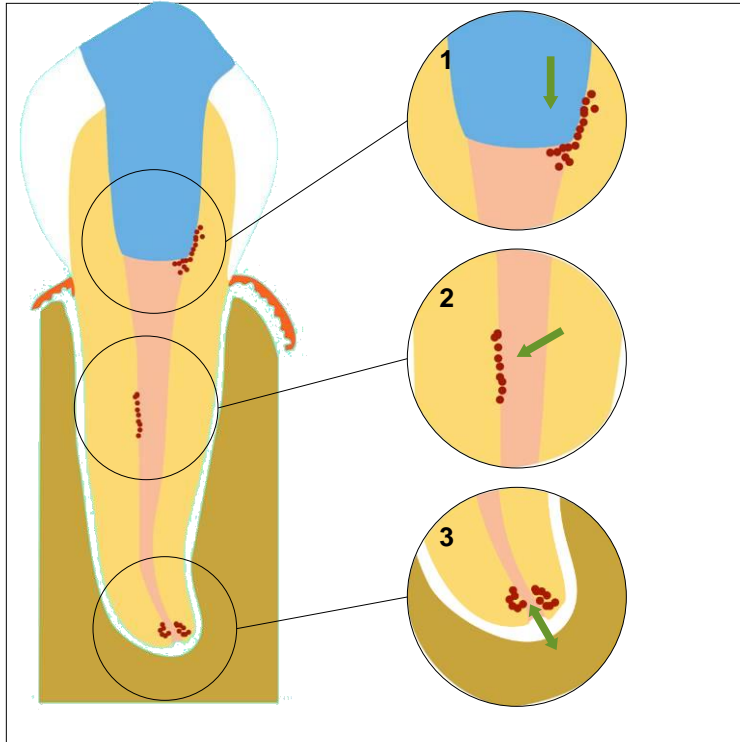


Plugger



Lentulo

# Function of root canal filling



1. **Good seal against infection and liquid**
2. **Close residual bacteria in root canal**

Quality guidelines for endodontic treatment,  
European Society of Endodontology (ESE), 1994

# Ideal root canal filling (Grossman 1988)

- 1. Easy mixing**
- 2. Sufficient working time**
- 3. Good seal**
- 4. X- ray contrast**
- 5. Easy removal**
- 6. No shrinkage**
- 7. Long term volume stability**
- 8. No bacterial growing**
- 9. No permeability for fluids**
- 10. Biocompatibility**
- 11. No staining**

# Classification of root canal fillings

➤ Solid

➤ Semisolid

➤ Pastes

# Guttapercha

Dried juice of the Taban tree (*Isonandra percha*)  
(gutta)

1,4 - polyisoprene

Crystallin structure (60%)

Brittle



# Guttapercha

- **Beta phase**
- **Alpha phase 42 – 49 °C**
  - plastic
  - **Gamma phase 56 – 62° (amorfní)**

## Cooling process

very slowly (less than 0,5°C) – alpha phase

normal cooling – beta phase

# Composition of guttapercha materials in endodontic

Guttapercha 19% – 22%

Zinc oxide 59 - 79%

Heavy metal salts 1% - 7%

Wax or resin 1% - 4%

# Sealers

## Chemically curing plastic materials

*Good adhesion to root canal walls as well as solid cones*

*X- ray contrast*

*Biocompatibility*

# Sealers

Zinc Oxide-Eugenol

Calciumhydroxide

Resins

Glasionomer

Silicone

# Sealers

## Importance

*Filling of the spaces between the solid cones*



*Seal of the root canal filling*

# Zinc - Oxid Eugenol

Powder:

Zinc oxide

Liquid:

Eugenol

Acidic resins

Good adhesivity, antimikrobial effect, cytotoxic.  
(resorbable)

# Zink Oxid Eugenol sealers

Pulp Canal Sealer (Kerr, USA))

Tubuli- Seal (Kerr, USA)

Caryosan (Spofa Dental, ČR)

# Calciumhydroxide sealers

Base ( powder)

Calcium hydroxide

Zinc oxide

*Other components and vehicula*



# Calcium hydroxide sealers

Catalyst (paste)

Zinc stearat

Titanium dioxide

Baryum sulphate

or

Eugenol,. Eukalypt

others

# Calcium hydroxide sealers

- Increase of the healing potential of periapical tissues
- Antibacterial effect
- Easy manipulation

*But!*

*Resorbable if not homogeneous*

*Not suitable for the single cone technique*

# Resins

➤ Rezorcin formaldehyd

➤ Epoxide

➤ Polyketone

➤ Metacrylate

# Rezorcín – formaldehyd resins

## Toxicity

N2, Endomethason, Riebler's paste, Foredent

# Epoxide resin

➤ Base (powder, paste)

Bismuth oxid

Titanium dioxide

Hexametylentetramine

(Silver)

➤ Catalyst (liquide, paste)

Bisphenoldiglycidylether

## Epoxid resin (*advantages*)

- Long working time
- Hydrophilic (good penetration)
- Good adhesion to the root canal walls
- Volume stability
- No dissolution
- Antibacterial

# Epoxid resin (*disadvantages*)

- Difficult removal
- Staining
- Initiatory roxicity

# Polyketone

## ➤ Base

Zinc oxide

Bismuth phosphate

Hexametylentetramine

## ➤ Liquid

Bisphenolglycidylether and other components



# Polyketon resins

## Advantages

Good adhesion

No contraction

No dissolution

## Disadvantages

High stickness

Not removable

Products: Diaket, Diaket A (3M ESPE)

# Methacrylate resins

Endo ReZ (Ultradent) – UDMA

For injection – single cone technique

Epiphany (Pentron)

Bis- GMA, etoxy bif- GMA, hydrophilic bifunctional methacrylates

Calcium hydroxide, baryum sulphate, baryum glass silica.

***Sealer in combination with Resilon***

# Glasionomer sealers

- Base (powder)

Aluminium silicate glass

- Liquid

Polyacrylic acid, polymaleic acid, tartaric acid

# Glasionomer sealers

## *(Advantages and disadvantages)*

### Advantages:

Curing under wet conditions, chemical bonding to hard dental tissues, no staining

### Disadvantages

Short working time, difficult removal,  
porous

### Products

Ketac Endo (3M ESPE), Endion (VOCO)

# Silicon based sealers

Polyvinylsiloxane (ev. in mixture with powdered guttapercha)

Biocompatibility

Hydrophilic

*Further investigation desirable.*

# Root canal filling

- A cone inside the sealer – core material

Guttapercha

Resilon

Silver cones

Custom cones

# Root canal filling

Guttapercha

Trans isomer of polyisoprene

2 crystalline forms (alpha, beta)

Beta – room temperature

Alpha after heating

Various process of cooling

Extremely slow cooling: Alpha phase recrystallize.

65°.

Less shrinkage, more dimensionally stable

# Root canal filling

Guttapercha

20% gutta-percha

65% zink oxide

10% radioopacifiers

5% plasticizers



# Root canal filling

Guttapercha

Cones: conventional and standardized sizes

Conventional: dimension of the tip and body

Standardized cones are designed to match the taper of the instrument.

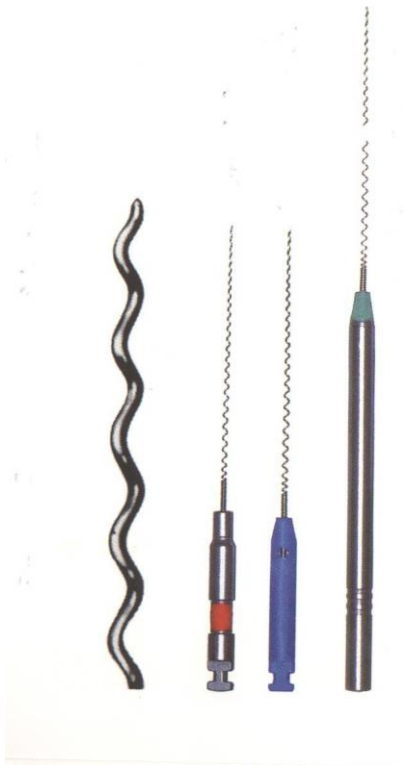# Root canal fillings - forms

- **Points (Cones)**
- **Materials for injection**
- **Plastic materials**

# Instruments

- Lentulo
- Compactors
- Compactors - carriers
- Others

# Lentulo




➤delivers pastes

➤1,5 – 2 mm ahead

➤at most for  $\text{Ca}(\text{OH})_2$

# Compactors

Spreader



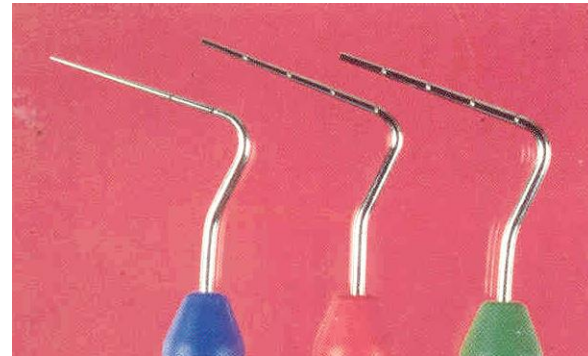
Pointed

Vertical introduction

*Lateral condensation*  
*technique* ↓

# Compactors

## Plugger



Not pointed

Vertical introduction

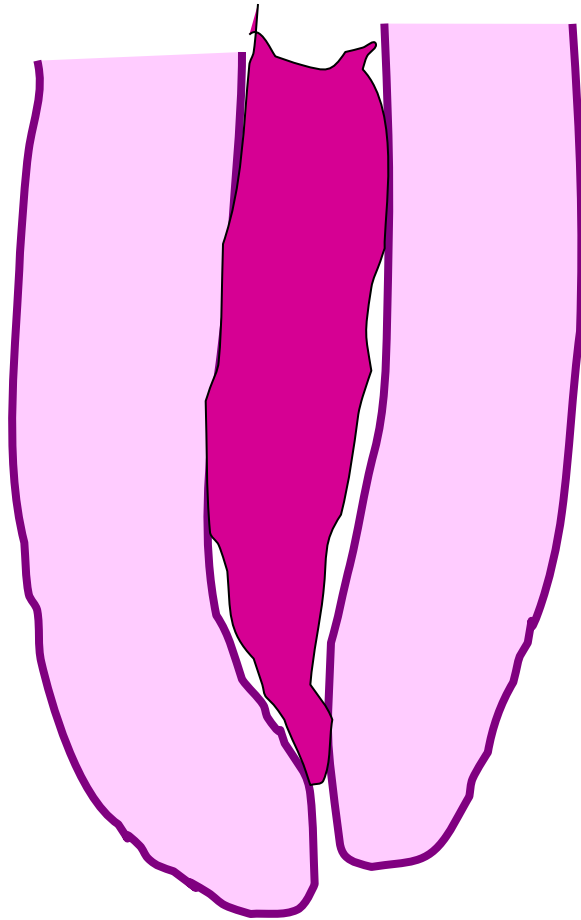
*Vertical condensatuion  
- compaction*

# Filling techniques

Cold

Warm

# Paste only

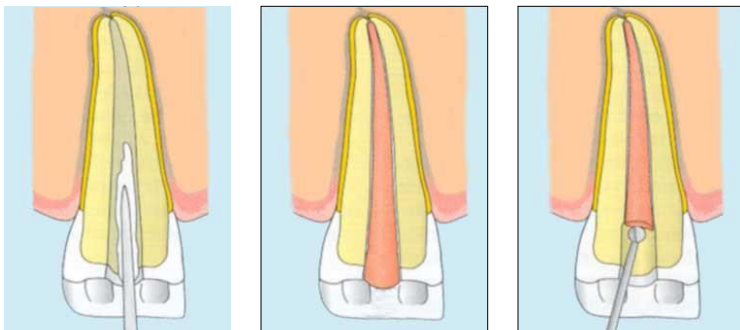



**Shrinkage, difficult  
removal**

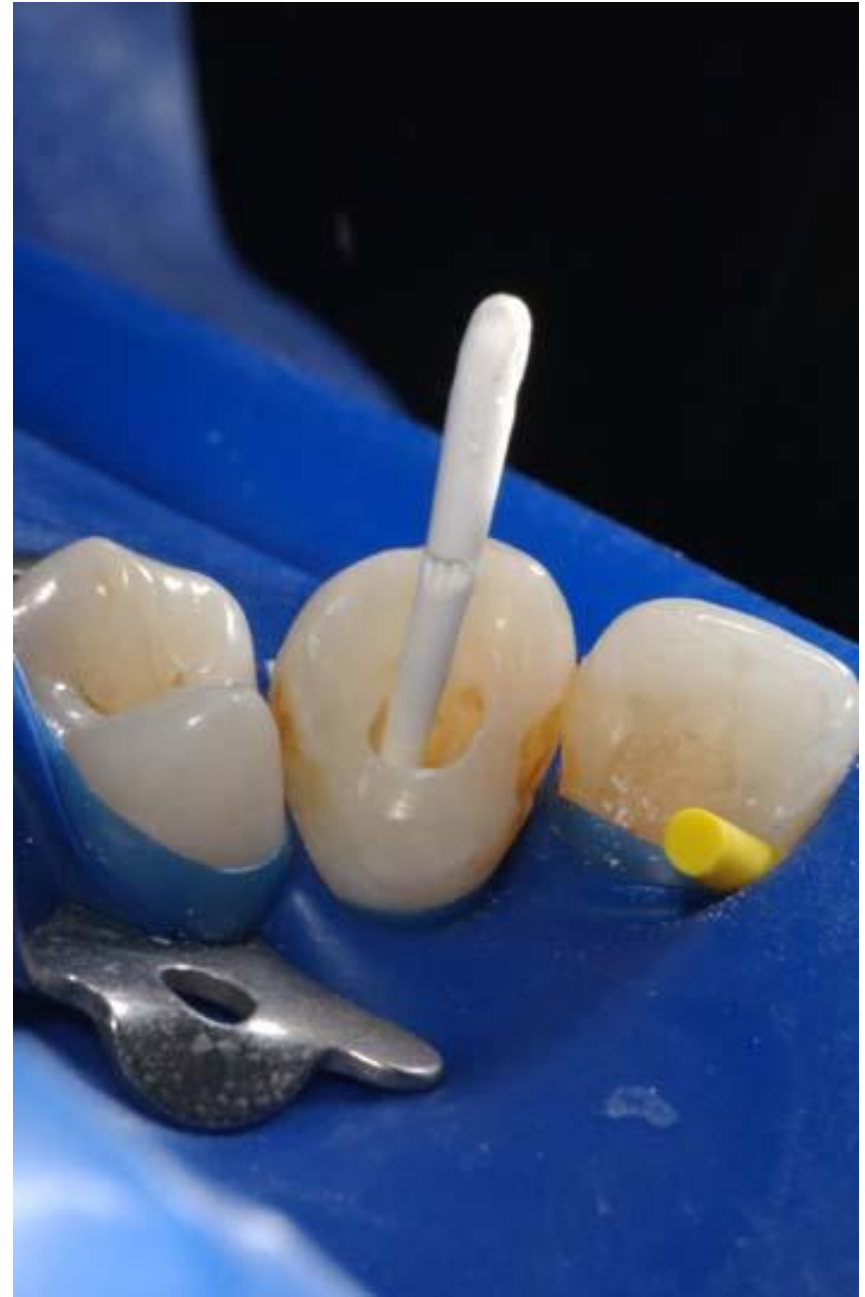
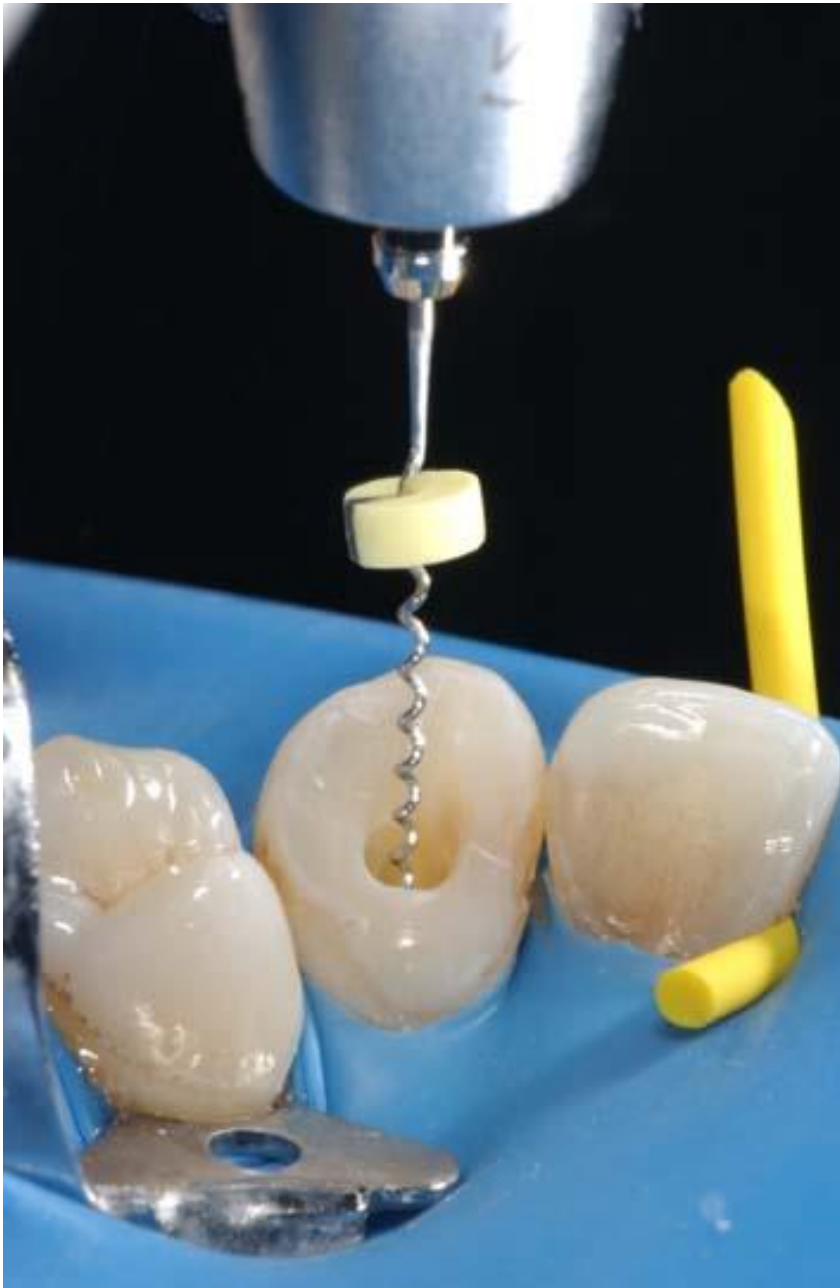


# Single cone technique

- Easy
- Fast
- Good control of WL
- Standard round preparation – risk of leakage

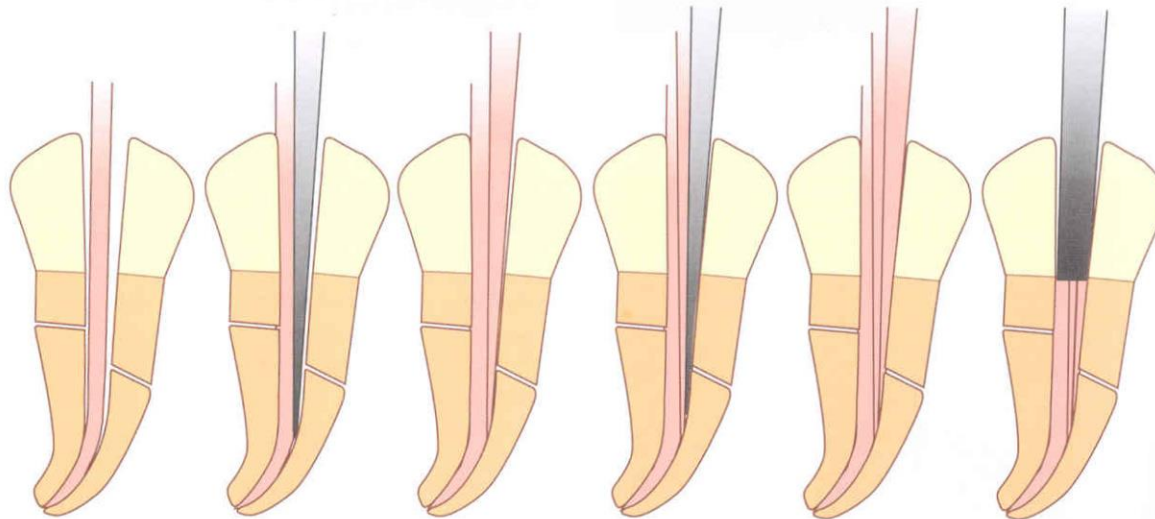


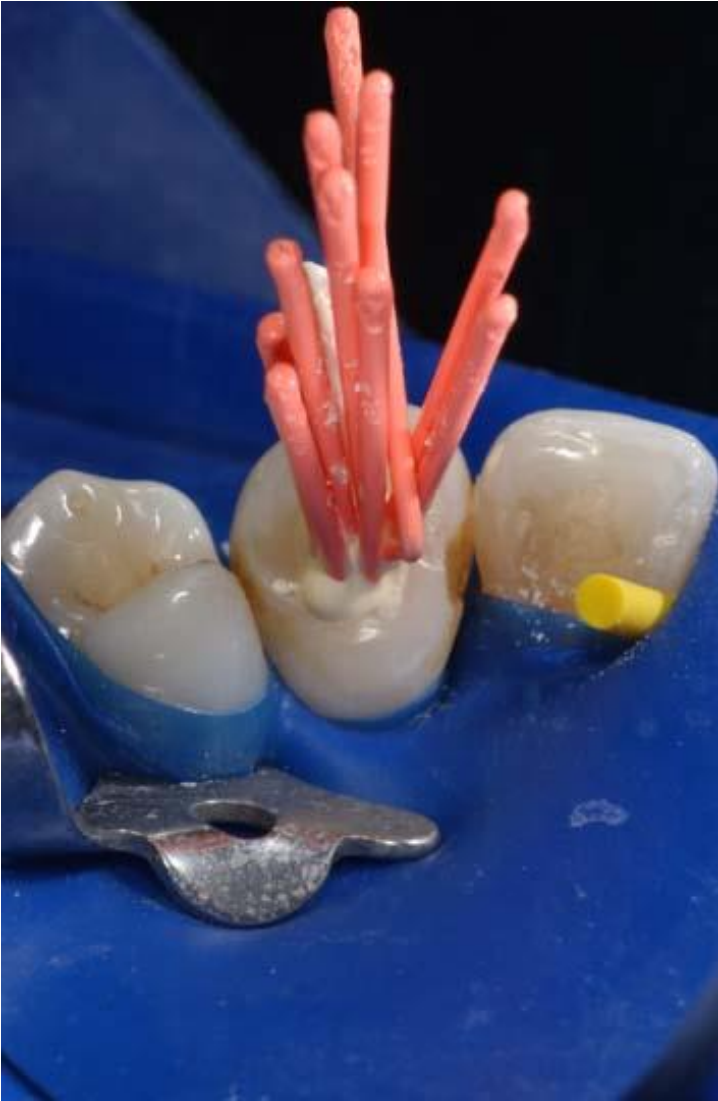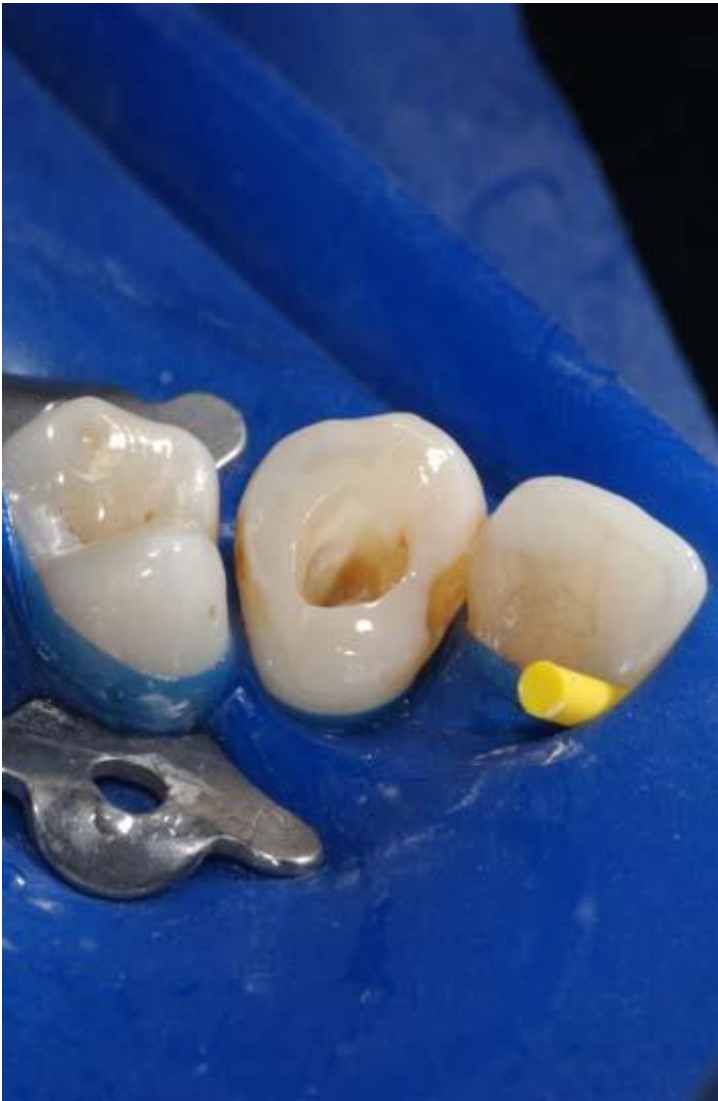Wesselink, P.: Root filling techniques, Textbook of Endodontology; p. 286-299, Blackwell Munksgaard 2003, Oxford



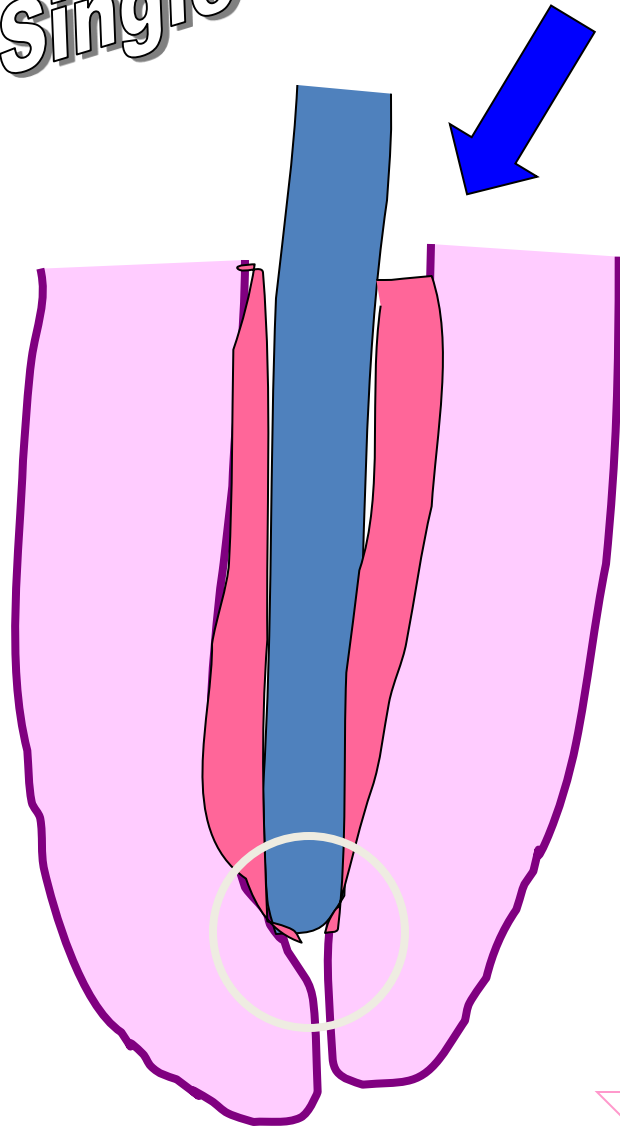


A

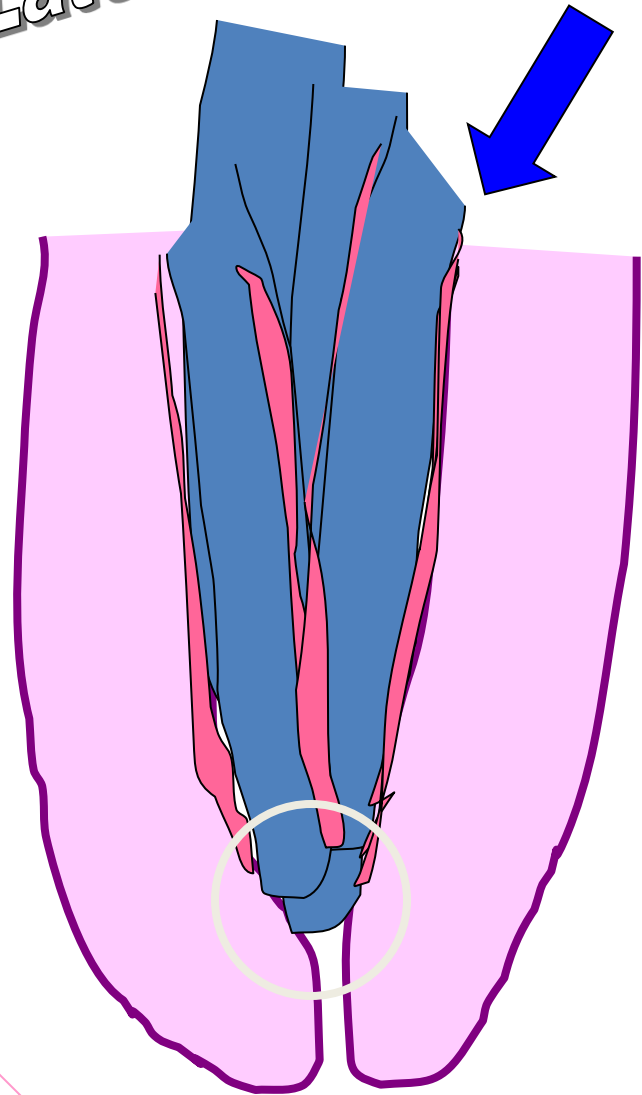




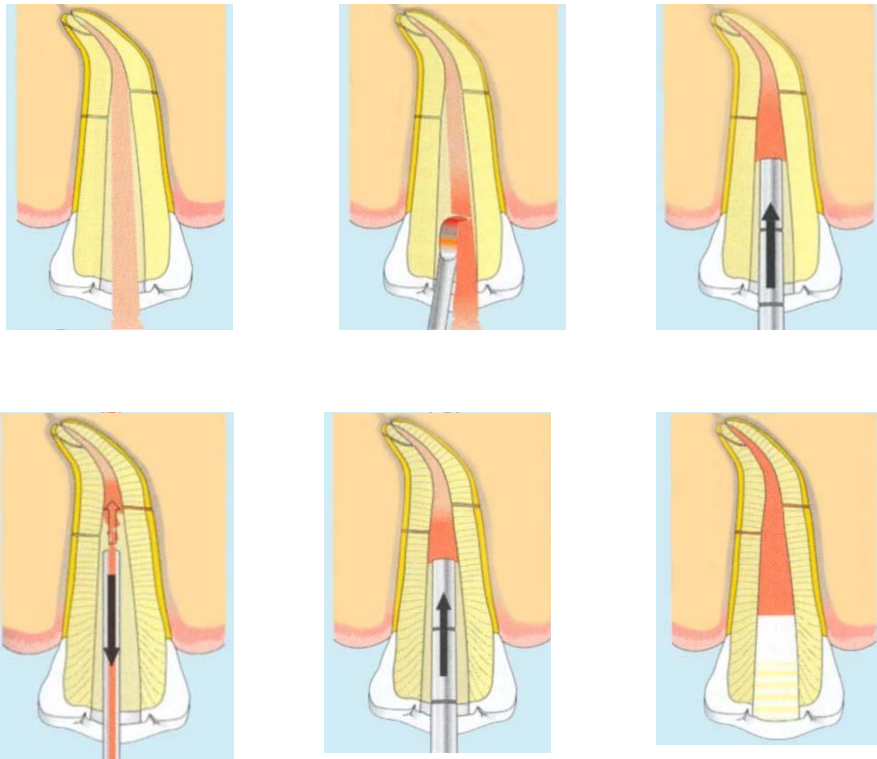
Single cone



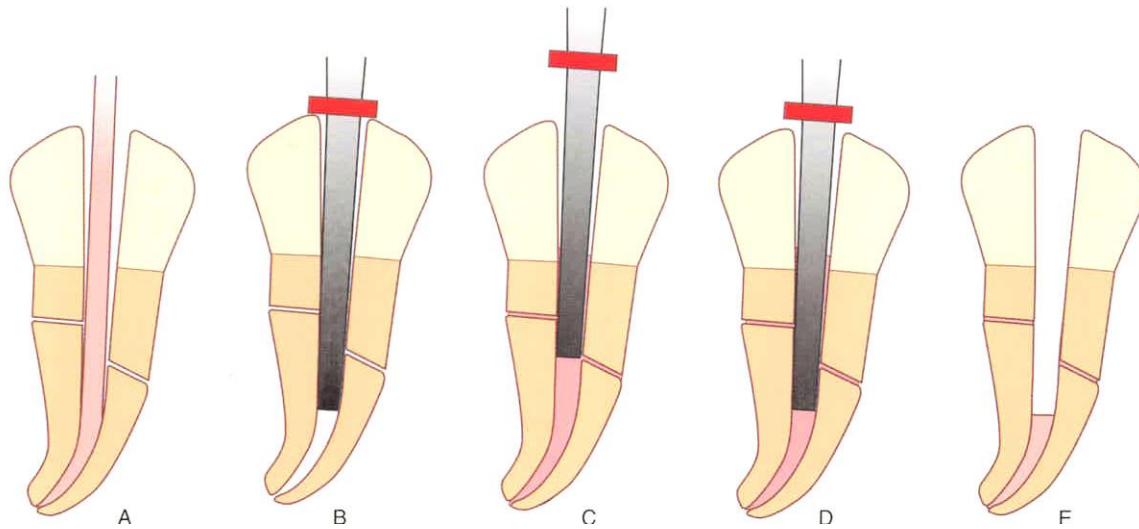
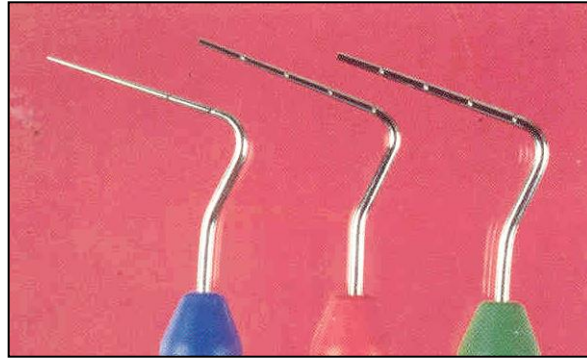Lateral compaction



# Vertical condensation (compaction)

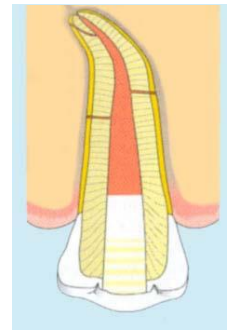
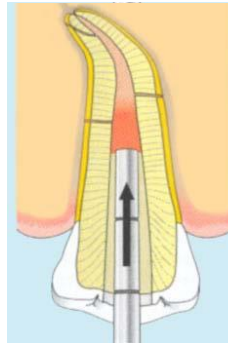
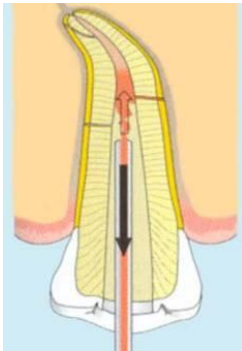






# Injection

- Rychlá technika
- Možná extruze sealeru
- Teplo



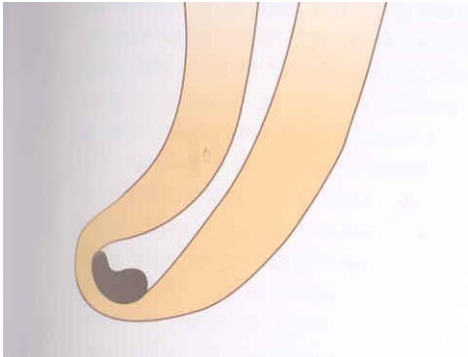
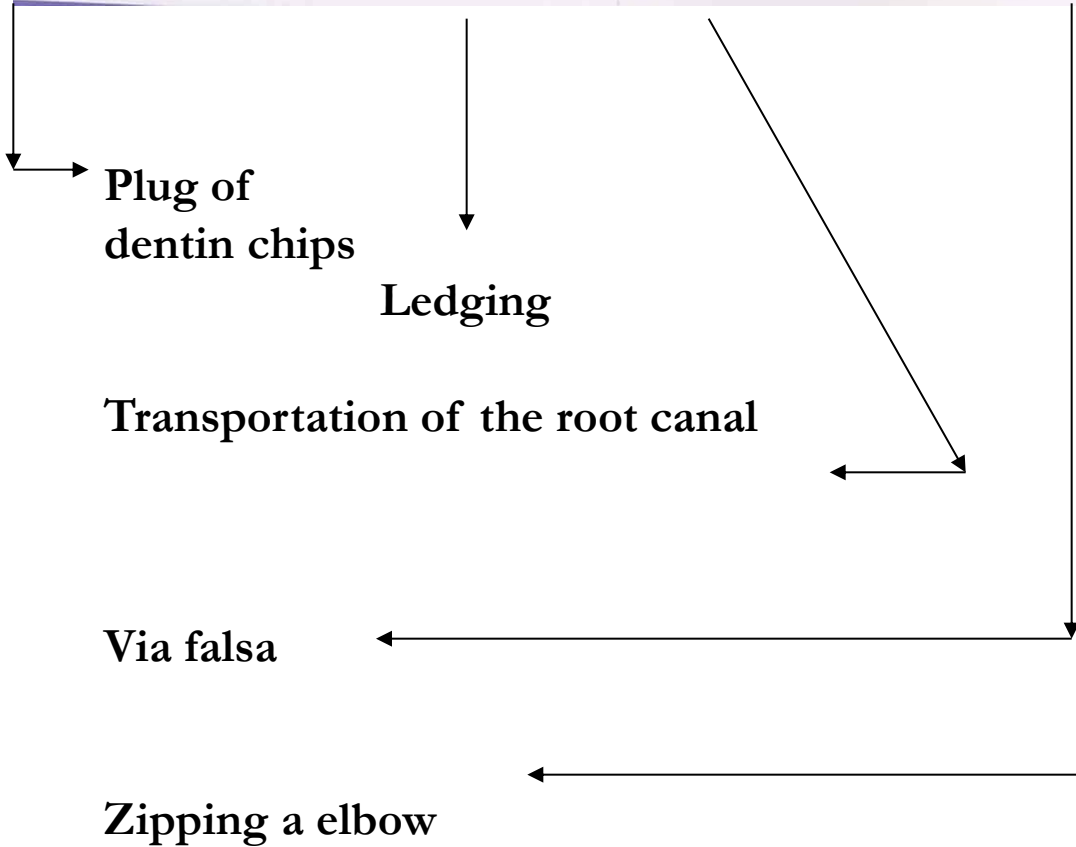
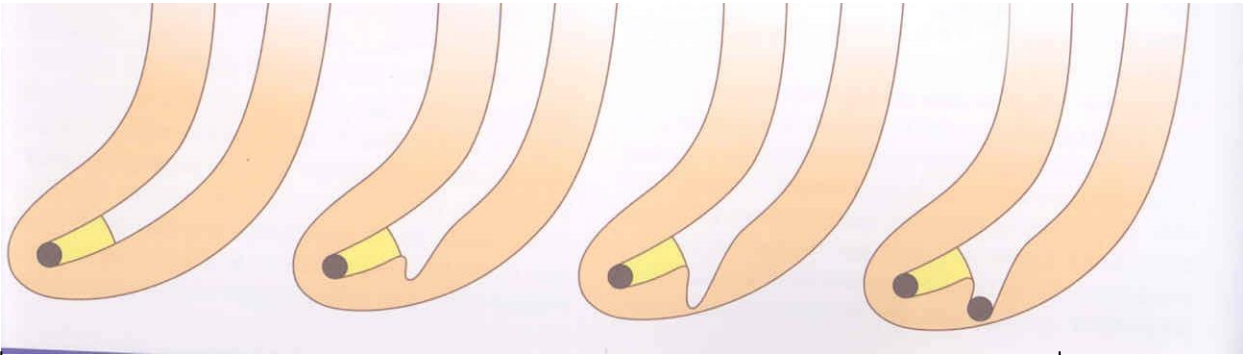


# Complications of endodontic treatment

**Local**

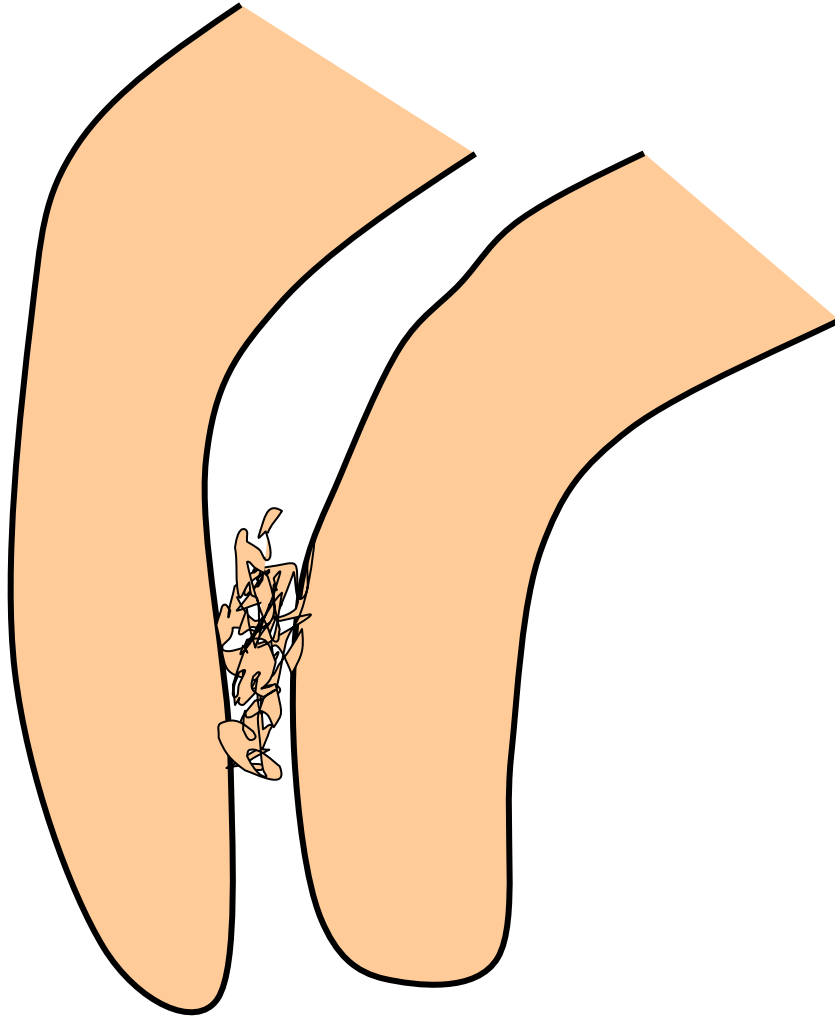
**Regional**

**Systemic**



# Local complications

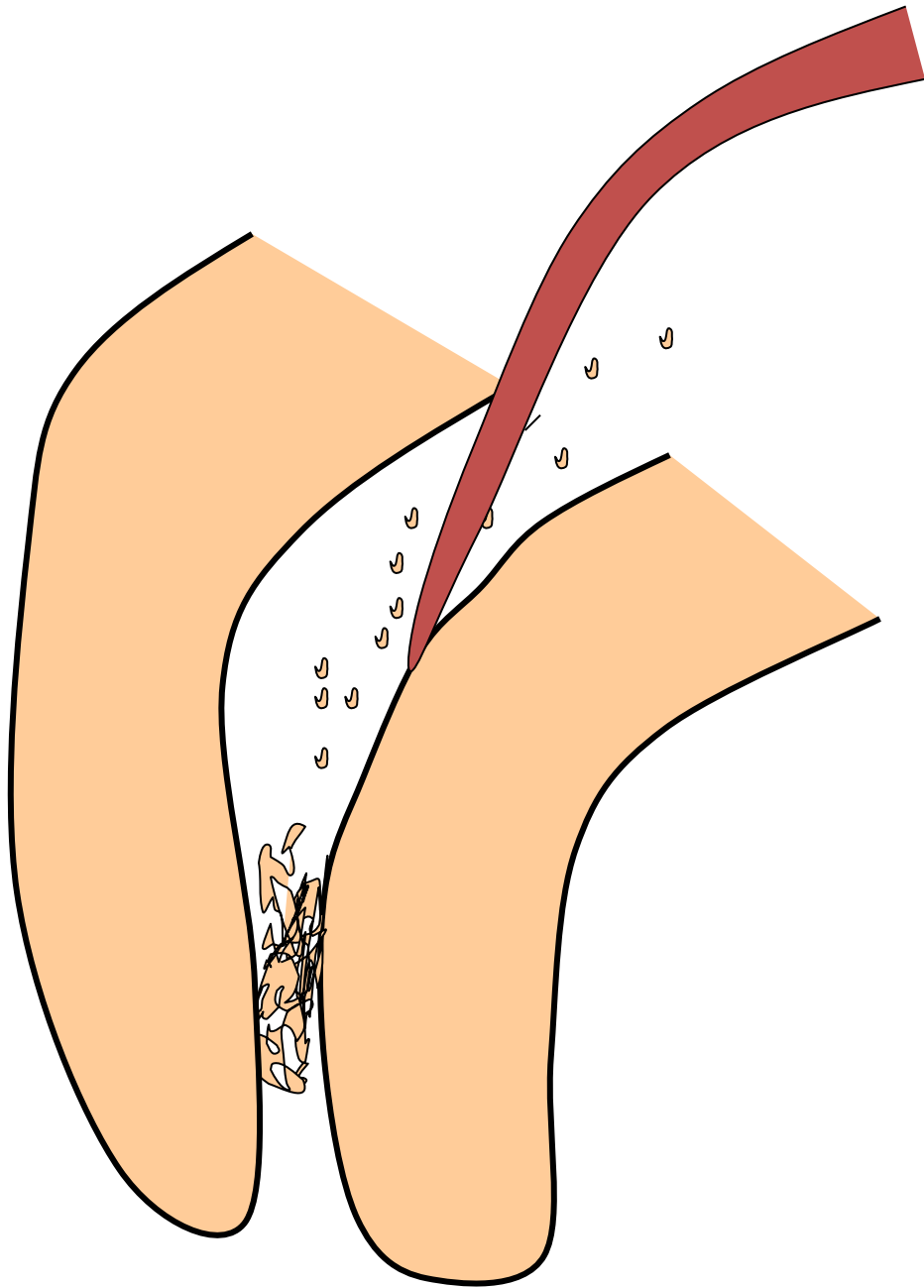
# Plug



## Reasons

**Insufficient irrigation and  
recapitulation**

*Loss of the working length*




## Solution

**Repeated careful  
instrumentation  
with a thin  
instrument**

*Irrigation is not  
effective in this  
case!!!*

# Ledging



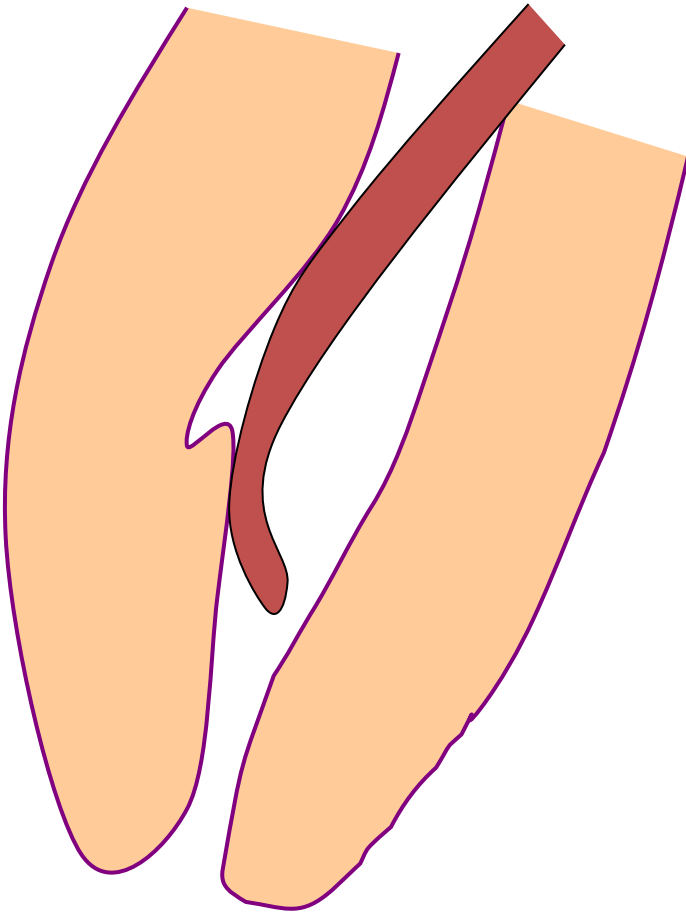
## Reasons

**The instrument is not bended in advance!**

**No control of the WL**

**=**

**No recapitulation Loss of the WL**



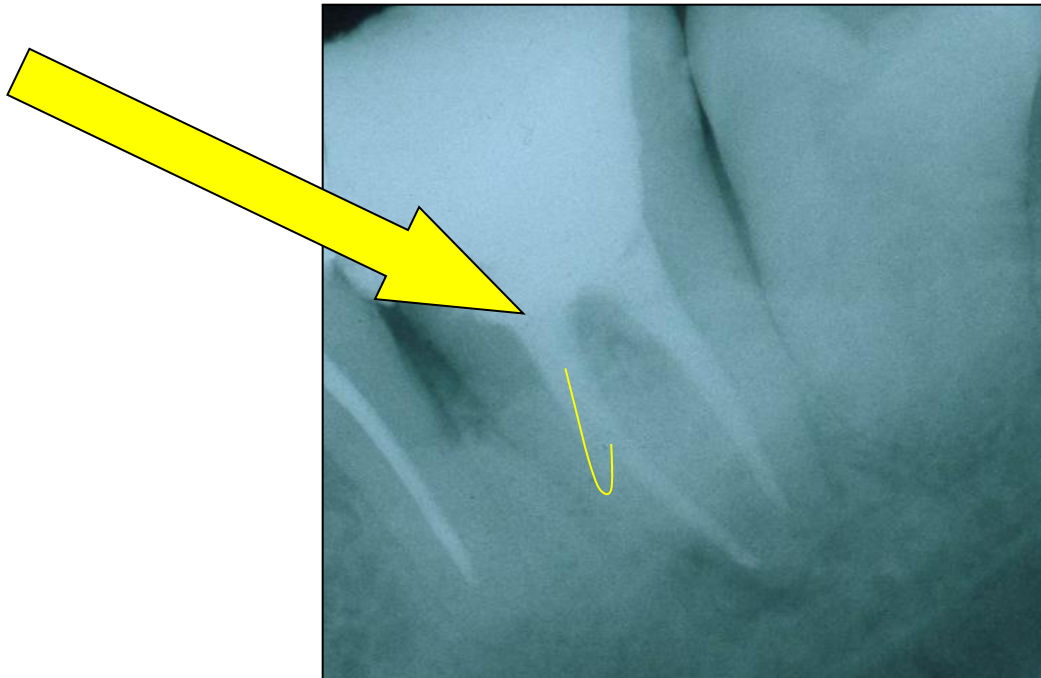
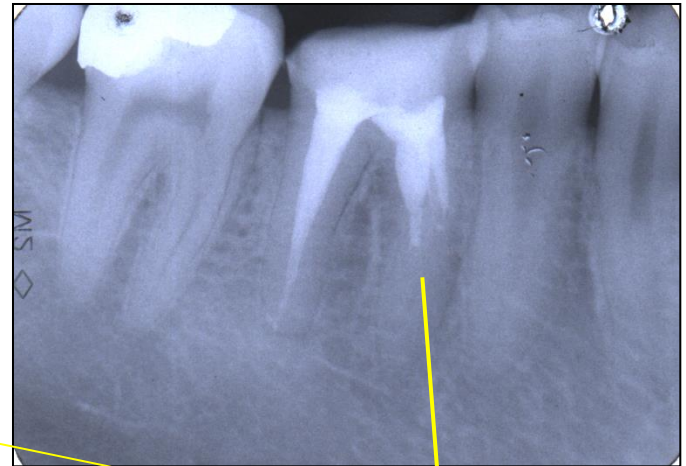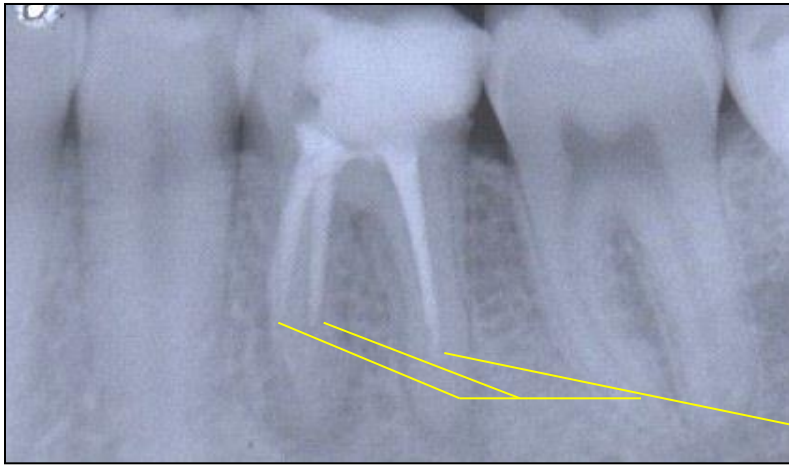
## Solution

The instrument must be  
bended in advance

Careful but complete rotation

Finishing with the fine filing

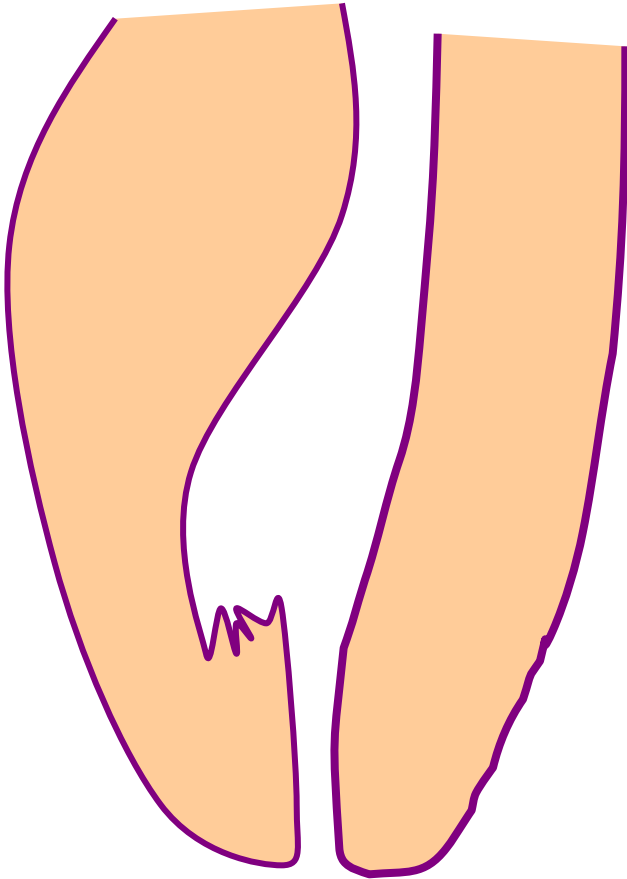
*No NiTi!!!*



**Ledging**

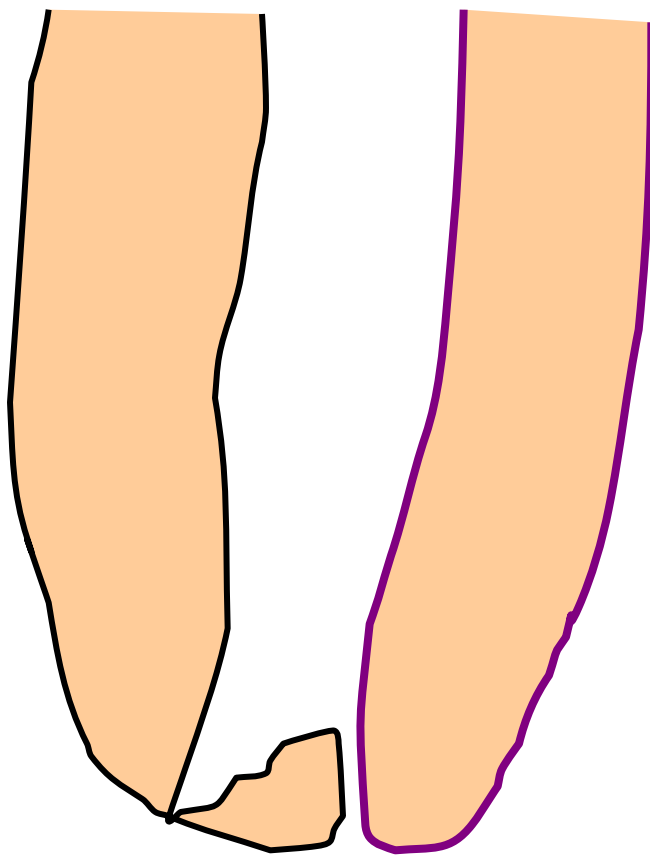
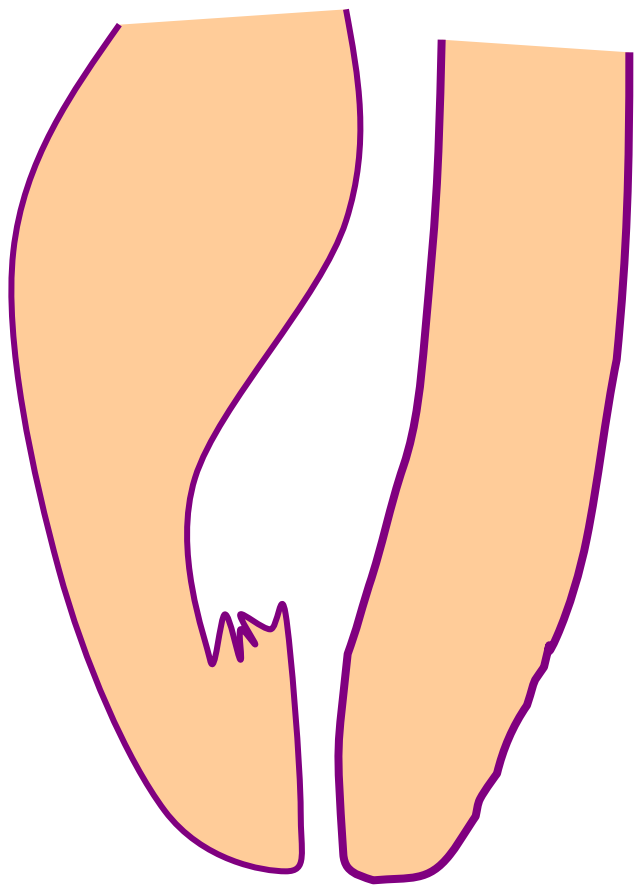
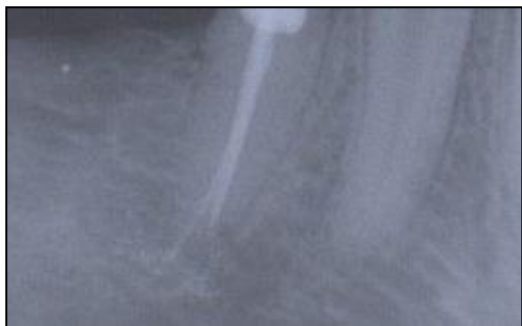

# Zippering a Elbow



**The instrument is not bended in advance!**

**Rotation in curved canals**



# Stripping

## Reasons

**Bad orientation in morphology – no diagnostic x-  
Instruments are not bended  
Rotary NiTi with a big taper**

*Dangerous zones*

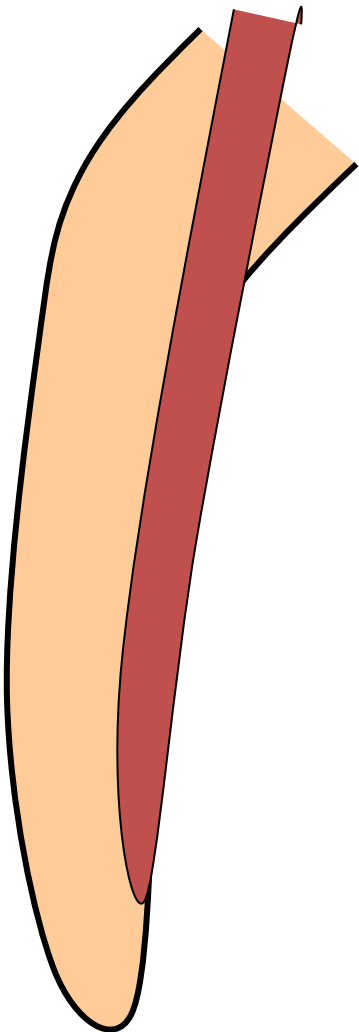
*Mandibular molars – mesial roots*

*Premolars, esp. maxillar*

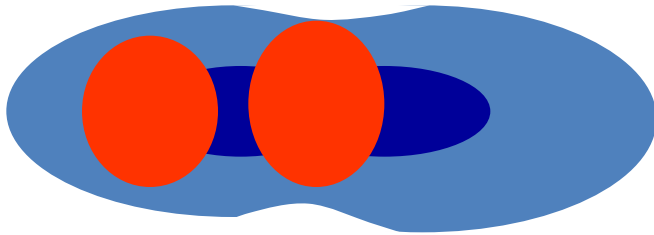
*Mandibular incisors*



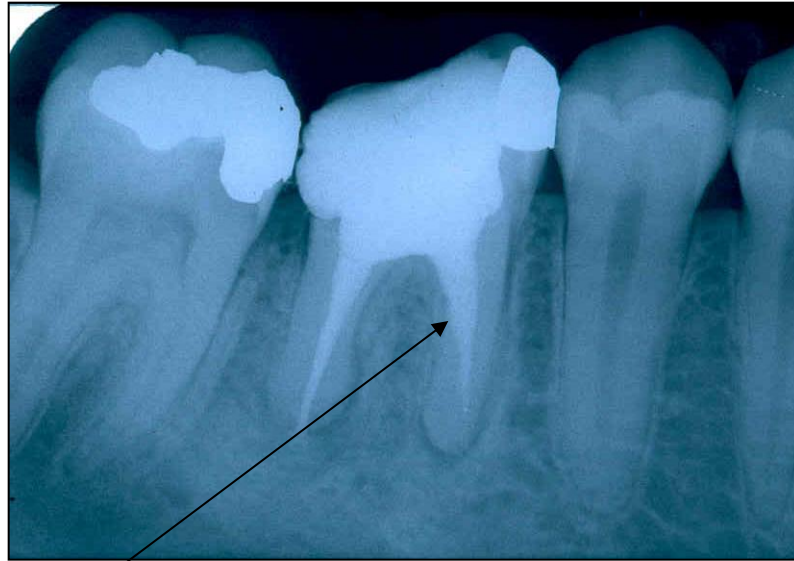*Oblast isthmu*



# Stripping



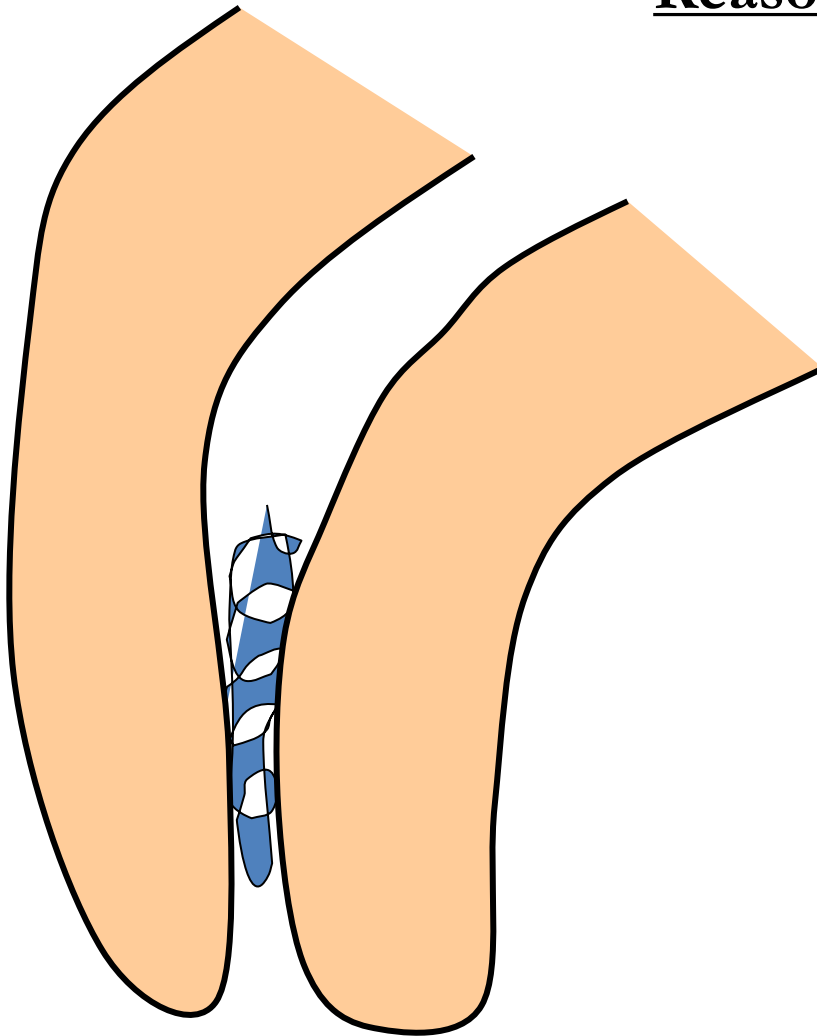
# Stripping



**Bend the instrument and eventually blunt it !**

# Fracture of the root canal instrument

## Reasons



**Insufficient  
coronal flaring**

**Old root canal  
instrument**

**Aggressive force**

**Incorrect  
movement of the  
root canal  
instrument**

## Solution

Enlargement of the  
root canal till the  
instrument

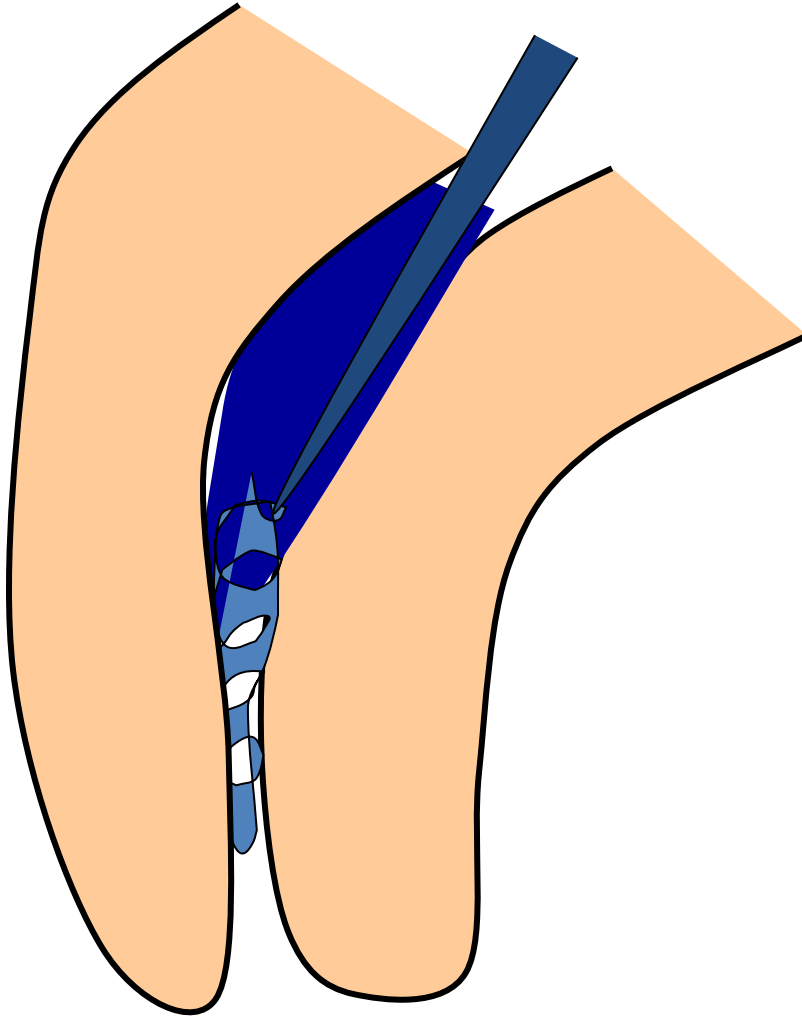
Ultrasound tips

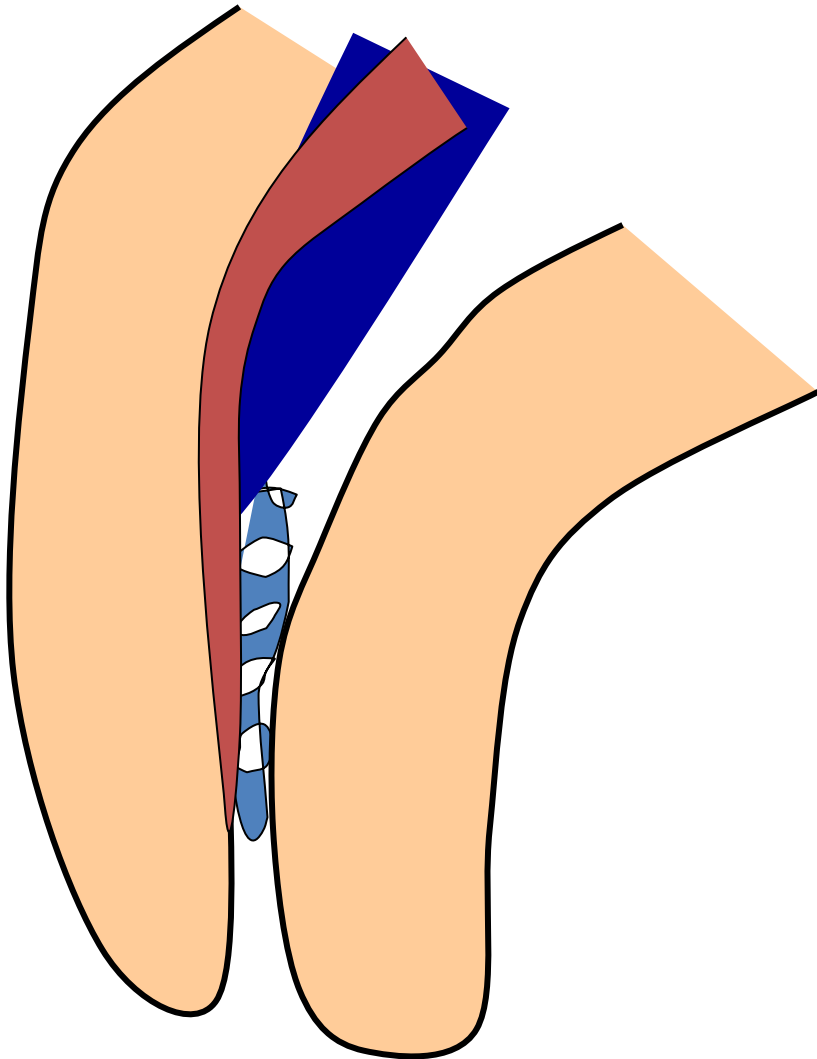
Rotating root canal  
instrument – caution!

Bypass

Leaving in

Surgical treatment

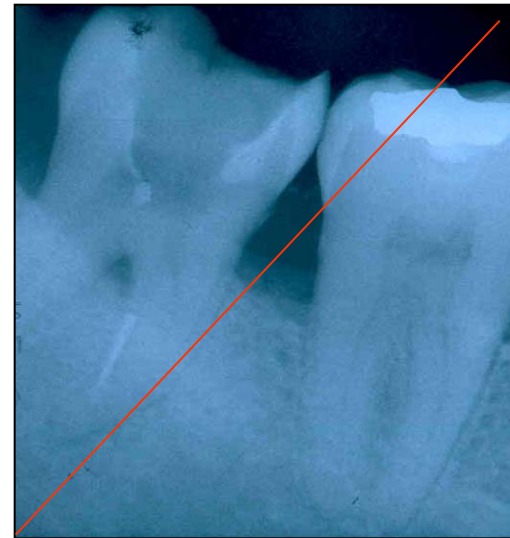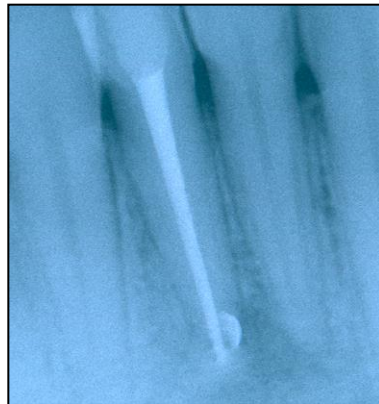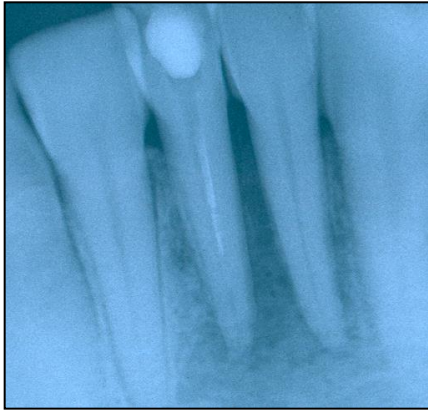




**Bypass**



# Fractured instrument



# Via falsa

- Perforation of the bottom of the pulp chamber or the coronal part of the root canal
- Perforation in the middle part of the root canal
- Apical perforation

LOT 000724 EXP 0507

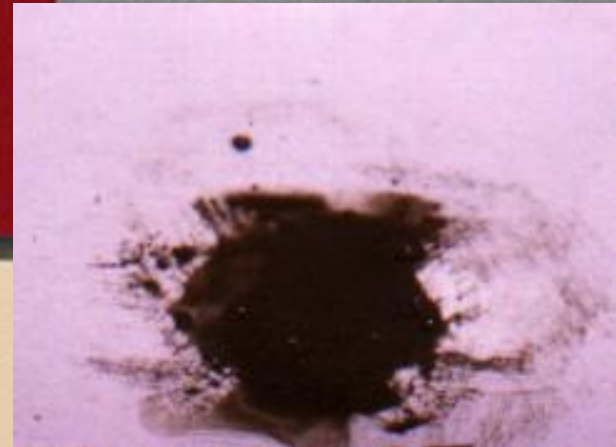
DENTSPLY

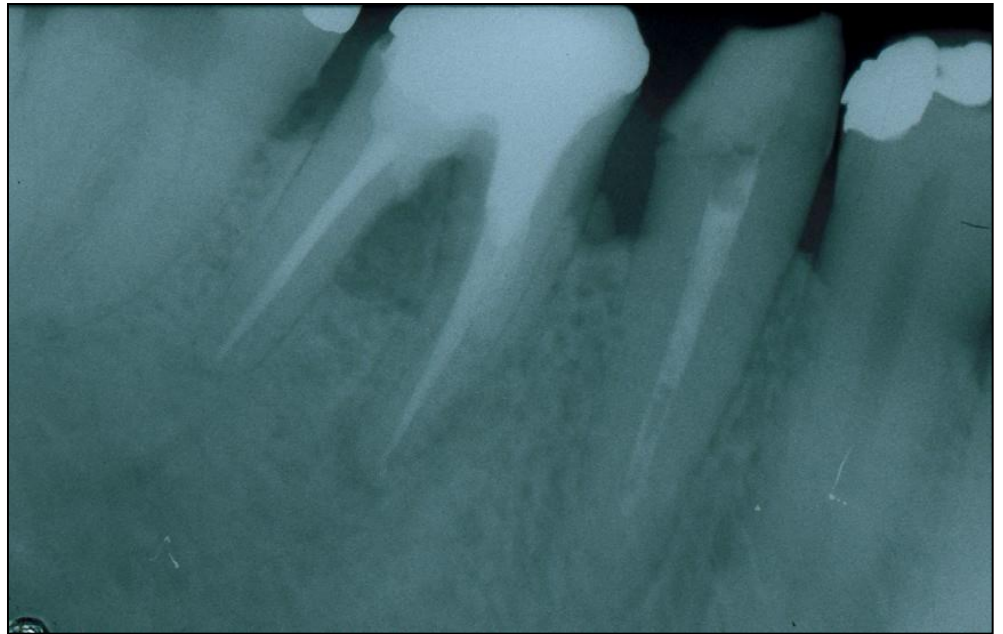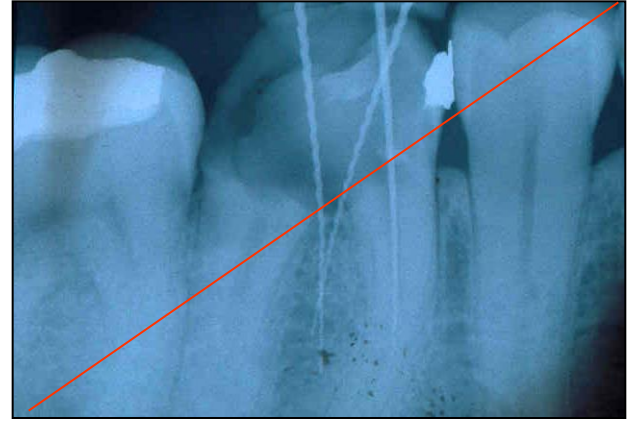
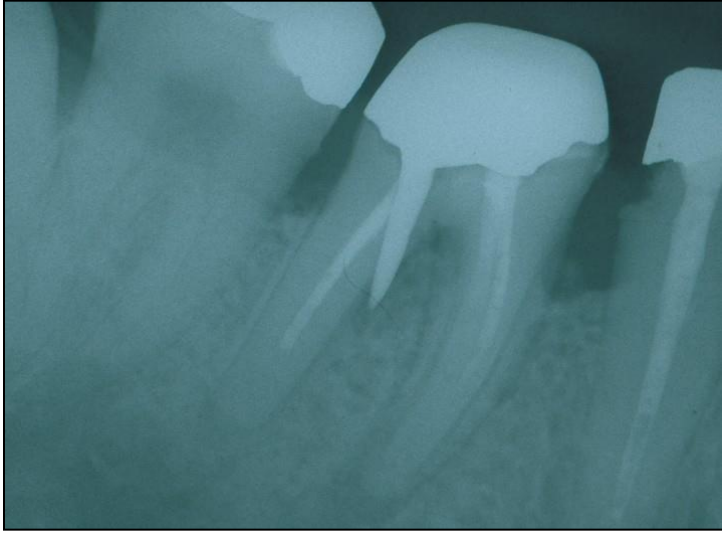
# PRO ROOT™

*MTA (Mineral Trioxide Aggregate)  
Root Canal Repair Material*

Contents: 1 gram (1 treatment)

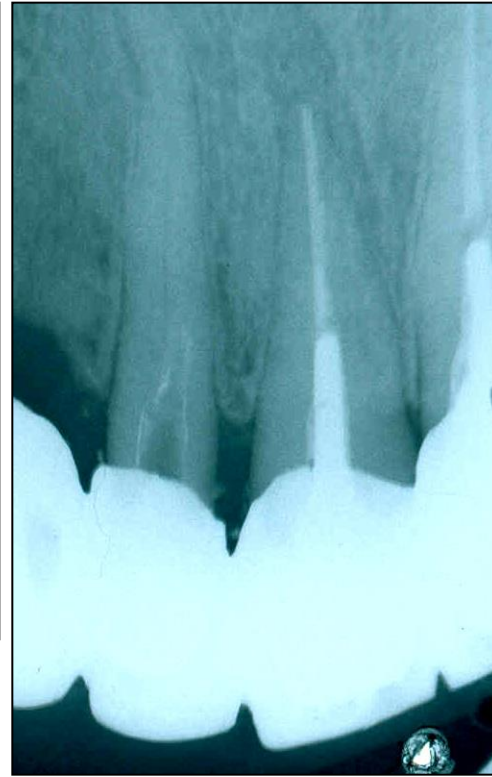
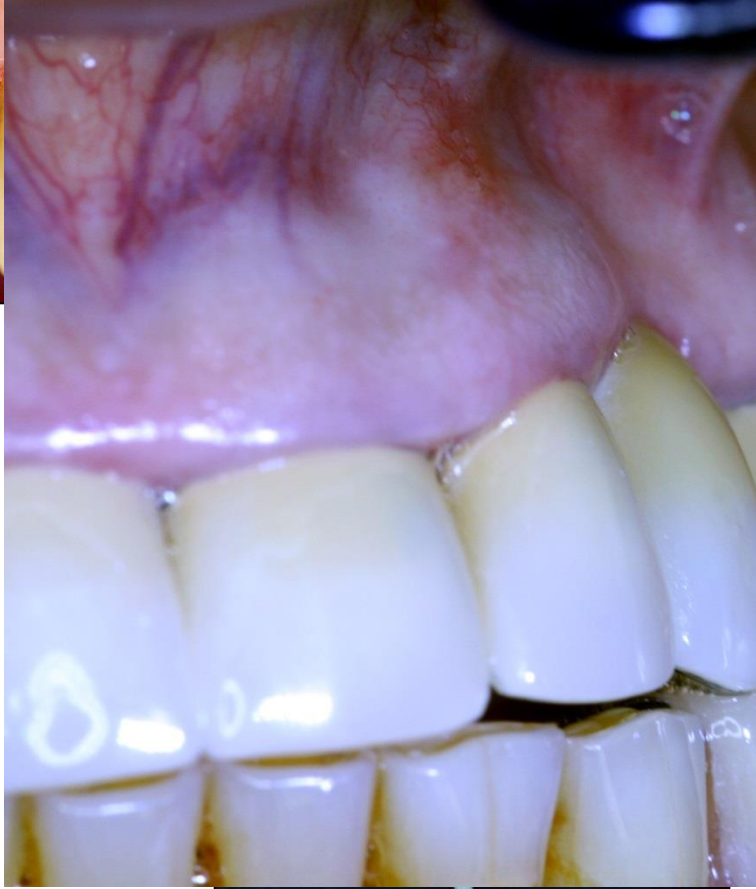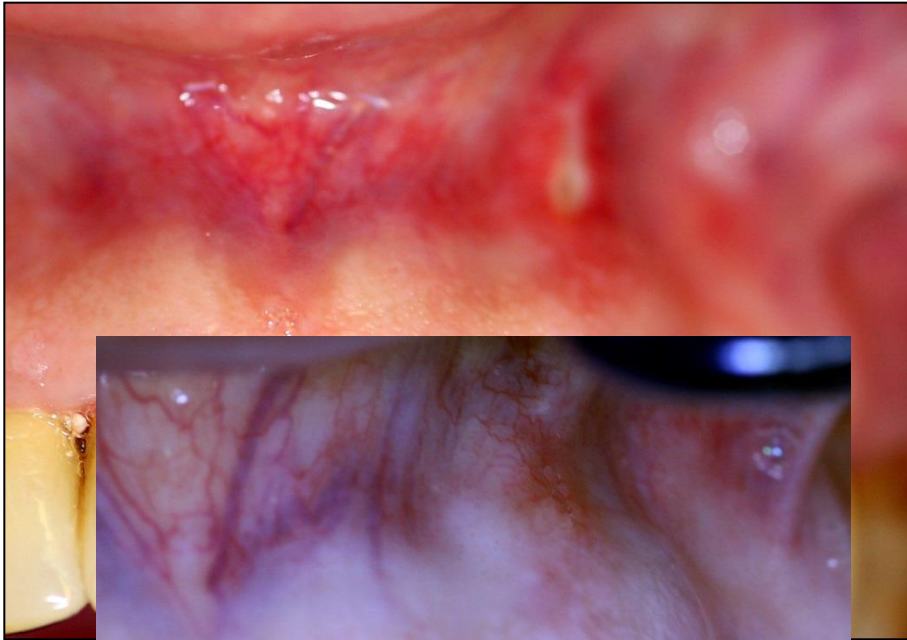
CE  
0120

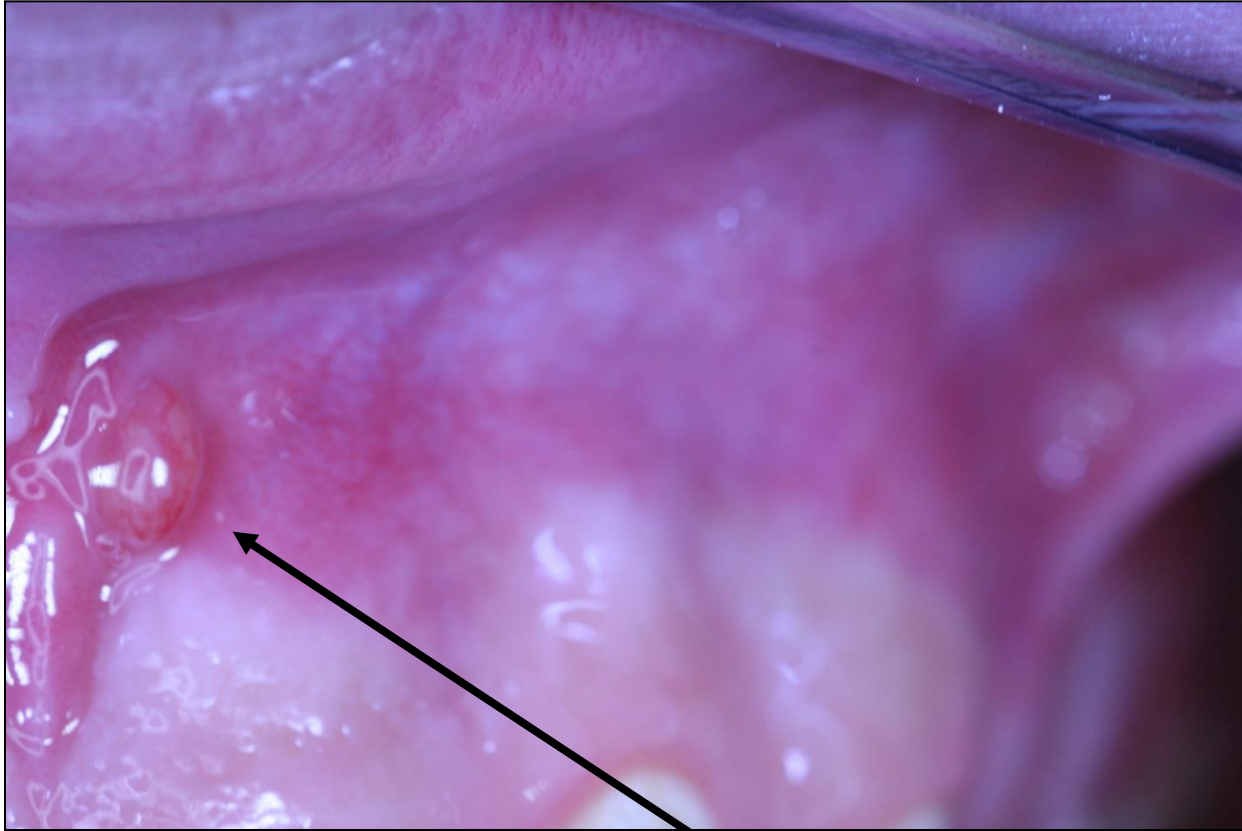




# Regional complications







**Píštěl**

# Systemic complications



# Systemic complications

- Periostitis
- Inflammation of soft tissues (face, neck)
- Gulp of the instrument (X ray, remnant diet, information)- cough
- Aspiration of the instrument (induce emesis, x-ray, evaluation)

