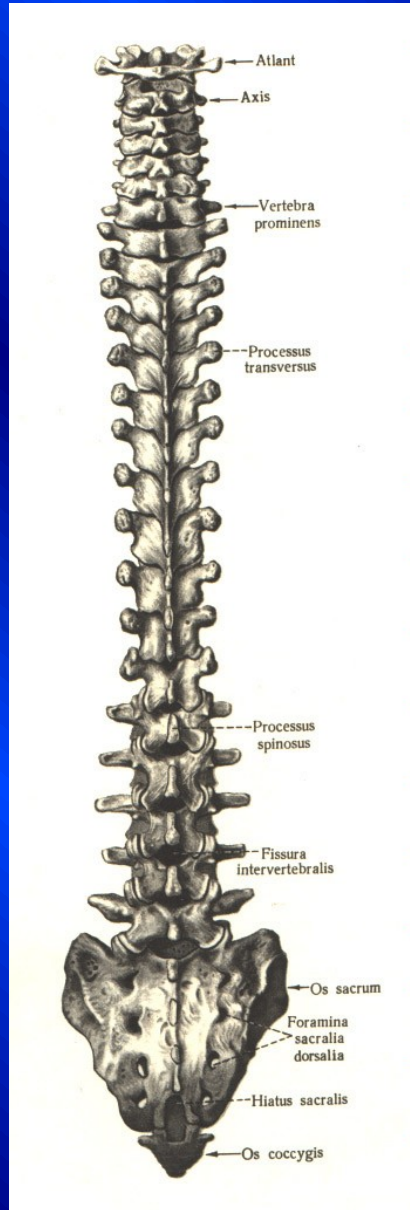


Spinal deformities

Physiological curves of the spine

Frontal level



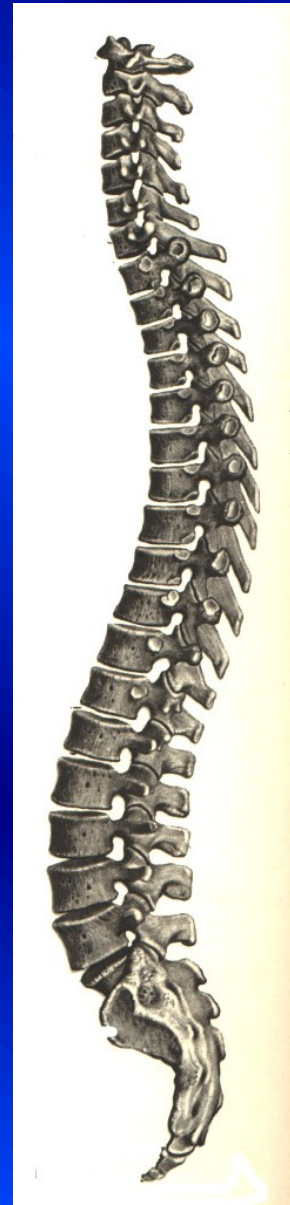
Sagittal level

Cervical lordosis

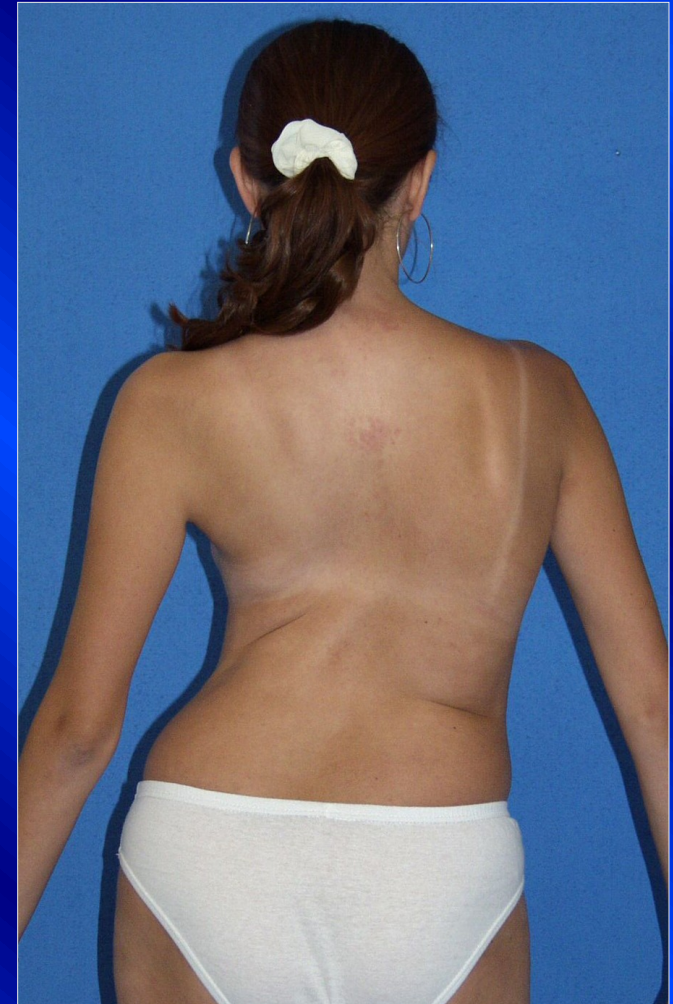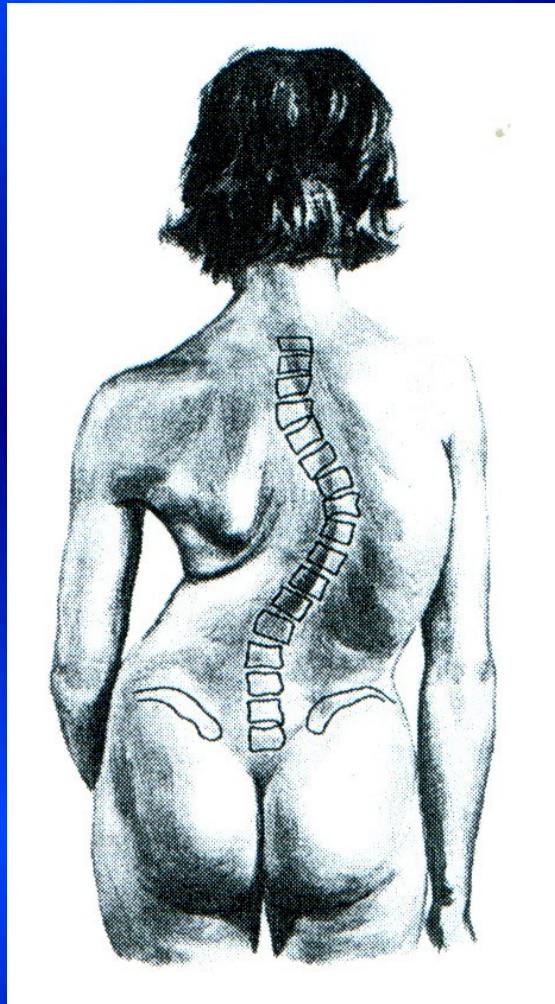
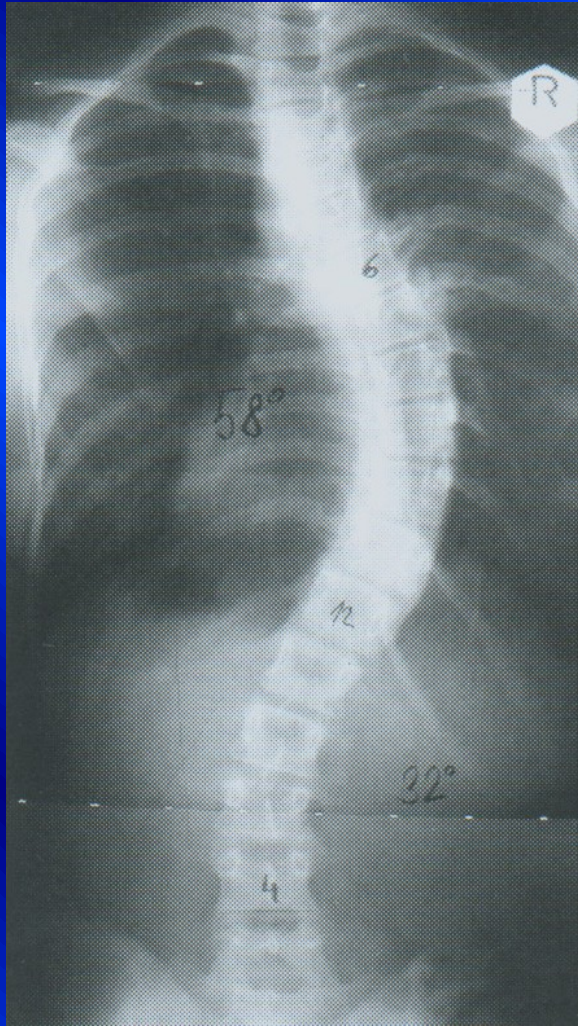
Thoracis kyphosis

Lumbar lordosis

Sacral kyphosis

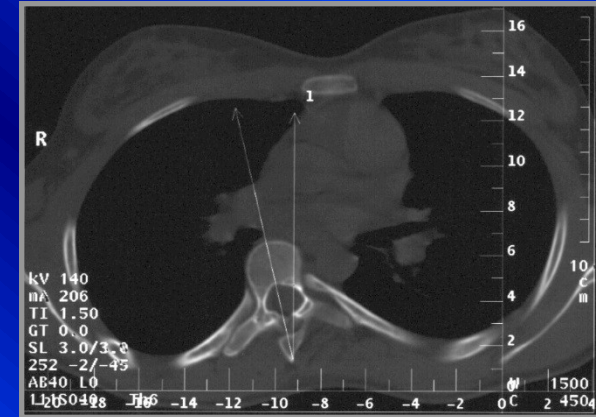

Scoliosis is a deformity in frontal level
in sagittal level and in transversal level

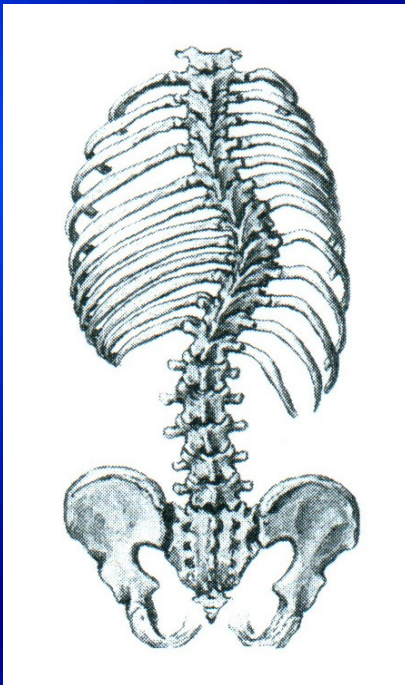


Scoliosis is 3D deformity

- frontal level – scoliosis
- sagittal level – hypo, hyperkyphosis
- transversal level – rotation, torsion
 - rib prominence
 - proc. spinosus tilted to concave side
 - narrowing of spinal canal



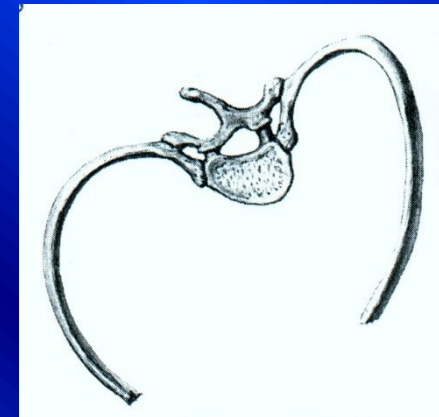
concave



convex

concave

convex



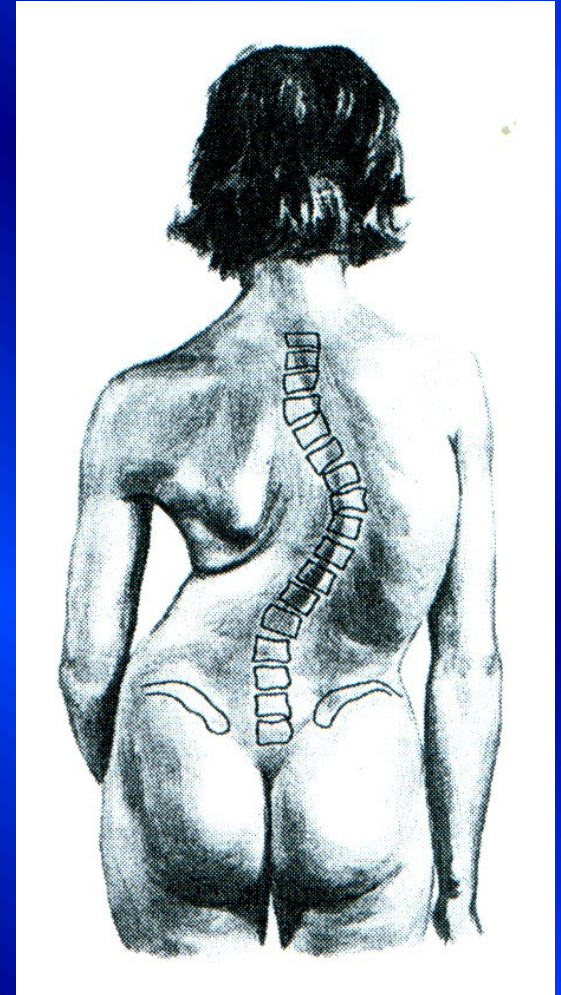Curve

Structural curve

- no flexibility
- based on structural changes

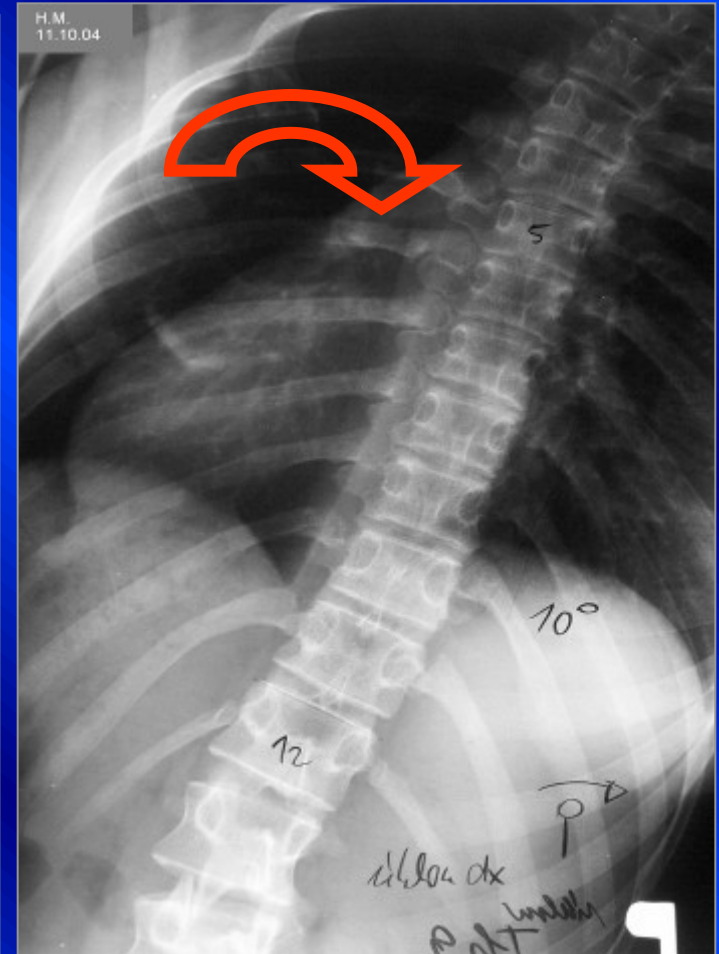
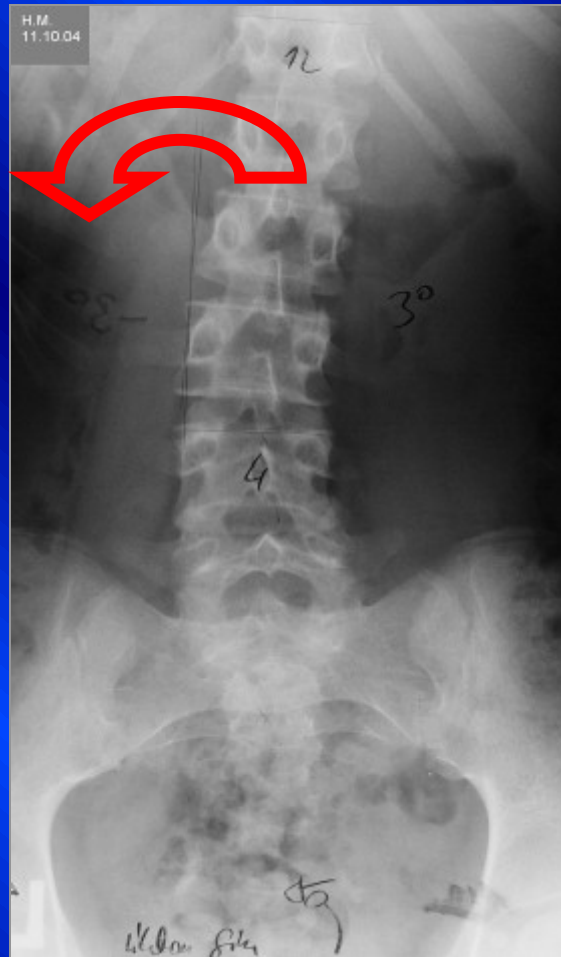
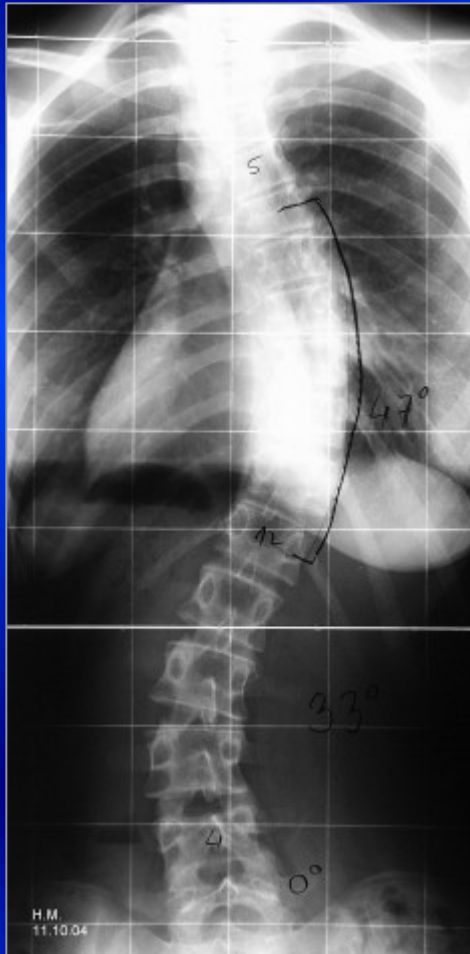
Nonstructural curve

- is flexible
- nonbased on structural changes



Structural curve

Structural and nonsctructural curve



Curves

Main curve

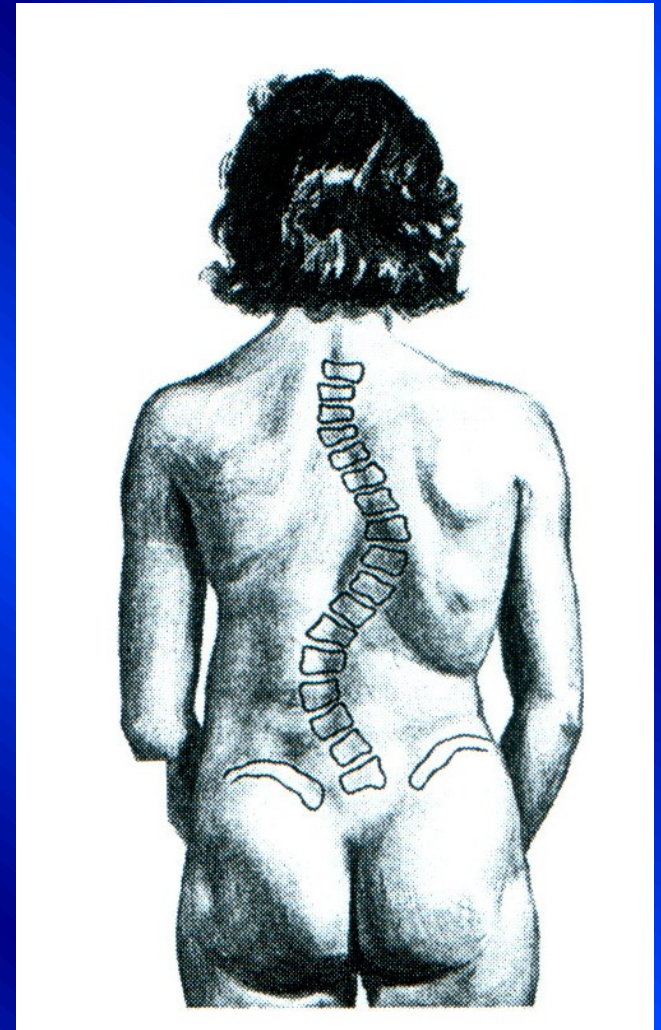- occurs earlier
- structural
- more serious

Compensated curve

Above and below main curve

Compensates stability of the trunk

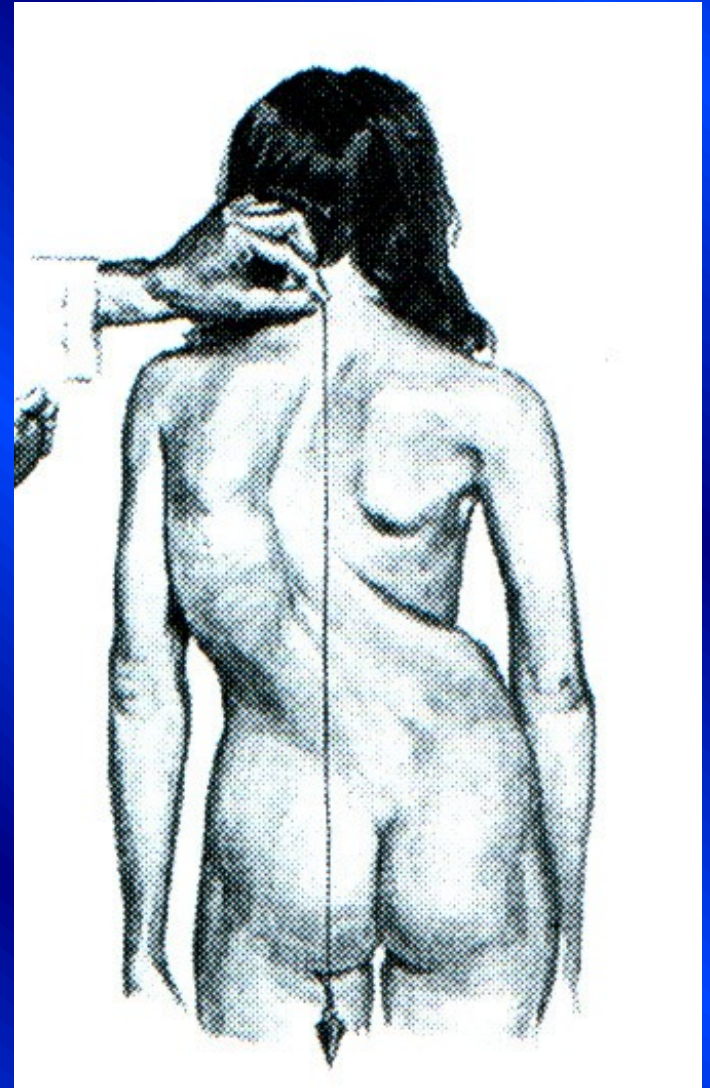
Later on changes into structural one



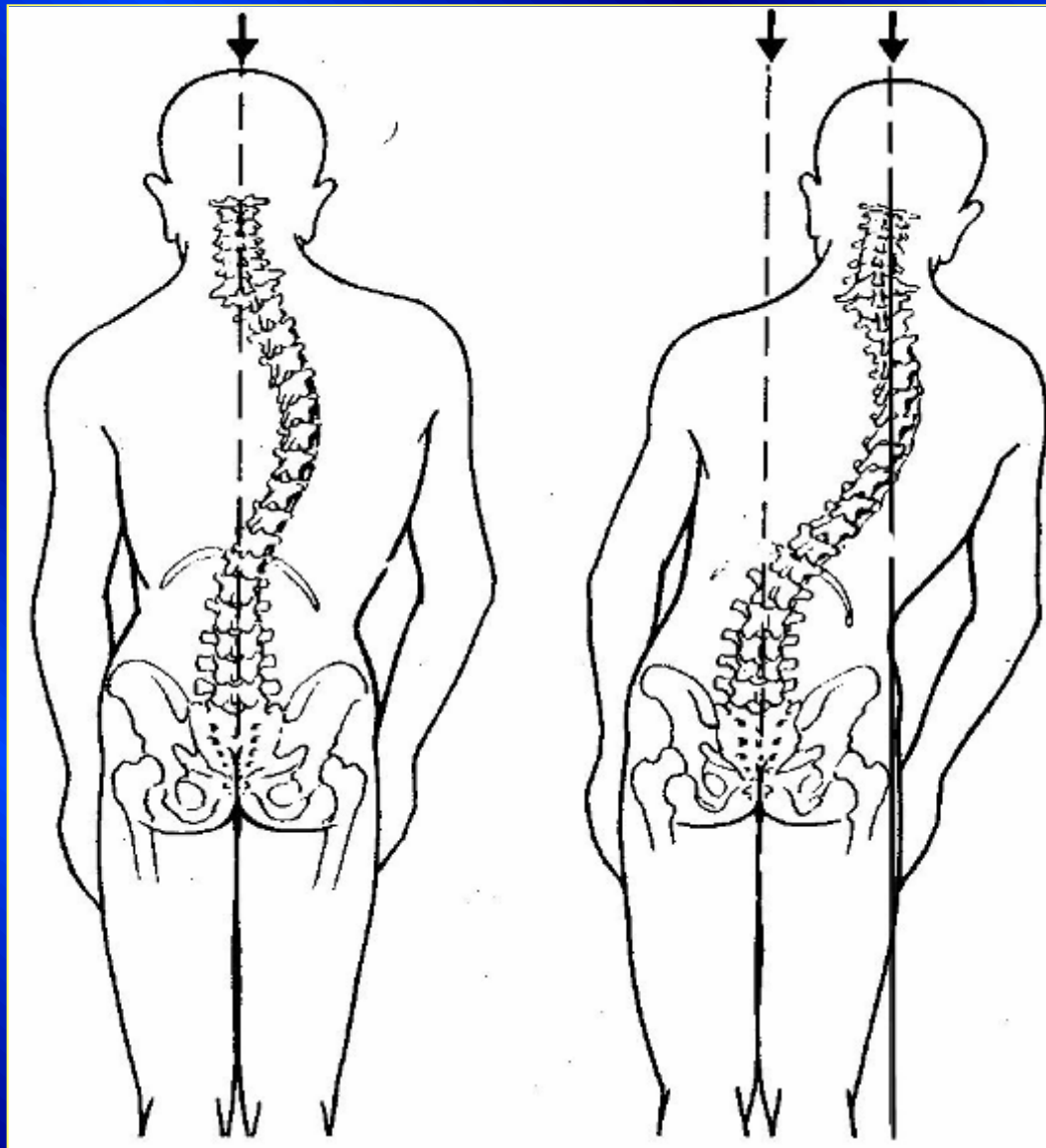
Scoliosis

Compensated

Decompensated

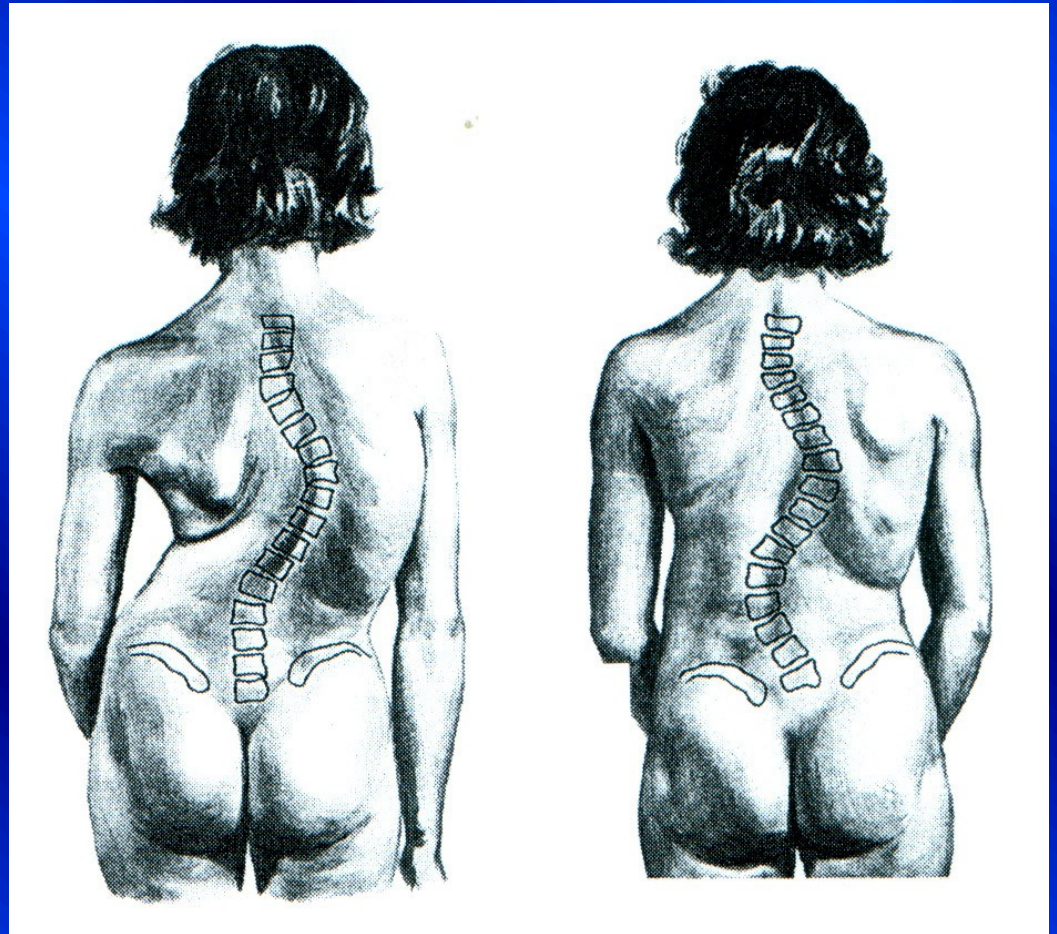


Trunk compensated/ decompensated



Curves

Cervical
Cervicothoracic
Thoracic
Thoracolumbar
Lumbar
Lumbosacral



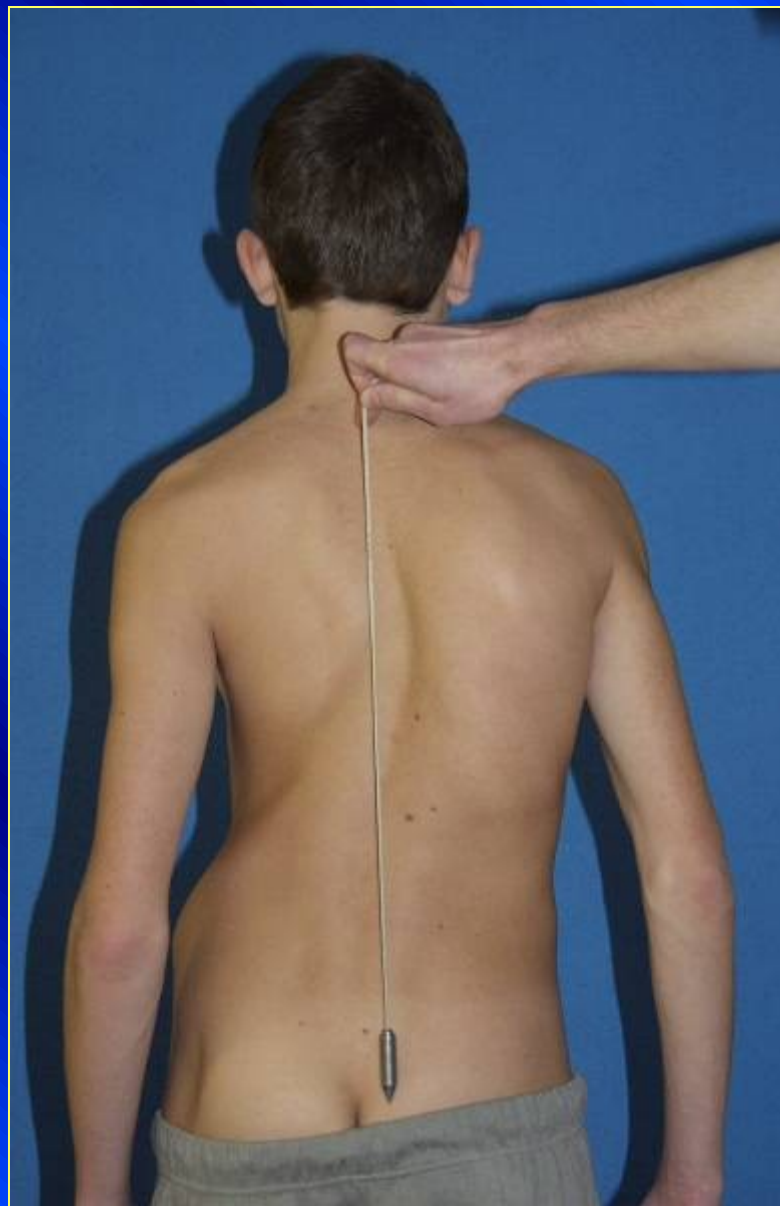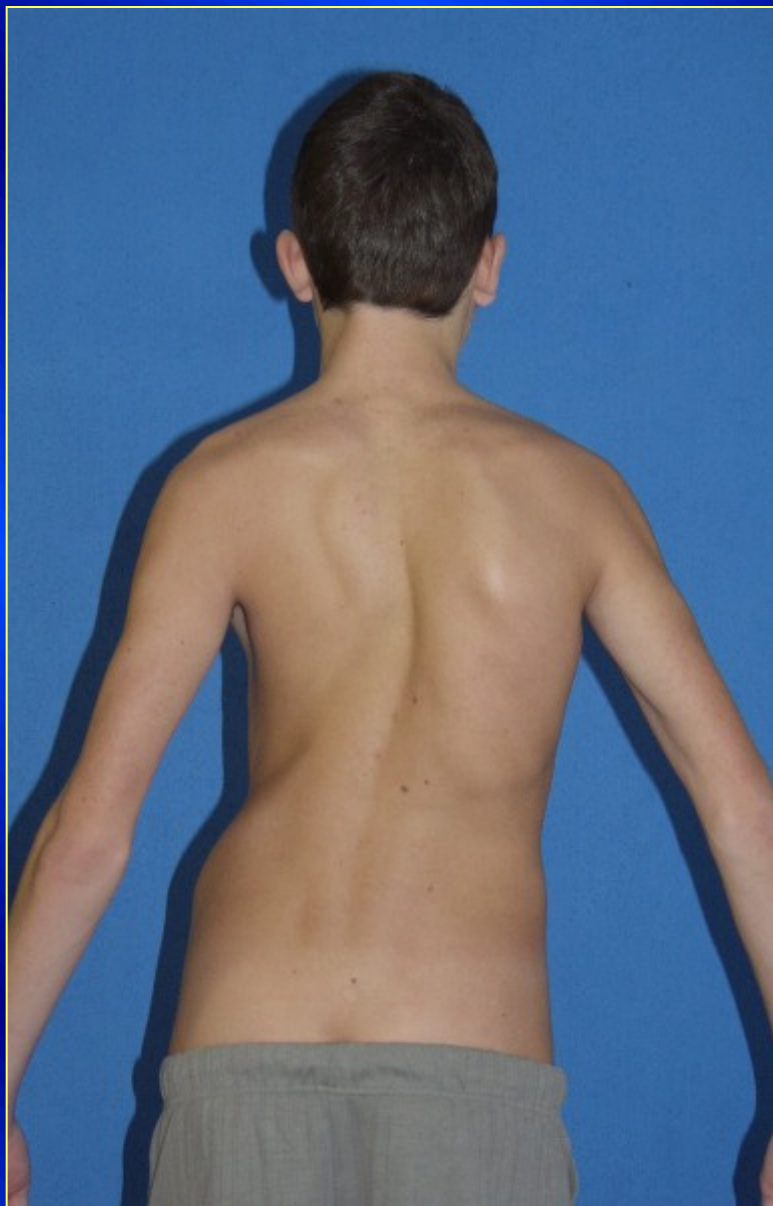Thorakální

Thorakolumbální

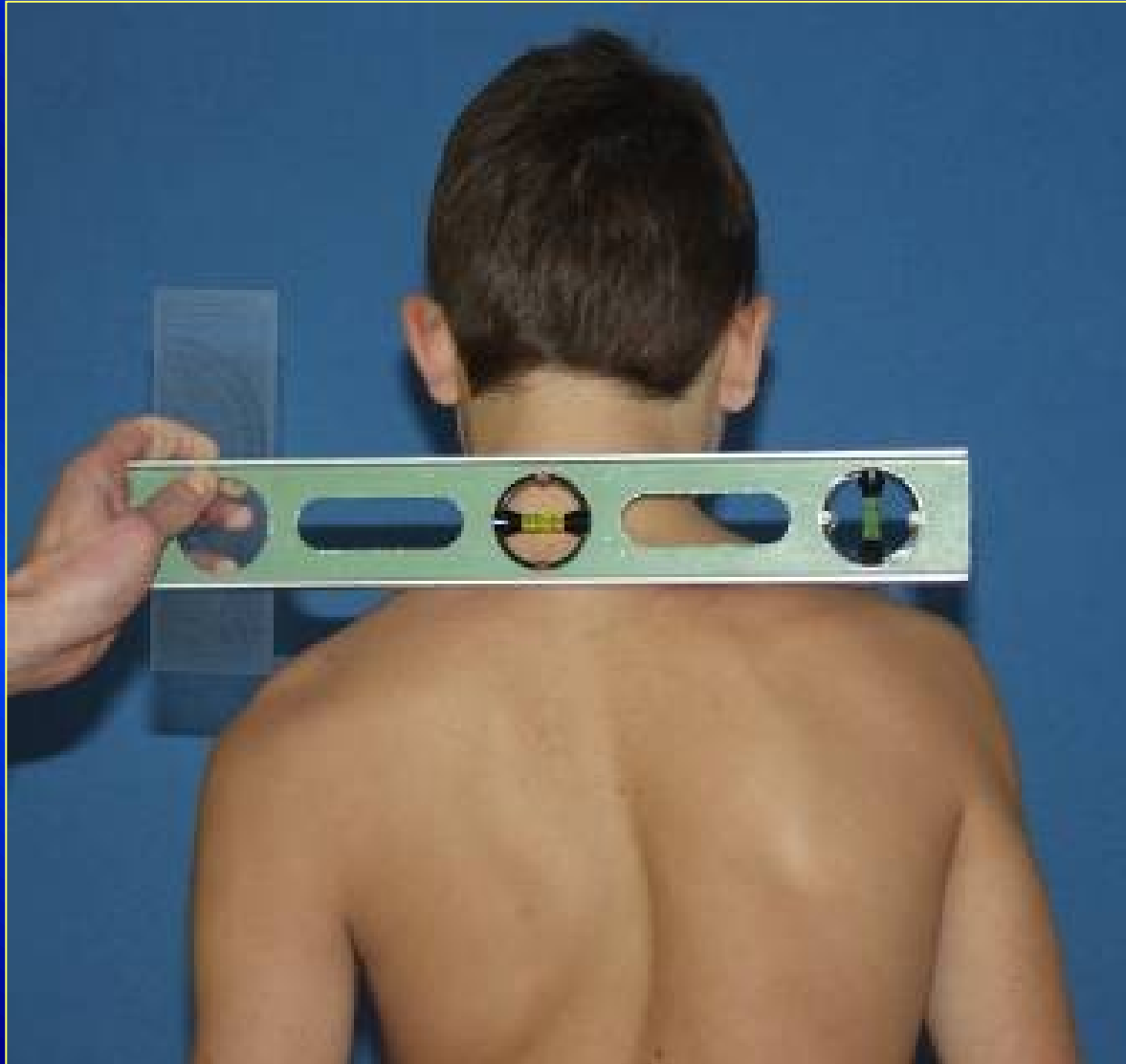
Clinical examination

- Compensation of the trunk
- Level of shoulders
- Asymetry of the waist
- Position of the pelvis
- Flexibility of curves
- Gibus in flexion
- Others: laxity, sexual development, length of extremities
- Functional examination of lungs- spirometry

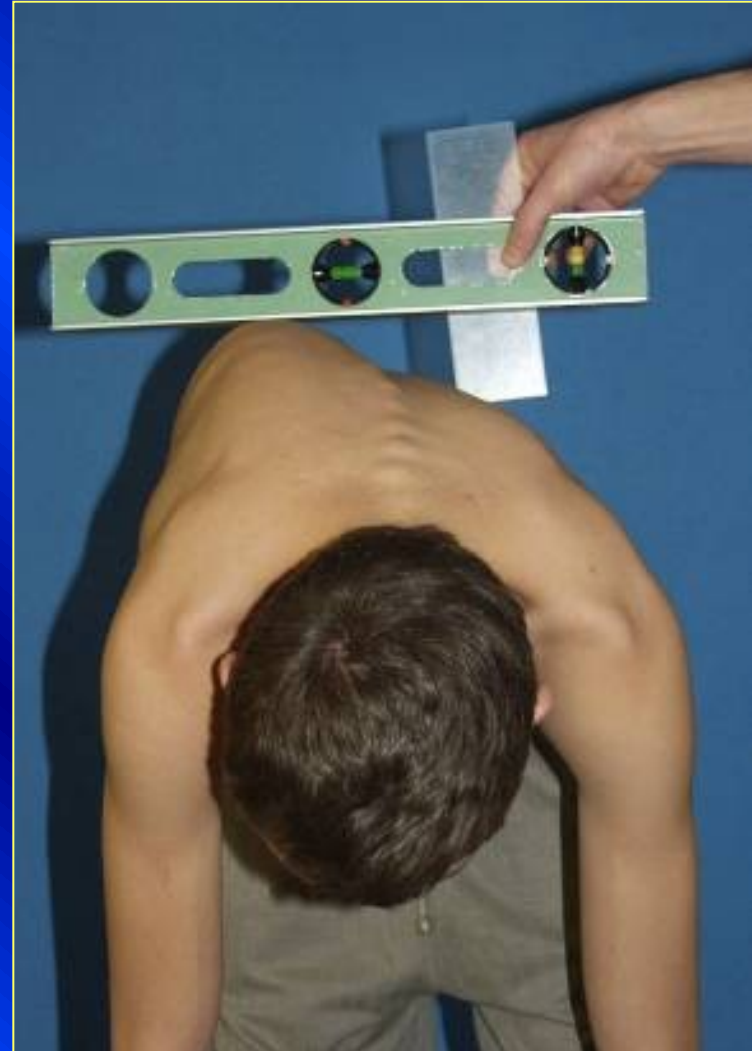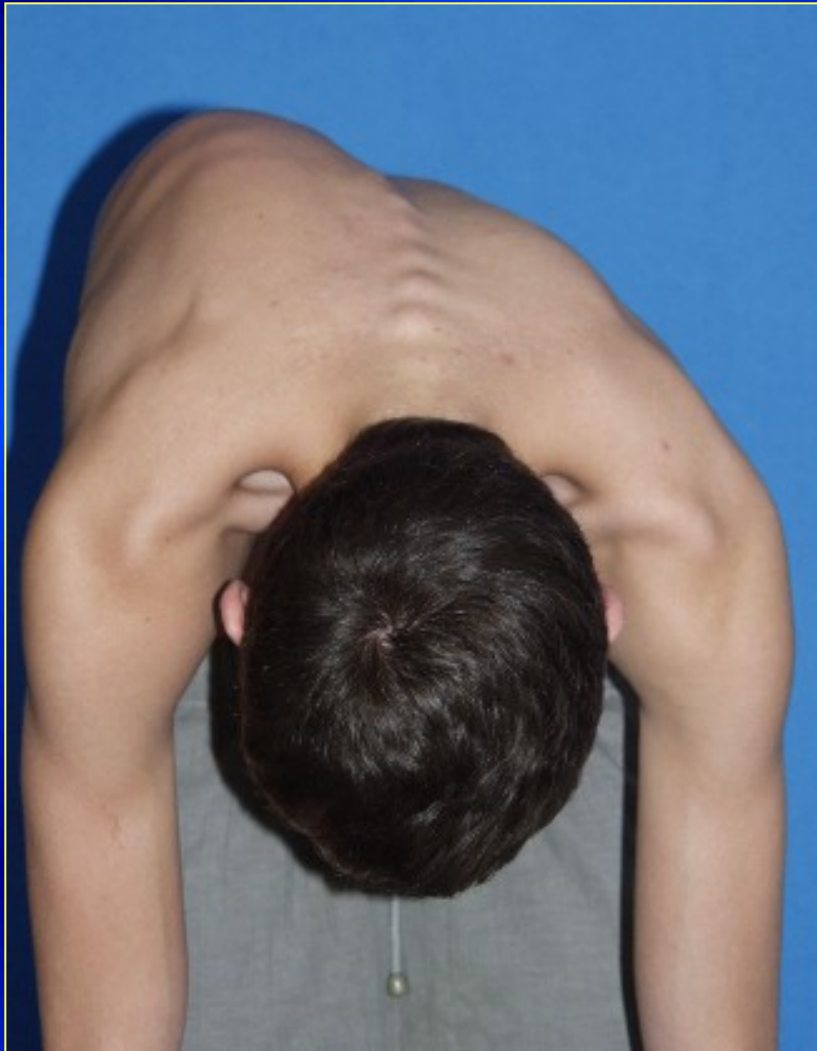Compensation of the trunk



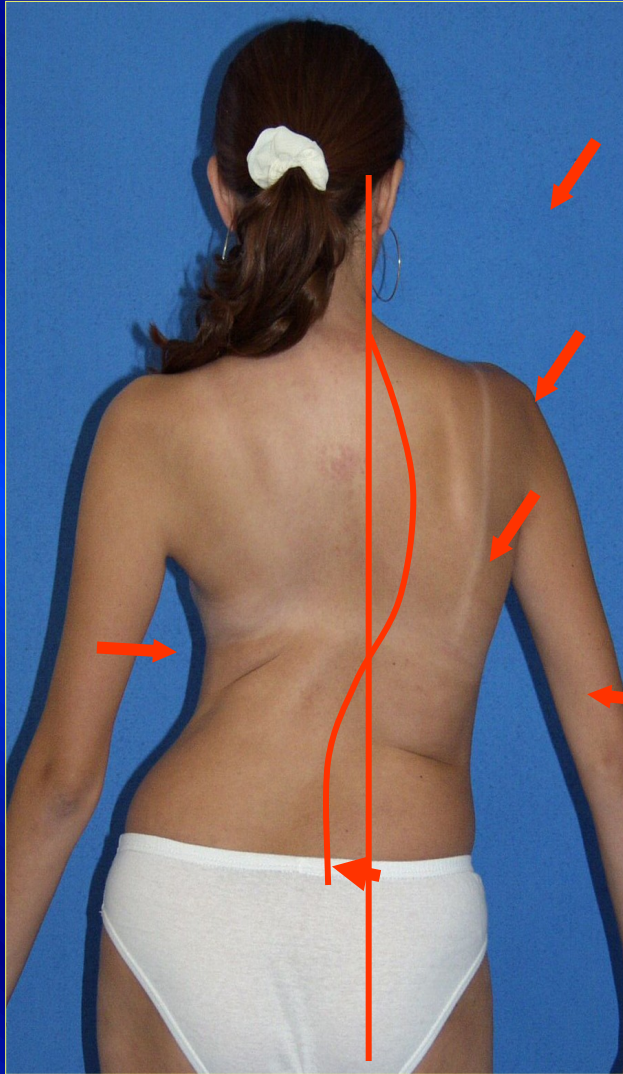
Level of shoulders



Gibus (hump) in flexion



Frontal balance



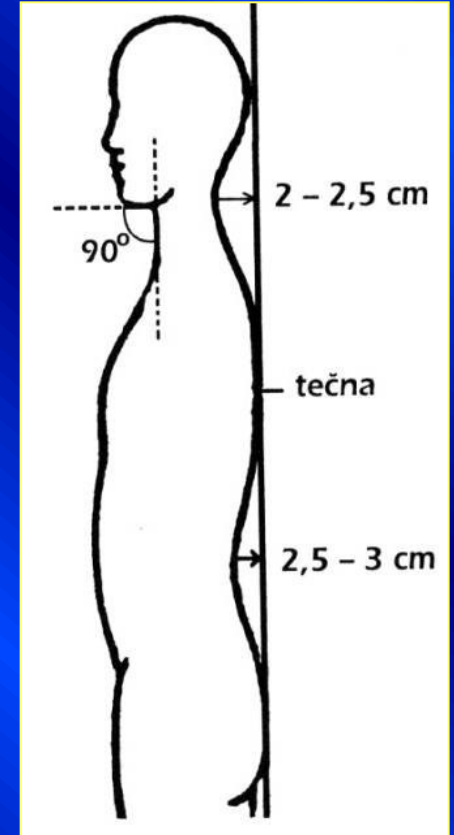
Výška ramen

Gibus

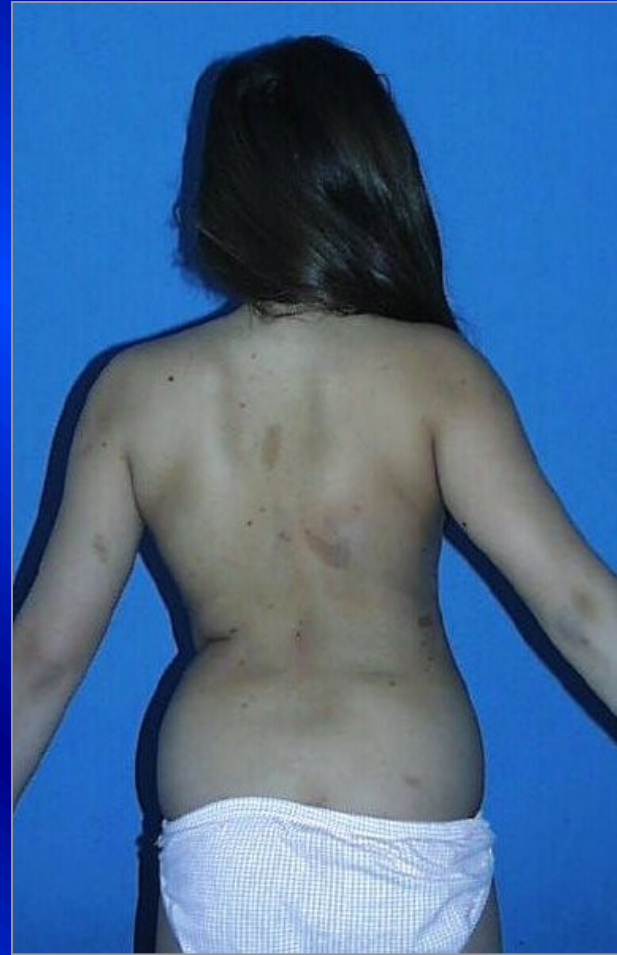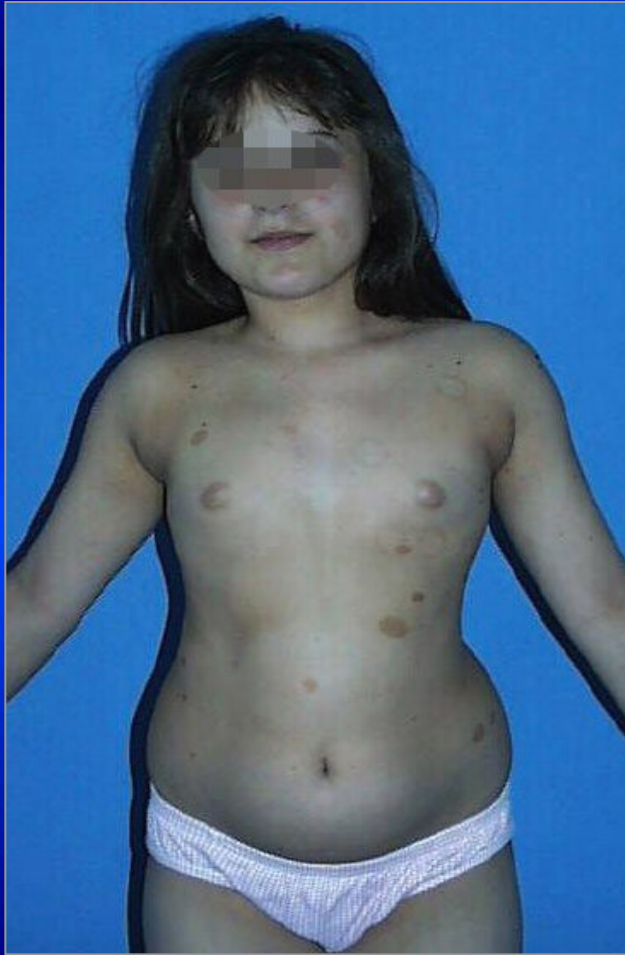Asymetrie tajle

Dekompenzace trupu

Sagittal balance



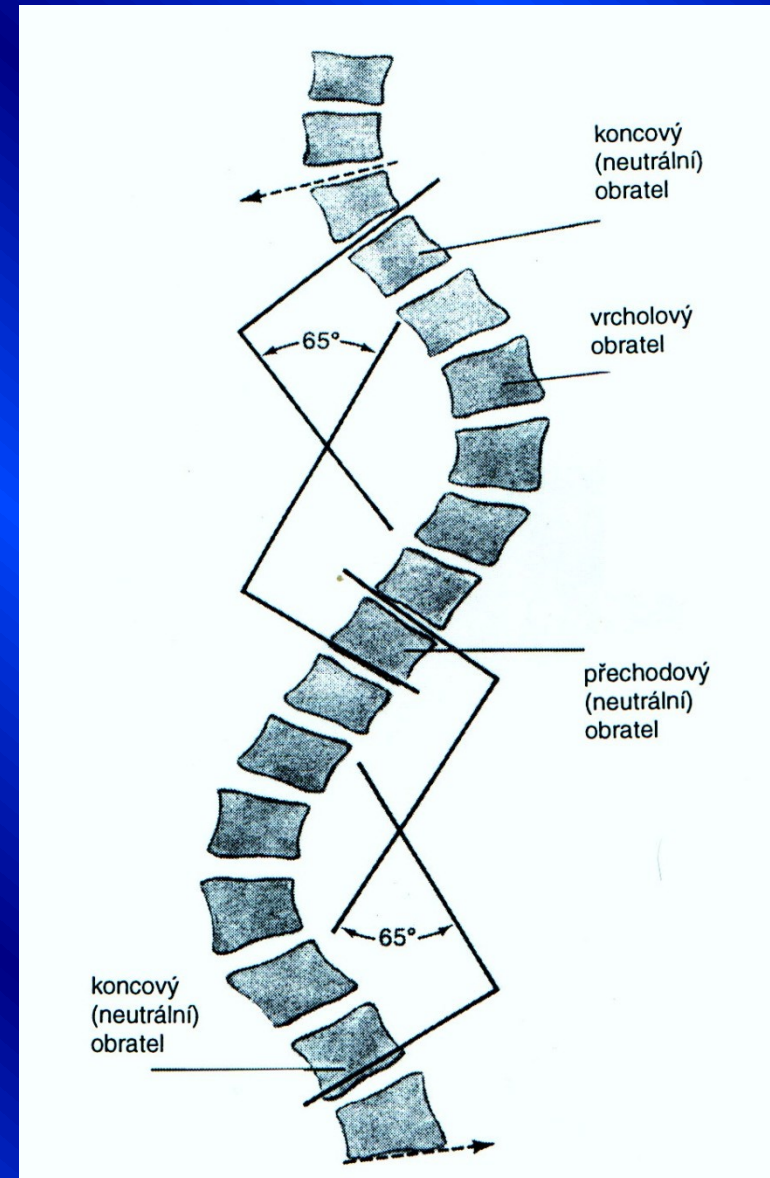
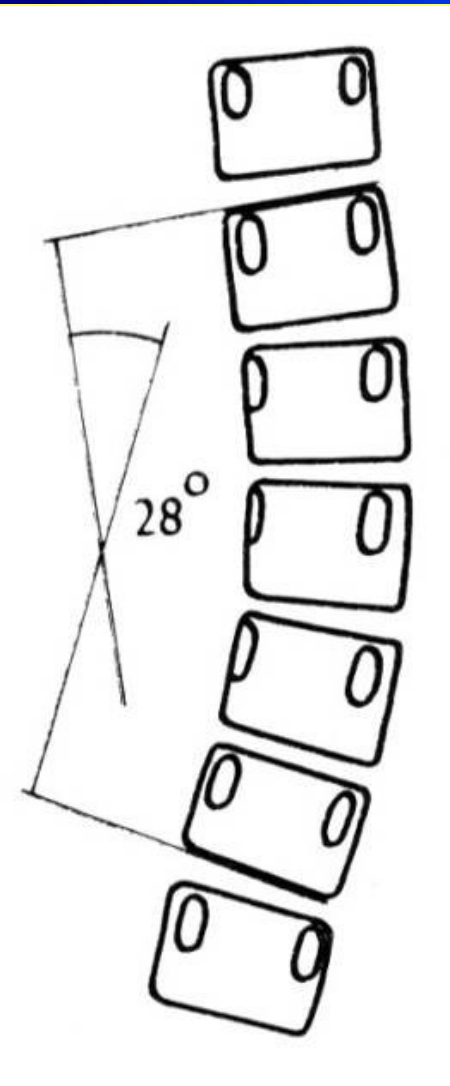
Neurofibromatosis „café au lait“



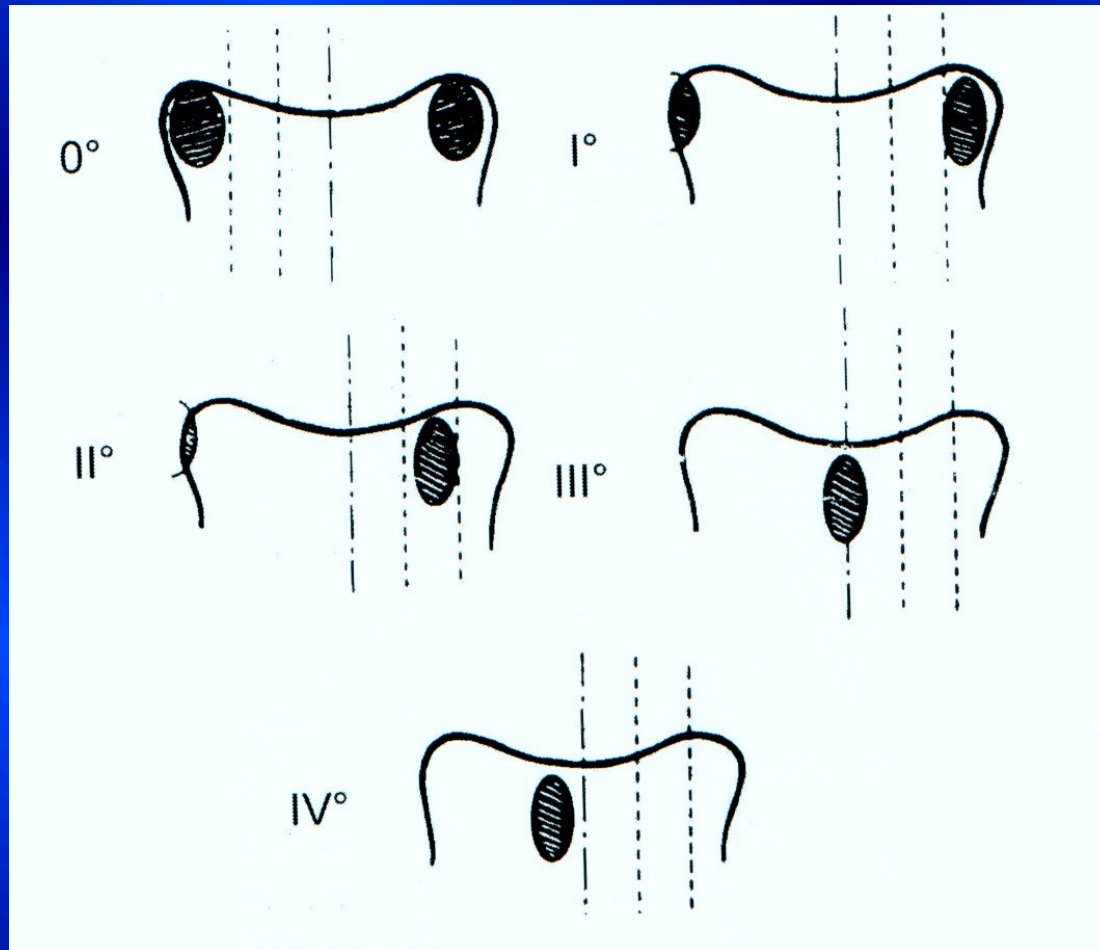
X- ray examination

- Long films 30x90 cm
- AP, lateral, in bending , in distraction
- Check up in 6 months
- Cobb angle
- Skeletal development

Cobb angle



Rotation of vertebrae- pedicles



Risser sign

0 no apophysis

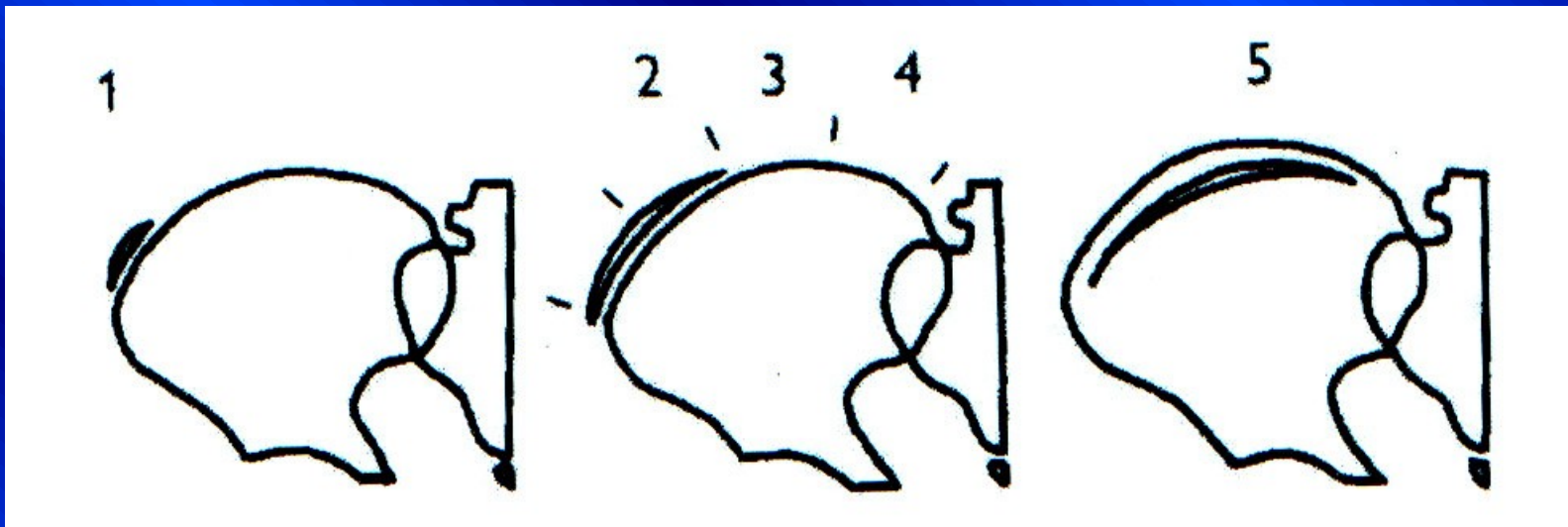
1 25%

2 50%

3 75 %

4 100 %

5 Fusion with iliac bone



Classification

- Orientation – right, left
- Localisation, C, CT, T, TL, L, LS
- Severity of the curve- Cobb angle
- Etiology

Classification

- Structural
 - Congenital
 - Idiopathic (80%) – infantile, juvenile, adolescent
 - Neuromuscular – neuropathic, myopathic
 - In neurofibromatosis
 - Secondary scoliosis Marfan sy, Ehlers-Danlos sy
 - Degenerative scoliosis
- Nonstructural
 - Postural
 - Hysterical
 - in other morbidities – tumor, infection

Idiopathic scoliosis

- Etiology unknown, multifactorial
- Genetic background
- Prevalence in girls 1,5 more often
- Progression- in girls 8 times more

Treatment

- Up 10° - no scoliosis
- 10-20 $^{\circ}$ - exercise therapy, follow up
- 20 - 40 $^{\circ}$ - orthosis, exercise therapy
- Above 40 $^{\circ}$ - surgery

Scoliosis in adults

Progression of the curvature

- low, in Cobb angle less than 30°
- often, in Cobb angle over 50° in thoracis
and over 30° in lumbar spine

Limited breathing in thoracic curves over 90°

Back pain

Idiopathic scoliosis

- **Infantile**
 - Up to 3 years of age
 - usually spontaneous resolving (90%),
 - in less cases severe progression
- **Juvenile**
 - 3 years of age – to onset of puberty
- **Adolescent**
 - Puberty - the end of growth

Exercise therapy

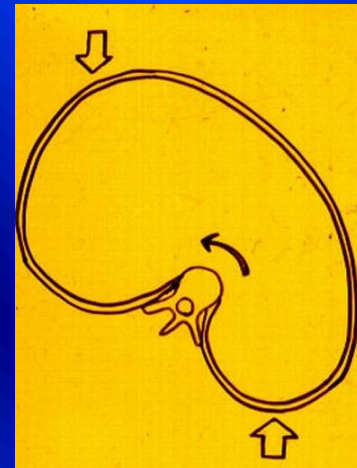
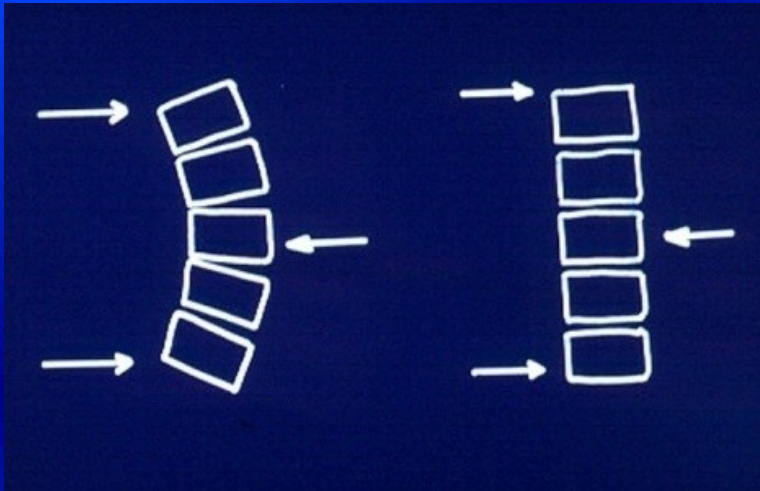
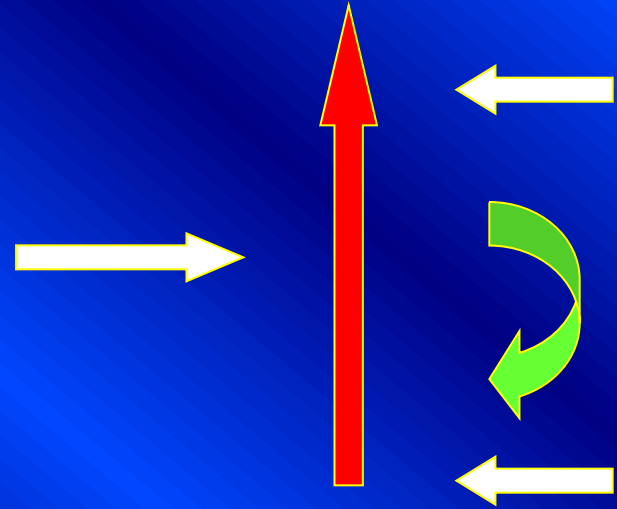
- Exercise, correct posture
- Pelvic alignment
- Strengthening of trunk and abdominal muscles
- Breathing
- High level activities
- Follow up in 6 months regime

Exercise + bracing

- To prevent progression
- Effective only in low curves
- Over 45° no effect
- Indication: in growing children with flexible curve
- Curves are progressive in fast growing periods
- To wear 23 hours per day, up to the end of growth (16-17 years) gradually to wear less hours per day.

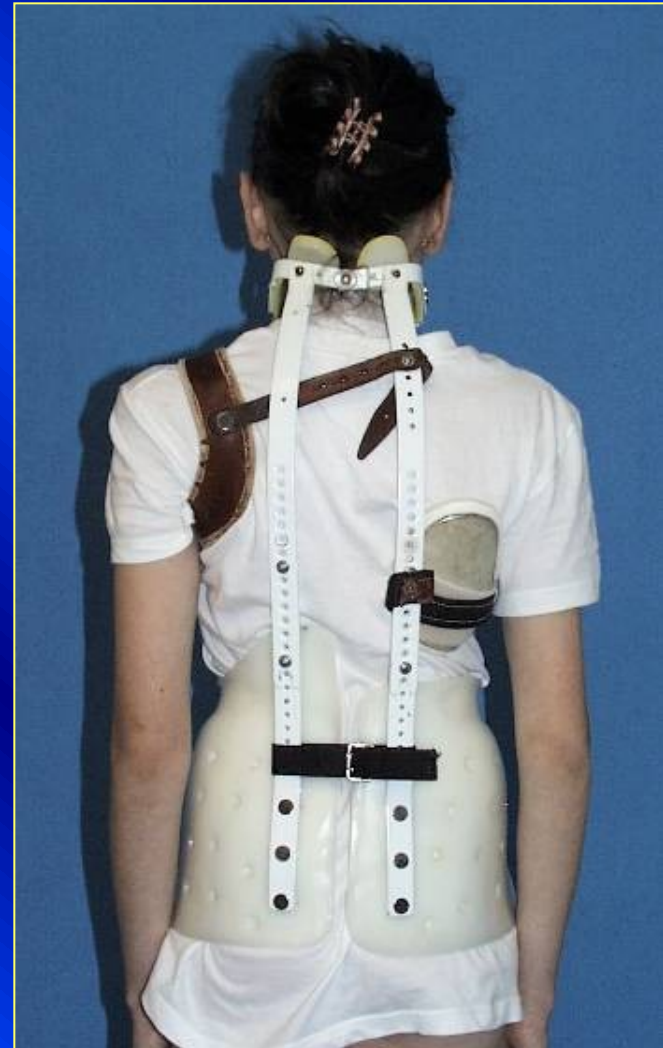
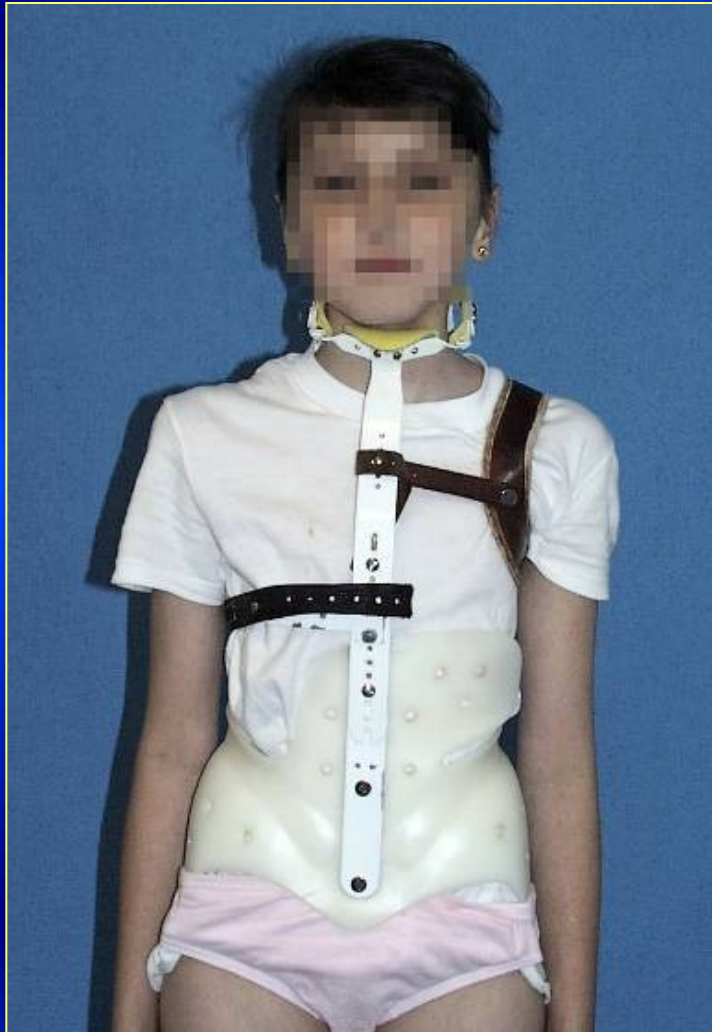Principles of the brace

- distraction
- derotation
- three point system



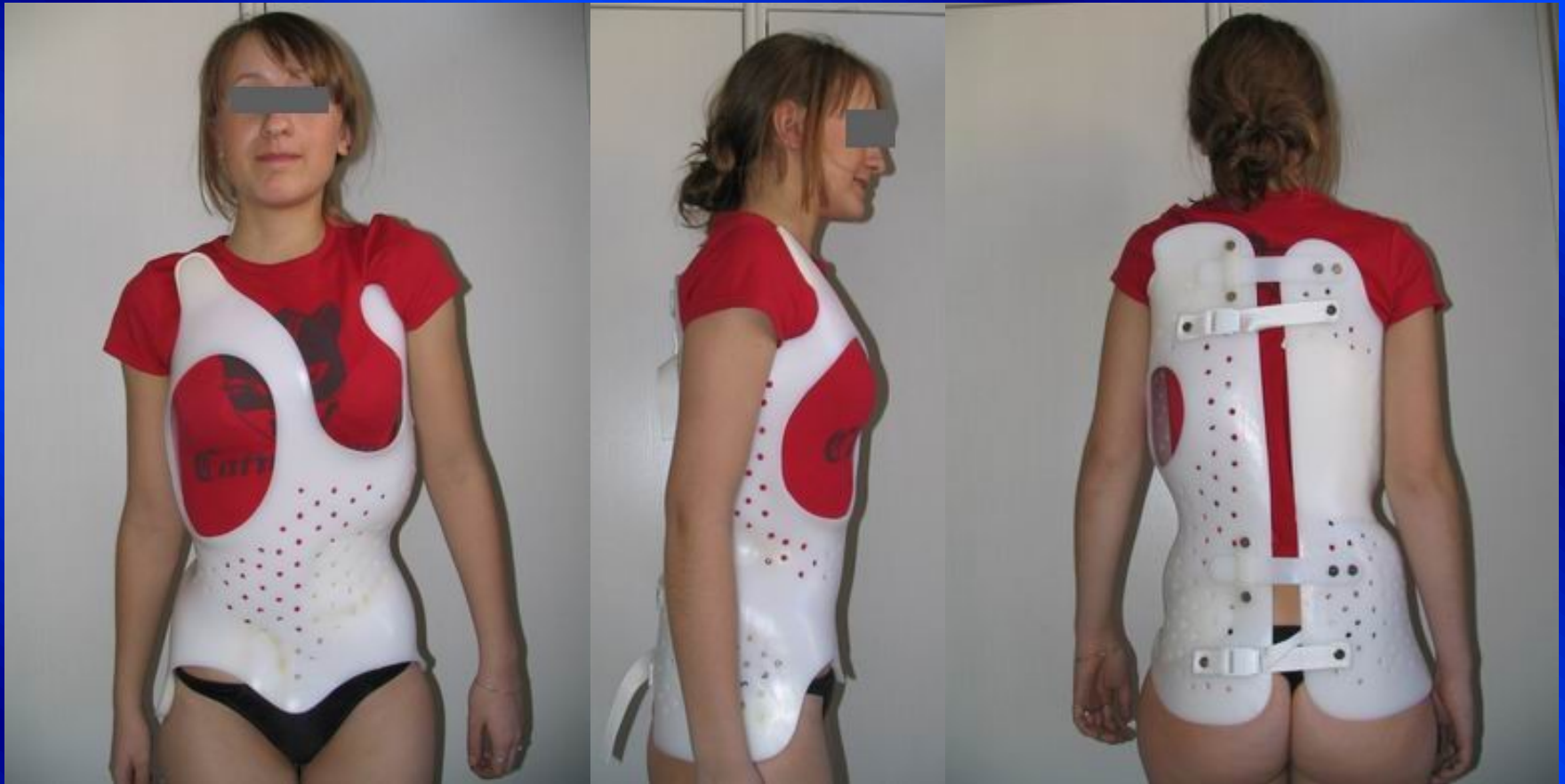Milwaukee orthosis

– curves T6 and above



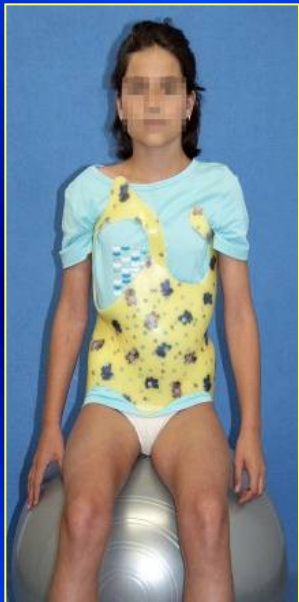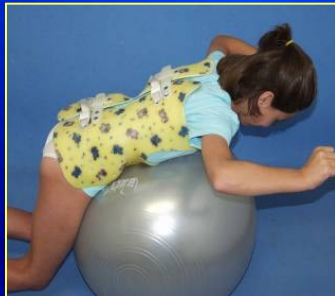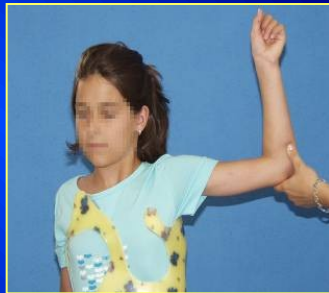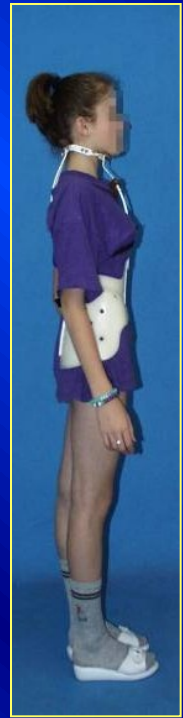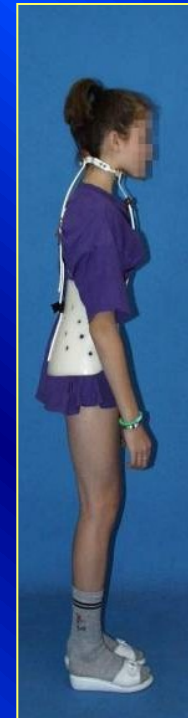TLSO orthosis

- curves in Th7 and lower



Exercise in a brace

- stretching
- correct posture
- exercise using balls
- activation in sports



- Without a brace
 - swimming
 - hippotherapy



- Breathing therapy
 - *deep breathing*
 - *bottles*
 - *derotation breathing*



Surgery

- **Indication:**

- Above 40° in fast progression
- Above 50° in all

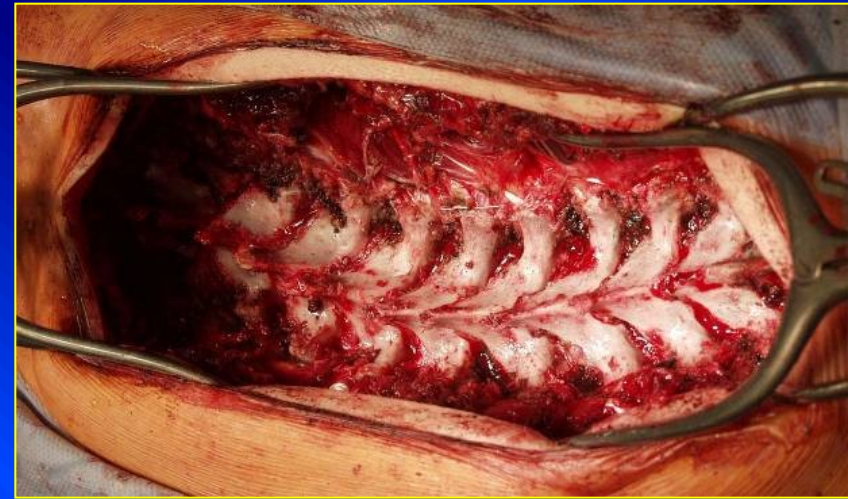
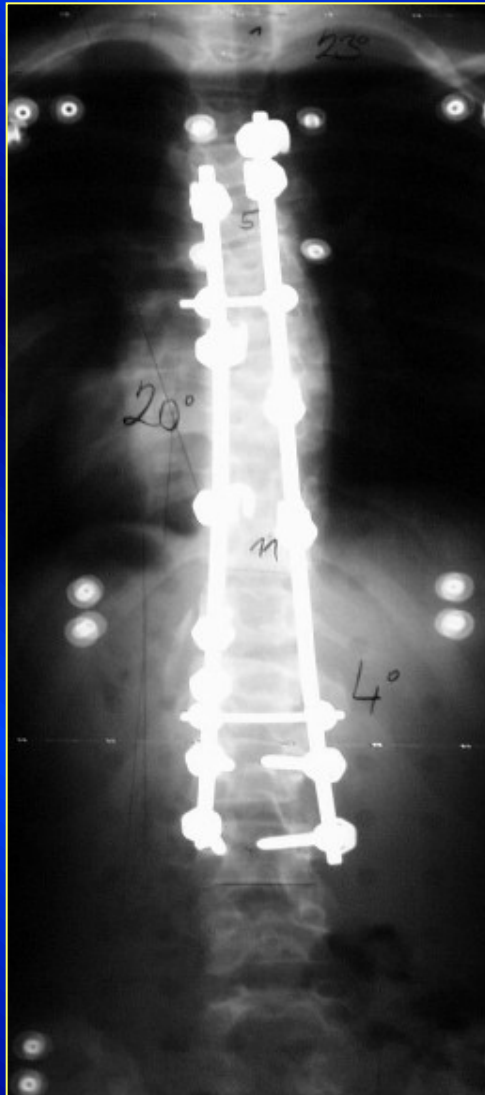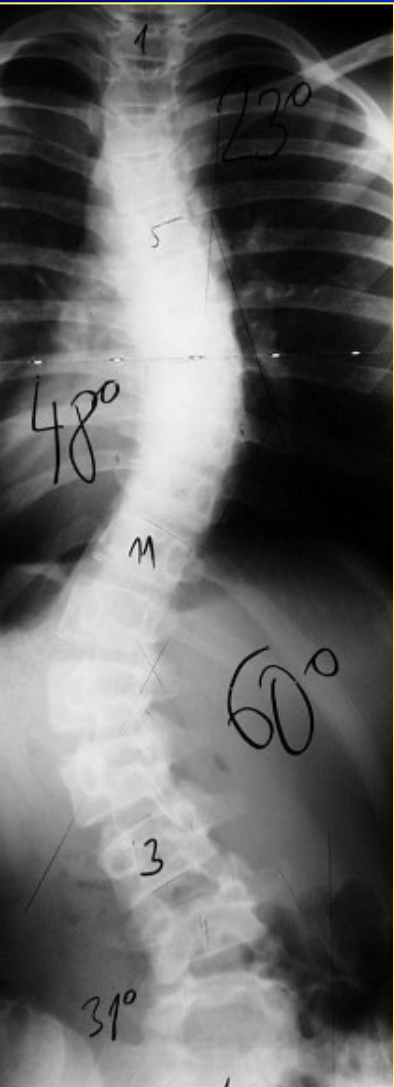- **Principles:**

- Correction of the curve (distractions, derotation, translation of vertebrae)
- Repeated distraction in younger patients (HRI)
- growing rods
- spondylodesis
- Postoperative bracing

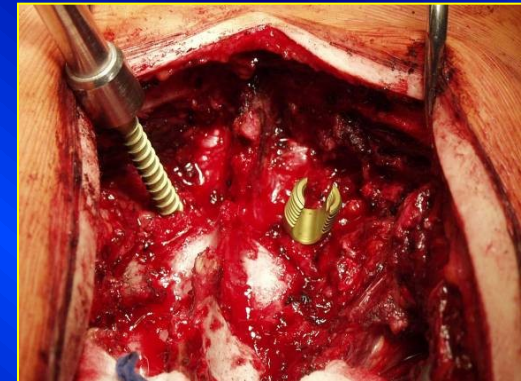
- The aim of surgery:
 - Correction of the curve
 - Prevent progression
 - Influence worsening of pulmonar function
(cor kyphoscolioticum- ischemic heart disease)
 - Improve situation for better muscle function
 - Prevent degenerative changes (spondylosis and spondylarthrosis)
 - Cosmetic effect

Dorsal approach

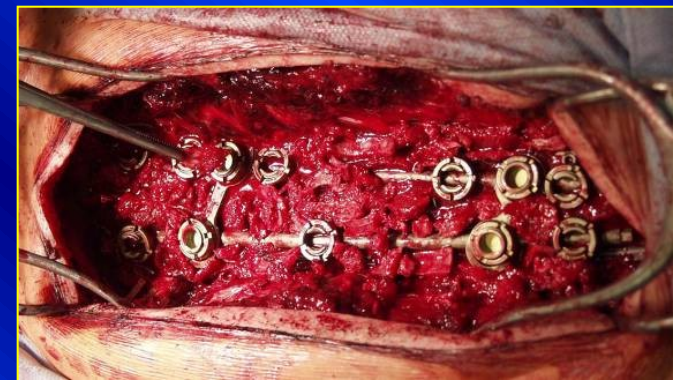skeletizace, resekce kloubů,
dekortikace zadních elementů



Transpedikulární
šrouby či
pedikulární háčky

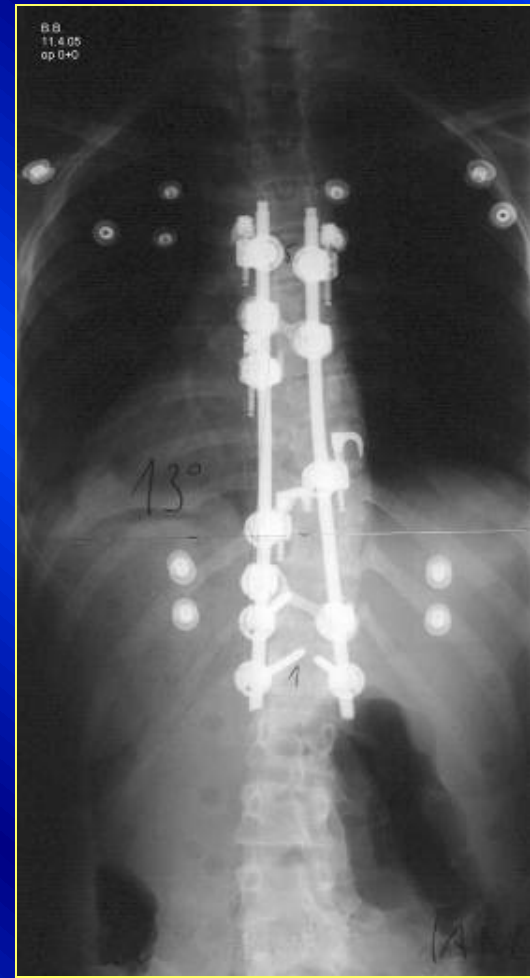
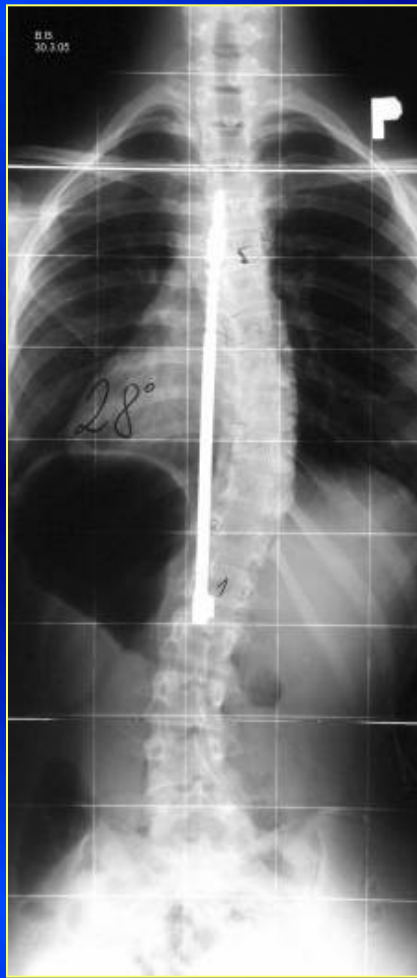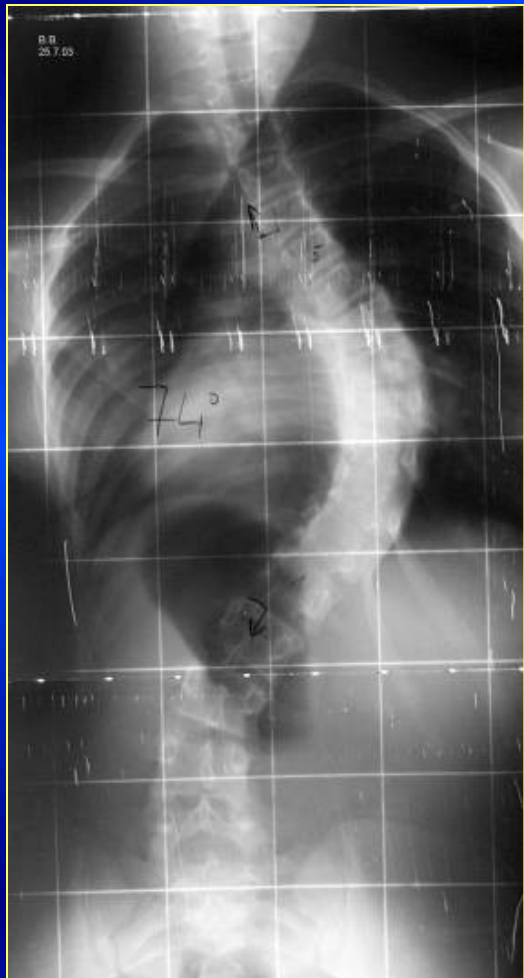


Dokončení,
propojení,
štěpy

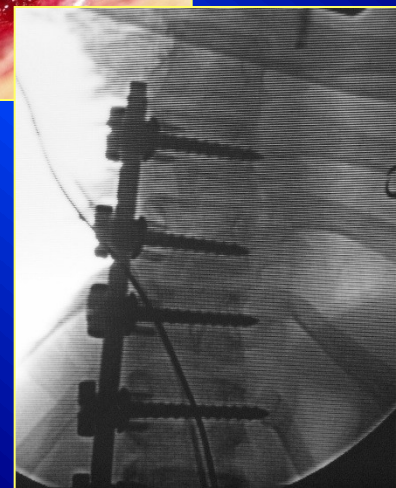
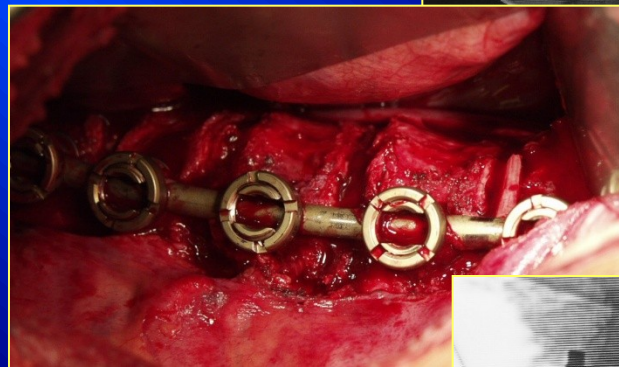
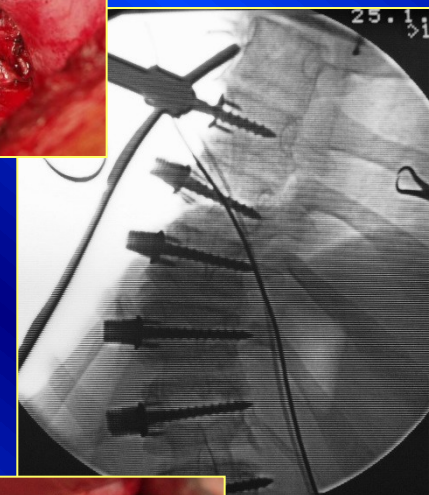
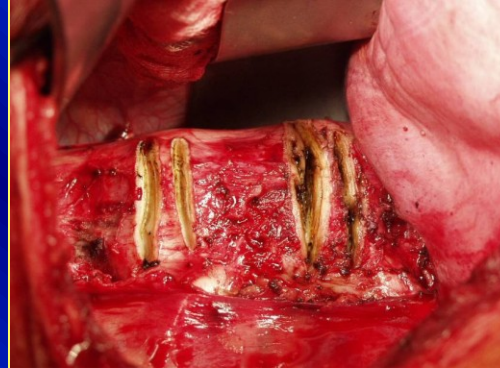
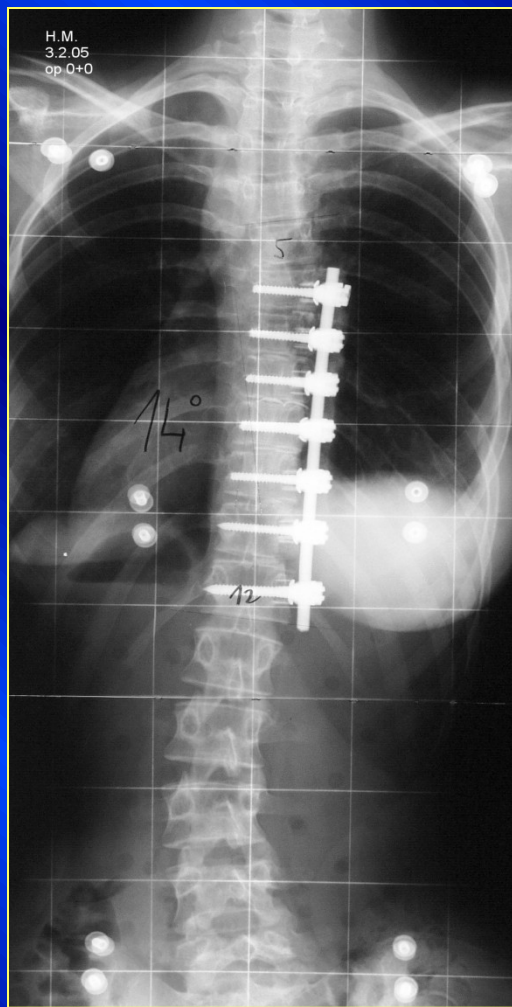
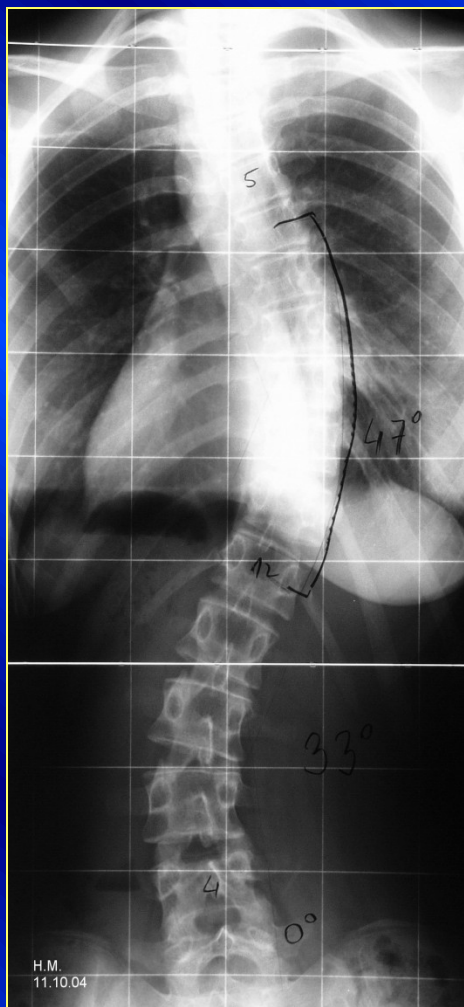

Juvenile scoliosis

HRI + repeated distraction, fusion later on



Dorsal approach



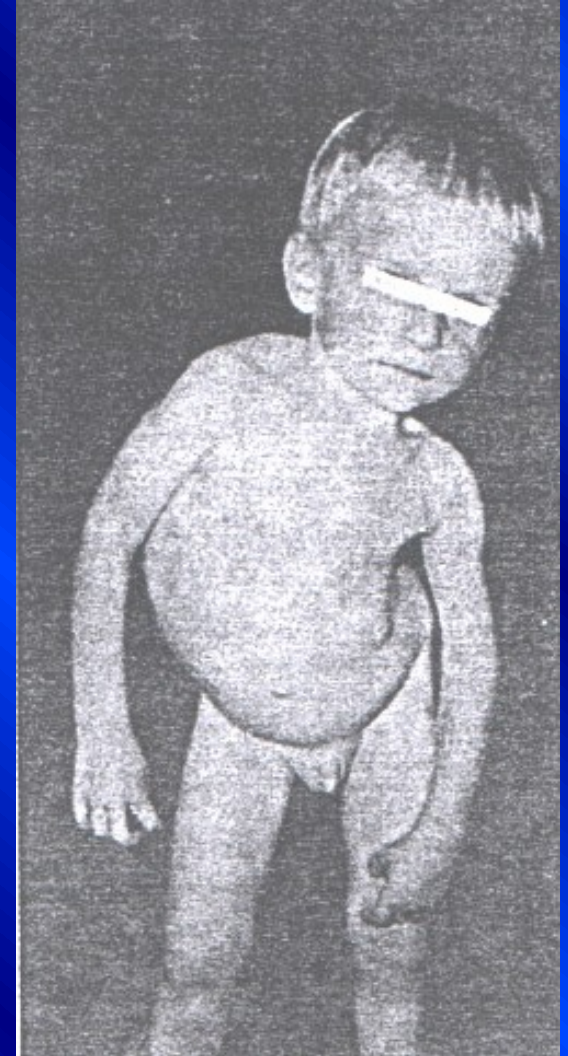
Congenital scoliosis

- from the childbirth
- asymmetric growth of the spine
- more often fast progression

Etiology:

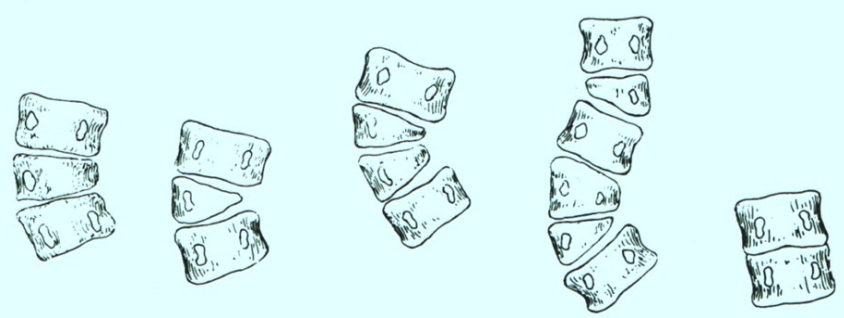
1. Disturbance of the form
2. Disturbance of segmentation
3. Combined disturbance

- Management: surgery
 - fusion
 - osteotomy + fusion
 - hemivertebrectomy

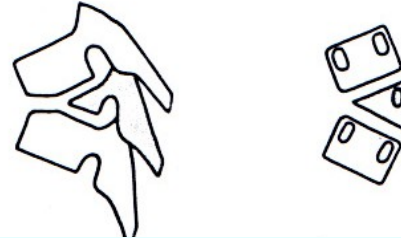

Disturbance
of the form

Wedge vertebra
Hemivertebra



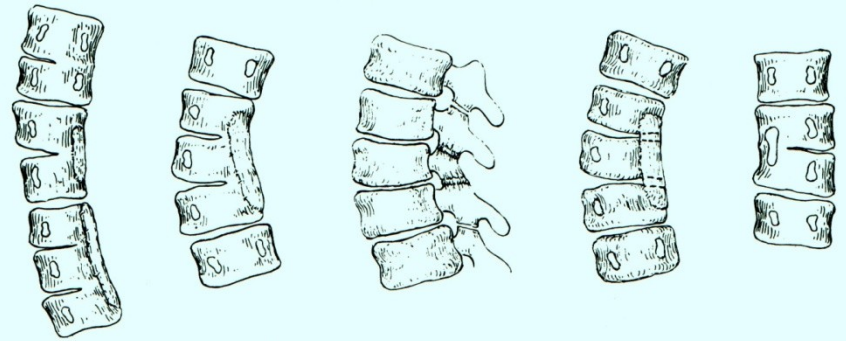
Hemivertebra



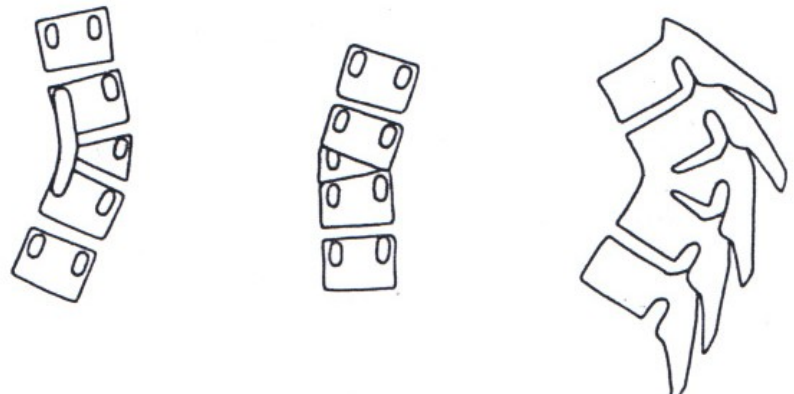
Disturbance of
segmentation

Nonsegmented
bone rod

Bone block



Combined disturbance



Neuromuscular scoliosis

Neuropatic: cerebral palsy, polio,
spinal dysraphism

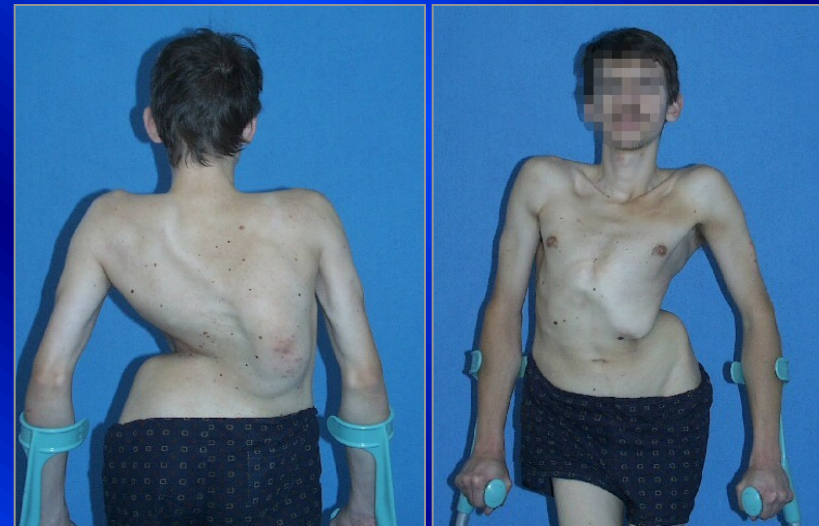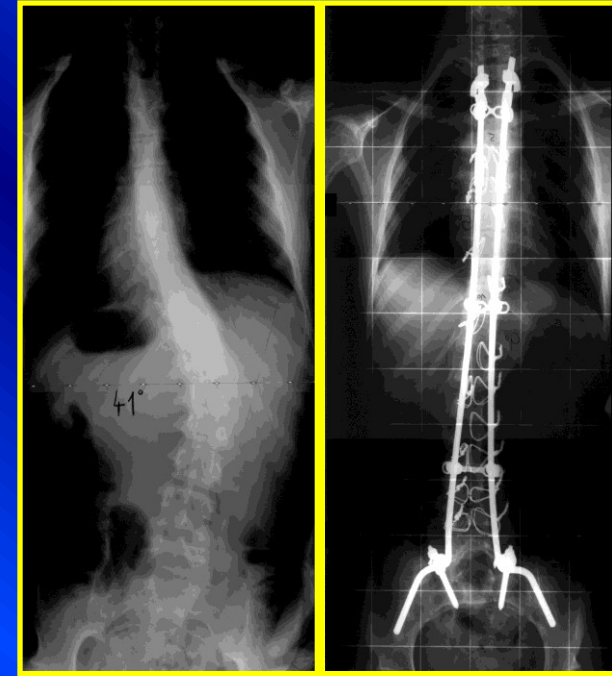
Myopathic: muscular dystrophy,
arthrogryphosis

„paralytic scoliosis“

Long, severe curves

Therapy:

Surgery, long fusion

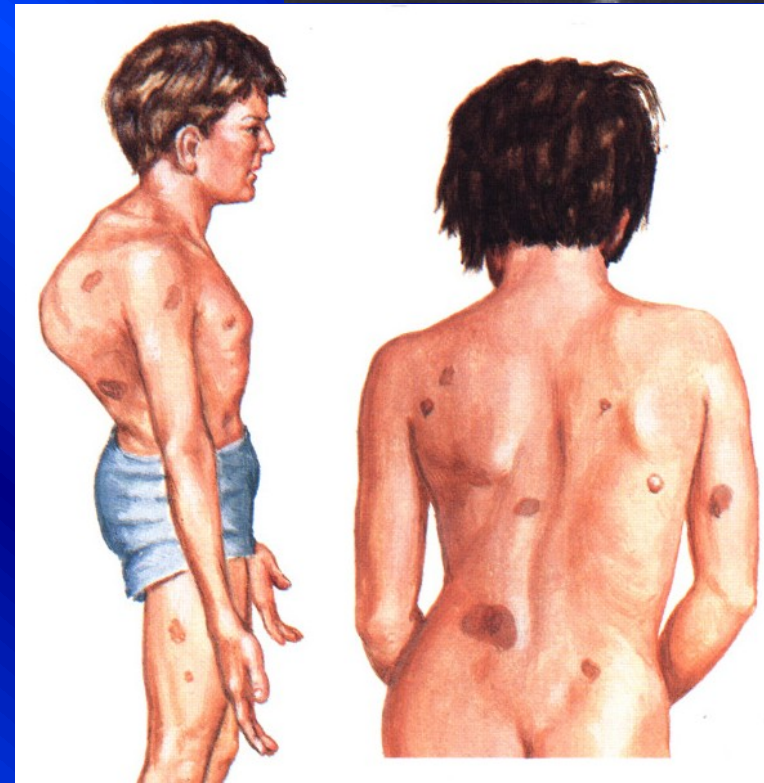
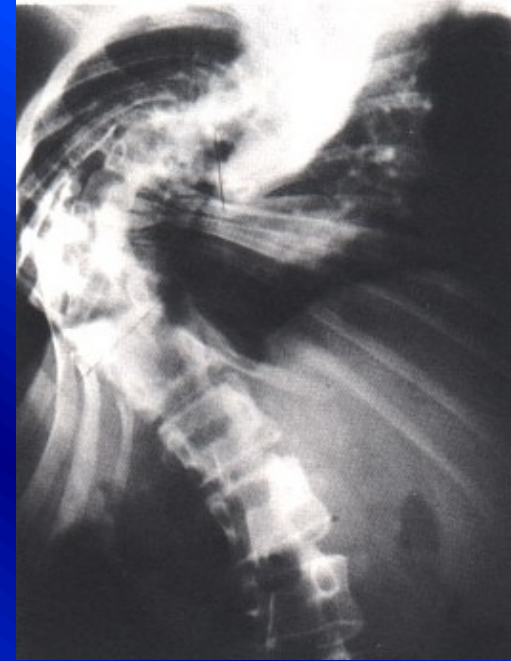

Scoliosis in neurofibromatosis

- short curve
- atypical shape of vertebrae
severe rotation
- changes of ribs

Typical:
Progressive
Surgery is necessary

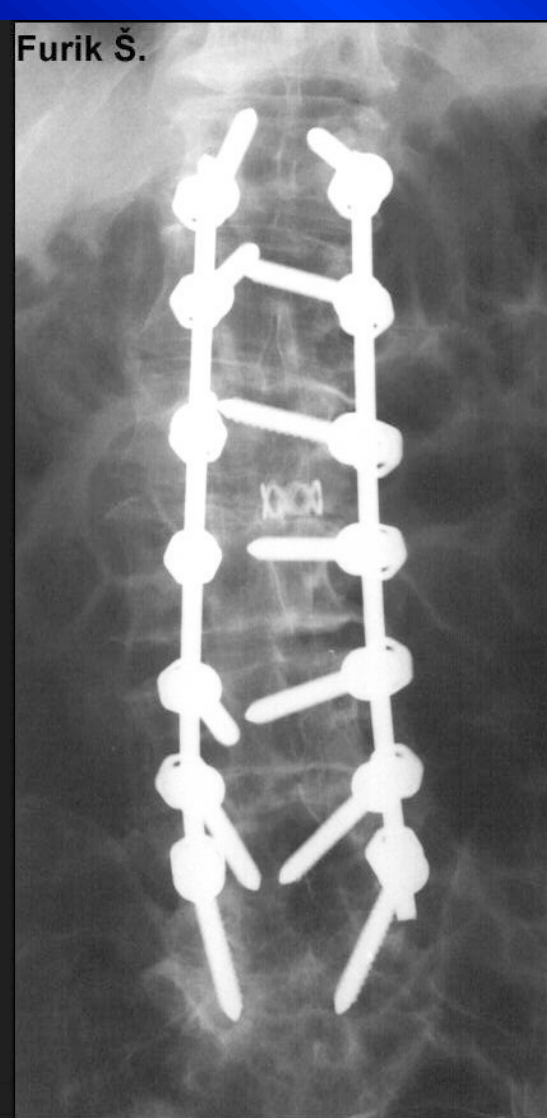
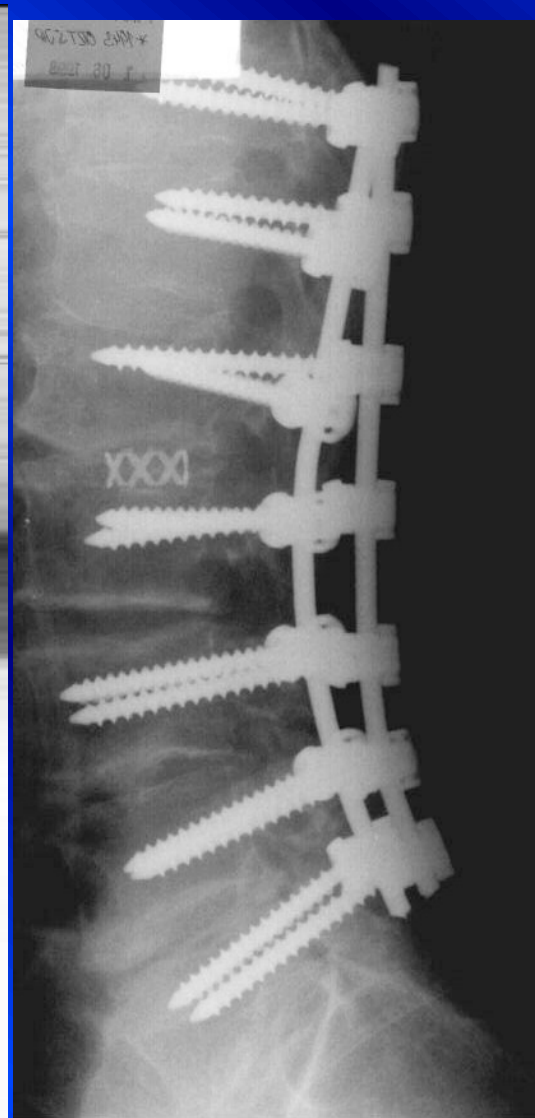
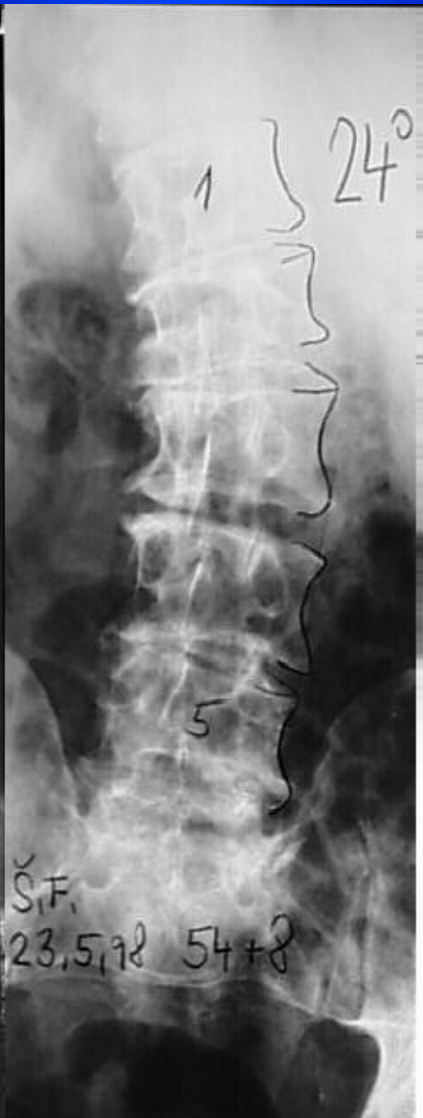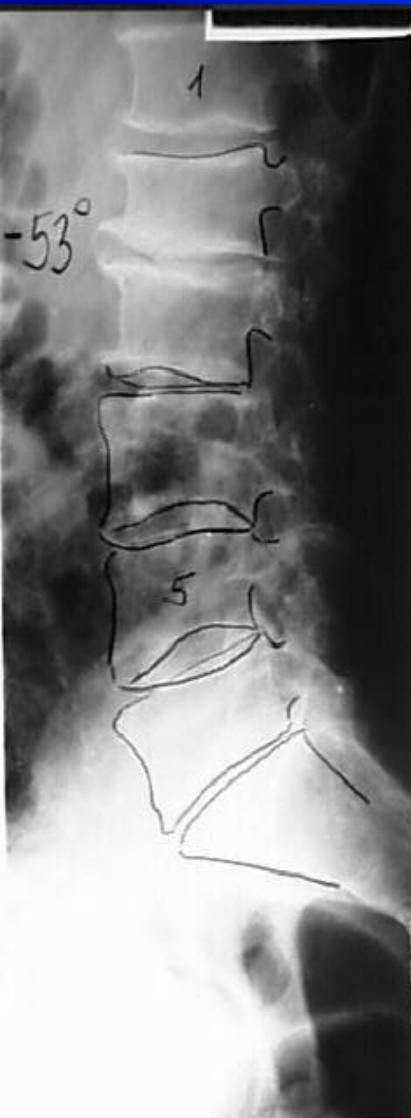Atypical:
Progression as in idiopathic
scoliosis- treatment the same



Secondary scoliosis

- Osteogenesis imperfecta
- Spondyloepiphyseal dysplasia
- Diastrophic nanism
- Rickets
- Marfan syndrom
- TB
- Injuries
- Degenerative scoliosis

Degenerative scoliosis



Nonstructural scoliosis

- Postural
- In sciatica
- Tumors
- Spondylodiscitis
- Leg length discrepancy
- Contractures in hip region
- Hysterical

Pathological kyphosis

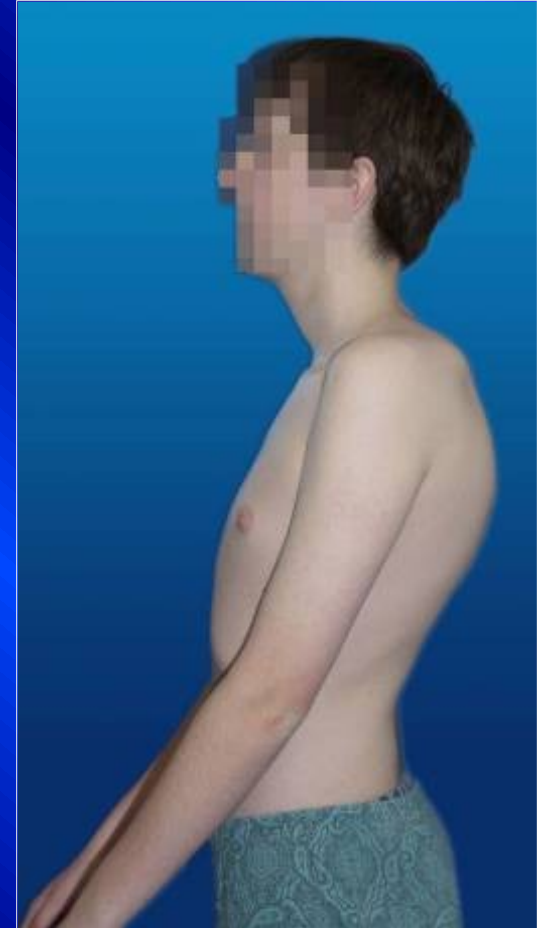- Congenial
- Neuromuscular
- Juvenile kyphosis

Others

- congenital deformity (achondroplasia, mucopolysacharidosis)
- posttraumatic (+ after laminectomy)
- after spondylodiscitis, TB)
- in tumors
- in osteoporosis, osteomalatia
- Postural kyphosis

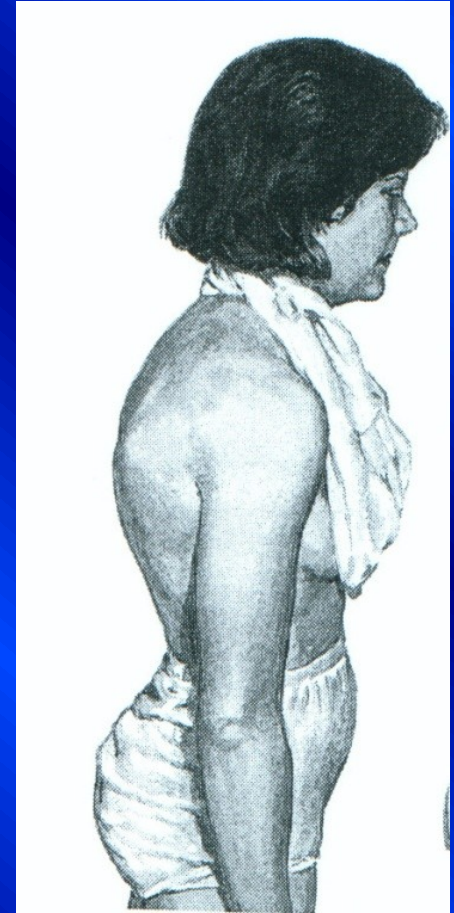
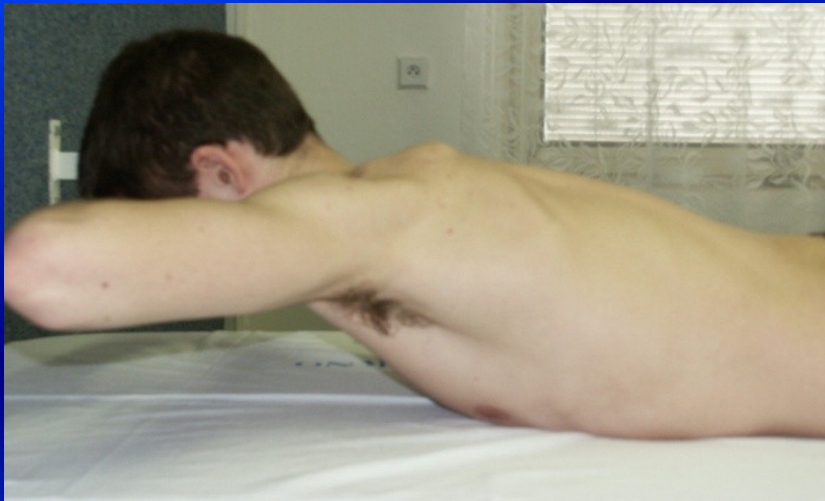Juvenile kyphosis

- 0,5 - 8 % of population
- boys more often
- age 12-18 years
- Etiology- idiopathic, multifactorial
- distal thoracic region more often



Juvenile kyphosis

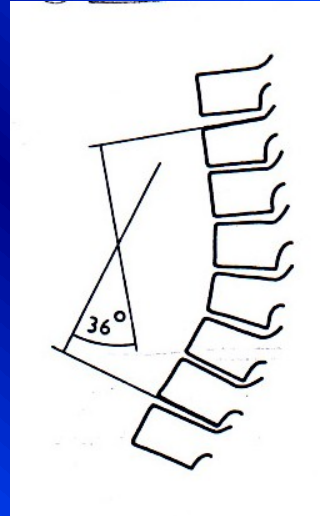
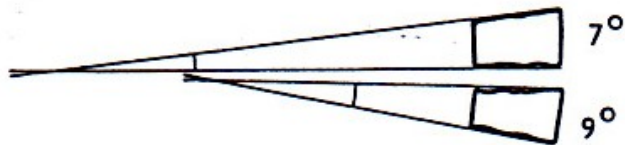
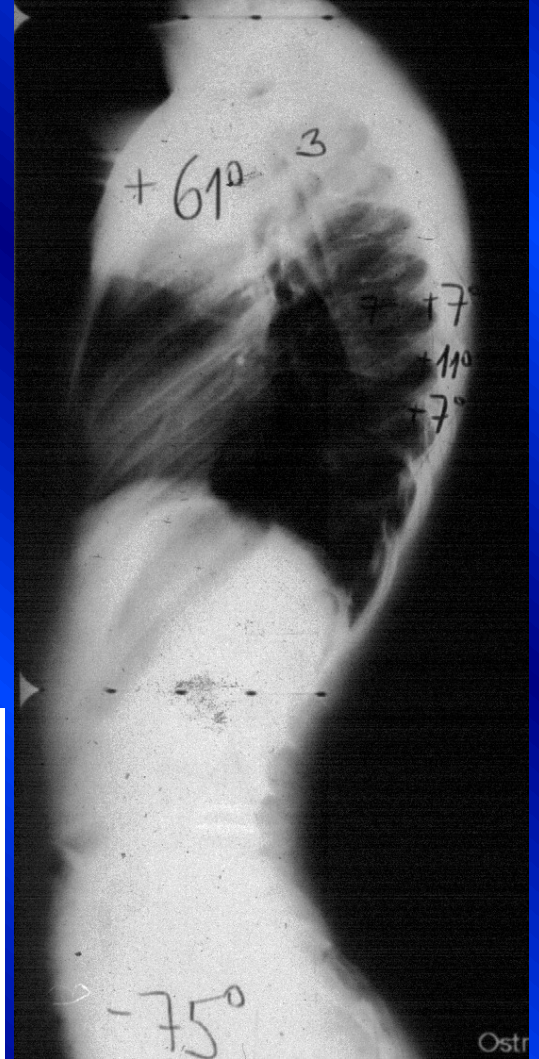- Increased thoracic kyphosis above 40°
- Fixed kyphosis (hyperextension test)
- Pain
- Limited movements
- Limited dynamics of the spine
- Progression of degenerative changes



Juvenile kyphosis

X ray findings:

- kyphosis above 40°
- Irregularities of end plates
- Schmorl's nodes
- Narrowing of intervertebral disc spaces
- Wedge deformity above 5°
at least in 3 vertebrae



Juvenile kyphosis

Stages

- I. stage - florid (9-12 years, flexible, round back, painful spine, muscle changes)
- II. stage- deformity (13-16 years, fixed advanced X ray changes)
- III. stage- consequences (chronic back pain)

Juvenile kyphosis

Therapy:

- Conservative

- exercise therapy
- orthosis
- plaster of Paris brace, later on orthosis
+ exercise
- in florid stage- no sports, no weightbearing
- NSAD, analgetics, myorelaxans

- Surgery + bracing + exercise

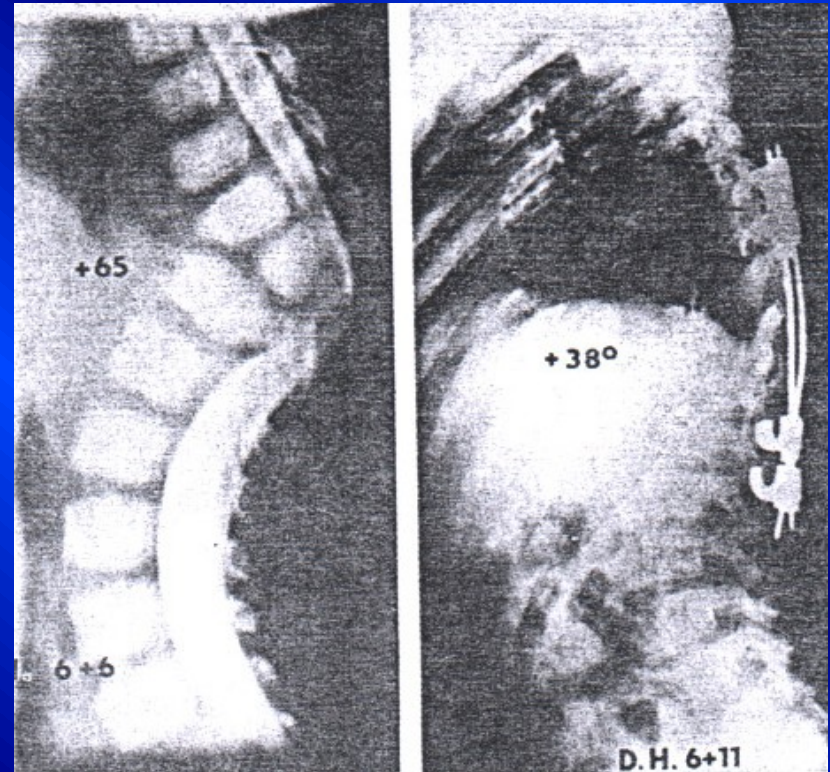
Congenital kyphosis

Etiology

- Disturbance of the form
- Disturbance of segmentation
- Combined disturbance

Therapy:

- to prevent progression
- Surgery in progressive curves
- Spondylodesis – fusion + bracing
till the end of the growth
- anterior osteotomy with correction of the curve
+ posterior fusion with instrumentation



Postural kyphosis

- in muscle imbalance
lack of exercise, lack of sports
sedentary way of life
- weak trunk and abdominal muscles
increased lumbar lordosis and thoracic kyphosis

Management:

- regular exercise of muscles- trunk, abdominal ..
- sports activities
- adherence to active life
- profesional fysiotherapy