

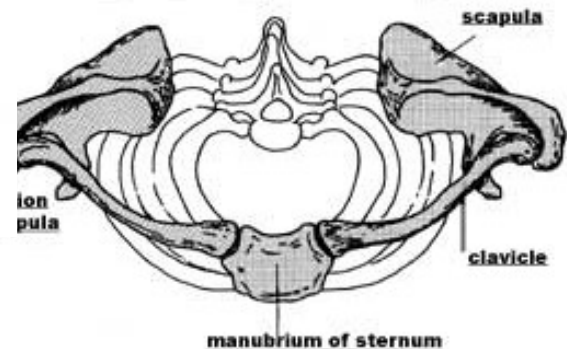
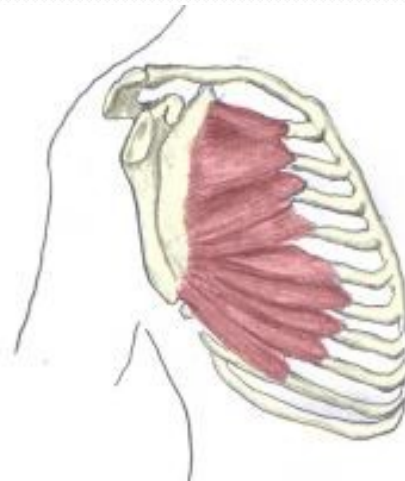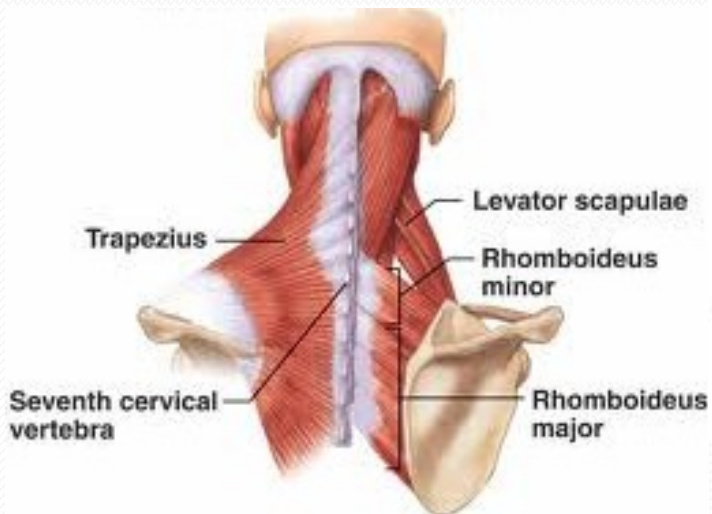
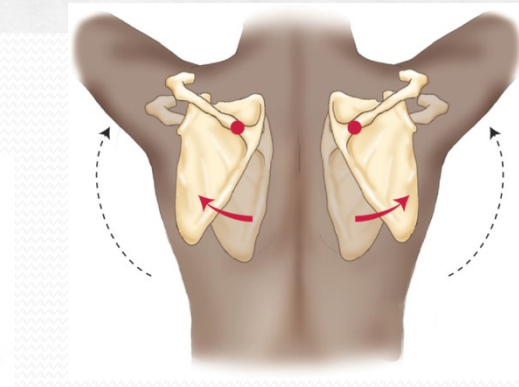
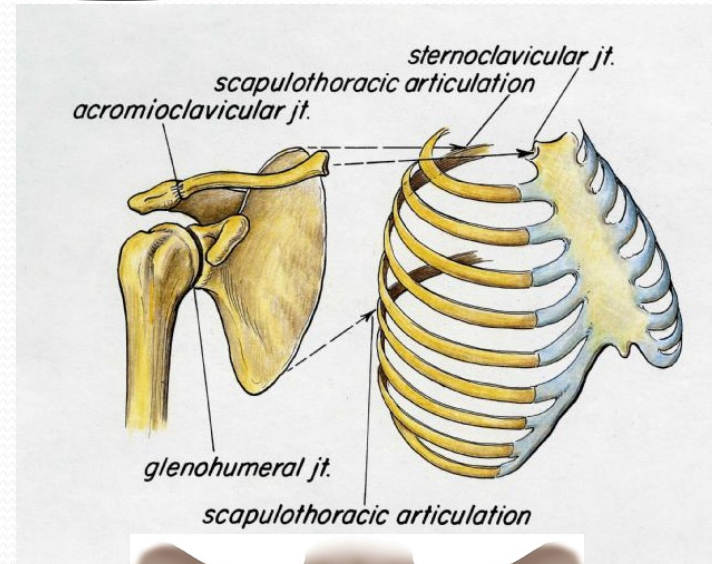


Shoulder

Pazourek, L., Rozkydal, Z.

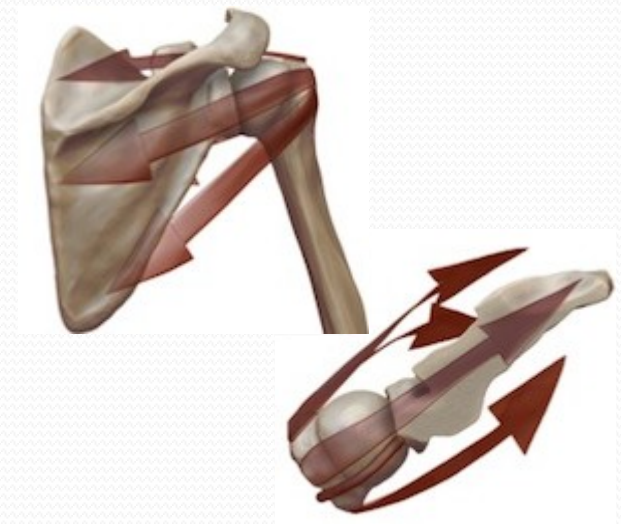
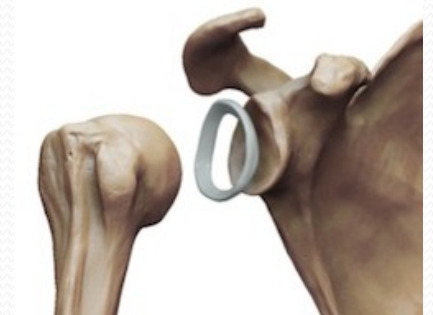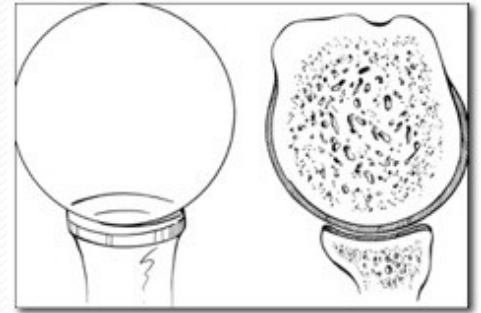
5 joints

- Glenohumeral
 - Acromioclavicular (AC)
 - Sternoclavicular (SC)
 - Thoracoscapular
 - Bursal joint
- + connection to Th and C spine



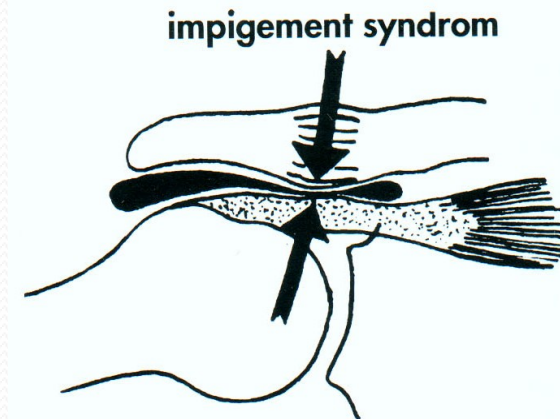
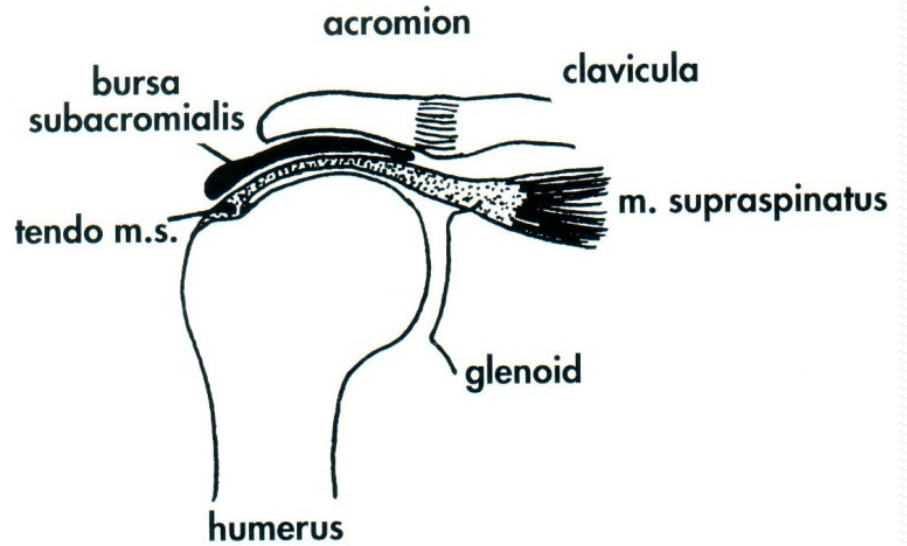
Stability of GH joint

- Biggest ROM
- small glenoid
- Soft tissue stability
 - Static: labrum glenoidale, capsule, glenohumeral ligaments
 - Dynamic: muscles of rotator cuff
deltoid muscle
- Pathology:
 - Most frequent dislocation
 - Instability- often



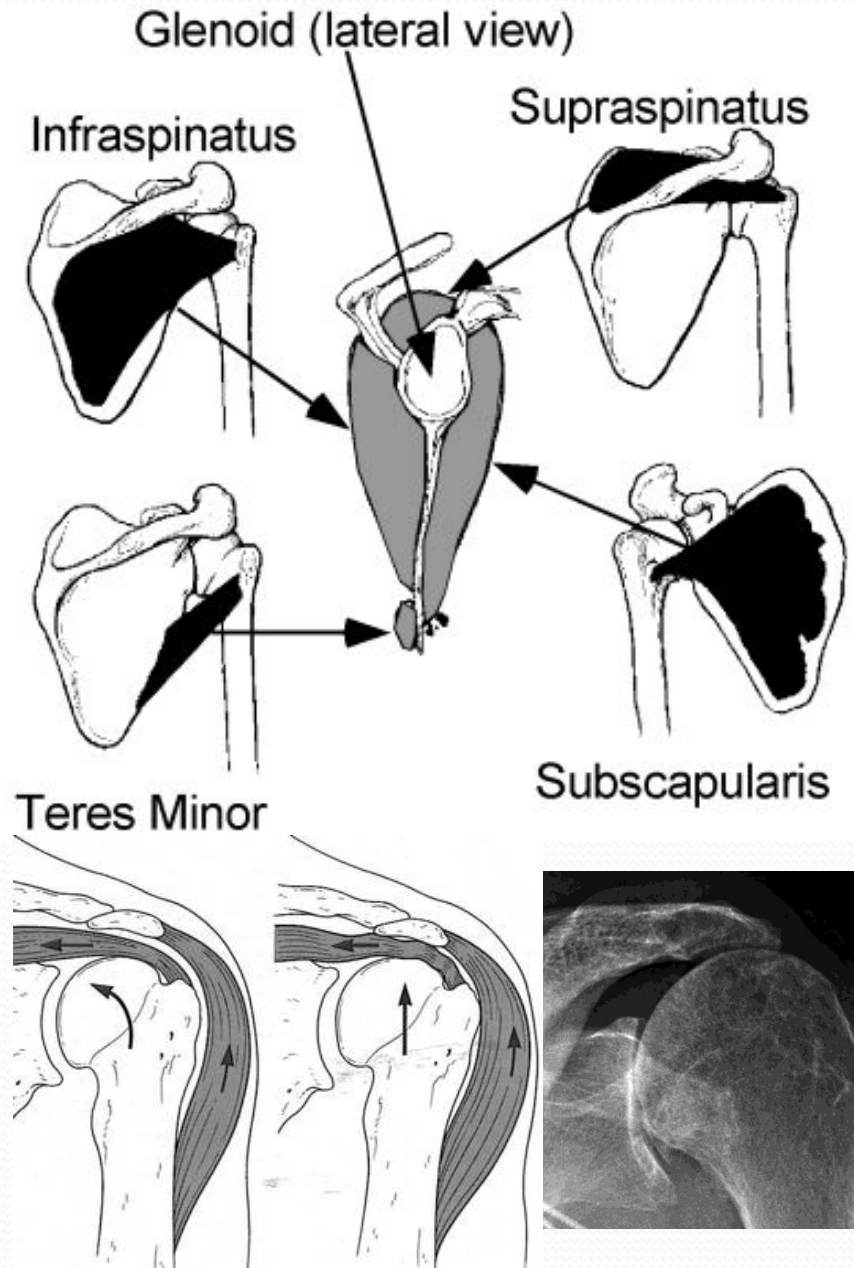
Subacromial joint

- Impingement syndrom
- Subacromial bursa



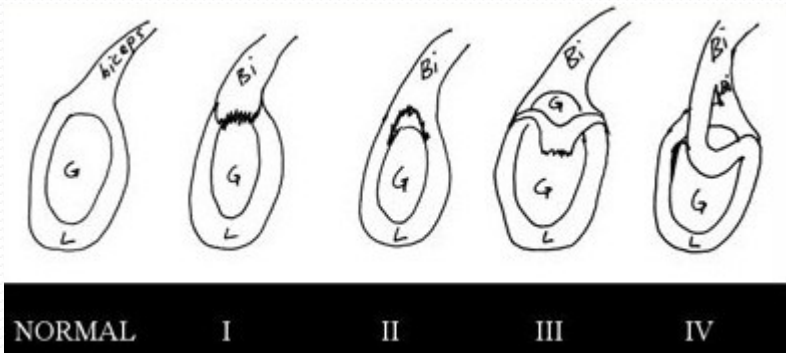
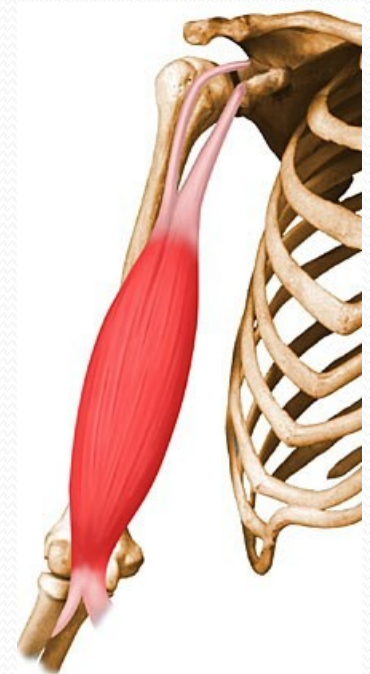
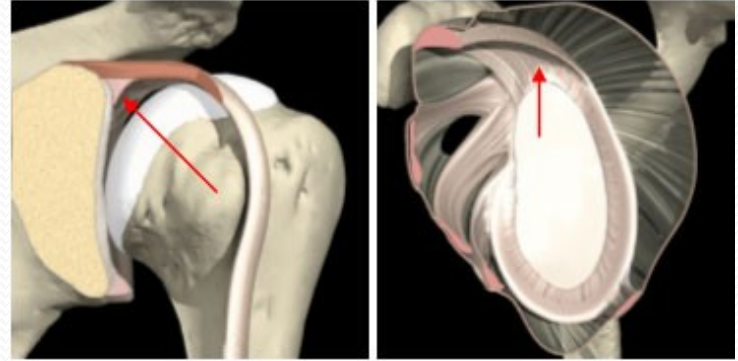
Rotator cuff

- m.subscapularis, m.supraspinatus, m.infraspinatus, m.teres minor
- Movement in GH joint
- Depression of the humeral head
- Dynamic stabilisation



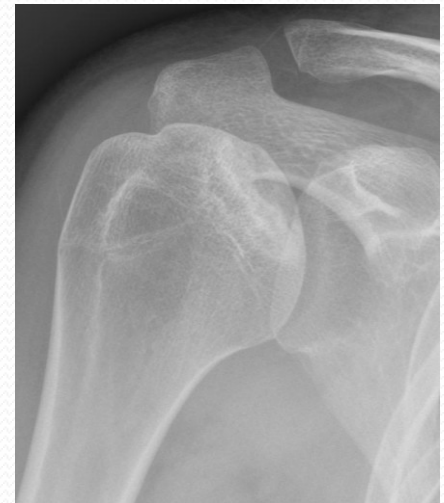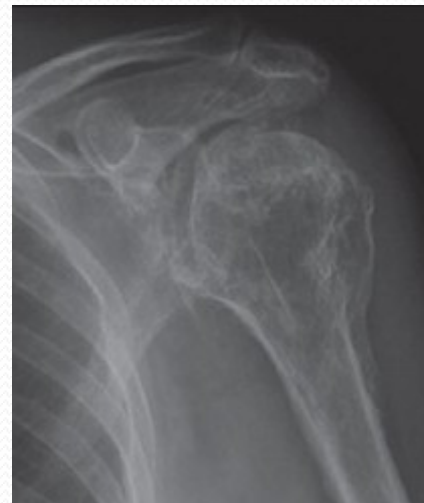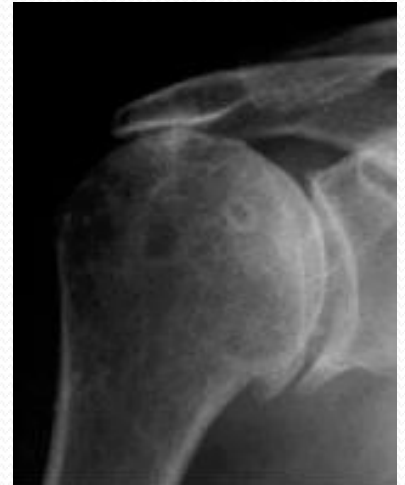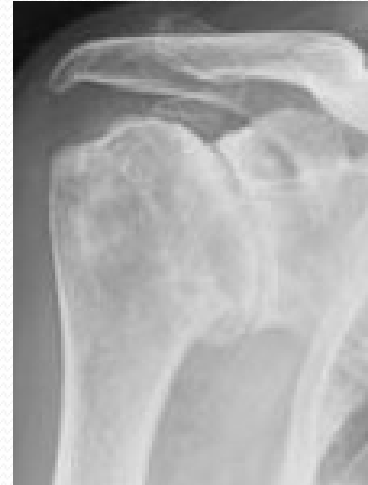Long head of biceps LCMBB

- intraarticular
- Insertion to upper portion of labrum
- Pathology:
 - tenosynovialitis
 - Rupture
 - SLAP



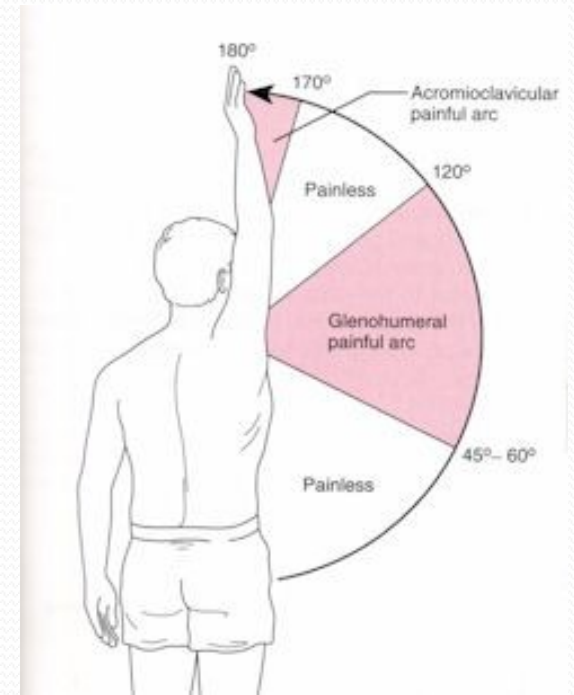
GH joint

- Primary O.A. less frequent
 - Posttraumatic
 - R.A.
 - Rotator artropathy
 - Necrosis of humeral head



Analysis of pain

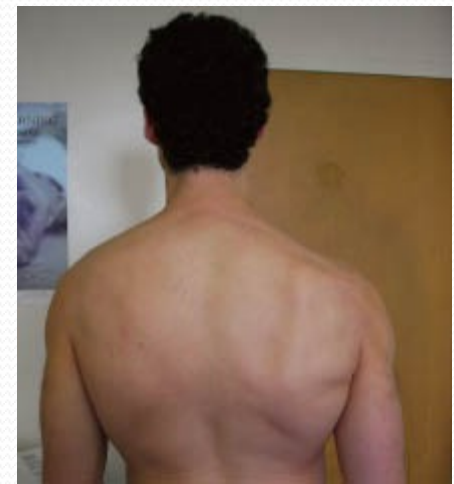
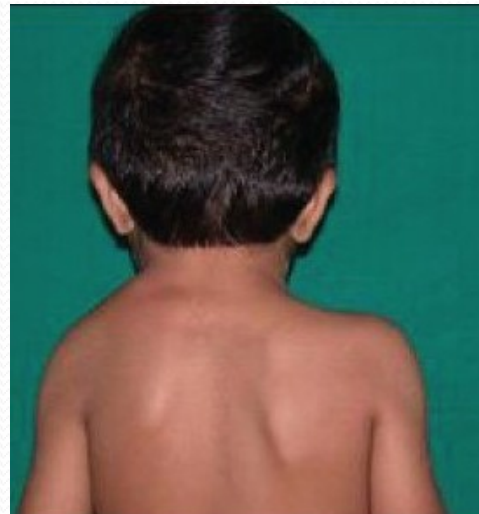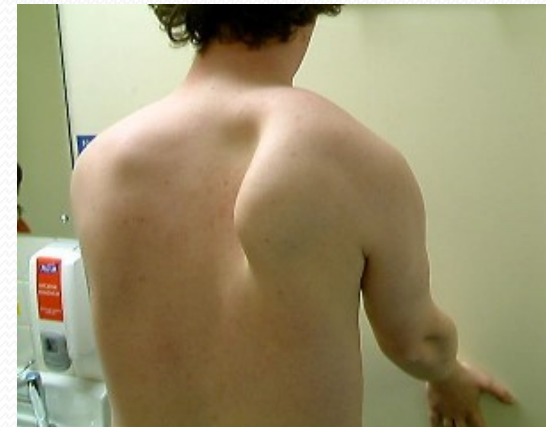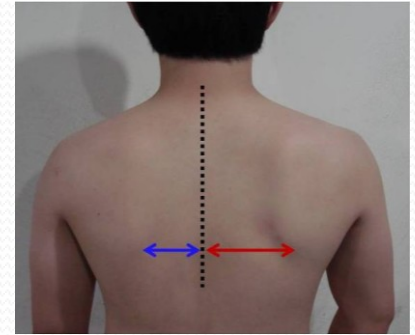
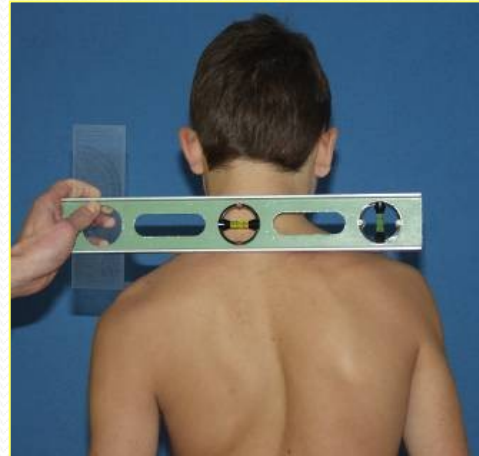
- impingement syndrom –painful arc
- **Pain in full elevation**– AC joint
- **Pain in abduction 20-30 degree**–supraspinatus



- **Pain in rest or during night** – pyogenic arthritis, O.A., R.A. acute rpt of RC, acute tendinitis
- **Pain irradiating to the shoulder**

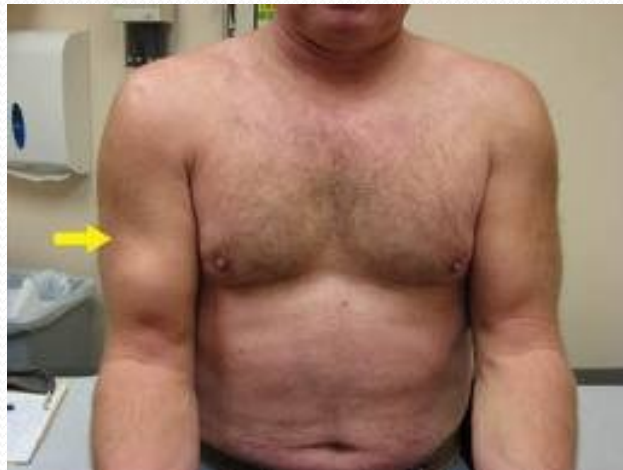
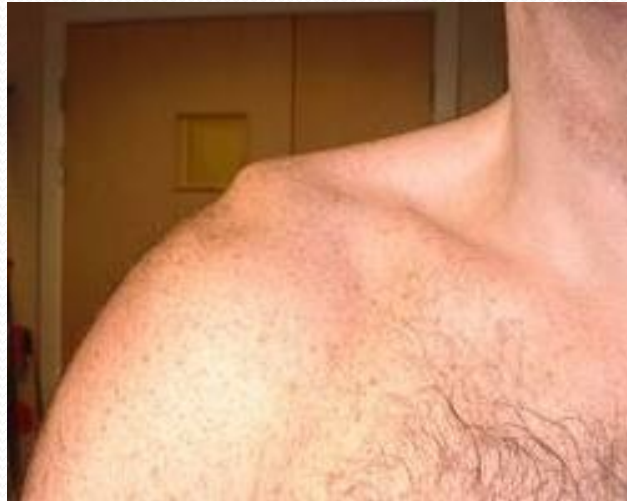Clinical examination

- Deformity of the spine
 - Muscle dysbalance
 - scapula alta -Sprengel
 - Palsy of n. thoracicus longus (m.serratus anterior)
 - Palsy of n. accesorius (m.trapezius)

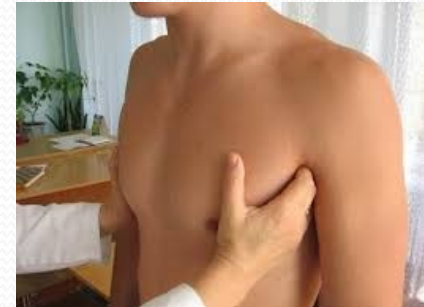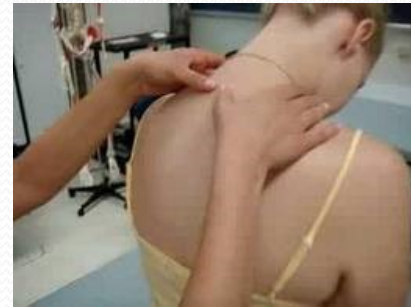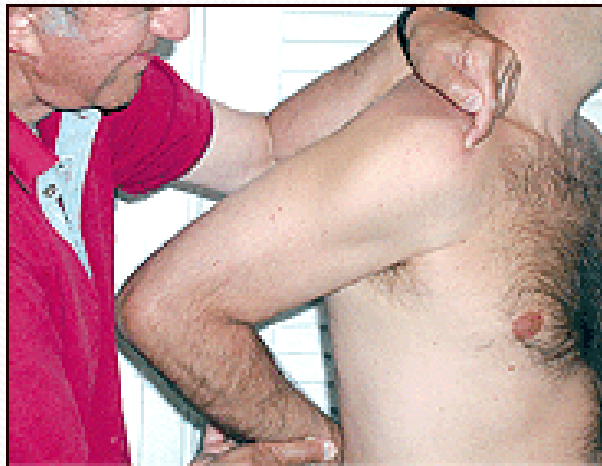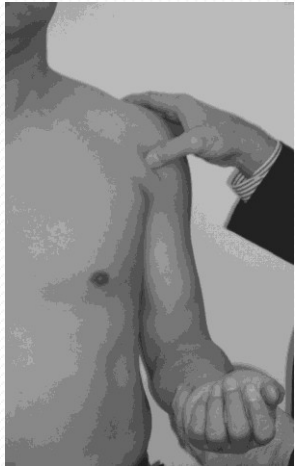
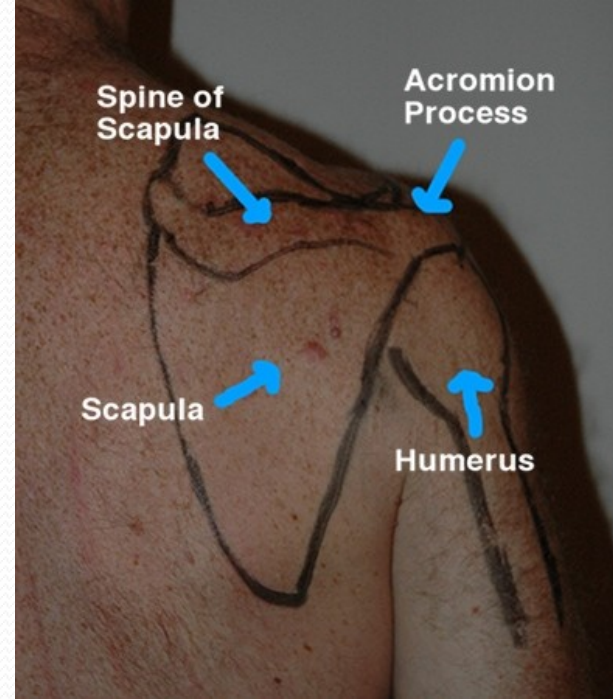
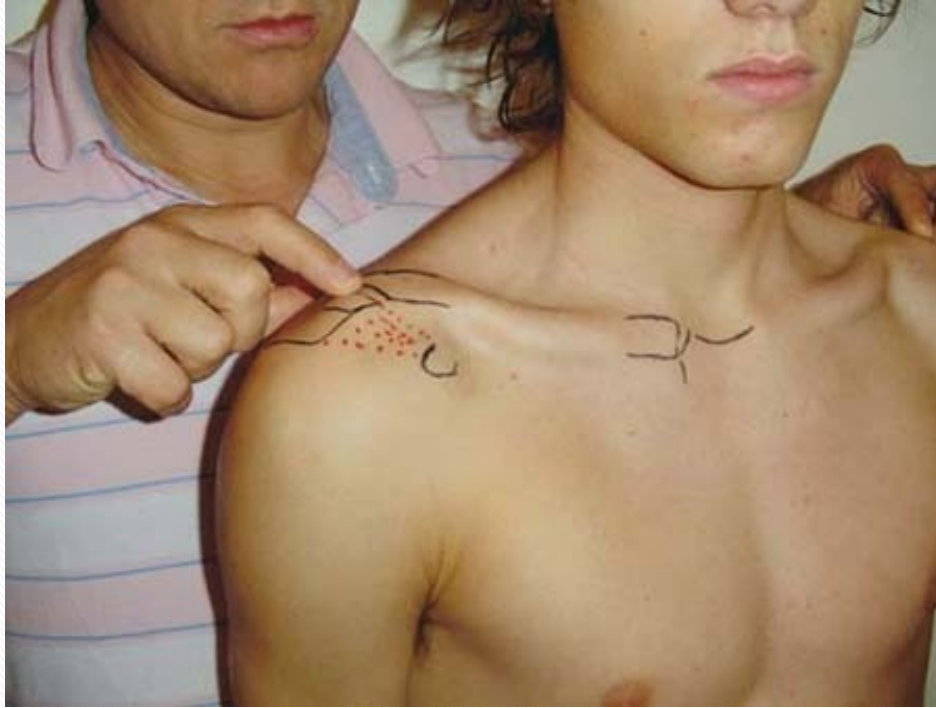


Clinical examination

- Muscles
- Antalgic position
- Swelling
- Skin

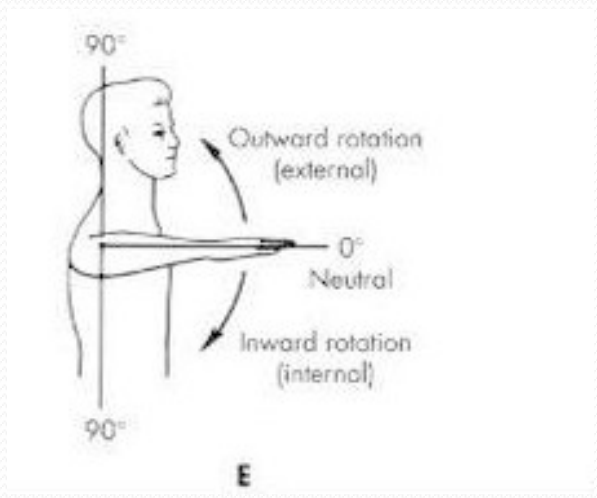
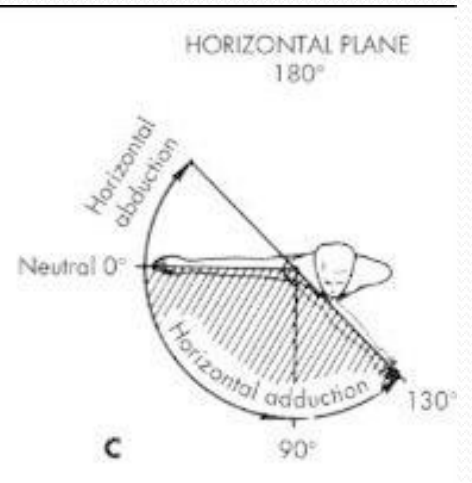
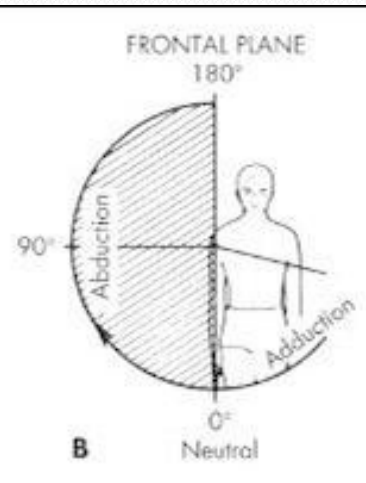
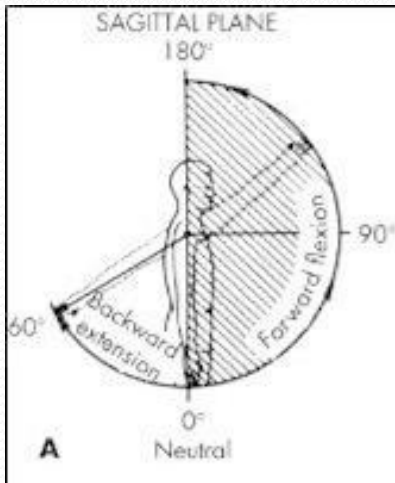
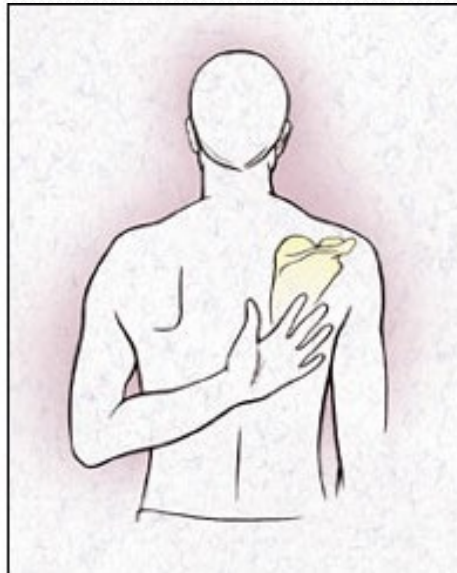
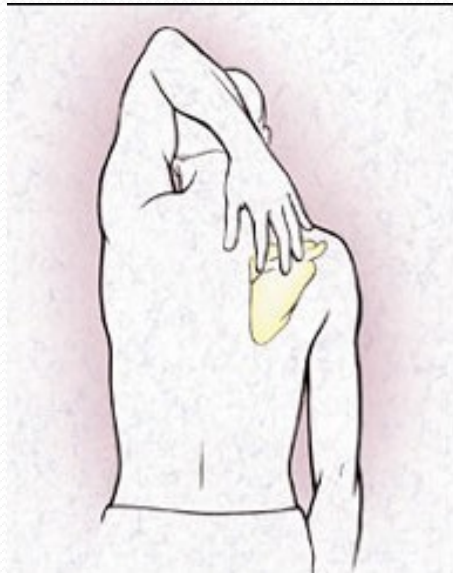


Clinical examination- tenderness



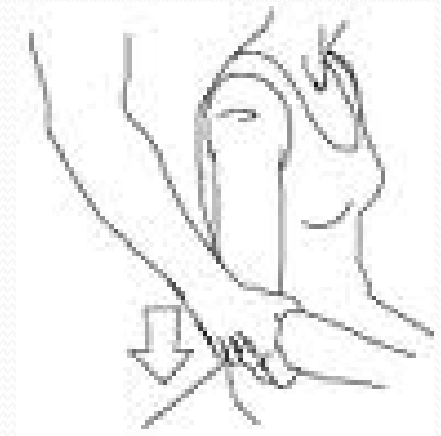
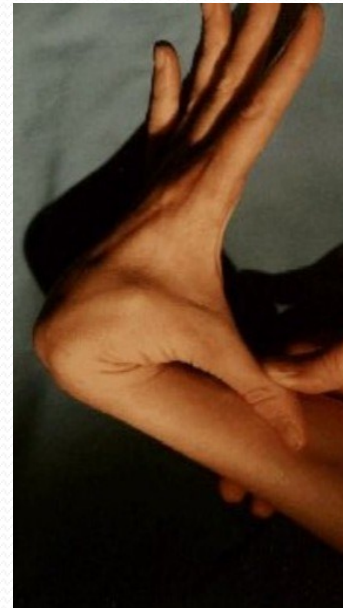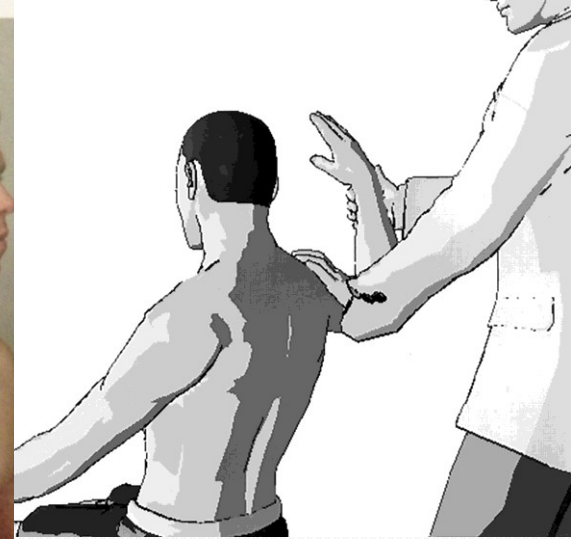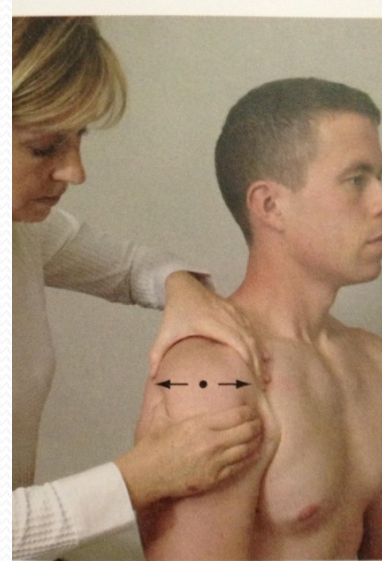
ROM

- SFTR



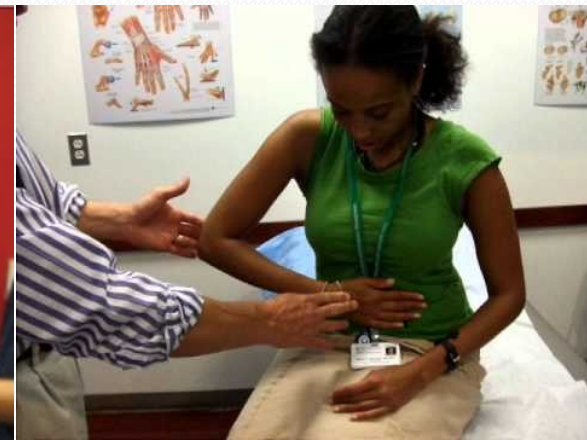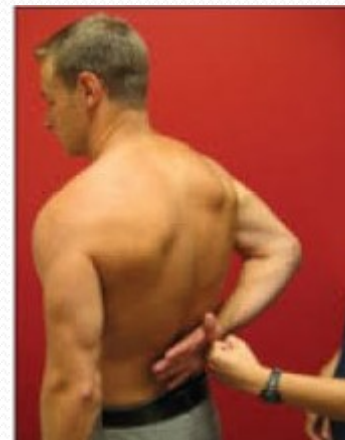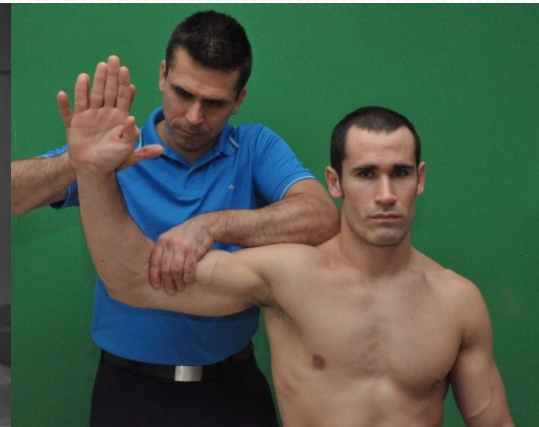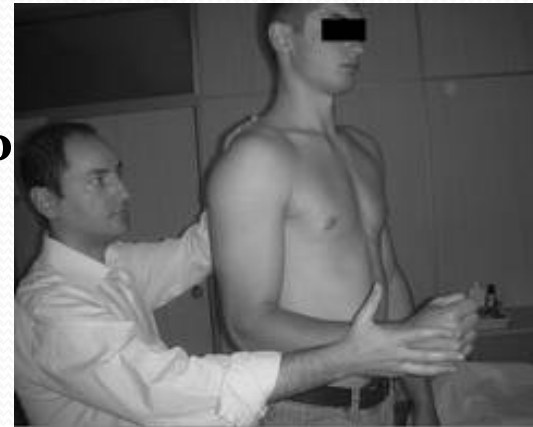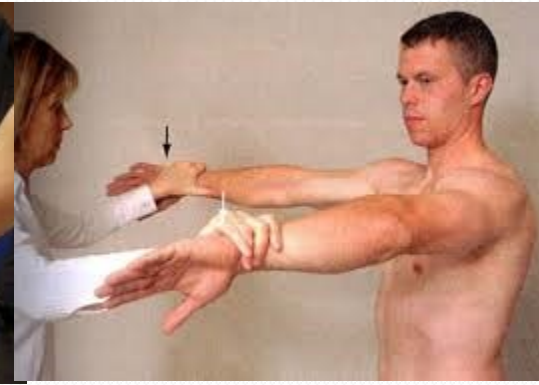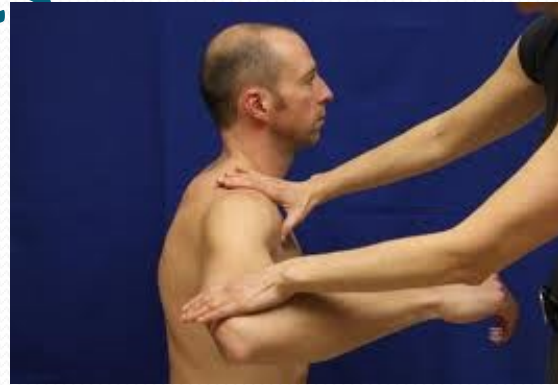Clinical examination – stability

- **Posttraumatic instability**
- (typicky unidirekcionální, přední)
 - přední zásuvka
 - Apperhension test
 - Jobeho relokační test
 - event. zadní zásuvka, zadní Apperhension test (u zadní instability)
- **Habitual instability**
 - příznaky mesenchymální laxicity
 - sulcus sign
 - známky multidirekcionální instability



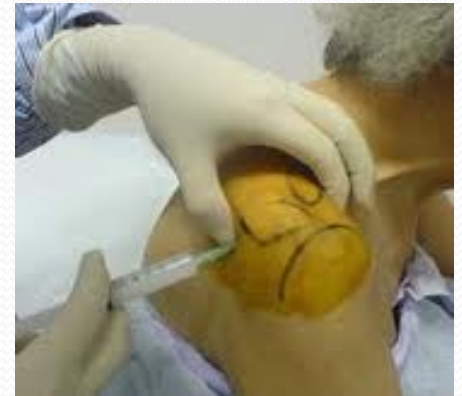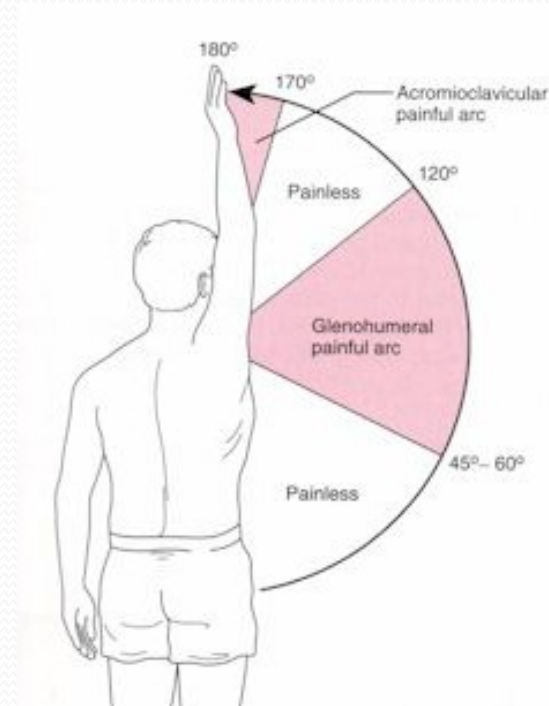
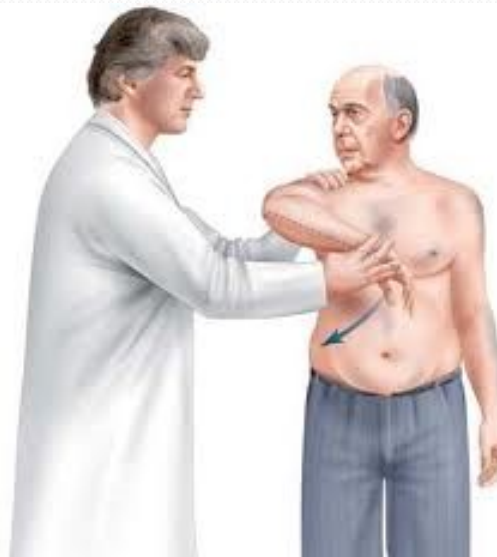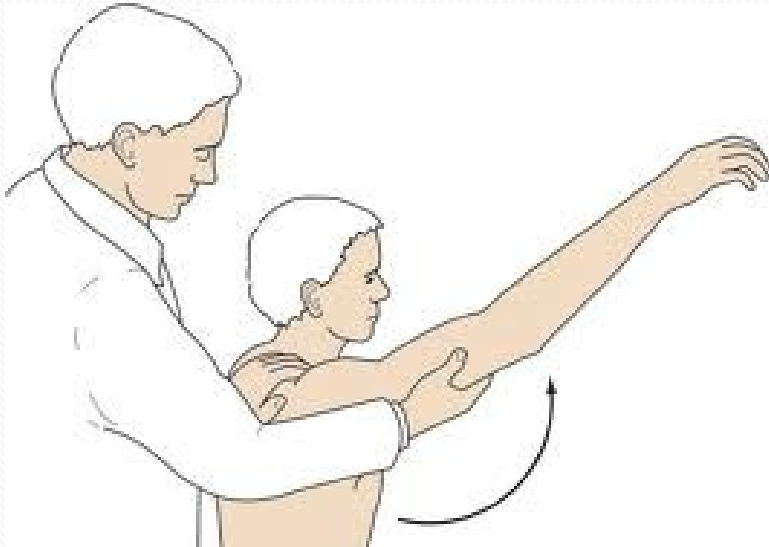
Rotator cuff tests

- Resistance tests
- **m.supraspinatus:**
 - Abduction
 - Jobe test
 - drop arm test
- **M. infraspinatus, teres minor**
 - External rotation
- **m.subscapularis**
 - Inner rotation
 - Gerber test
 - Napoleon sign (press belly test)



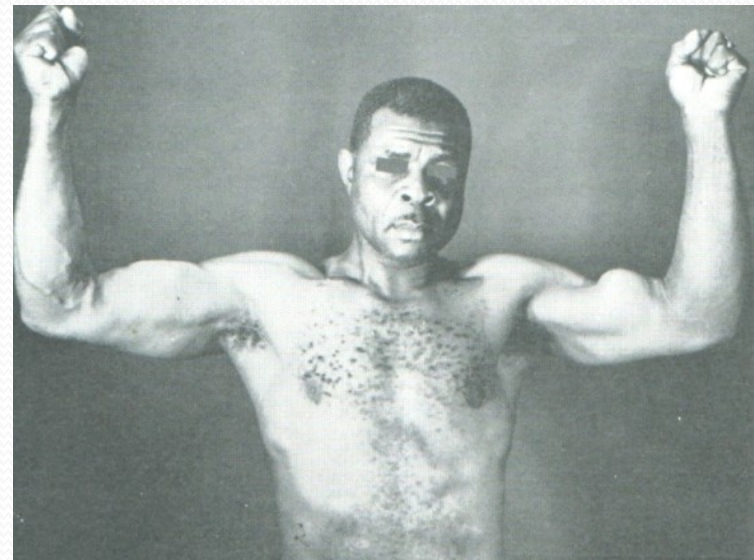
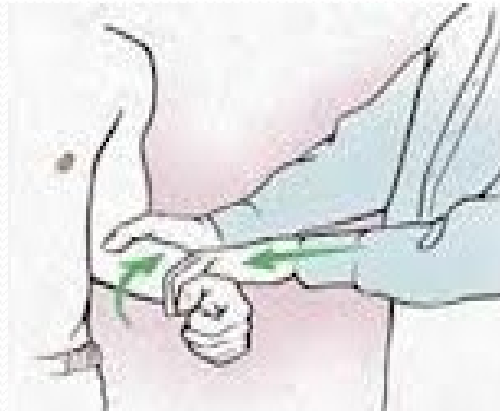
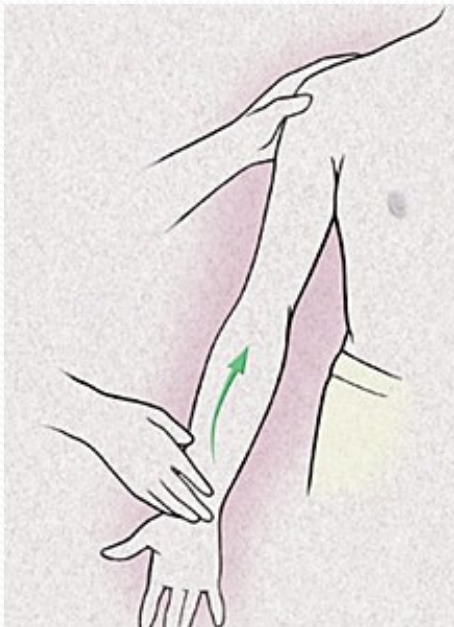
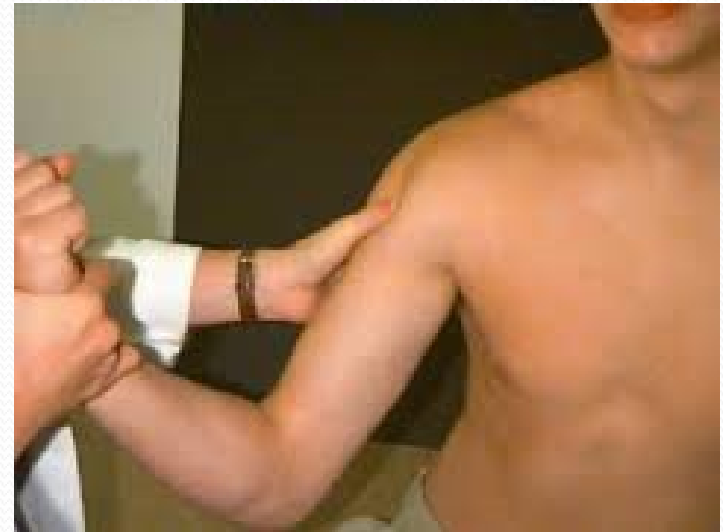Impingement syndrom

- Painful arc (60 – 120 degree)
- crepitation
- impingement sign Neer
- impingement sign Hawkins and Kennedy
- Neer infiltration test



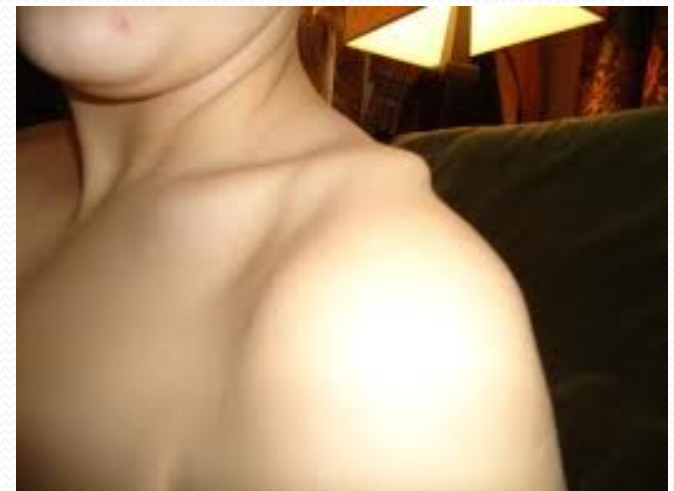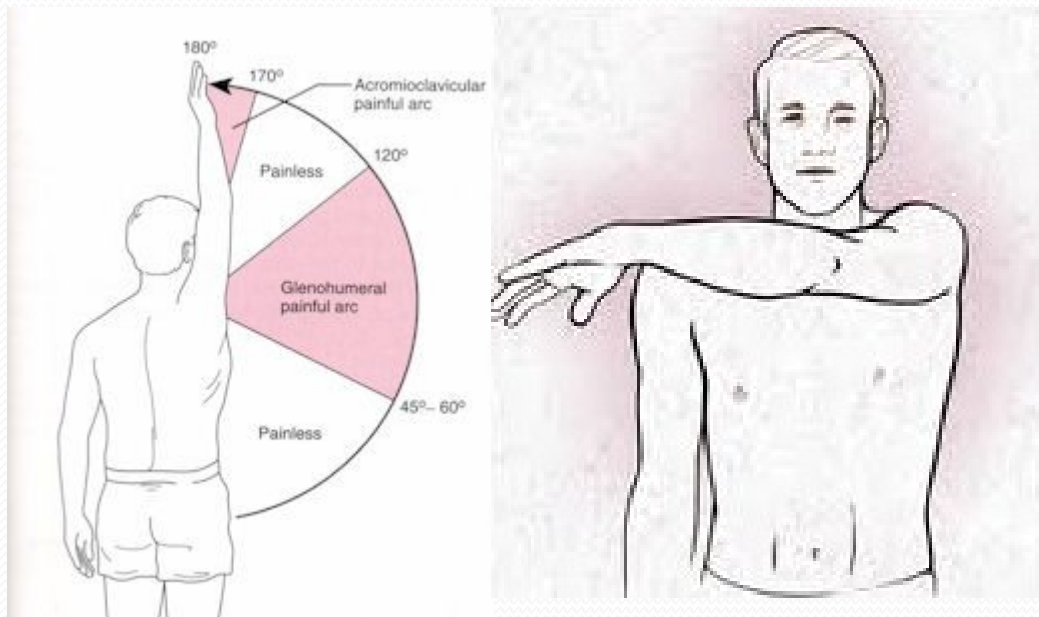
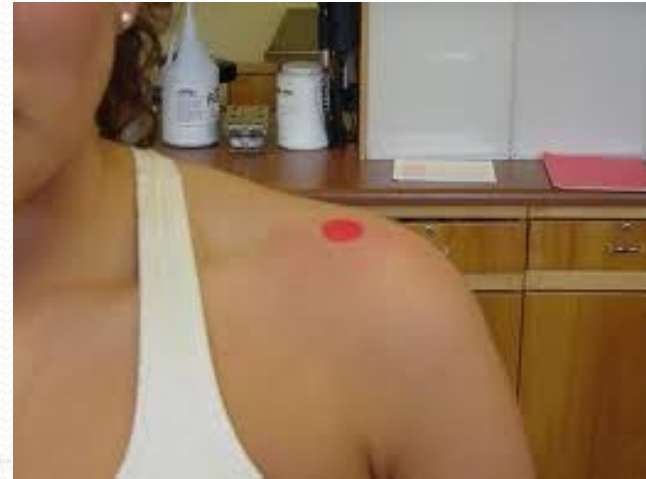Tests for CLMBB

- Tenderness
- Speed test
- Yergasson test
- Distalisation of muscle belly



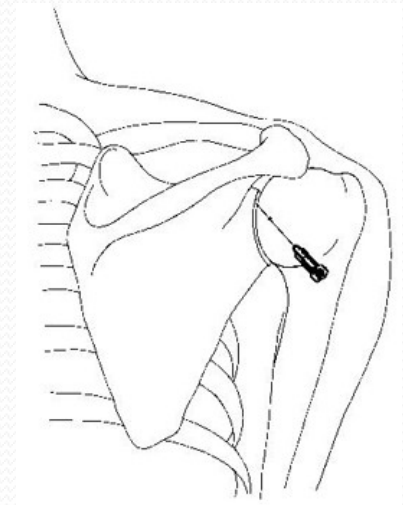
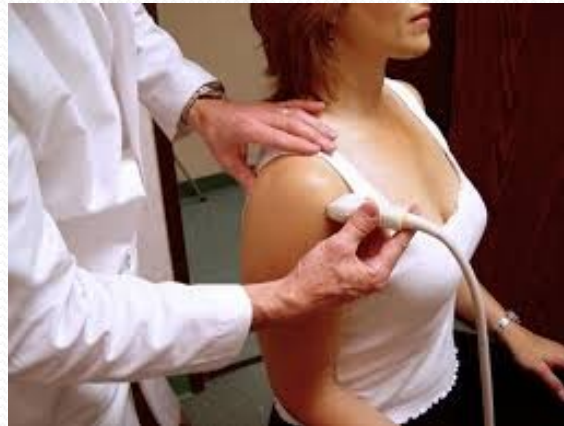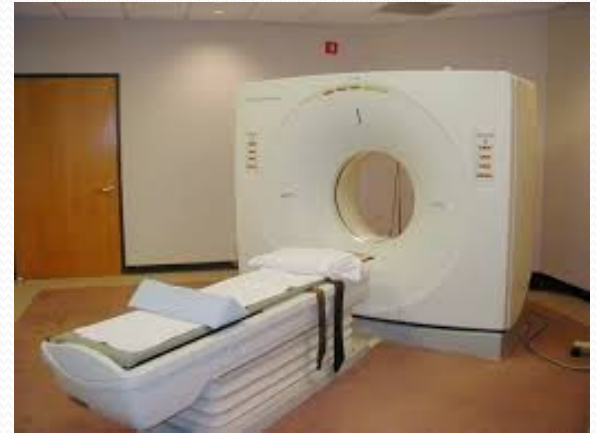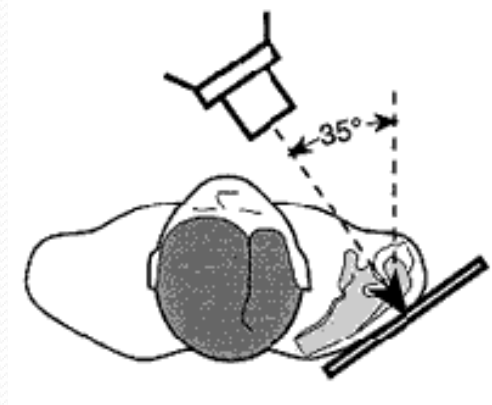
Tests for AC joint

- tenderness
- painful full elevation
- Dislocation of clavicle



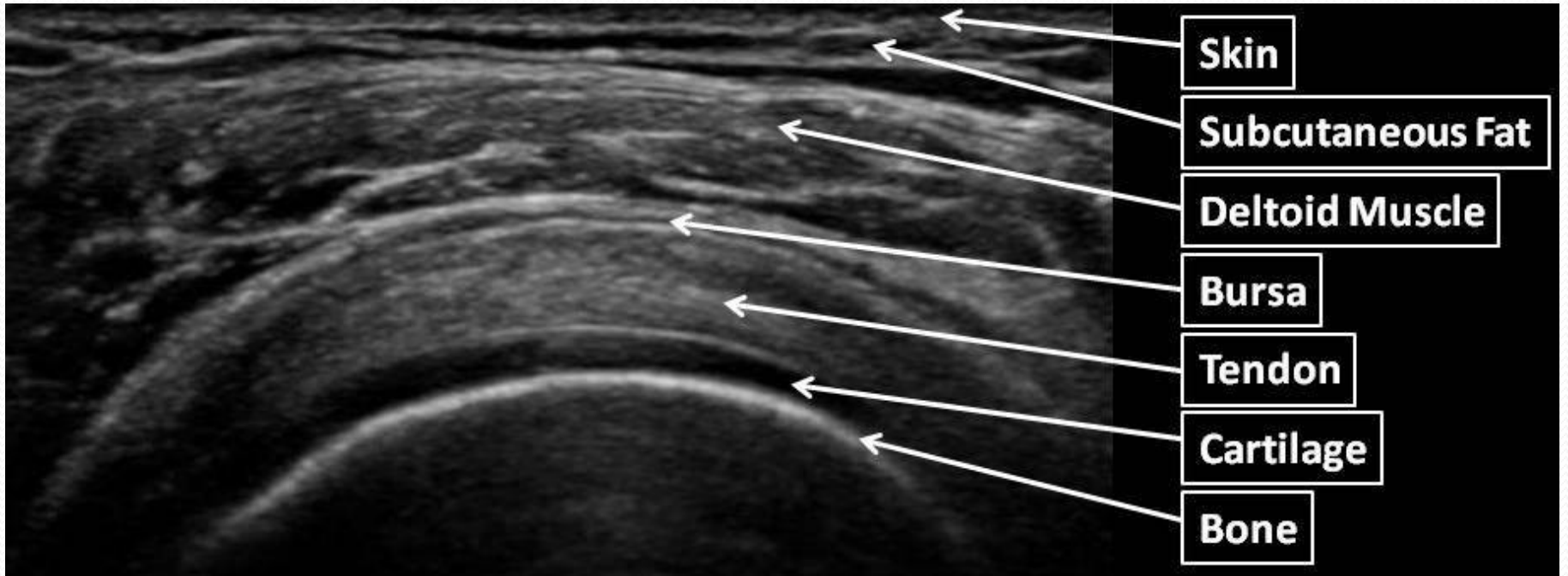
Imaging

- Ultrasonography
- X-ray
- CT
- MRI
- Others



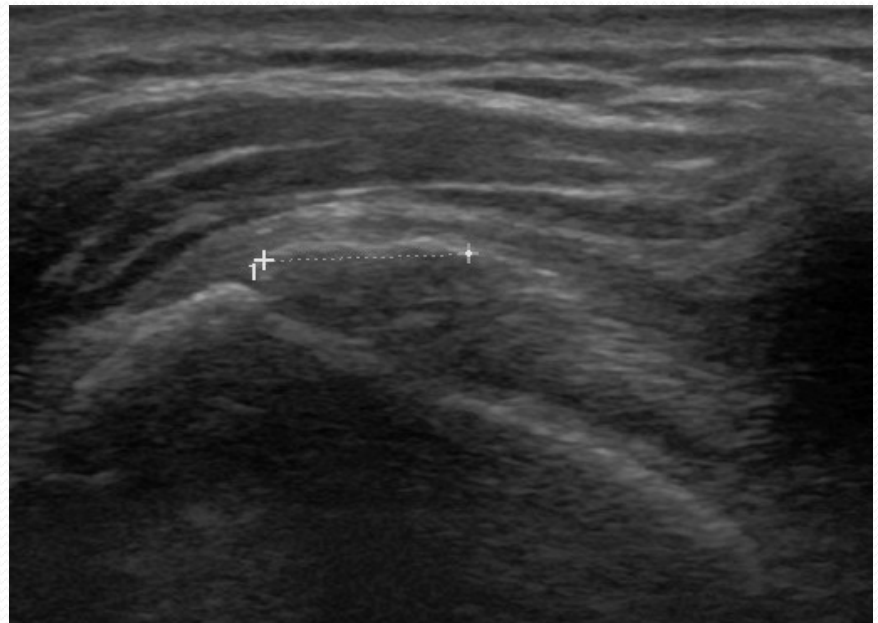
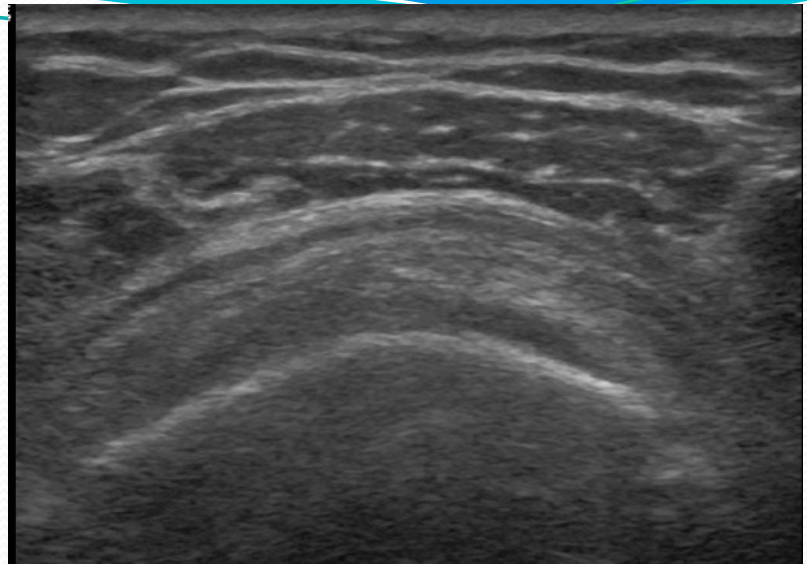
Ultrasonography

USG



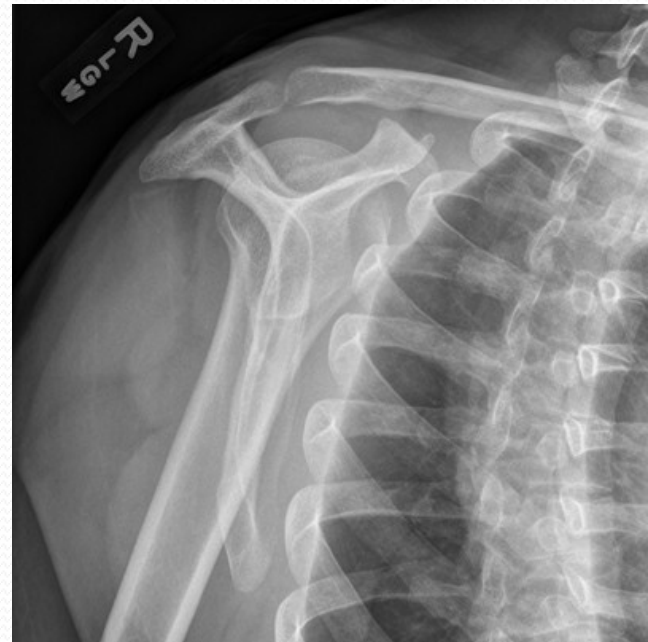
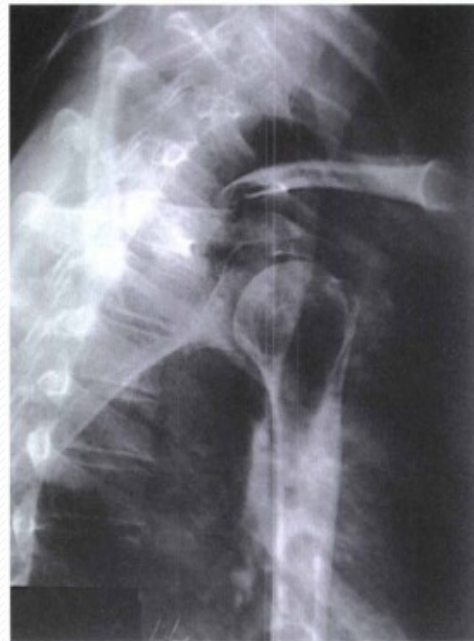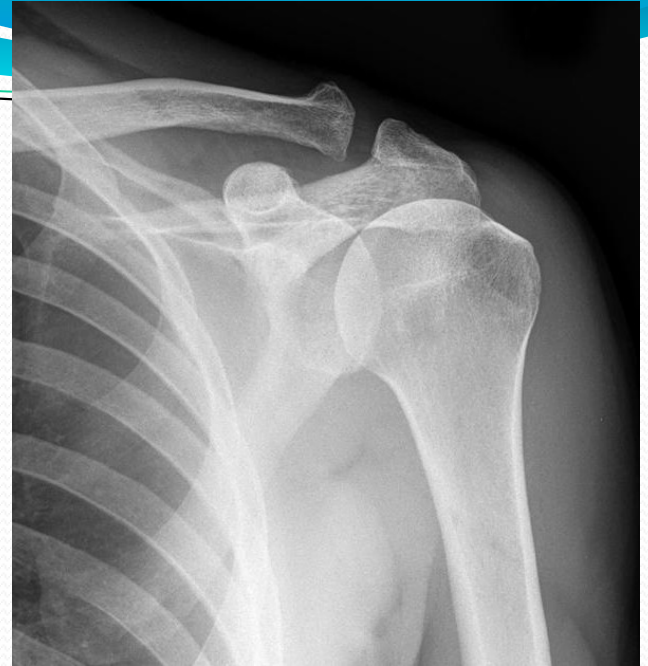USG

- impingement syndrom
- SA bursa
- RC
- Changes in



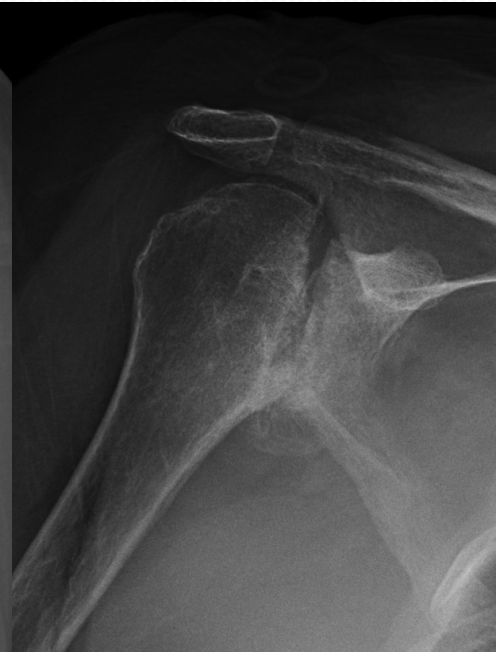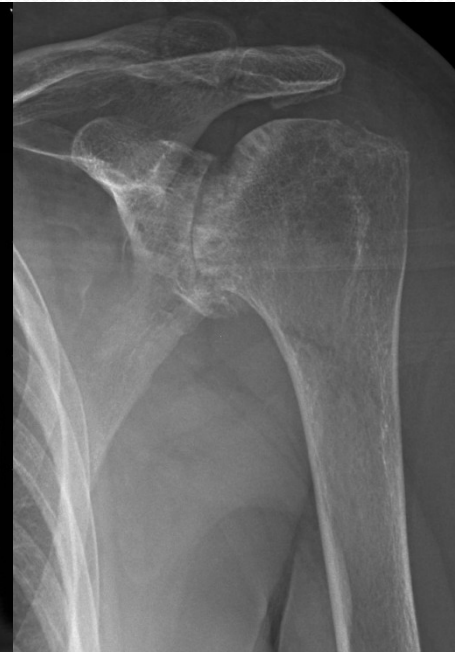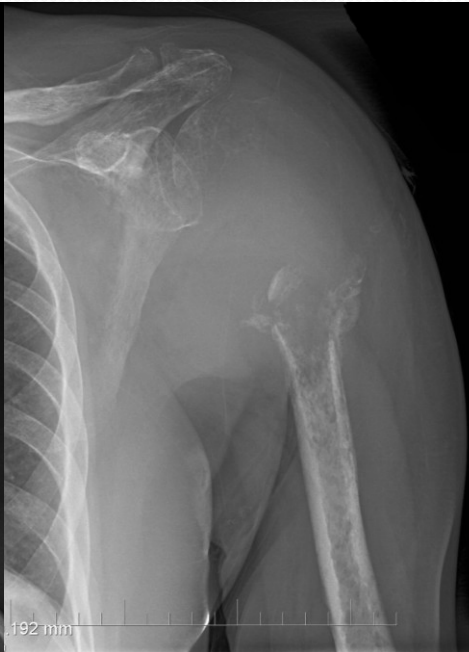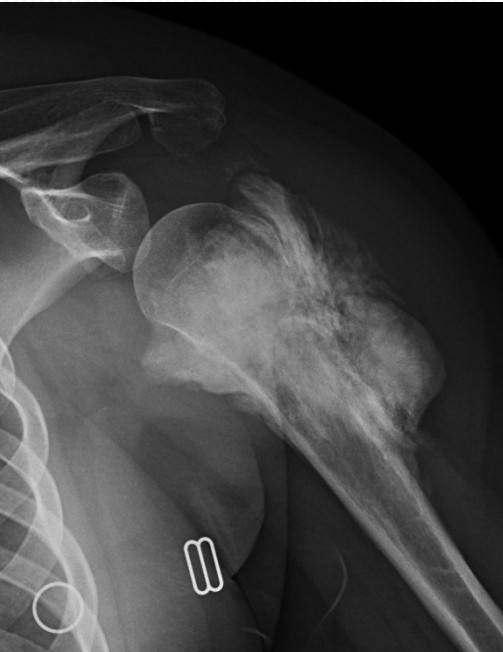
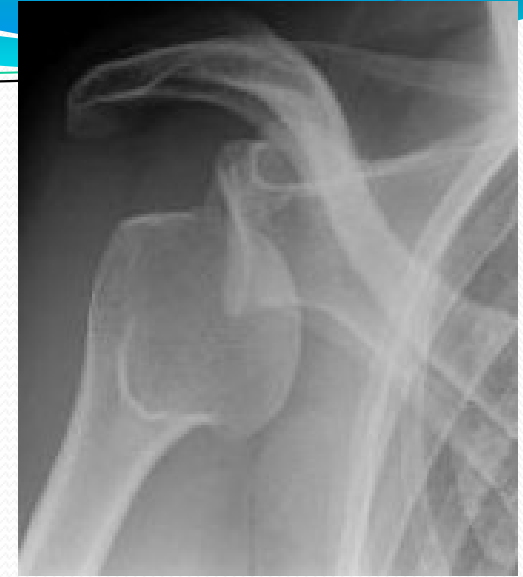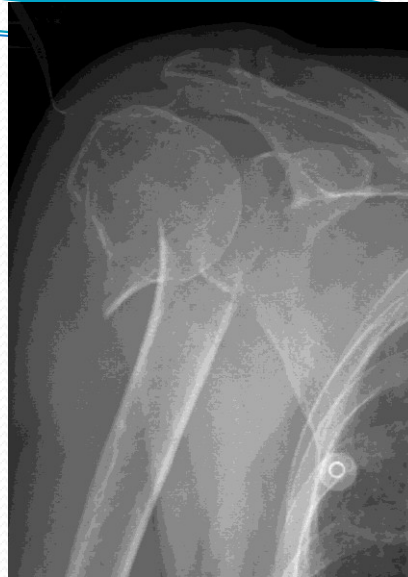X ray

- ap
- axial
 - inferoposterior
 - transthoracal
- Y projection



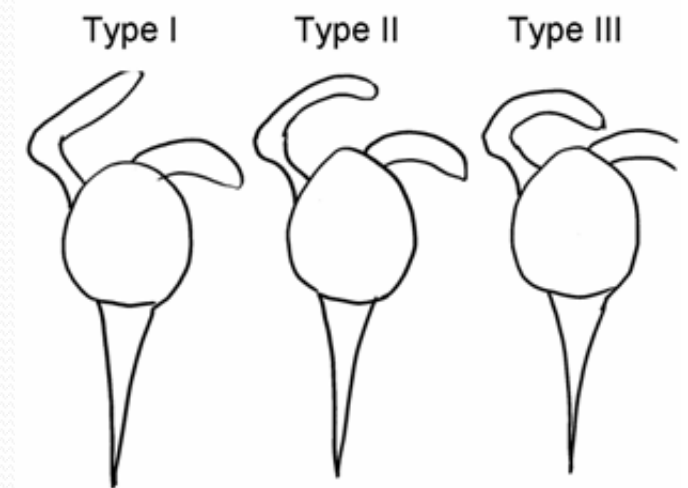
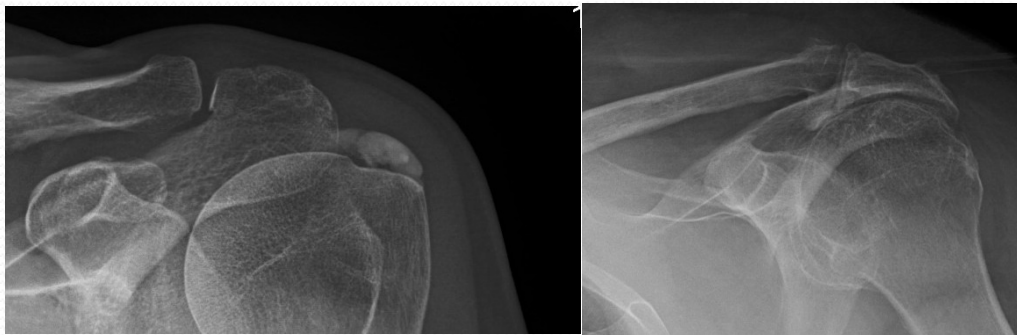
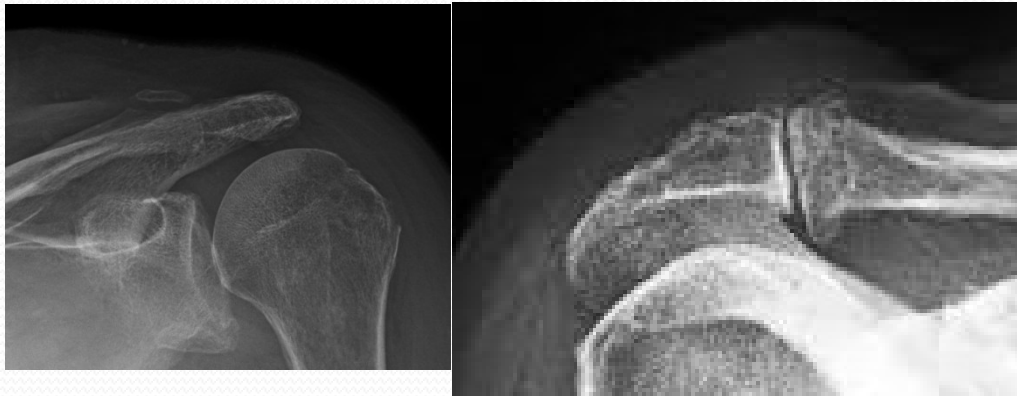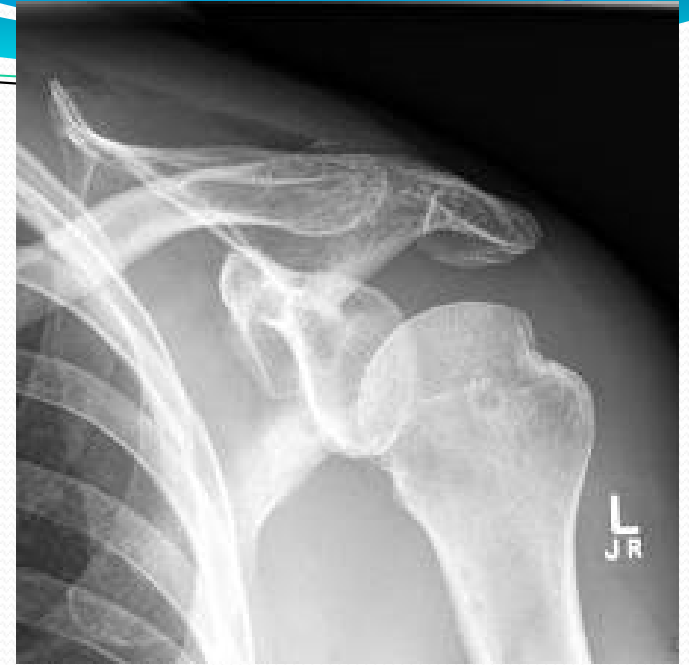Xray

- X ray



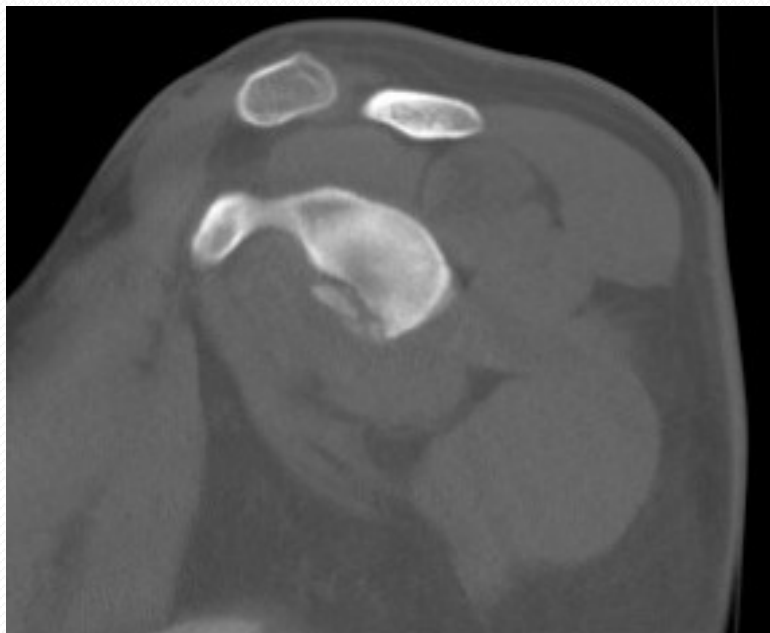
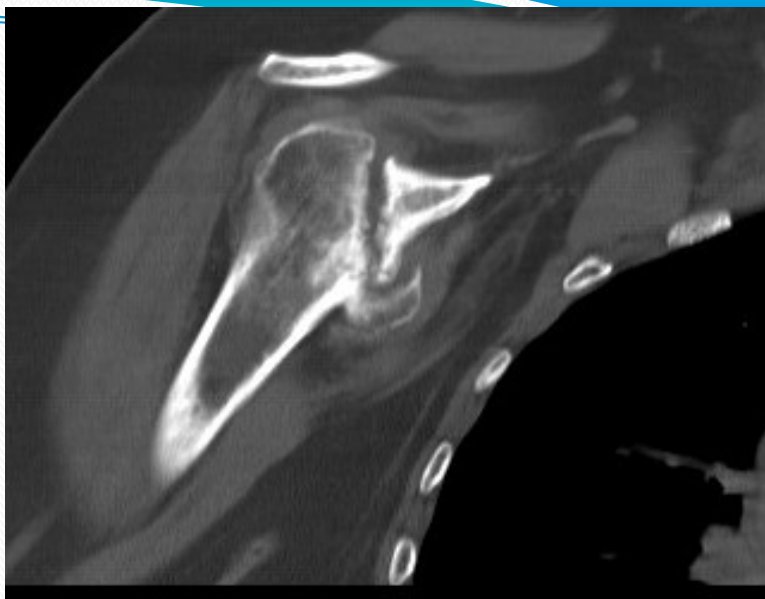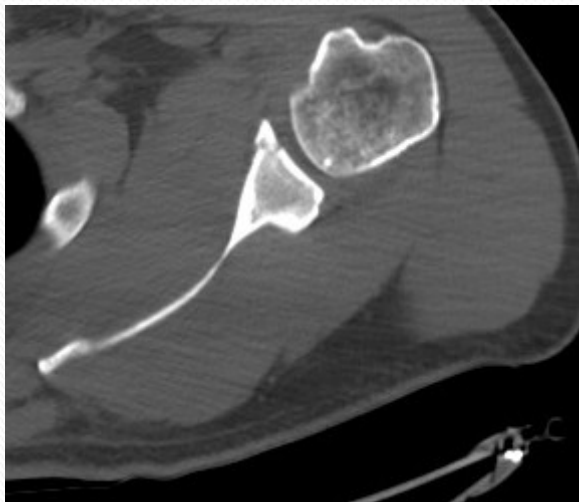
X ray

- instability (Hill Sachs defect)
- Subacromial space



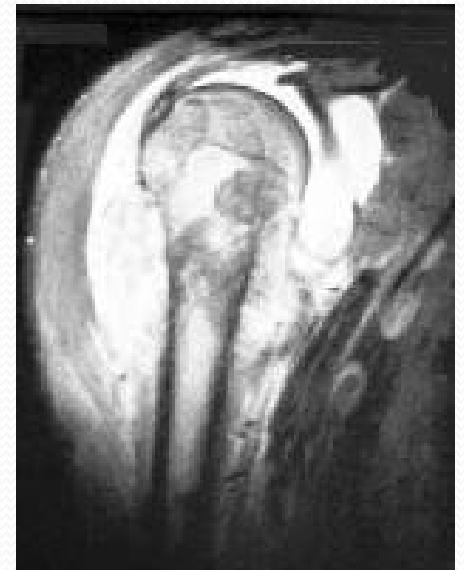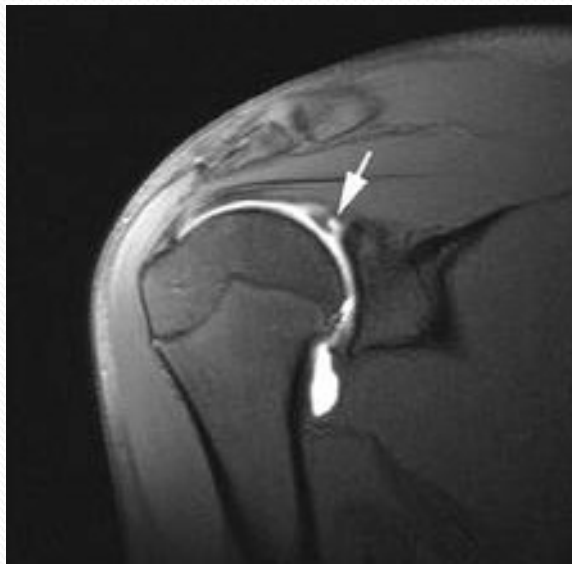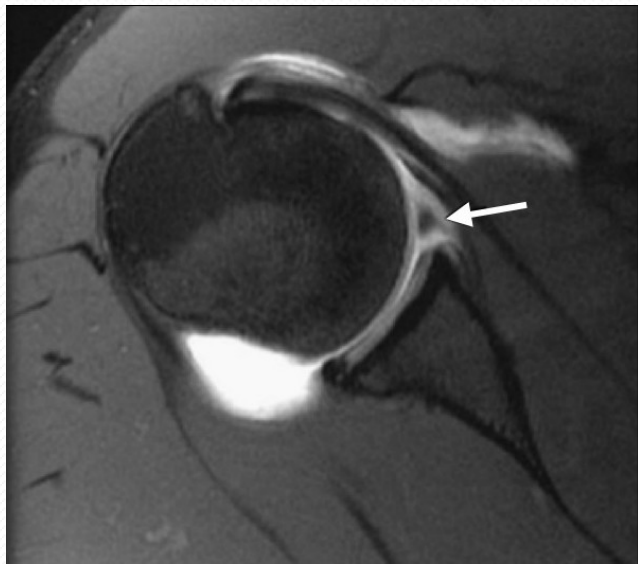
CT

- CT



MRI

- Soft tissue



Painful shoulder

Tenosynovitis of tendon of long head of biceps

Rupture of tendon of long head of biceps

Subacromial bursitis

Supraspinatus tendinitis

Rotator cuff rupture

Impingement syndrom

Frozen shoulder syndrom

Osteoarthritis of glenohumeral joint

Disorders of acromioclavicular joint

Inflammations

Tumors

Referred pain from cervical spine

Tenosynovitis of long head of biceps

Tenderness

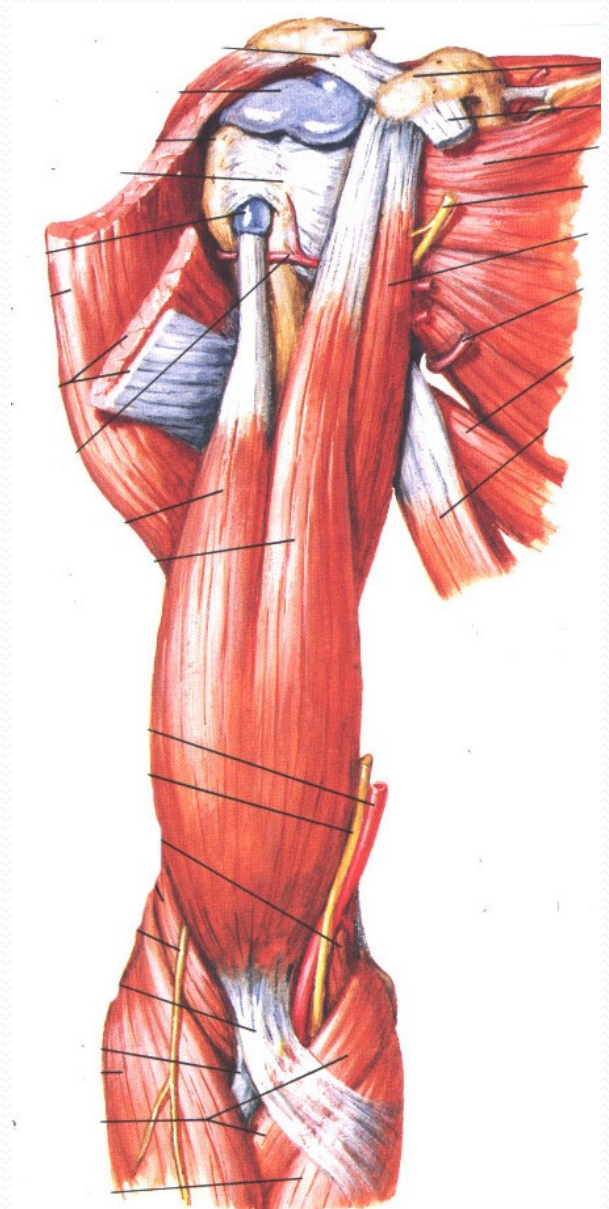Resisted flexion and supination
of the elbow

Therapy:

Corticosteroids locally

Rest, sling

NSAID



Rupture of long head of biceps

Therapy:

Rest, sling

NSAID

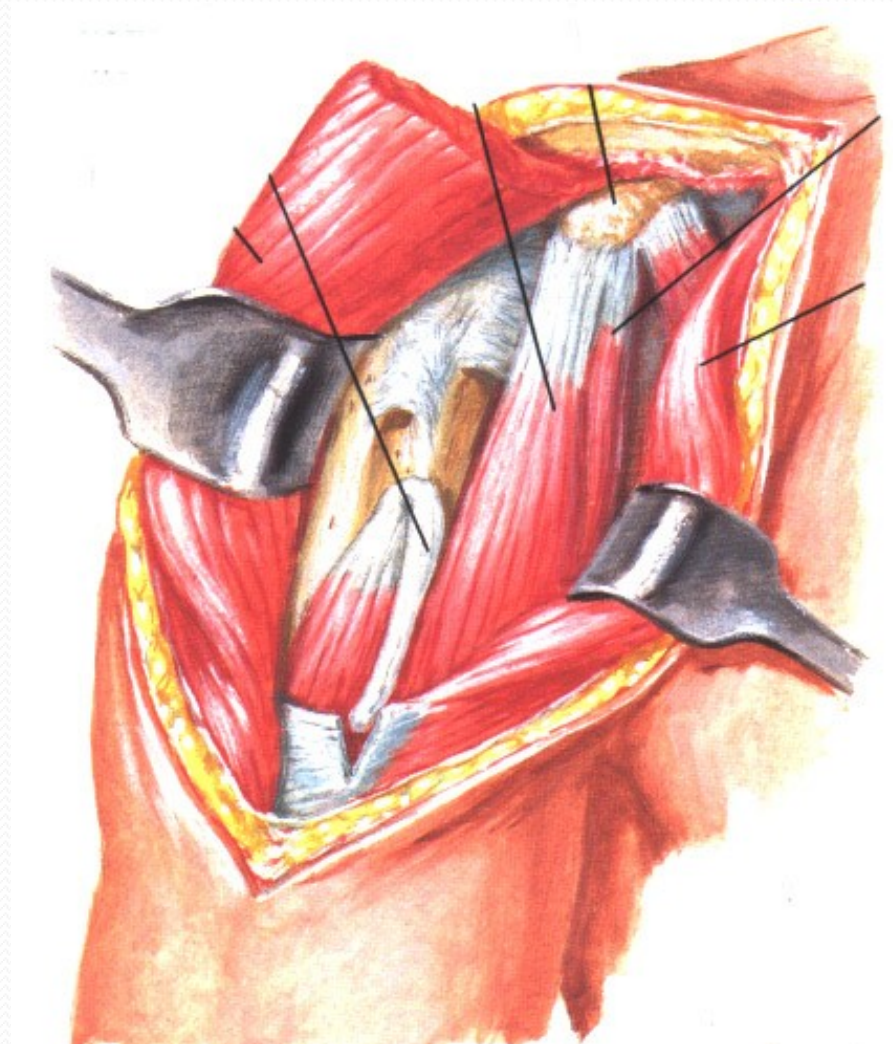
Surgery – up to 40 years

Conservative- over 40 years

Surgery:

key hole fixation to the humerus

Suture to the short head
of biceps

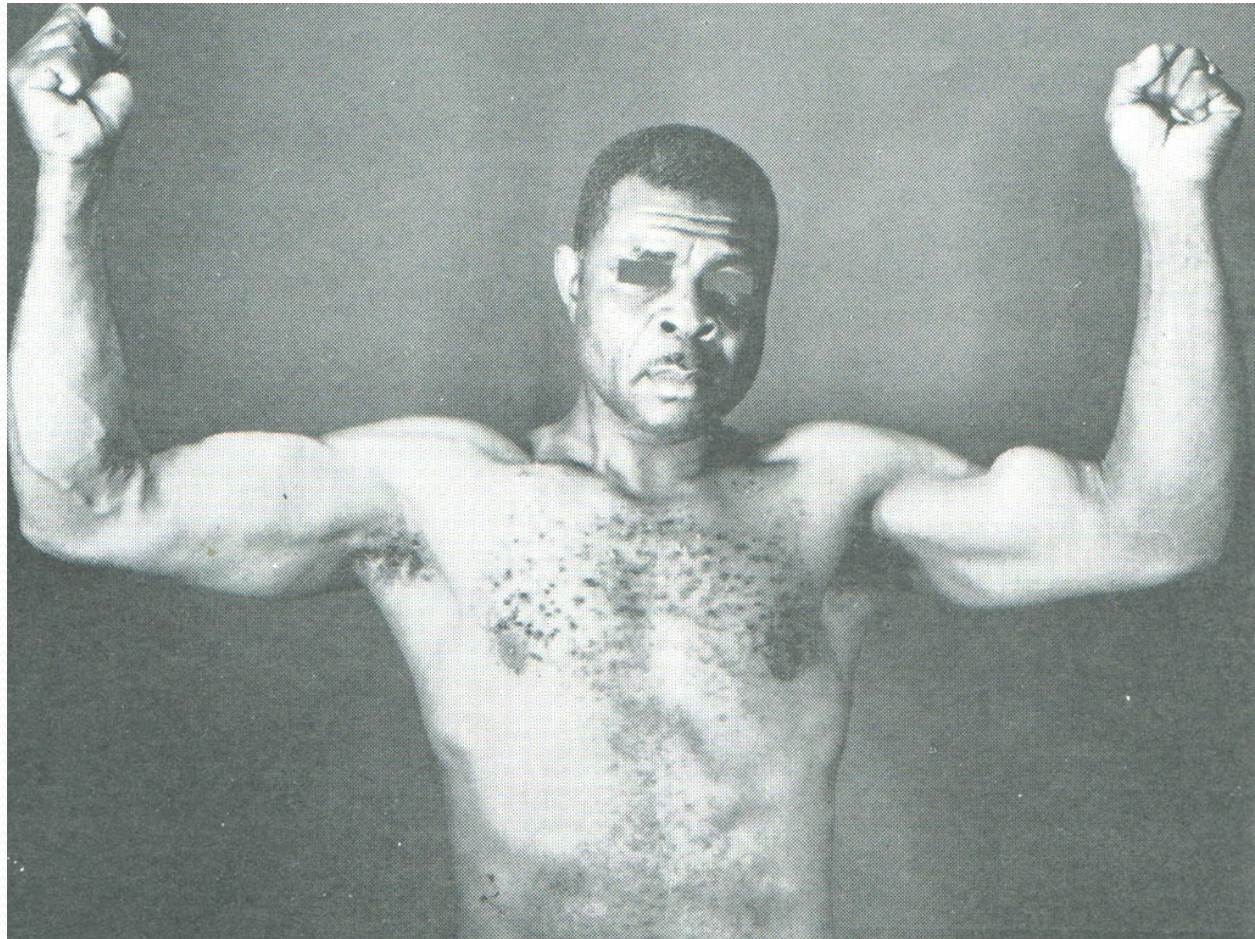


Rupture of long head of biceps

Tenderness

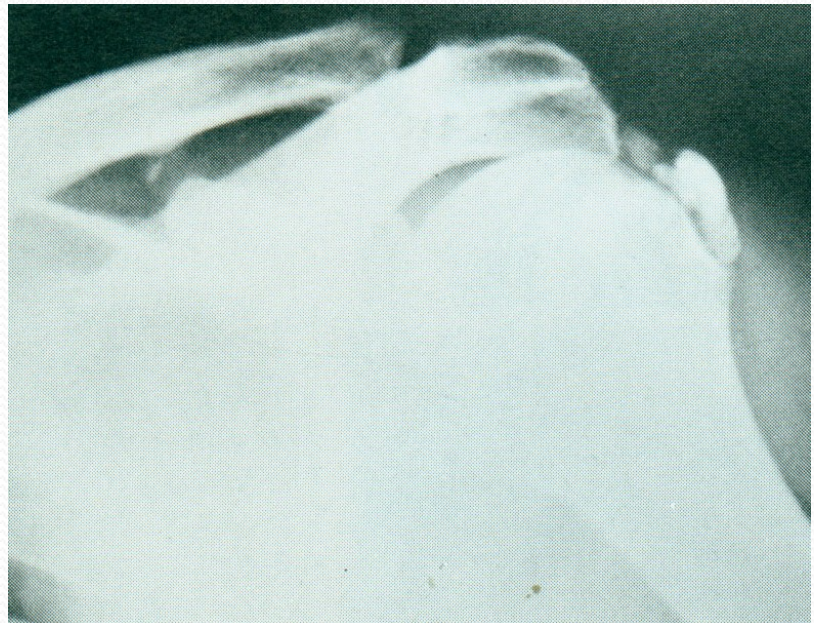
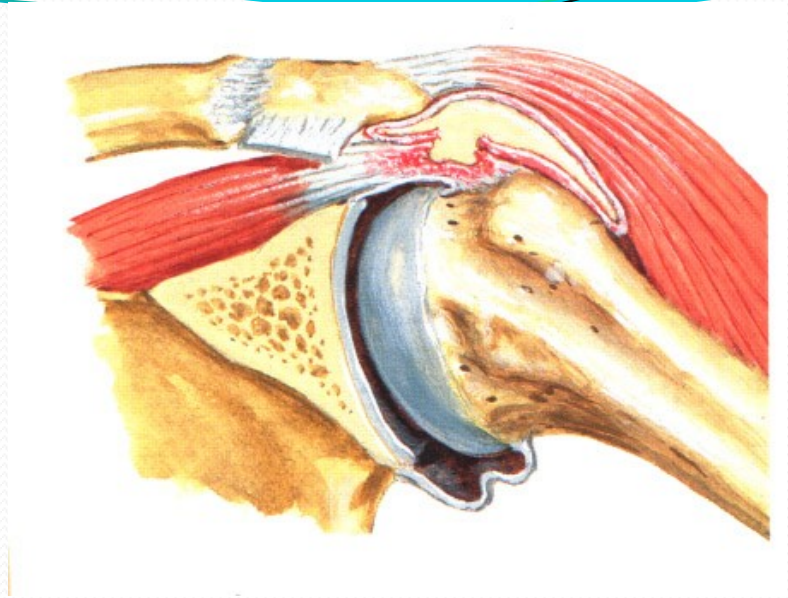
Distalisation of
muscle belly

Diminished strength



Subacromialis bursitis

Inflammation
White fluid
Severe, burning pain
Restricted movements
Tenderness
Calcifications



Subacromial bursitis

Conservative treatment:

Rest, sling

Lavage with 2 needles

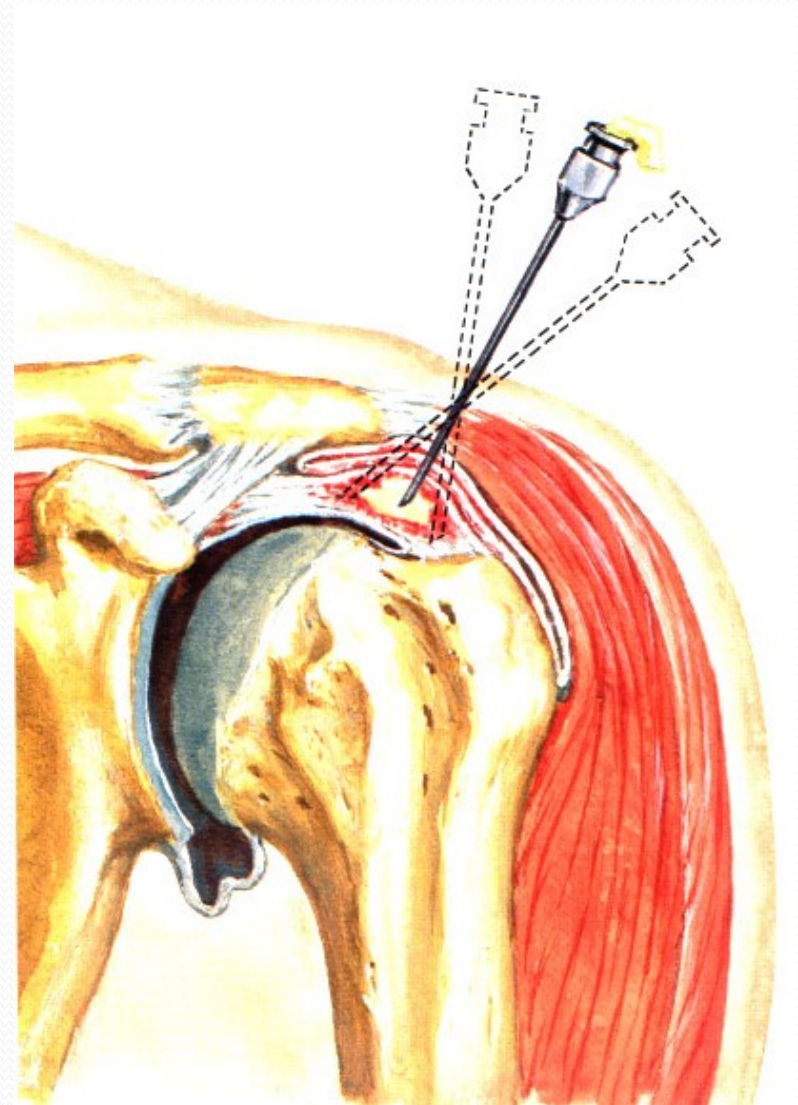
Corticosteroids locally

NSAID

Physiotherapy

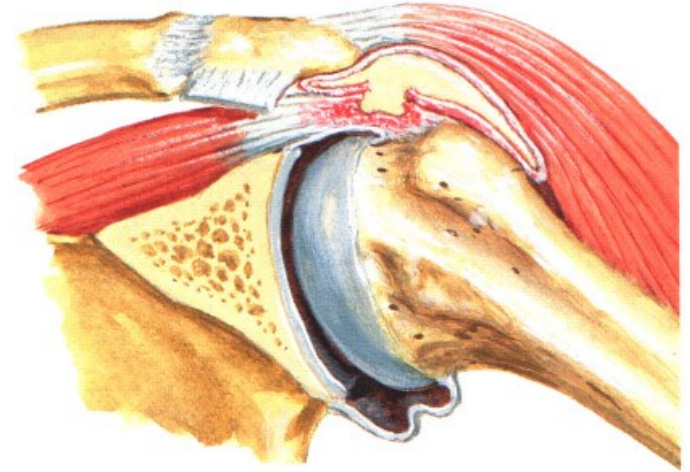
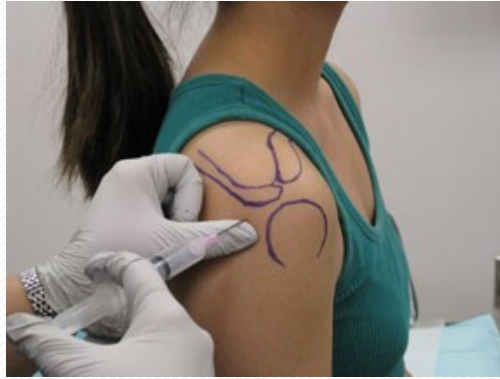Surgery:

Removal of bursa



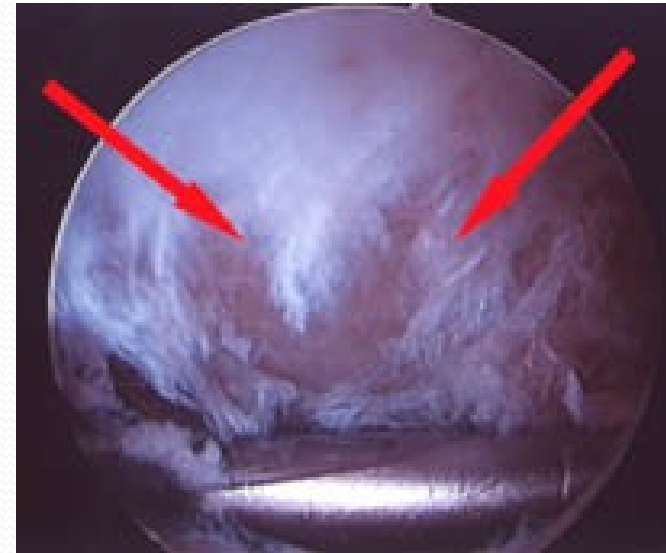
Bursitis subacromialis

- Therapy



1. Conservative

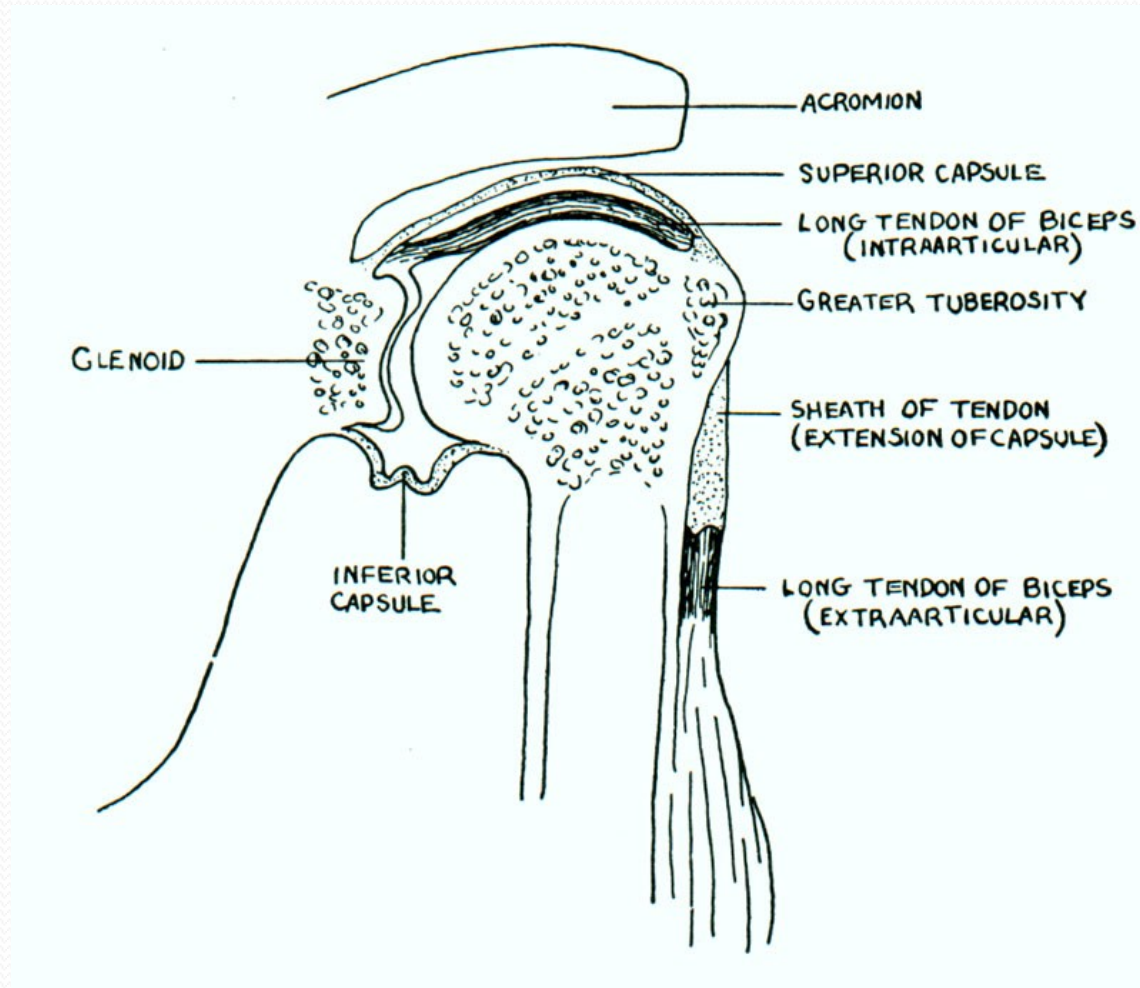
2. Surgery



Supraspinatus tendinitis

Tenderness over greater tuberosity
Limited movements

Therapy:
Rest, NSAID
Corticosteroids
Physiotherapy



Rotator cuff

Rotator cuff:

m. supraspinatus

m. infraspinatus

m. teres minor

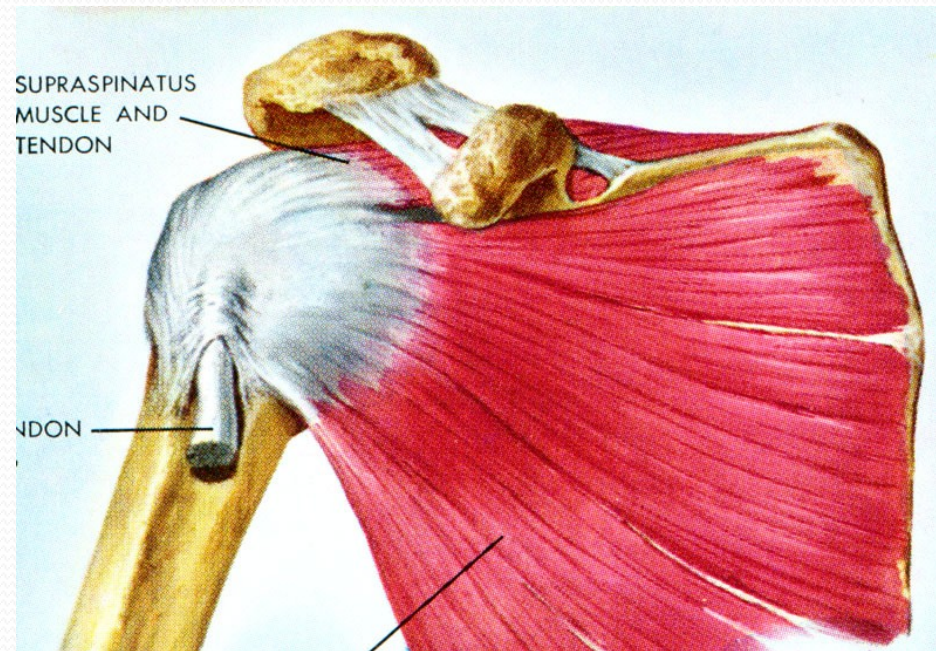
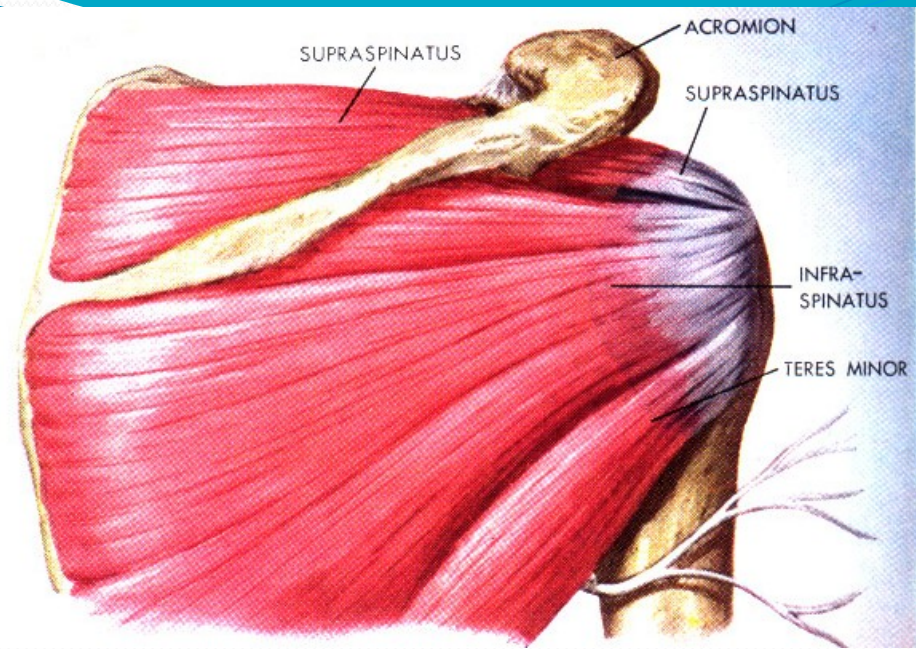
m. subscapularis

Function:

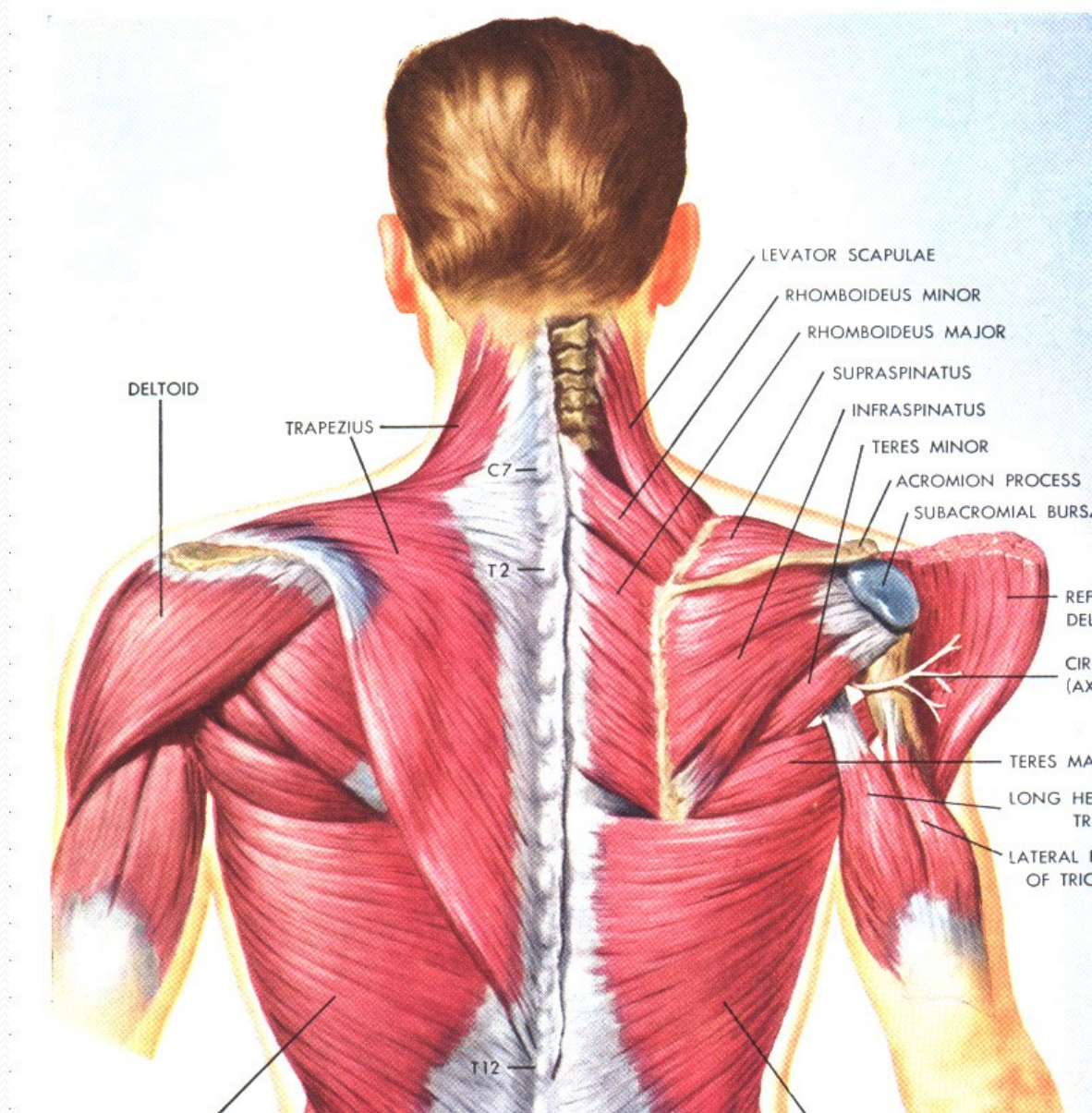
First 30° of abduction

Pressure of the humeral head
into glenoid cavity

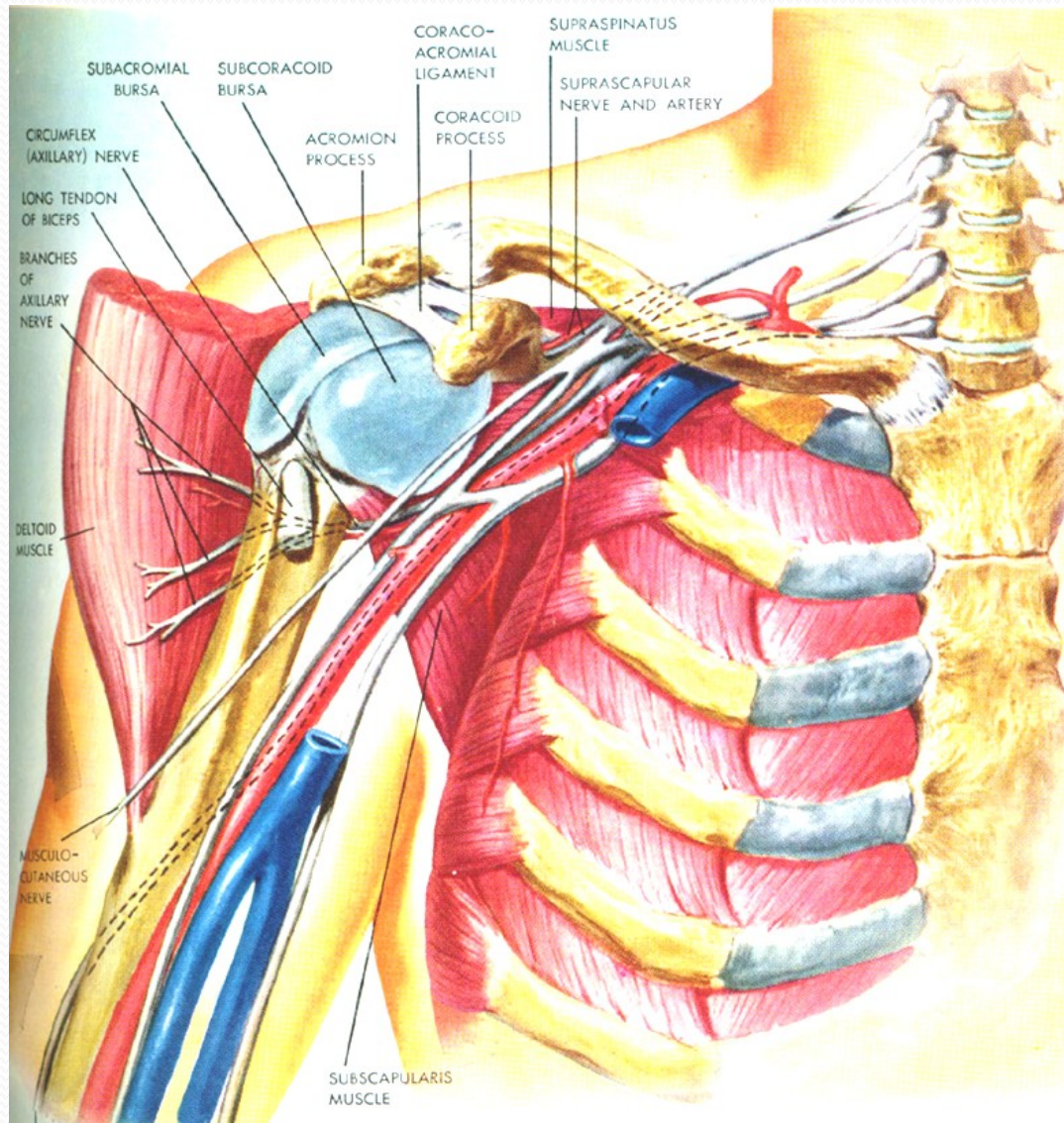
Depressor of the humeral
head



Anatomy of the shoulder



Anatomy of the shoulder



Rupture of rotator cuff

Partial rupture:

Severe pain

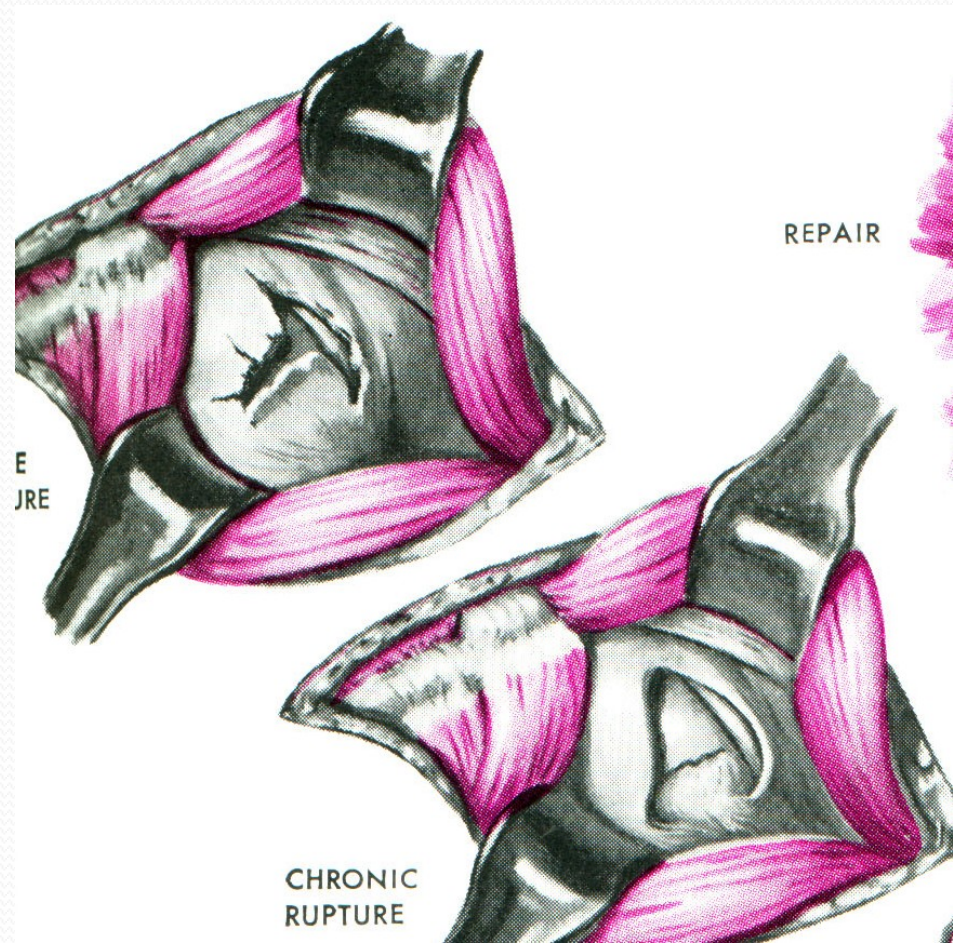
Painful arc

Painful abduction

Keeps the arm in position
of adjusted abduction

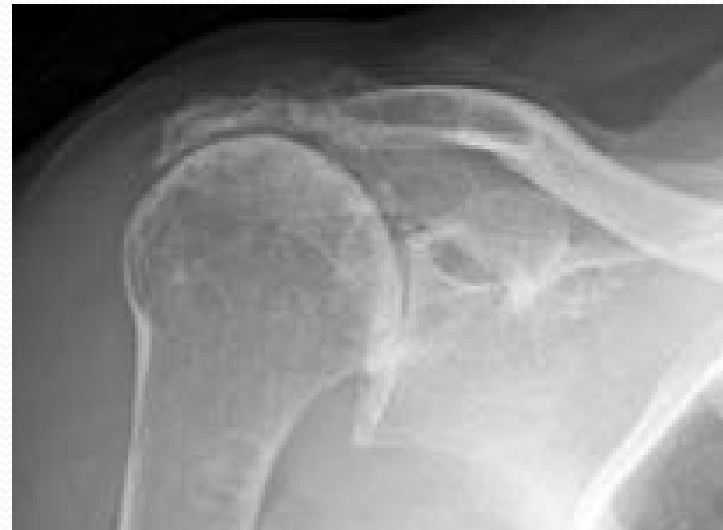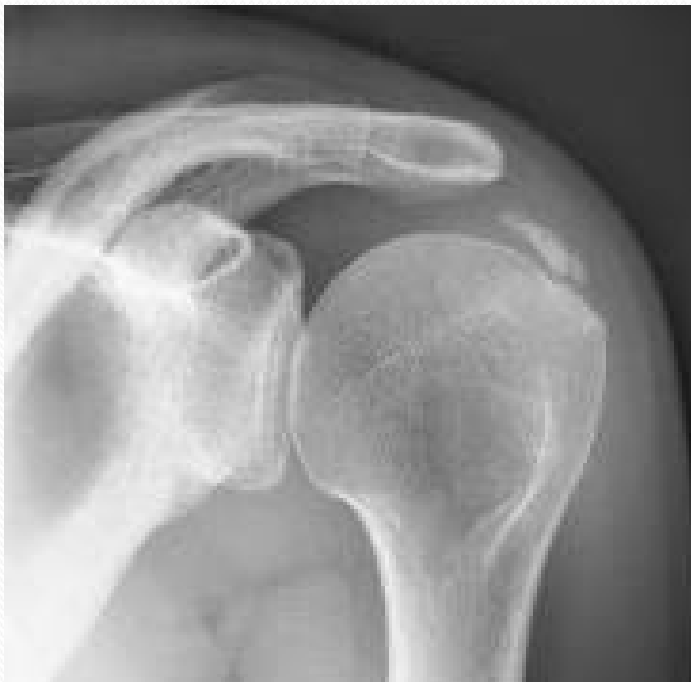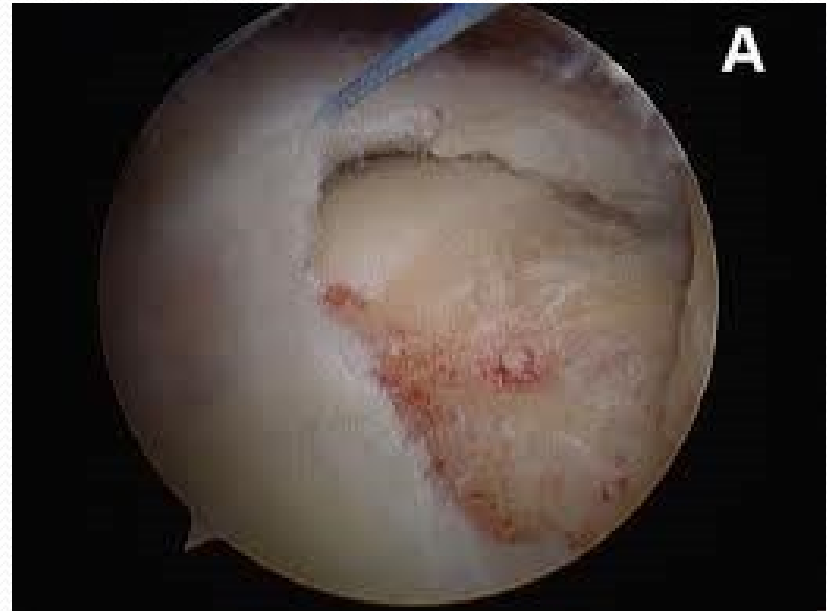Ultrasonography

Management: conservative



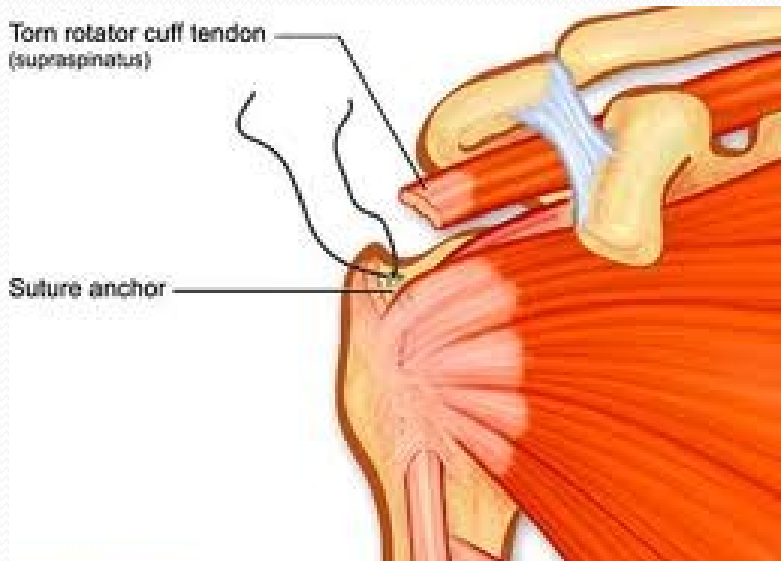
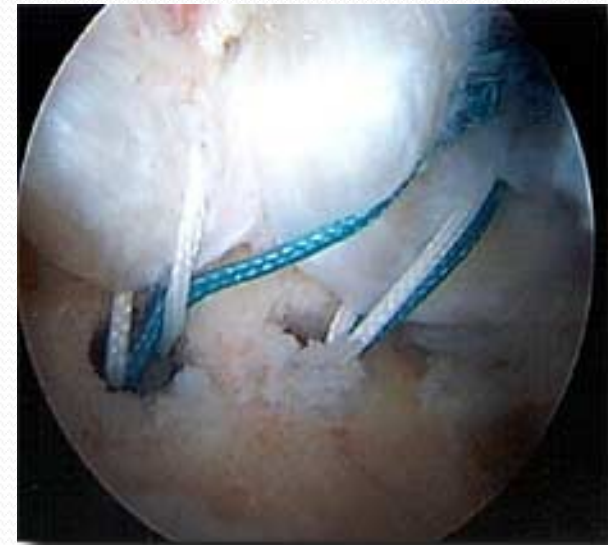
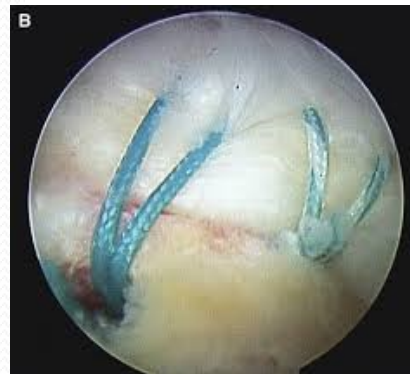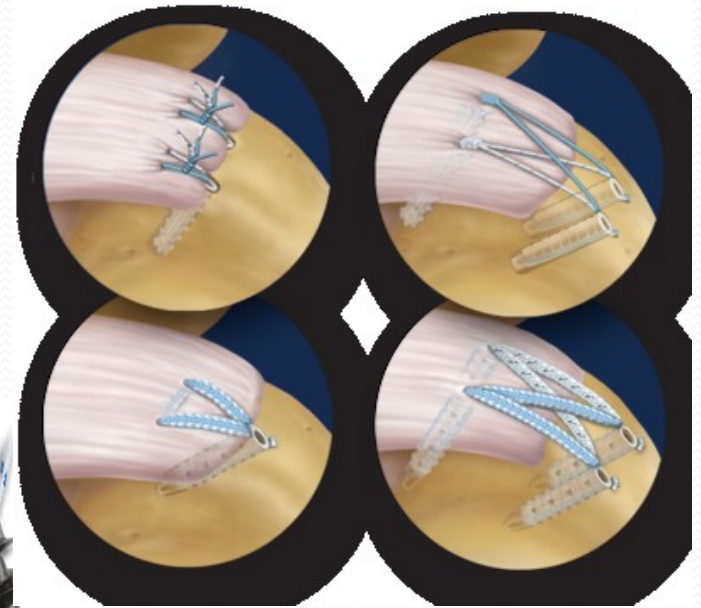
RC

- Tendinopathy
- Degenerative rupture
- Rotator arthropathy



RC

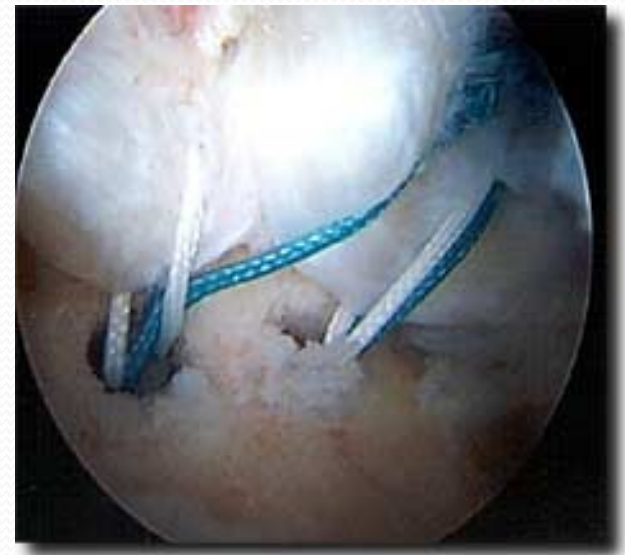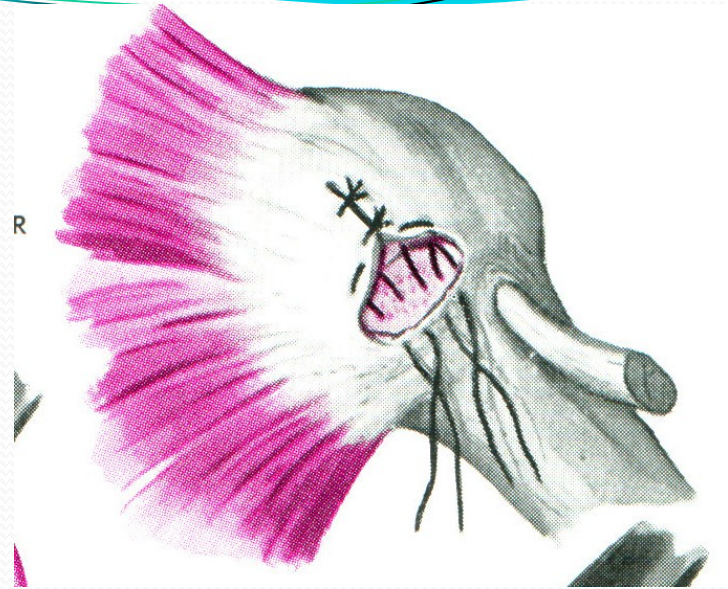
- Suture of RC
- reverse total joint arthroplasty



Rupture of rotator cuff

Complete rupture:
No active abduction
Lifting of the shoulder

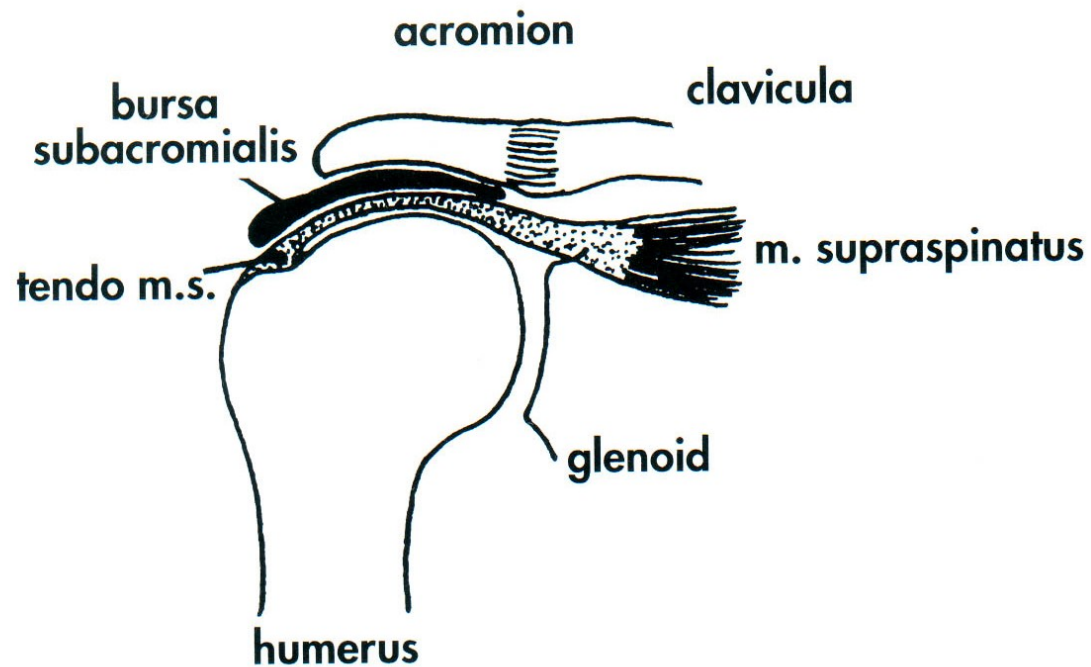
Management:
suture: ASC, open surgery
- attachment to greater
tuberosity



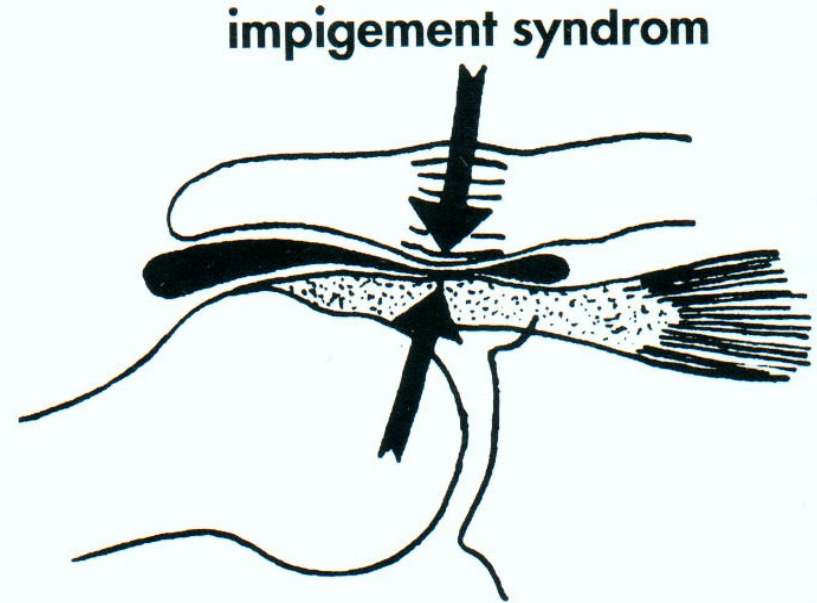
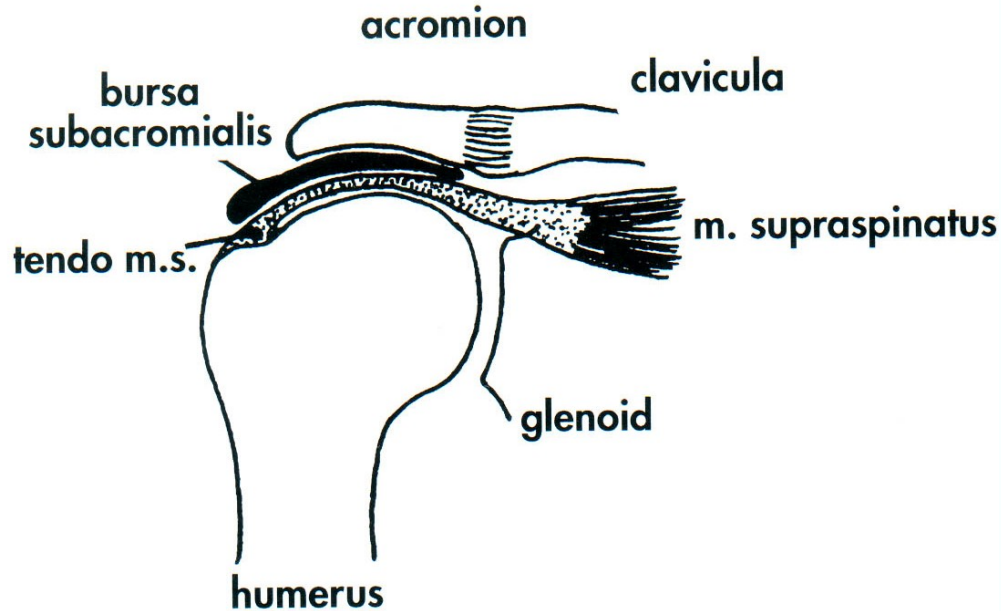
Impingement syndrom

Greater tuberosity impinges
to distal surface
of acromion and
coracoacromial ligament

Narrowing of subacromial
space

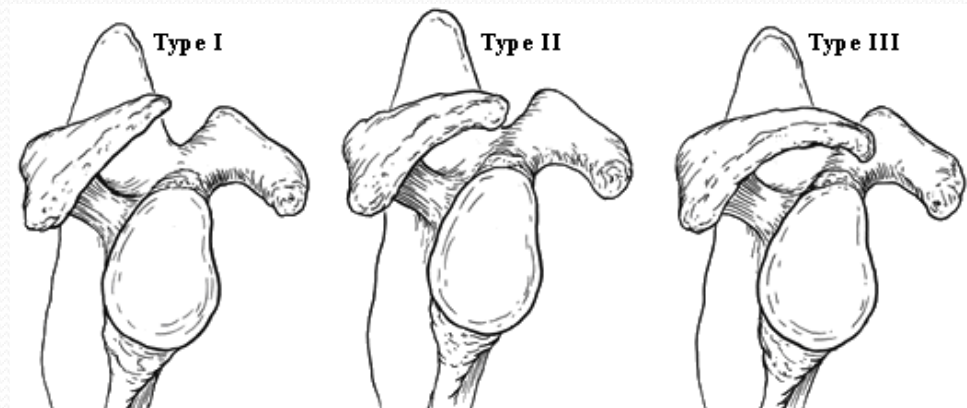


Impingement syndrom



Causes

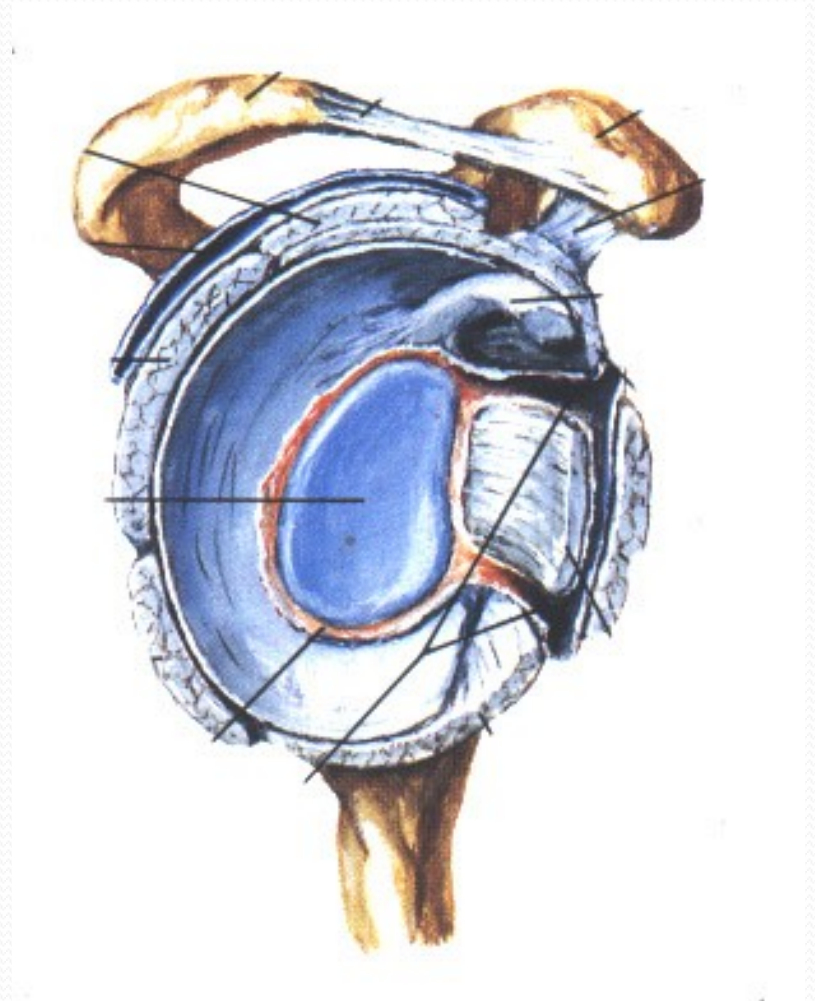
- acromion spur
- Change of acromion
- Distal osteophytes of AC
- Prominence of tuberculum maius



Impingement syndrom

Stages:

1. Swelling, hemorrhage of supraspinatus
2. Fibrosis, tendinitis, bursitis
degenerative changes of cuff
3. Rupture of rotator cuff
and long biceps tendon



Impingement syndrom

Symptoms:

Painful arc

Impingement sign

Impingement test

Jobe test

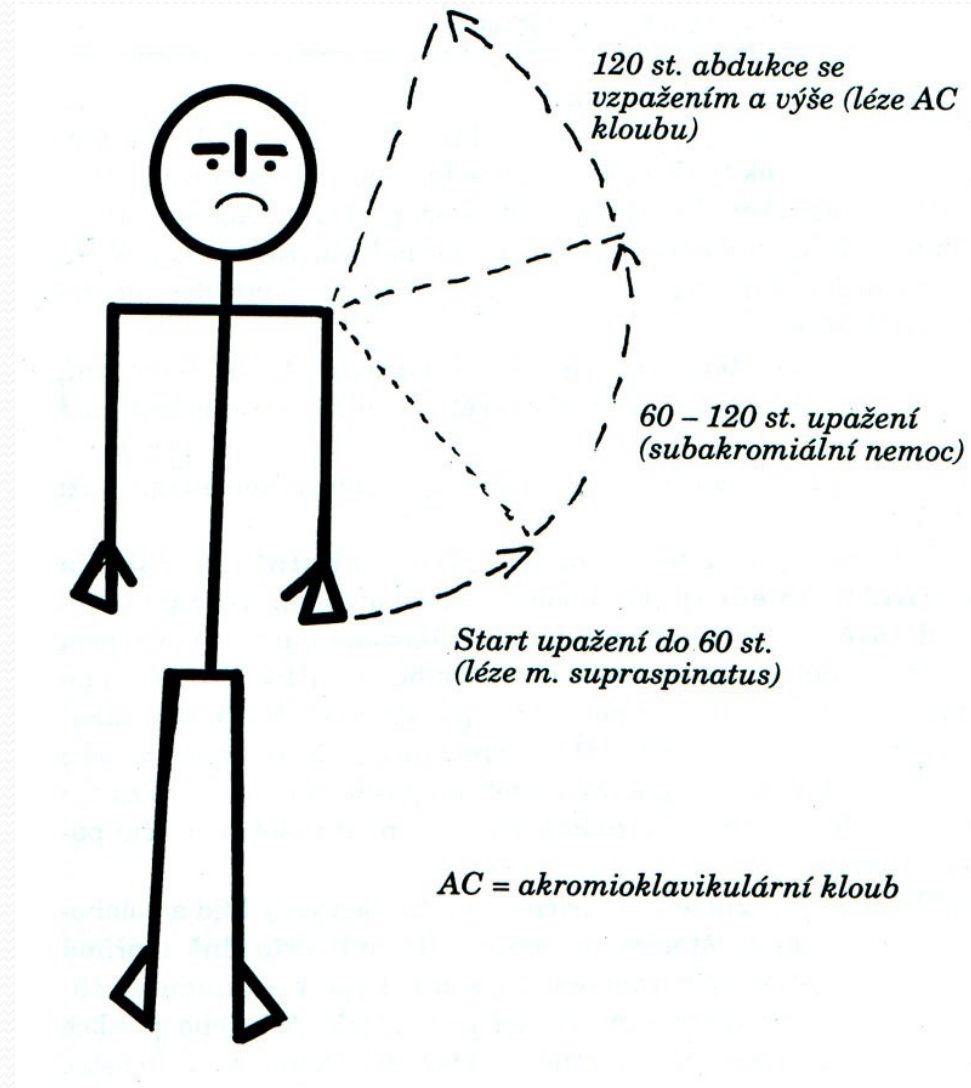
X-ray:

Narrowed subacromial space

Y view- outlet view

Arthrography

Ultrasonography



Impingement syndrom

Therapy:

1. stage: conservative

Rest, NSAID,

Physiotherapy,

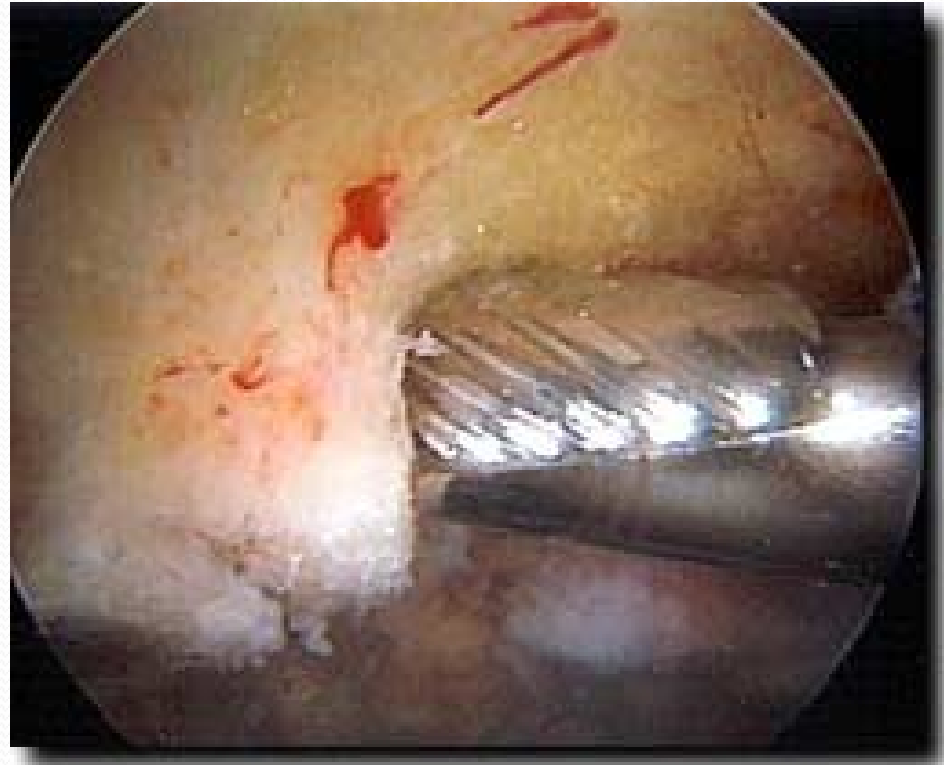
Local corticosteroids

2. stage: the same

+ bursectomy, ASAD

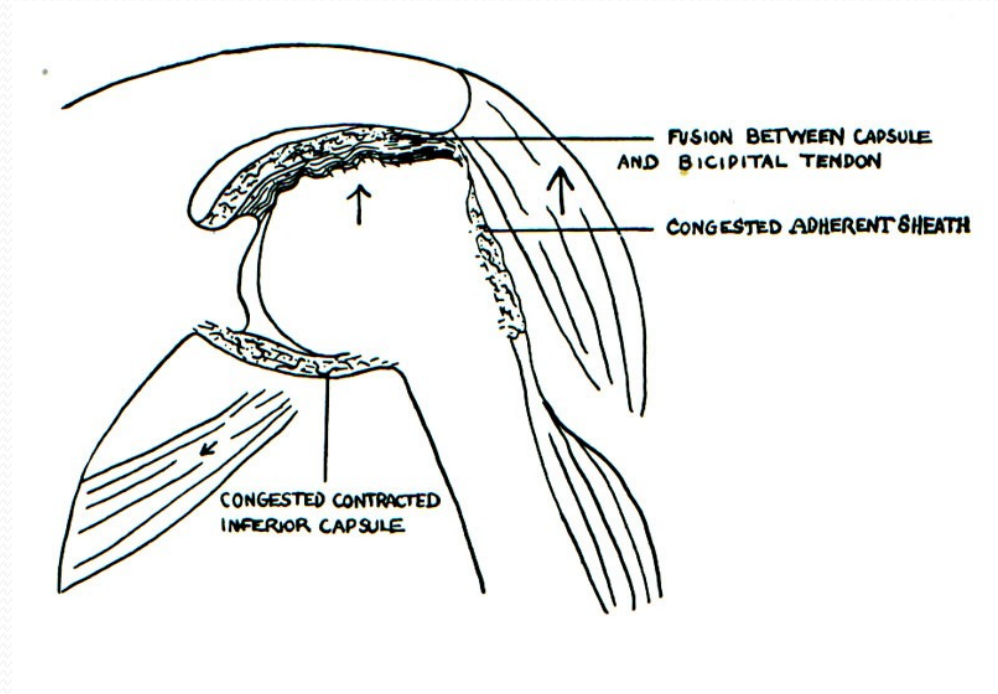
3. stage: ASAD

Subacromial decompression



Frozen shoulder- capsulitis adhesiva

- Progressive limitation of movements
- Pain
- No motivation for movement
- Shrinkage of capsule
- Adhesions in distal recessus
- Tightening of soft tissue
- Muscle spasm
- Low capacity of joint space



The cause

All conditions limiting
joint movements:

Impingement syndrom

Arthrosis of AC joint

Posttraumatic conditions

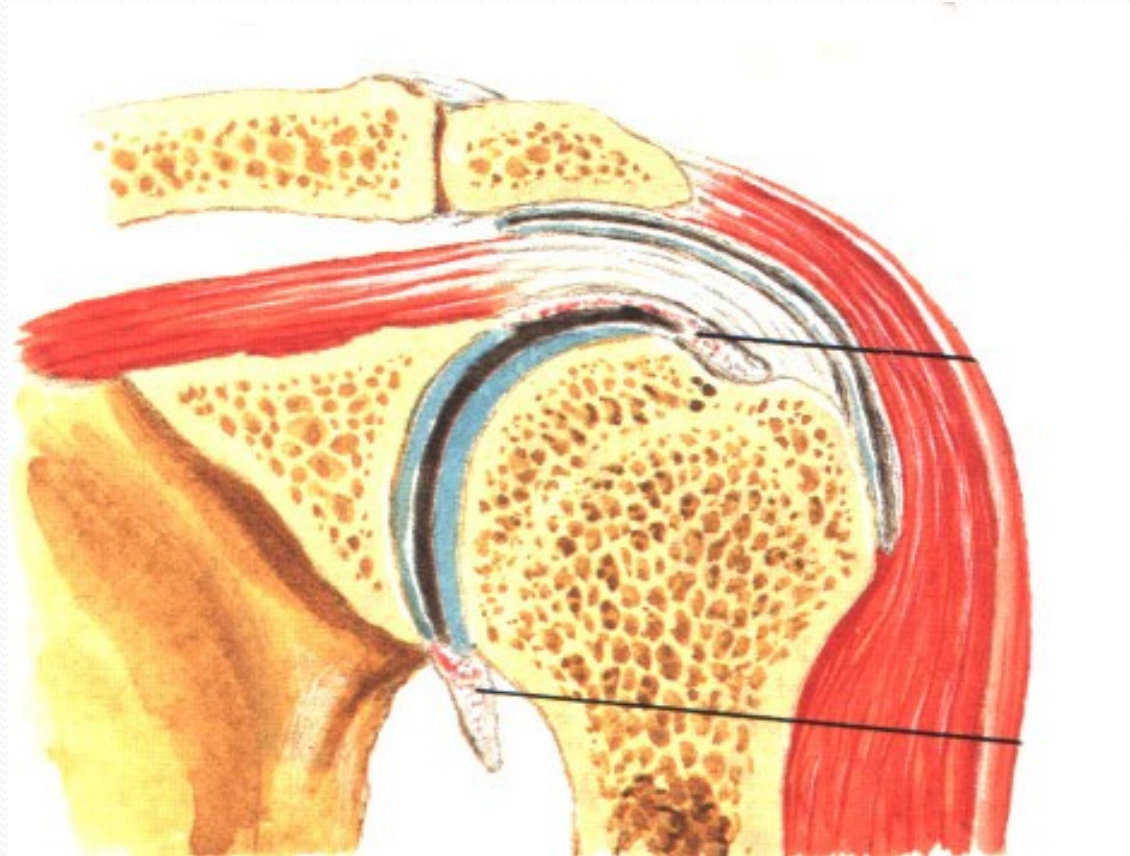
Inflammations

Thoracic outlet syndrom

Tumors of the lungs

Disorders of pleura

Cardiac disorders



Frozen shoulder

Management:

Long lasting period

Heat

Passive movements

Positioning

Active movements

Physiotherapy

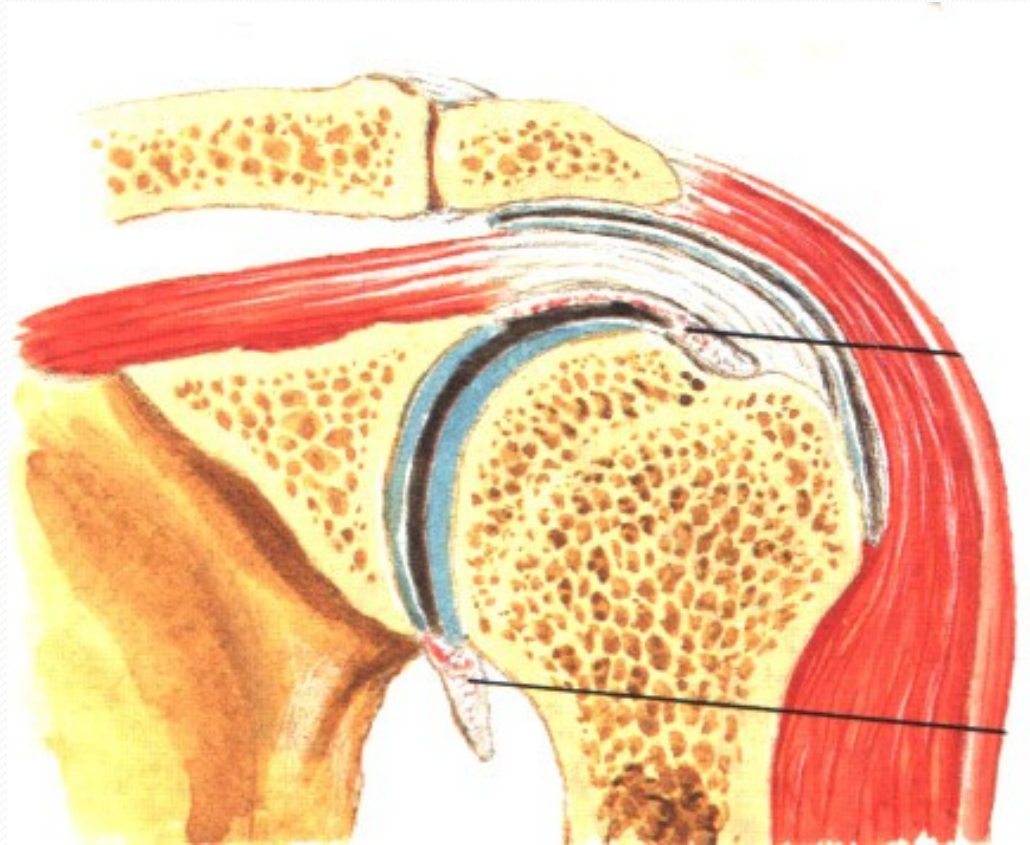
NSAID

Local corticosteroids

ASC- decompression

Redressement force

Removal of adhesions



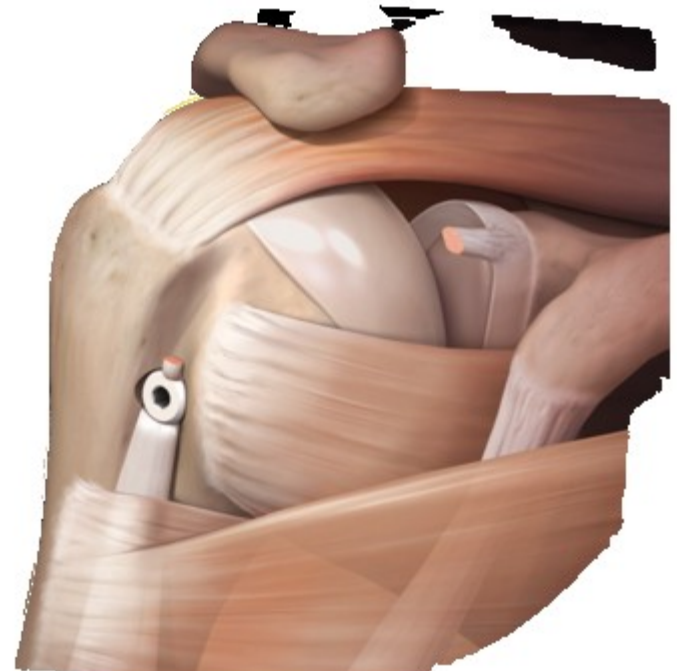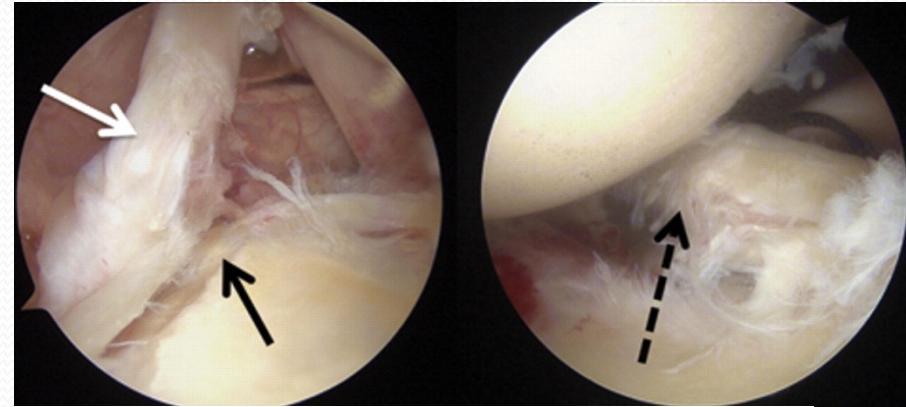
Long head of biceps

Tenosynovitis
in SLAP lesion

- subluxation
- parcial or total rupture

Th.:

- conservative
- ASC debridement
- Tenotomy, tenodesis



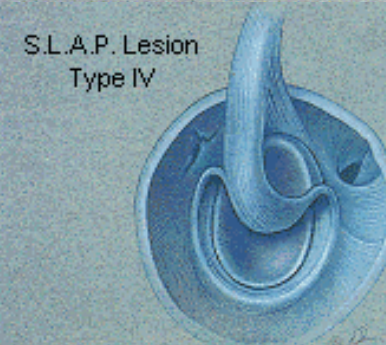
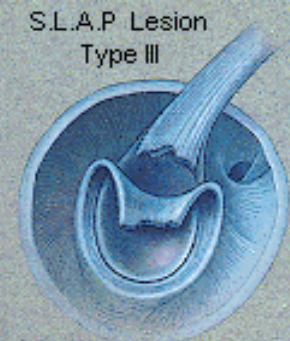
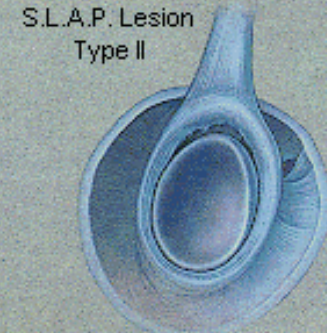
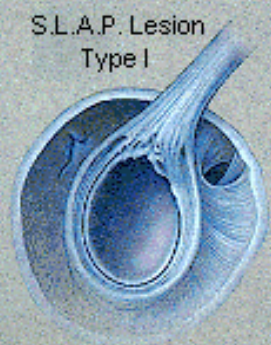
SLAP lesion

- = superior labrum anterior, posterior

- **Causes**

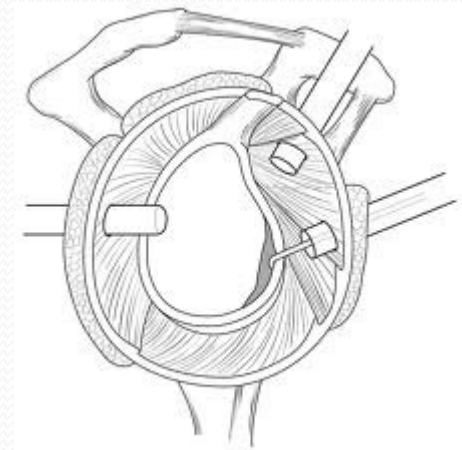
- Subluxation, dislocation
- Microtraumatisation
- throwing shoulder

- **Snyder classification**

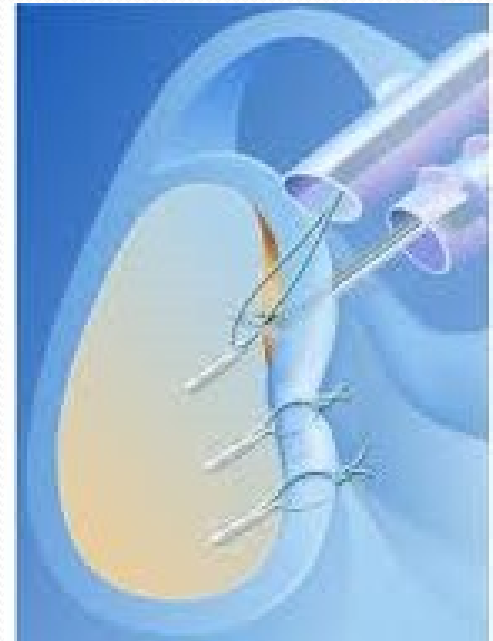
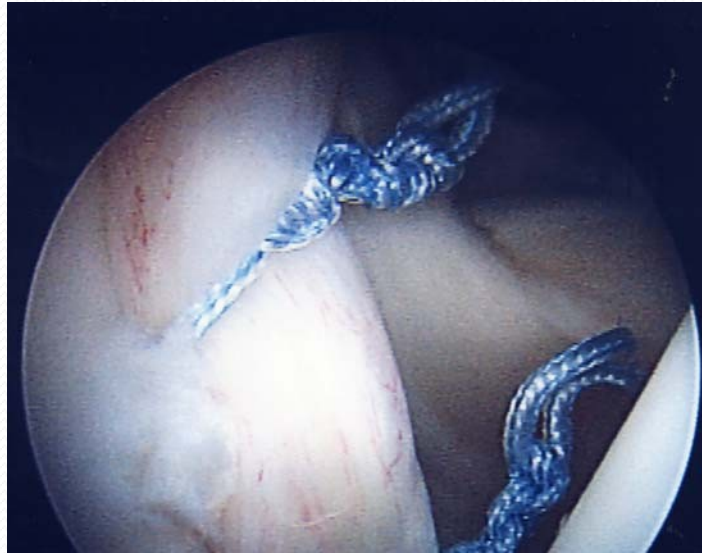

Instability of GH joint

- Acute, chronic posttraumatic
- Multidirectional, unidirectional
- Habitual
- Posterior, anterior
- Neglected

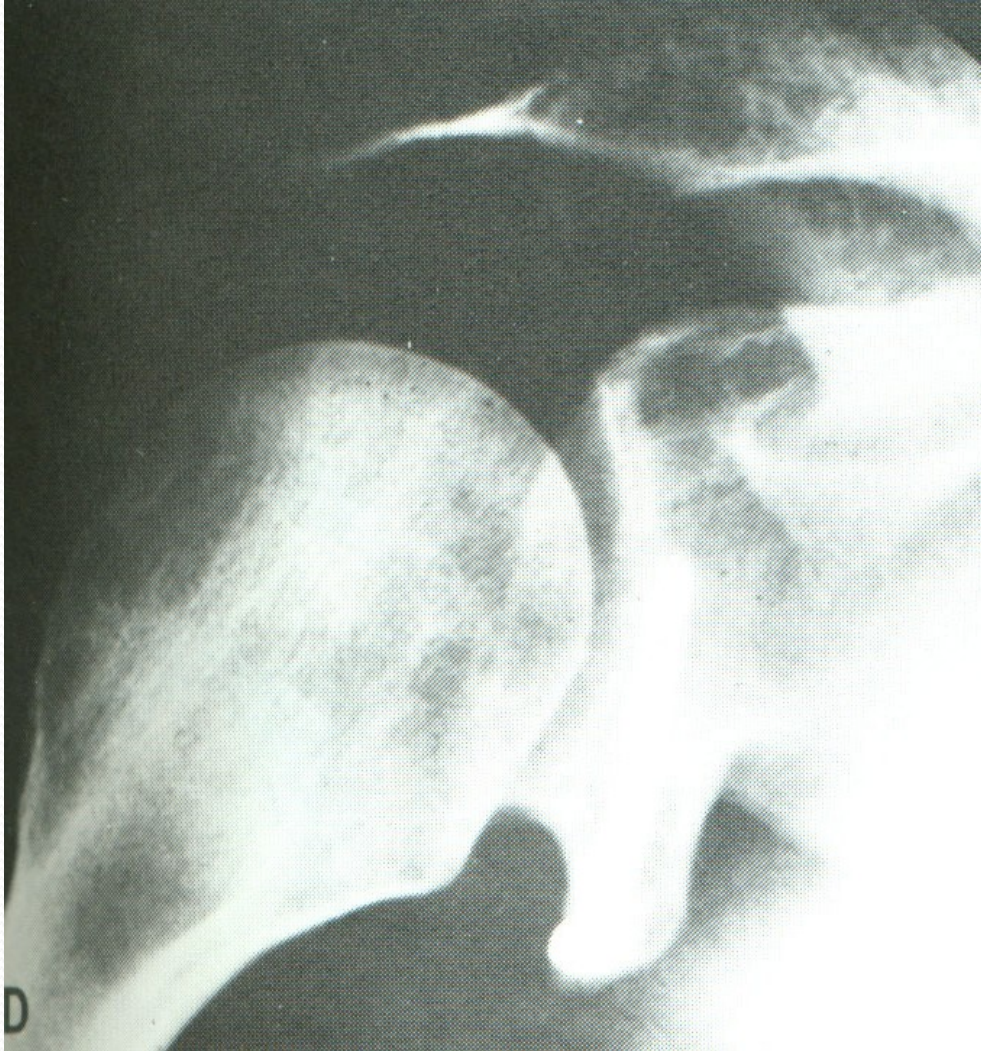


- **History**



Glenohumeral osteoarthritis

- omarthrosis



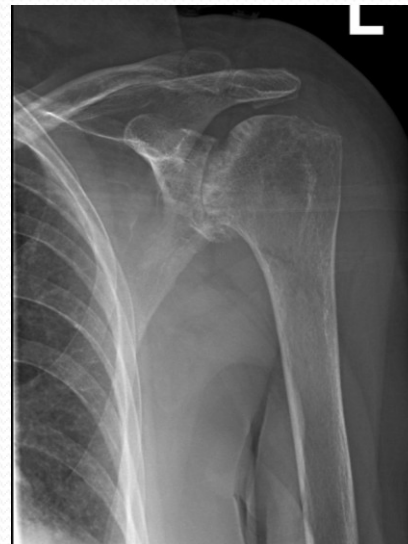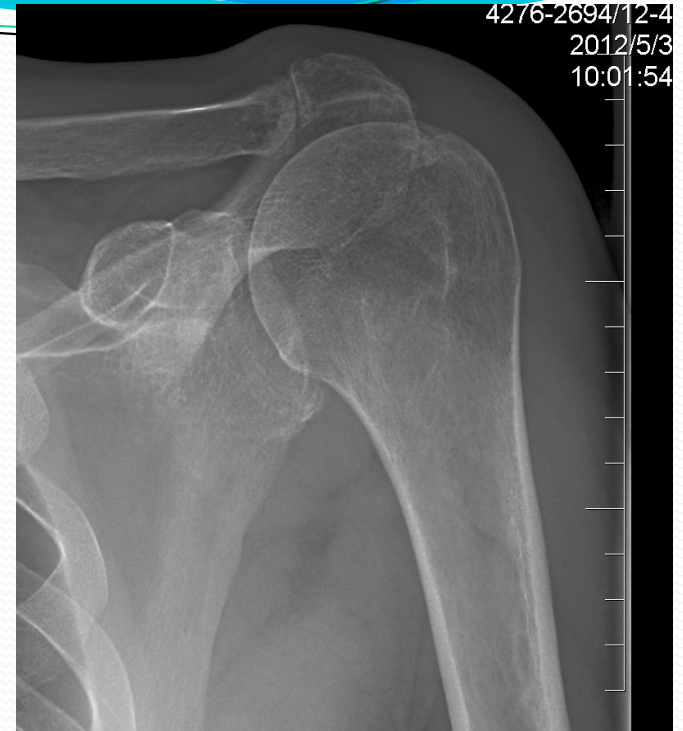Therapy:

Conservative

Total shoulder replacement

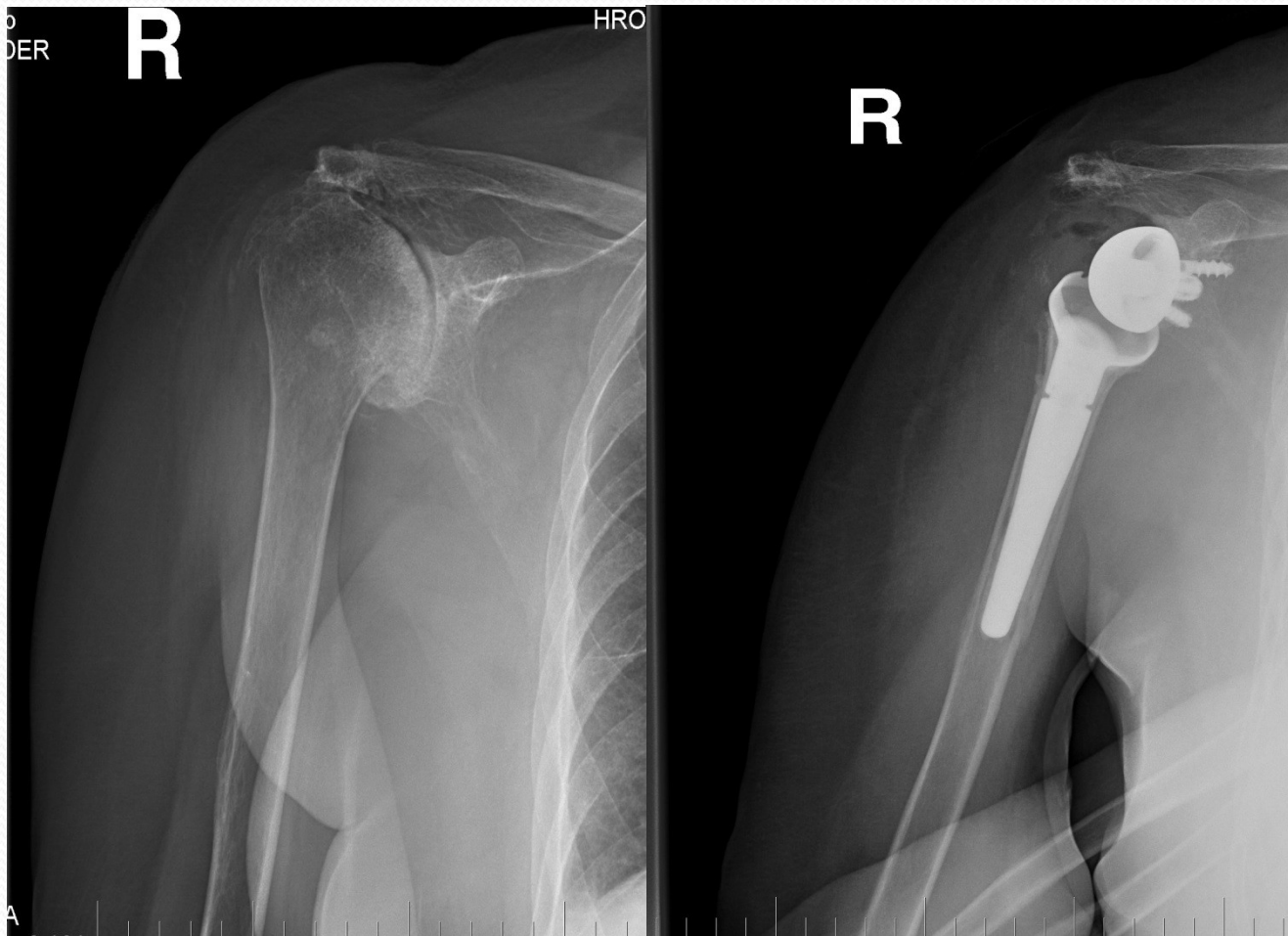
Osteoarthritis

- Secondary
- Postraumatic
- In R.A.
- Rotator arthropathy
- Primary
- Therapy
 - Conservative
 - surgery
 - Resurfacing
 - Head prosthesis
 - Total joint
 - Reverse total joint





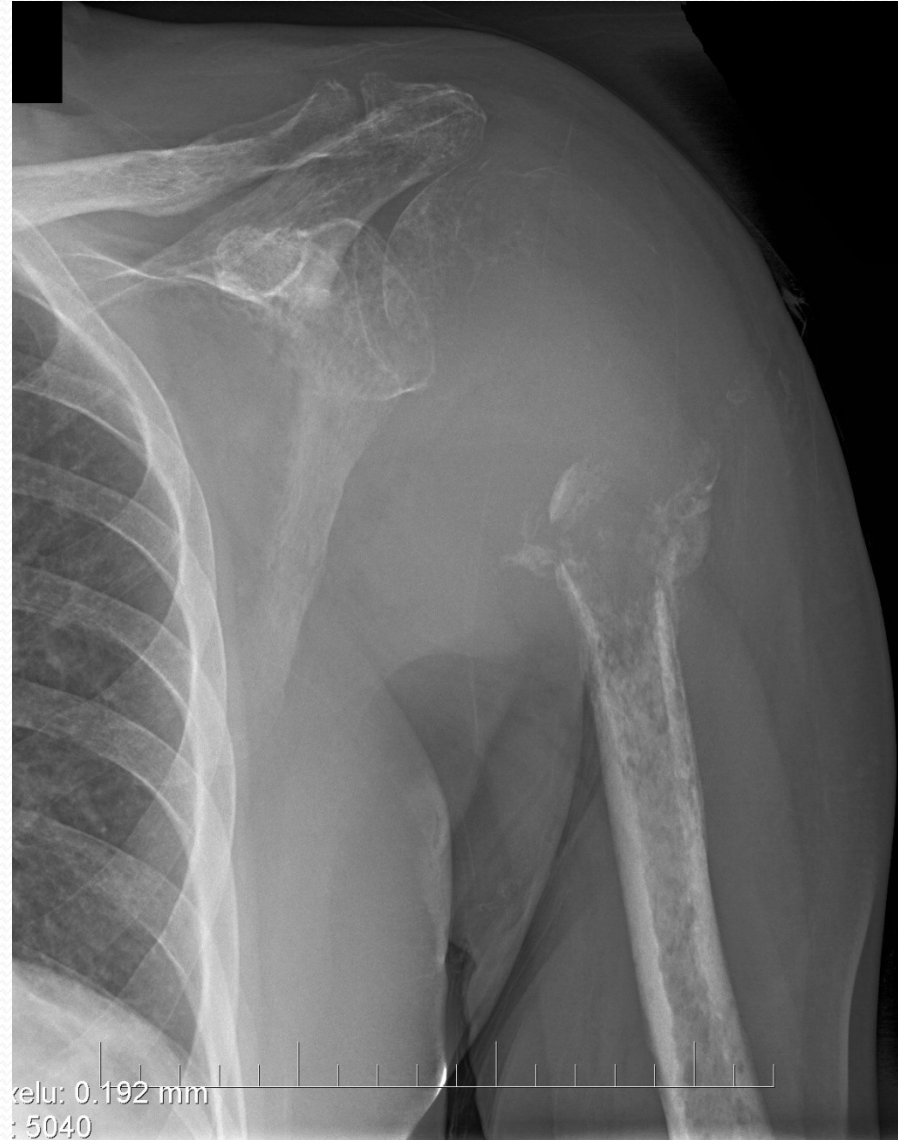Rotator arthropathy



Reverse total shoulder arthroplasty

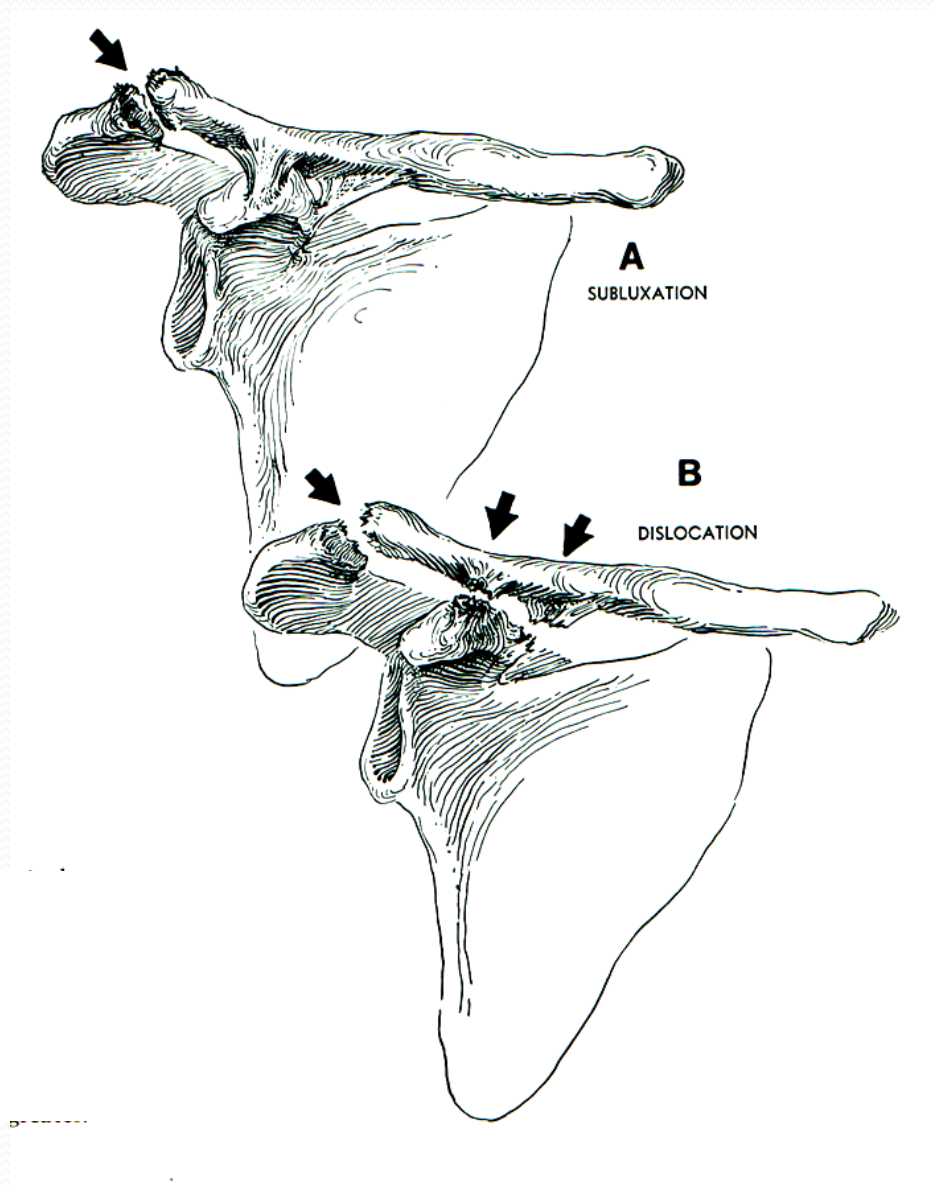
Infection and tumors

- Pyogenic arthritis
- Tumors
 - OSA, CHoSA, Ewing- sa
 - Metastases
 - Benign tumors
 - Myeloma



Disorders of acromioclavicular joint

Synovitis
O.A.
Sprain
Subluxation
Dislocations



Referred pain to the shoulder

Cervical spine

Thoracic outlet syndrom

Cardiac diseases

Lung and pleura disorders

Herpes zoster neuralgia