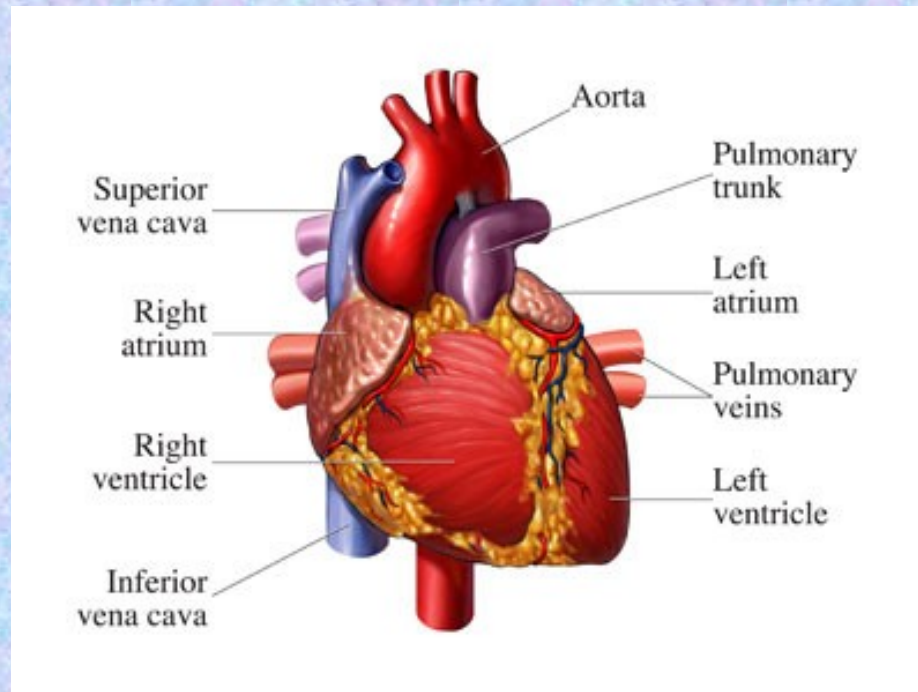
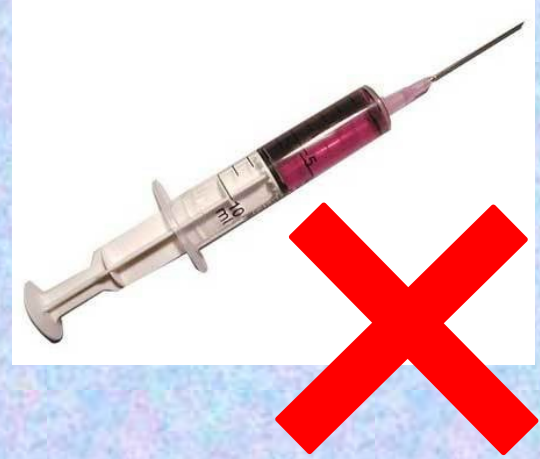

EXAMINATION TECHNIQUES

IN CARDIOLOGY

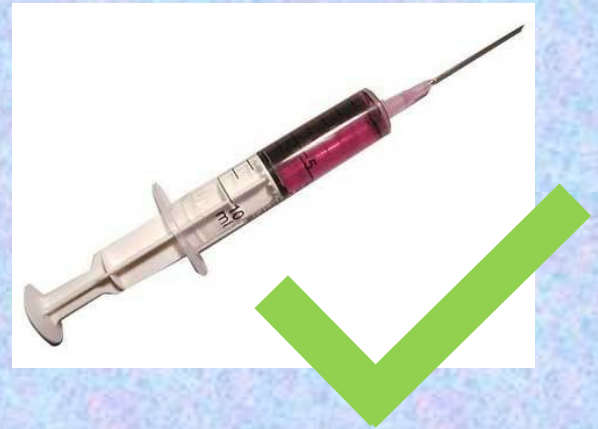

- **Non-invasive methods**



- **Invasive methods**

- (by puncture needle or catheter)



NON – INVASIVE METHODS

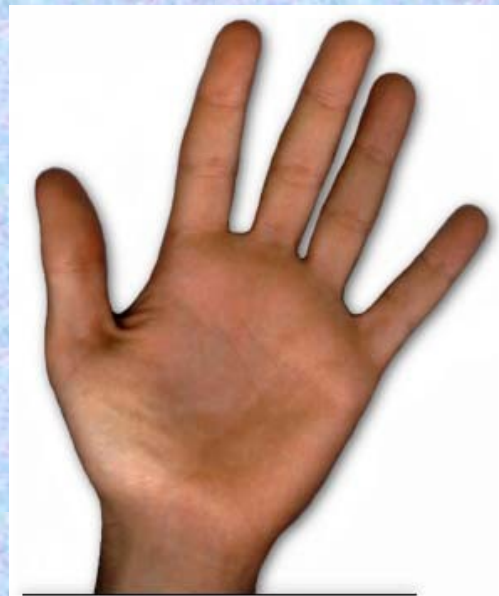
Basic – used together with examination of patients



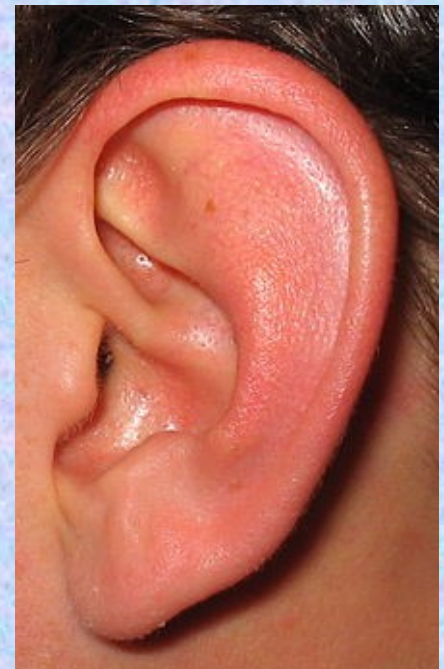Inspection



Percussion

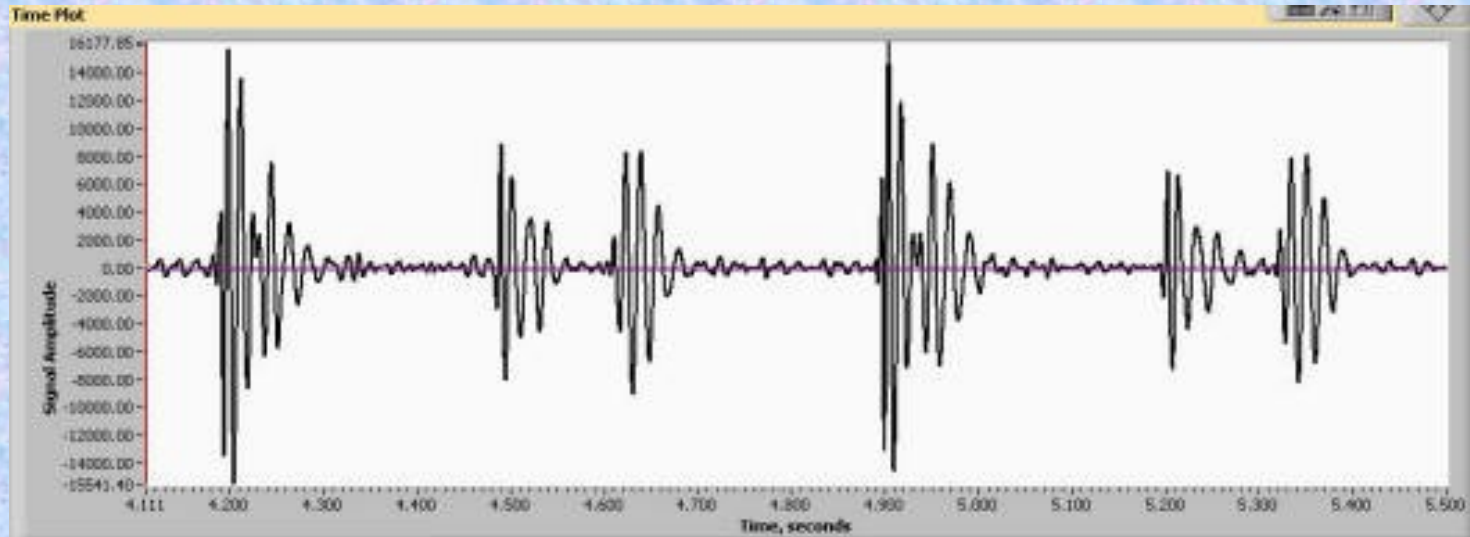


Palpation



Auscultation

- **PHONOCARDIOGRAPHY**



S1

S2

S3

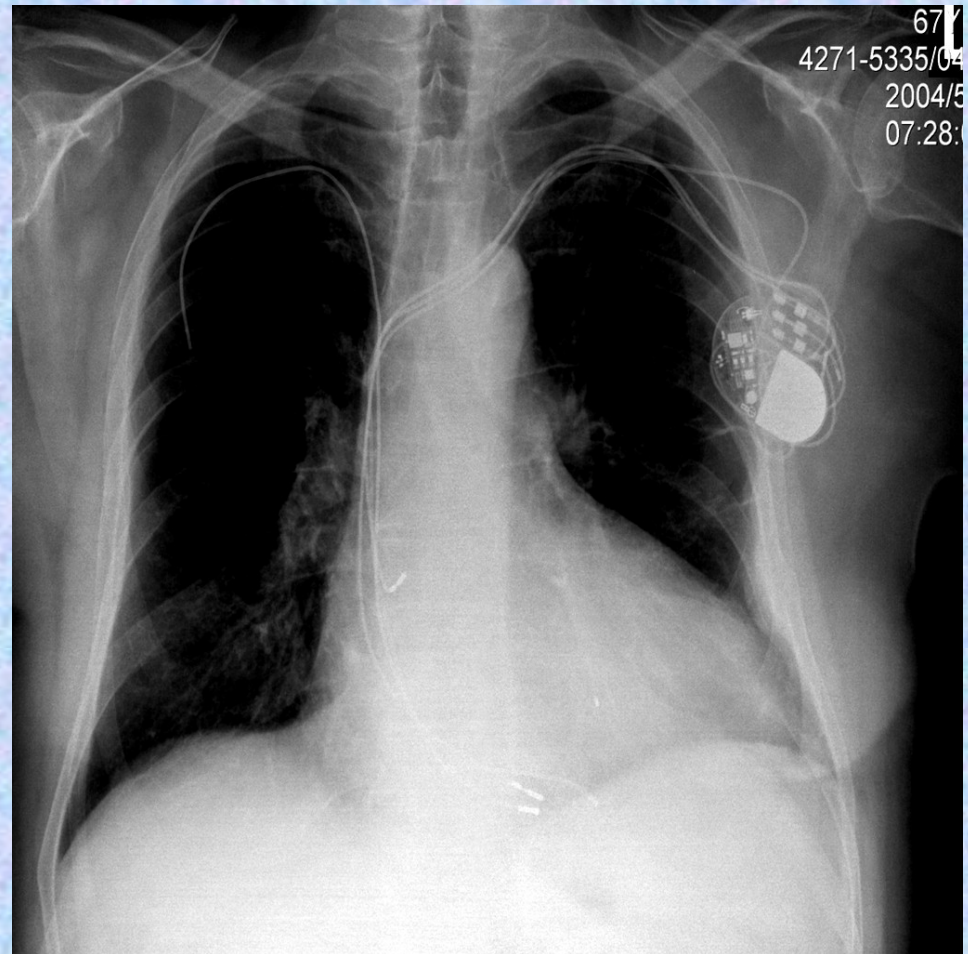
S1

S2

S3

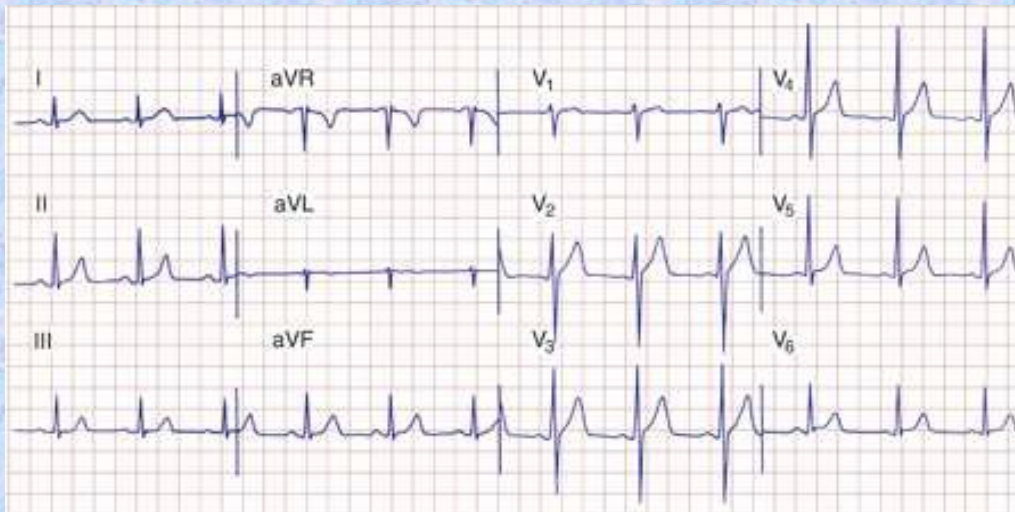
X-ray

Chest x-ray provides useful information about cardiac size and shape, as well as the state of the pulmonary vasculature, and may identify noncardiac causes of the patient's symptoms



ELECTROCARDIOGRAPHY

- A routine 12-lead ECG
- The major importance of the ECG is to assess cardiac rhythm and determine the presence of left ventricle hypertrophy or prior myocardial infarction or QRS width
- Normal ECG excludes left ventricle dysfunction

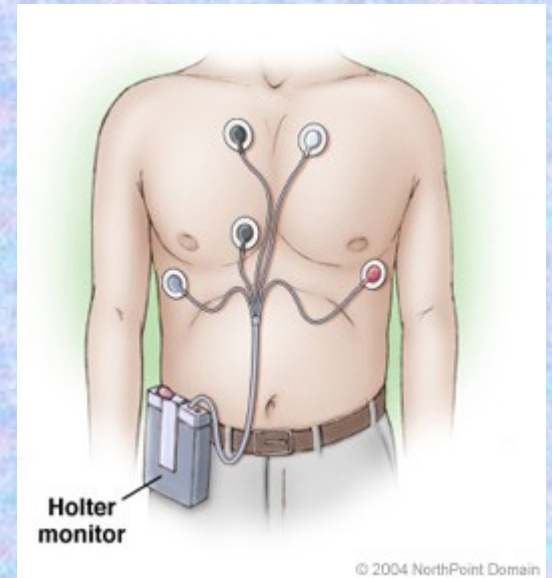


Source: Longo DL, Fauci AS, Kasper DL, Hauser SL, Jameson JL, Loscalzo J: *Harrison's Principles of Internal Medicine, 18th Edition*: www.accessmedicine.com

Copyright © The McGraw-Hill Companies, Inc. All rights reserved.

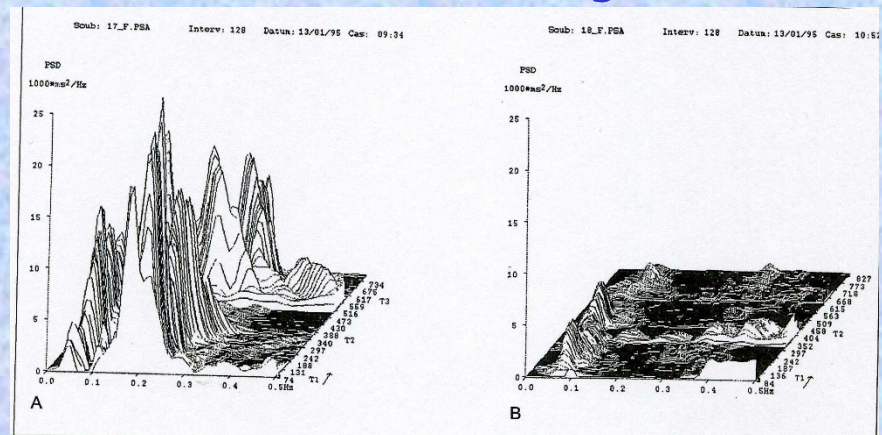
ELECTROCARDIOGRAPHY

- **HOLTER MONITORING**
- 24-hour ECG record



✓ *estimation of heart rate variability*

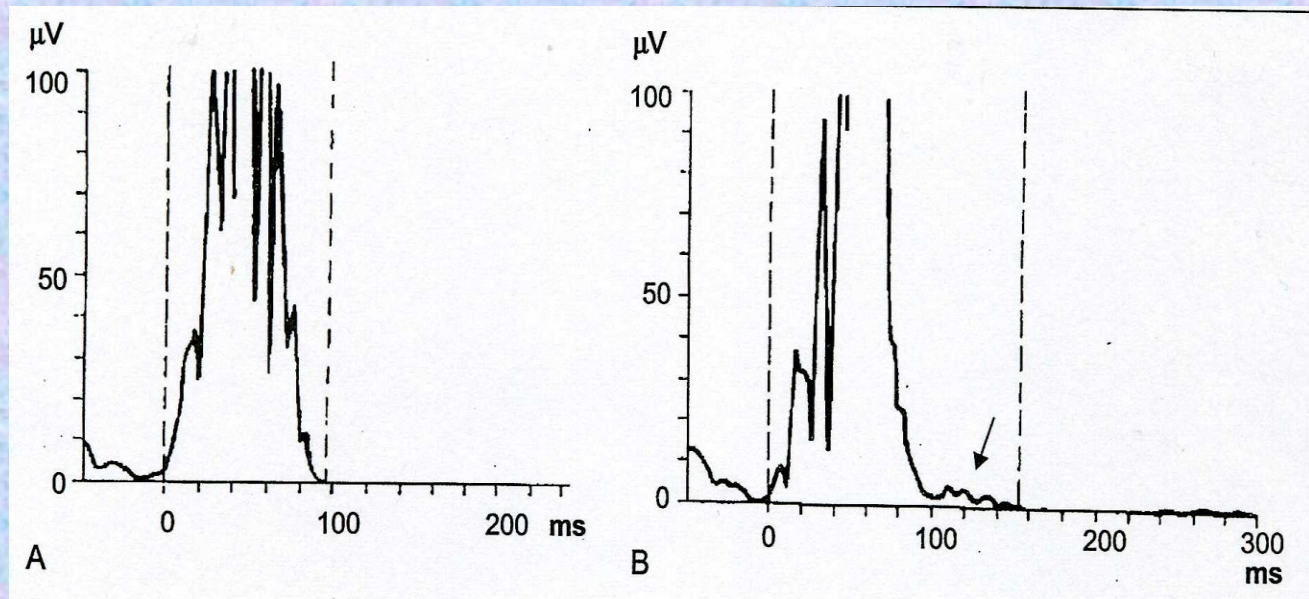
- time analysis
- spectral analysis



ELECTROCARDIOGRAPY

- **HOLTER MONITORING**

✓ *late potentials*



Reveal - implantable recorder

**Patient Activator and
Reveal® Plus ILR**



**Medtronic CareLink®
Programmer**



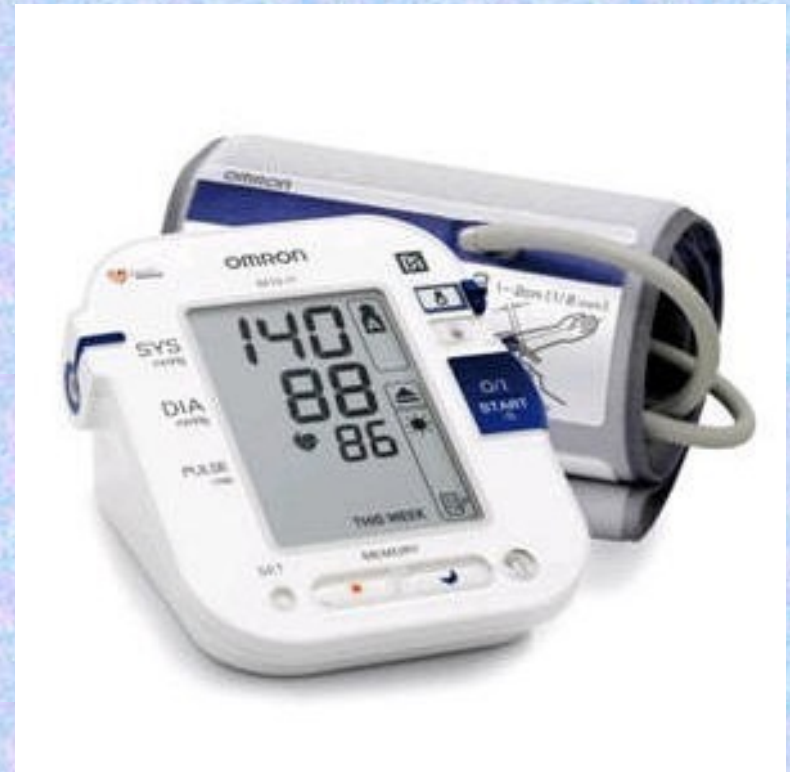- small device, without electrodes
- recorder of ECG during syncope
 - activation by patients
 - or autoactivation
- continuously monitoring 36 month, 42 min episodes at memory
- simple implantation, simple evaluation.

BLOOD PRESSURE MEASUREMENT



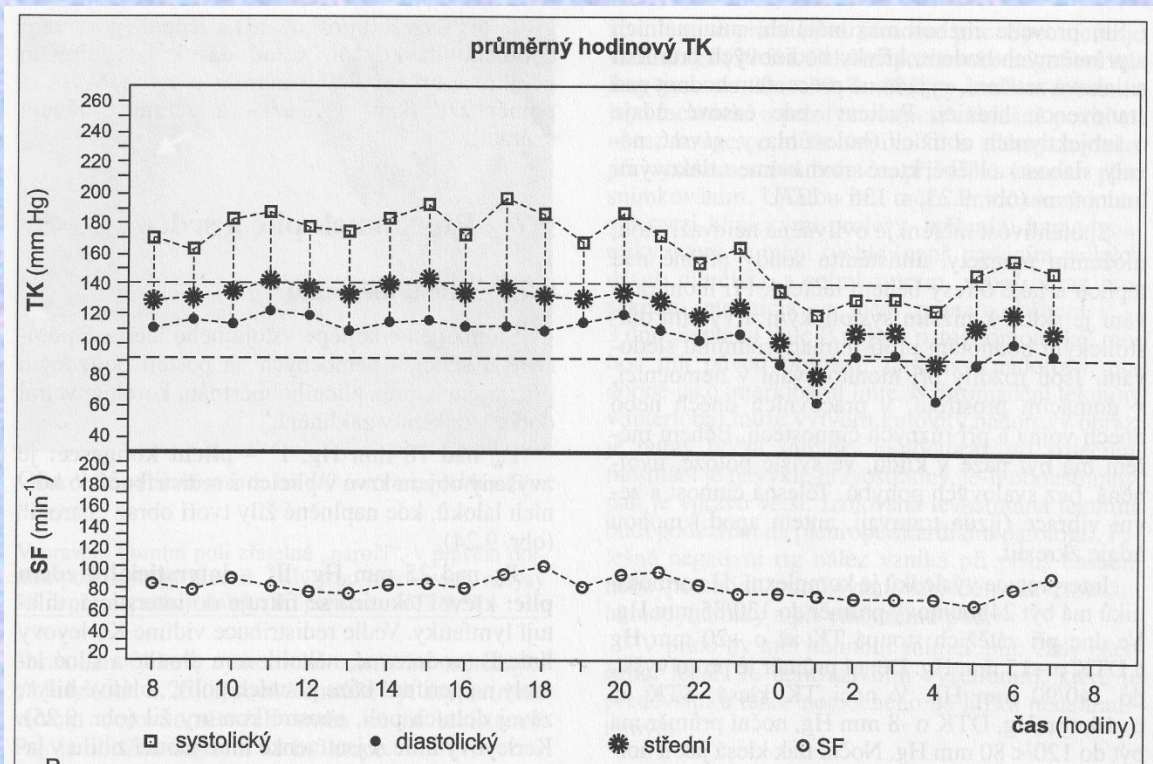
AUSCULTATORY METHOD

OSCILOMETRIC METHOD




BLOOD PRESSURE MEASUREMENT

- **AMBULATORY BLOOD PRESSURE MONITORING - ABPM**



BLOOD PRESSURE MEASUREMENT

- continuously beat-to-beat measurement
- Peñáz principle - photoplethysmography
- It is based on clamping the volume of finger arteries by fast changes of **pressure** in a special cuff equipped with a photoelectric plethysmograph to measure the vascular volume.

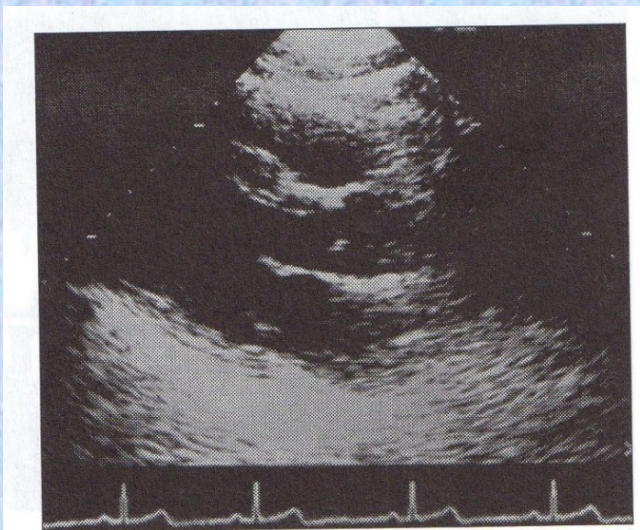
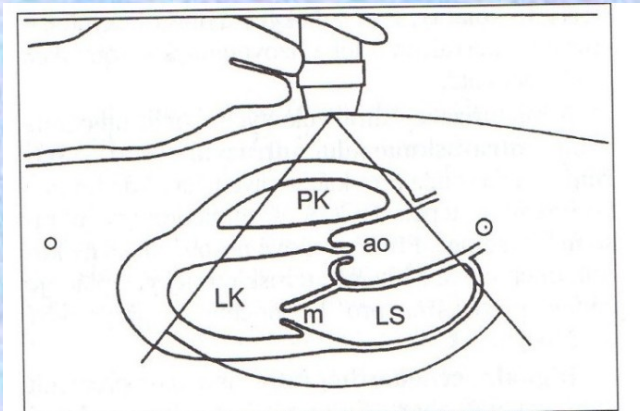


- We need than **pressure in the cuff corresponded to the pressure of the digital artery**
- **Method: photoplethysmography**
- Recorded photoelectric plethysmogram
- The new term: **Transmural pressure** – P_t (the pressure across the wall of the artery)
- BP, P_c (pressure in cuff), P_t
- We estimated: **$BP = P_c - - - P_t = 0 - - -$**
 photoplethysmogram registered the highest amplitude of oscillation --
 - we measure the **MAP**
- **Step by step** increase of P_c , in the moment of the highest amplitude – **feed-back loop** started for obtained(keeping) the constant volume of the finger

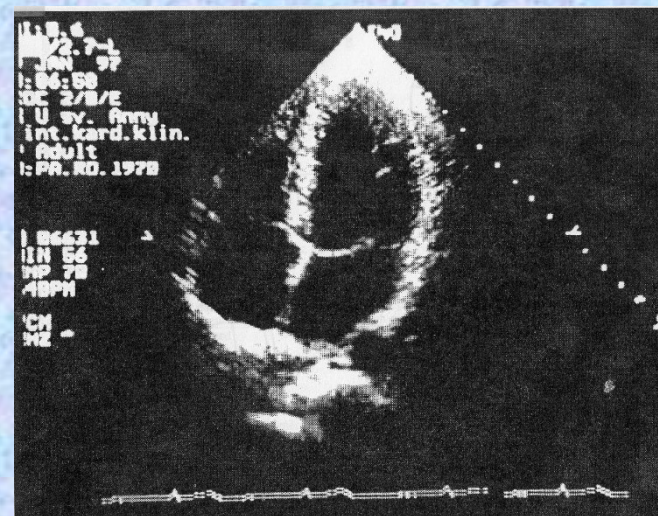
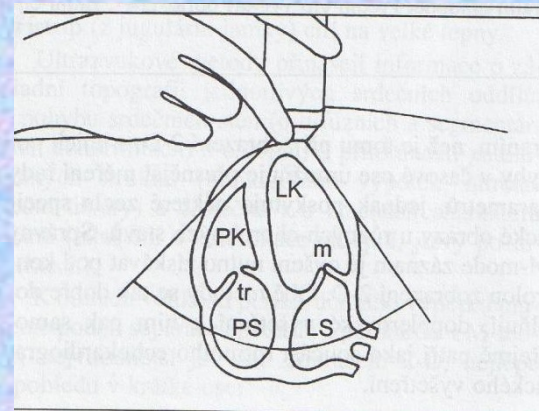
ECHOCARDIOGRAPHY

most widespread methods

PARASTERNAL LONG-AXIS VIEW

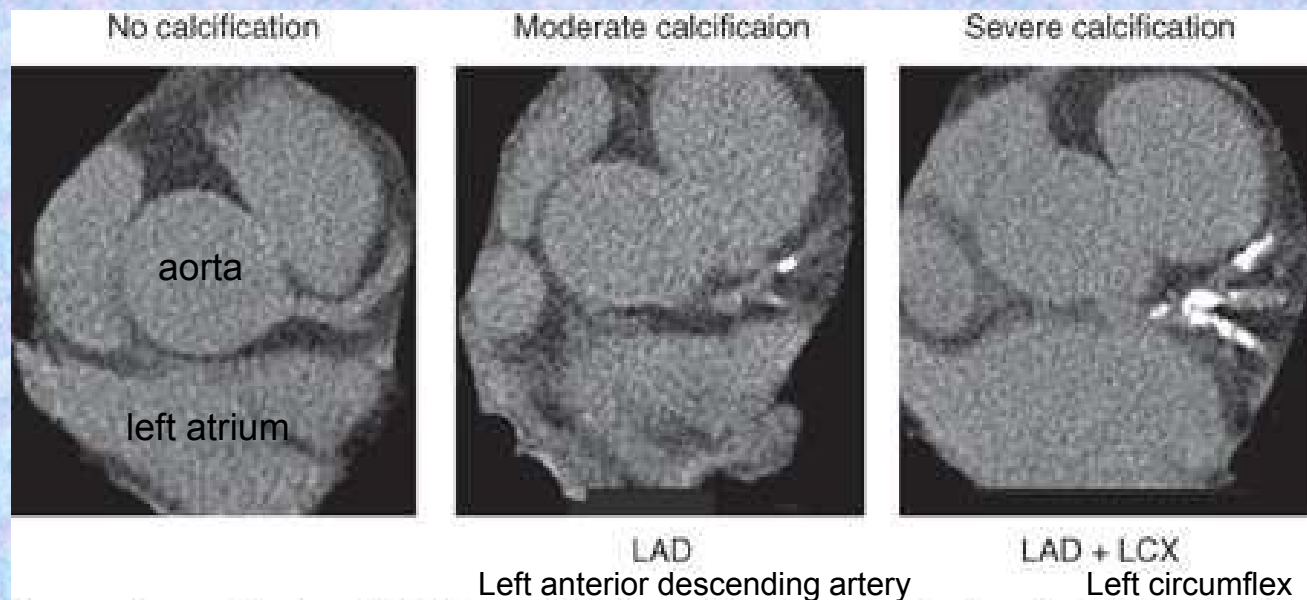


APICAL VIEW



COMPUTED TOMOGRAPHY

- CT is a fast, simple, noninvasive technique that provides images of the myocardium and great vessels;
- CT uses x-rays to create tomographic slices of objects-this is accomplished by rotating an x-ray beam around the object and measuring the transmission of x-rays through the object at many angles, called projections

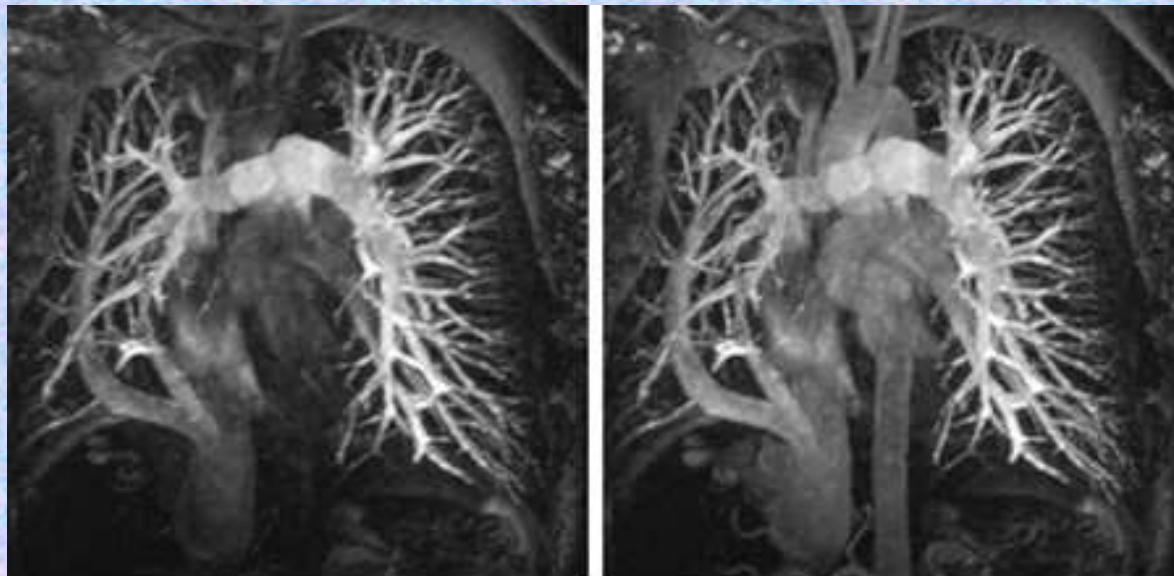


Source: Longo DL, Fauci AS, Kasper DL, Hauser SL, Jameson JL, Loscalzo J: *Harrison's Principles of Internal Medicine, 18th Edition*: www.accessmedicine.com

Copyright © The McGraw-Hill Companies, Inc. All rights reserved.

MAGNETIC RESONANCE IMAGING

- Based on the magnetic properties of hydrogen nuclei
- Used to quantify accurately EF, ESV, EDV, cardiac mass
- Without the need for ionizing radiation

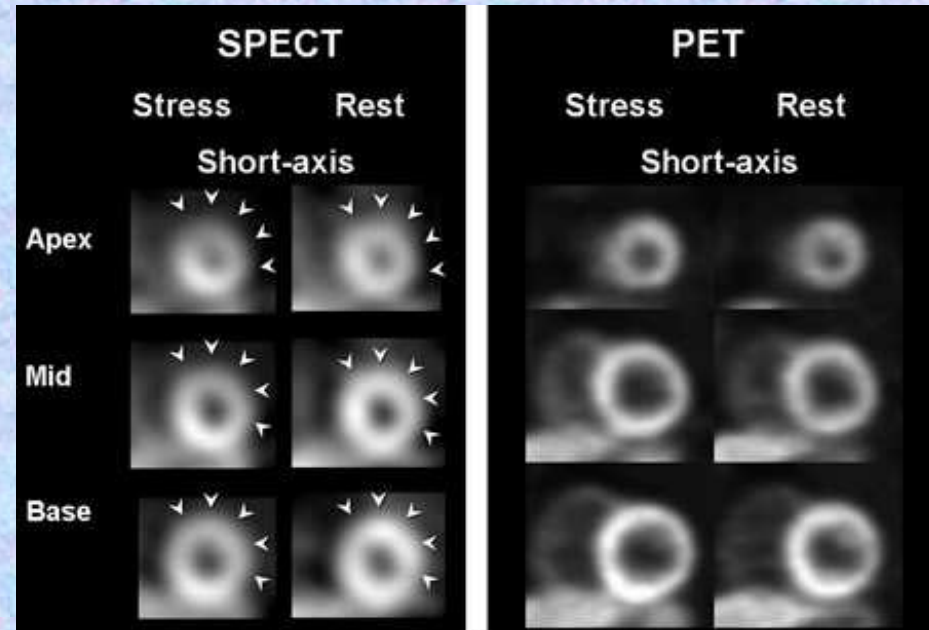


Source: Longo DL, Fauci AS, Kasper DL, Hauser SL, Jameson JL, Loscalzo J: *Harrison's Principles of Internal Medicine, 18th Edition*: www.accessmedicine.com

Copyright © The McGraw-Hill Companies, Inc. All rights reserved.

NUCLEAR CARDIOLOGY

- Nuclear (or radionuclid) imaging requires intravenous administration of isotopes
- Single photon emission computed tomography
SPECT and positron emission tomography
PET



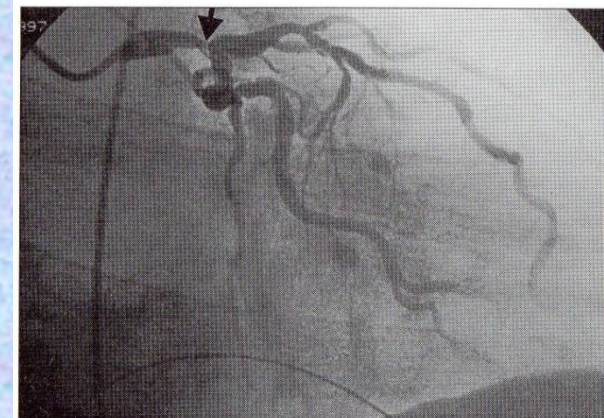
Source: Longo DL, Fauci AS, Kasper DL, Hauser SL, Jameson JL, Loscalzo J: *Harrison's Principles of Internal Medicine, 18th Edition*: www.accessmedicine.com
Copyright © The McGraw-Hill Companies, Inc. All rights reserved.

INVASIVE TECHNIQUES

- **CARDIAC CATHETERIZATION**
- ***Right heart catheterization*** – uses a balloon-tipped flotation catheter that is inserted into the **femoral or jugular vein**. Using fluoroscopic guidance, the catheter is advanced to the *right atrium - right ventricle – pulmonary artery* and *pulmonary wedge position* (as a surrogate for left atrial pressure = wedge pressure)

INVASIVE TECHNIQUE

- **CARDIAC CATHETERIZATION**
- ***Left heart catheterization*** – with the aid of fluoroscopy, the catheter is guided to ascending *aorta* – across the aortic valve into *left ventricle* (inserted into a.femoralis, a.axillaris, a.brachialis)
- A needle-tipped catheter to puncture the atrial septum during right heart catheterization
- **+ *coronary angiography***



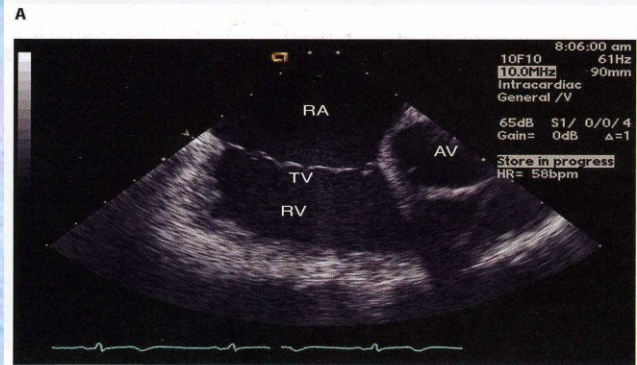
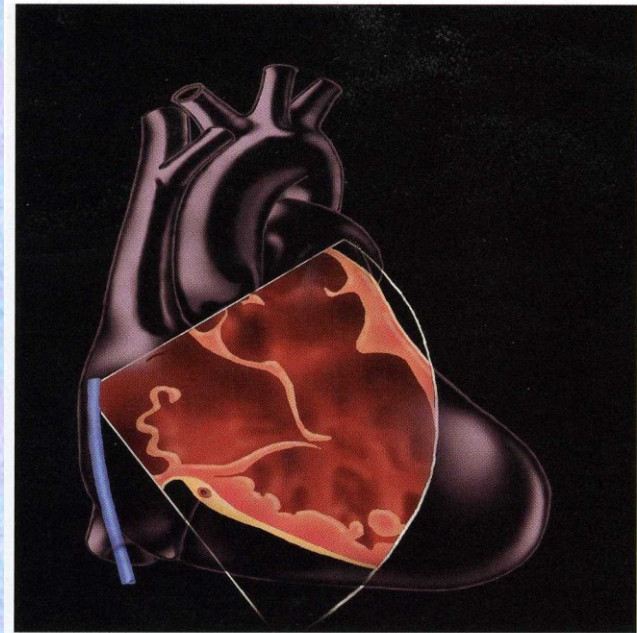
INVASIVE TECHNIQUE

- How do we use cardiac catheterization?
 - ✓ Pressure measurement
 - ✓ Blood flow measurement
 - ✓ Biopsy of tissue
 - ✓ Blood samples for oxygen-saturation analysis to screen for intracardiac shunts
 - ✓ Electric potentials measurement

Intracardiac Echocardiography

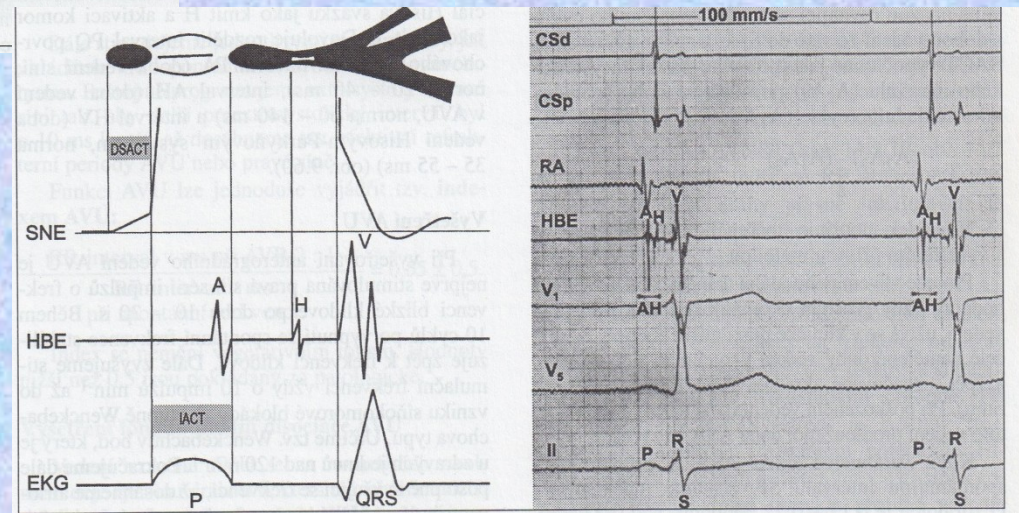
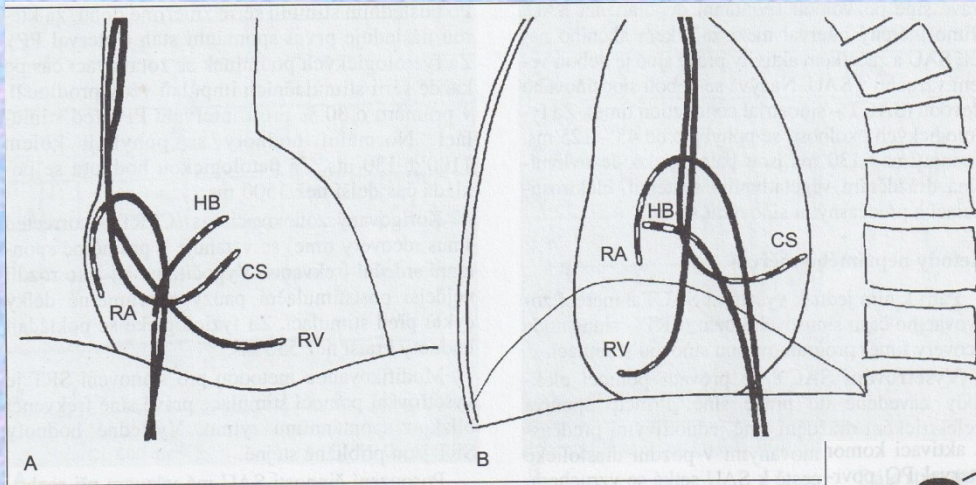
Is an intravascular ultrasound modality that provides diagnostic imaging of cardiac structures from within the heart.

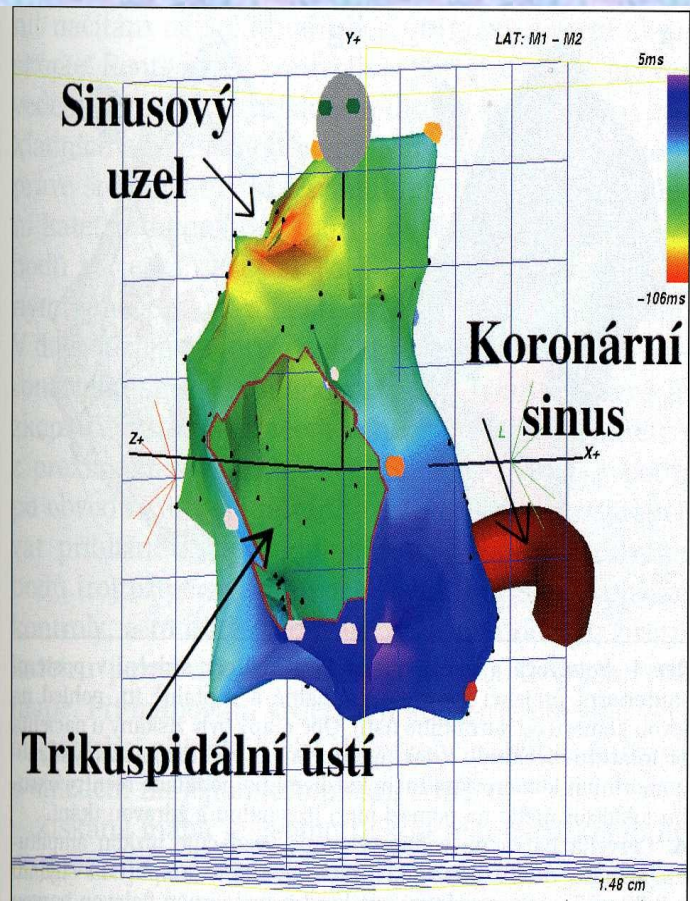
The first catheters used high frequency transducers (20-40 MHz) containing a single ultrasound crystal that rapidly rotated at the end of catheter



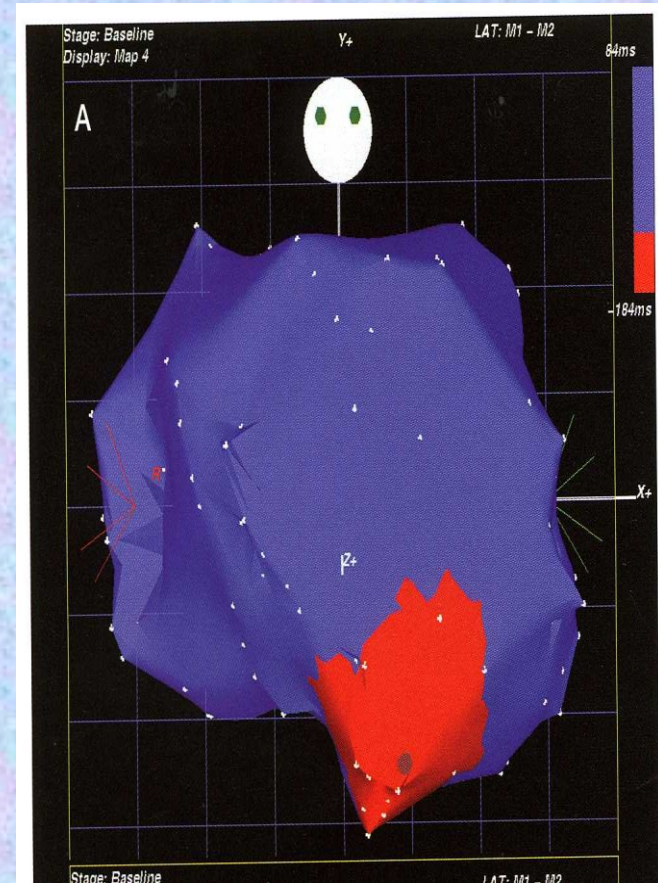
INVASIVE TECHNIQUE

- ELECTROPHYSIOLOGY EXAMINATION

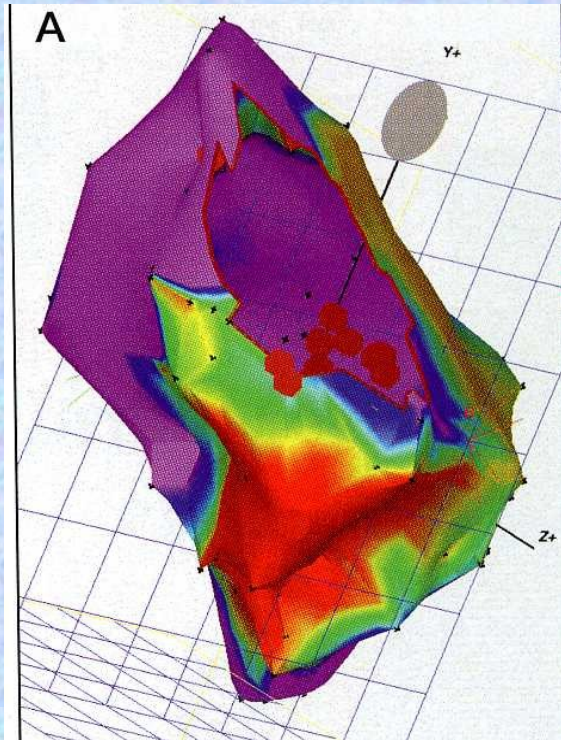




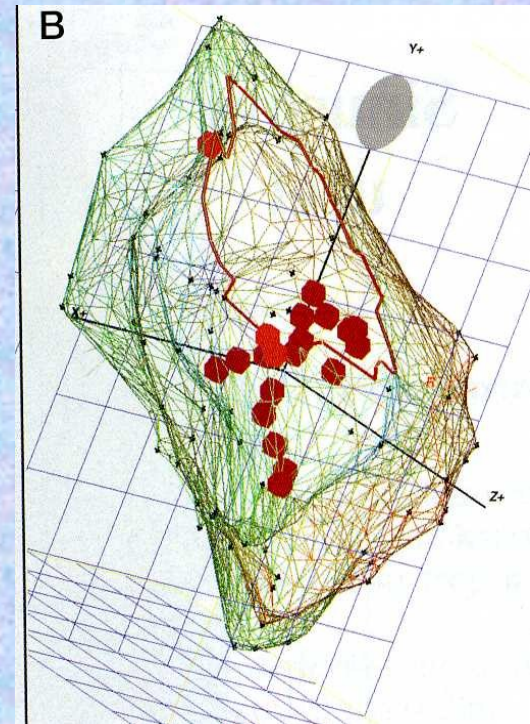
Activation map - Activation map of right atrium in left sloping projection - Sinus rhythm



Activation propagation map - propagation of left ventricular map



Voltage map – red color – places with a lower voltage, violet – healthy myocardium



Voltage map in network design – visibility of the catheter

- **THANK YOU FOR YOUR ATTENTION**