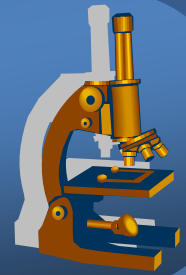


Systematic pathology

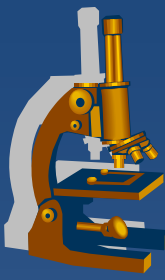


Genital system pathology

Breast pathology



Male genital tract pathology



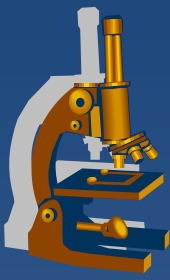
- x Prostate**
- x Penis, scrotum**
- x Testis, epididymis**

⇒ *congenital defects*

⇒ *circulatory disorders*

⇒ *inflammations*

⇒ *tumors*



Prostate gland

Prostate gland



✗ inborn defects uncommon

✗ circulatory disorders:

⇒ *infarction*

- in the setting of benign hyperplasia
- regenerative + reparative processes adjacent to the infarction focus may mimic a malignant lesion (esp. in needle biopsy)

Prostate gland



x inflammations:

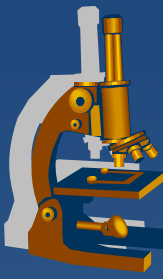
⇒ *bacterial (acute purulent or chronic)*

- systemic symptoms, dysuria, frequency, local pain
- ascendent, iatrogenic (cathetrisation, surgery, ...)
- *E. coli, Klebsiella, Proteus, enterobacter...*
- tb
 - most common tb presentation in the male genital system
 - local spread or isolated metastasis of lung tb
 - diff. dg. x reactive or idiopathic granulomatous prostatitis

⇒ *abacterial*

- most common, chronic pain or asymptomatic
- *Chlamydia trachomatis, ureaplasma...*

Prostate gland



x pseudotumors, tumors:

⇒ *Benign prostatic hyperplasia*

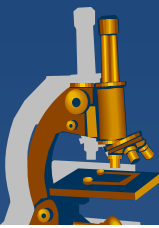
⇒ *Carcinoma*

- **Acinar**
- Ductal
- Squamous cell
- Adenosquamous
- Transitional cell
- Neuroendocrine

⇒ *Secondary tumors*

- local ca infiltration from adjacent organs (bladder, rectum)
- haematogenous metastases (lung ca, malignant melanoma, ..)

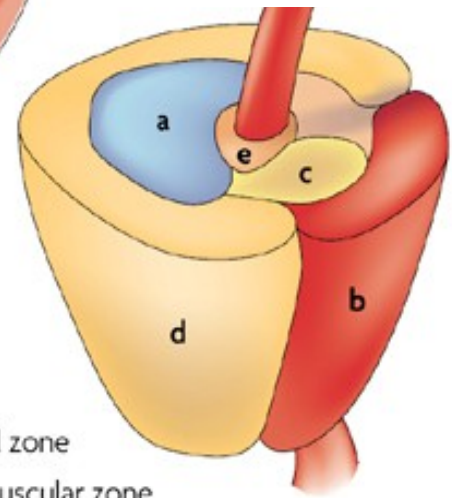
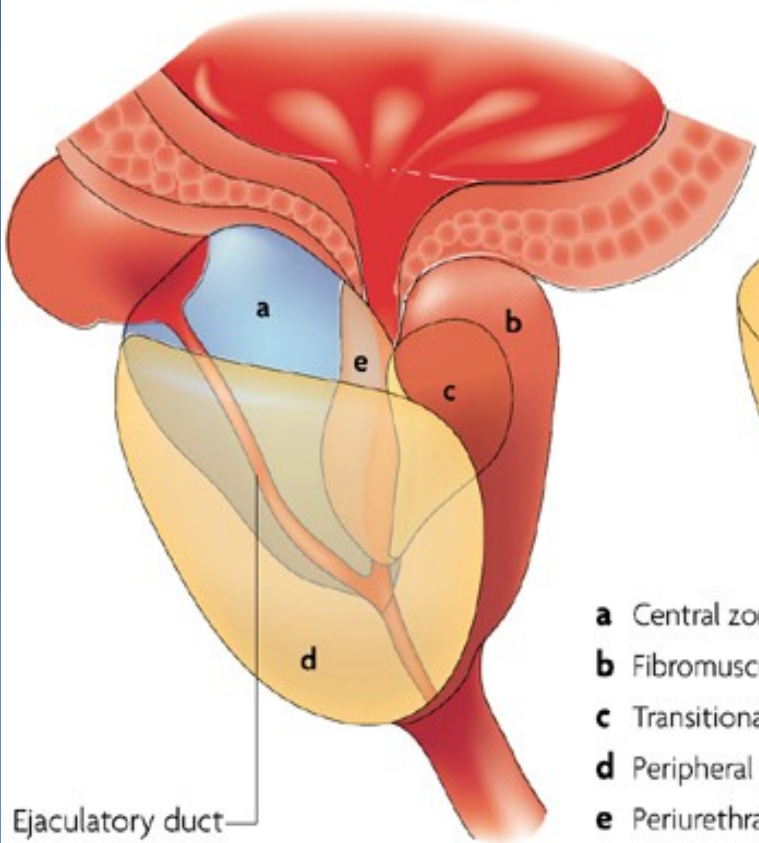
Zonal predisposition of prostate diseases



	Prostate zone		
	Peripheral	Transition	Central
Focal atrophy	Medium-high prevalence	Medium-high prevalence	Low prevalence
Acute inflammation	Low prevalence	Low prevalence	None
Chronic inflammation	Medium-high prevalence	Medium-high prevalence	Low prevalence
Benign prostatic hyperplasia	None	High prevalence	Low prevalence
High-grade PIN	Medium-high prevalence	Low prevalence	None
Carcinoma	Medium-high prevalence	Low prevalence	None

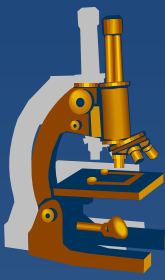
High prevalence Low prevalence
 Medium-high prevalence None

Prostate zones



- a** Central zone
- b** Fibromuscular zone
- c** Transitional zone
- d** Peripheral zone
- e** Periurethral gland region

Ejaculatory duct



Benign prostatic hyperplasia

x epidemiologic factors:

- ⇒ *age (BPH prevalence rising with age, 70% by age 60, 90% by 80)*
- ⇒ *geographic/racial (low in Asia, more common in W Europe)*

x pathogenesis:

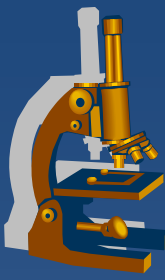
- ⇒ *not completely clear*
- ⇒ *hormonal dysbalance, dihydrotestosteron induced growth factors → stromal proliferation + ↓ death of glandular cells*

x gross nodular hyperplasia:

- ⇒ *periurethral (transition zone) mostly affected → urethral compression + obstruction → dysuria*

x consequences:

- ⇒ *lower urinary tract symptoms, acute/chronic urinary retention, cystitis*
- ⇒ *bladder hypertrophy + diverticula, hydroureter + -nephrosis, pyelonephritis*



Benign prostatic hyperplasia

x micro:

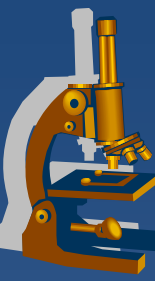
⇒ ***nodular structure***

⇒ ***glands:***

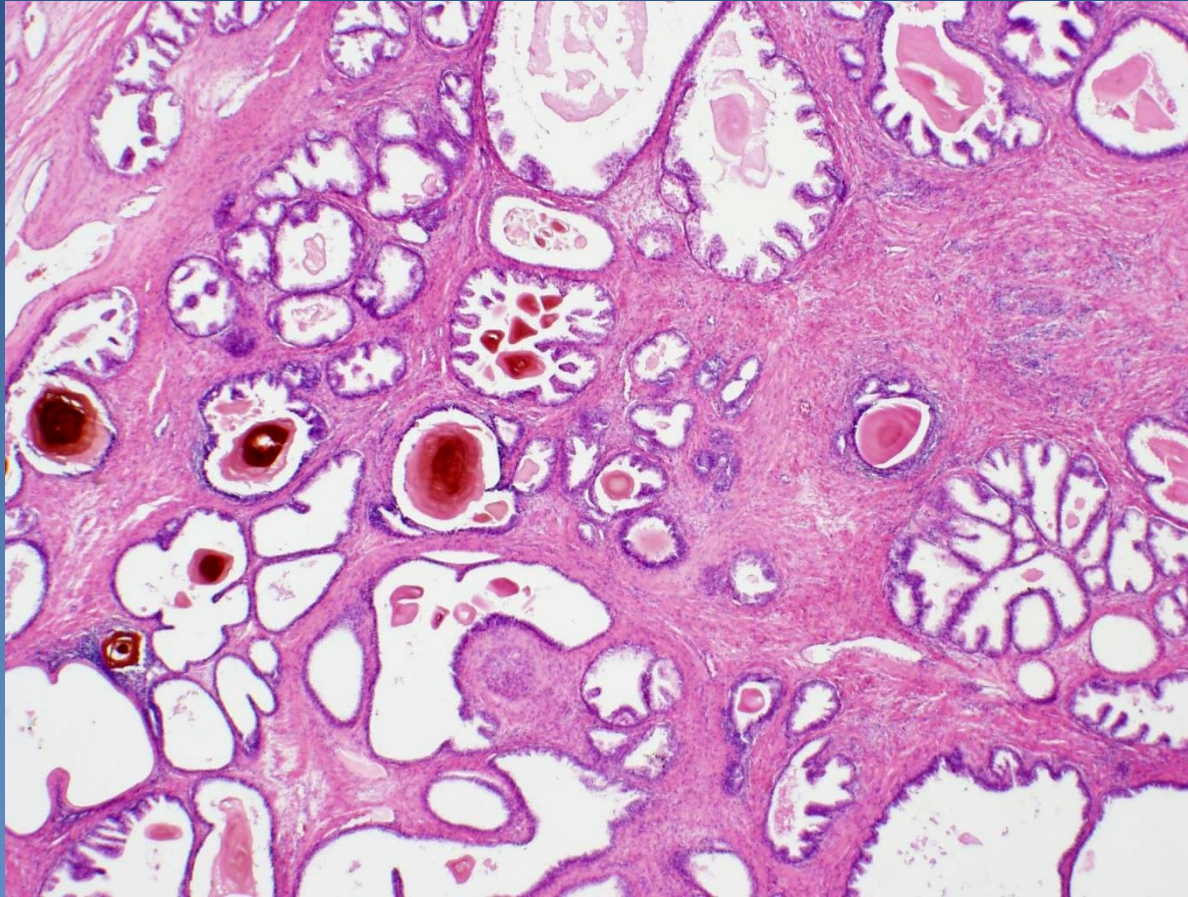
- hyperplastic, uneven size, common cystic dilatation
- bi-layered epithelium – external myoepithelial (!x invasive ca), inner secretory (sm. papillary proliferation)
- inspissated luminal secretions → corpora amylacea

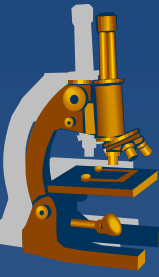
⇒ ***stroma:***

- hyperplastic, common purely stromal fibromuscular nodules
- disperse chronic inflammatory reaction

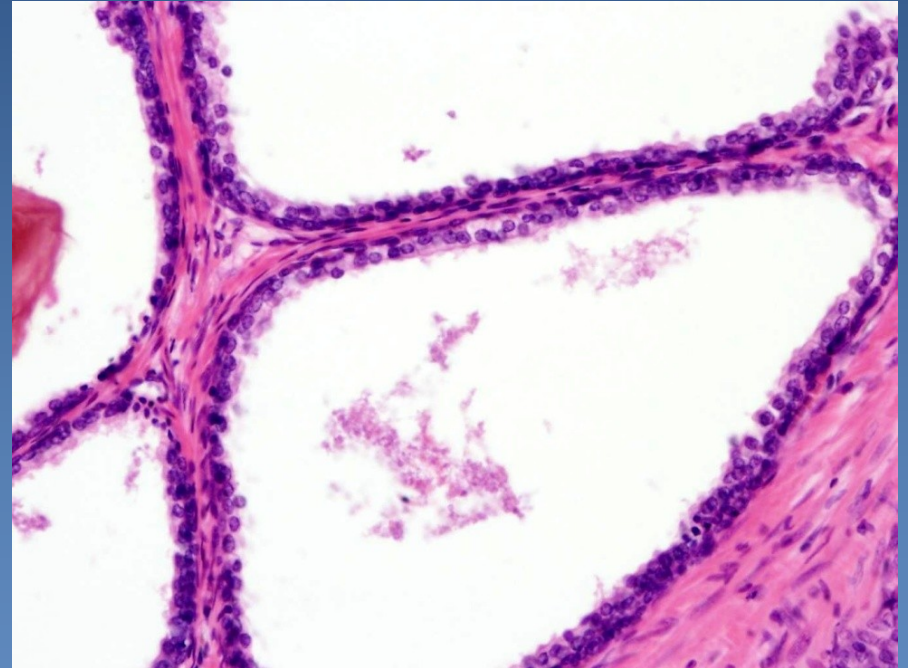
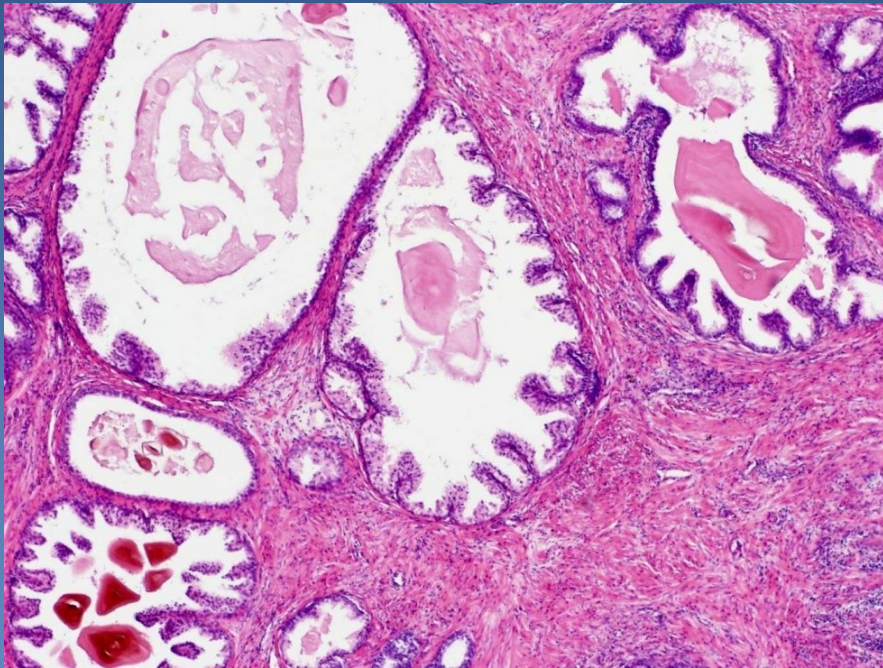


Benign prostatic hyperplasia





Benign prostatic hyperplasia



Prostatic adenocarcinoma



- x ↑ incidence
 - ⇒ *1st – 3rd of the most common male malignancies (prostate – lungs – colorectal)*

- x **peripheral zone of prostate, dorsal part (per rectum!)**

- x dg.:
 - ⇒ *needle biopsy (most common, by suspicion)*
 - ⇒ *transurethral resection (BHP treatment – accidental)*
 - ⇒ *suprapubic prostatic resection*

Prostatic adenocarcinoma



× Prostatic intraepithelial neoplasia (PIN)

⇒ *Low-grade*

- more numerous acinar cells, without significant nuclear atypias

⇒ *High-grade*

- significant cytonuclear atypia of acinar cells (enlarged nucleus, prominent nucleolus)
- **commonly in proximity of acinar adenocarcinoma – precursor lesion**

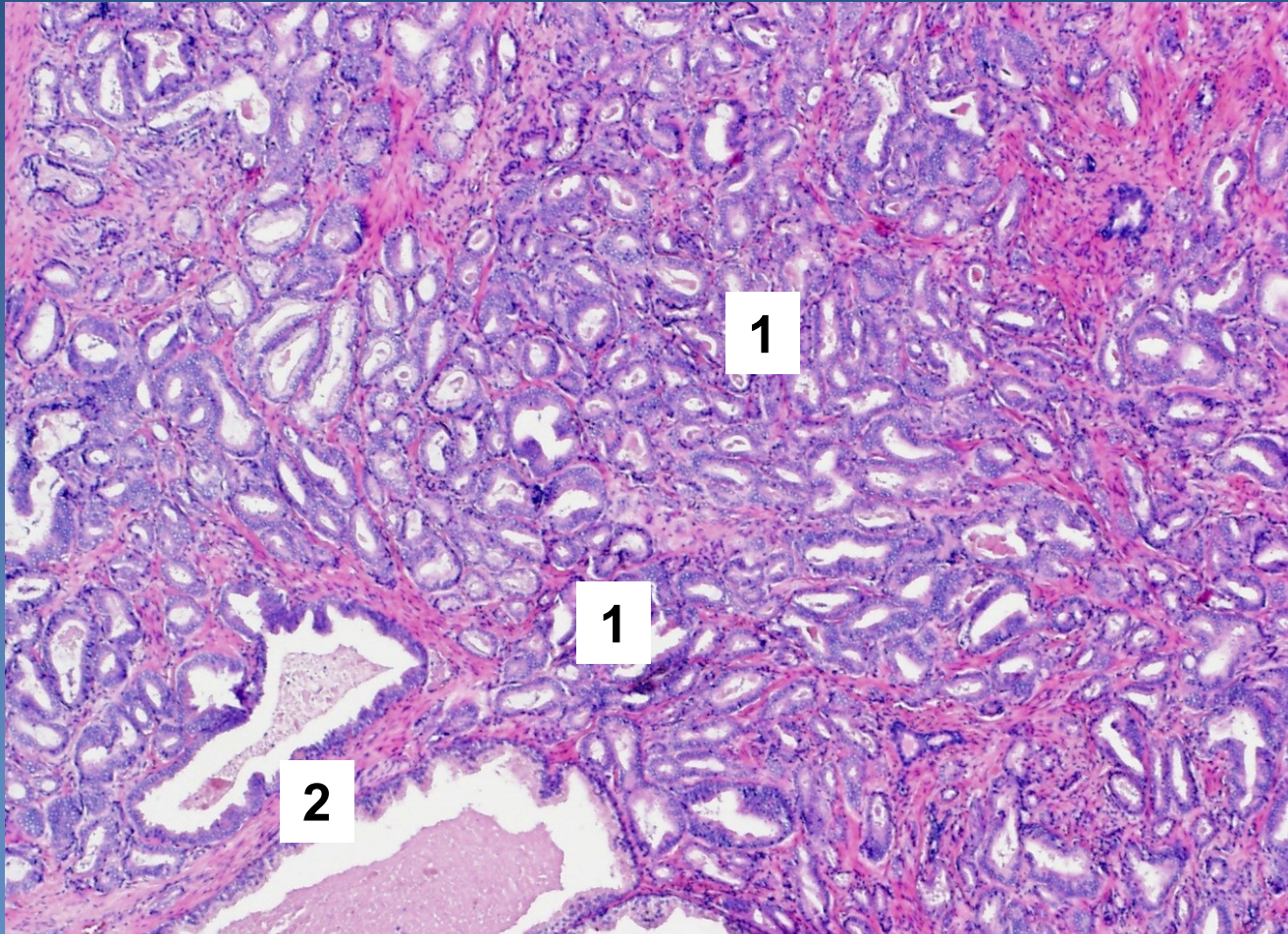
Acinar prostatic adenocarcinoma



x micro:

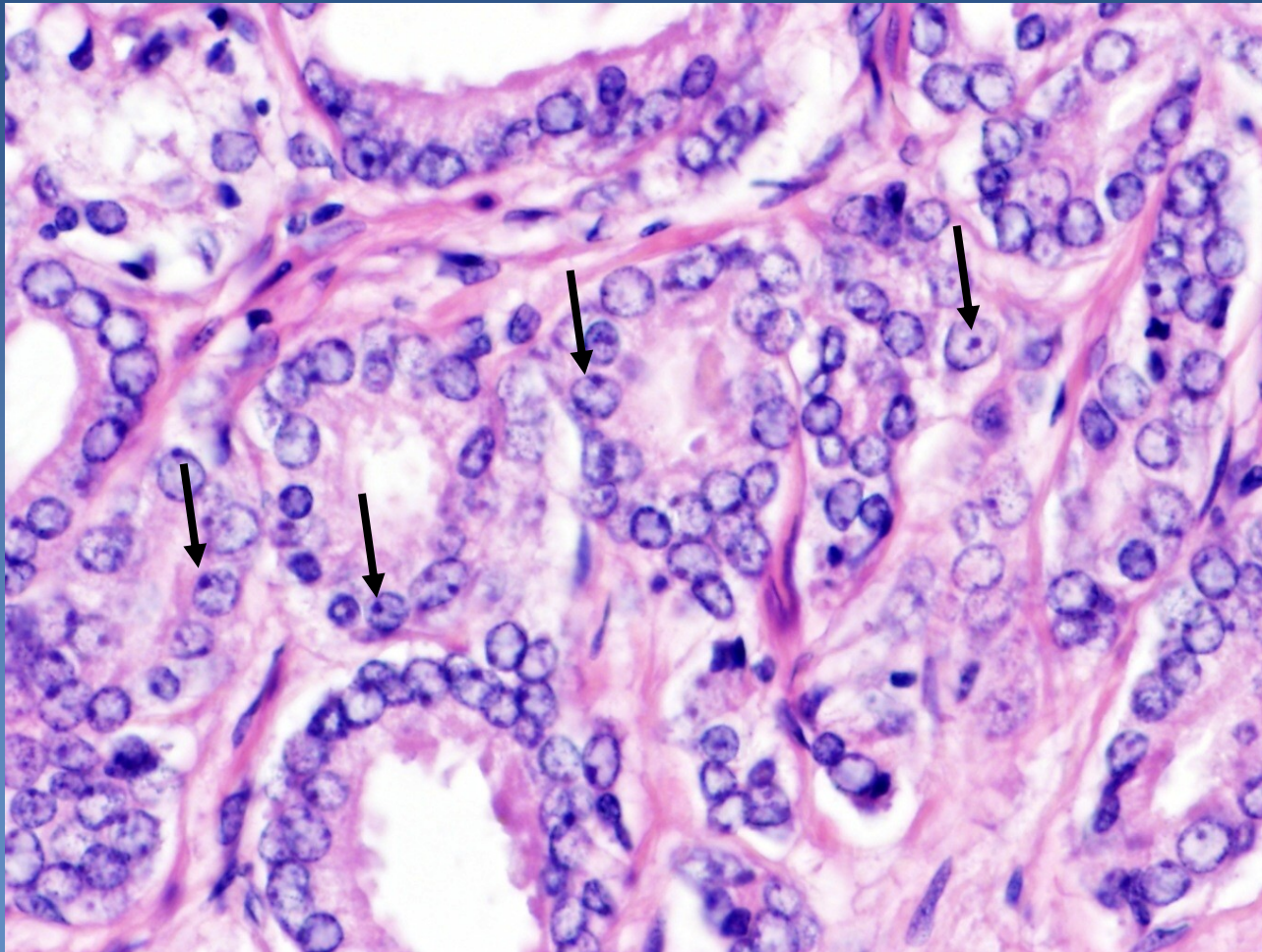
- ⇒ neoplastic cells with round nuclei and prominent nucleoli*
- ⇒ smaller crowded glands **without detectable layer of basal cells***
 - immunohistochemistry: HMW CK, p63 negative
 - neoplastic acini infiltrating between normal glands
 - intraluminal crystalloids (pale eosinophilic substance)
- ⇒ perineural and/or extraprostatic propagation possible*

Acinar prostatic adenocarcinoma



Small neoplastic acini (1) growing between prostatic glands (2)

Acinar prostatic adenocarcinoma




Nucleoli (arrows). Missing basal layer.

Acinar prostatic adenocarcinoma



✘ Gleason histologic grading (WHO modification):

- grade of glandular differentiation, growth pattern
- **combined score - dominant + secondary pattern in 5-grade system**
- grade 1 similar to normal prostatic tissue (uncommon in ca)
- grade 5 with solid, dissociated pattern
- final combined score, commonly Gleason score 7 (4+3)



Acinar prostatic adenocarcinoma



x spread

⇒ *local (per continuitatem)*

- into periprostatic soft tissues, seminal vesicles, urinary bladder (!x transitional cell ca, may be both in the same patient)

⇒ *via lymphatics*

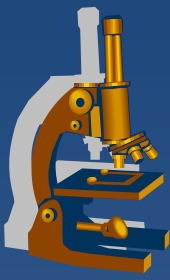
- into regional LN

⇒ *via blood*

- into bones – osteoblastic/osteosclerotic metastases (pelvis, vertebrae, ribs, long bones)
- later into liver, lungs...

x prognosis

- ### ⇒ *depend on the clinical stage (TNM), Gleason score, pre-operative PSA level in serum*



Testis, epididymis

Testis, epididymis



x congenital defects

⇒ *cryptorchidism (undescended testis)*

x circulatory and regressive changes

⇒ *necrosis (haemorrhagic infarction) – typical due to testicular torsion, ! emergency*

⇒ *atrophy – senile involution, vascular, hormonal...*

⇒ *intrasacrotal swelling*

- hydrocele (serous fluid in tunica vaginalis)
- haematocele (haemorrhage into tunica vaginalis)
- varicocele (varicose veins)
- spermatocele (cystic dilatation of epididymis ducts)

Testicular tumors



- × **Germinal**

 - ⇒ *from germ cell*

- × **Sex cord-stromal**

 - ⇒ *from specialized mesodermal gonadal stroma*

- × **Mixed germ cell – sex cord stromal tumors**

- × **Other primary tumors**

- × **Metastatic (secondary) tumors**

Testicular tumors : histopathological report



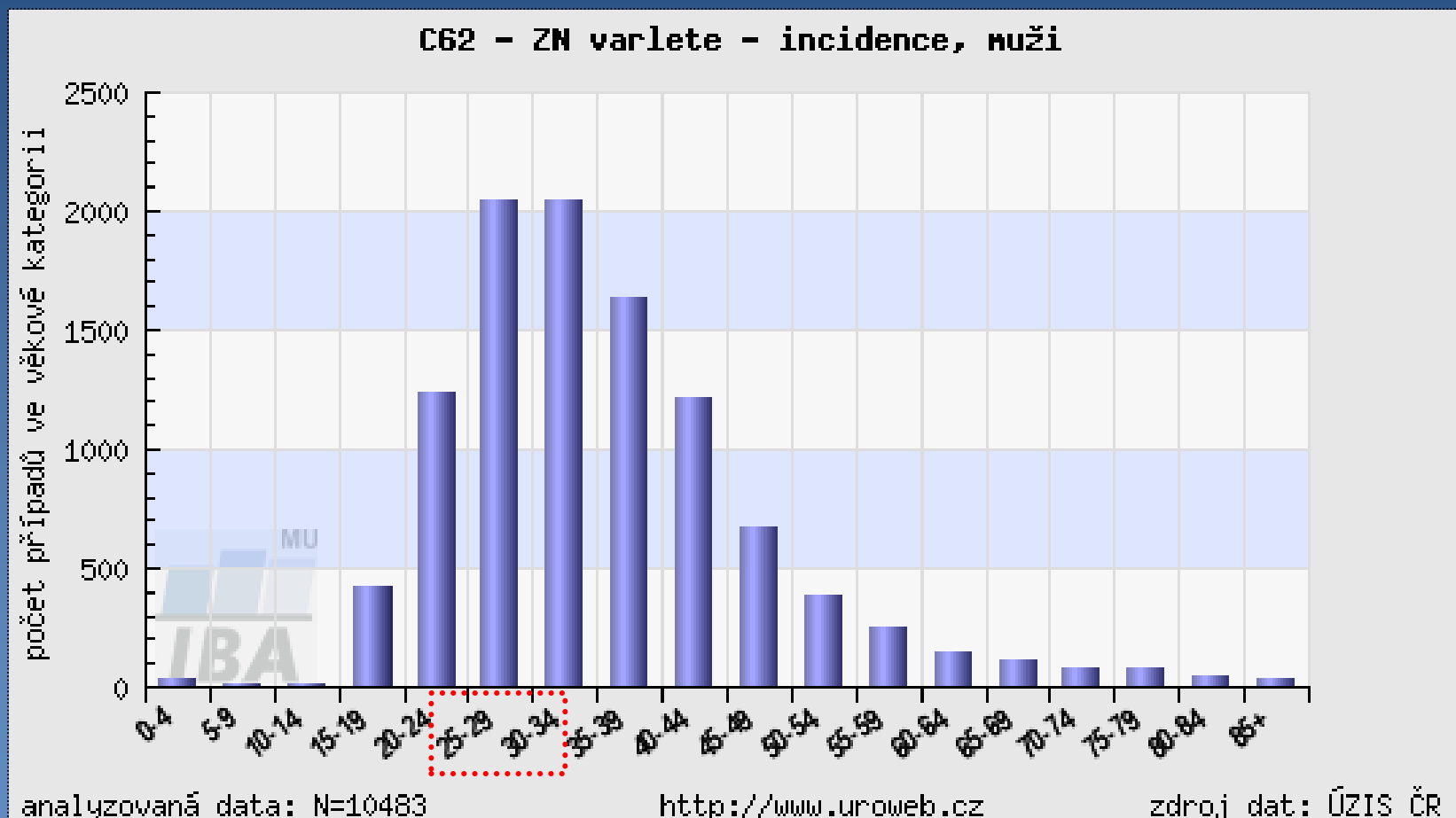

- x** gross picture (incl. size)
- x** histological type
- x** presence of vascular / lymphatic propagation
- x** tumor staging (TNM classification)
- x** presence of intratubular germ cell neoplasia (ITGCN - in situ germ cell lesion)

Germ cell tumors



- x ~90 % of primary testicular tumors
- x cryptorchidism
 - ⇒ 3-5x ↑ risk of malignancy in undescended testis
- x oncogenic markers:
 - ⇒ α FP, hCG, PLAP, CEA, LDH
 - ⇒ detection in serum, tissues
 - ⇒ important in diagnosis, monitoring the response to therapy, patient check-up after therapy

Age structure of testicular tumors patients

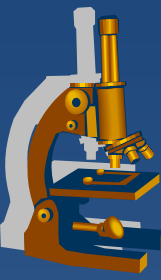


Germ cell tumors



- ✘ Germ cell tumors derived from germ cell neoplasia in situ
 - ⇒ *GCNIS precursor lesion of most germ cell tumors*
 - ⇒ **basic classification:**
 - ⇒ *seminoma*
 - ⇒ *non-seminomatous tumors*

- ✘ Germ cell tumors unrelated to GCNIS
 - ⇒ *prepubertal teratoma*
 - ⇒ *spermatocytic tumor*
 - ⇒ *prepubertal yolk-sac tumor*



Germ cell tumors+ GCNIS

- x** germ cell tumors of 1 histologic type – 60 %
- x** mixed germ cell tumors – 40 %
- x** metastases into LN (paraaortal LN),
via blood (most commonly into lungs)

Germ cell tumors histogenesis



Differentiation along gonadal line (gonocyte, spermatogonia)
without further differentiation potential.

Seminoma

Original primitive
germ cell

Undifferentiated cell

Embryonal carcinoma

Totipotent cell

Extraembryonal differentiation

Yolk sac tumor

Choriocarcinoma

Intraembryonal differentiation

Teratoma (mature, immature, with
malignisation of somatic elements)

Polyembryoma

Germ cell tumors classification



x tumors of single histologic type

⇒ ***Seminoma*** (+ variants)

⇒ ***Non-seminomatous germ cell tumors***

- **Embryonal carcinoma**
- **Yolk sac tumor**
- **Choriocarcinoma**
- **Teratomas**
 - mature
 - immature
 - with malignisation of somatic elements

Germ cell tumors classification



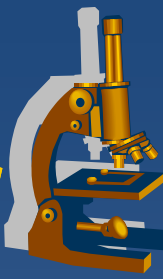
- x mixed germ cell tumors**

 - ⇒ tumors with >1 histogenetic type*

- x Spermatocytic tumor**

 - ⇒ separate clinical and pathological entity
(different morphology/prognosis)*

Germ cell tumors Characteristics



	age	marker	structure
Seminoma	30-50	10% HCG	solid, clear cells, lymphocytic stroma
Embryonal carcinoma	20-30	90% HCG/AFP	undiff. cells, organoid, necrosis
Yolk sac	<3	90% AFP	variable
Choriocarcinoma	20-30	100% HCG	cyto- + syncytiotrophoblast
Teratoma	no predilection	possible HCG,AFP	variable structures of >1 germ layer
Mixed tu	15-30	possible HCG,AFP	variable structures

Seminoma



x classical

⇒ *morphological variants:*

- seminoma with high mitotic rate (anaplastic), same treatment
- seminoma with syncytiotrophoblastic cells (↑ HCG)

⇒ *mostly age 25 - 45 years*

⇒ *tumor cells*

- in solid nests
- large cell, clear cytoplasm (glycogen), distinctive cellular membrane, large nuclei with 1-2 nucleoli

⇒ *fibrovascular septa*

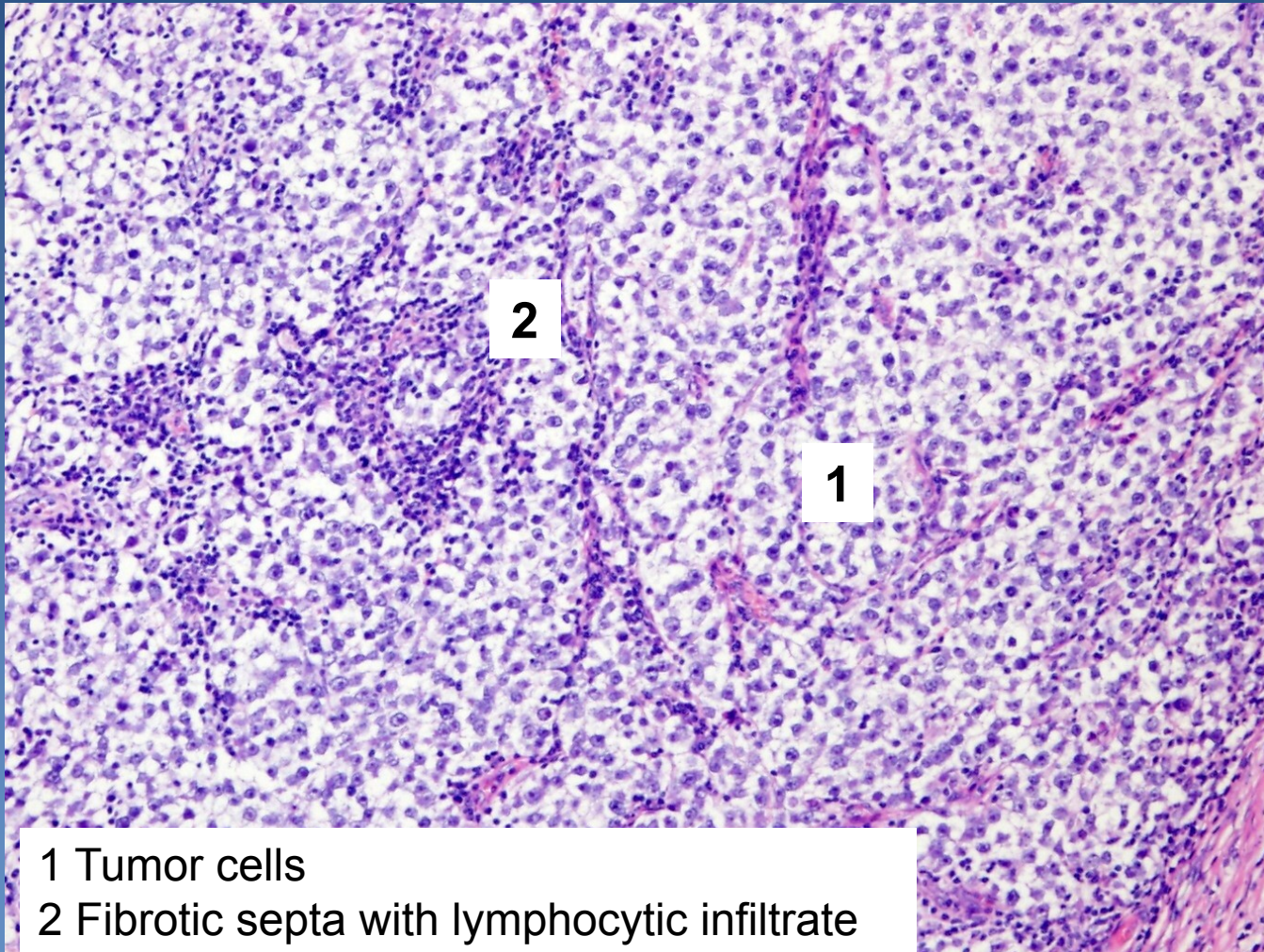
- with lymphocytic infiltrate (event. + granulomas)

⇒ *immunohistochemistry: PLAP+*

⇒ *marker – 10% HCG*

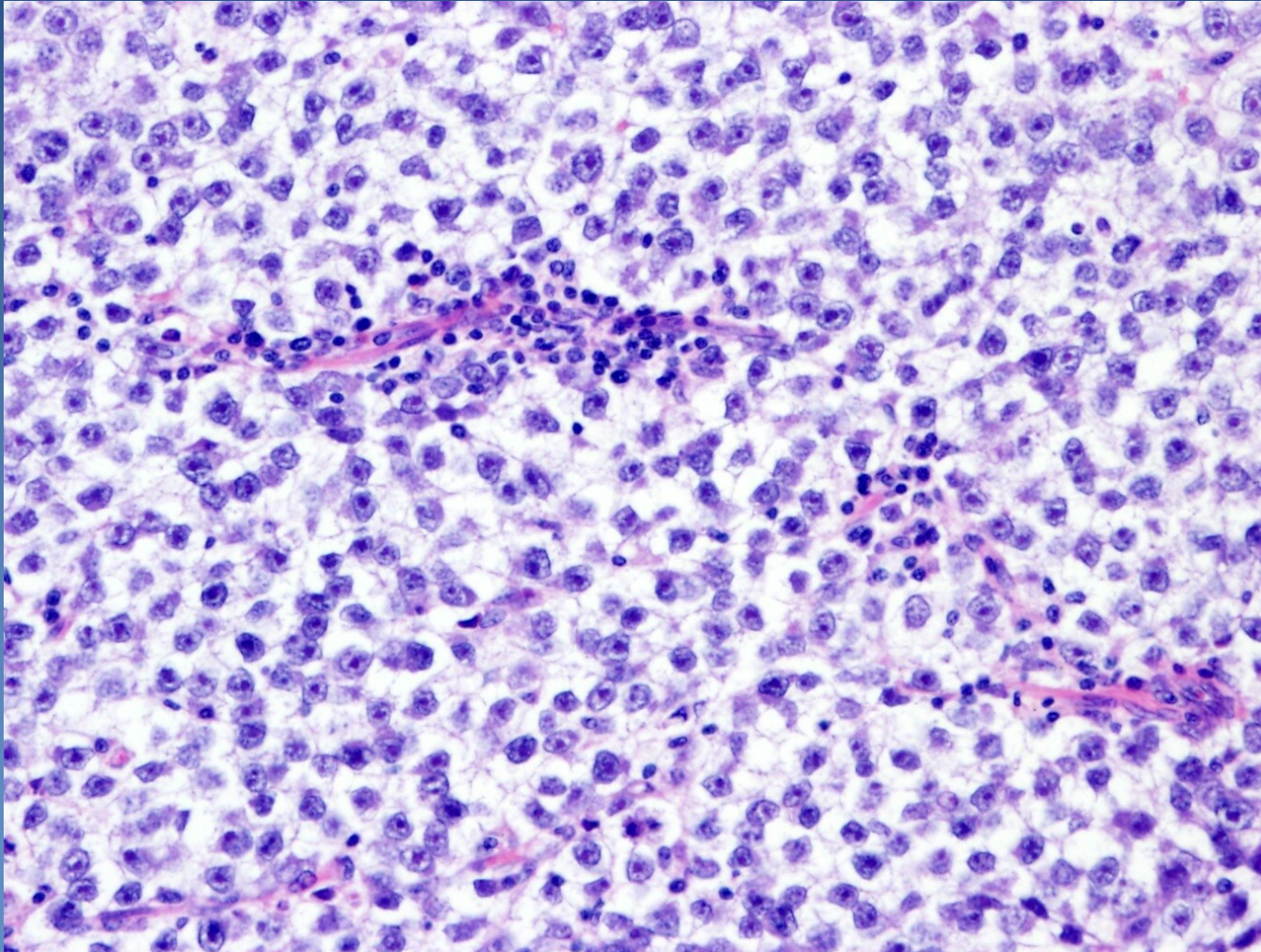
⇒ *radio- and chemosensitive (usually good prognosis)*

Seminoma



- 1 Tumor cells
- 2 Fibrotic septa with lymphocytic infiltrate

Seminoma

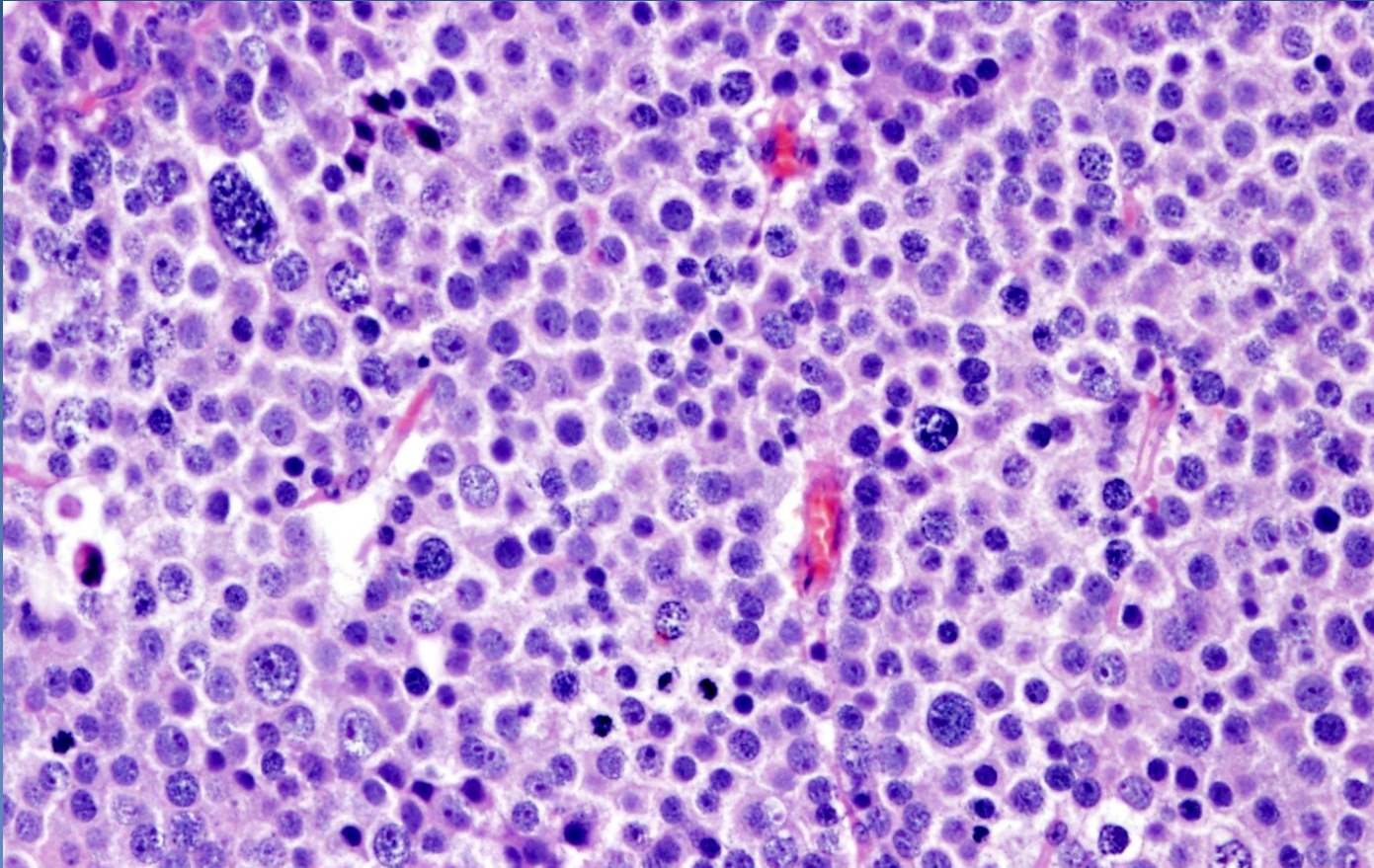


Spermatocytic tumor



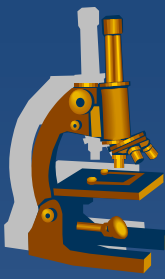
- ⇒ *quite distinctive tumor, not a part of mixed germ cell tumors*
- ⇒ *only in the testis, older M, rare*
 - locally aggressive, no metastases
- ⇒ *tumor cells*
 - variable size (≈early stages of spermatogenesis)
 - **no glycogen**, no association with intratubular germ cell neoplasia
- ⇒ *fibrovascular septa without lymphocytic reactive infiltrate*
- ⇒ *IHC: PLAP-*

Spermatocytic tumor



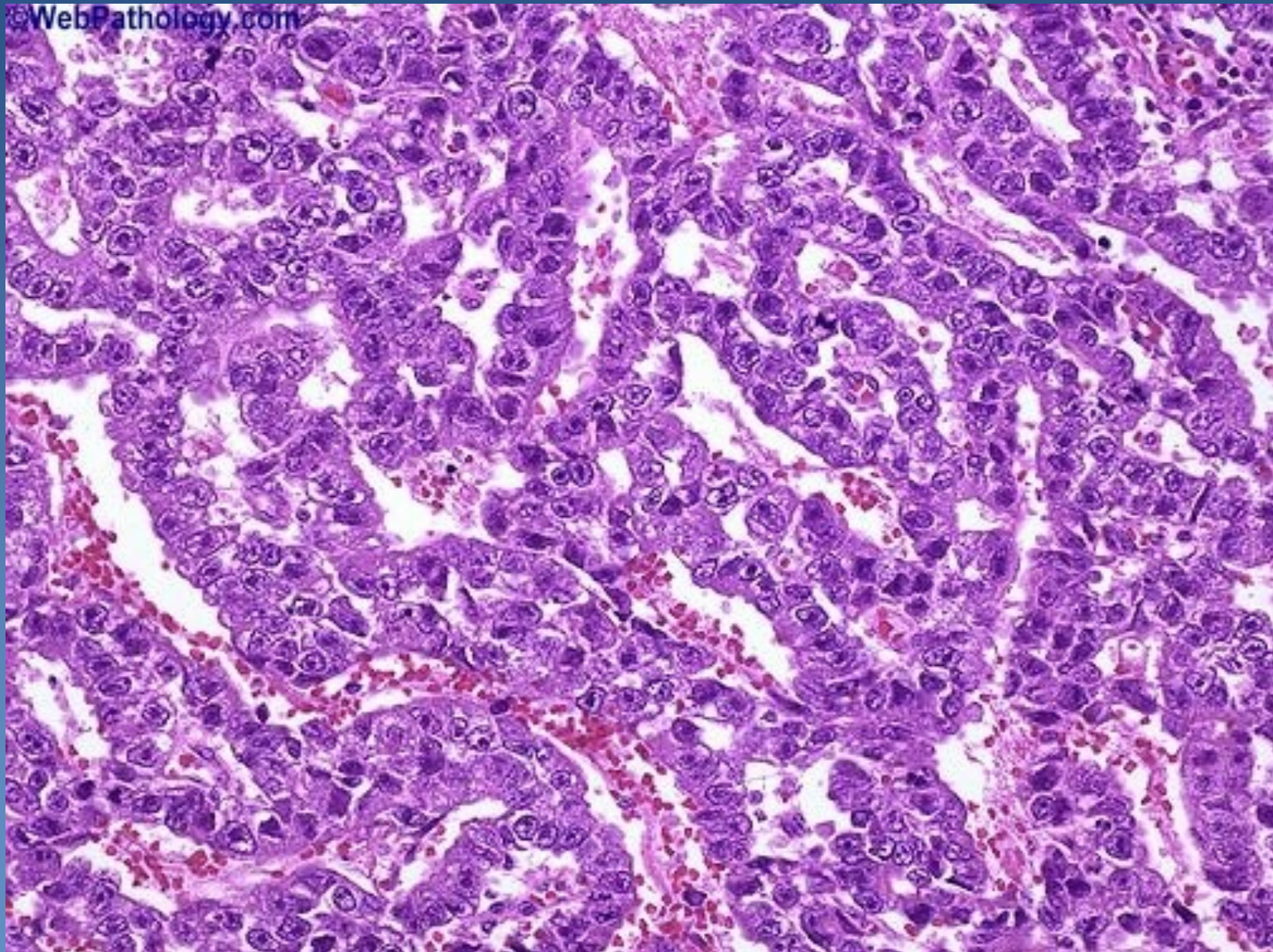
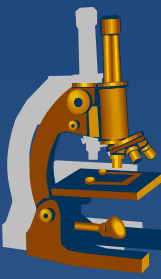
Mixture of polymorphic tumor cells (~ early stages of spermatogenesis): large cells with lacy chromatin, middle-sized cells with round nuclei, small lymphocyte-like cells.
Fibrotic septa without lymphocytic infiltrate

Embryonal carcinoma



- ✗ undifferentiated tumor, cells of epithelial appearance
- ✗ commonly as part of mixed germ cell tumors
 - ⇒ *worse prognosis*
- ✗ **micro:**
 - ⇒ *solid, trabecular, abortive tubular formations*
 - ⇒ *large cells, high mitotic activity*
 - ⇒ *stroma without lymphatic reaction*

Embryonal carcinoma



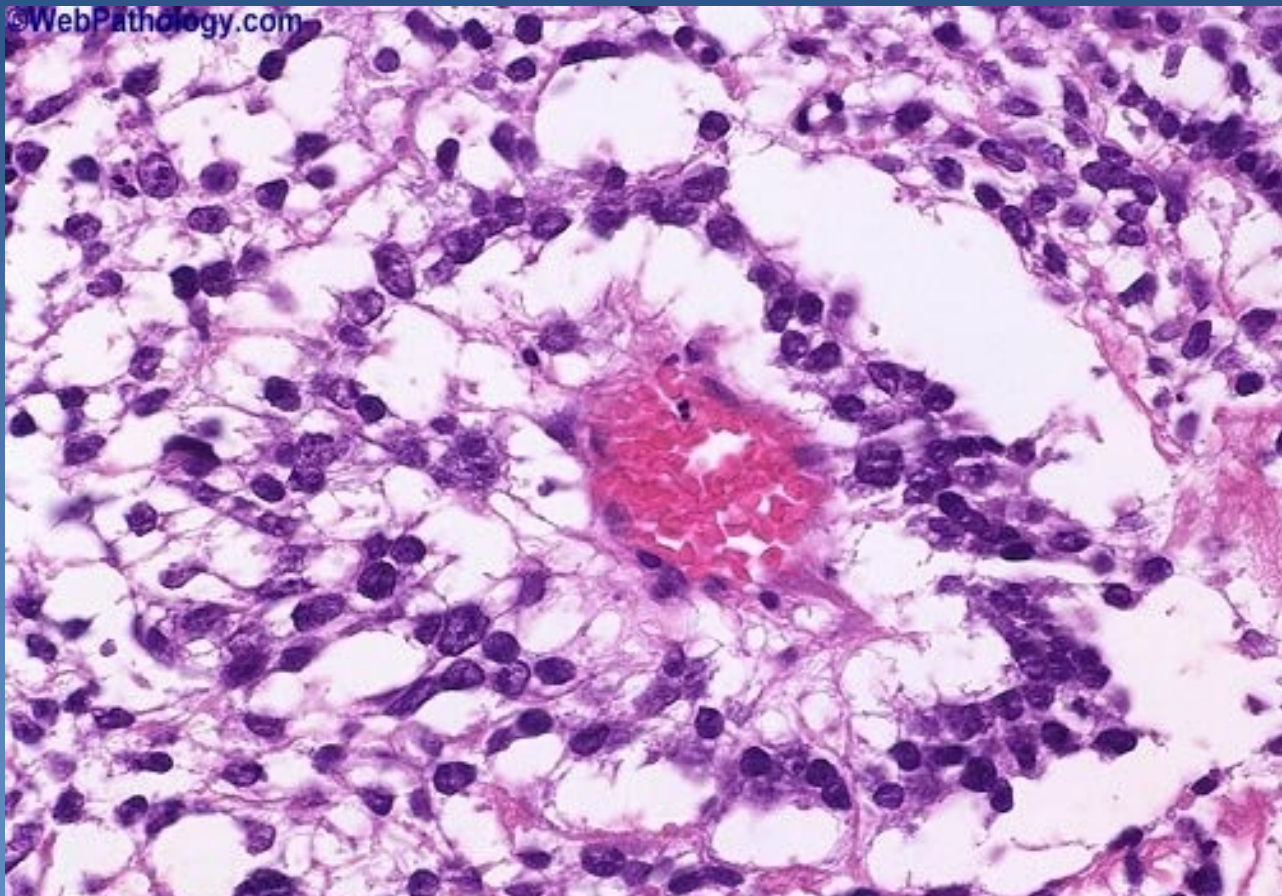
Yolk sac tumor



- ✗ ~ yolk sac structures, extraembryonal mesodermal tissues
- ✗ in pure form in infants, young (<3 yrs) children, better prognosis
- ✗ in adults a component of mixed germ cell tumors, worse prognosis
- ✗ α -fetoprotein (AFP) secretion – IHC, serum

- ✗ **micro:**
 - ⇒ *microcystic, reticular, papillary formation, variable patterns*
 - ⇒ *glomeruloid structures (Schiller-Duval bodies)*
 - stalk with capillary lined on the surface by layer of tumor cells
 - ⇒ *tumor cells*
 - flat, polygonal or cuboidal

Yolk sac tumor



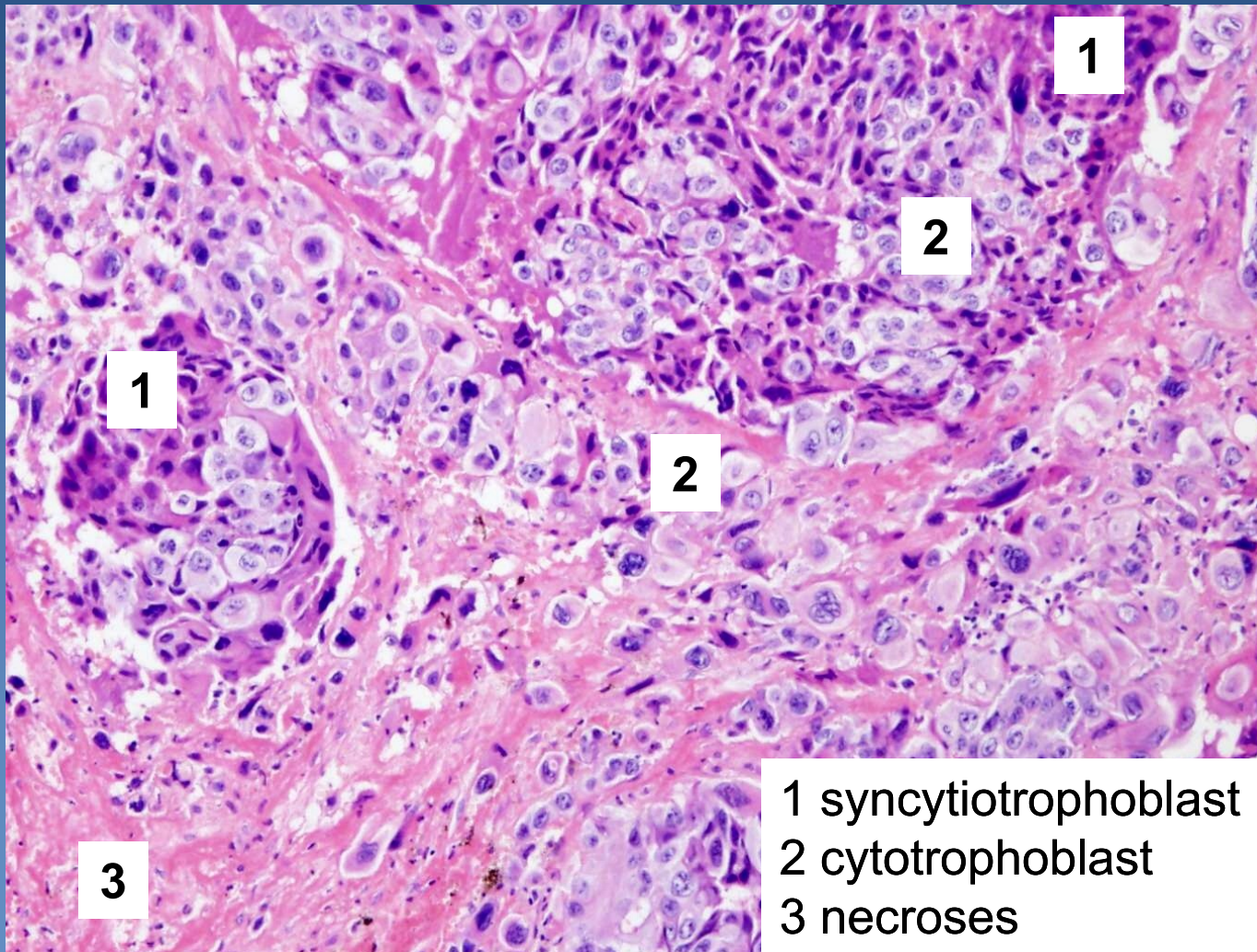
Schiller-Duval body (glomeruloid formation)

Choriocarcinoma

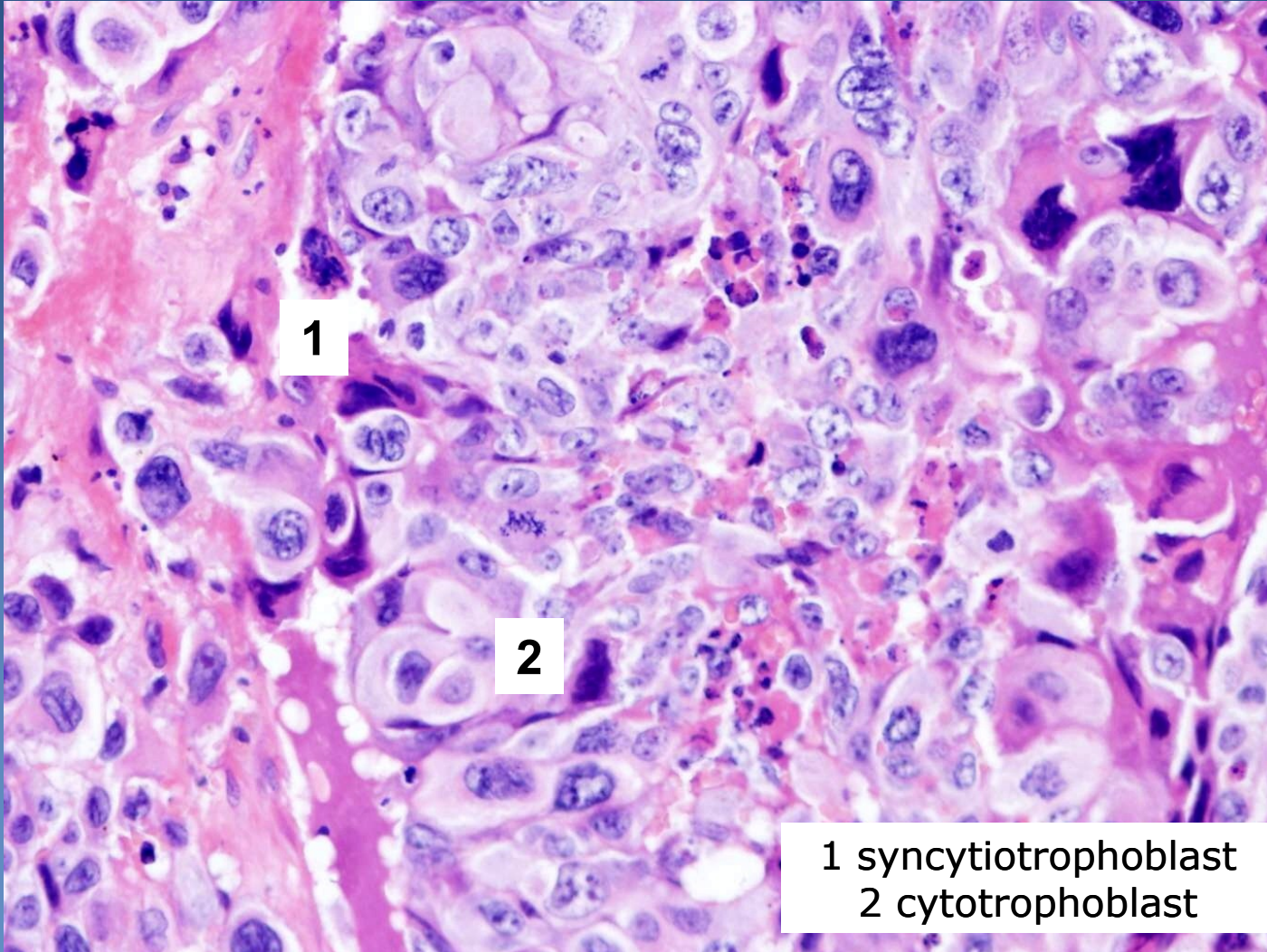


- ✘ mixture of syncytiotrophoblast, cytotrophoblast, intermediate trophoblast cells
- ✘ pure very rare, more commonly as component of mixed germ cell tumors, HCG ↑
- ✘ gross/ micro:
 - ⇒ *haemorrhagic + necrotic tumor*
 - ⇒ *variable patterns of syncytiotrophoblast with admixture of larger polygonal cells of cytotrophoblast event. + intermediate trophoblast*

Choriocarcinoma



Choriocarcinoma



Teratoma



x intraembryonal differentiation

⇒ *terminal differentiation into 3, 2 or 1 germ layers (monodermal teratoma)*

x mature uncommon in testis (x ovary); pure in children

x histologic classification

⇒ *differentiated mature t.*

- completely matured tissues with organoid structure
- commonly cystic, containing serous fluid, mucus, keratin

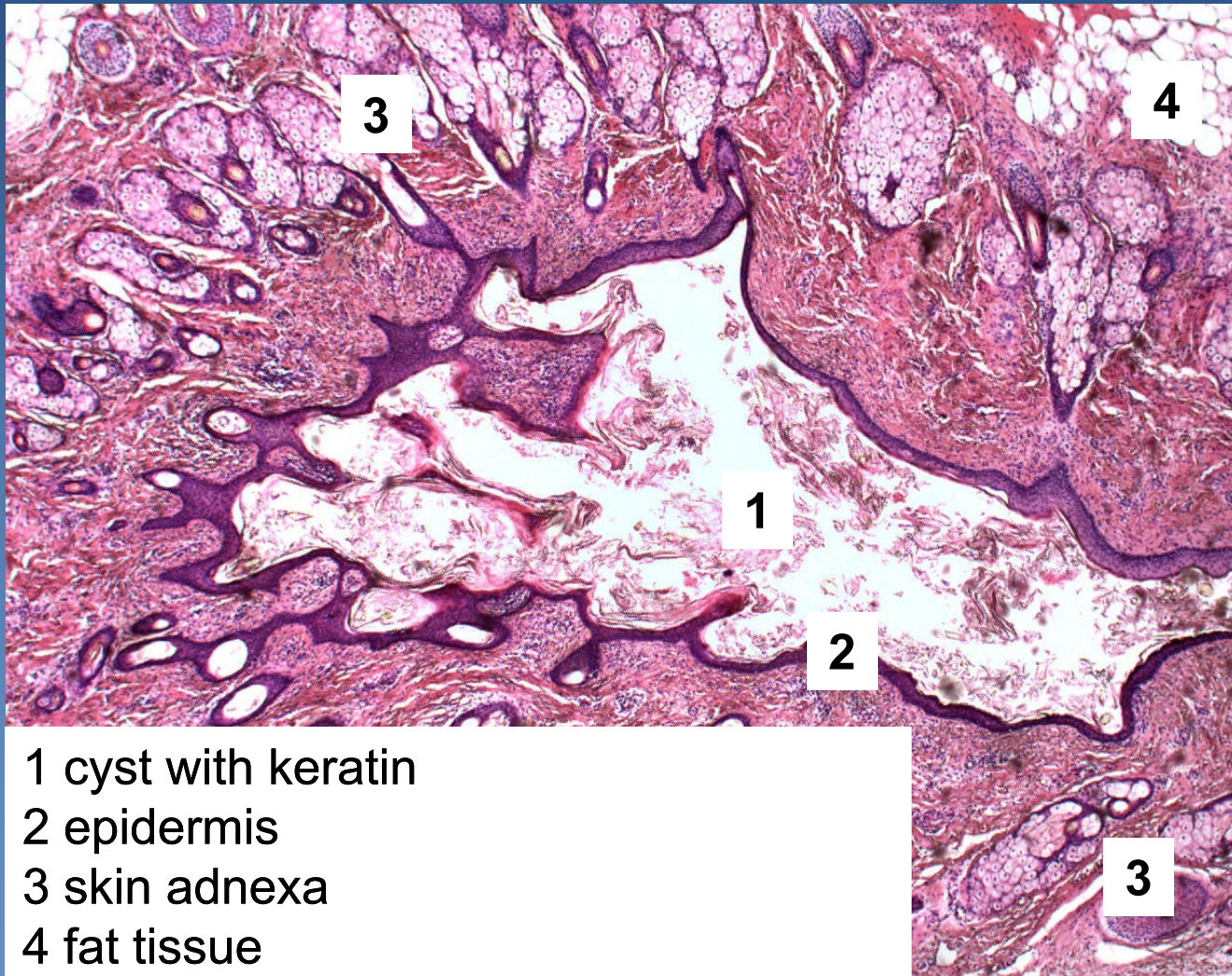
⇒ *differentiated immature t.*

- immature tissues of embryonal/fetal appearance (neuroectoderm)

⇒ *t. with somatic type malignancy*

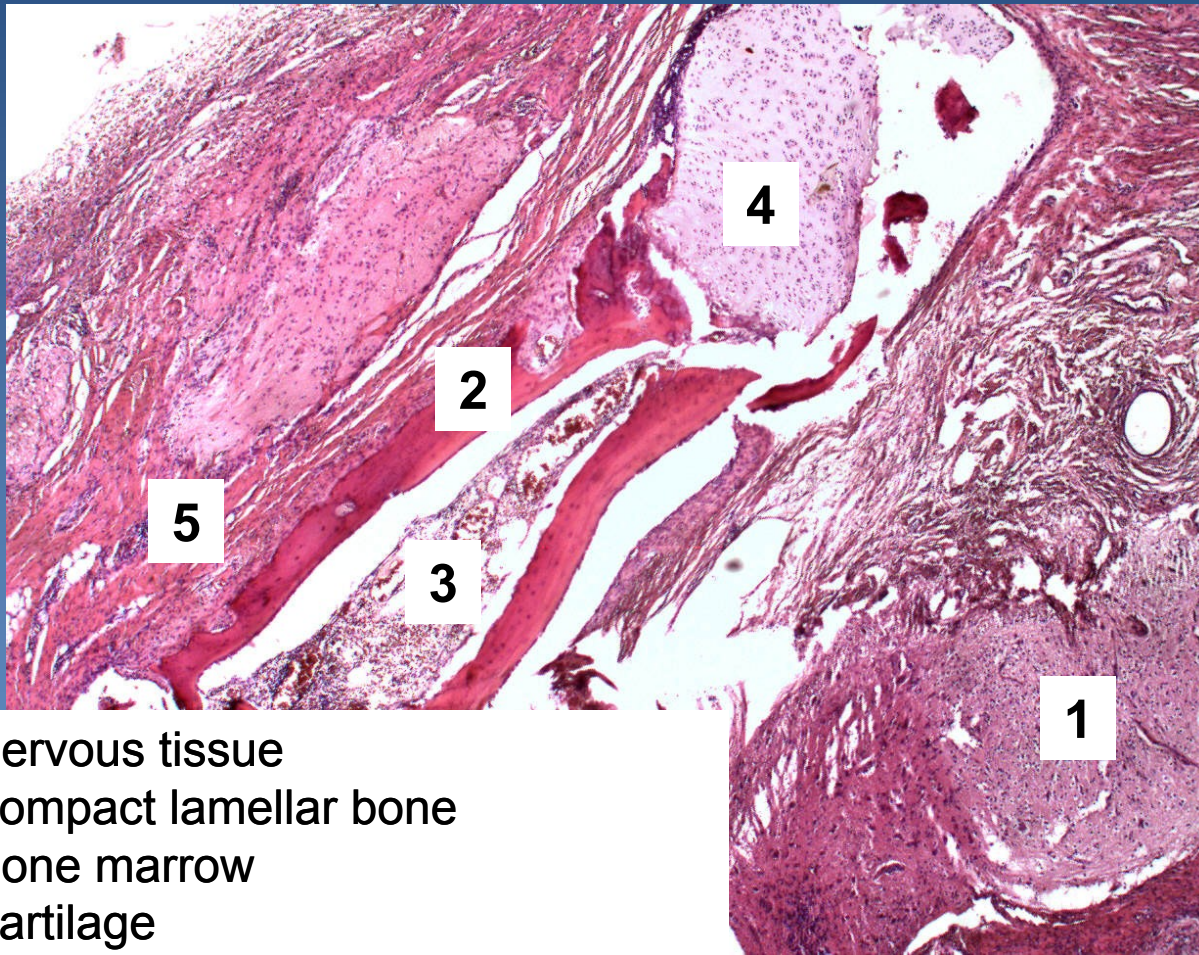
- sarcoma, carcinoma, PNET

Differentiated mature teratoma (dermoid cyst)



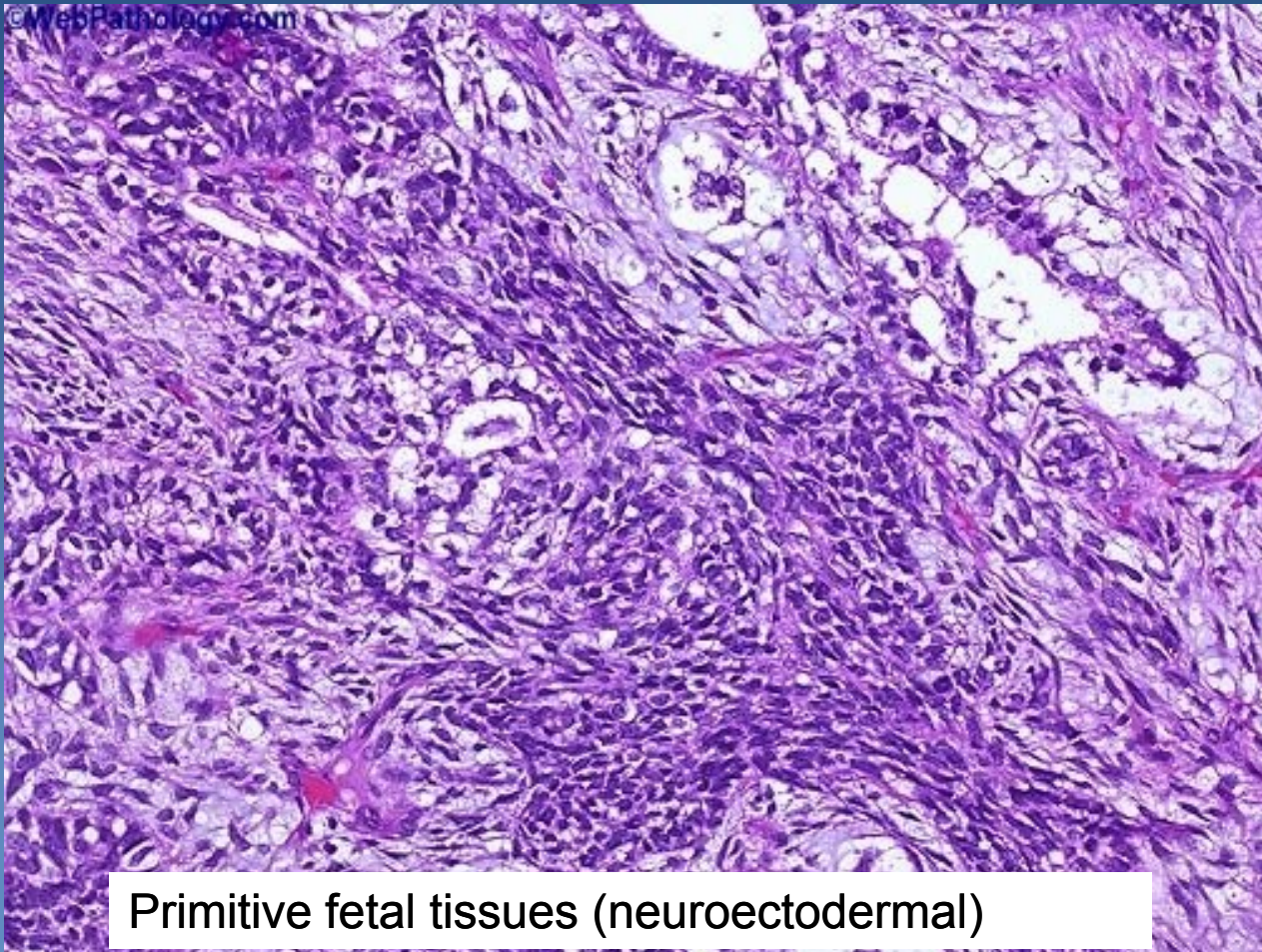
- 1 cyst with keratin
- 2 epidermis
- 3 skin adnexa
- 4 fat tissue

Differentiated mature teratoma



- 1 nervous tissue
- 2 compact lamellar bone
- 3 bone marrow
- 4 cartilage
- 5 striated muscle

Differentiated immature teratoma



Primitive fetal tissues (neuroectodermal)

Extragenadal germ cell tumors (EGT)



- ✗ primary germ cell tumors arising in extragonadal localisation

- ✗ more common in males

- ✗ origin unclear:
 - ⇒ *from primordial germ cells?*
 - ⇒ *faulty migration?*
 - ⇒ *faulty localisation of totipotent cells?*
 - ⇒ *ectopic germ cells in healthy people?*

Extragenital germ cell tumors (EGT)



✗ localisation:

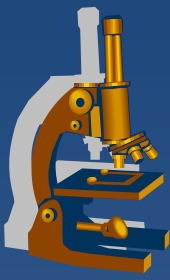
⇒ *in midline structures (pathway of germ cells descensus into gonadal blastema):*

- brain (pineal, suprasellar) sacrococcygeal, anterior mediastinum, retroperitoneum,..., thymus, prostate, stomach,.....

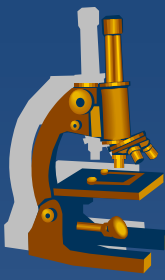
✗ seminomas, non-seminomatous

✗ pure or mixed

✗ general prognosis worse, except EGT seminoma



Female genital system pathology



- x vulva**
- x vagina**
- x exocervix, endocervix**
- x uterine body**
 - ⇒ *endometrium*
 - ⇒ *myometrium*
- x fallopian tubes**
- x ovaries**

Pathology



- ⇒ *inborn defects*
- ⇒ *circulatory disorders*
- ⇒ ***inflammations***
- ⇒ ***tumors***



Vulva

Vulvar neoplasia



x condyloma accuminatum

⇒ *low-risk HPV (6, 11)*

⇒ *squamous cell papilloma with koilocytar epithelial transformation*

x vulvar intraepithelial neoplasia - VIN

⇒ *high-risk HPV (16)*

⇒ *VIN II, III –high risk of progression into SCC*

x carcinoma

⇒ *squamous ca (90 %)*

- **precursor lesions:**

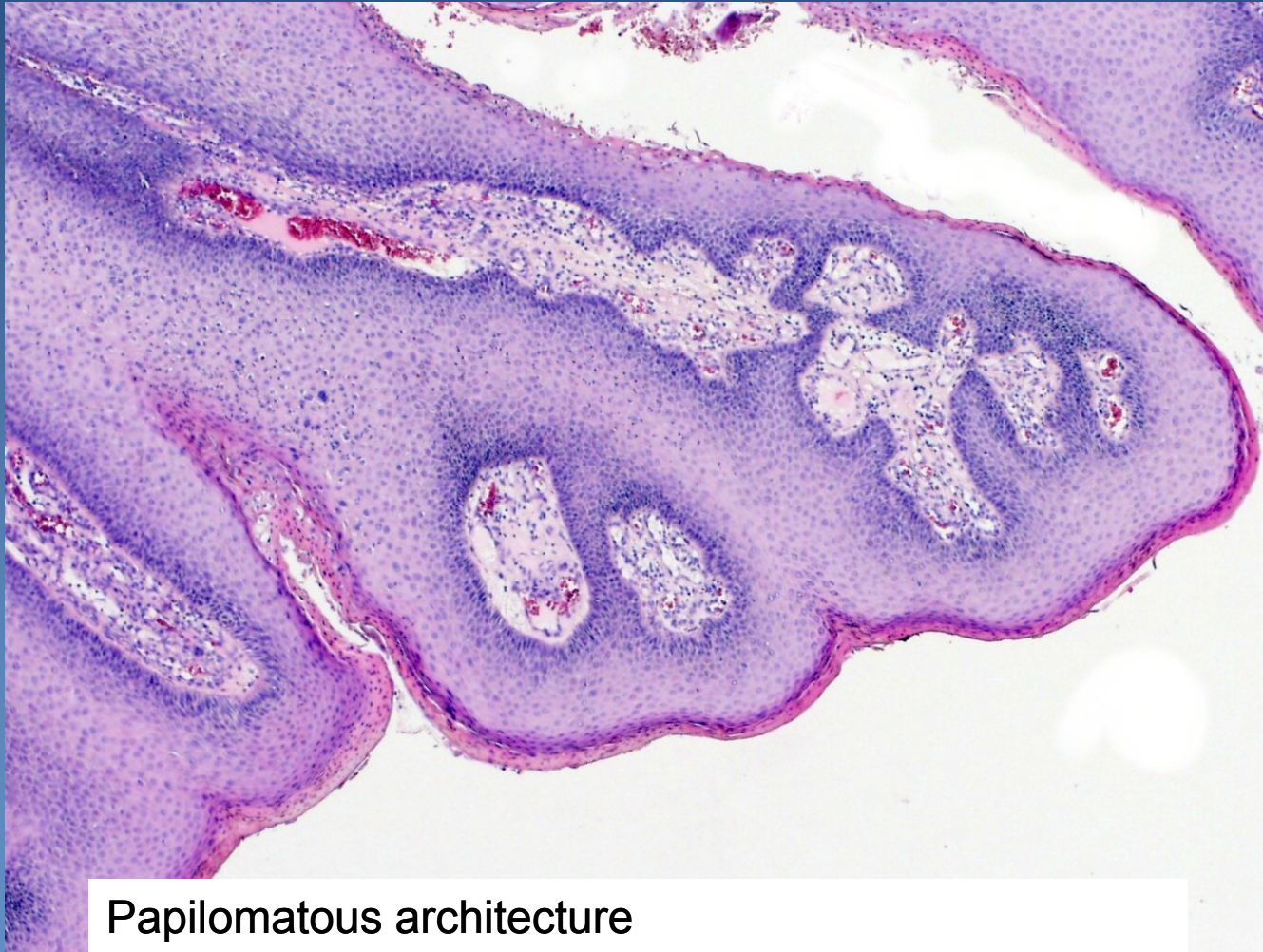- VIN II, III

- lichen sclerosus (in older females)

⇒ *adenocarcinoma, basal cell carcinoma*

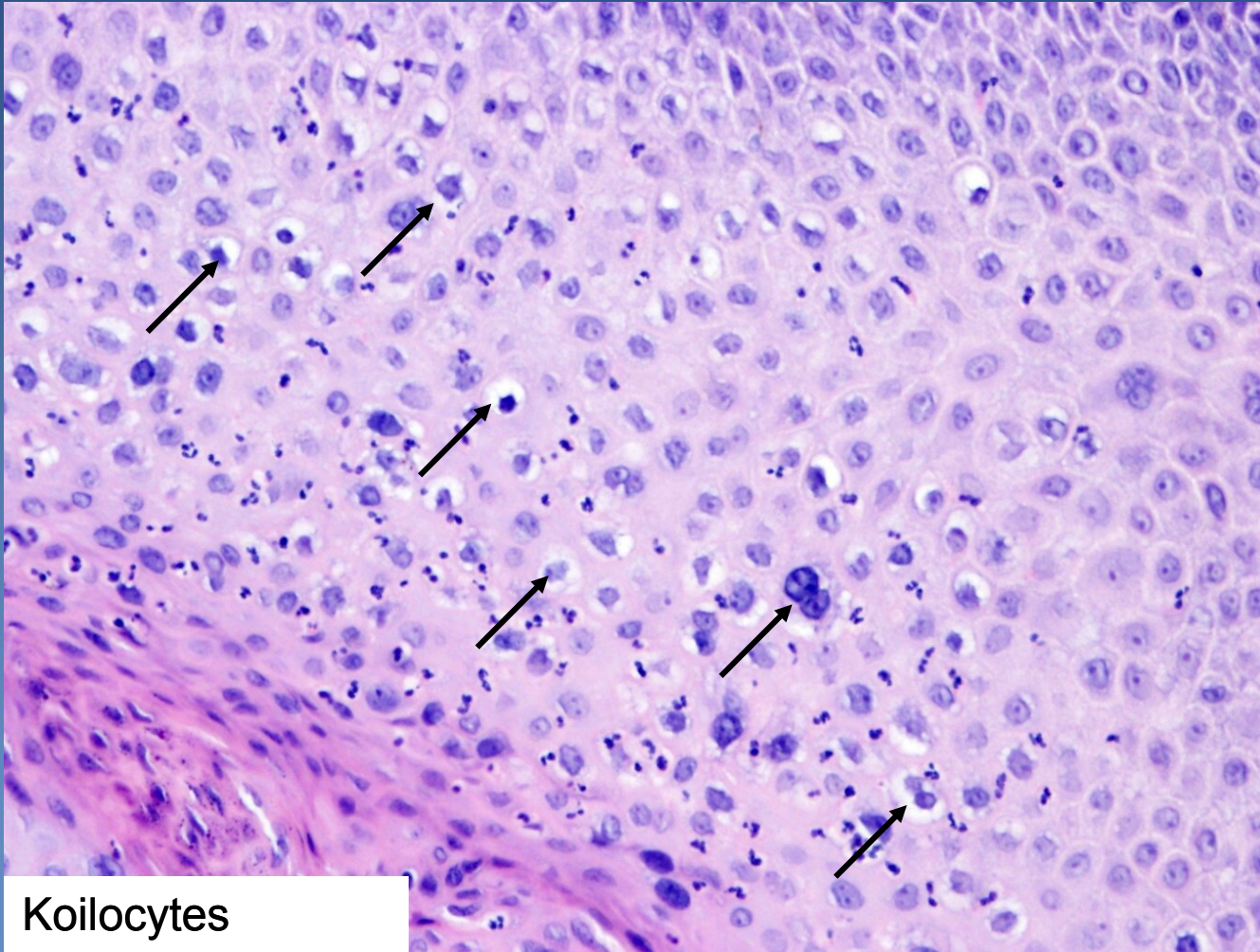
x malignant melanoma

Condyloma accuminatum



Papillomatous architecture

Condyloma accuminatum

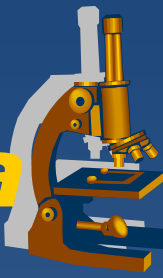


Koilocytes
(arrows)



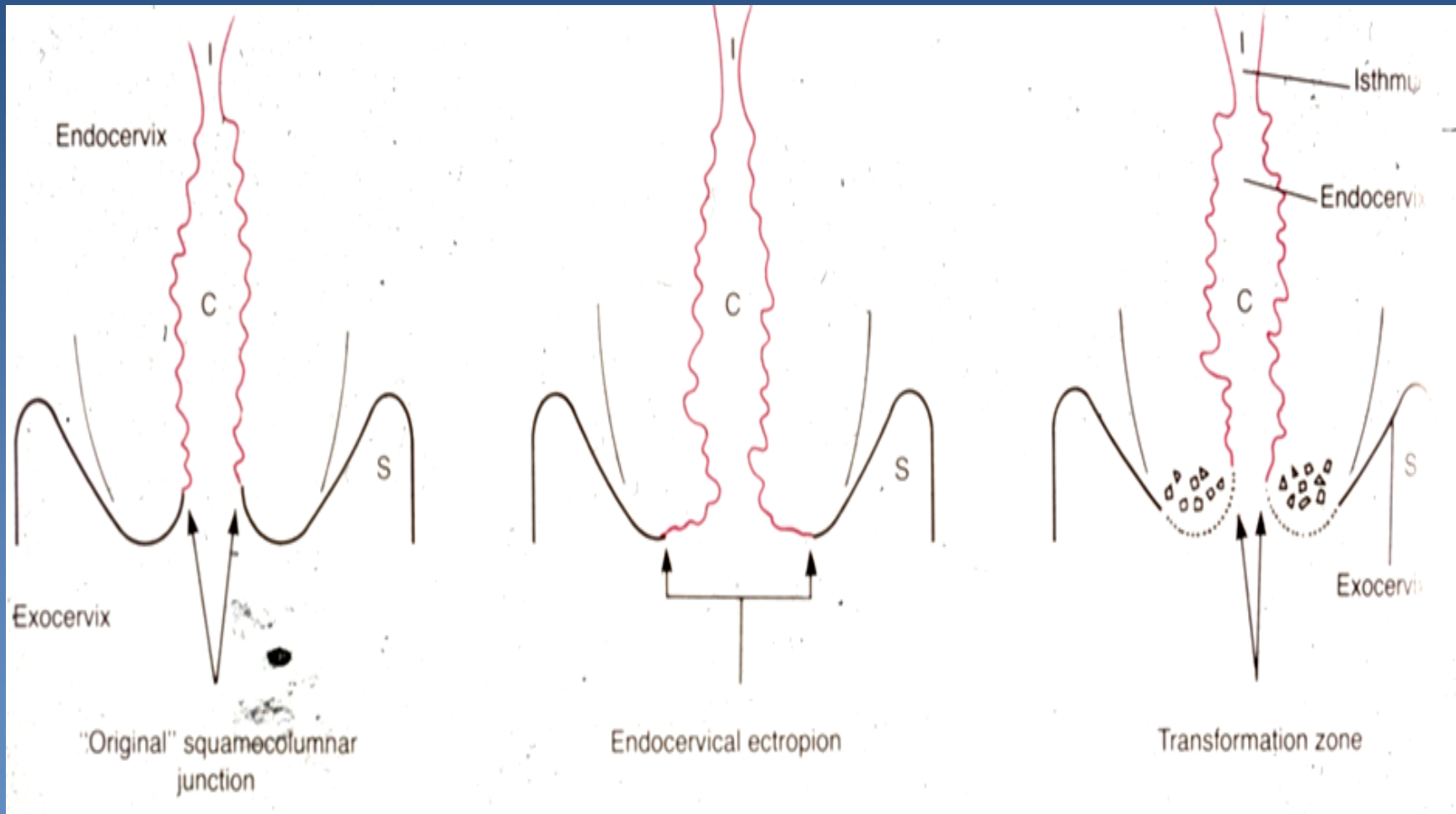
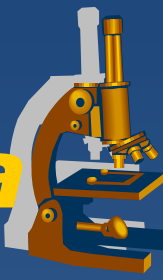Cervix (endocervix, exocervix)

Cervical squamous metaplasia

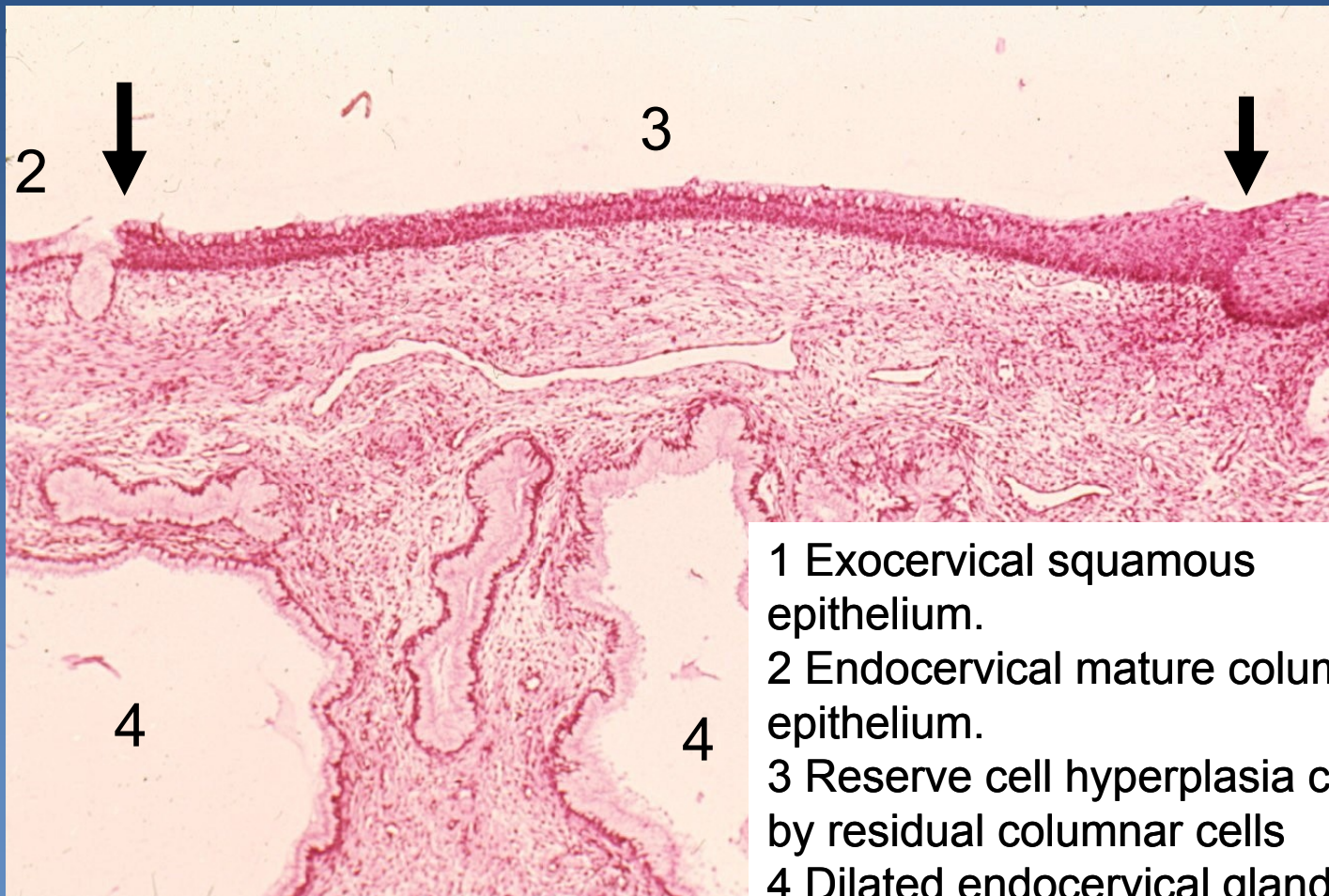
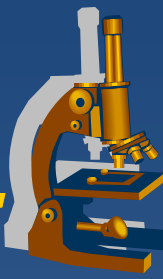


- ✘ transformation zone (squamo-columnar junction)
 - ⇒ *eversion of columnar epithelium into vagina (ectopy, ectropium)*
 - ⇒ *reserve cell hyperplasia → immature squamous metaplasia → mature metaplasia*
- ✘ closure of endocervical glands by overgrowth of squamous epithelium → *ovulation (cystic dilatation of the glands)*

Cervical squamous metaplasia



Squamous metaplasia, ovulosis.



- 1 Exocervical squamous epithelium.
- 2 Endocervical mature columnar epithelium.
- 3 Reserve cell hyperplasia covered by residual columnar cells
- 4 Dilated endocervical glands

Cervical preneoplastic changes + intraepithelial lesion



- ✘ LR (low-risk) HPV (6,11) →→→ *koilocytic atypia* of squamous cells
 - ⇒ *replication + cytopathic viral effect, productive infection*
 - ⇒ *nuclear atypia, cytoplasmic perinuclear halo*
- ✘ Cervical dysplasia – intraepithelial neoplasia associated with **HR (high-risk) HPV**:
 - ⇒ **HR HPV**:
 - 16, 18, 31, 33, 35
 - ⇒ *deregulation of the cell cycle, ↑ proliferation, ↓ or arrested maturation*

Cervical preneoplastic changes



x risk factors

⇒ HPV

- early sexual activity (<16 years of age)
- number of sexual partners

⇒ other STD (HSV, chlamydia)

⇒ cigarette smoking

⇒ early age of first pregnancy

⇒ combined oral contraceptives

⇒ immunosuppression

Cervical intraepithelial neoplasia



× Older classification

⇒ *CIN I (mild dysplasia):*

- koilocytic atypia + changes in the lower third of epithelium:
 - anisokaryosis
 - nuclear enlargement, hyperchromasia
 - loss of cell polarity
 - nuclear superposition

⇒ *CIN II (moderate dysplasia):*

- changes in the lower 2/3 of epithelial thickness, progressive atypia, expansion of the immature basal cells

⇒ *CIN III (severe dysplasia):*

- changes in the whole epithelium, diffuse atypia, almost complete loss of maturation

Cervical intraepithelial lesion



✘ 2 categories, according to the risk of progression and clinical management:

⇒ ***LSIL (low-grade squamous intraepithelial lesion)***

= ***CIN I, exophytic or flat condylomatous lesion***

- mostly self-limited (viral clearance), productive infection, lower rate of progression

⇒ ***HSIL (high-grade squamous intraepithelial lesion)***

= ***CIN II/III + ca in situ***

- majority persists or progresses to carcinoma

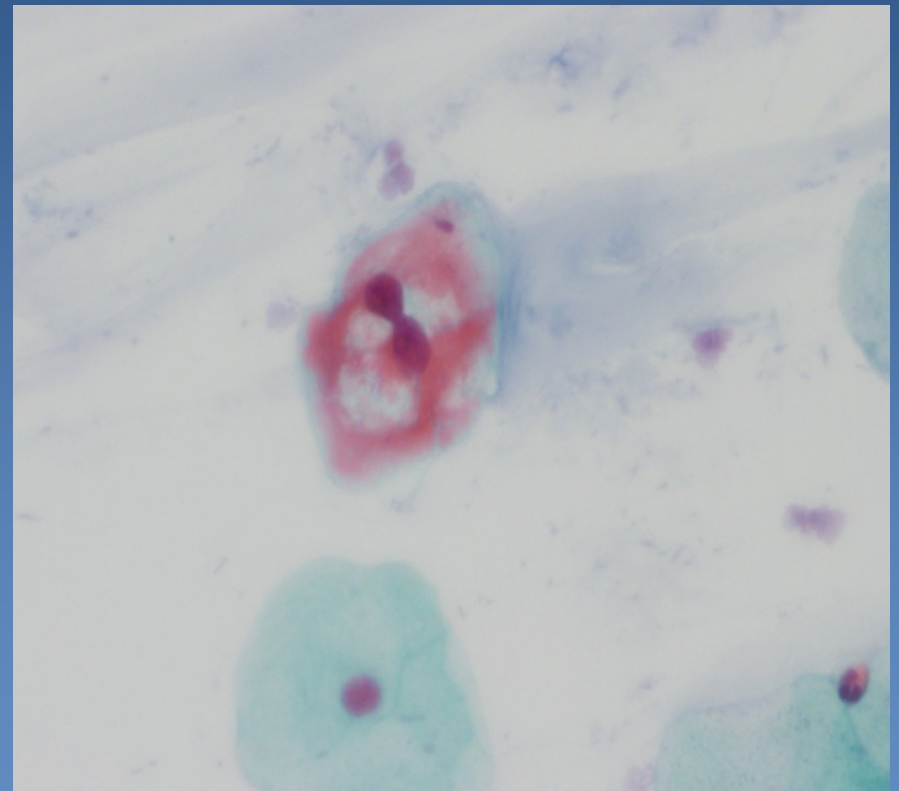
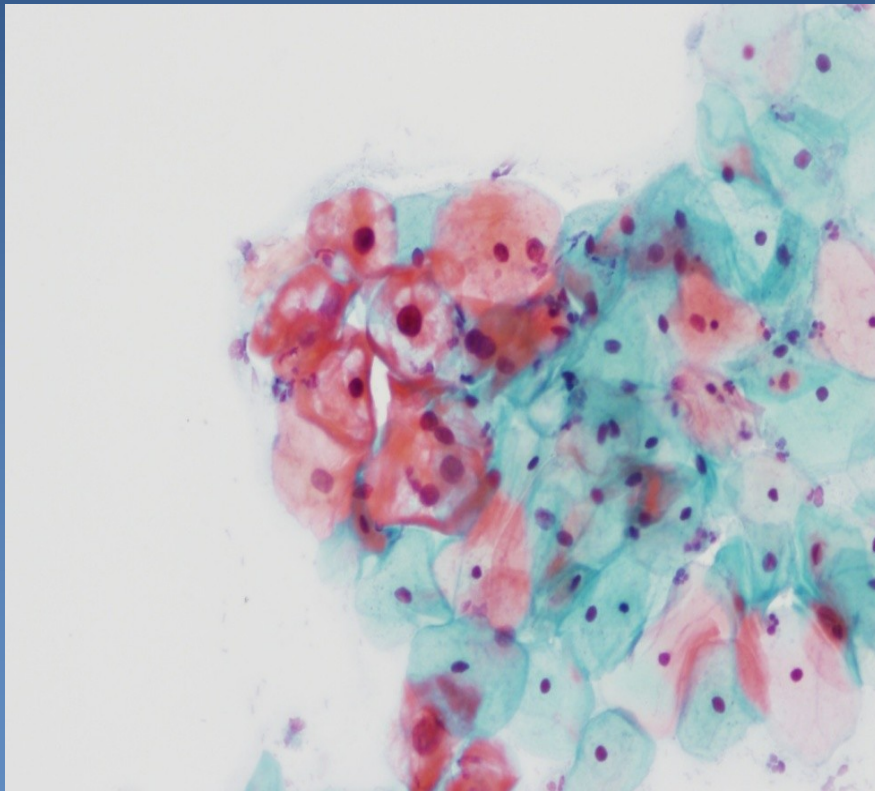
Cervical cytology: LSIL



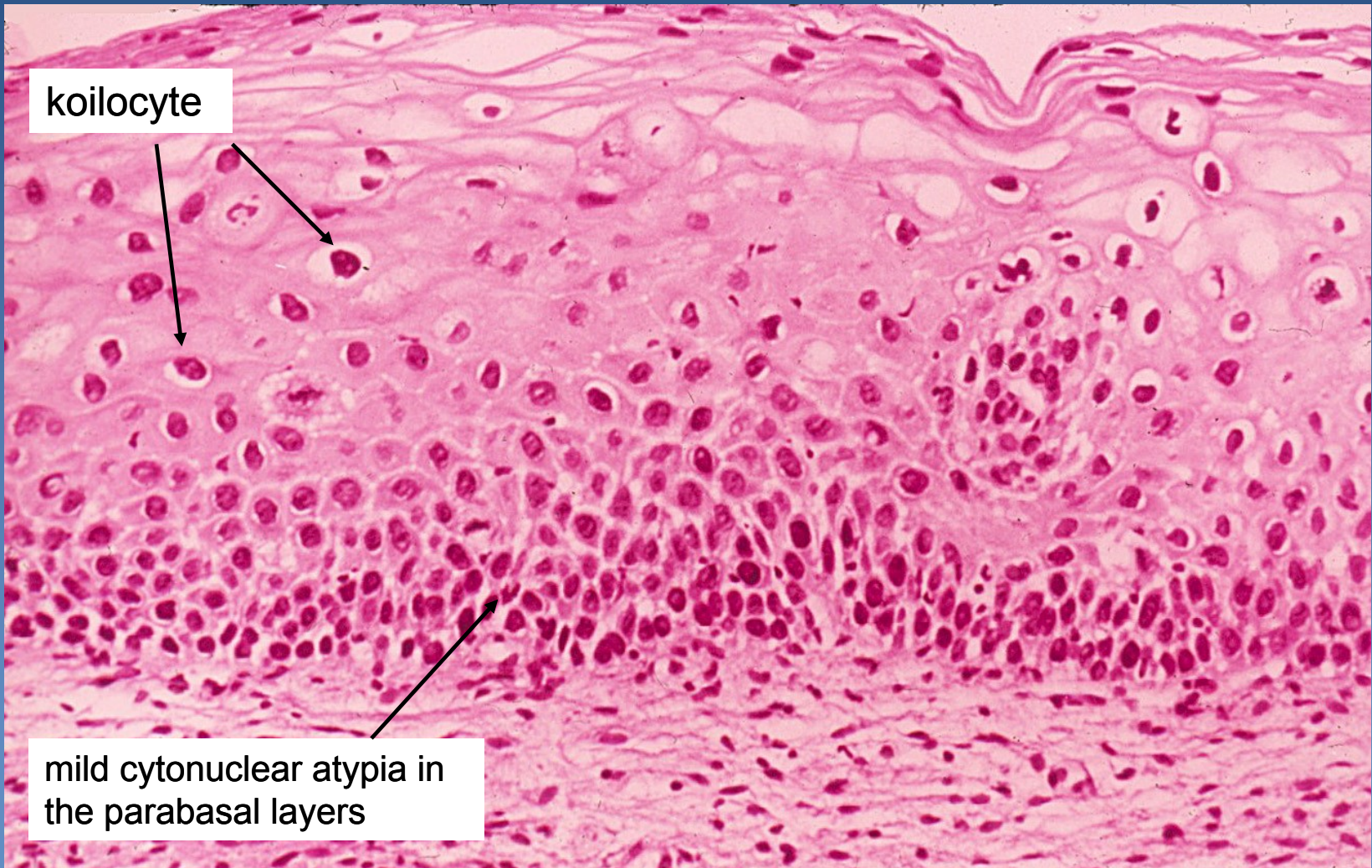
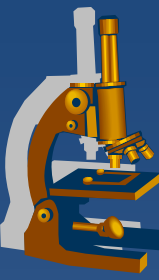
screening of cervical carcinoma

cytology (Bethesda System) + colposcopy

koilocytes with dyskaryotic nuclei



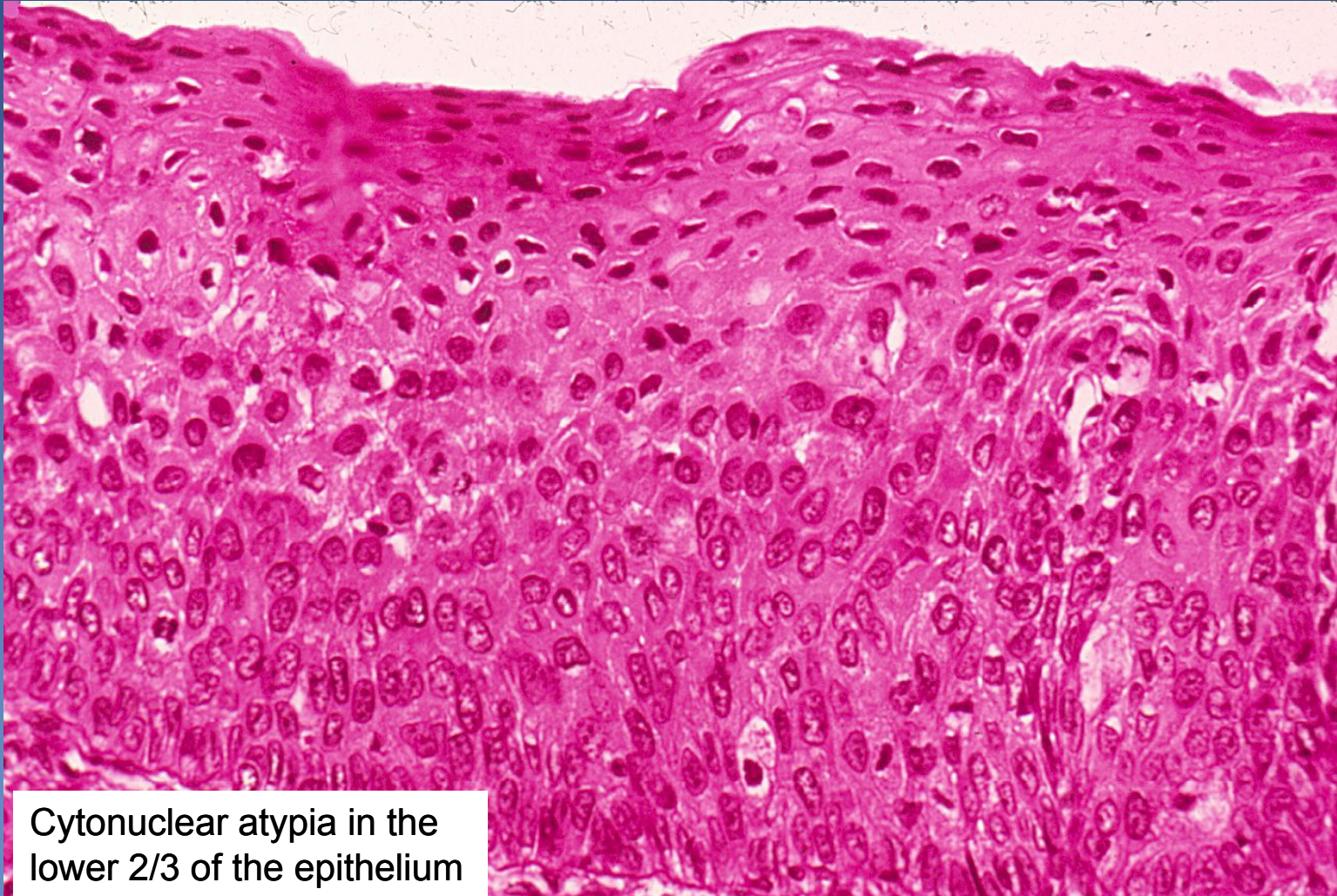Cervical intraepithelial lesion LSIL (CIN I)



koilocyte

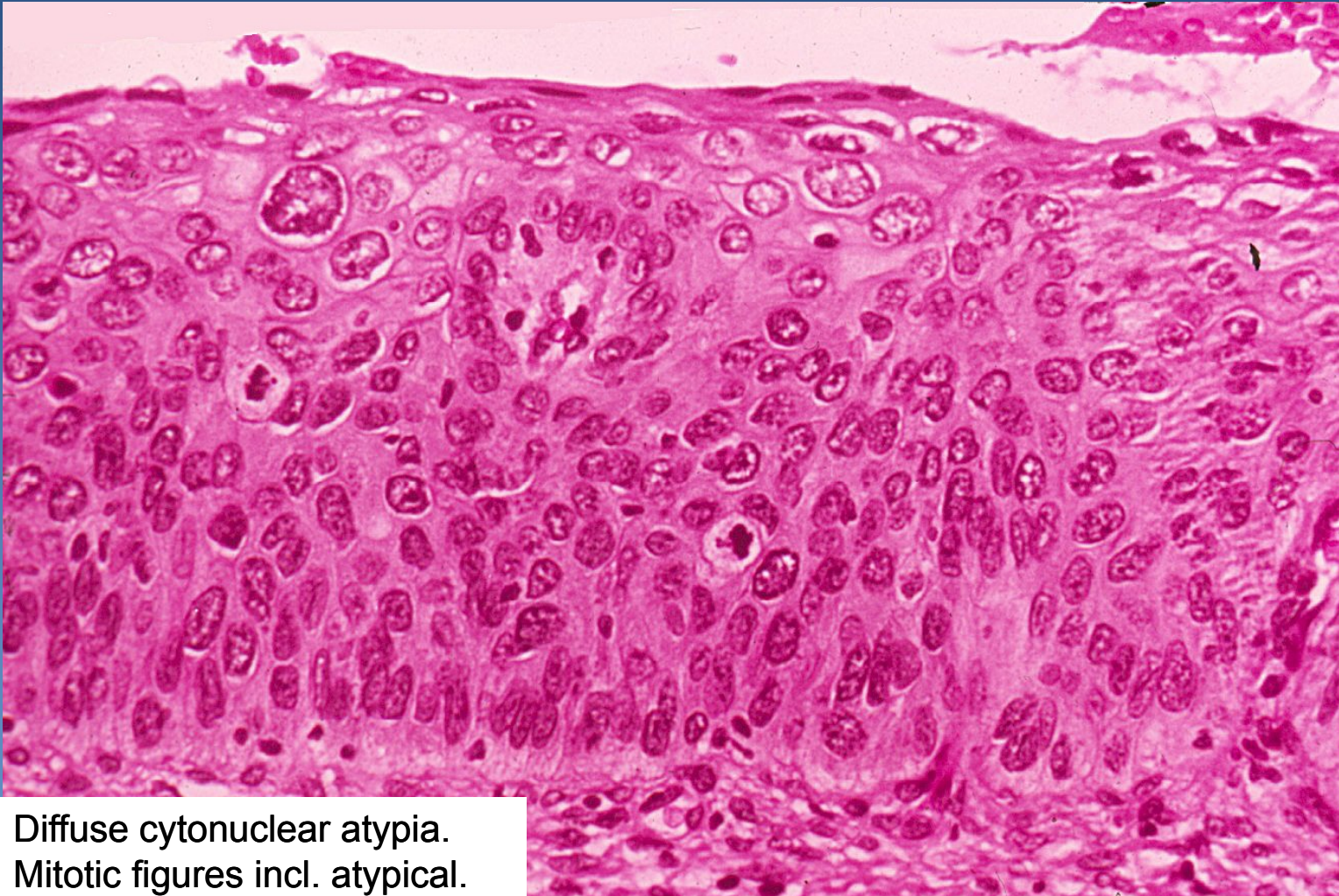
mild cytonuclear atypia in
the parabasal layers

Cervical intraepithelial lesion HSIL (CIN II)



Cytonuclear atypia in the lower 2/3 of the epithelium

Cervical intraepithelial lesion HSIL (CIN III)

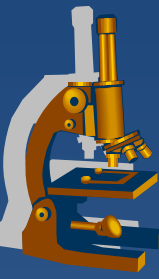


Diffuse cytonuclear atypia.
Mitotic figures incl. atypical.

Invasive cervical squamous cell carcinoma



- ✘ almost always by HSIL progression
- ✘ mostly starts in the transformation zone
- ✘ growth:
 - ⇒ *local progression*
 - size + depth of the invasive component
 - direct invasion into adjacent organs, fistulae
 - regional LN metastases
 - ⇒ *distant metastases via blood (lung, liver, bone marrow)*
- ✘ ↑ incidence, but mostly lower stages (if screened), ↓ mortality



Other cervical carcinomas

- x Adenocarcinoma**

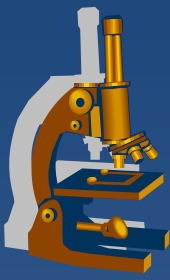
 - ⇒ *cervical glandular intraepithelial lesion*

 - ⇒ *adenocarcinoma in situ*

 - ⇒ *! diff. dg. x endometrial ca*

- x Adenosquamous carcinoma**

- x Neuroendocrine cervical carcinoma**



Uterine corpus

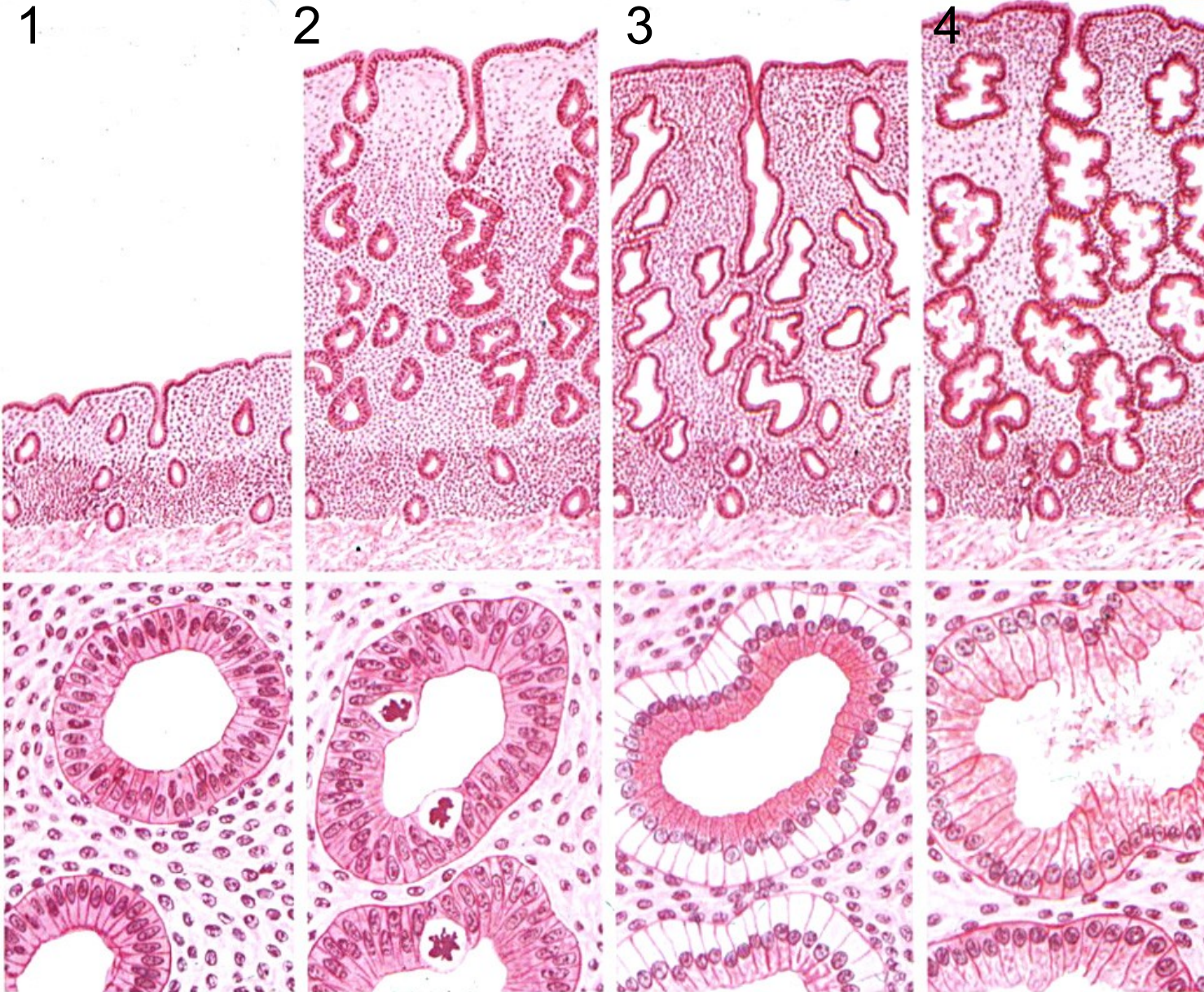
Endometriosis



- ✘ foci of functional endometrium (glands + stroma) in an ectopic localisation
 - ⇒ *ovaria, cavum Douglasi, fallopian tubes, peritoneum, bladder, umbilical skin, ... lung, bones ...)*
 - ⇒ *cyclical changes during MC*
 - haemorrhagic (chocolate) cysts, hemosiderin pigmentation
 - ⇒ *pain, pelvic inflammatory disease + adhesions, infertility*
 - ⇒ *possible source of endometrioid adenocarcinoma*

- ⇒ *adenomyosis:*
 - endometrial diverticula (outpouching of basalis into myometrium, mostly no functional hormonal changes)

Endometrium, menstrual cycle



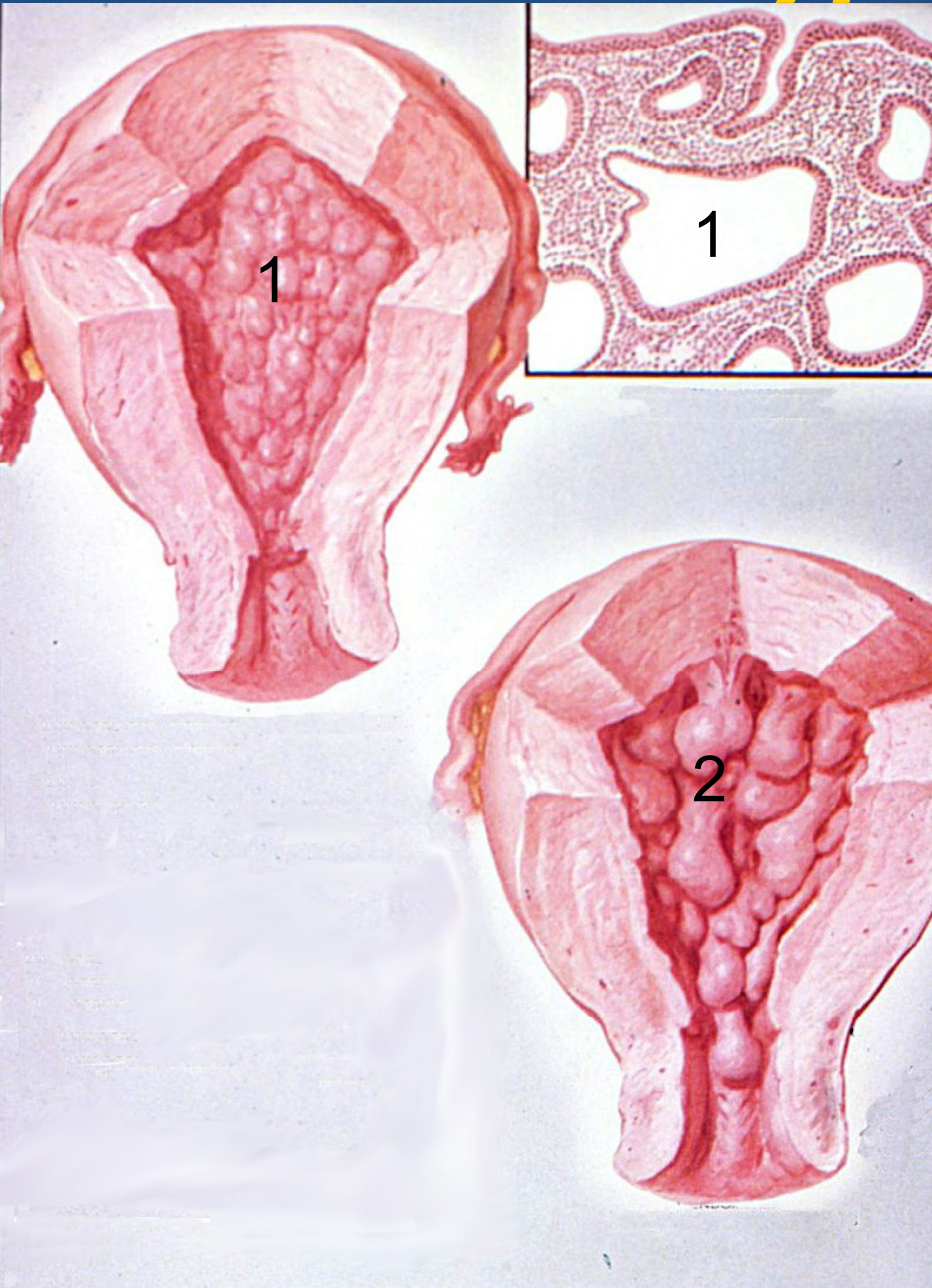
- 1 Early proliferation
- 2 Late proliferation
- 3 Early secretion
- 4 Late secretion

Endometrial hyperplasia



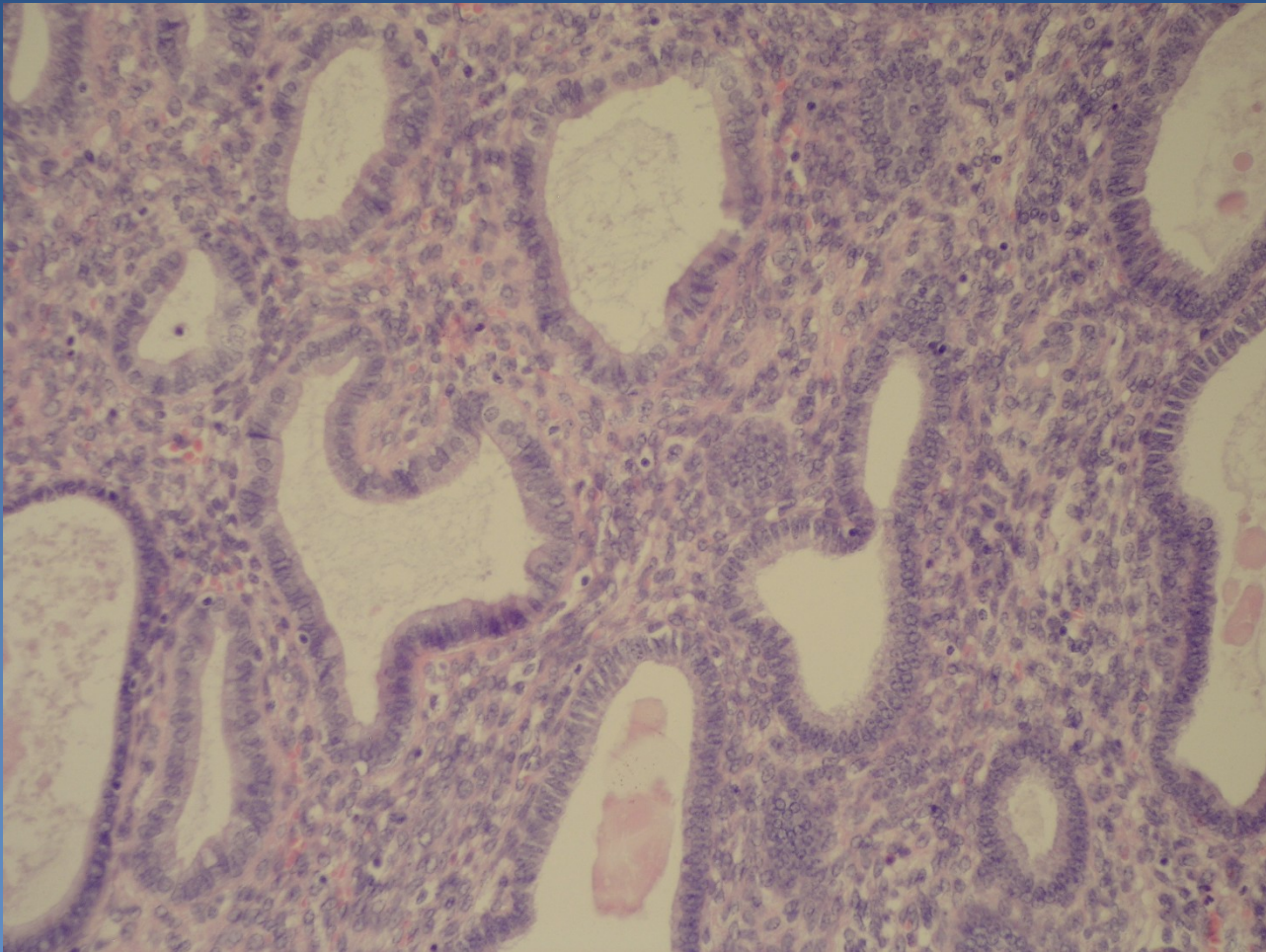
- × **increased glandular proliferation** - ↑ gland-to-stroma ratio
- × **classification according to architecture, cytological atypia**
- × **simple** – dilated irregular glands, epithelial stratification, „swiss cheese“
 - ⇒ **without atypia**, almost no progression to adenocarcinoma,
 - ⇒ **with atypia** → cytologic atypia present, low progression, rare
- × **complex** – irregular branching crowded glands, ↓ stroma (back-to-back)
 - ⇒ **without atypia**
 - ⇒ **with atypia** → **endometrial intraepithelial neoplasia EIN** (round nuclei + nucleoli) monoclonal – neoplastic – **high grade of progression**, commonly (1/4-1/2) concurrent ca present;

Endometrial hyperplasia



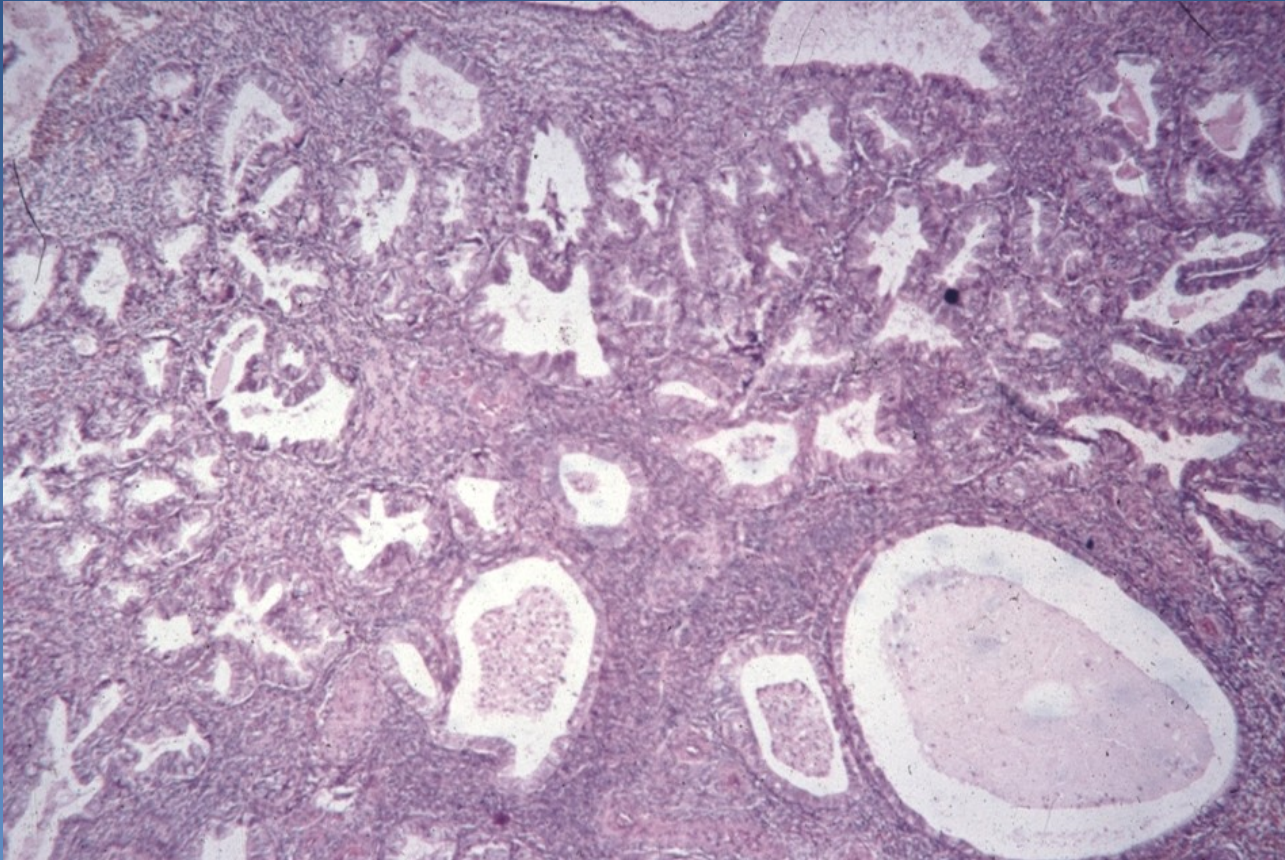
- 1 Endometrial hyperplasia
- 2 Polypous endometrial hyperplasia

Simple hyperplasia

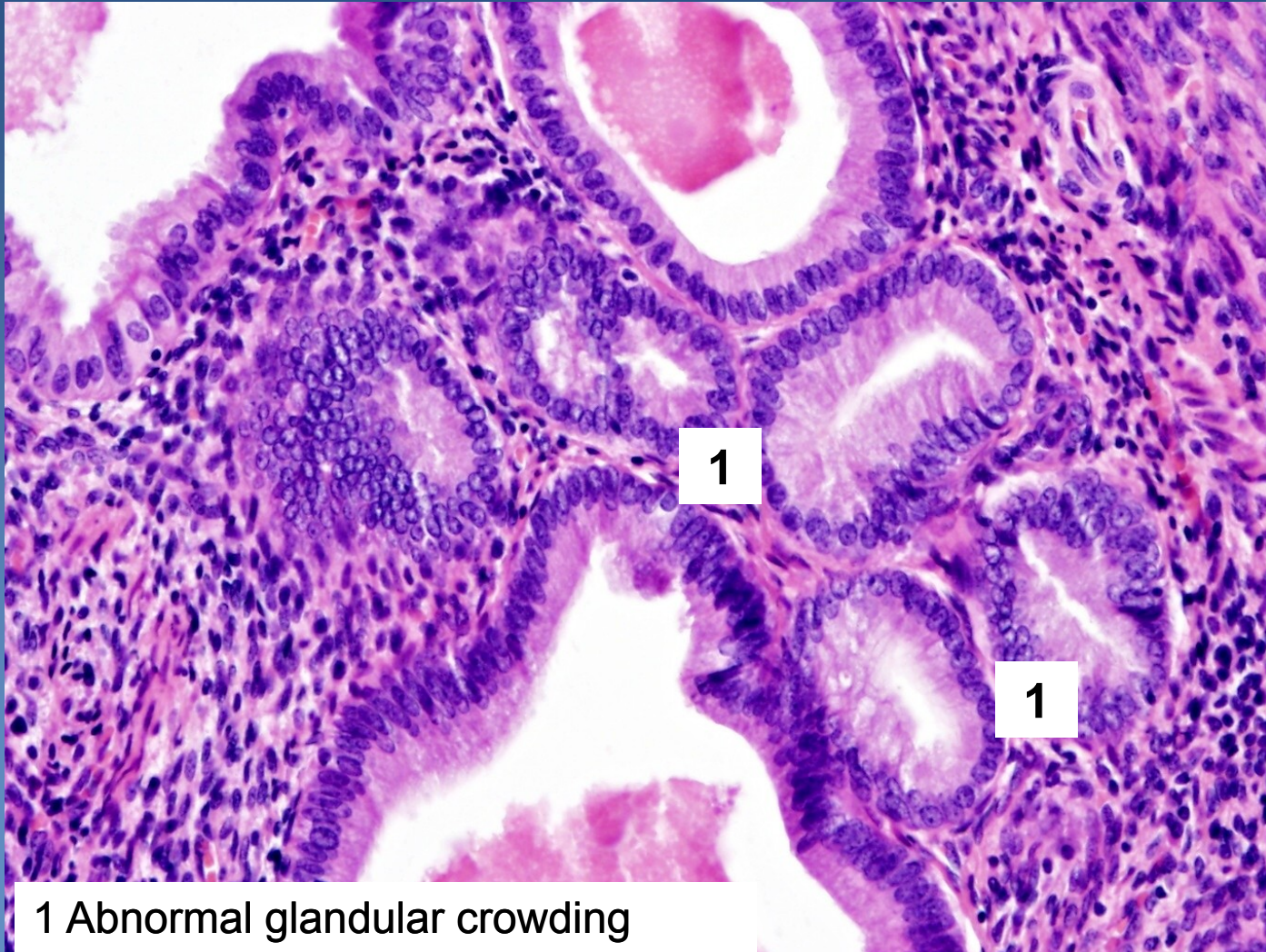


Cystic transformation of endometrial glands
Stromal hyperplasia

Complex hyperplasia

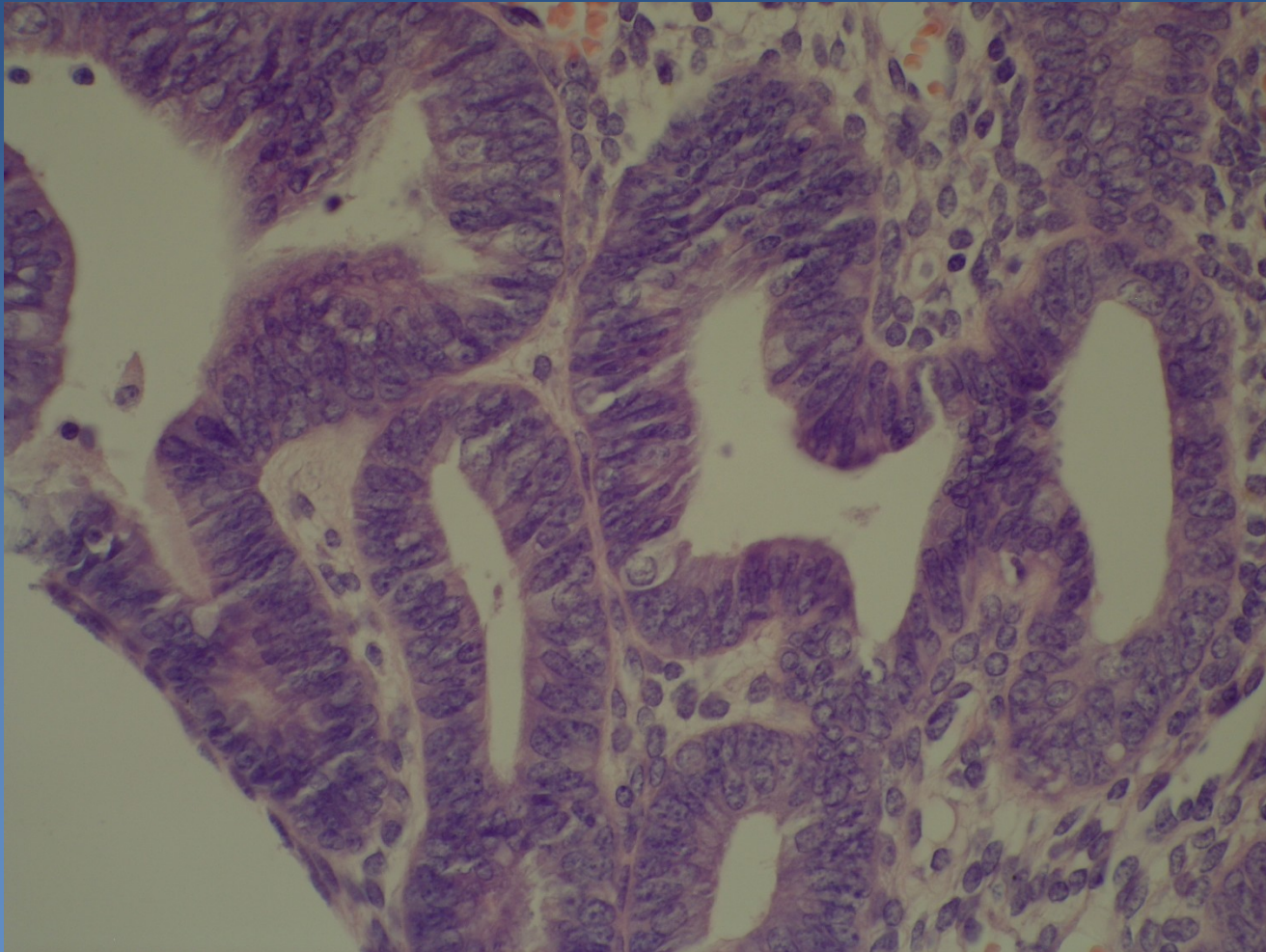


Complex hyperplasia



1 Abnormal glandular crowding

Complex hyperplasia with atypia



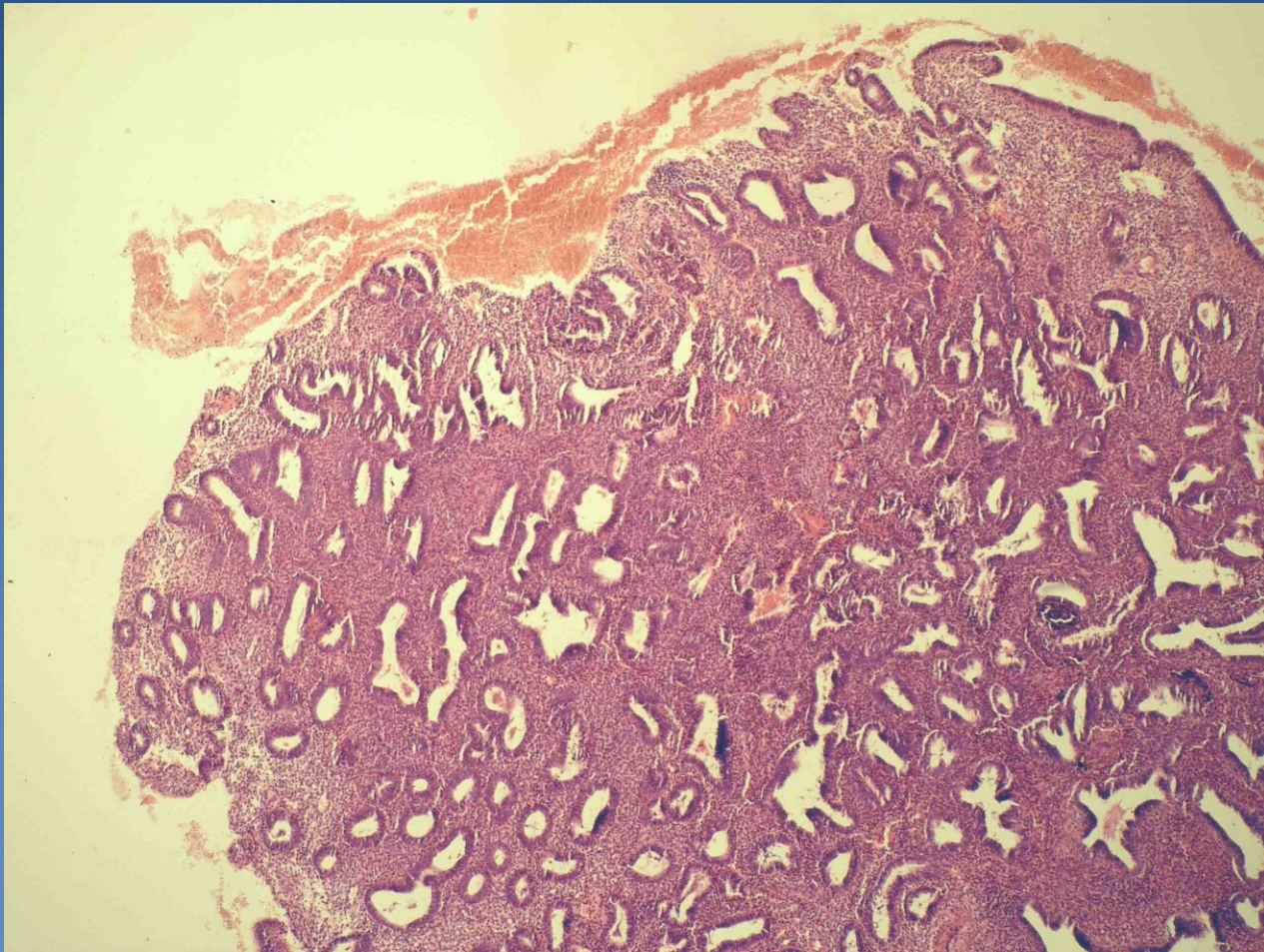
Stratification of epithelial cells, vesicular nuclei, visible nucleoli

Endometrial polyp

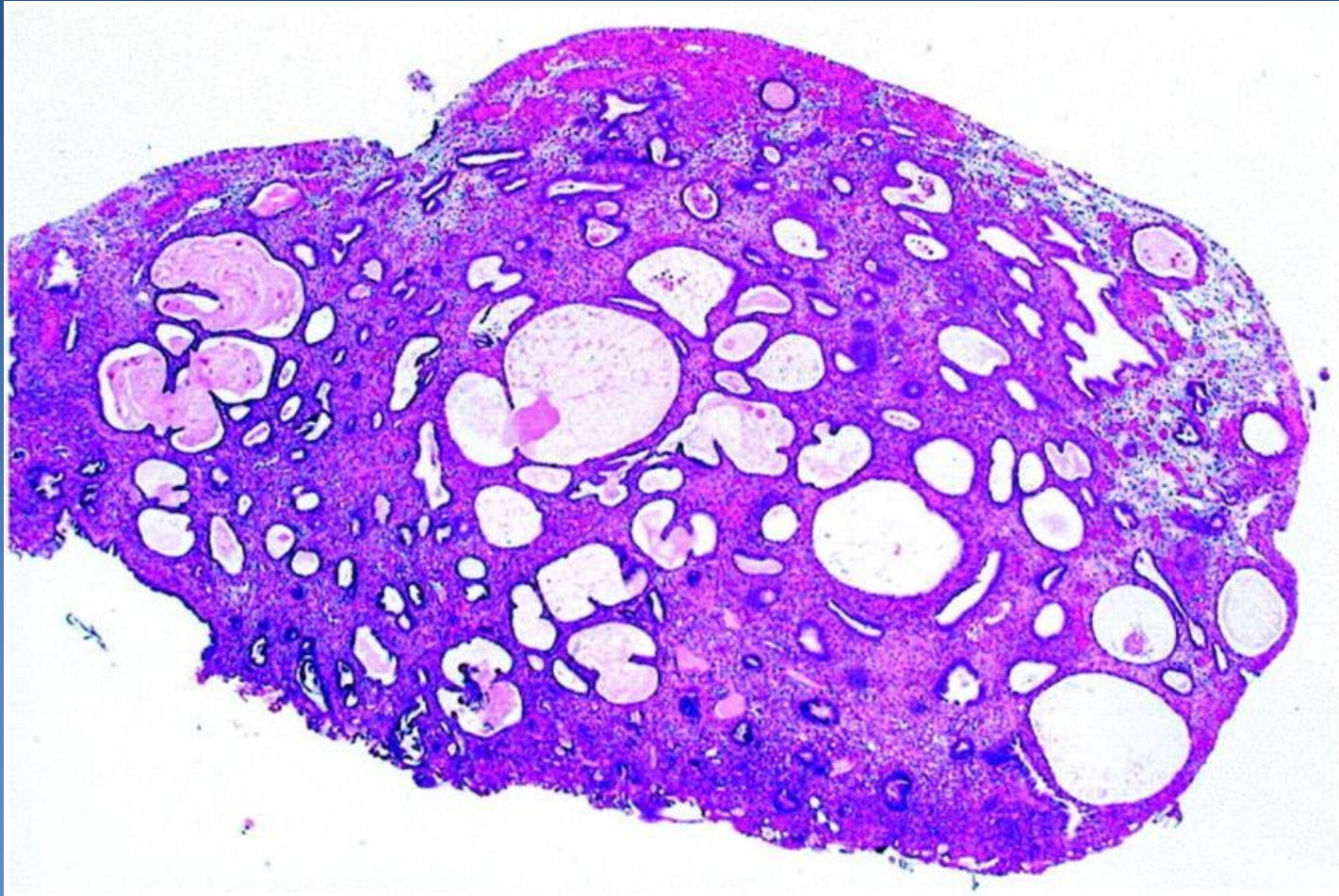


- ✘ sessile/pedunculated, solitary/multiple exophytic endometrial focus
 - ⇒ abnormal bleeding common
 - ⇒ functional/hyperplastic/atrophic endometrium
 - ⇒ stromal fibrosis, thick-walled arteries
 - ⇒ may be in association with endometrial hyperplasia, possible progression to atypical hyperplasia → adenocarcinoma

Endometrial polyp - hyperplastic



Endometrial polyp – cystic atrophic

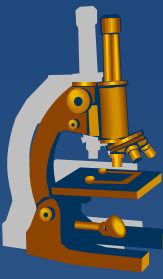


Endometrial adenocarcinoma



- ✗ Most common malignant tumor of female genital
 - ⇒ 2. cervical ca, 3. ovarian tumors
- ✗ **Abnormal bleeding**
- ✗ **type I: perimenopause**
 - ⇒ *Risk factors:*
 - ⇒ *unopposed estrogenic stimulation – endo-/exogenous*
 - ⇒ *DM, obesity, early menarche - late menopause*
 - ⇒ *precursor **atypical endometrial hyperplasia***
 - ⇒ *better prognosis, lymphatic spread possible*

Endometrial adenocarcinoma



✘ histologic forms:

⇒ *type I*

- **endometrioid adenocarcinoma**
- mucinous
- tubal (ciliated)
- squamous cell
- adenosquamous

Endometrial adenocarcinoma



x Type II

⇒ ***postmenopausal***

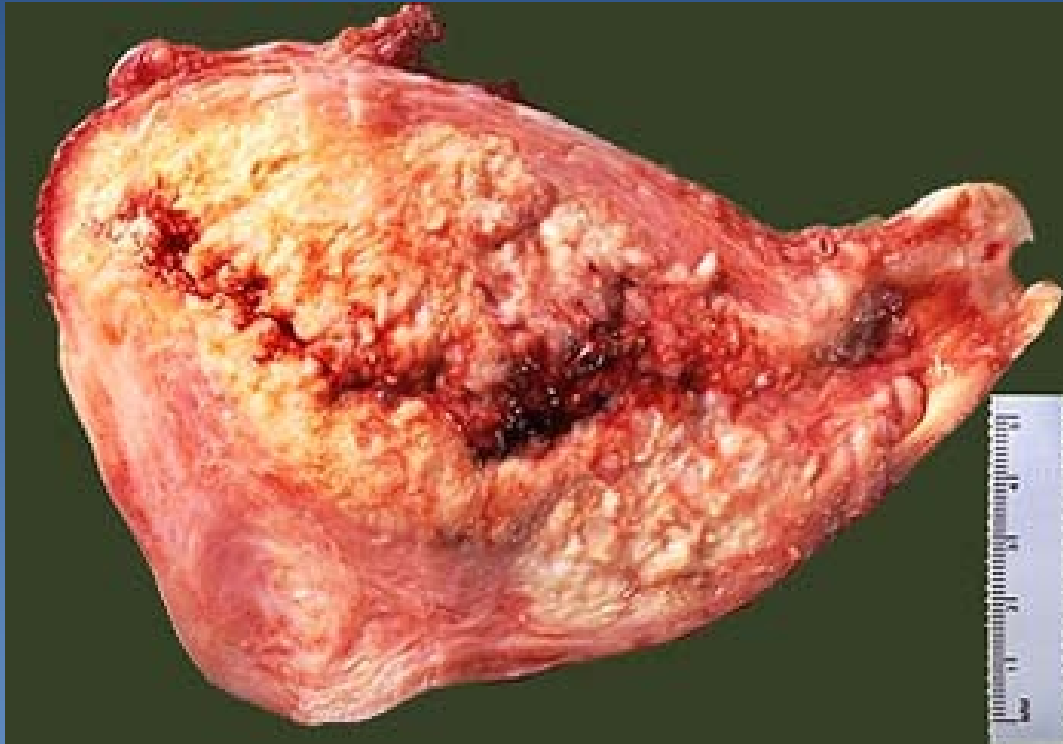⇒ ***without estrogenic stimulation, p53 mutation (→ aggressive; intraperitoneal, lymphatic spread)***

⇒ ***in the setting of atrophic endometrium***

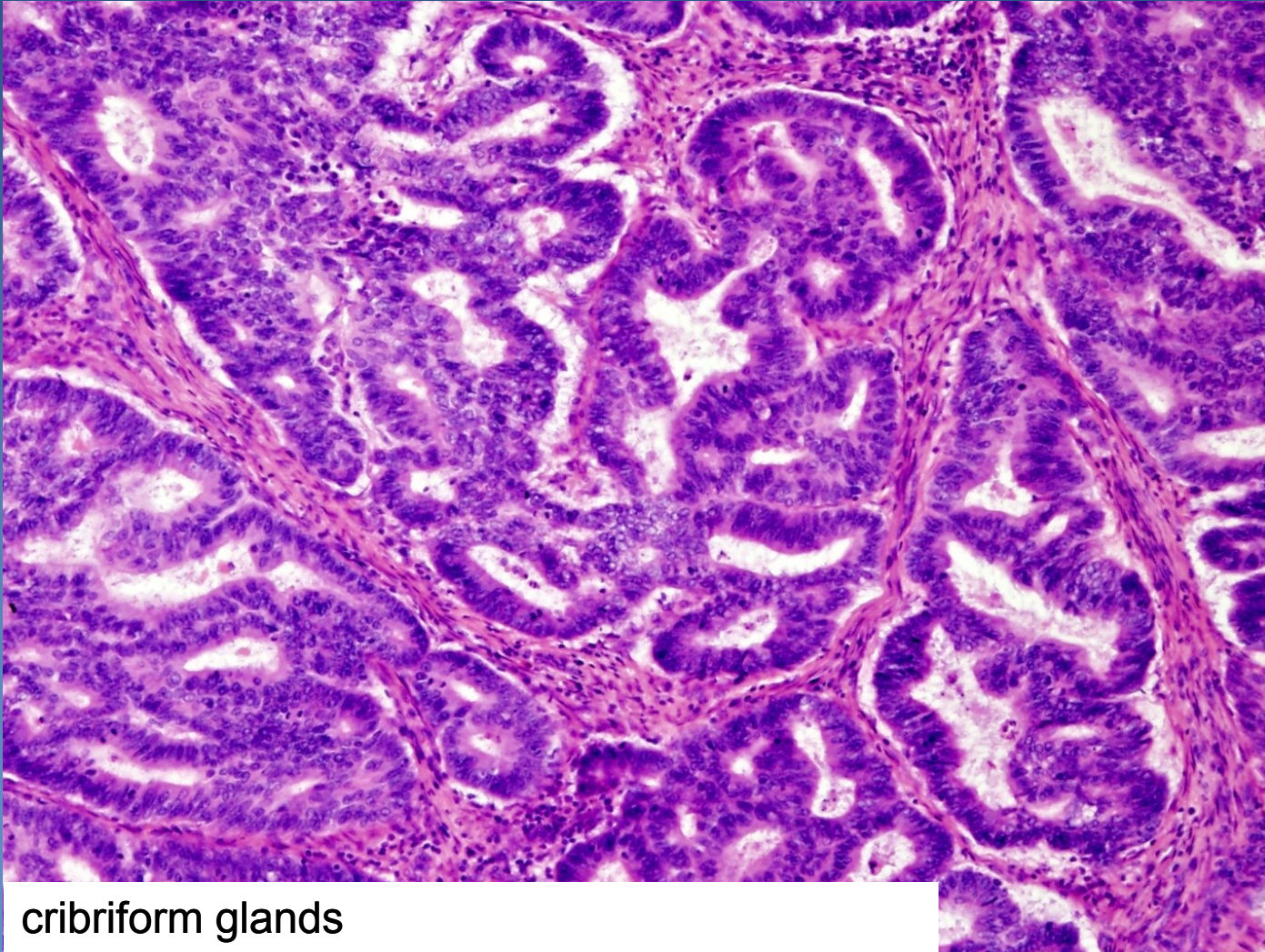
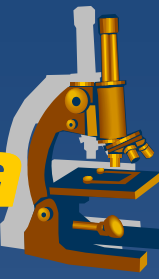
⇒ ***poorly differentiated (serous, clear cell)***

⇒ ***undifferentiated (metaplastic carcinoma)***

Endometrial adenocarcinoma

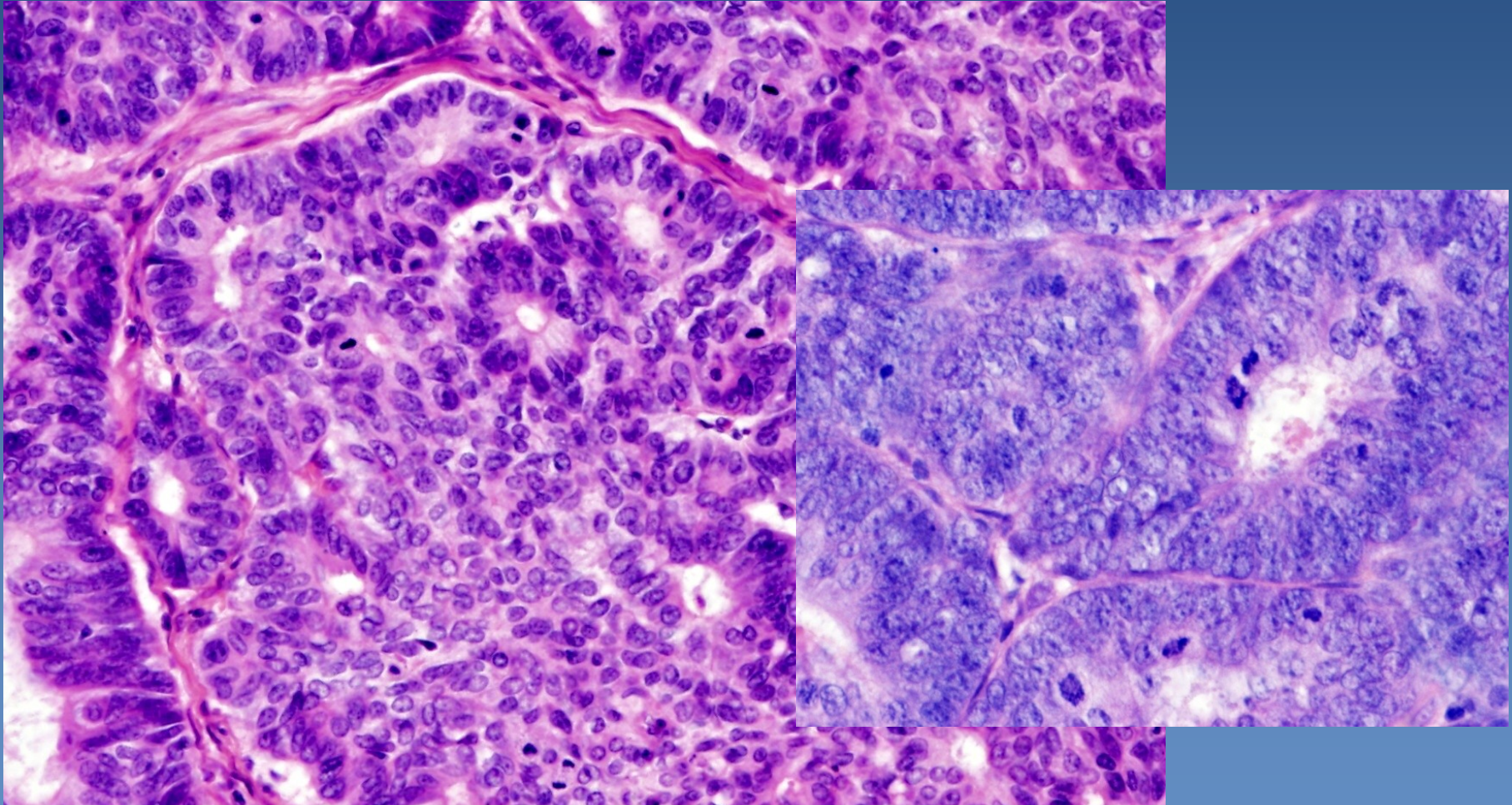
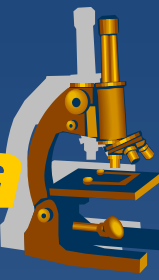


Endometrioid adenocarcinoma



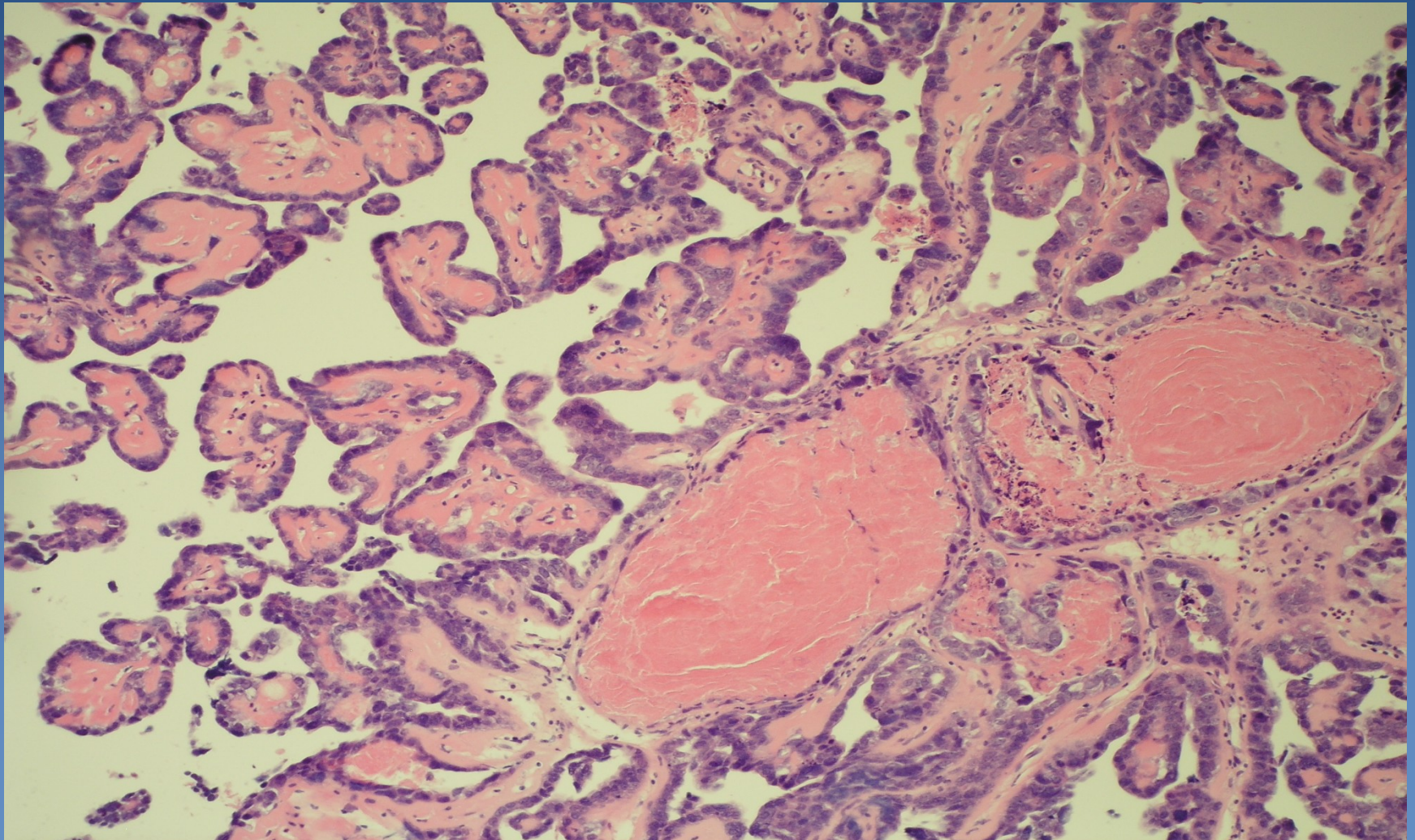
cribriform glands

Endometrioid adenocarcinoma



Epithelial stratification, cellular atypias, mitotic activity

Serous adenocarcinoma



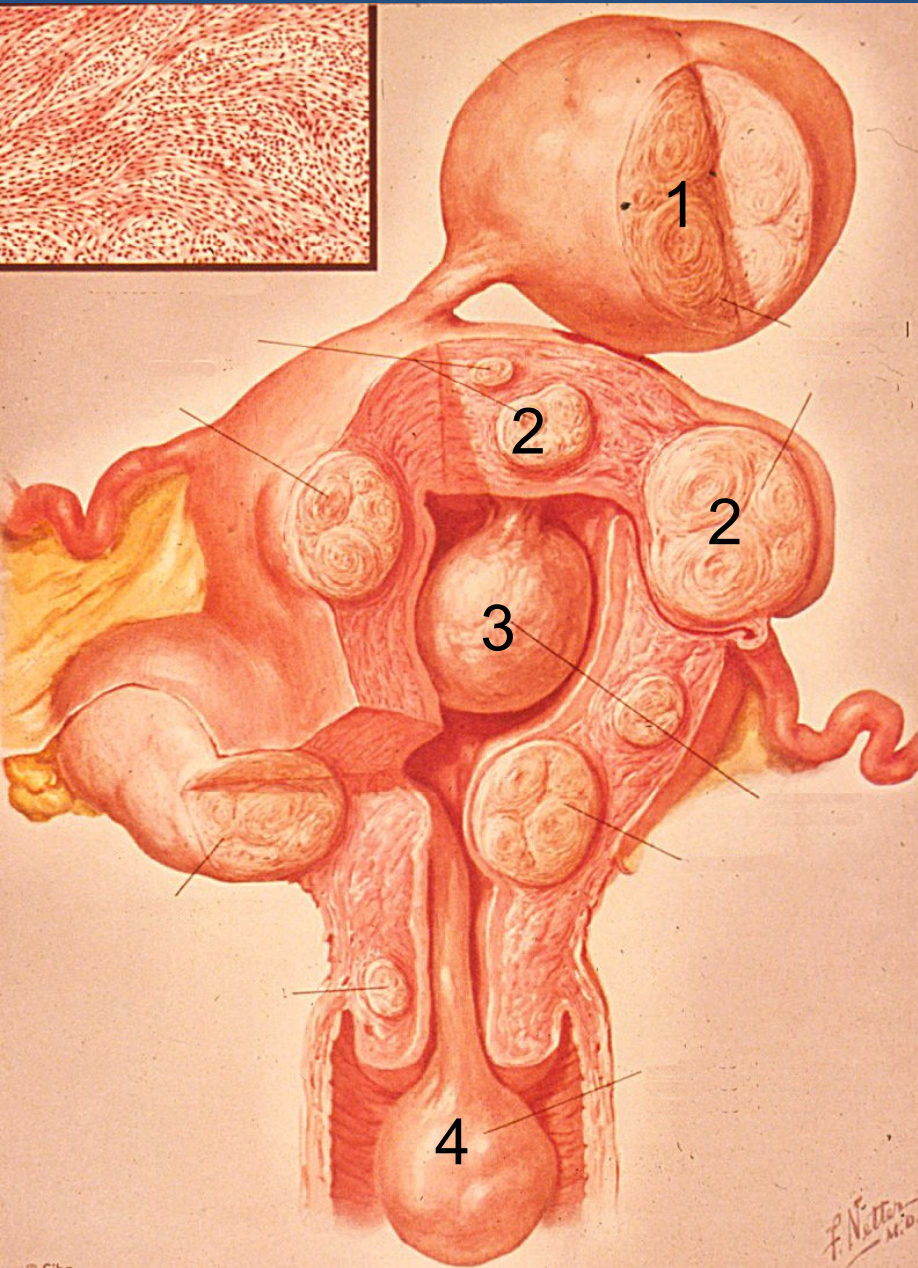
Mesenchymal tumors



x Leiomyoma

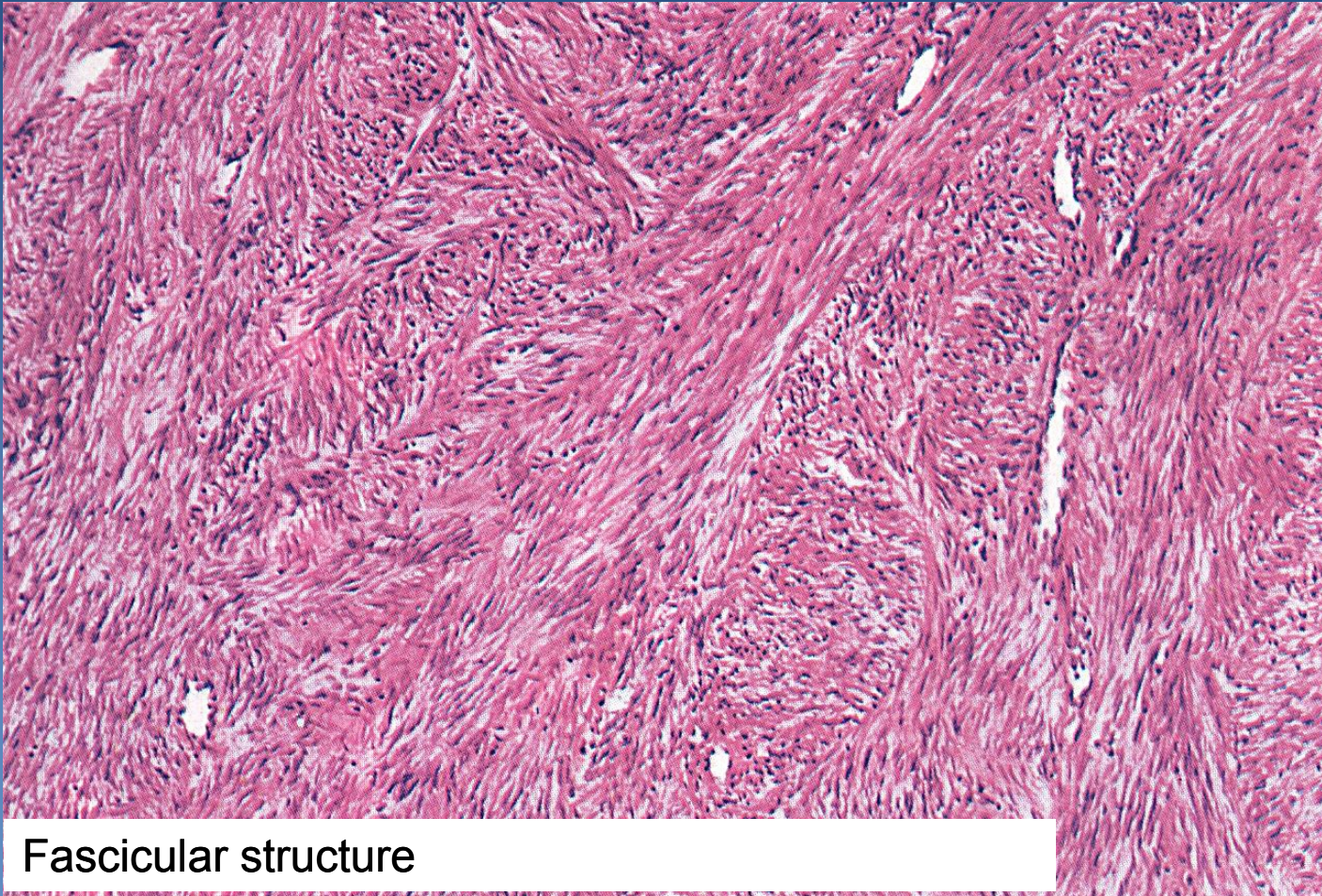
- ⇒ *most common benign female tumor (usual in later reproductive age)*
- ⇒ *size: mm - cca 20 cm*
- ⇒ *symptoms due to localisation/topography (bleeding, infertility, compression of adjacent organs)*
- ⇒ *uterus myomatosus (multiple leiomyomas)*
- ⇒ *common regressive changes (oedema, fibrosis, hyalinisation, calcification)*

Uterine leiomyomas



- 1 Subserous leiomyoma
- 2 Intramural myoma
- 3 Submucosal myoma
- 4 „Nascent“ submucosal myoma

Leiomyoma



Fascicular structure

Pathology of pregnancy

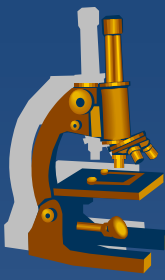


- ✗ ectopic pregnancy
- ✗ spontaneous abortion (placental disorders incl. placentation abnormalities, vascular lesions, inflammation – ascending, hematogenous; umbilical cord pathology)
- ✗ pre-eclampsia – systemic endothelial dysfunction; hypertension + oedema + proteinuria, hypercoagulative state; may → eclampsia (CNS – convulsion, coma)
- ✗ **Gestational trophoblastic disease**

Gestational trophoblastic disease



- x** proliferation of gestational trophoblast with progressive malignant potential or frankly malignant
- x** hydatidiform mole
 - ⇒ *partial, complete - benign;*
 - ⇒ *invasive – uncertain biol. potential*
 - ⇒ *from abnormal conception*
 - ⇒ *abnormal placenta with villous hydrops and variable degree of trophoblastic proliferation*
- x** trophoblastic tumors – choriocarcinoma, etc.



Gestational choriocarcinoma

- ✗ subsequent to molar pregnancy (50%), abortion (25%), normal gestation (22,5%), ectopic pregnancy (2,5%)
- ✗ atypical syncytio- and cytotrophoblast, no villi, minimal stroma, no angiogenesis; foci of haemorrhage, necrosis present
- ✗ early haematogenous spread (lung, vagina, brain, liver...)
- ✗ highly elevated HCG
- ✗ chemosensitive (x germ cell tumor – low response to therapy, bad prognosis)



Ovary

Ovarian cysts



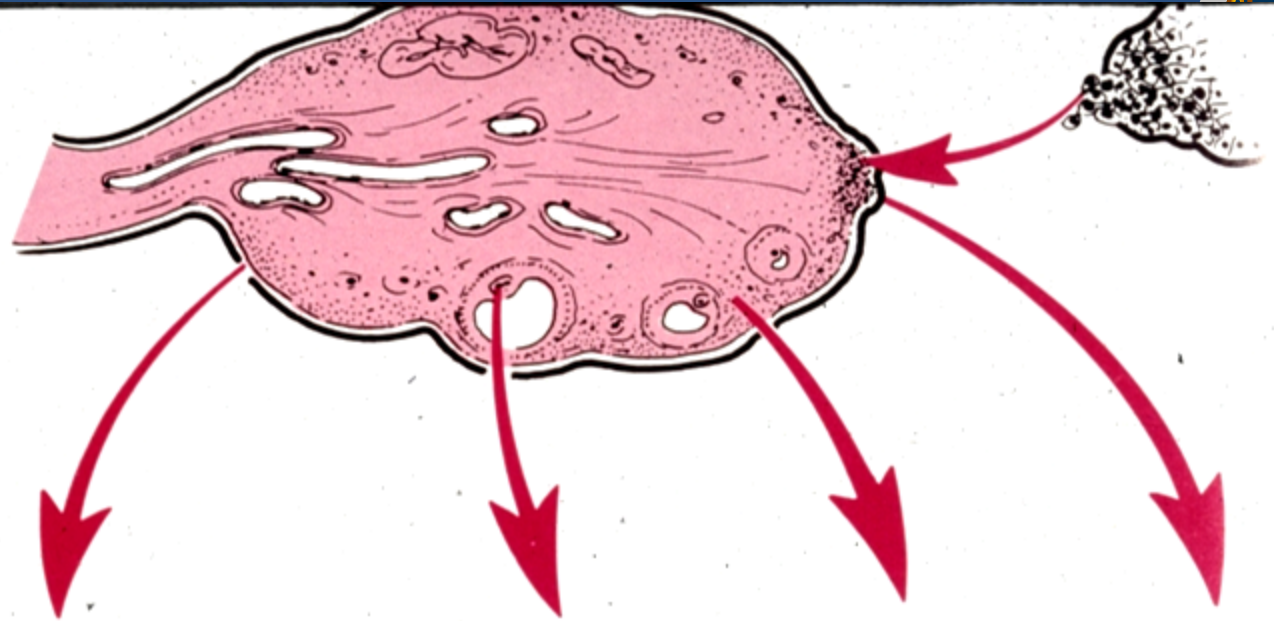
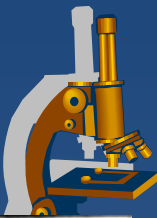
× non-neoplastic

- ⇒ inclusion c. (*mesothelial, epithelial*)
- ⇒ functional c. (*follicular, luteal, polycystic ovary syndrome, ovarian hyperstimulation syndrome*)
- ⇒ endometriosis

× neoplastic

- ⇒ surface epithelial tumors,
- ⇒ germ cell tumors
- ⇒ sex-cord stromal tumors
- ⇒ metastatic tumors
- ⇒ *others*

Ovarian tumors

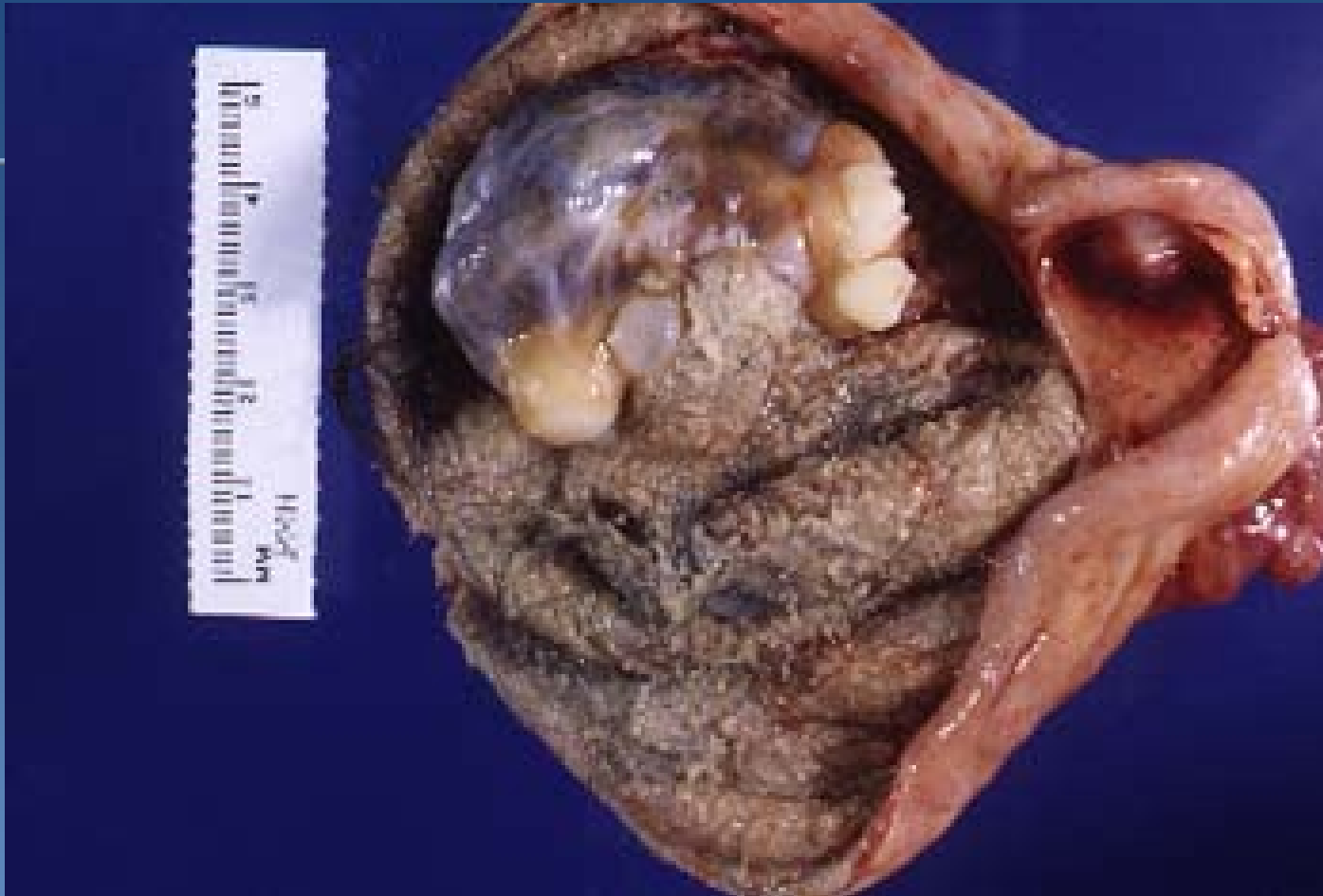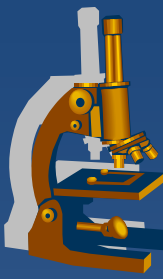


Origin	Surface epithelial cells (common epithelial tumors)	Germ cell	Sex cord–stroma	Metastasis to ovaries
Frequency	65–70%	15–20%	5–10%	5%
Age group affected	20 + years	0–25 + years	All ages	Variable
Types	<ul style="list-style-type: none"> • Serous tumor • Mucinous tumor • Endometrioid tumor • Clear cell tumor • Brenner tumor • Unclassifiable 	<ul style="list-style-type: none"> • Teratoma • Dysgerminoma • Endodermal sinus tumor • Choriocarcinoma 	<ul style="list-style-type: none"> • Fibroma • Granulosa–theca cell tumor • Sertoli–Leydig cell tumor 	

Germ cell tumors



- x counterpart to germ cell testicular tumors
- x dysgerminoma – ovarian „seminoma“
- x most common female germ cell tumor:
 - ⇒ *benign mature (differentiated) teratoma, usually in the form of dermoid cyst*



Dermoid cyst – mature cystic teratoma

Sex cord-stromal tumors



x Granulosa-theca cell tumors

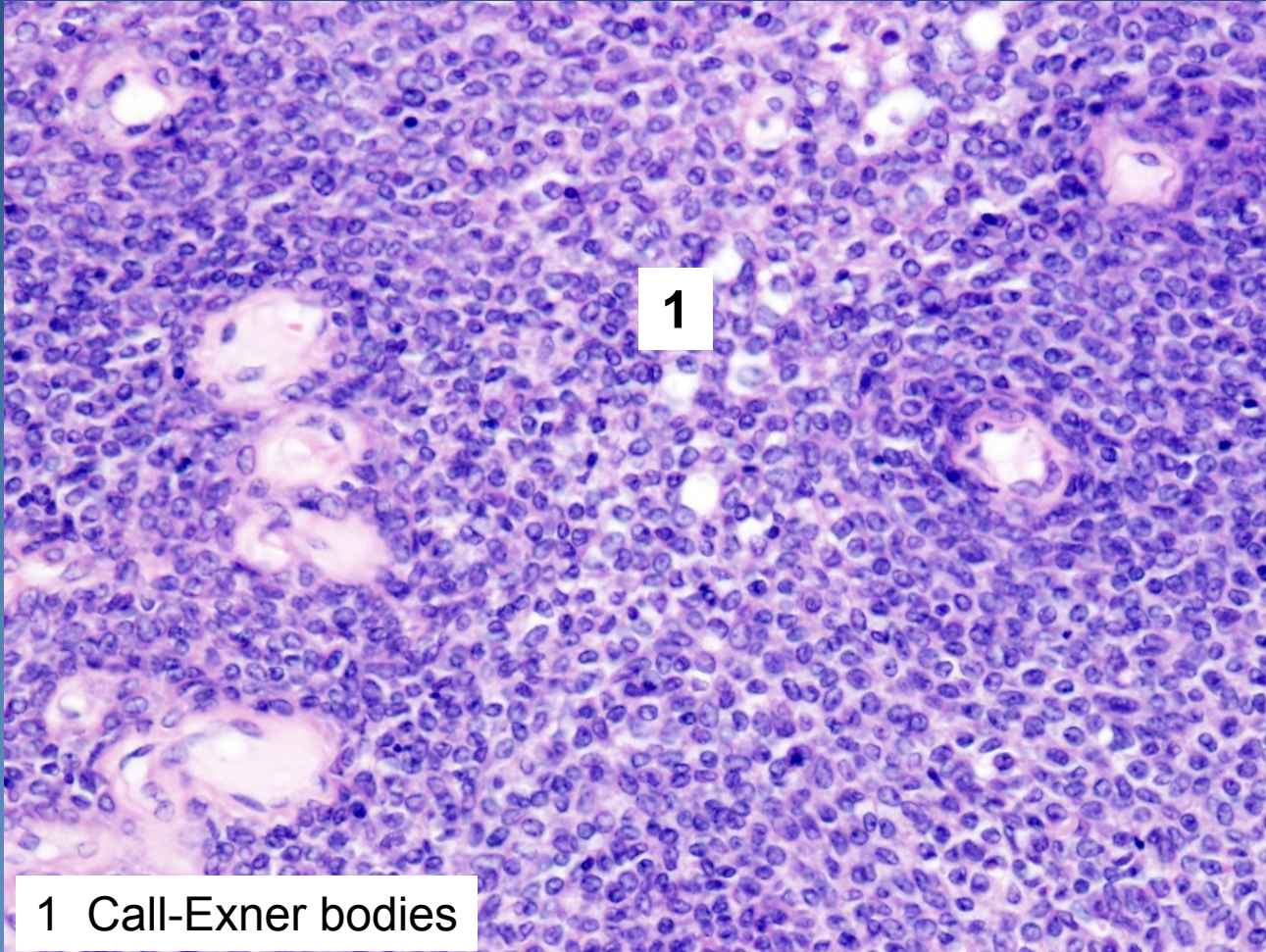
- **granulosa cell tumor (adult type)** – Call-Exner bodies; malignant potential, estrogen production
- **granulosa cell tumor (juvenile type)**
- **thecoma**
- **fibrothecoma**
- *fibroma*
- *fibrosarcoma*

x Sertoli-Leydig cell tumors

x Steroid cell tumors

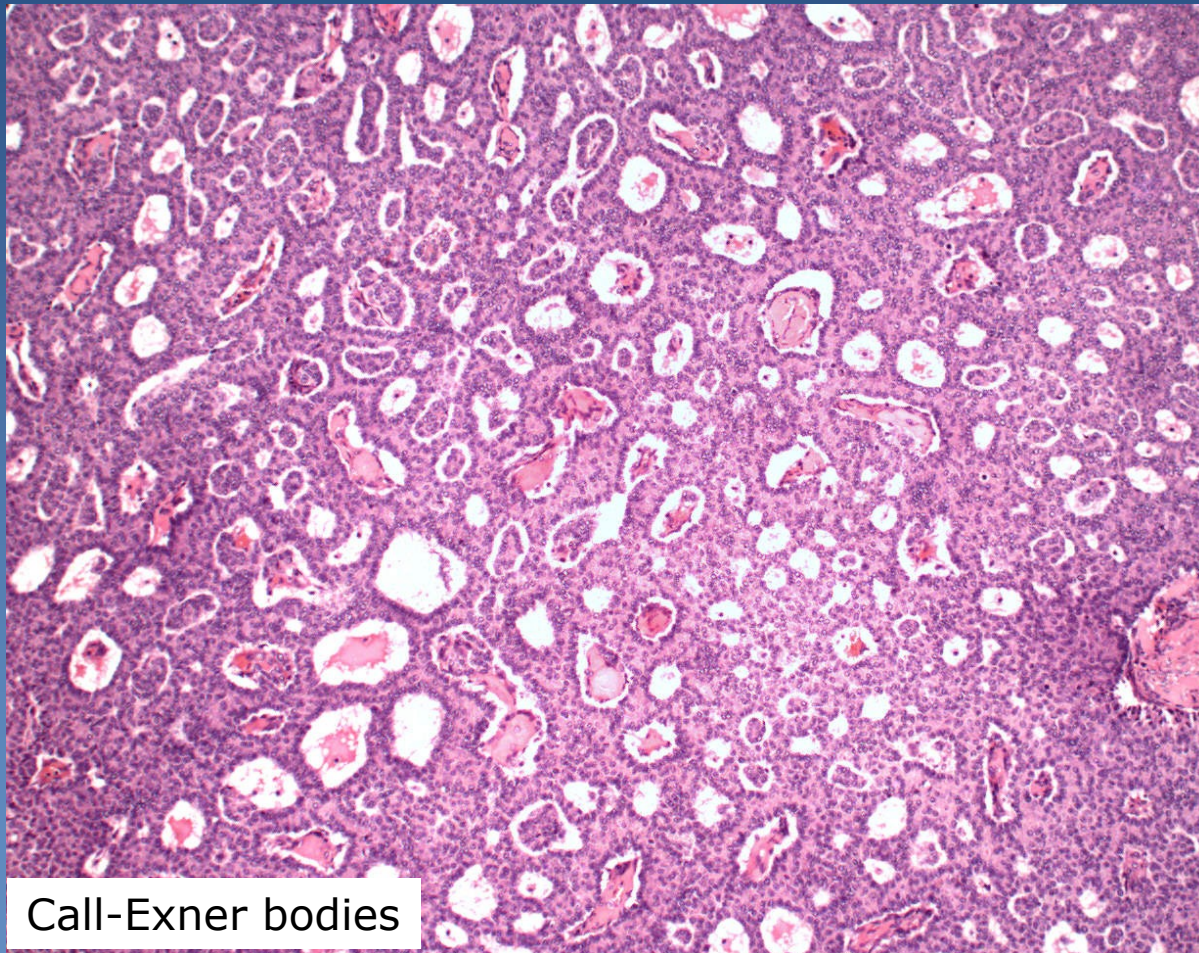
- resemble steroid hormone-secreting cells
- possible androgenic secretion

Granulosa cell tumor

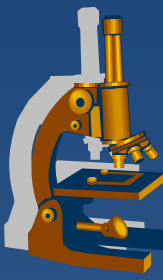


1 Call-Exner bodies

Granulosa cell tumor



Call-Exner bodies



Other tumors

- x Mixed germ cell sex cord-stromal tumors**
- x Primary ovarian mesothelioma, adenomatoid tumor**
- x Soft tissue tumors not specific to the ovary**
- x Malignant lymphomas**

....

- x Secondary ovarian tumors**
 - ⇒ *Krukenberg tumor (metastatic mucinous adenocarcinoma)*
 - ⇒ *pseudomyxoma peritonei,...*

Surface epithelial-stromal tumors



- ✗ Coelomic epithelium (mesothelium with the ability of transformation into Müllerian epithelium) → hyperplasia and metaplasia of the surface epithelium → neoplastic transformation

Biologic potential

- ✗ Benign
 - ⇒ *commonly in form of cystadenoma*
- ✗ Low malignant potential
 - ⇒ *borderline malignancy – moderate atypias, mitotic activity, architectonic changes (multilayering, irregular papillary budding), ! no invasion, but non-invasive peritoneal implants possible*
- ✗ Malignant

Surface epithelial-stromal tumors



Epithelial type

- ✗ *Serous*
- ✗ *Mucinous, endocervical-like and intestinal-type*
- ✗ *Endometrioid*
- ✗ *Clear cell tumors*
- ✗ *Transitional cell tumors*
- ✗ *Mixed tumors of müllerian epithelium*

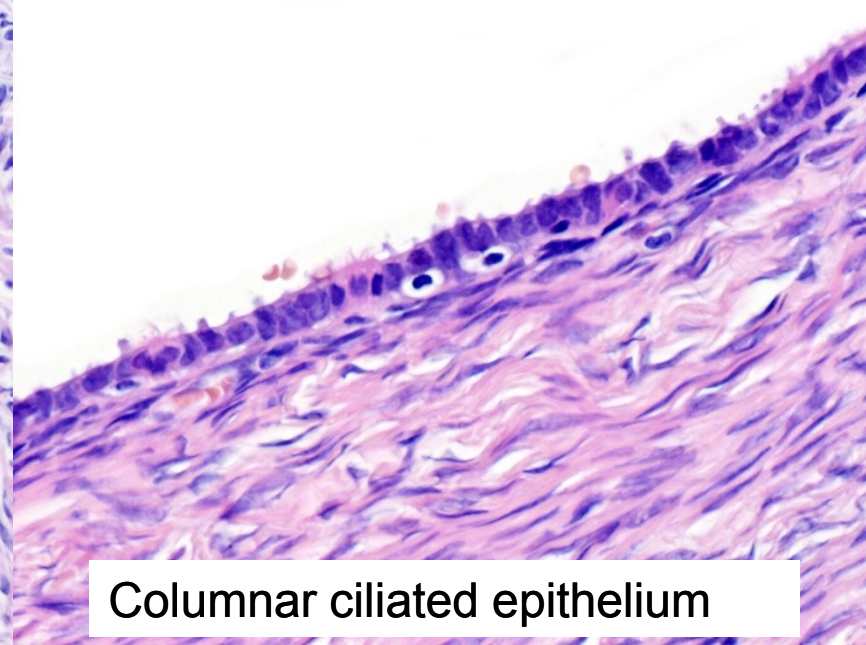
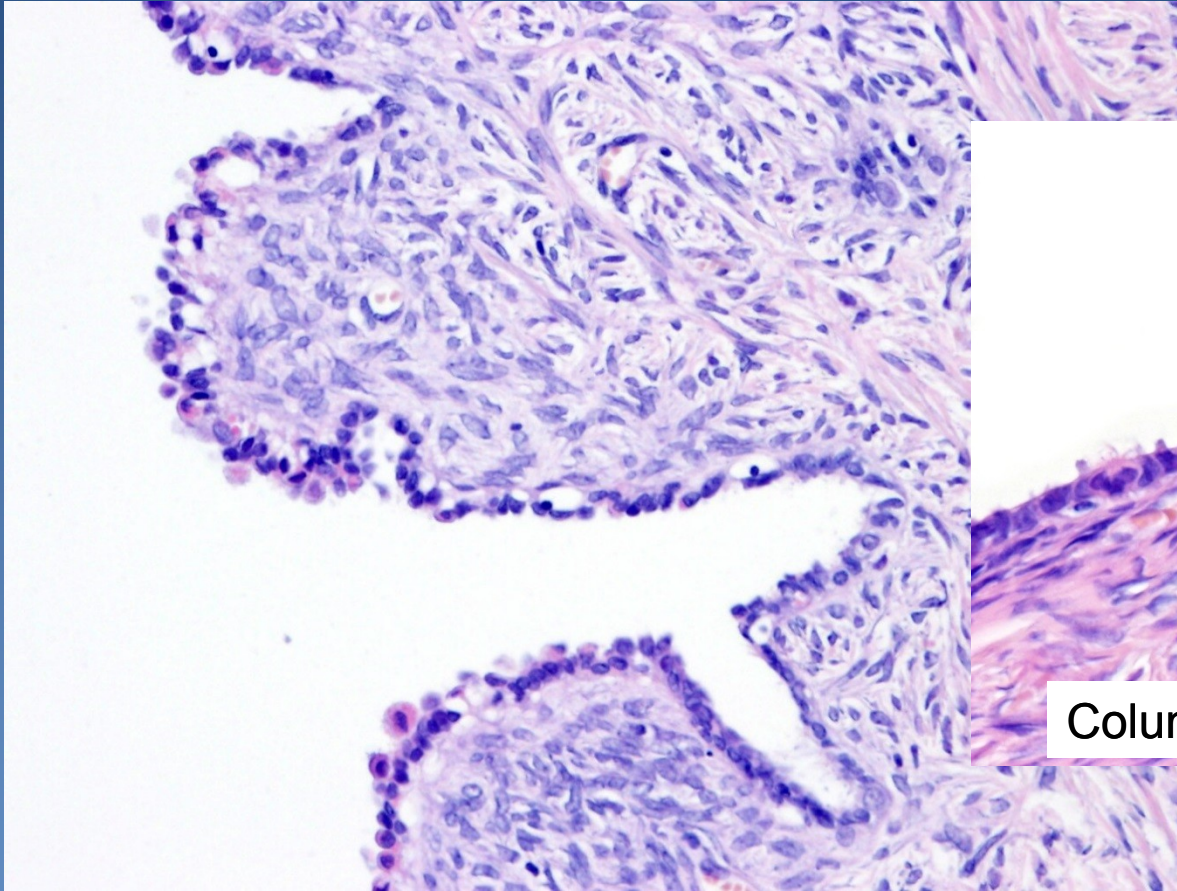
Surface epithelial-stromal tumors



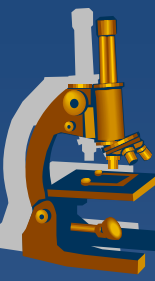
Form of growth

- ✗ Cystic
- ✗ Papillary incl. inverted
- ✗ Solid
- ✗ Increased amount of neoplastic stroma, mixed tumor (adenofibroma, adenosarcoma, etc.)

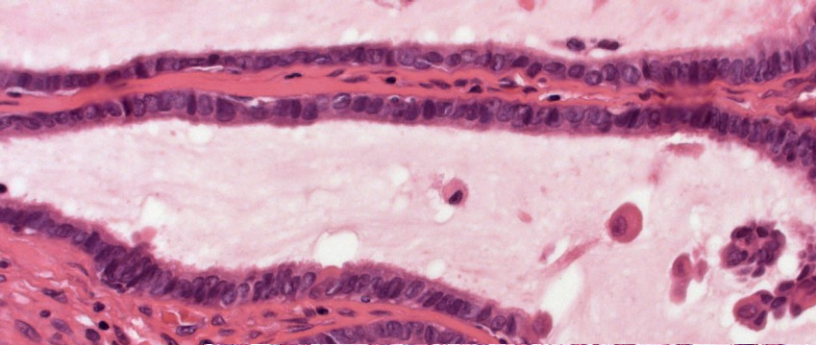
Serous cystadenoma (*cystadenofibroma*)



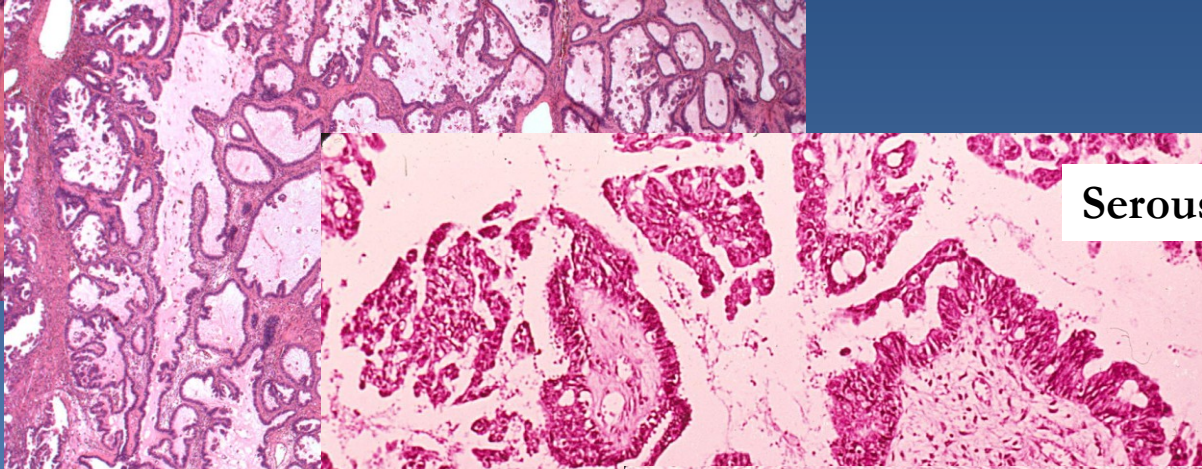
Columnar ciliated epithelium



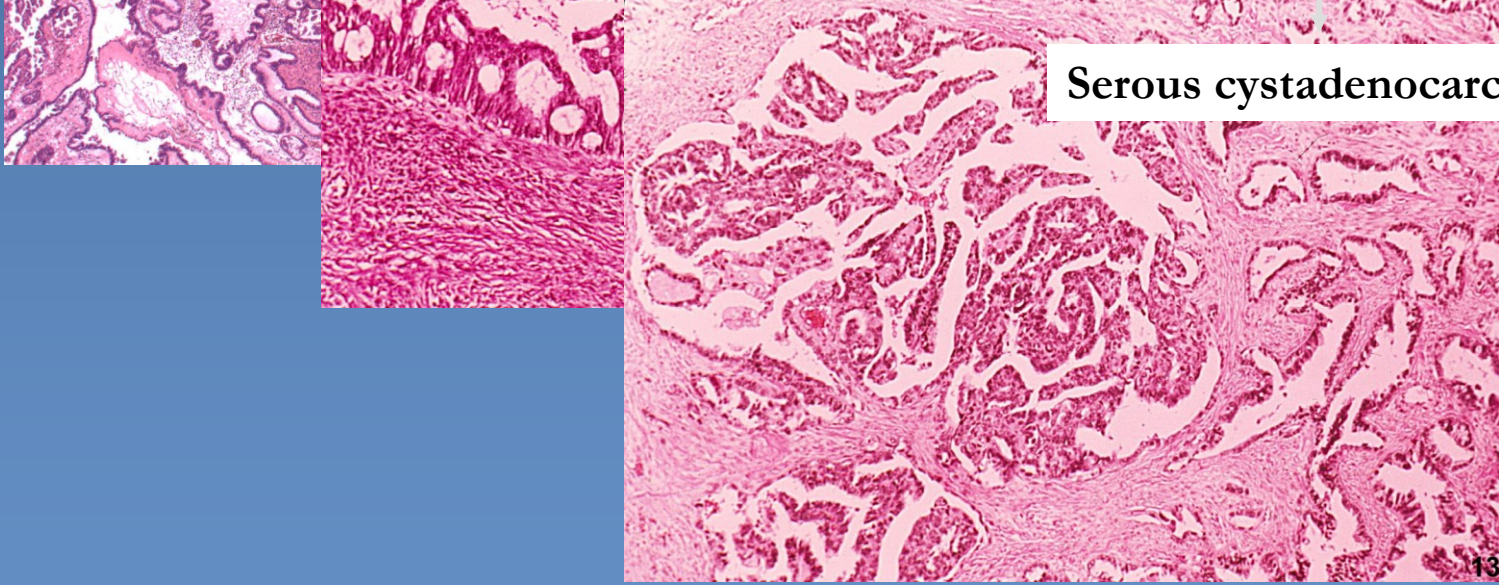
Serous cystadenoma



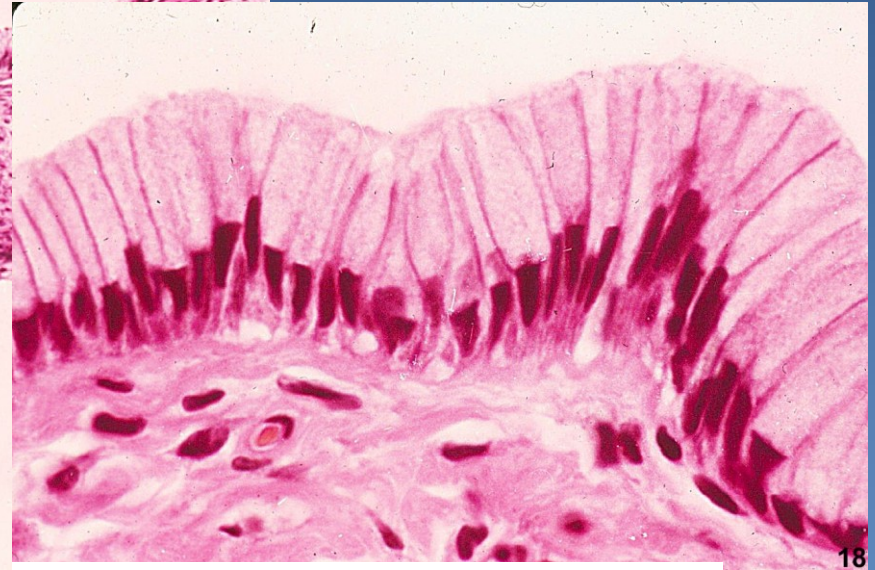
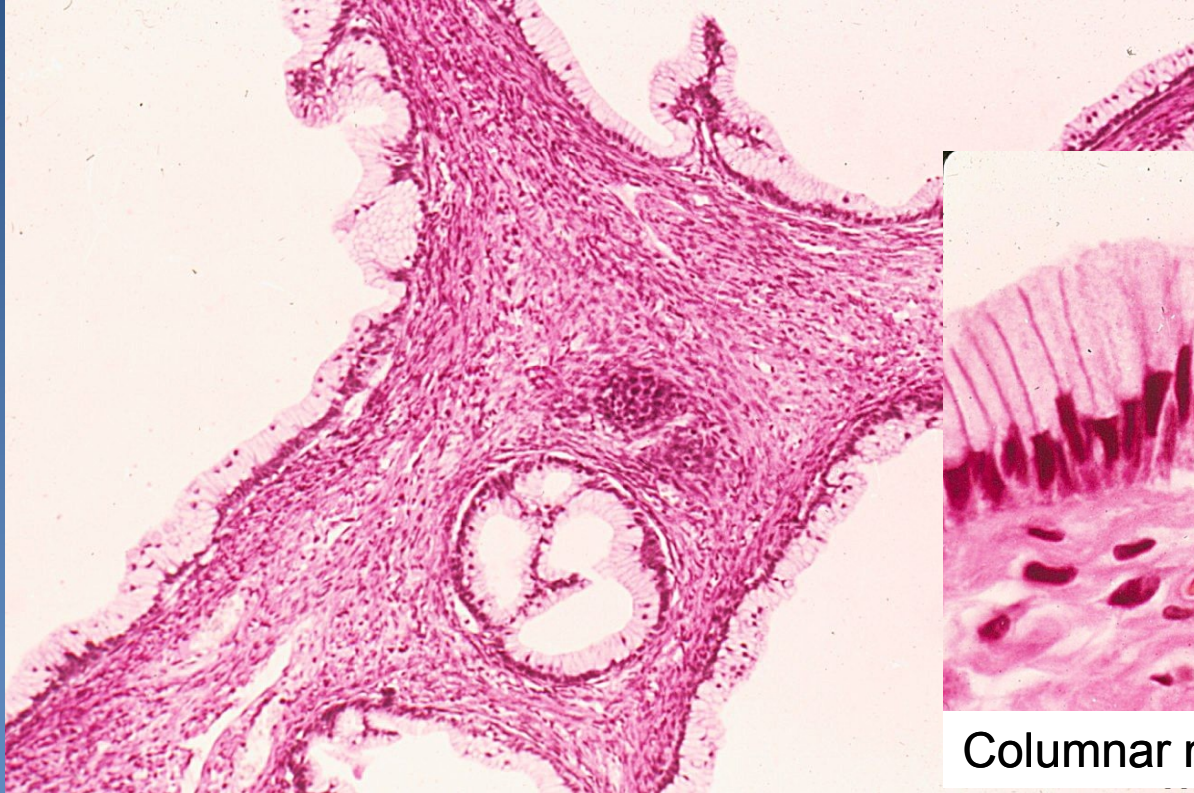
Serous borderline tumor



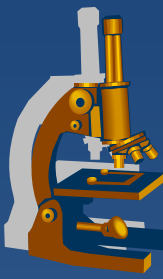
Serous cystadenocarcinoma



Mucinous cystadenoma



Columnar mucinous epithelium



Mucinous cystadenoma

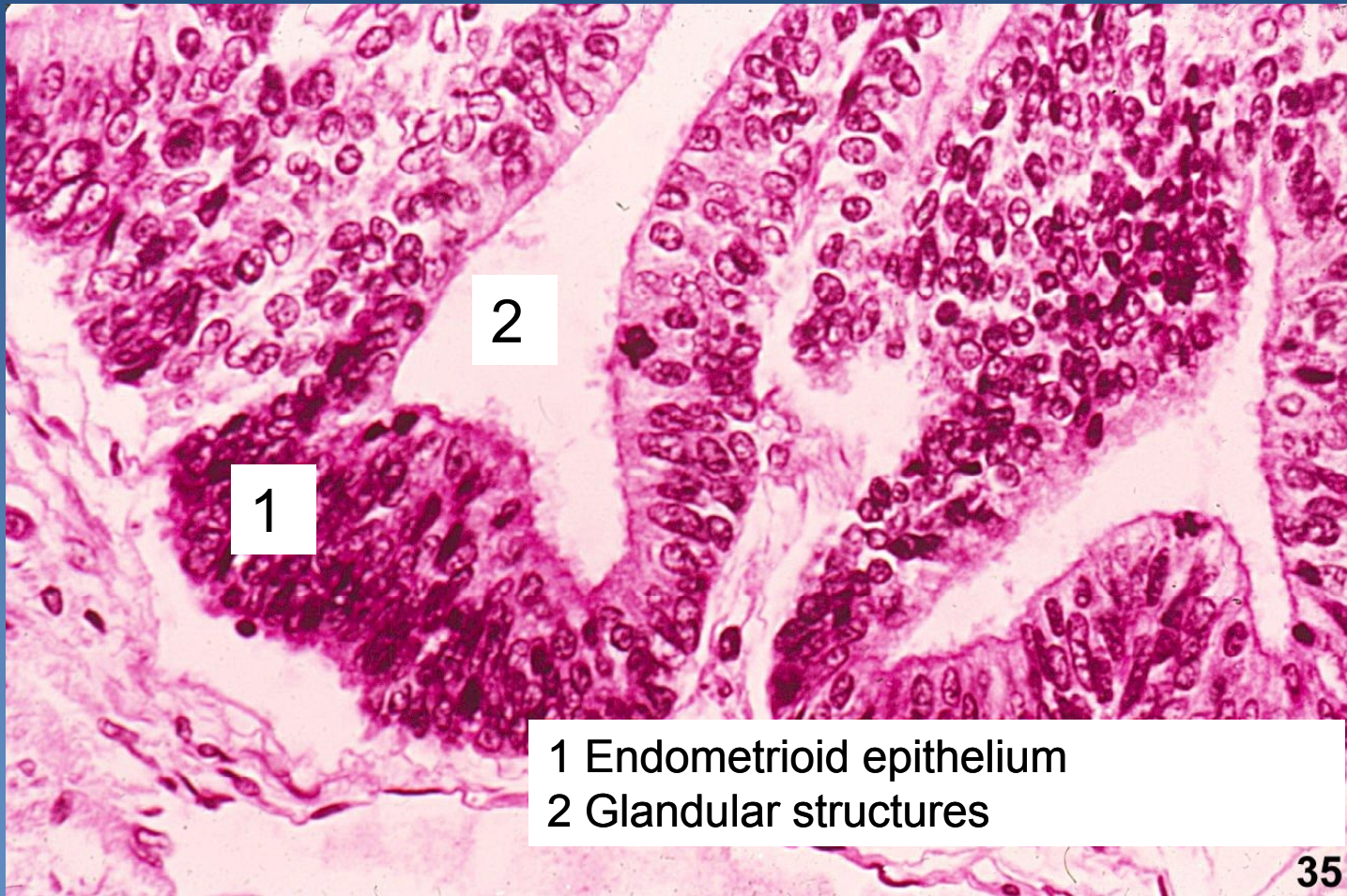
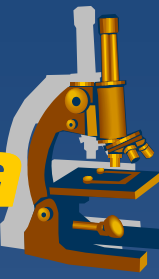


Mucinous borderline tumor



Mucinous cystadenocarcinoma

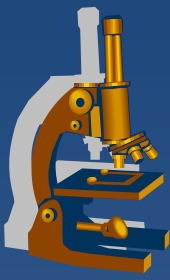
Endometrioid adenocarcinoma



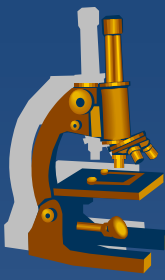
Surface epithelial-stromal tumors



- ✘ Serous adenocarcinoma
 - ⇒ 60-80%, 30-50% bilateral
 - ⇒ usually smaller size, rapid growth
 - ⇒ common psammoma bodies
- ✘ Mucinous adenocarcinoma
 - ⇒ 5-15%, 10-20% bilateral
 - ⇒ large size, slow growth
- ✘ Endometrioid adenocarcinoma
 - ⇒ 10-30%, 10-30% bilateral
 - ⇒ slow growth, haemorrhagic content
 - ⇒ squamous metaplasia common



Pathology of the breast



- x Skin
- x **Nipple and areola**
- x **Mammary gland**
- x Soft tissues
 - ⇒ *inborn defects*
 - ⇒ *circulatory disorders*
 - ⇒ ***inflammations***
 - ⇒ ***non-neoplastic lesions***
 - ⇒ ***tumors***



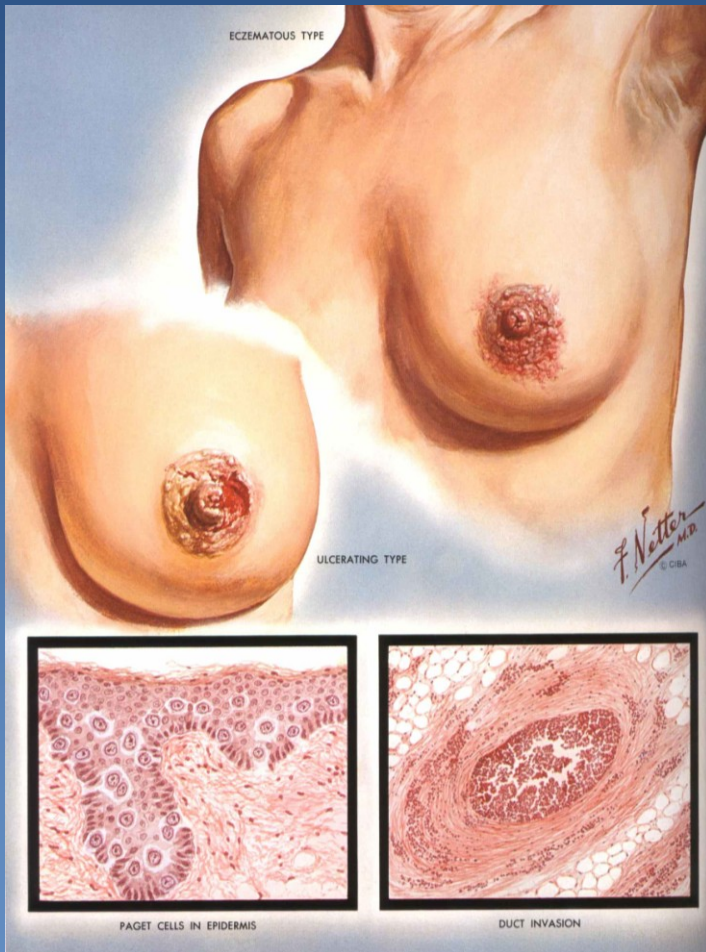
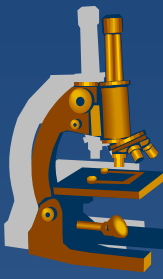
Nipple and areola

Paget's carcinoma of the nipple

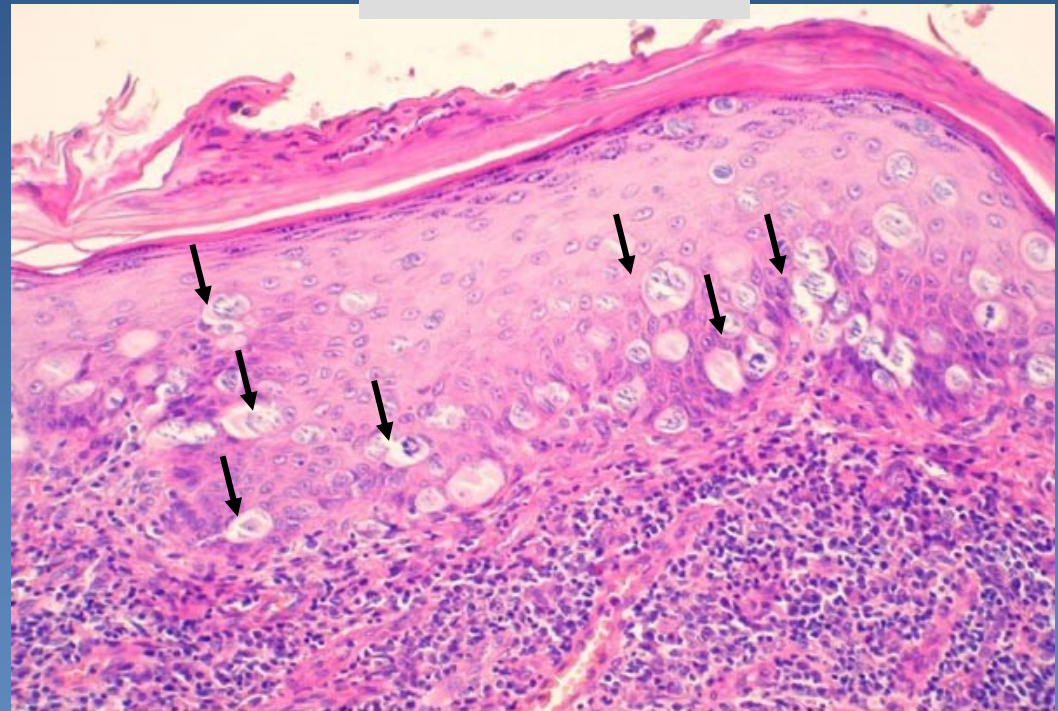


- ✘ **single neoplastic cells dispersed in the squamous cell epithelium** of the nipple
- ✘ usually concurrent with DCIS (ductal carcinoma in situ) or invasive breast carcinoma
- ✘ gross: eczema-like (erythema, oozing/ ulcerated lesion)

Paget's carcinoma of the nipple



www.mamma.cz

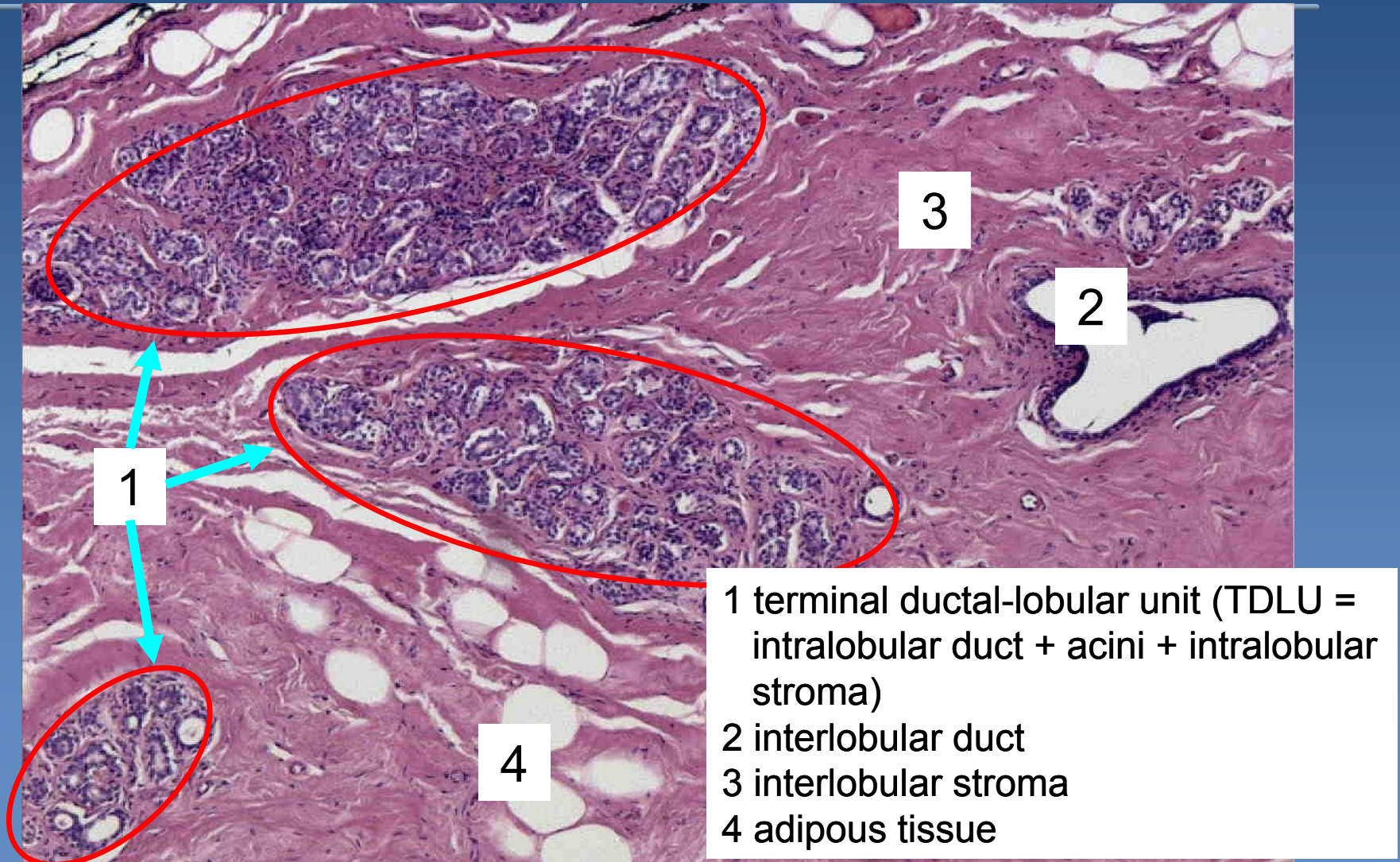


Single neoplastic cells (arrows) dispersed in squamous cell epithelium



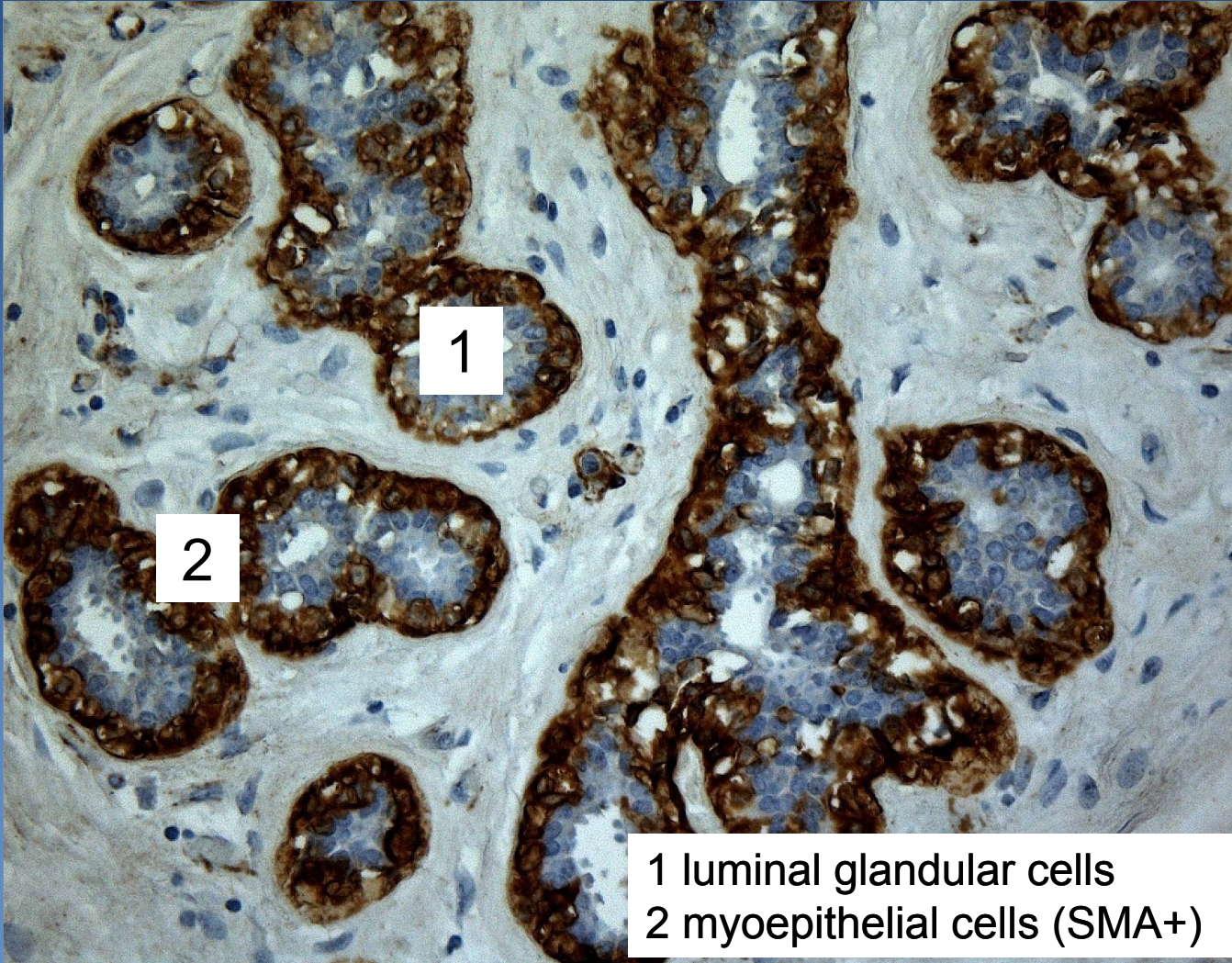
Mammary gland

Fertile mammary gland - histology



TDLU

IHC anti-SMA



1 luminal glandular cells
2 myoepithelial cells (SMA+)

Benign epithelial lesions



- x benign alterations in ducts and lobules**
- x common lesions**

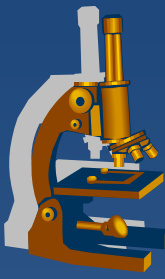
⇒ *palpable irregularities (lumps, granularity), +/- tender*

⇒ *etiology:*

- hormone dependent
- inflammation-associated

⇒ *diff. dg.: malignant tumors*

Benign epithelial lesions



- x** classification according to the risk of developing subsequent breast carcinoma
- x** non-proliferative breast changes – fibrocystic change
 - ⇒ *cysts +/- apocrine metaplasia*
 - ⇒ *fibrosis*
 - ⇒ *adenosis*

Benign epithelial lesions



- ✗ proliferative breast disease without atypia
 - ⇒ proliferation of ductal epithelium +/-stroma
 - ⇒ usually in combination
 - ⇒ calcification common (mammography)
 - ⇒ epithelial hyperplasia (usual ductal hyperplasia – simple, florid)
 - ⇒ sclerosing adenosis
 - ⇒ papillomatosis
 - ⇒ complex sclerosing lesion

Benign epithelial lesions



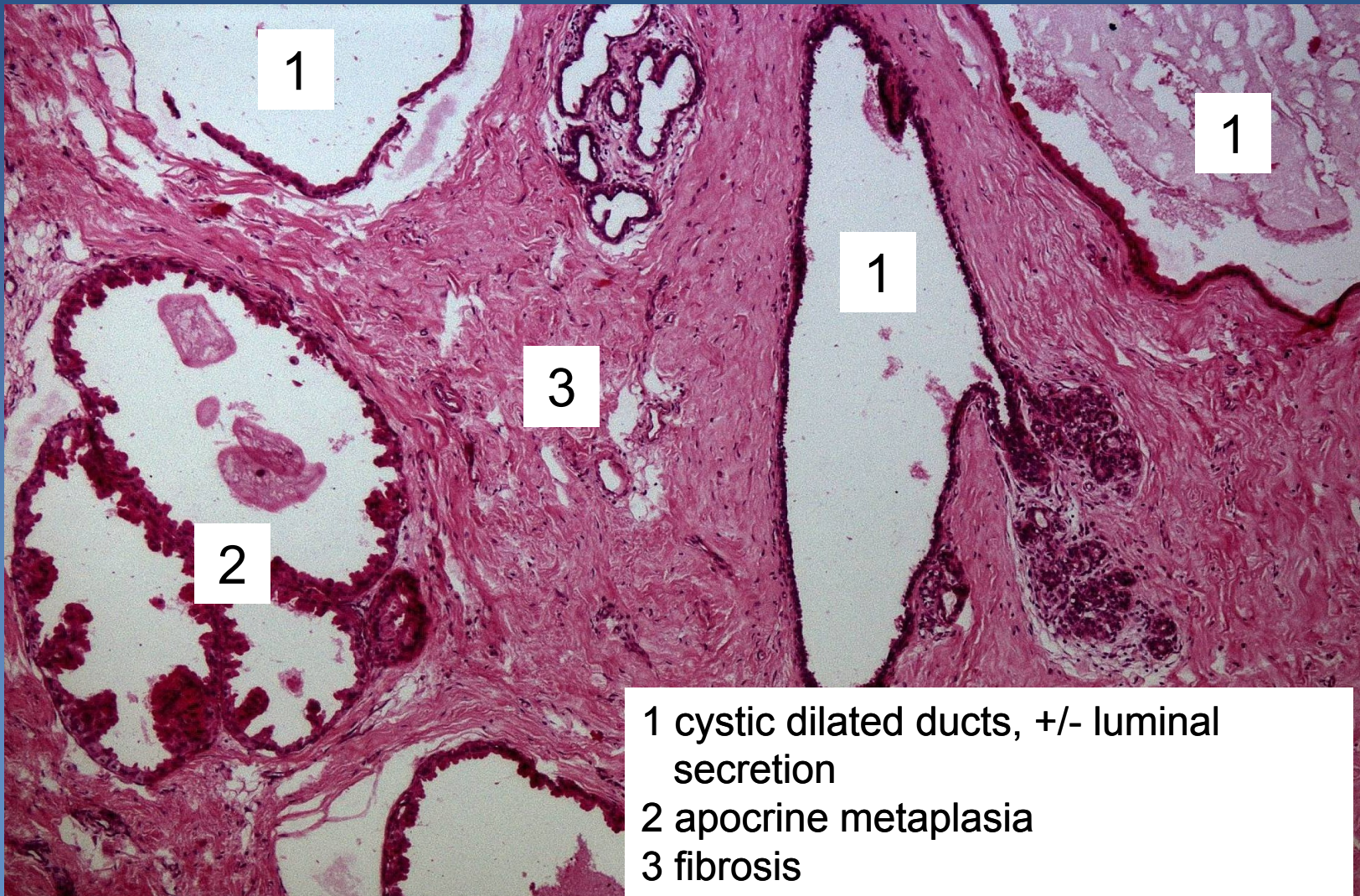
- x** proliferative breast disease with atypia
 - ⇒ *atypical ductal hyperplasia*
 - ⇒ *atypical lobular hyperplasia*

Fibrocystic change



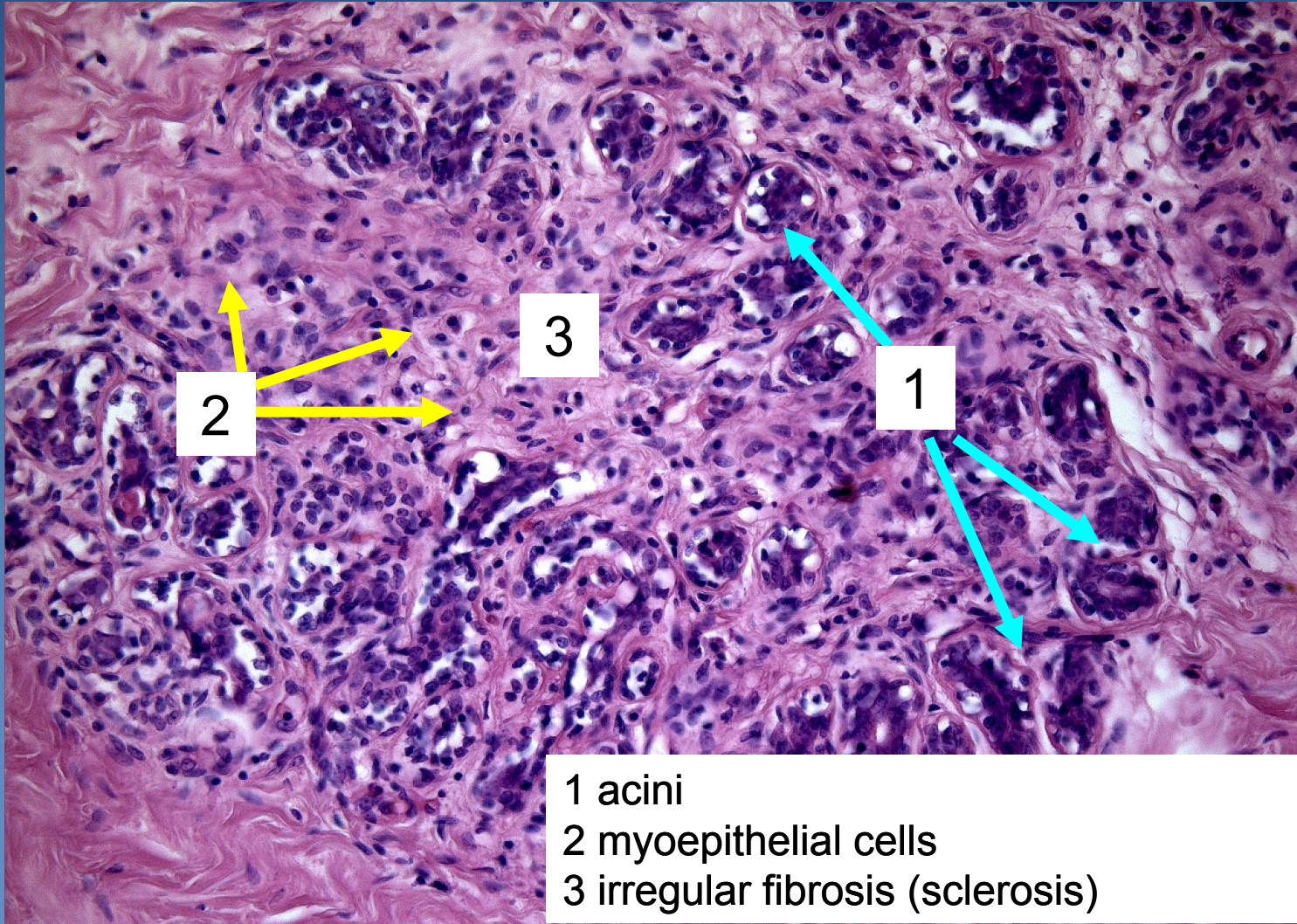
- x palpable „lumpy“ firmer tissue**
- x micro:**
 - ⇒ *extensive fibrosis*
 - ⇒ *+ cysts (apocrine metaplasia)*
 - ⇒ *+ adenosis (lobulocentric proliferative lesion = increased number of acini in a lobule, preserved lobular architectonics)*
 - ⇒ *commonly + ductal and/or lobular hyperplasia*
- x no increased risk of malignant transformation** (unless atypical epithelial hyperplasia present)

Fibrocystic change

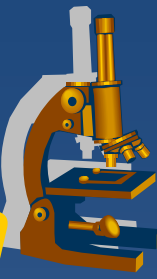


- 1 cystic dilated ducts, +/- luminal secretion
- 2 apocrine metaplasia
- 3 fibrosis

Sclerosing adenosis

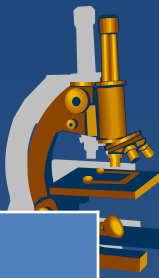


Proliferative breast disease with atypia / in situ neoplasia



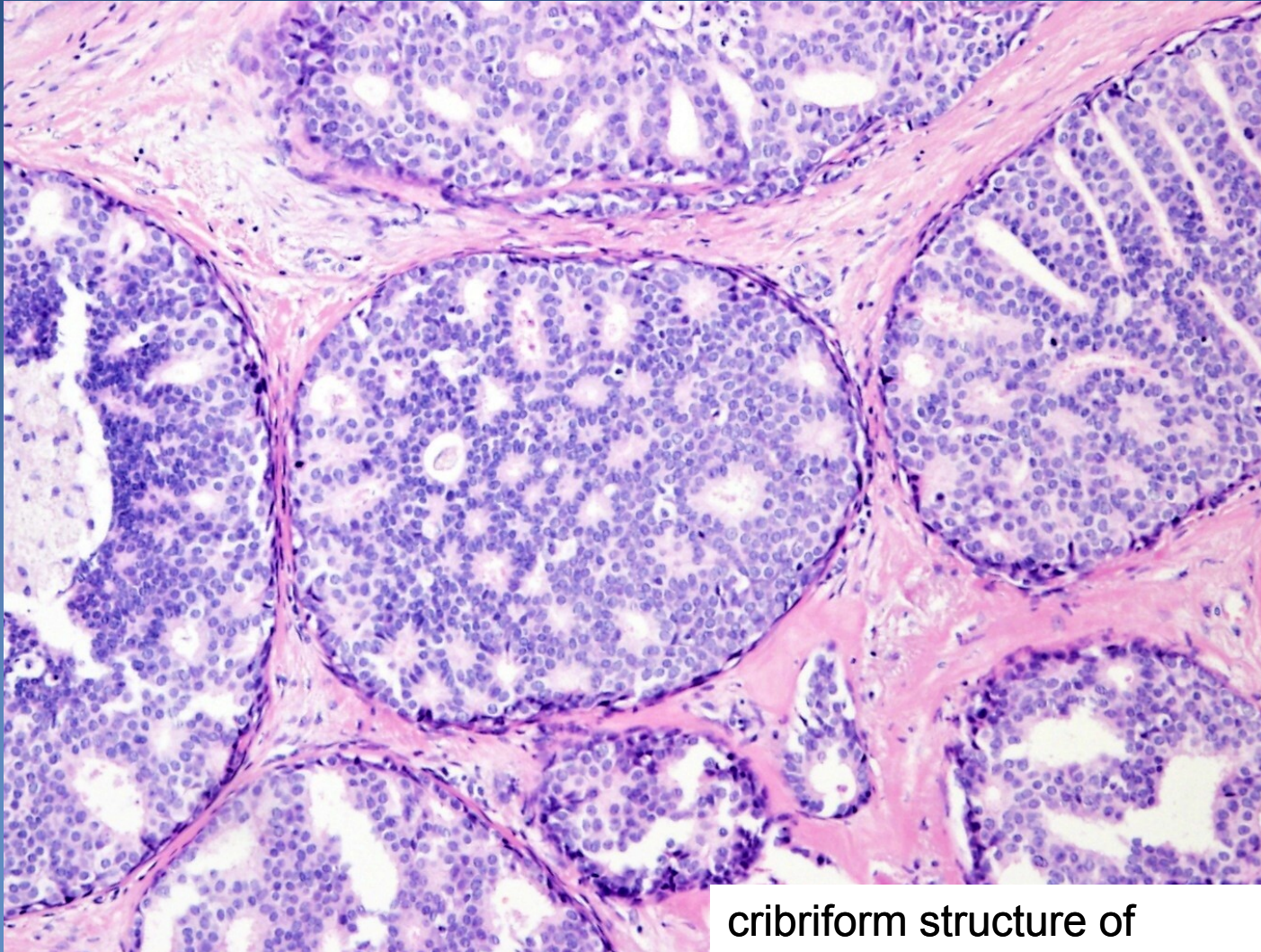- x** relatively common
- x** potential progression into invasive carcinoma – precursor lesion
 - ⇒ ***Atypical ductal hyperplasia (ADH)***
 - ⇒ ***Atypical lobular hyperplasia (ALH)***
 - ⇒ ***Ductal carcinoma in situ (DCIS)***
 - non- high grade
 - high grade
 - ⇒ ***Lobular carcinoma in situ (LCIS)***

Proliferative epithelial lesions and in situ neoplasia



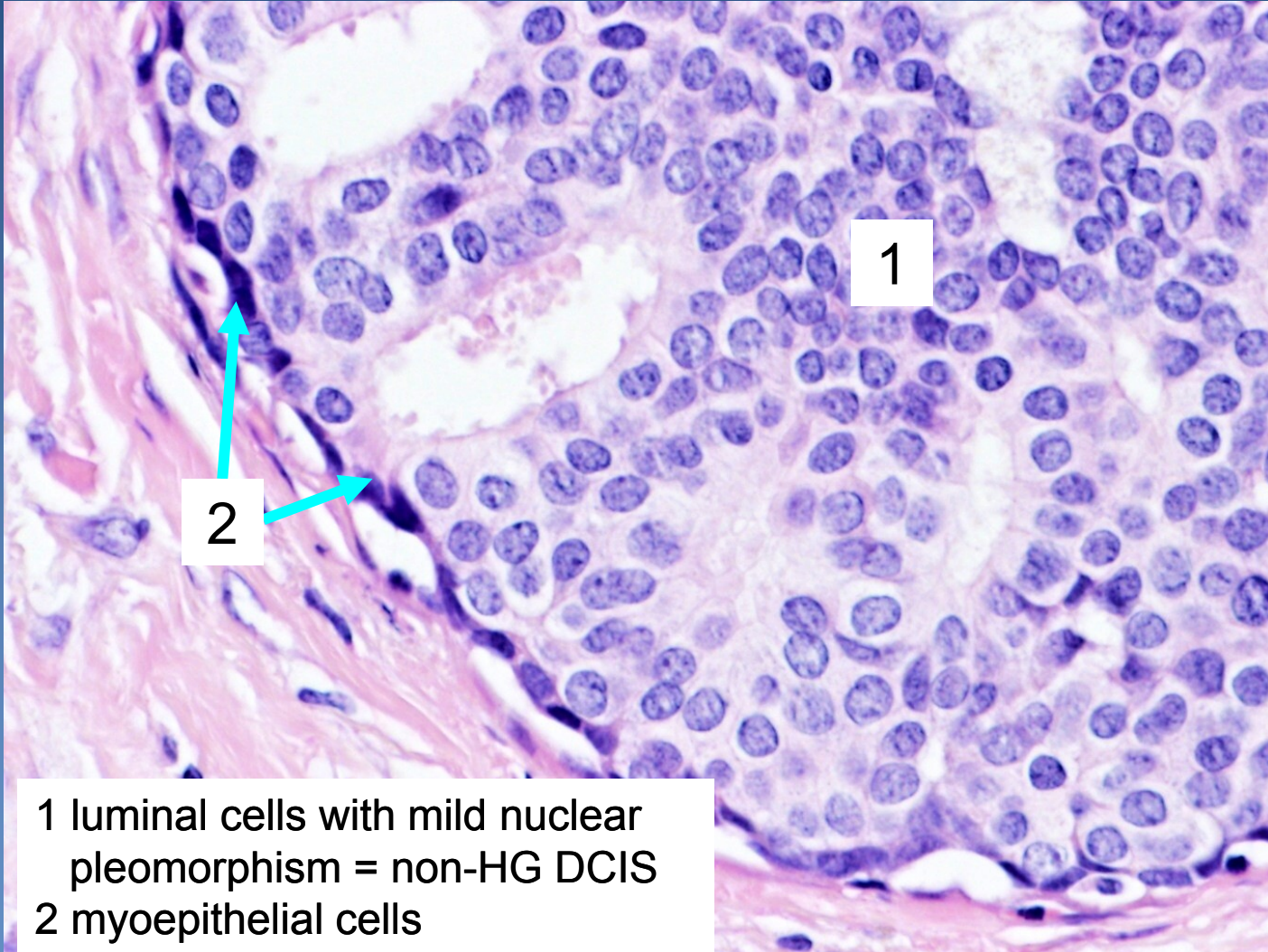
Diagnosis	Morphology
<ul style="list-style-type: none"> • Focal fibrosis • Cysts • Florid adenosis • Sclerosing adenosis 	<ul style="list-style-type: none"> • focal increase of TDLU stroma • dilated ducts • increased number of acini • increased number of acini + TDLU fibrosis
<ul style="list-style-type: none"> • Ductal hyperplasia • Lobular hyperplasia • Ductal papillomatosis • Fibroadenomatoid hyperplasia 	<ul style="list-style-type: none"> • ductal epithelium proliferation • acinar epithelium proliferation • epithelial proliferation in dilated ducts • ductal epithelial + TDLU stromal proliferation
<ul style="list-style-type: none"> • Atypical ductal hyperplasia • Atypical lobular hyperplasia 	<ul style="list-style-type: none"> • ductal epithelium proliferation + atypias • acinar epithelium proliferation + atypias
<ul style="list-style-type: none"> • DCIS, non-high grade • LCIS 	<ul style="list-style-type: none"> • intraductal ca in situ with mild nuclear pleomorphism • lobular ca in situ
<ul style="list-style-type: none"> • DCIS, high grade 	<ul style="list-style-type: none"> • intraductal ca in situ with severe nuclear atypias

DCIS



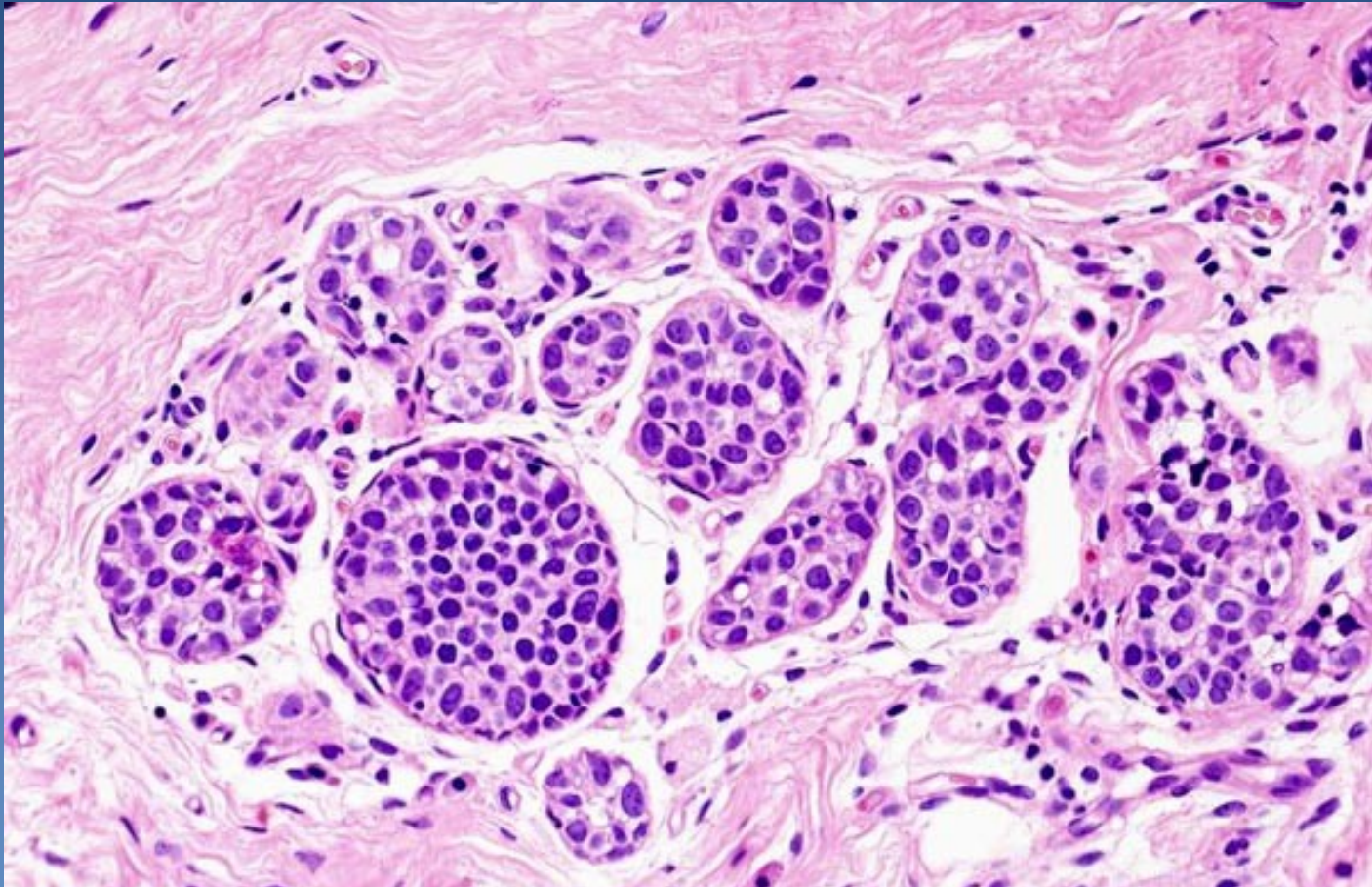
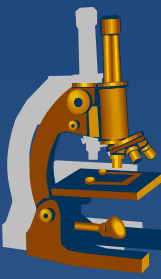
cribriform structure of
DCIS

DCIS



1 luminal cells with mild nuclear pleomorphism = non-HG DCIS
2 myoepithelial cells

LCIS



Expanded acini filled by mildly pleomorphic cells, intact basement membrane

Malignant epithelial tumors



Breast carcinoma

- x commonest** malignancy in females in high-income countries
- x rising incidence**
- x falling mortality**
 - ⇒ *screening + better diagnostics*
 - ⇒ *known modifiable risk factors*
 - ⇒ *more effective therapy*
- x metastases**
 - ⇒ *lymphatic spread – regional LN (mostly axillary)*
 - ⇒ *hematogenous spread (bones, lung, liver, brain...)*

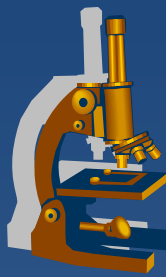
Malignant epithelial tumors



- x Sporadic carcinomas** ($\approx 95\%$)
 - \Rightarrow *accidental sequential mutations*
 - \Rightarrow *mostly perimenopausal/postmenopausal, old age (50-75)*

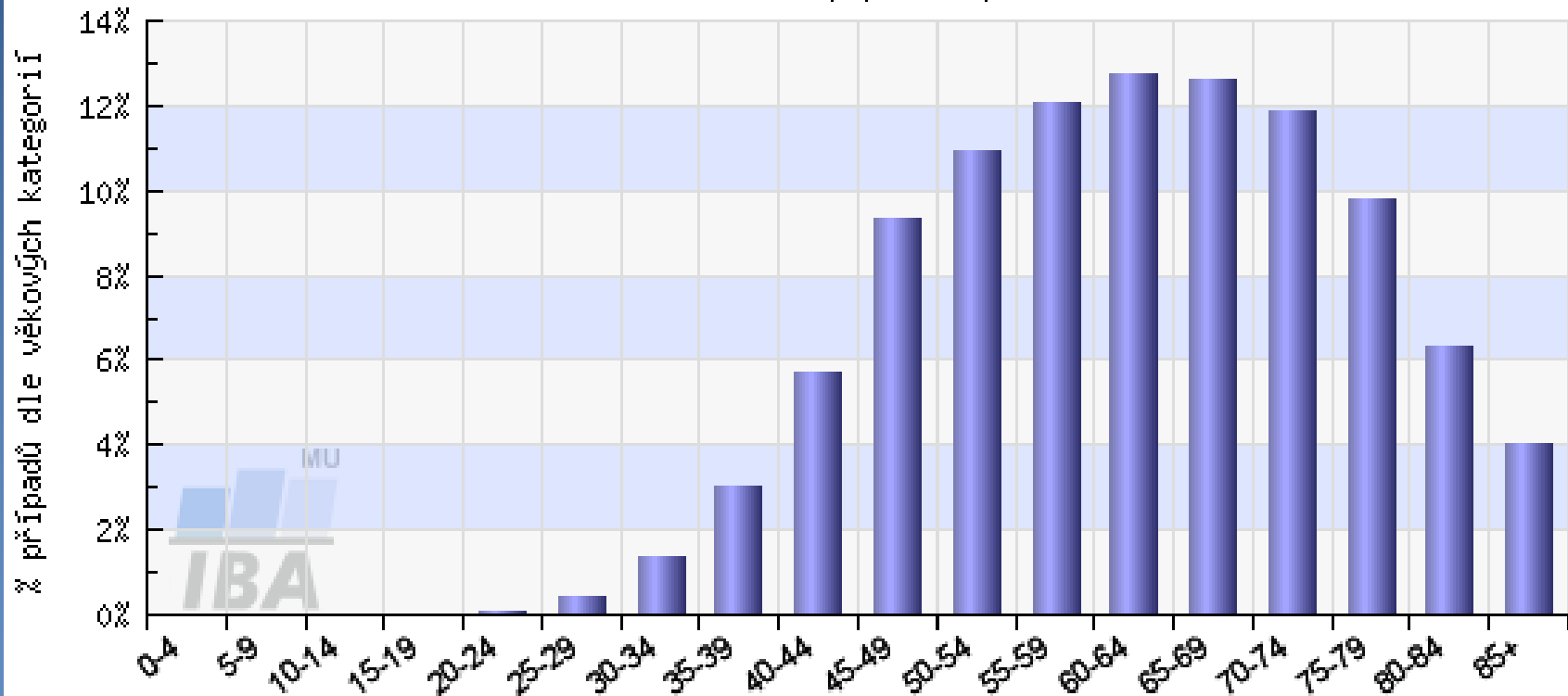
- x Familial carcinomas** ($\approx 5\%$)
 - \Rightarrow *hereditary mutations in some TSG (BRCA1, BRCA2...)*
 - \Rightarrow *typical in young females (after age of 20)*
 - \Rightarrow *possible multicentric, bilateral \rightarrow prophylactic mastectomy*
 - \Rightarrow *\uparrow risk of ovarian carcinomas*

Age incidence



C50 - ZN prsu - Incidence, ženy

věková struktura populace pacientů



Analyzovaná data: N=142275

<http://www.svod.cz>

Zdroj dat: ÚZIS ČR

WHO classification of carcinomas



✗ Invasive ca, no special type (NST) = ductal ca, NOS

✗ Invasive lobular carcinoma

- ✗ Tubular ca
- ✗ Invasive cribriform ca
- ✗ Medullary ca
- ✗ Mucin producing ca
- ✗ Neuroendocrine tumors
- ✗ Invasive papillary ca
- ✗ Invasive micropapillary ca

- ✗ Apocrine ca
- ✗ Metaplastic ca
- ✗ Lipid-rich ca
- ✗ Secretory ca
- ✗ Oncocytic ca
- ✗ Adenoid-cystic carcinoma
- ✗ Acinic cell ca
- ✗ Glycogen-rich clear cell ca
- ✗ Sebaceous ca
- ✗ Inflammatory ca

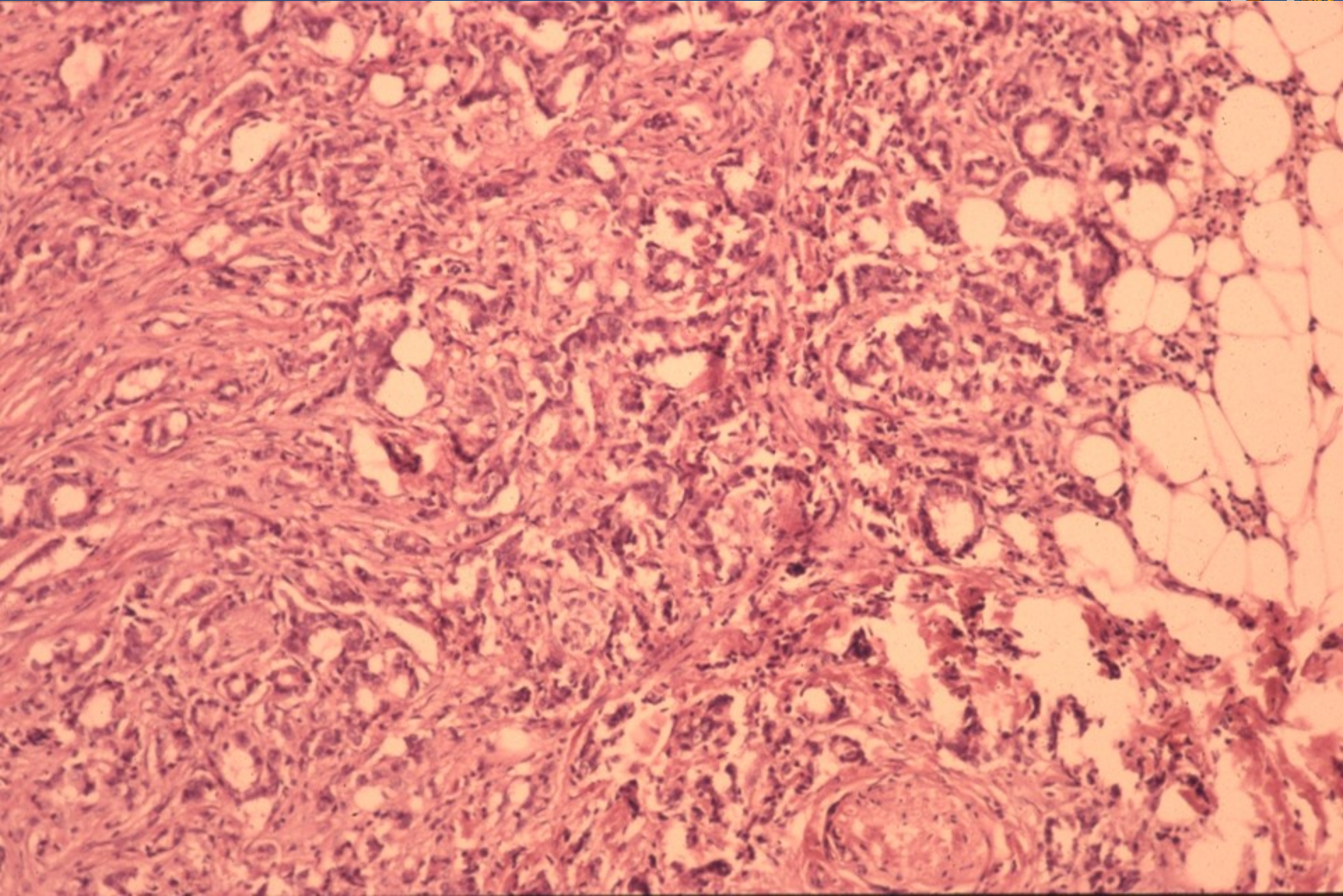
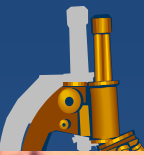- ✗ Bilateral carcinoma

Invasive carcinoma NST

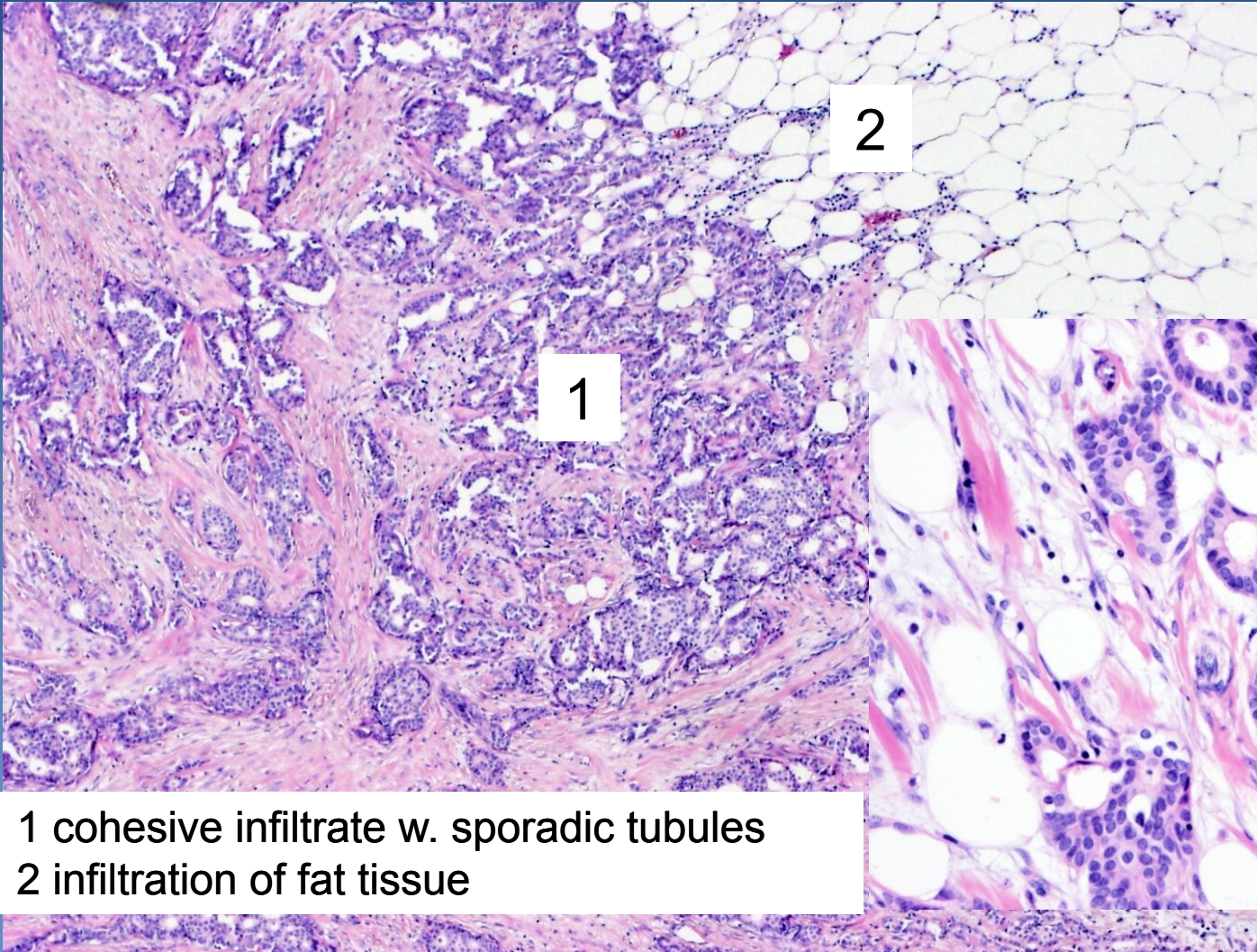
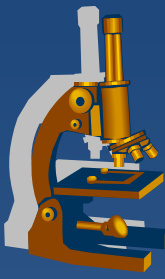


- ✘ most common (formerly invasive ductal ca)
- ✘ gross:
 - ⇒ *firm lesion, irregular border*
- ✘ micro:
 - ⇒ *cohesive (E-cadherin+) tumor cells*
 - tubules, trabeculae, solid clusters
 - variable grade of nuclear pleomorphism, mitotic activity (gr. I-III)
 - ⇒ *loss of outer myoepithelial cell layer (p63-, SMA-)*
 - ⇒ *dense fibrotic stroma, desmoplasia*
 - ⇒ *infiltrative growth, commonly adjacent DCIS*

Invasive carcinoma NST

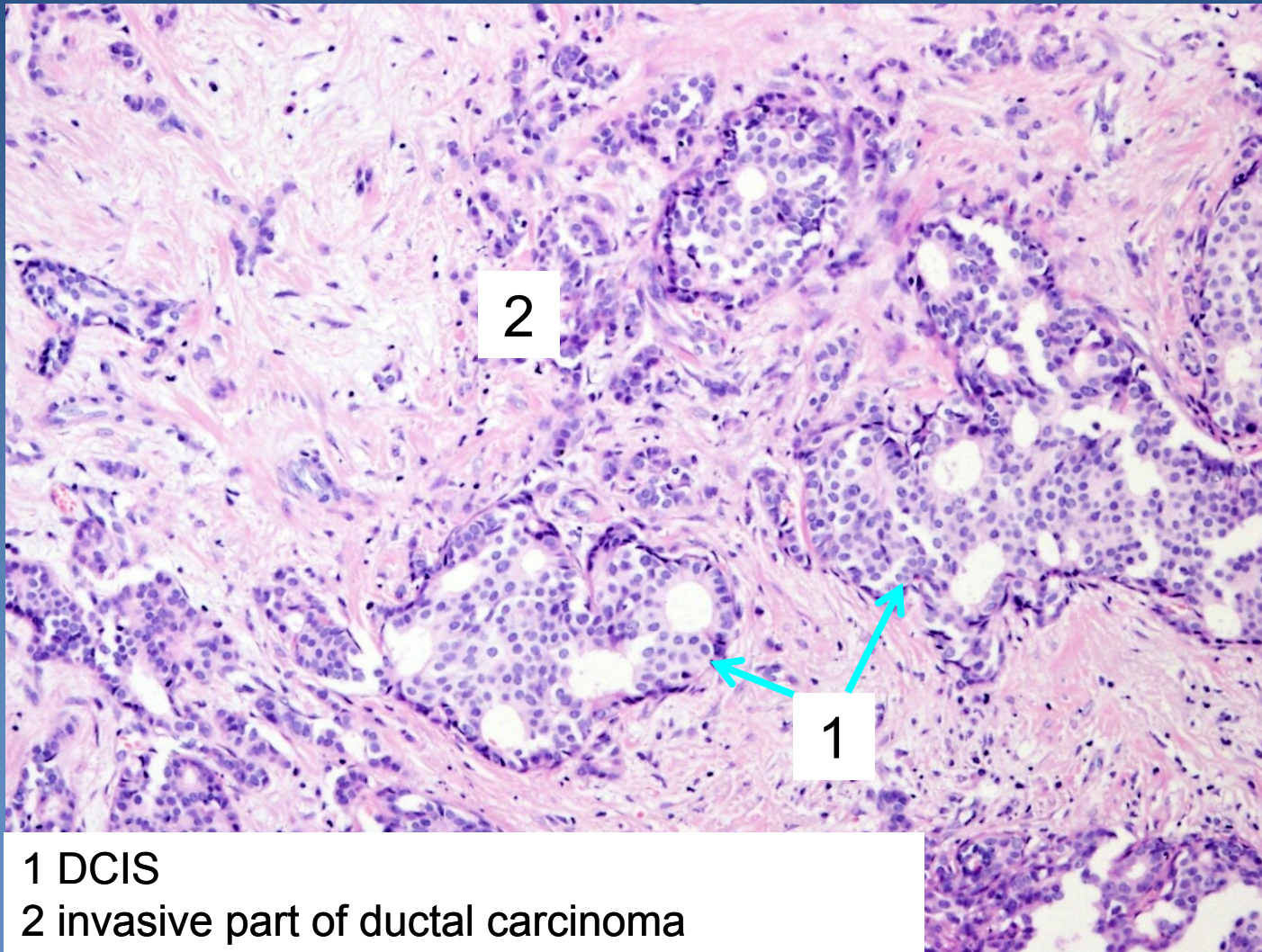


Invasive carcinoma NST



1 cohesive infiltrate w. sporadic tubules
2 infiltration of fat tissue

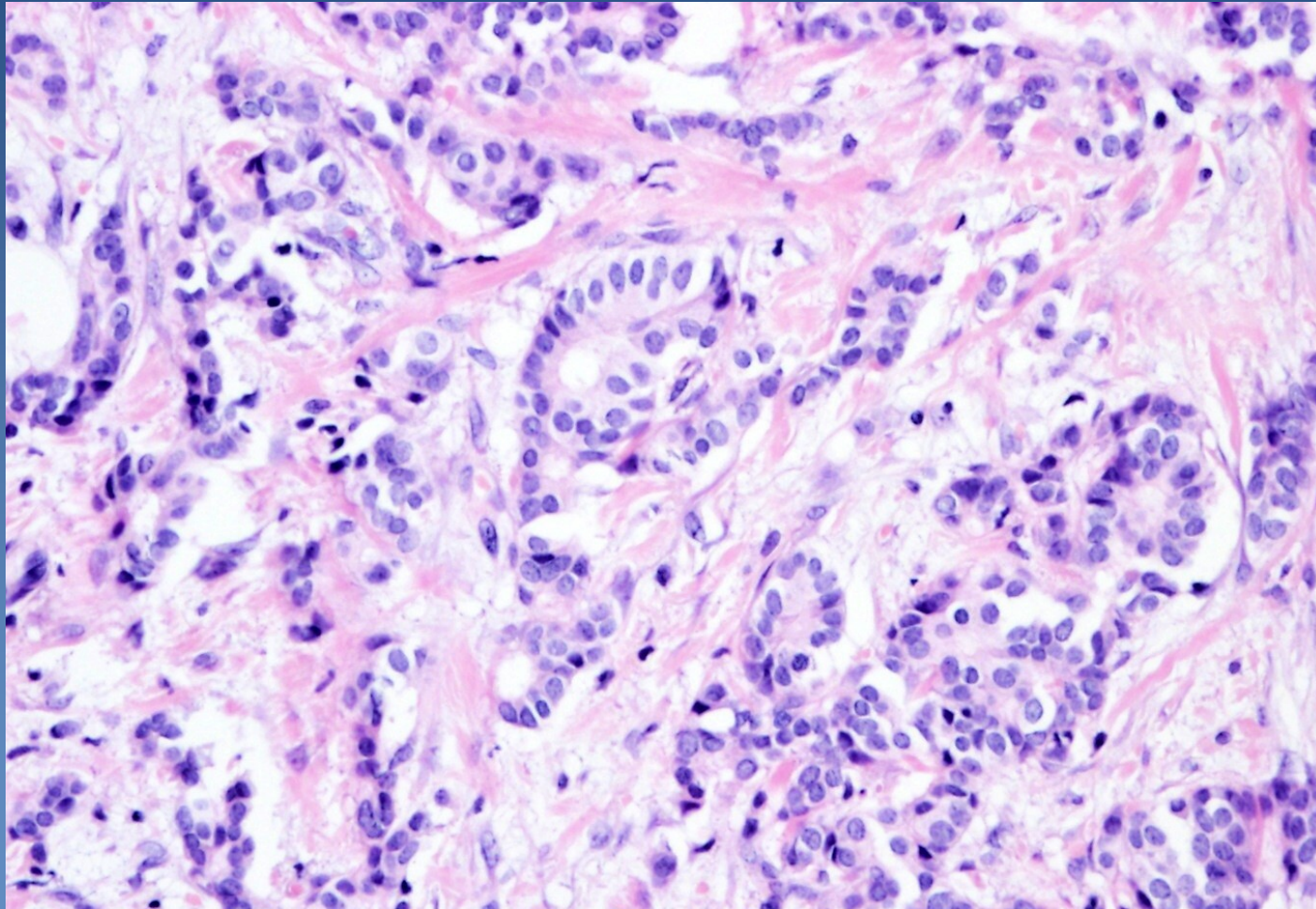
Invasive carcinoma NST



1 DCIS

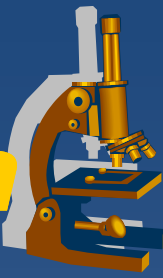2 invasive part of ductal carcinoma

Invasive carcinoma NST



Tumorous infiltrate with irregular small tubules

Invasive lobular carcinoma



✗ more commonly multicentric

✗ micro:

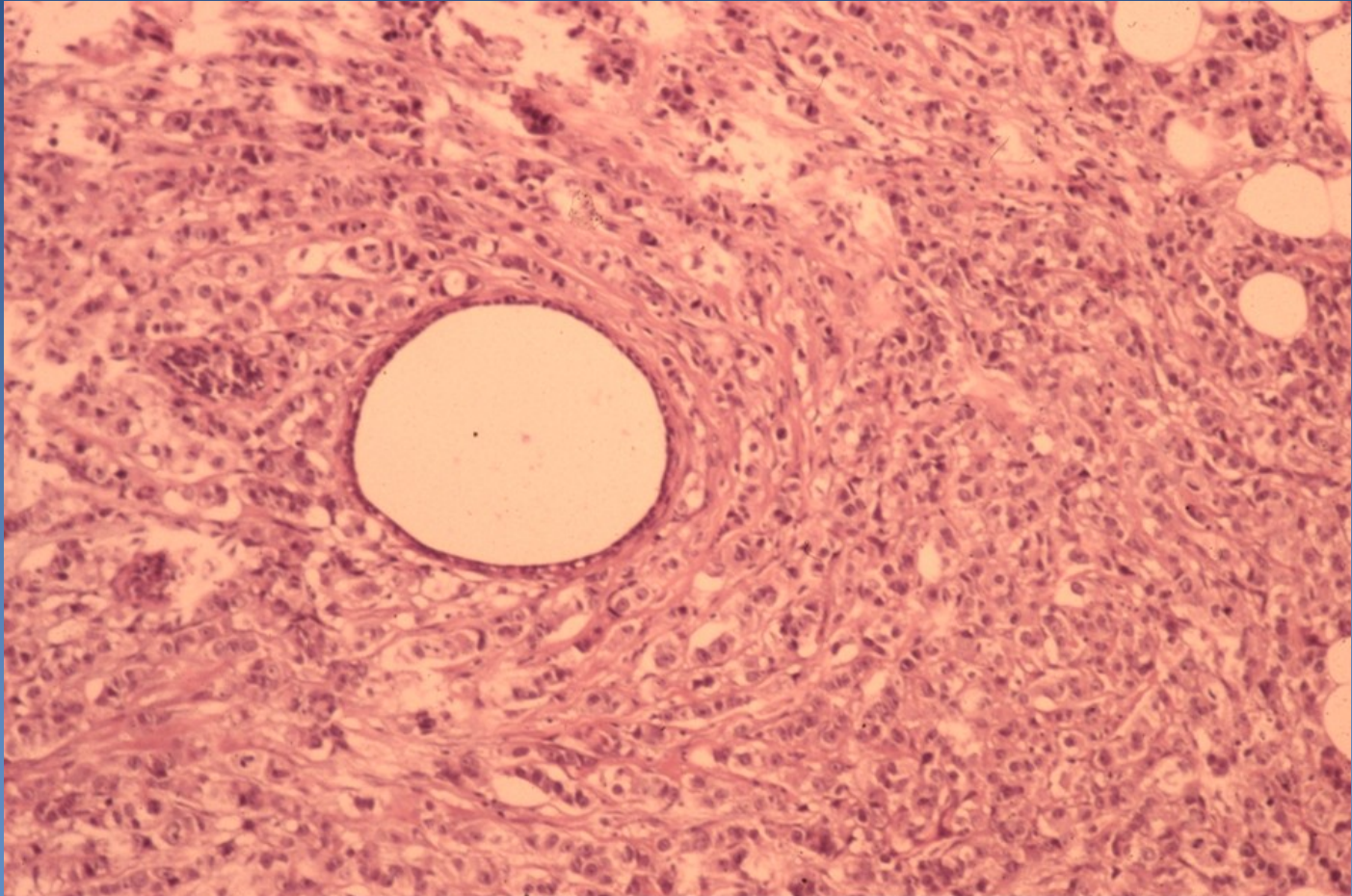
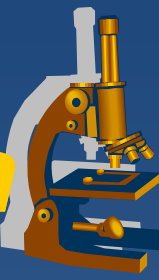
⇒ ***loss of cell cohesivity (E-cadherin-)***

- cell lines, „indian file“
- concentric formations around duct (target-like)
- loss of myoepithelial layer (SMA-)

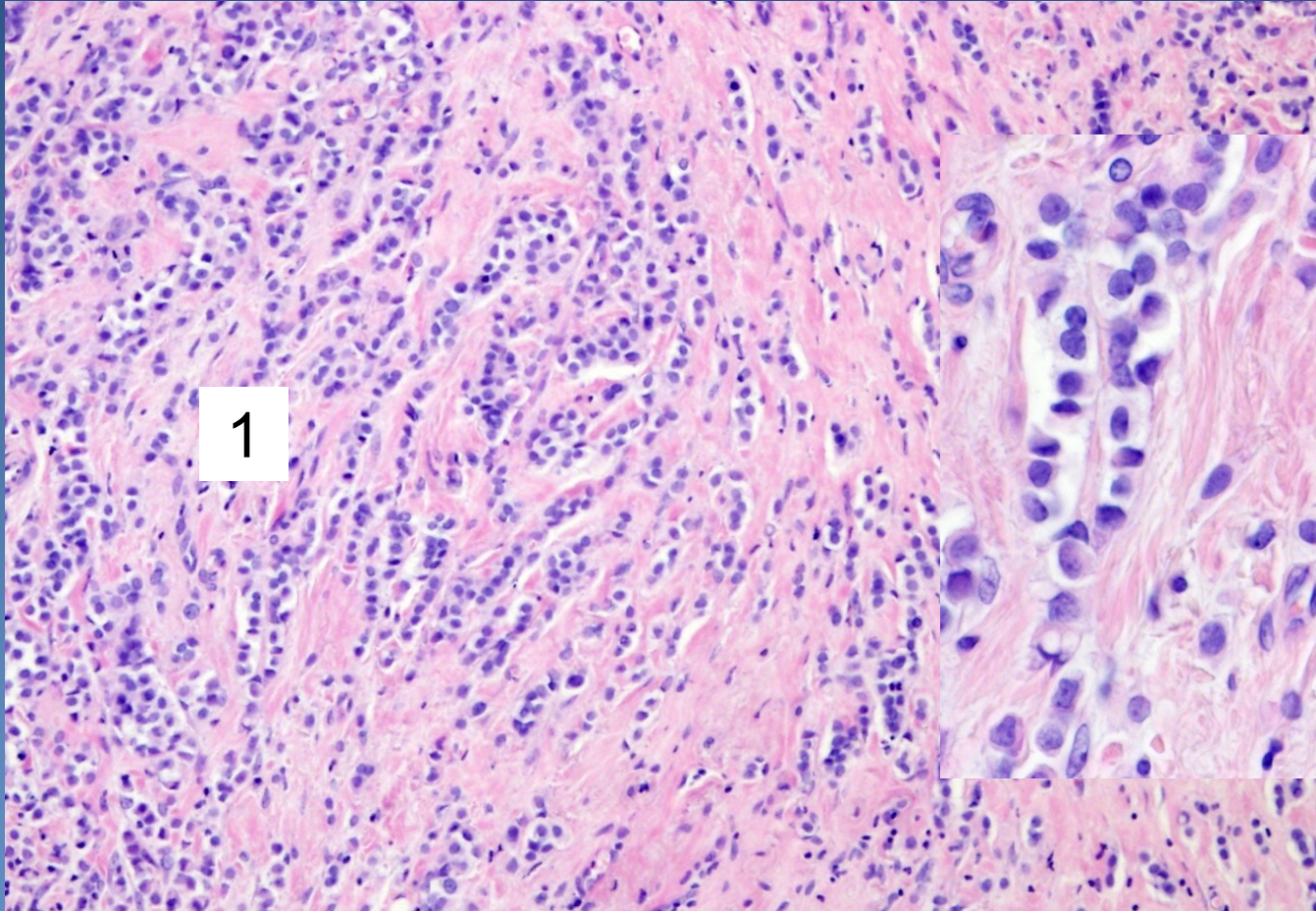
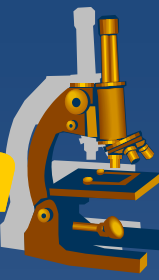
⇒ ***dense stroma***

⇒ ***infiltrative growth, may be adjacent to LCIS***

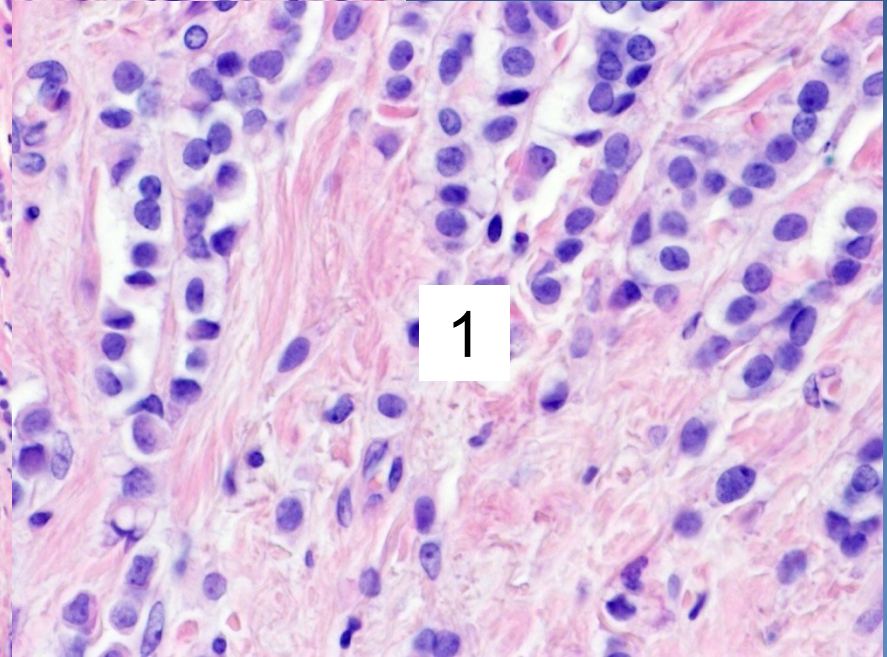
Invasive lobular carcinoma



Invasive lobular carcinoma



1



1

1 dyscohesive tumor cells in single file (Indian file)

Fibroepithelial (mixed) tumors



- x** very common

- x** **Fibroadenoma (FA)**

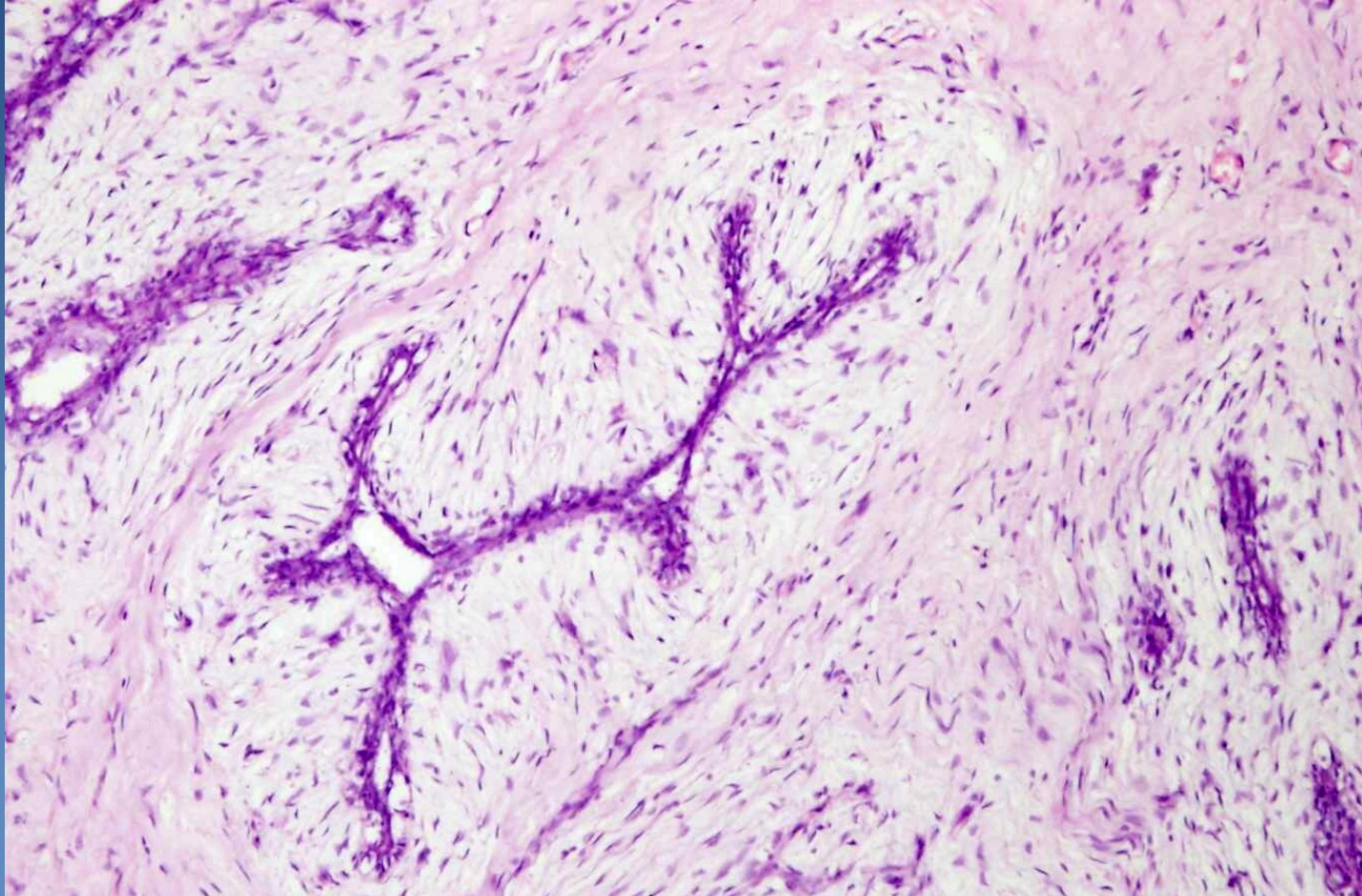
 - ⇒ *most common breast tumor in young females*

 - ⇒ *benign, circumscribed, mobile, rubbery*

 - ⇒ *proliferating ducts + increased amount of stroma (edematous or hyalinised)*

 - ⇒ *pericanalicular, intracanalicular growth*

Fibroadenoma



Slit-like newly formed ducts compressed by edematous stroma

Fibroepithelial (mixed) tumors



x Phyllodes tumor

⇒ *rare (<1% of all breast tumors)*

⇒ *gross – leaflike structure and cysts (cystosarcoma phyllodes)*

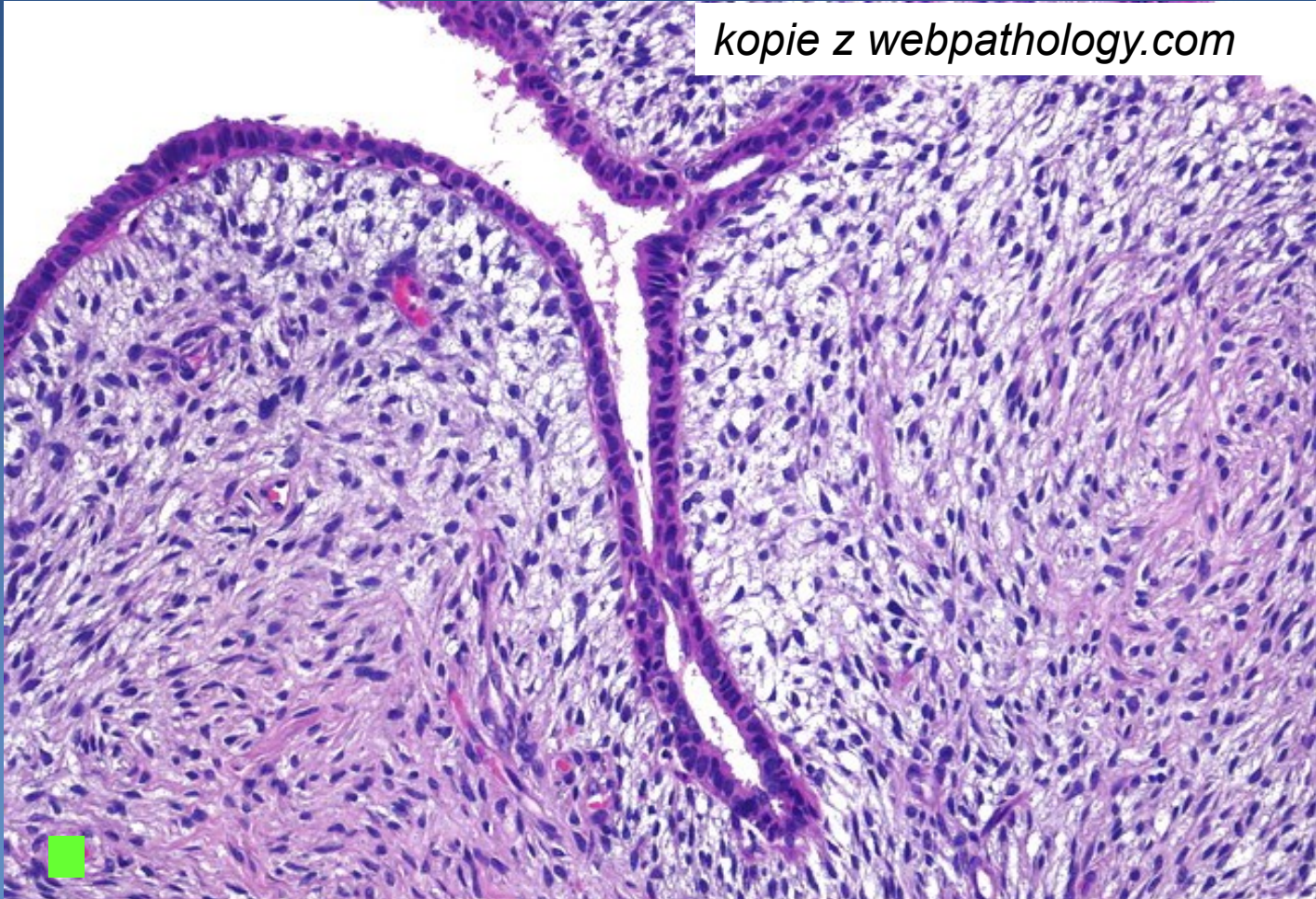
⇒ *micro similar to FA, increased stromal cellularity*

- *stromal component benign / with atypias / malignant (sarcoma)*
- *biologic behaviour:*
 - *benign*
 - *broderline*
 - *malignant*

Phyllodes tumor



kopie z webpathology.com



Hypercellular stroma compressing ducts

Male breast pathology



x gynecomastia

⇒ *most common*

- up to 30% adult males, commonly bilateral

⇒ *enlarged subareolar gland*

⇒ *hyperthyroidism, liver cirrhosis, CHRI, chronic respiratory failura, hypogonadism, hormone therapy.*

x carcinoma

⇒ *rare, hereditary risk possible (BRCA2)*

⇒ *worse general prognosis (usually late dg.)*