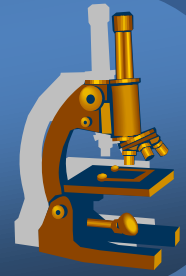


Systemic Pathology



***CARDIOVASCULAR
system***

ATHEROSCLEROSIS



- disease of large and medium-sizes arteries with lipid deposition into intima
- active inflammatory process
- endogenous risk factors, mostly noninfluenceables :
 - *age, MxF (estrogen?), familiar factors (f. hypercholesterolemia), hereditary homocysteinemia*
- exogenous risk factors:
 - *hyperlipidemia (LDL) ←←← hypothyreoidism, nephrotic sy;*
 - *hypertension, diabetes mellitus, life style smoking (nicotine, CO), sedentary life, food + obesity; ↑CRP, ↑ phosphate level (food, metabolic dysregulation)*

Atherosclerosis - pathogenesis



1. Endothelial injury

- *mechanic* (\uparrow BP, turbulence)
- *endotoxins, immune complexes, exogenous toxins (cig. smoke), \uparrow cholesterol*

\uparrow *expression of cell adhesion molecules, \uparrow permeability, \uparrow thrombogenicity*

2. Lipoprotein insudation (LDL) – **oxidation** in intima

3. Inflammation

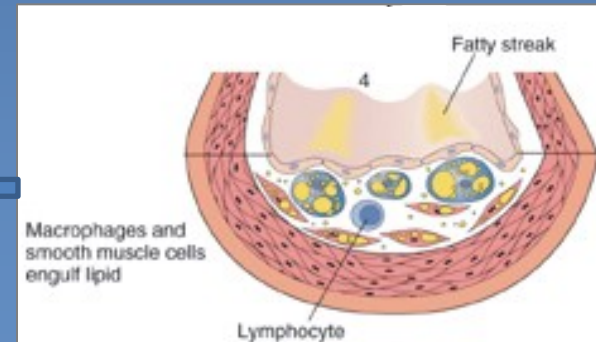
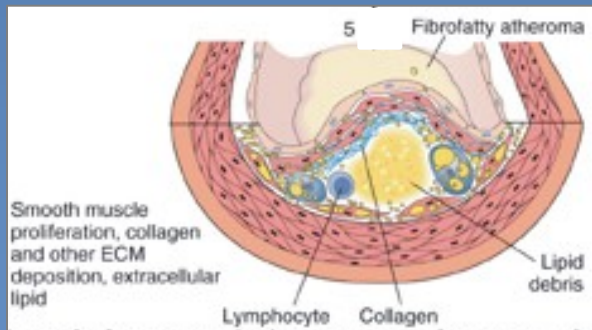
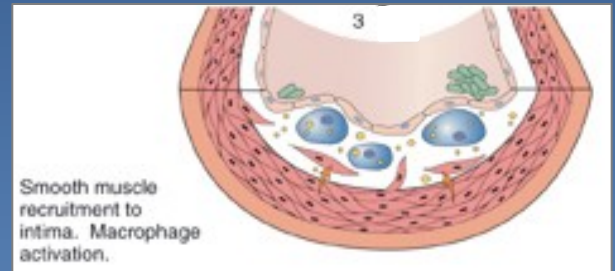
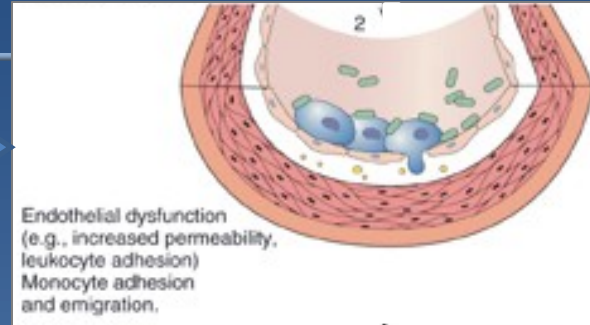
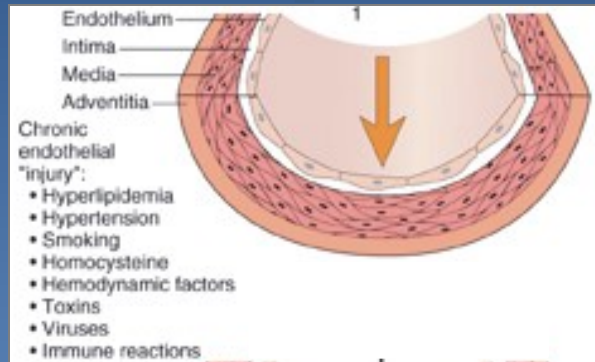
- *blood monocytes (\rightarrow foam cells), T-cells, platelets, smooth muscle cells*

4. Repair - proliferation of myointimal cells

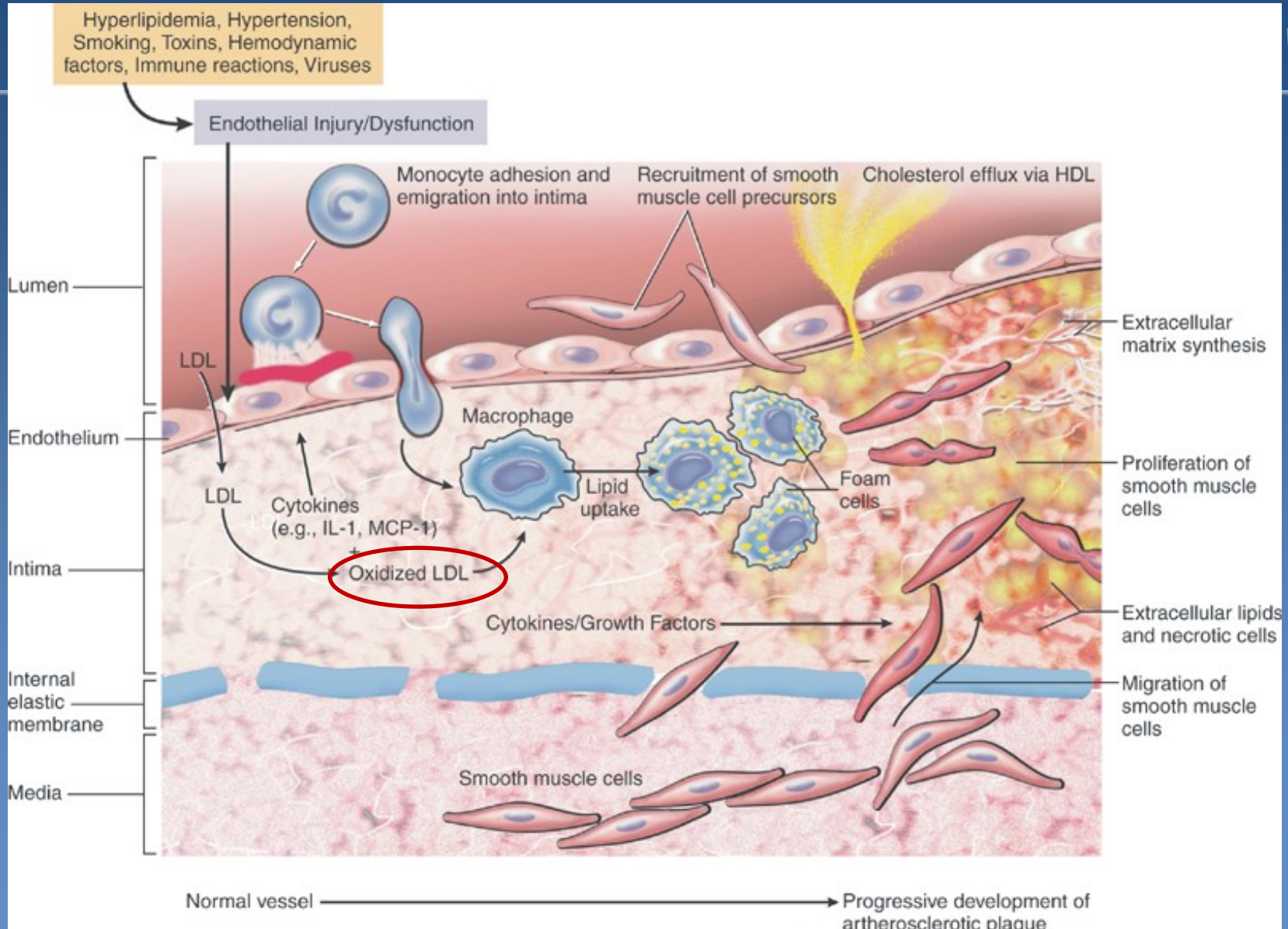
- *synthesis of collagen, elastin, proteoglycans \rightarrow **fibrotic plaque**, + lipid accumulation - **atheromatous plaque***

stable plaque under repeated inflammation turns into unstable plaque – fibrous cap + endothelium rupture - thrombus

Atherosclerosis - pathogenesis



atherosclerosis – cell interactions in an atheromatous plaque



Atherosclerosis



- ✗ fatty streak
- ✗ fibrotic plaque
- ✗ atheromatous plaque
- ✗ complicated atheromatous plaque
(ulceration, calcification, thrombosis)

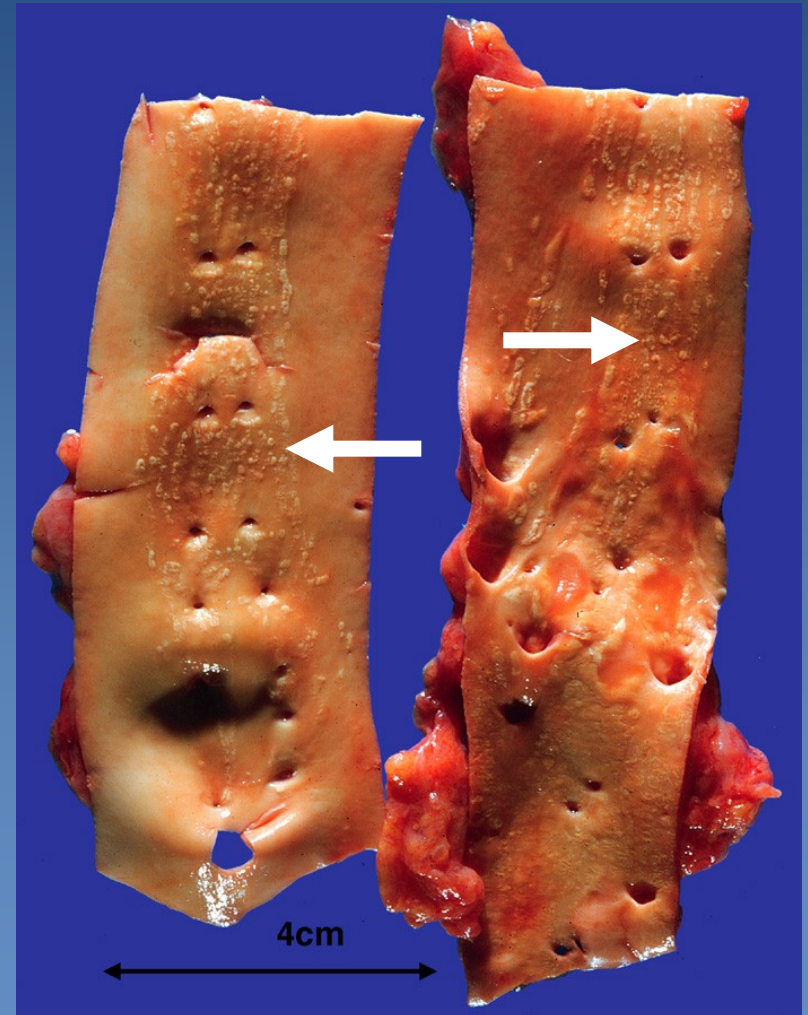
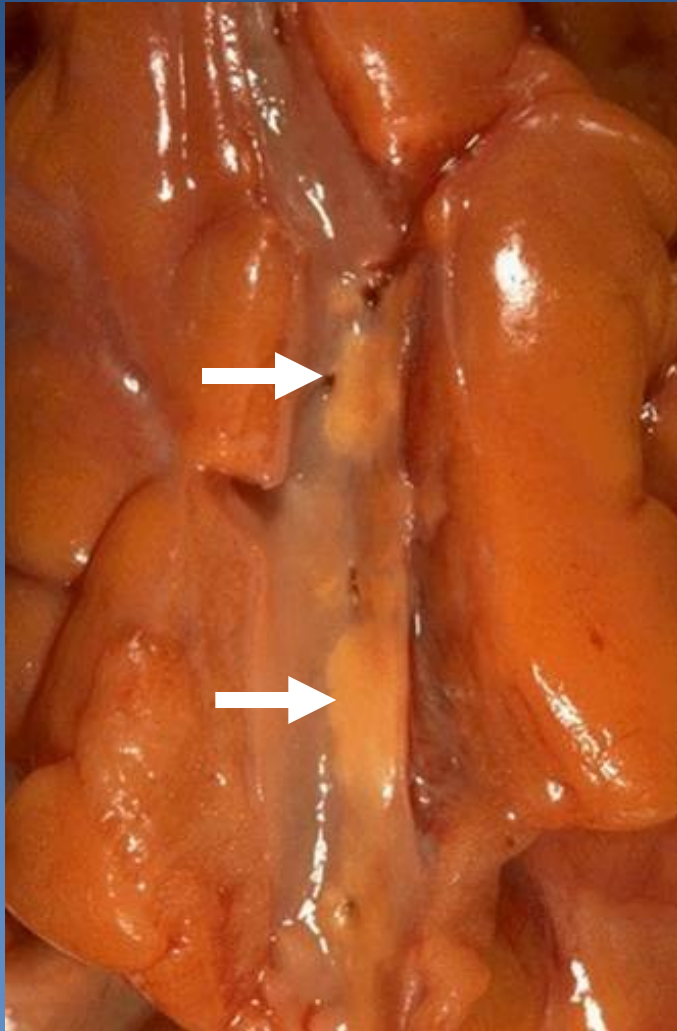
Atherosclerosis



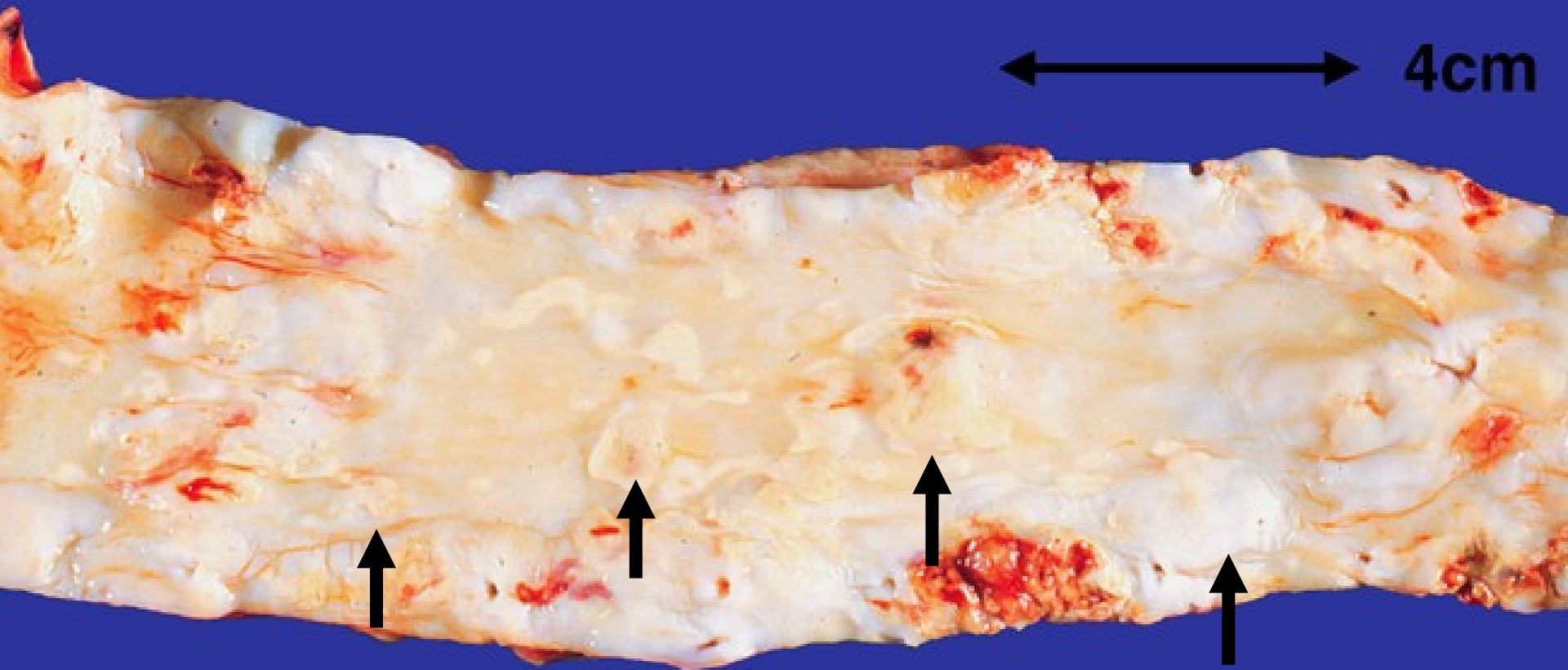
SEQUELS: arterial occlusion in situ

- ✗ chronic (→ hypoxia, atrophy)
- ✗ acute (→ ischemia, infarction, encephalomalatia)
- ✗ embolism (thrombus, plaque material)
- ✗ weakening of arterial wall (aneurysm), risk of rupture
- ✗ bleeding (from plaque, fissured wall)
- ✗ calcification (hypertensive factor)

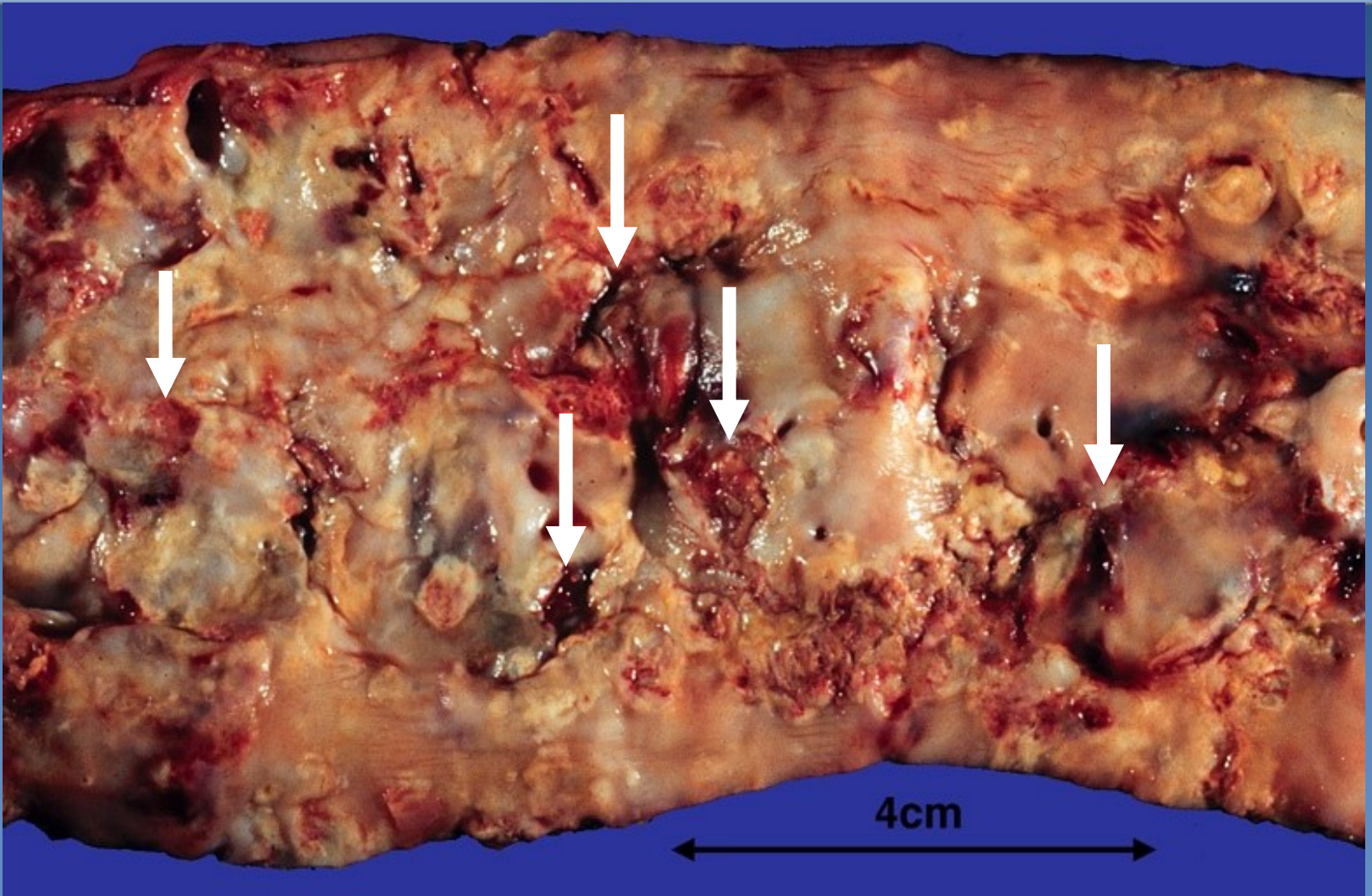
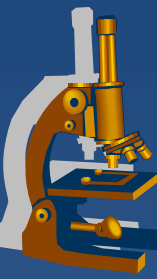
Atherosclerosis- fatty streak



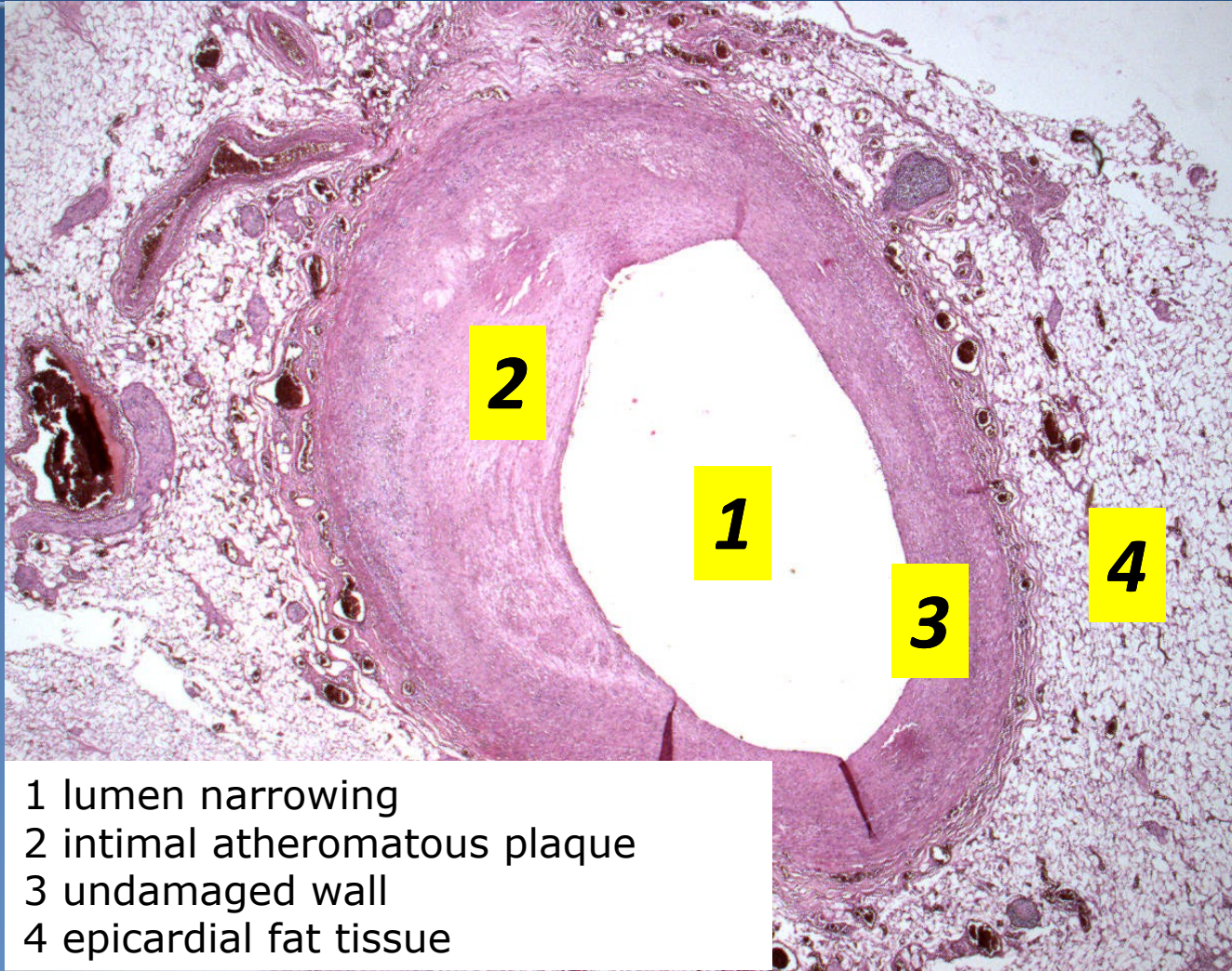
Atherosclerosis - fibrous and atheromatous plaques



Atherosclerosis- plaque ulceration, mural thrombosis

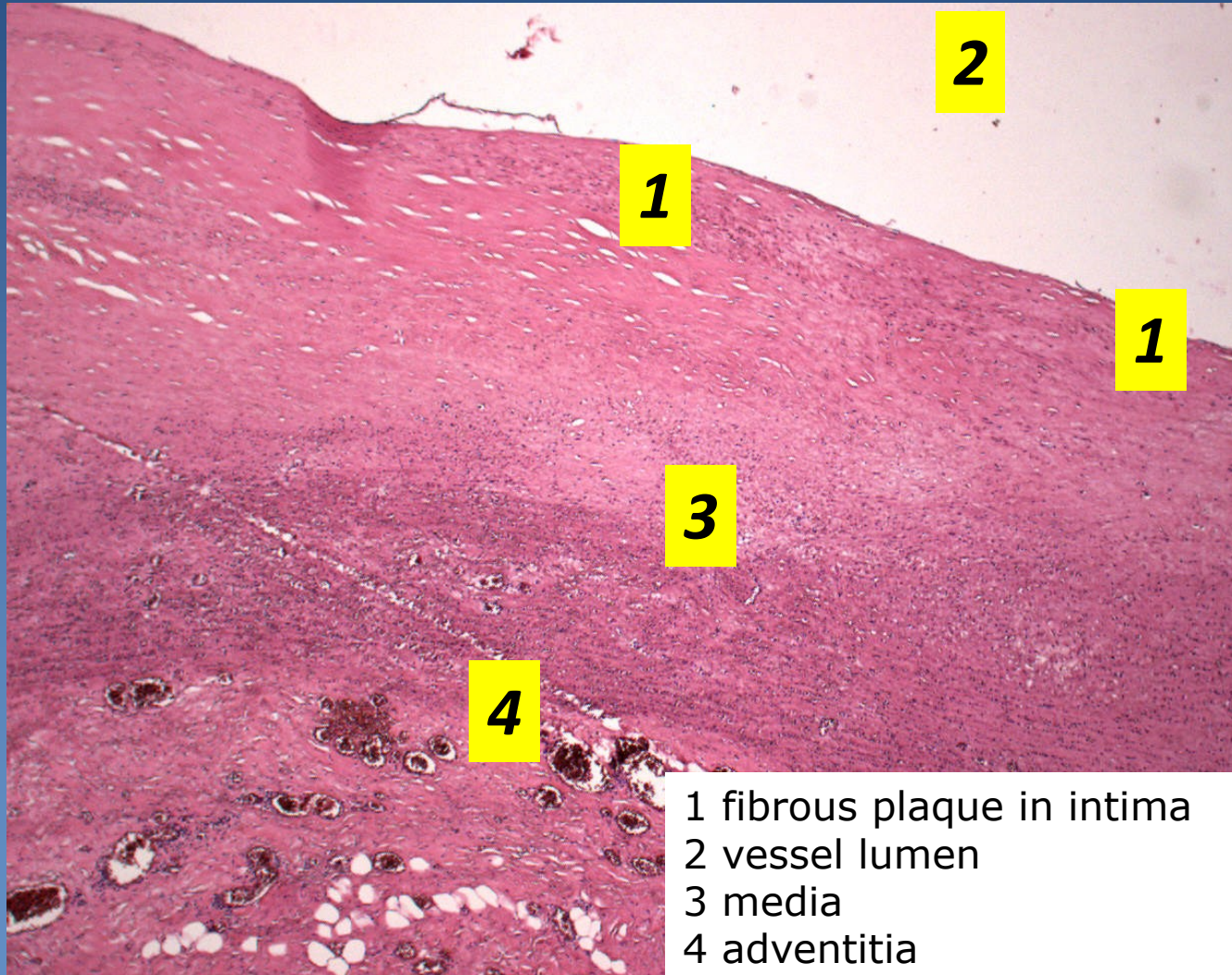


Atherosclerosis- coronary artery

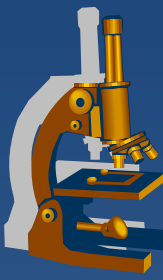


- 1 lumen narrowing
- 2 intimal atheromatous plaque
- 3 undamaged wall
- 4 epicardial fat tissue

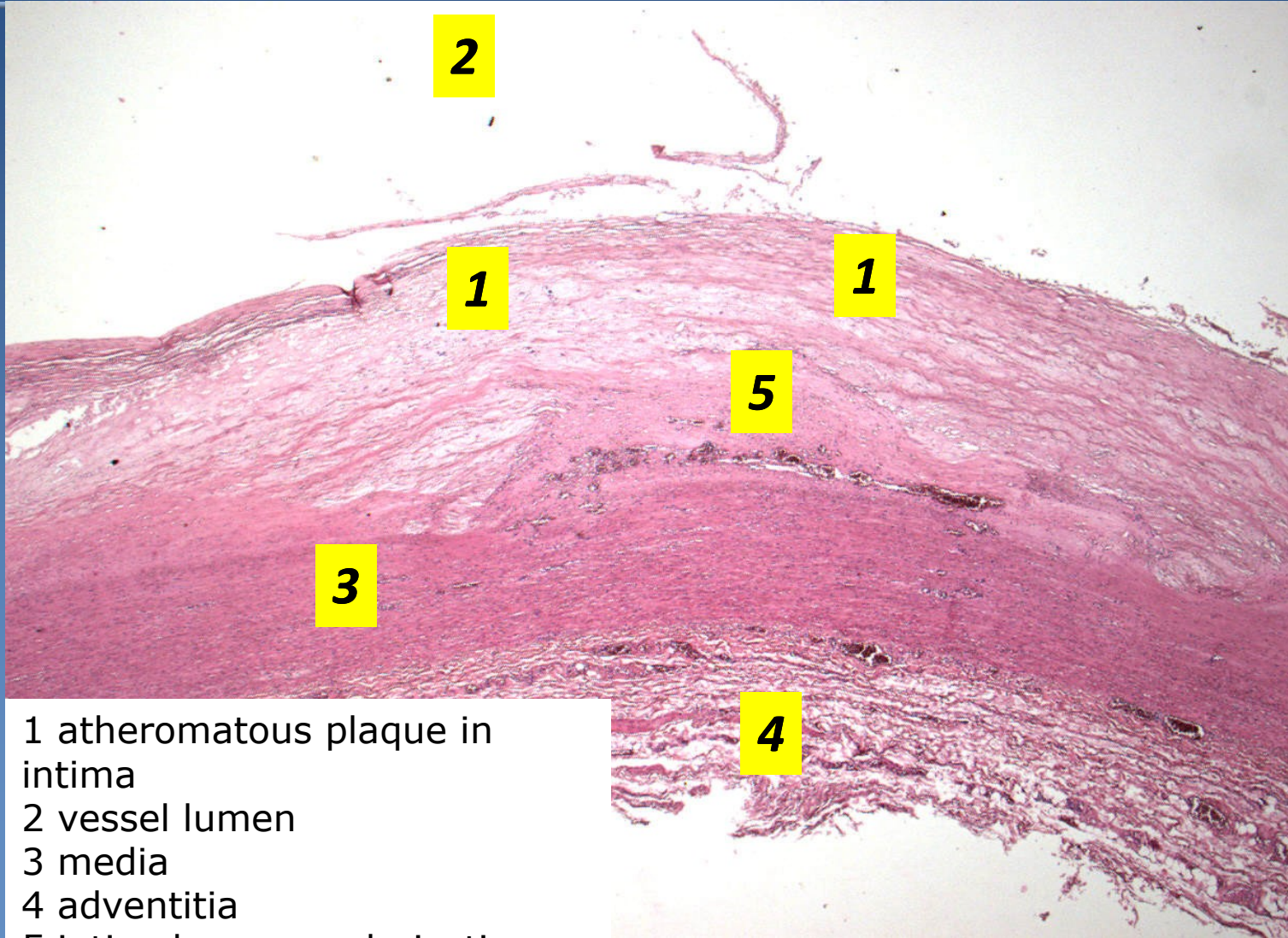
Atherosclerosis – fibrous plaque



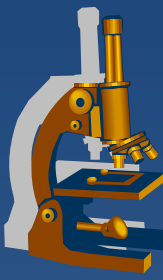
- 1 fibrous plaque in intima
- 2 vessel lumen
- 3 media
- 4 adventitia



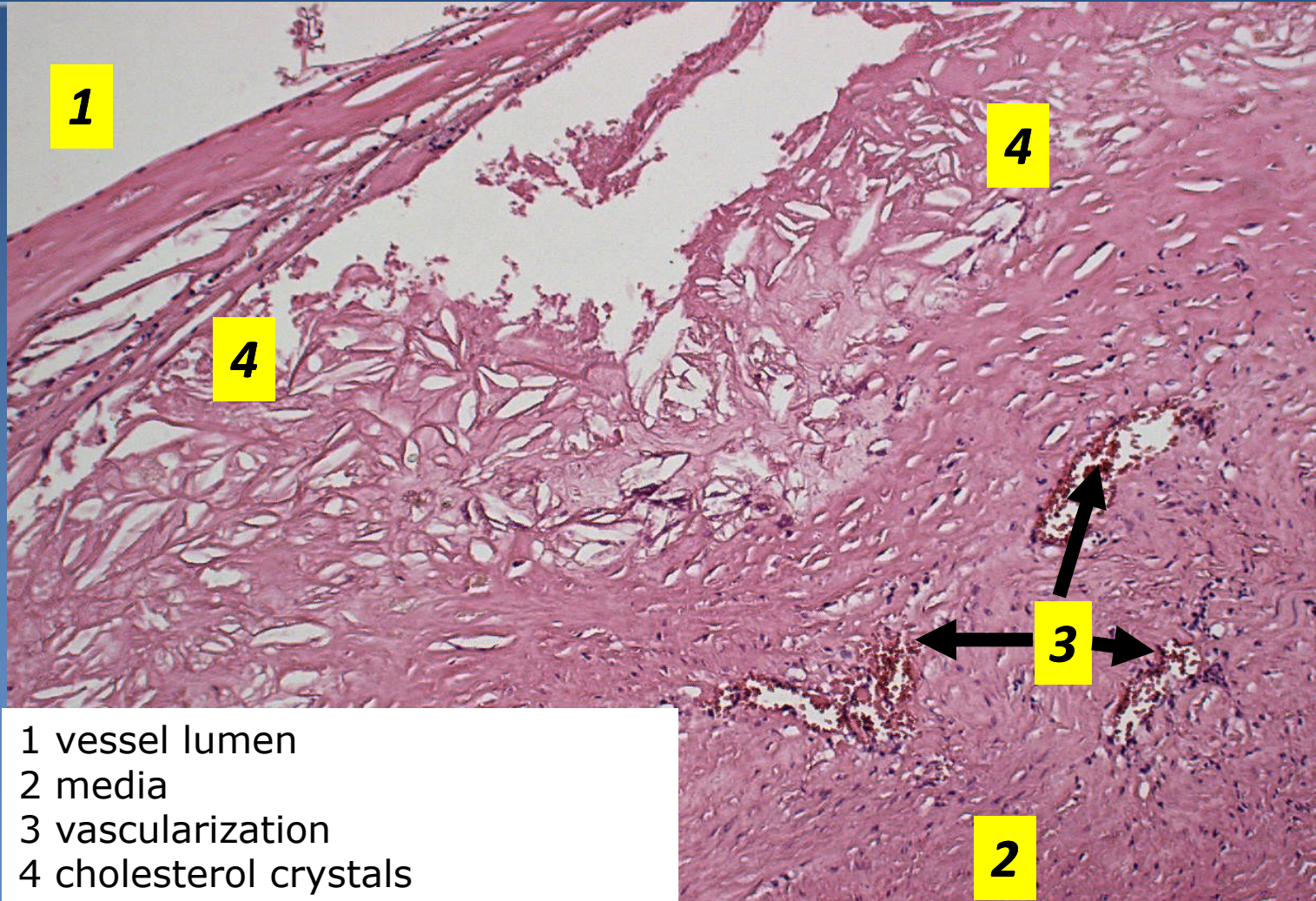
Atherosclerosis - atheromatous plaque



- 1 atheromatous plaque in intima
- 2 vessel lumen
- 3 media
- 4 adventitia
- 5 intimal neovascularization

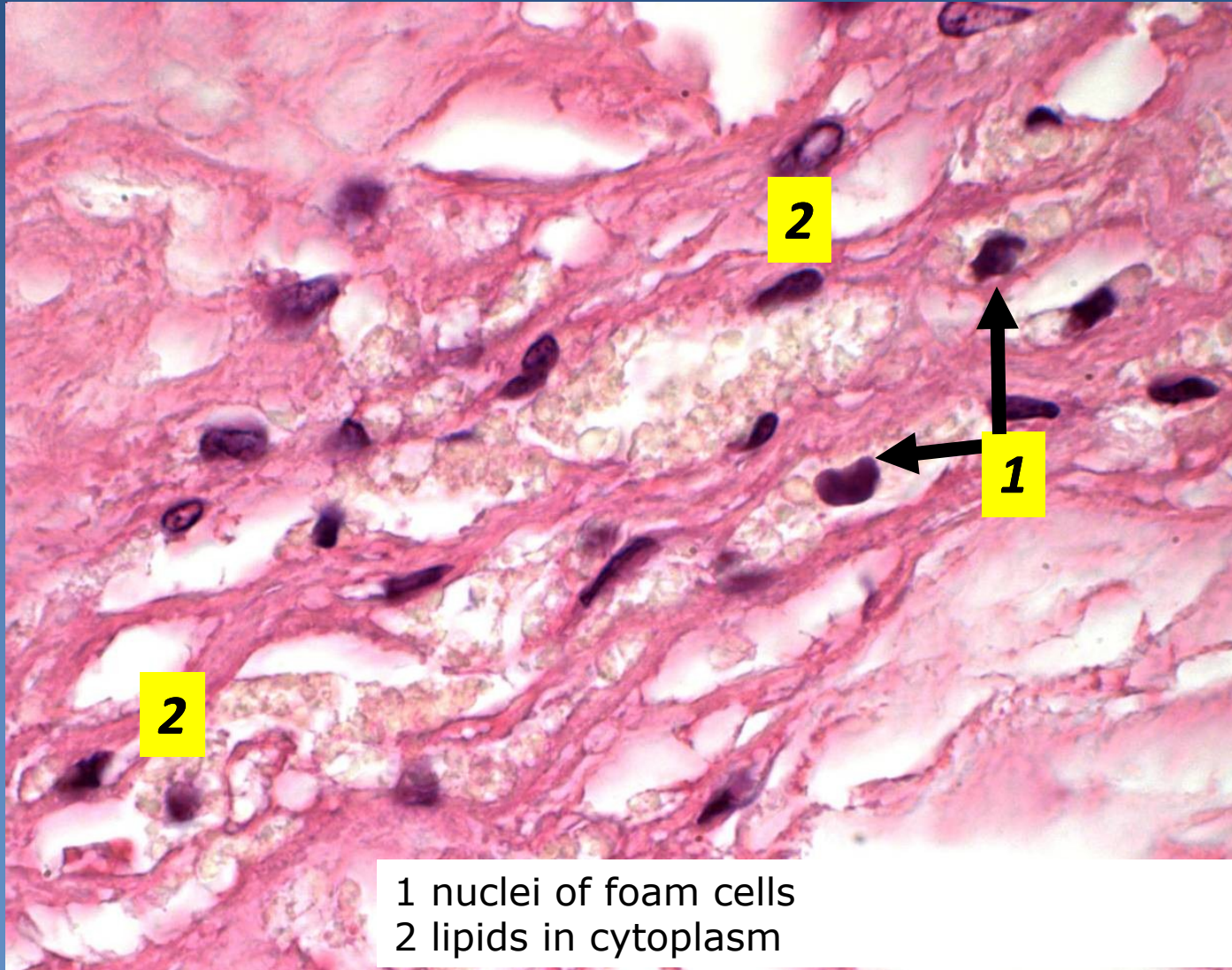


Atherosclerosis - atheromatous plaque, intimal neovascularization

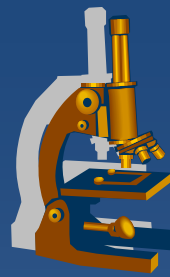


- 1 vessel lumen
- 2 media
- 3 vascularization
- 4 cholesterol crystals

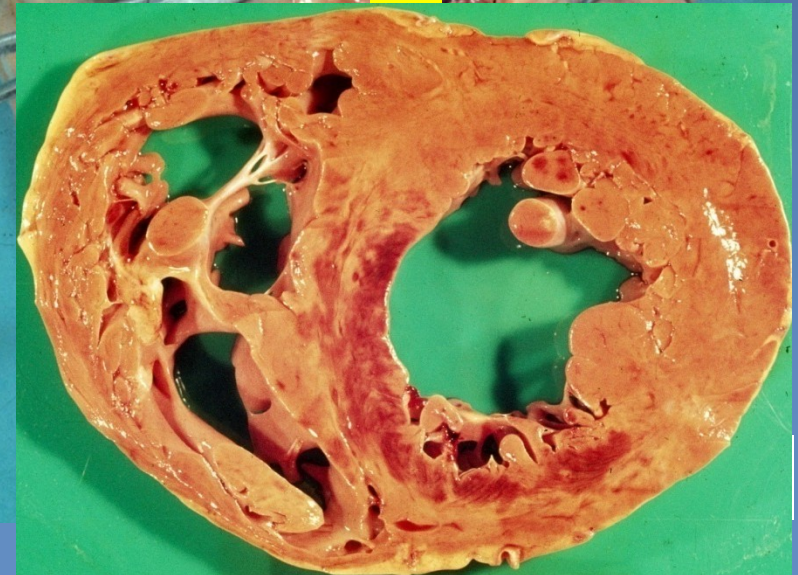
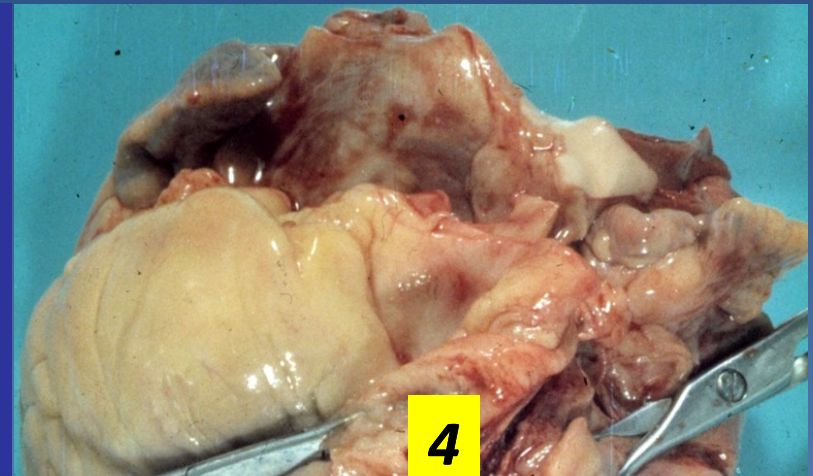
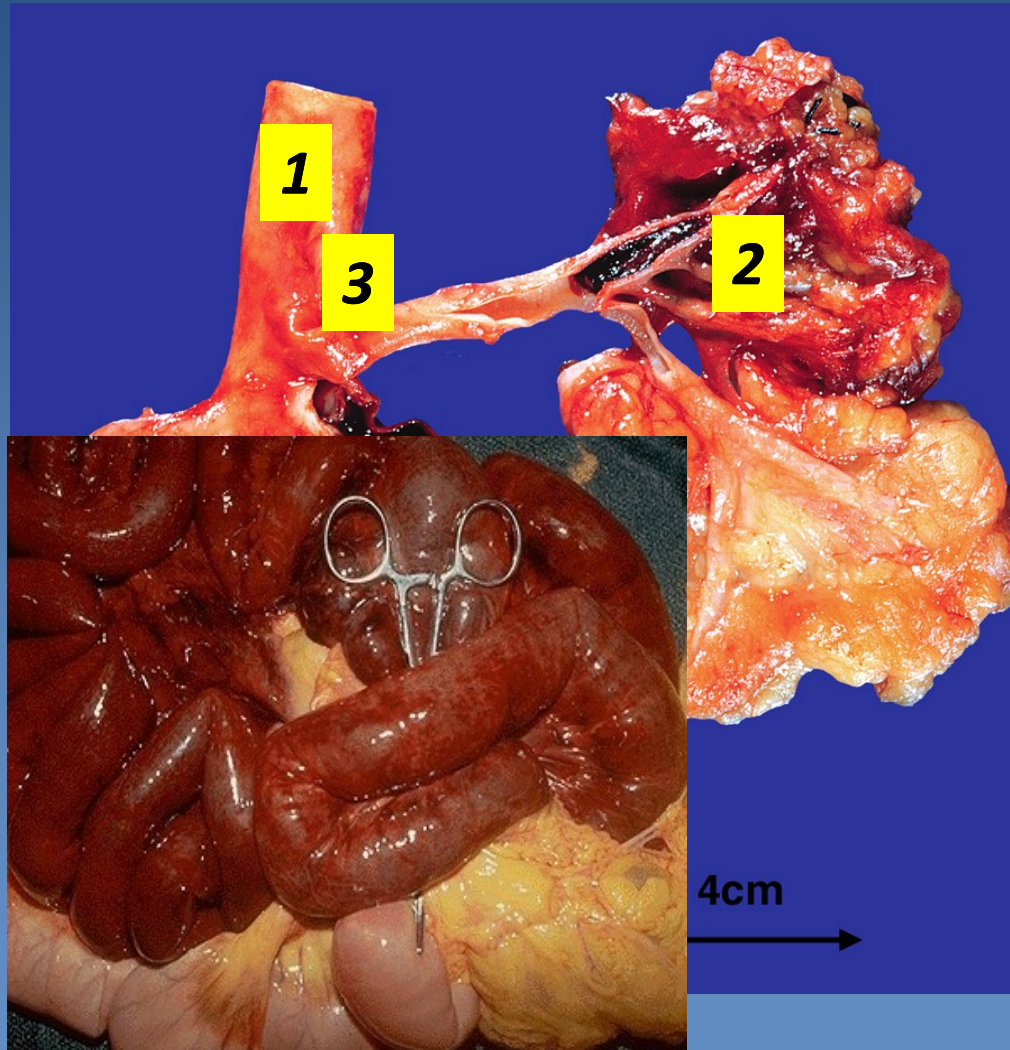
Atherosclerosis – foam cells in atheromatous plaque



1 nuclei of foam cells
2 lipids in cytoplasm



Atherosclerosis – complications thrombosis/thrombembolia

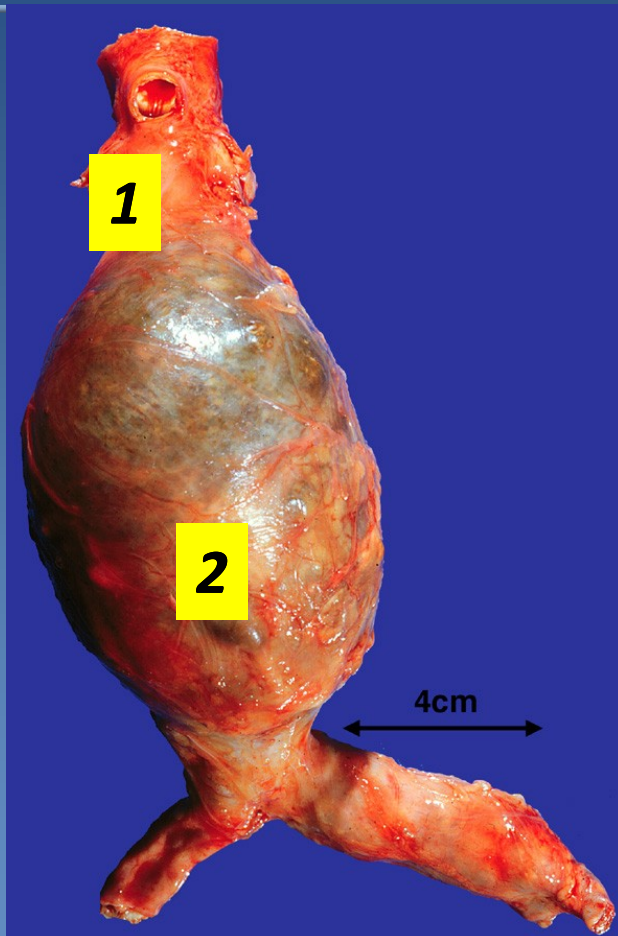


Aneurysm

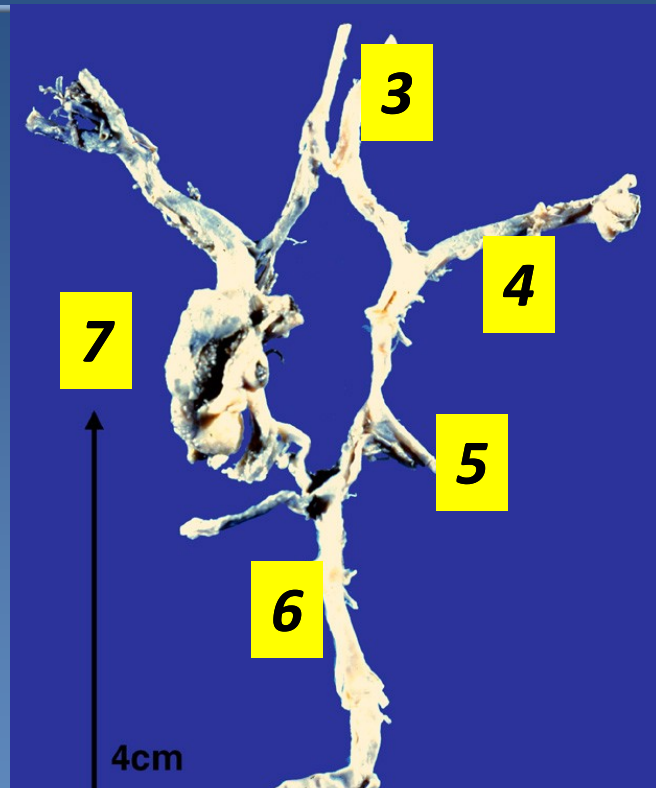


- ✗ localized, blood-filled balloon-like bulge in the wall of a blood vessel.
 - ⇒ *the circle of Willis in the brain, thoracic and abdominal aortic aneurysm*
- ✗ atherosclerotic aneurysm x syphilitic
- ✗ etiology:
 - ⇒ *hereditary defects in the structure, atherosclerosis, inflammation, perifocal disease process, accidents ...*
- ✗ false aneurysm
- ✗ serpentine aneurysm, arteriovenous aneurysm

Atherosclerosis - complications - aneurysm



1 abdominal aorta
2 aneurysm



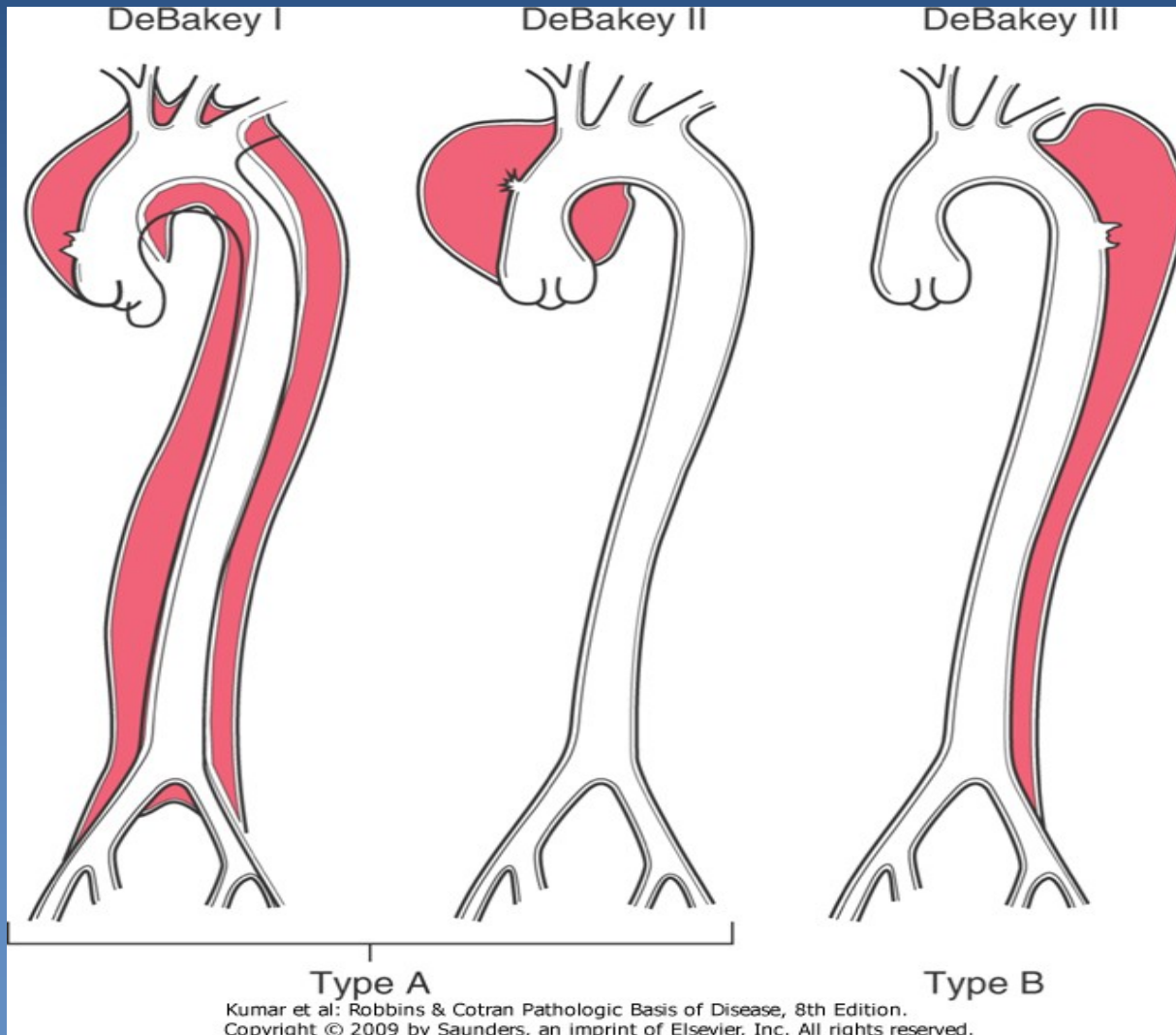
3 a. cerebri anterior
4 a. cerebri media
5 a. cerebri posterior
6 a. basilaris
7 aneurysm

Aortic dissection

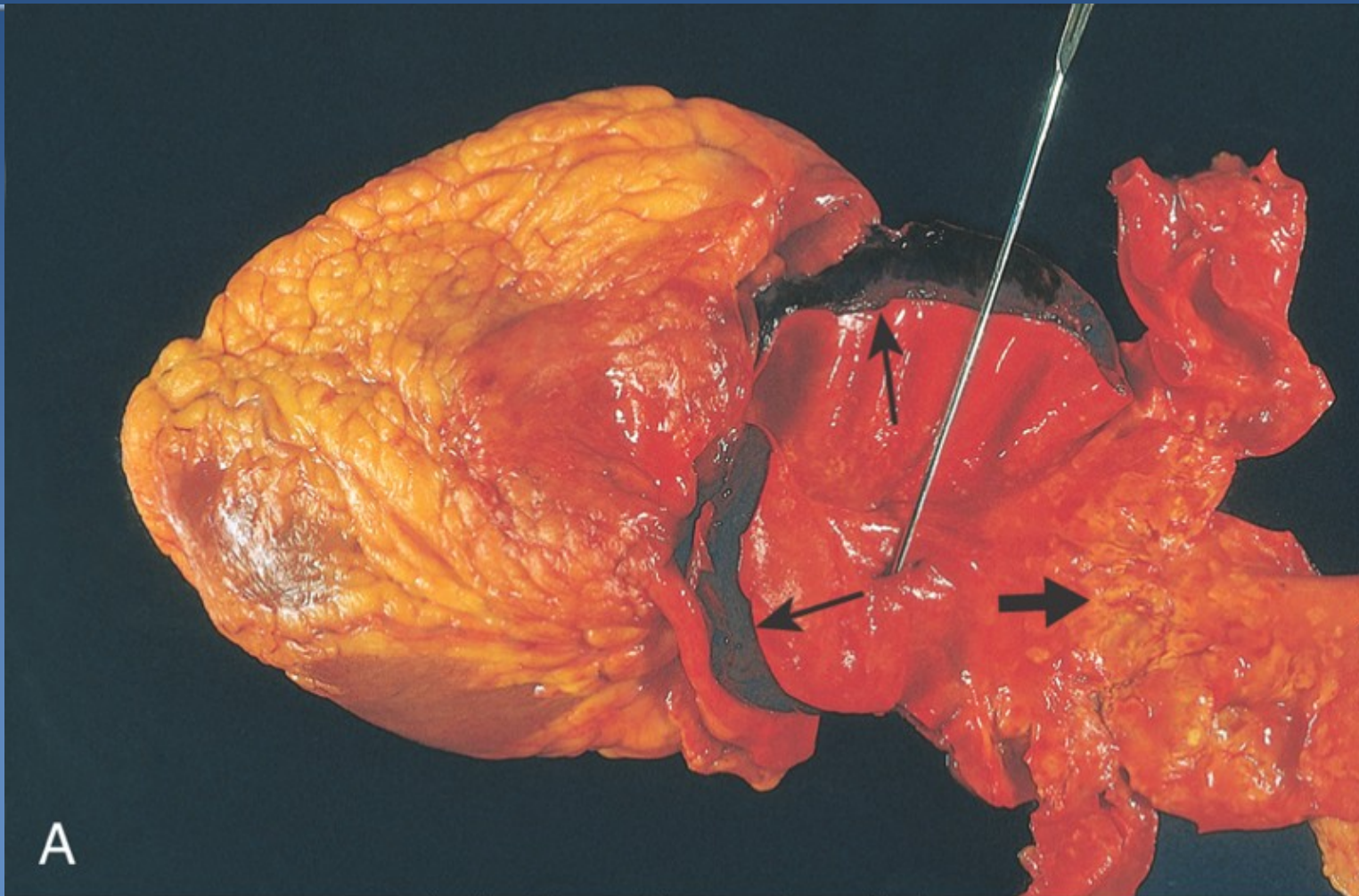


- ✗ tear in aortic intima - intramural bleeding through media, false lumen, possible „double-barreled“ aorta
- ✗ typical in ascending aorta, 1–8 cm above aortic valve
- ✗ ante– and retrograde spread to the aortic root
- ✗ common thrombosis in false lumen
- ✗ risk of external rupture (→ **hemoperikardium**), progression at the aortic branches (→ **variable organ's ischemia**), **heart failure**
- ✗ predisposition – hypertension, Marfan sy, cystic medial necrosis, ...

Aortic dissection




Aortic dissection

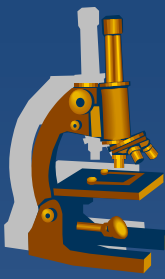


Kumar et al: Robbins & Cotran Pathologic Basis of Disease, 8th Edition.
Copyright © 2009 by Saunders, an imprint of Elsevier, Inc. All rights reserved.

Aortic dissection



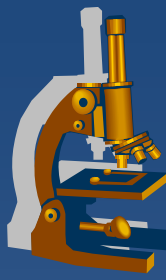
Arteriosclerosis



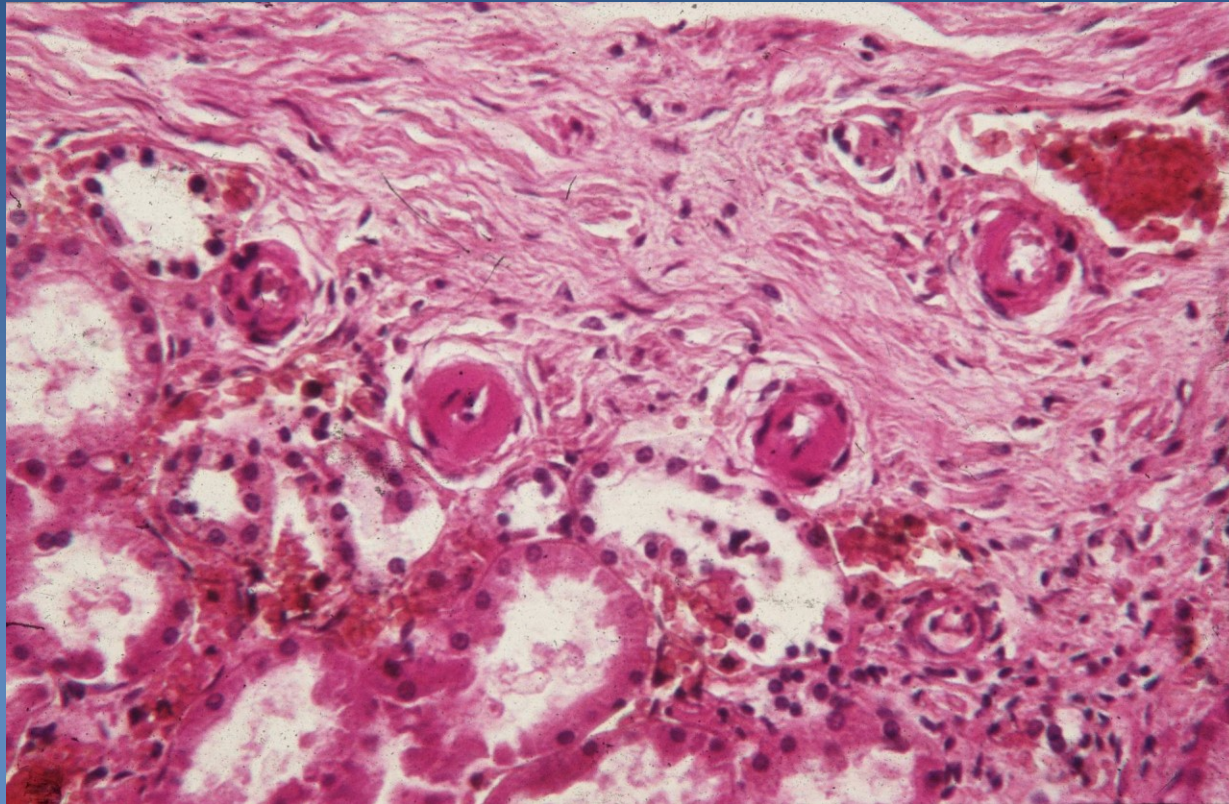
- ✗ in muscular arteries
- ✗ smooth muscle hypertrophy
- ✗ intimal fibrosis
- ✗ collagenisation of elastic membrane
- ✗ hyalinisation (hyaline a.)

age and/or hypertension related changes

→ nephrosclerosis, cerebral ischemia, ...



Hyaline arteriolosclerosis



VASCULITIS



- ✗ Vessel wall inflammation
- ✗ signs: local (ischaemia, necrosis – infarction, ulceration); systemic
- ✗ Classification according cause: **infectious x non-infectious** (commonly immune-mediated, ANCA+/ANCA-)
- ✗ Affected organs : all organs with vessels
- ✗ Type (size) of vessel involved: Large-vessel
Medium-vessel
Small-vessel

Vasculitis



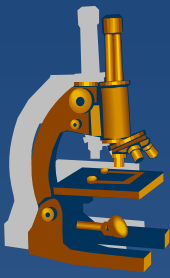
× **ANCA⁺ vasculitis** (dangerous, even fatal within a few years, if not recognised)

- ⇒ *Wegener granulomatosis*
- ⇒ *Churg-Strauss syndrome*
- ⇒ *microscopic polyangiitis*

× **ANCA⁻ vaskulitis:**

- ⇒ *polyarteritis nodosa*
- ⇒ *Kawasaki disease*
- ⇒ *giant-cell arteriitis (Horton, temporal)*
- ⇒ *Takayasu arteriitis*
- ⇒ *thrombangiitis obliterans (Bürger disease)*
- ⇒ *leukocytoclastic (allergic) vasculitis – cca 30%*

Etiology



× **immune-mediated/associated process**

× **infection**

⇒ *ie. streptococcus, ...*

⇒ *direct cause of infective v., or trigger factor of pathological immune processes*

× **other**

Possible clinical signs of systemic vasculitis



ORL: - repeated respiratory tract inflammation

- exudate rich in plasma cells + eosinophils

Kidney: - glomerulonephritis

Lung: - variable presentation of lung diseases + hemoptysis

Skin: - ulceration, necrosis, petechiae-purpura

GIT: - ischemic ulcerations (sharply demarcated, without HP, minimal inflammation)

Chronic debilitating disease – clinical signs of tumor!!

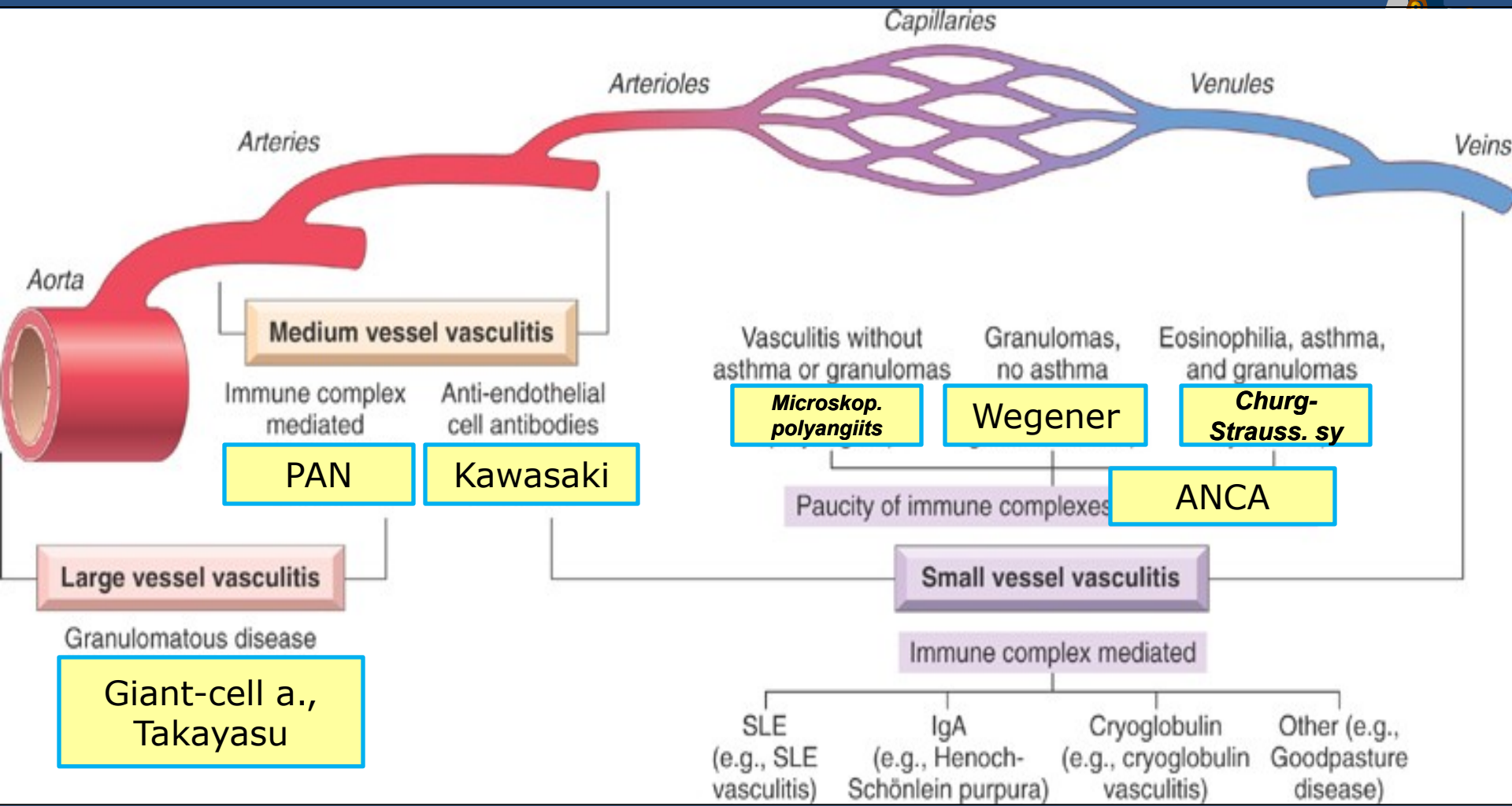
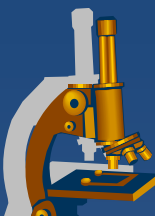
Patient presentation



- fever, nausea, myalgia, arthralgia
 - skin purpura
 - signs of nephritis
 - abdominal pain



general malaise (~ severe influenza, long duration, resistant to usual therapy)
sinusoid course (relapse --- remission --- relapse--)



ANCA+ vasculitis



× incidence ?????

⇒ ≤20/1mil. inhabitants

⇒ age 65+ - 53/1mil. inhabitants

× prognosis:

⇒ untreated ANCA⁺ vasculitis ≥80% fatal in 2 yrs

⇒ treated ANCA⁺ vasculitis : ≥80% survives 5 yrs

⇒ renal failure in elders >70 yrs - in 40% due to ANCA⁺ vasculitis

granulomatosis with polyangiitis (Wegener granulomatosis)

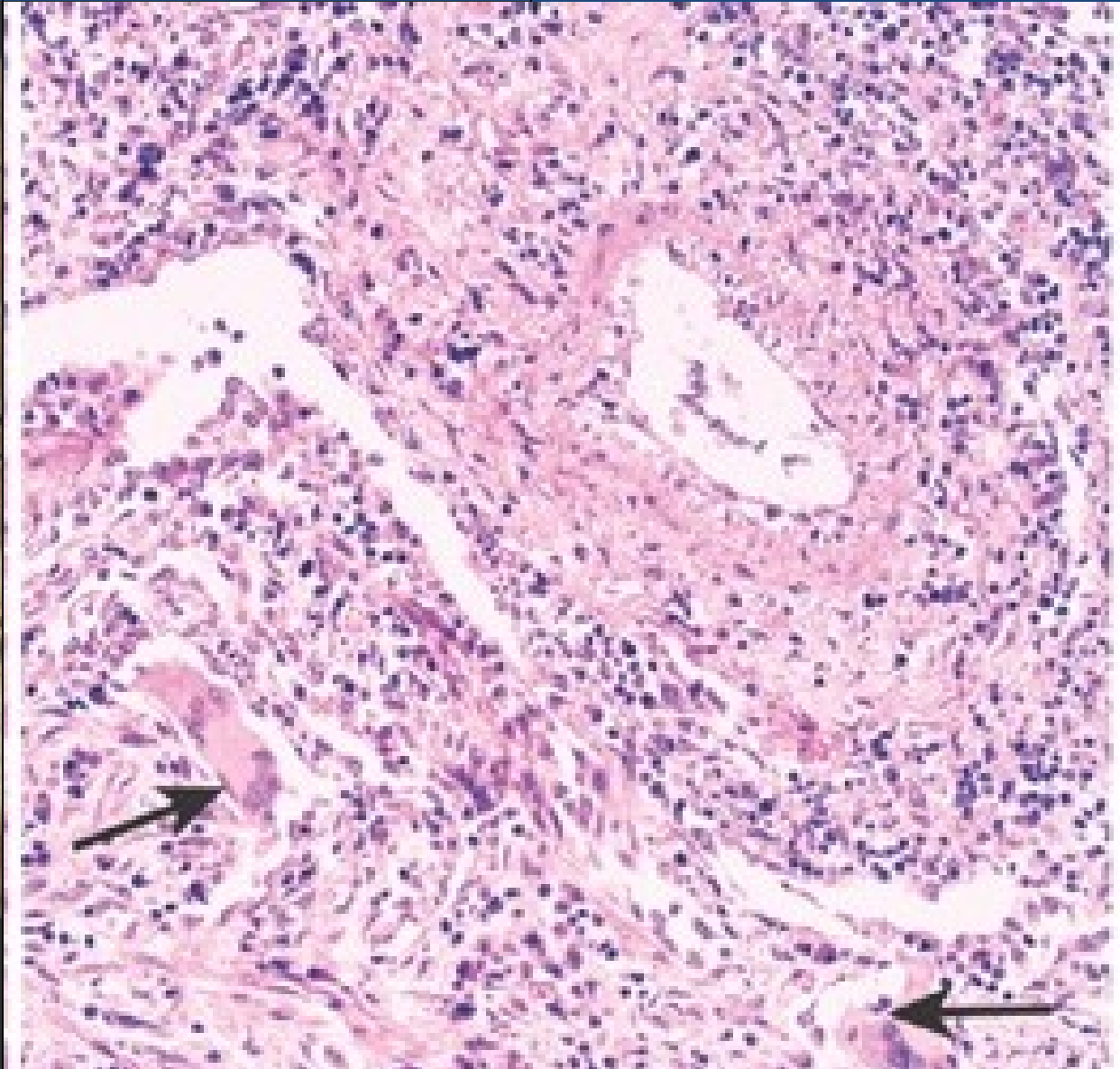


- ✗ clinically as **pneumonitis**, persistent X-ray with bilat. nodular infiltrates, **chronic sinusitis** with mucosal **ulcerations of nasopharynx** (sometimes destructive axial structures), **ARI / CHRI** (focal necrosis, sickle cell GLN)

granulomatosis with polyangiitis (Wegener granulomatosis)



- ✘ persistent pneumonitis (95%) – nodular infiltrates
- ✘ chronic sinusitis (90%) – ulcerations, event. Destructive
- ✘ renal disease (80%) – glomerulonephritis
- ✘ other features: rashes, muscle pains, articular involvement, mono-/polyneuritis



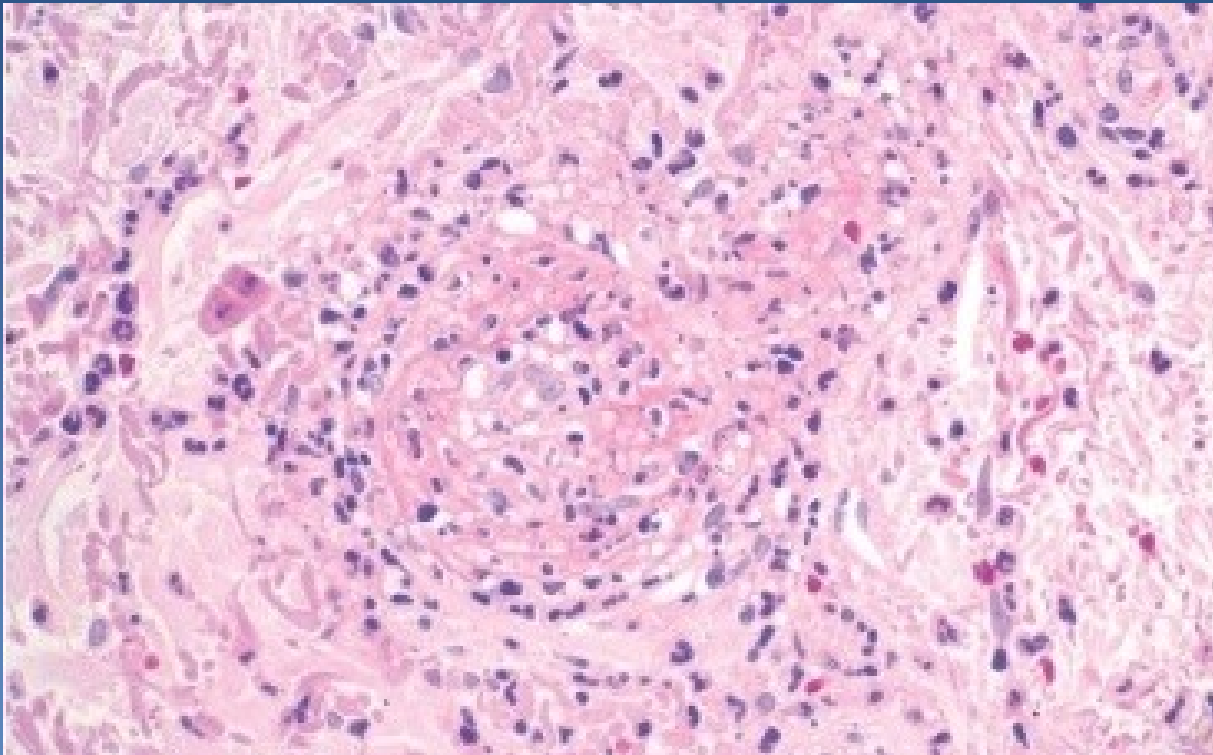
Small vessel vasculitis with giant-cell granulomatous reaction

ANCA+ VASCULITIS: microscopic polyangiitis



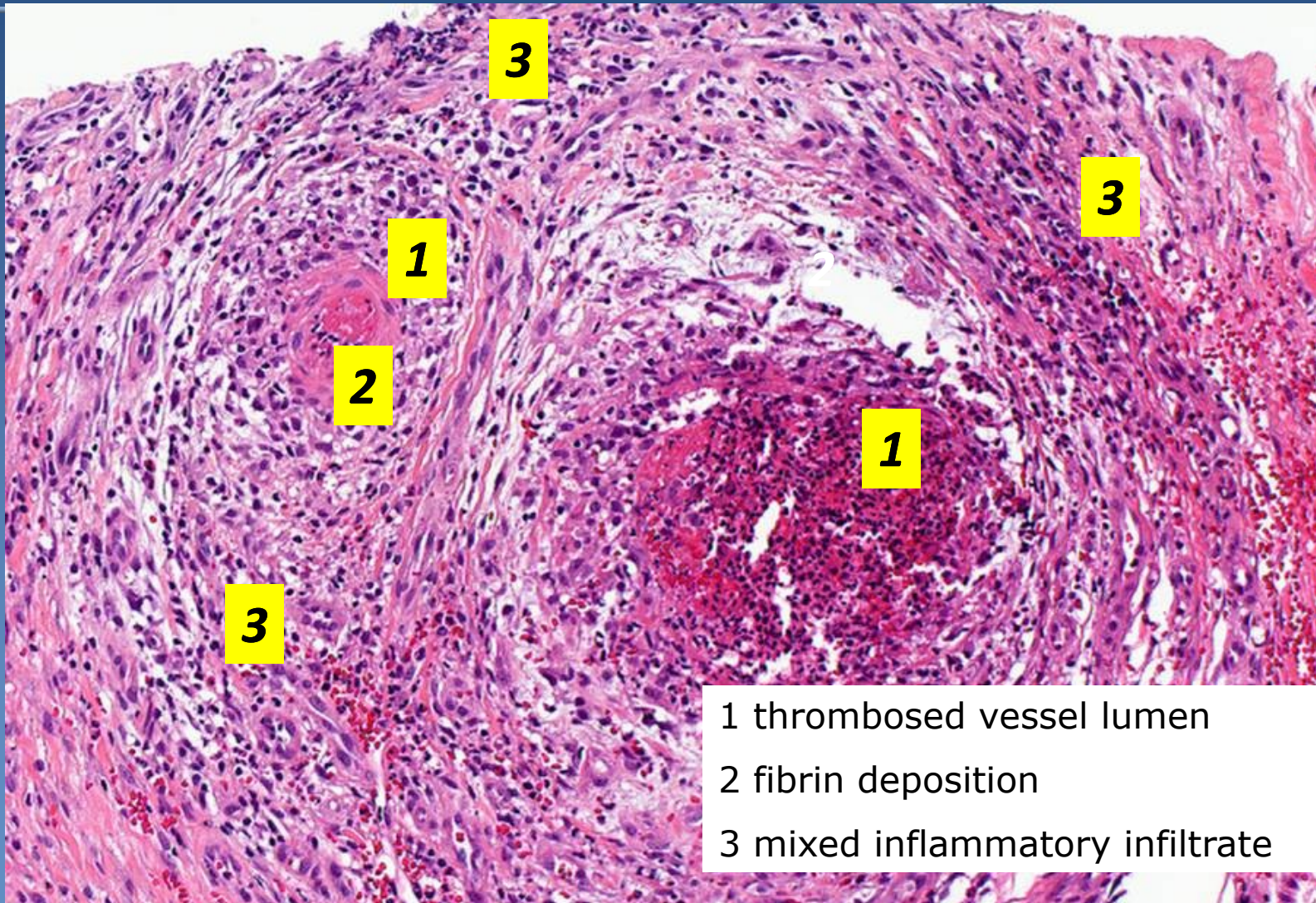
- ✗ ANCA in approx. 70% (remaining by immune complexes or antibodies)
- ✗ = **necrotizing vasculitis** arterioles, capillaries, venules (synonyms: leukocytoclastic v., hypersensitive v., allergic v.)
- ✗ : **SKIN**, kidney, lung, GIT, brain...
- ✗ highly variable etiopathogenesis (part of systemic connective tissue diseases; allergic response to exogenous antigens – bacteria, viruses, drugs)
- ✗ micro:
 - ⇒ *fibrinoid necrosis of vessel wall with neutrophils and chromatin fragments from neutrophil's nuclei - leukocytoclastic*
 - ⇒ *all lesions in the same stage of evolution* (X *polyarteritis nodosa*)

leukocytoclastic vasculitis



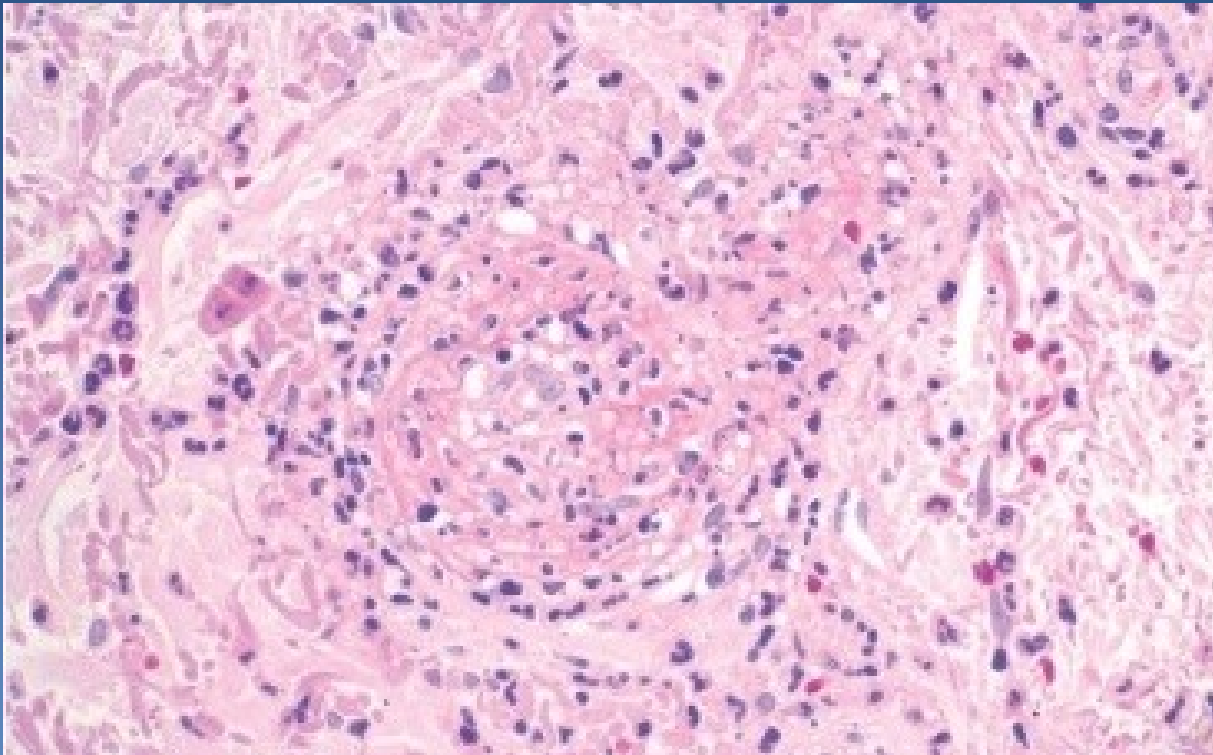
nuclear fragments from neutrophils in a small vessel wall

polyarteritis nodosa



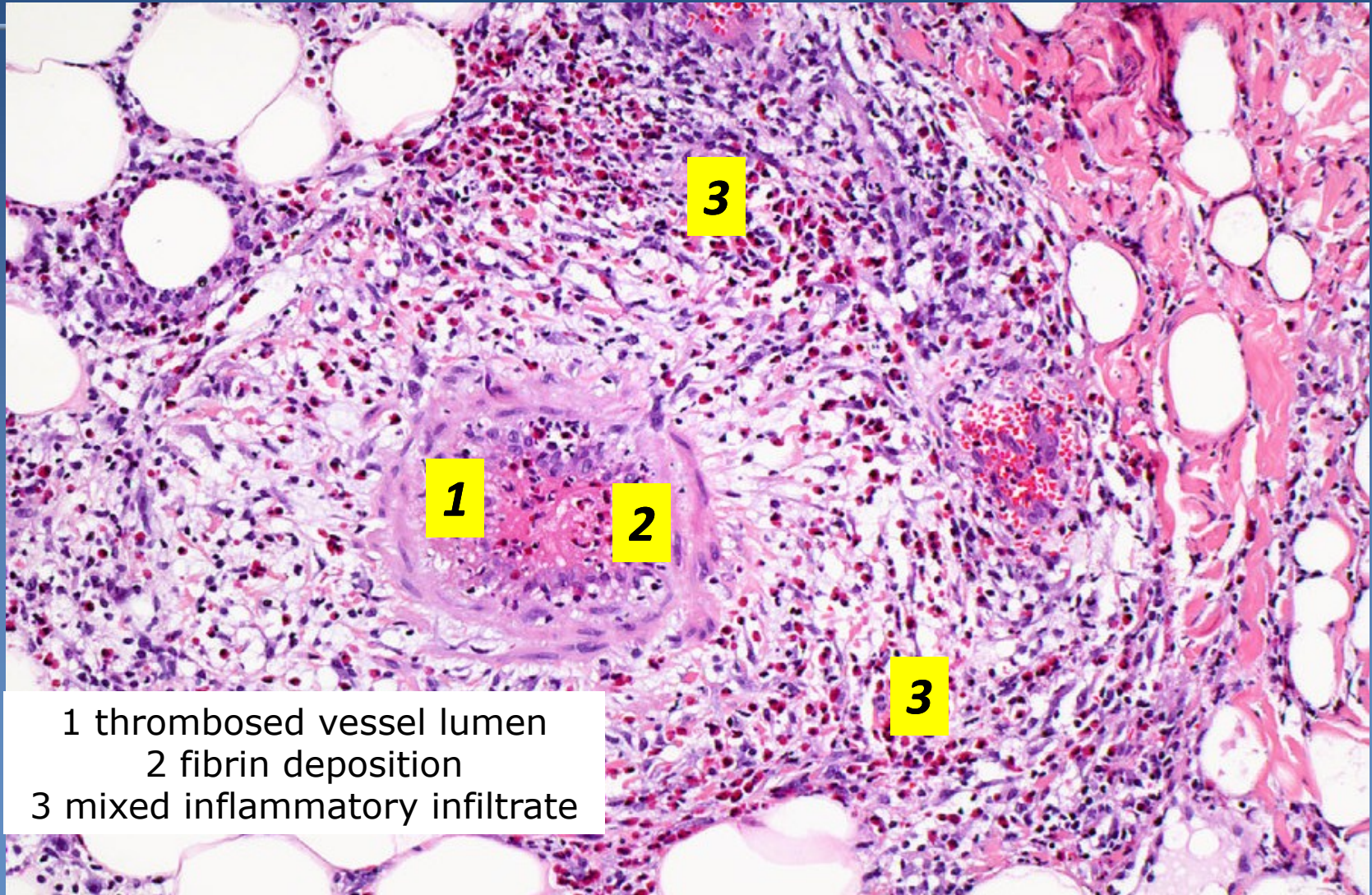
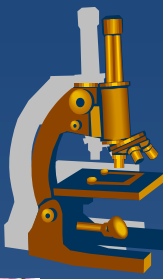
- 1 thrombosed vessel lumen
- 2 fibrin deposition
- 3 mixed inflammatory infiltrate

leukocytoclastic vasculitis



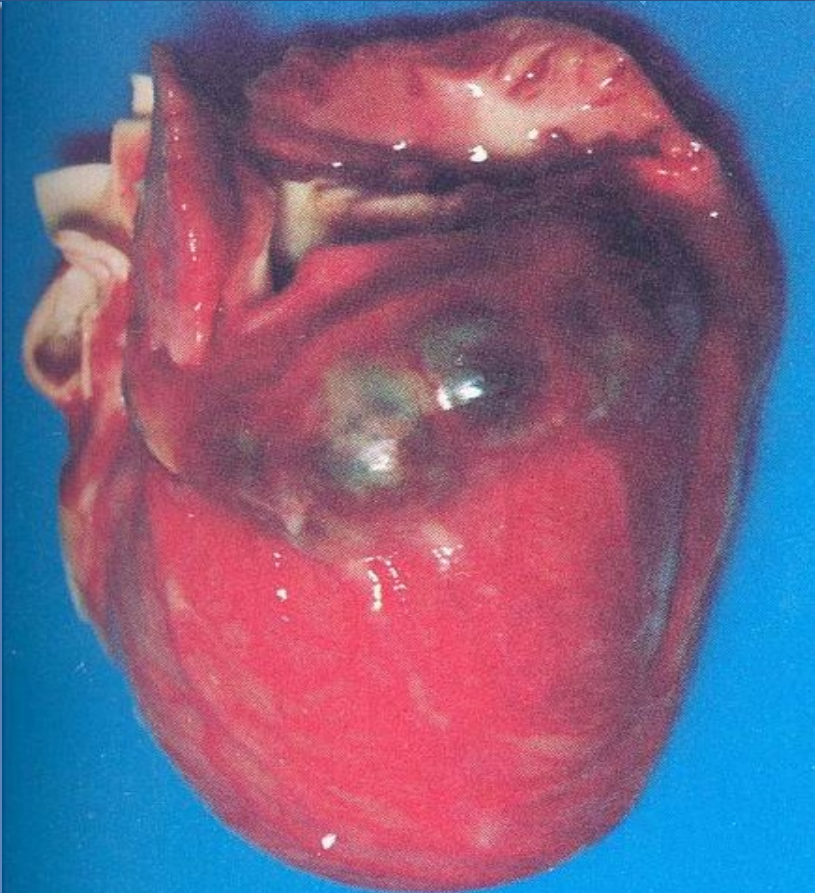
nuclear fragments from neutrophils in a small vessel wall

polyartereritis nodosa

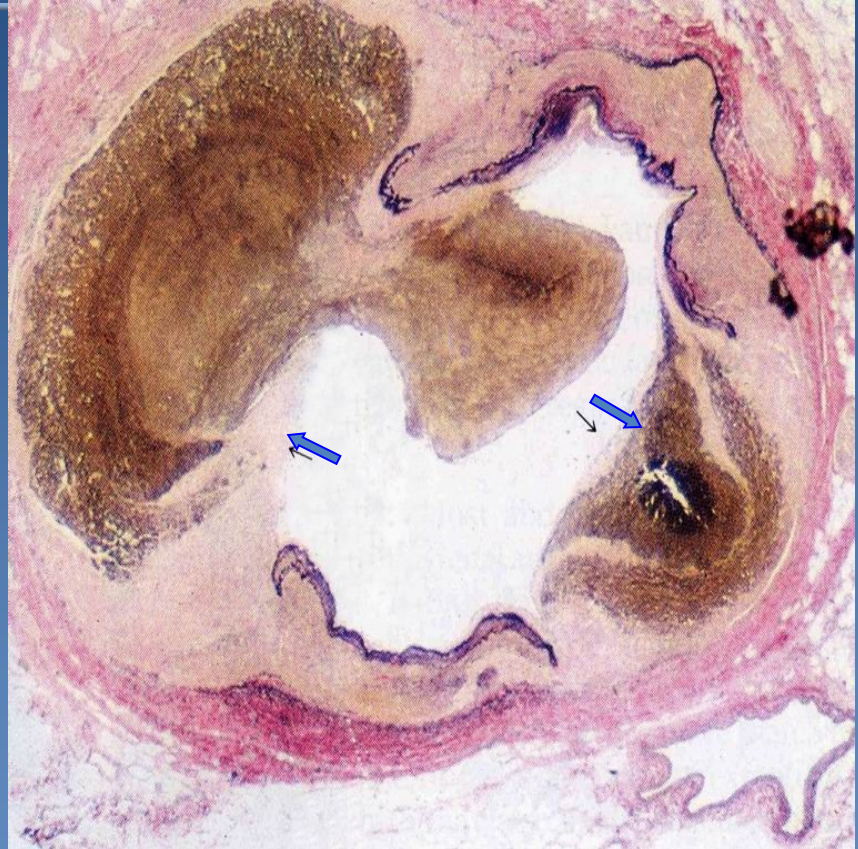


1 thrombosed vessel lumen
2 fibrin deposition
3 mixed inflammatory infiltrate

Kawasaki disease

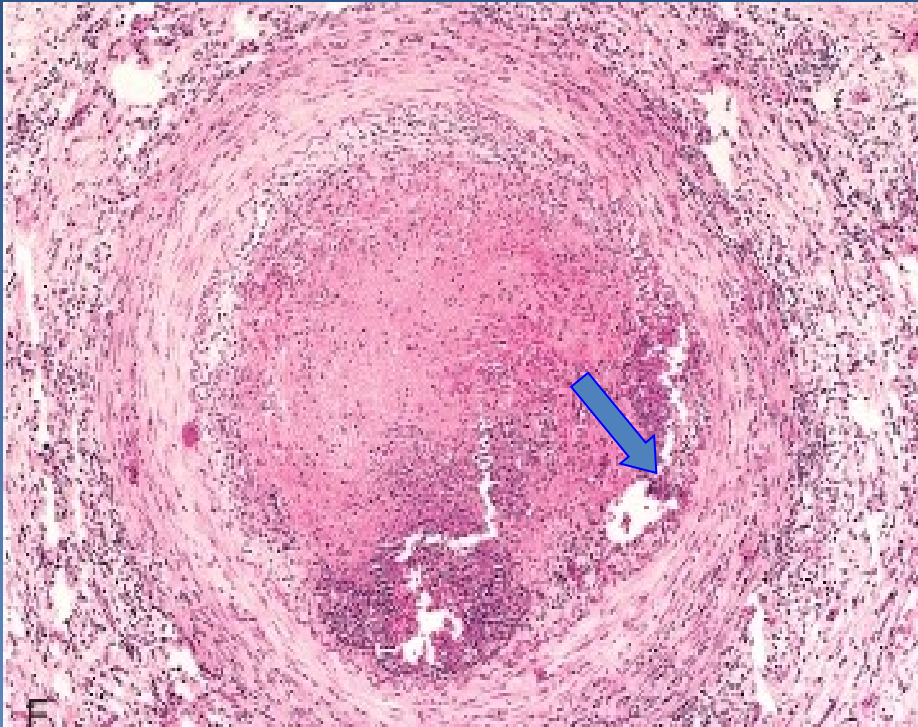


Coronary aneurysms in a child' heart

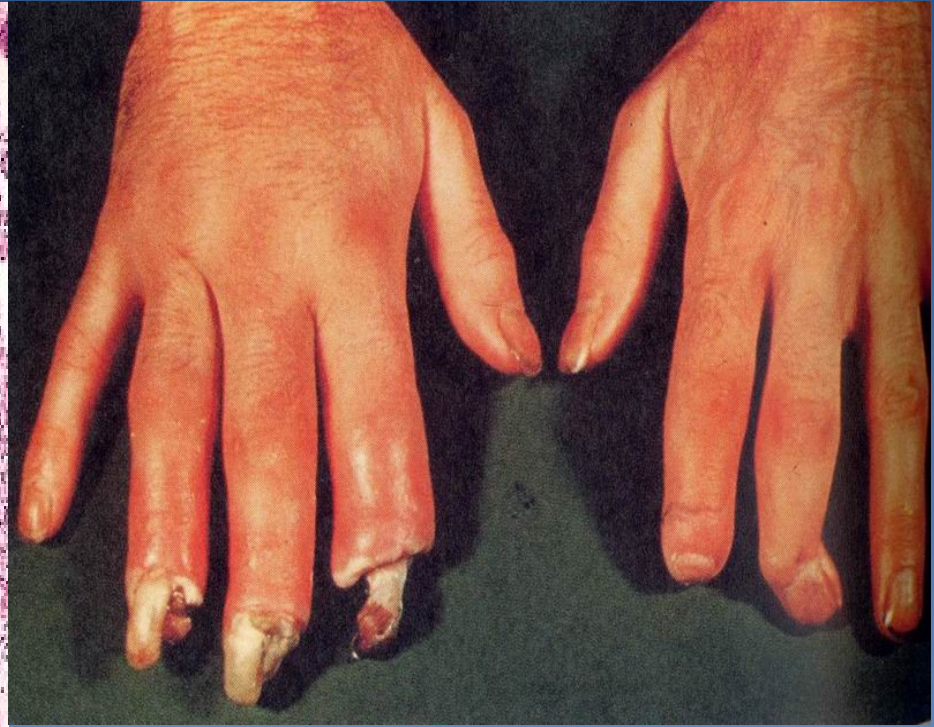

coronary artery with lamina elastica interna defects (arrows) and thrombotized aneurysms

Thrombangiitis obliterans (*Bürger disease*)



Obliterative thrombosis with granuloma with central microabscess (arrow)



acral necroses

infectious vasculitis



× rare

× cause:

- ⇒ *direct transfer of infection from surrounding tissues*
- ⇒ *infected emboli during pyemia*

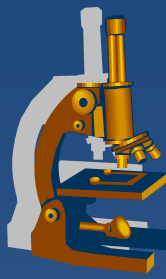
× bacterial (commonly in sepsis):

- ⇒ *Staph., Strep., Neisseria*
- ⇒ *G- rods*
- ⇒ *aortitis luetica*
- ⇒ *mycobacteria*
- ⇒ *bacillary angiomatosis = opportunistic infections (eg AIDS)*

× fungal (*Aspergillus, Mucor*)

× viral (hepatitis B, C; HIV, CMV, SARS-CoV-2)

× parasitic (*Schistosoma, amoebiasis*)

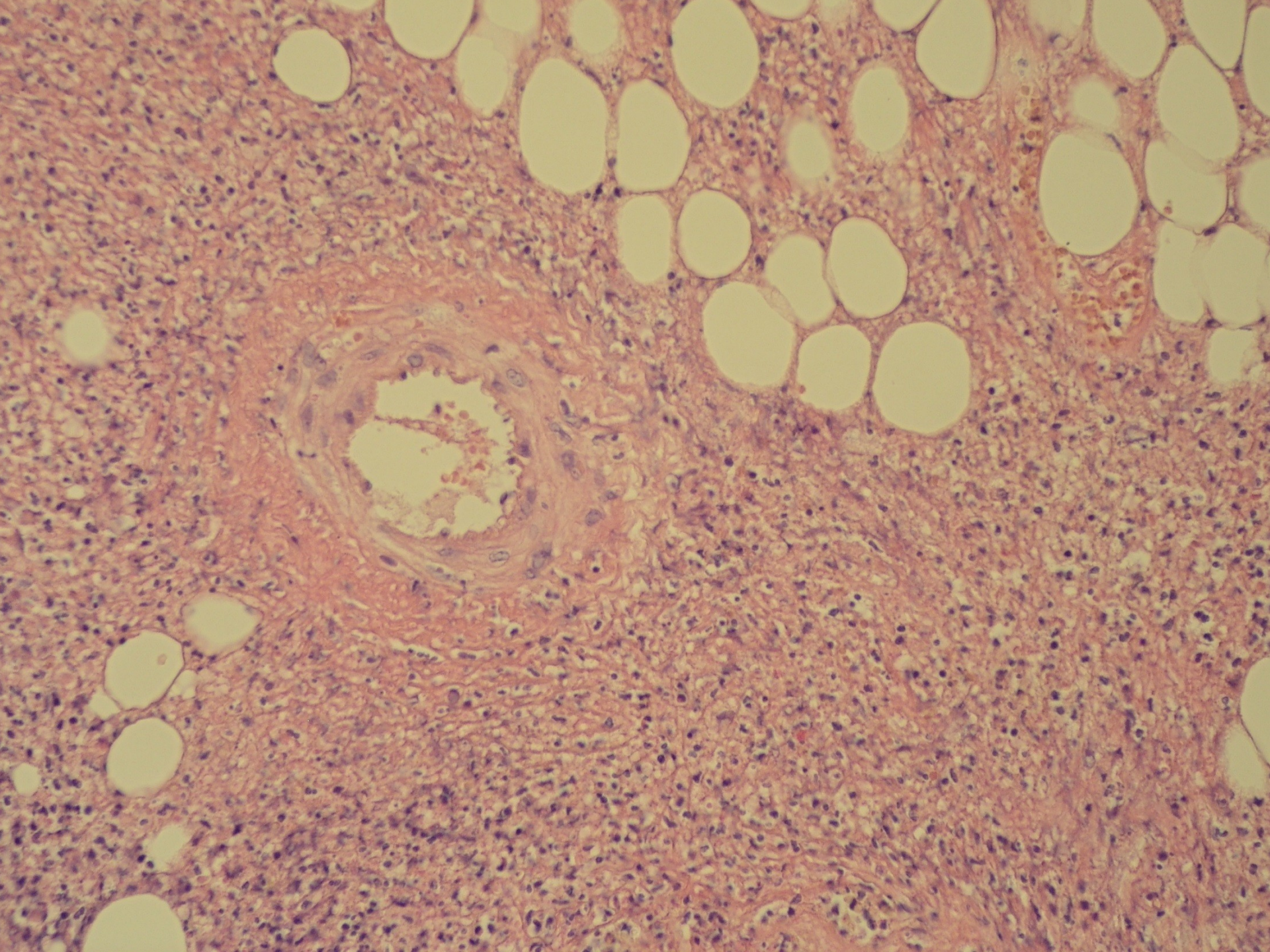


Infectious vasculitis

- × direct invasion of vascular wall by inf. pathogen

- × primary angioinvasive microorganism
Fungi: *Aspergillus*, *Mucor* - thrombosis → ischemic necrosis

- × secondary vasculitis - **localized vasculitis** in focal infection
 - ⇒ purulent – meningitis
 - ⇒ pneumonia
 - ⇒ abscess, fasciitis – pyogenic bacteria
 - ⇒ granulomatous
 - obliterative endarteritis – TB tertiary syphilis, I
 - Lepra
 - ⇒ lymphocytic vasculitis – rickettsia (spotted fever, Q fever etc.)
 - ⇒ recurrent herpes, CMV
 - ⇒ necrotizing vasculitis – anthrax



Vasculopathy, thrombosis in COVID-19

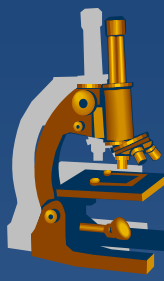


✘ microangiopathy

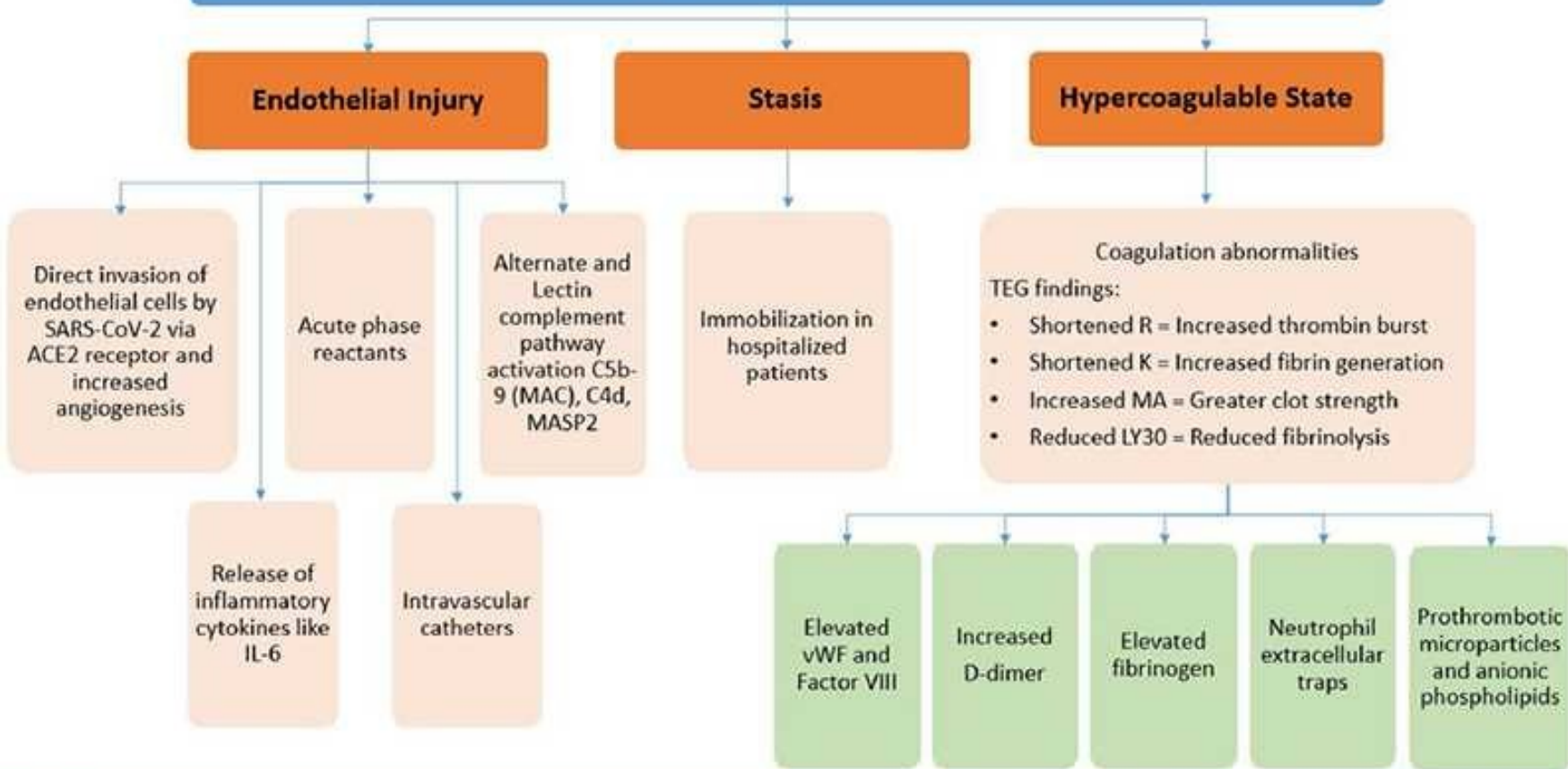
- ⇒ *endotheliitis*
- ⇒ *diffuse microthrombosis (platelets + fibrin), lungs in ARDS, kidney, heart, liver*
- ⇒ *capillary congestion*
- ⇒ *angiogenesis*

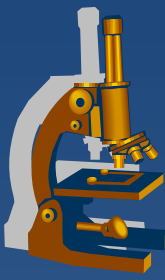
✘ coagulopathy /hypercoagulability w. thrombosis, thrombembolisation

- ⇒ *endothelial damage, circulating prothrombotic factors, blood stasis*
- ⇒ *deep venous thrombosis*
- ⇒ *infarctions inc. stroke*

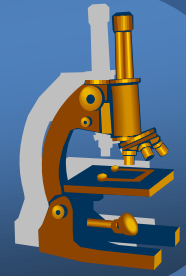


SARS-CoV-2 and Virchow's Triad

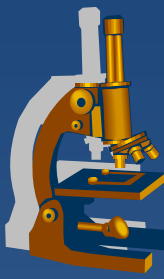




Cardiac pathology



Morphology



- ✗ pericardial sac – cca 30ml clear yellowish fluid
- ✗ **male = 300 – 350 g**,
 - *hypertrophy > 400g*
- ✗ **myocardium:**
 - RV 3 – 4 mm
 - LV 12 – 15 mm
- ✗ **foramen ovale**
 - *closed x opened → paradoxical embolia*



Congenital cardiovascular disease

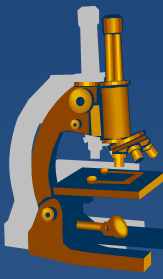
Congenital heart defects



- x** approx. 2,5 % of live newborns
- x** in children mostly ventricular septal defect
- x** in adults mostly atrial septal defect
- x** prenatal diagnostics

- x** possible signs
 - ⇒ *dyspnoe, possible cyanosis, polycythemia*
 - ⇒ *growth retardation*
 - ⇒ *repeated infections (lungs, valves)*
 - ⇒ *possible paradoxical embolization*

Morphological classification



- ✗ abnormal heart position
- ✗ abnormal connection between ventricles and arteries (transposition)
- ✗ septal defects
- ✗ valvular defects
- ✗ dct. arteriosus persistens
- ✗ combination of multiple defects

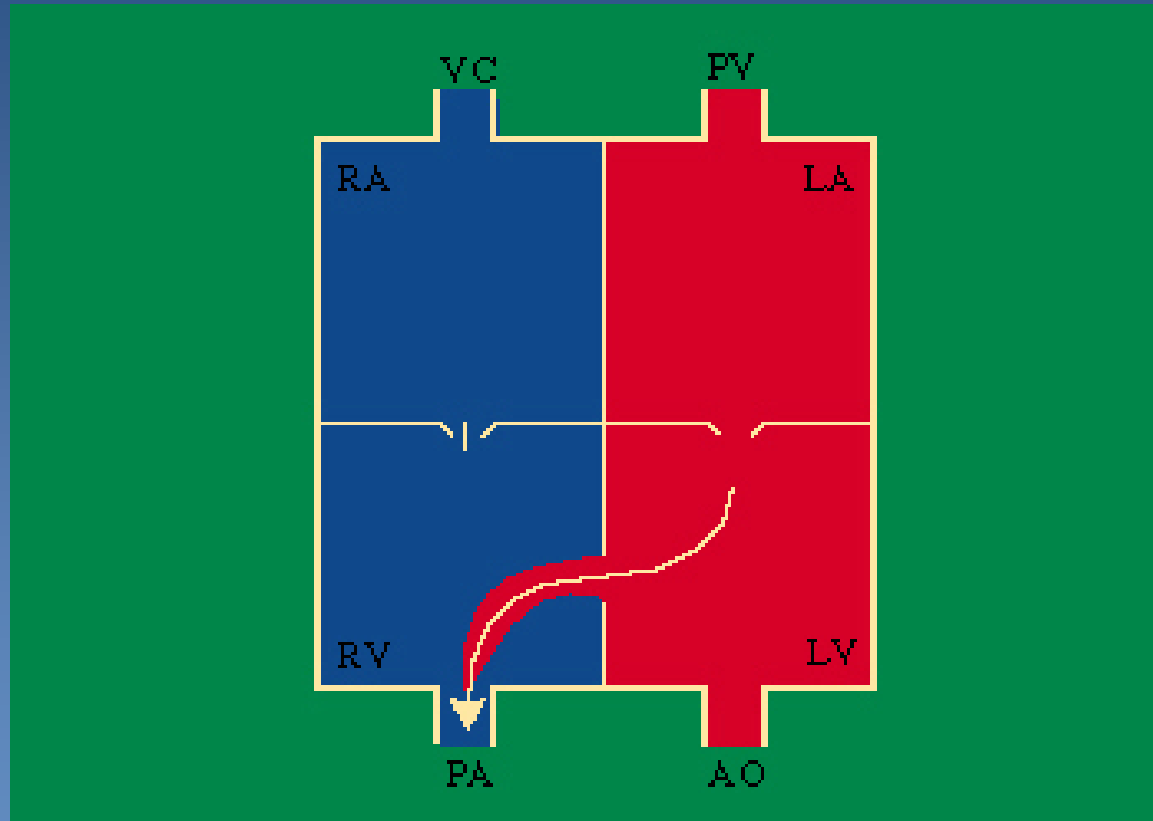
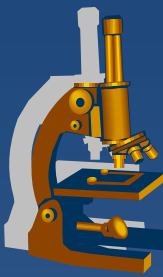
Pathological shunts



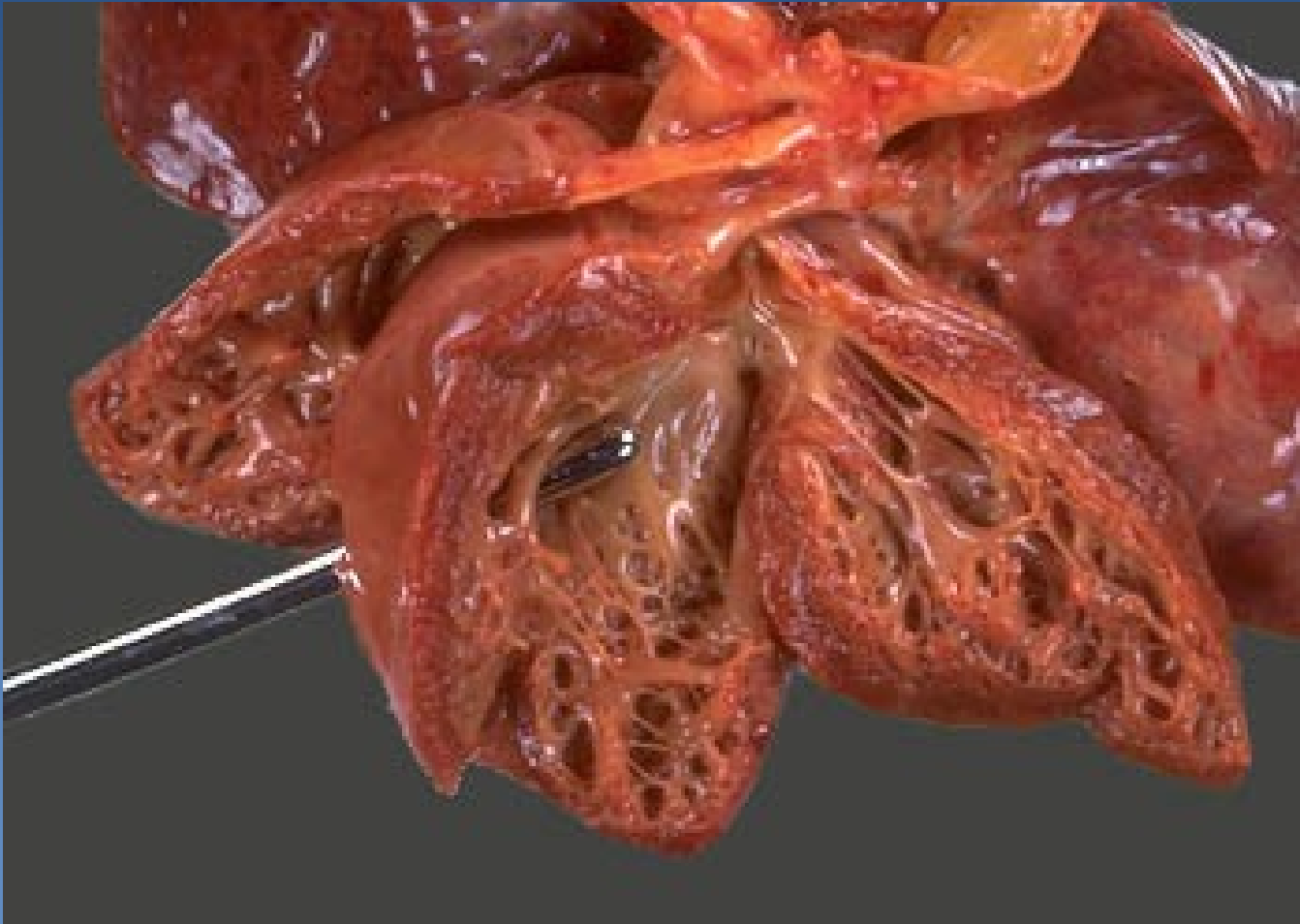
- ✗ atrial septal defect
- ✗ ventricular septal defect
- ✗ patent ductus arteriosus

Initially left-to right shunts, i.e. non-cyanotic,
later (in heart defects) right ventricular
hypertrophy – reverse shunt, cyanotic
defect

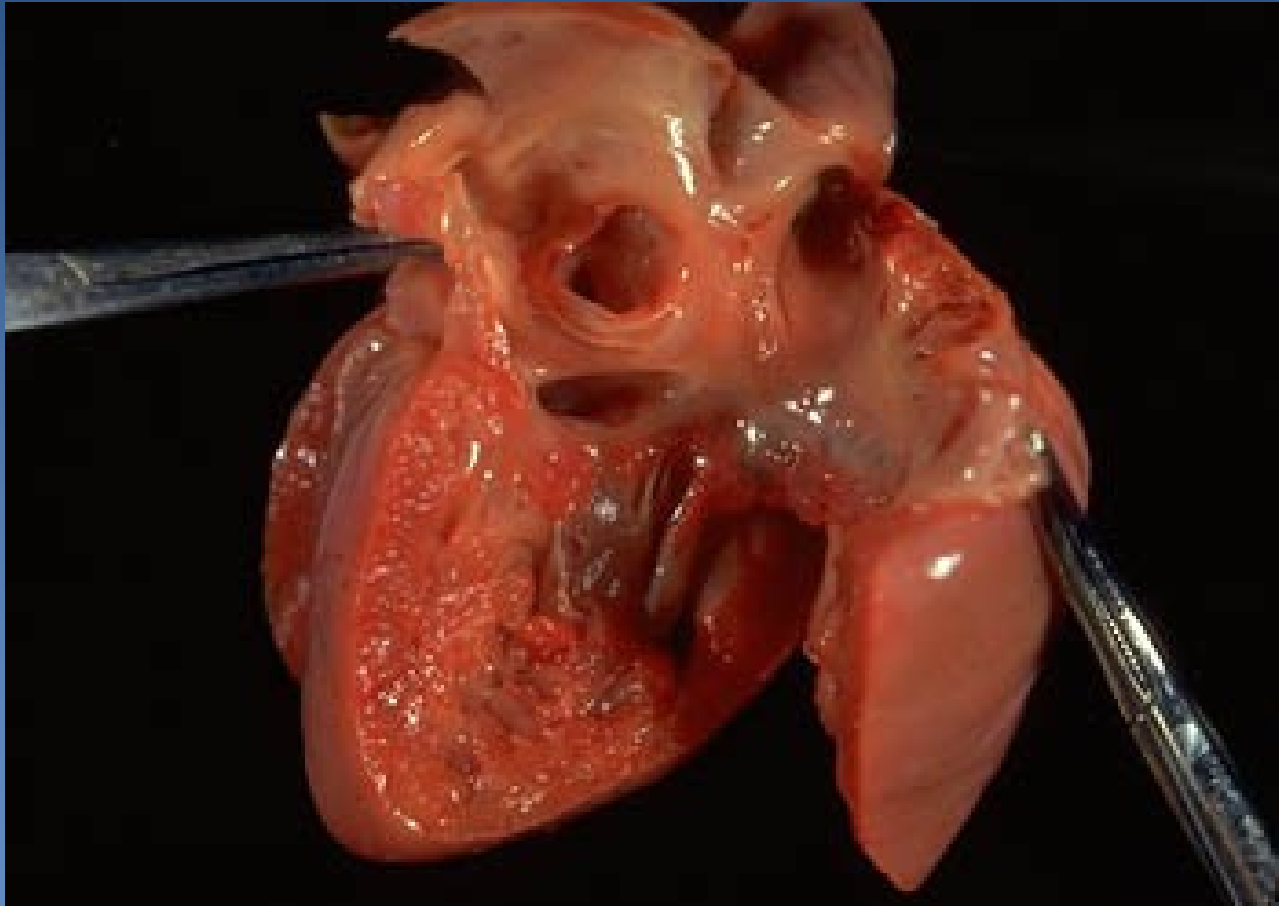
Ventricular septal defect



Ventricular septal defect



Atrial septal defect



Congenital stenosis



- x** coarctation of the aorta – congenital constriction
- x** valvular stenosis

Hypertrophy, hypertension and dilatation ahead of stenotic part. Collateral circulation, if possible.

Coarctation of the aorta



- ✗ Aortic constriction
- ✗ with patent duct. arteriosus (pre- or postductal)
- ✗ with closed duct. arteriosus

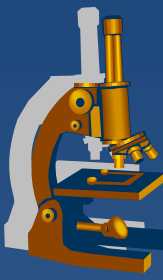
Congestive heart failure,
bacterial endocarditis,
intracerebral haemorrhage

Complex congenital heart disease

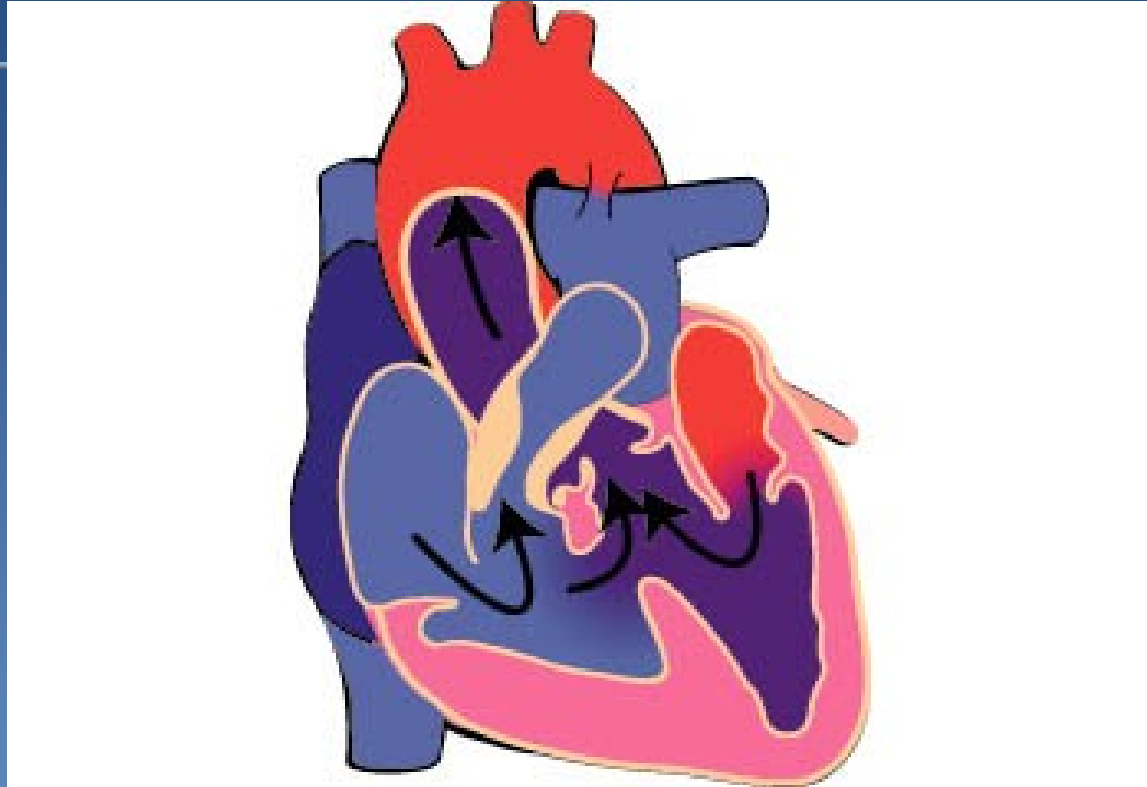


- x** Fallot's tetralogy
- x** transposition of the great arteries

Combination of malformations, i. e.
hypoplasia, shunting or incorrect
connection, stenosis, etc.



Fallot's tetralogy



ventricular septal defect with dilated overriding aorta,
stenosis of the pulmonary valve,
right ventricular hypertrophy

Pericardial pathology



1) Pericardial effusion

- transudate in congestive heart failure or hypoproteinemia, slow (up to 500ml – pericardial dilatation)

2) haemopericardium

– wall rupture in MI or aortic root dissection → **fatal cardiac tamponade**

diastolic filling restriction

Pericardial pathology



3) Inflammatory exudate in pericarditis:

a) non-infectious

– pericarditis epistenocardiaca, uremic, post-operative, SLE, Dressler sy (post-MI autoimmune)

b) infectious

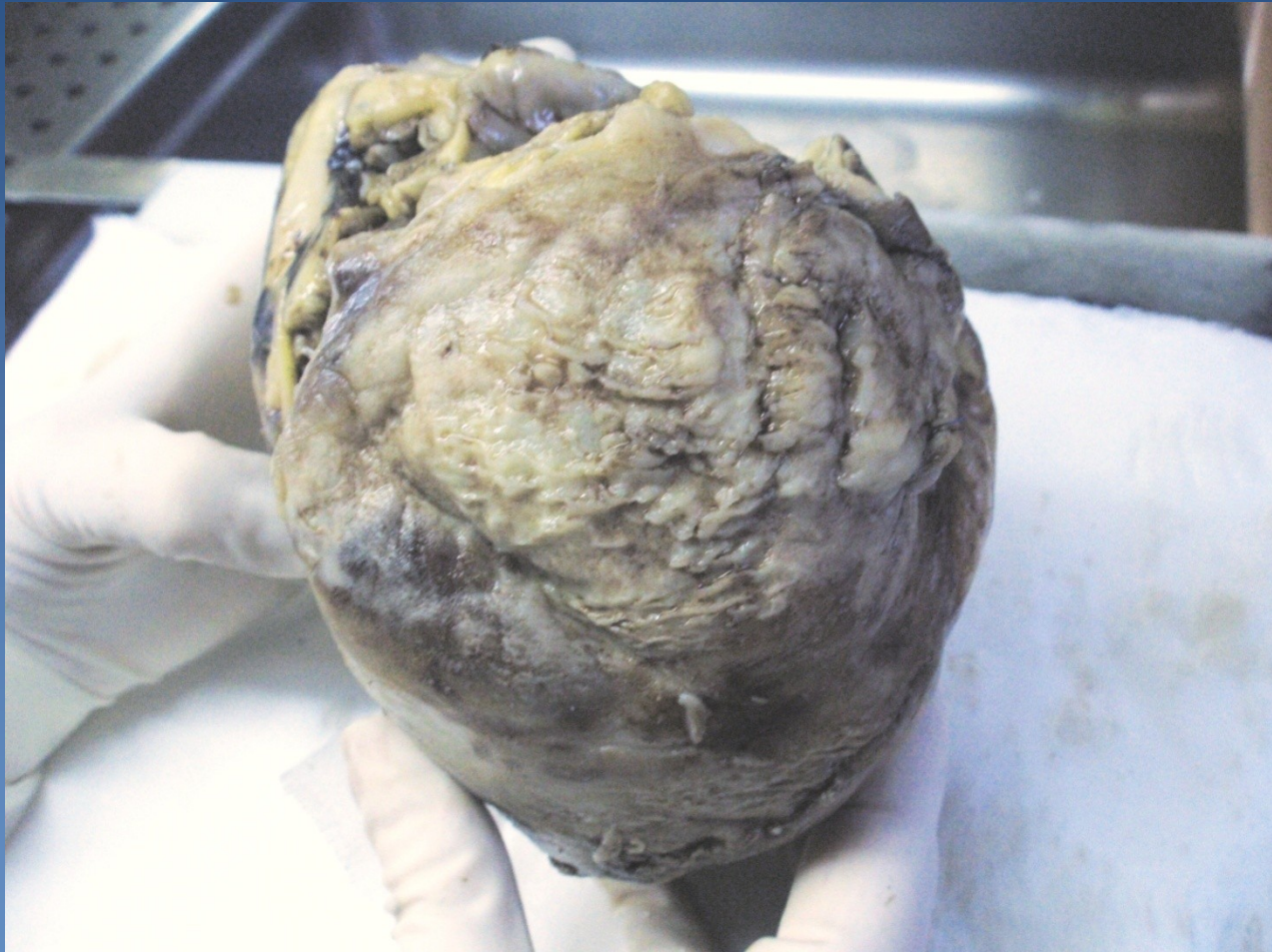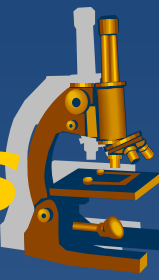
– *haematogenous, direct spread, lymphogenous; variable agents*

Acute fibrinous pericarditis

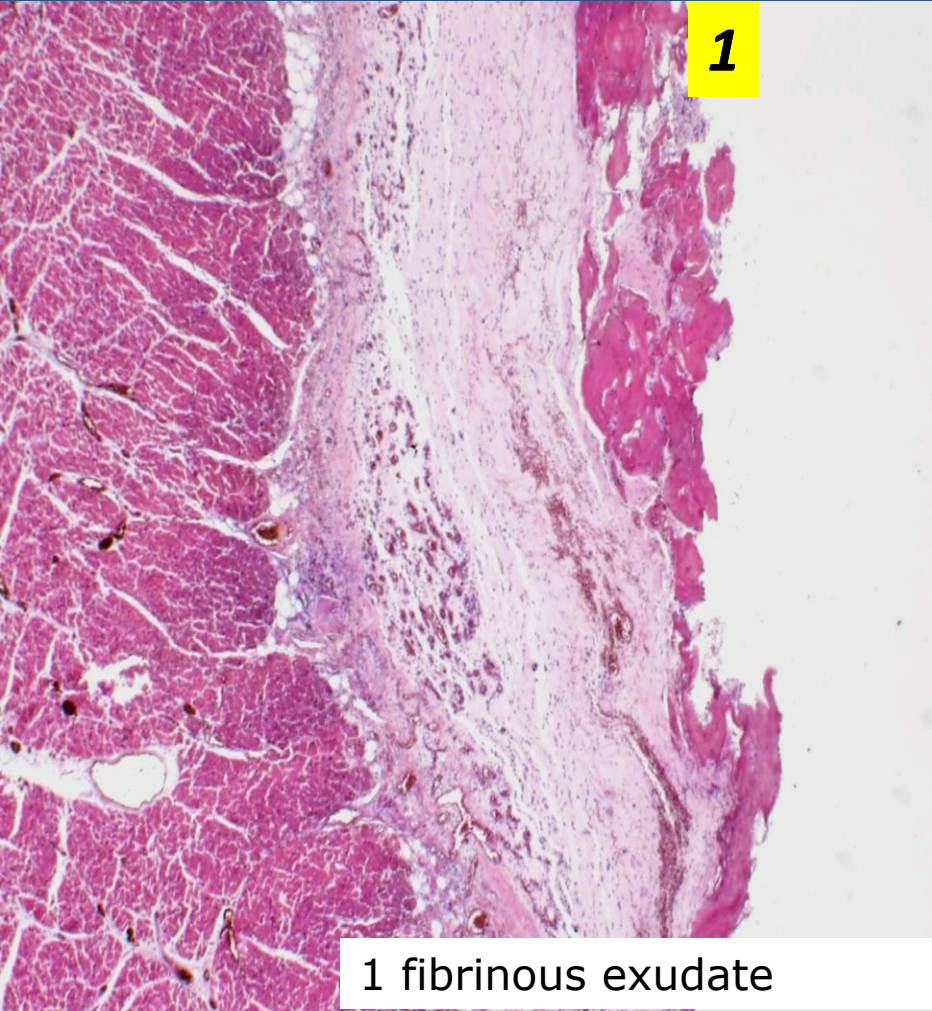


- ✘ Gross: yellow-greyish superficial coating – granular layer, villi - cor villosum, hirsutum;
- ✘ Micro: mesh of thin eosinophilic strands, commonly + inflammatory infiltrate
- ✘ Healing: may be complicated. Fibrinolysis x organisation by granulation tissue → adhesions, dystrophic calcification.

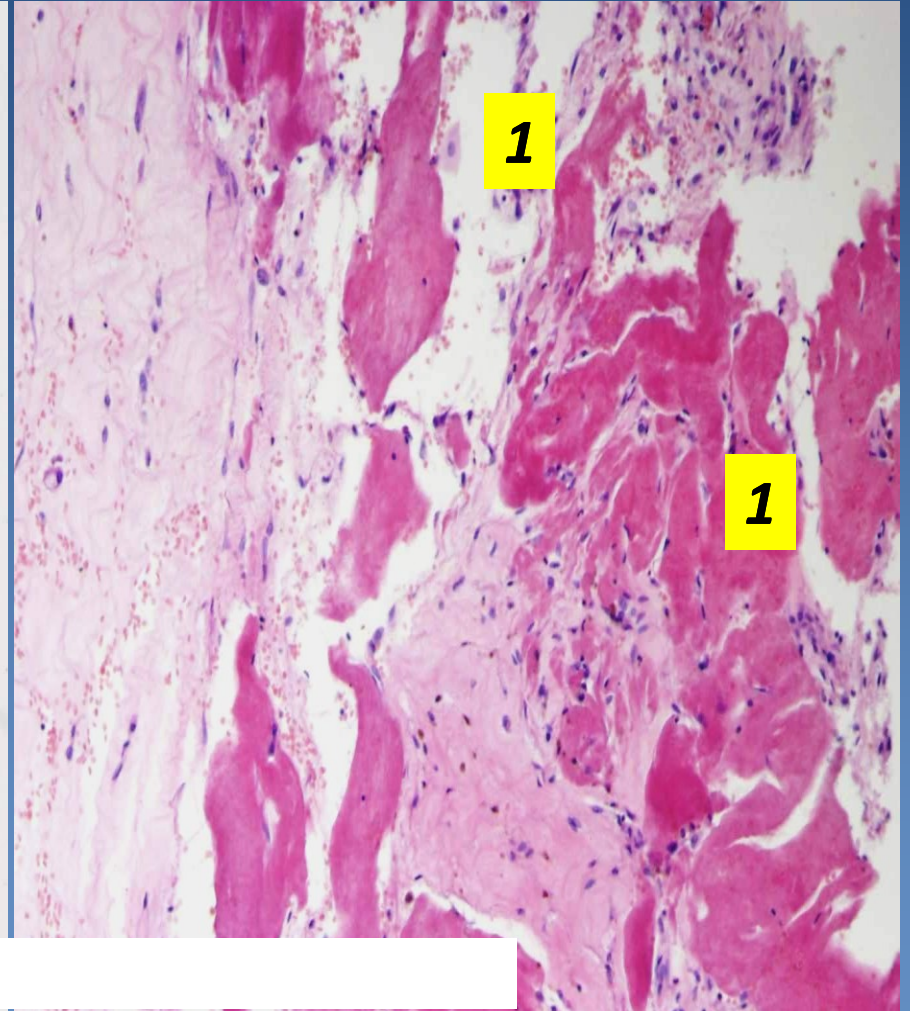
Acute fibrinous pericarditis



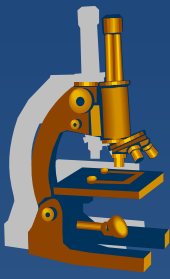
fibrinous pericarditis



1 fibrinous exudate



Hypertension



- × systemic
- × pulmonary
- × portal

Systemic hypertension



× Primary (essential) h.

⇒ *multifactorial*

⇒ *genetics incl. abnormal transmembrane Na/K transport in renal tubules*

⇒ *inborn defects incl. low birthweight, decreased nephron number*

⇒ *acquired risk factors*

× Secondary h. (renal, endocrine hyperfunction, aortic coarctation, drug induced)

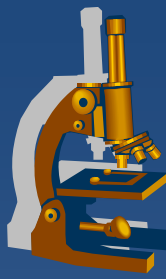
× Endothelial + vessel wall lesions

⇒ *hyaline – circular hyperplastic arteriolosclerosis*

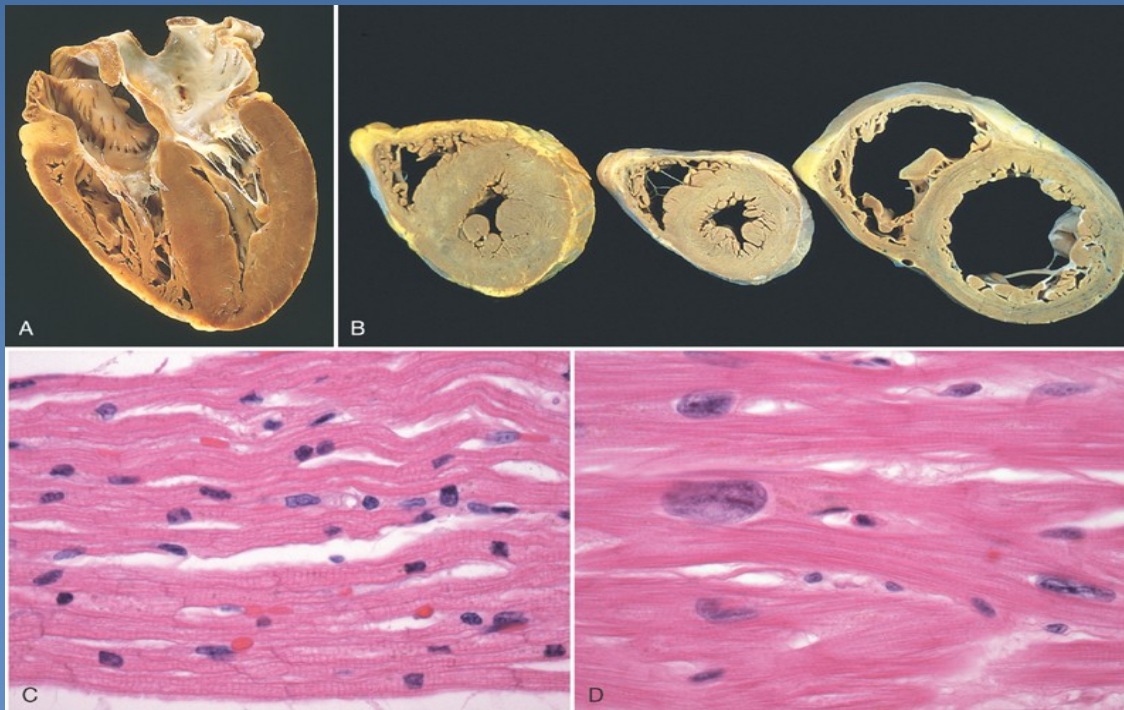
⇒ *fibrinoid necrosis + thrombosis in malignant hypertension*

⇒ *arteries w. intimal and smooth muscle hyperplasia*

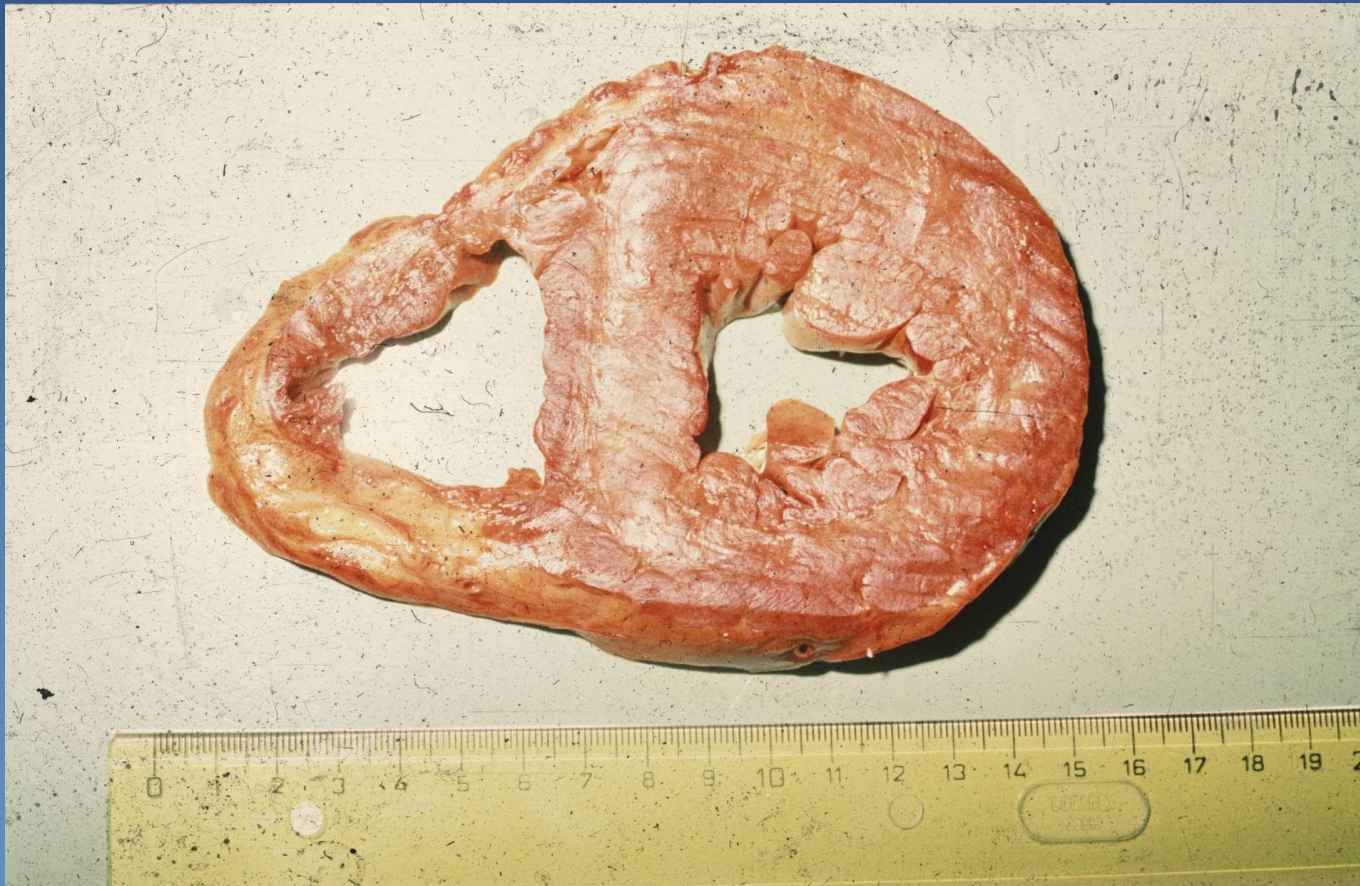Systemic hypertension and heart



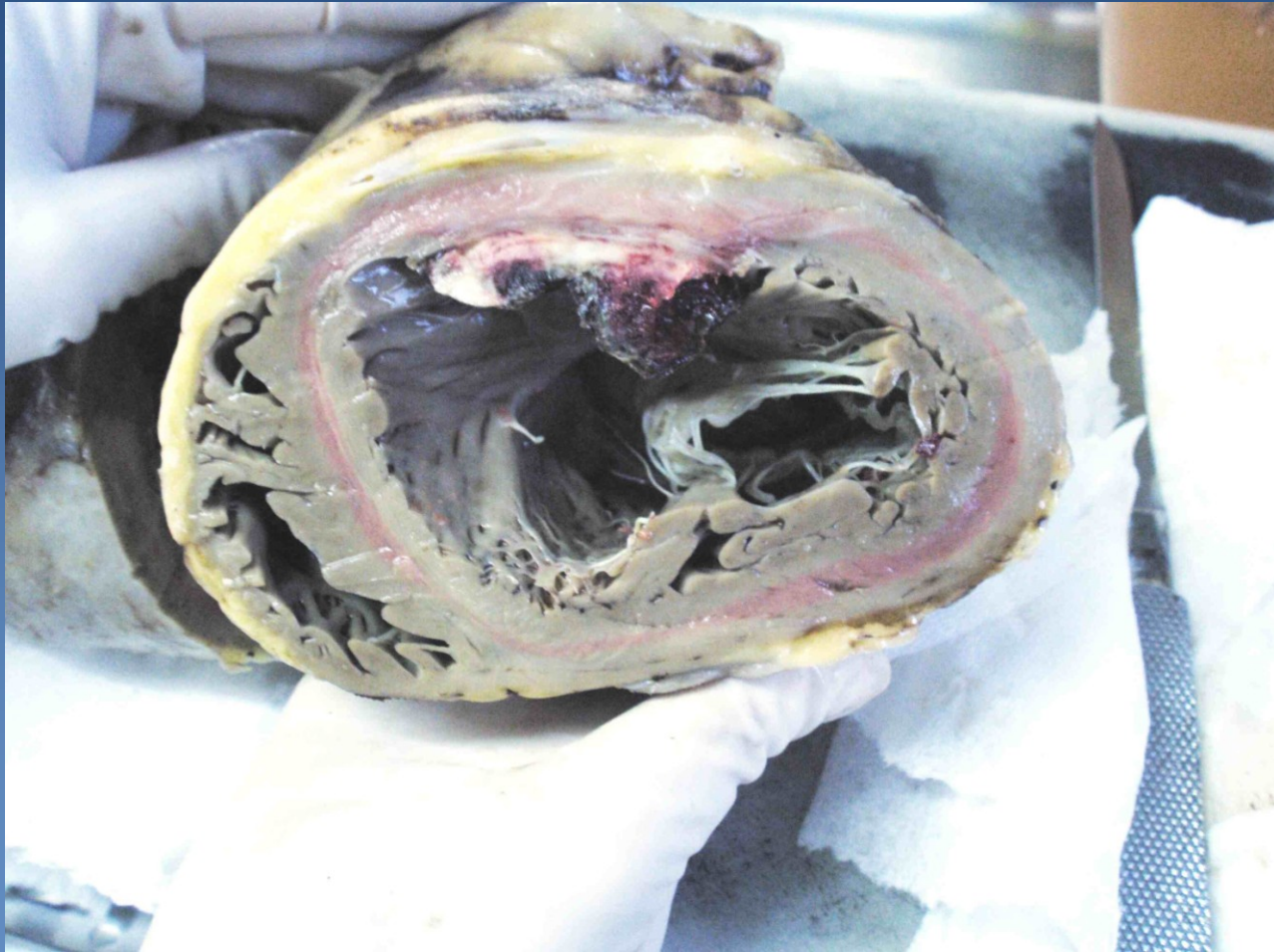
- × 90–95% essential , risk factor for AS
- × **work overload** → LV adaptation to ↑ peripheral resistance = **cor hypertonicum** (concentric LV hypertrophy) → limited compensatory mechanisms → **cor hypertonicum decompensatum** (dilatation of hypertrophic LV)
- × → heart insufficiency ← relative coronary incompetence



Cor hypertonicum



LV hypertrophy



Heart failure



- ✘ heart unable to pump blood at a rate sufficient for metabolic demands of the tissues
- ✘ systolic dysfunction - ↓ myocardial contractile function (ischemic injury, pressure or volume overload – valvular disease, hypertension, cardiomyopathy)
- ✘ diastolic dysfunction - inability to dilatate sufficiently (massive LV hypertrophy, myofibrosis, amyloidosis)
- ✘ cardiac – extracardial pathologic changes

Heart failure



- ✗ failure of normal pumping action of the heart
- ✗ failure of forward and backward → to cardiogenic shock
- ✗ manifestations of the heart and heart out

Cardial changes



- × **disproportion between heart function and peripheral vascular resistance**
- × differ according rapidity of development:
 - **sudden** → acute dilatation
 - **chronic** → adaptation → → →
*myocardial hypertrophy (↑ nutritional demands) +/- ventricular dilatation
(enhanced contractility – Frank-Starling mechanism), + activation of
neurohumoral systems (norepinephrin, renin-angiotensin sy, atrial natriuretic peptide*

Extracardial changes

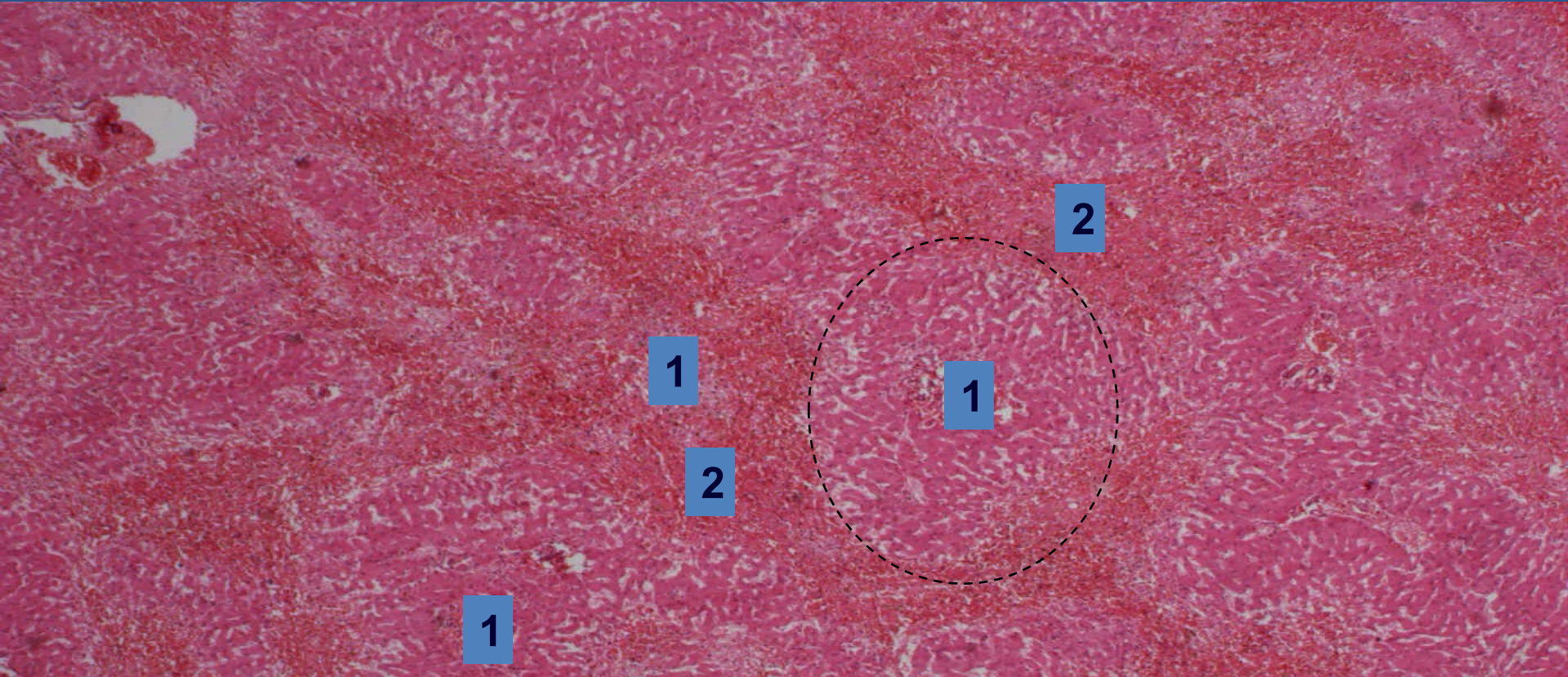
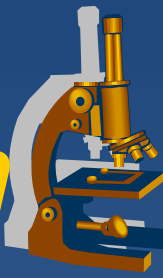

- × **venous congestion** – e.g. liver (-> *hepar moschatum*)
- × **induration** – fibroproduction (liver, spleen, kidney)
- × **oedema** –
- × **cyanosis** – visible on acral parts

***Chronic venous congestion
(nutmeg liver - hepar moschatum)***



Hepatic venous congestion

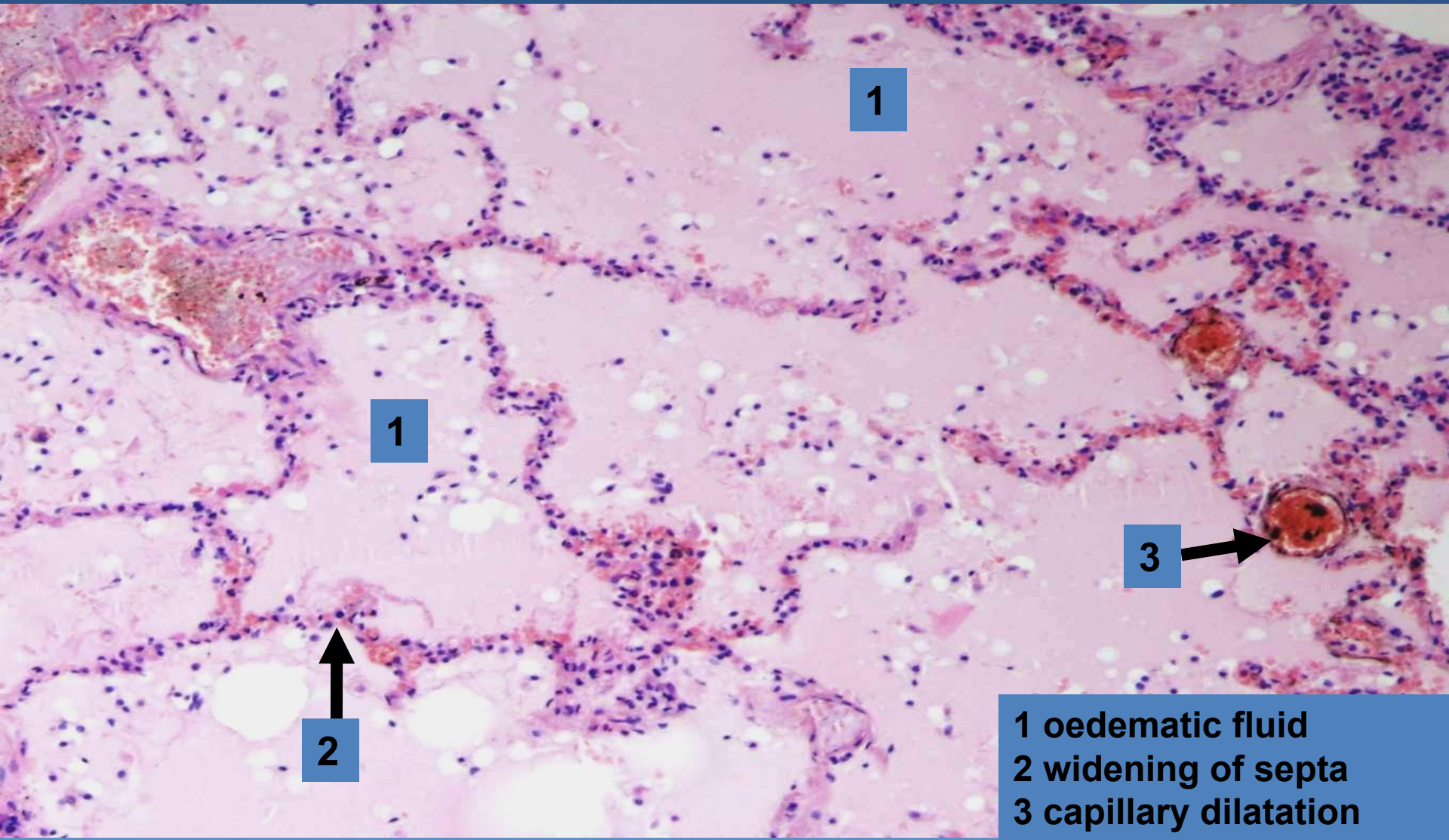


1 Portal spaces

2 Congestive lines (severe congestion with hepatocyte necrosis)

--- pseudolobule: confluent remnants of 3 lobules, centrally portal space

Pulmonary oedema



1

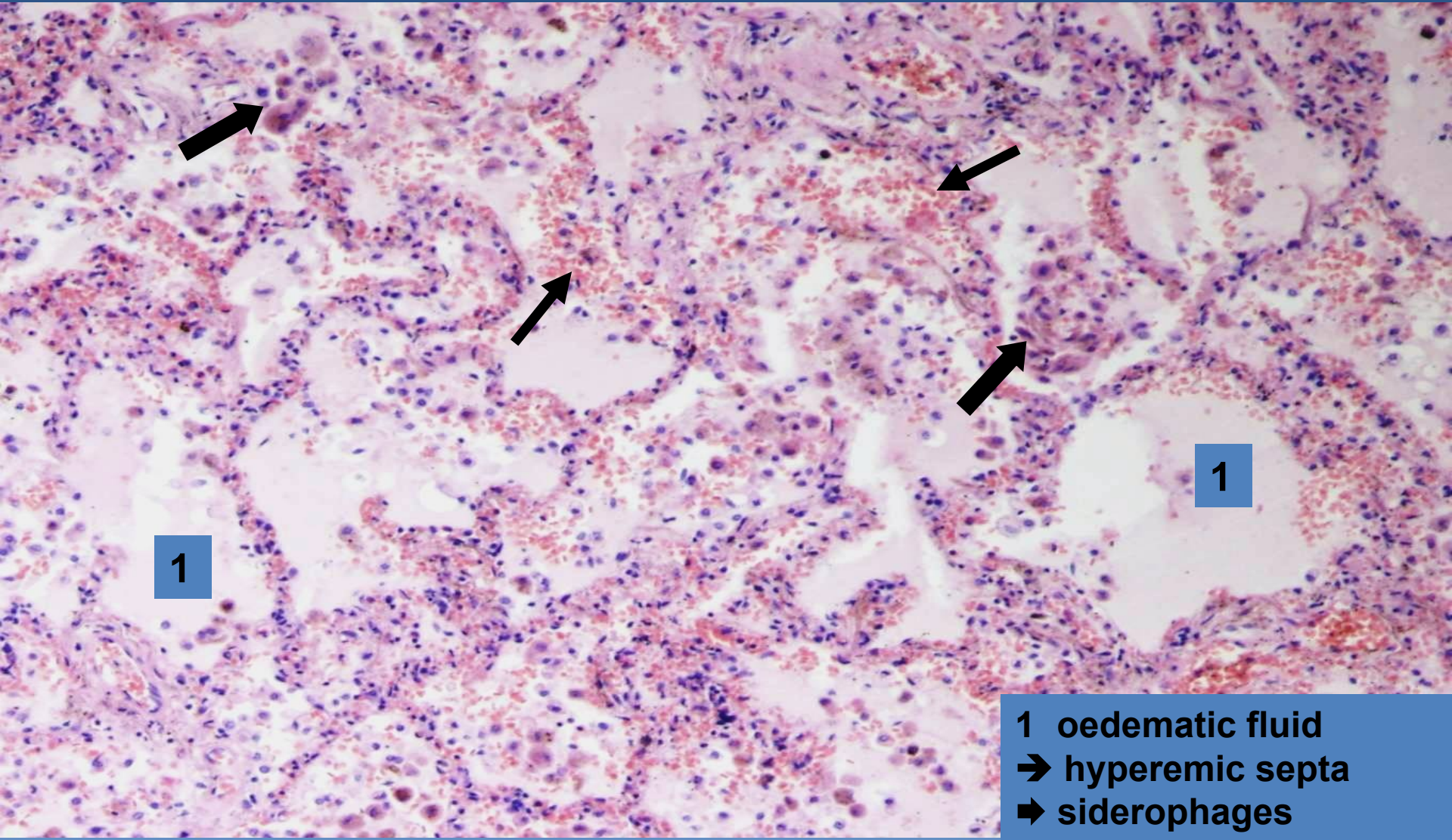
1

3

2

1 oedematous fluid
2 widening of septa
3 capillary dilatation

Chronic pulmonary venous congestion



- 1 oedematous fluid
- hyperemic septa
- ➡ siderophages

Ischemic heart disease (IHD)



- ✘ group of pathophysiologically related syndromes resulting from **myocardial ischemia** (hypoxia or anoxia, ↓ nutrients, ↓ removal of metabolites)
- ✘ imbalance between the demand and supply by coronary arteries.
- ✘ important factor – coronary AS
- ✘ forms:
 - ⇒ *angina pectoris*
 - ⇒ *myocardial infarction (MI)*
 - ⇒ *chronic IHD with heart failure*
 - ⇒ *sudden cardiac death*

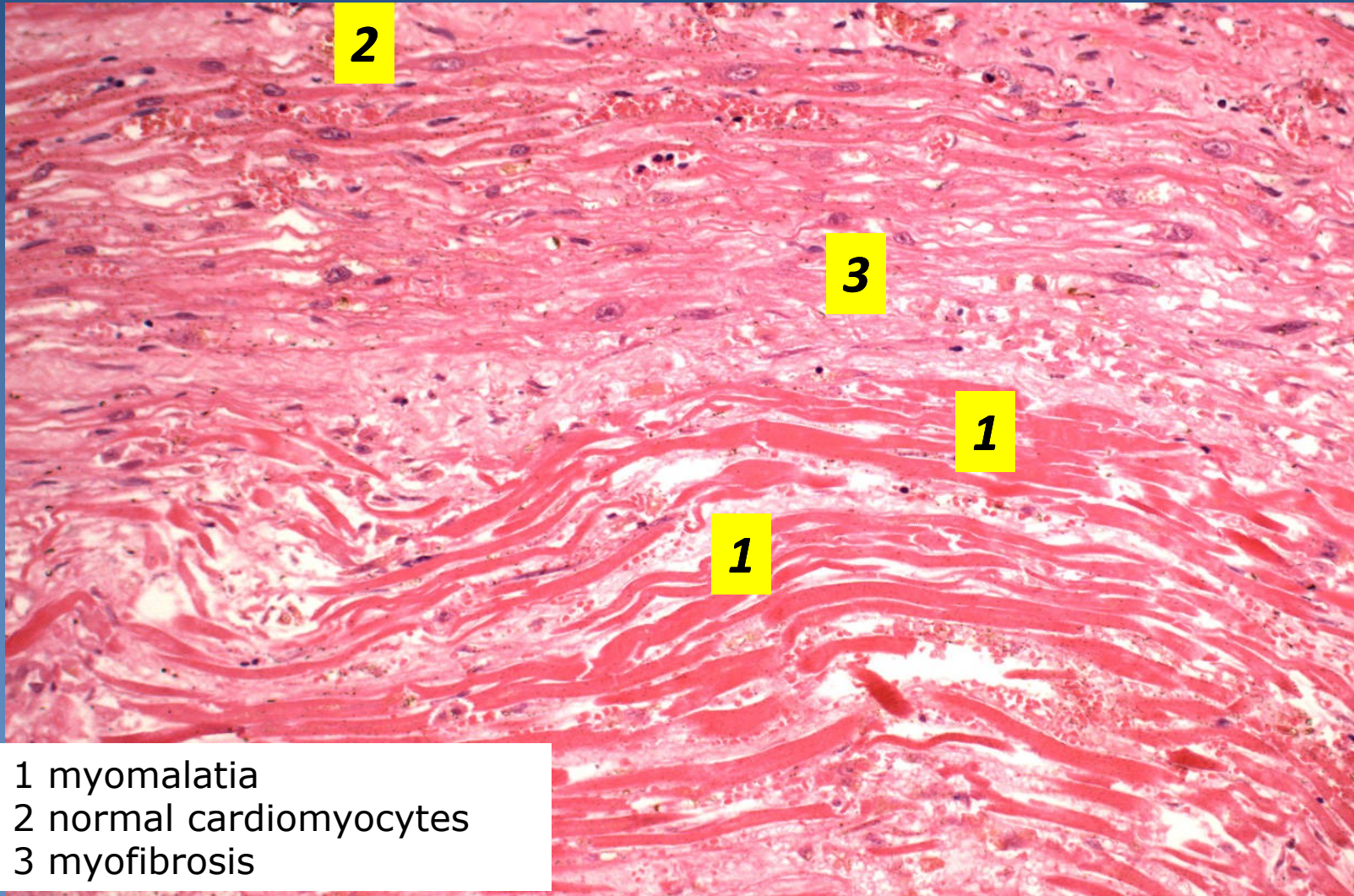
Ischemic heart disease (IHD)



x Morphology of myocardial ischemia:

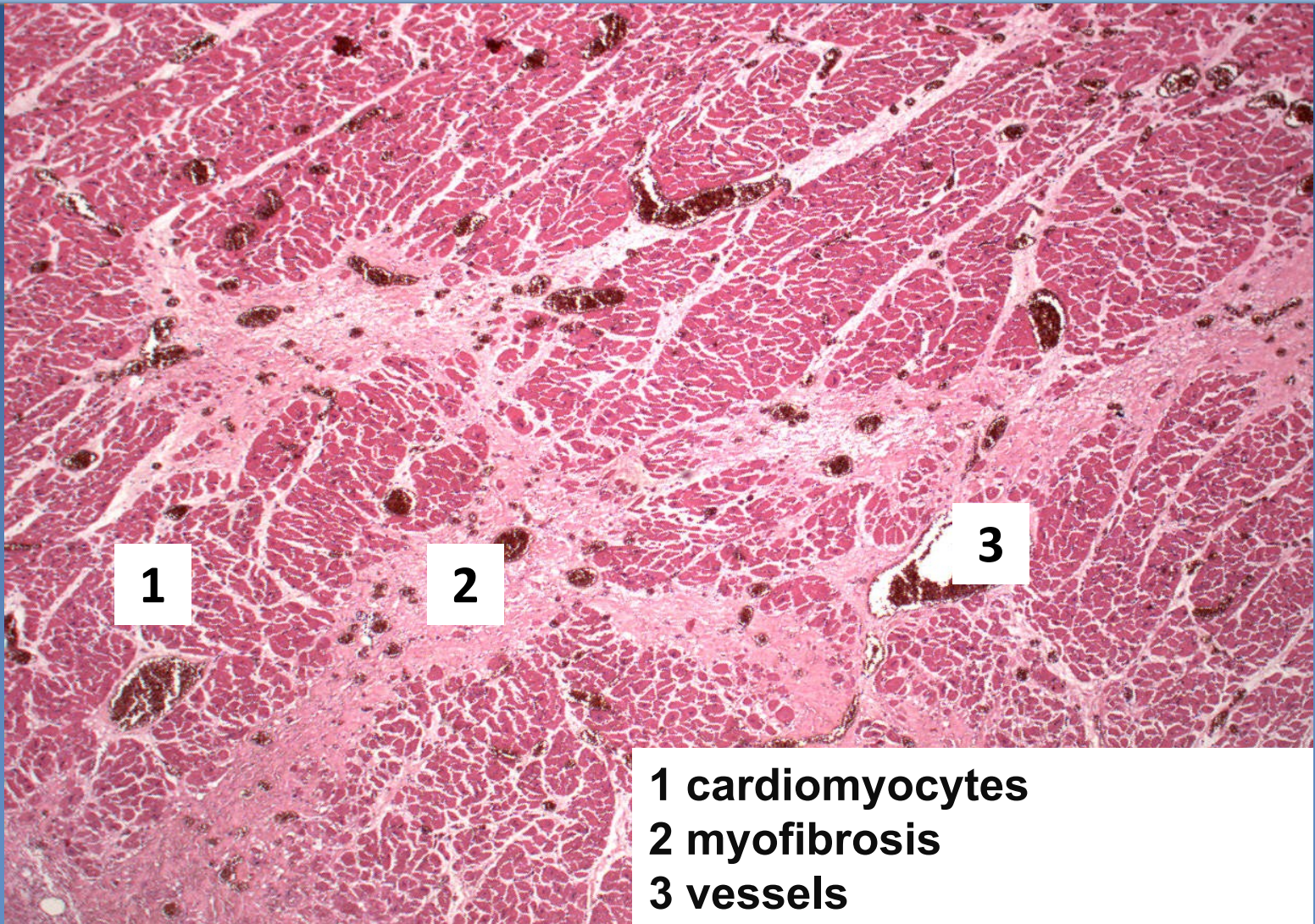
- ⇒ *myofibrosis*
- ⇒ *myomalatia (= partial necrosis – cardiomyocytes only)*
- ⇒ *myocardial infarction: transmural/subendocardial (complete coagulative necrosis incl. interstitium)*

Myomalatia



- 1 myomalatia
- 2 normal cardiomyocytes
- 3 myofibrosis

Myofibrosis



1

2

3

1 cardiomyocytes
2 myofibrosis
3 vessels

Pathogenesis of IHD

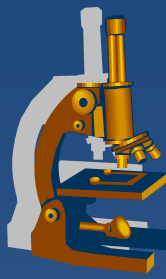


1) AS of coronary aa.

- commonly at a. branching
- fixed obstruction by plaque (fibrous, atheromatic)
- acute plaque change (rupture, erosion, haemorrhage, thrombosis)
- 75% stenosis – ischemia during \uparrow workload – stable angina pectoris
- 90% stenosis – ischemia even at rest – unstable angina - preinfarction

2) non-atherosclerotic

- coronary emboli – endocarditis, atrial fibrillation, mural thr., paradoxical e.
- coronary vasospasm
- aortic dissection
- coronary vasculitis
- congenital coronary aa. defects
 - hematologic disorders, amyloidosis, shock, etc.



Angina pectoris (AP)

× **transient myocardial ischemia** → chest pain !!!

1. stable (typical)

- due to increased workload, duration ≤ 15 min, relieved by rest or nitroglycerin
- no myocardial necrosis
- subendocardial LV myocardium

2. unstable

- increasing frequency / duration of pain attack, even at rest
- plaque disruption + mural thrombosis, possible vasospasm
- preinfarction angina

3. variant (Prinzmetal) angina

- mostly unrelated to physical activity, coronary vasospasm - vasodilatative therapy

Myocardial infarction



× ischaemic coagulative necrosis

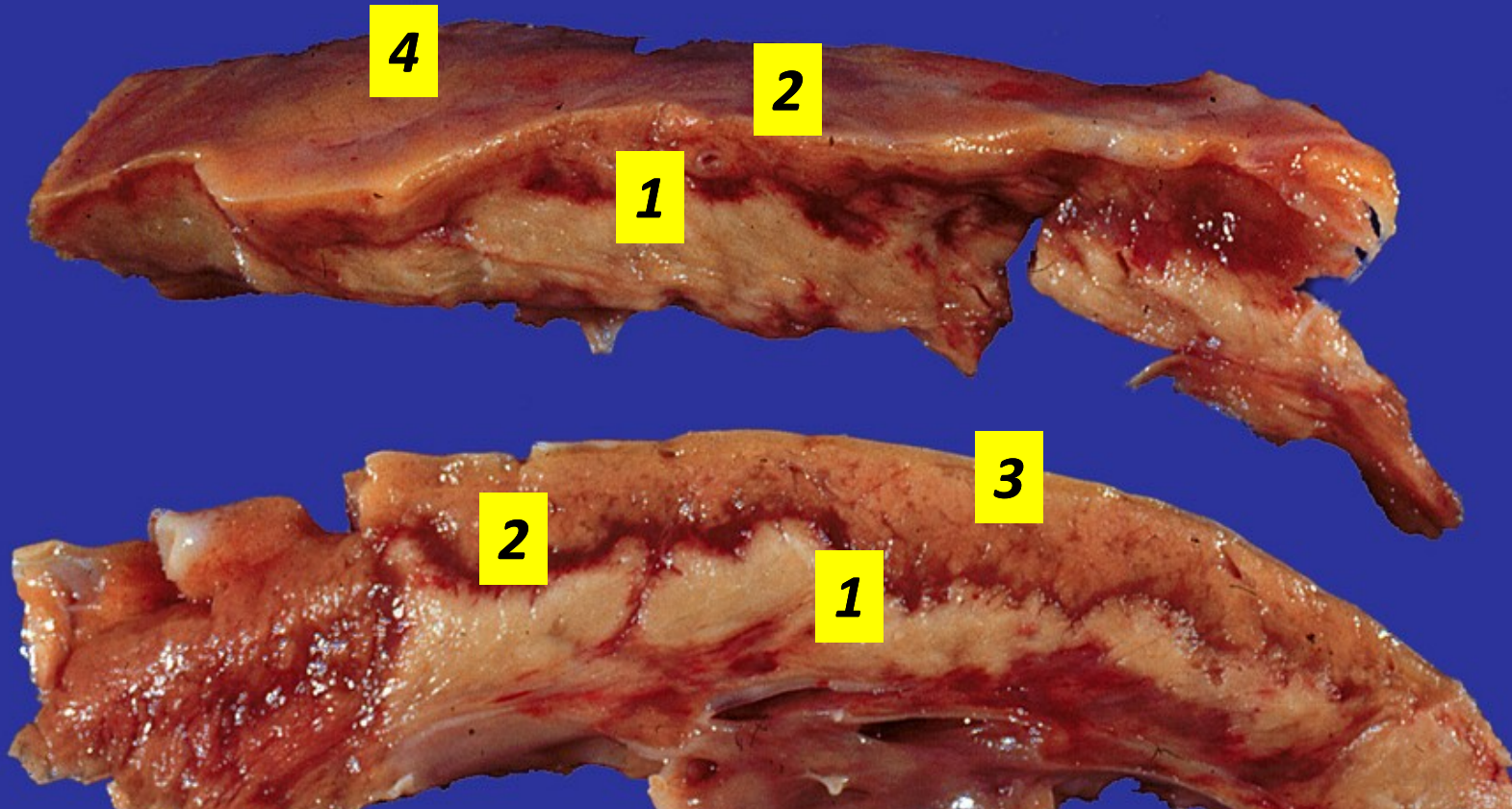
× causes:

- ⇒ *usually coronary thrombosis*
- ⇒ *complicated atheromatic plaque*
- ⇒ *event. embolism*
- ⇒ *spasm*
- ⇒ *inflammation*
- ⇒ *rarely systemic causes.*

× gross

- ⇒ **evolution**; *first signs (red, softer) after 12 hrs*
- ⇒ **2-3 days** *established infarction (yellowish, haemorrhagic rim)*
- ⇒ **weeks** – *formation of firm white fibrotic scar*

Myocardial infarction



1 subendocardial coagulative necrosis 2 hyperemic rim 3 normal myocardium 4 epicardium

Myocardial infarction



× micro:

- ⇒ necrotic cells more red*
- ⇒ loss of nuclei and striation*
- ⇒ neutrophils*
- ⇒ later macrophages in stroma*
- ⇒ reparation by granulation tissue -> scar*

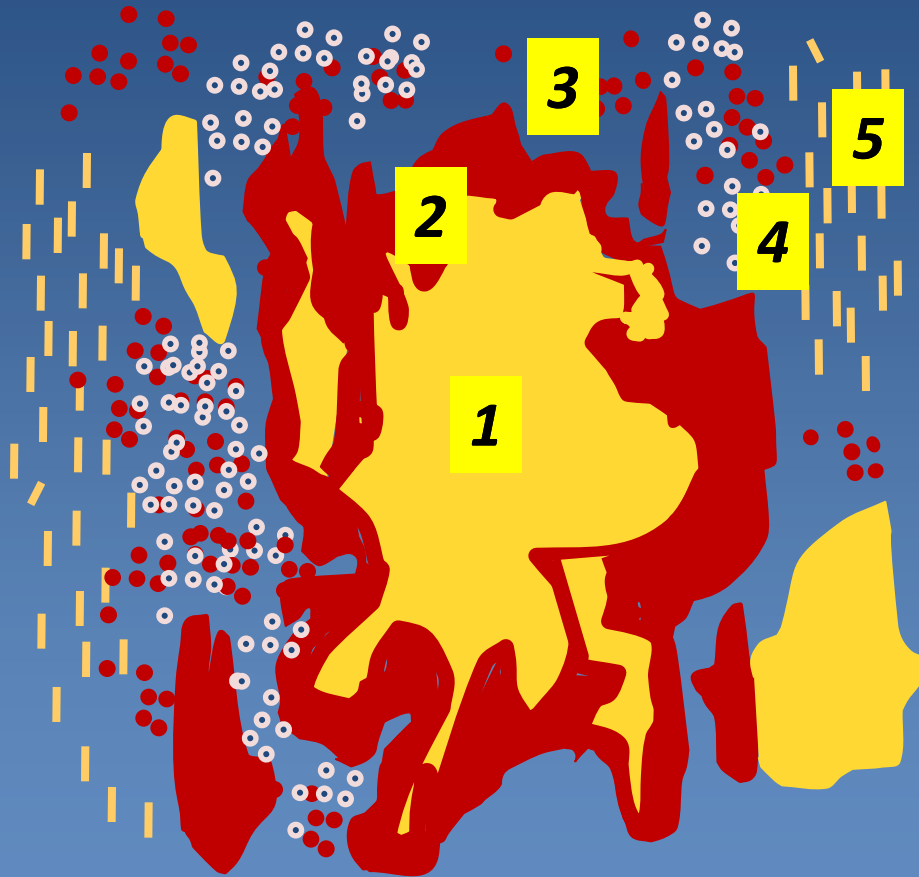
Myocardial infarction








micro:

- × **12-24 hr:** edema, hypereosinophilia of necrotic cells, pyknosis
- × **1-3 days:** neutrophils, loss of nuclei
- × **3-7 days:** macrophages at the border, desintegration of myofibers
- × **1-2 weeks:** repair by granulation tissue
- × **cca 2 months:** scar

Microscopic changes in developed MI



- 1 coagulative necrosis 
- 2 myomalatia 
- 3 hyperemic rim 
- 4 neutrophils 
- 5 regressive changes 

Myocardial infarction



× **transmural (QIM, STEMI) - + ST elevation on ECG**

- $\geq \frac{3}{4}$ of wall thickness, breadth >25 mm
- complete coronary artery obstruction
emergency angioplasty/stenting

× **non-transmural (subendocardial, Non-STEMI)**

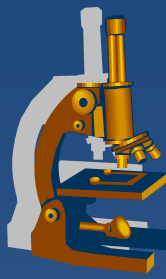
- internal $\frac{1}{4}$ až $\frac{1}{2}$ of LV wall
- collateral blood flow, incomplete obstruction, shorter ischemia
- stenosis + systemic hemodynamic problem (hypotension, ...)

Myocardial infarction



- × Type 1: spontaneous MI
 - ⇒ *unstable AS plaque + thrombosis*
- × Type 2: ischemic dysbalance
 - ⇒ *demand and supply dysbalance*
 - hypotension, anaemia, sepsis, surgery
- × Type 3: heart death due to MI
- × Type 4: MI associated w. stenting
- × Type 5: MI associated w. ao-coronary bypass

- × Incidental MI
- × Reinfarction up to in 28 days
- × Recurrent MI after 28 days



MI complications

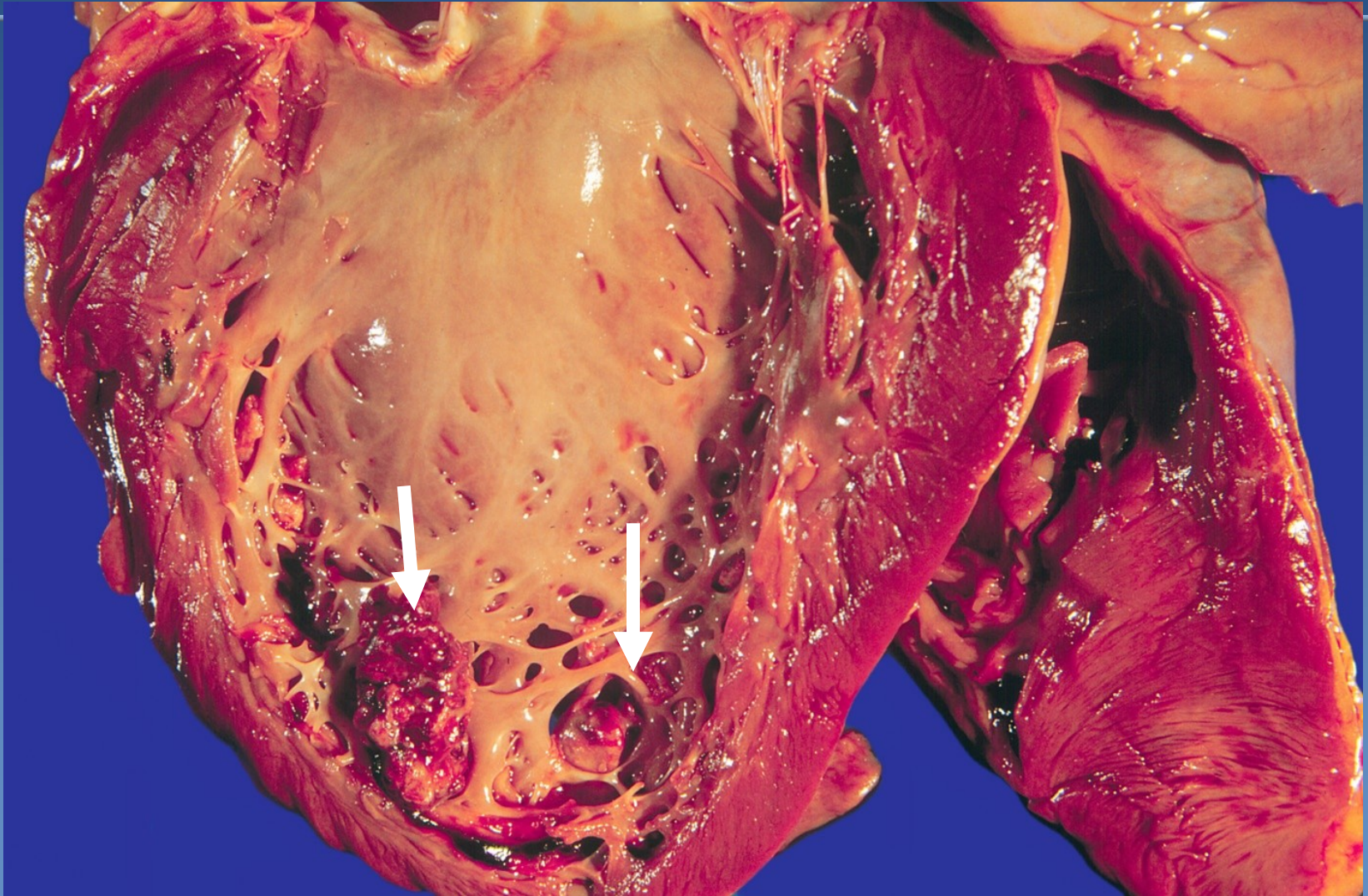
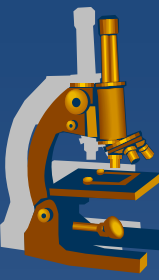
1. **sudden death (arrhythmia)**
2. **cardiogenic shock (contractile dysfunction)**
3. **pericarditis epistenocardiaca**
-> sero-fibrinous inflammation
4. **mural thrombosis**
-> embolism into systemic circulation (-> brain, kidney, intestine, spleen infarction)
5. **ventricular aneurysm**
-> acute – risk of rupture, thrombosis; chronic – LV insufficiency
6. **cardiac rupture**
-> free wall, septum, : tamponade / acute heart failure
7. **papillary muscle rupture**
-> valvular incompetence → acute heart failure

MI complications

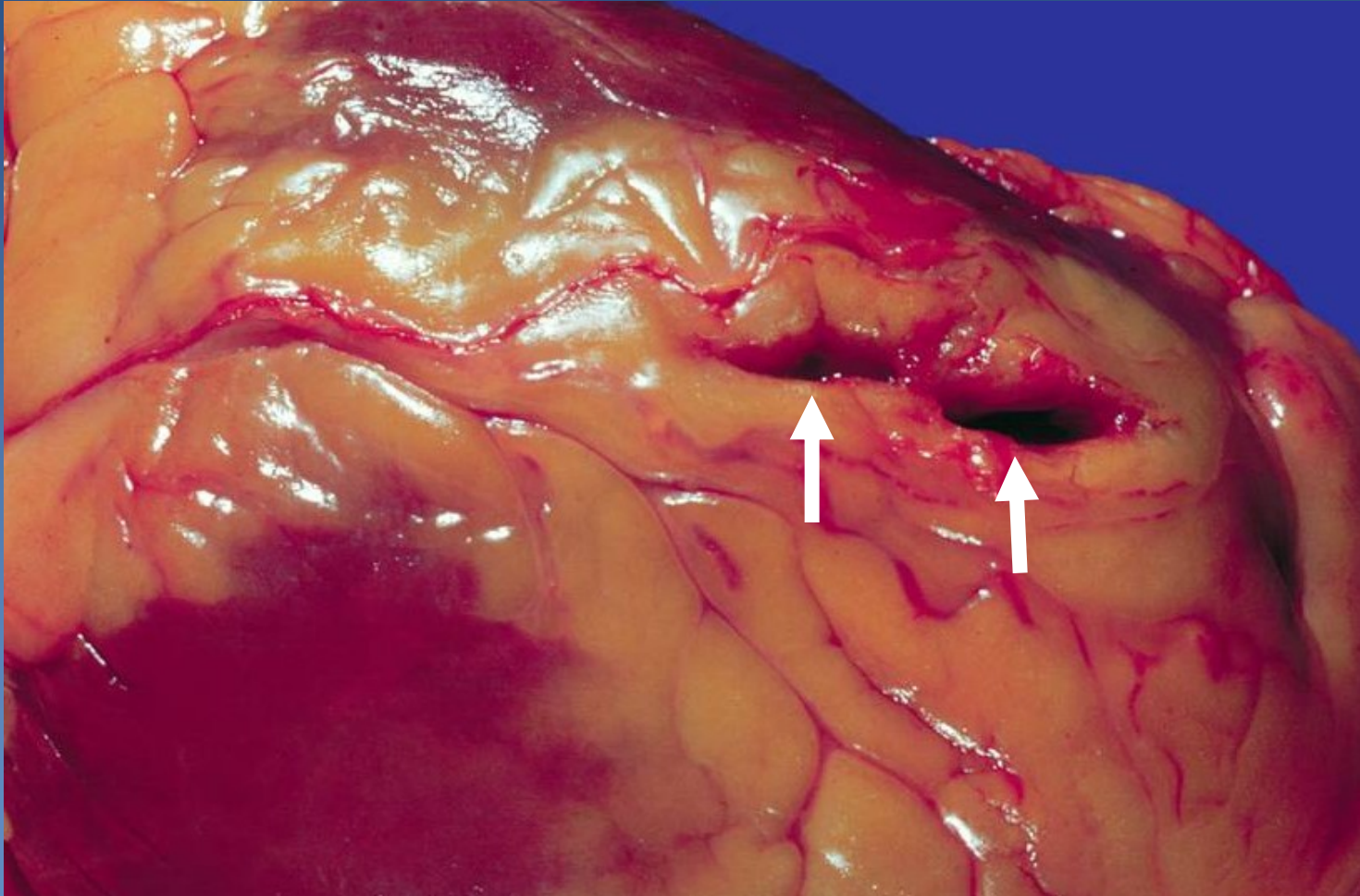


- x** persistent pain – extension of infarct
- x** Dressler's syndrome – autoimmune; chest pain, fever, effusion during weeks – months
- x** progressive late heart failure - IHD

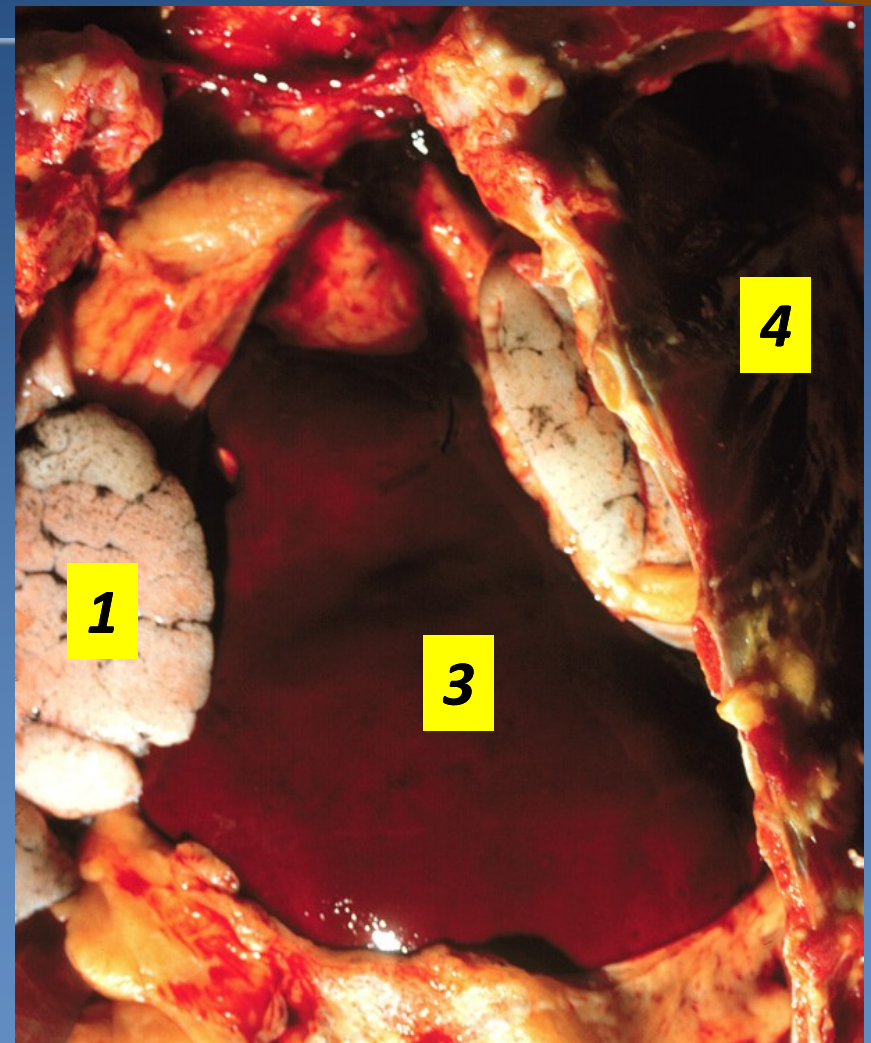
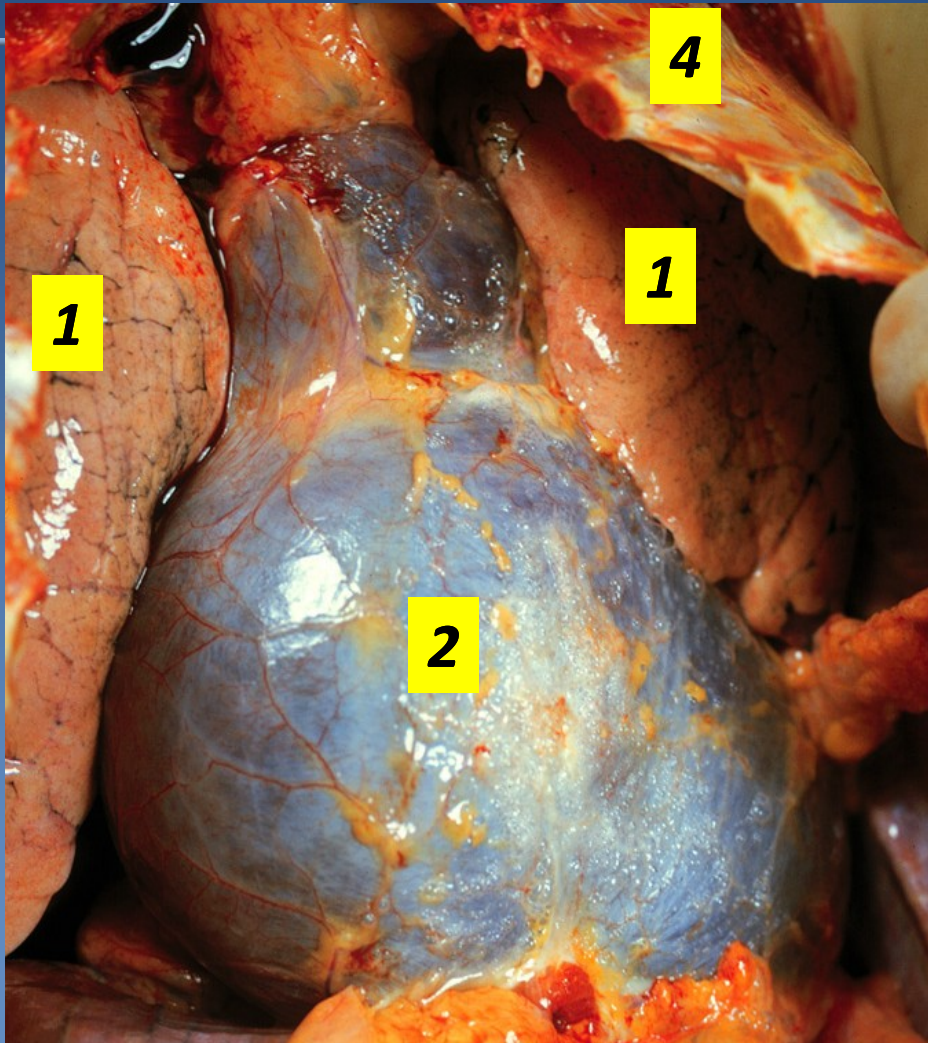
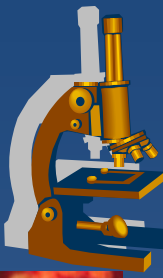
MI – mural thrombosis



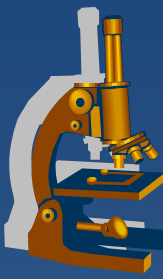
Mi - rupture



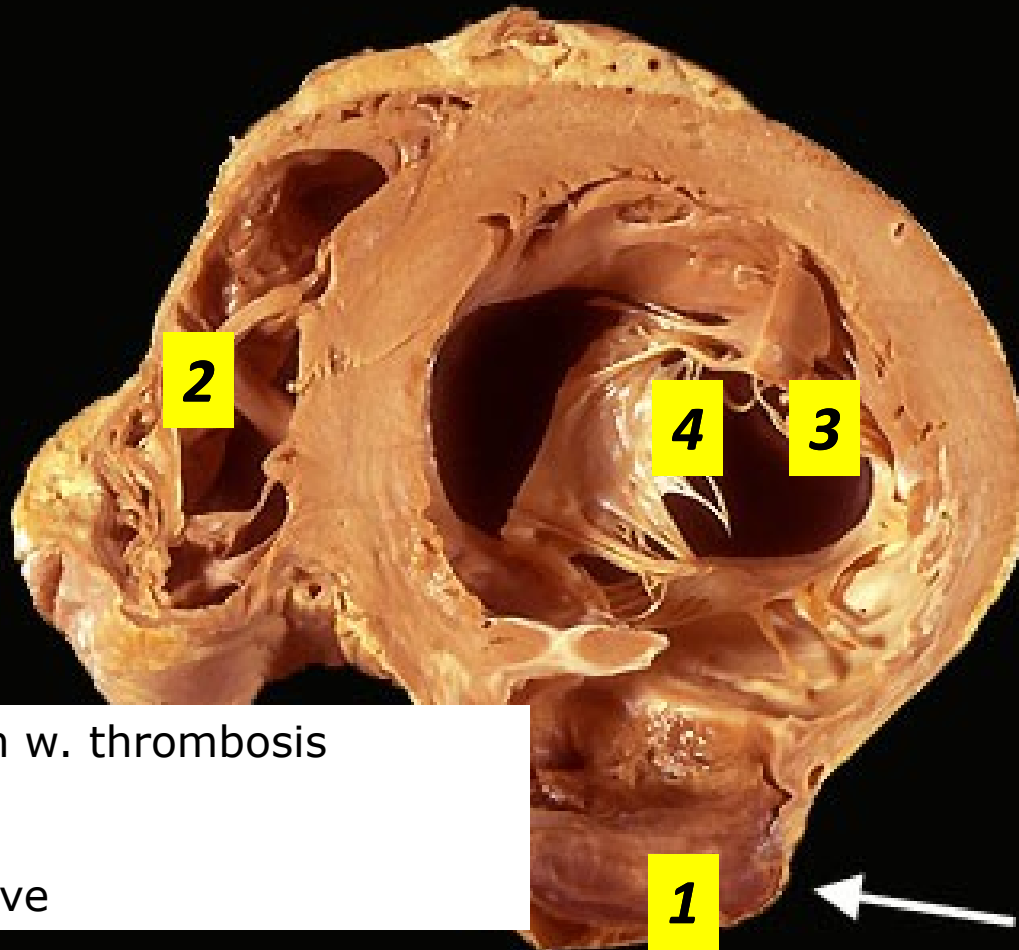
MI – rupture, tamponade



1 lung 2 pericardial sac 3 blood coagulum 4 thoracic wall



MI – LV aneurysm



- 1 aneurysm w. thrombosis
- 2 RV
- 3 LV
- 4 mitral valve

Chronic ischemic heart disease (IHD)



- ✘ angina pectoris or MI in anamnesis
- ✘ progressive heart failure due to ischemic myocardial damage → LV failure → congestive RV failure
- ✘ heart hypertrophy + dilatation, myofibrosis and/or post-MI scars
- ✘ multiple coronary arteries with significant AS stenosis
- ✘ imminent risk of MI, sudden cardiac death due to arrhythmia, heart failure

Sudden cardiac death



= unexpected death from cardiac causes, without preexisting symptoms or within 1 hr of the onset of symptoms

✗ most commonly due to lethal arrhythmia (ventricular fibrillation, asystole)

✗ sudden collapse without signs of acute MI

✗ other causes:

⇒ *dissecting/ruptured aortic aneurysm*

⇒ *pulmonary thromboembolism*

⇒ *massive intracerebral haemorrhage*

⇒ *heritable conditions incl. anatomic, electrical – channelopathies*

Myocarditis



- ✗ myocardial inflammatory damage without ischemia

- ✗ **gross:**
 - ⇒ *cardiac dilatation, flabby, mottled myocardium*

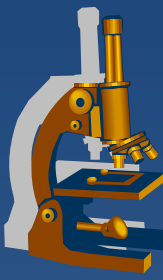
- ✗ **micro:**
 - ⇒ *inflammatory infiltrate (according etiology) + cardiomyocyte regressive changes incl. necrosis*

- ✗ **etiology:**
 - ⇒ viruses, rickettsia, chlamydia, bacteria (diphtheria, sepsis), fungi, protozoa (toxoplasmosis), helminths (trichinosis)
 - ⇒ immune-mediated (*drug hypersensitivity, postviral, rheumatic fever, rejection*)
 - ⇒ *ionising radiation*
 - ⇒ unknown (*giant-cell myocarditis*)

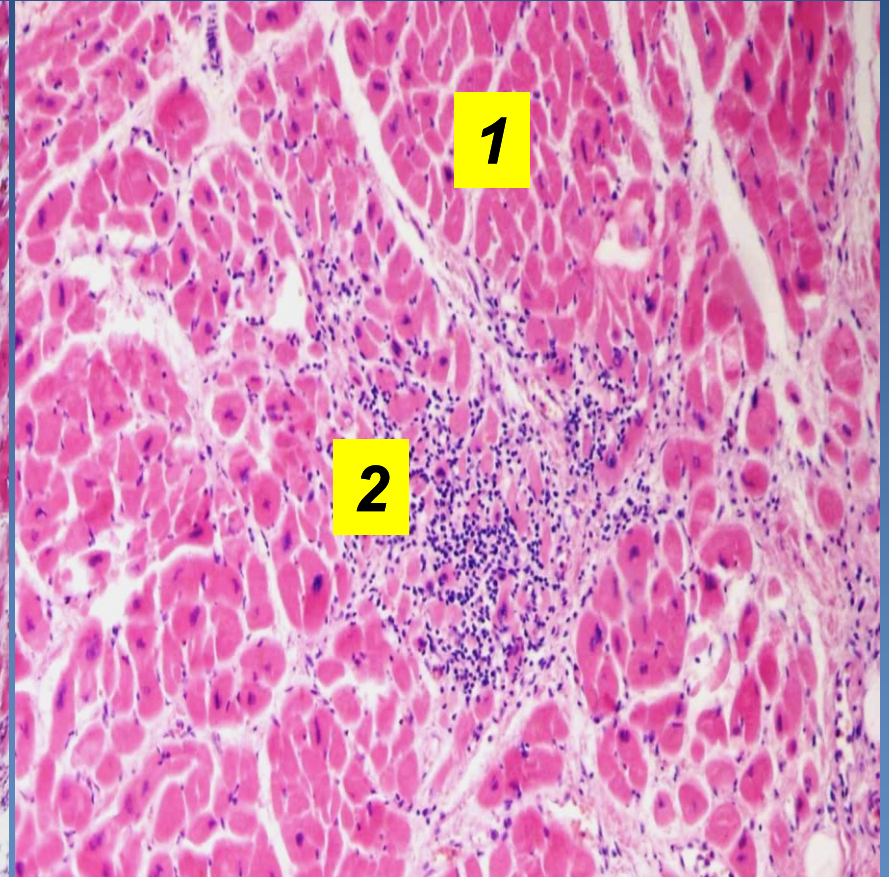
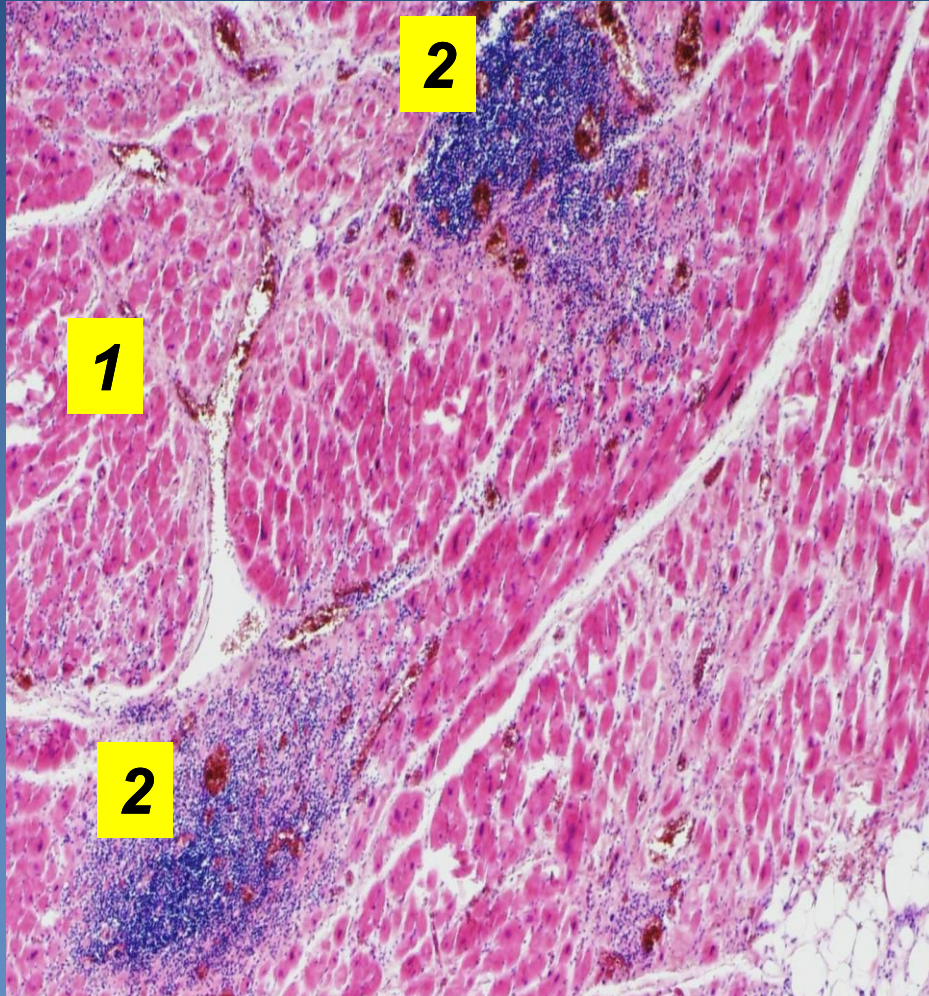
Viral myocarditis



- ✗ *Coxsackie, parvovirus B19, influenza, EBV, CMV, HIV*
- ✗ inflammatory infiltrate: T-cells mostly
- ✗ after acute attack commonly autoimmune-mediated cardiomyocytes destruction and fibrosis → dilated cardiomyopathy

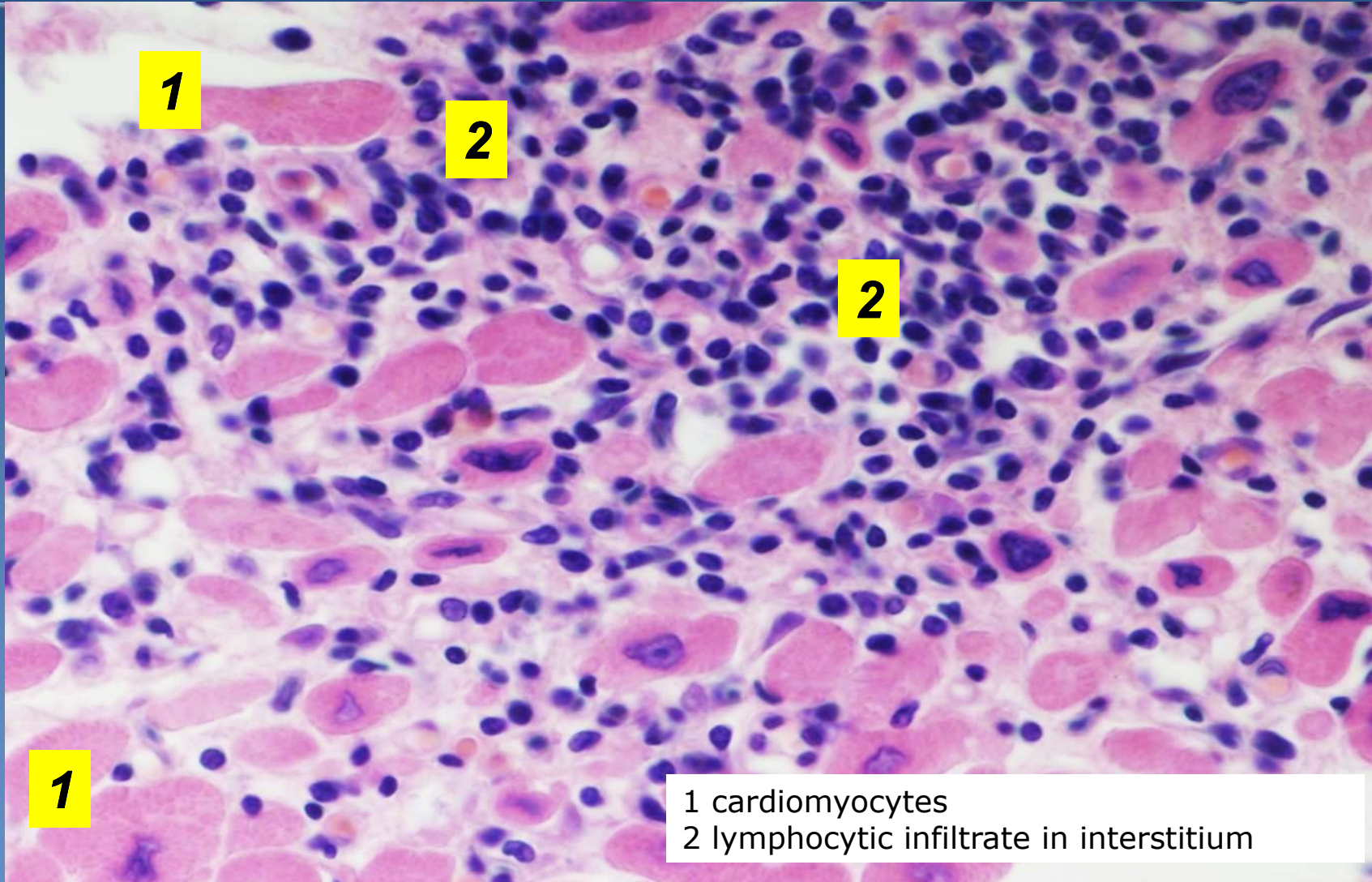


Viral myocarditis



1 cardiomyocytes
2 lymphocytic infiltrate in interstitium

Viral myocarditis



1 cardiomyocytes
2 lymphocytic infiltrate in interstitium

Heart and COVID-19



- ✘ patients w. preexisting cardiovascular lesions in increased risk of worse course (approx. 1/2 in hospitals)
- ✘ general common cardiovascular lesions
 - ⇒ 10-20 %, raised troponin, arrhythmia in acute stage
 - ⇒ cardiomyopathy in „Long COVID syndrome“ 30-90 d. after dg., abnormalities on MRI, atypical stenocardias, dyspnoea
- ✘ etiology
 - ⇒ hypoxia + ischemia due to lung lesions (pneumonia, ARDS)
 - ⇒ lymphocytic myocarditis
 - ⇒ microvasculopathy + thrombosis
- ✘ in children and teens possible part of COVID-associated multisystem inflammatory syndrome in children (MIS-C)

MIS-C



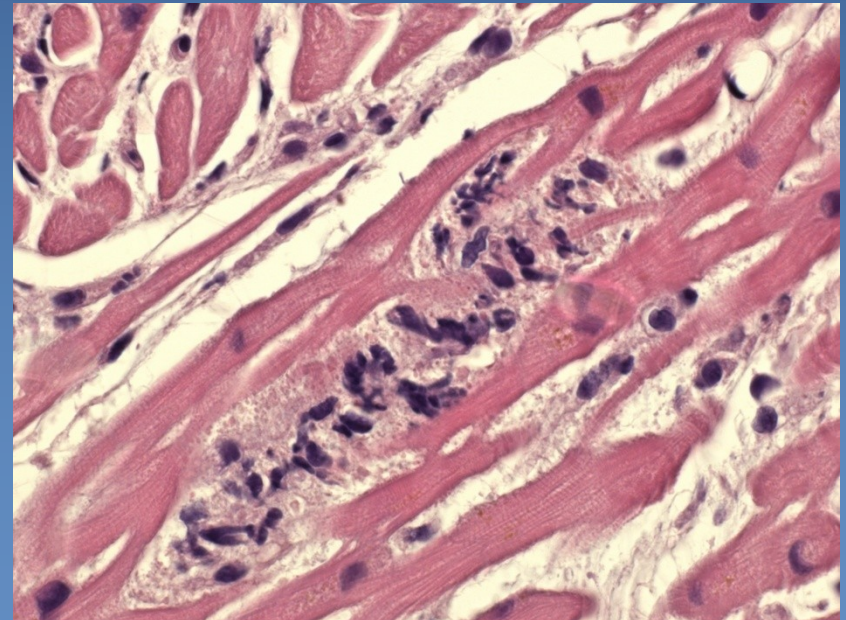
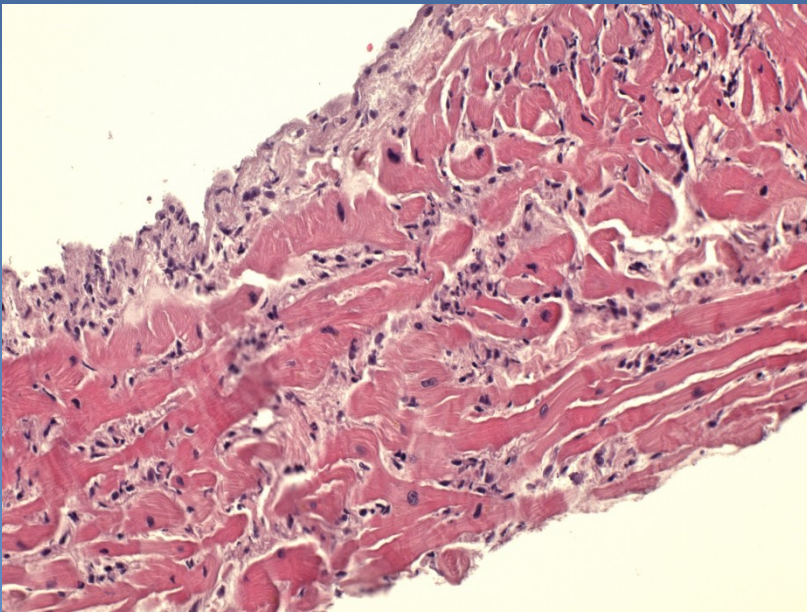
- ✗ Kawasaki-like disease
- ✗ delayed signs, some weeks after infection (commonly 3-4)
- ✗ fever, inflammatory signs in lab tests, lesion up to failure in min. 2 organ systems (heart in 80 %, renal, GIT, lung, neurological, ...), association w. SARS-CoV-2
- ✗ commonly acute heart failure, shock, peri-myocarditis
- ✗ rare (cca 10 %) coronary aneurysms
- ✗ micro: myocarditis w. oedema, mixed infl. reaction w. neutrophils, macrophages, lymphocytes, eosinophils), possible cardiomyocyte necrosis
- ✗ most patients survive, rapid recovery

MIS-C

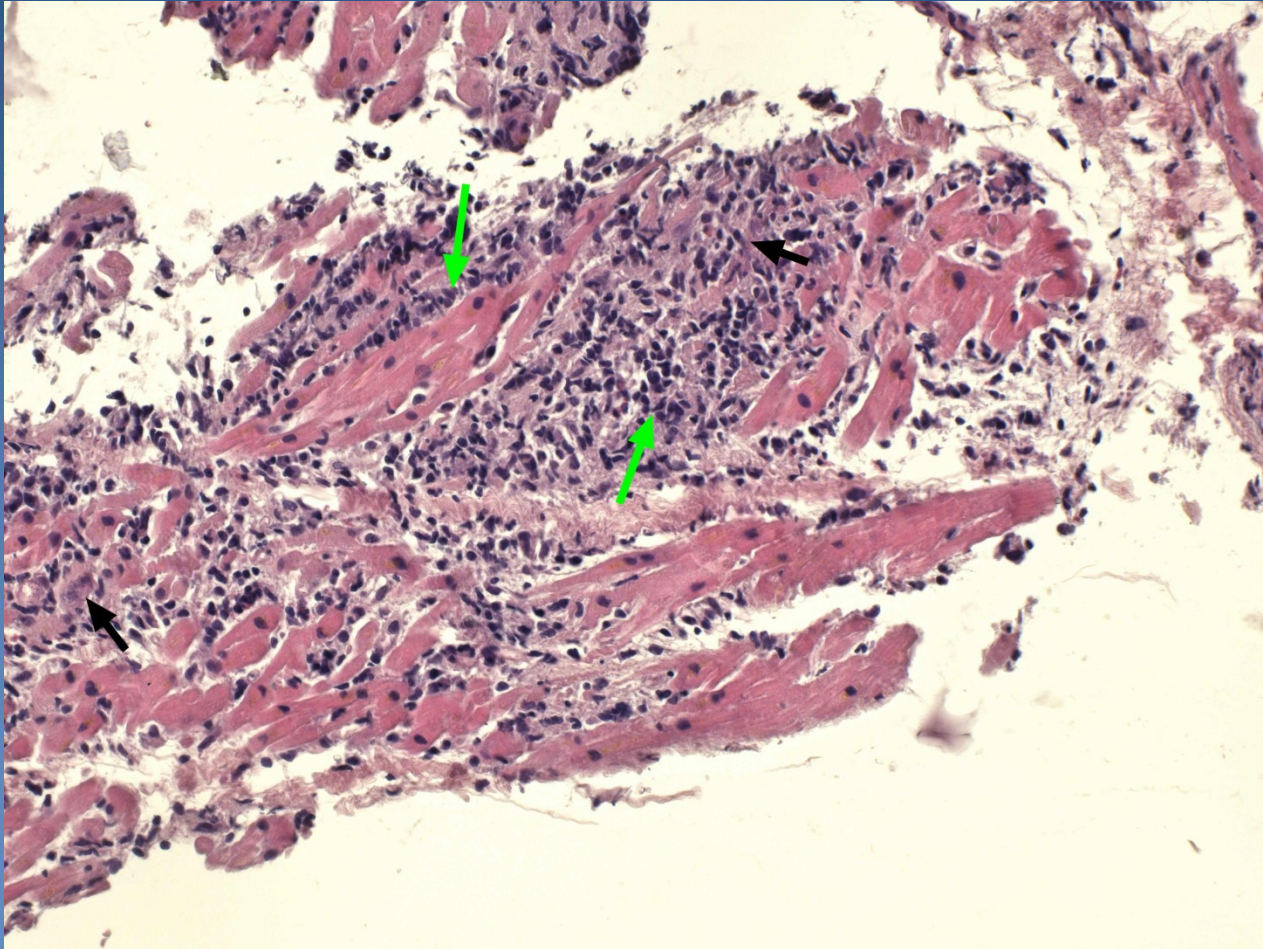


✗ male, age 19

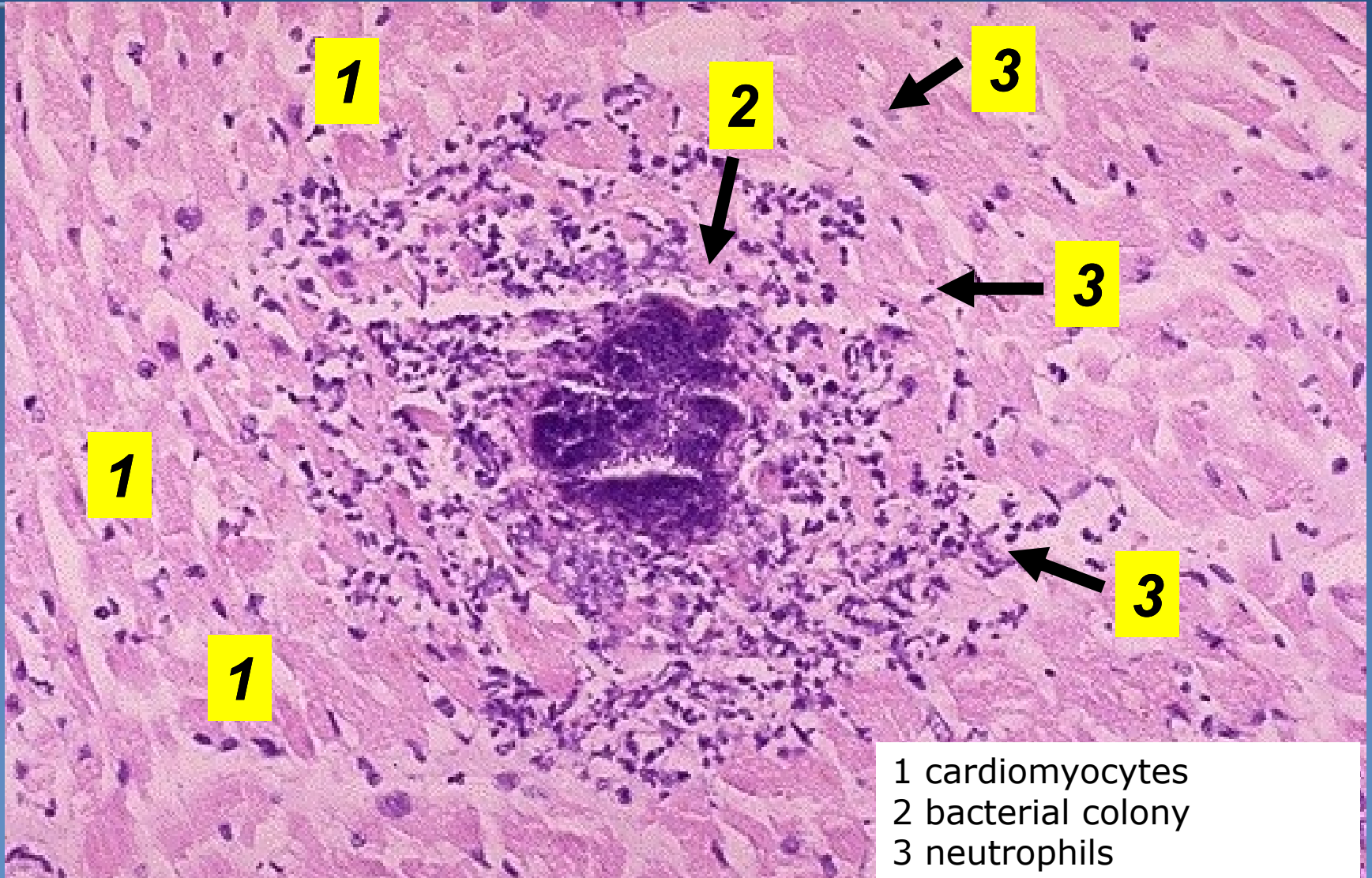
✗ EMB



Eosinophilic myocarditis



Septic myocarditis



Cardiomyopathies



= heart disease due to myocardial abnormality, with heart dysfunction
diagnosis after exclusion of IHD, valvular disease, congenital d. or hypertension

✘ heterogenous group of disorders:

⇒ dilated (DCM)

– dilatation + hypertrophy, ↓ LV contraction, possible mural thrombosis; 20–50% genetic (AD);
alcoholic, peripartum, myocarditis...

⇒ hypertrophic (HCM)

– massive LV hypertrophy, 100% genetic, diastolic dysfunction, histologic „disarray“

⇒ restrictive cardiomyopathy

– diastolic dysfunction, ↓ of compliance - ↓ filling, myocardial stiffness

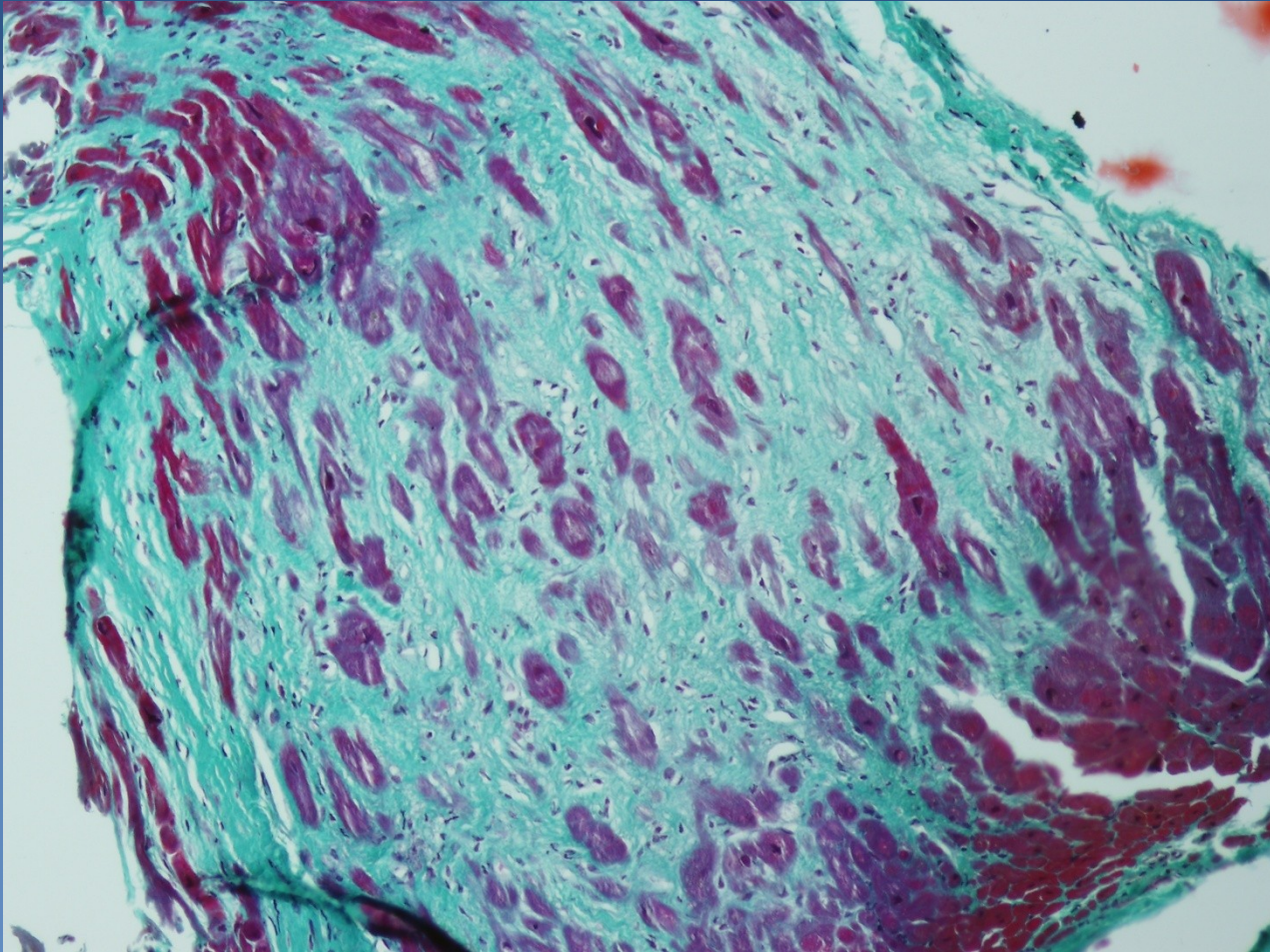
⇒ specific CM

– Duchenne muscle dystrophy, toxic (drugs), endocrine d., metabolic d. (hemochromatosis, amyloidosis, glykogenosis, ...)

Dilated cardiomyopathy



Cardiomyopathy

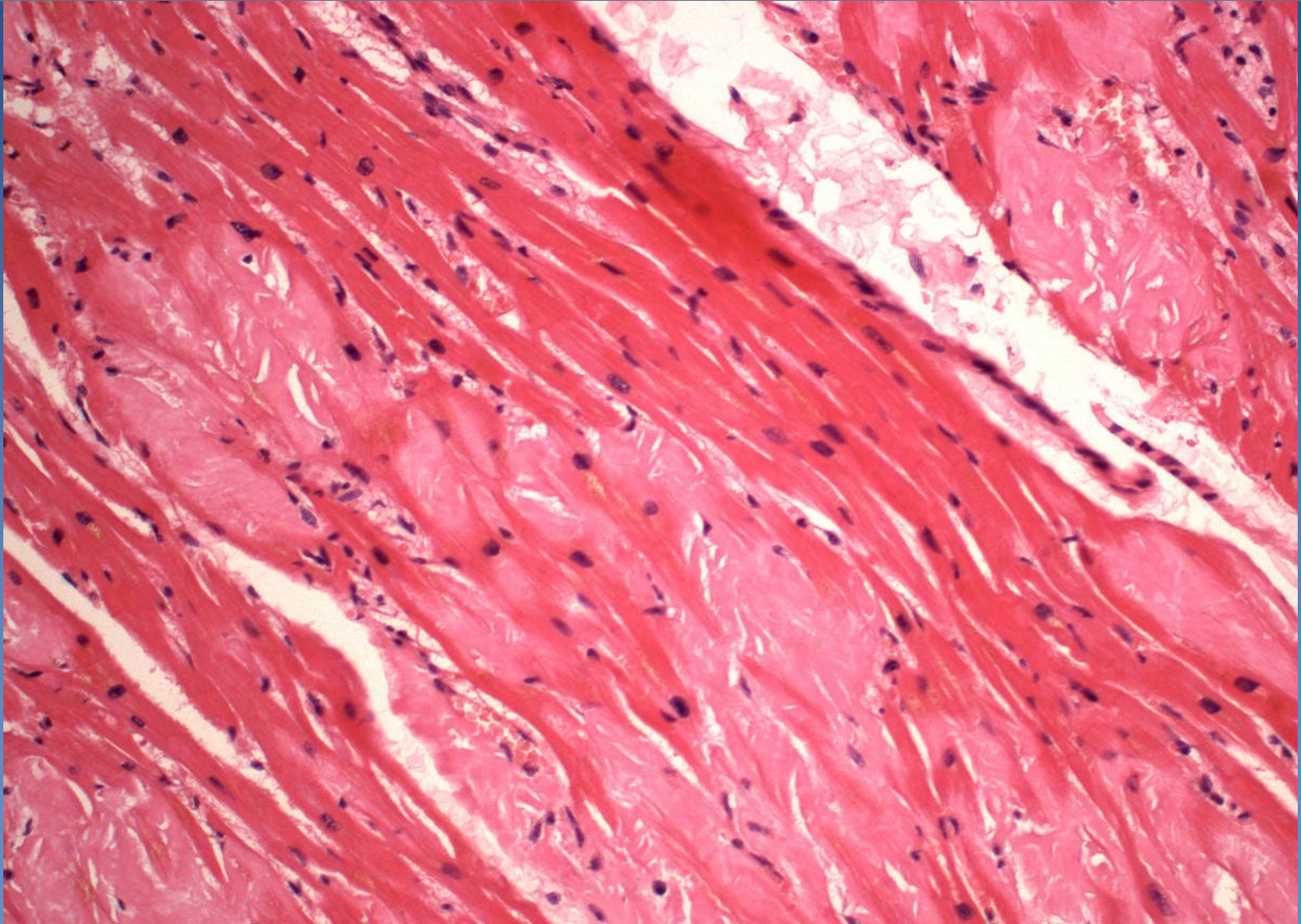
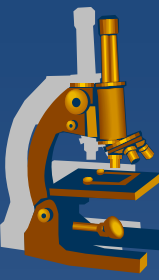


Myocardial amyloidosis

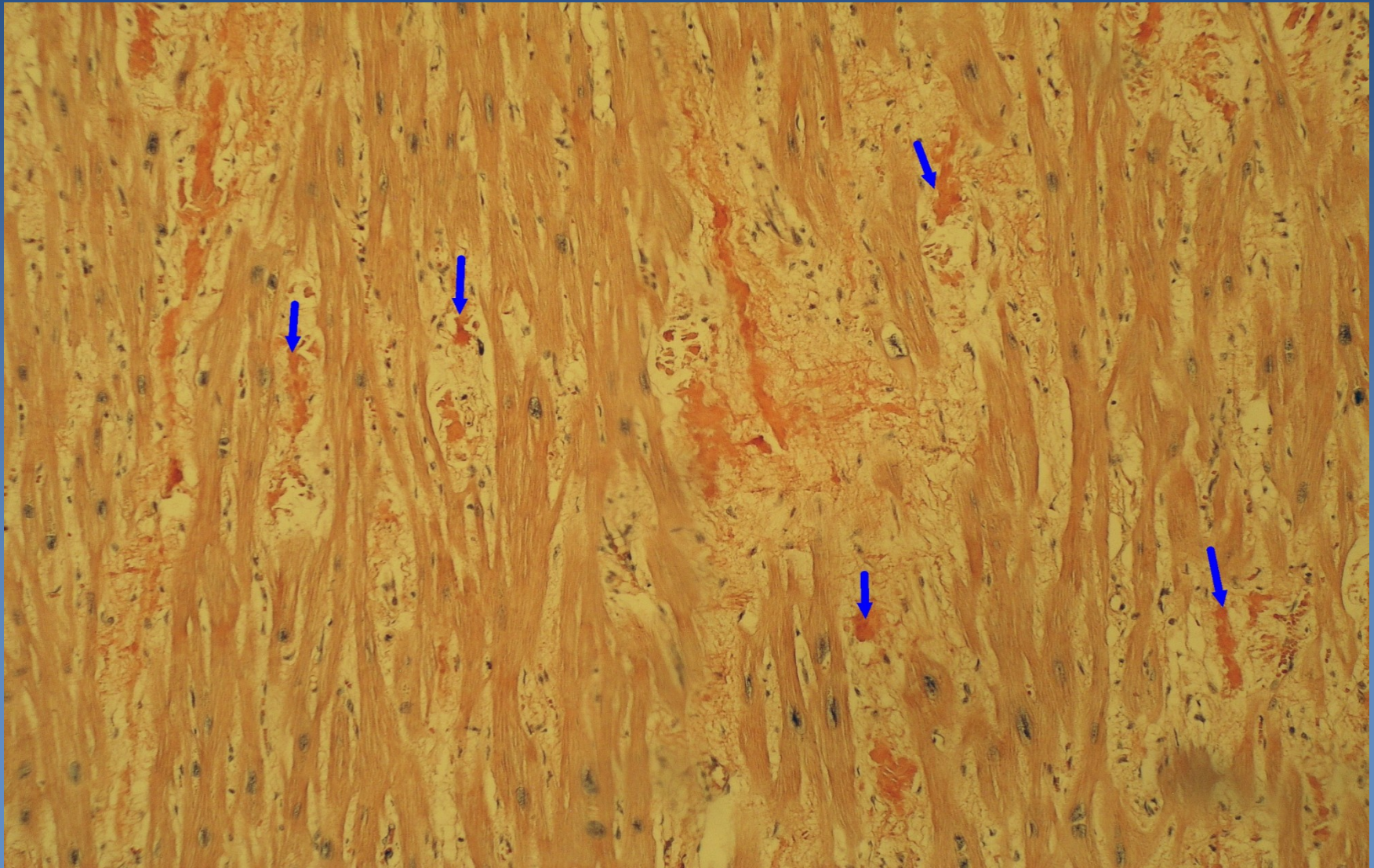


- ✗ local x systemic (mostly AL amyloidosis)
- ✗ senile amyloidosis
 - ⇒ *atrial + ventricles; amyloid protein = prealbumin (transthyretin)*
- ✗ *isolated atrial amyloidosis*
 - ⇒ *amyloid protein = atrial natriuretic peptide*
- ✗ **gross**: consistency normal - firm (rubbery)
- ✗ **micro**: variable amyloid deposits v interstitium and vessels, Congo red + polarization

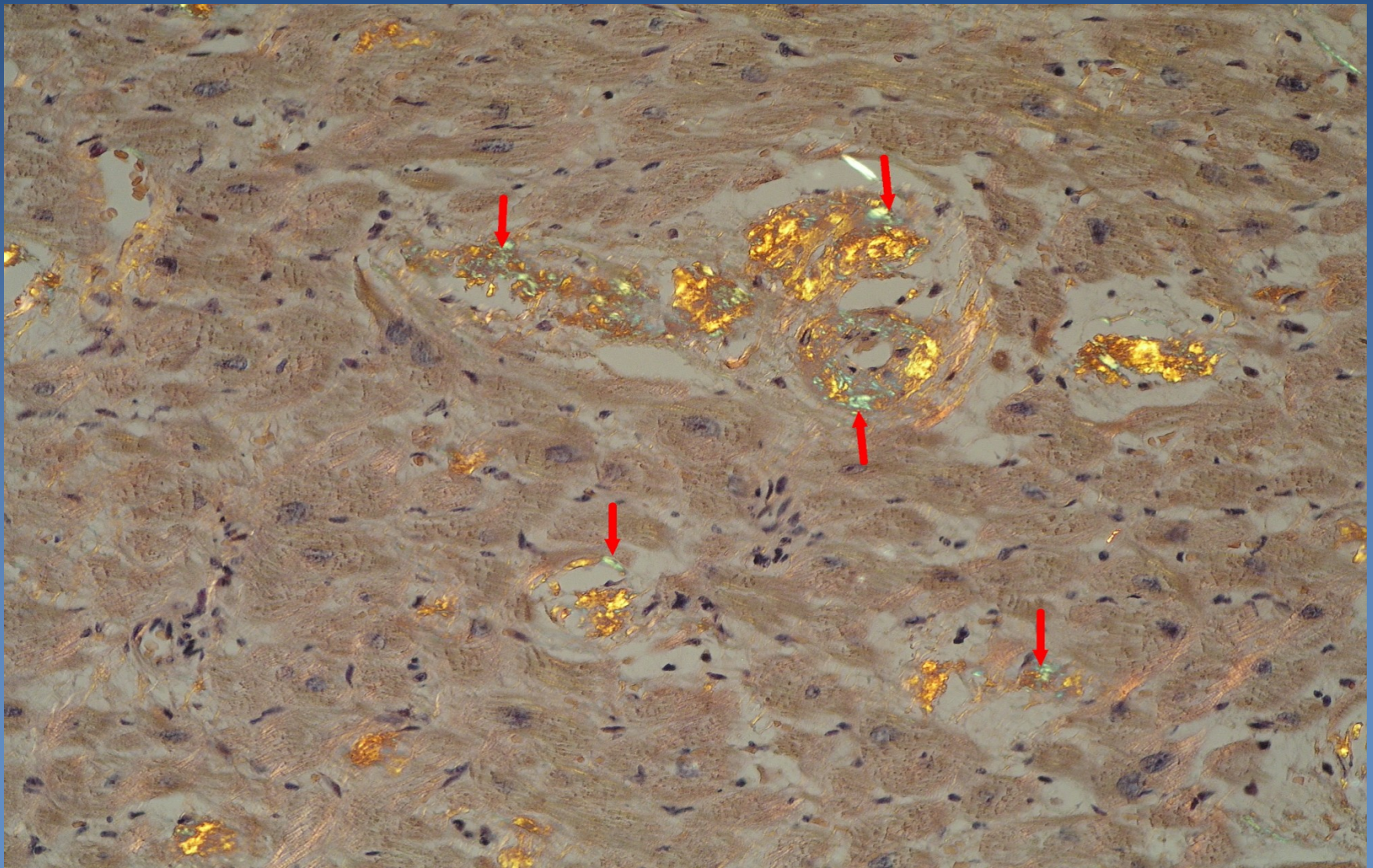
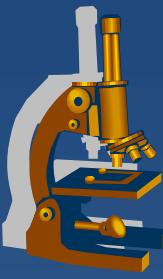
Myocardial amyloidosis



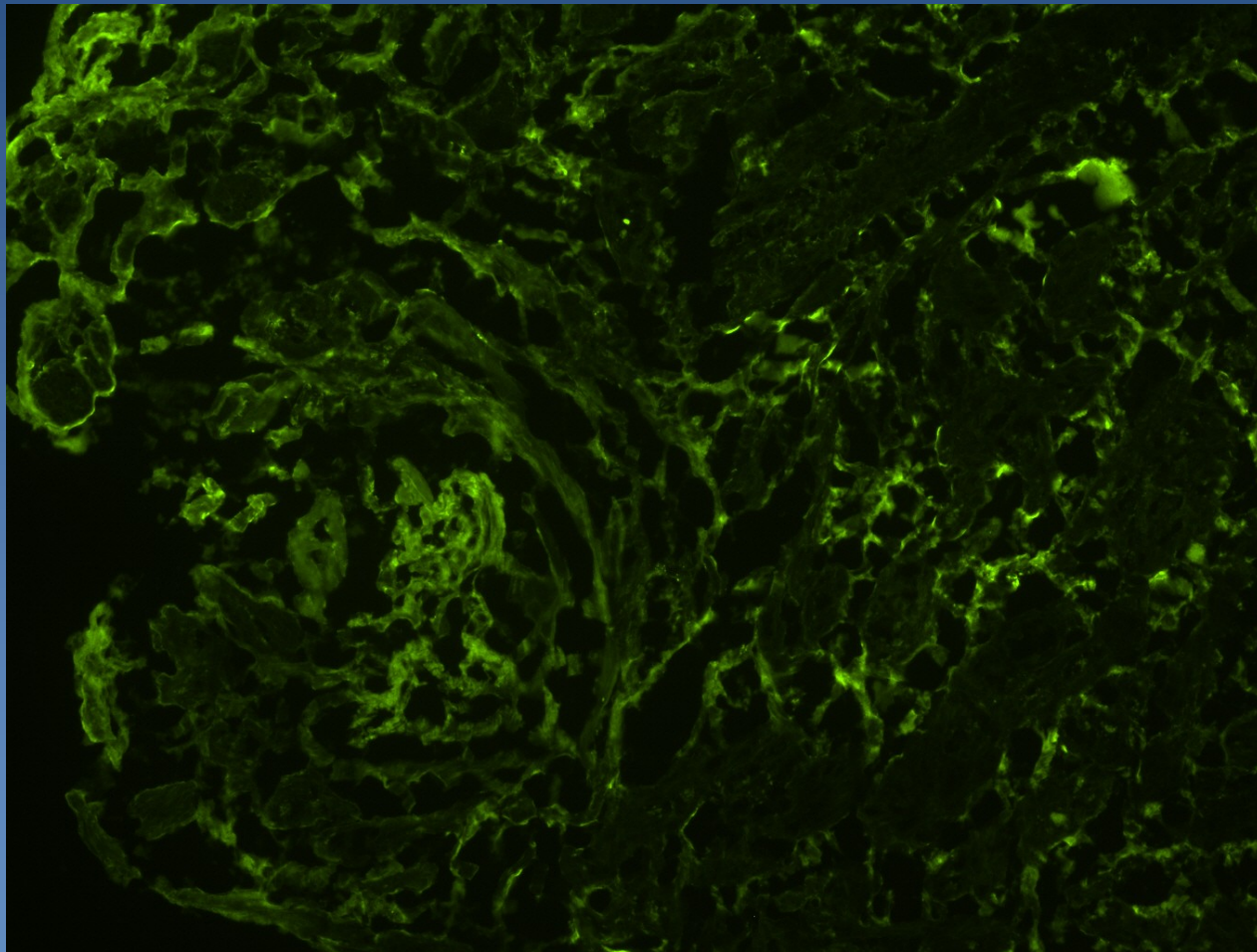
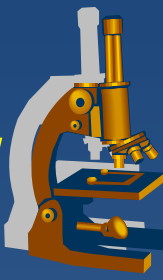Myocardial amyloidosis



Myocardial amyloidosis



Myocardial amyloidosis - IMF



Endocardial / valvular diseases



- ✘ endocarditis

 - ⇒ *infectious or immune-mediated endocardial inflammation*

- ✘ degenerative diseases

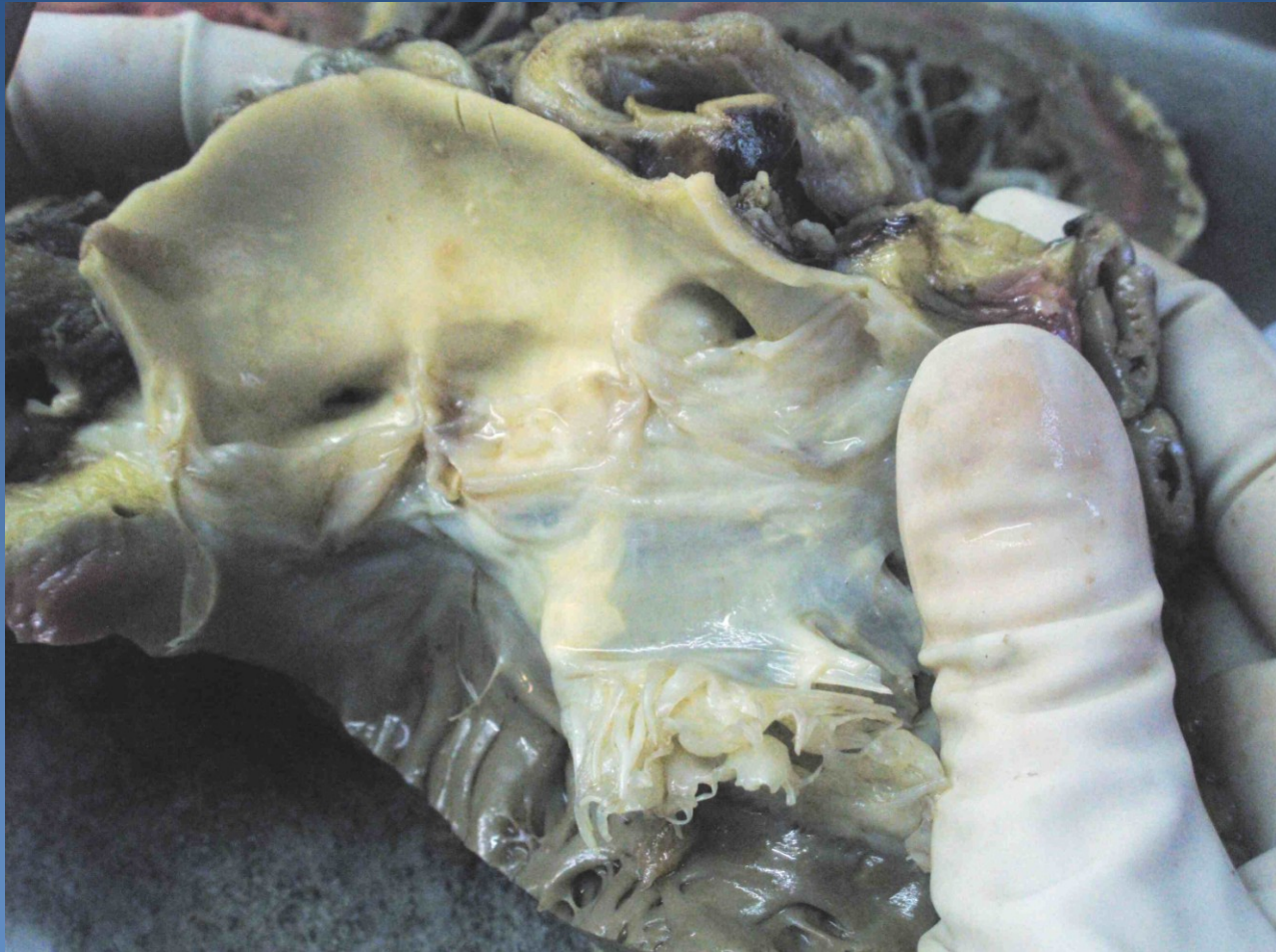 - ⇒ *calcific aortic (rarely mitral) stenosis, mitral valve prolapse, annular and marginal sclerosis*

- ✘ endocrine diseases

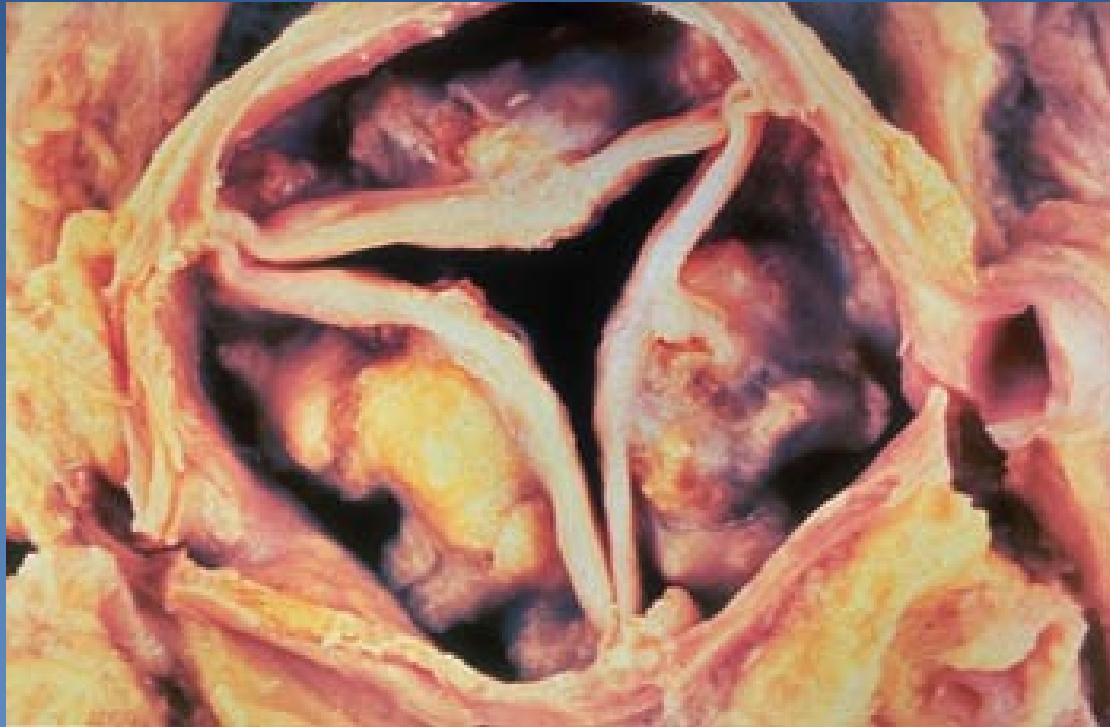 - ⇒ *carcinoid syndrome*

- ✘ nonbacterial thrombotic endocarditis (in debilitated patients)

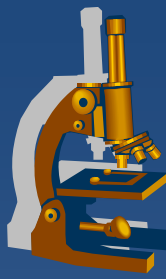
Mitral valve prolapse



Aortic valve calcification



Rheumatic fever, rheumatic heart disease



✗ acute non-purulent, **immune-mediated** systemic poststreptococcal inflammation (cross-reactive antibodies)

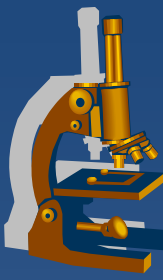
✗ acute stage: **PANCARDITIS**

⇒ *fibrinous pericarditis + myocarditis with Aschoff bodies (foci of **fibrinoid necrosis** + inflammatory reaction + verrucous endocarditis (small depositions of fibrin along the closure lines of Ao a Mi valves)*

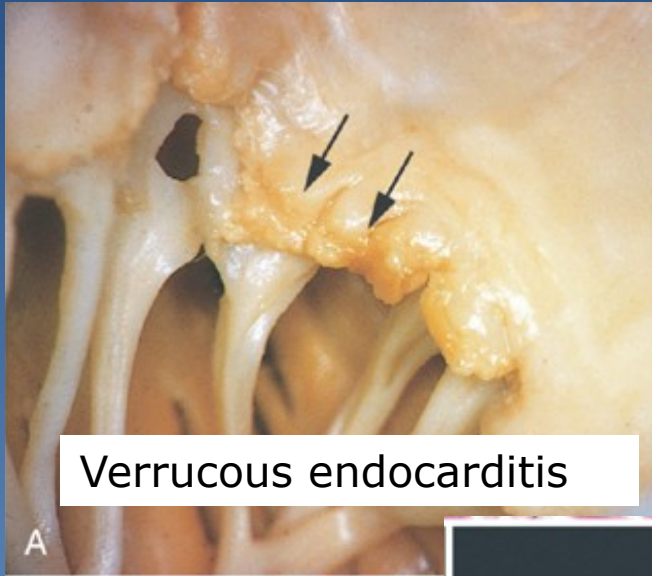
⇒ *acute endocarditis commonly recurrent*

✗ chronic stage:

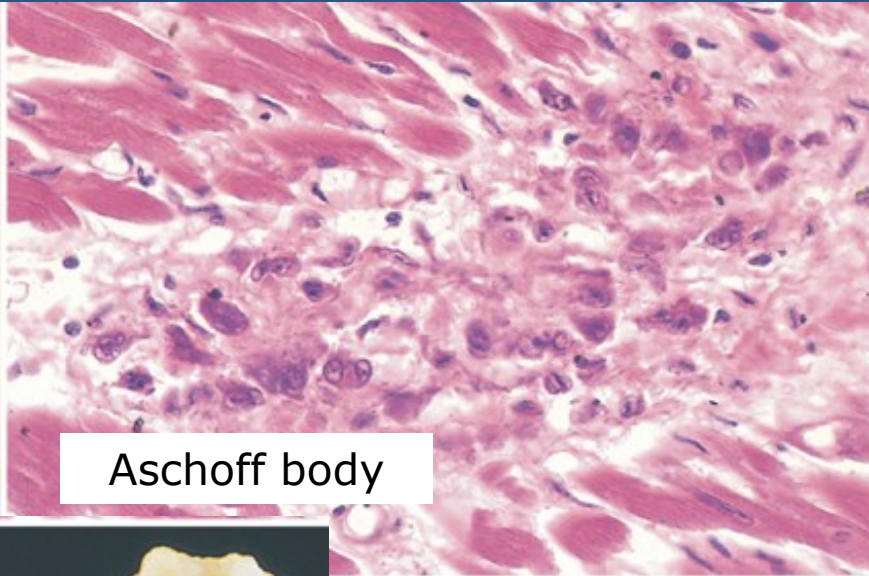
⇒ *diffuse fibrous thickening + distortion, commissural fusion → dystrophic calcification - stenosis + incompetence)*



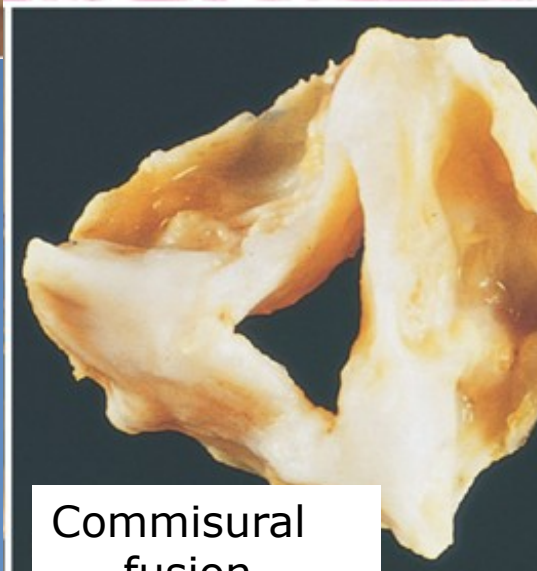
rheumatic heart disease



Verrucous endocarditis



Aschoff body



Commissural fusion

Infective endocarditis



- ✘ commonly by highly virulent microorganisms
 - ⇒ *Strep. pyogenes, Strep. pneumoniae, Staph. aureus, ... ev. fungi*
- ✘ subacute IE – less virulent microorganisms
 - ⇒ *viridans streptococci*
- ✘ predisposition:
 - ⇒ *deformed valve, bioprosthesis, postcatethrization, i.v. drug addicts*
- ✘ bacteremia - endocardial damage by bacteria - trombosis = infective vegetation

Infective endocarditis



✗ **gross:** friable red-brown mass 0,5-2 cm on leaflets or chordae tendinae, valvular damage incl. ulceration

✗ **micro:**

⇒ *fibrin + bacterial colonies + neutrophils (+ granulation tissue)*

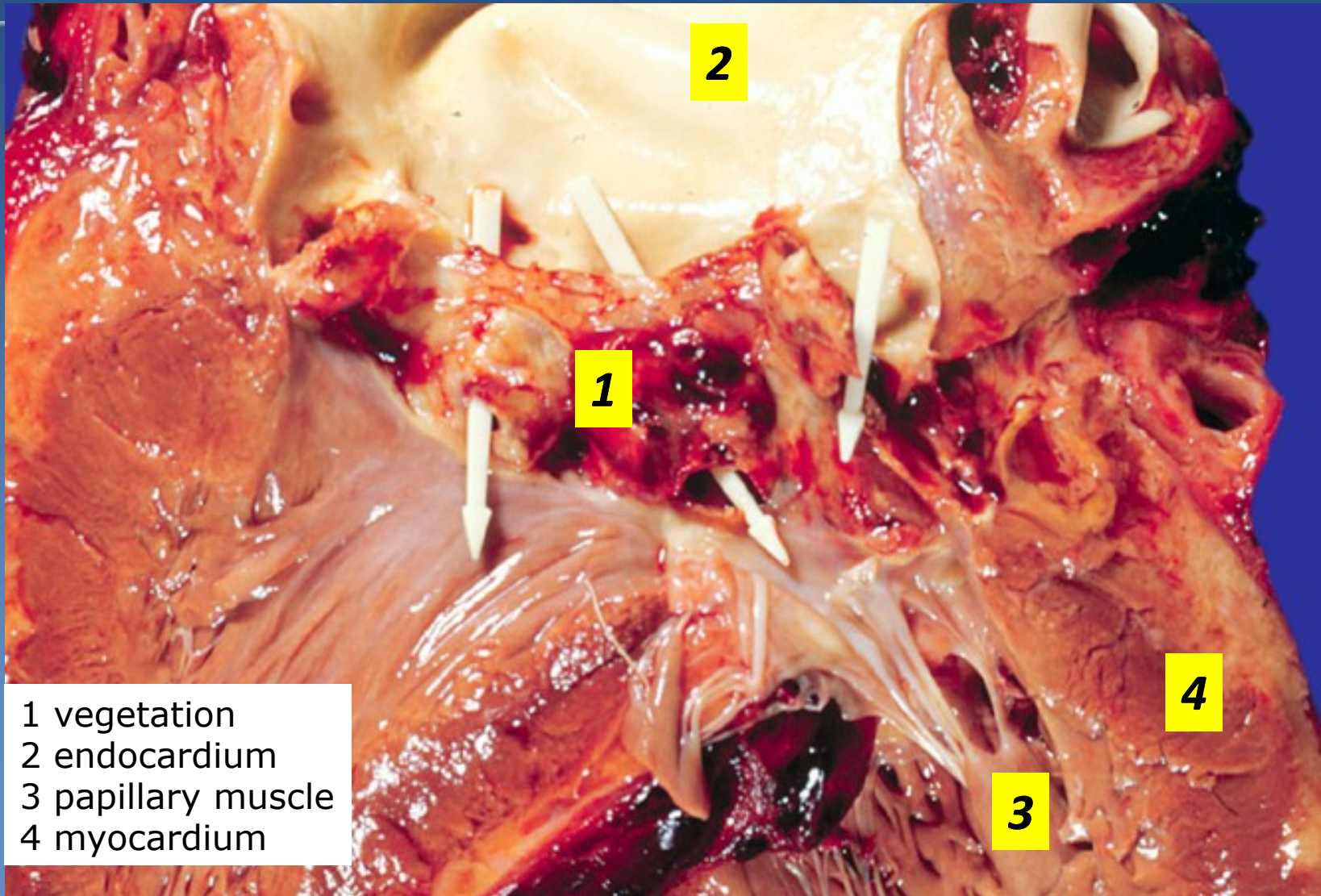
⇒ *Inflammation/ necrosis of the valve tissue*

✗ **complications:**

⇒ *acute: valvular damage, myocarditis + abscess, pyemia, thrombembolism*

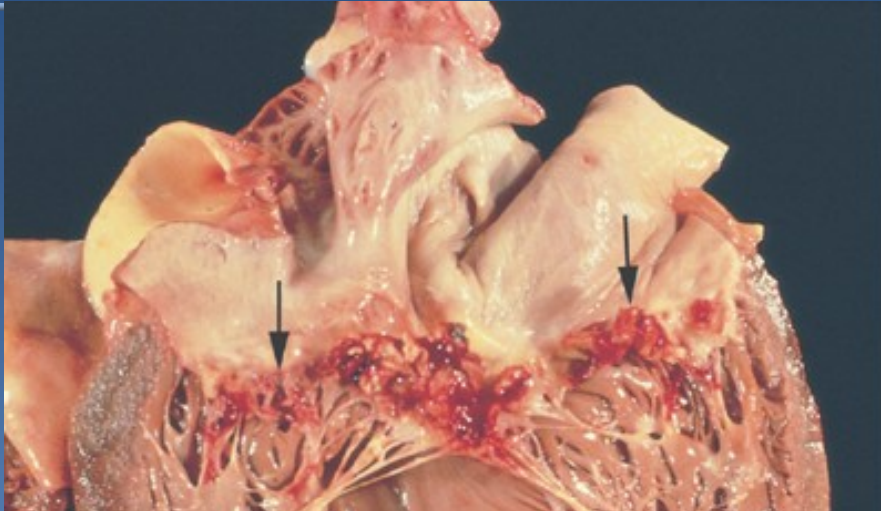
⇒ *chronic valvular disease*

Infective endocarditis- valve destruction

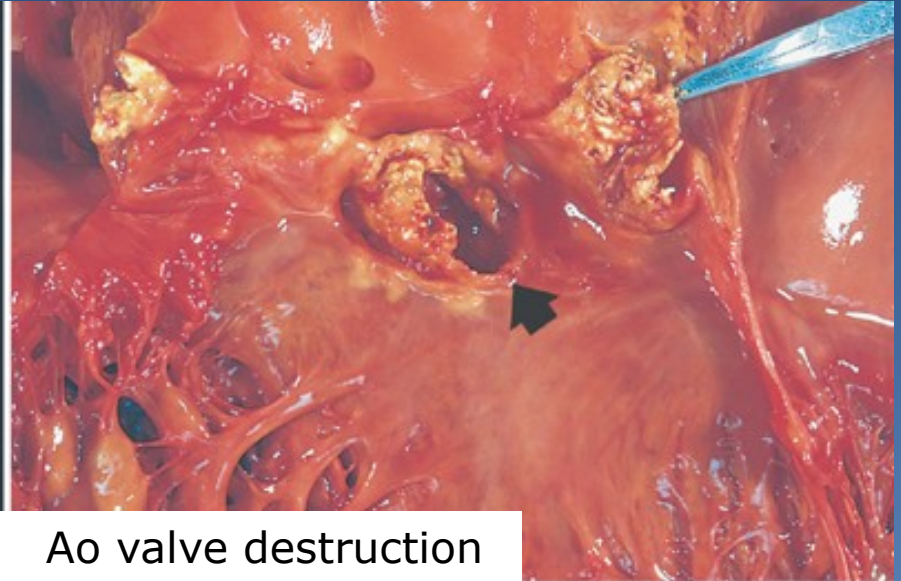


- 1 vegetation
- 2 endocardium
- 3 papillary muscle
- 4 myocardium

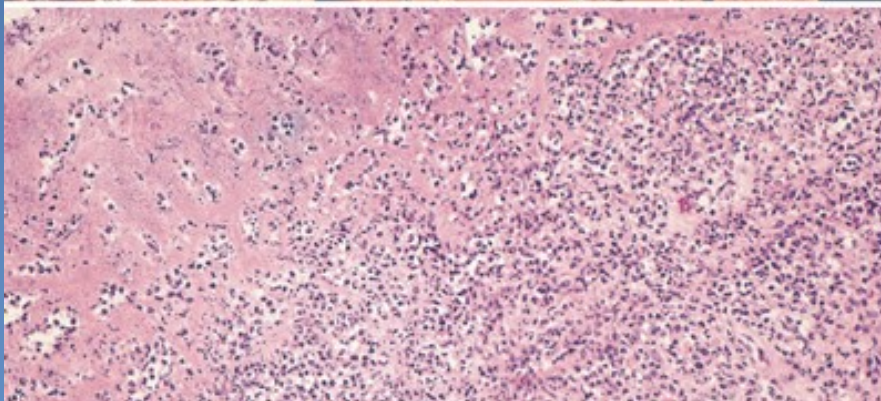
Infective endocarditis



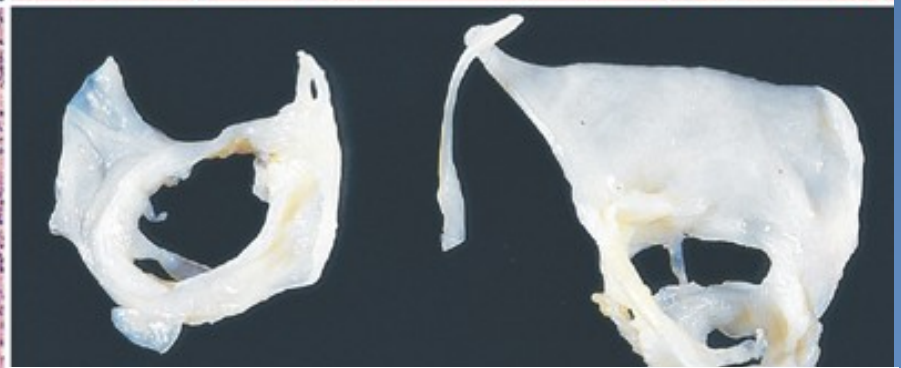
Mi vegetations



Ao valve destruction

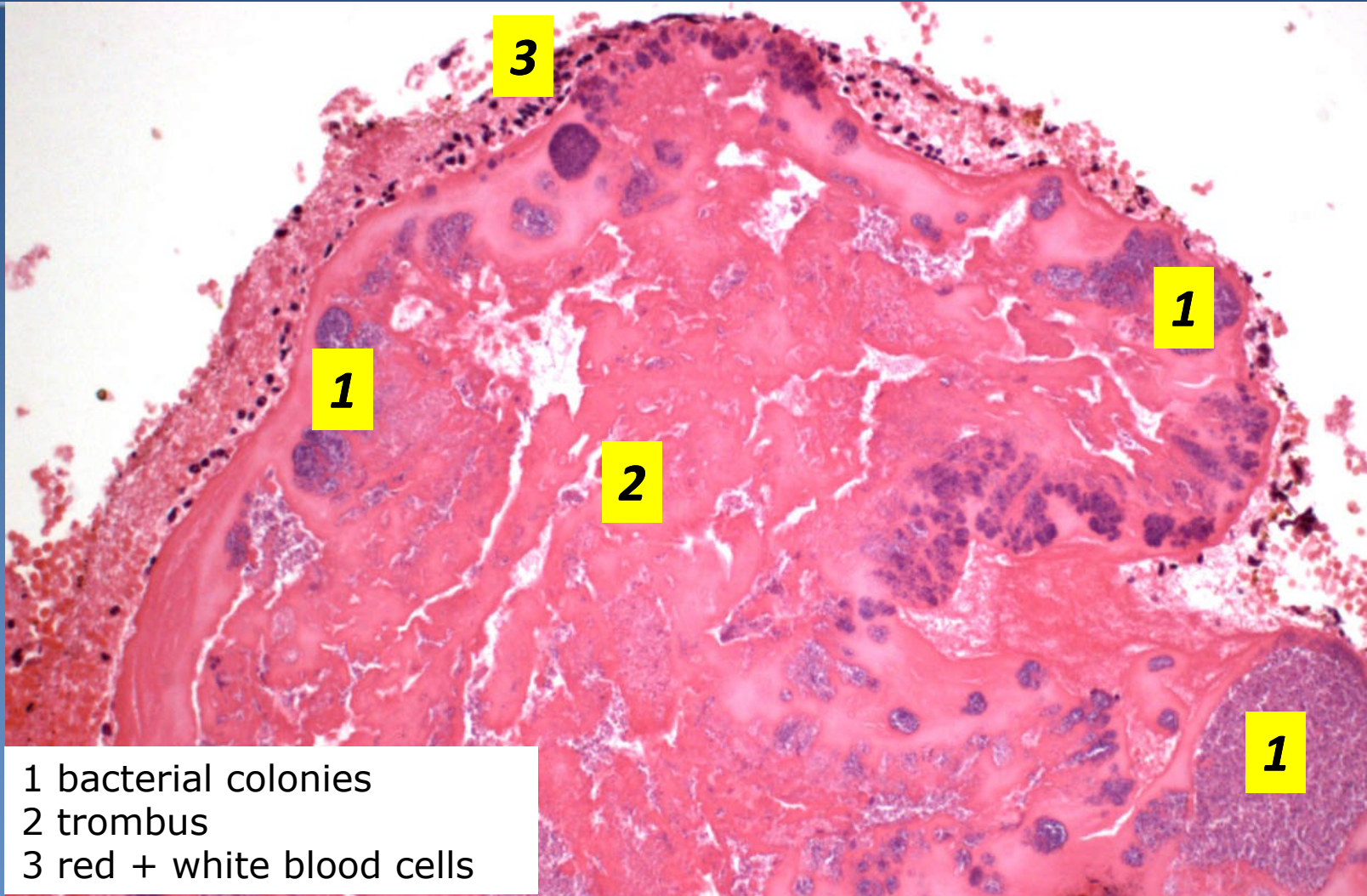


purulent inflammation



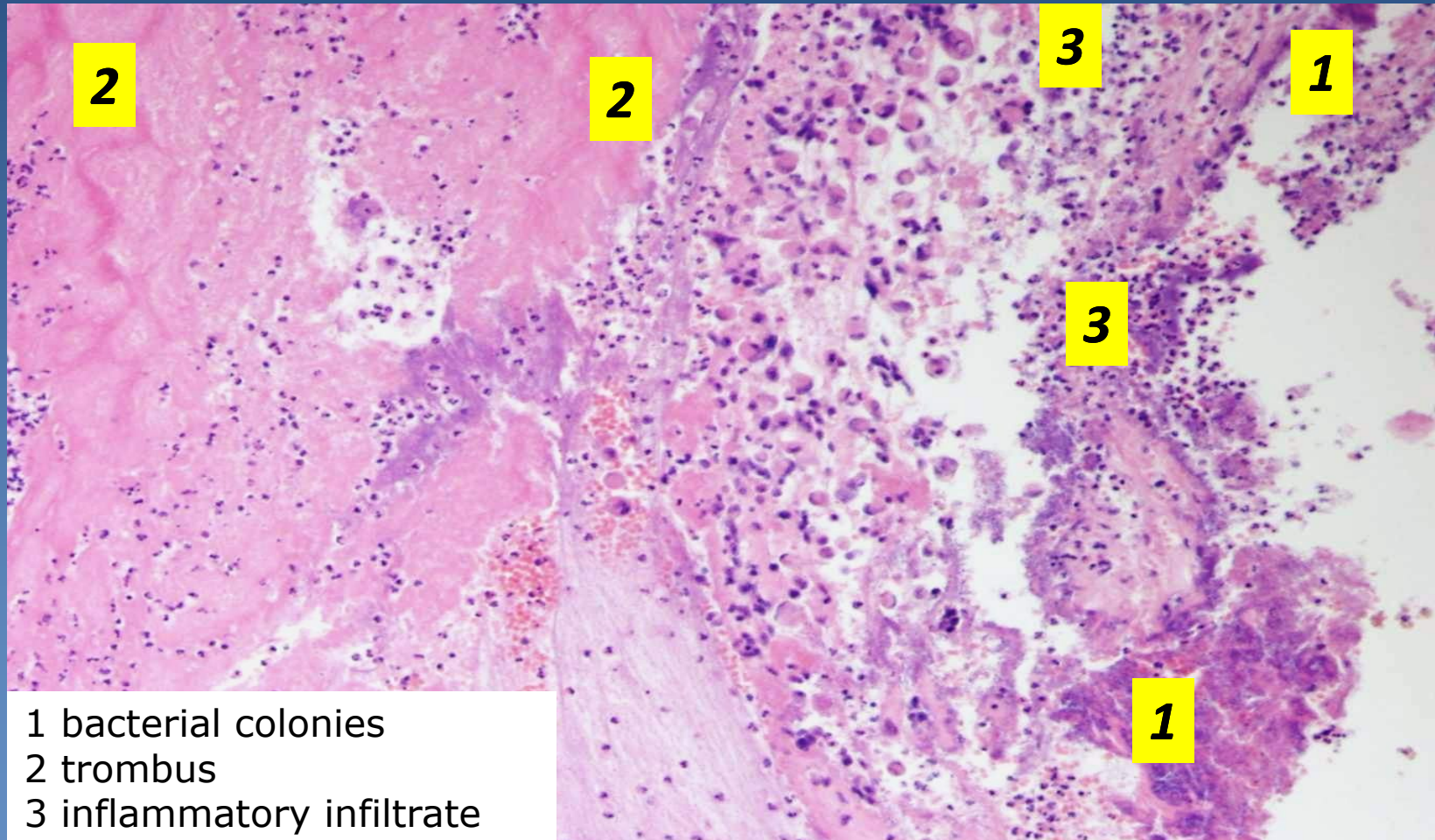
IE repair (Mi fenestration without vegetations)

Infective endocarditis - vegetations



- 1 bacterial colonies
- 2 trombus
- 3 red + white blood cells

Infective endocarditis - vegetations



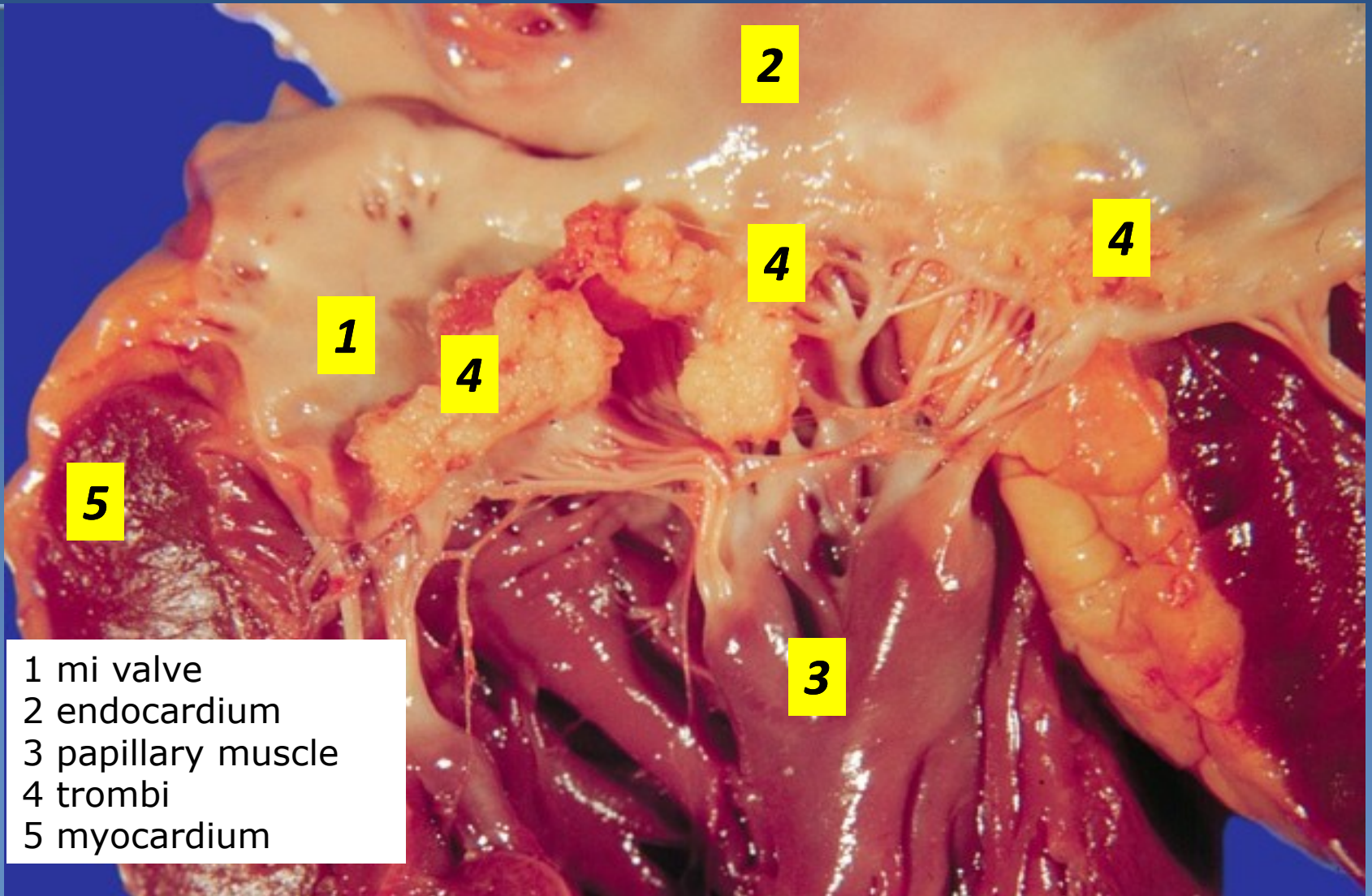
- 1 bacterial colonies
- 2 trombus
- 3 inflammatory infiltrate

Non-bacterial thrombotic endocarditis



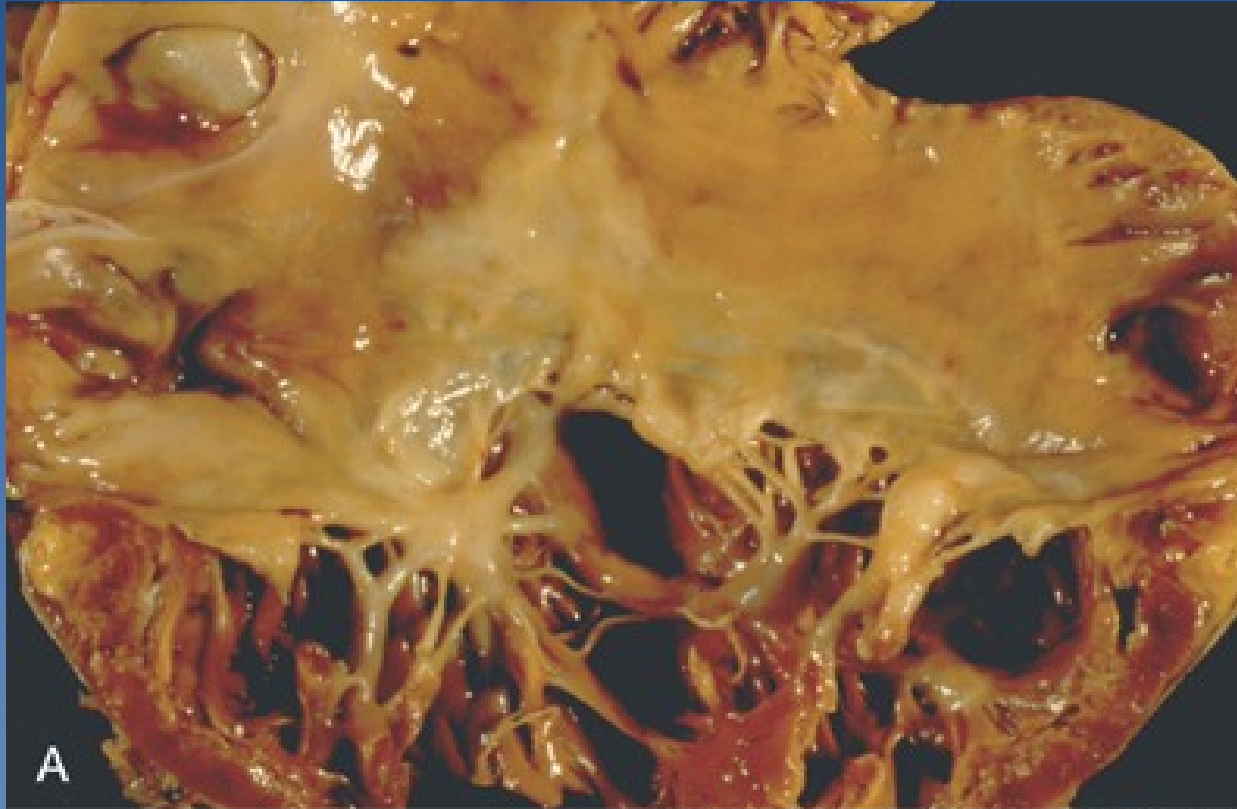
- ✗ **sterile** vegetations due to **hypercoagulative state** \Rightarrow concurrent venous thrombosis and lung embolization
- ✗ **in generalized malignancies**, chronic nephropathy with uremia, COPD etc.
- ✗ mostly on **mitral valve** (normal)
- ✗ micro: verrucous vegetations (single or multiple), 1-5 mm, bland thrombi
- ✗ possible source of **emboli**

Non-bacterial thrombotic endocarditis

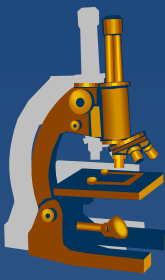


- 1 mi valve
- 2 endocardium
- 3 papillary muscle
- 4 trombi
- 5 myocardium

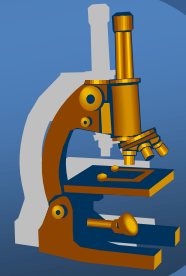
Carcinoid syndrome



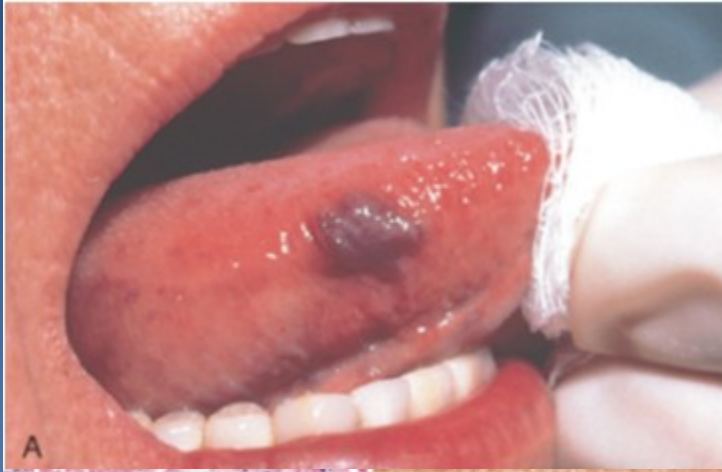endocardial fibrous plaquelike thickenings – RA, RV



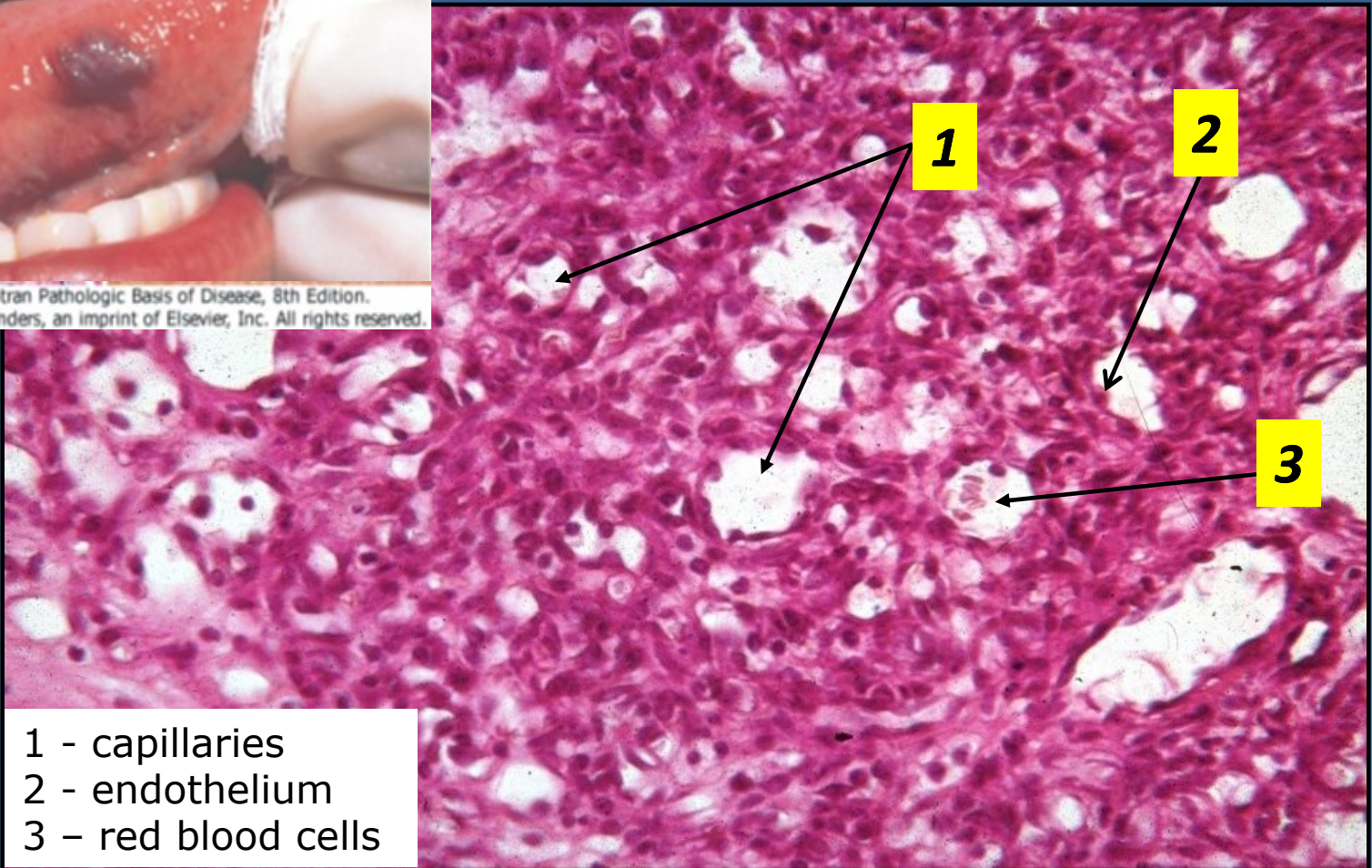
Cardiovascular tumors



Capillary hemangioma



Kumar et al: Robbins & Cotran Pathologic Basis of Disease, 8th Edition.
Copyright © 2009 by Saunders, an imprint of Elsevier, Inc. All rights reserved.



- 1 - capillaries
- 2 - endothelium
- 3 - red blood cells

Cavernous hemangioma

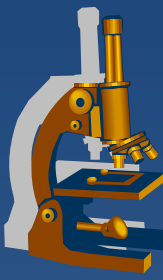


xgross:

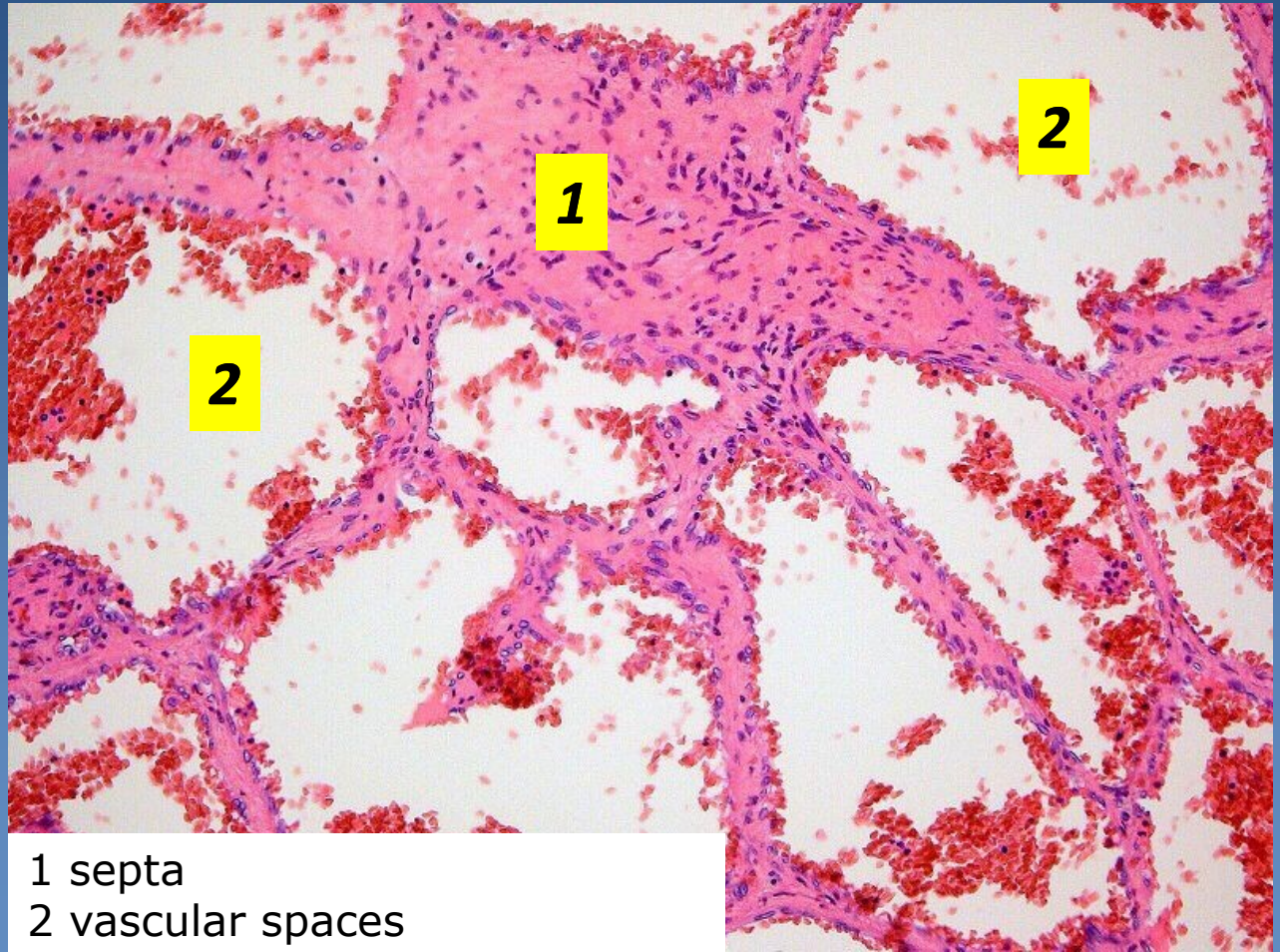
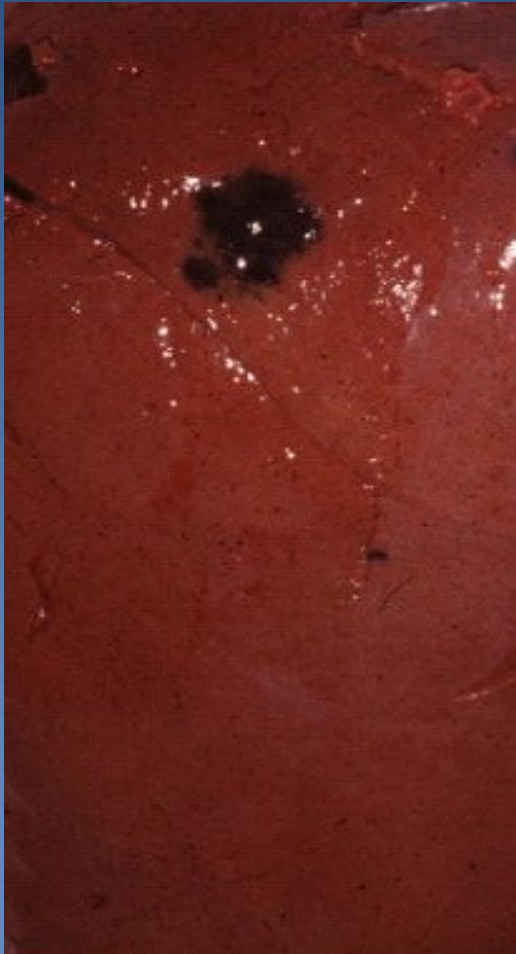
- ⇒ red -blue focus (nodular)
- ⇒ possible large size (-15 cm)
- ⇒ liver, spleen, skin; commonly multiple

xmicro:

- ⇒ large blood-filled vascular spaces divided by fibrous septa



Cavernous hemangioma



1 septa
2 vascular spaces

Kaposi sarcoma



× classic form

- ⇒ *chronic*
- ⇒ *in mediterranean or jewish origin*
- ⇒ *usually (90%) confined to skin*

× endemic

- ⇒ *south-african children*
- ⇒ *lymphadenopathic*
- ⇒ *aggressive*

× immunosuppression (transplant) associated

- ⇒ *– internal organs in 50%*

× AIDS associated

Kaposi sarcoma

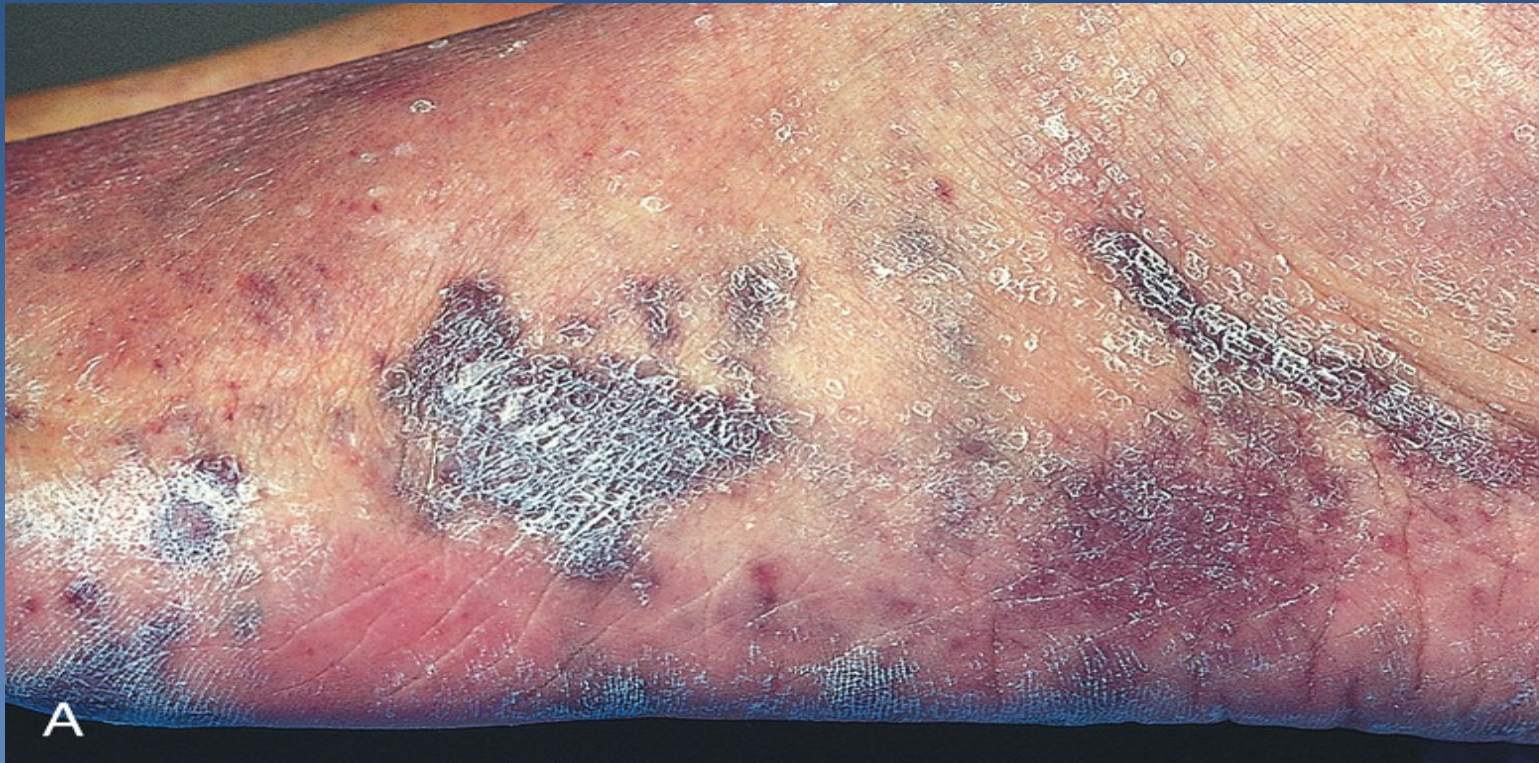

- ✗ HHV-8
- ✗ hyperproliferation of endothelial cells
- ✗ prevention of apoptosis

- ✗ **gross:**
 - ⇒ *red to purple patches*
 - ⇒ *raised plaques*
 - ⇒ *nodules*

- ✗ **micro:**
 - ⇒ *irregular blood spaces*
 - ⇒ *plump atypical endothelial cells*
 - ⇒ *perivascular aggregates of spindle cells*

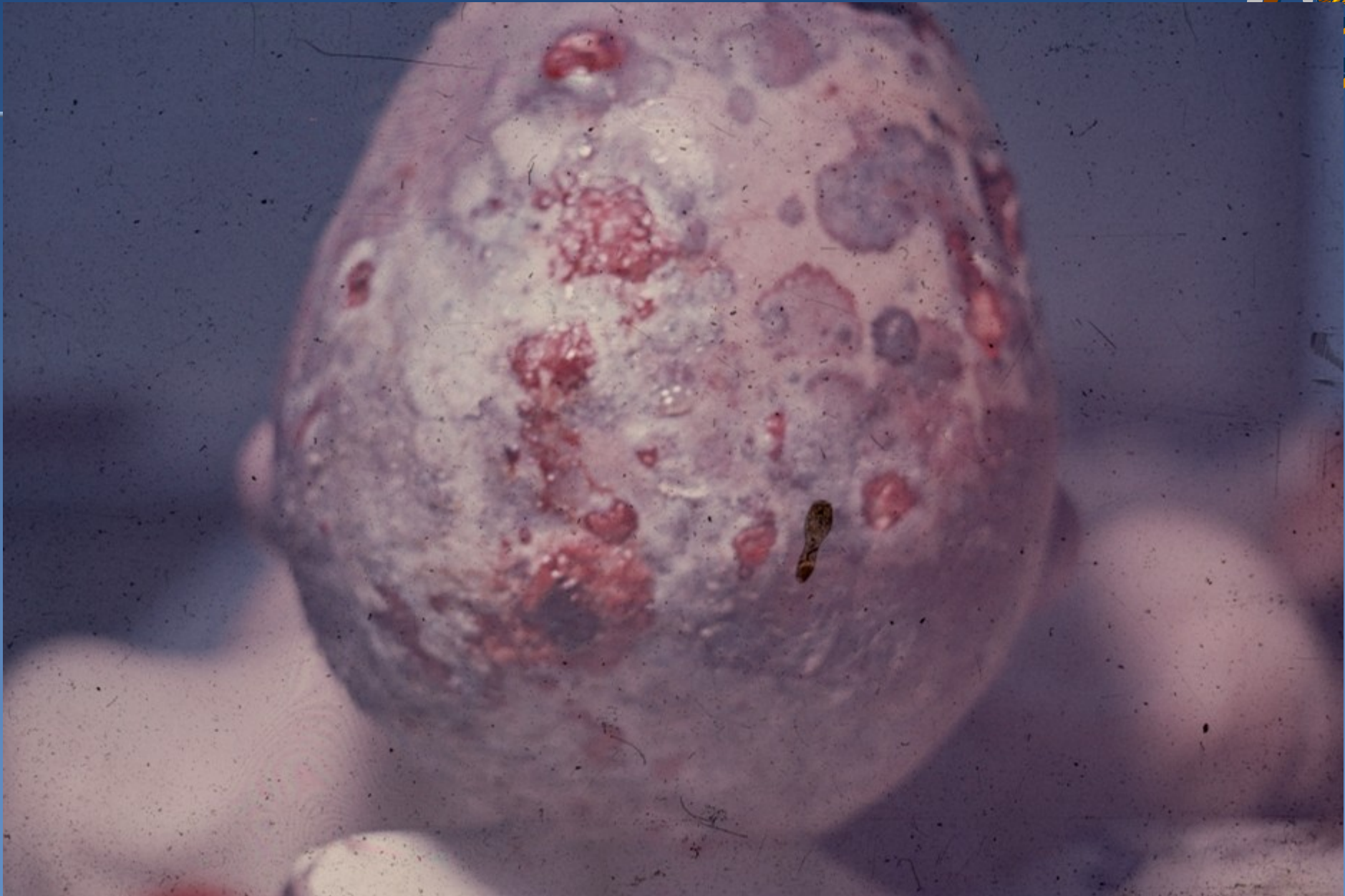

Kaposi sarcoma



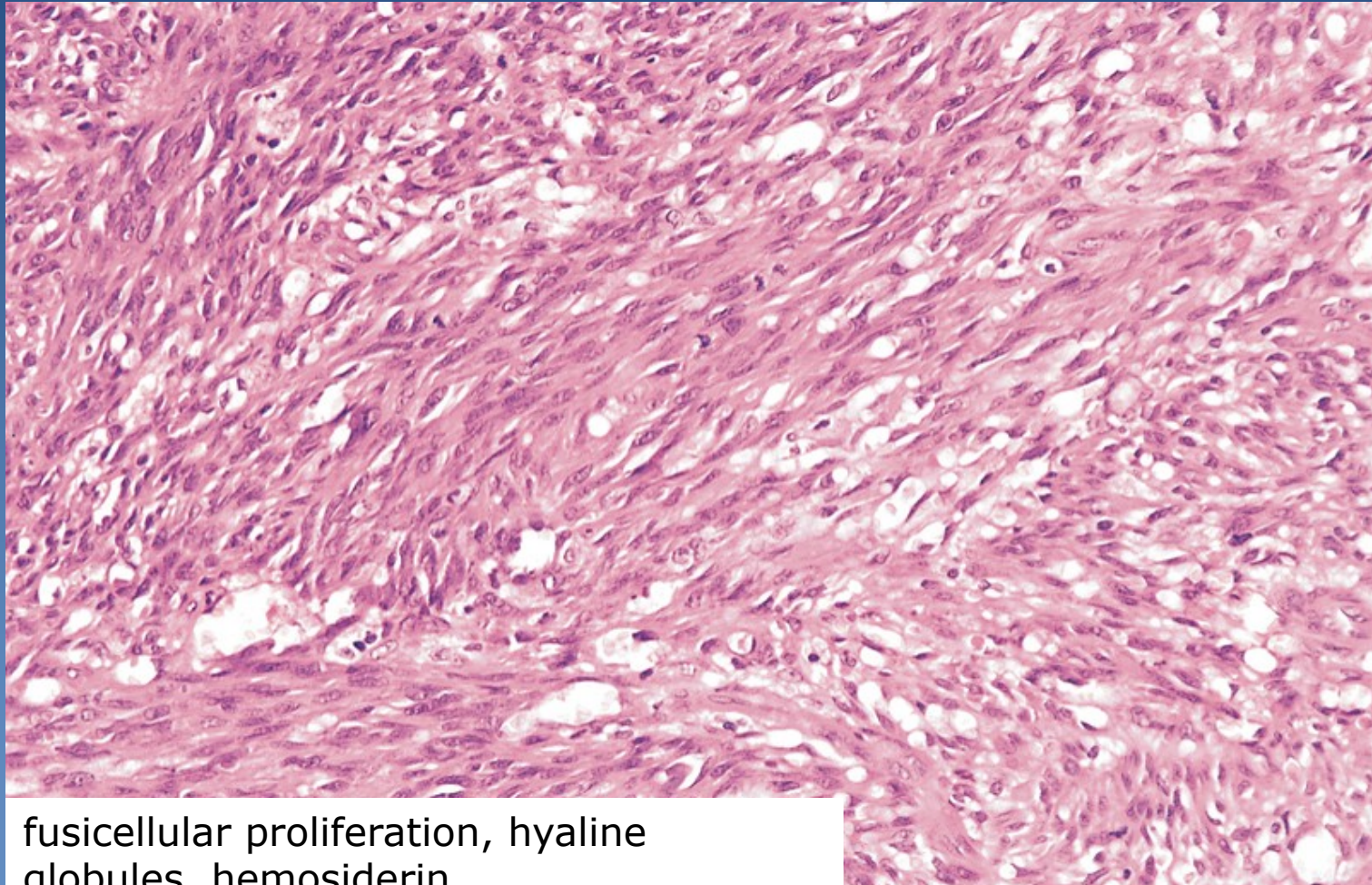
A

Kumar et al: Robbins & Cotran Pathologic Basis of Disease, 8th Edition.
Copyright © 2009 by Saunders, an imprint of Elsevier, Inc. All rights reserved.

Kaposi sarcoma



Kaposi sarcoma



fusicellular proliferation, hyaline globules, hemosiderin

se, 8th Edition.
nc. All rights reserved.

Heart tumors



- ✗ primary tumors rare, mostly **benign myxomas**

- ✗ malignant mesenchymal (sarcomas)
 - ⇒ *leiomyo - , rhabdomyo - , hemangio - , fibrosarcoma*

- ✗ secondary tumors
 - ⇒ *100 x more common than primary*
 - ⇒ *metastases + infiltrates : lung, breast carcinomas, malignant melanoma, malignant lymphomas and leukemias*
 - ⇒ *direct spread (lung ca, mesothelioma, renal ca)*
 - ⇒ *pericarditis carcinomatosa – hemorrhagic effusion*

Benign tumors

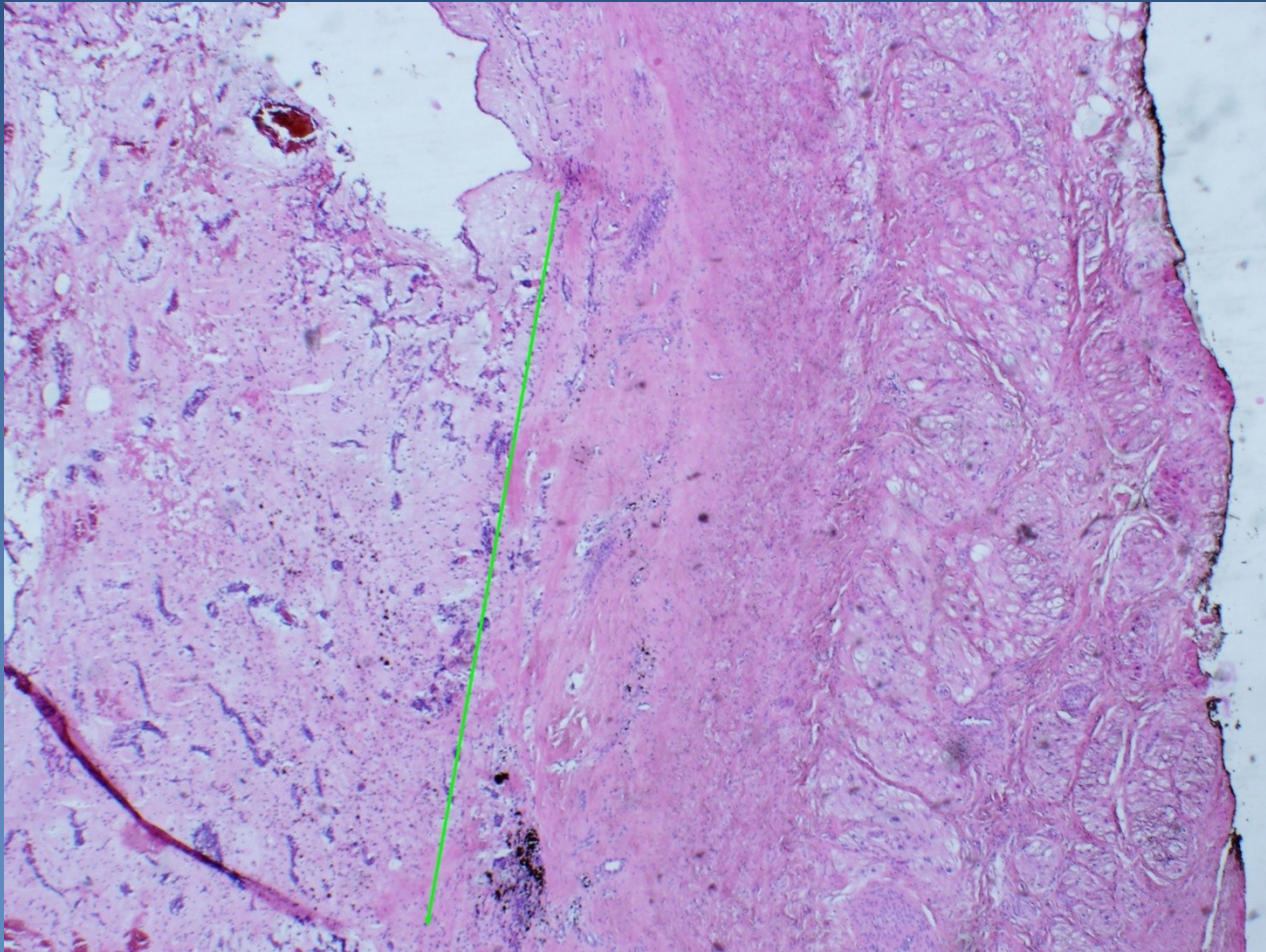


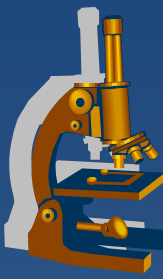
✘ Myxoma

- ⇒ *mostly in the left atrium (fossa ovalis on septum)*
- ⇒ *4 – 6 cm, usually single*
- ⇒ *sessile x pedunculated, papillary x villous, soft – gelatinous, regressive changes (haemorrhage, fibrosis)*
- *micro: polygonal (stellate / globular) cells in myxoid matrix (acid mucopolysaccharides)*

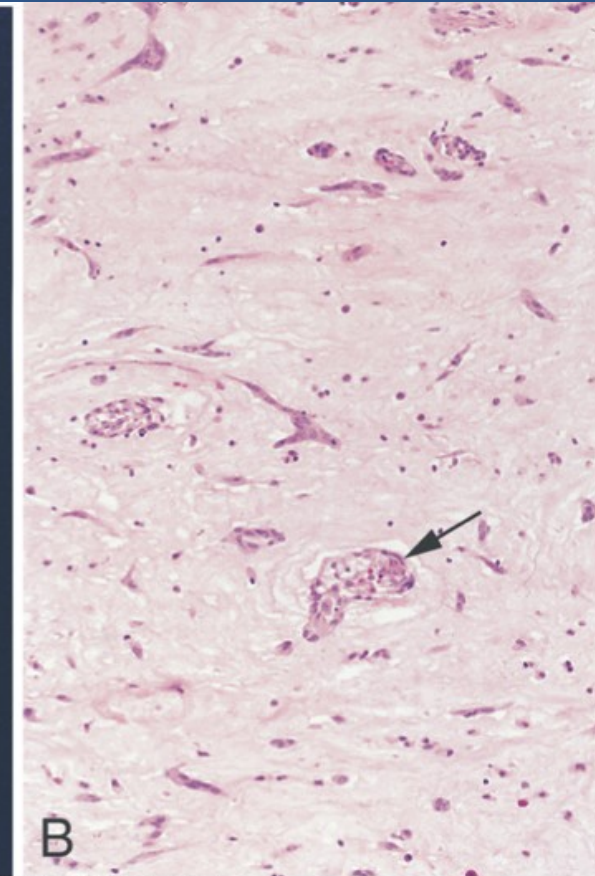
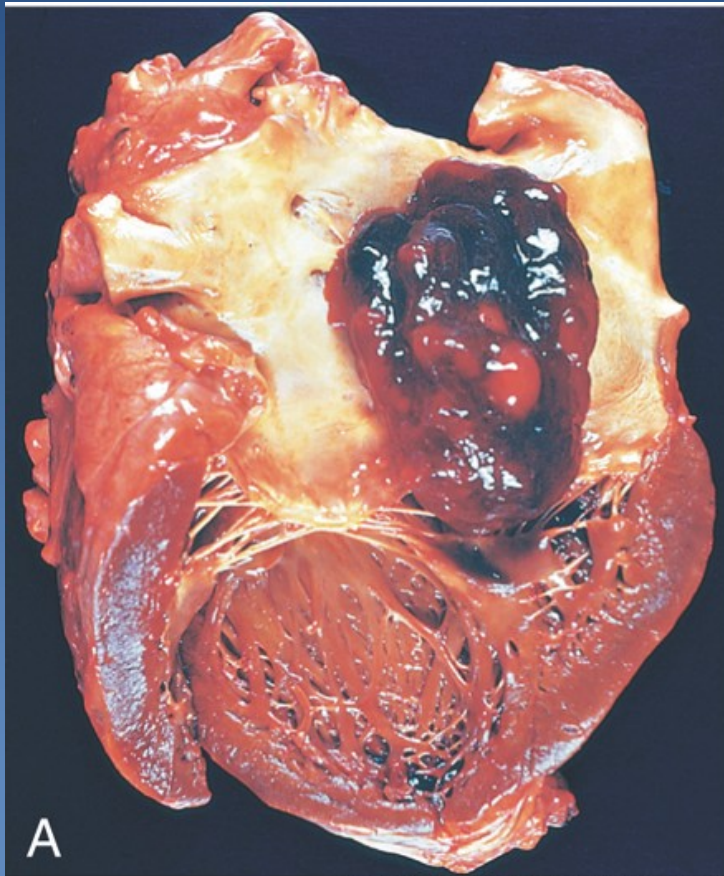
✘ **other: hemangioma, lipoma, rhabdomyoma...**

LV myxoma

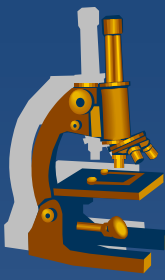




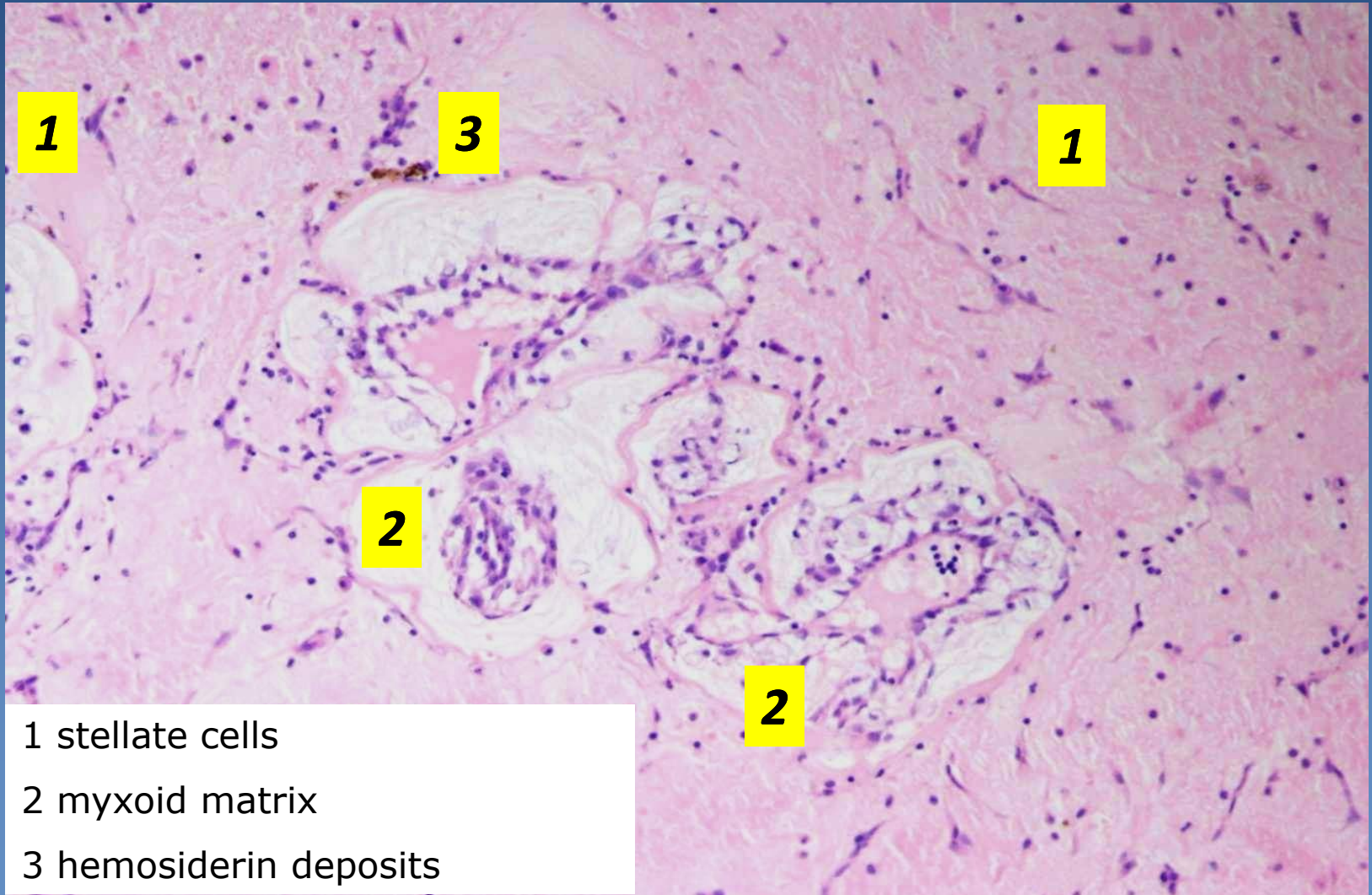
LV myxoma



Kumar et al: Robbins & Cotran Pathologic Basis of Disease, 8th Edition.
Copyright © 2009 by Saunders, an imprint of Elsevier, Inc. All rights reserved.



Myxoma (100x)



1

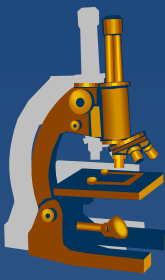
3

1

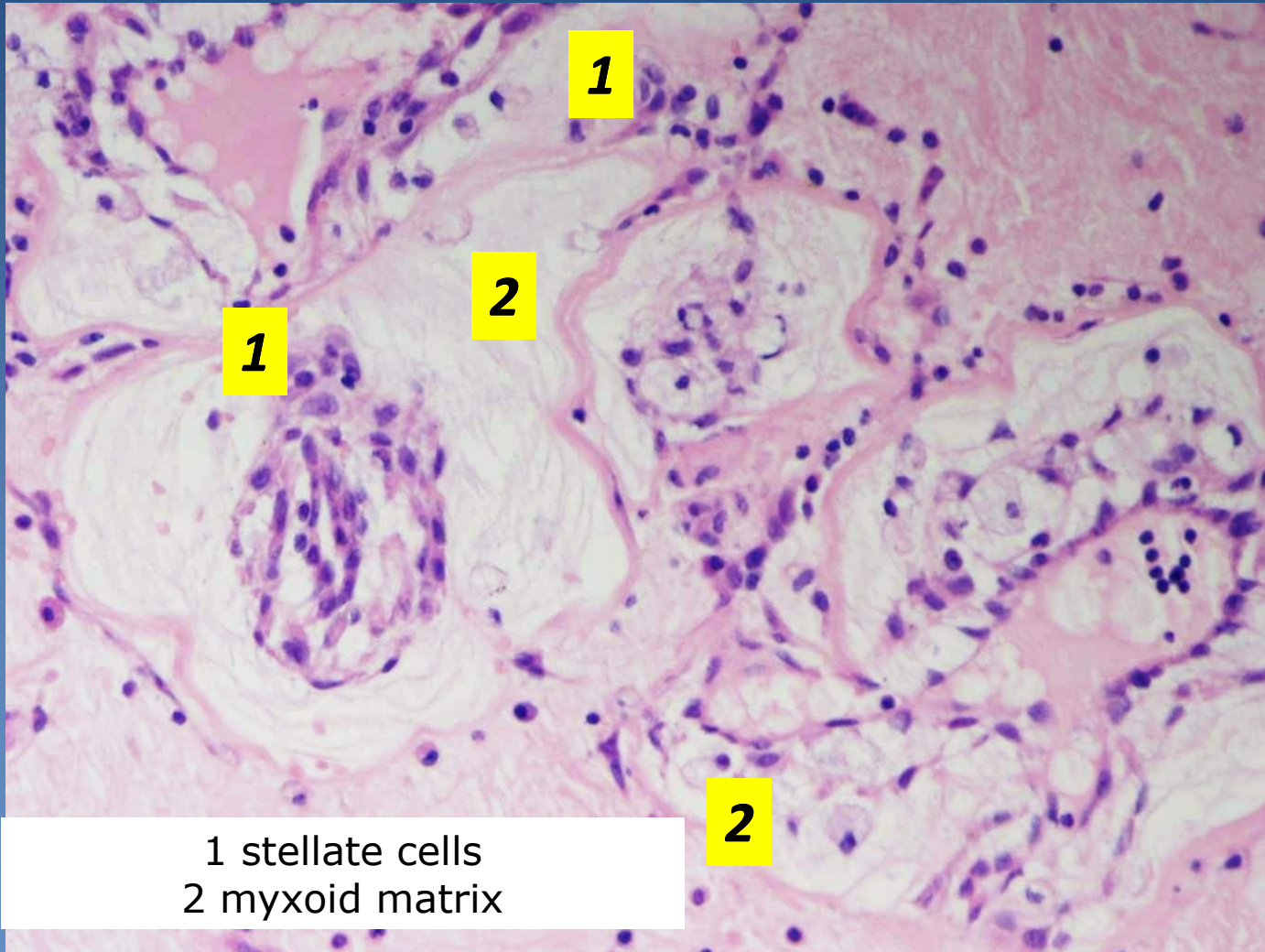
2

2

- 1 stellate cells
- 2 myxoid matrix
- 3 hemosiderin deposits

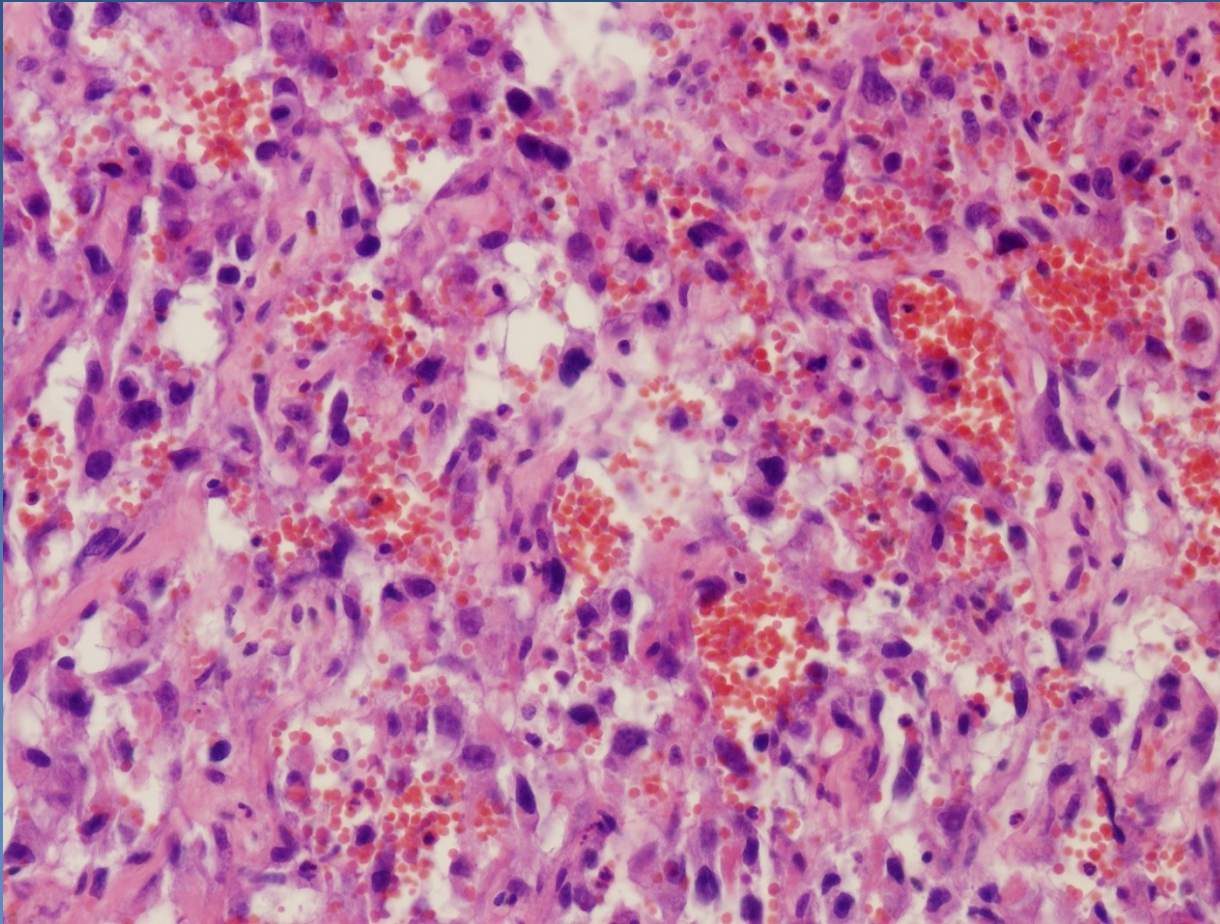


Myxoma (400x)



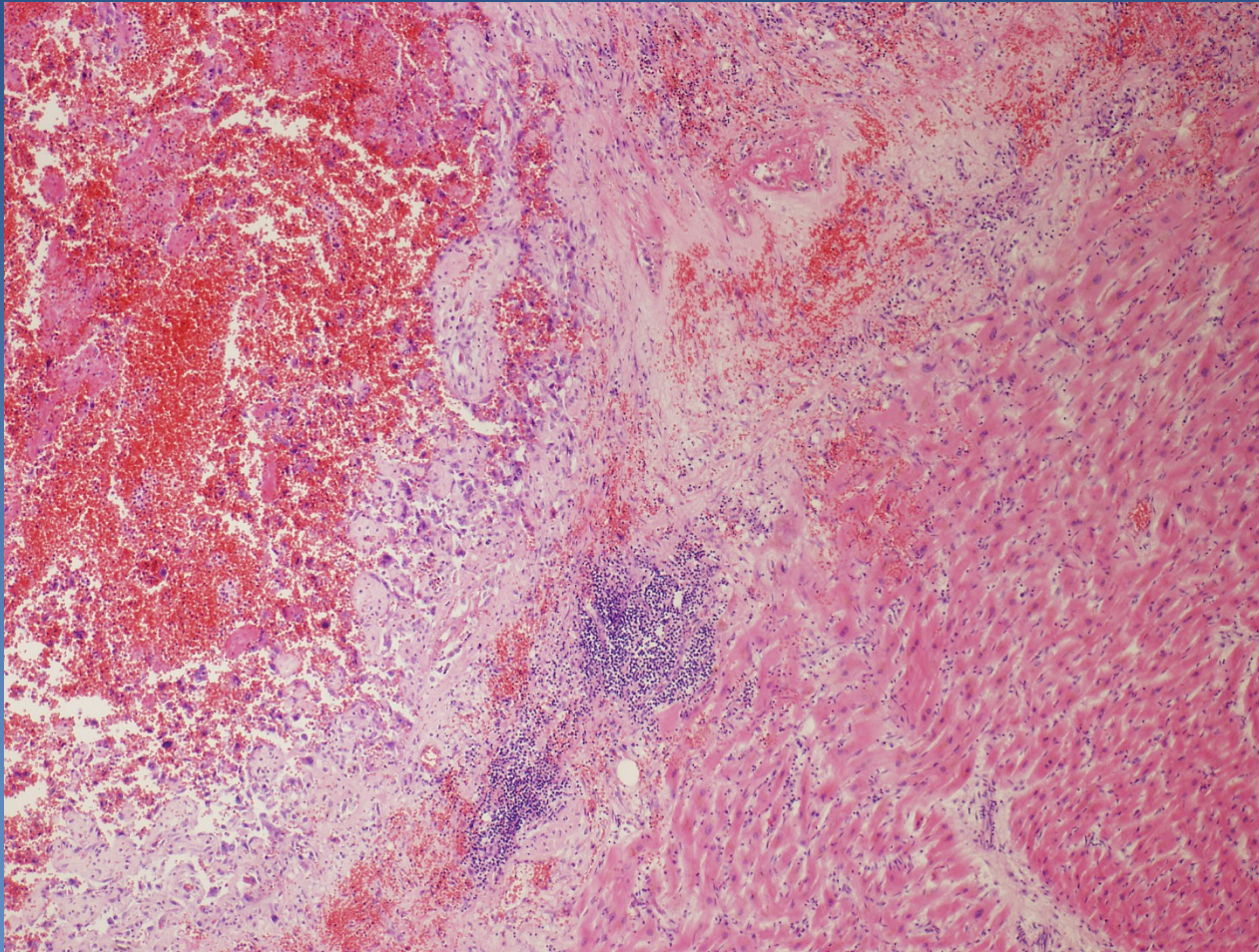
1 stellate cells
2 myxoid matrix

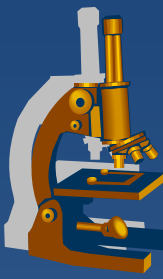
Pericardial angiosarcoma



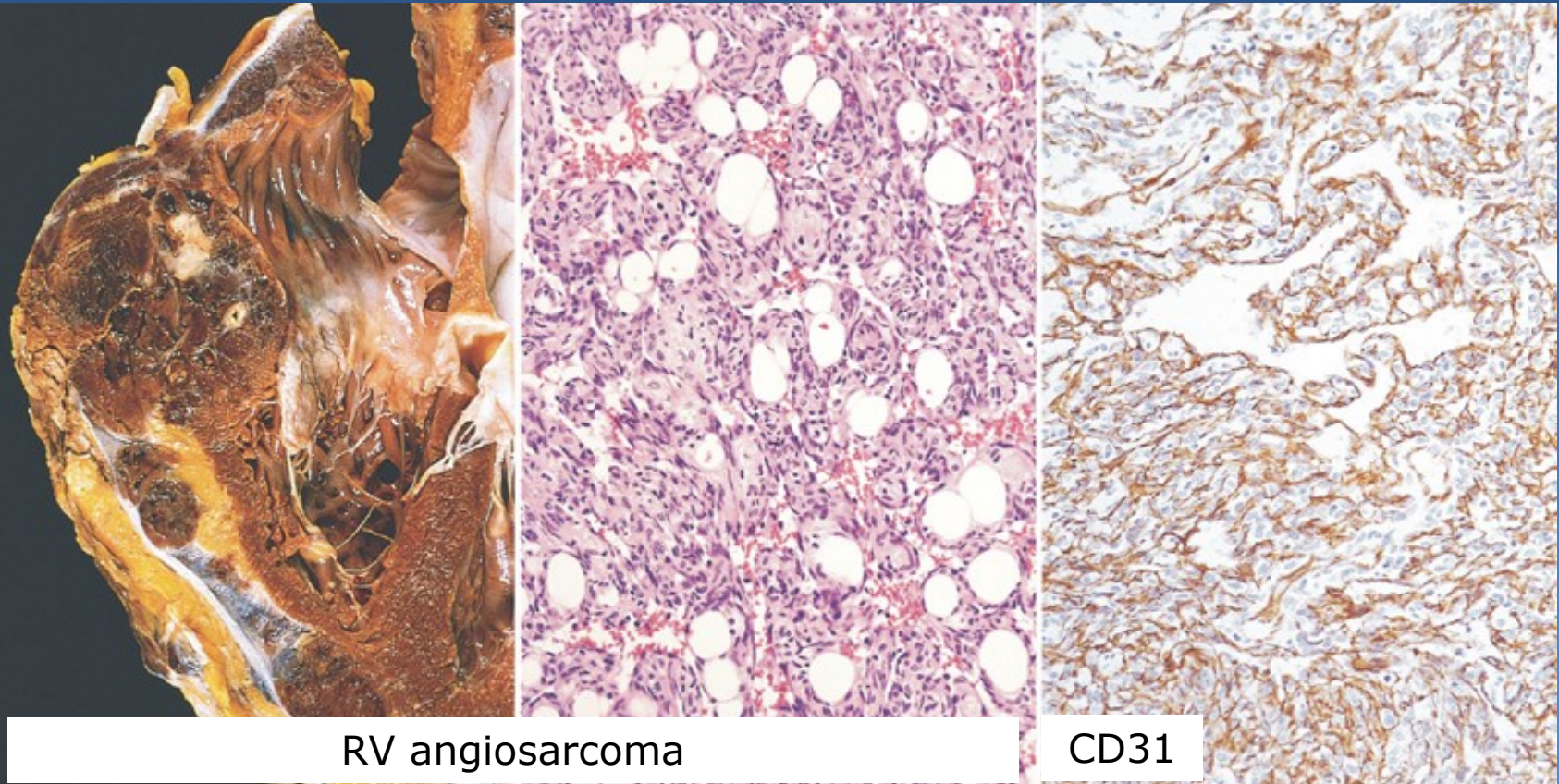
biopsy

Pericardial angiosarcoma





Angiosarcoma

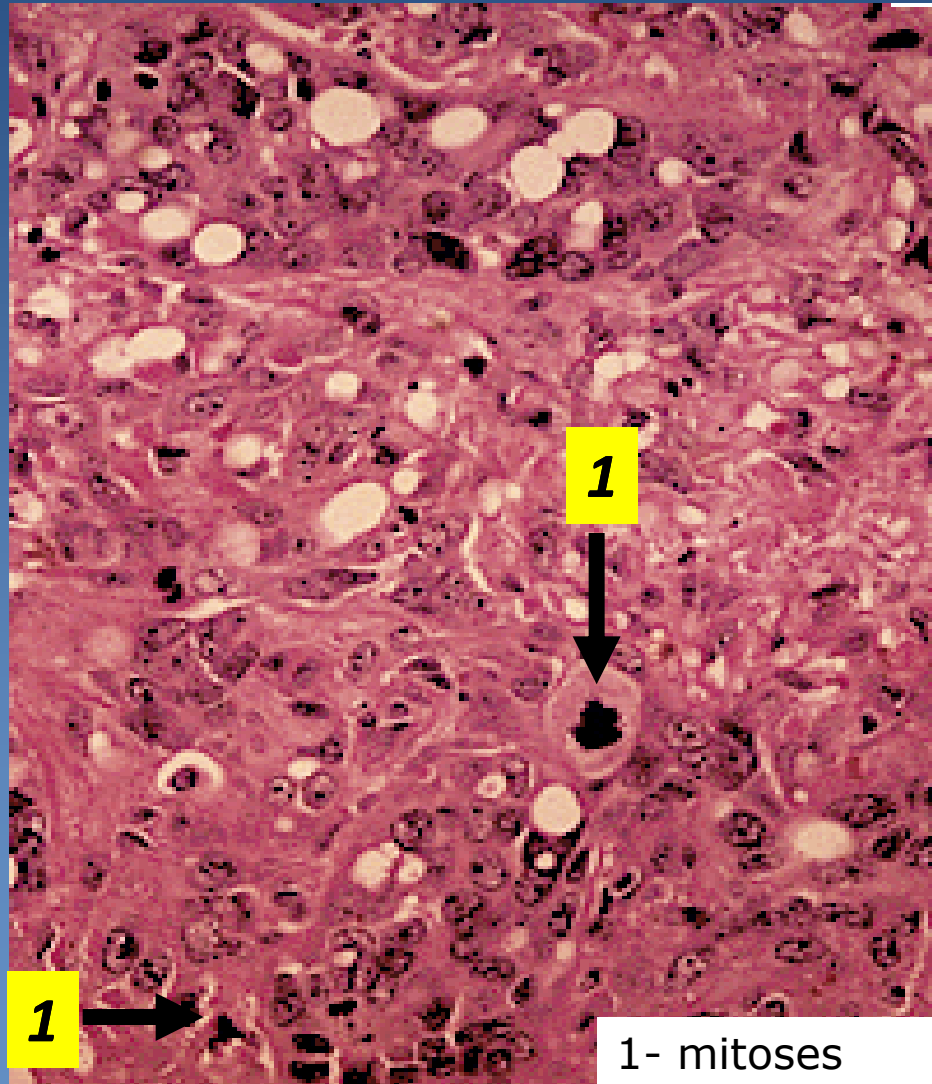


RV angiosarcoma

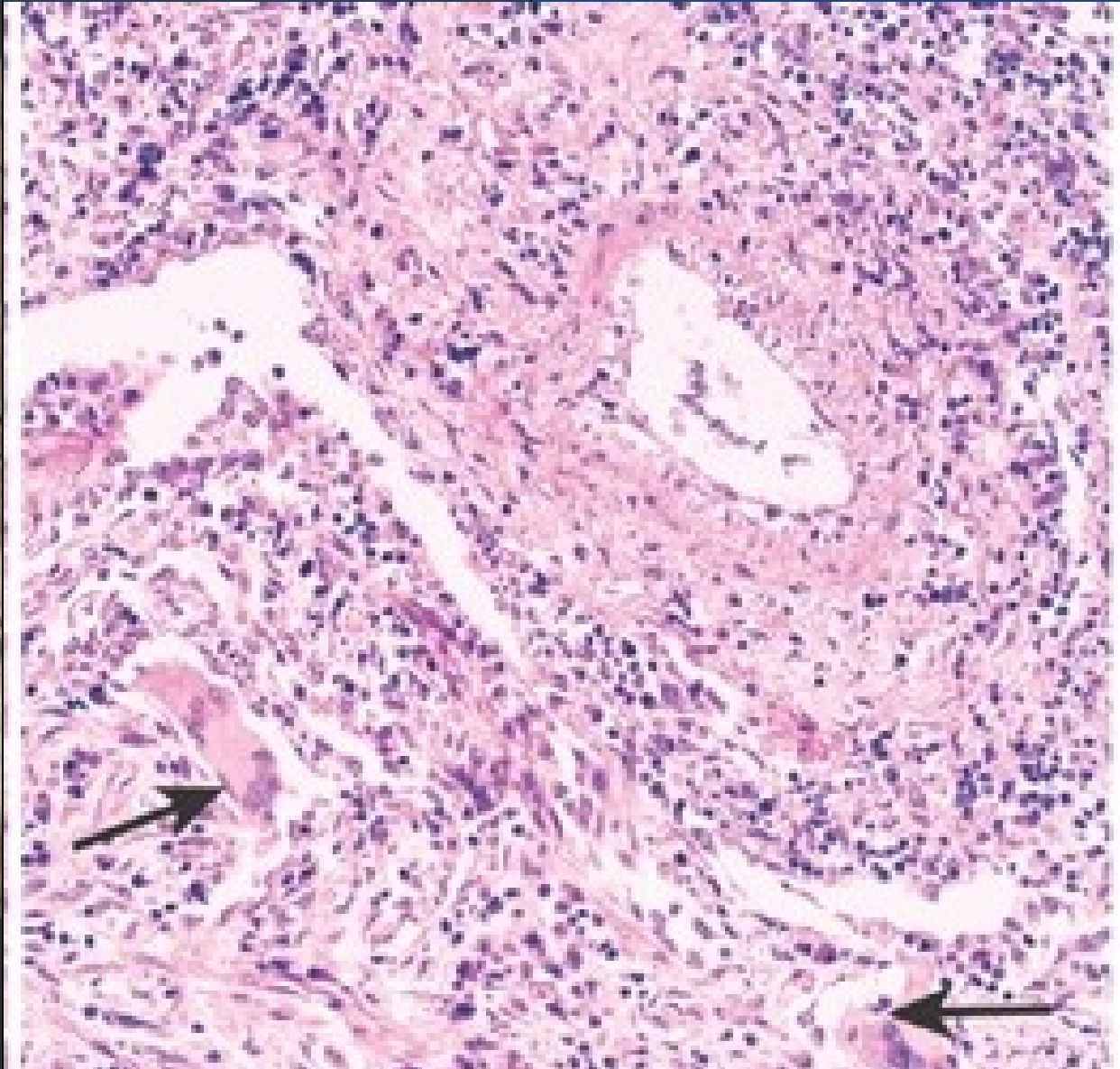
CD31

Kumar et al: Robbins & Cotran Pathologic Basis of Disease, 8th Edition.
Copyright © 2009 by Saunders, an imprint of Elsevier, Inc. All rights reserved.

Angiosarcoma



1- mitoses



Small vessel vasculitis with giant-cell granulomatous reaction

