

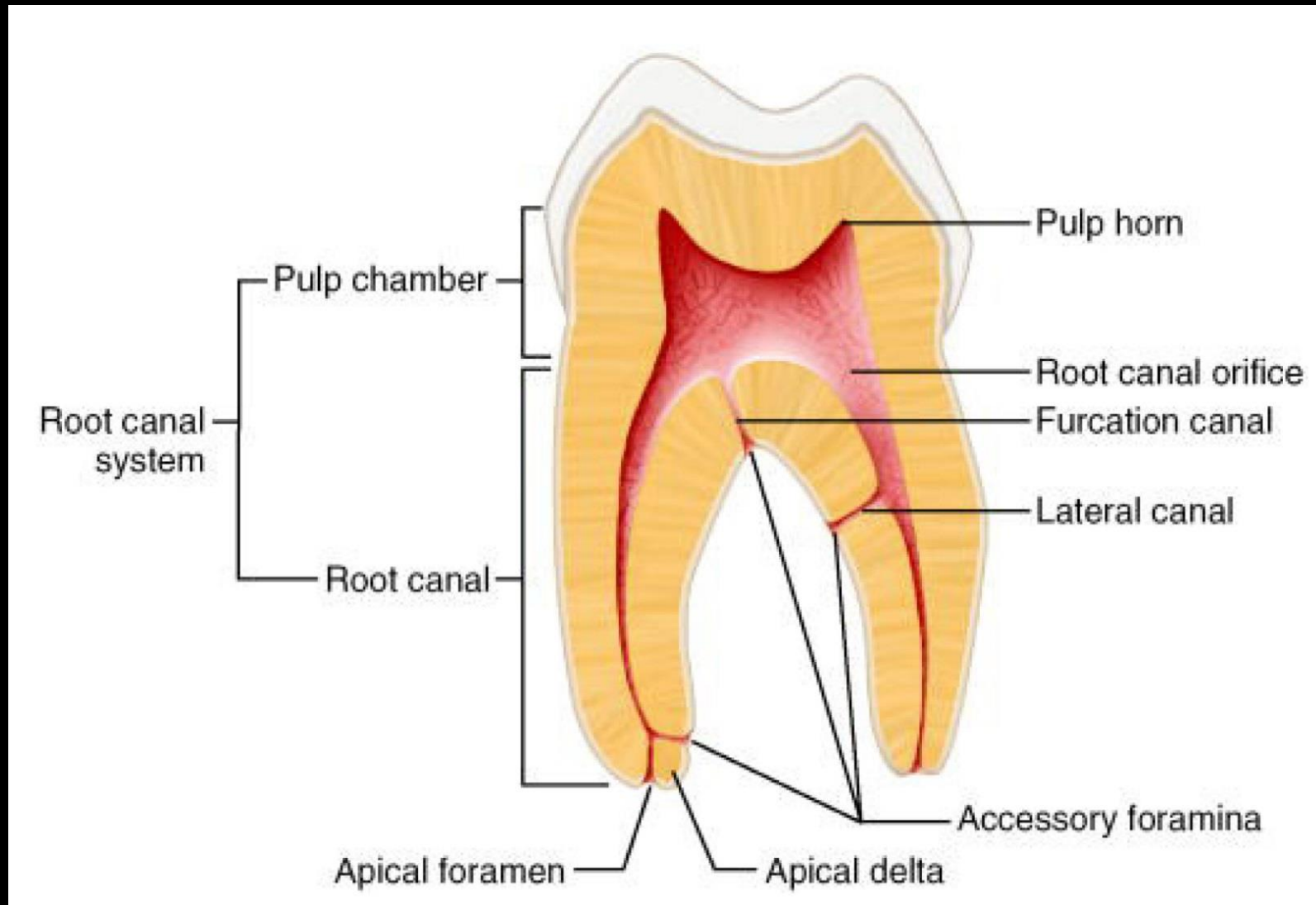
Tooth morphology and pulpal access cavities

Restorative dentistry

Endodontics I.

8.3.2021

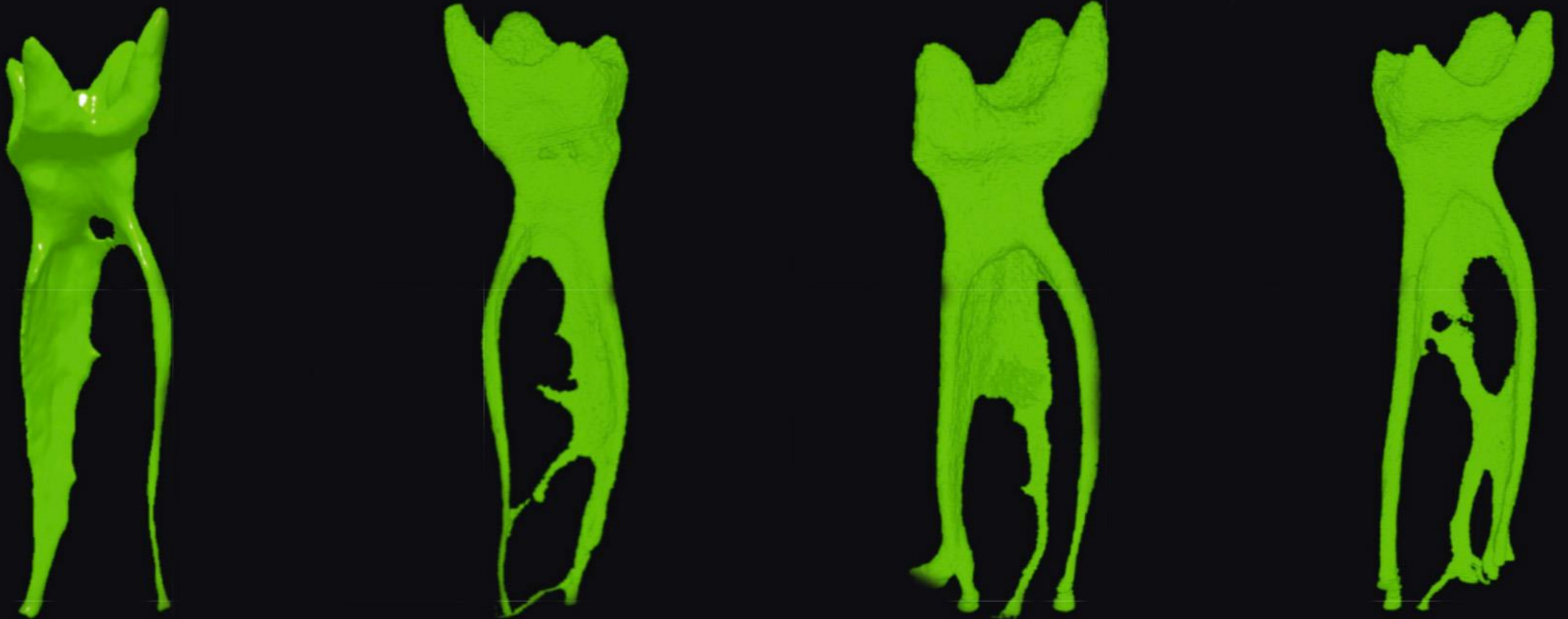
Basic terminology



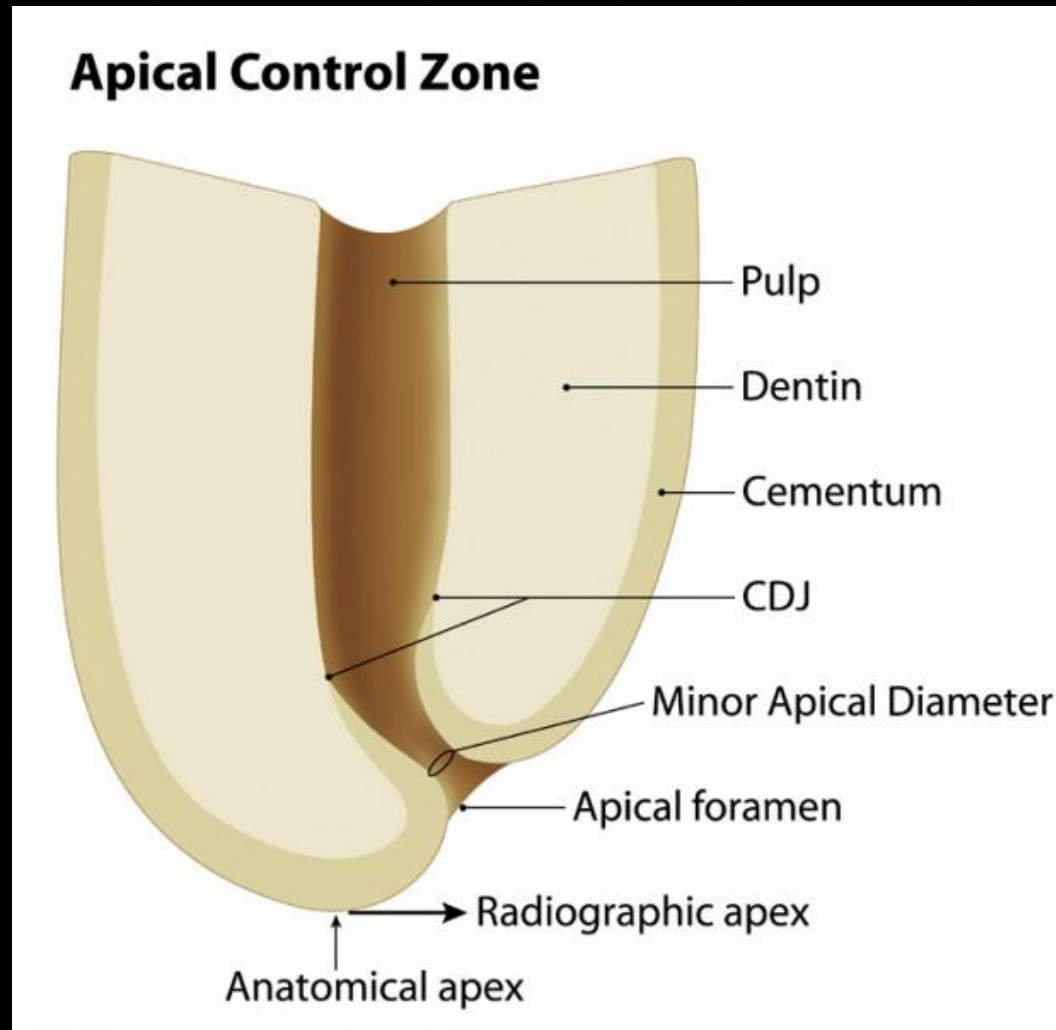
Basic terminology

- Periodontium
- Dentin tubules
- Endodont – morphological and functional connection of pulp and dentin

Root canal doesn't run in straight line, usually its mesially curved. It can split in branches, not rounded diameter.

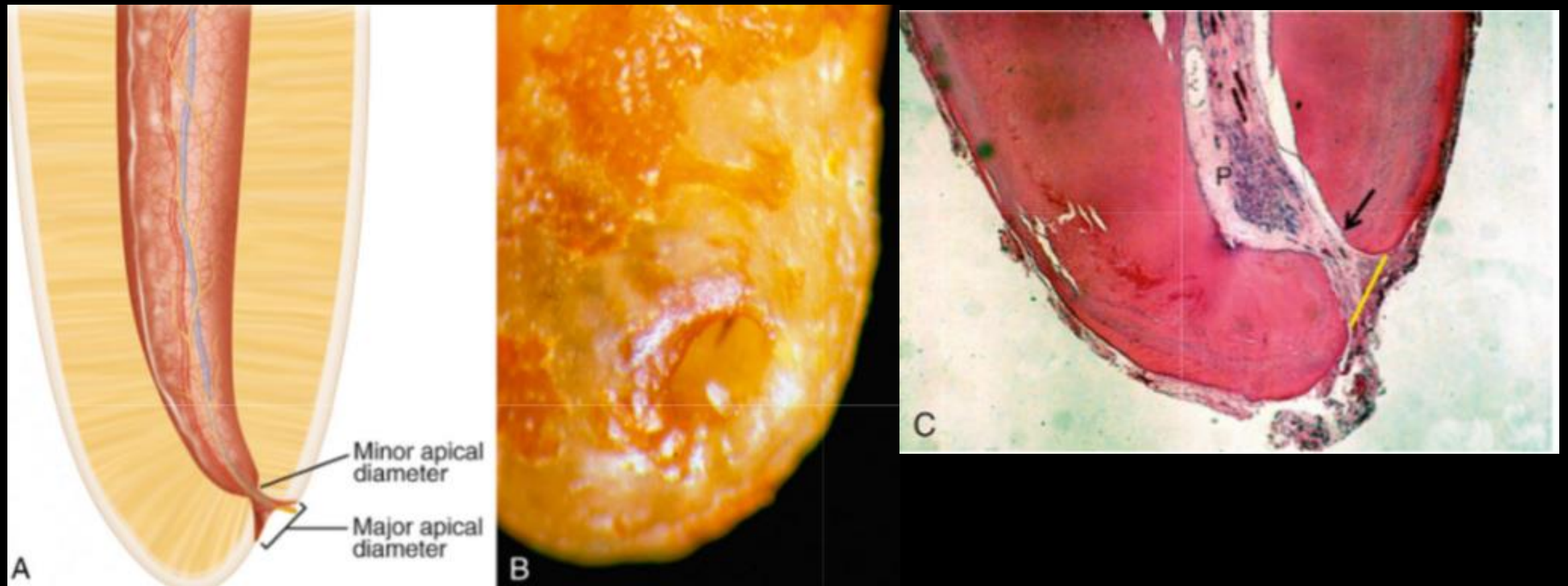


Morphology of the root apex



- <http://theendoacademy.com/wp-content/uploads/2013/04/apex-LargeType-001-620x604.jpg>

Morphology of the root apex



Preparation of access cavity

- Opening of pulp chamber and removing its roof -> creating access cavity.

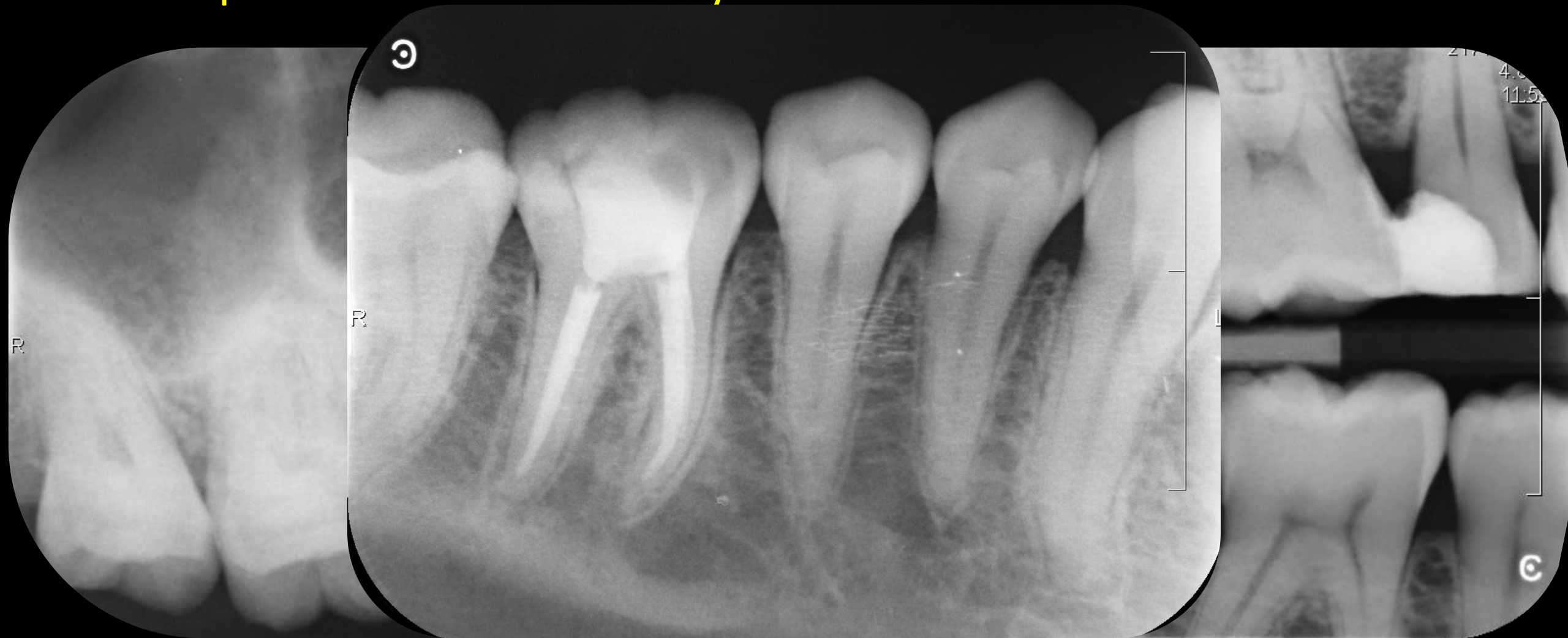Access cavity preparation

- Removing of caries.
- Preserving remaining hard dental tissues.
- Remove roof of pulp chamber.
- Removing of all content from pulp chamber.
- Localization of entrances to root canal system.
- Straight-line access to root canal.

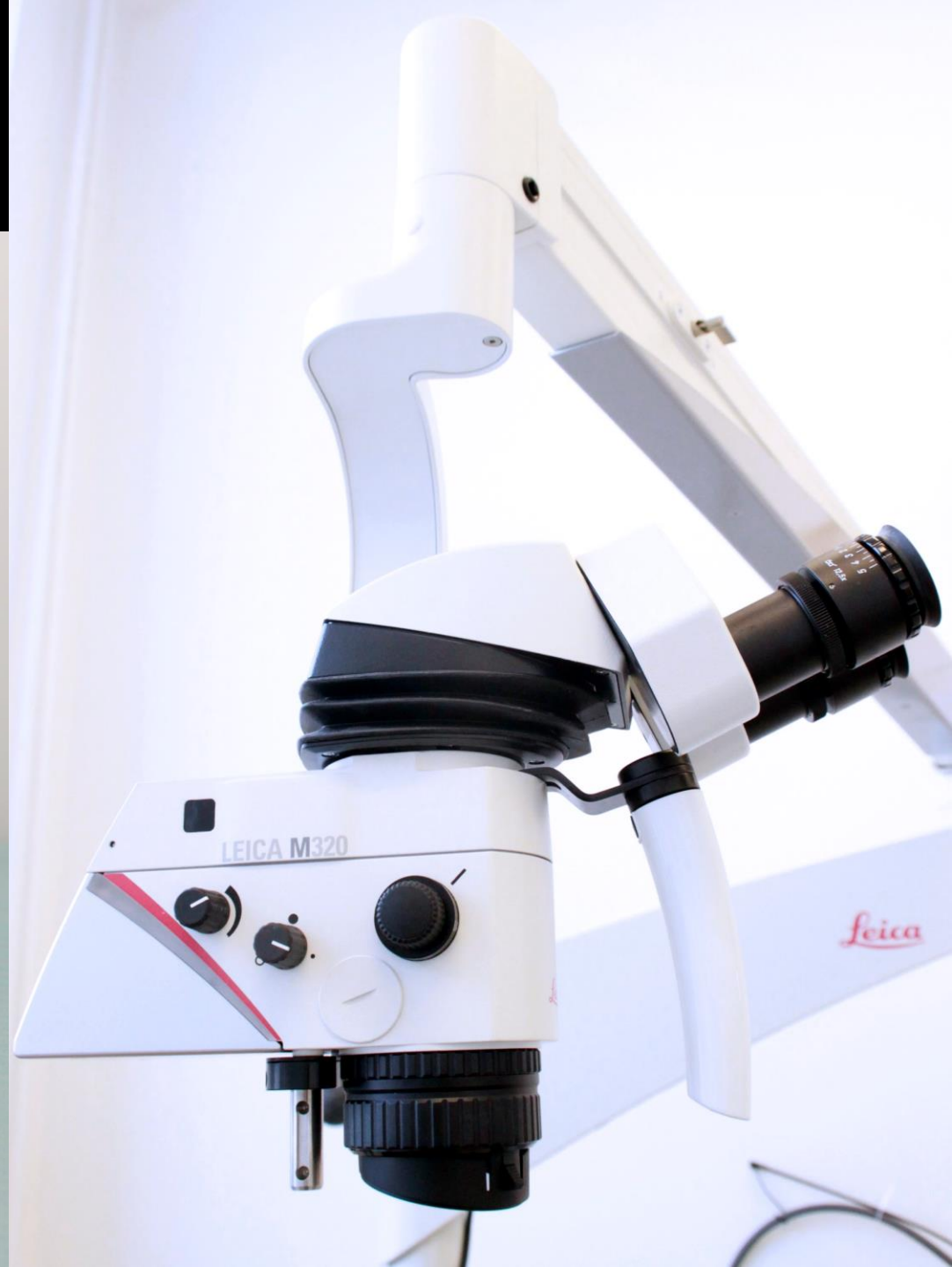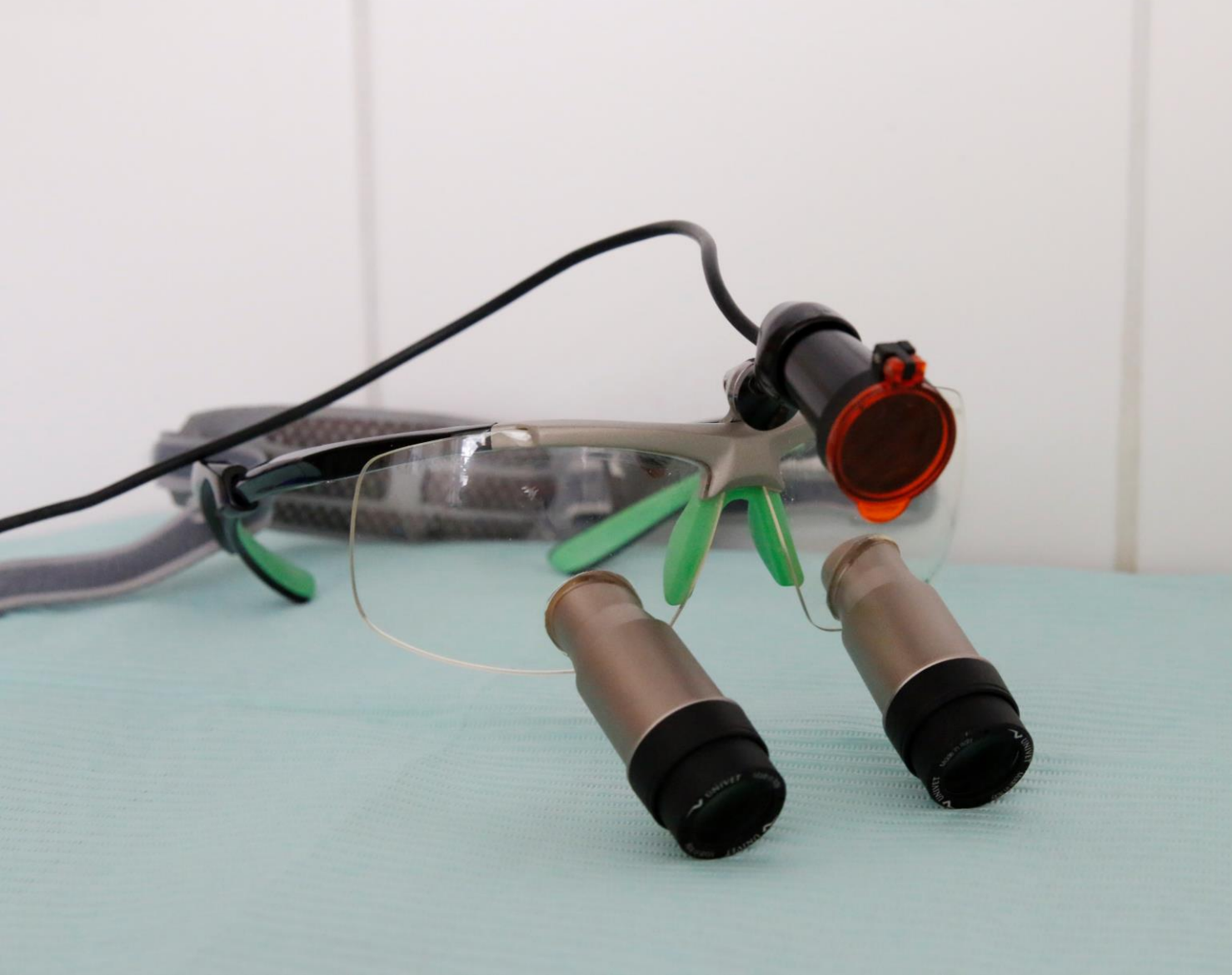Access opening – guidelines

- X-ray intraoral
- Illumination and magnification
- Micromotor
- Burs
- Endo probe
- Ultrasound tips

Proper intraoral X-ray



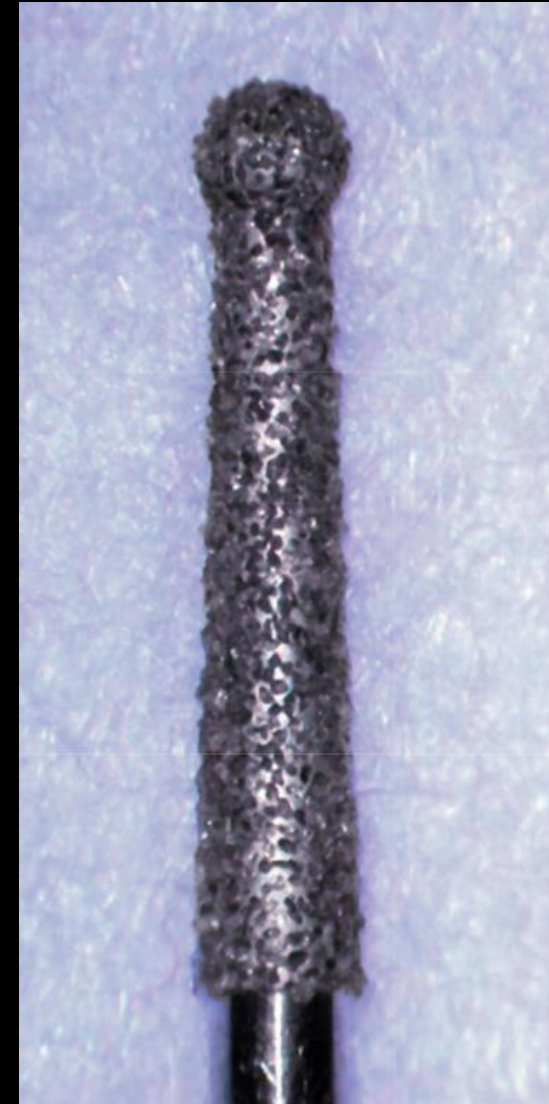
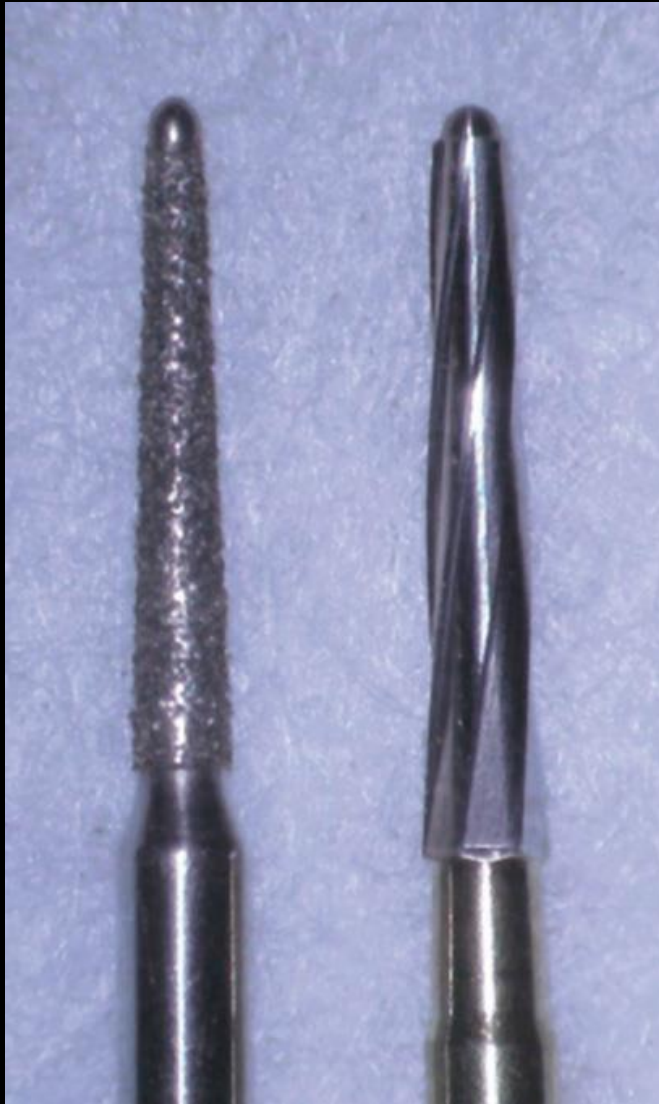Illumination and magnification



Preparation of access cavity

- Mikromotor max. 40000 RPM.
- Sharp and sterile burs.
- Round diamond bur, dia trepan, round bur.
- Batt bur – safe ended burs – non-active tip.
 - perfect for removing roof of pulp chamber

Batt bur and dia trepan



Localization of root canal orifices

- Endodontic probe
- Microopener
- Ultrasound tips



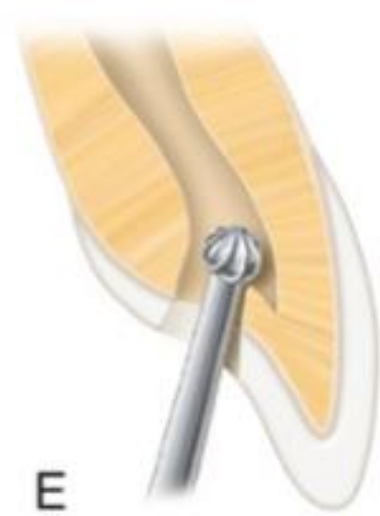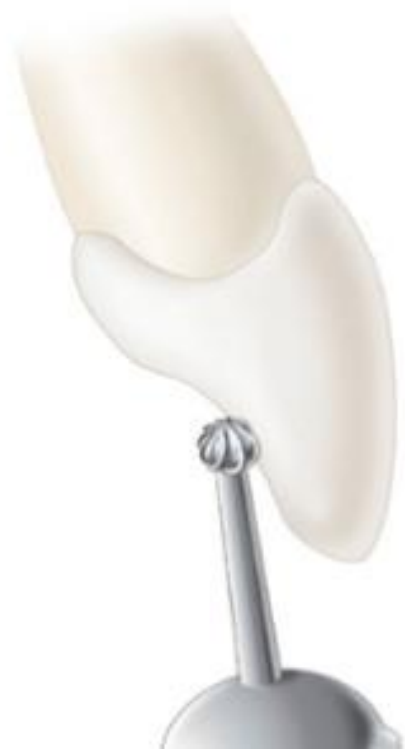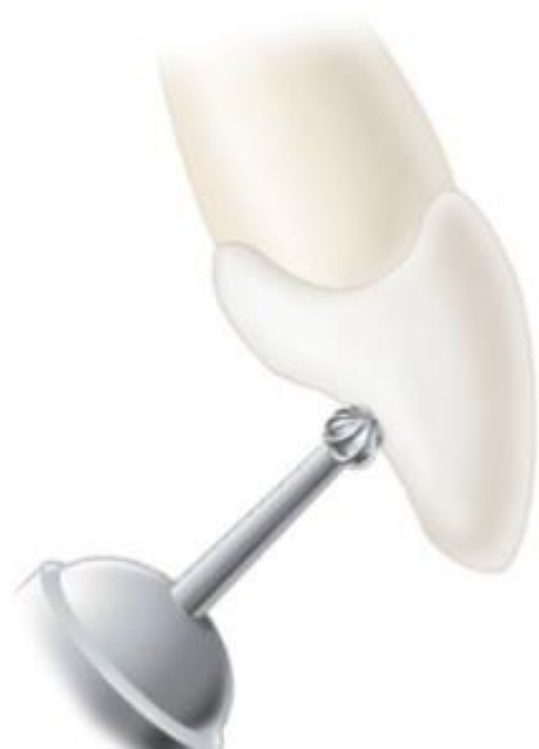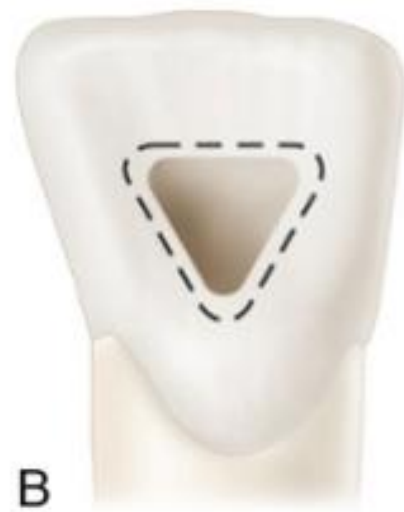Ultrasound preparation

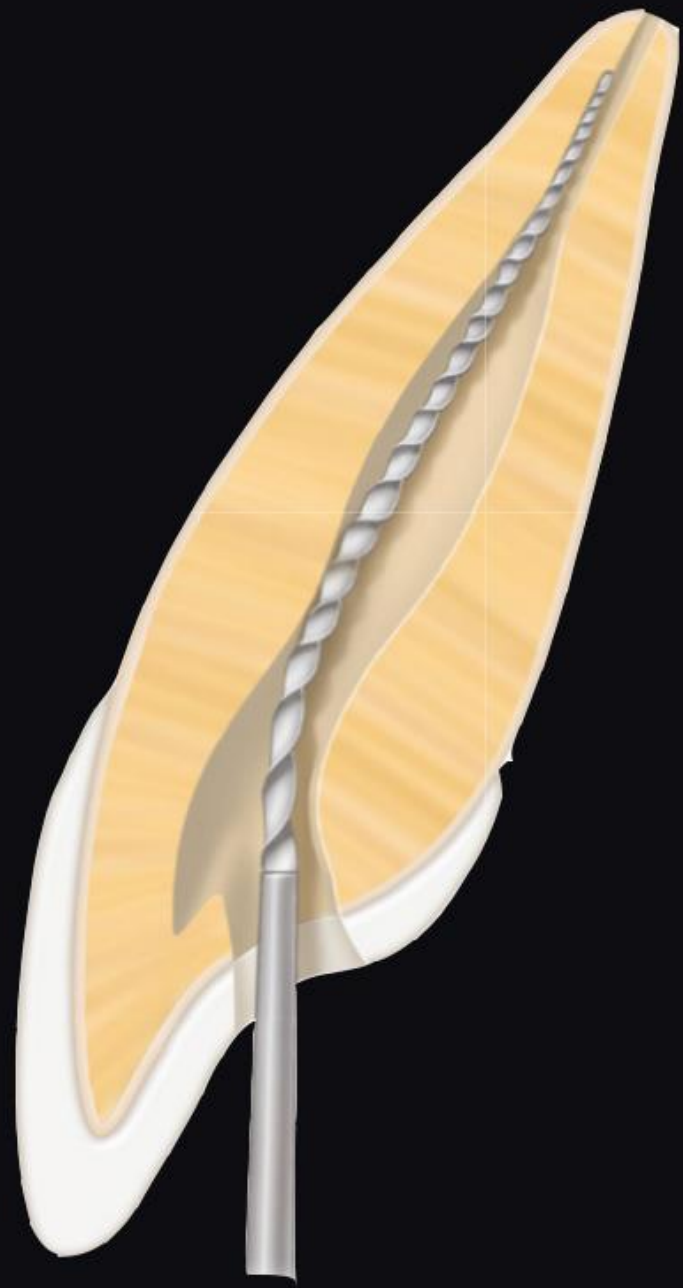- Precise preparation under control of sight.
- Ideal for removal of pulp stones, calcifications, smoothing walls.



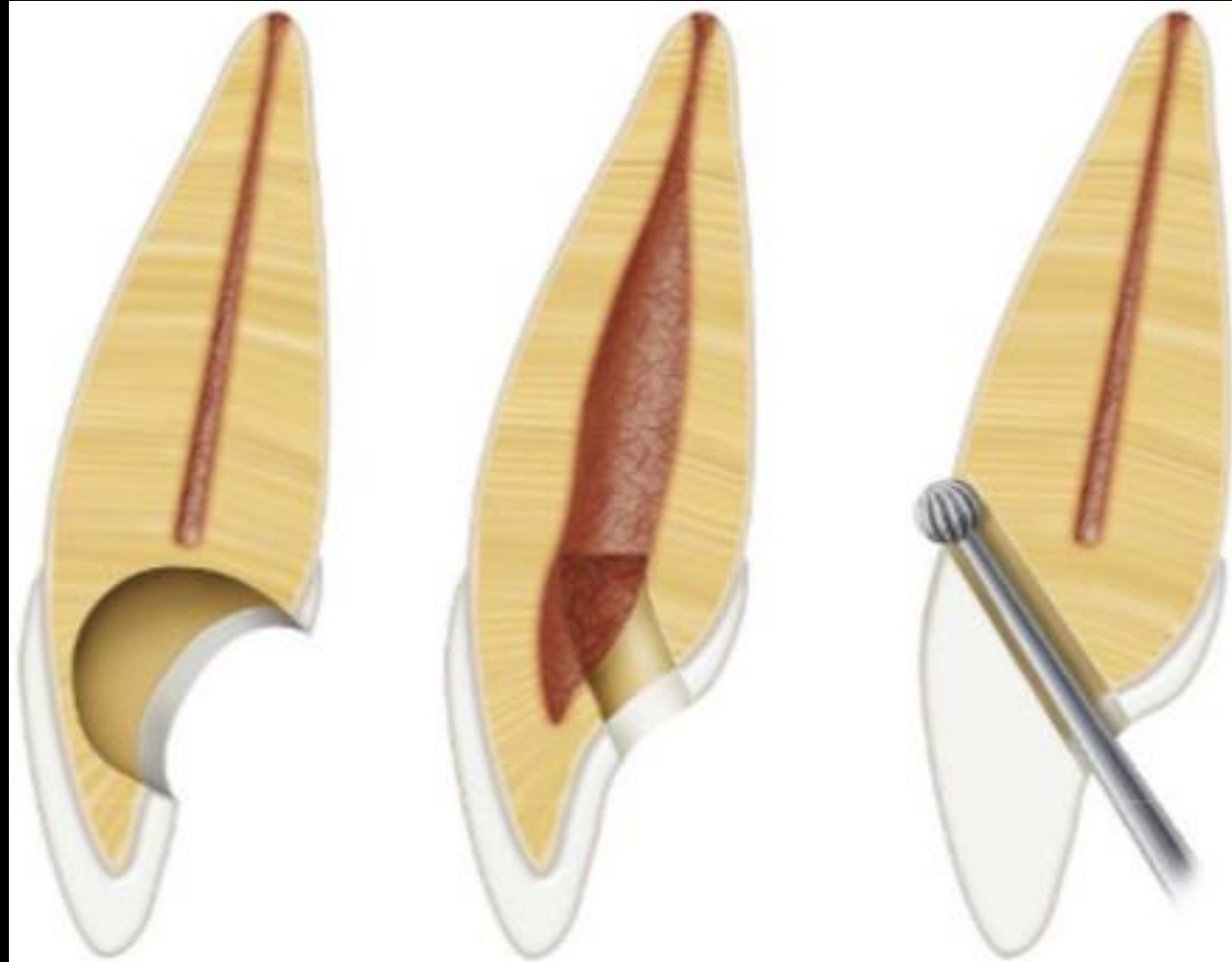Opening access - frontal teeth

- In the middle of the palatal surface we will start preparation of opening access, size up to $\frac{1}{2}$ of predicted size.
- In ENAMEL we use diamond burs, angle 90° to the surface.
- In DENTIN we use standart round bur, paralell with long axis of the tooth.
- Penetration into pulp chambre – probe.
- Extension of opening access to incizal edge.



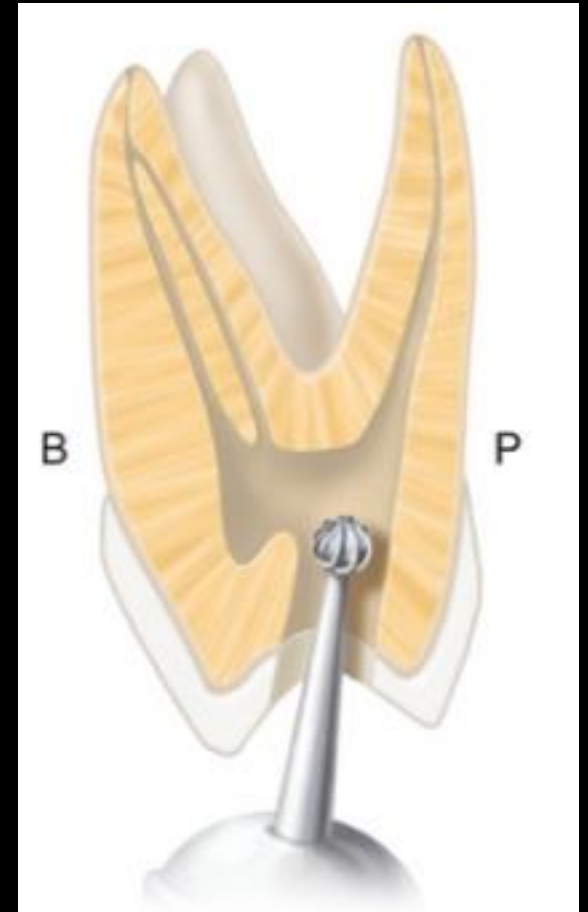


Failures during access cavity preparation

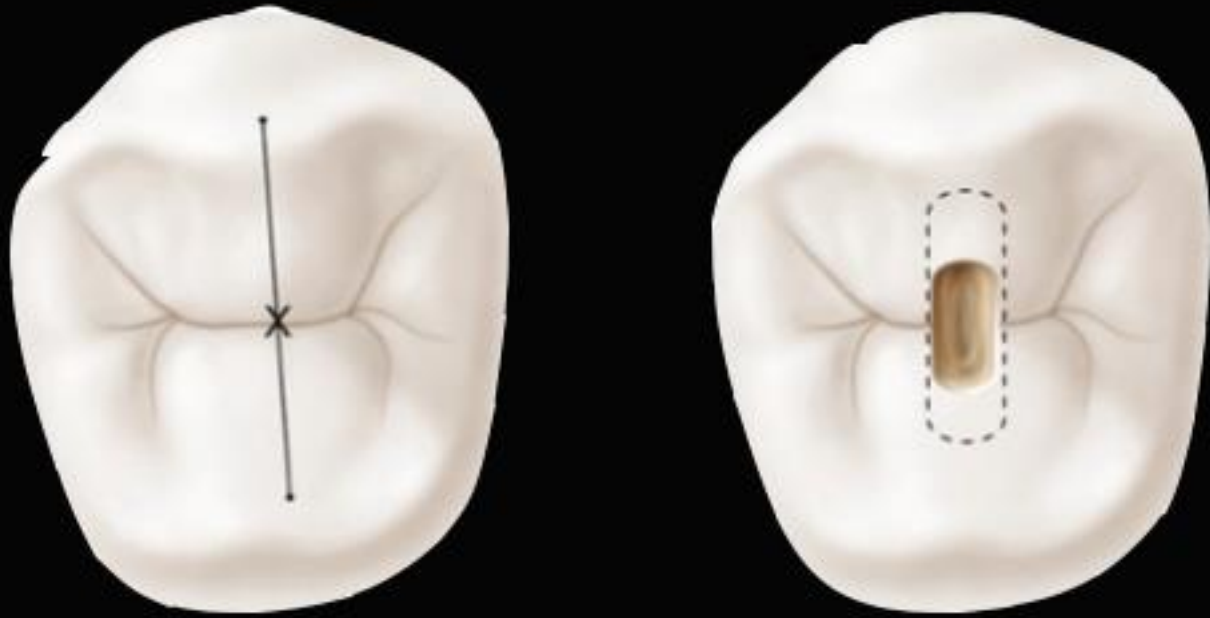

Opening access - distal teeth

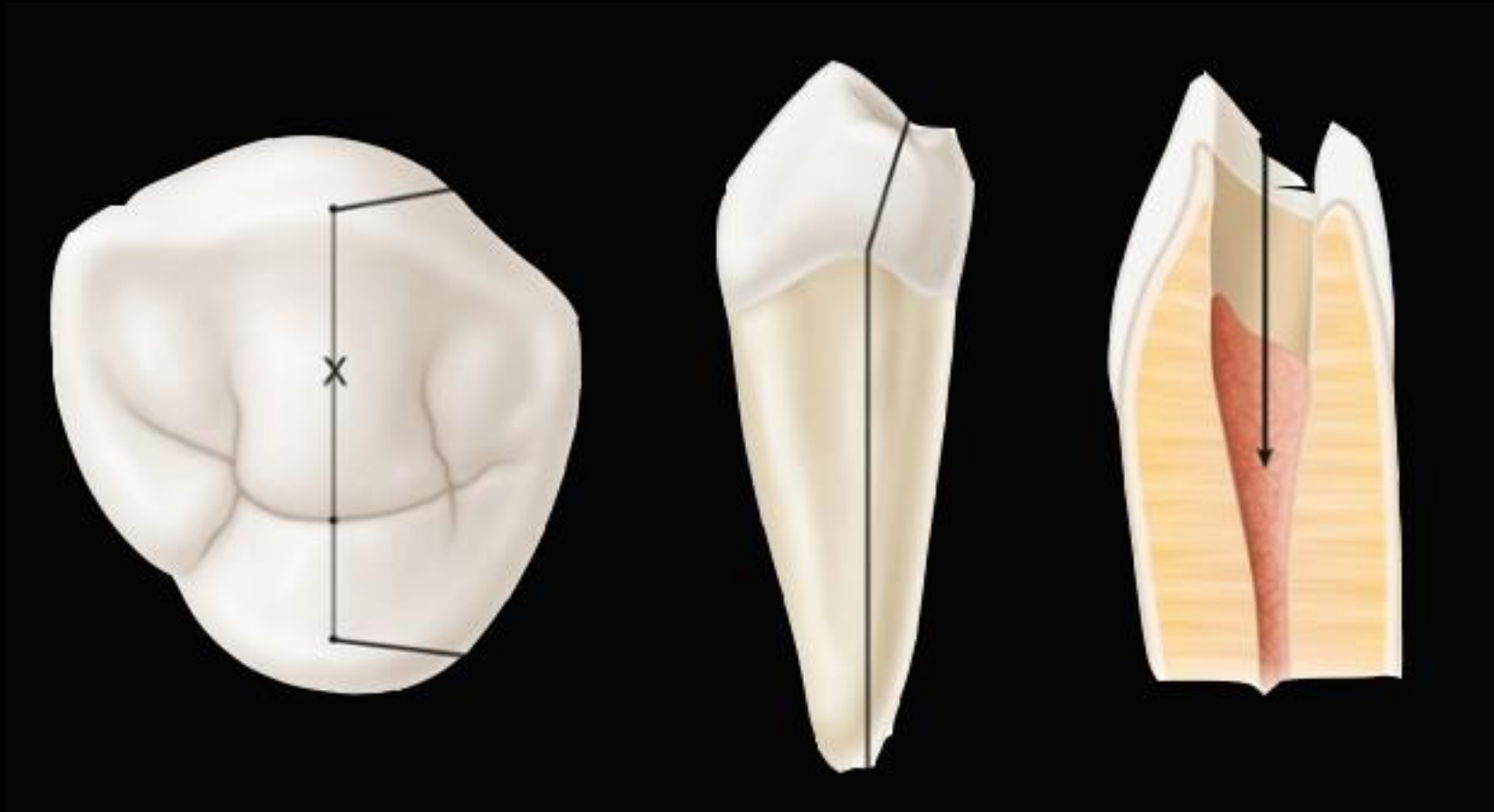- In ENAMEL we use diamond burs, angle 90° to the surface.
- In DENTIN we use standart round bur, rotations max. 40 000 per minute. Perpendicular to oclusal surface.
- Entrance to pulp chambre can be verified by using probe.



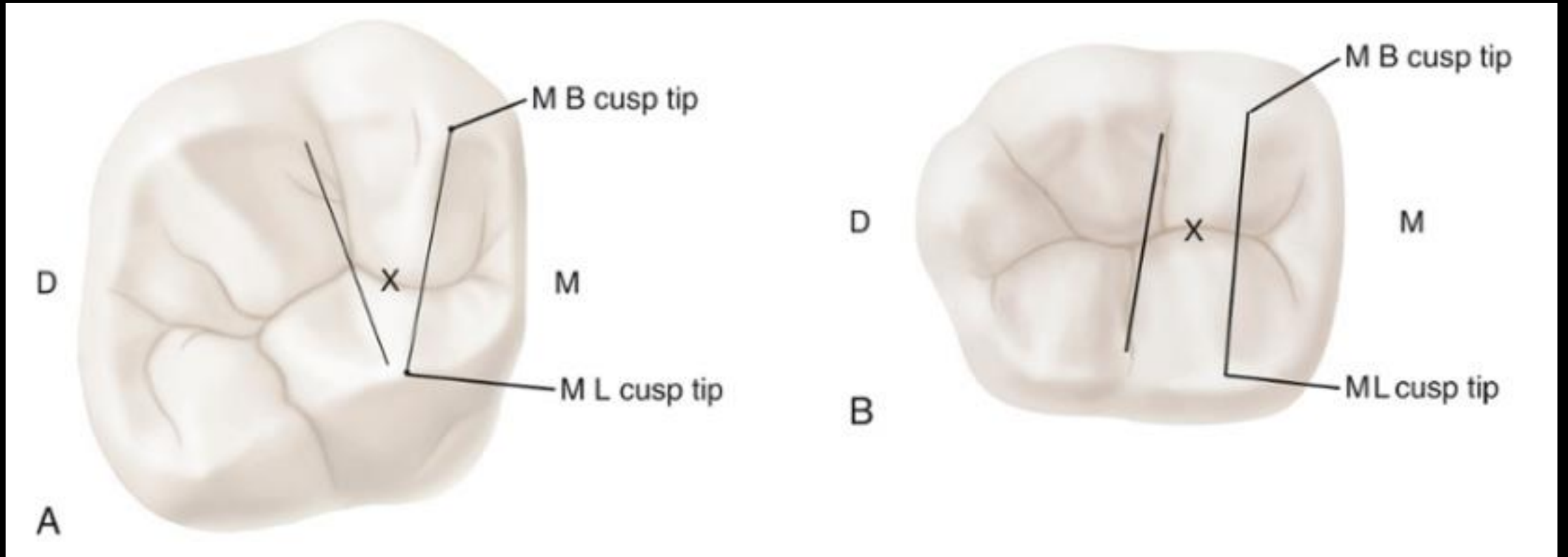
Opening access is localized on line between vestibular and oral cusp.



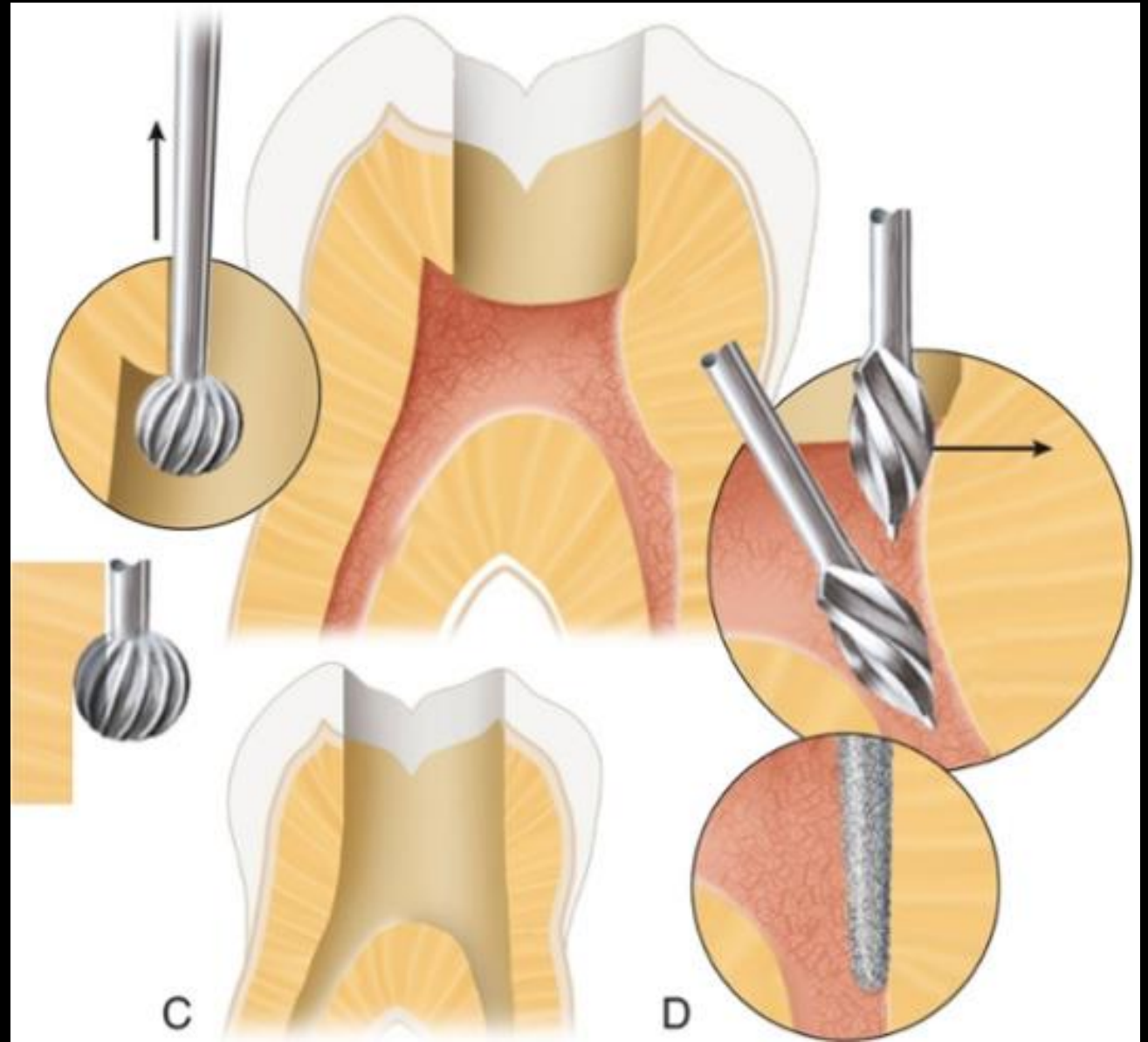
For lower premolars the opening access must respect lingual inclination of crown.



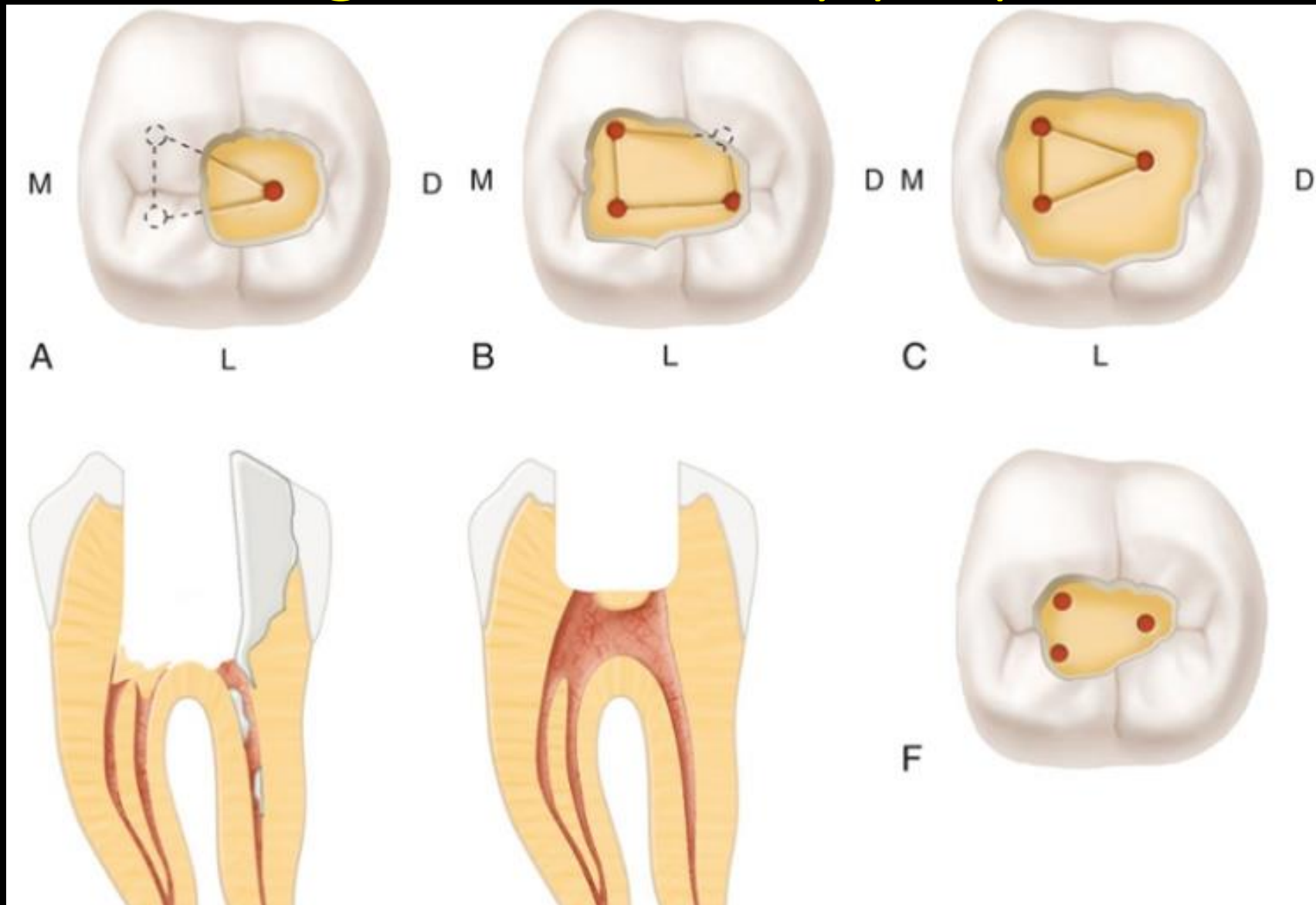
For molars the correct starting location is on the central groove halfway between the mesial and distal boundaries.



- Completely remove roof of pulp chamber.
- Straight line access into root canal.



Failures during access cavity preparation

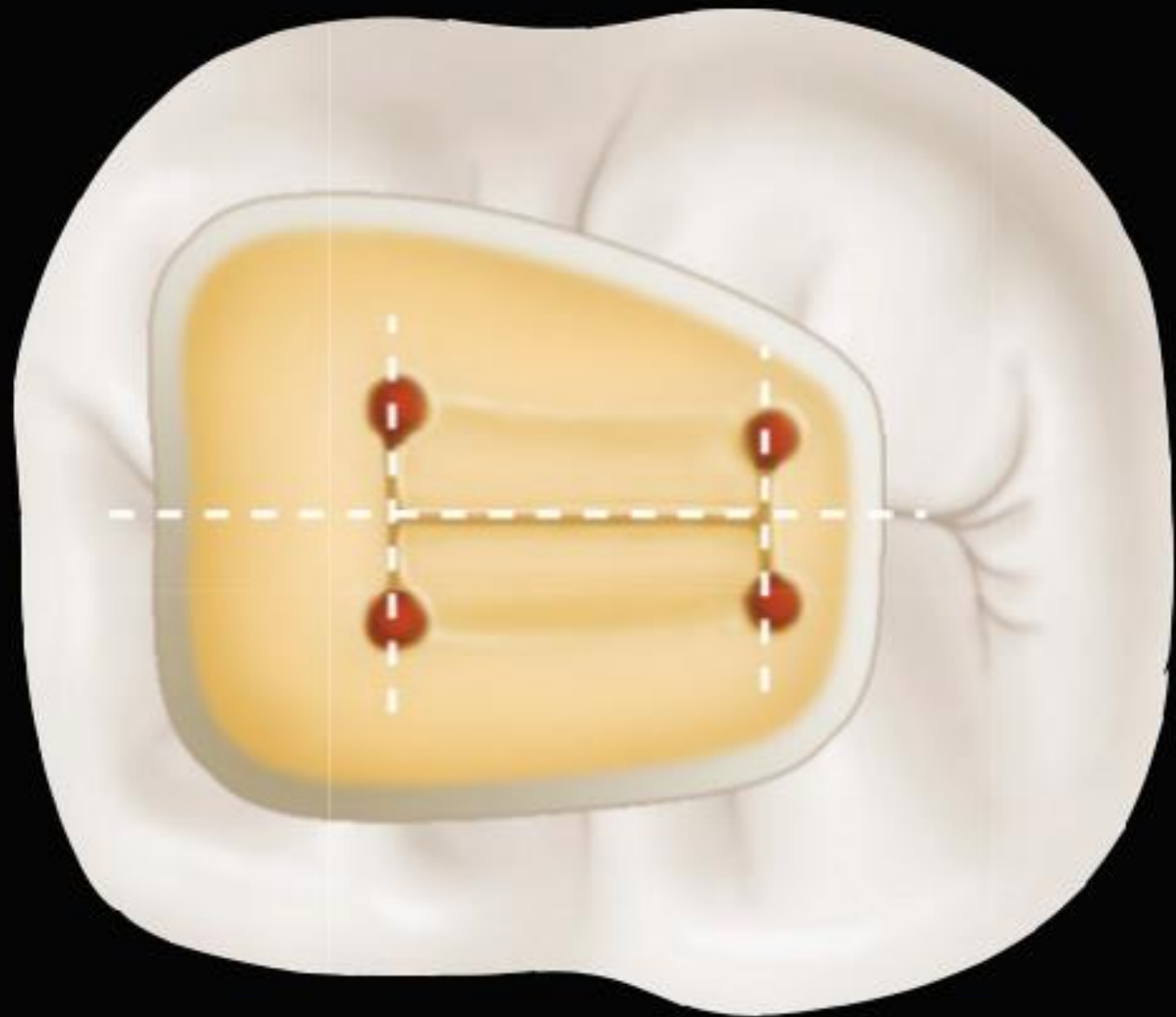


Localization of root canal orifices

- Knowledge of morphology.
- Diagnostic X-ray.
- Magnification and illumination
- Equipment

Guidelines for localization orifices of root canals

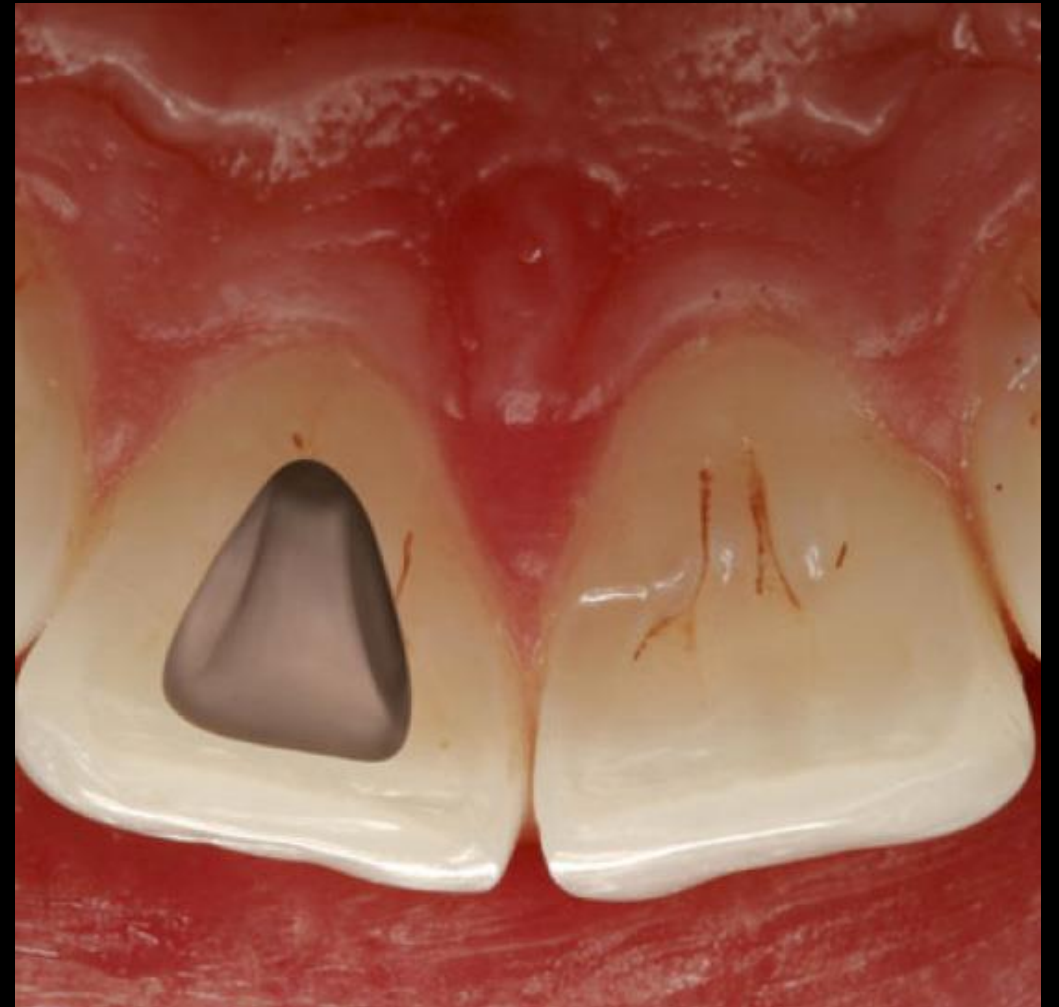
- *Centrality:* The floor of the pulp chamber is always located in the center of the tooth at the level of the CEJ.
- *Symmetry:* Except for the maxillary molars, canal orifices are equidistant from a line drawn in a mesiodistal direction through the center of the pulp chamber floor. Except for the maxillary molars, canal orifices lie on a line perpendicular to a line drawn in a mesiodistal direction across the center of the pulp chamber floor.
- *Color change:* The pulp chamber floor is always darker in color than the walls.
- *Orifice location:* The orifices of the root canals are always located at the junction of the walls and the floor; the orifices of the root canals are always located at the angles in the floor-wall junction; and the orifices of the root canals are always located at the terminus of the roots' developmental fusion lines.
- More than 95% of the teeth these investigators examined conformed to these spatial relationships.

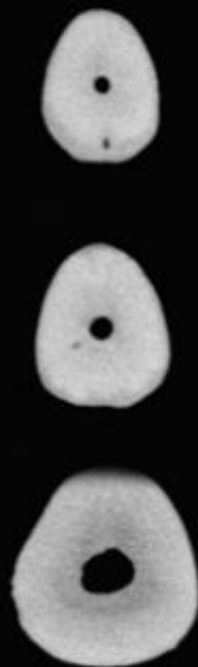
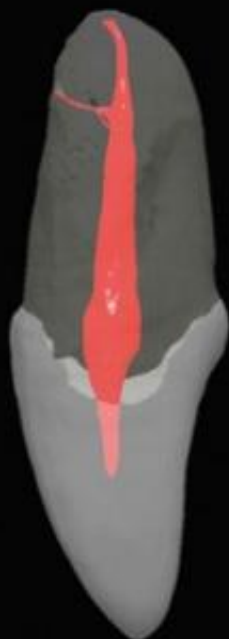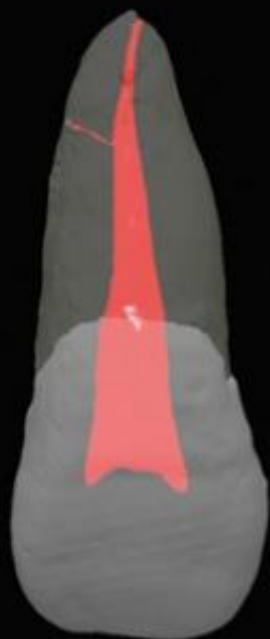
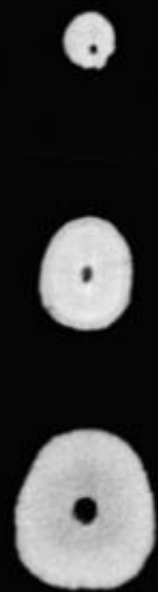
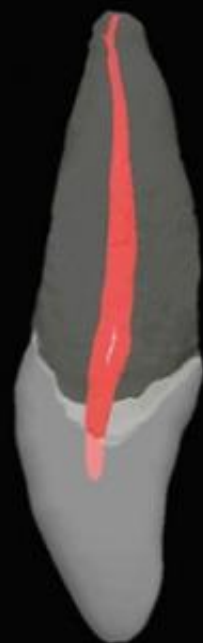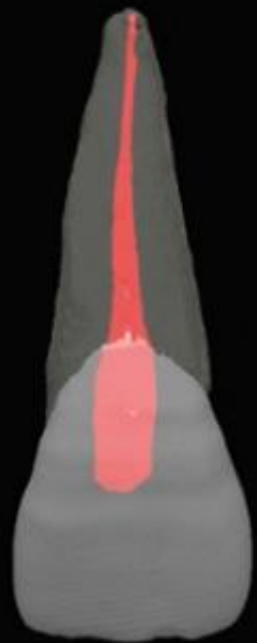


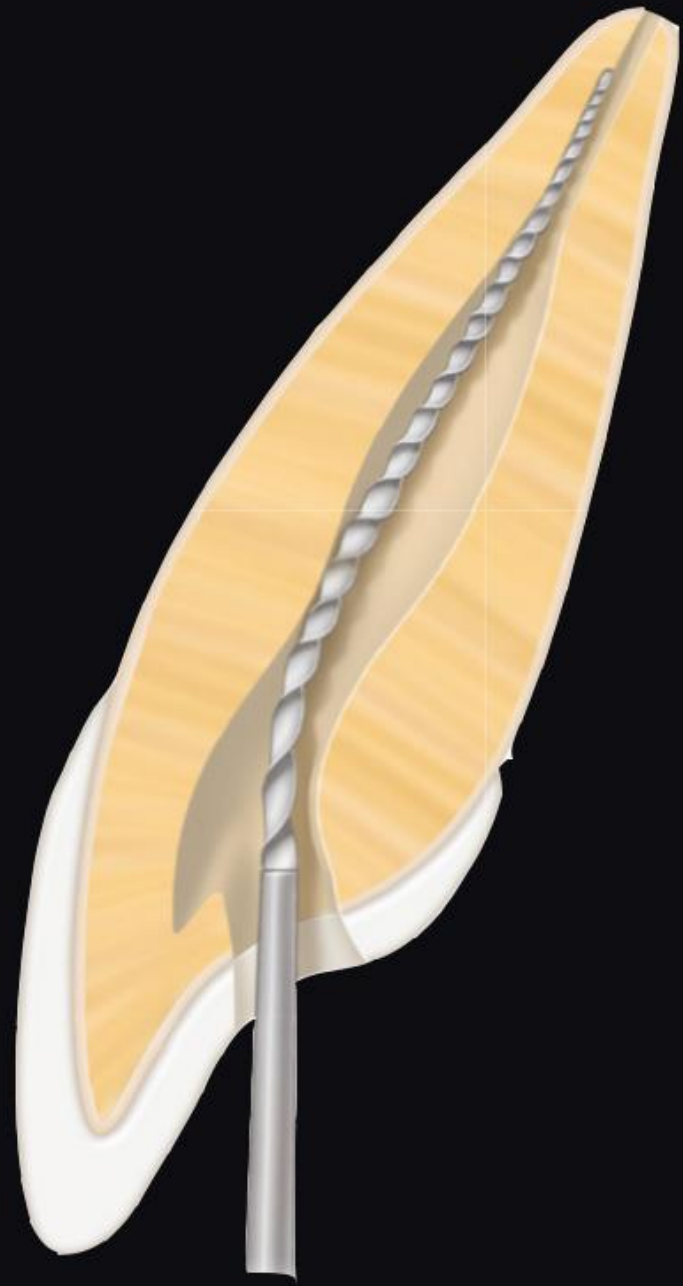
Naked eye vs. microscope

Maxillary central incisor

- The access cavity has triangular outline.
- 1 root – 1 root canal





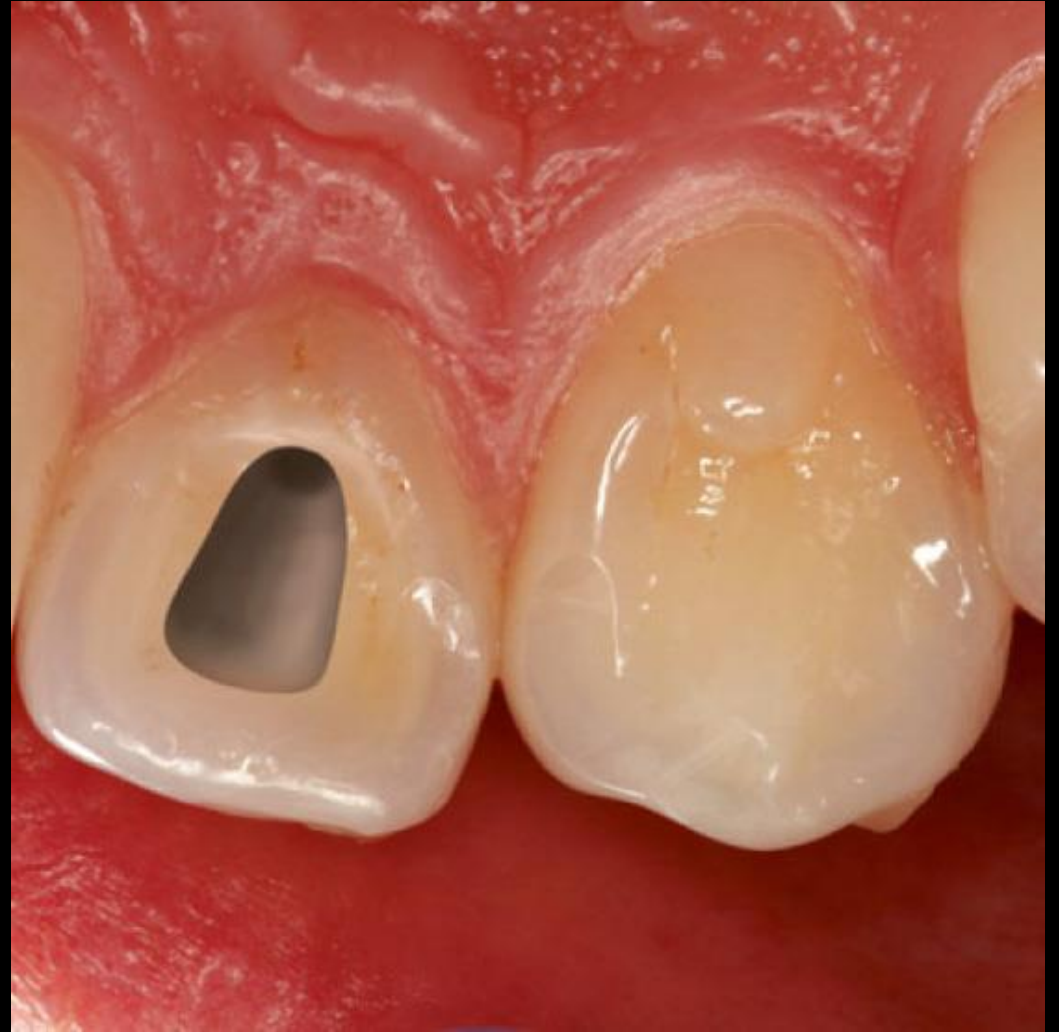

Maxillary central incisor

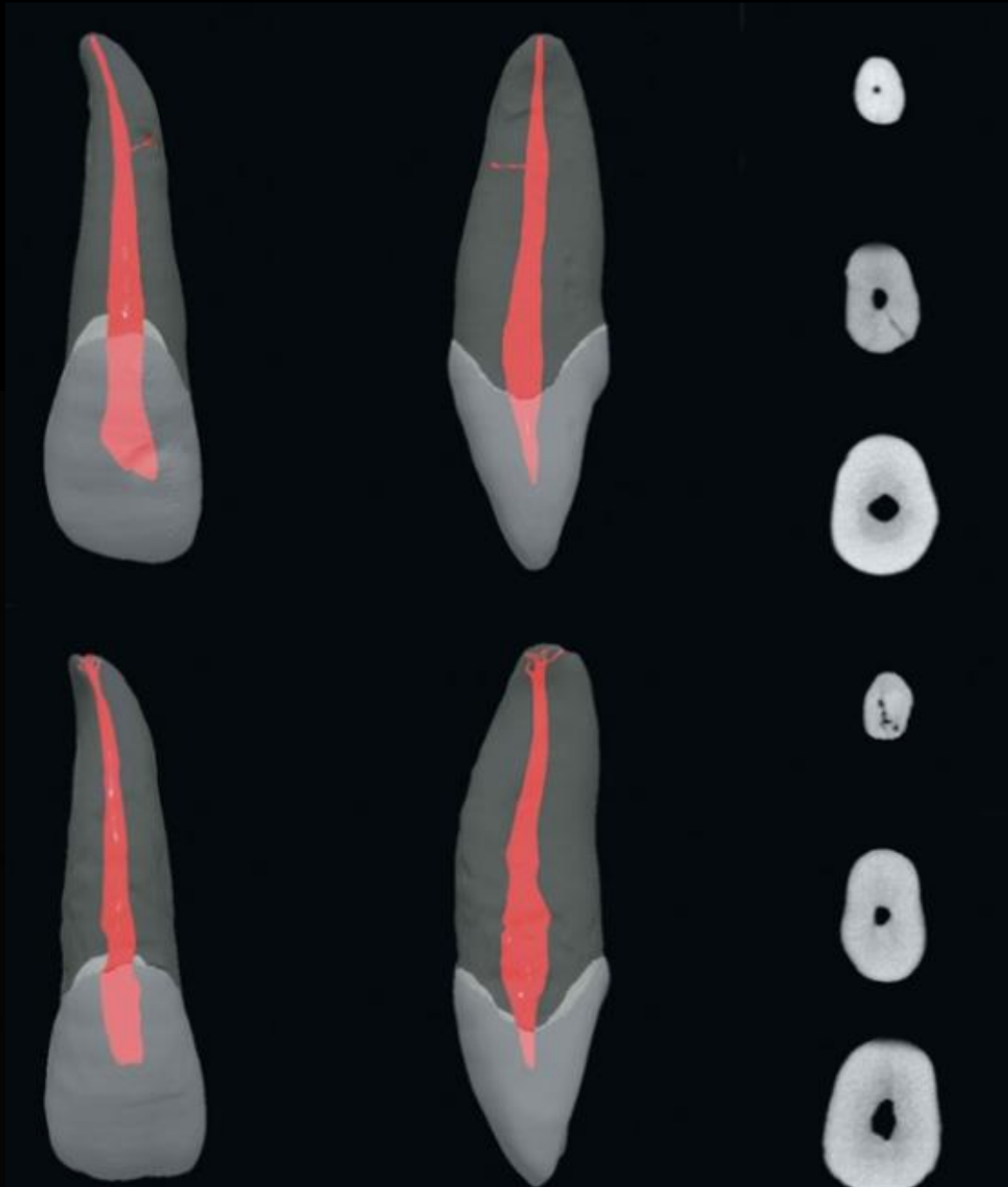
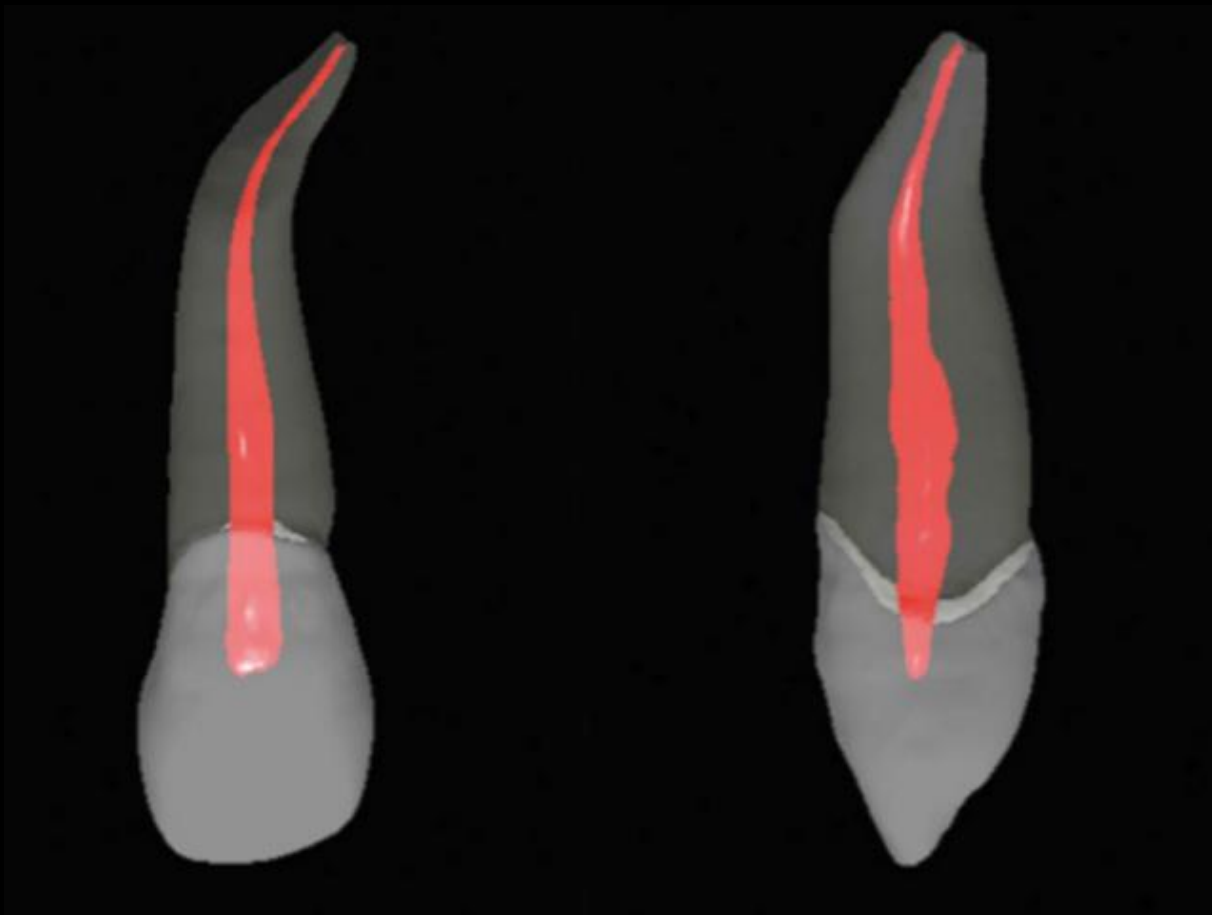
Length of tooth	23,5mm
Length of crown	10,5mm
Length of root	13mm
Width of crown	8,5mm
Width of cervical area	7mm

Maxillary lateral incisor

- The access cavity is triangular and reproduces the shape of the endodontic space.
- 1 root – 1 root canal



In 53% cases we can find distal curvature in the apical third of the root.

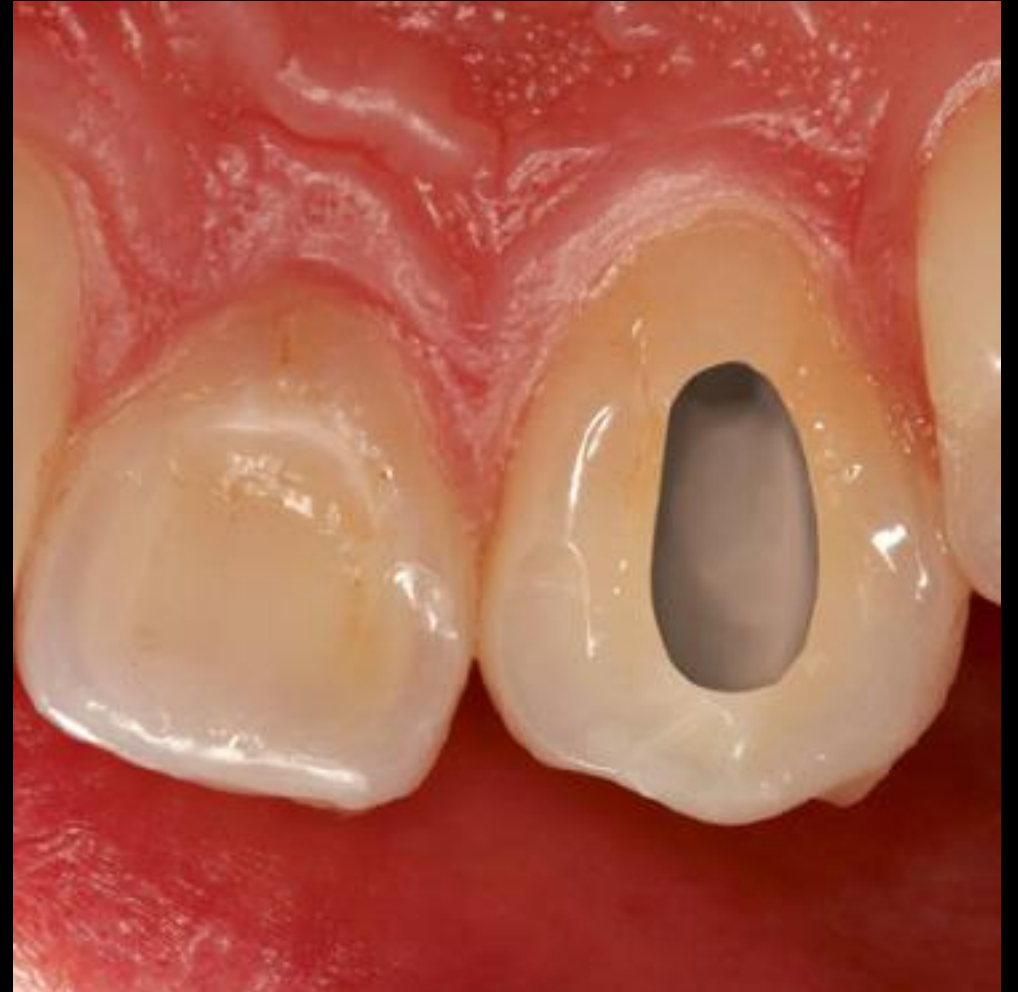

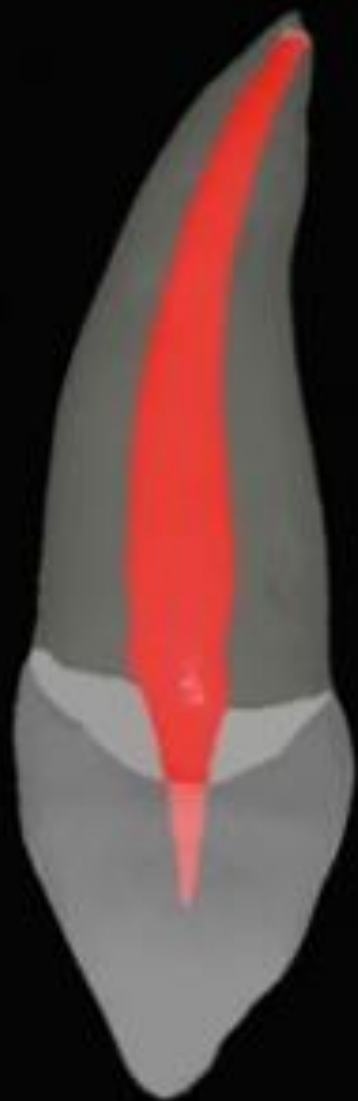Maxillary lateral incisor

Length of tooth	22mm
Length of crown	9mm
Length of root	13mm
Width of crown	6,5mm
Width of cervical area	5mm

Maxillary canine

- The access cavity of the pulp chamber has an oval shape, going from the cusp to the cingulum of the coronal cervical one-third.
- 1 root – 1 root canal.



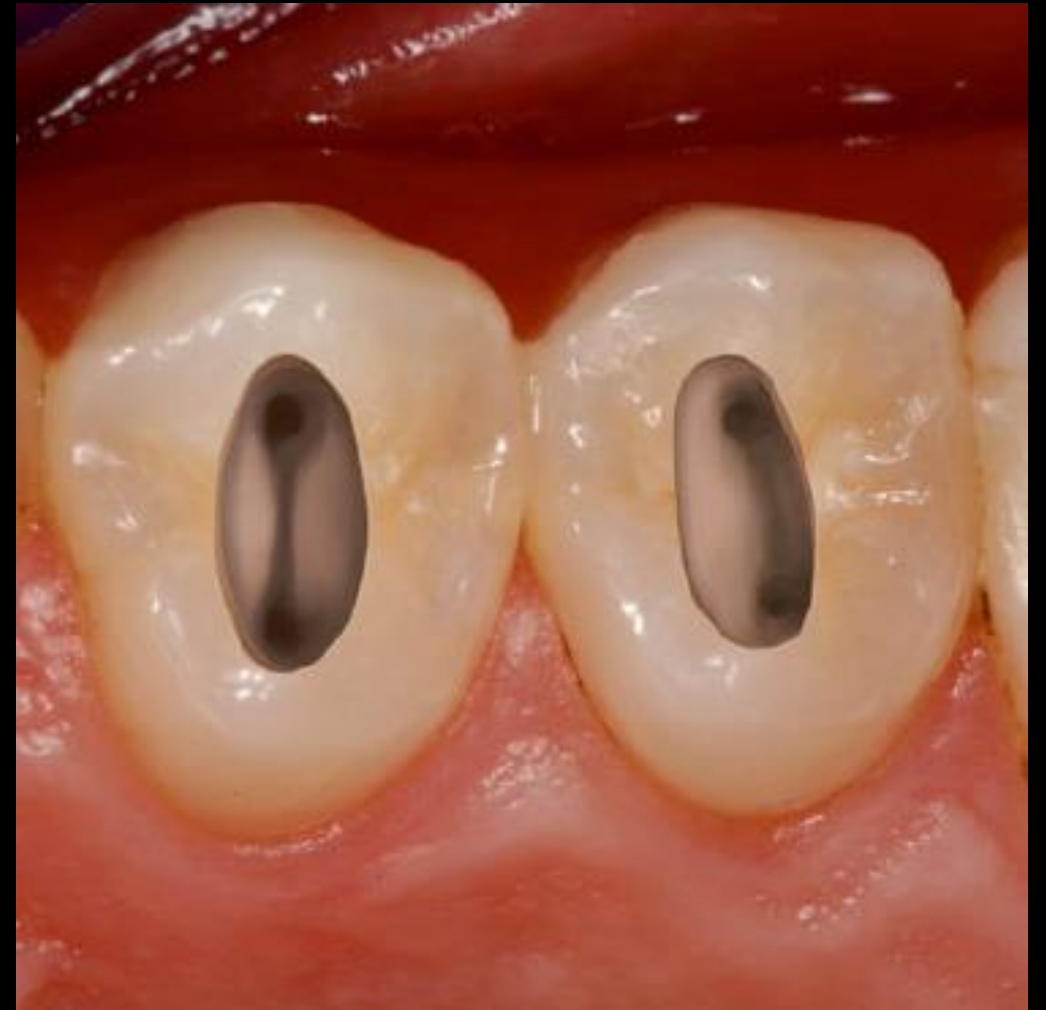

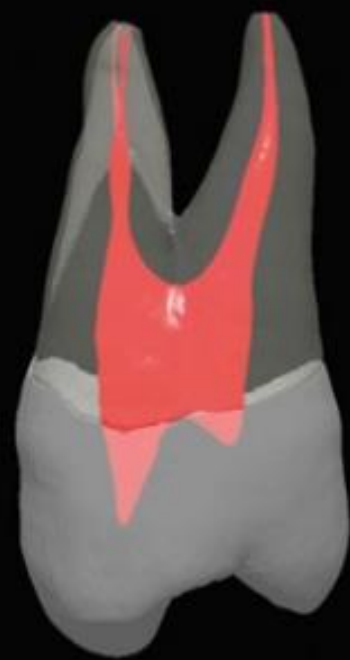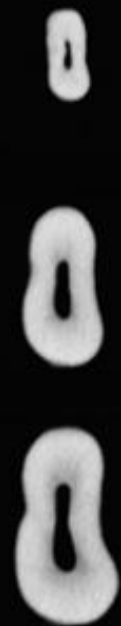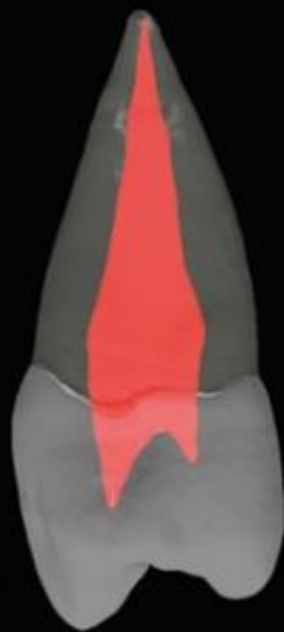
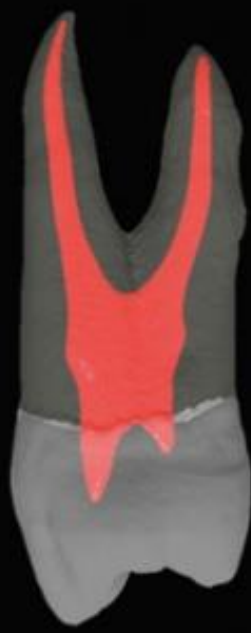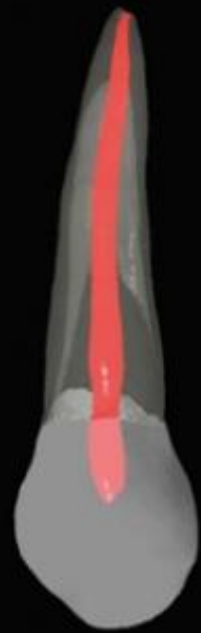Maxillary canine

Length of tooth	27 mm
Length of crown	10 mm
Length of root	17 mm
Width of crown	7,5 mm
Width of cervical area	7mm

Maxillary first premolar

- Vestibular and palatal pulp horn.
- The access preparation for the maxillary first premolar is oval or slot shaped.
- P root – 1rc.
- V root – 1rc 95 %, 2rc 5%.



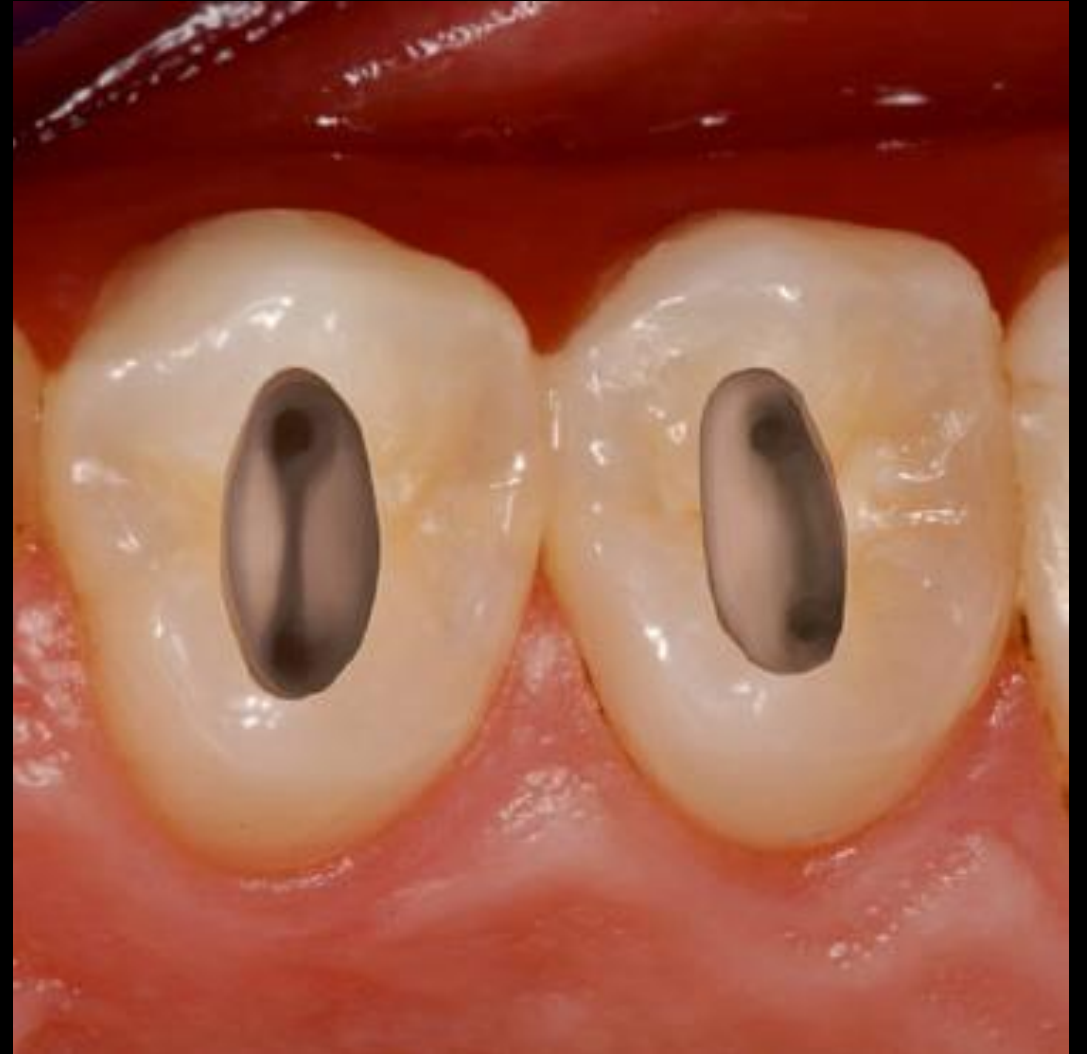

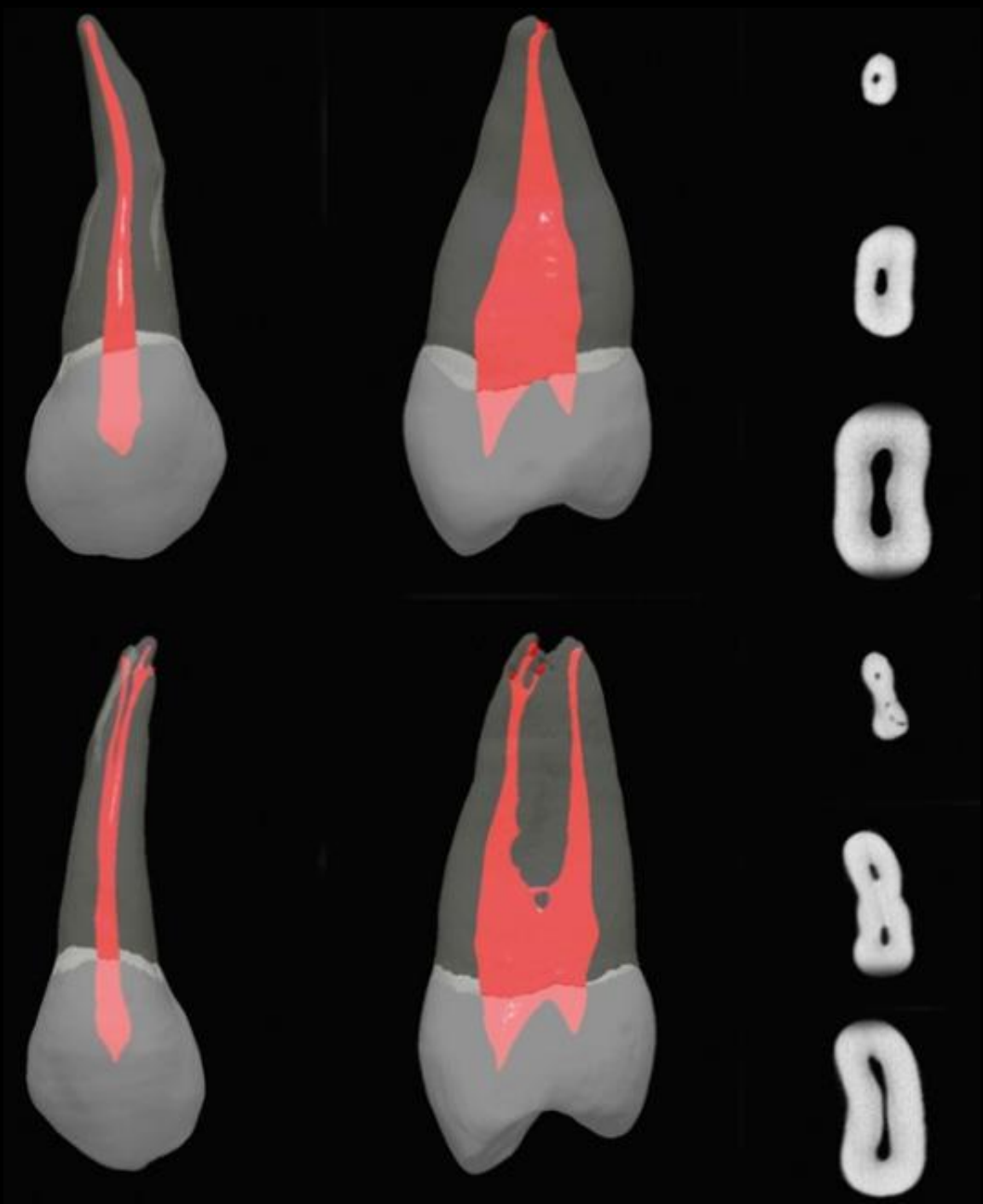
Maxillary first premolar

Length of tooth	22,5 mm
Length of crown	8,5 mm
Length of root	14 mm
Width of crown	7 mm
Width of cervical area	5 mm

Maxillary second premolar

- Vestibular and palatal pulp horn.
- The access preparation for the maxillary second premolar is oval or slot shaped.





Tooth	No. of Teeth	Type I (1) Canals	Type II (2-1) Canals	Type III (1-2-1) Canals	Total With One Canal at Apex	Type IV (2) Canals	Type V (1-2) Canals	Type VI (2-1-2) Canals	Type VII (1-2-1-2) Canals	Total With Two Canals at Apex	Type VIII (3) Canals	Total With Three Canals at Apex
Maxillary first premolar	400	8	18	0	26	62	7	0	0	69	5	5
Maxillary second premolar	200	48	22	5	75	11	6	5	2	24	1	1



Type I



Type II



Type III



Type IV



Type V



Type VI



Type VII



Type VIII

A One canal at apex

B Two canals at apex

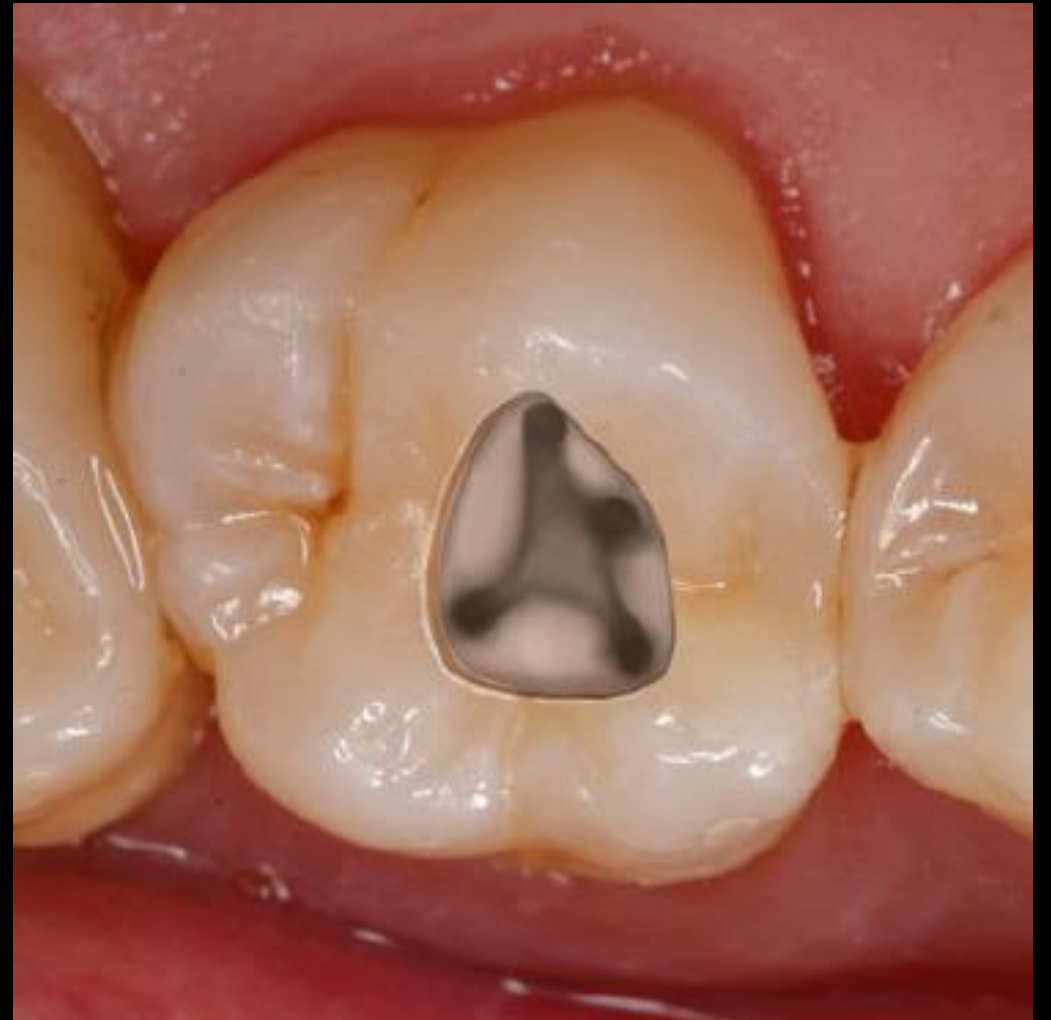C Three canals at apex

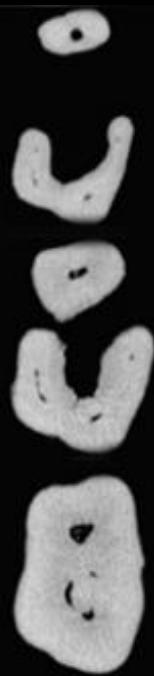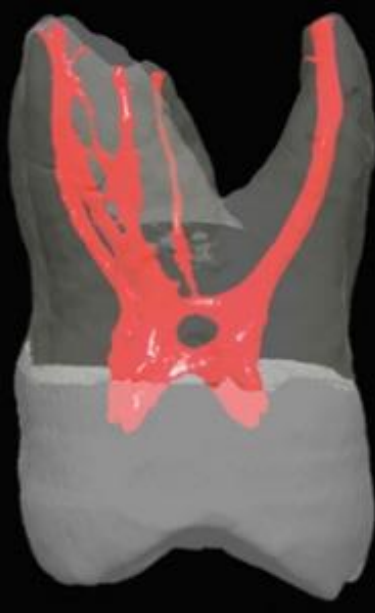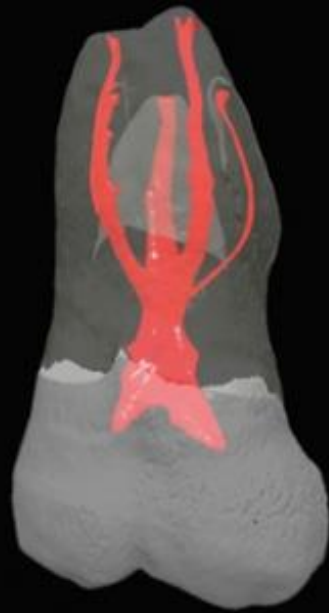
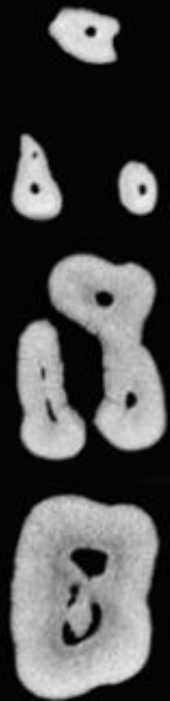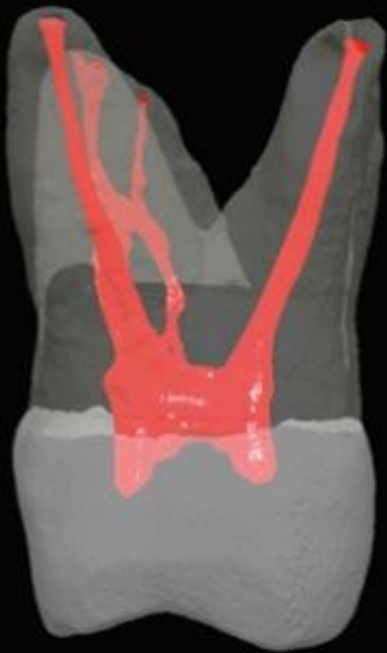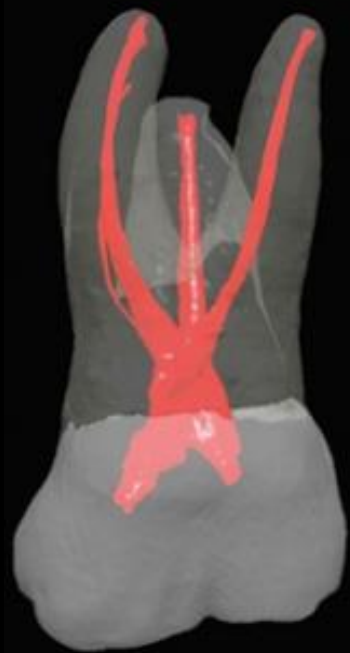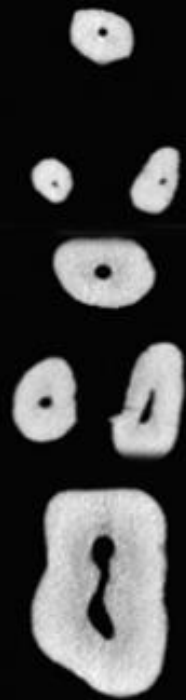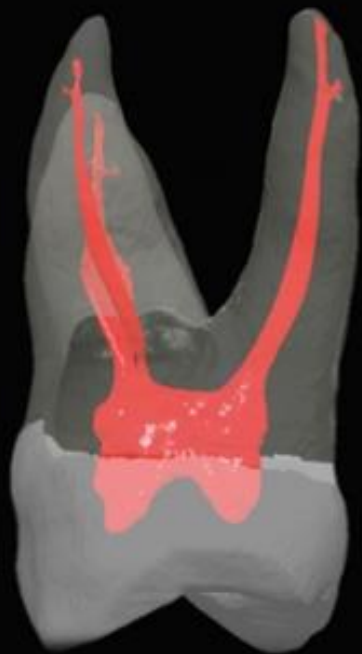
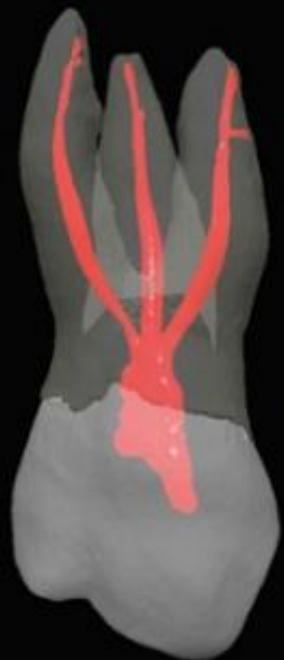Maxillary second premolar

Length of tooth	22,5 mm
Length of crown	8,5 mm
Length of root	14 mm
Width of crown	7 mm
Width of cervical area	5 mm

Maxillary first molar

- The maxillary first molar is the largest tooth in volume and one of the most complex in root and canal anatomy.
- The access cavity has a rhomboid shape, with the corners corresponding to the four orifices.
- P root – 1rc (55% B curved).
- DB root – 1rc 96%, 2rc 4%.
- MB root – 1rc 5-40%%, 2rc 95-60%





Tooth	No. of Teeth	Type I (1) Canals	Type II (2-1) Canals	Type III (1-2-1) Canals	Total With One Canal at Apex	Type IV (2) Canals	Type V (1-2) Canals	Type VI (2-1-2) Canals	Type VII (1-2-1-2) Canals	Total With Two Canals at Apex	Type VIII (3) Canals	Total With Three Canals at Apex
Maxillary first molar												
Mesiobuccal	100	45	37	0	82	18	0	0	0	18	0	0
Distobuccal	100	100	0	0	100	0	0	0	0	0	0	0
Palatal	100	100	0	0	100	0	0	0	0	0	0	0



Type I



Type II



Type III



Type IV



Type V



Type VI



Type VII



Type VIII

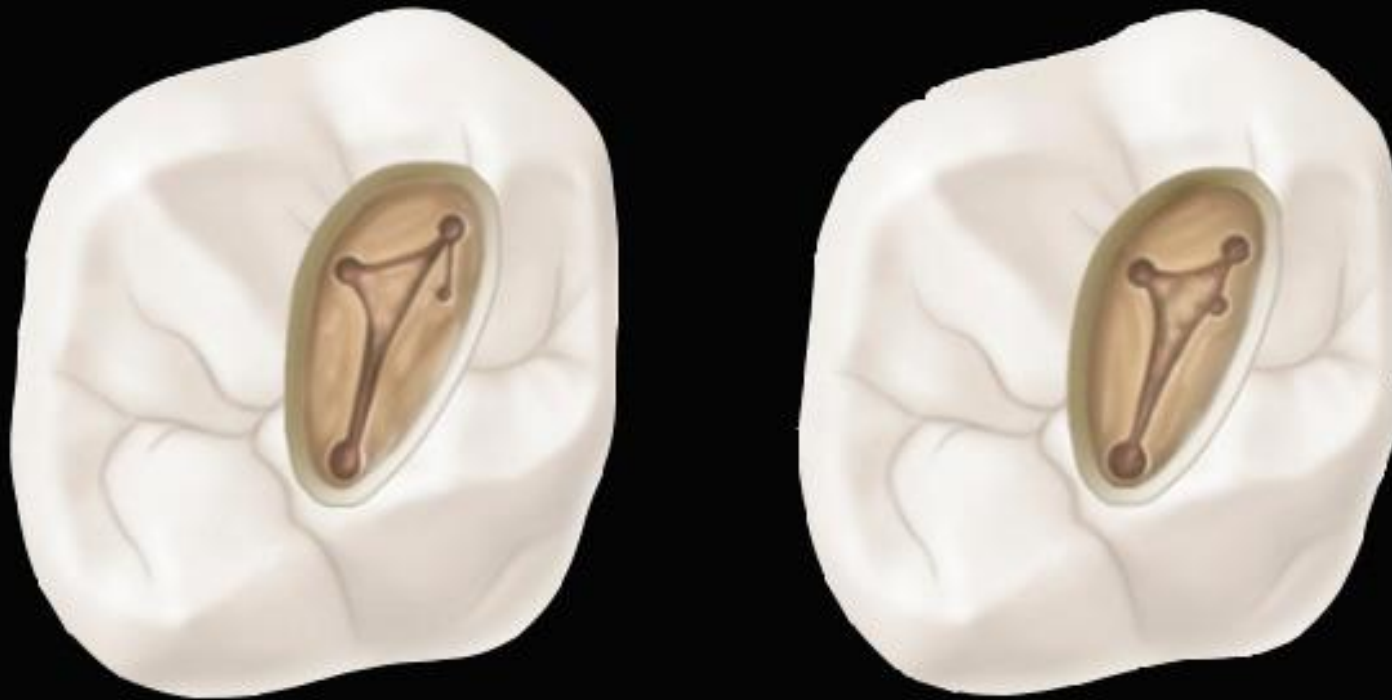
A One canal at apex

B Two canals at apex

C Three canals at apex

MB2

- Localised on the line connectin MB a P root canal, under dentin shoulder.
- Removing shoulder-> US StartX 2.

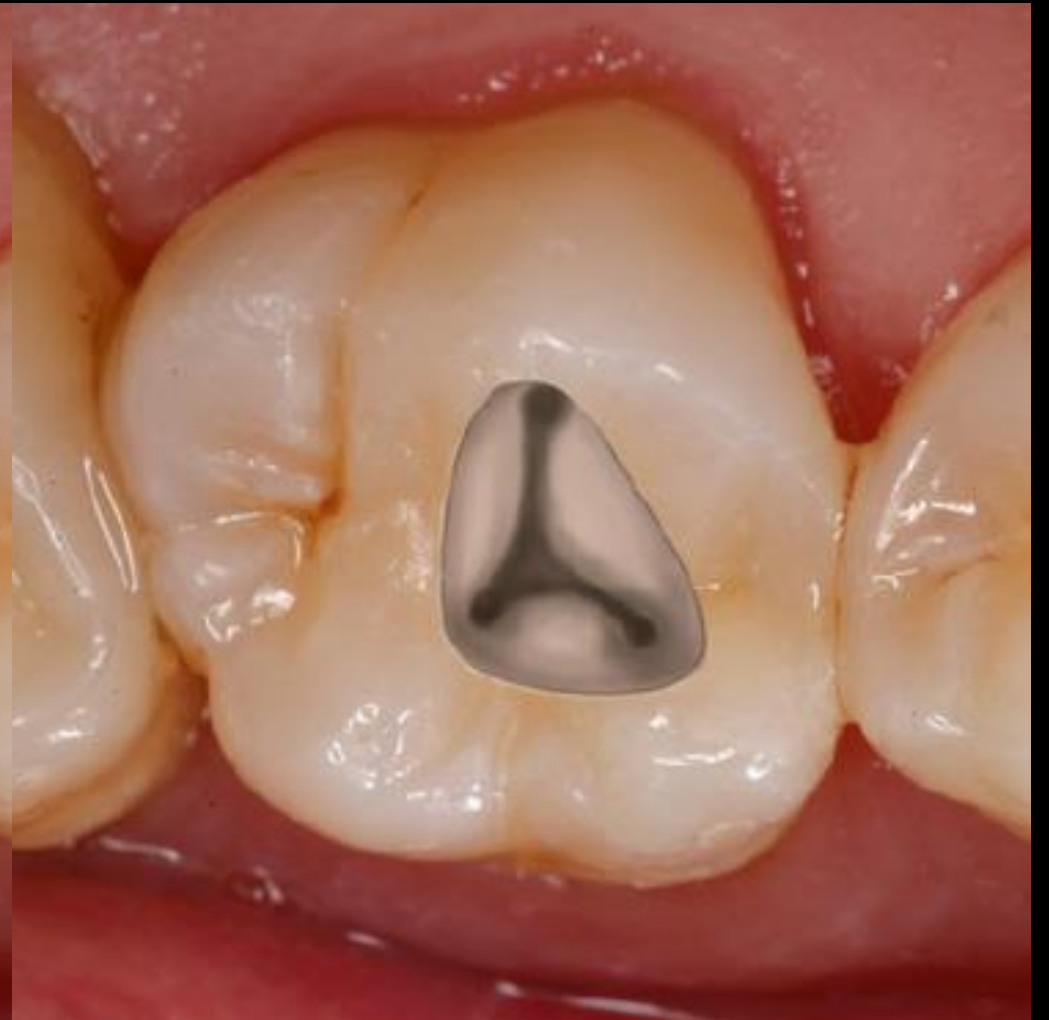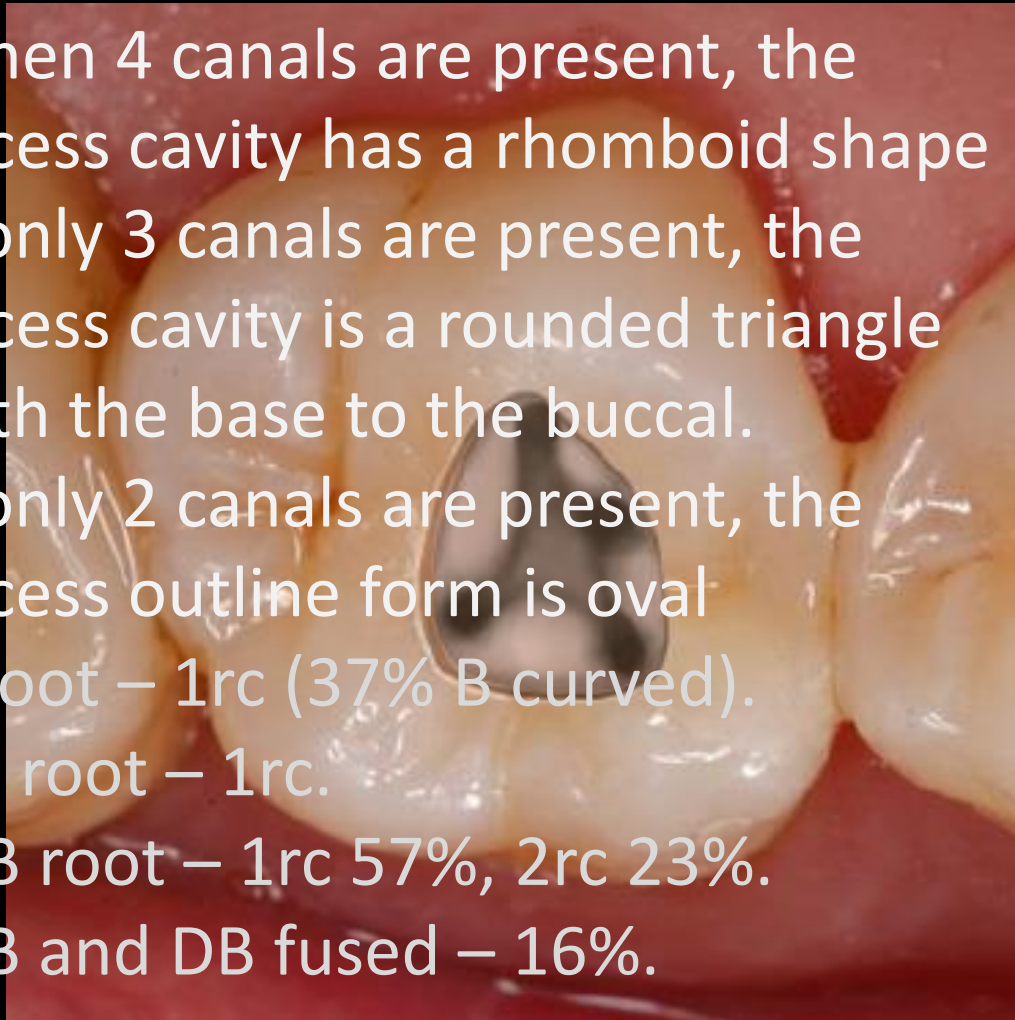


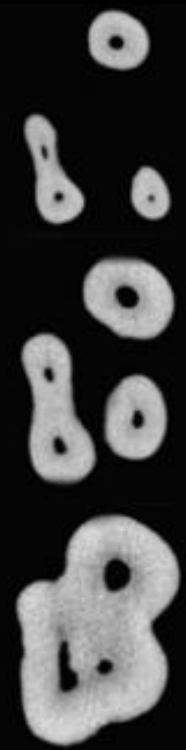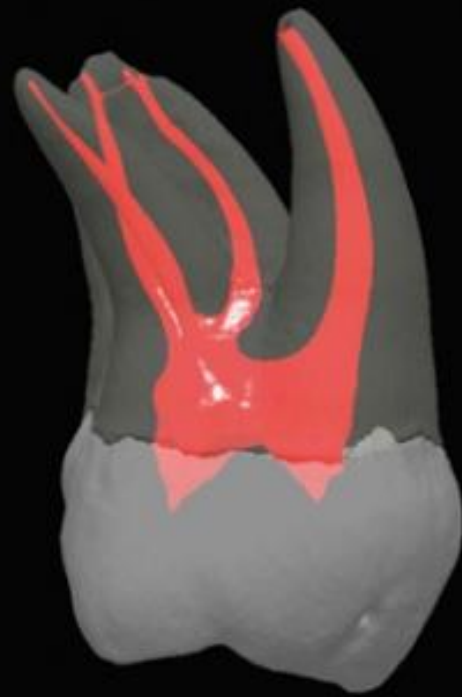
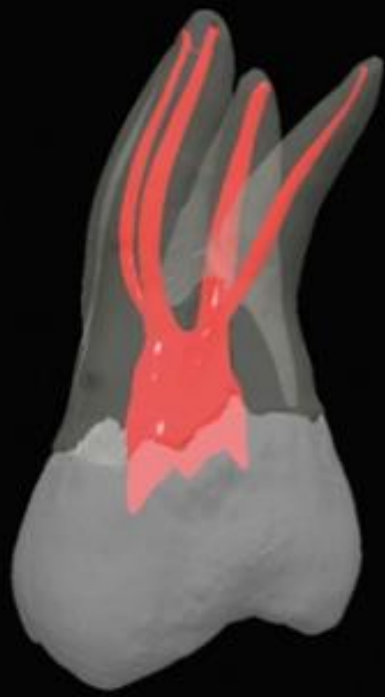
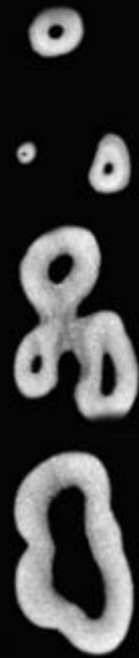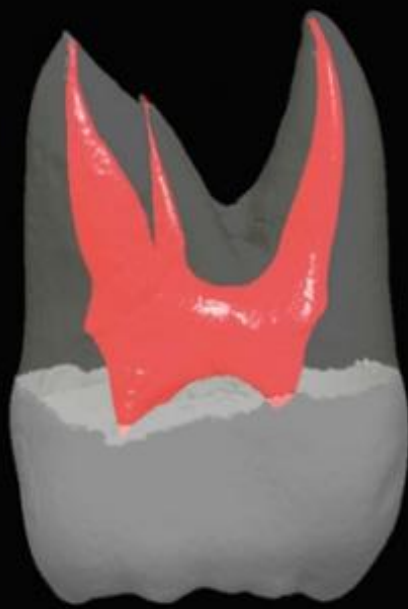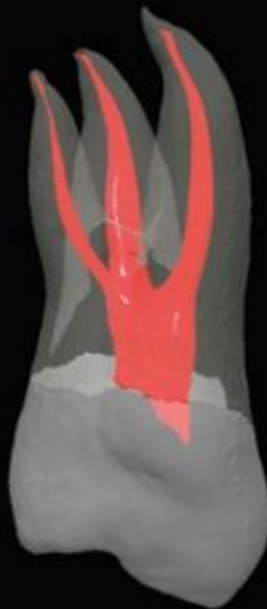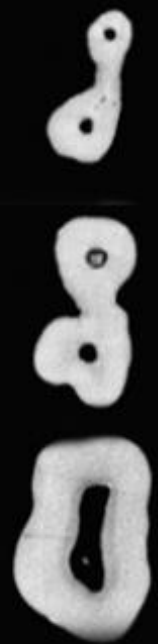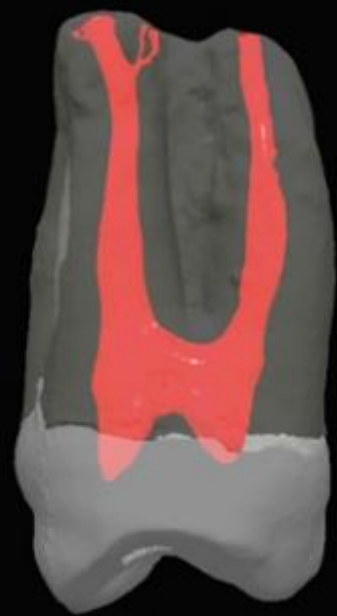
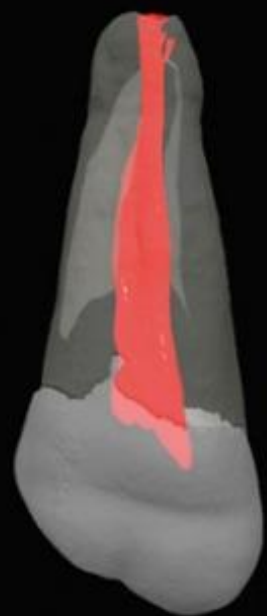
Maxillary first molar

Length of tooth	20/22mm
Length of crown	7,5mm
Length of root	12/13mm
Width of crown	10mm
Width of cervical area	8mm

Second upper molar

- When 4 canals are present, the access cavity has a rhomboid shape
- If only 3 canals are present, the access cavity is a rounded triangle with the base to the buccal.
- If only 2 canals are present, the access outline form is oval
- P root – 1rc (37% B curved).
- DB root – 1rc.
- MB root – 1rc 57%, 2rc 23%.
- MB and DB fused – 16%.





Tooth	No. of Teeth	Type I (1) Canals	Type II (2-1) Canals	Type III (1-2-1) Canals	Total With One Canal at Apex	Type IV (2) Canals	Type V (1-2) Canals	Type VI (2-1-2) Canals	Type VII (1-2-1-2) Canals	Total With Two Canals at Apex	Type VIII (3) Canals	Total With Three Canals at Apex
Maxillary second molar												
Mesiobuccal	100	71	17	0	88	12	0	0	0	12	0	0
Distobuccal	100	100	0	0	100	0	0	0	0	0	0	0
Palatal	100	100	0	0	100	0	0	0	0	0	0	0



Type I



Type II



Type III



Type IV



Type V



Type VI



Type VII



Type VIII

A One canal at apex

B Two canals at apex

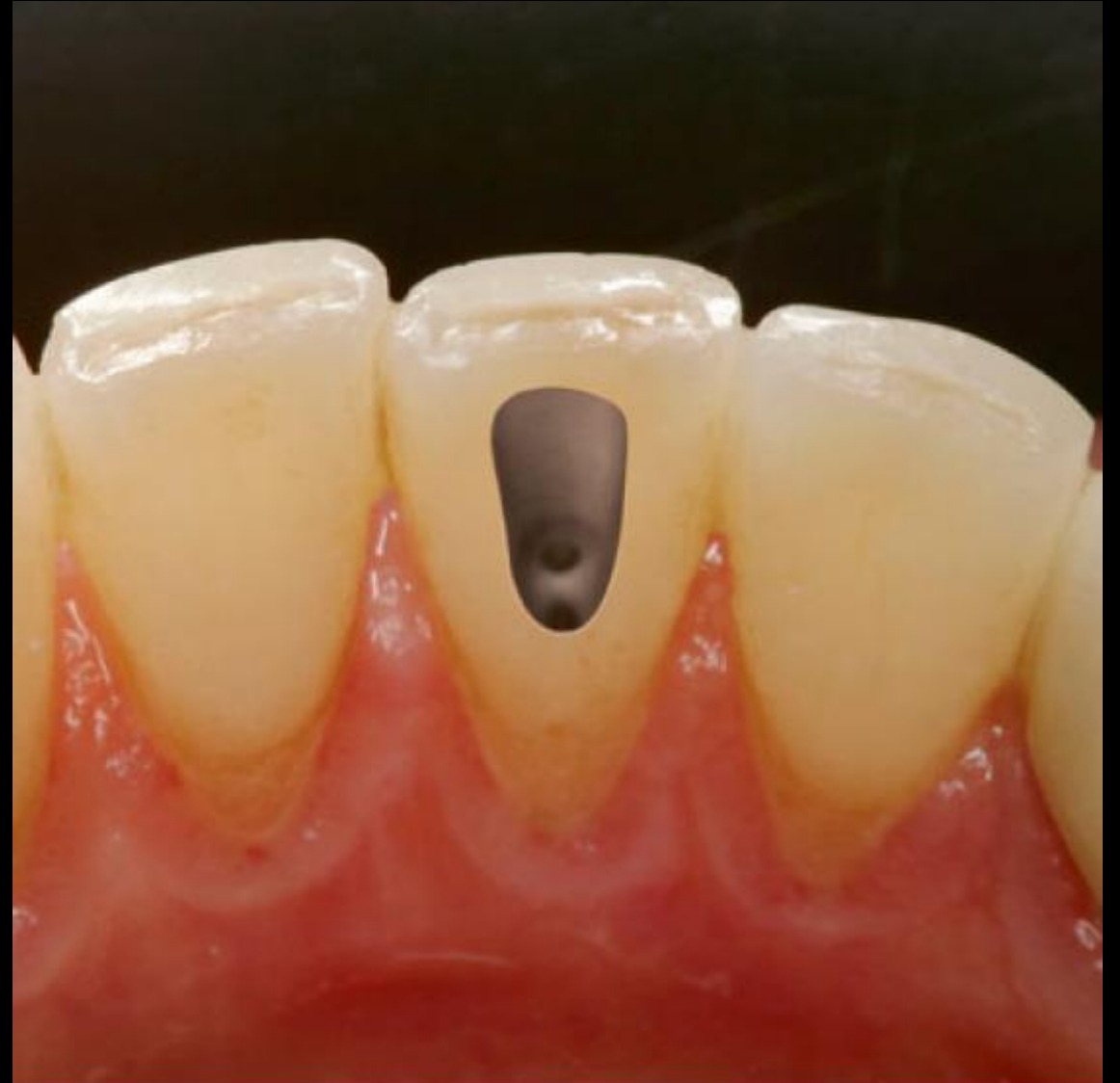C Three canals at apex

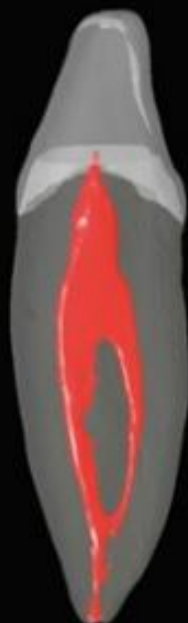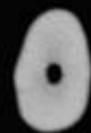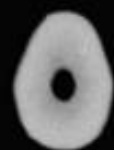
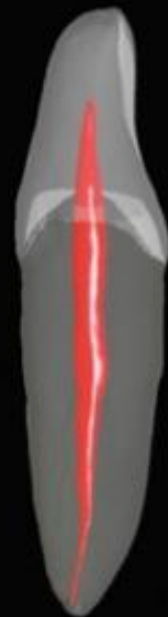

Second upper molar

Length of tooth	19/21mm
Length of crown	7mm
Length of root	11/12mm
Width of crown	9mm
Width of cervical area	7mm

Mandibular central and lateral incisor

- High difficulty – small proportions of tooth
- The external outline form may be triangular or oval, extended to incisal edge.
- 1 root – 1 root canal 75%, 2 root canals 25%





Mandibular central incisor

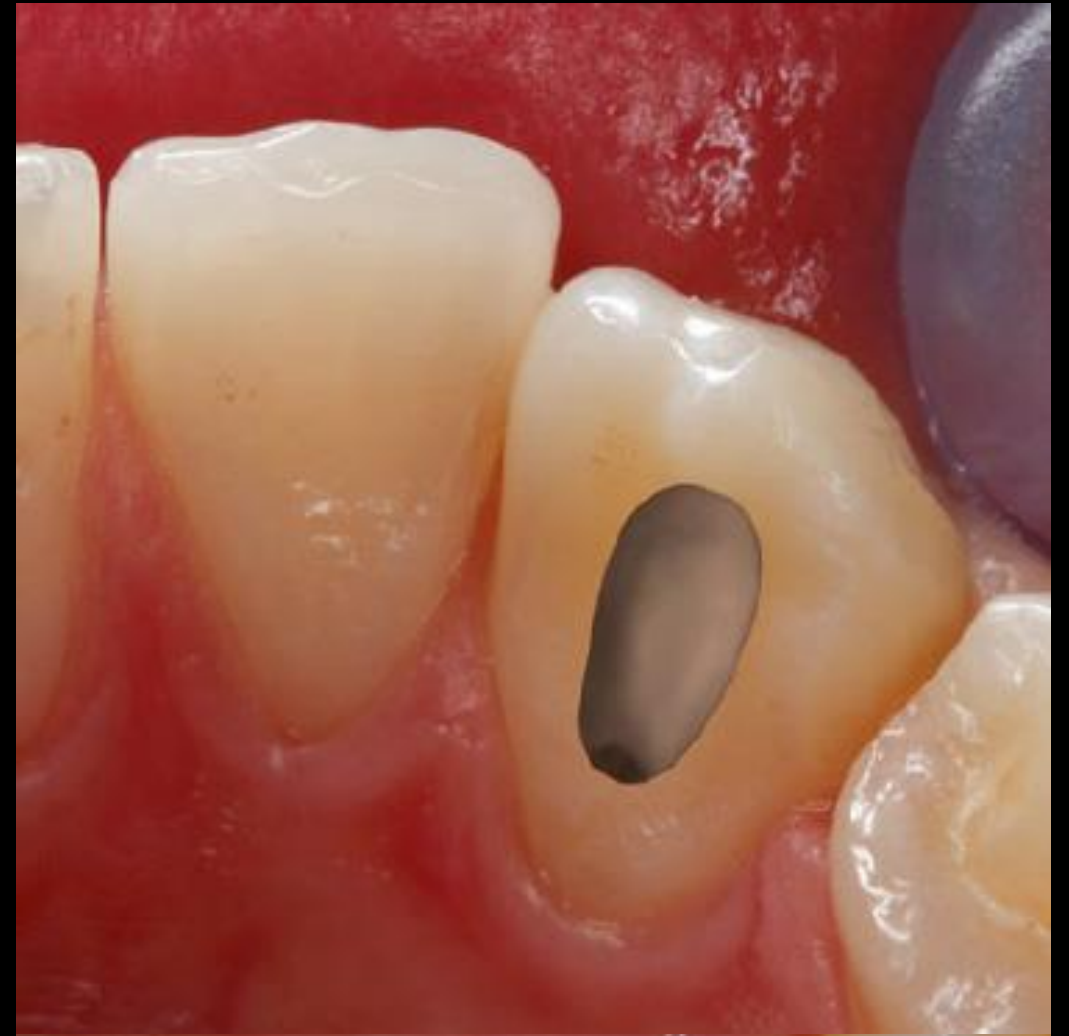Length of tooth	22 mm
Length of crown	9,5 mm
Length of root	12,5 mm
Width of crown	5 mm
Width of cervical area	3,5 mm

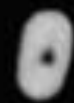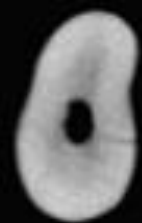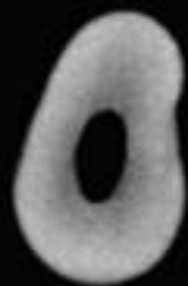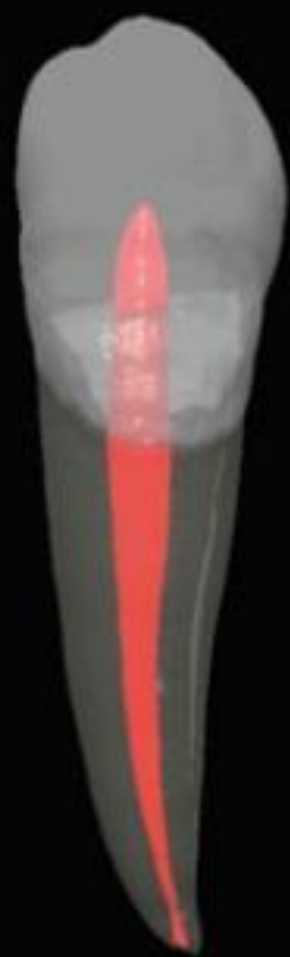Mandibular lateral incisor

Length of tooth	23,5 mm
Length of crown	9,5 mm
Length of root	14 mm
Width of crown	5,5 mm
Width of cervical area	4 mm

Mandibular canine

- The access cavity for the mandibular canine is oval or slot shaped.
- 1 root – 1 rc in 94%, 2 rc in 6%



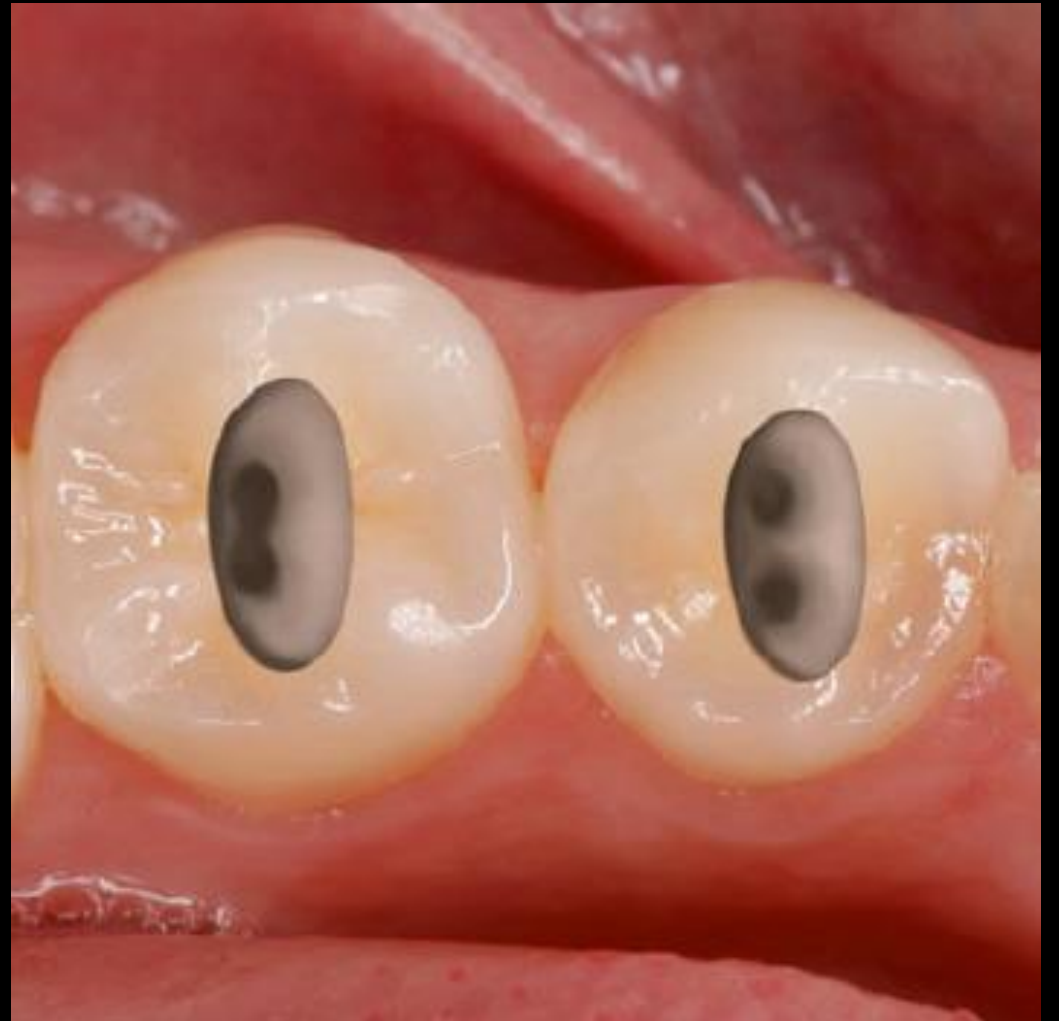

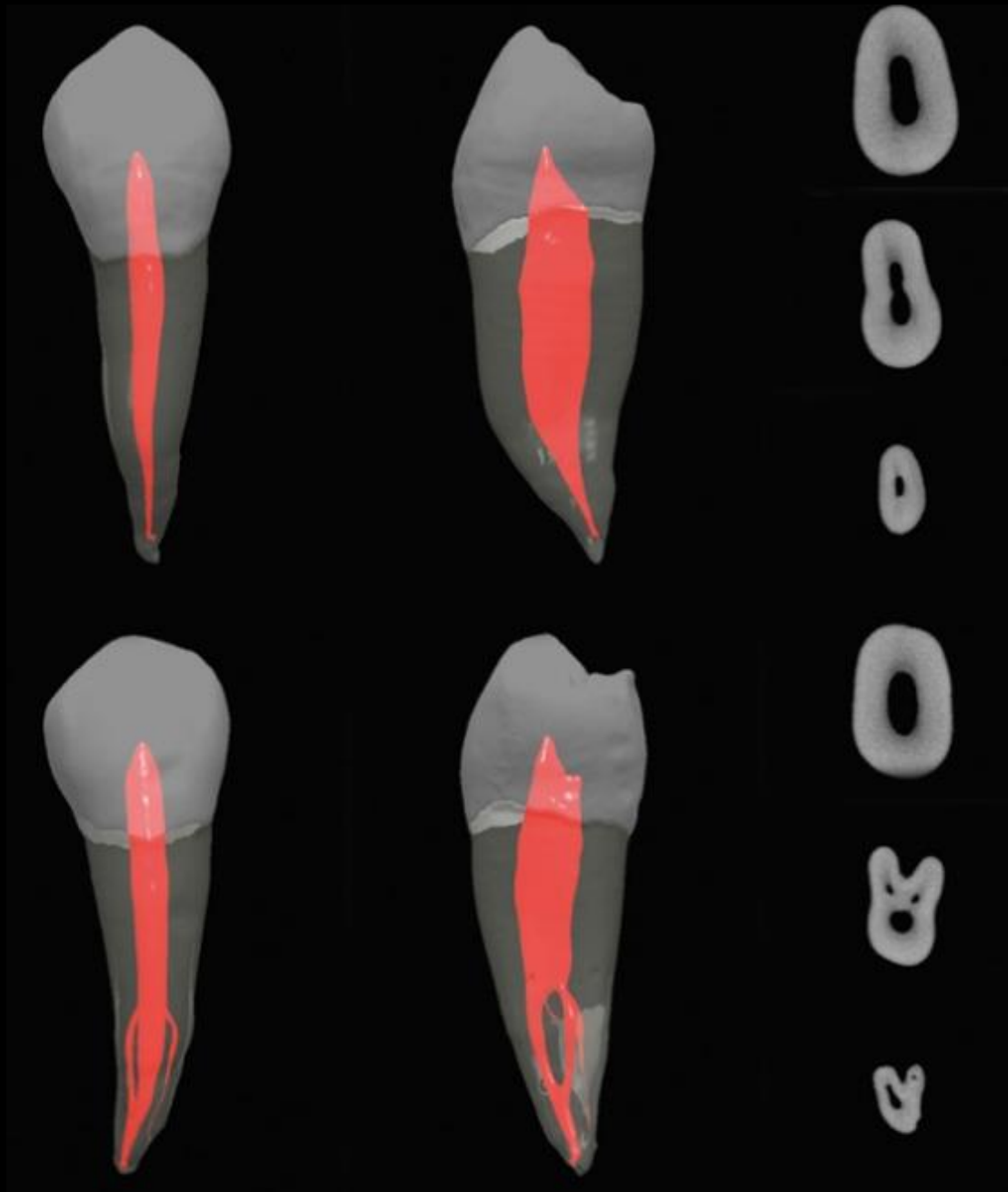
Mandibular canine

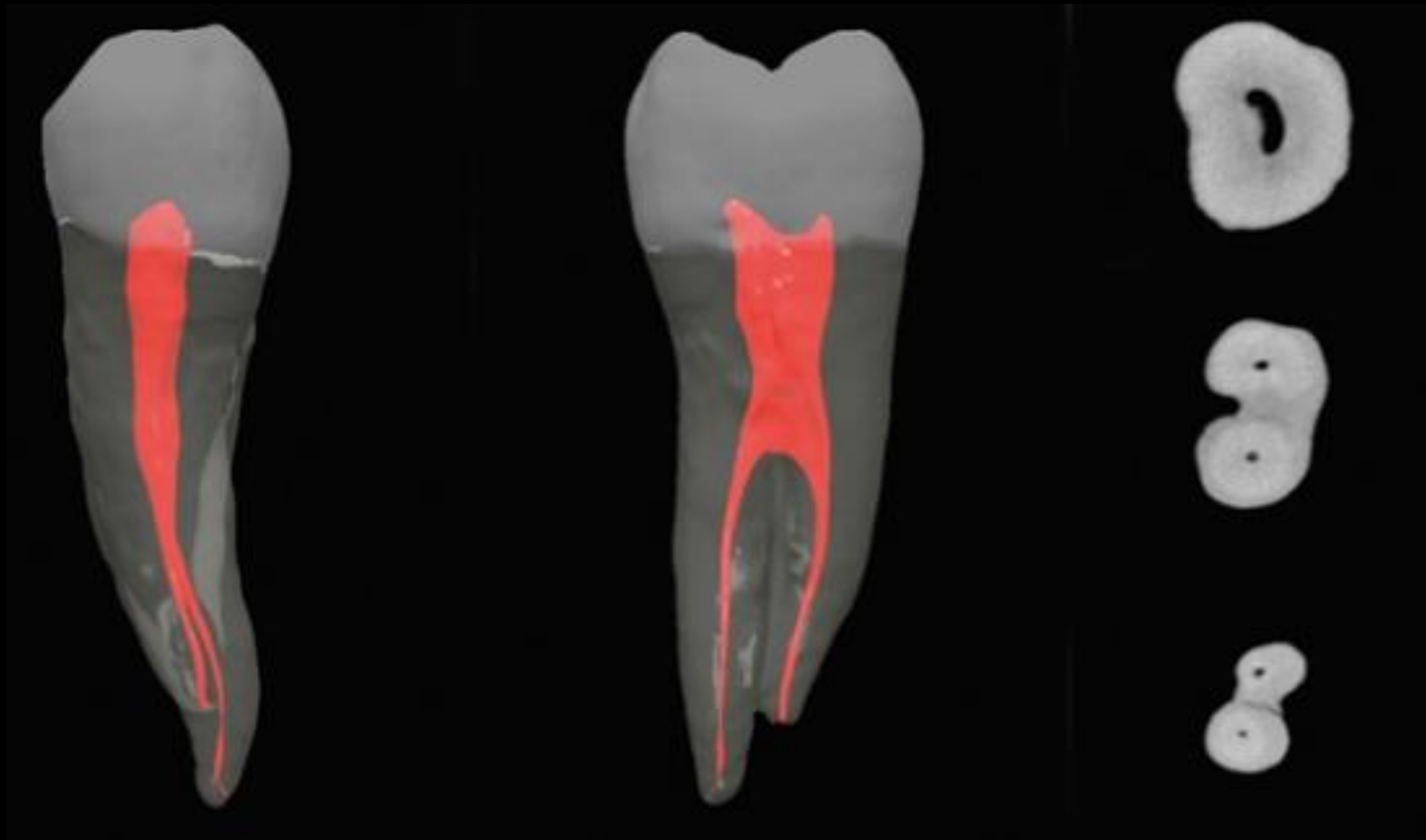
Length of tooth	23 mm
Length of crown	10 mm
Length of root	17 mm
Width of crown	7,5 mm
Width of cervical area	5,5 mm

Mandibular first premolar

- Two pulp horns. Lingual inclination of crown.
- The access preparation is oval or slot shaped.
- 1 root – 1rc 74%.





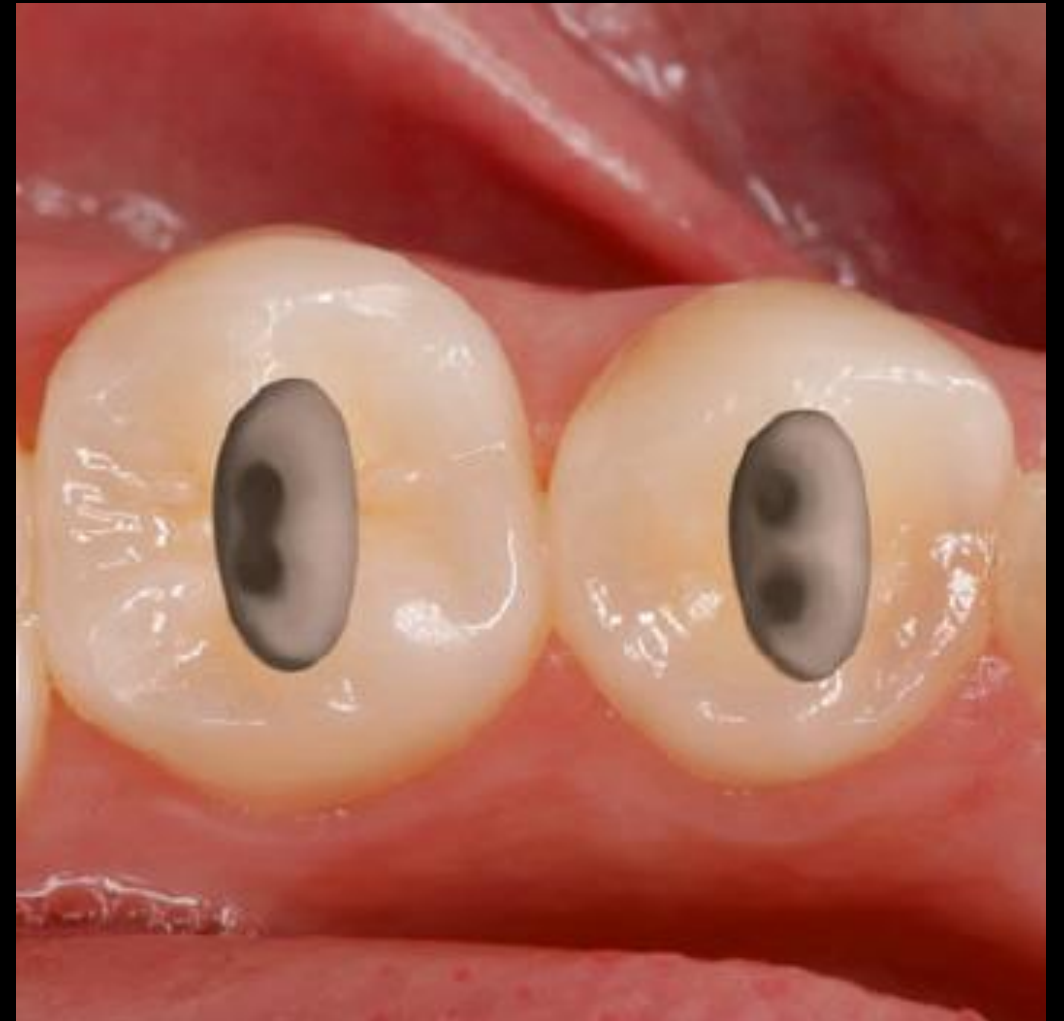

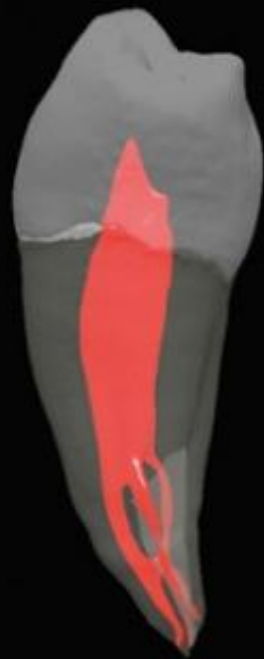
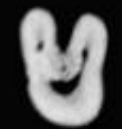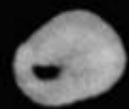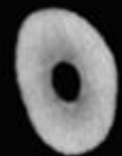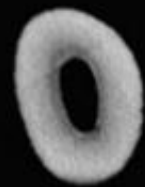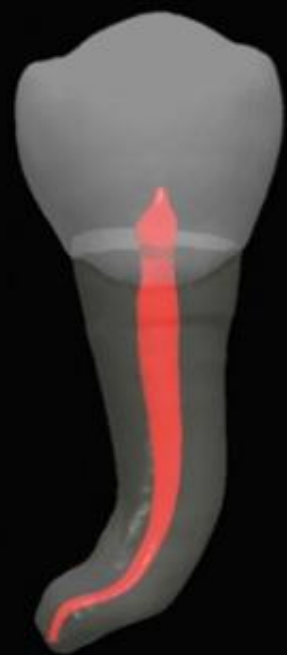Mandibular first premolar

Length of tooth	24,5 mm
Length of crown	8,5 mm
Length of root	14 mm
Width of crown	6 mm
Width of cervical area	5 mm

Mandibular second premolar

- Two pulp horns. Lingual inclination of crown.
- The access preparation is oval or slot shaped.
- 1 root – 1rc 97%.



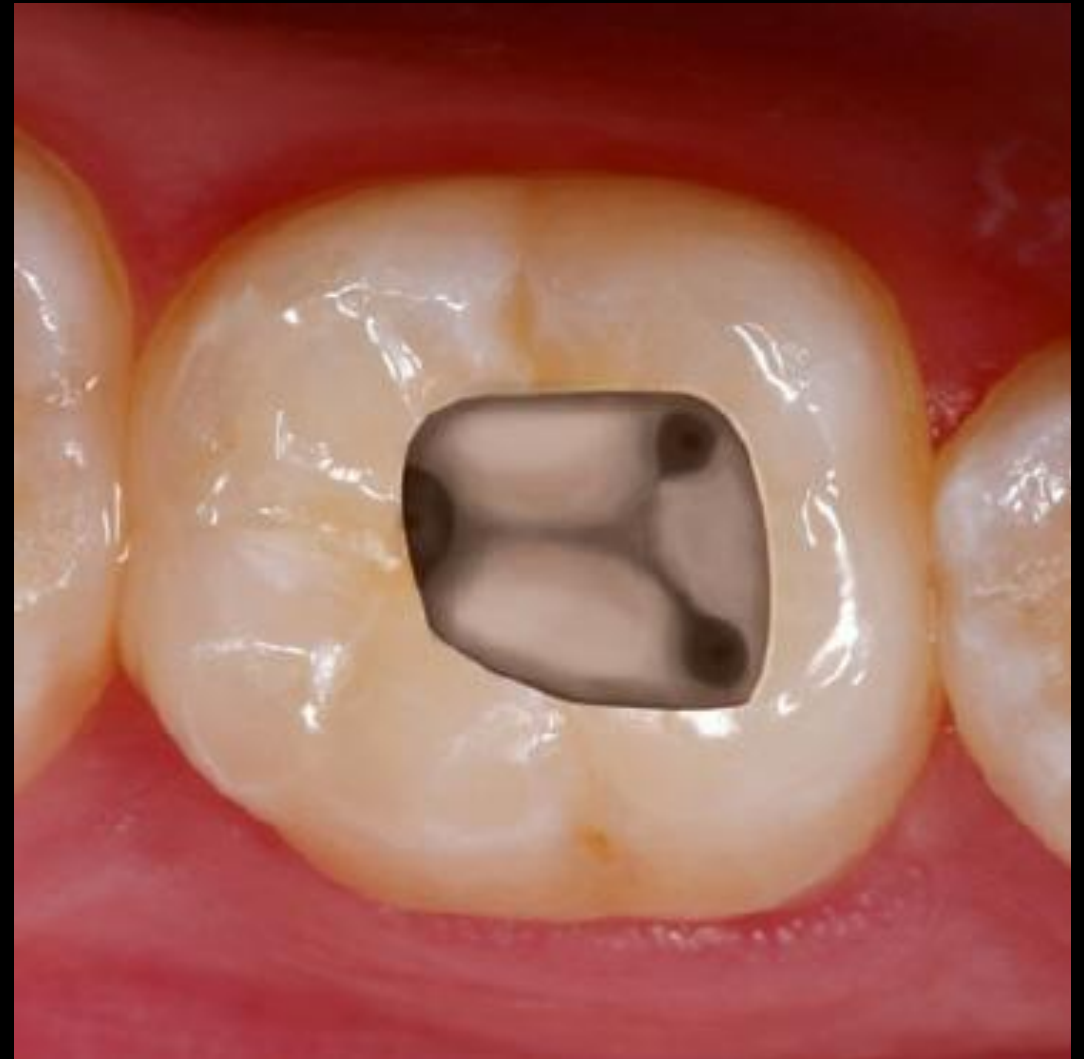

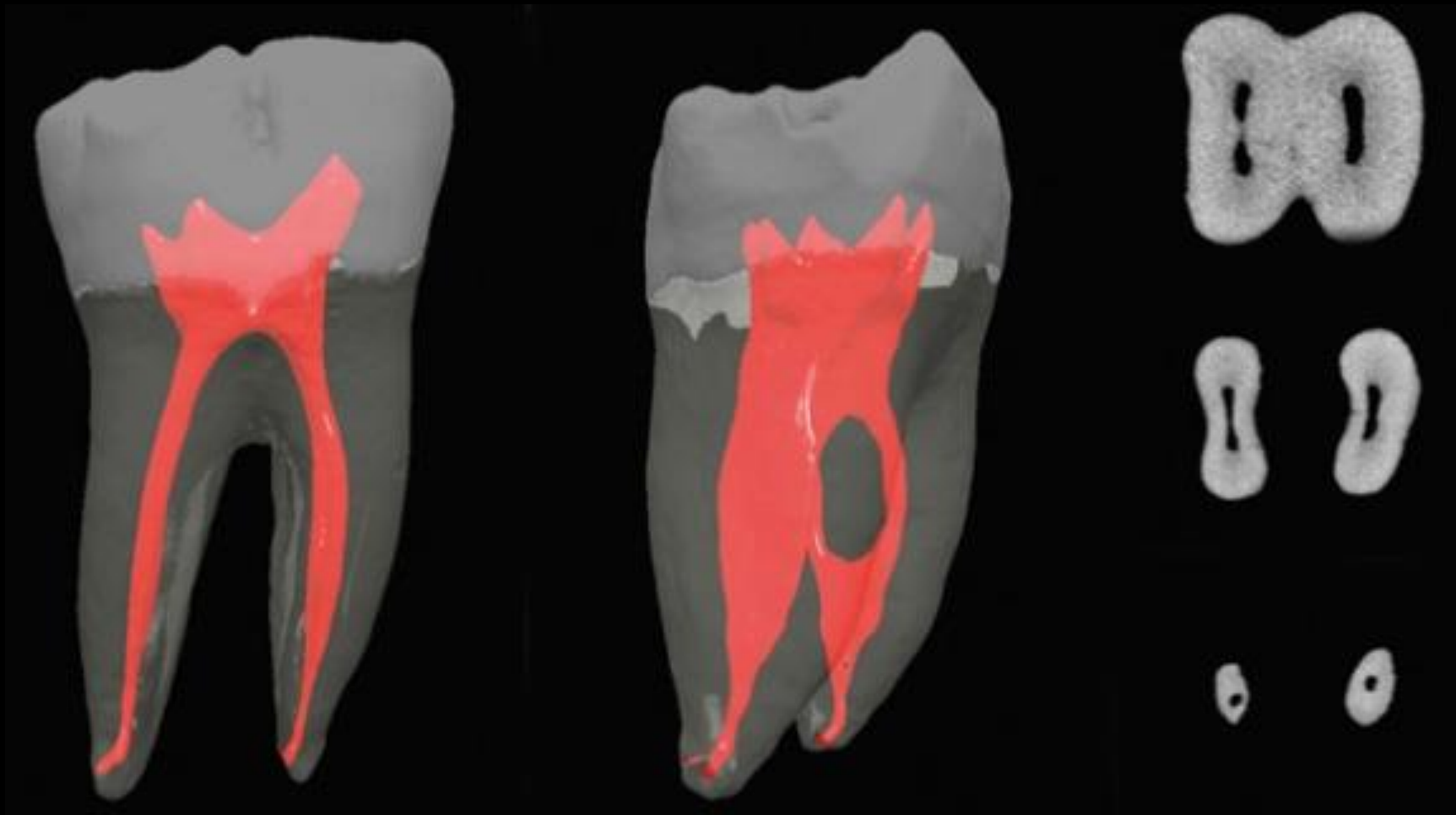
Mandibular second premolar

Length of tooth	24,5 mm
Length of crown	8,5 mm
Length of root	14 mm
Width of crown	7 mm
Width of cervical area	5 mm

Mandibular first molar

- It is often extensively restored, and it is subjected to heavy occlusal stress. Consequently, the pulp chamber frequently has receded or is calcified.
- The access cavity is typically trapezoid or rhomboid, regardless of the number of canals present.
- M root – 1rc 12%, 2rc 87%, 3rc 1%
- D root – 1rc 70%, 2rc 30%.





Tooth	No. of Teeth	Type I (1) Canals	Type II (2-1) Canals	Type III (1-2-1) Canals	Total With One Canal at Apex	Type IV (2) Canals	Type V (1-2) Canals	Type VI (2-1-2) Canals	Type VII (1-2-1-2) Canals	Total With Two Canals at Apex	Type VIII (3) Canals	Total With Three Canals at Apex
Mandibular first molar												
Mesial	100	12	28	0	40	43	8	10	0	59	1	1
Distal	100	70	15	0	85	5	8	2	0	15	0	0



Type I



Type II



Type III



Type IV



Type V



Type VI



Type VII

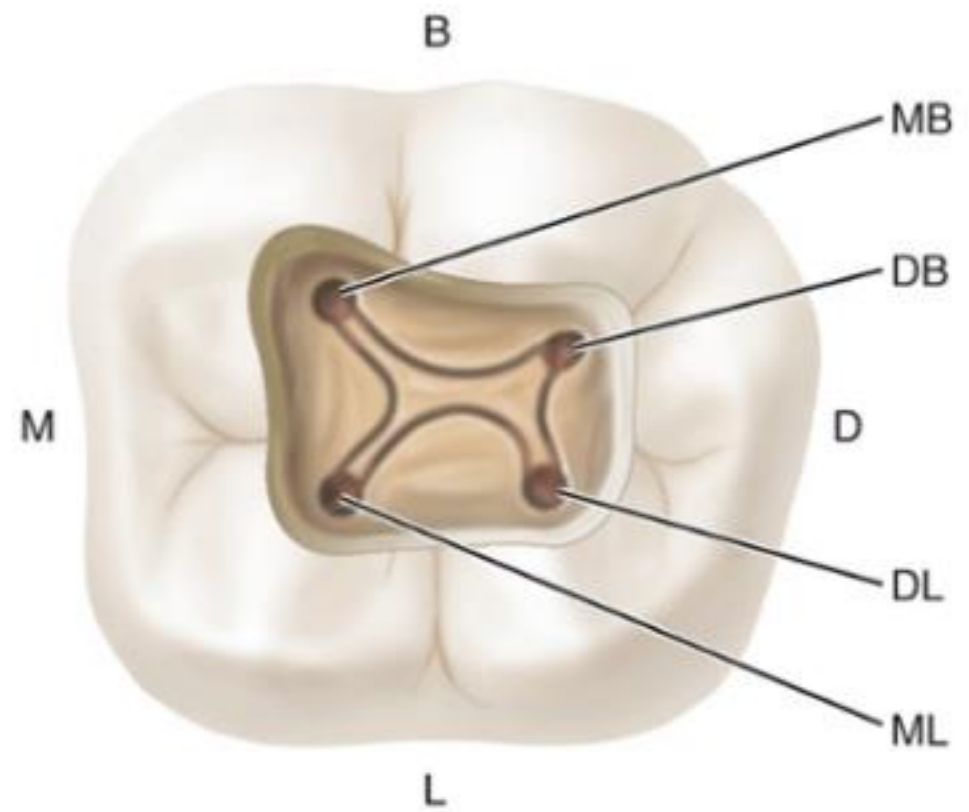
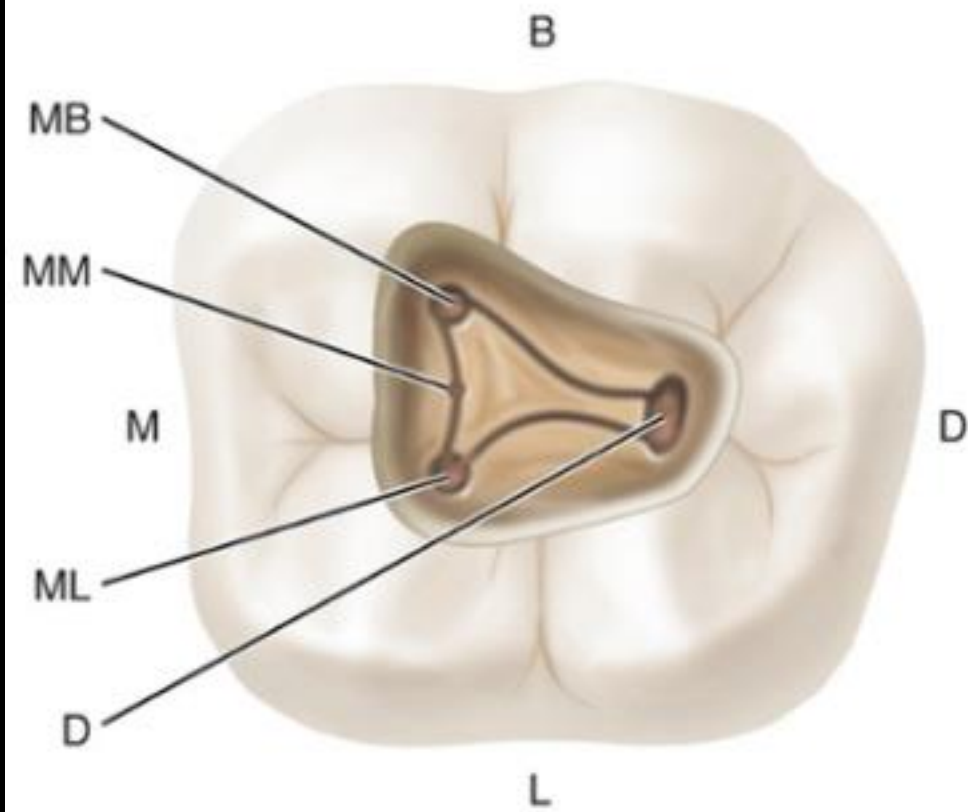


Type VIII

A One canal at apex

B Two canals at apex

C Three canals at apex

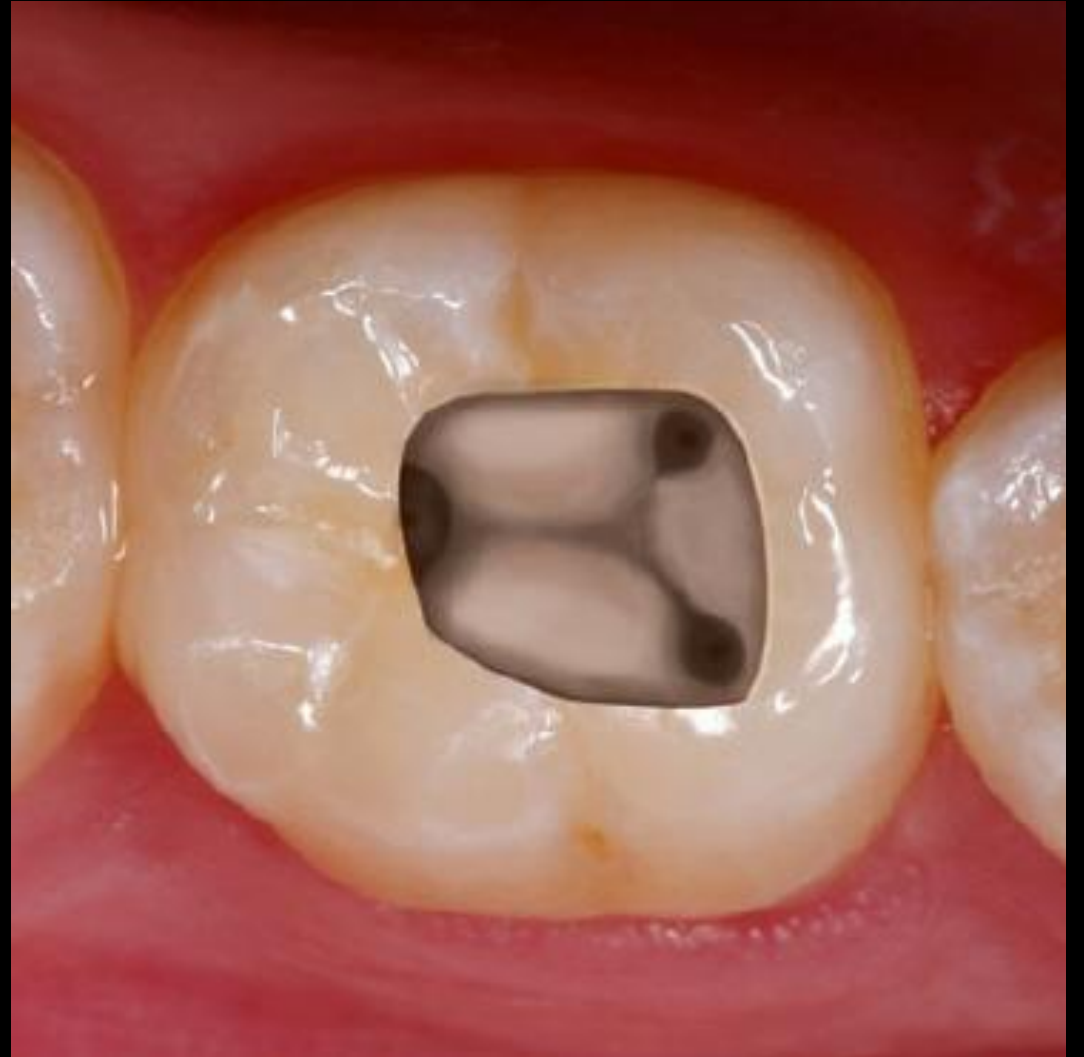

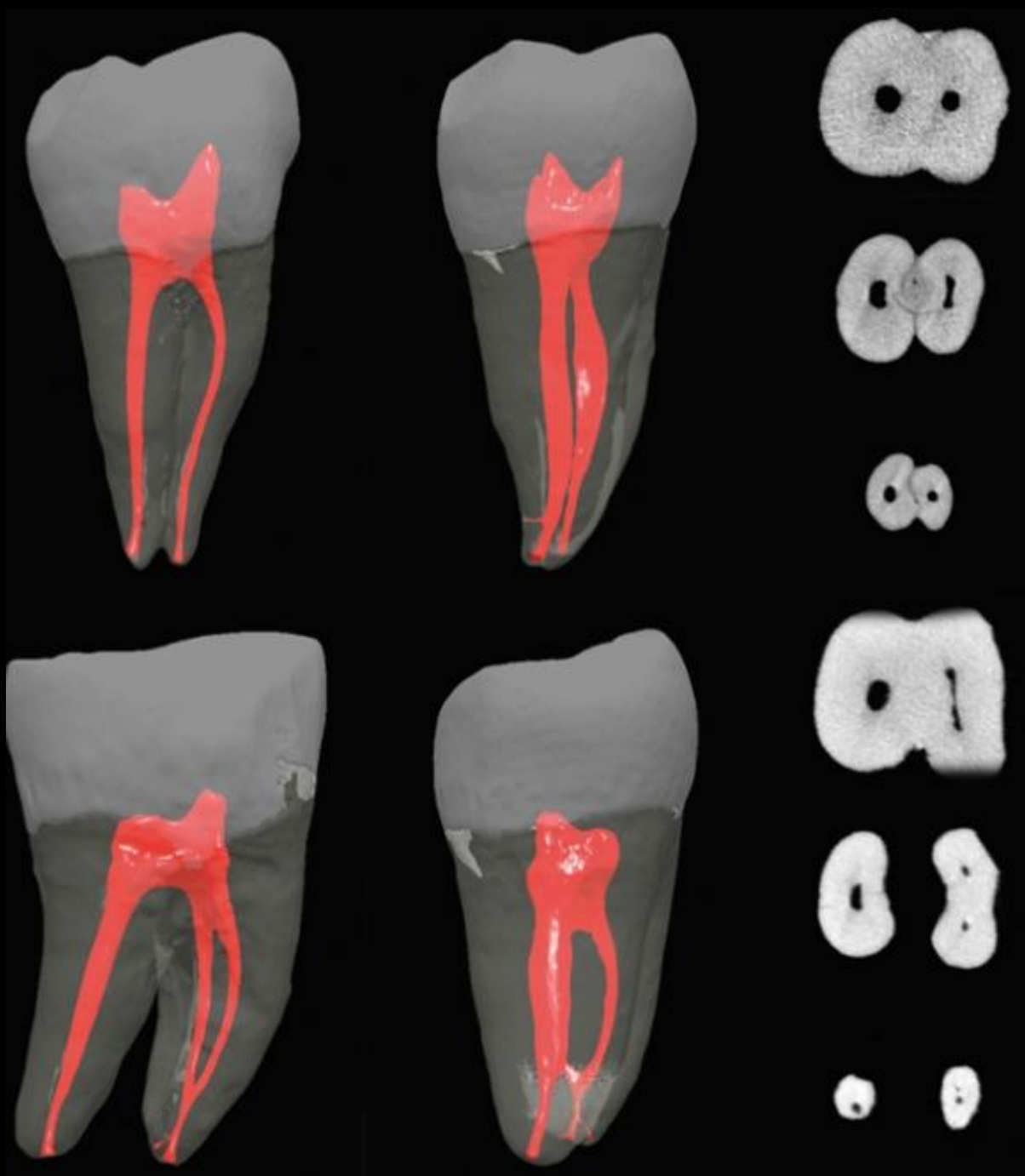
Mandibular first molar

Length of tooth	21,5mm
Length of crown	7,5mm
Length of root	14mm
Width of crown	11mm
Width of cervical area	9mm

Mandibular second molar

- The access cavity is typically trapezoid or rhomboid.
- M root – 1kk 27%, 2kk 73%.
- D root – 1kk 92%, 2kk 8%.





Tooth	No. of Teeth	Type I (1) Canals	Type II (2-1) Canals	Type III (1-2-1) Canals	Total With One Canal at Apex	Type IV (2) Canals	Type V (1-2) Canals	Type VI (2-1-2) Canals	Type VII (1-2-1-2) Canals	Total With Two Canals at Apex	Type VIII (3) Canals	Total With Three Canals at Apex
Mandibular second molar												
Mesial	100	27	38	0	65	26	9	0	0	35	0	0
Distal	100	92	3	0	95	4	1	0	0	5	0	0



Type I



Type II



Type III



Type IV



Type V



Type VI



Type VII



Type VIII

A One canal at apex

B Two canals at apex

C Three canals at apex

Mandibular second molar

Length of tooth	20mm
Length of crown	7mm
Length of root	13mm
Width of crown	10mm
Width of cervical area	8mm

Literature sources

- Cohen Pathways of the Pulp - 10th edition
- Cohen Pathways of the Pulp - 11th edition
- Laser in endodontics