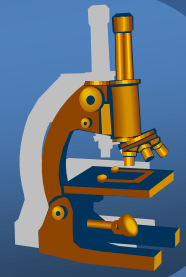
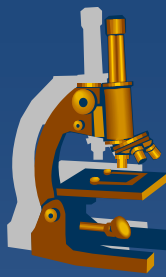


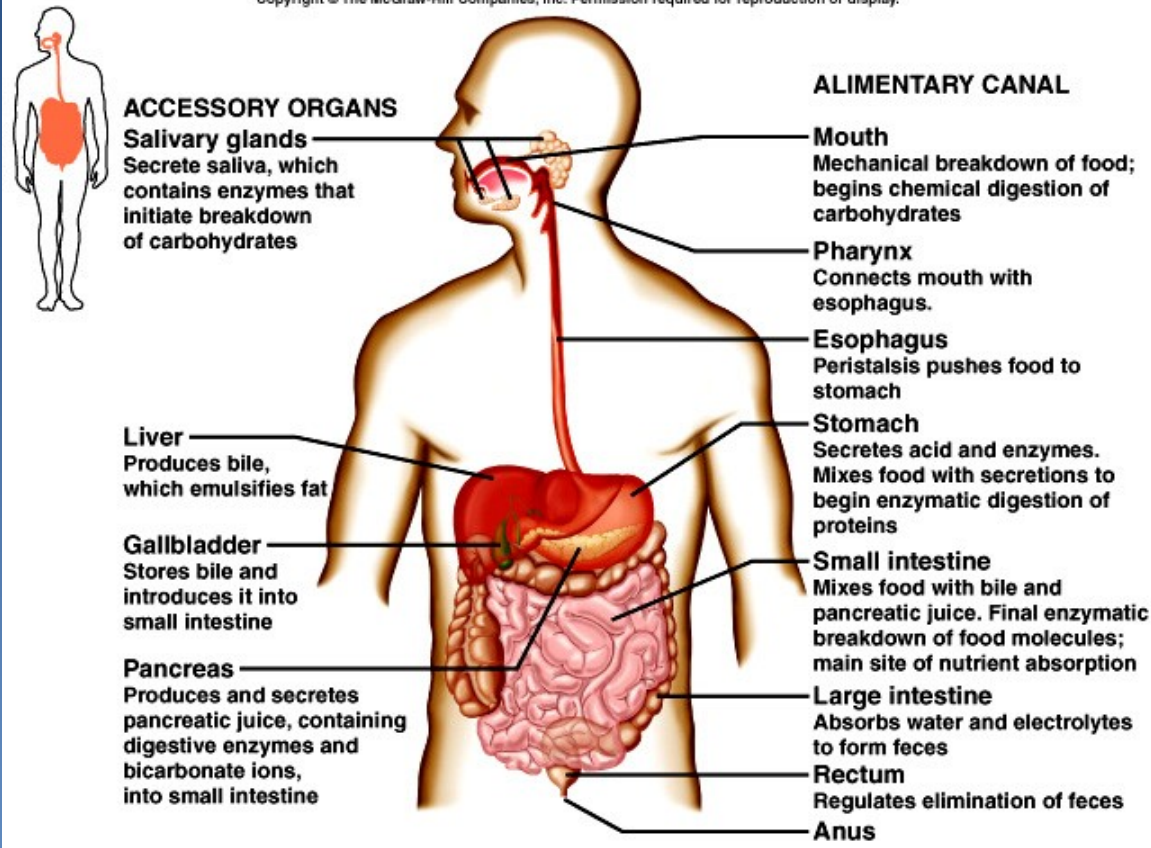
***Systematic pathology
practice***

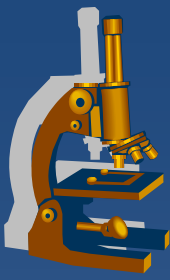


GIT PATHOLOGY



Copyright © The McGraw-Hill Companies, Inc. Permission required for reproduction or display.





ORAL CAVITY

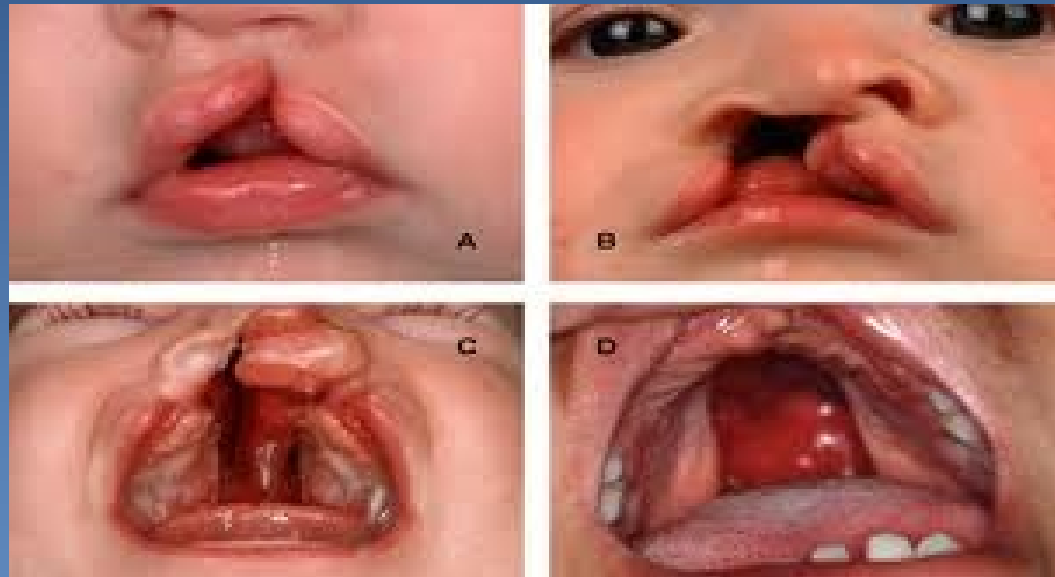Congenital disorders: hare-lip and cleft palate



- ✗ incidence 1 : 950 newborns
- ✗ lateral cleft – isolated or complete
 - ⇒ *fusion defect* of the first branchial arch –maxilar process with fronto-nasal lateral process
 - genetic x acquired (environmental)
 - unilateral x bilateral

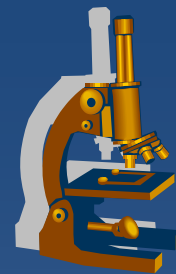
 - ⇒ *cheiloschisis (upper lip) – complete/incomplete*
 - ⇒ *gnathoschisis (jaw)*
 - ⇒ *palatoschisis (hard palate)*
 - ⇒ *uranoschisis (soft palate)*
 - ⇒ *staphyloschisis (uvula)*
- ✗ medial, oblique, transverse cleft (rare)

Cheilognathopalatoschisis

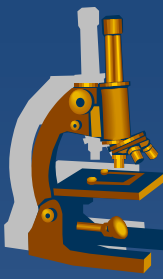


copy

Salivary glands

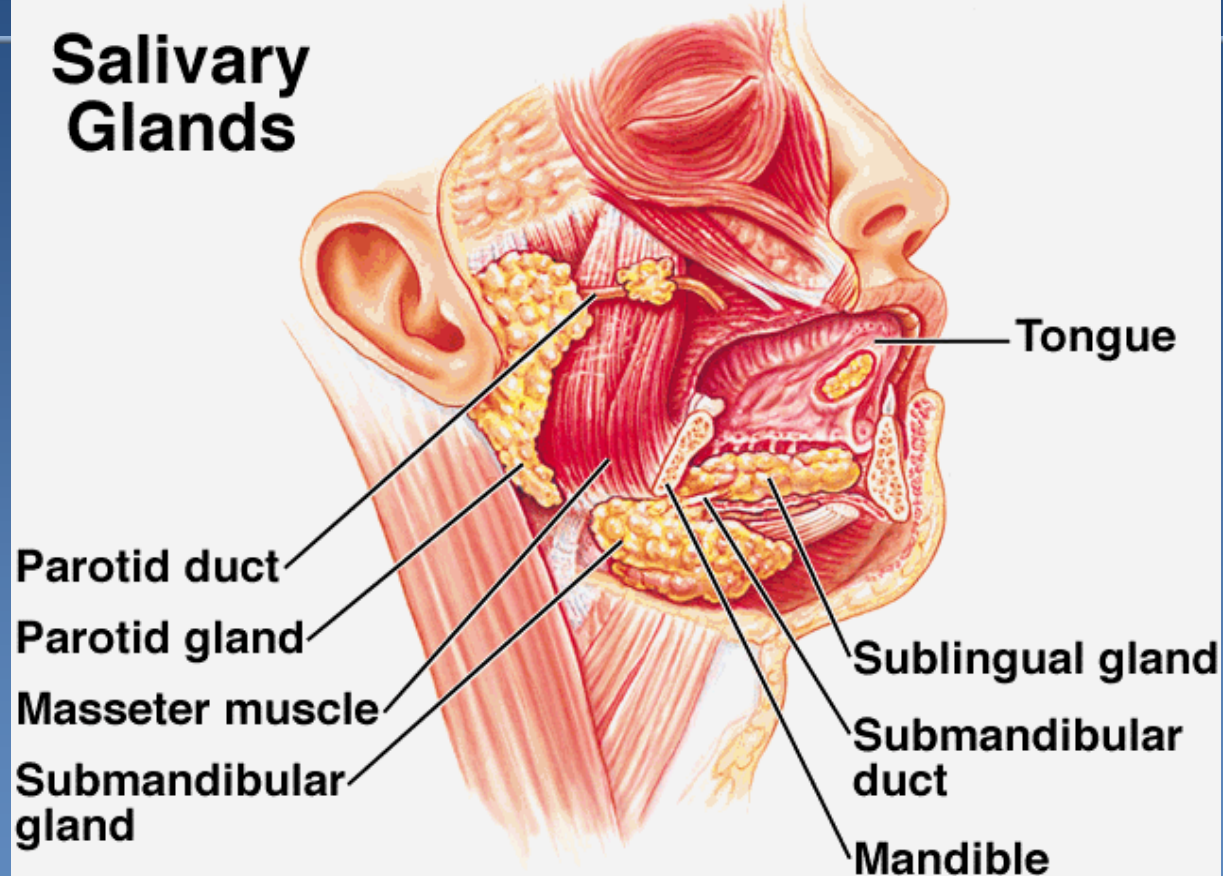


- x 3 pairs of large major salivary glands, numerous small ones
- x serous / mucinous
- x secretory units → glandular ducts
- x double cell layer – external myoepithelia
- x tumors mostly in the parotid gland, in adults usually epithelial tumors

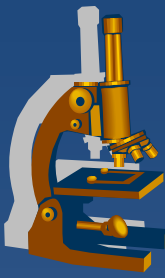


Copyright © The McGraw-Hill Companies, Inc. Permission required for reproduction or display.

Salivary Glands



Salivary gland tumors



- x** parotid

 - ⇒ *cca 75%, mostly benign (70-85%)*

- x** submandibular

 - ⇒ *40% malignant*

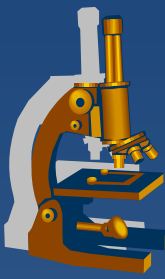
- x** minor salivary glands

 - ⇒ *50% malignant*

- x** sublingual

 - ⇒ *mostly malignant*

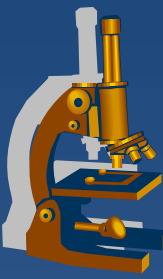
Histologic types



Selected types

- x pleomorphic adenoma (benign mixed tumor)
- x adenolymphoma (Warthin tumor)
- x oncocytoma
- x mucoepidermoid carcinoma
- x adenoid cystic carcinoma
- x malignant mixed tumor

Pleomorphic adenoma (mixed tumor of salivary glands)



- ✘ former name „myxochondroepithelioma“
- ✘ benign epithelial tumor
- ✘ 80% in the parotid gland, most common parotid tu
- ✘ any age, mostly middle-late adult age
- ✘ slow-growing firm mass
- ✘ well-demarcated, but capsule incomplete
- ✘ frequent recurrences after incomplete resection
- ✘ low risk of malignant transformation (4%), in long duration, recurrences

Pleomorphic adenoma



x micro:

⇒ *histologic diversity*

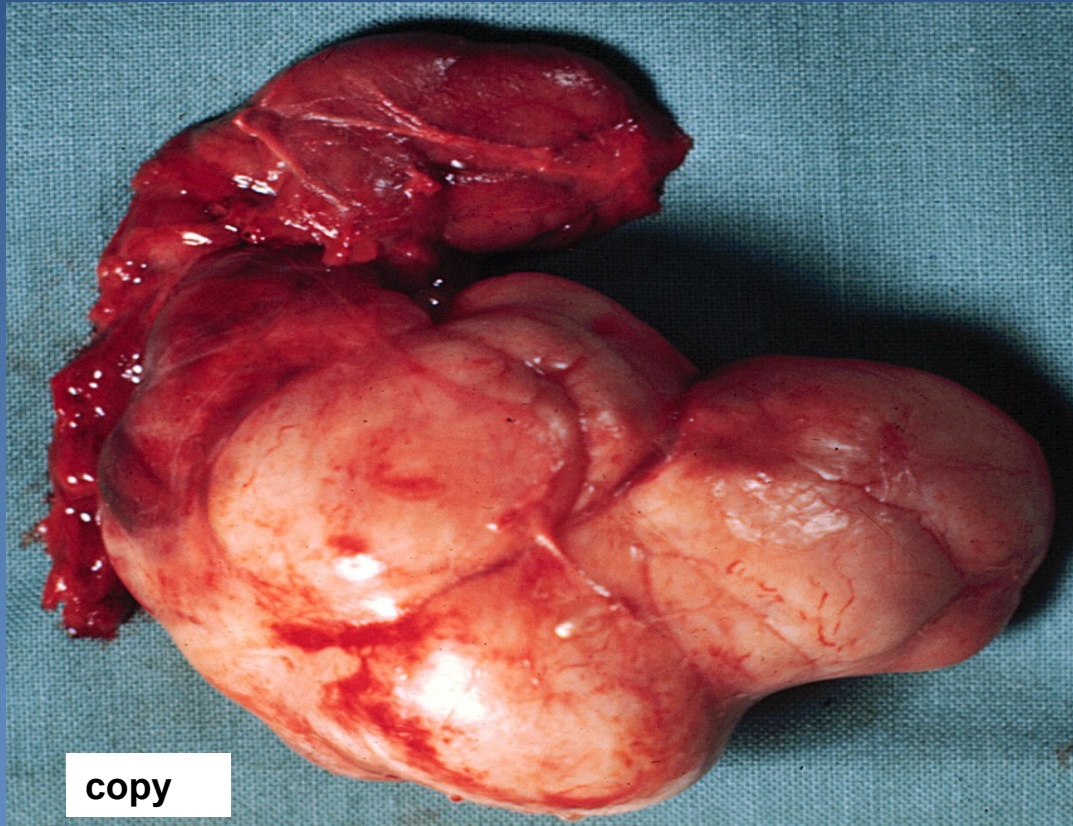
⇒ *ductal and myoepithelial tumor cells*

⇒ *epithelial elements in strands or sheets*

⇒ *myxoid to chondroid stroma produced by myoepithelia*

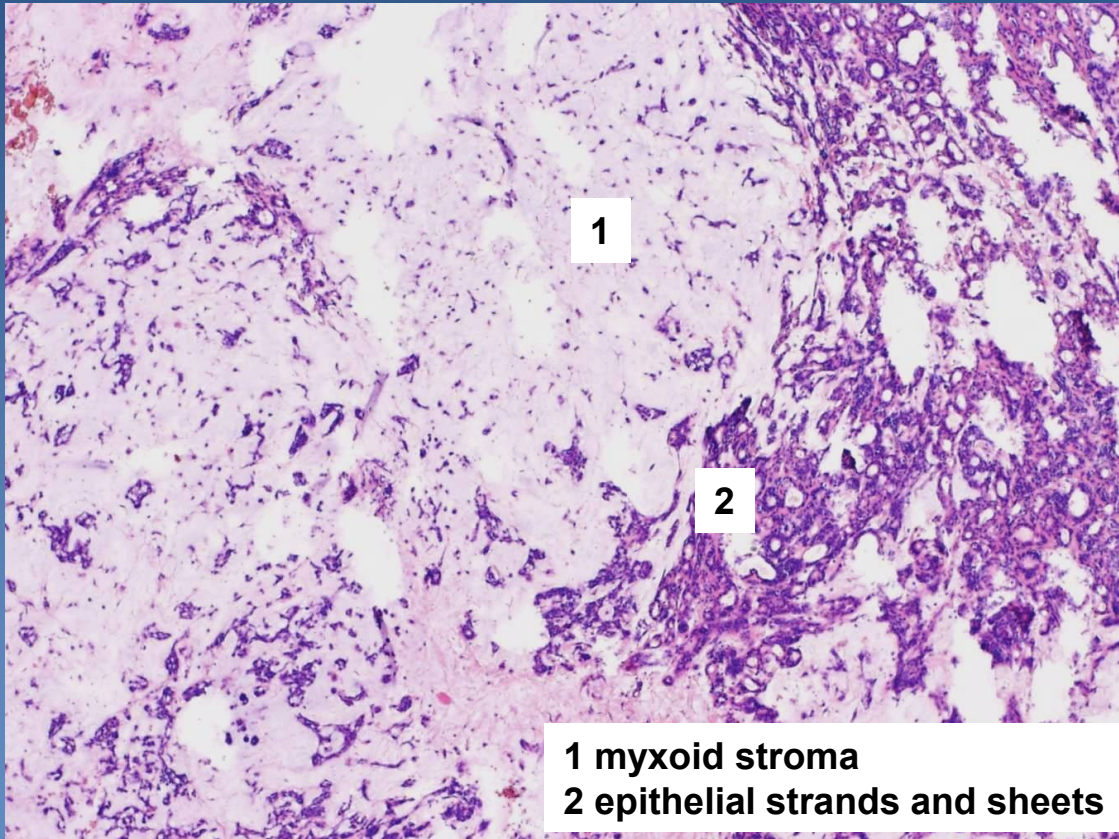
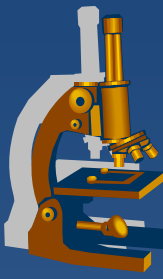
⇒ *often penetrates the capsule → protuberances*

Pleomorphic adenoma



copy

Pleomorphic adenoma

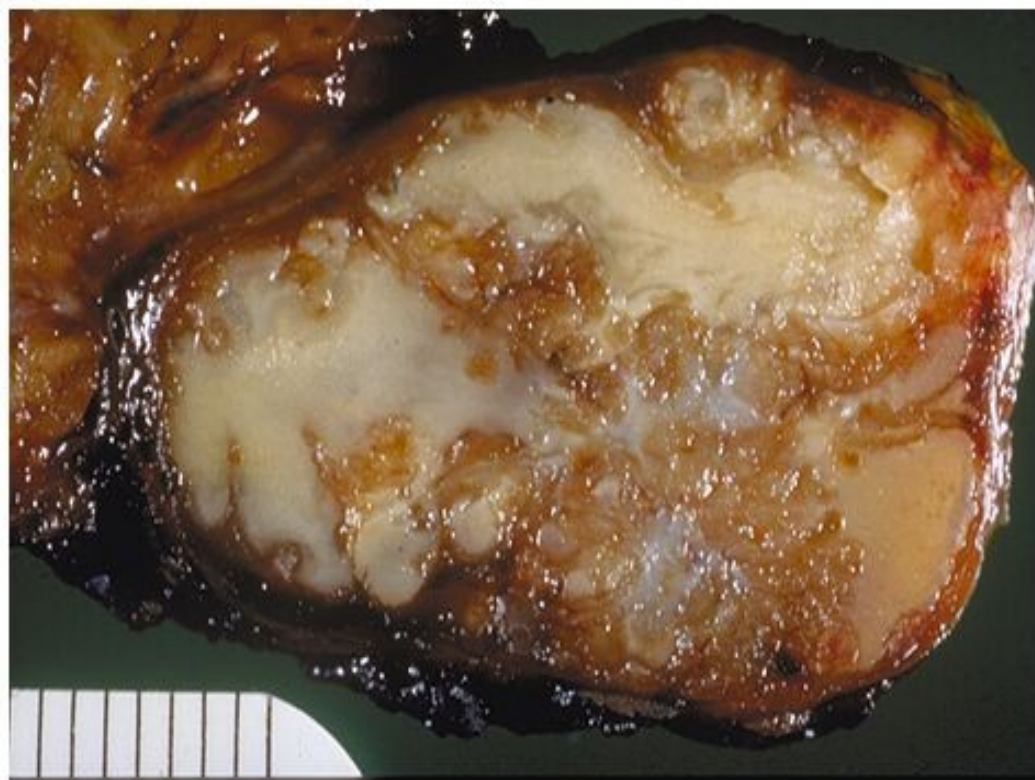
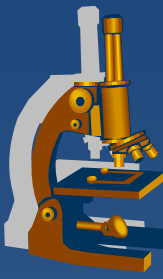


Warthin's tumor (cystadenolymphoma)



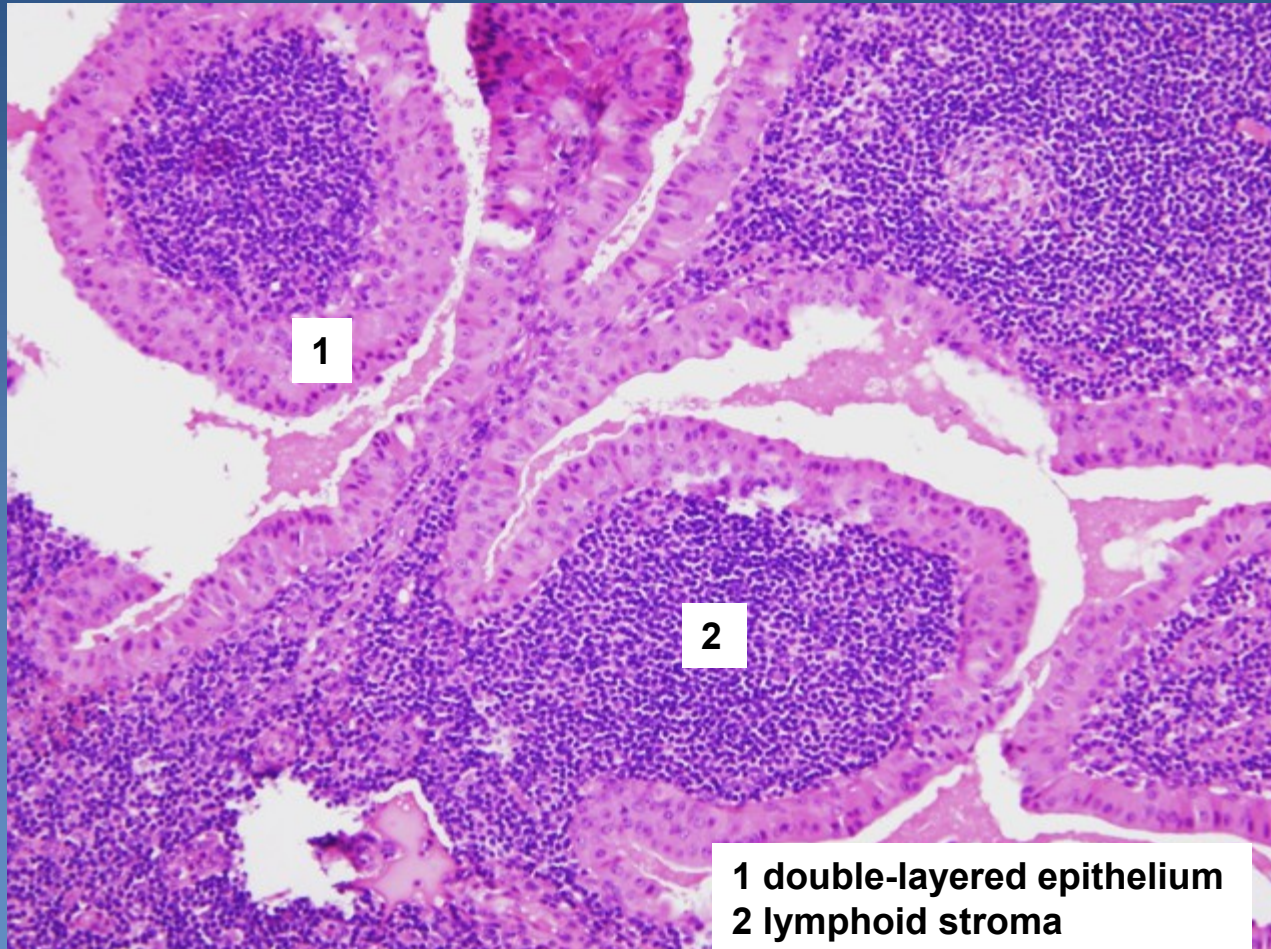
- × 5-10% of total salivary gland tumors, benign
- × M > F, 6th-7th decade
- × lower pole of the parotid gland
- × low recurrence rate, malignant transformation (ca, malignant lymphoma) highly uncommon
- × risk factors:
 - ⇒ *smoking (8x), radiation, EBV*
- × origin? (heterotopic salivary tissue in a LN; reactive epithelial proliferation + lymphocytic infiltration)
- × histology:
 - ⇒ *cystic or cleftlike spaces with double-layered epithelial lining, dense lymphoid stroma (usually + germinal centers)*

Warthin's tumor (cystadenolymphoma)



Copyright © 2002, Elsevier Science (USA). All rights reserved.

Warthin's tumor (cystadenolymphoma)



Tonsillitis chronica



- ✗ recurrent chronic inflammation
- ✗ acute exacerbations - enlarged, red, swollen painful tonsils
- ✗ gross:
 - ⇒ *mostly purulent exudate with necrotic epithelial cells and bacteria in crypts forming semi-firm foul-smelling debris*
 - ⇒ *pseudomembranous tonsillitis (diff. dg. x EBV)*

Tonsillitis chronica



× complications: local, distant

⇒ *phlegmonous acute tonsillitis (necrosis and ulceration, penetration of bacteria into the interstitium → inflammation may progress into retrotonsillar stroma)*

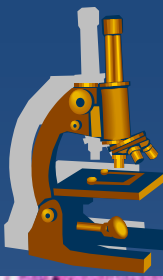
⇒ *abscessi (tonsillar, peritonsillar, retropharyngeal) + spread*

⇒ *distant – rheumatic fever, glomerulonephritis*

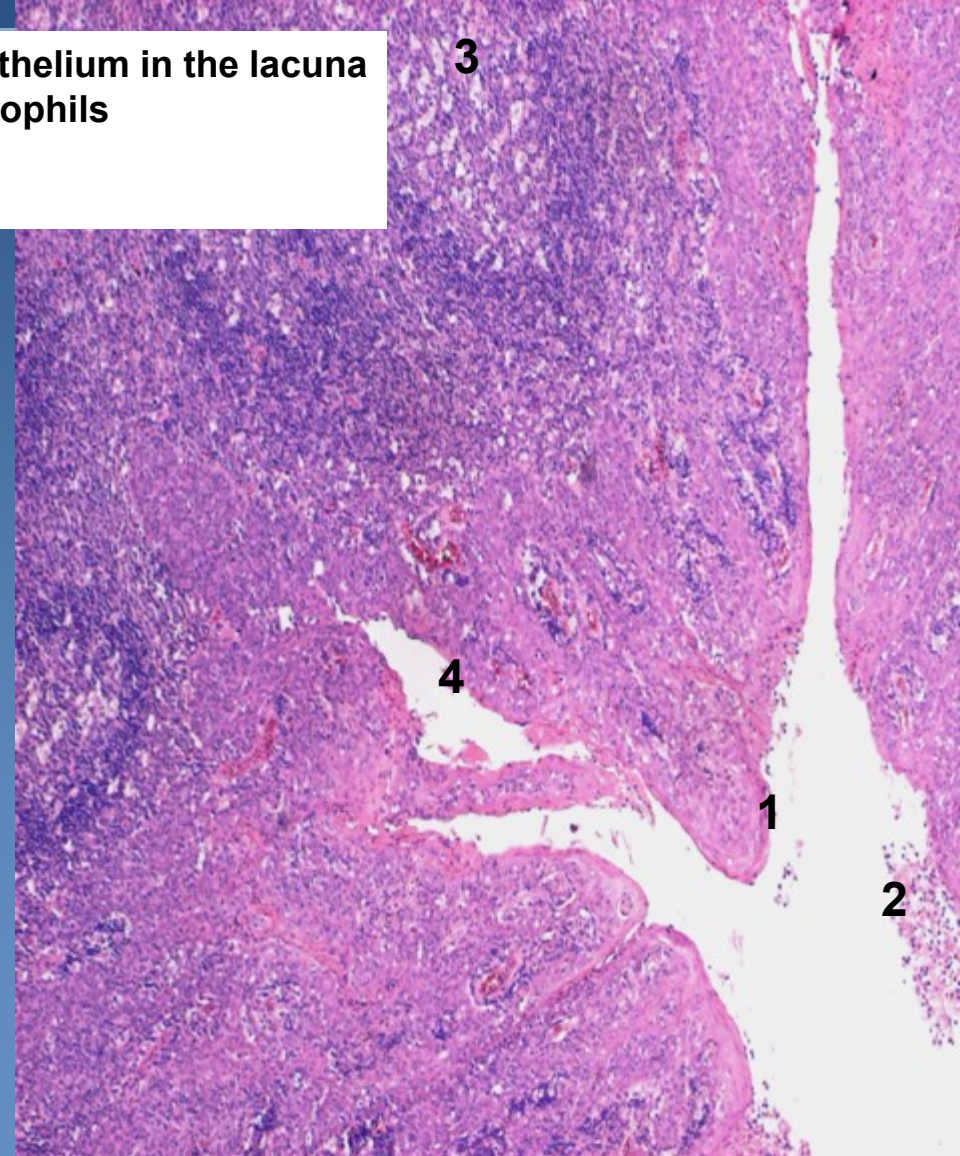
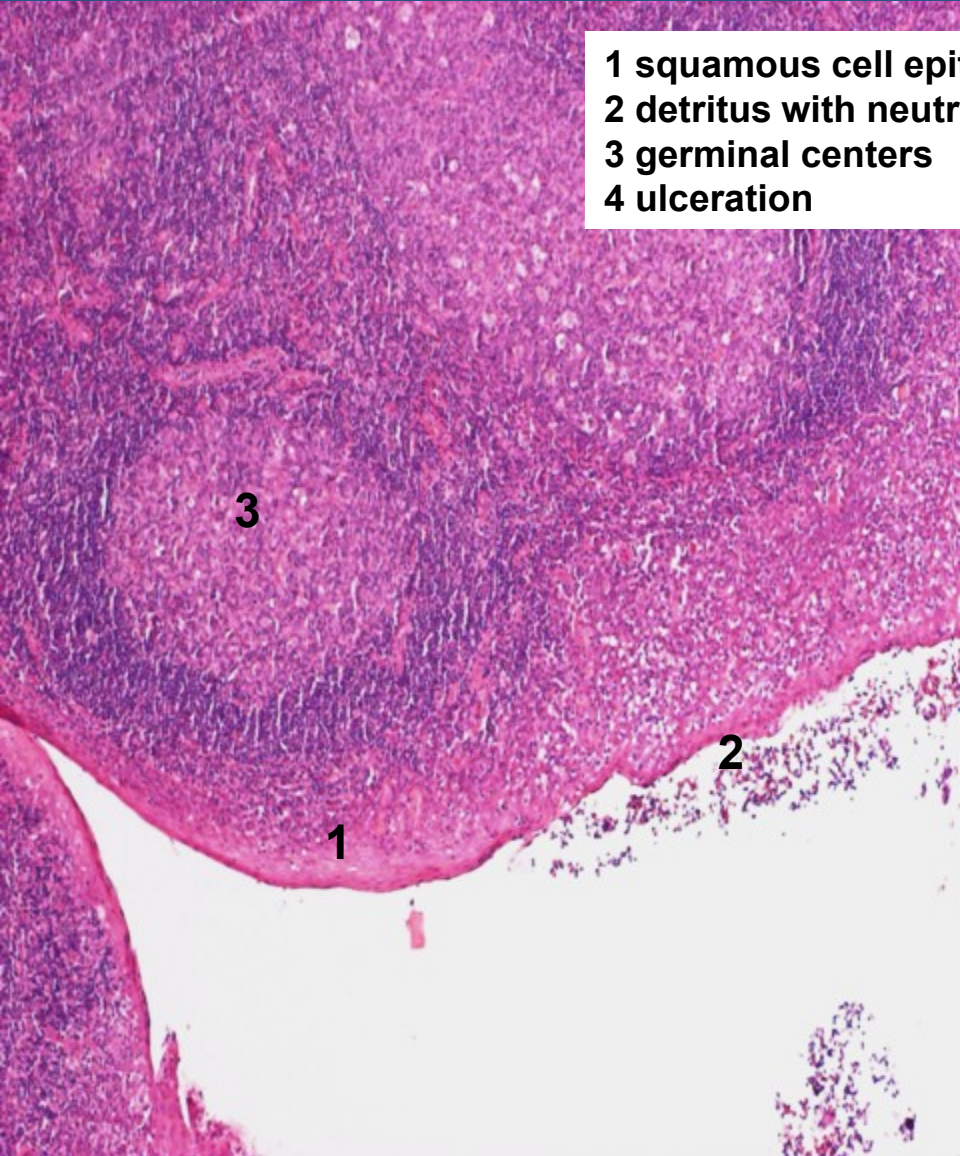
× micro:

⇒ *reactive hyperplasia of lymphoid tissue, lacunae filled with neutrophils, debris and bacteria, local fibrotisation*

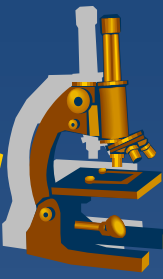Tonsilla palatina ***chronic purulent inflammation***



- 1 squamous cell epithelium in the lacuna
- 2 detritus with neutrophils
- 3 germinal centers
- 4 ulceration



Precanceroses and tumors



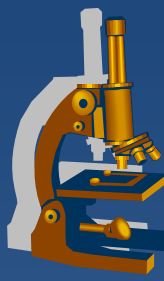
- ✗ mostly epithelial, less commonly mesenchymal lesions

- ✗ sequence

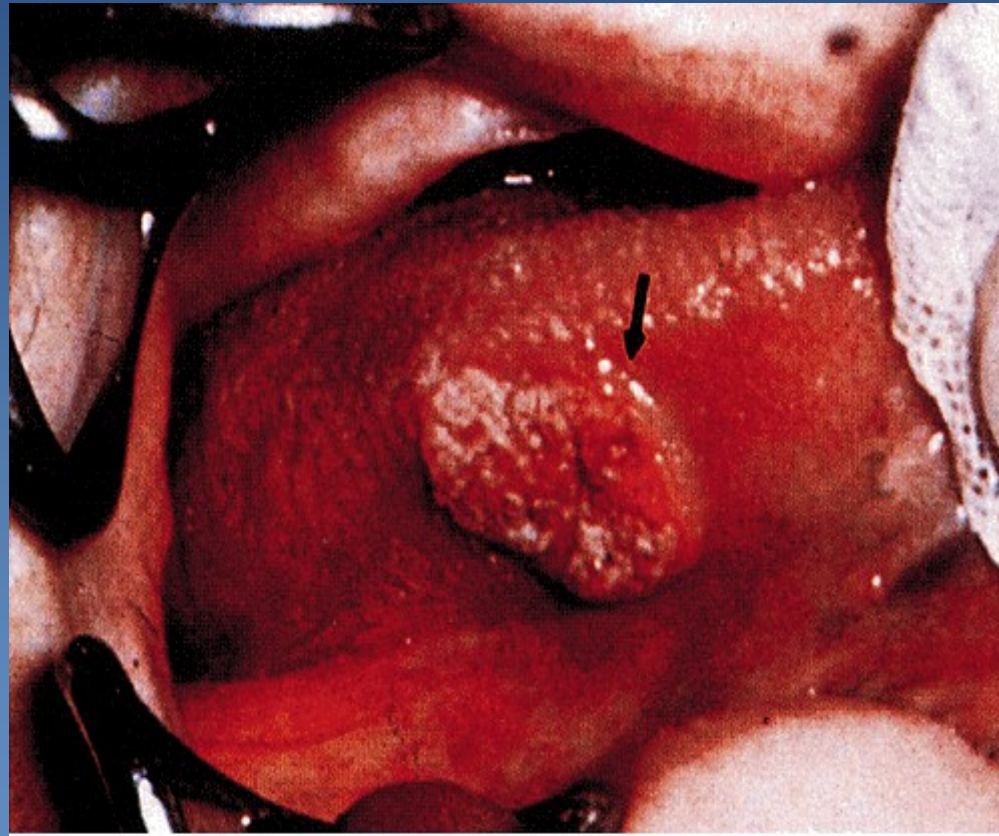
 - ⇒ *normal tissue – hyperplasia – dysplasia – CIS – invasive carcinoma*

- ✗ risk factors

 - ⇒ *smoking, alcohol, their combination; irradiation, HPV, betel, other chronic irritation*



Squamous cell carcinoma



elevated/ulcerated firm lesion

Esophageal diverticula



- × **diverticulum** – an acquired outpouching of the esophageal wall involving all the layers of the wall (true diverticulum)
- × Zenker's diverticulum (pharyngoesophageal) - *most common type, located on the posterior wall in the pharyngoesophageal junction, weakening of m. constrictor pharyngis, developed by pulsion (forcible distension of the esophagus) → pulsion diverticulum*
- × Midthoracic diverticulum - *in the mid-chest; developed by traction (external forces pulling on the wall - inflammation with scarring e.g.) → traction diverticulum*
- × Epiphrenic diverticula - *above the diaphragm*
- × Signs: *dysphagia, regurgitation, foetor ex ore*
- × Complications: *putrid inflammation, ulceration, perforation into mediastinum*

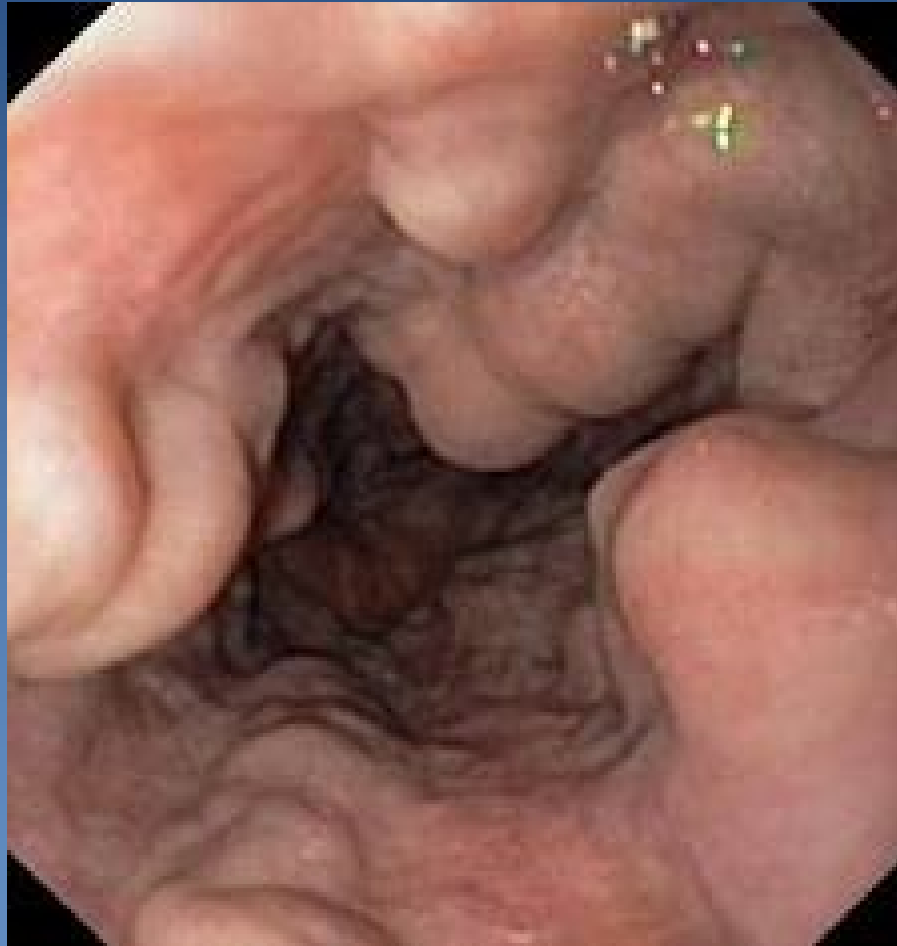Esophageal varices



- x congested and dilated submucosal veins in the distal third of the esophagus
- x in portal hypertension
- x porto-caval anastomoses
- x complications - *rupture with massive hemorrhage into the lumen, haematemesis, haemorrhagic shock*

Esophageal varices

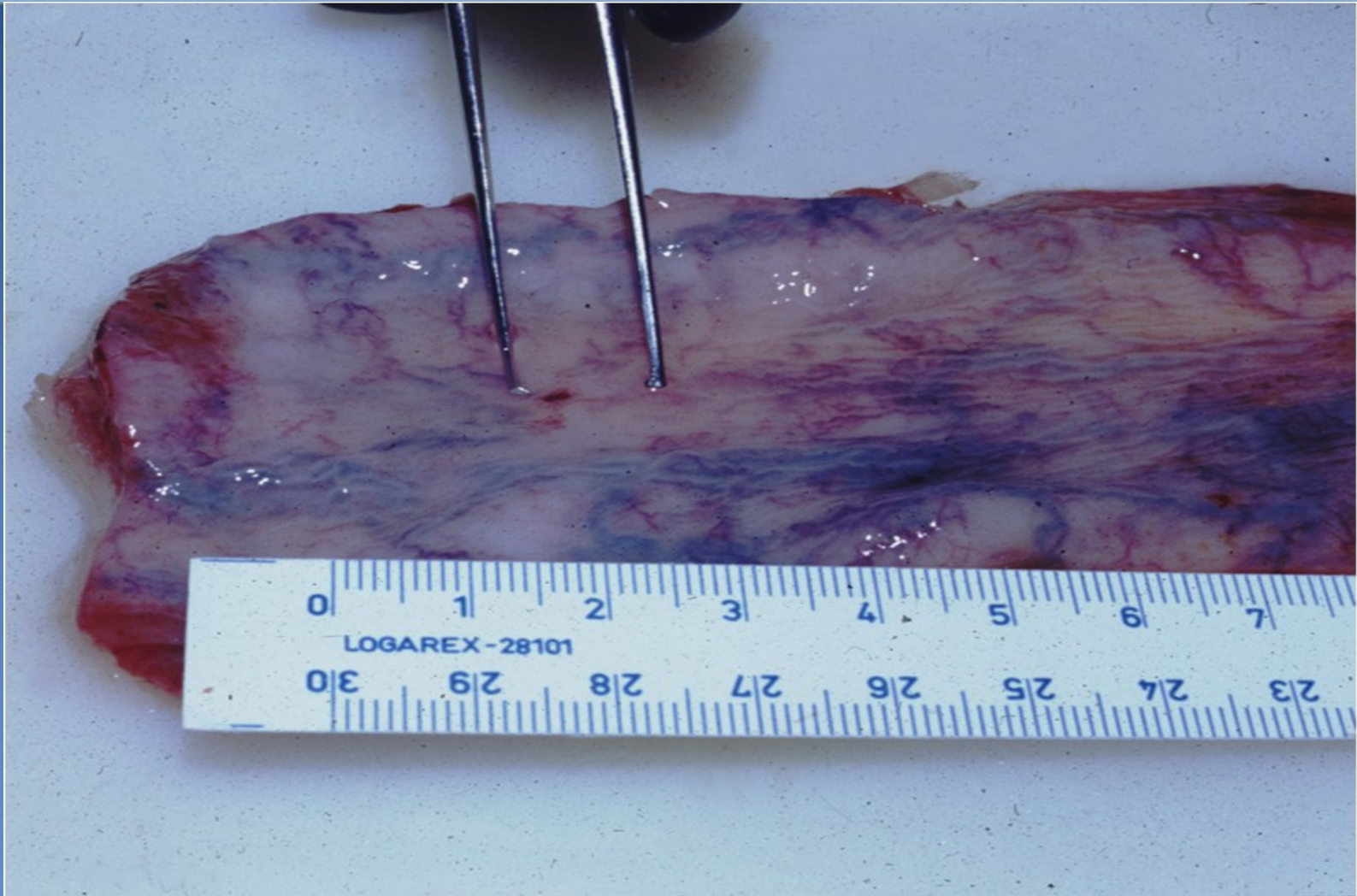
- endoscopy



copy

Esophageal varices

gross



Mycotic oesophagitis



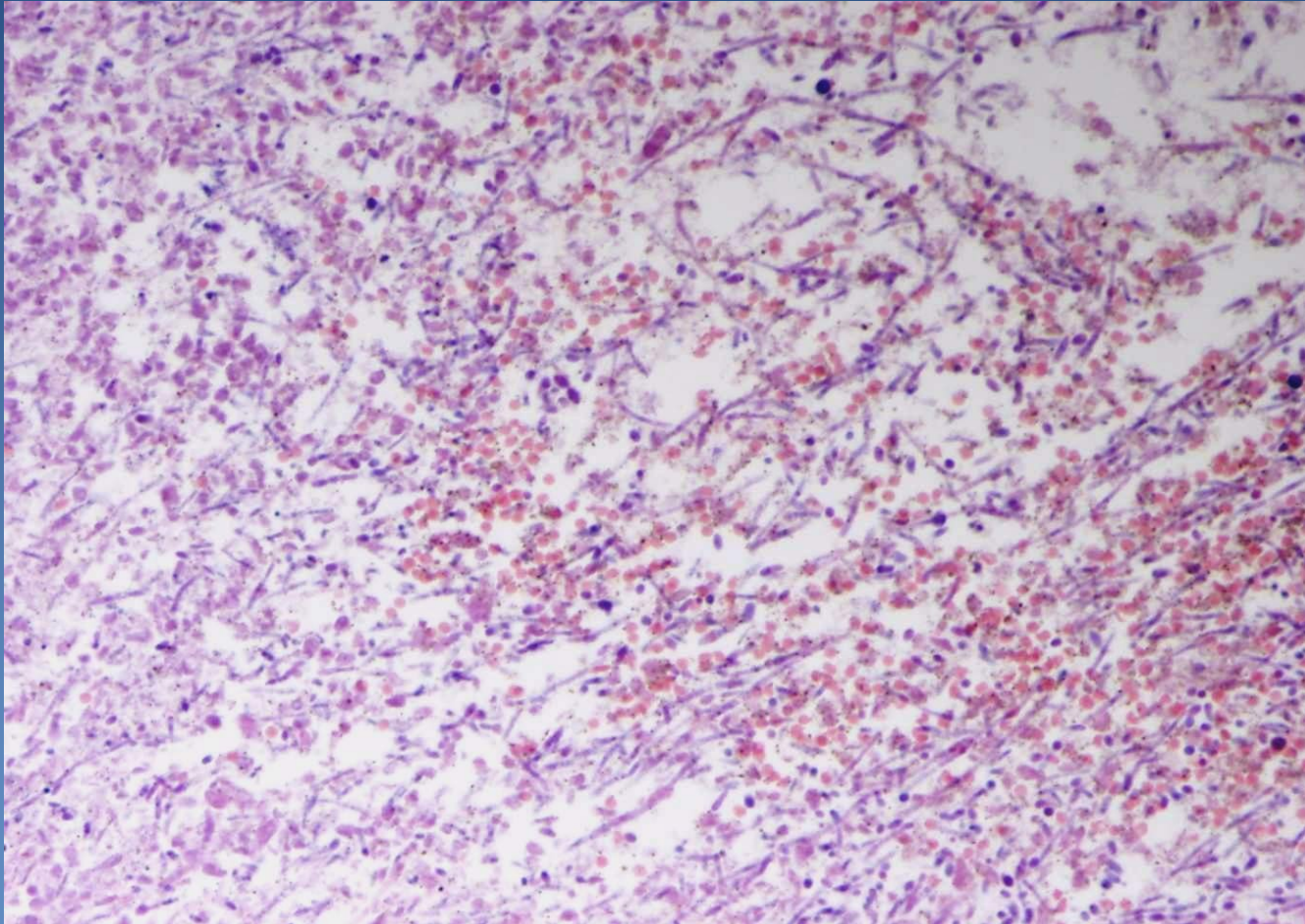
- x candida, aspergillus, mucor, cryptococcus**
- x superficial form** *low-level immunodeficiency, patients on broad-spectrum ATB or corticosteroids therapy, diabetics, pregnancy...*
- x generalised form + secondary deep mycotic infections** – *high-grade immunodeficiency - AIDS, neoplasia (haemathologic), immunosuppression, debilitated patients*

Mycotic oesophagitis

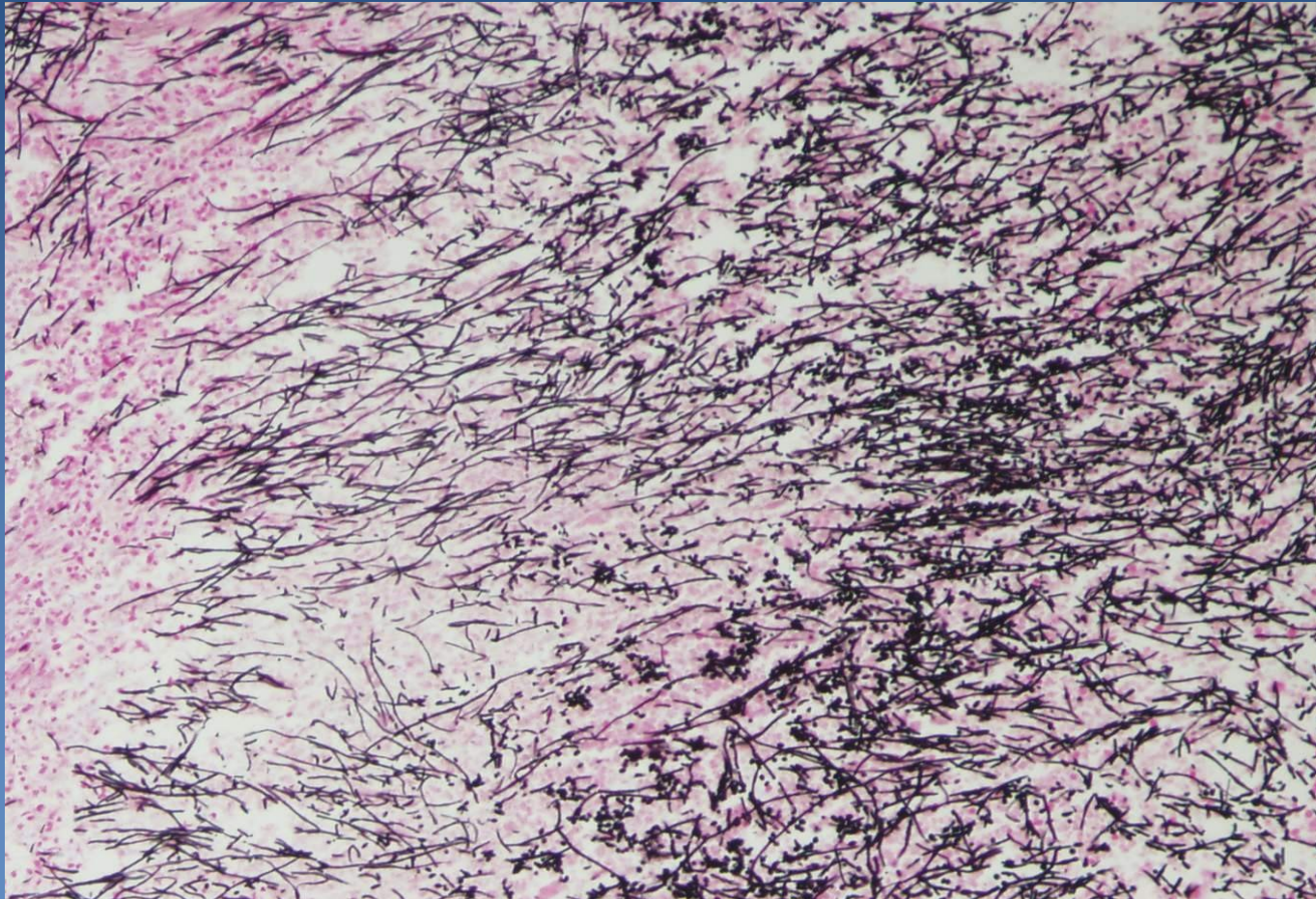


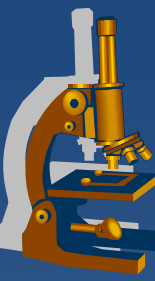
- ✗ gross:
 - ⇒ *white to gray pseudomembranes with hemorrhagic bases after removal*
- ✗ micro:
 - ⇒ *necrotic mucosa with mixed inflammatory infiltrate, numerous fungal organisms (pseudo/hyphae, yeasts)*
- ✗ special impregnation/staining for detection of the fungi (Grocott, PAS, Giemsa)

Mycotic oesophagitis

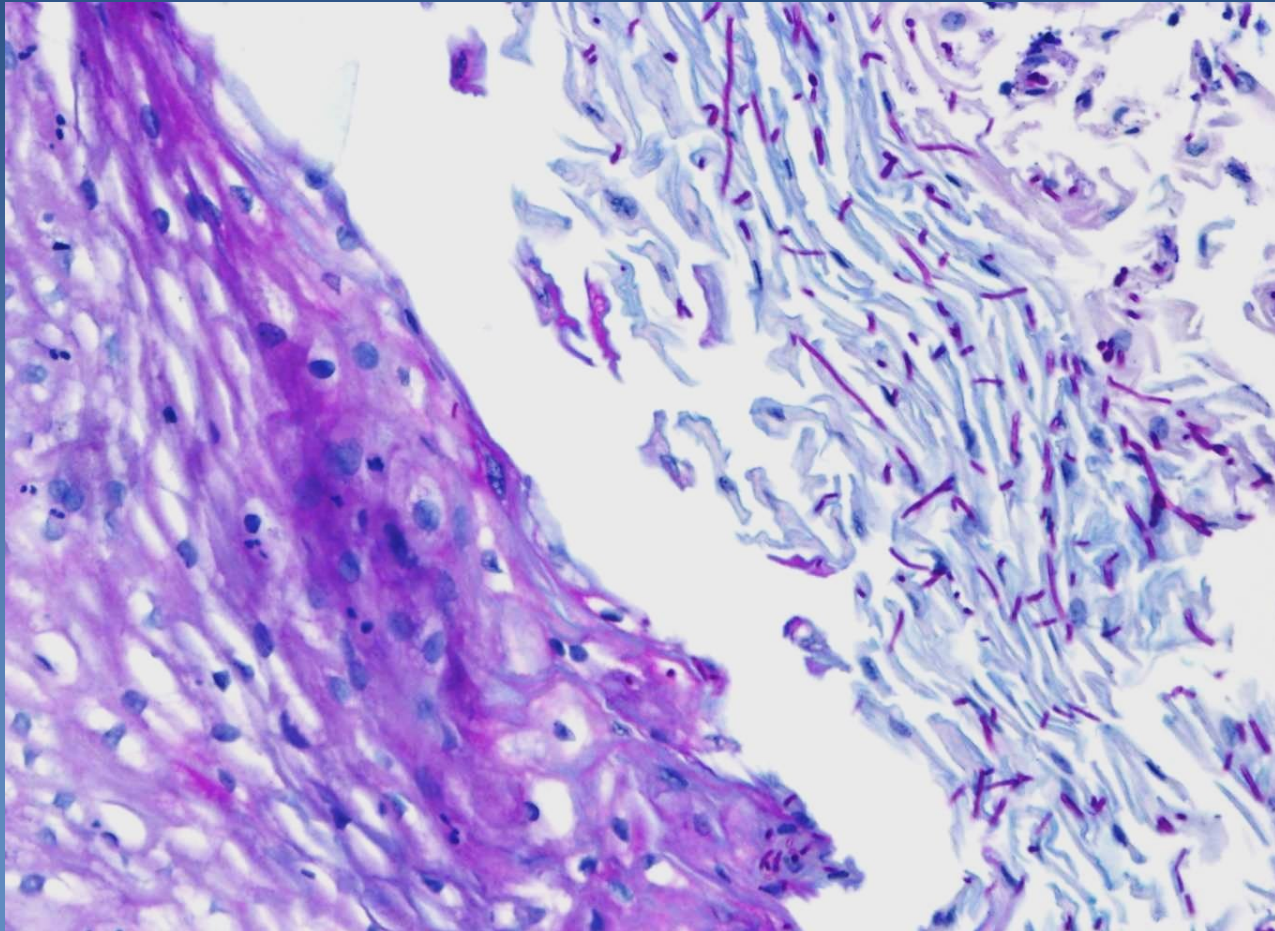


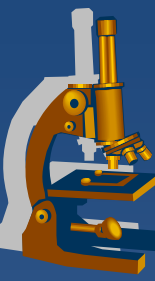
Mycotic oesophagitis ***(Groccott silver impregnation)***



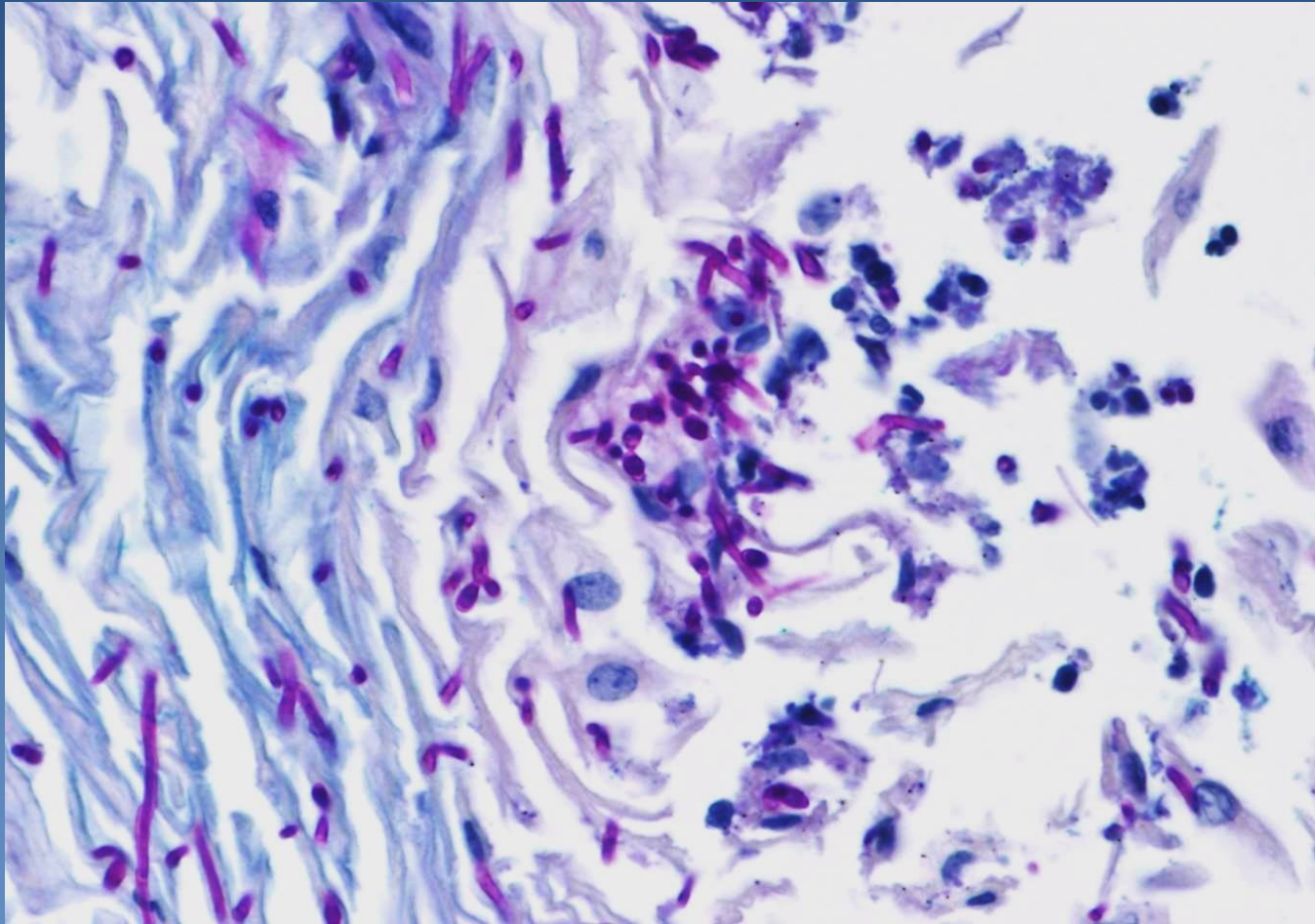


Mycotic oesophagitis - detail ***(PAS staining)***





Mycotic oesophagitis - detail ***(PAS staining)***

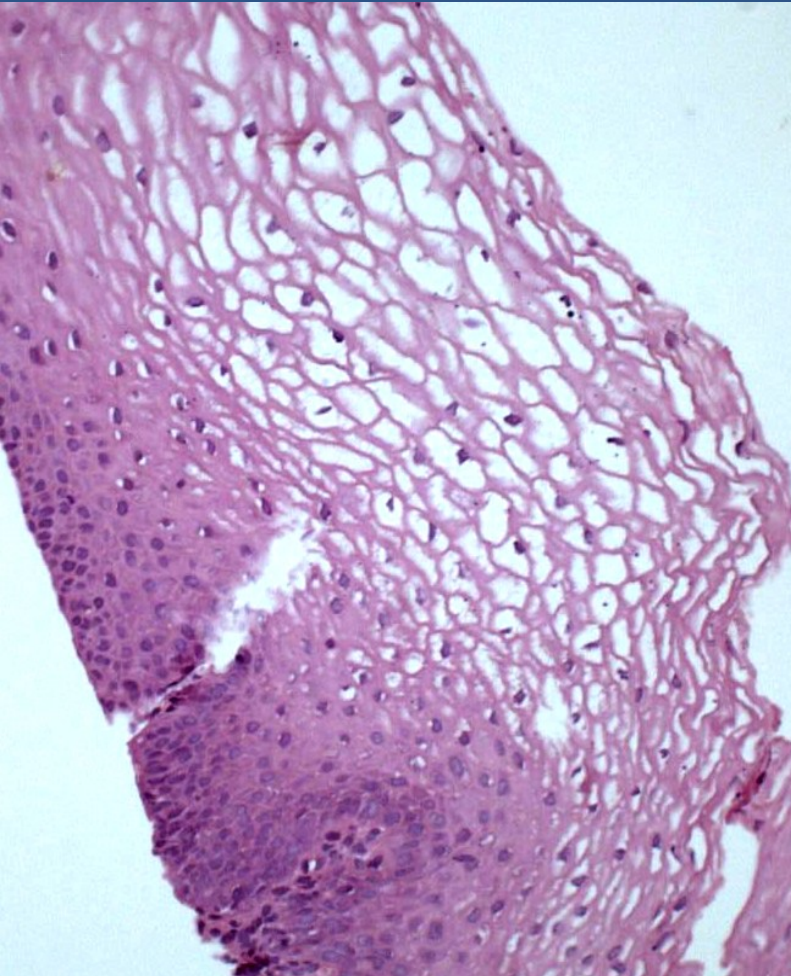


Reflux oesophagitis

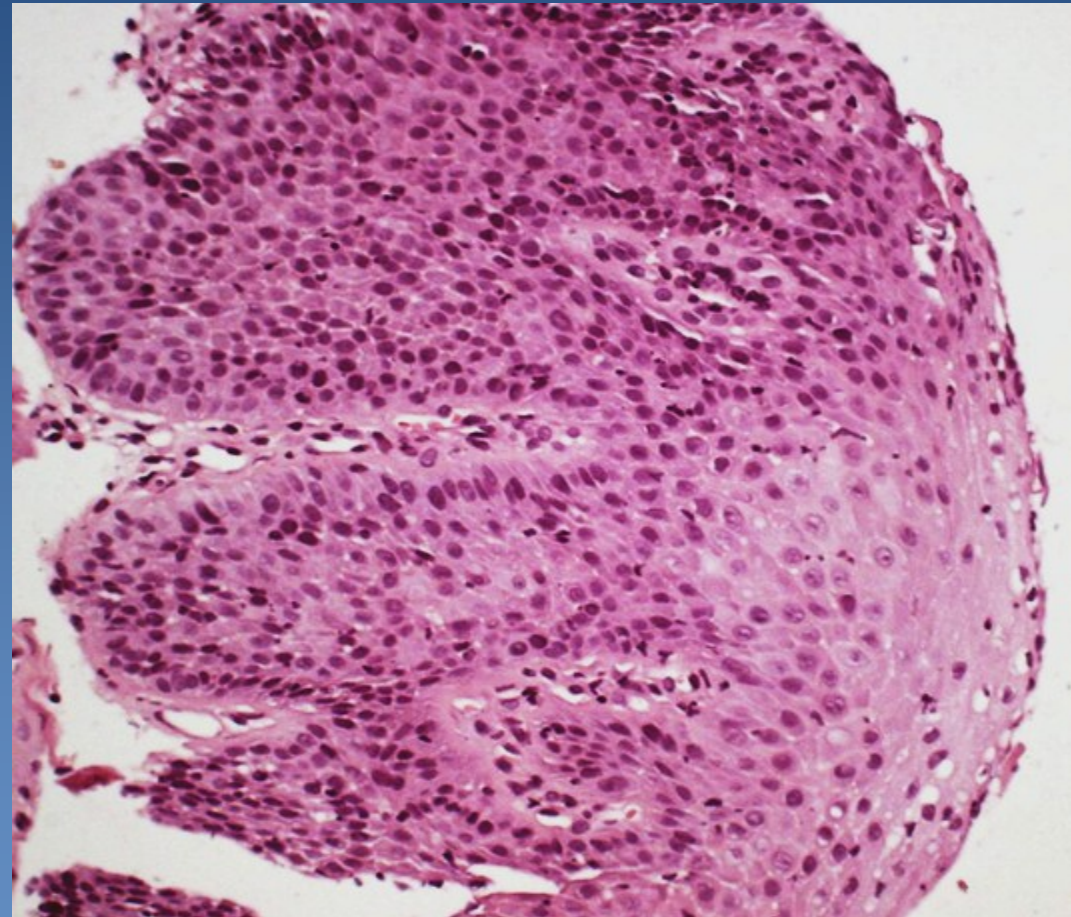


- × chemically caused inflammation in gastro-oesophageal reflux disease (sq. epithelium sensitive to acids)
- × signs x pathology – low correlation
 - ⇒ *heartburn, dysphagia*
- × gross:
 - ⇒ *mucosal hyperemia, epithelial erosions, ulcerations, scarring, stenosis*
- × micro:
 - ⇒ *3 reactive alterations of the squamous cell epithelium: basal zone hyperplasia, elongation of lamina propria papillae, inflammatory infiltrate with eosinophils.*
- × complication: Barrett's oesopagus (predisposition to malignancy)!

Reflux oesophagitis

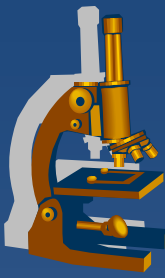


Regular oesophageal epithelium



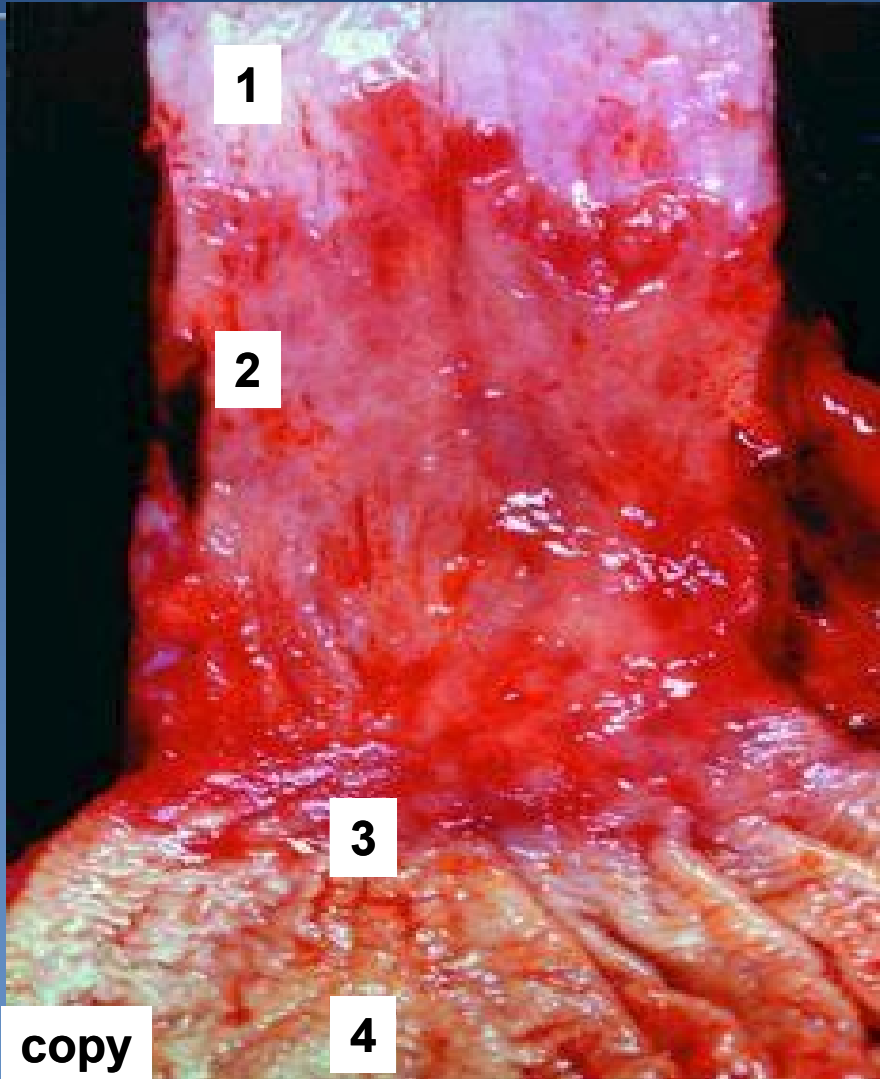
Reflux oesophagitis: basal zone hyperplasia (>20%), elongation of lamina propria papillae (into the superficial 1/3)

Barrett's oesophagus



- ✗ complication of reflux oesophagitis
- ✗ risk for the development of adenocarcinoma!
- ✗ replacement of the normal squamous cell epithelium by columnar epithelium with goblet cells (= intestinal metaplasia) → risk of dysplasia
- ✗ → oesophageal adenocarcinoma (so-called Barrett's carcinoma)

Barrett's oesophagus



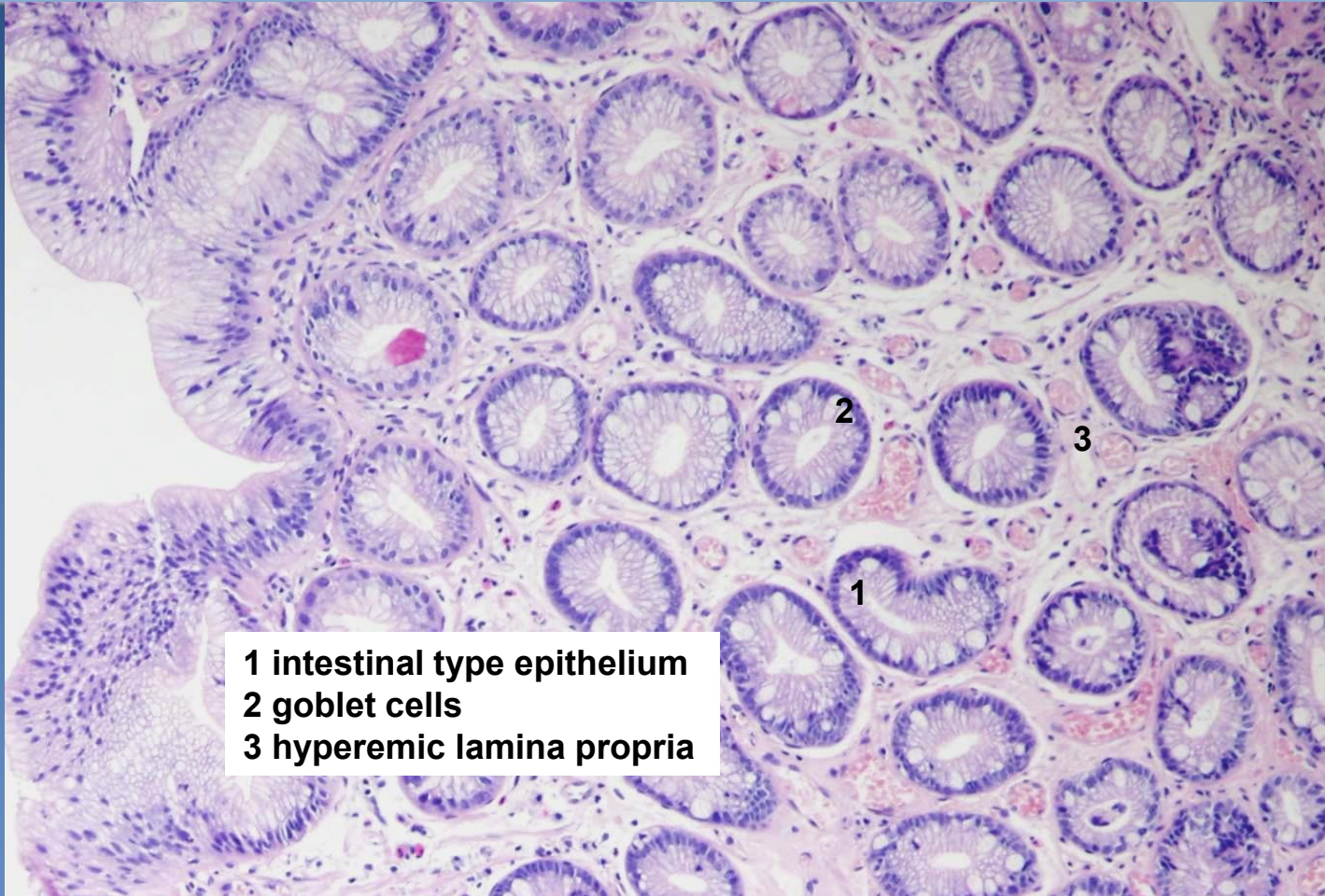
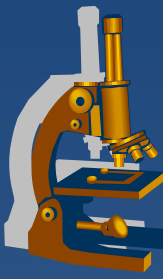
1 regular oesophageal mucosa

2 metaplasia

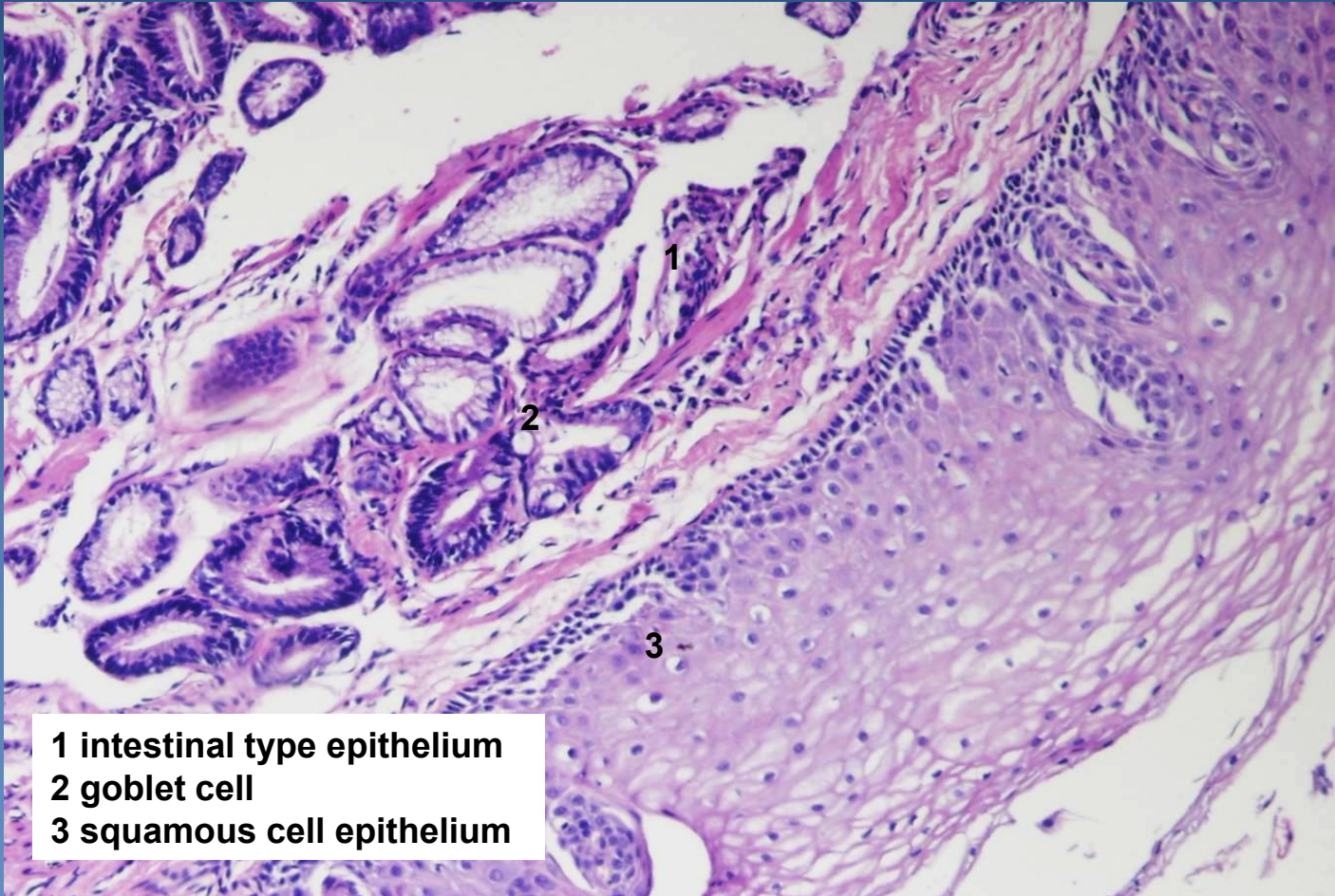
3 gastro-oesophageal junction

4 cardia

Barrett's oesophagus

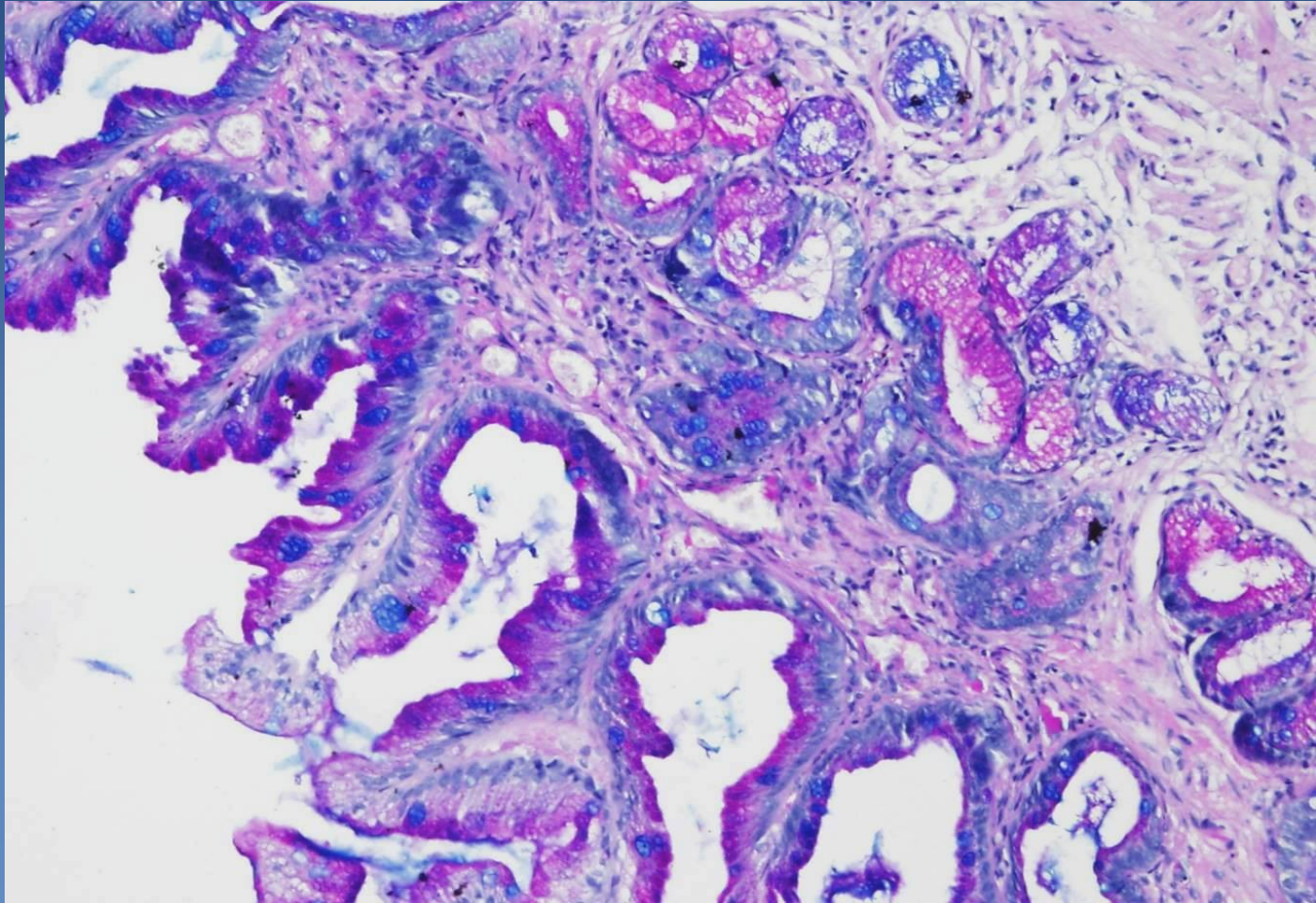


Barrett's oesophagus

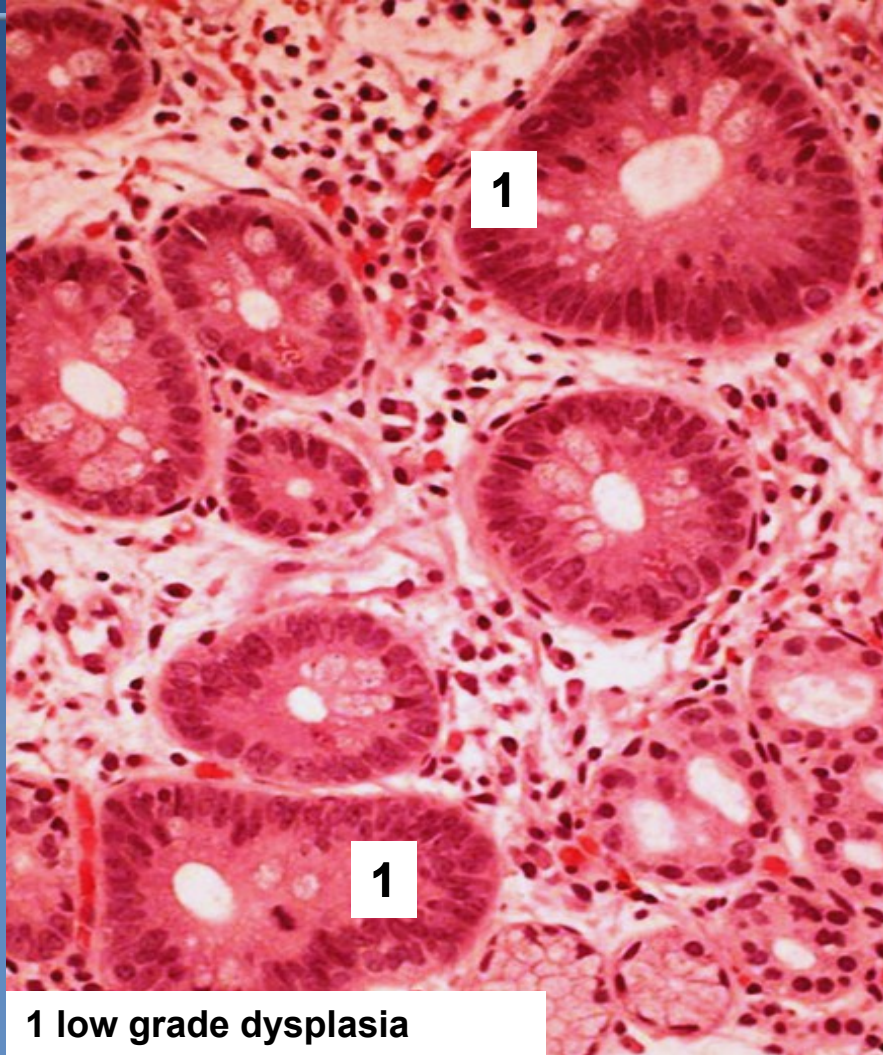


Barrett's oesophagus

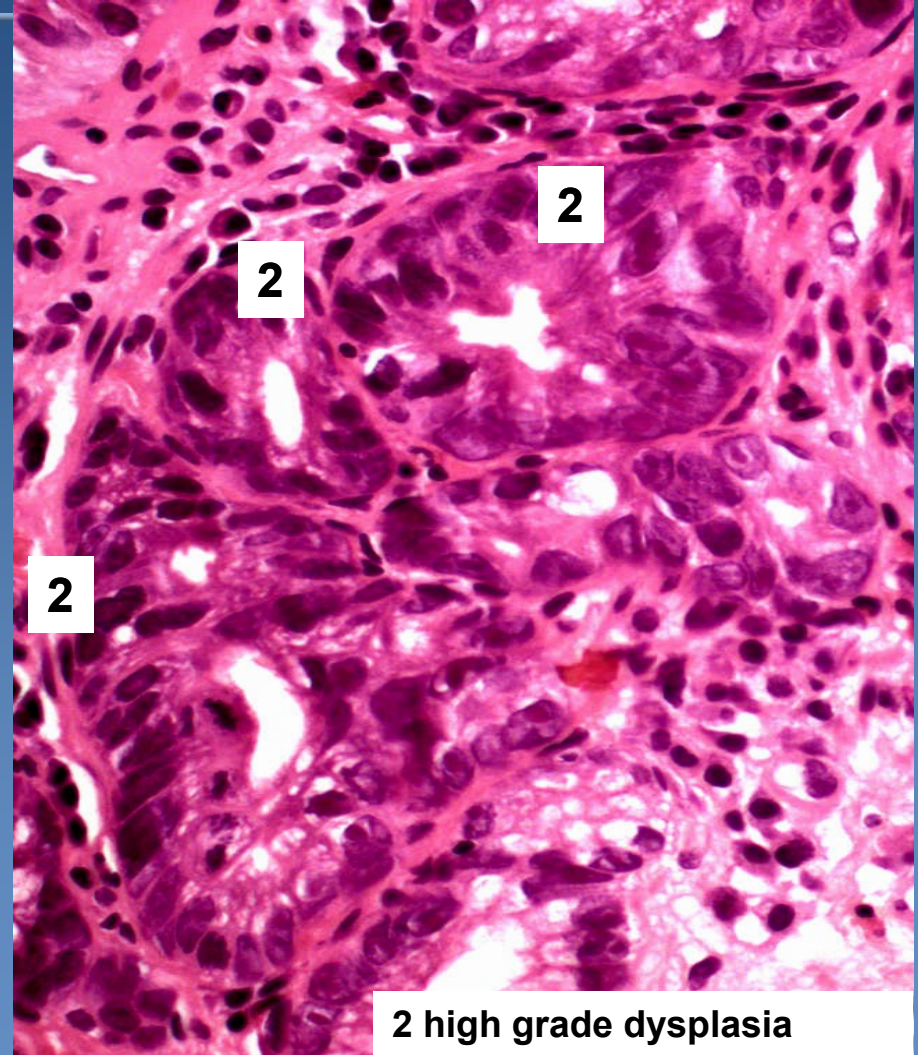
PAS ALC staining – blue goblet cells



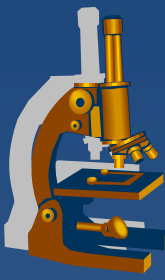
Barrett's oesophagus *- dysplastic epithelium*



1 low grade dysplasia



2 high grade dysplasia



Squamous cell carcinoma of the oesophagus

- ✗ usually in the mid-third of the esophagus
- ✗ M>F, >45 yrs of age
- ✗ Risk factors:
 - ⇒ *carcinogenic substances in food (aflatoxin, nitrosamines), tobacco, alcohol, HPV, very hot beverages, chronic inflammation*
- ✗ Symptoms:
 - ⇒ *dysphagia, weight loss, cachexia*

Squamous cell carcinoma of the oesophagus



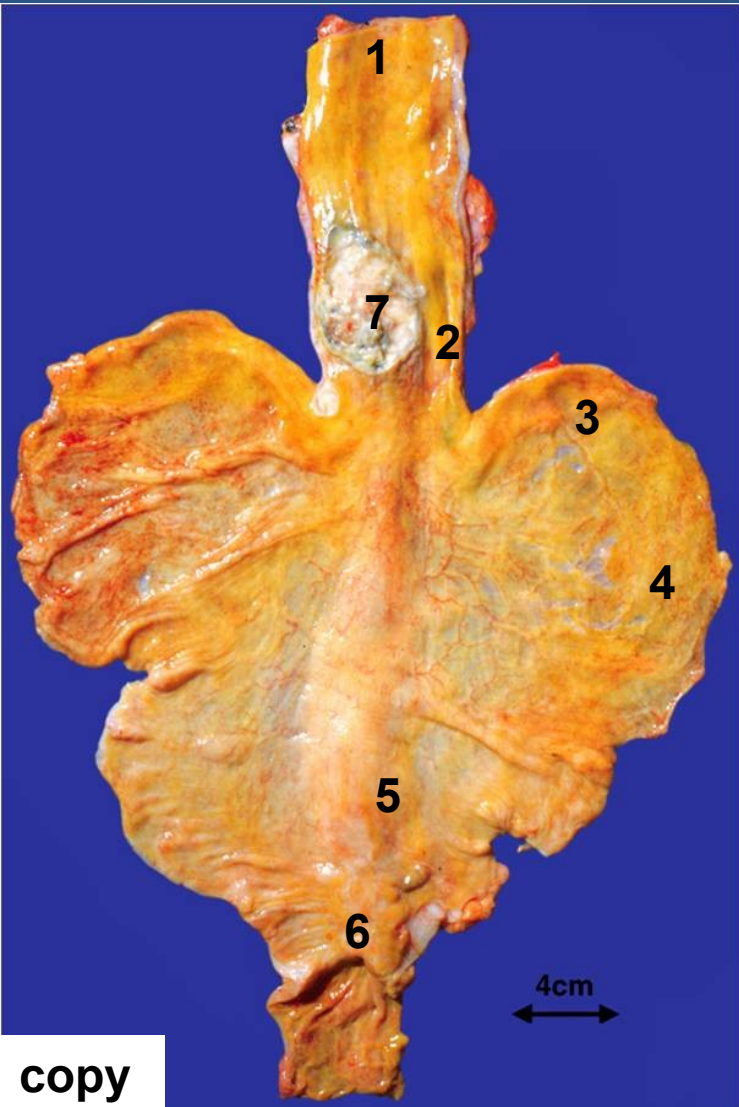
- x gross:**

- ⇒ *polypoid exophytic mass, ulcerative or diffuse infiltrative neoplasm*

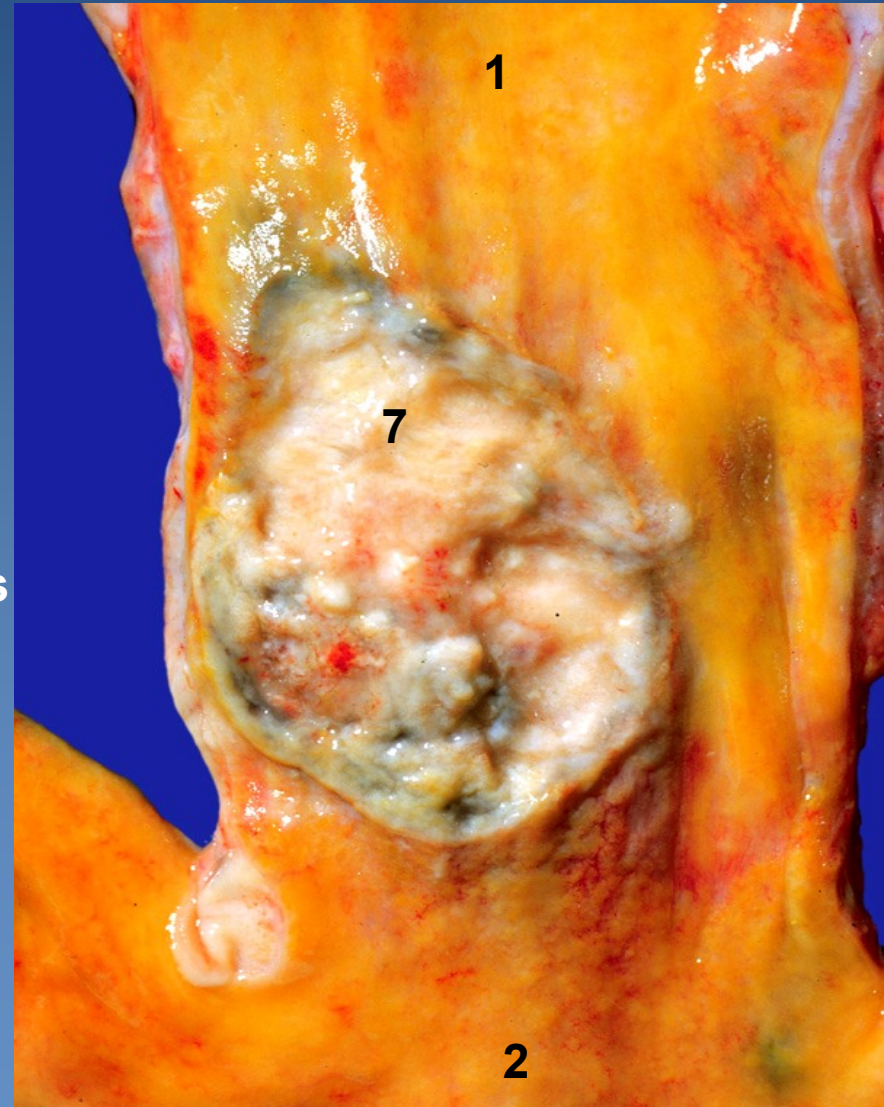
- x bad prognosis:**

- ⇒ *tendency to spread through submucosal lymph vessels → distant satellite tumor foci*

Squamous cell carcinoma of the oesophagus

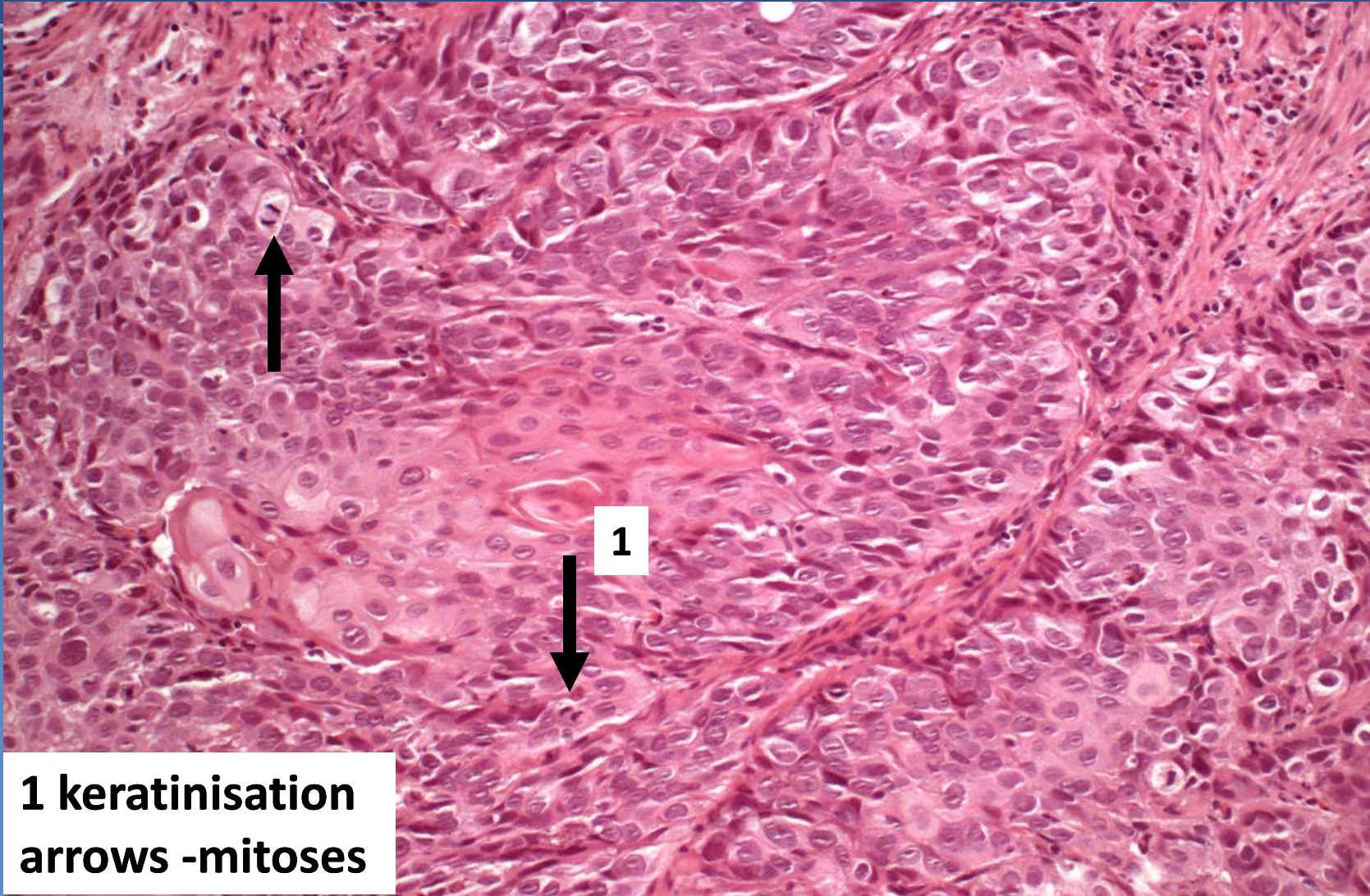
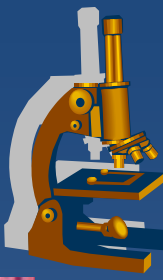


- 1 esophagus
- 2 cardia
- 3 fundus
- 4 body
- 5 antrum
- 6 pylorus
- 7 tumor

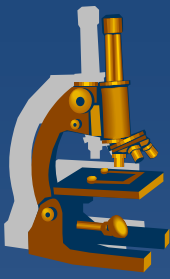


copy

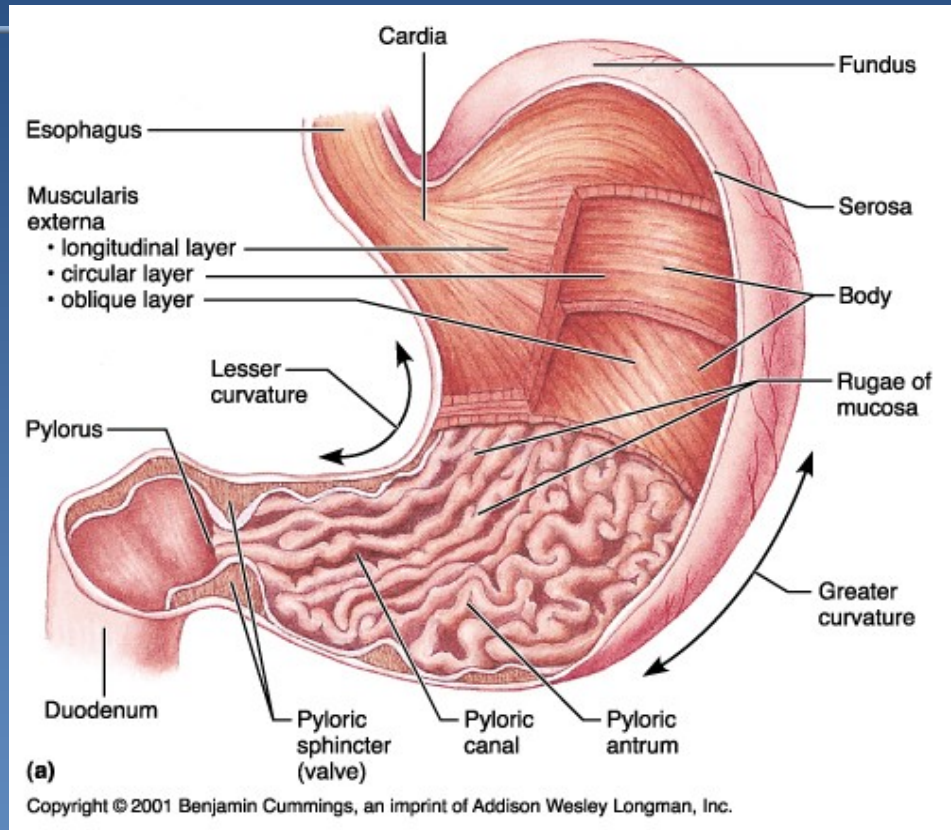
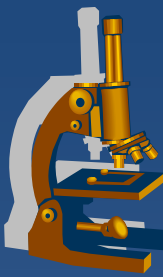
Squamous cell carcinoma of the oesophagus

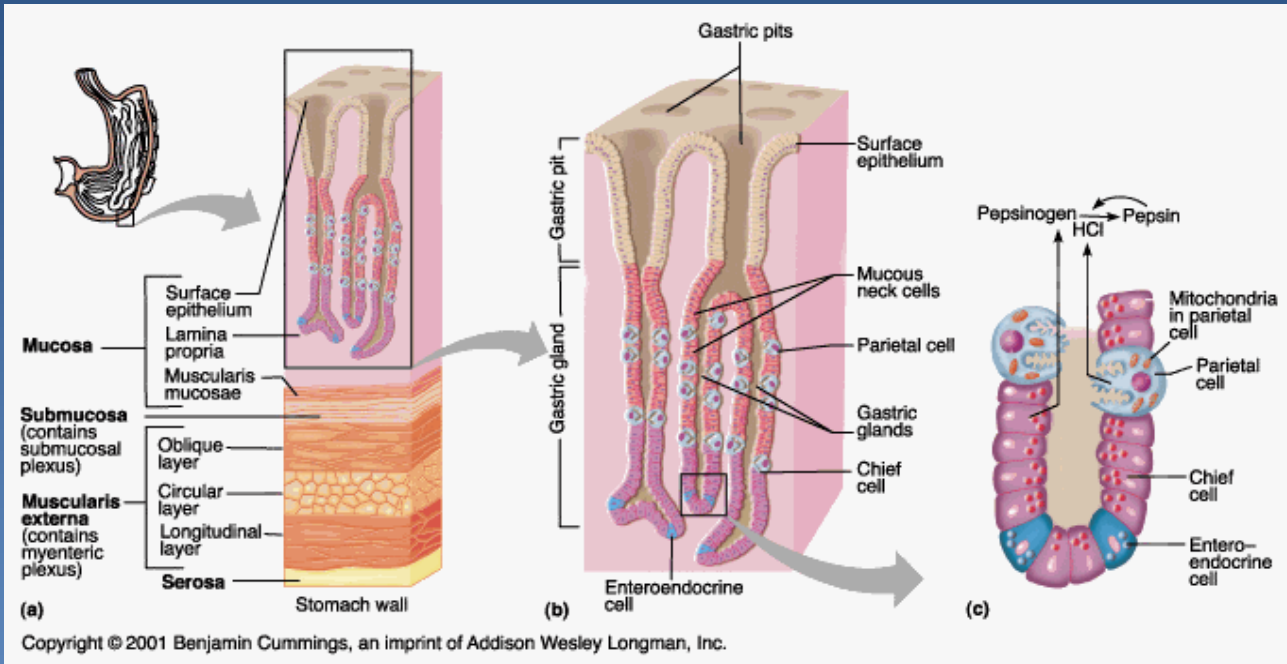
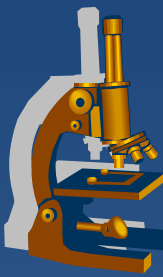


**1 keratinisation
arrows -mitoses**

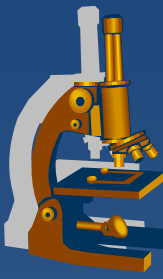


STOMACH





Gastritis



× two general types:

⇒ **acute** - *acute mucosal inflammatory process of a transient nature, causes: salt, spices, alcohol, NSAIDs, stress, infection*

- **gross:**

hyperemic, oedematous mucosa with erosions, haemorrhage

- **micro:**

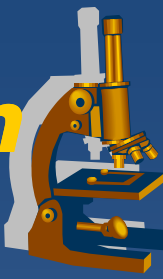hyperemia, oedema, neutrophilic (foveolar) inflammatory infiltrate, erosions

Gastritis



- ⇒ **chronic** - chronic inflammatory changes leading to mucosal atrophy and epithelial metaplasia
- usually associated with *Helicobacter pylori*
 - **micro evaluation:**
 - » inflammatory infiltrate in lamina propria mucosae - lymphoplasmocytic (grade of chronicity) + neutrophils (grade of activity)
 - » presence of HP (+/-) and quantitative analysis
 - » presence of atrophy, intestinal metaplasia (complete, incomplete) and possible dysplasia

Clinical-pathological classification of chronic gastritis

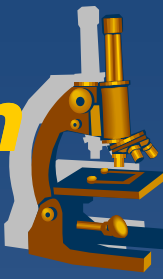

- 1) Chronic non-atrophic gastritis (superficial)
(„B“)

- 2) Chronic atrophic gastritis
 - I. Autoimmune gastritis („A“)
 - II. Chronic multifocal atrophic gastritis

- 3) Special forms (chemical - reactive,
lymphocytic, eosinophilic, granulomatous)

Clinical-pathological classification of chronic gastritis

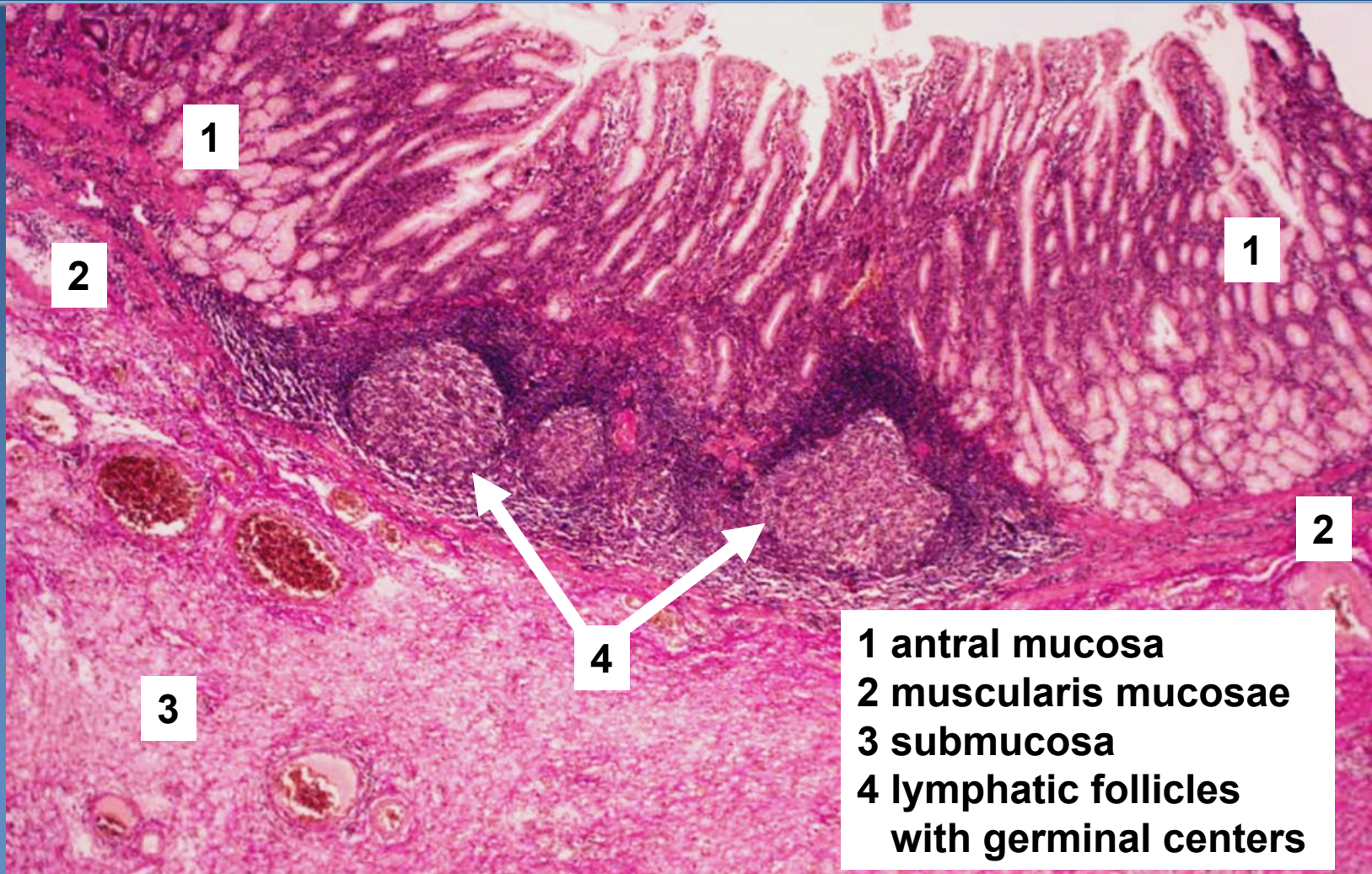


× **Chronic non-atrophic gastritis (superficial)**

⇒ *Helicobacter pylori*

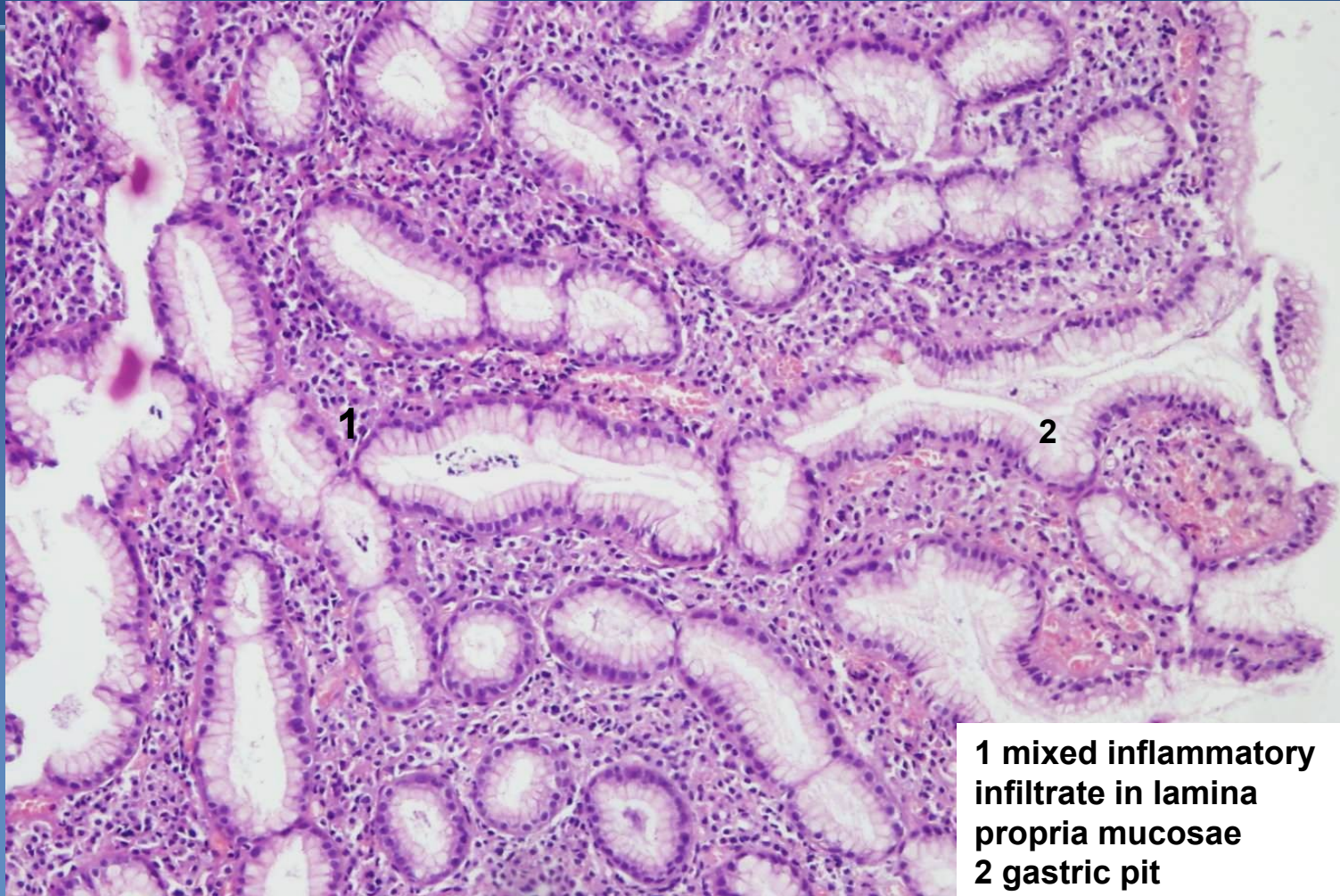- **gross:** **antrum** and body mucosa
- **micro:** superficial or deep inflammation, active chronic gastritis, lymphocyte and plasma cell response forming lymphatic follicles in the glandular area, final mucosal atrophy
- **higher risk of developing NHL**

Chronic non-atrophic gastritis - follicular



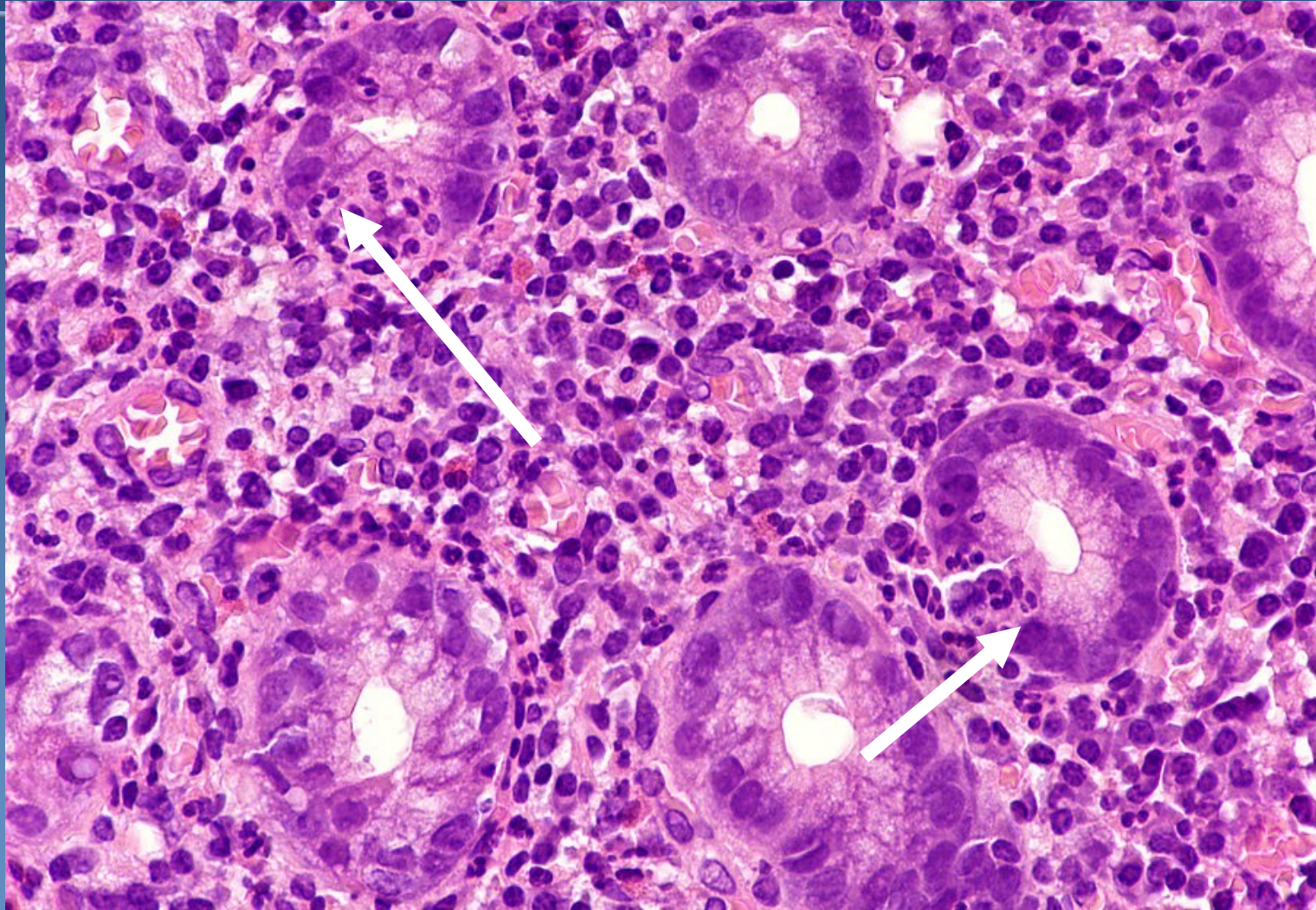
- 1 antral mucosa**
- 2 muscularis mucosae**
- 3 submucosa**
- 4 lymphatic follicles
with germinal centers**

Chronic non-atrophic gastritis ***- detail of the mucosa***



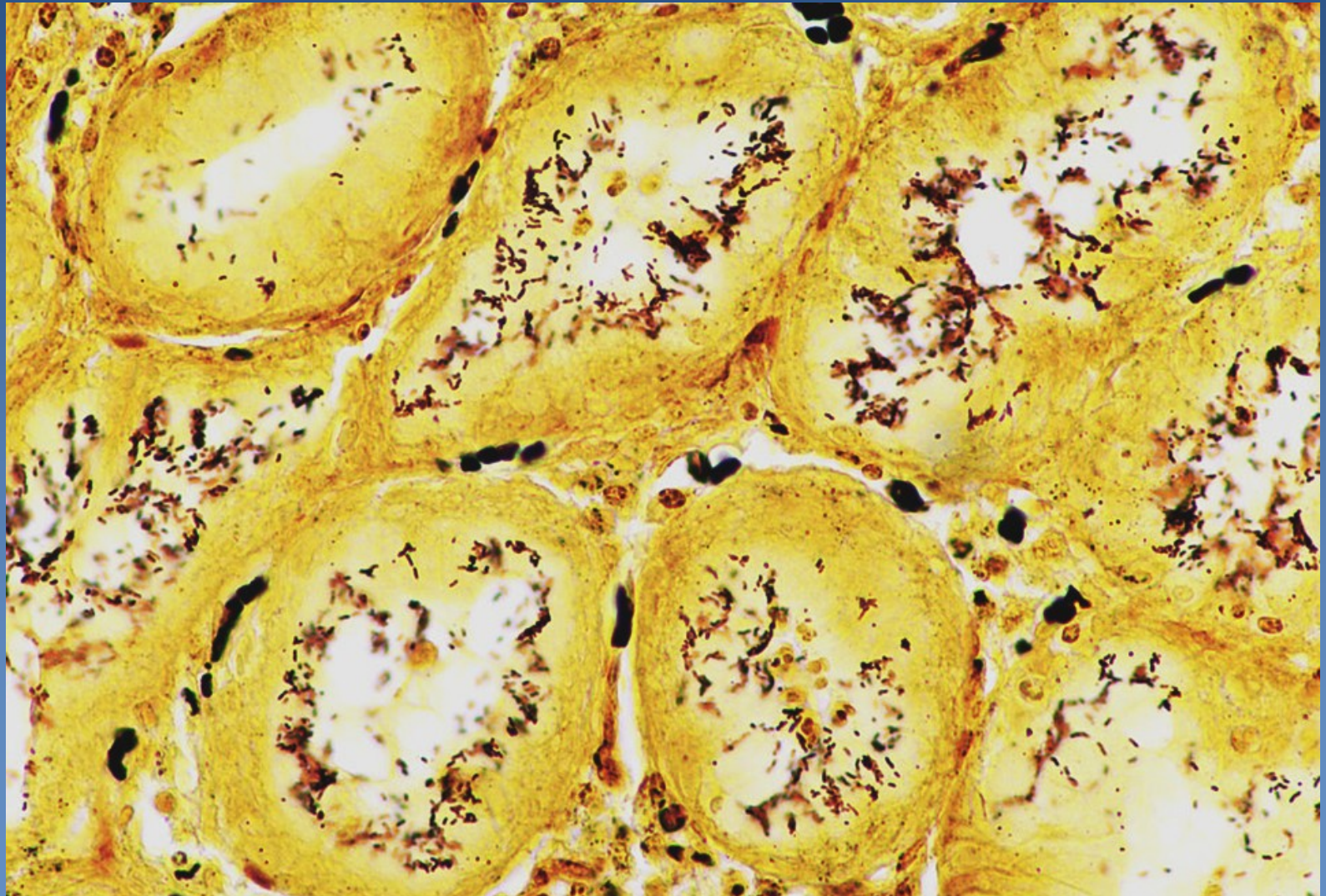
**1 mixed inflammatory
infiltrate in lamina
propria mucosae
2 gastric pit**

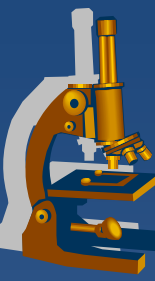
Chronic active gastritis ***- grade of activity 2***



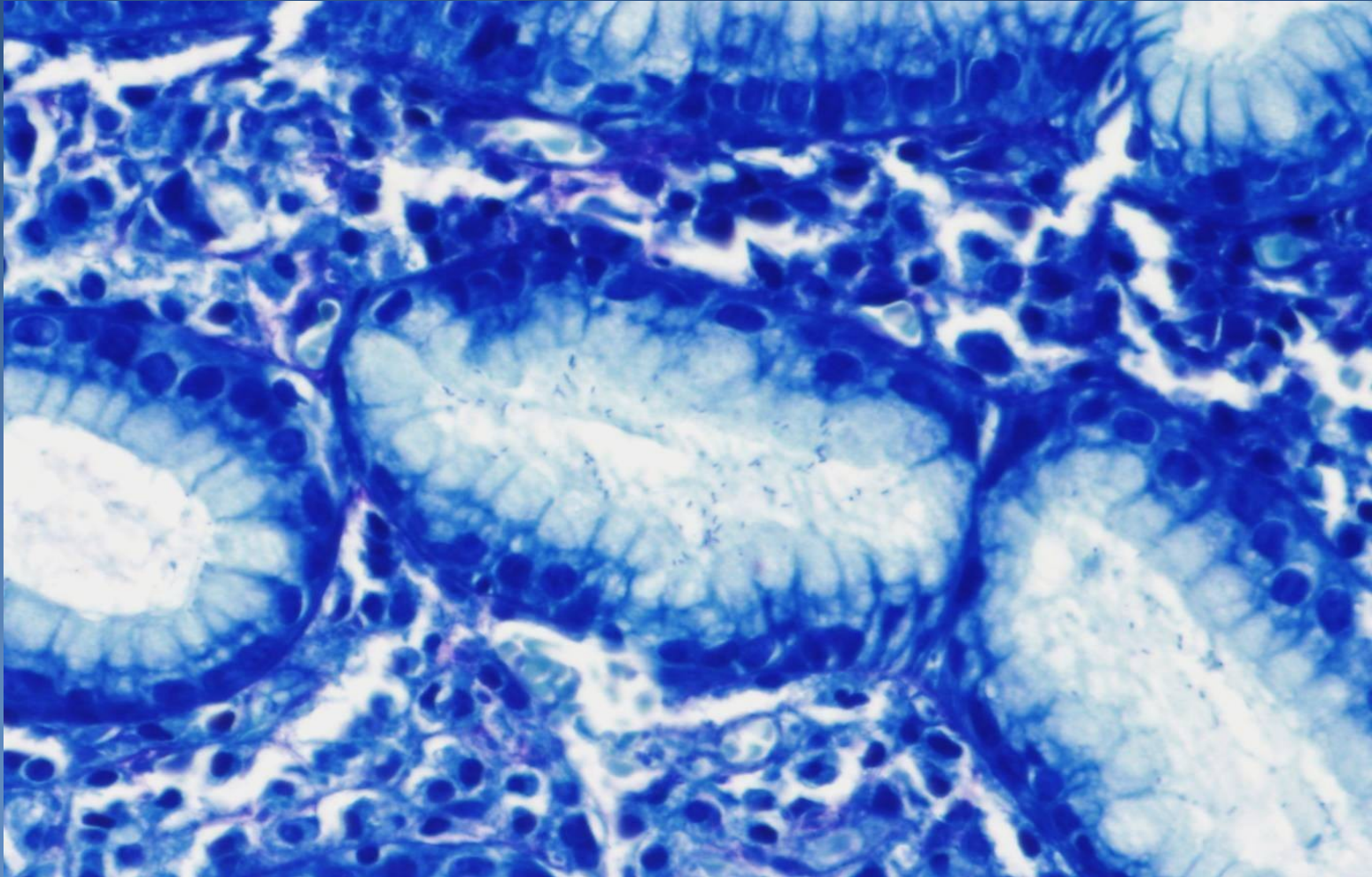
intraepithelial neutrophils

***Chronic non-atrophic gastritis
Helicobacter pylori (Warthin-Starry)***

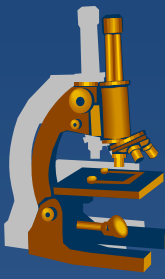



***Chronic non-atrophic gastritis
Helicobacter pylori (Giemsa–Romanowski)***



Chronic gastritis



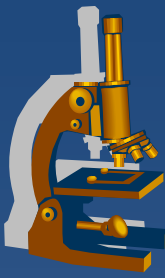
× Chronic atrophic gastritis

1/ Autoimmune chronic atrophic gastritis („A“)

⇒ *autoimmune, anti-parietal cell and anti-intrinsic factor antibodies, hypochlorhydria, association with vitamin B12 deficiency and pernicious anemia*

- *gross: mucosa of the gastric **body** and fundus atrophy*
- *micro: chronic non-active gastritis (severe mucosal atrophy with intestinal or pseudopyloric metaplasia, fibrosis)*
- *higher risk of developing adenocarcinoma!*

Chronic gastritis



× **Chronic atrophic gastritis**

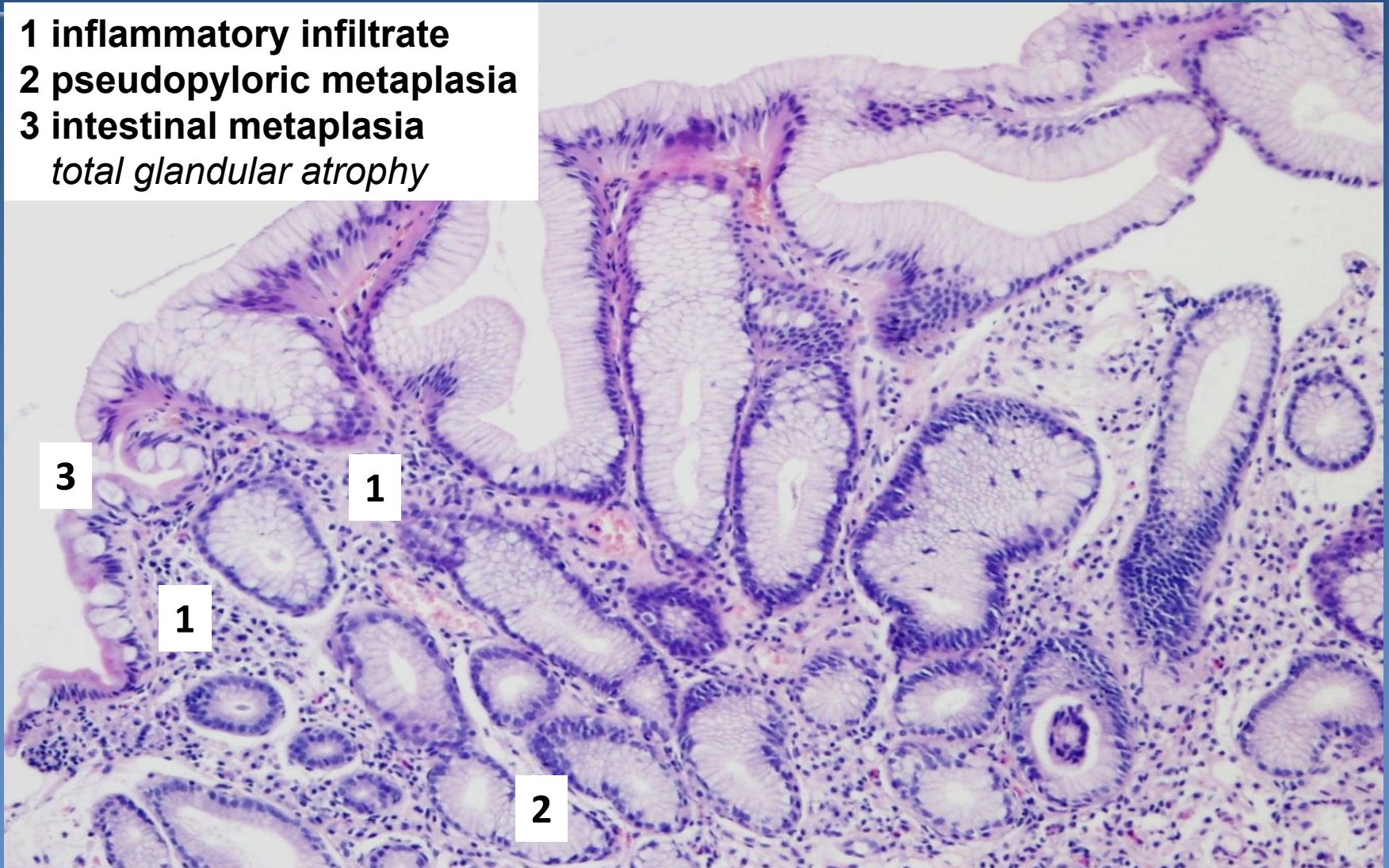
2/ **Chronic multifocal atrophic gastritis (pangastritis)**

- ⇒ *Helicobacter pylori-associated*
- ⇒ *low grade of inflammation (body + antrum)*
- ⇒ *epithelial reactive changes, erosions*
- ⇒ *uneven distribution of atrophic foci*

Chronic atrophic gastritis (gastric body)



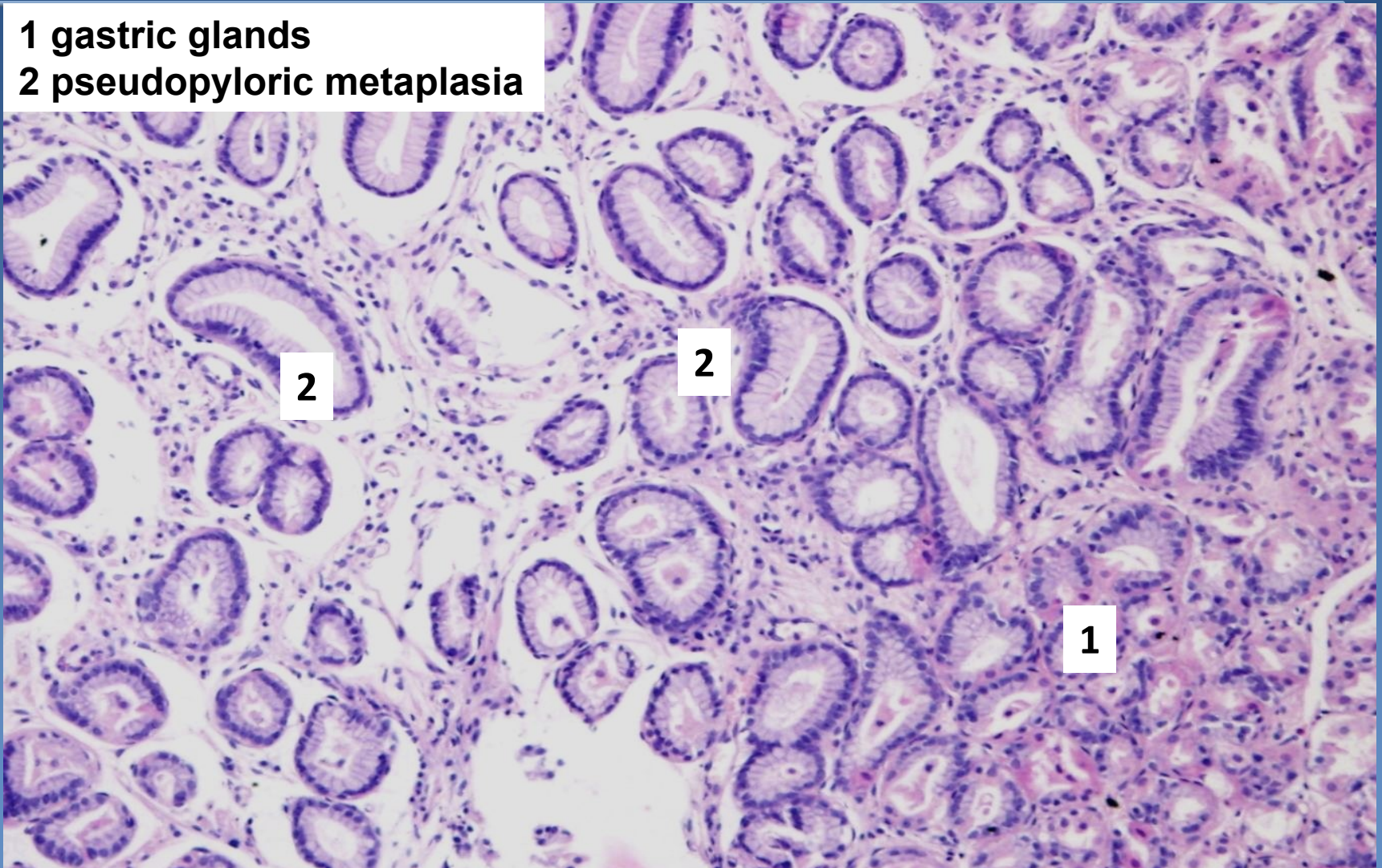
- 1** inflammatory infiltrate
- 2** pseudopyloric metaplasia
- 3** intestinal metaplasia
total glandular atrophy



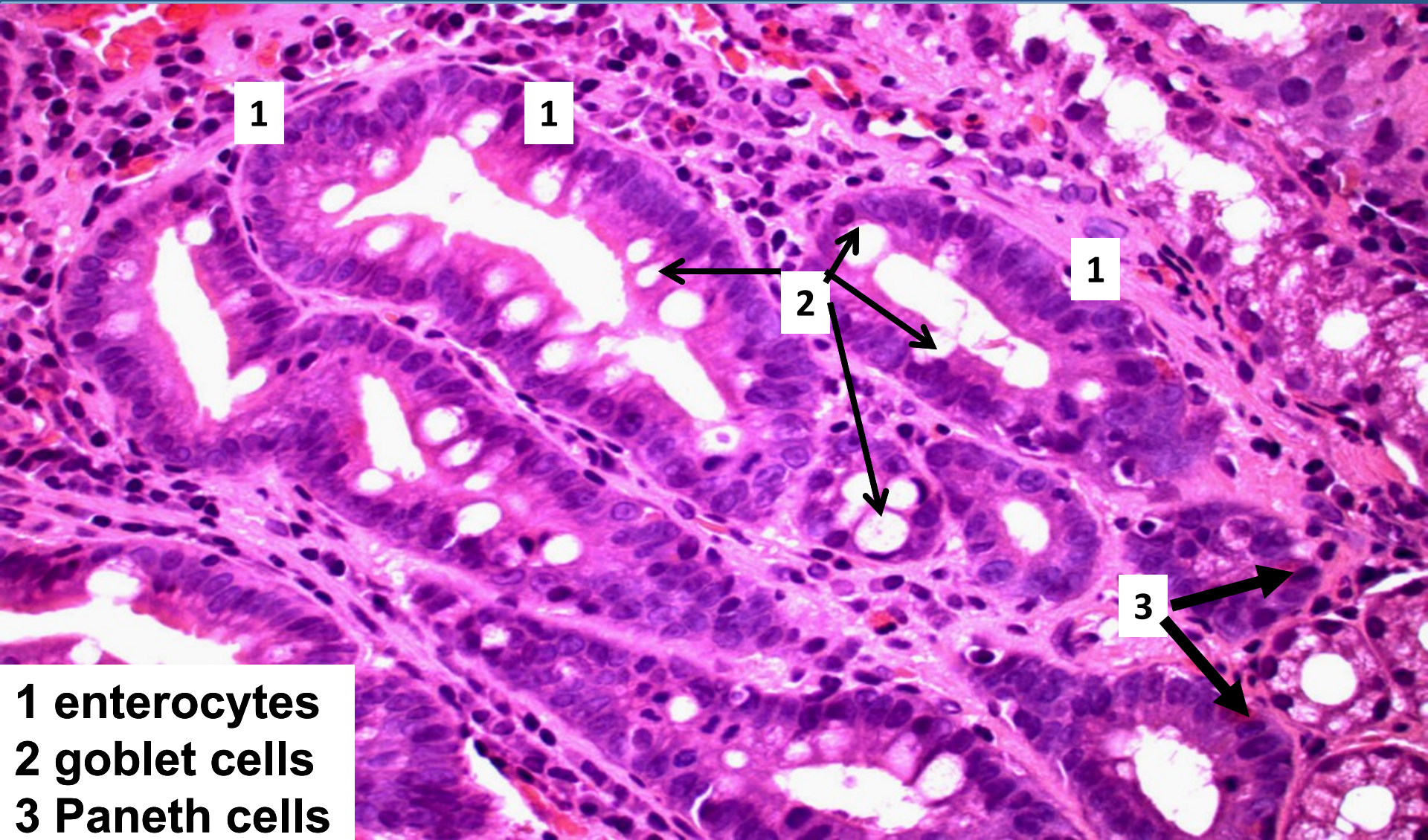
Chronic atrophic gastritis (gastric body)



1 gastric glands
2 pseudopyloric metaplasia



Chronic gastritis *- intestinal metaplasia*



1 enterocytes
2 goblet cells
3 Paneth cells

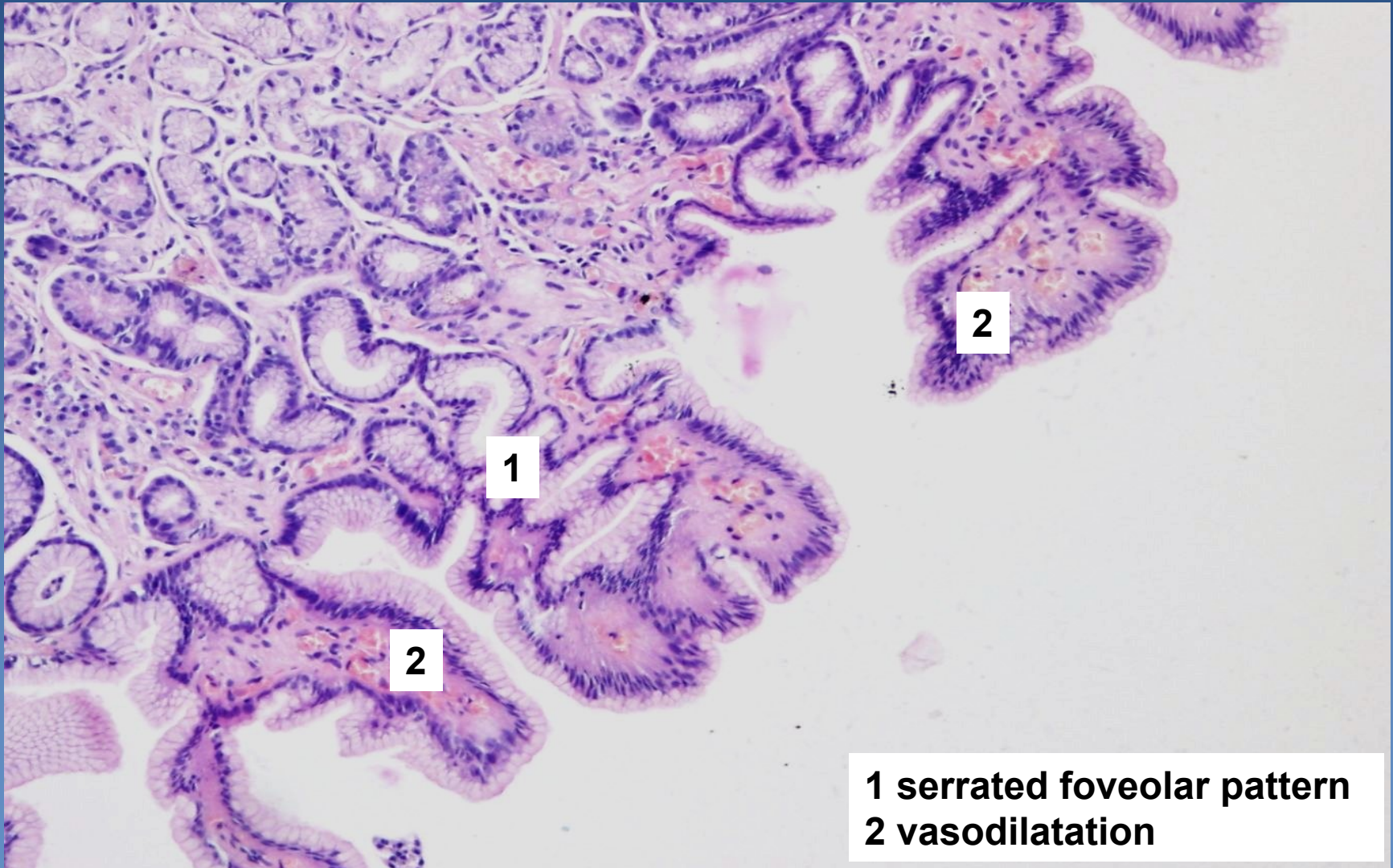
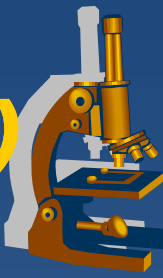Chronic gastritis



Special forms:

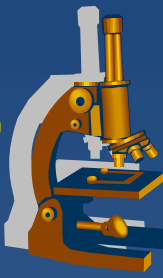
- × Chemical (reflux) gastritis / reactive gastropathy (former „C“)
 - ⇒ *bile reflux, duodenal reflux after partial gastrectomy, NSAIDs*
 - ⇒ *micro: hyperemic, oedematous mucosa, foveolar hyperplasia, vasodilatation, little inflammatory response*
- × Lymphocytic, eosinophilic, granulomatous...

Reactive gastropathy (gastritis C) mild changes

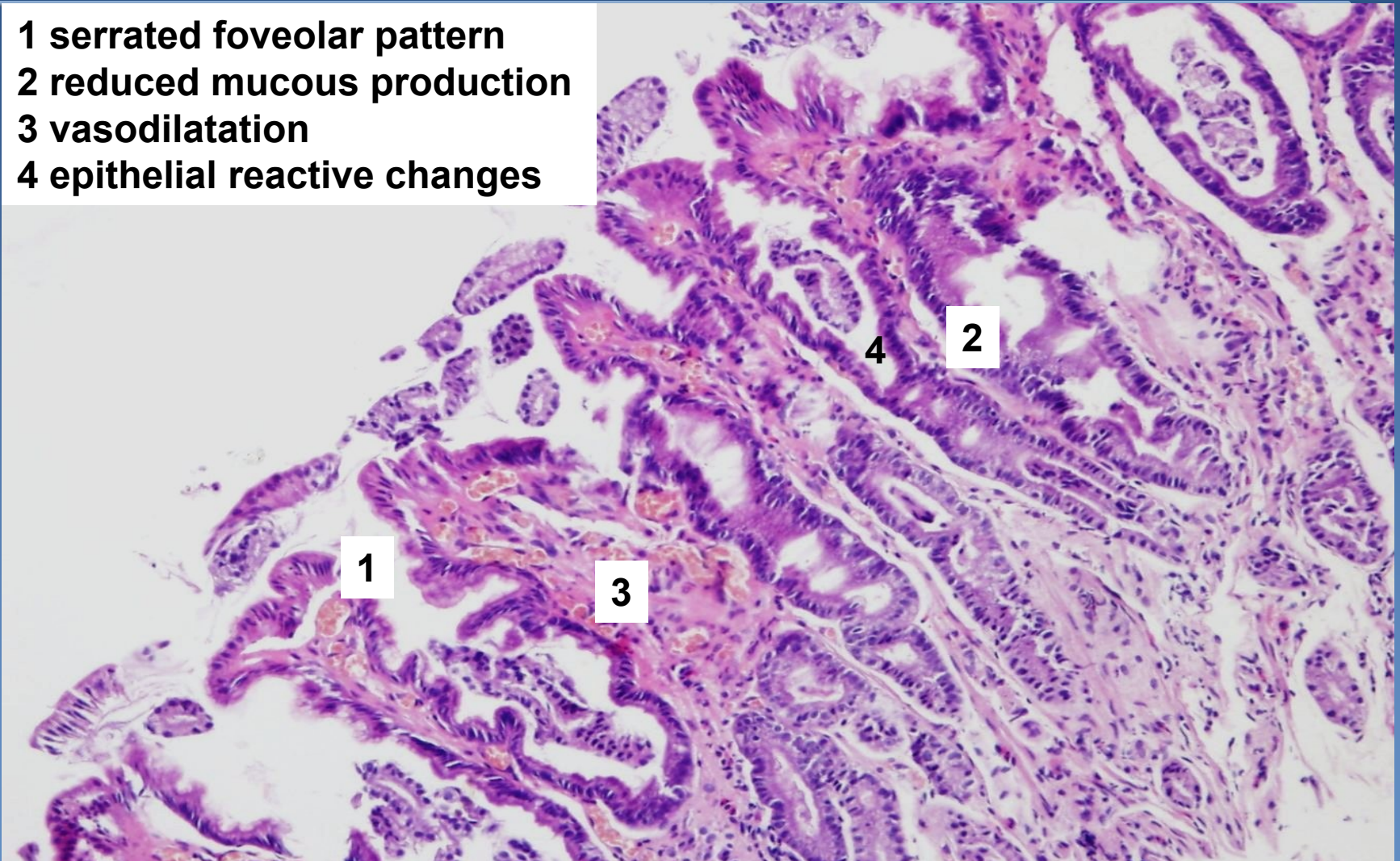


**1 serrated foveolar pattern
2 vasodilatation**

Reactive gastropathy (gastritis C) severe changes



- 1 serrated foveolar pattern**
- 2 reduced mucous production**
- 3 vasodilatation**
- 4 epithelial reactive changes**



Hypertrophic gastropathy



✗ uncommon, large mucosal folds

⇒ *marked epithelial hyperplasia (↑ growth factor release), may mimic a tumor:*

- Ménétrier's disease (hyperplastic hypersecretory gastropathy with protein loss)
- hypersecretory gastropathy (hyperplasia of parietal and chief cells)
- glandular hyperplasia in Zollinger - Ellison syndrome (in neuroendocrine tumors with gastrin production)

Gastric erosions



- x definition:

- ⇒ *limited by m. mucosae, tiny superficial defects < 3 mm*

- x causes:

- ⇒ *NSAIDs, alcohol, vomiting, stress, burns, infection*

- x localisation:

- ⇒ *antrum and body*

- x microcirculation disorder, capillary rupture

- x complete regeneration within a few days

Peptic ulceration



- x **Ulcer definition:** *mucosal defect progressing through the m. mucosae **into the submucosa or deeper***
- x **risk factors/causes:**
 - ⇒ *general: genetics, age, stress, alcohol, smoking*
 - ⇒ *local: gastric hyperacidity, HP gastritis, NSAIDs*
- x **localisation:**
 - ⇒ *pylorus, lesser curvature, bulbus duodeni, (Meckel's diverticulum, stomic junction, GE junction)*

Gastric ulceration



Acute ulcer:

- ⇒ *sharply demarcated defect 4 - 25mm; acute gastritis, severe stress (shock, trauma, burns), NSAIDs, severe hyperacidity*

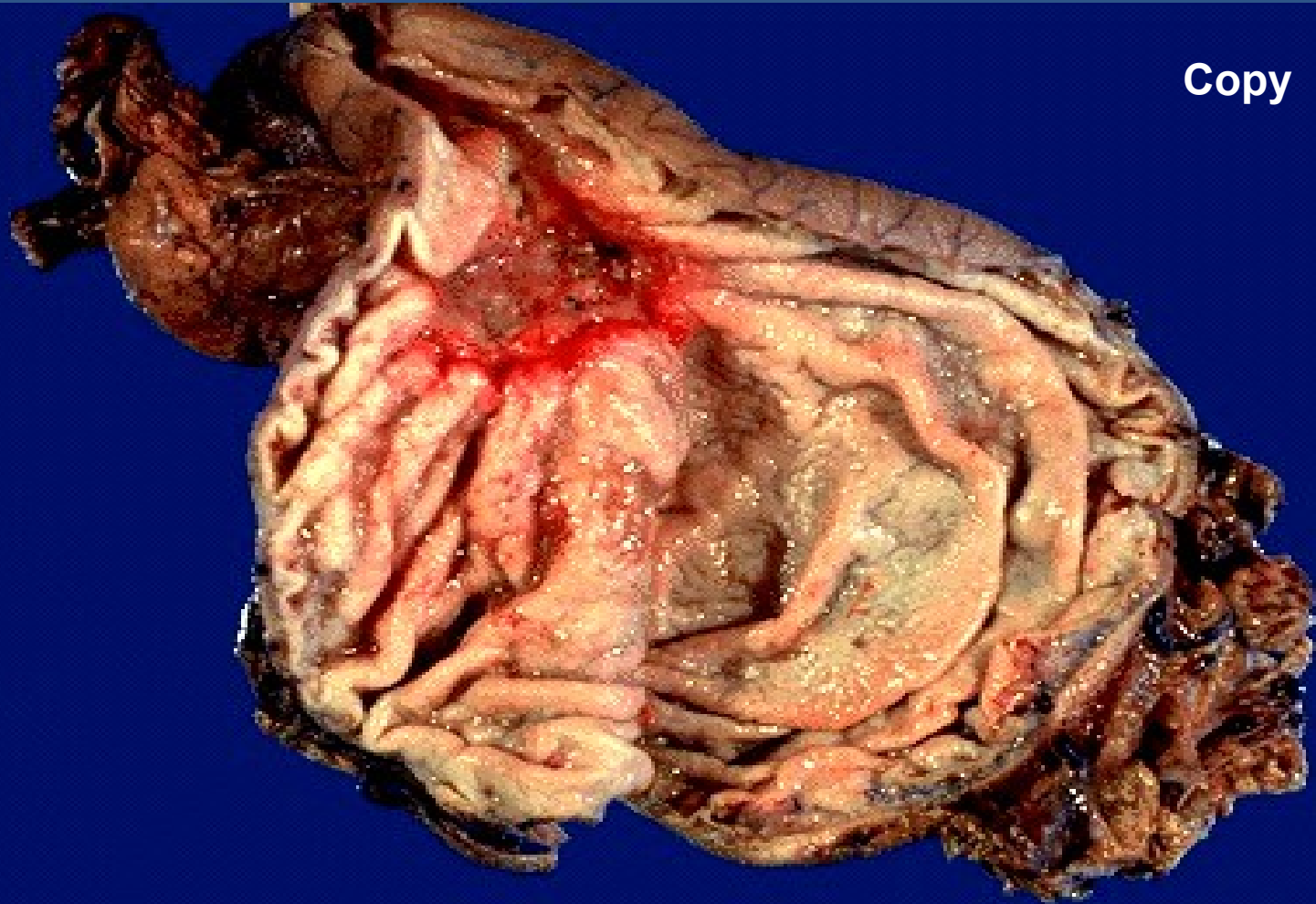
Chronic ulcer:

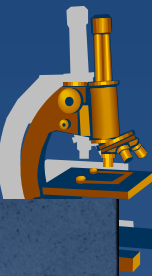
- ⇒ *slightly overhanging margins, radial adjacent mucosal folds*
- ⇒ *gross: smooth base*
- ⇒ *4 histologic zones: 1) fibrinoid necrosis and cell debris – active u. 2) mixed inflammatory infiltrate 3) granulation tissue 4) fibrous scar*
- ⇒ *complications: bleeding (overt, occult), penetration, perforation, scarring + obstruction, rare malignant transformation*

Chronic peptic ulcer of the stomach

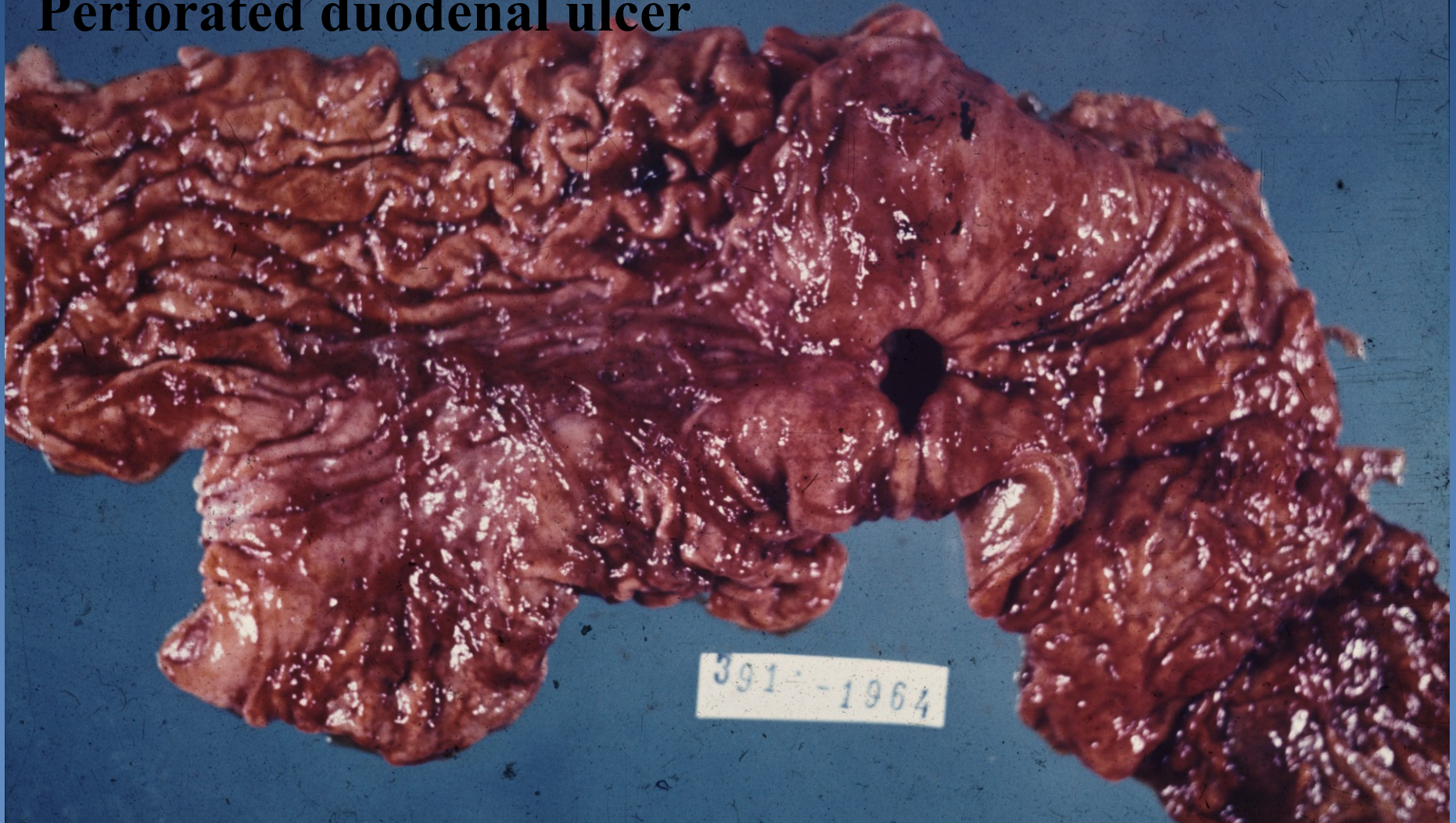

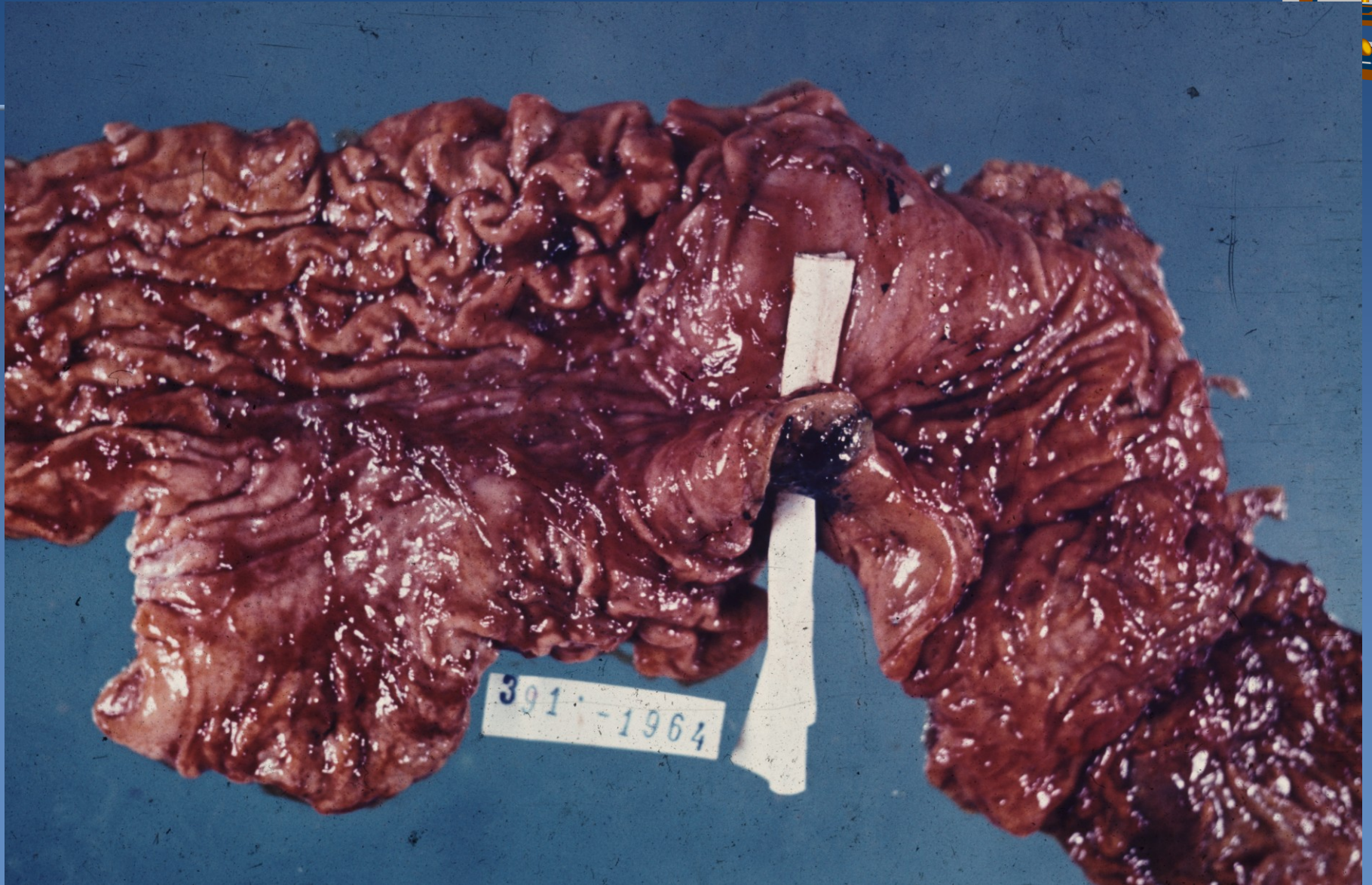
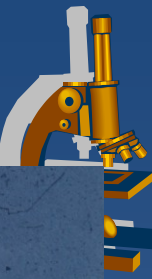
Copy



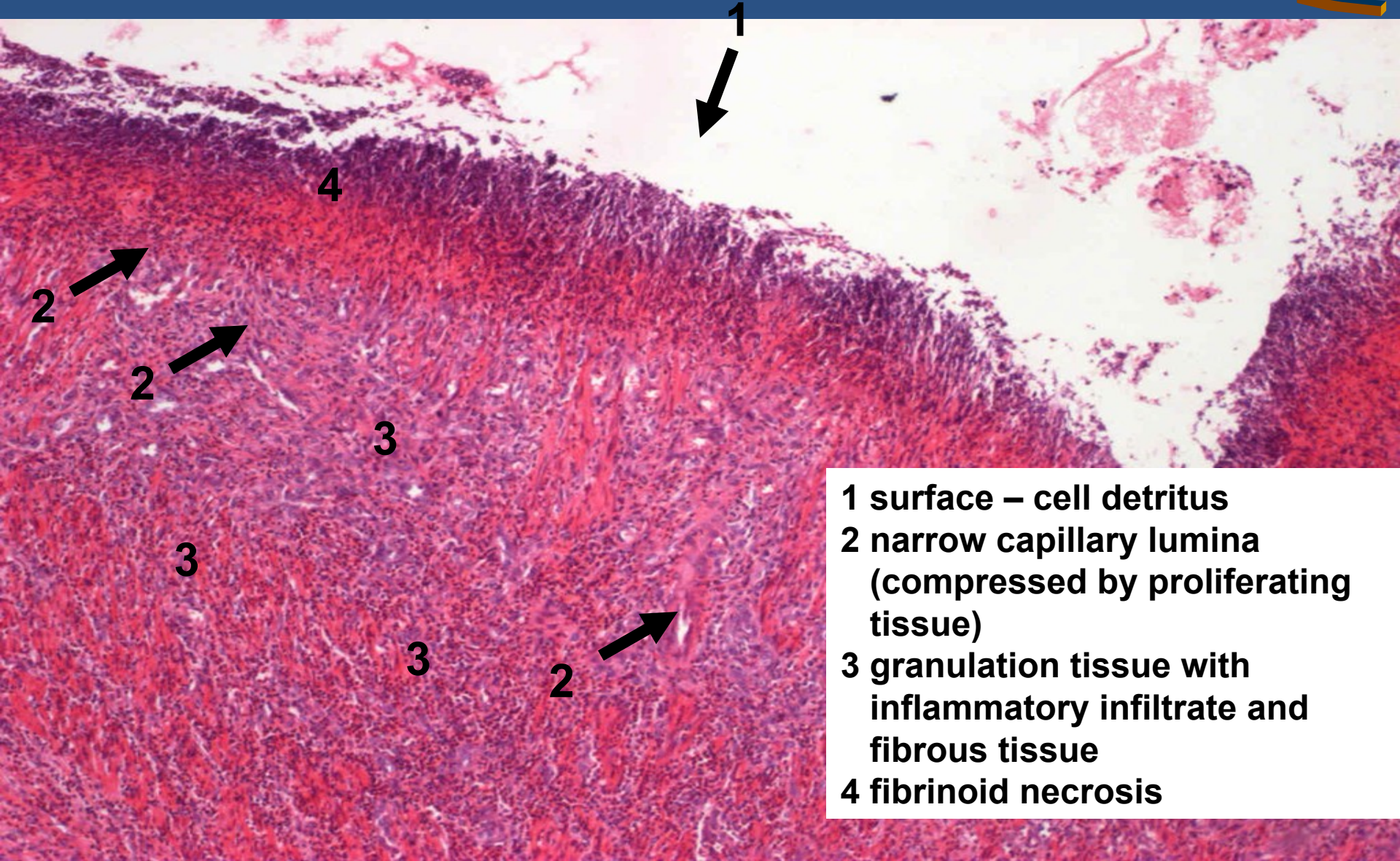
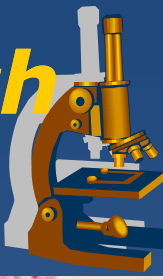

Perforated duodenal ulcer





Chronic peptic ulcer of the stomach **- basis**



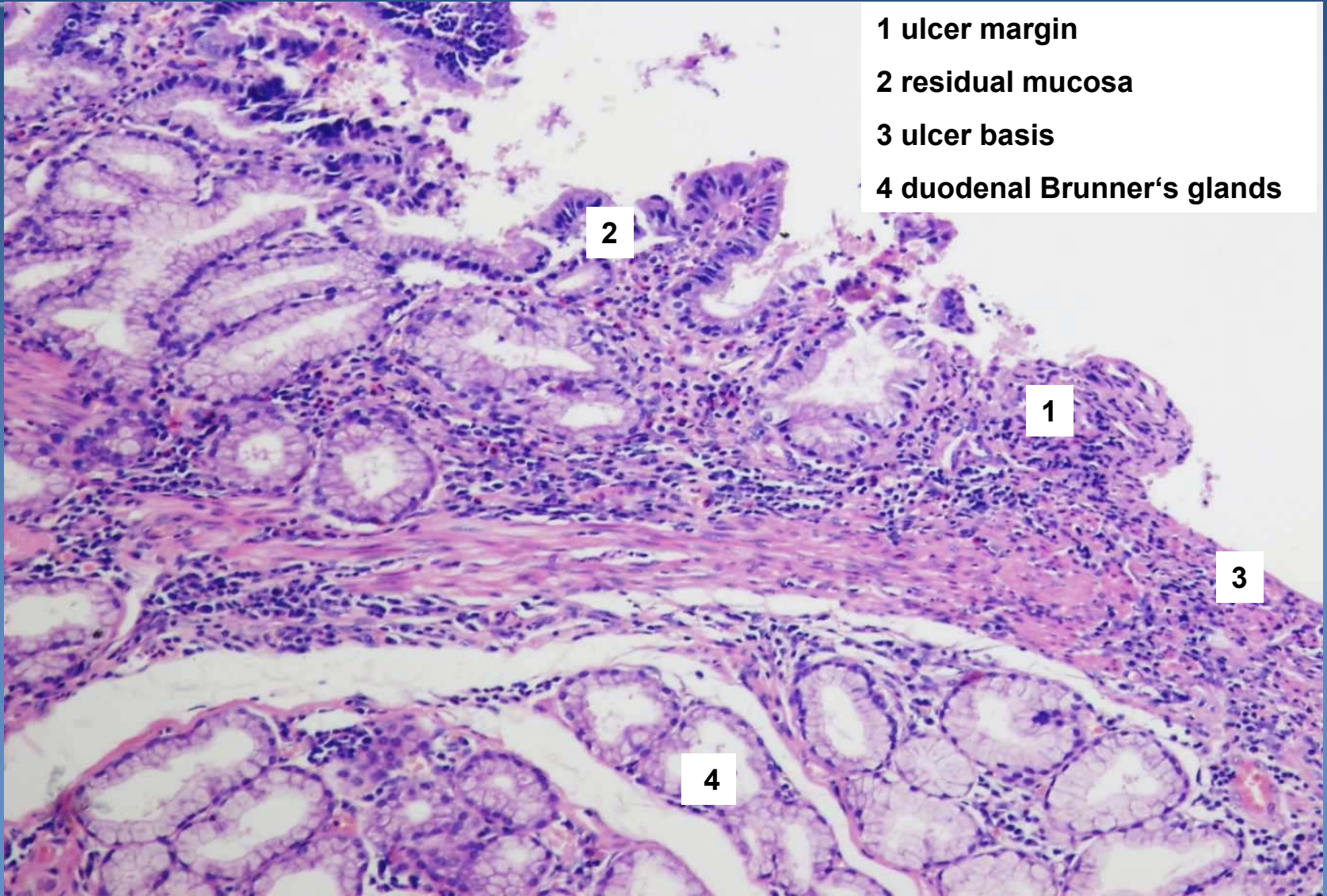
- 1 surface – cell detritus**
- 2 narrow capillary lumina
(compressed by proliferating
tissue)**
- 3 granulation tissue with
inflammatory infiltrate and
fibrous tissue**
- 4 fibrinoid necrosis**

Peptic duodenal ulcer

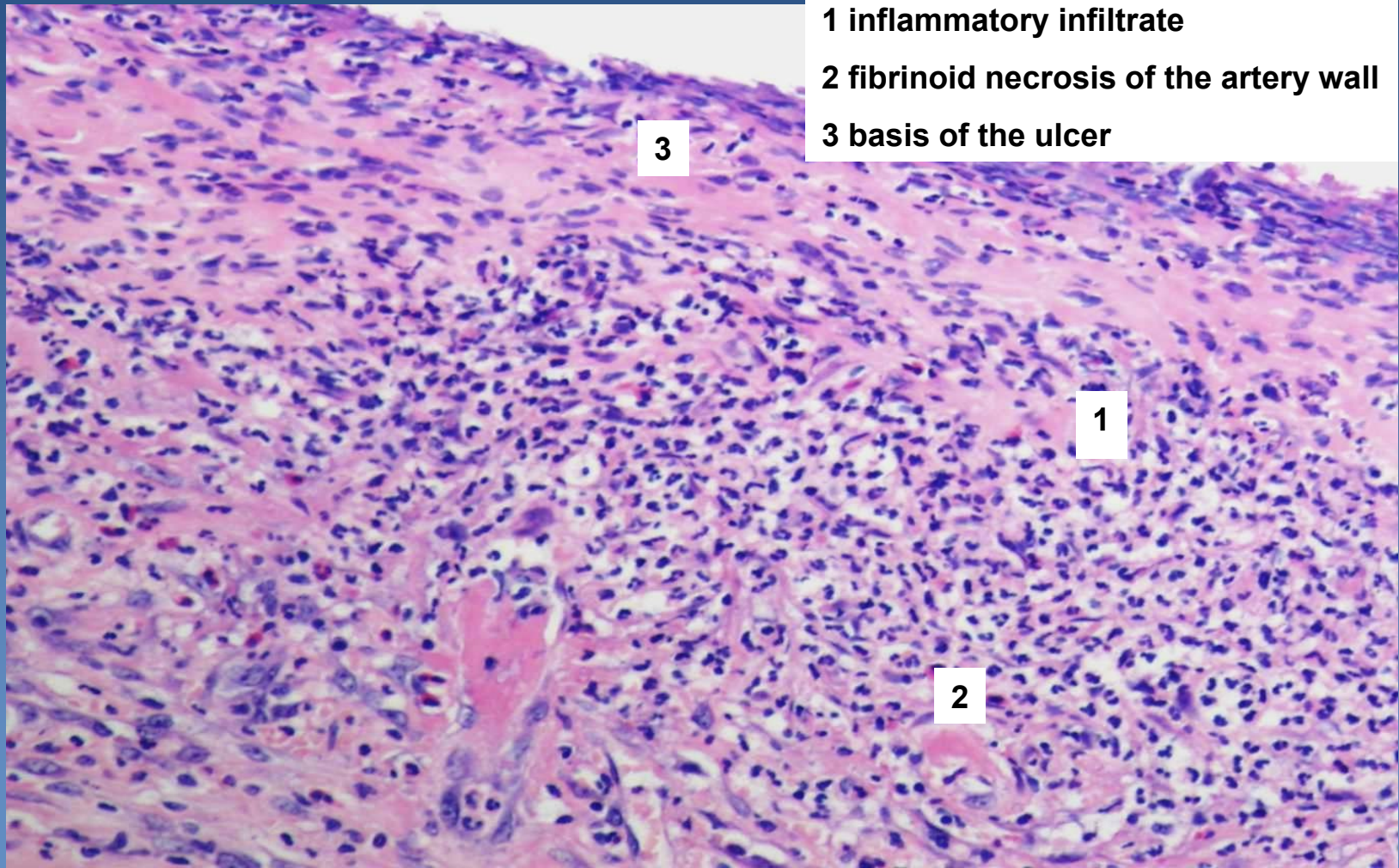
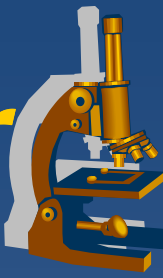- edges of the ulcer



- 1 ulcer margin
- 2 residual mucosa
- 3 ulcer basis
- 4 duodenal Brunner's glands



Chronic peptic duodenal ulcer ***- basis of the ulcer***

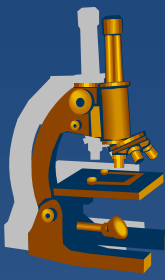


1 inflammatory infiltrate
2 fibrinoid necrosis of the artery wall
3 basis of the ulcer

3

1

2



Important gastric tumors

x PSEUDOTUMORS

⇒ *non-tumorous polyps (inflammatory, hyperplastic, fundic gland polyps)*

x EPITHELIAL

⇒ *adenoma (in the setting of chronic gastritis/intest. metaplasia)*

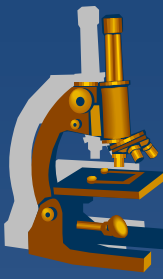
⇒ *malignant: carcinoma (adenoca, neuroendocrine ca, ...)*

x NON-EPITHELIAL

⇒ *gastrointestinal stromal tumors (GISTs)*

⇒ *lymphomas (NHL: MALT, DLBCL)*

Gastric carcinoma



- ✗ most common malignant gastric tumor
- ✗ location: antrum, pylorus, lesser curvature
- ✗ risk factors:
 - ⇒ *precursor lesions: chronic gastritis with intestinal metaplasia, infection with HP, intraepithelial neoplasia*
 - ⇒ *EBV, dietary carcinogenes (salted, smoked food), familial*
- ✗ clinical features:
 - ⇒ *vomiting, abdominal discomfort, weight loss, anorexia*
 - Direct spread into adjacent organs/tissues*
 - Metastases: LN regional, distant (Troisier's supraclavicular LN), portal circulation (liver), peritoneal dissemination, lung, ovarian **Krukenberg tumor** in females.*

Gastric carcinoma



Classification:

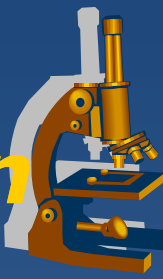
- ✘ macroscopical:
 - ⇒ *exophytic (polypous)*
 - ⇒ *excavated (ulcerated)*
 - ⇒ *infiltrative (linitis plastica)*
- ✘ depth of invasion:
 - ⇒ **early**: *only in mucosa and submucosa*
 - ⇒ **advanced**: *extended into the muscular wall*
- ✘ histological type

WHO *histological classification of gastric tumors*



- × Tubular
- × Papillary
- × Mucinous
- × Signet-ring cell
- × Adenosquamous
- × Squamous
- × Undifferentiated
- × Neuroendocrine

Lauren's histological classification



× Intestinal:

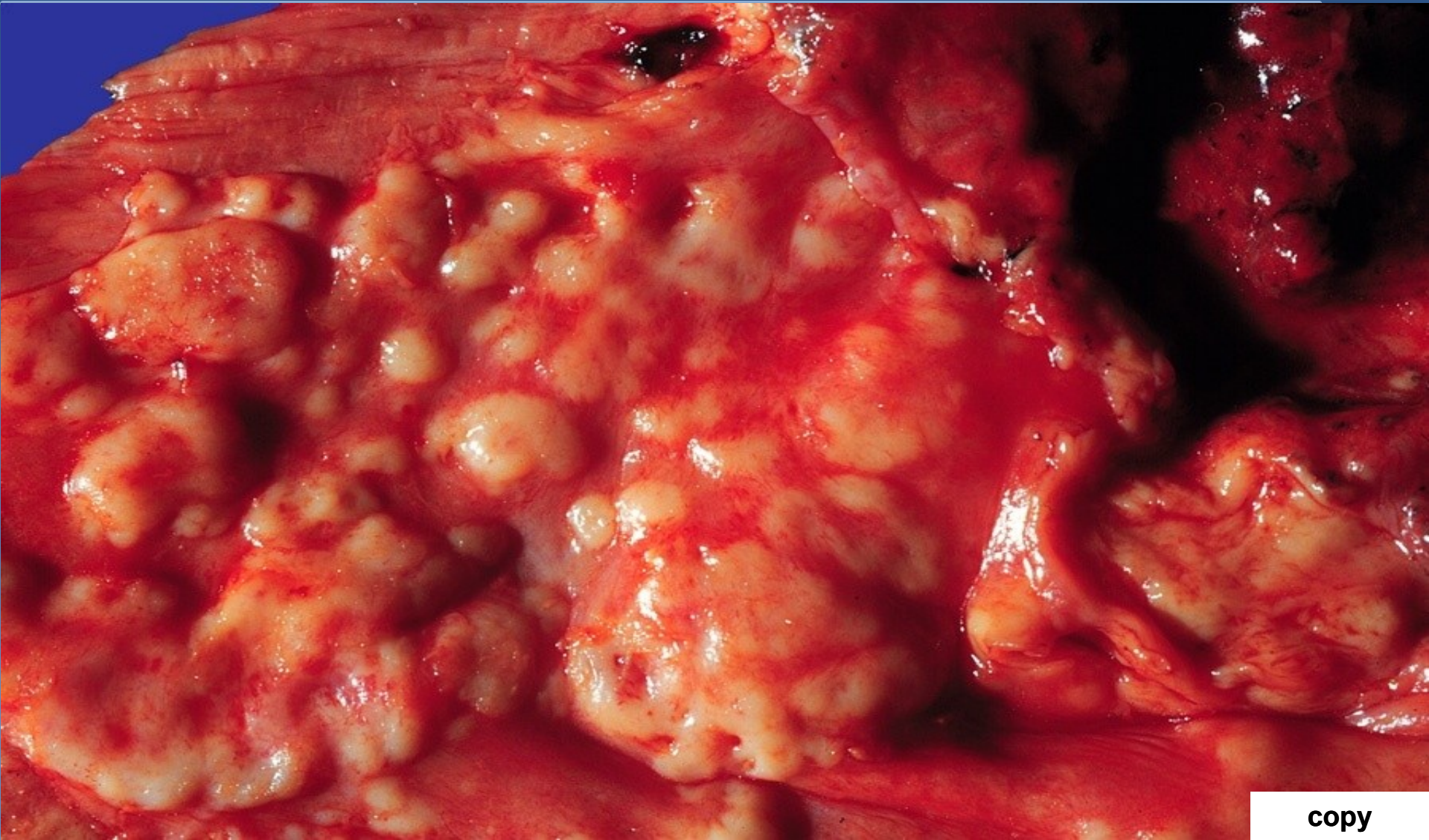
- ⇒ 50%, HP chronic gastritis, ↓ tendency
- ⇒ intestinal metaplasia-connected, neoplastic tubular glands/papillary formations, columnar epithelium, expansive growth
- ⇒ > 50 yrs, M:F 2:1

× Diffuse:

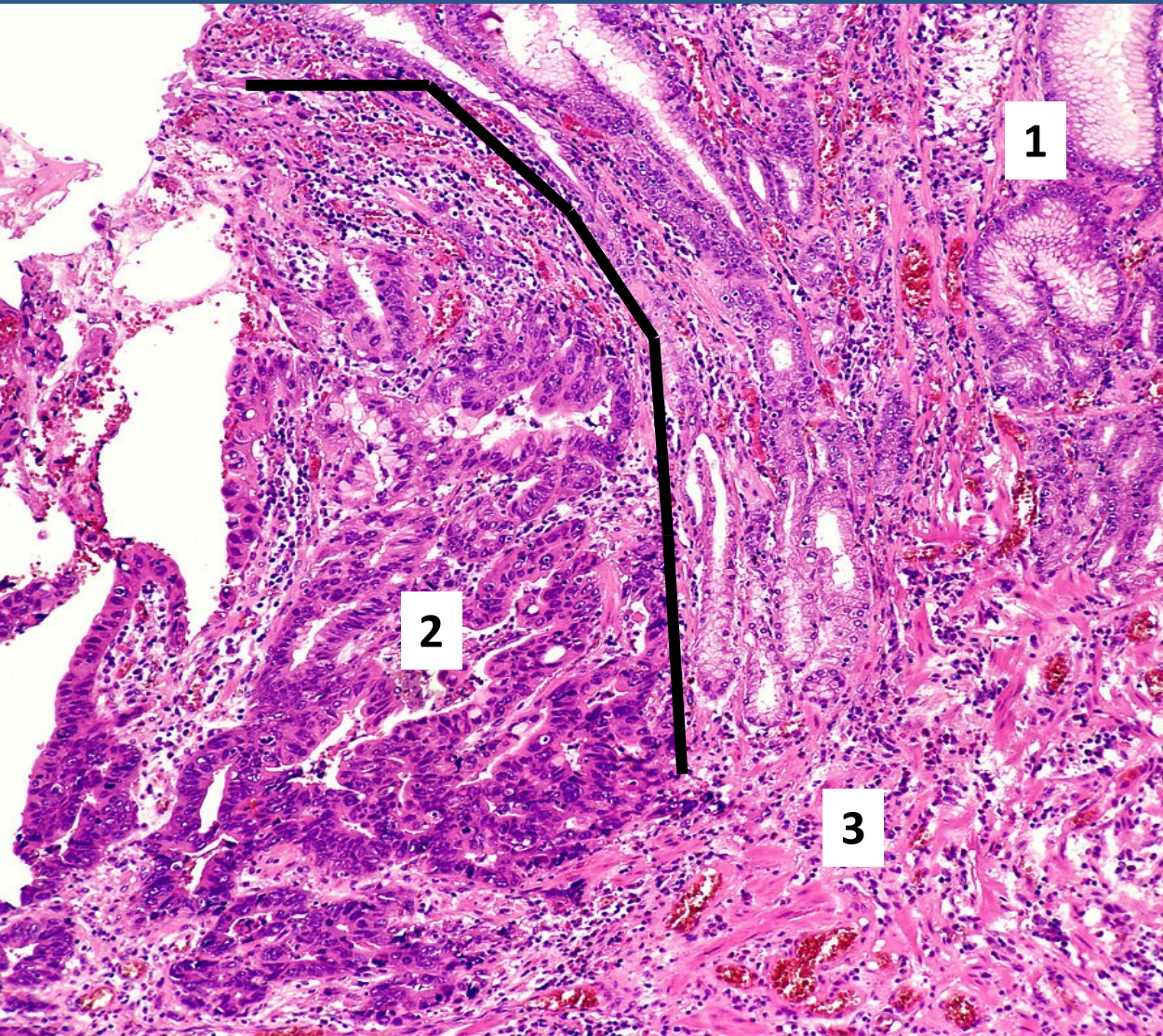
- ⇒ 30%, ↑ tendency
- ⇒ dissociated cells infiltrating singly / in small clusters into the stomach wall, signet-ring cells possible, reactive desmoplasia - fibrosis (scirrhous)
- ⇒ earlier age, M:F 1:1

× Mixed

Gastric adenocarcinoma ***- exophytic growth***



Gastric adenocarcinoma ***- intestinal type***



1

1 normal gastric mucosa

2

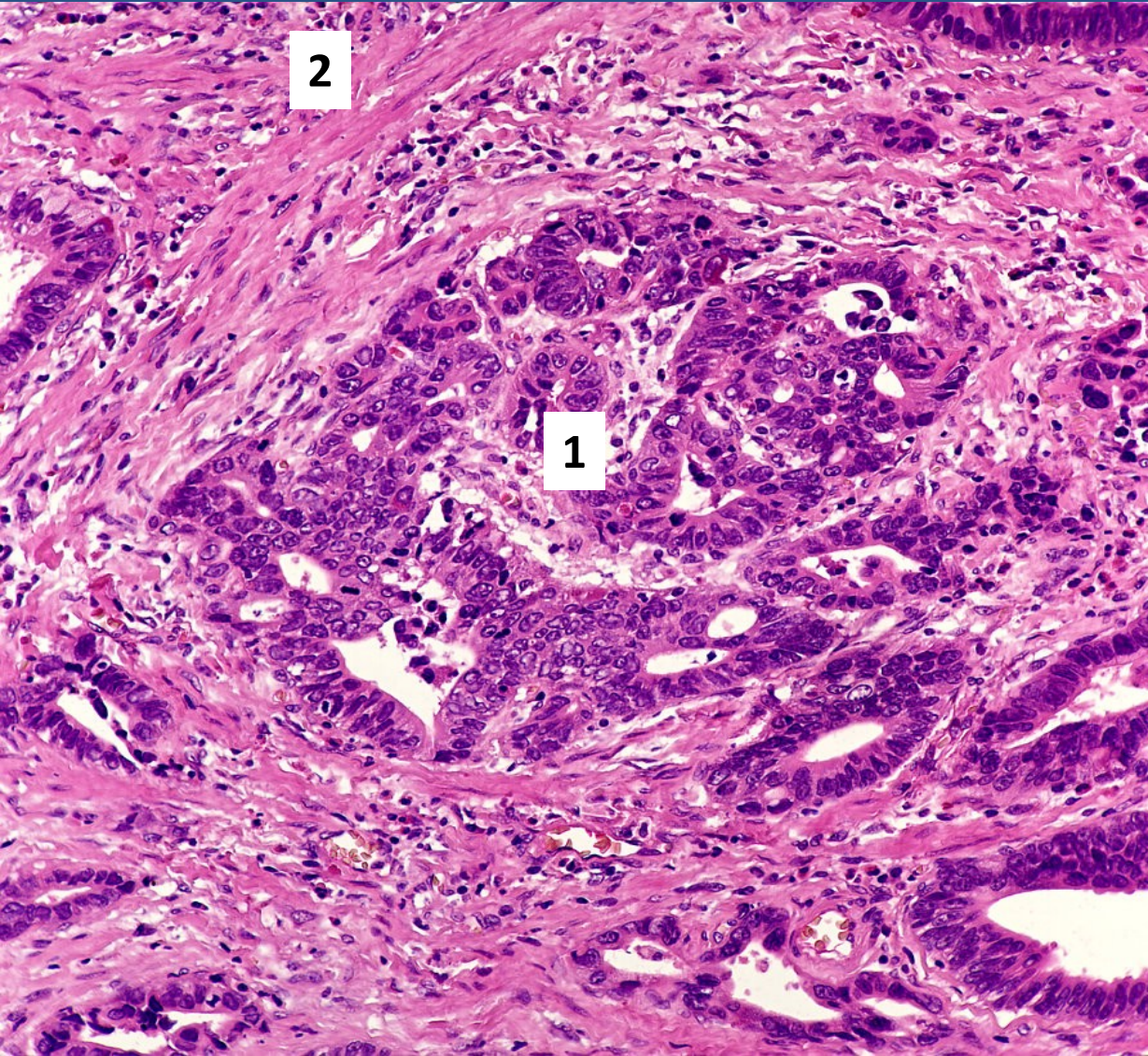
**2 tubopapillary
adenocarcinoma**

3

3 muscularis mucosae

**line - sharp demarcation
of the tumor from
normal mucosa**

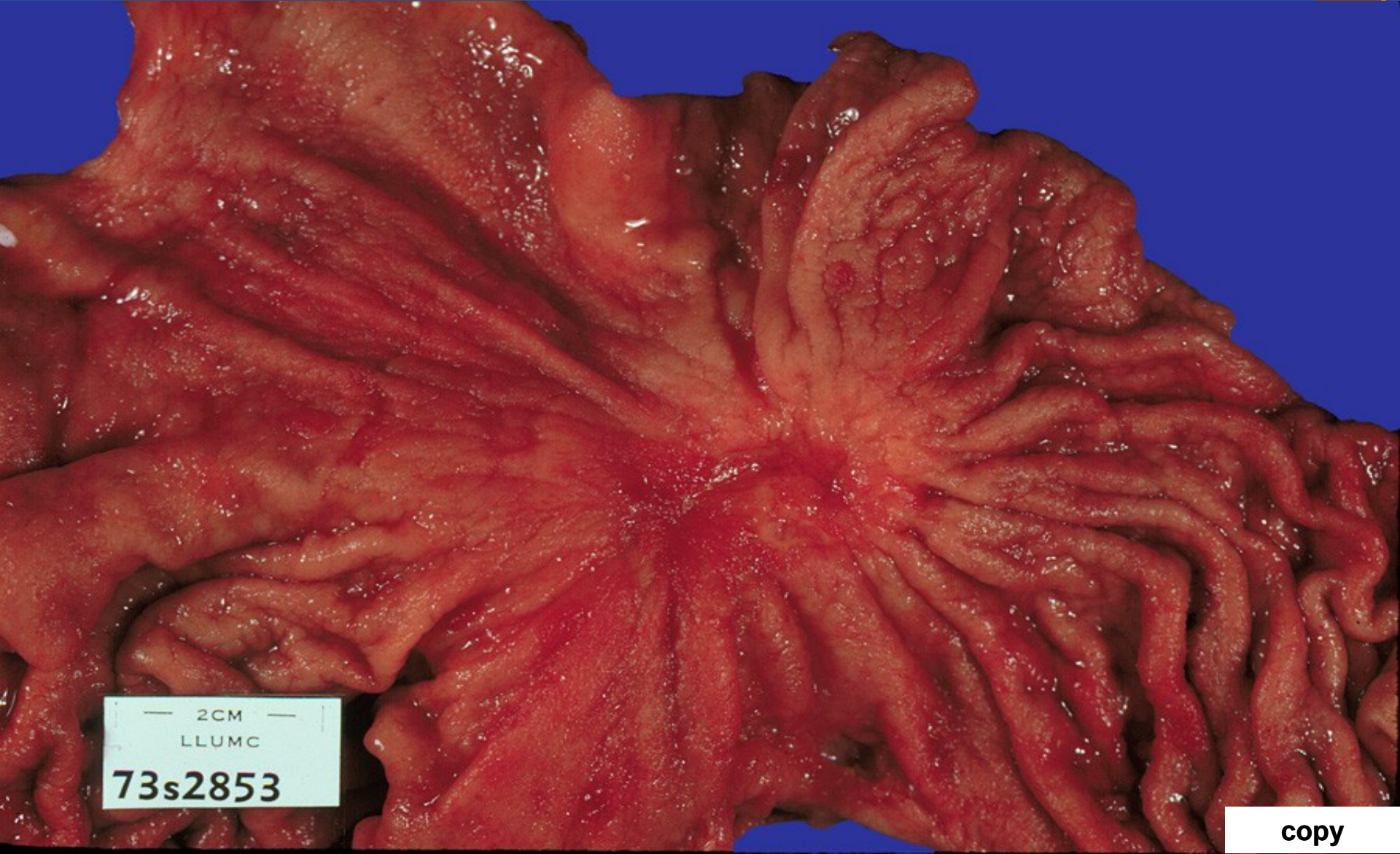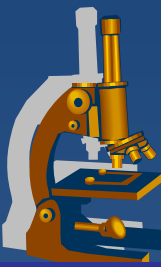
Gastric adenocarcinoma (intestinal type) infiltration into lamina muscularis propria



1 tumor cells

2 smooth muscle cells

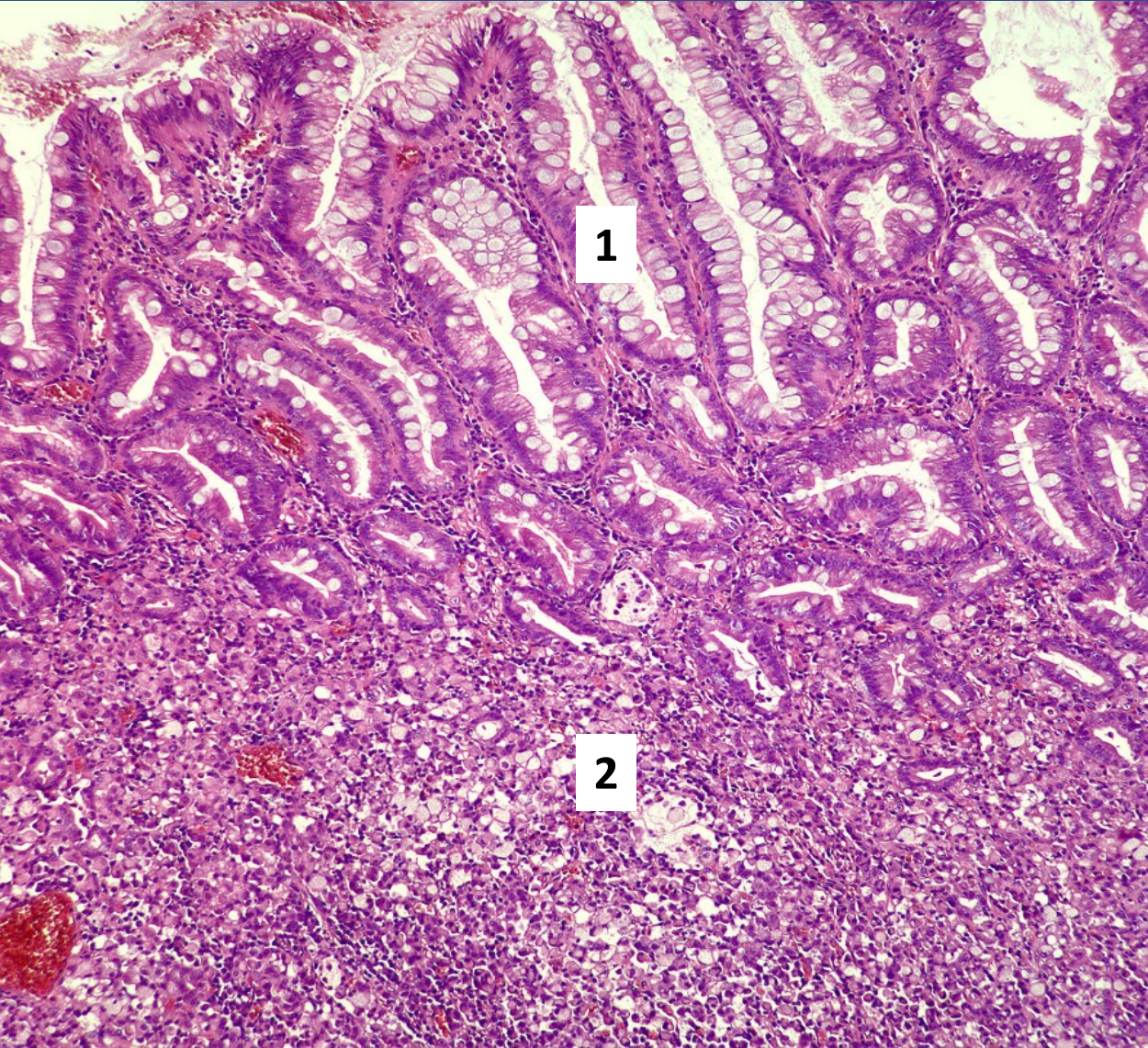
Gastric adenocarcinoma ***- diffuse type***



— 2CM —
LLUMC
73s2853


copy

Gastric adenocarcinoma *- diffuse type*

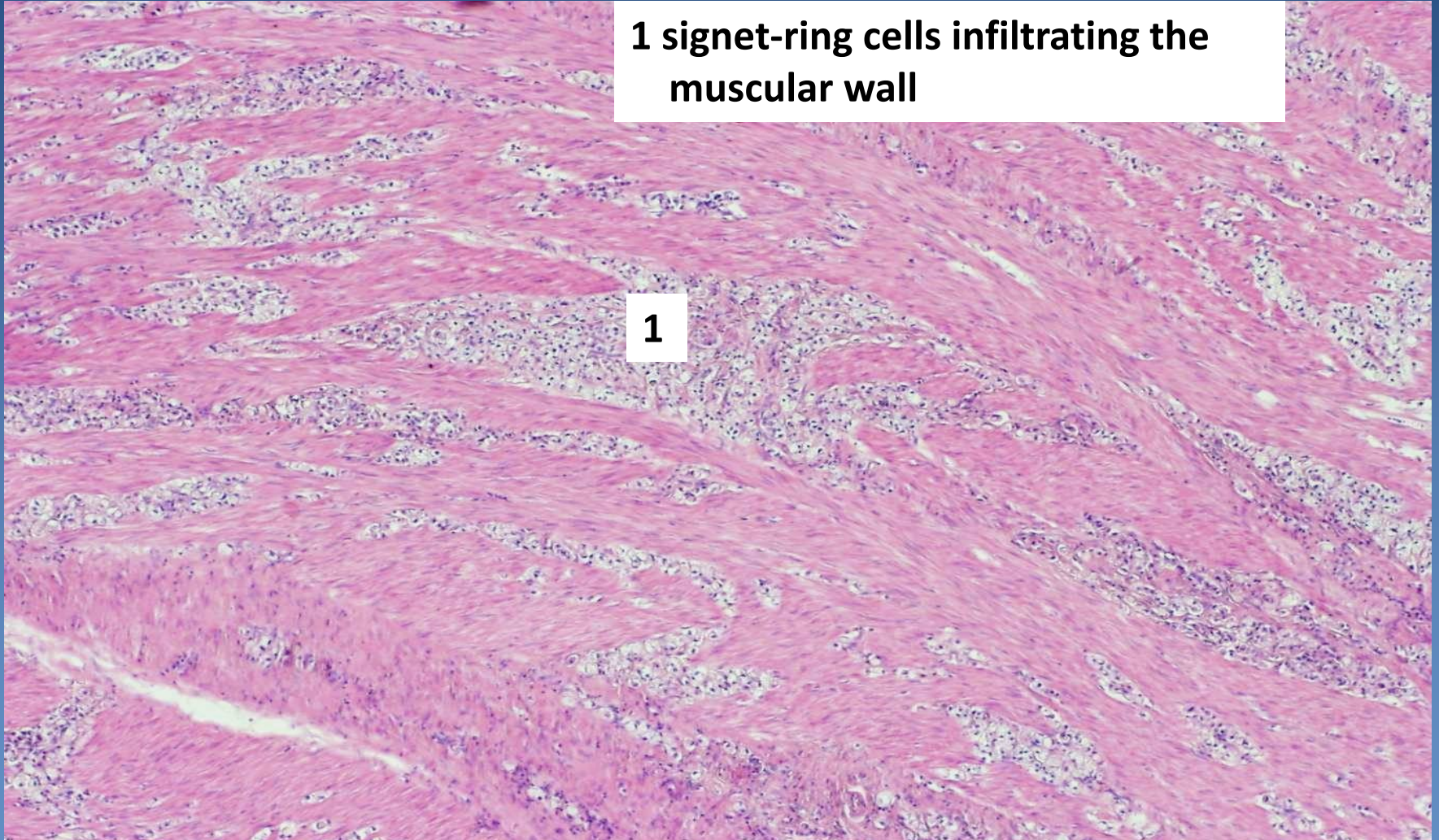


1 intestinal metaplasia
of the mucosa

2 diffuse infiltration with
signet-ring cells



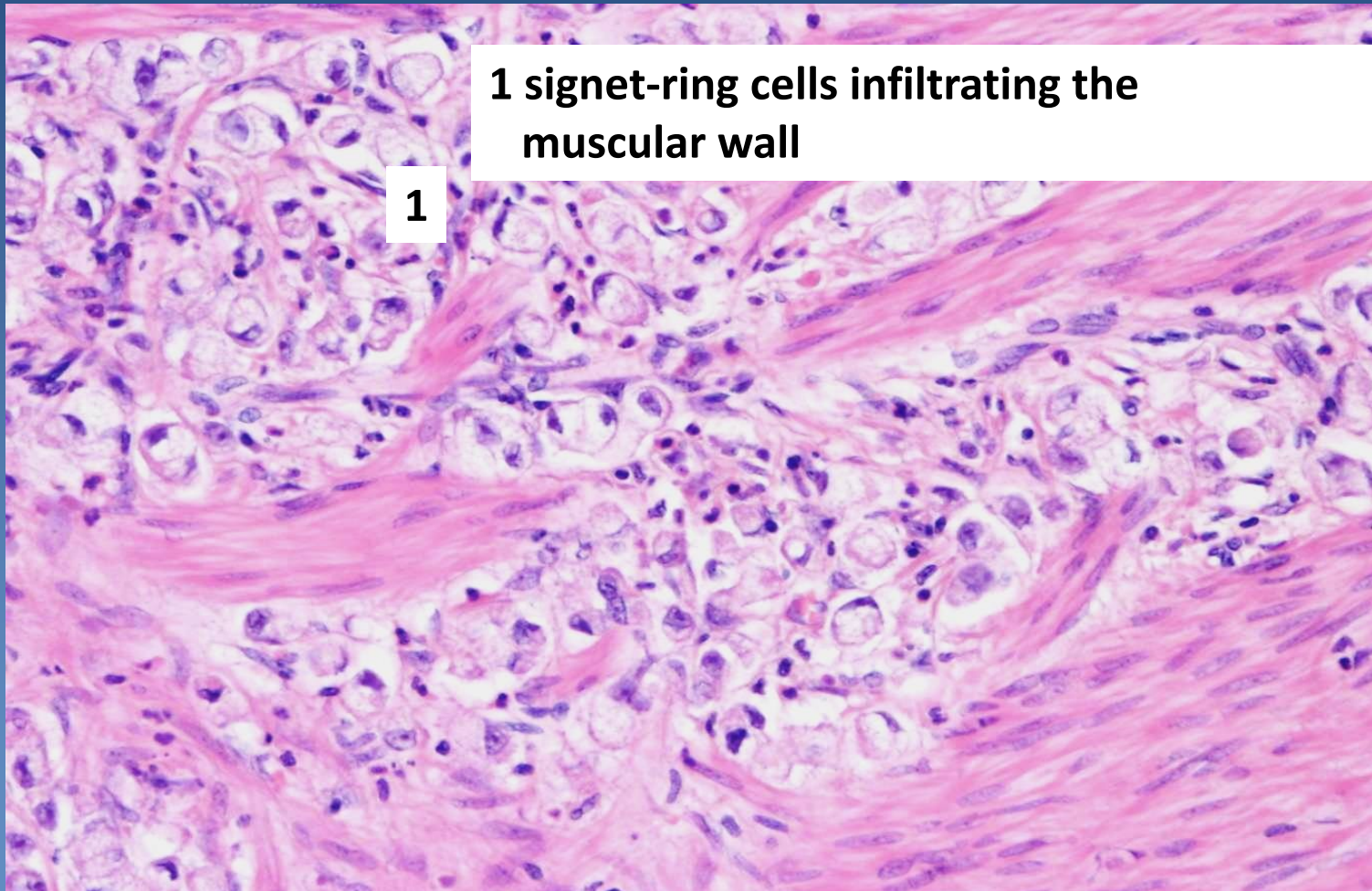
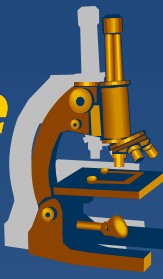Gastric adenocarcinoma - diffuse type ***- infiltration into lamina muscularis propria***



1 signet-ring cells infiltrating the muscular wall

1

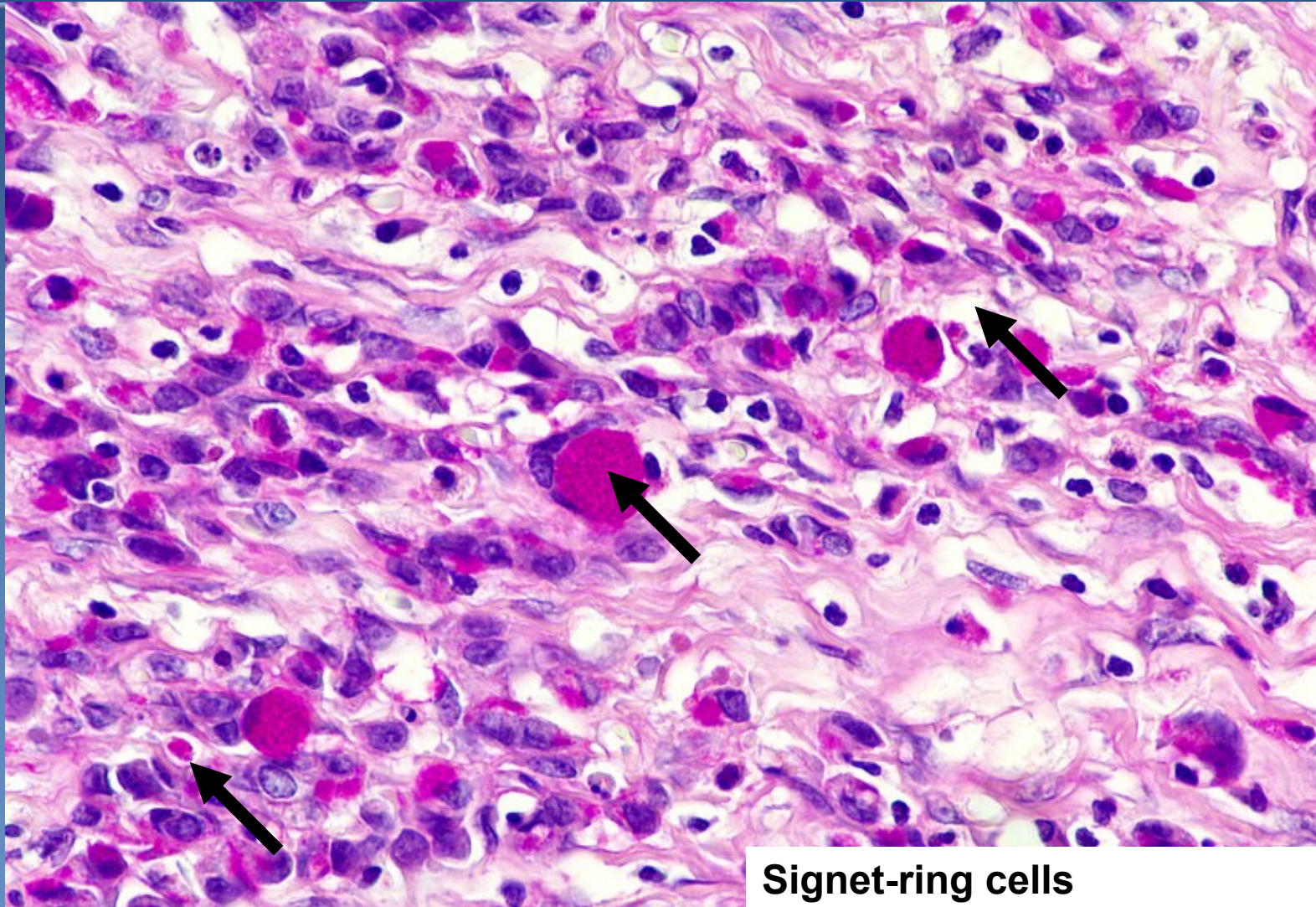
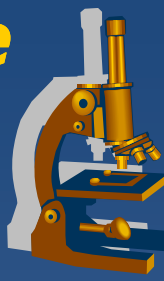
Gastric adenocarcinoma - diffuse type detail



1 signet-ring cells infiltrating the muscular wall

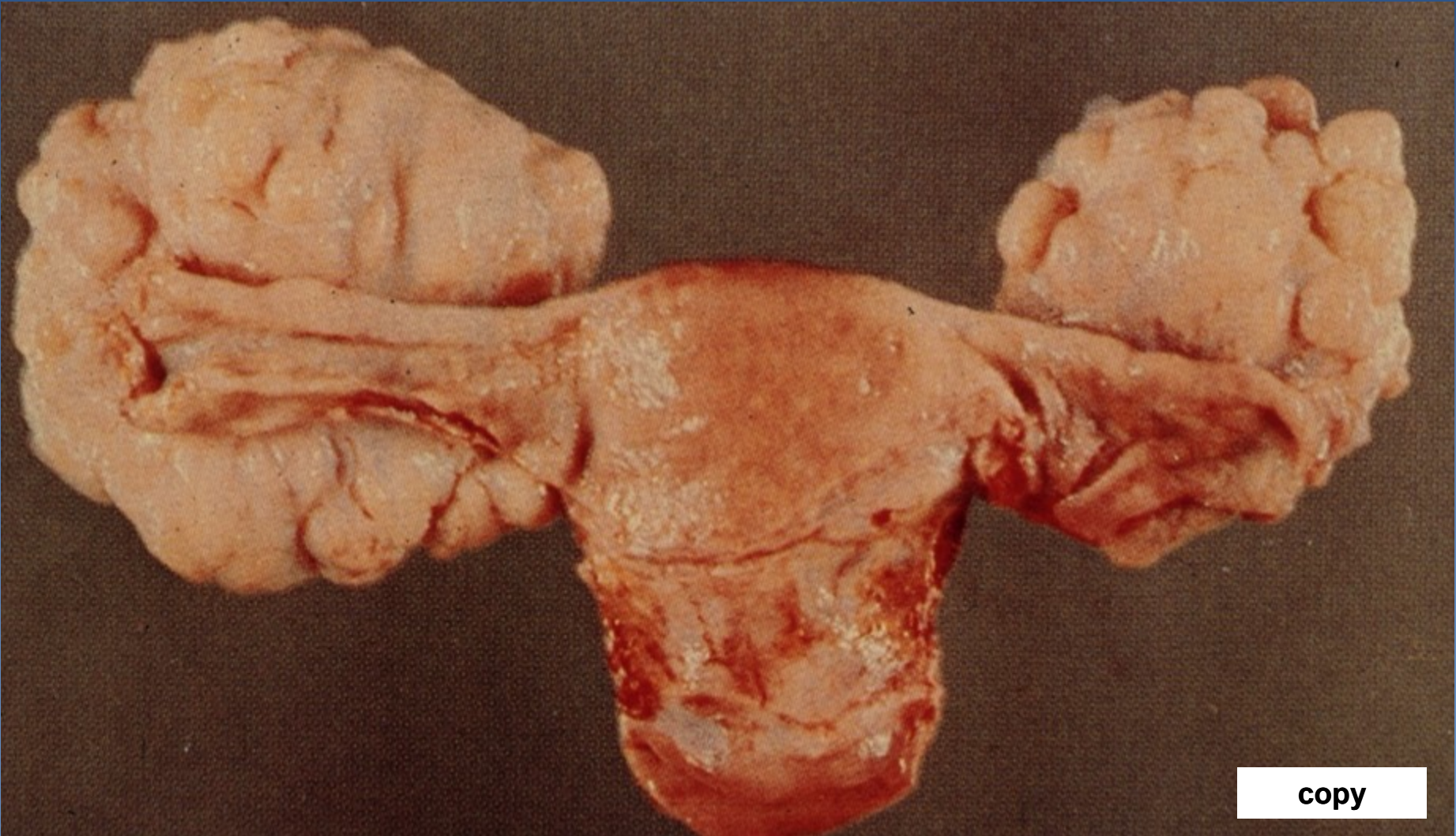
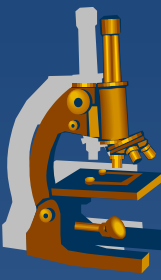
1

Gastric adenocarcinoma - diffuse type detail (PAS)



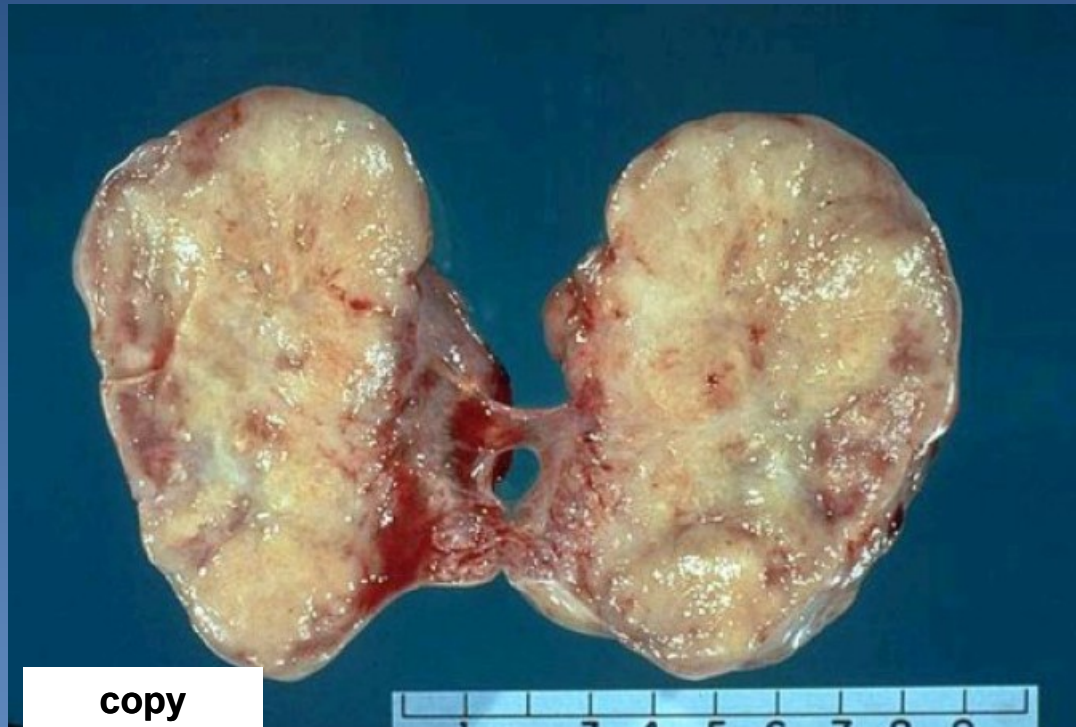
Signet-ring cells

Krukenberg tumor



copy

Krukenberg tumor

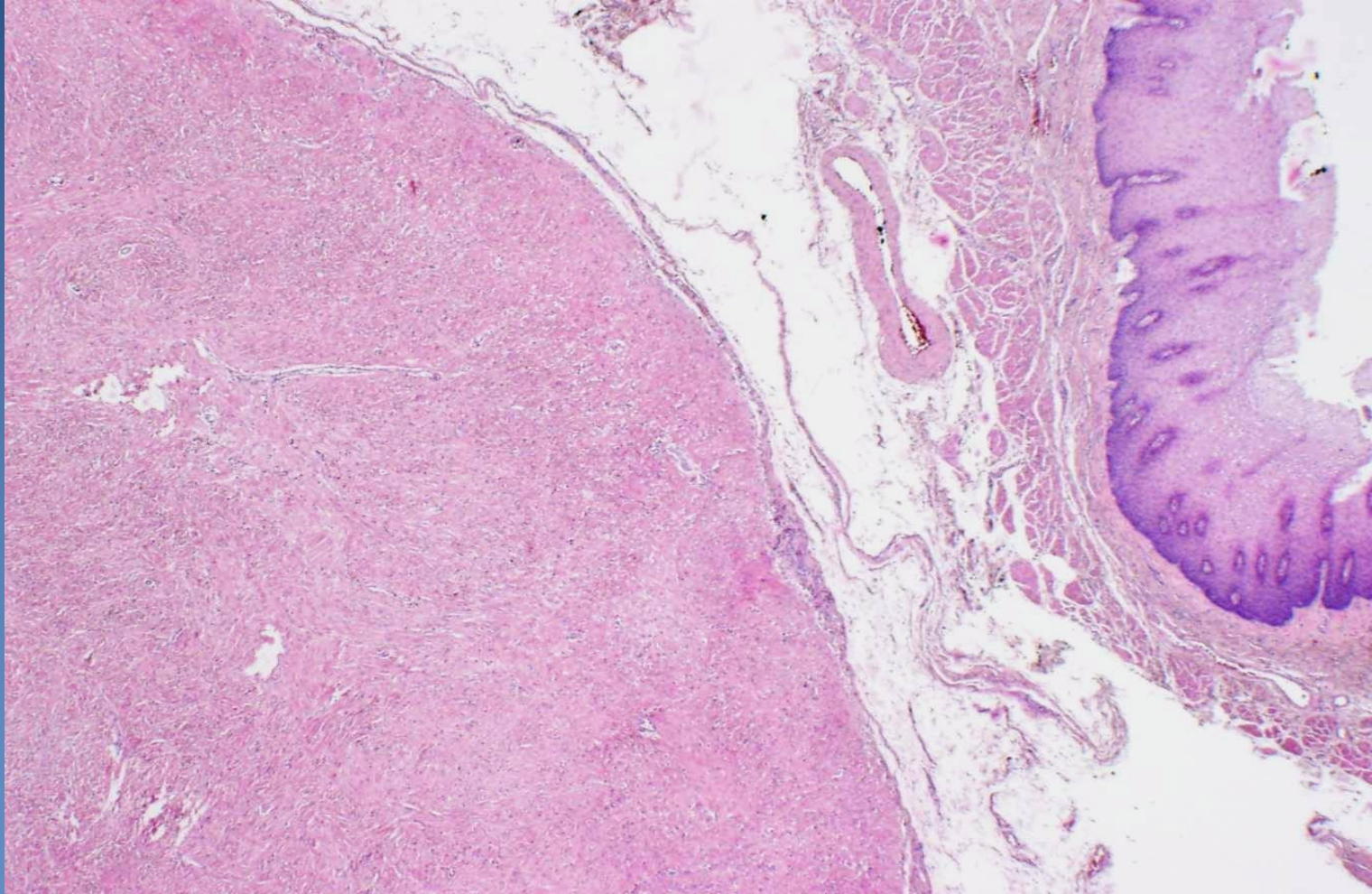


Gastrointestinal stromal tumors (GISTs)

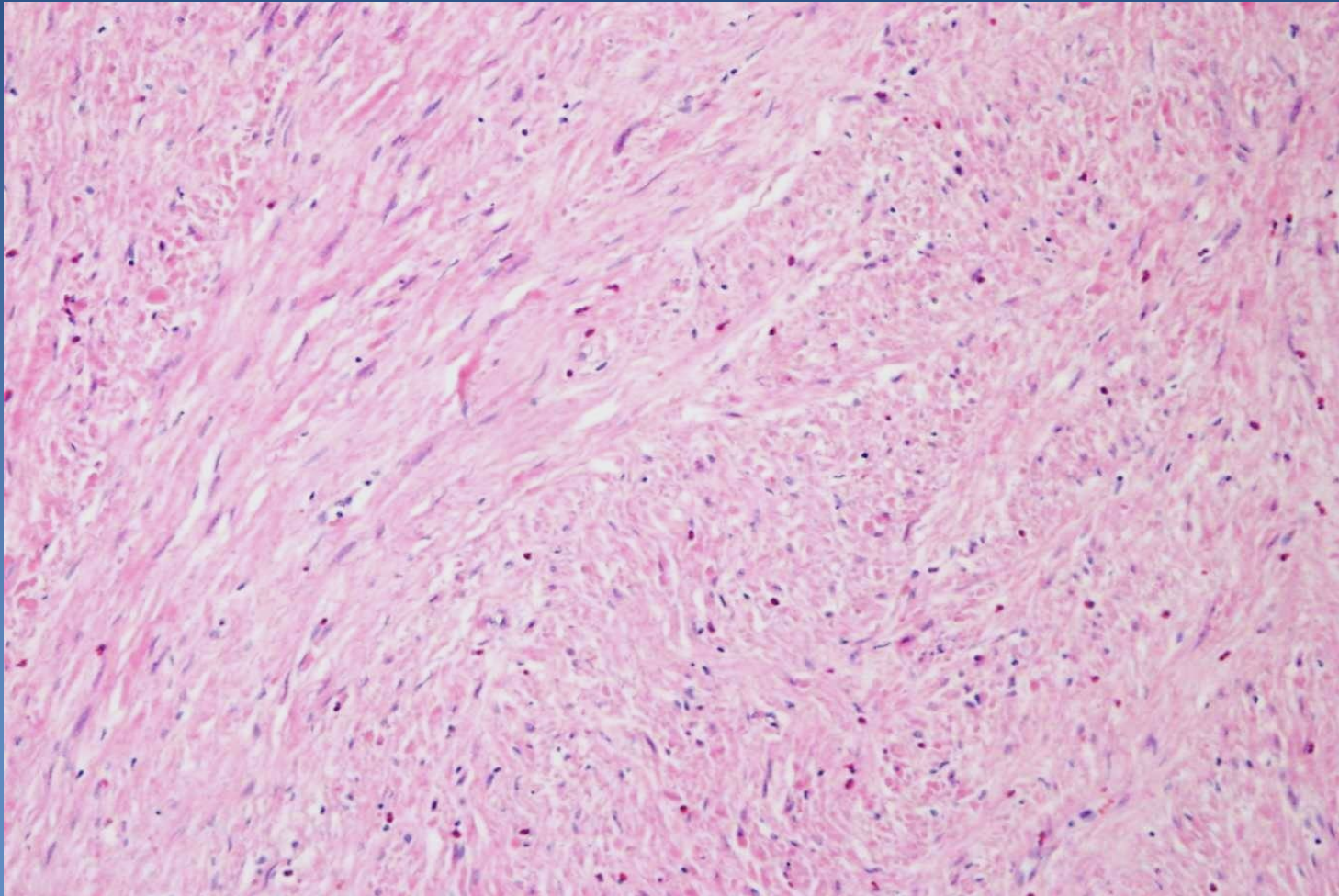
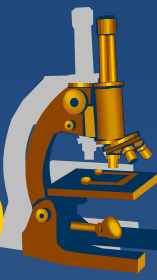


- ✘ mesenchymal tumors
- ✘ arising from intestinal cells of Cajal (pacemaker cells controlling peristalsis)
- ✘ origin anywhere in the GIT: predominantly the stomach and small intestine
- ✘ spindle-like or epitheloid cells, IHC CD117+,
- ✘ biologic behaviour prognosis :
 - ⇒ *according to mitotic rate, size, localization*

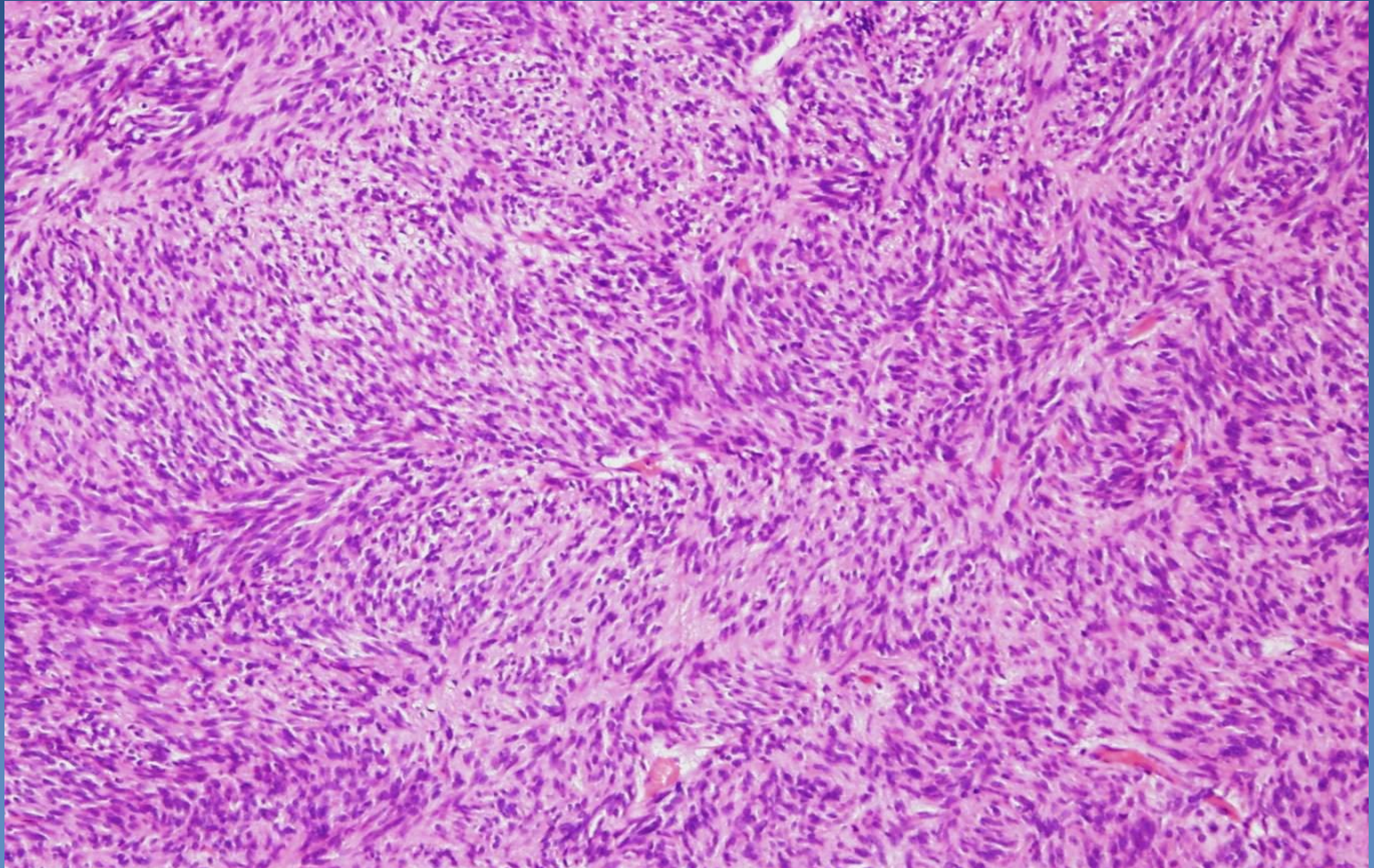
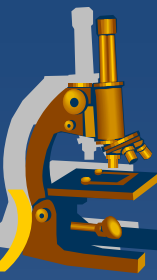
Oesophageal GIST



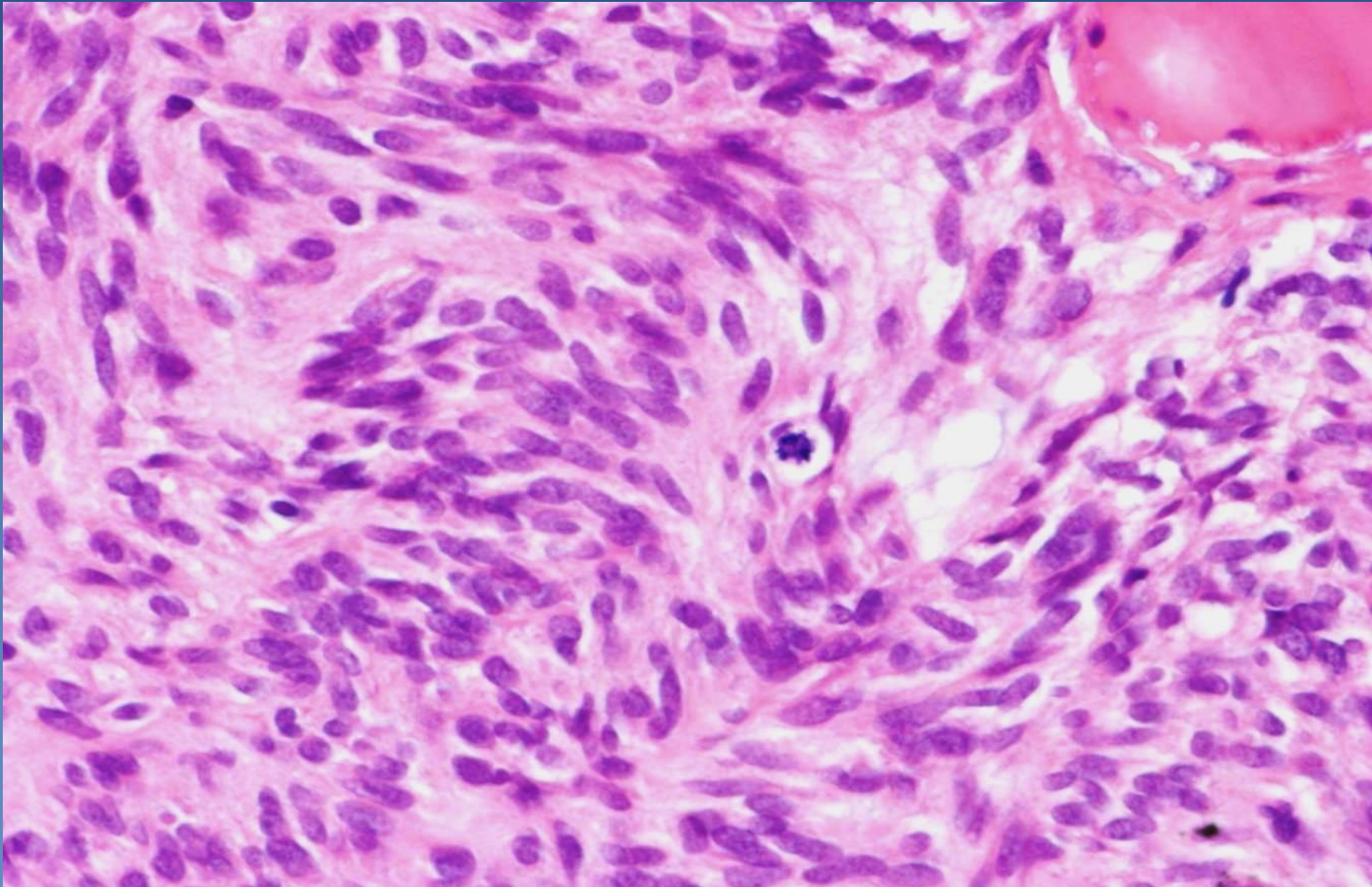
Oesophageal GIST - detail (spindle-like cells, low malignancy)



Oesophageal GIST - detail (spindle-like cells, highly malignant)

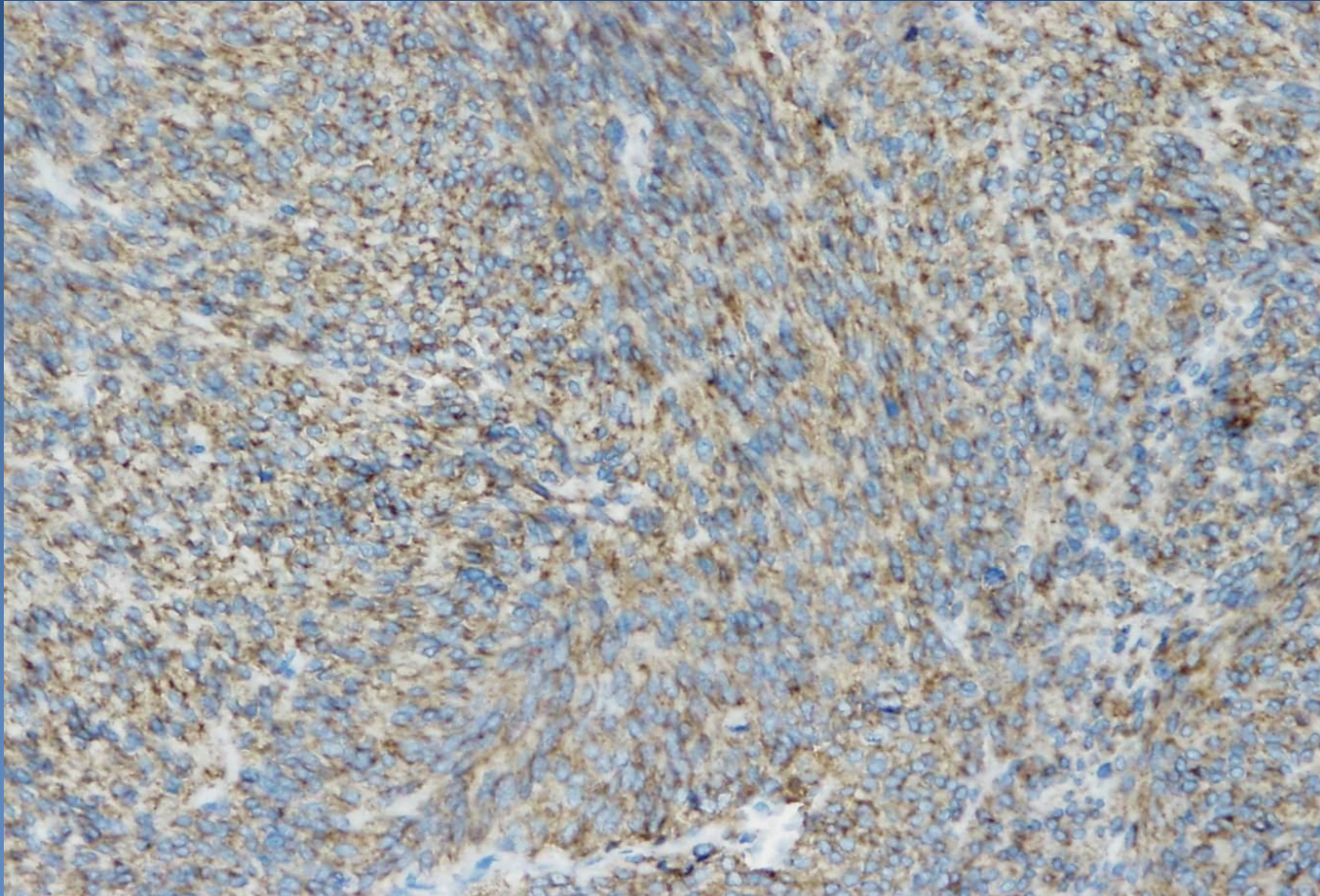
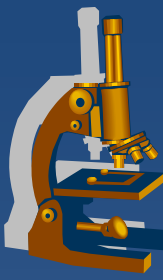


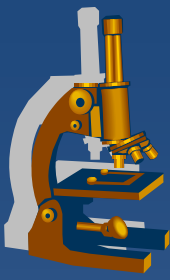
***Intestinal GIST - detail
(spindle-like cells, highly
malignant)***



Intestinal GIST

IHC CD117 positivity





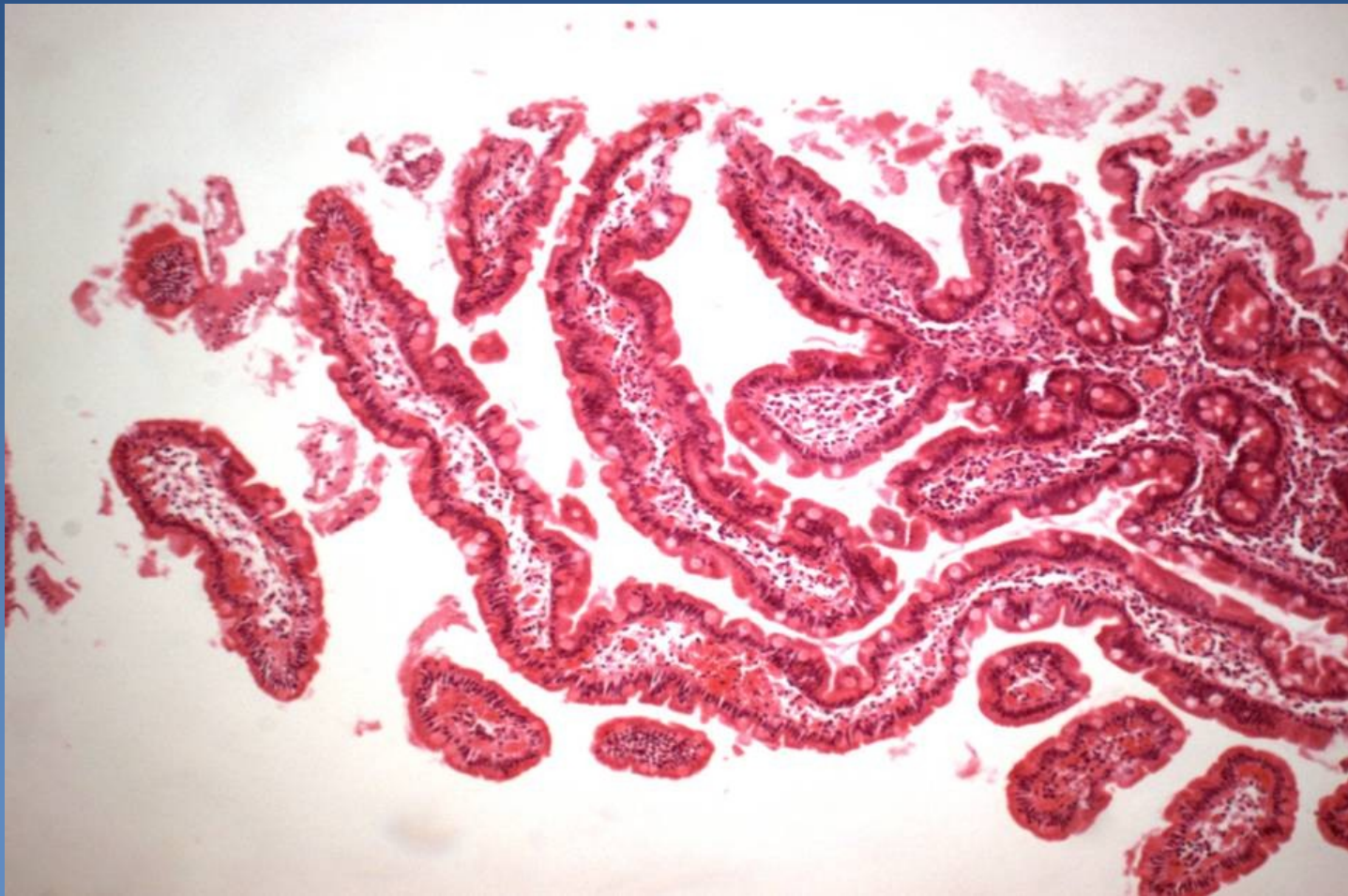INTESTINES

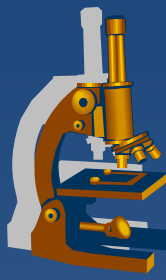
Normal mucosa of the small intestine



- x villi to crypts height ratio 3:1 – 5:1**
- x standard number of intraepithelial lymphocytes: 40 IEL / 100 enterocytes**
 - ⇒ *brush border – microvilli (PAS+, alkaline phosphatase +)*
 - ⇒ *differentiated enterocytes*

Normal villi of the small intestine





Malabsorption syndromes

- x a group of symptoms resulting from an alteration in the digestion / absorption of nutrients mostly in the small intestine
- x symptoms:
 - ⇒ *anorexia, diarrhea, steatorrhea, weakness, weight loss, abdominal distention,*
 - ⇒ *growth disturbances, eczema, neurologic/psychologic disturbances, bleeding disorders, anaemia, tetany*
- x disturbance of:
 - ⇒ **digestion** *intraluminal, terminal in the brush border*
 - ⇒ **mucosal absorption** - *enterocytes abnormalities, reduced intestinal surface area*
 - ⇒ *lymphatic transport*



Malabsorption syndromes

- x** Classification

 - ⇒ ***primary*** – enterocytes' disorder (inborn, acquired)

 - ⇒ ***secondary*** – cause apart from enterocytes

- x** commonly mixed causes

Defects of mucosal absorption



- ✘ **Brush border enzymatic deficiency** (lactose intolerance – lactase deficiency)

- ✘ **Celiac disease** gluten (gliadin)-sensitive enteropathy

Celiac disease



- x prevalence 0,5-1% in Caucasian Europeans
- x associated with dermatitis herpetiformis
Duhring, DM I., Sjögren sy, etc.
- x immunological sensitivity to gluten (component
of wheat)
- x antibodies EMA, ARA, TG (non-specific anti-
gliadin)
- x genetic (HLA), immune, exogenous factors

Celiac disease



- x gluten-free diet necessary, sm. lifelong
- x risk of malignant disease:
 - ⇒ *malignant lymphomas (T-cell), carcinomas of the small intestine*
- x clinical
 - ⇒ *infancy (6-24 m.), adults 30-60 yrs; silent, latent*
- x symptoms:
 - ⇒ *irritability, diarrhoea, fatigue...*
- x endoscopy:
 - ⇒ *loss of mucosal folds, mosaic mucosal pattern, prominence of the submucosal vessels*

Celiac disease



- ✘ micro: most changes in the proximal part of the small intestine
- ✘ basic histologic features:
 - ⇒ *increased number of intraepithelial T-cells*
 - ⇒ *inflammatory infiltrate (plasma cells, eosinophils, neutrophils, T-cells) in lamina propria mucosae*
 - ⇒ *villous atrophy*
 - ⇒ *reactive hyperplasia (elongation) of the crypts*

Marsh classification 0-IV



- ✘ Stage 0: normal mucosa
- ✘ Stage I: infiltrative
 - ⇒ *increased number of IEL*
- ✘ Stage II: hyperplastic
 - ⇒ *proliferation of the crypts*
- ✘ Stage III: destructive
 - ⇒ *villous atrophy*
- ✘ Stage IV: hypoplastic
 - ⇒ *crypt hypoplasia, loss of villi*

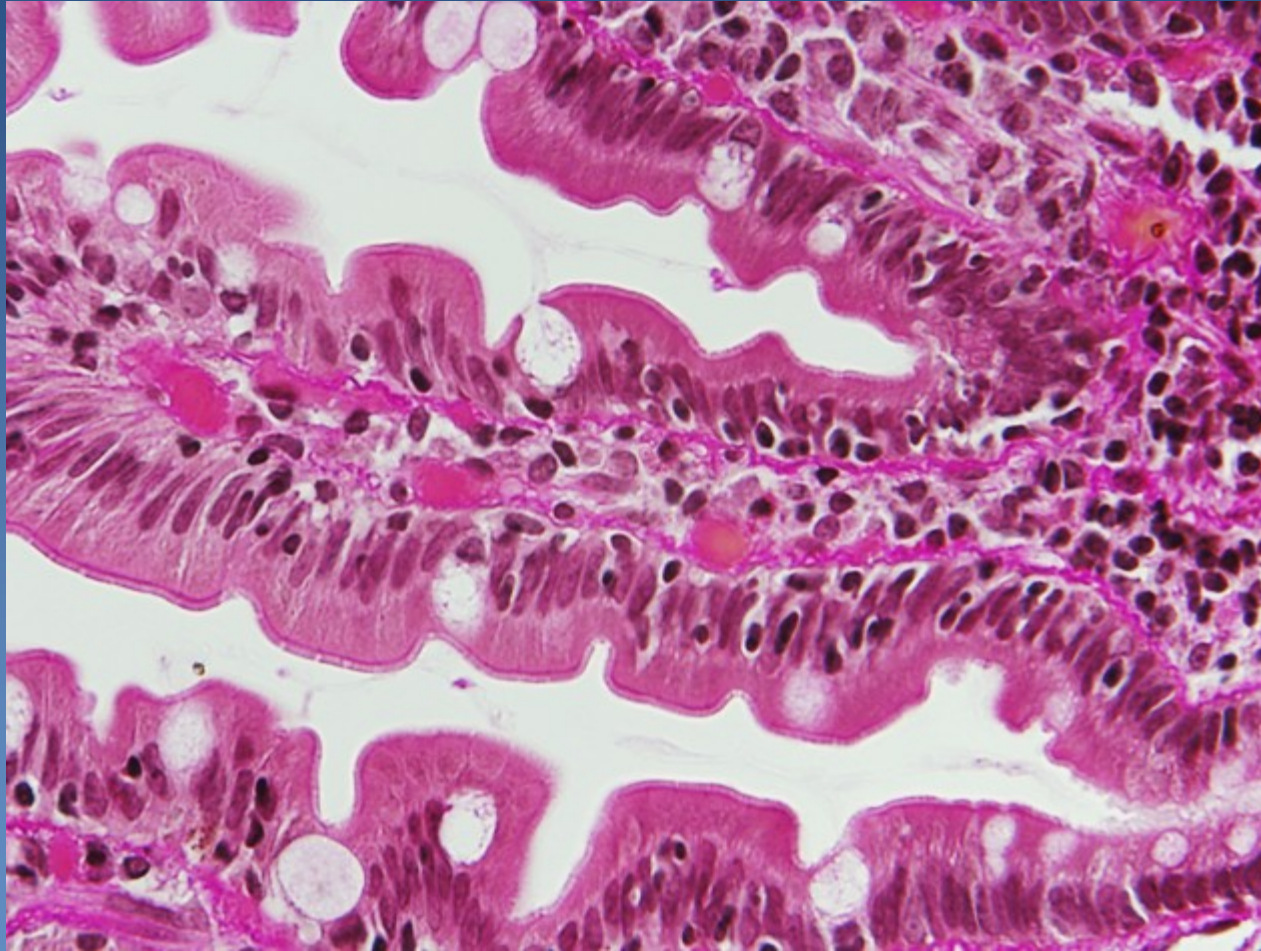
Celiac disease



- ✘ IEL – specific activated CD8+ T-cell subpopulation
- ✘ direct cytotoxic activity – killing of enterocytes
- ✘ increased enterocytes' turnover
- ✘ non-specific histology – diff. dg. alimentary allergies, viral infections, giardiasis, tropical sprue

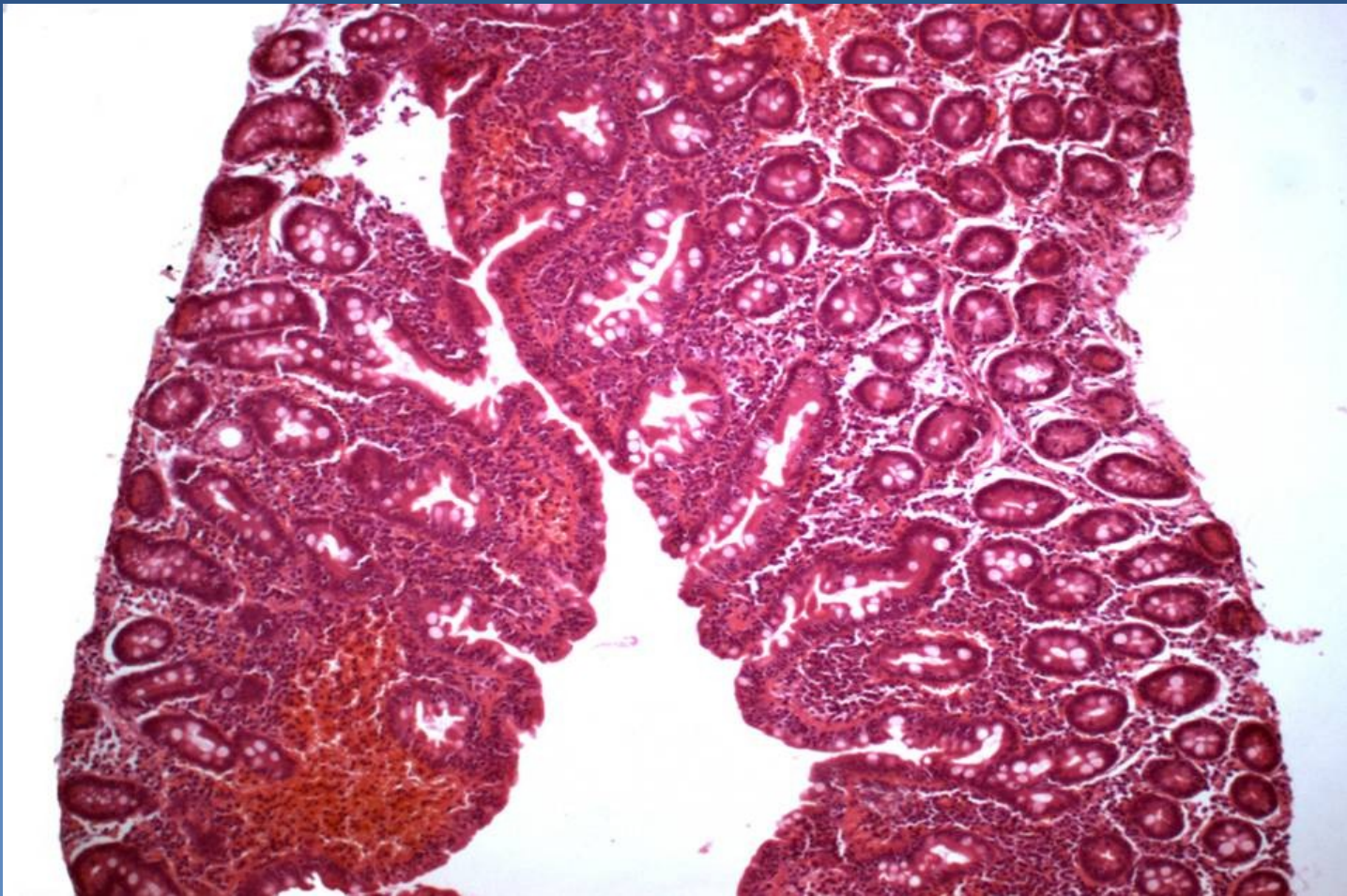
Celiac disease

Marsh I

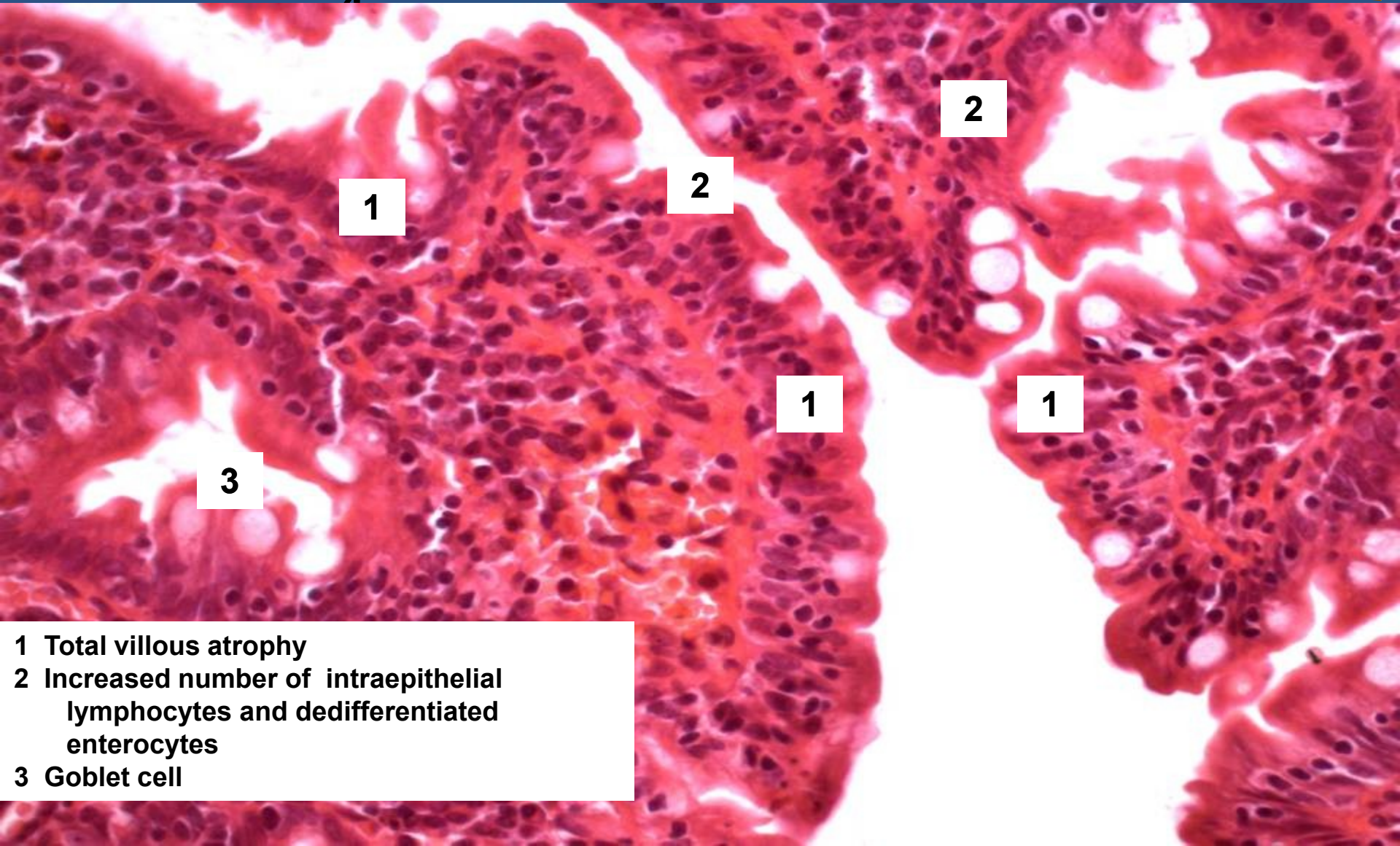
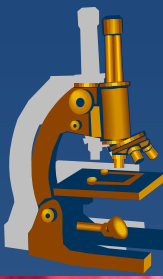


Celiac disease

Marsh IIIc



Celiac disease atrophic mucosa - detail



1

2

2

1

1

3

- 1 Total villous atrophy
- 2 Increased number of intraepithelial lymphocytes and dedifferentiated enterocytes
- 3 Goblet cell

Inflammatory bowel disease (IBD)



- ✗ idiopathic, chronic relapsing inflammatory disorders of not completely known origin
- ✗ genetic predisposition, immunologic factors
- ✗ etiology:
 - ⇒ *aberrant local immune response to exogenous stimulus (microbiome) → increased transepithelial permeability → inflammation acceleration*
- ✗ **Crohn disease**
- ✗ **Ulcerative colitis**
- ✗ **Indeterminated colitis (10-15%)**

IBD



x common histologic features:

- 1) abnormal crypt architecture**
- 2) crypt atrophy**
- 3) dense inflammatory infiltrate in lamina propria, basal plasmacytosis**
- 4) Paneth cell metaplasia in the left colon**

Crohn's disease



x Clinical features:

- ⇒ *recurrent attacks of diarrhea, abdominal pain, fever*
- ⇒ *abrupt beginning, lasting days to weeks, symptom-free intervals,*
- ⇒ *common other AI diseases:*
 - iritis, ankylosing spondylitis, erythema nodosum, PSC

x Gross:

- ⇒ ***terminal ileum***, or anywhere else in the GIT (oral-anus)
- ⇒ ***sharply demarcated , segmental lesions and skip lesions:***
 - shallow → longitudinal ulcers
 - wall stenosis and thickening, fissuring, fistulae

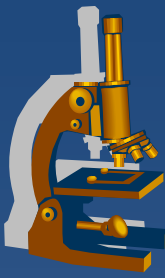
Crohn's disease



x Histology:

- ⇒ **transmural** inflammatory infiltrate
- ⇒ formation of lymphatic follicles/germinal centres
- ⇒ **non-caseating granulomas** (not always present) in submucosa, subserosa and regional lymph nodes
- ⇒ fissuring, ulceration
- ⇒ fibrosis

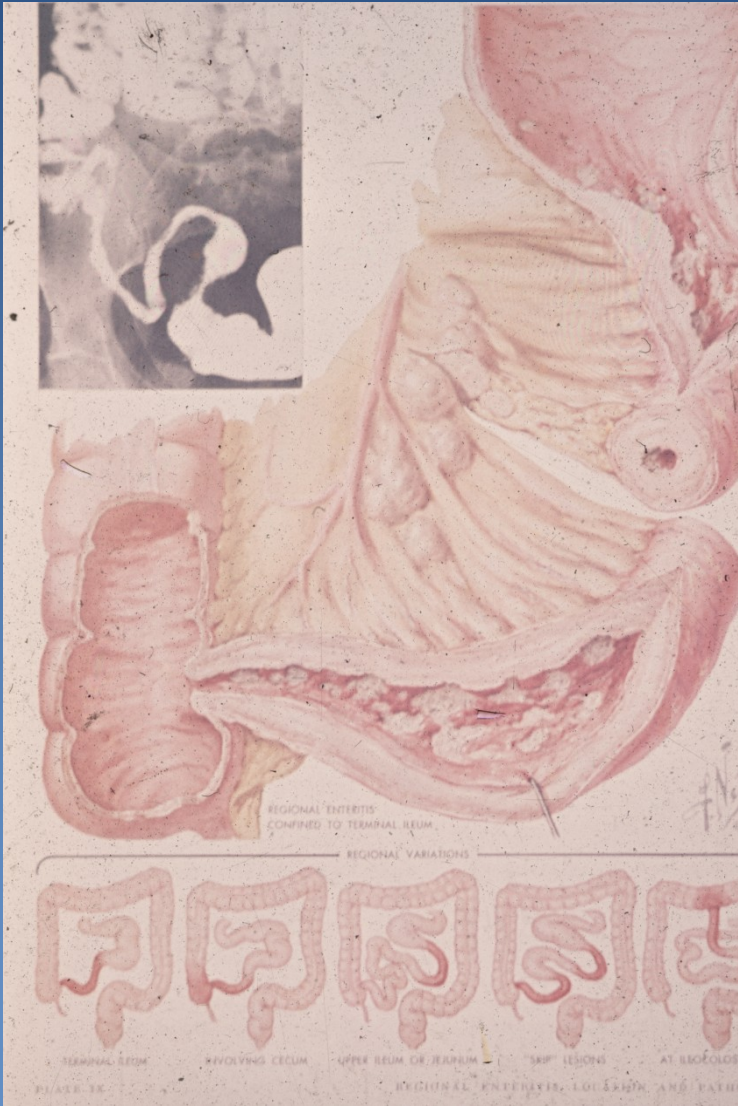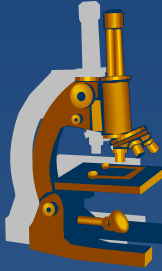
Crohn's disease



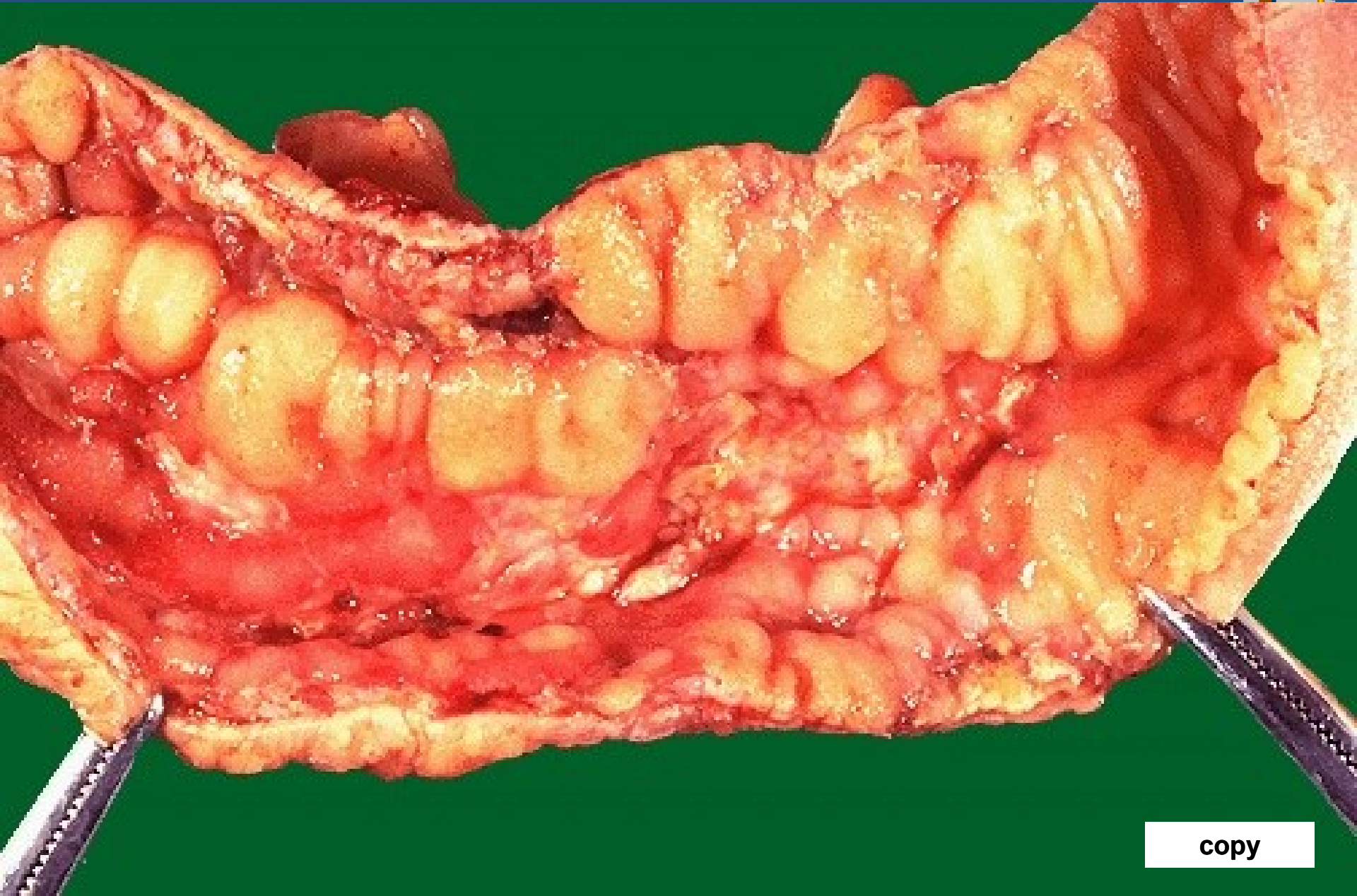
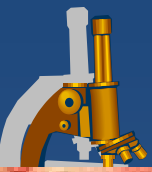
x *Complications:*

- ⇒ narrowed lumen, intestinal strictures, obstruction*
- ⇒ malabsorption, protein loss*
- ⇒ perforation, peritonitis, fistulae formation*
- ⇒ hemorrhage*
- ⇒ systemic AA amyloidosis*
- ⇒ carcinoma*

Crohn's disease

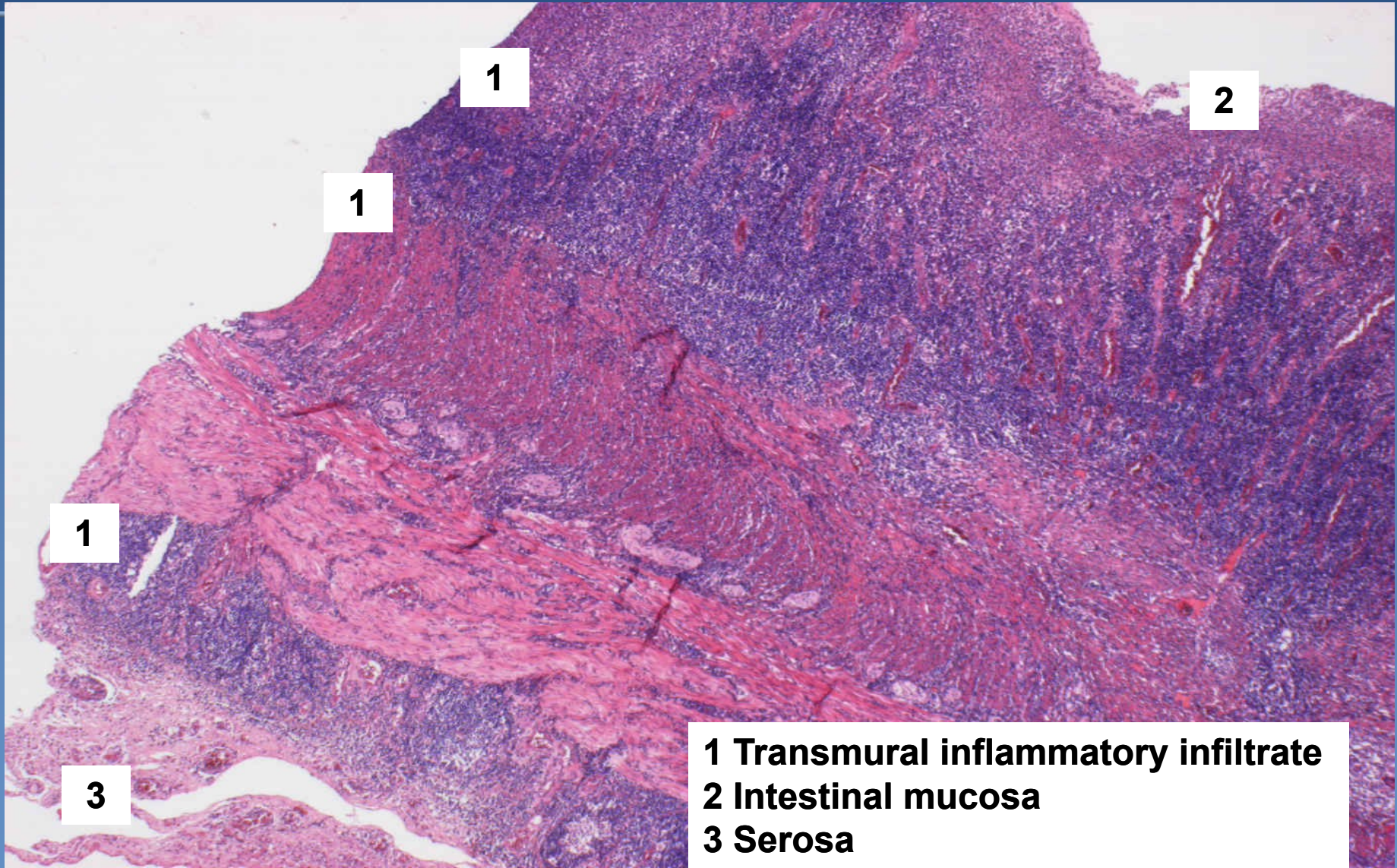


Crohn's disease



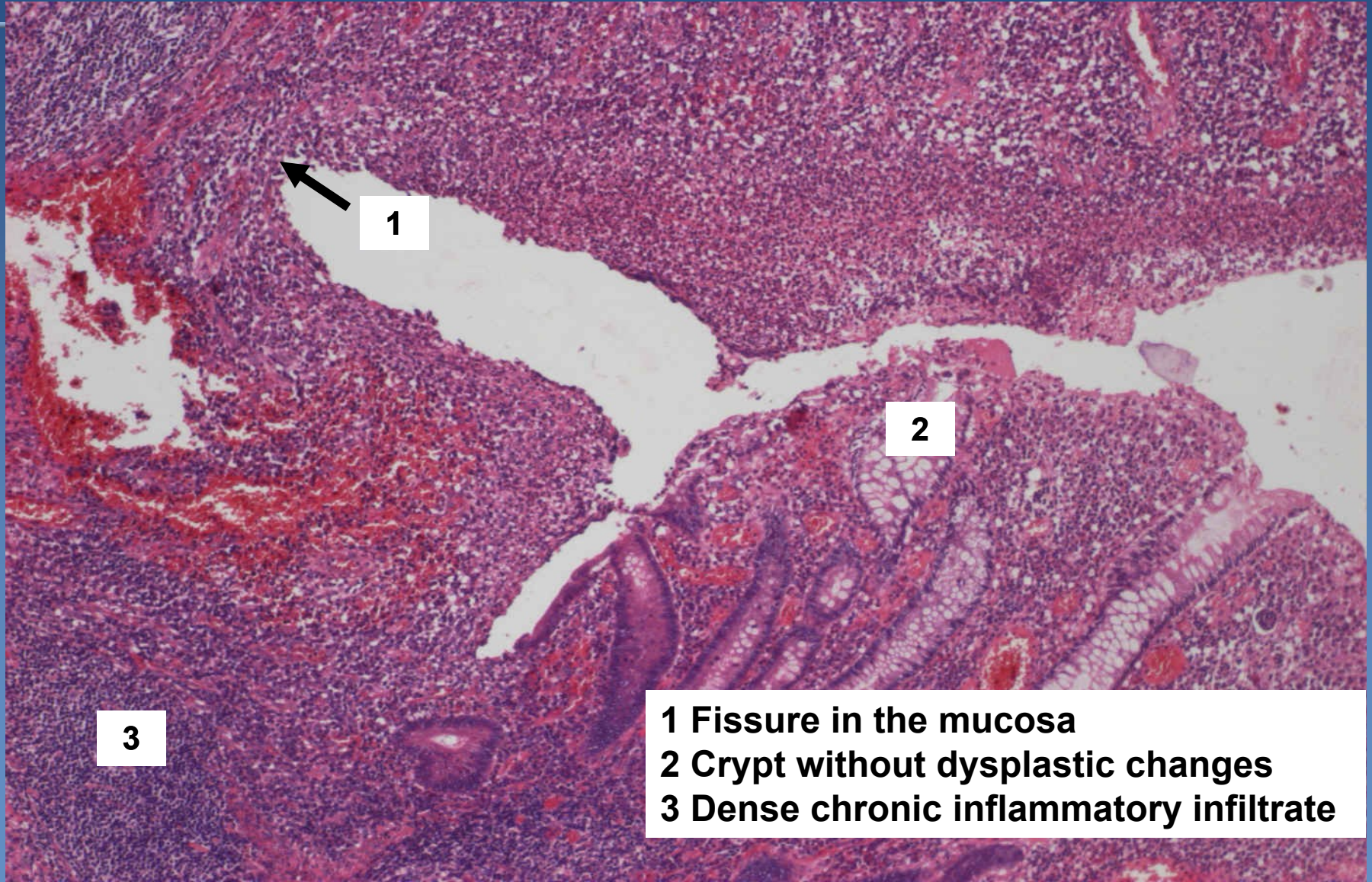
copy

Crohn's disease in the colon ***(transmural chronic inflammatory infiltrate)***



- 1 Transmural inflammatory infiltrate**
- 2 Intestinal mucosa**
- 3 Serosa**

Crohn's disease - Enteritis regionalis



1

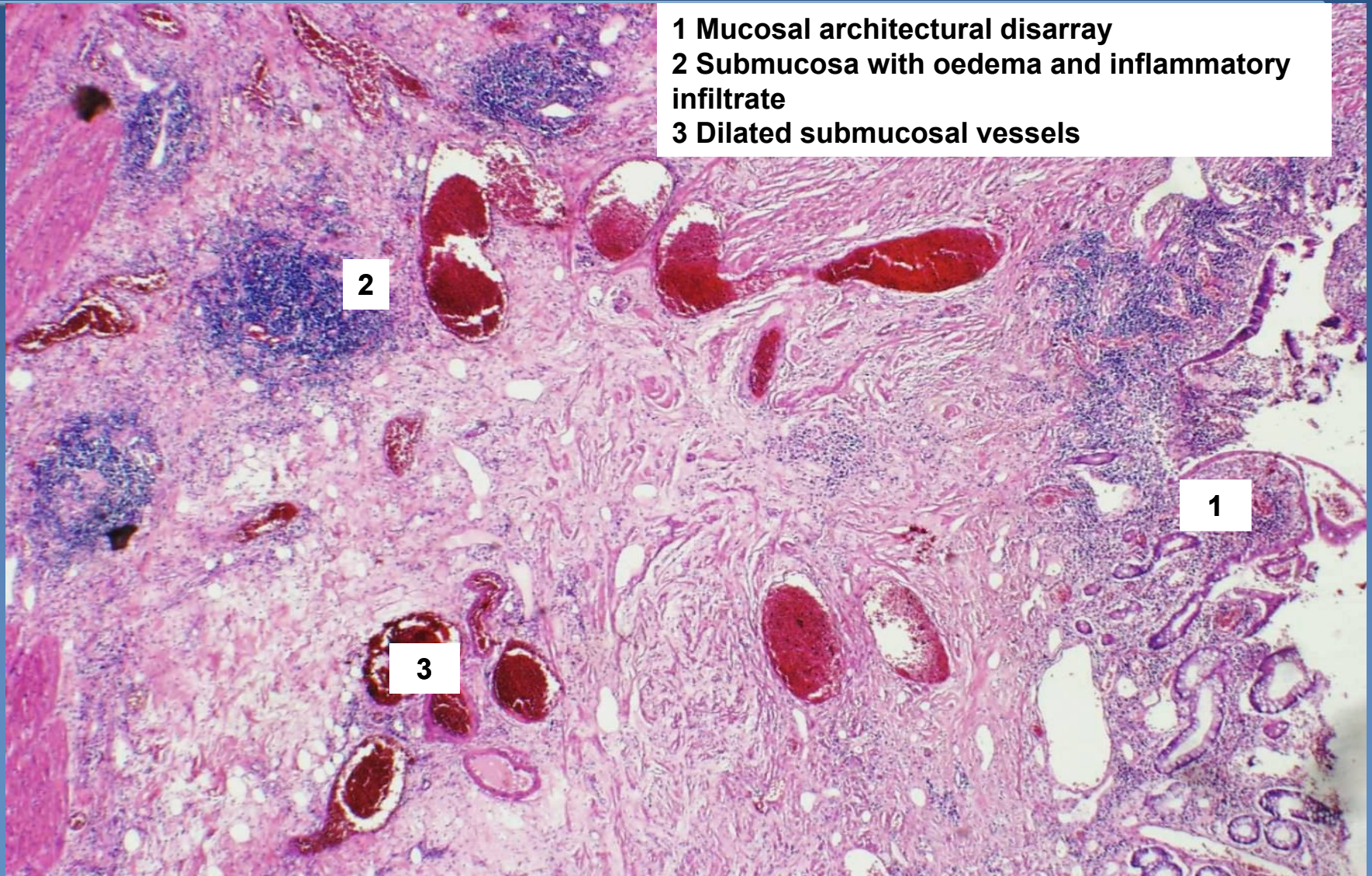
2

3

- 1 Fissure in the mucosa
- 2 Crypt without dysplastic changes
- 3 Dense chronic inflammatory infiltrate

Crohn's disease

inflammatory infiltrate in the submucosa

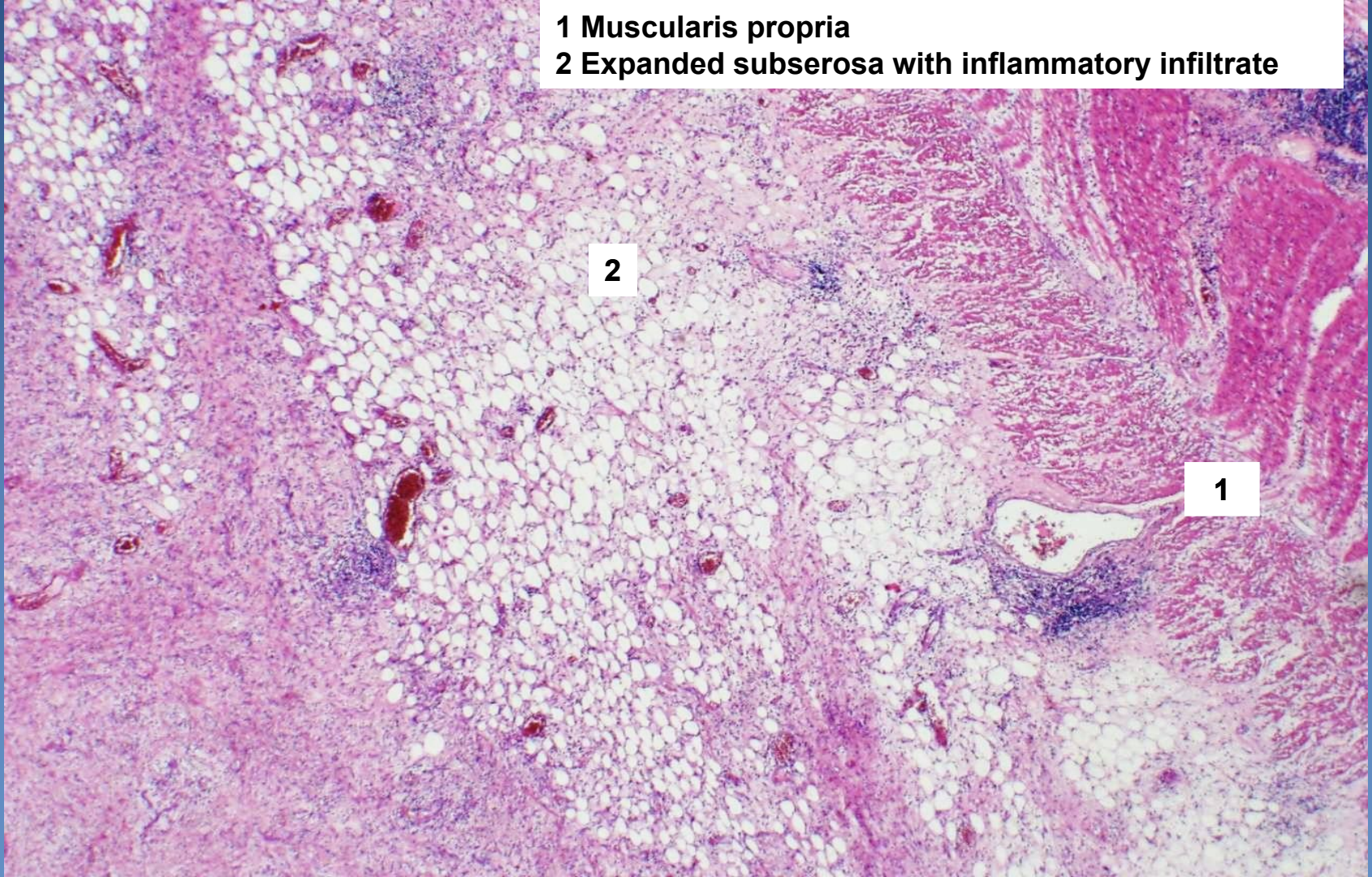

- 1 Mucosal architectural disarray**
- 2 Submucosa with oedema and inflammatory infiltrate**
- 3 Dilated submucosal vessels**

Crohn's disease ***inflammatory infiltrate in the subserosa***

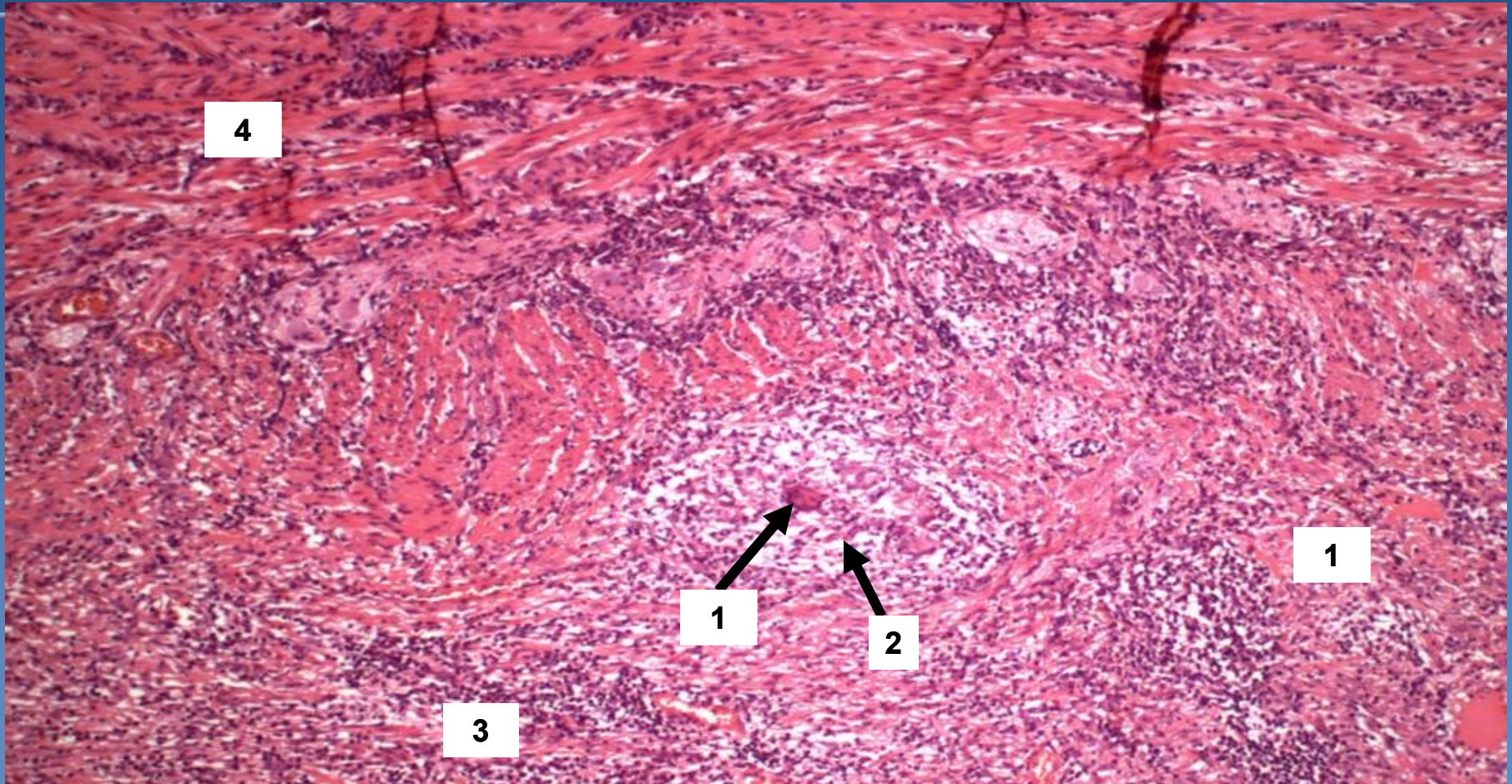


1 Muscularis propria
2 Expanded subserosa with inflammatory infiltrate



Crohn's disease

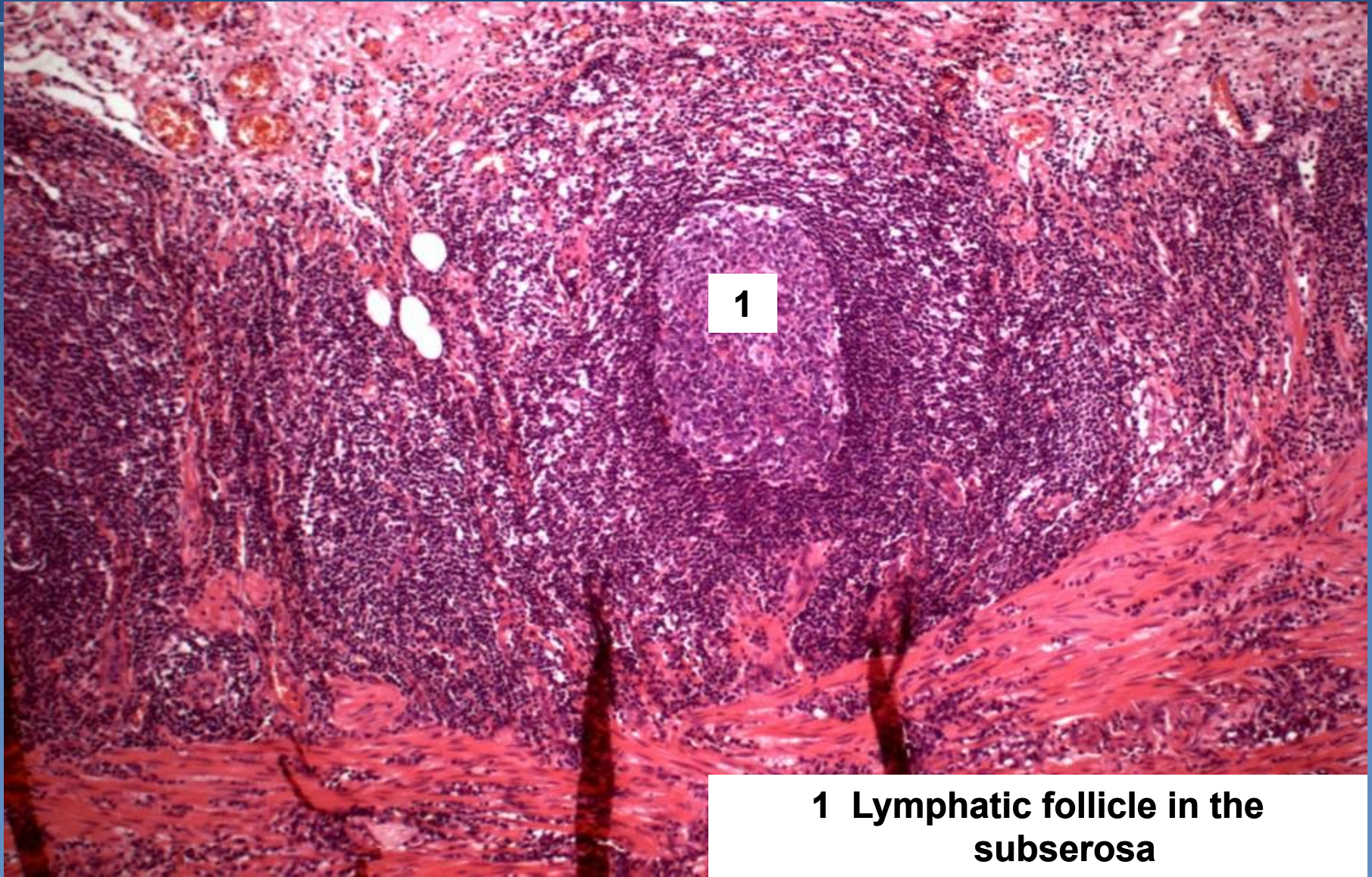
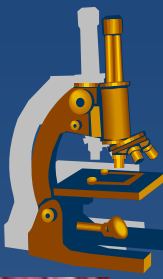
- granuloma in the submucosa



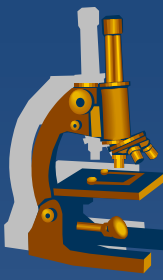
- 1 Multinucleated giant cell
- 2 Granuloma in the submucosa
- 3 Inflammatory infiltrate in the submucosa
- 4 Muscularis propria with inflammatory infiltrate

Crohn's disease

- inflammatory infiltrate



1 Lymphatic follicle in the subserosa



Ulcerative colitis

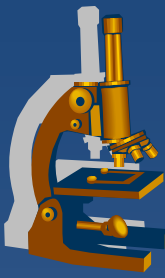
x Clinical features:

- ⇒ *relapsing attacks of bloody mucoid diarrhea, cramps, lower abdominal pain*
- ⇒ *start - rectum + sigmoid, continuous retrograde extension, may affect the entire **colon** (pancolitis)*
- ⇒ *unclear etiology, autoimmune and genetic factors, variable triggers*
- ⇒ *associated with systemic disorders (eye, skin, joint, bile tract – primary sclerosing cholangitis)*

x Gross:

- ⇒ *hyperemia, oedema, flat **ulcerations**, regenerative hyperplastic mucosa forming pseudopolyps*

Ulcerative colitis



x Micro:

- ⇒ *non-specific inflammatory infiltrate only in the mucosa and submucosa*
- ⇒ *crypt abscesses, crypt destruction*
- ⇒ *no granulomas, no skip lesions*
- ⇒ *very little fibrosis, no mural thickening*
- ⇒ *high risk of carcinoma development*

Ulcerative colitis



x Microscopic phases of the inflammation:

⇒ **1. active**

- hyperemia, mixed inflammatory infiltrate, crypt abscesses

⇒ **2. healing**

- less neutrophils, no crypt abscesses, epithelial regeneration

⇒ **3. remission**

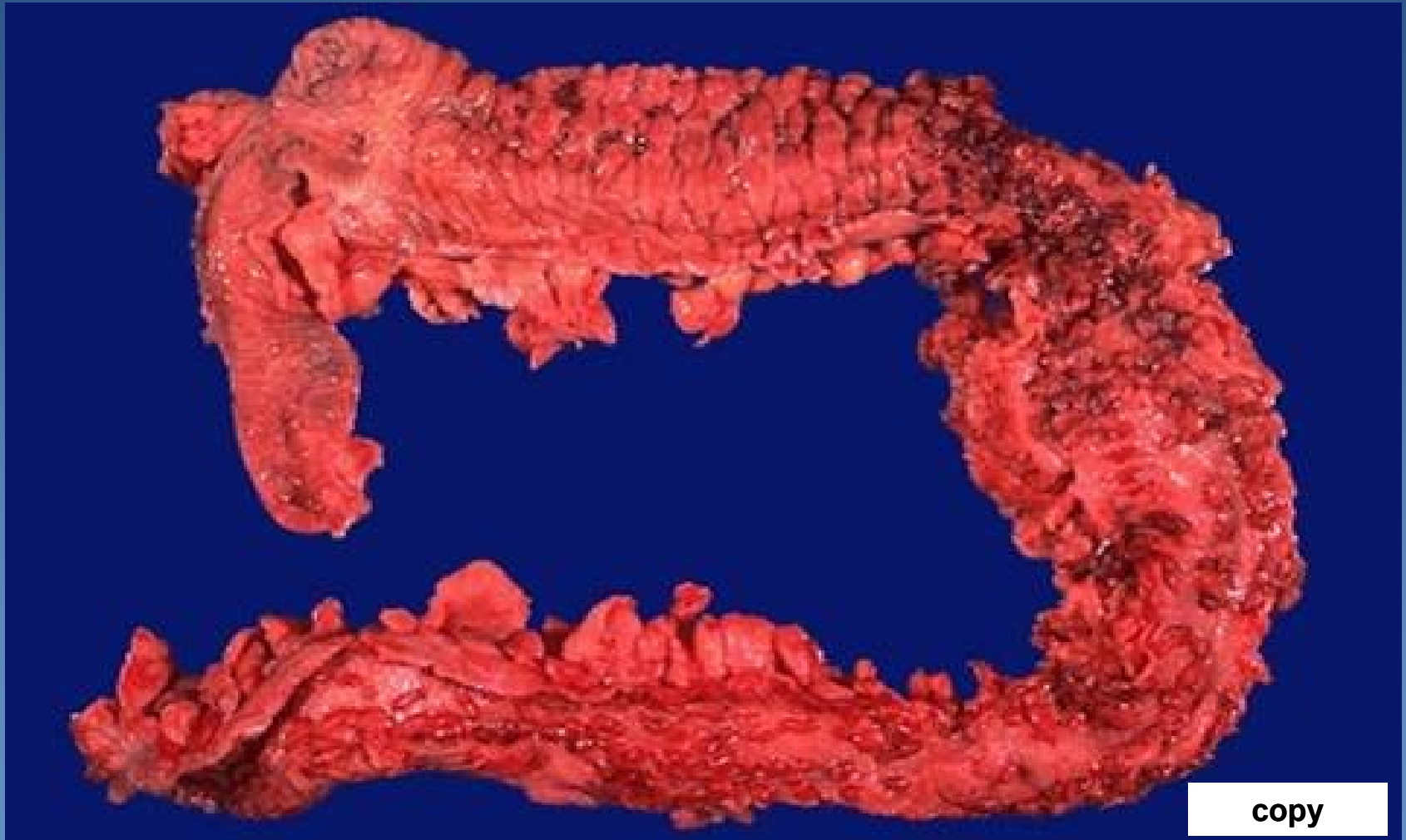
- mucosal architectural disarray, atrophy, inflammatory changes sm.
only in the **rectum**

x Complications:

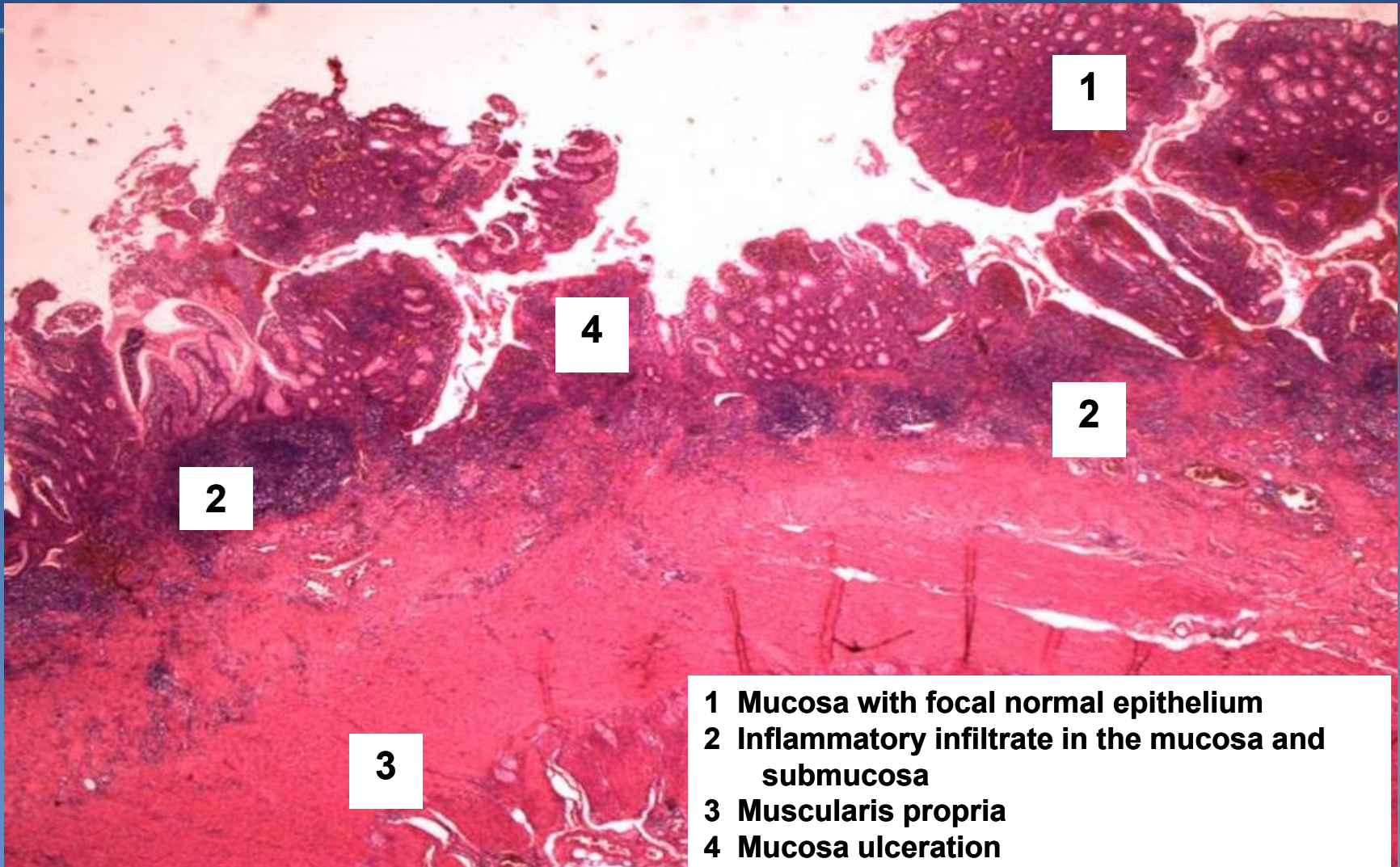
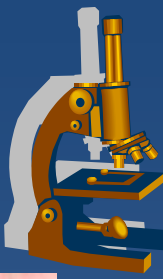
- ⇒ *toxic megacolon, hemorrhage, perforation, peritonitis, carcinoma development*

Ulcerative colitis

- gross

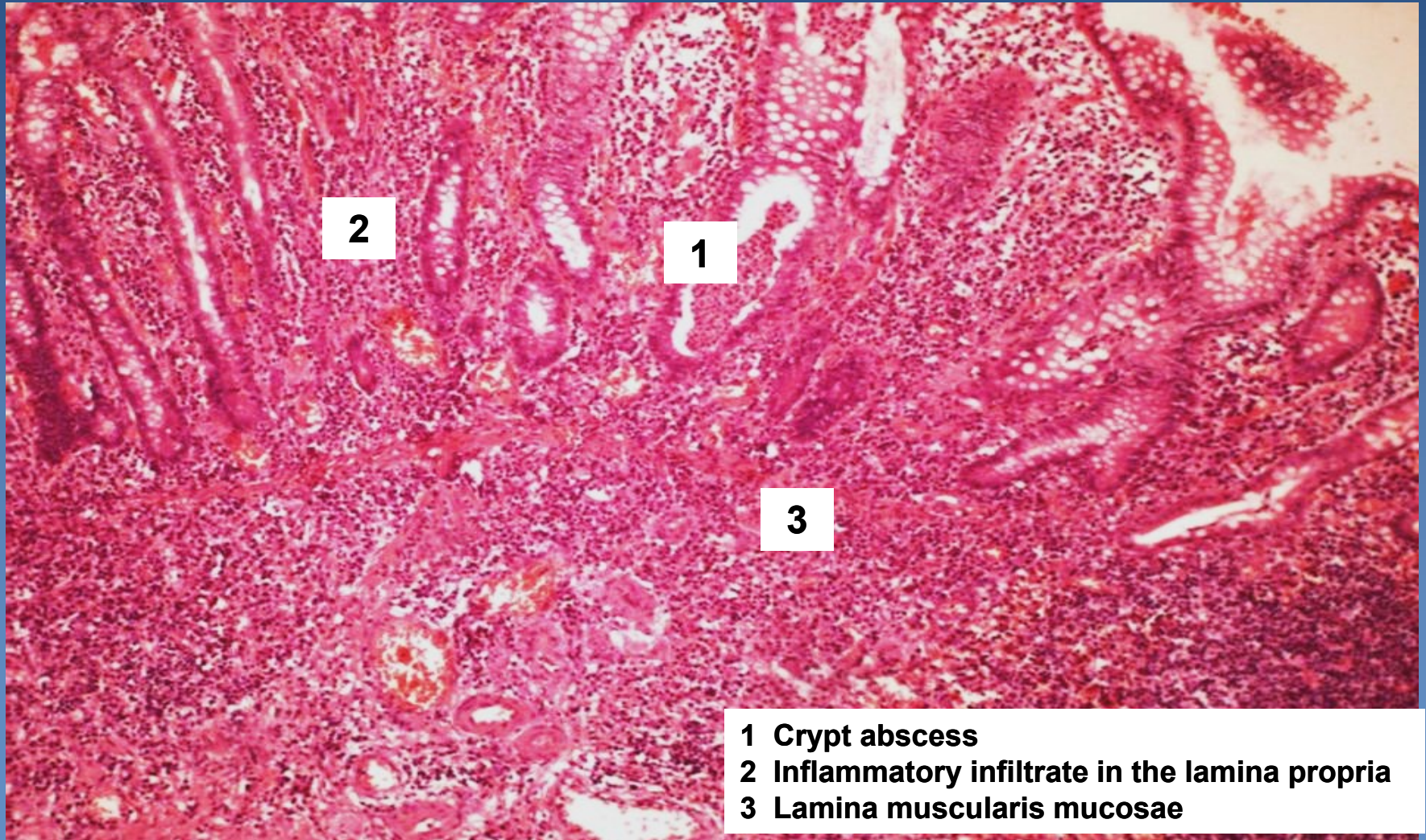


Ulcerative colitis *superficial inflammatory infiltrate*



- 1 Mucosa with focal normal epithelium
- 2 Inflammatory infiltrate in the mucosa and submucosa
- 3 Muscularis propria
- 4 Mucosa ulceration

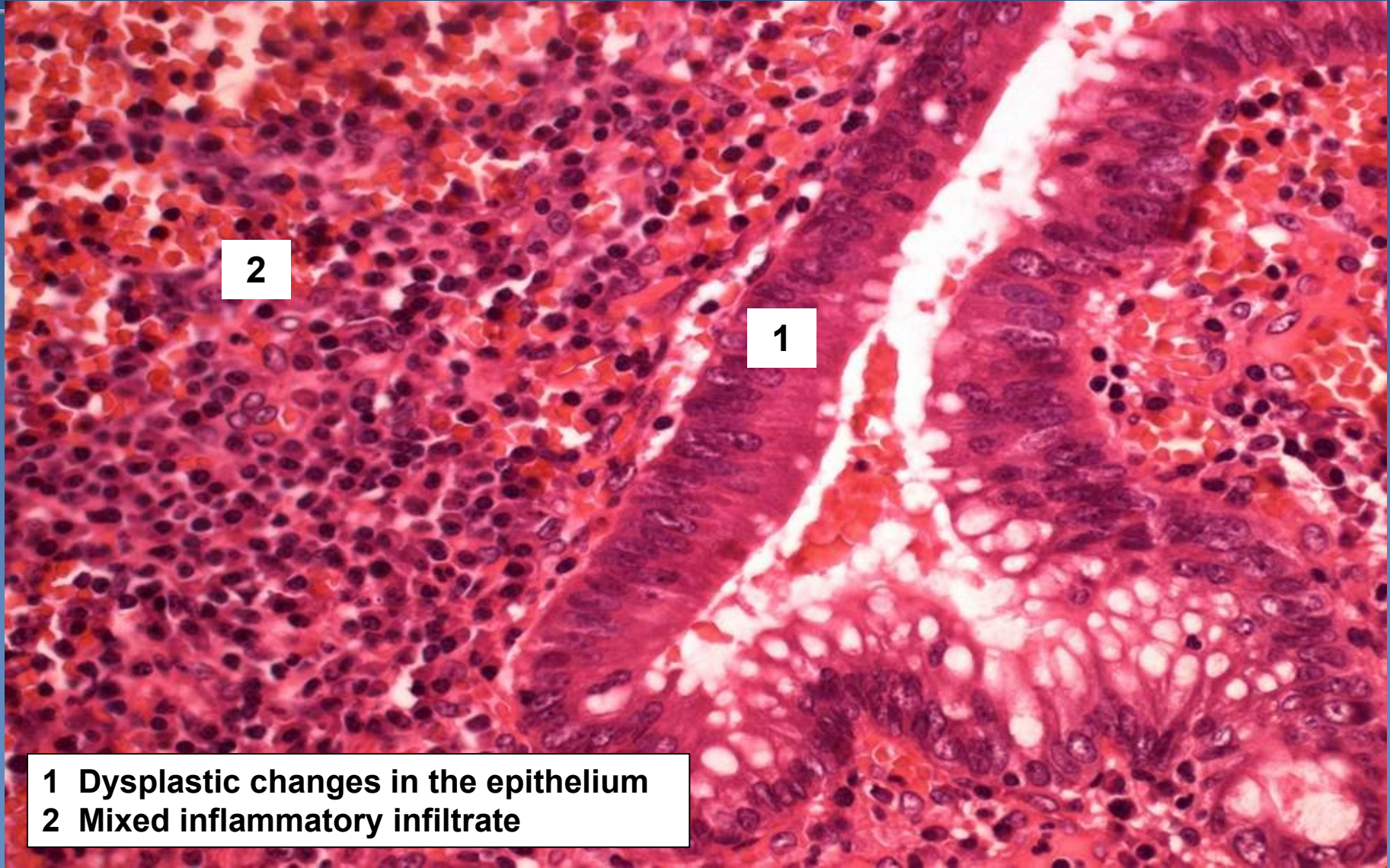
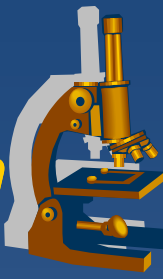
Ulcerative colitis - crypt abscess



- 1 Crypt abscess**
- 2 Inflammatory infiltrate in the lamina propria**
- 3 Lamina muscularis mucosae**

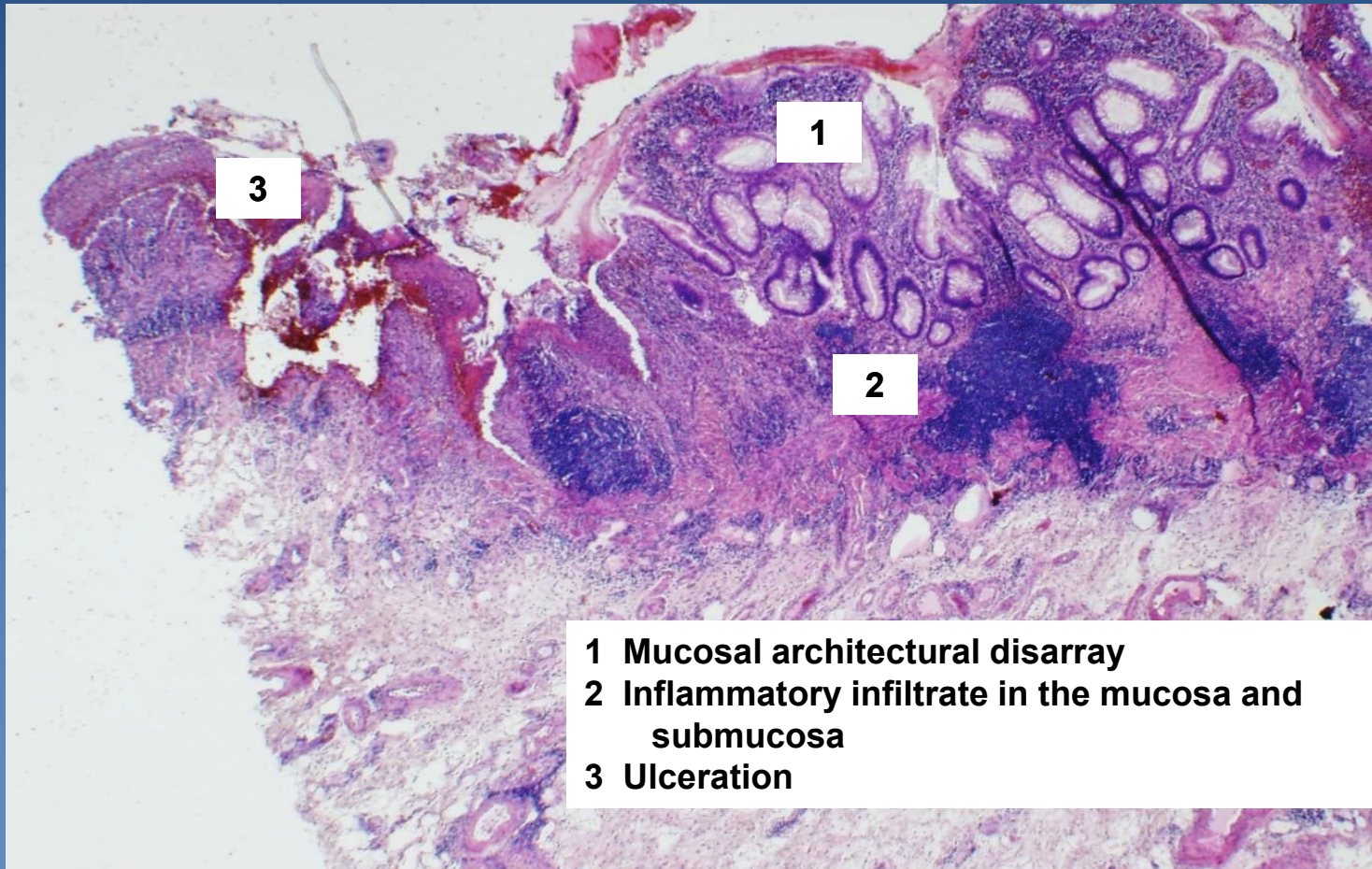
Ulcerative colitis

- dysplastic changes in the epithelium



- 1 Dysplastic changes in the epithelium
- 2 Mixed inflammatory infiltrate

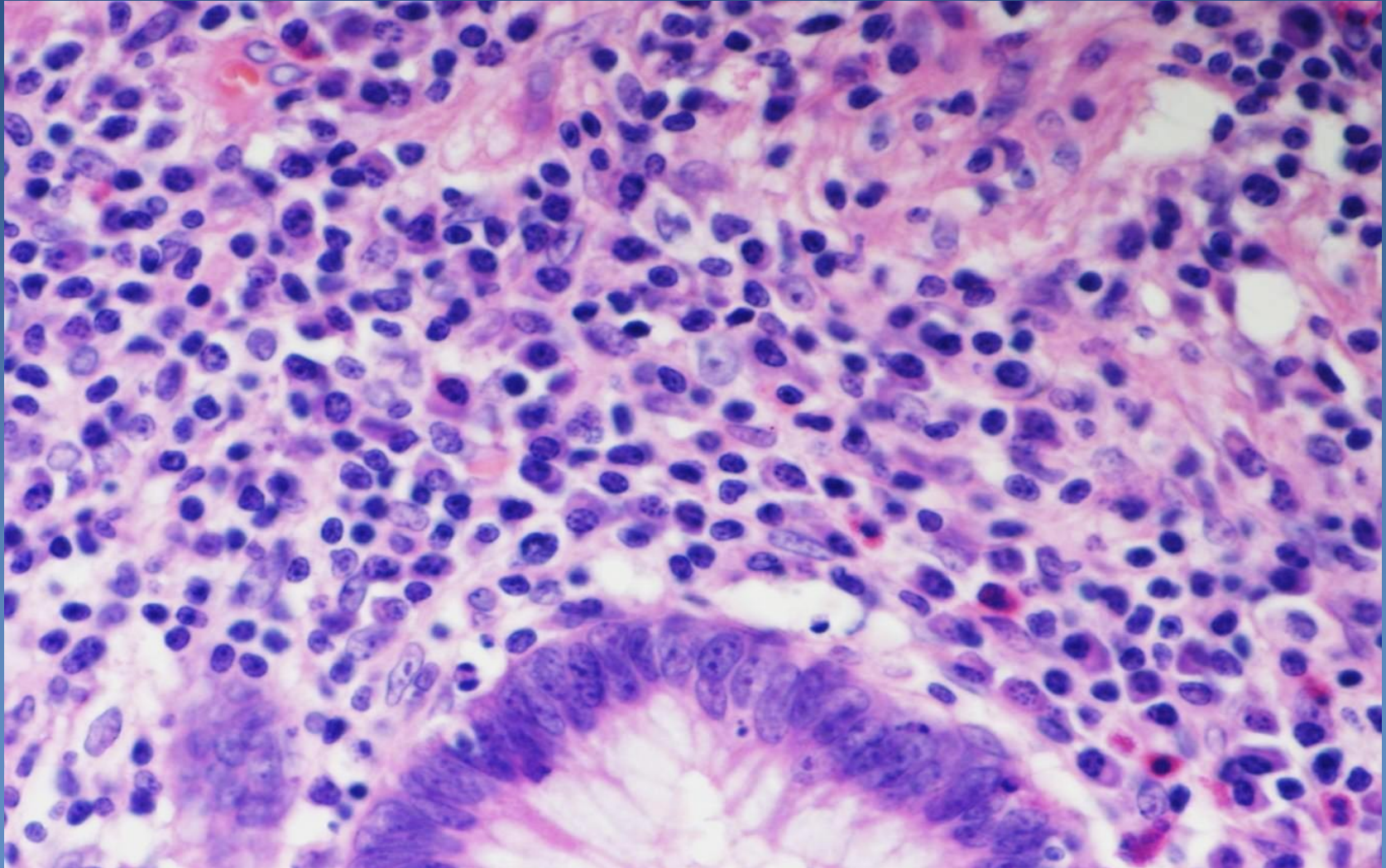
Ulcerative colitis



- 1 Mucosal architectural disarray
- 2 Inflammatory infiltrate in the mucosa and submucosa
- 3 Ulceration

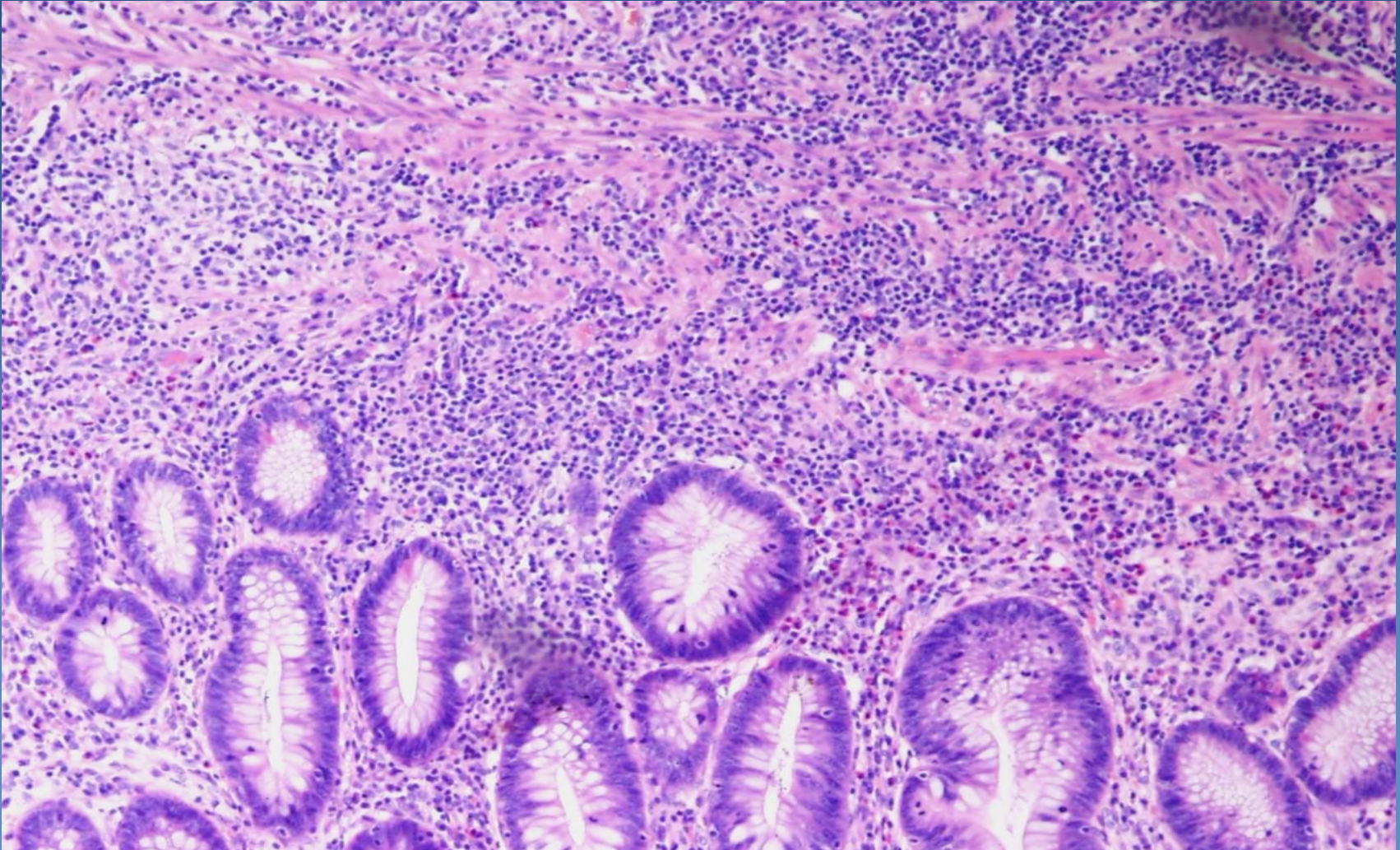
Ulcerative colitis

basal plasmacytosis



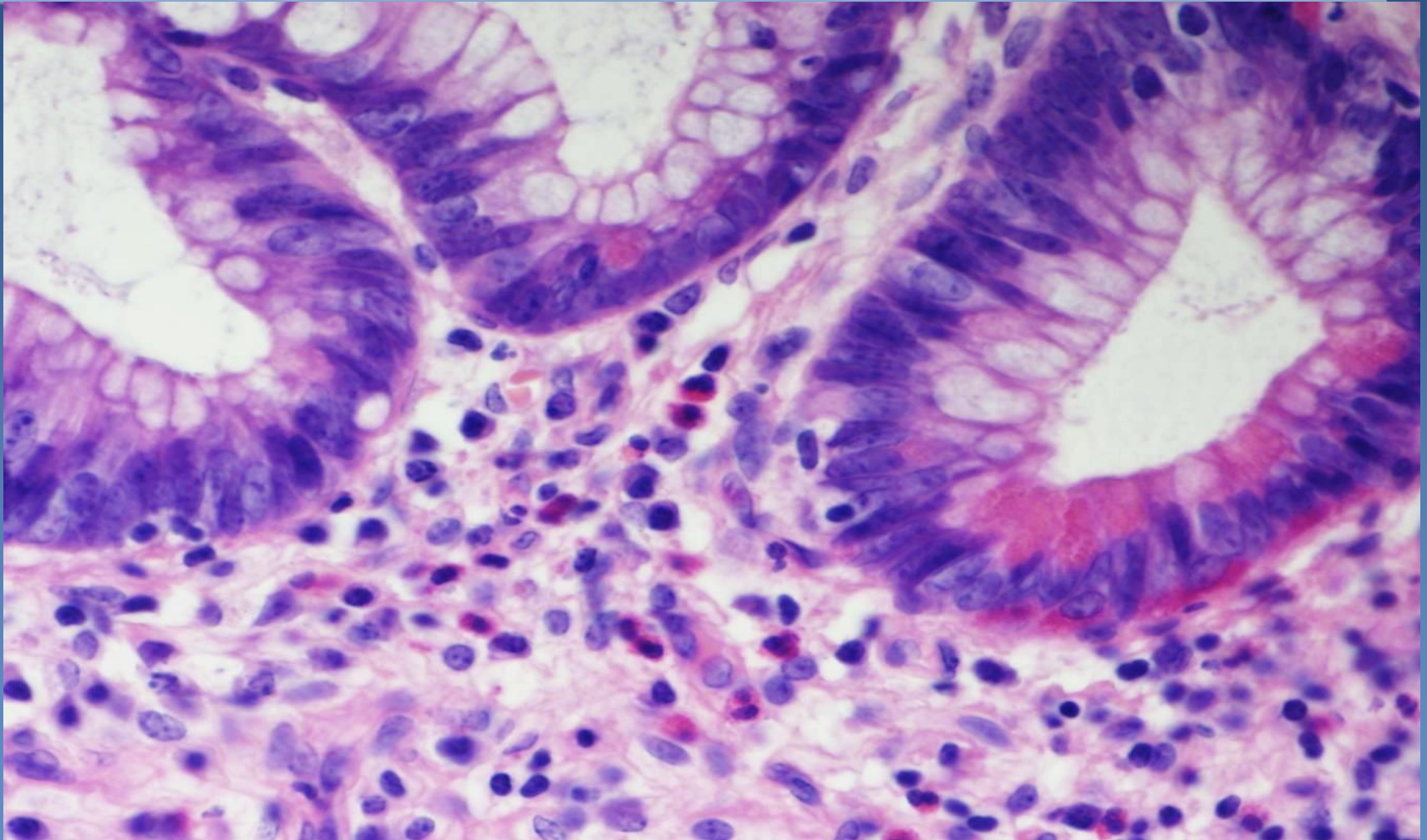
Ulcerative colitis

basal plasmacytosis



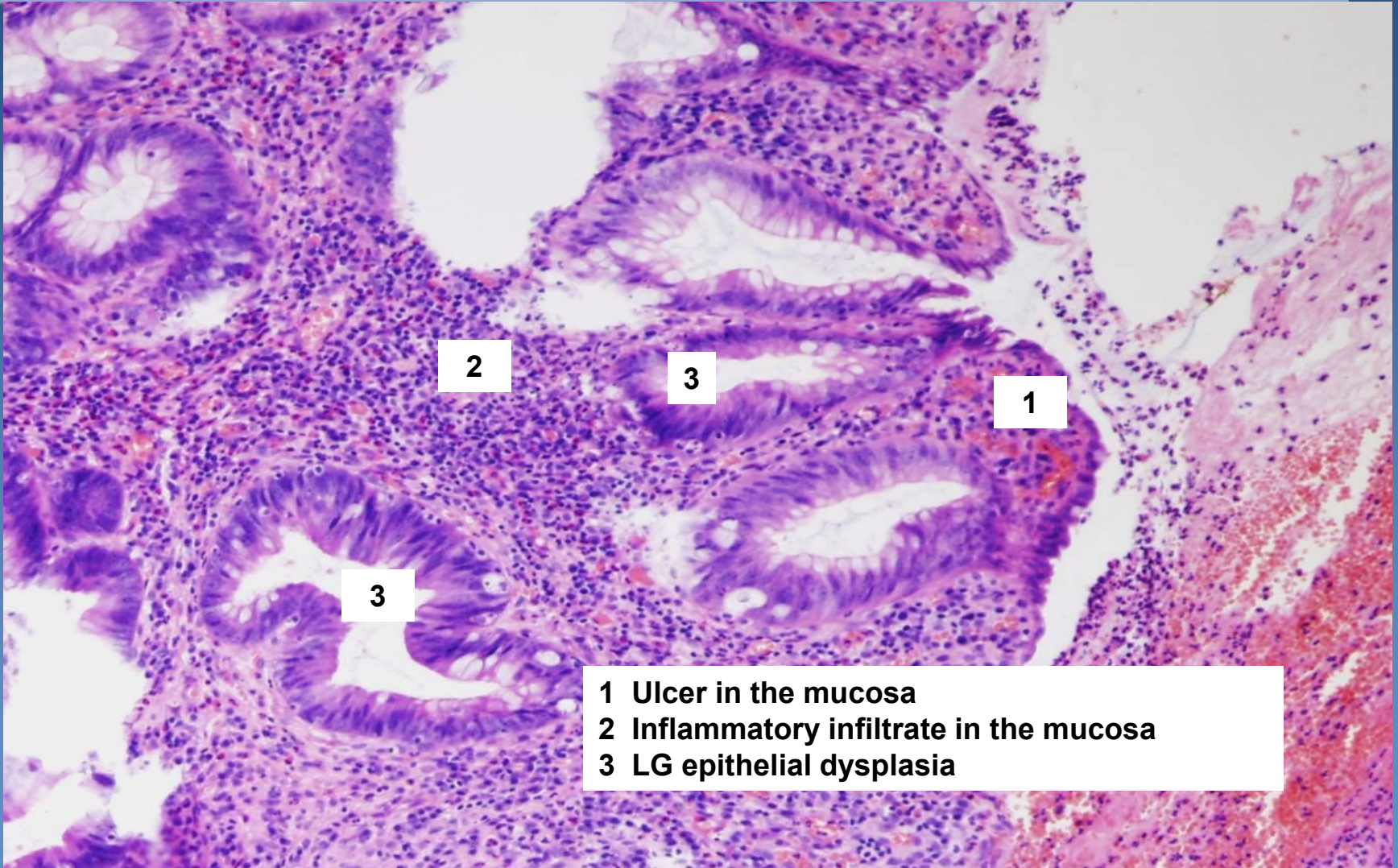
Ulcerative colitis

Paneth cell metaplasia in the left colon



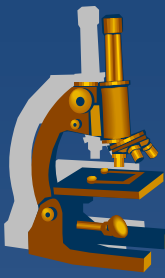
Ulcerative colitis

epithelial dysplasia



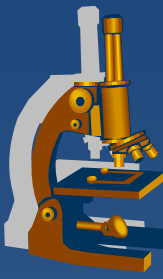
- 1 Ulcer in the mucosa
- 2 Inflammatory infiltrate in the mucosa
- 3 LG epithelial dysplasia

Further types of enterocolitis



- x pseudomembranous
- x ischemic
 - ⇒ *short-term decreased blood supply to the intestine (shock, trauma, surgery)*
- x microscopic (collagenous, lymphocytic)
 - ⇒ *chronic watery diarrhea, normal colonoscopy, associated with autoimmune diseases*
- x infectious
- x postradiation
- x others

Pseudomembranous colitis



xetiology:

- ⇒ *infection – bacterial (Clostridium difficile, Salmonella, Staph. aureus)*
- ⇒ *antibiotic-associated*
- ⇒ *uremia*

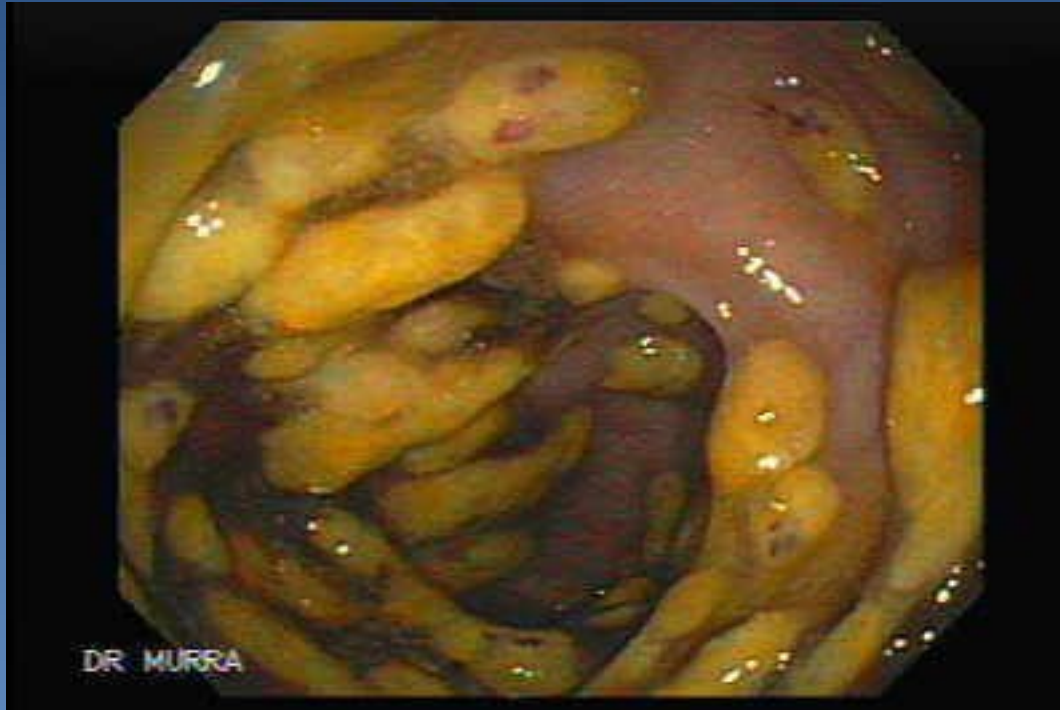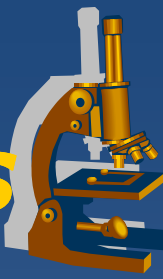xgross:

- ⇒ *greyish pseudomembranes on the mucosal surface, ulcers*

xmicro:

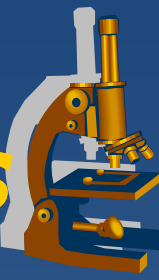
- ⇒ *fibrinous pseudomembrane with neutrophils, bacteria and macrophages, adherent to the necrotic mucosa*

Pseudomembranous colitis

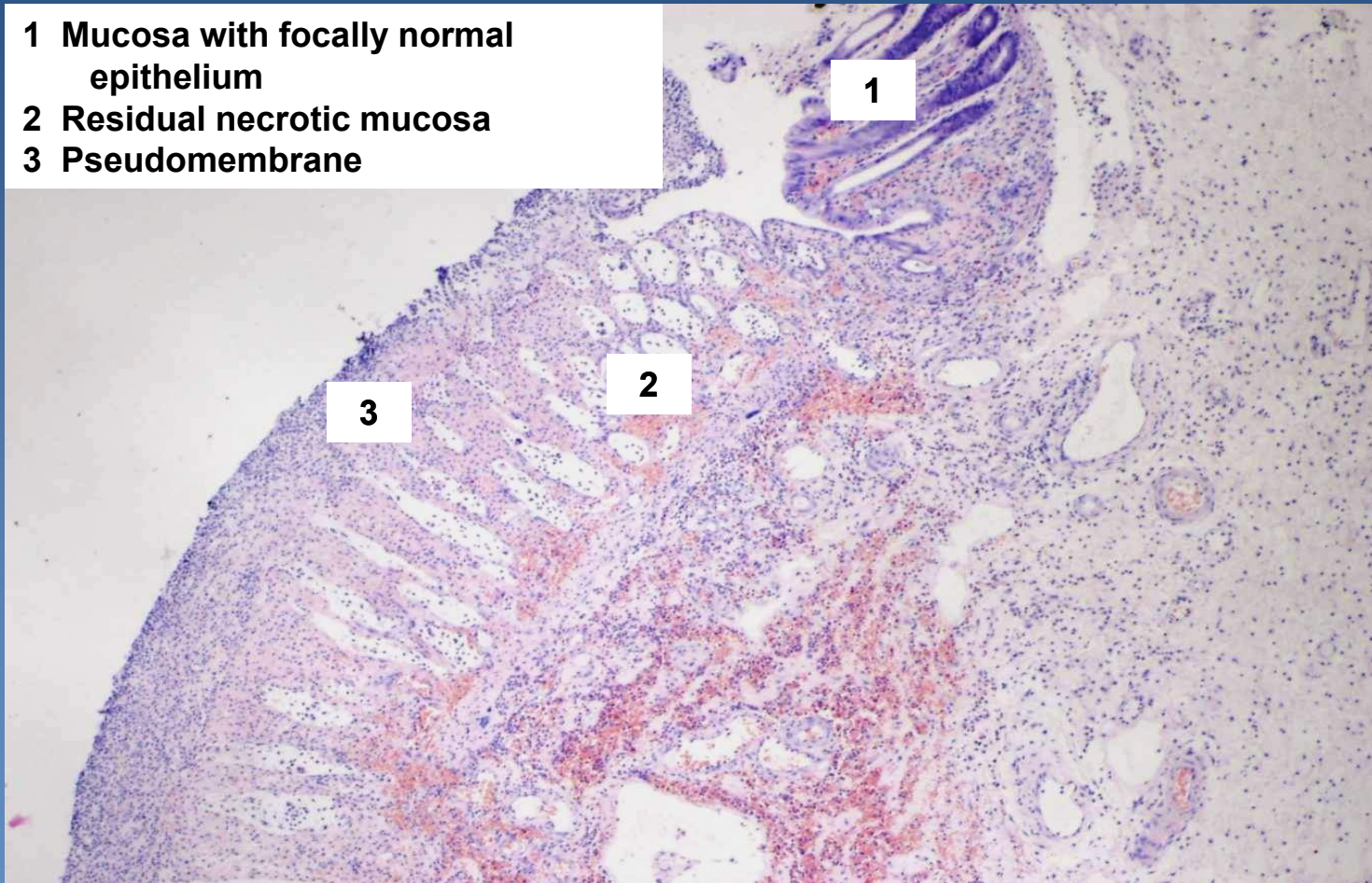


✘ Endoscopy (copy)

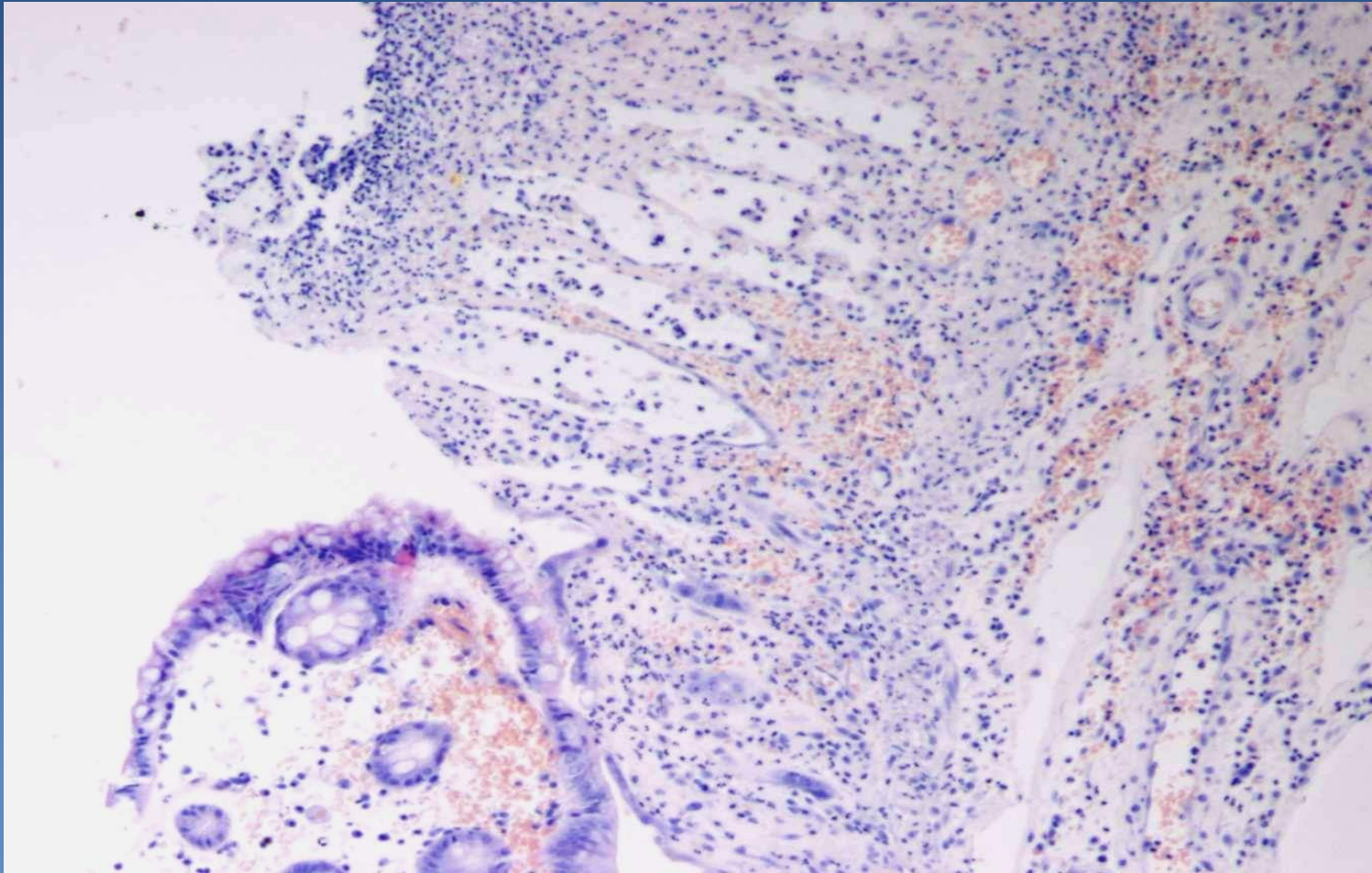
Pseudomembranous colitis



- 1 Mucosa with focally normal epithelium
- 2 Residual necrotic mucosa
- 3 Pseudomembrane



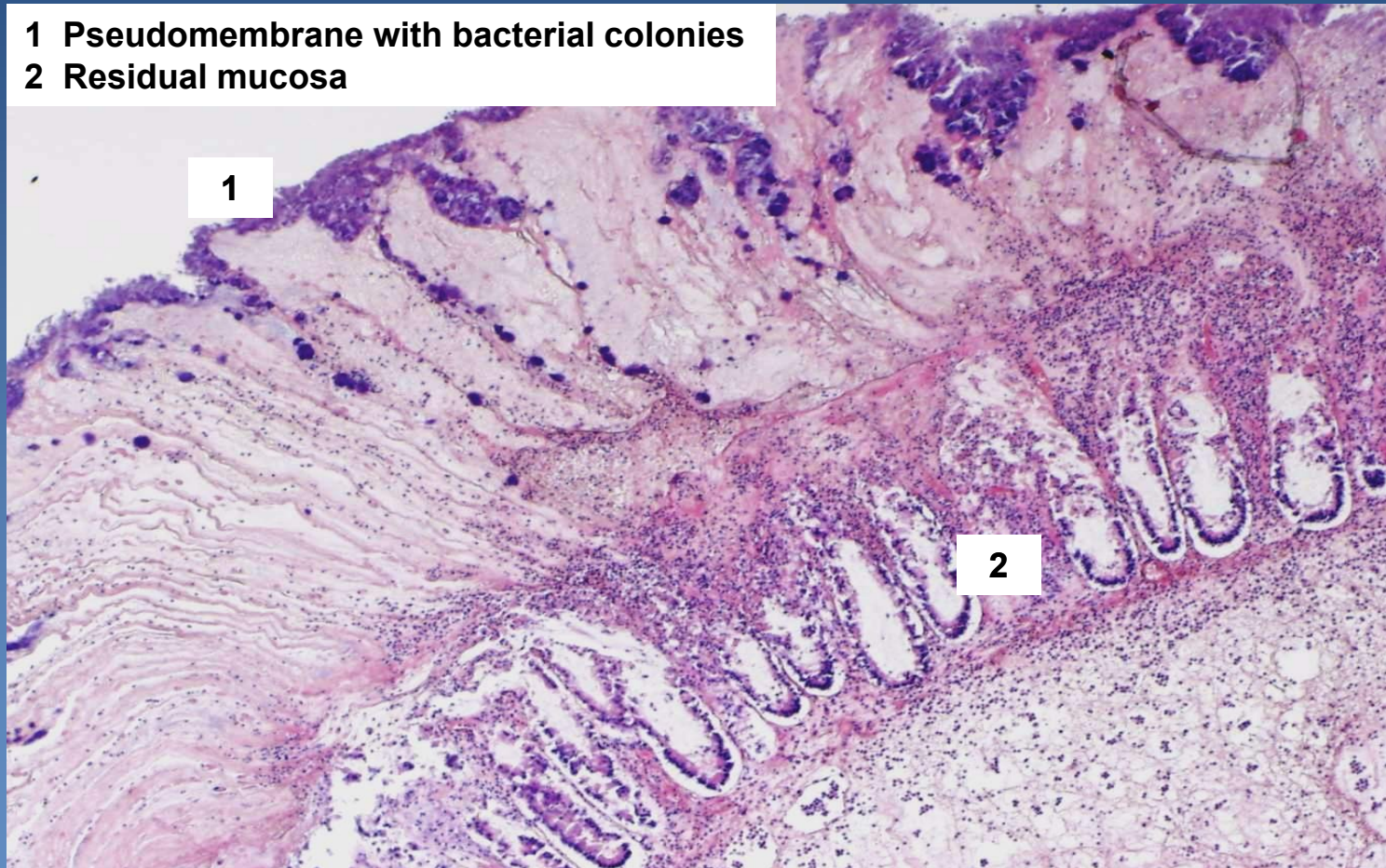
Pseudomembranous colitis *- detail*



Pseudomembranous colitis ***(Clostridium difficile etiology)***



- 1 Pseudomembrane with bacterial colonies
- 2 Residual mucosa



Ileus – intestinal obstruction/disruption of the normal motility



×mechanic (strangulation, obturation)

- ⇒ ***Adhesions***
- ⇒ ***hernias***
- ⇒ ***volvulus***
- ⇒ ***invagination***
- ⇒ ***tumors***
- ⇒ ***obstruction (foreign body)***
- ⇒ ***congenital atresia***
- ⇒ ***meconial in cystic fibrosis***

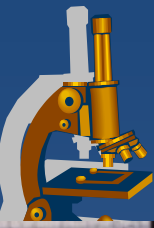
×dynamic

- ⇒ ***paralytic: toxic-infective, drugs, peritonitis, post-operative***
- ⇒ ***vascular: hemorrhagic infarction***
- ⇒ ***myopathy, neuropathy***
- ⇒ ***Hirschprung' disease***

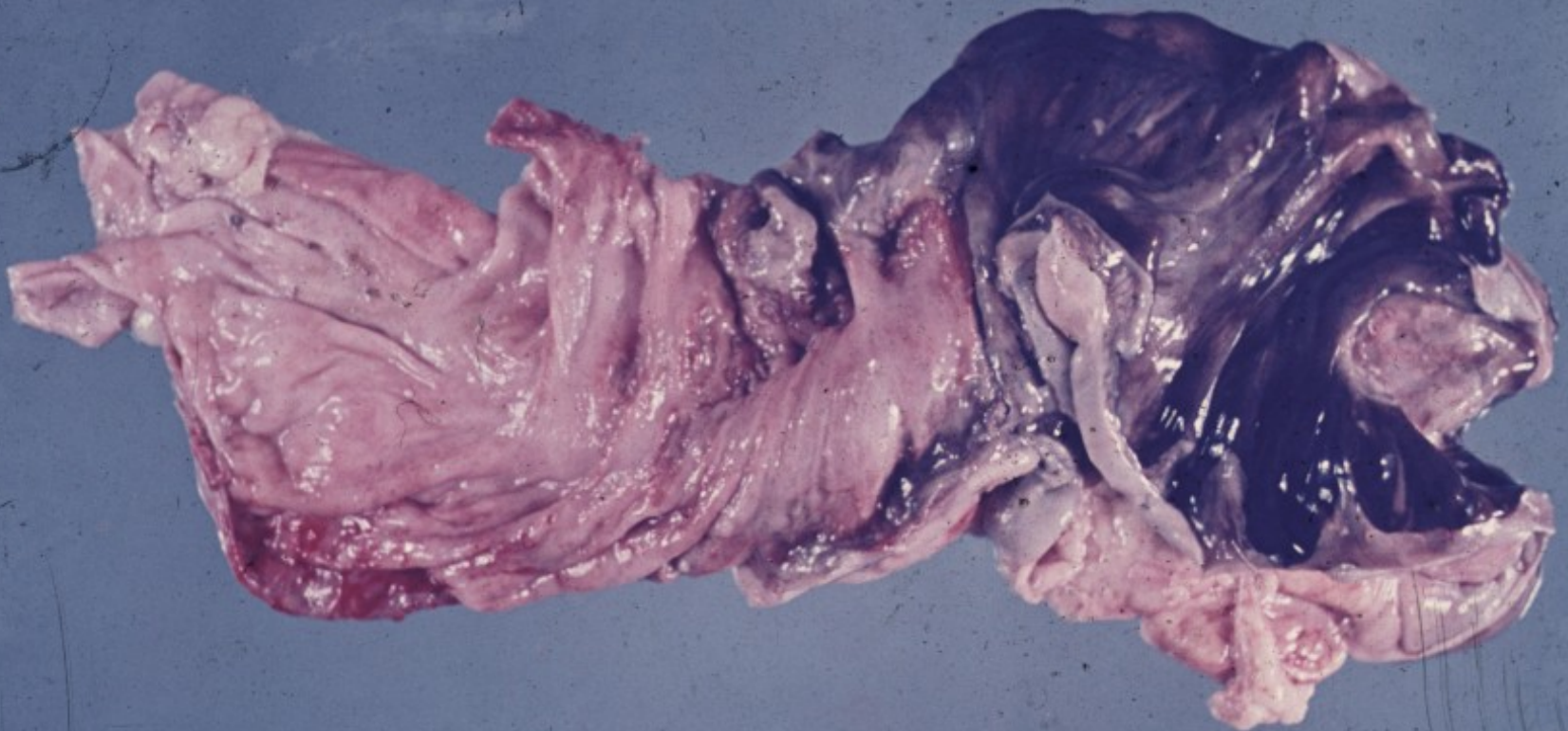Ileus



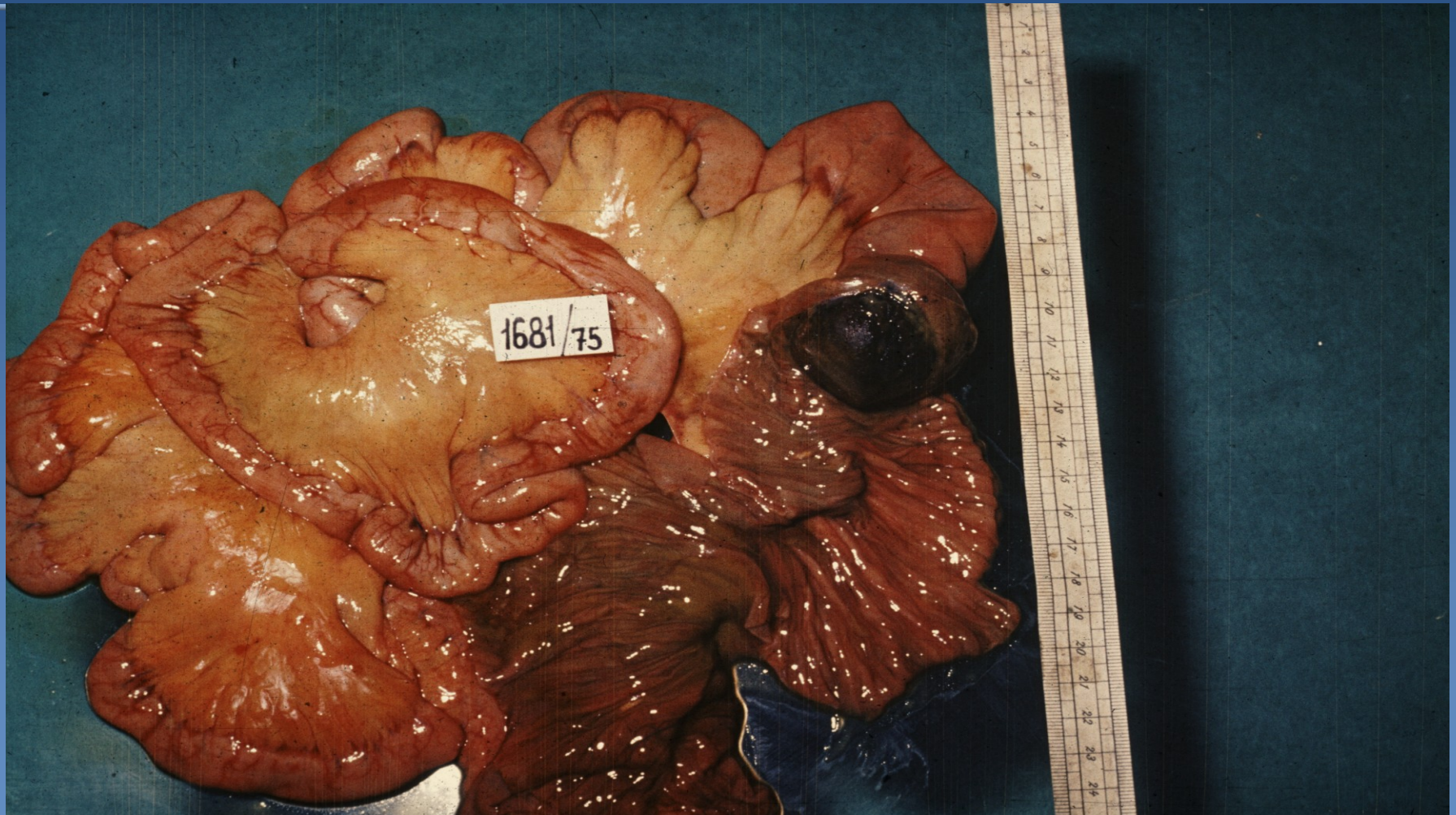- ✘ Clinical features: signs of „acute abdomen“ with acute pain, cramps, abdominal distention, nausea and vomiting, stop of the stool/gases passage
- ✘ Type / severity of the signs according to localisation + stage of obstruction
- ✘ Intestinal wall in/above the obstruction:
 - dilatation → inflammation → (peritonitis, sepsis)
 - mural necrosis → perforation → stercoral (fecal) peritonitis



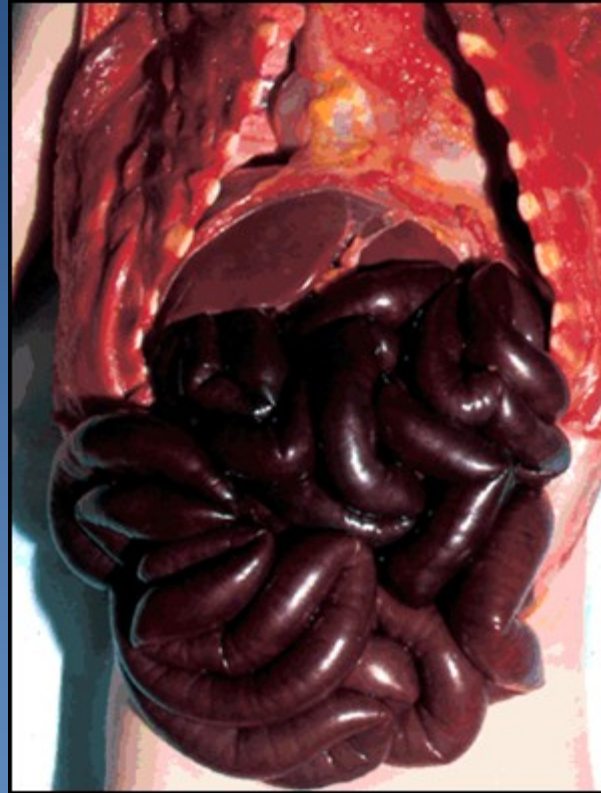
Volvulus, bowel infarction



Gallstone ileus



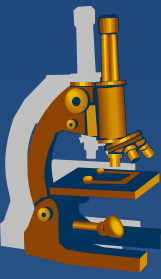
Hemorrhagic infarction of the intestine



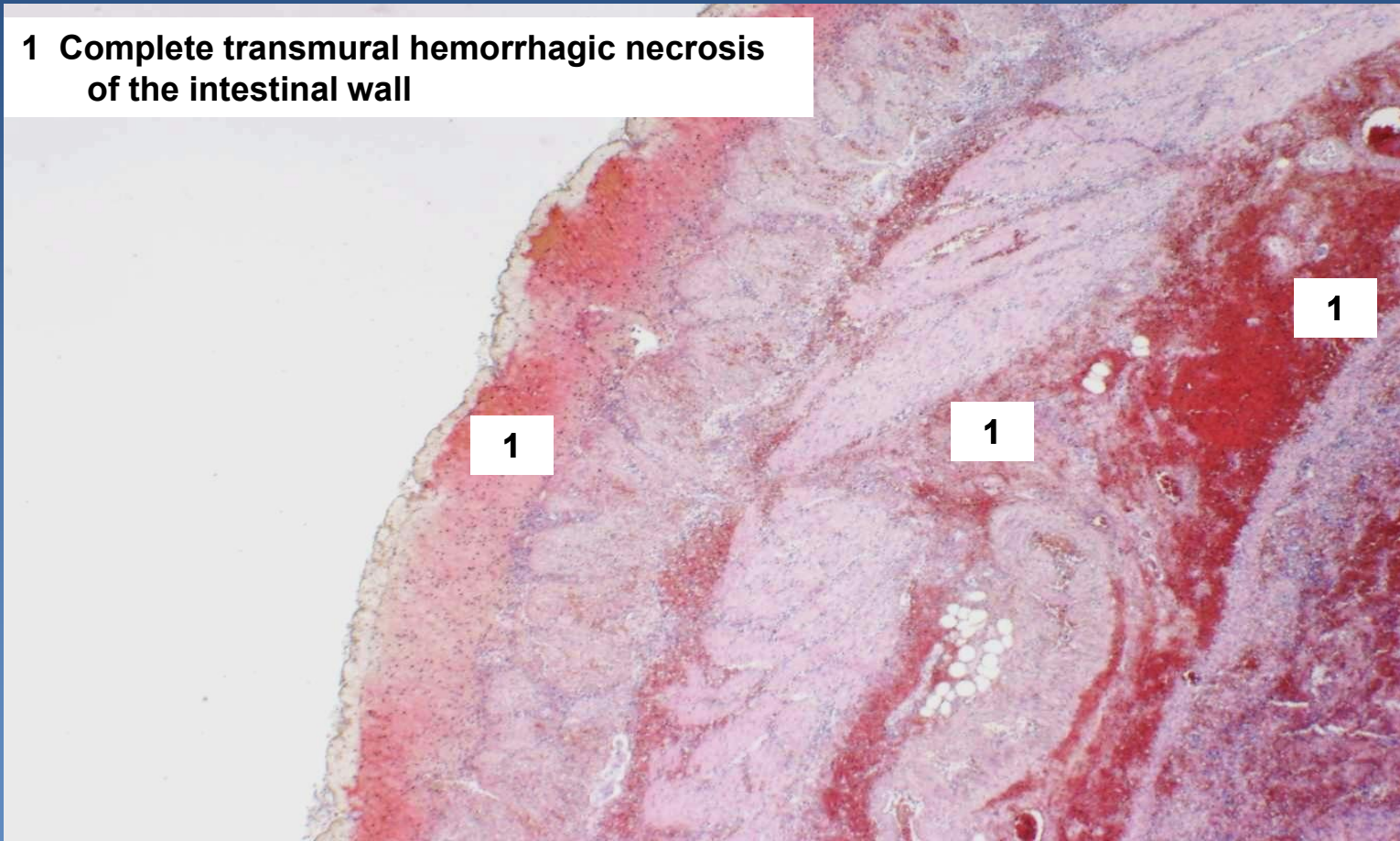
copy

x result of intestinal ischemia

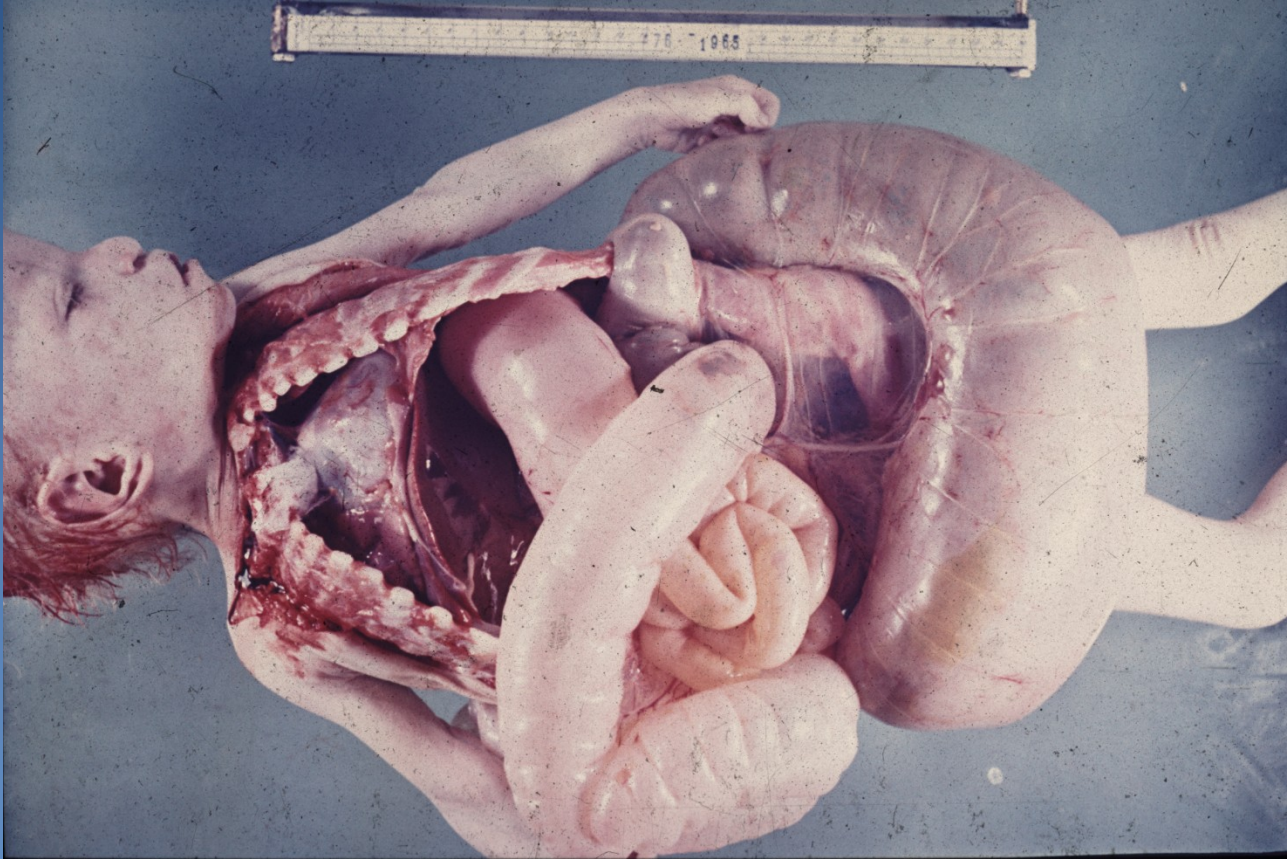
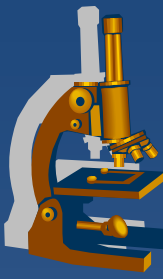
Hemorrhagic infarction of the intestine



1 Complete transmural hemorrhagic necrosis of the intestinal wall



Hirschprung' disease



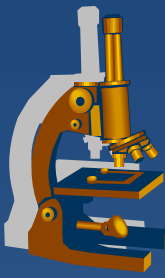
Intestinal polyps



x Non-neoplastic polyps

- ⇒ **hyperplastic polyp** (<5 mm) minimal malignant potential, part of group of serrated lesions
- ⇒ **juvenile polyp** - hamartoma; in children under 5 years, in the rectum, sporadic or part of juvenile polyposis sy (AD, haemorrhage, ↑ risk of ca)
- ⇒ **Peutz - Jeghers** hamartoma polyps + mucocutaneous hyperpigmentation; single/multiple (P-J syndrome - ↑ risk of pancreatic, pulmonary, ovarian, breast cancer)

Intestinal polyps



× Neoplastic sporadic adenomatous polyps

- ⇒ **tubular adenoma** (*smaller, spheric, pedunculated*)
- ⇒ **villous adenoma** (*large, flat, sessile, often HG dysplasia and high malignant potential*)
- ⇒ **tubulovillous adenoma**

Familial syndromes



1/ Familial hereditary polyposis syndromes

⇒ familial adenomatous polyposis (FAP):

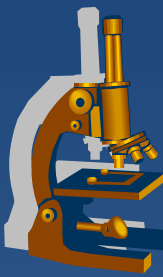
AD, mutation of suppressor APC gene, 100-2500 colonic adenomas, teenagers, 100% risk of cancer

⇒ Gardner syndrome: FAP variant, dental anomalies

extraintestinal tumors: osteomas, gliomas, lipomas, fibromas

⇒ Peutz - Jeghers syndrome :

melanotic mucosal and cutaneous pigmentation with hamartomatous intestinal polyps

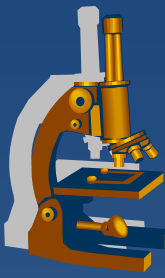


2/ Lynch syndrome

(hereditary non-polyposis colorectal cancer, AD), DNA mismatch repair defect + increased rate of mutations; younger age, right colon.

Increased risk of multiple tumors of the stomach, small intestine, liver, gallbladder tract, urinary tract, brain, skin, prostate.

Serrated lesions



- ⇒ *special heterogenous group of polypous lesions, serrated (sawtooth, stellate) morphology, part of intraepithelial neoplasias*
- ⇒ *precursors of perhaps one third of colorectal cancers*
- ⇒ *classification: dysplastic, non-dysplastic*

Classification of serrated lesions/polyps



x Non-dysplastic

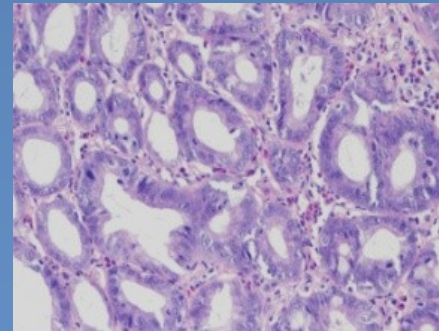
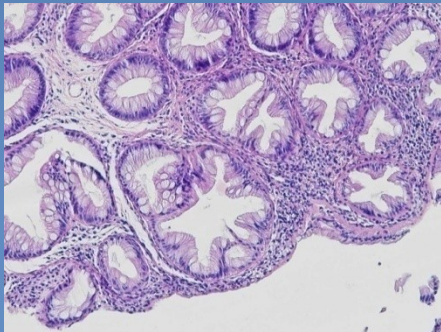
⇒ *hyperplastic polyp*

⇒ *sessile serrated adenoma/polyp*

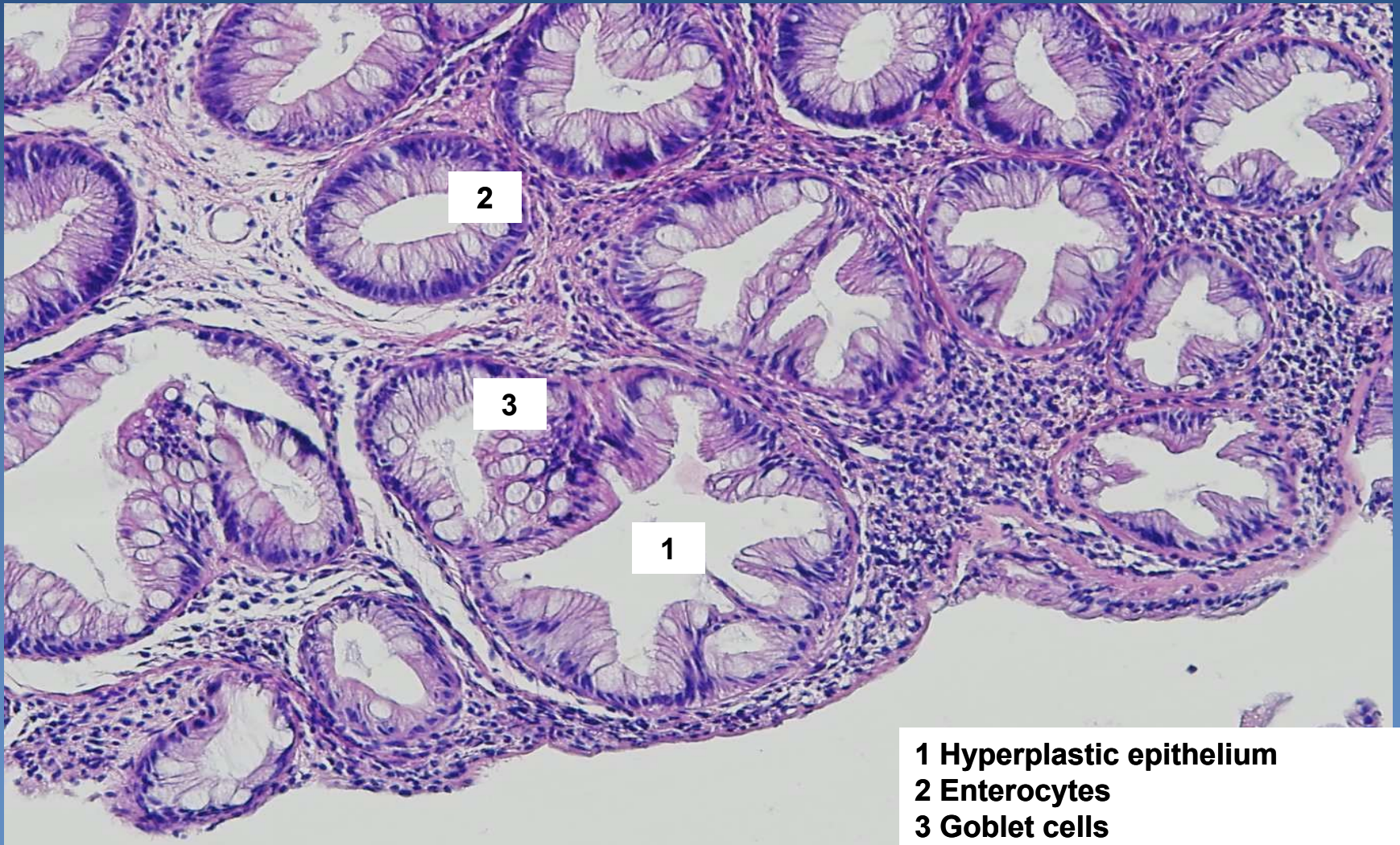
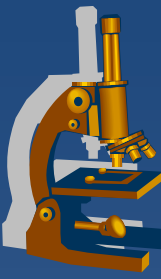
x With dysplasia

⇒ *sessile serrated adenoma/polyp w. dysplasia*

⇒ *traditional serrated adenoma*

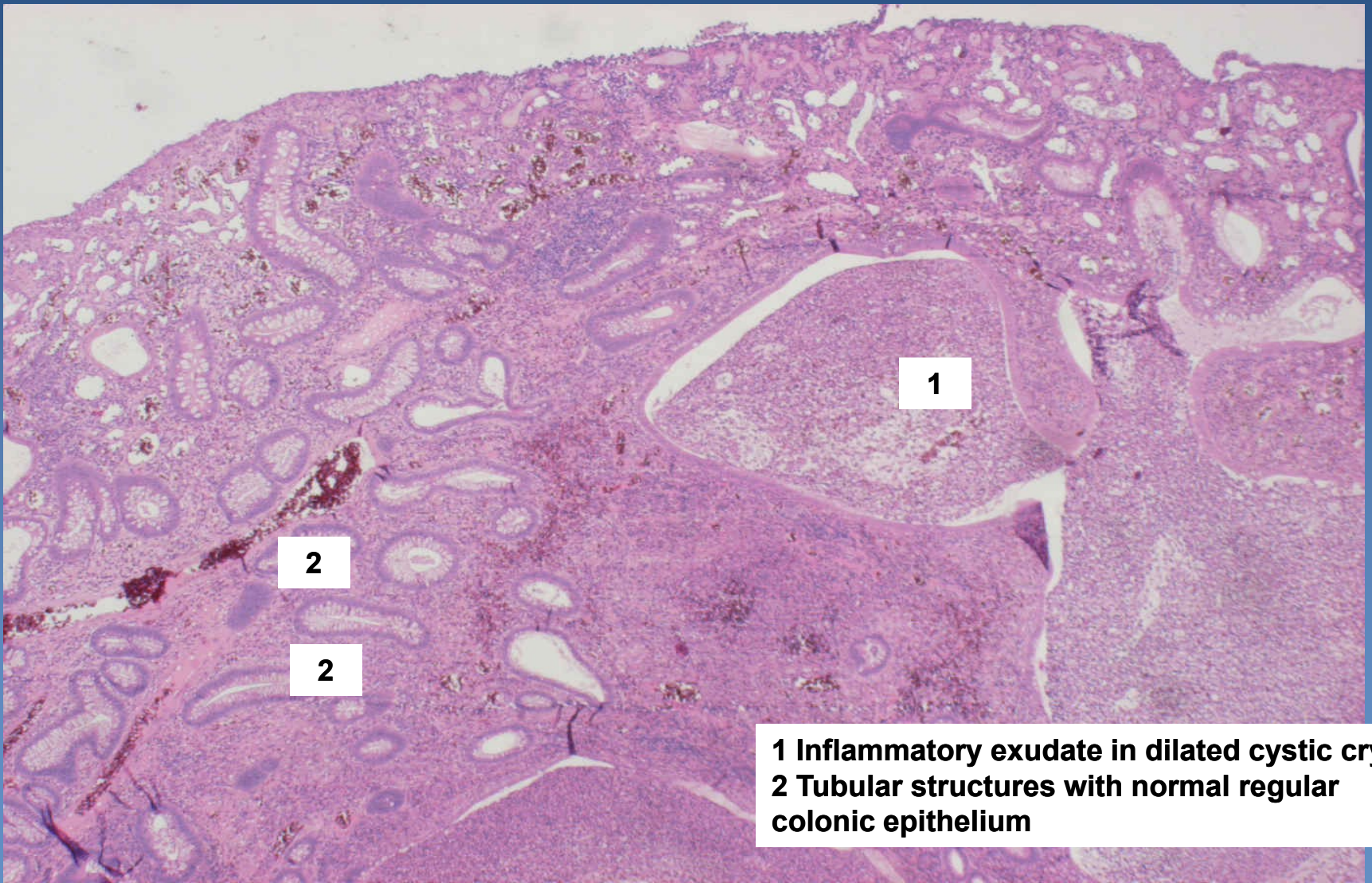


Colon – hyperplastic polyp



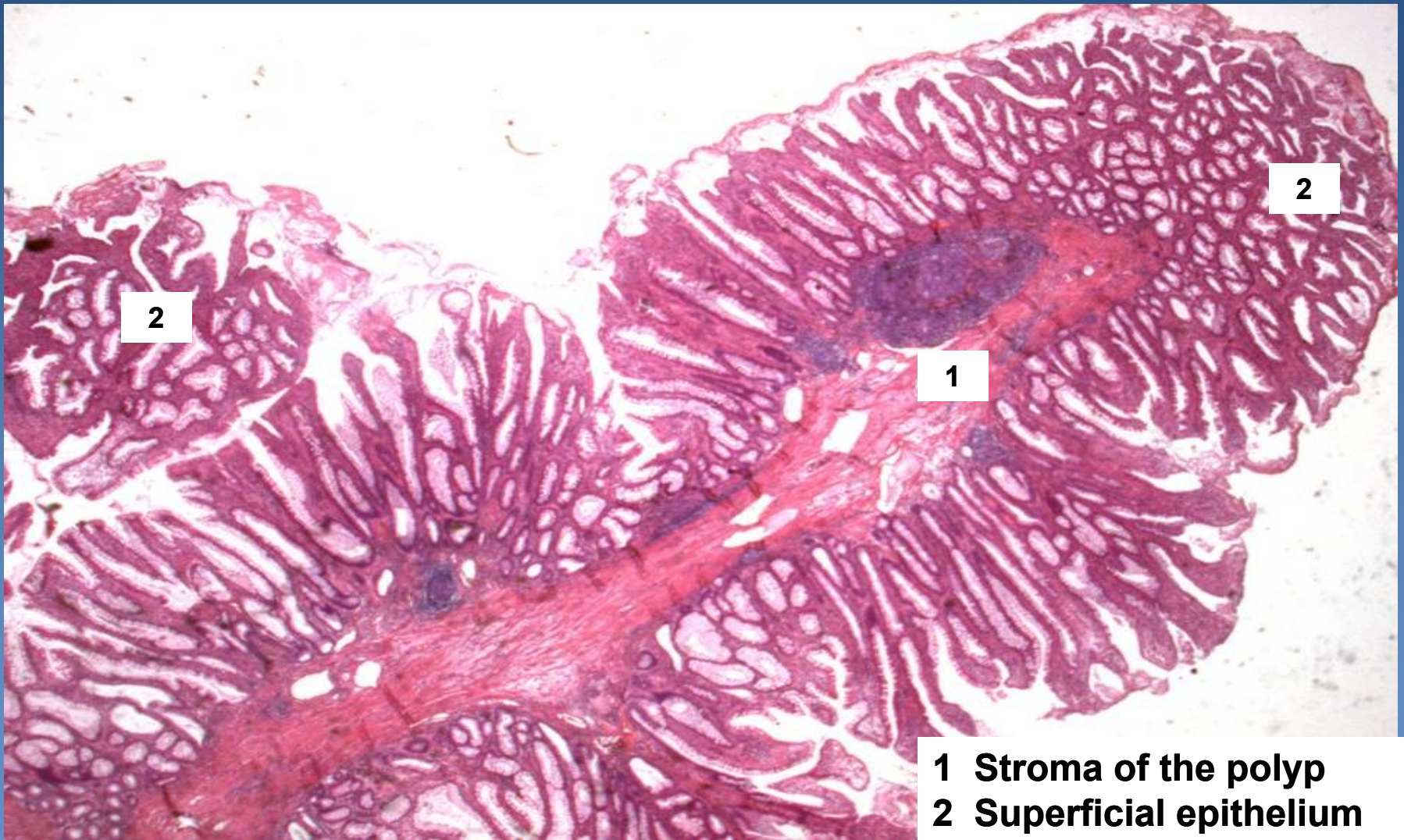
- 1** Hyperplastic epithelium
- 2** Enterocytes
- 3** Goblet cells

Colon - juvenile polyp



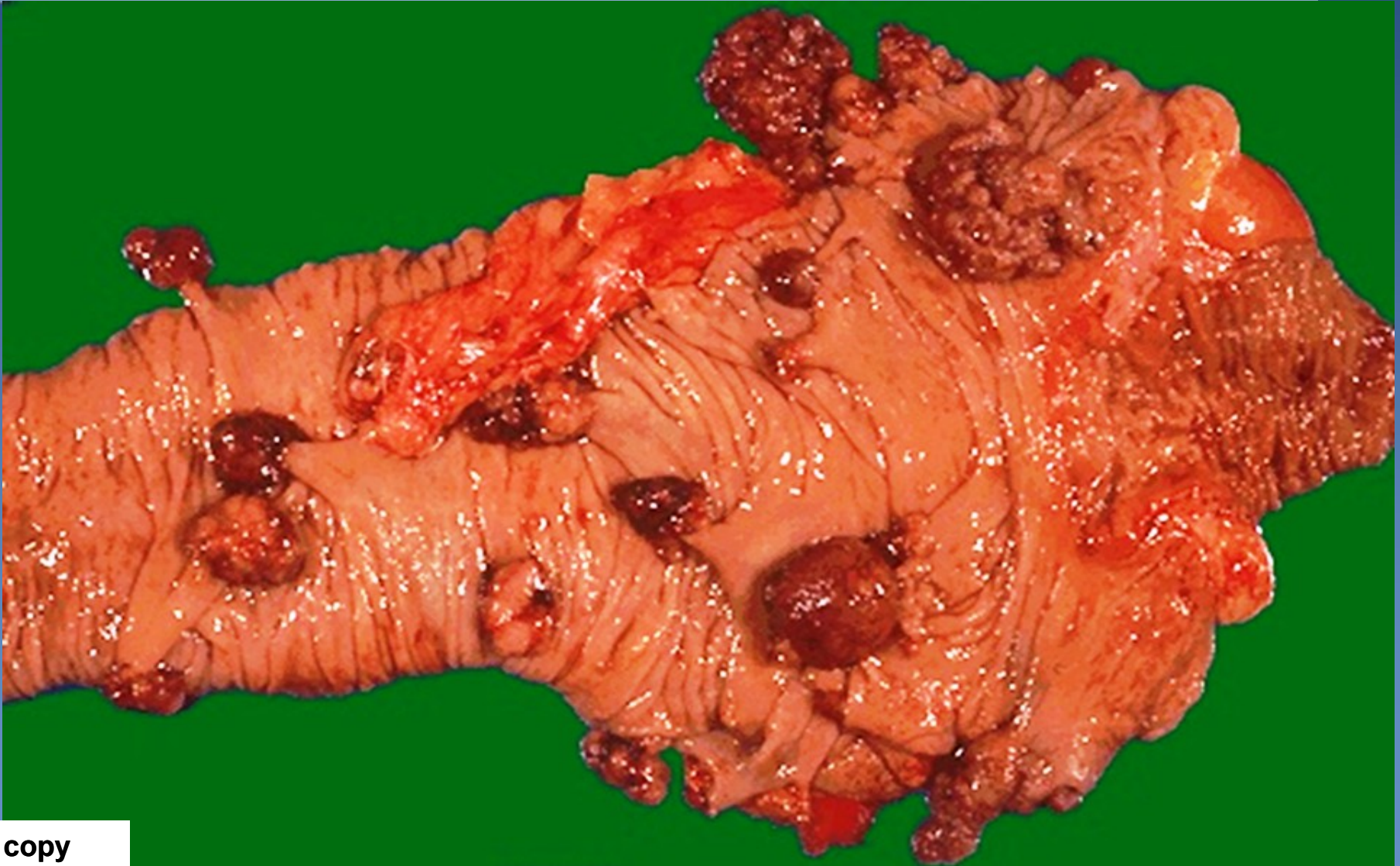
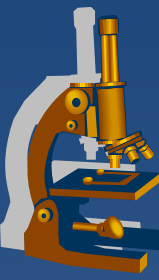
1 Inflammatory exudate in dilated cystic crypt
2 Tubular structures with normal regular colonic epithelium

Colon - hamartomatous P-J polyp

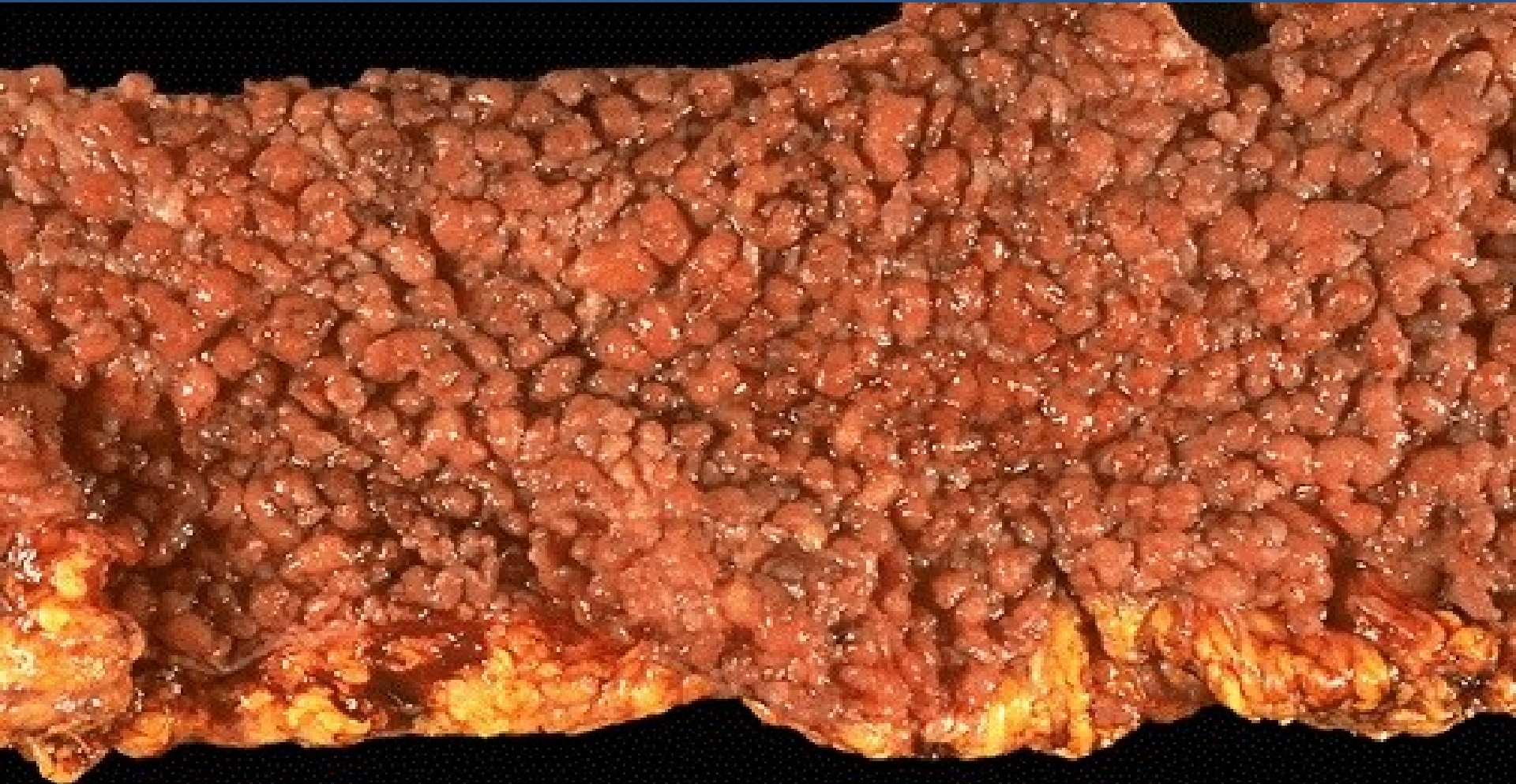
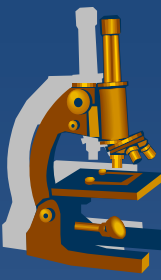


- 1** Stroma of the polyp
- 2** Superficial epithelium

Adenomas

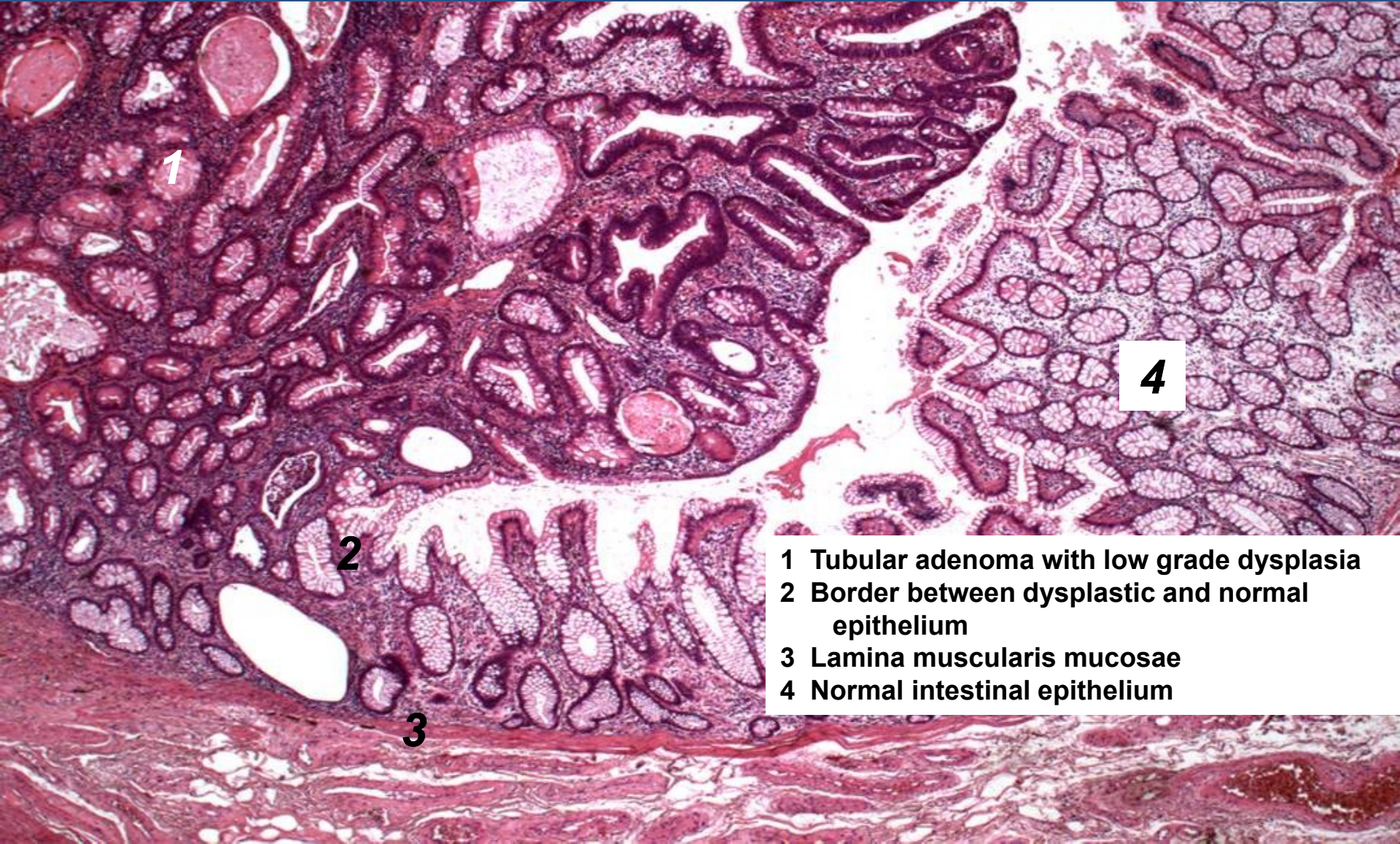
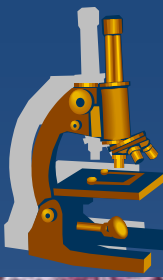


Polyposis of the colon



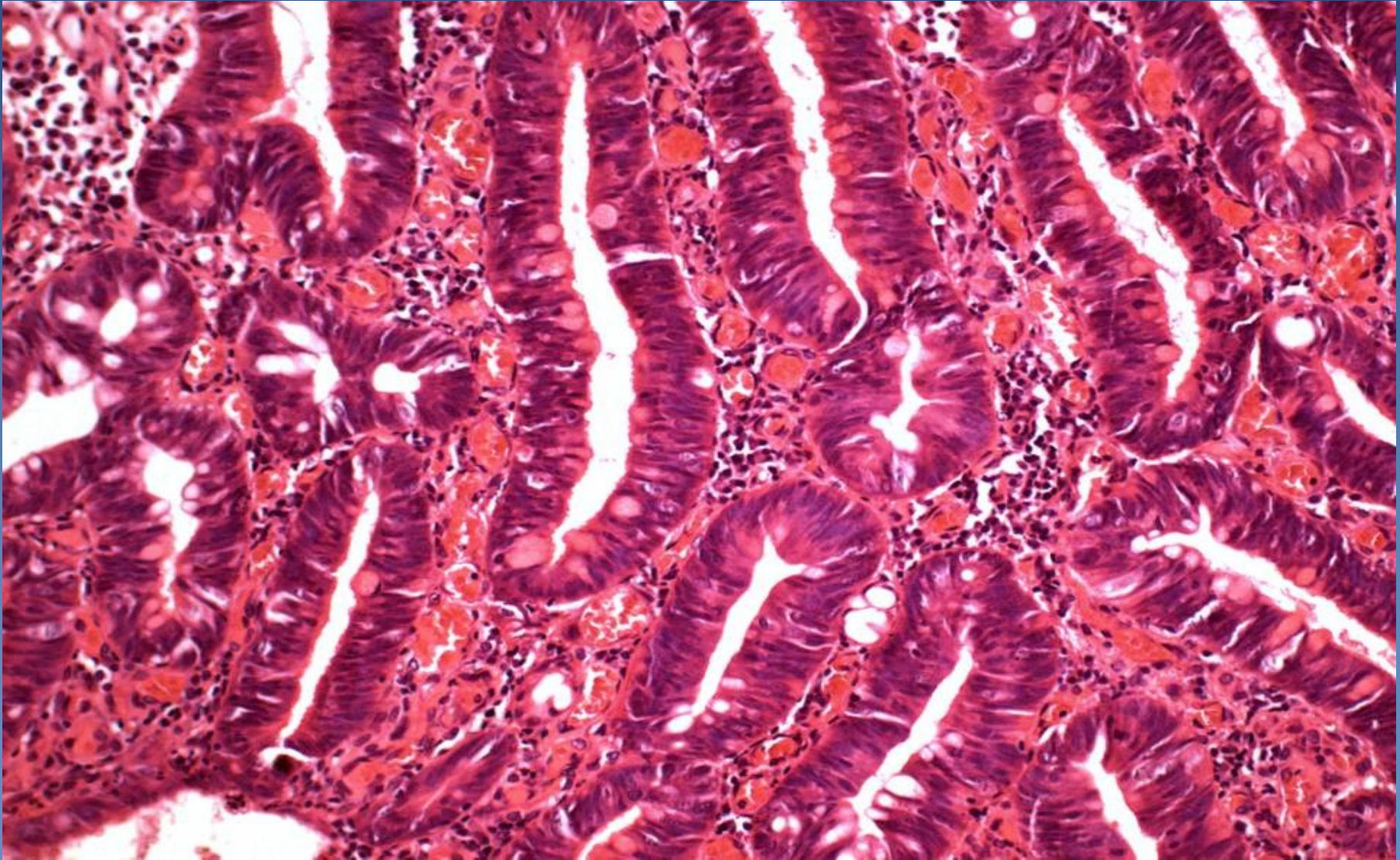
copy

Tubular adenoma

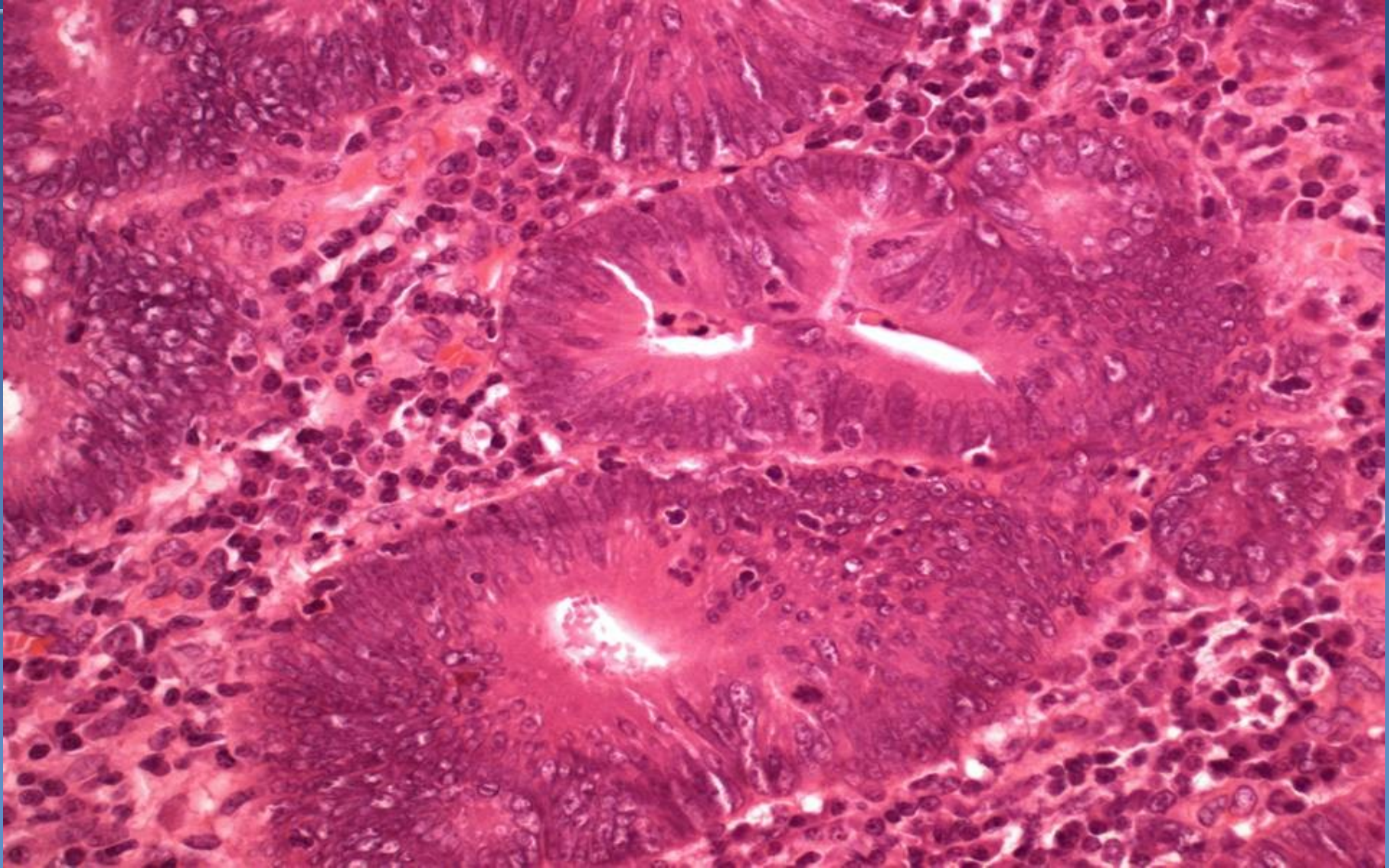


- 1 Tubular adenoma with low grade dysplasia
- 2 Border between dysplastic and normal epithelium
- 3 Lamina muscularis mucosae
- 4 Normal intestinal epithelium

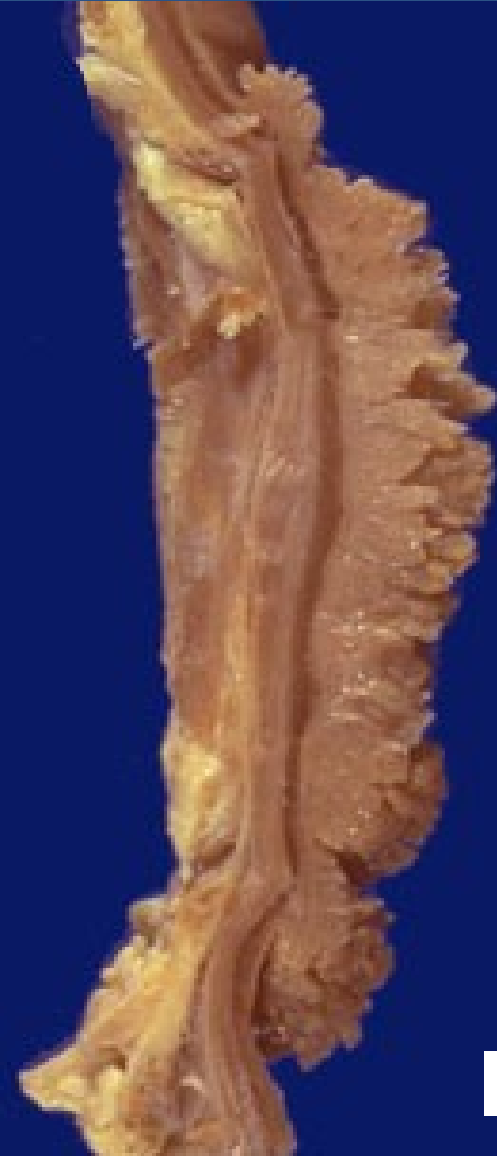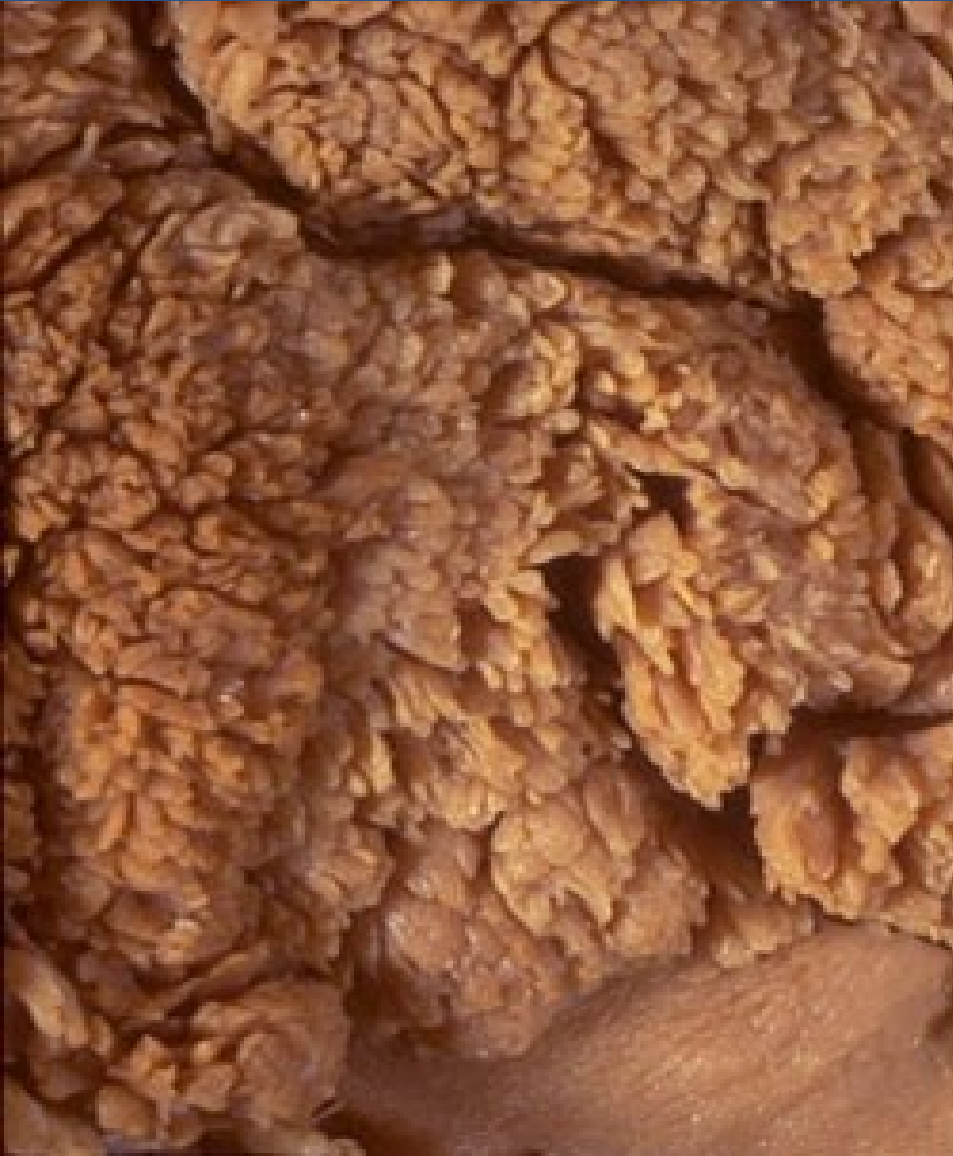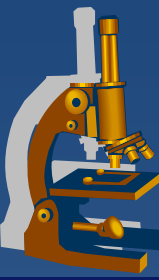
***Tubular adenoma
– low grade dysplasia***



***Tubular adenoma
– high grade dysplasia***

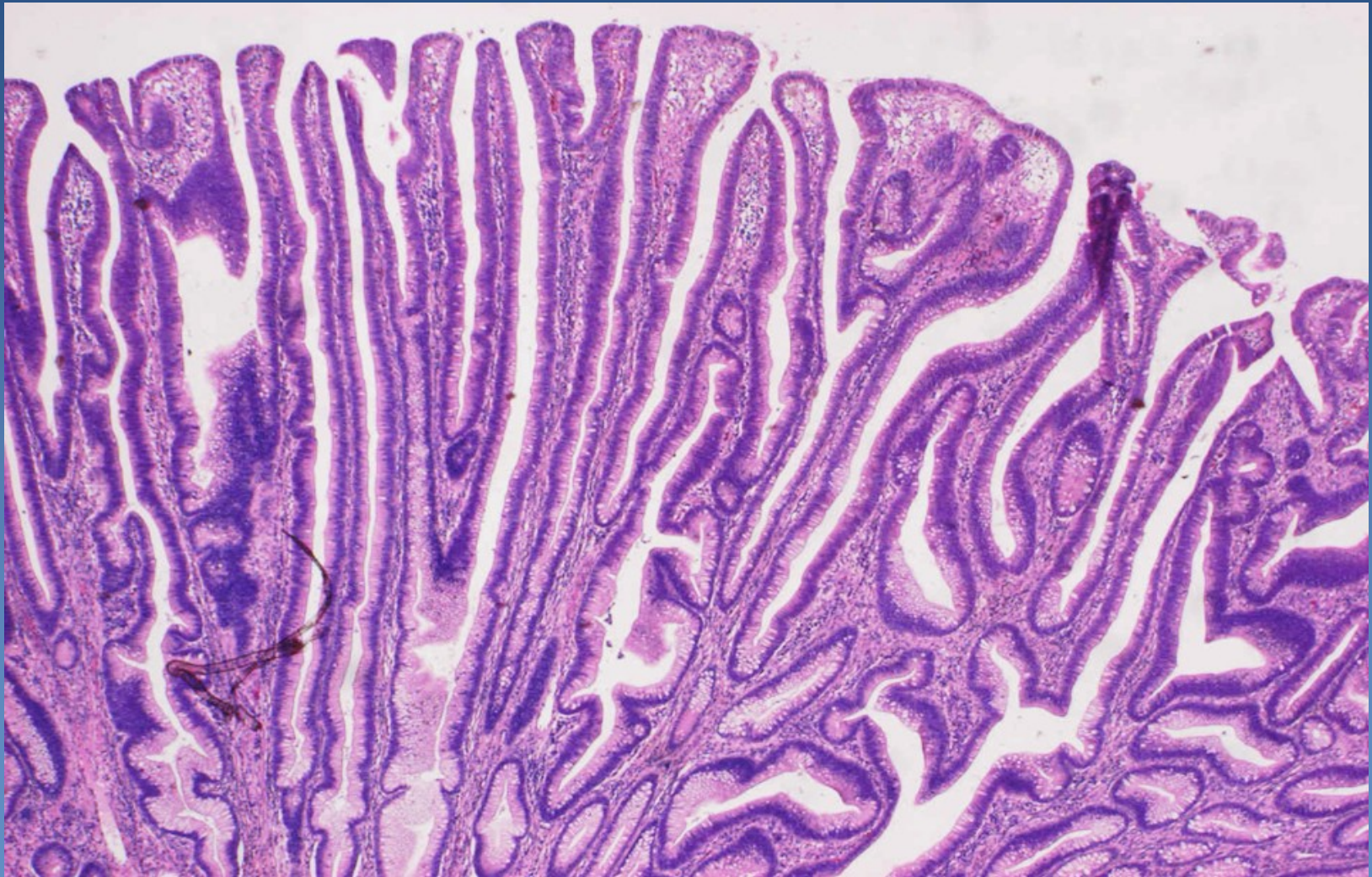
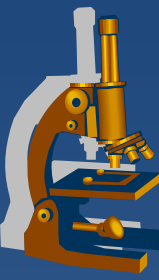


Villous adenoma



copy

Villous adenoma



Colorectal carcinoma



- ✗ high incidence in the Czech Republic and other developed countries
- ✗ 60 - 70 % in the rectum and sigmoid (50% detectable by per rectum examination)
- ✗ Risk factors: lifestyle + diet, smoking, alcohol
 - ⇒ *high intake: refined carbohydrates, fat, red meat*
 - ⇒ *decreased intake: unabsorbable vegetable fiber, protective micronutrients (vitamins A,C,E)*
- ✗ predisposing factors: genetic
 - ⇒ *polyposis*
 - ⇒ *ulcerative colitis*

Colorectal carcinoma



×Gross:

⇒ *exophytic, polypous*

- proximal colon - long time asymptomatic

⇒ *endophytic, ulcers with heaped-up edges*

- distal colon - early stenosis

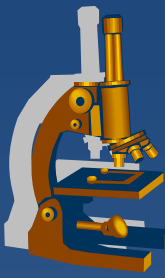
⇒ *annular*

- encircling lesions

⇒ *infiltrative*

- rare, linitis plastica type

Colorectal carcinoma



×Micro:

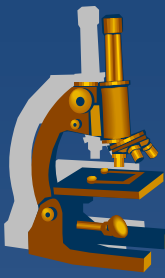
⇒ *tubular adenocarcinoma (most frequently)*

⇒ *other adenocarcinoma types:*

- cribriform comedo-type
- micropapillary
- medullary
- mucinous
- serrated
- signet ring cell

⇒ *adenosquamous, spindle-like, squamous cell, undifferentiated*

Colorectal carcinoma



- ✘ **TNM classification and tumor progression:**
 - ⇒ *pTis intraepithelial/intramucosal (100% 5-year survival, no metastases)*
 - ⇒ *pT1 submucosa (90% survival)*
 - ⇒ *pT2 into the muscularis propria (+LN metastases possible);*
 - ⇒ *pT3 subserosa (+ metastases common), 35% survival in LN meta - pT3N1*
 - ⇒ *pT4 transperitoneal/invasion into adjacent organ*
Distant metastases present - 8% survival.

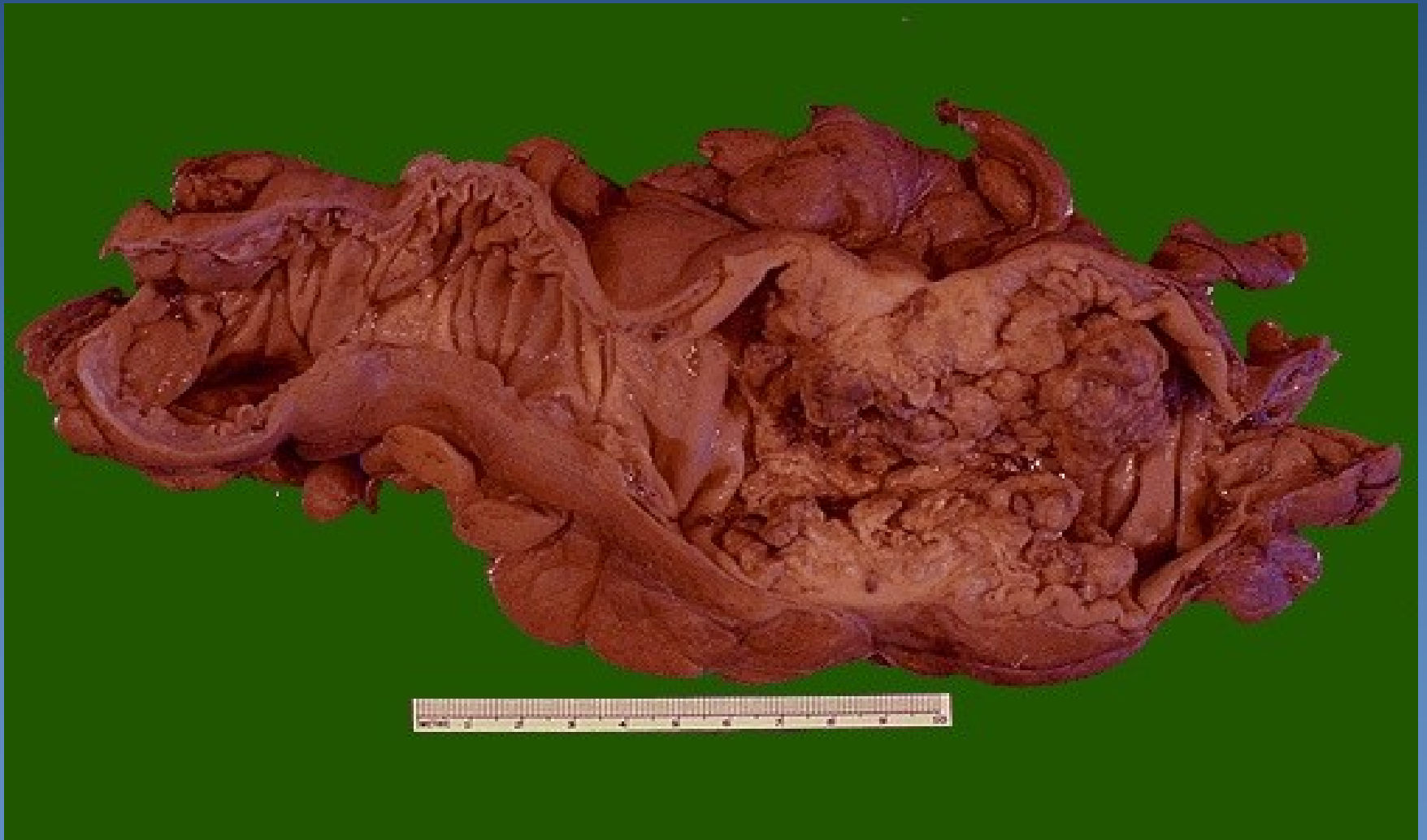Colorectal carcinoma



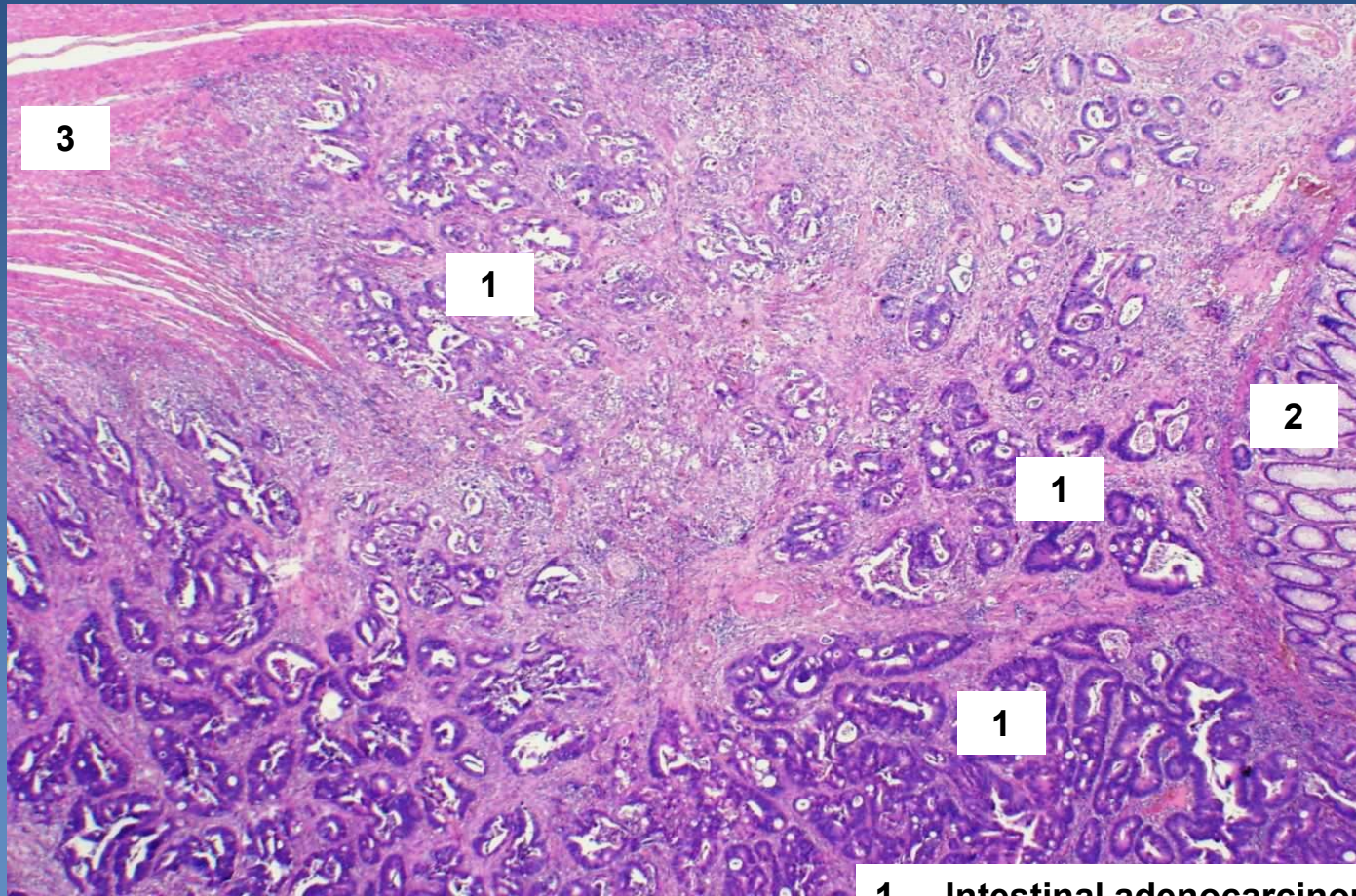
Staging

- ✗ stage I: T1, T2, no meta
- ✗ stage II: T3, T4, no meta
- ✗ stage III: any T, LN meta, no distant meta (M0)
- ✗ stage IV: any T, any N, M1

Colorectal carcinoma

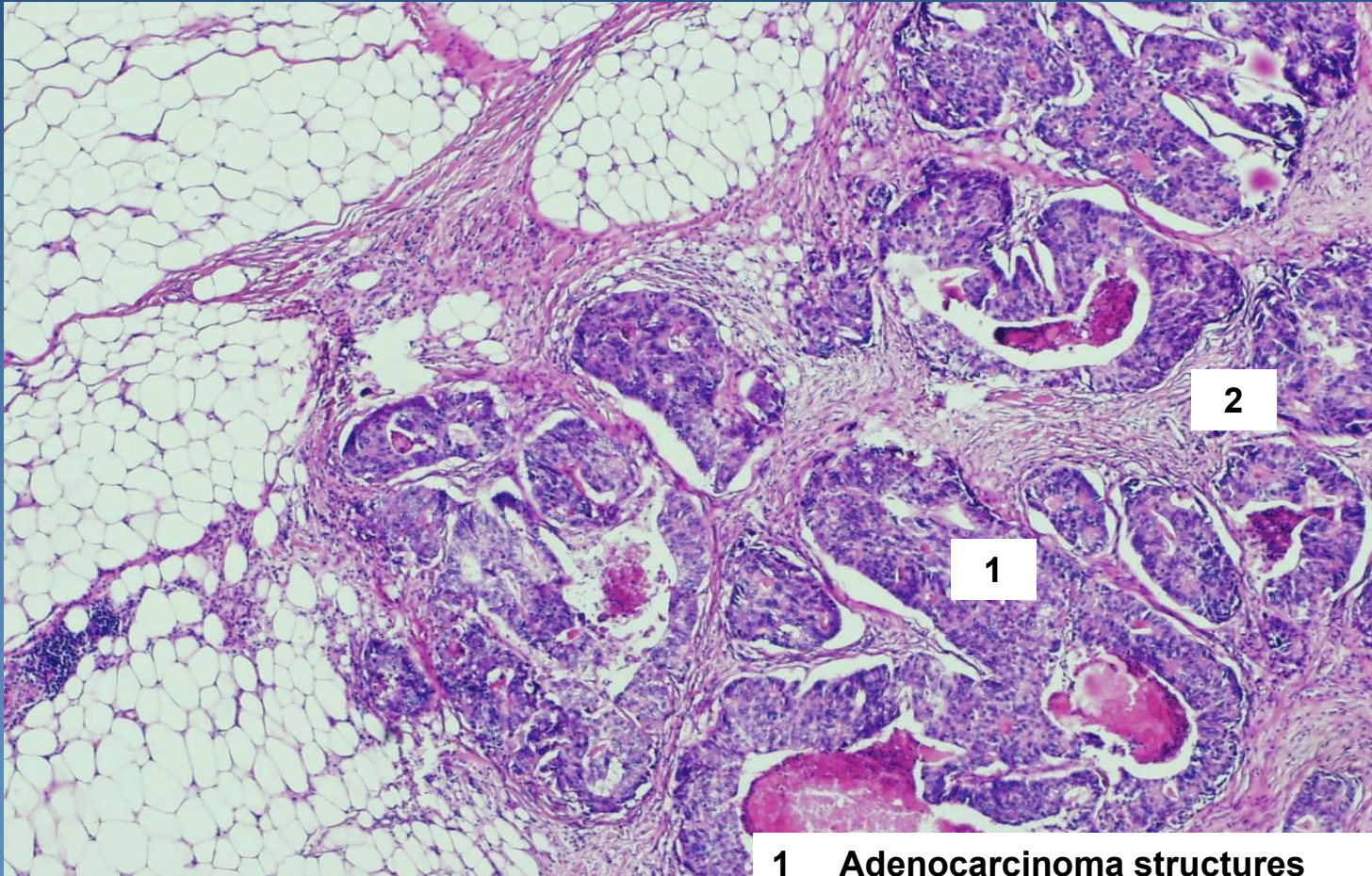


Adenocarcinoma of the colon



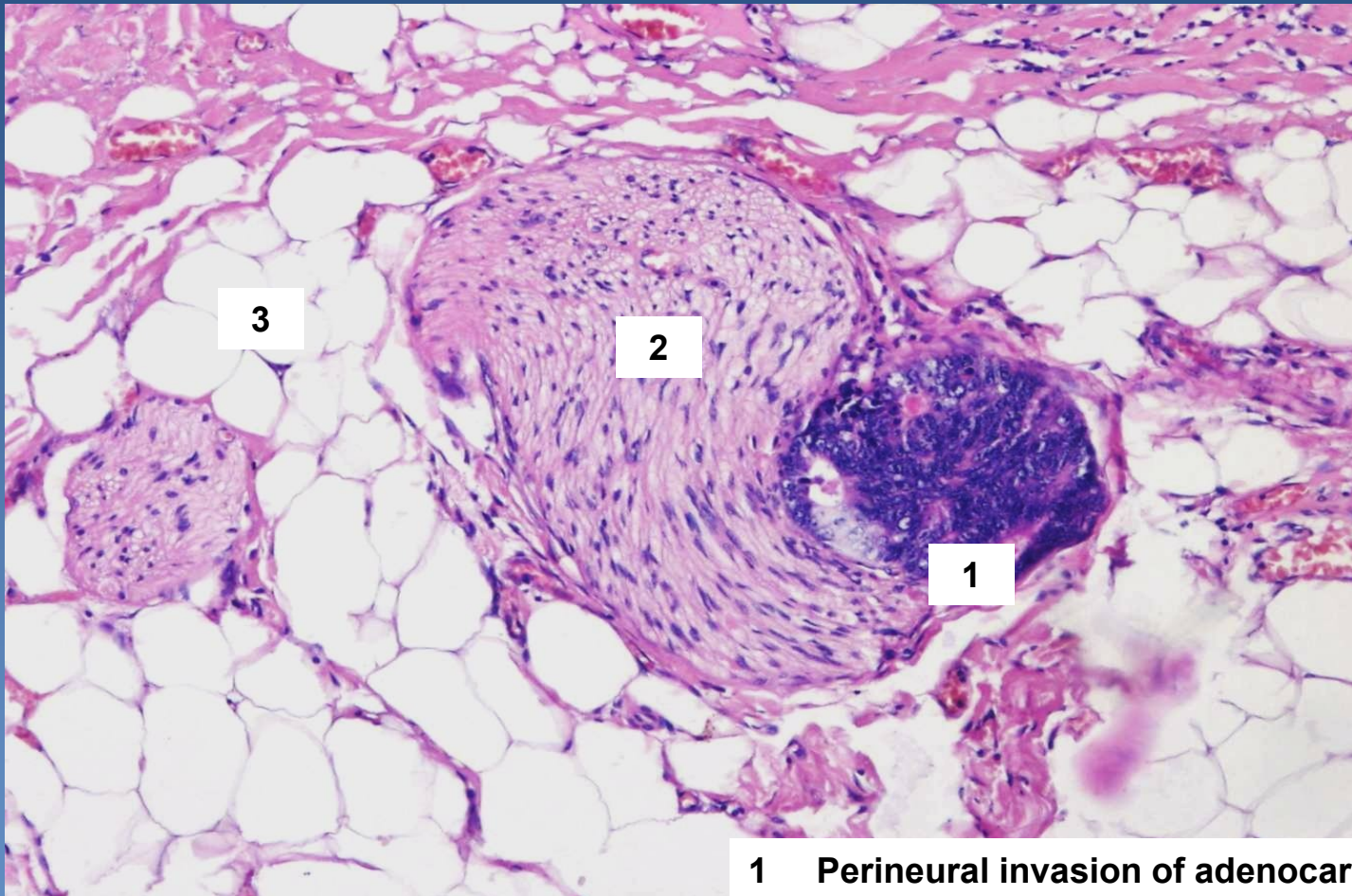
- 1** Intestinal adenocarcinoma structures
- 2** Normal colonic epithelium
- 3** Muscularis propria

Adenocarcinoma of the colon



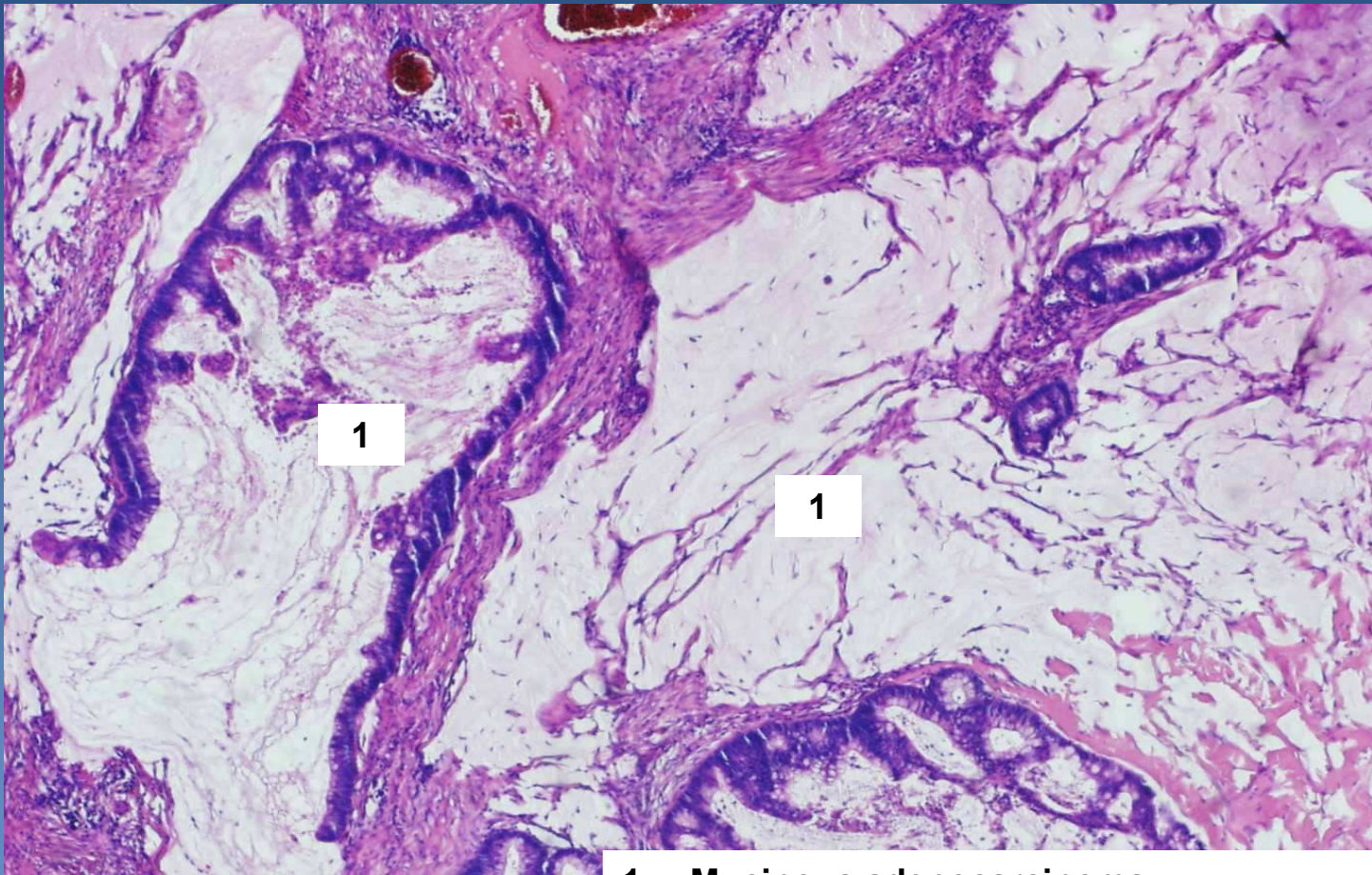
- 1 Adenocarcinoma structures**
- 2 Pericolonic fat and fibrous tissue**

Adenocarcinoma of the colon



- 1** Perineural invasion of adenocarcinoma
- 2** Peripheral nerve
- 3** Pericolonic fat

Adenocarcinoma of the colon

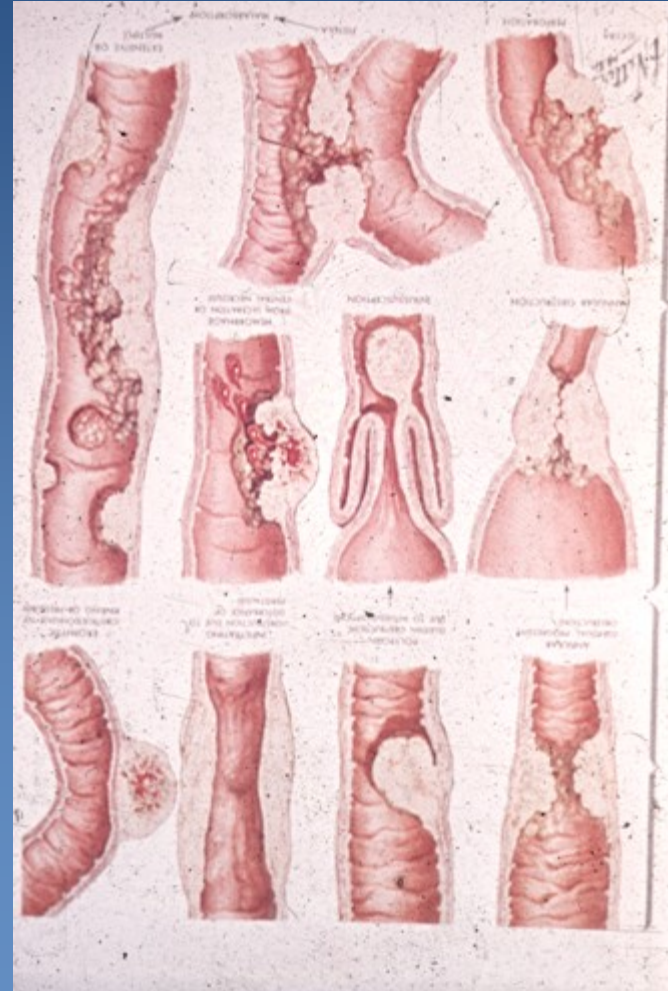

1 Mucinous adenocarcinoma

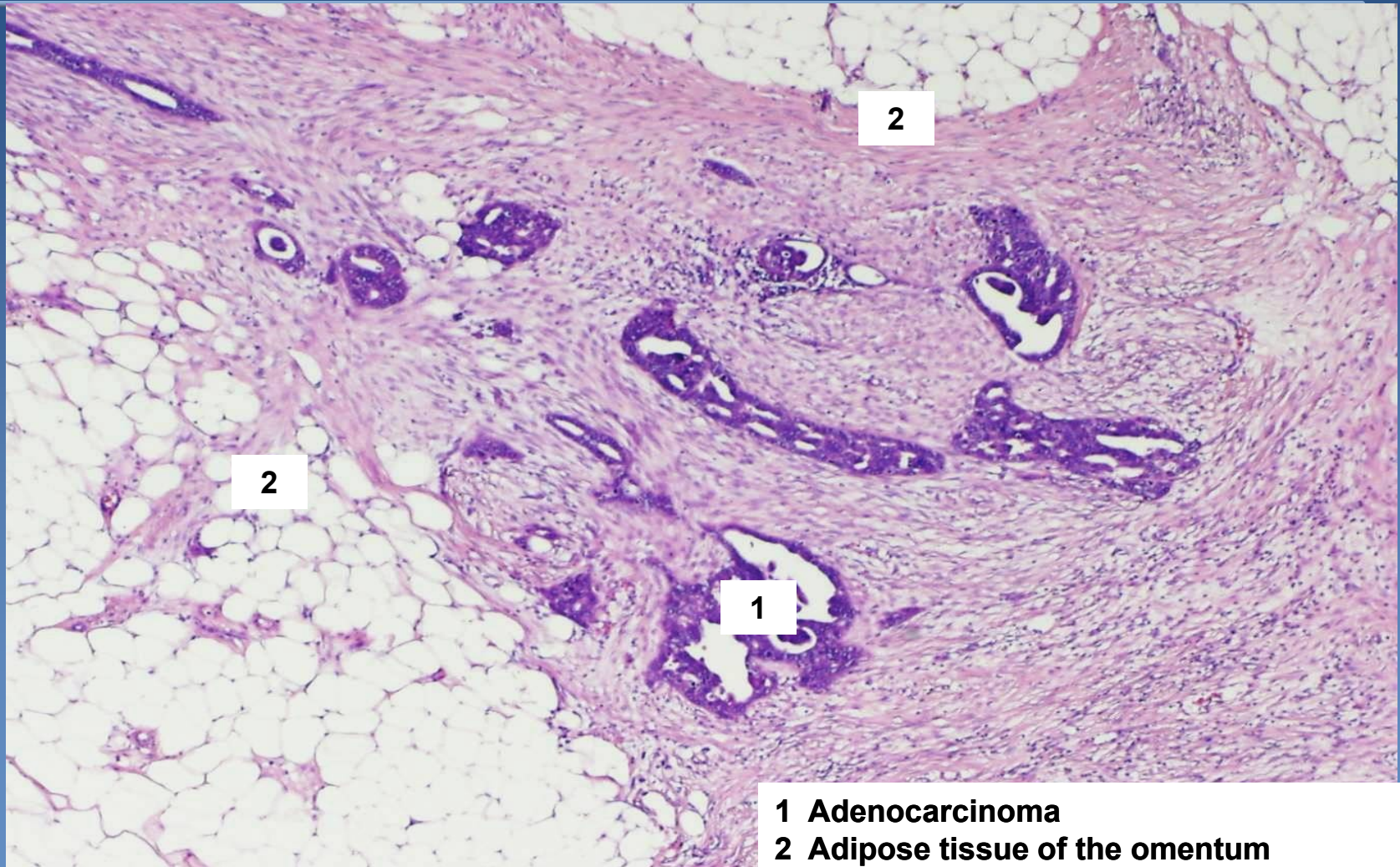
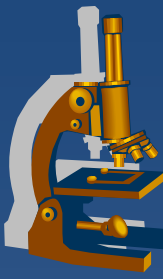
Colorectal carcinoma - complications



- ✗ stenosis
- ✗ obstructive ileus
- ✗ hemorrhage (occult!, overt)
- ✗ perforation
- ✗ penetration
- ✗ stercoral peritonitis

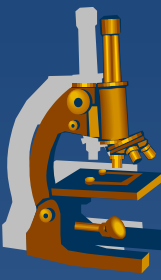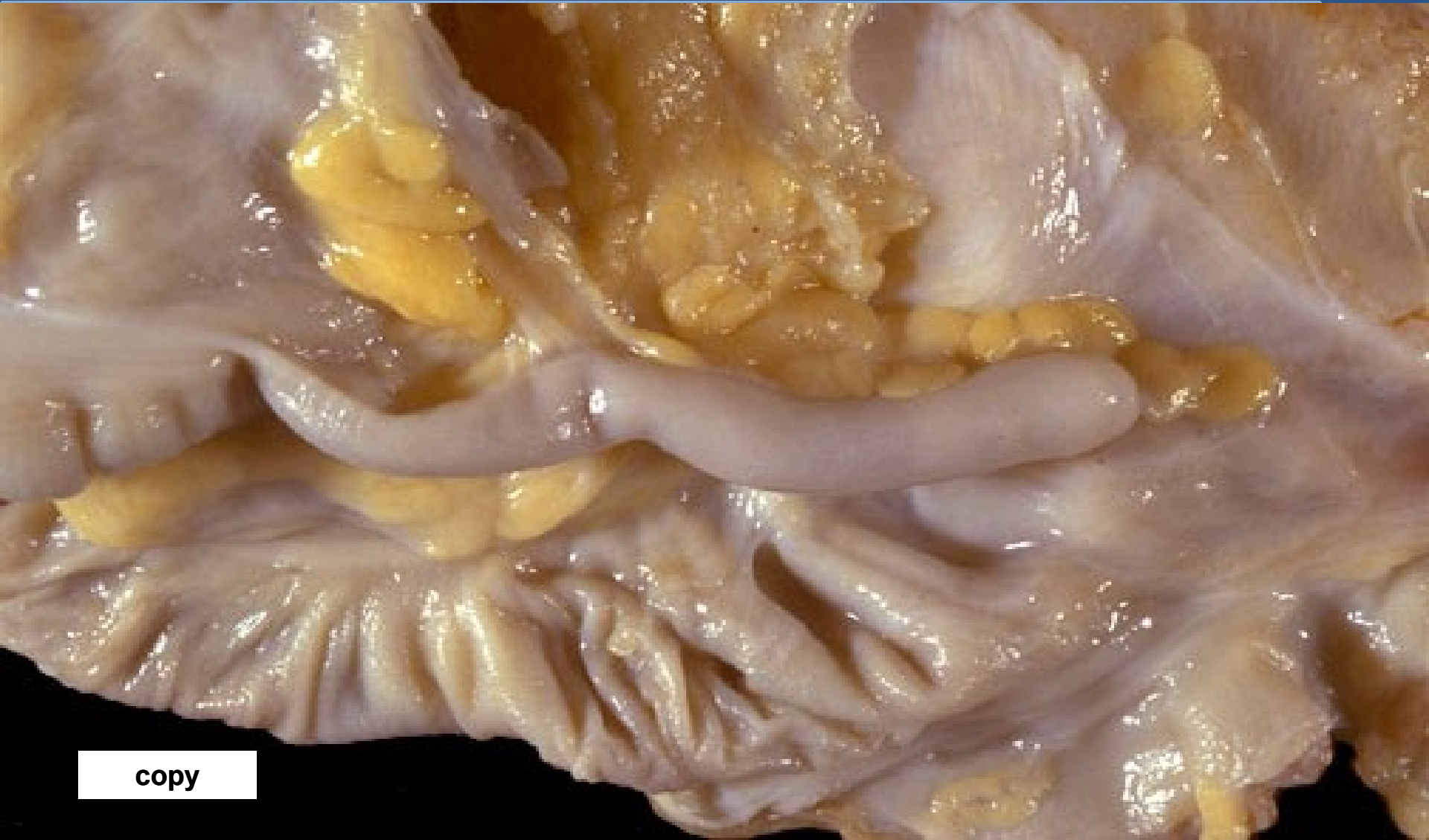


Peritoneal carcinomatosis ***widespread metastases in the peritoneum/ omentum***



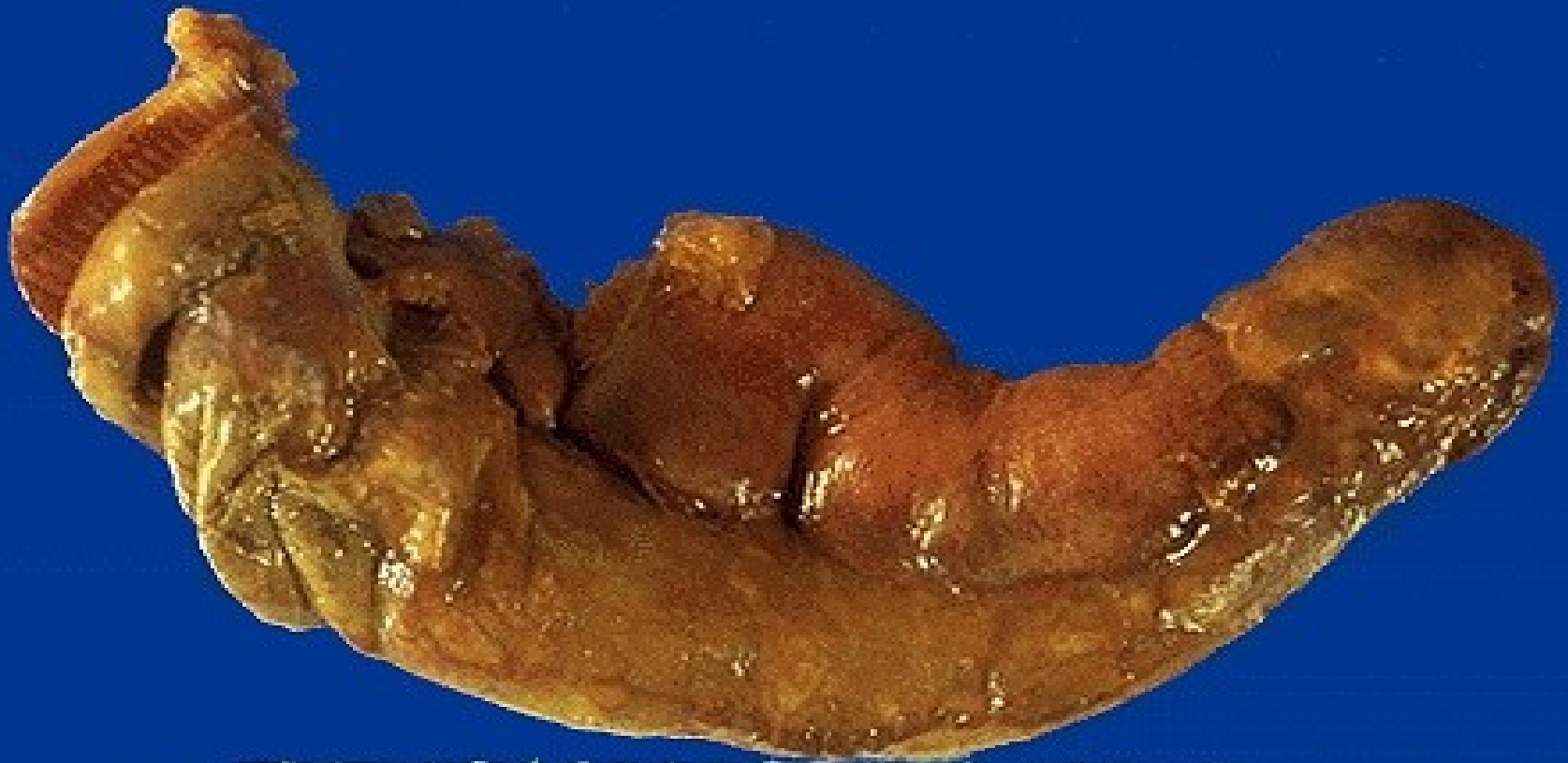1 Adenocarcinoma
2 Adipose tissue of the omentum

Appendix - normal



copy

Appendix - periappendicitis



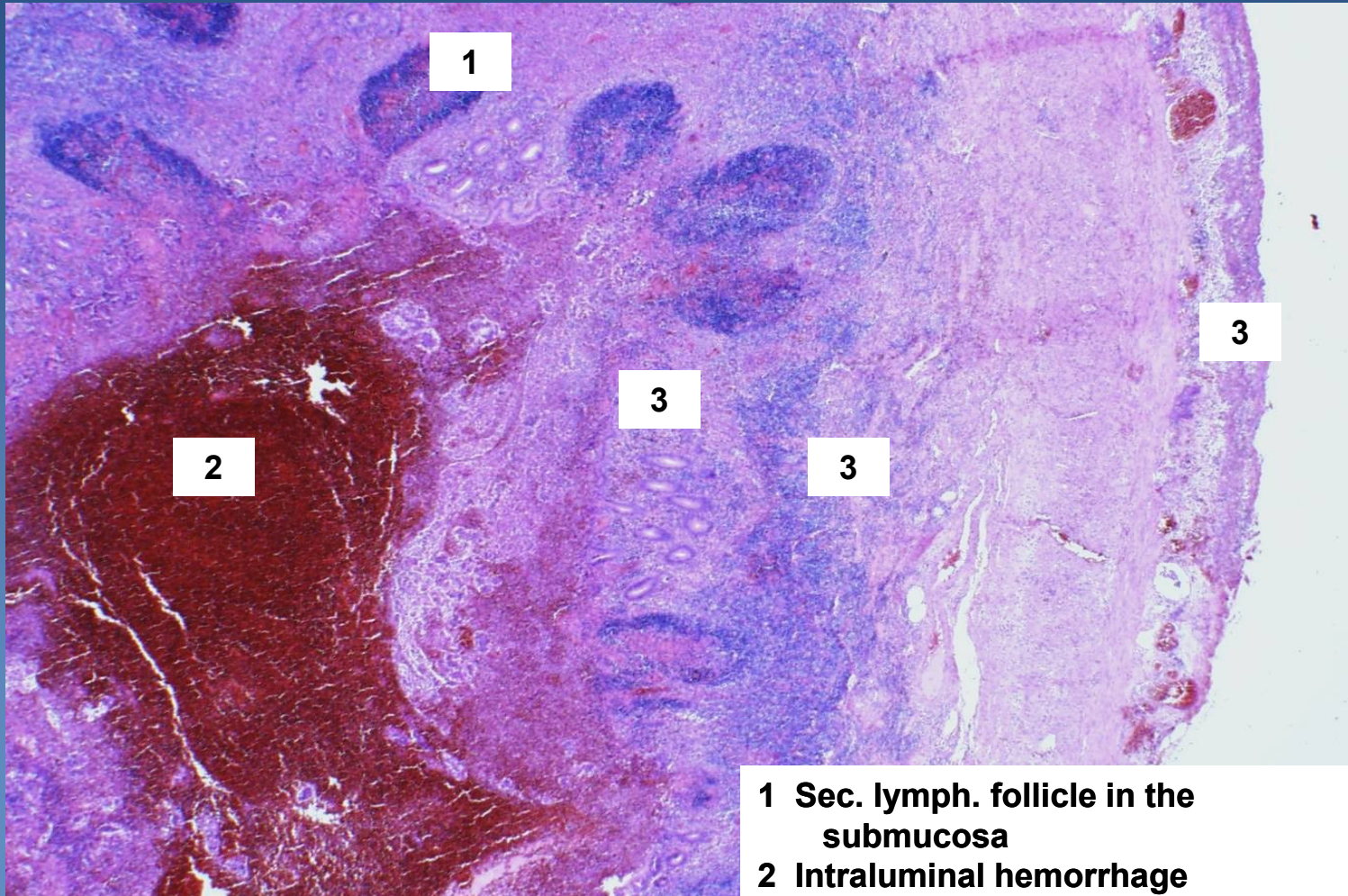
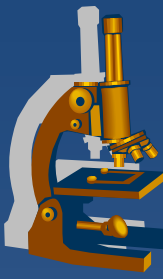
copy

Appendicitis



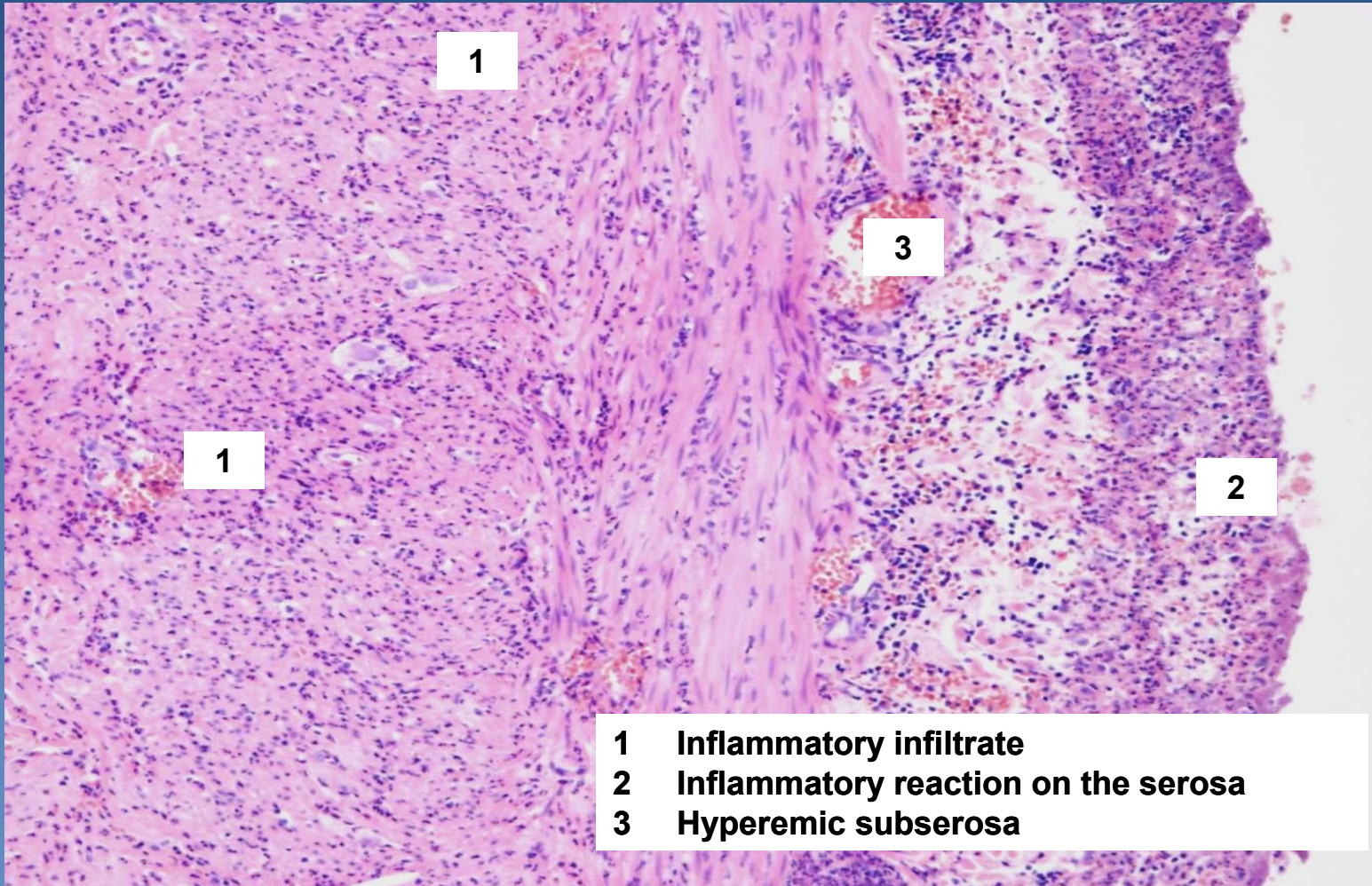
- ✘ Causes: ?obstruction, stool stagnation → collapse of the draining veins → ischemia of the wall → bacterial proliferation → inflammation (catarrhal, phlegmonous)
- ✘ Trombosis of mesenteric veins → ischemic necrosis of the appendiceal wall → secondary bacteria invasion → gangrenous inflammation
- ✘ Complications:
 - ⇒ *peritonitis*
 - ⇒ *periappendiceal abscess*
 - ⇒ *portal pyemia*
 - ⇒ *adhesions*

Phlegmonous appendicitis

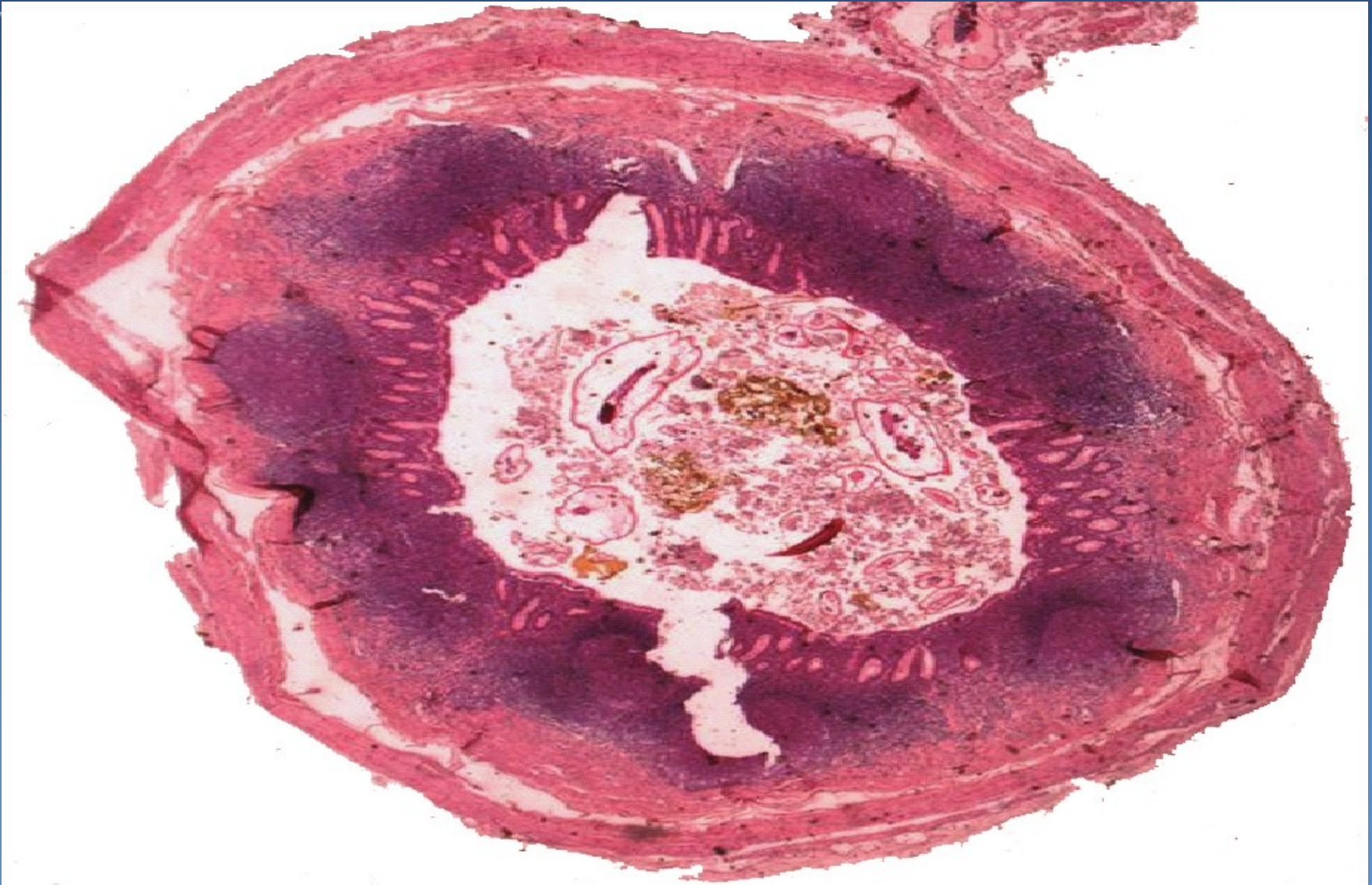


- 1 Sec. lymph. follicle in the submucosa**
- 2 Intraluminal hemorrhage**
- 3 Inflammatory infiltrate**

Phlegmonous appendicitis *- detail*



Parasitic appendicitis
- *Oxyuriasis vermicularis* (pinworm)
in the lumen



Neuroendocrine tumors (NETs)



✗ arise from neuroendocrine cells of the gastro-entero-pancreatic system (GEP-NET)

✗ histologic classification WHO 2010:

⇒ ***NET G1 (carcinoid)***

⇒ ***NET G2***

⇒ ***NEC G3 large cell or small cell type***

⇒ ***compound adenoneuroendocrine carcinoma***

Neuroendocrine tumors (NET)



- × arise from neuroendocrine or precursor cells of the GIT mucosa
- × mostly in the ileum and appendix (80%)
- × all NETs (except for a very few) **are considered malignant** in various grade

GEP-NET



x classification *depends on:*

⇒ *location*

⇒ *type of the endocrine product*

x gross:

⇒ *small, round-shaped, flat nodules of yellowish colour, infiltrating the wall to different depth, superficially ulcerated or covered with normal mucosa, sometimes exophytic*

GEP-NET



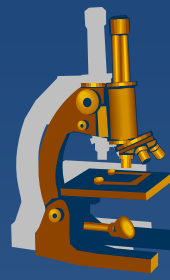
xmicro:

- ⇒ *trabecular, glandular structures - tubules, palisading or compound structure*
- ⇒ *regular cells with clear cytoplasm and round or oval-shaped nucleus; slight nuclear polymorphism*
- ⇒ *low mitotic activity*
- ⇒ *chromogranin A in cytoplasm*

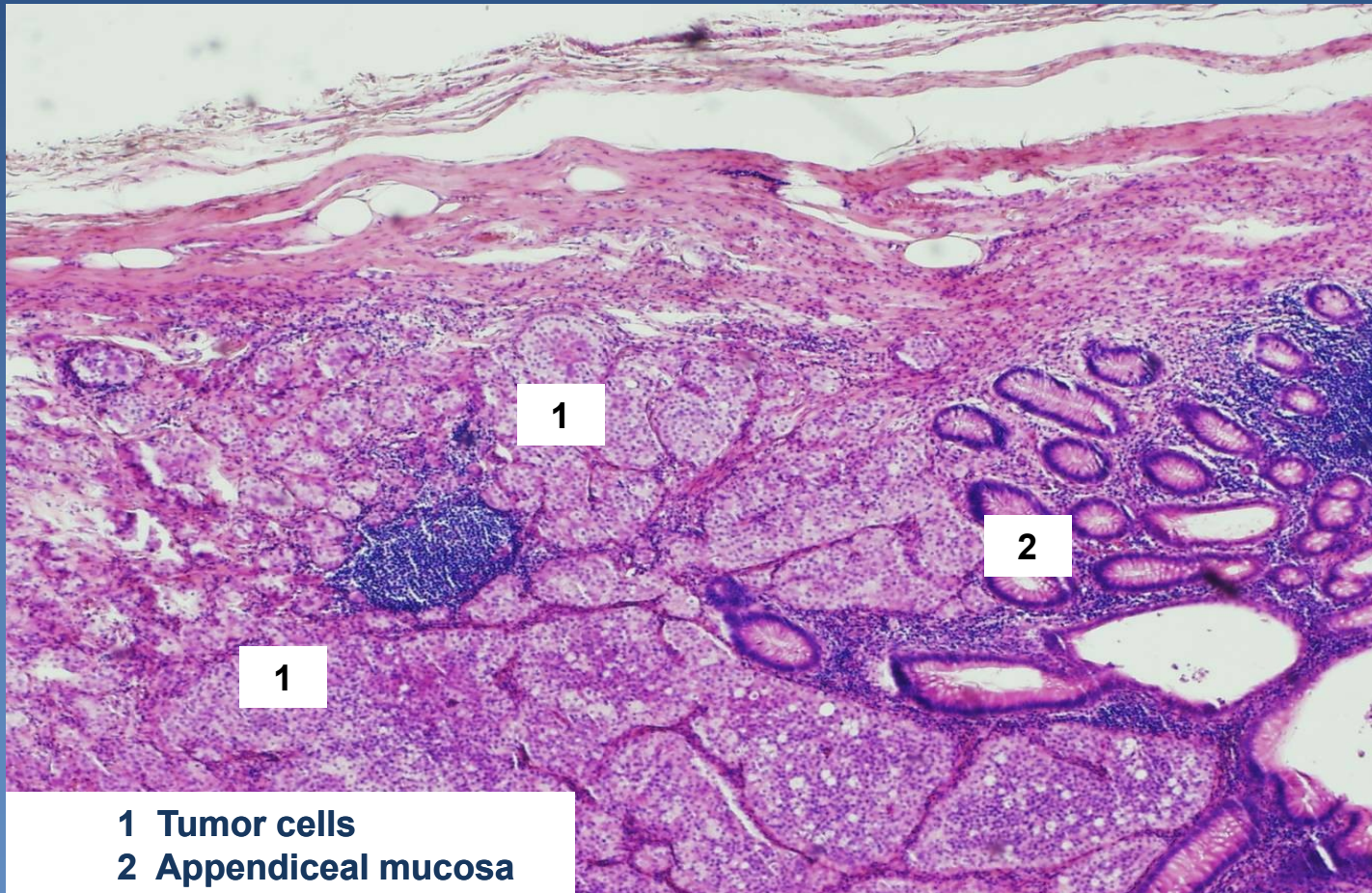
GEP-NET



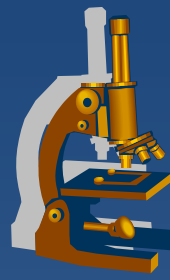
- ✗ possible production of various endocrine substances: serotonin, somatostatin, gastrin
- ✗ *serotonin active only locally in intestine → intestinal hypermotility with diarrhea*
- ✗ **liver metastases → carcinoid syndrome:**
cutaneous „flush“ and cyanosis, nausea and vomiting, asthmatic bronchoconstrictive attacks, endocardial fibrosis in right ventricle, hepatomegaly



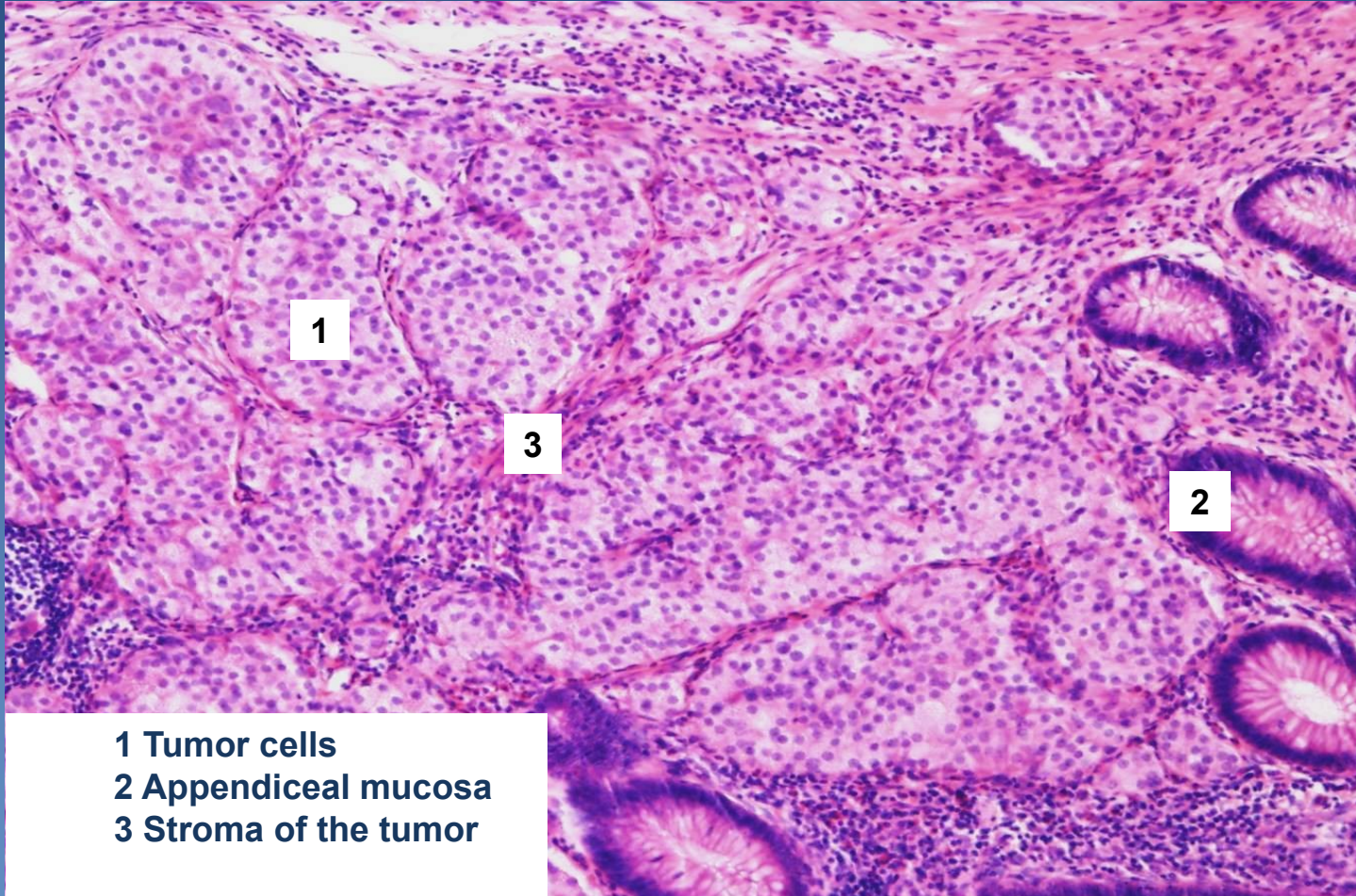
Carcinoid of the appendix



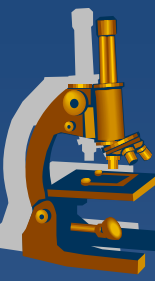
- 1 Tumor cells
- 2 Appendiceal mucosa



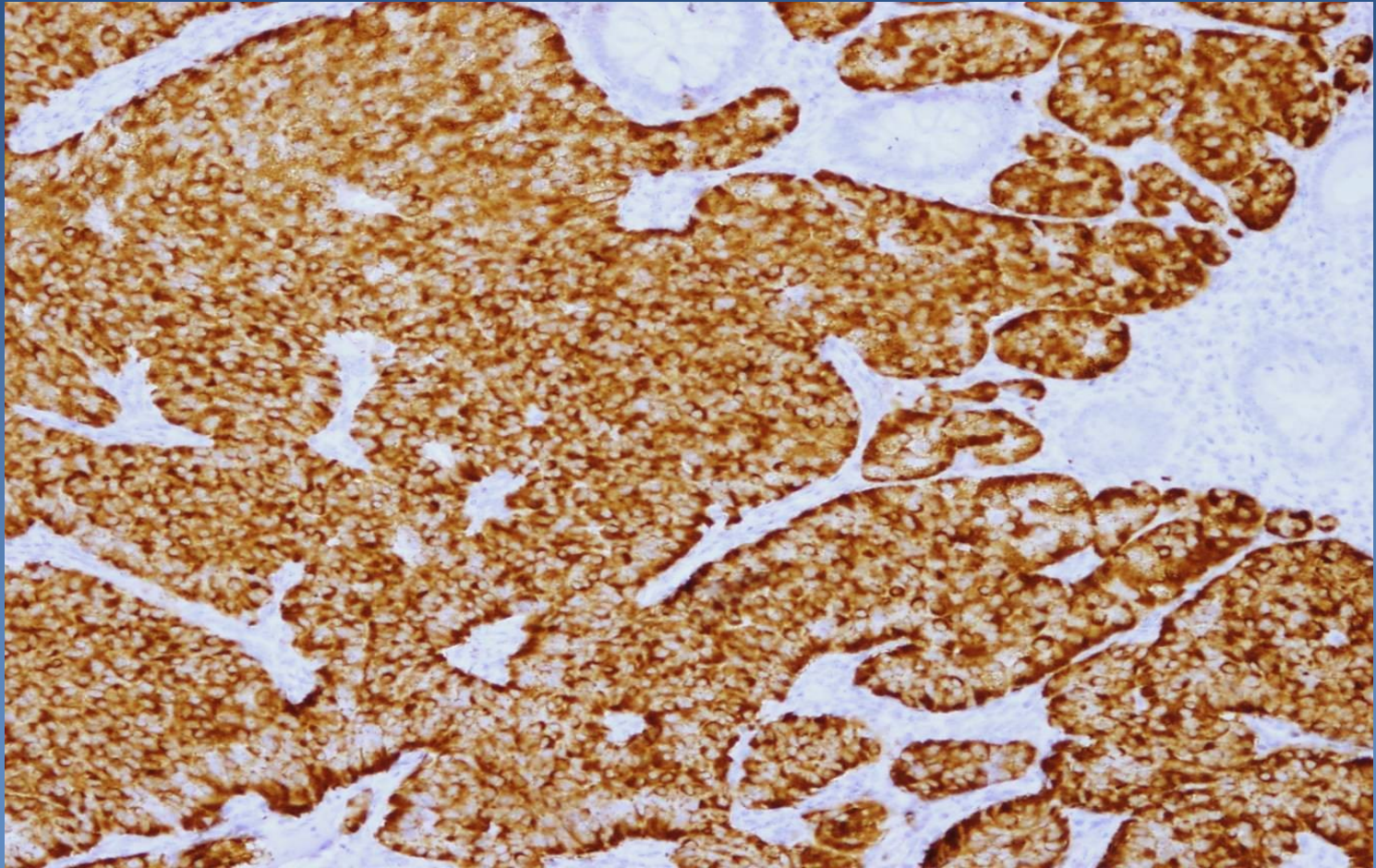
Carcinoid of the appendix detail

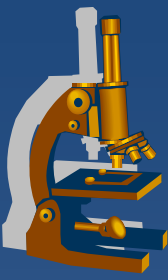


- 1 Tumor cells**
- 2 Appendiceal mucosa**
- 3 Stroma of the tumor**



Carcinoid of the appendix ***(IHC chromogranin)***





***THANK YOU FOR
ATTENTION***