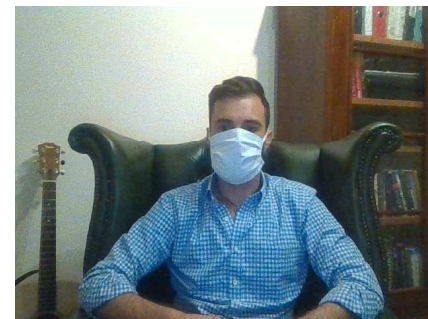

MUNI
MED


Prosthetics

Field, its essentials and use in practice

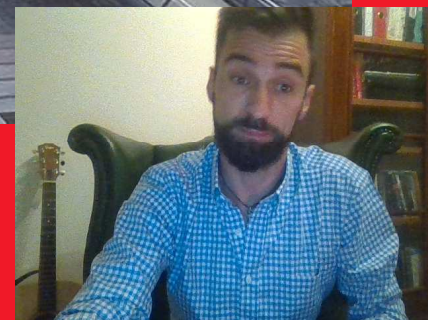Department of Orthopedic Surgery – Faculty of Medicine – Masaryk University
Assistant professor Jan Kocanda



MUNI MED

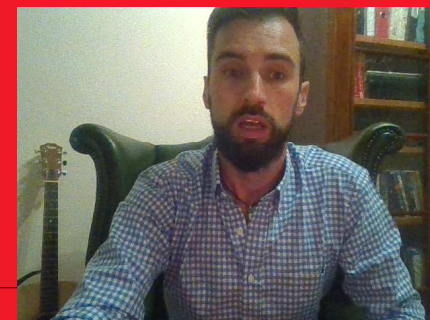

Prosthetics - Faculty of Medicine Masaryk University



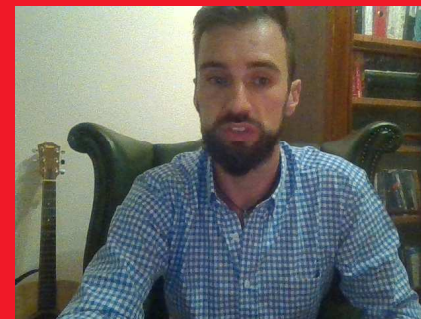

Prosthetics - Faculty of Medicine Masaryk University



MUNI
MED

Prosthetics - Faculty of Medicine Masaryk University



MUNI
MED

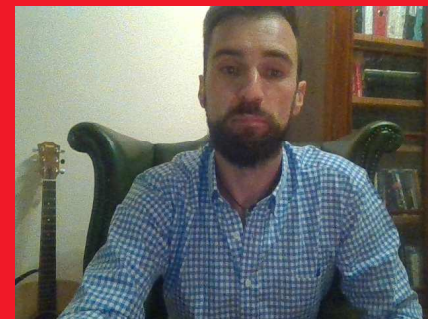Prosthetics - Faculty of Medicine Masaryk University



MUNI
MED

**Acknowledgements to assoc prof Zdenek Rozkydal & assoc prof Ivan Muller
for database**

Prosthetics - Faculty of Medicine Masaryk University



Orthopaedic Prosthetics

- Medical and technical production
- Distribution of rehabilitative care







Orthopaedic Prosthetics

- Proteometry – gets data for the design, production and application
- Prosthetics - the doctrine of replacement of lost parts of the body and function
- Orthotics - the doctrine of replacement of the lost functions of the body
- Epitetics - the doctrine of cosmetic covering of part of the body
- Kalceotika - the doctrine of orthopedic footwear
- Adjuvatics - the doctrine of operator aids



History

21st?



Proteometry

- History with a focus on social and work history
- Clinical examination
- Kinesiological analyses (GROSS a spol. 2005).
- Anthropometric examination
- Kartezian planes:
 - 3D, frontal, sagittal, transversal
 - orthopedic somatometry (base points, limb length, measuring sheets)



Prosthetics

doctrine on the replacement of lost body parts

□ Prothesis:

- Replacement: body parts and functions

- Requirements:

 - statics, dynamics, controllability
 - durability, aesthetics

- Construction:

 - Stump bed

 - Module (thigh, leg, leg, joint)

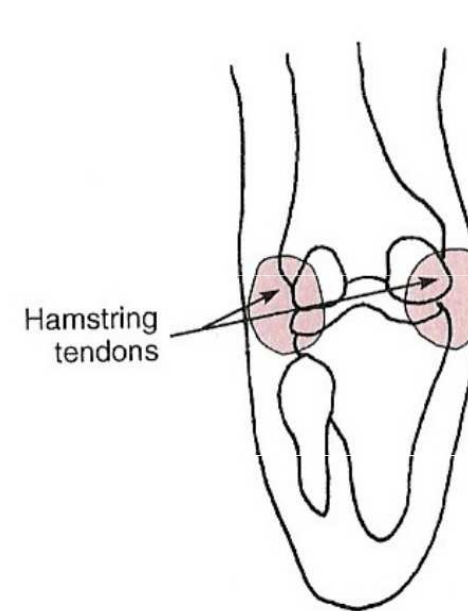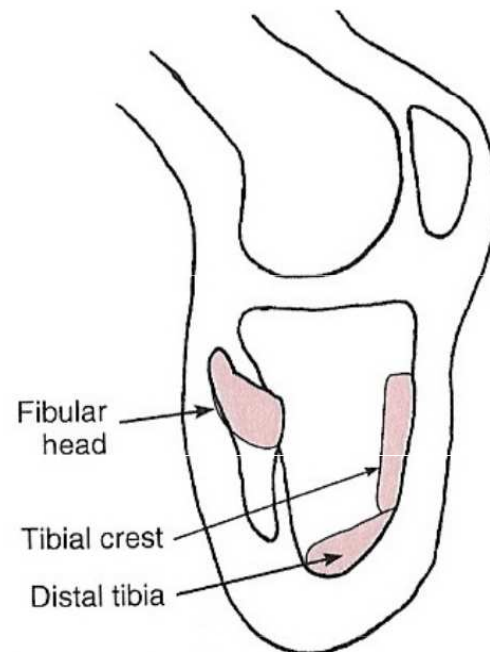
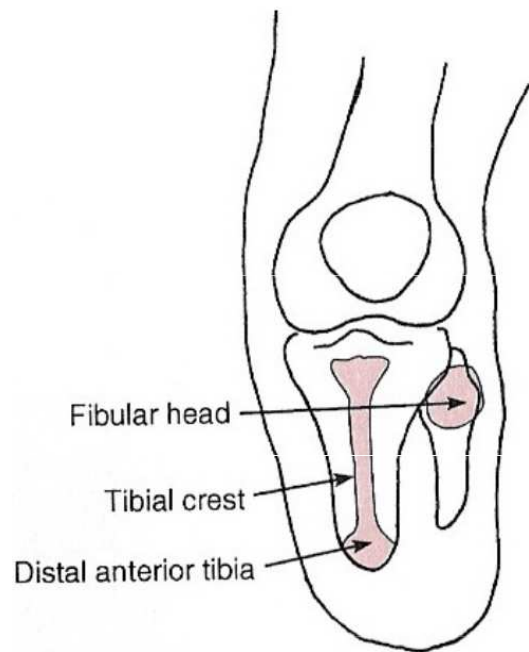
 - Auxiliary parts: bandages, stools



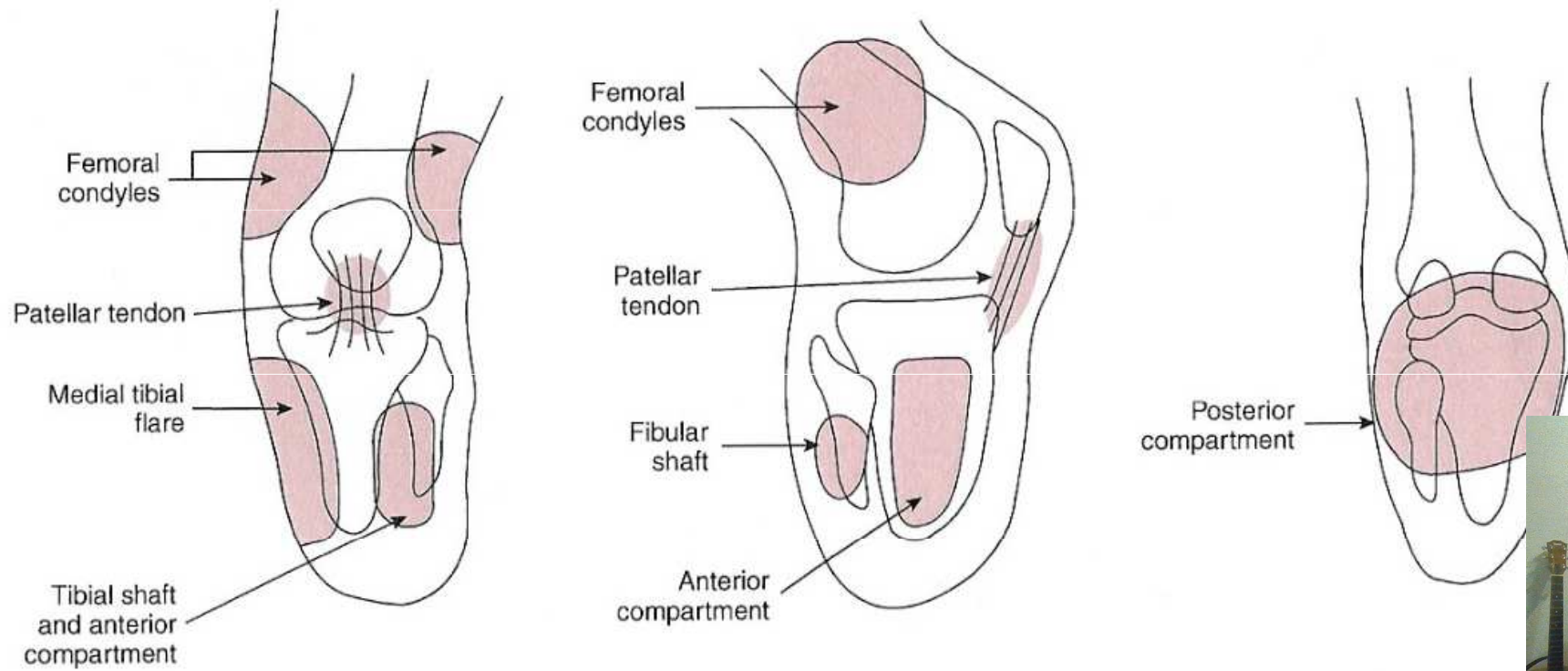
Prosthetics

Construction – stump bed

Intolerant





Transtibial: PTB Weightbearing





Prosthetics

Construction – stump bed



Prosthetics

Construction – stump bed

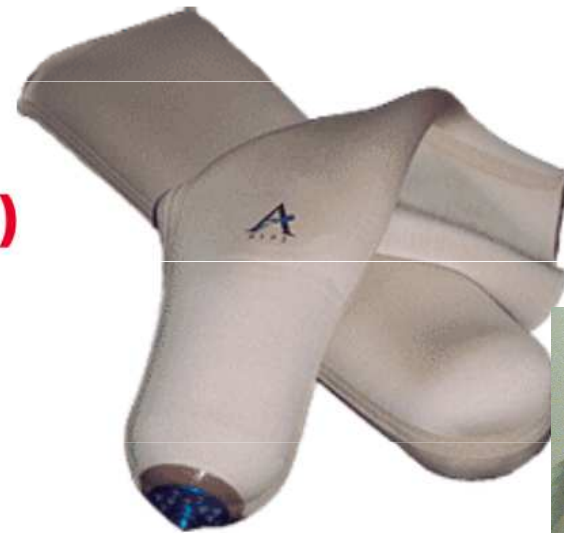

Prosthetics

Construction – stump bed


Interface material

- **Hard socket with ply socks or nylon**
 - **Themoplastic**
- **Gel Liner**
- **Soft inserts**
 - **Pelite (foam)**






Prosthetics

Stump moulding – stump bed





Prosthetics

Production – stump bed – negative positives





Prosthetics

Production – stump bed – silicone/rubber, thermoplastic






Prosthetics

Production – stump bed – exarticulation in the hip




Prothetics

Production – stump bed – exartulation in the hip



Prosthetics

Production – stump bed – exarticulation in the hip



Prosthetics

Construction – module



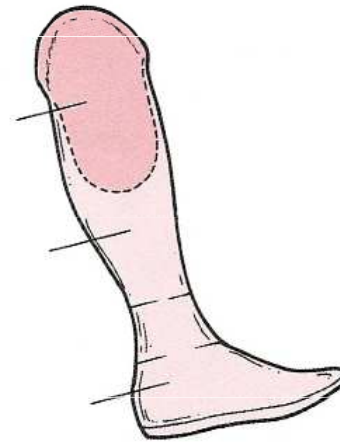
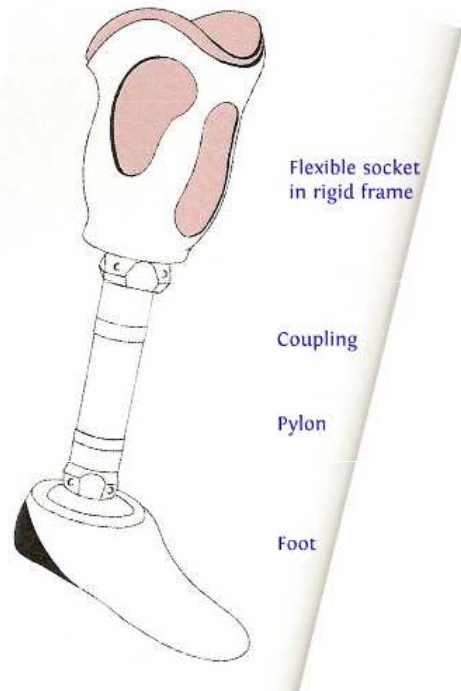
Prosthetics - Faculty of Medicine Masaryk University



Prosthetics

Construction Module

Endoskeleton



Exoskeleton



Prosthetics

Rehabilitation


- Training the seat
- Proprioception
- Work out
- Coordination of movement
- Walk
- Stay in the inpatient department
-



Prosthetics

Prosthesis of the upper limb

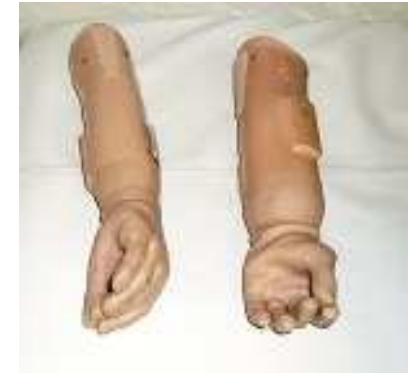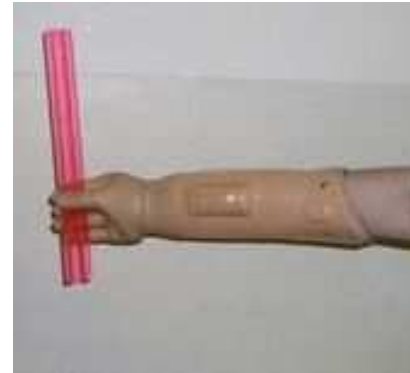
- Cosmetic
- Cosmetic with mechanical hand
- Bioelectric prosthesis



Prosthetics

Prostheses of the upper limb

- Cosmetic
- Cosmetic with mechanical hand
- Bioelectric prosthesis



Orthosis

doctrine on the replacement of lost body functions

Weakened or lost function

Brace:

serial or individual

torso or limbs



Orthosis

doctrine on the replacement of lost body functions

Static:

- Solid without movement, relieve pain, stabilize the limb

Dynamic:

- Controlled movement, replace lost or weakened functions of muscles and joints



Orthosis

And parts of them

- Splints
- Joints
- Calipers
- Strokes
- Pelotons
- Auxiliary parts (sleeves)
-



Orthosis

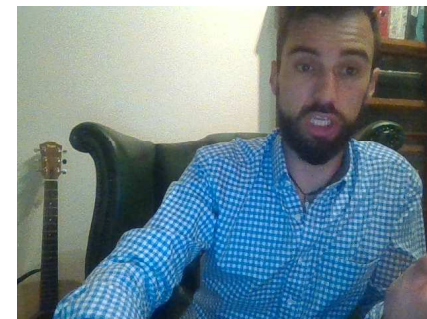
doctrine on replacing lost body functions

Brace:

- serial or individual
- torso or limb
- fixation (restrict movement)
- corrective (adjusting position)
- extension (straightening the limb)
- leveling (mechanical length)
- support (reliever from load)
- for work

Dynamic

Static



Orthosis

Upper limbs

Finger brace

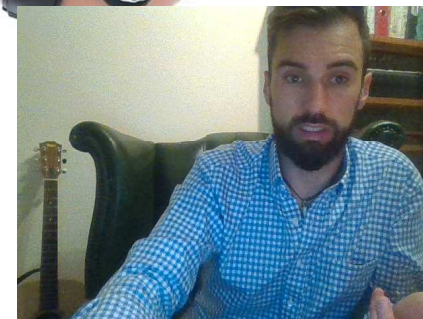
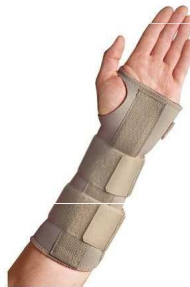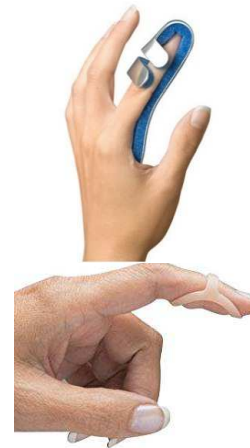- Dynamic: Flexible strokes
- Static

Wrist/forearm:

- Rigid
- Semirigid

Forearm:

- epicondylitis
- elbow



Orthosis

Upper limbs

Prosthetics - Faculty of Medicine Masaryk University



Orthosis

Pain shoulder syndrome

- Tendosynovitis capitis longi m. bicipitis brachii
- Rupture of the tendon long head of the biceps
- Bursitis subacromialis
- Tendinitis m. supraspinati
- Rupture of the rotator cuff
- Impingement shoulder syndrome
- Frozen shoulder syndrome
- Arthrosis art. glenohumeralis
- Affective acromioclavicular joint
- Inflammation
- Tumors
- Trauma
- Pain transferred from another place
- Postoperative treatment



Orthosis

Shoulder joint

□ Orthopedic surgery:

- Arthroscopy:
 - SLAP lesions
 - Rotator cuff repair
 - SA decompression
- Endoprosthesis:
 - hemiarthroplasty
 - Rev TSR
 - TSR
- Traumatology:
 - ORIF
 - IM nail

□ Brace:

- Arthroscopy
 - Desault 4 – 6 weeks
 - Abduction orthosis
 - Scarf hinge
- Endoprosthesis:
 - No fixation/DO
 - No fixation/DO
 - No fixation /DO
- Traumatology:
 - No fixation 90% ORIF performance
 - Conservative Therapy: DO/AD
 - Individual orthosis and splints
 - Scarf hinge



Orthosis

Shoulder joint

Desault Orthosis

- fixation for 4 – 6 weeks
- a) active exercises of fingers, wrists
- b) passive and later active elbow movement
- b1) (arm in internal rotation!)
- c) isometry of arm muscles in the orthosis
- d) adjustment of the posture

Abduction splint/orthosis

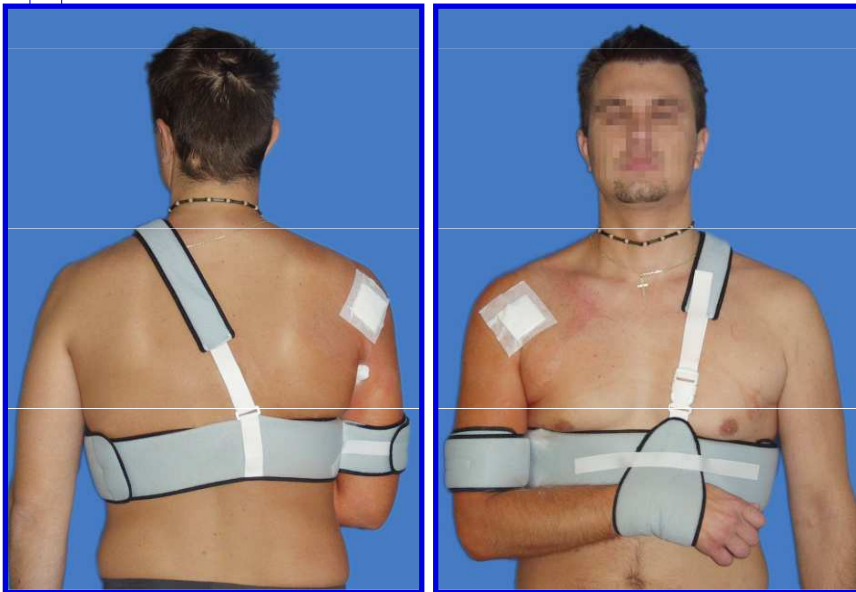- fixation 4 – 6 weeks
- a) active exercise of fingers, wrists
- b) passive and later active elbow movement
- c) modification of the posture



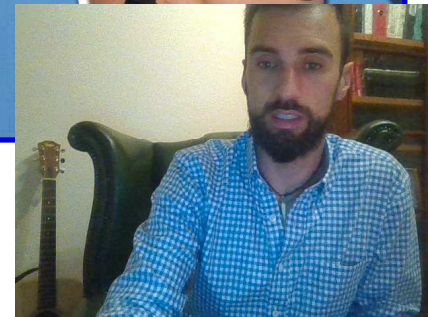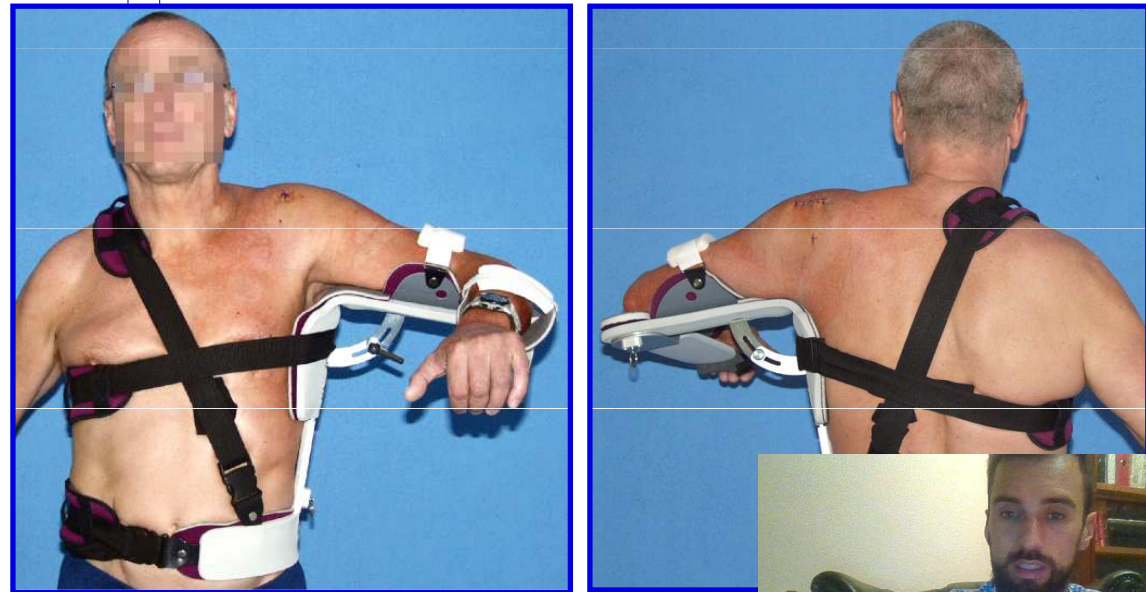
Orthosis

Shoulder joint

Desault Orthosis



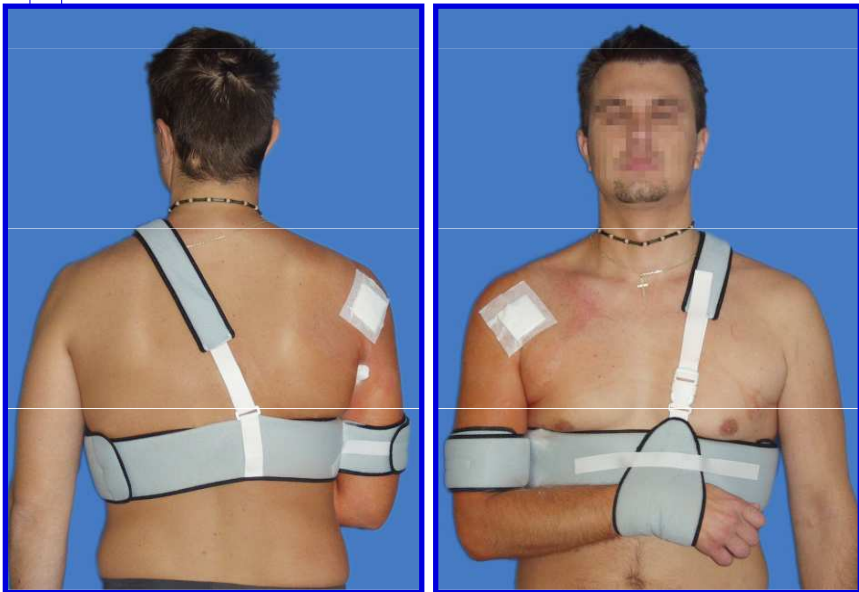Abduction splint/orthosis



Orthosis

Shoulder joint

Desault Orthosis



Abduction splint/orthosis



Orthosis

Pierre-Joseph Desault

□ Pierre-Joseph Desault

- 6 Feb 1738 – 1 June 1795
- France
- Anatomy/surgeon

Prosthetics - Faculty of Medicine Masaryk University

368

EMINENT PRE-LISTERIANS

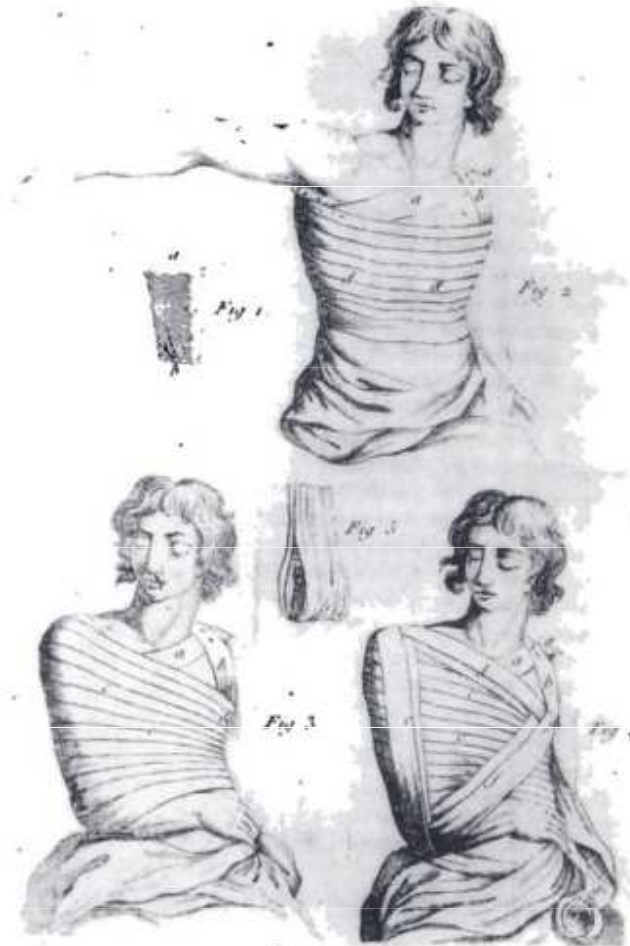

FIG. 81. Desault's bandage for fractured clavicle. From: *Oeuvres chirurgicales de P. J. Desault*

364

EMINENT PRE-LISTERIANS




FIG. 80



Orthotics

Lower limb




**MUNI
MED**

TLSO brace

Types and clinical use

Prosthetics - Faculty of Medicine Masaryk University



MUNI MED



Prosthetics - Faculty of Medicine Masaryk University



Prosthetics

- Prosthetics - doctrine on the replacement of lost parts of the body
- Orthotics - doctrine on the replacement of lost body functions
- Epithetics - doctrine on cosmetic cover of the body part
- Kalceotika - doctrine of orthopedic shoes
- Adjuvatics - doctrine of aids
-



Corsetotherapy

- Stop/mitigate the progression of spinal deformity
- Maintain steady position of the fuselage
- NMS sometimes questionable and problematic



Differential diagnosis of pathologies

etiology: physical, chemical, biological and in particular genetic and multifactorial

Trauma
Radiotherapy
Postural
Laminectomy

PHYSICAL INFLUENCES

Injuries
Iatrogenic causes
Faulty posture
Muscle dysbalance

Osteoporosis
Osteomalacia

CHEMICAL INFLUENCES

Hormone/Corticoid Therapy
Menopausa

Achondroplasia,
Mucopolysaccharides
Oncology
Infectious causes
M Bechterev
M Scheuermann

BIOLOGICAL INFLUENCES

Genetics
Combination of influences
Congenital kyphosis – disorders of
segmentation and fo
Neuromuscular kyph
Degenerative change







Conservative treatment of trauma

A) Rest

B) Collars:



- soft/molitan
- Philadelphia



Conservative treatment of trauma


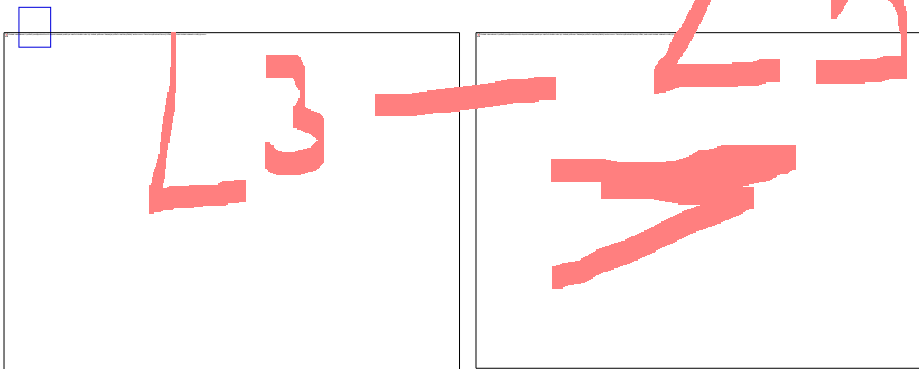

rest

C: Halo traction




Conservative treatment of trauma

- Rest
- Th fracture: Jewet's brace/TLSO
- Th-L fracture: Jewet's brace, lumbar belt




Conservative treatment of trauma

Plaster TLSO: not adequate in traumatology these days



Conservative treatment of trauma



Corsetotherapy

Indications:

- Scoliosis: Congenital, Idiopathic, Neuromuscular, Degenerative
- Traumas: primarily, event. postoperative treatment
- Oncology: primarily, event. postoperative treatment

Degeneration: ~~postoperative treatment~~

Objective: ~~stabilization~~ correction



Principle of three-point fixation

Pelvic belt – neck circle – side pressure pellets


- Primary forces:
 - acts indirectly on the spine through surrounding structures
 - axis: tensile – for deformity in the sense of stretching: pelvis – cervical pelotes
 - sides: pressure – through the rib cage by pressure on the vertebra

- Milwaukee Brace
- Thorakolumbosacral orthosis (TL~~SO~~)
- Two-part cervikothoracolumbusal orthosis (CTLSO).
- Carlson and Payette (2017) braces supporting sed
-




Principle of three-point fixation

Milwaukee Brace (May & Lockard, 2011)





Principle of three-point fixation

Thorakolumbossacral orthosis (author unknown, 2018)




Principle of three-point fixation

Thoracosocal corset of synthetic material



Principle of three-point fixation

Sample sit-supporting orthosis supplemented with additional compensatory aids (Carlson & Payette)



Morbus Scheuermann

Holger Werfel Scheuermann (1877-1960) - Dánsko - 1920 osteochondritis deformans juvenilis dorsi

- Abnormal increase in lower thoracic kyphosis in puberty with rigidity and typical X-ray changes (ASCANI and co. 1985)
- Disparity between growth hormone production and sex hormones with vertebral fragility (Bradford 1985)
- The cause is not yet fully known
- Genetics/Multifactorial




Epidemiology and Etiology

Morbus Scheuermann


- Aseptic necrosis of the vertebrae (Scheuermann 1920)
- Herniation of discs into vertebrae (C.G. Schmorl 2 May 1861 – 14 August 1932)
- Mechanical overload ("apprentice's back," Mau 1927, Keim 1975)
- Hereditary talents (Sörensen 1964, prof. Vlach a spol. 1990 – 36%)
- Hormonal influences (Ipolito 1981)
- 0.5 - 8 % of the population
- More often boys (but 612, Ž:M 1,2:1; ORTK FN, odb.as.Filipovič 2001)
- Age 12-18 years
- Enchondral ossification disorder
- More often lower thoracic spine
-

Prosthetics - Faculty of Medicine Masaryk University



Epidemiologie a etiologie

Morbus Scheuermann youtube

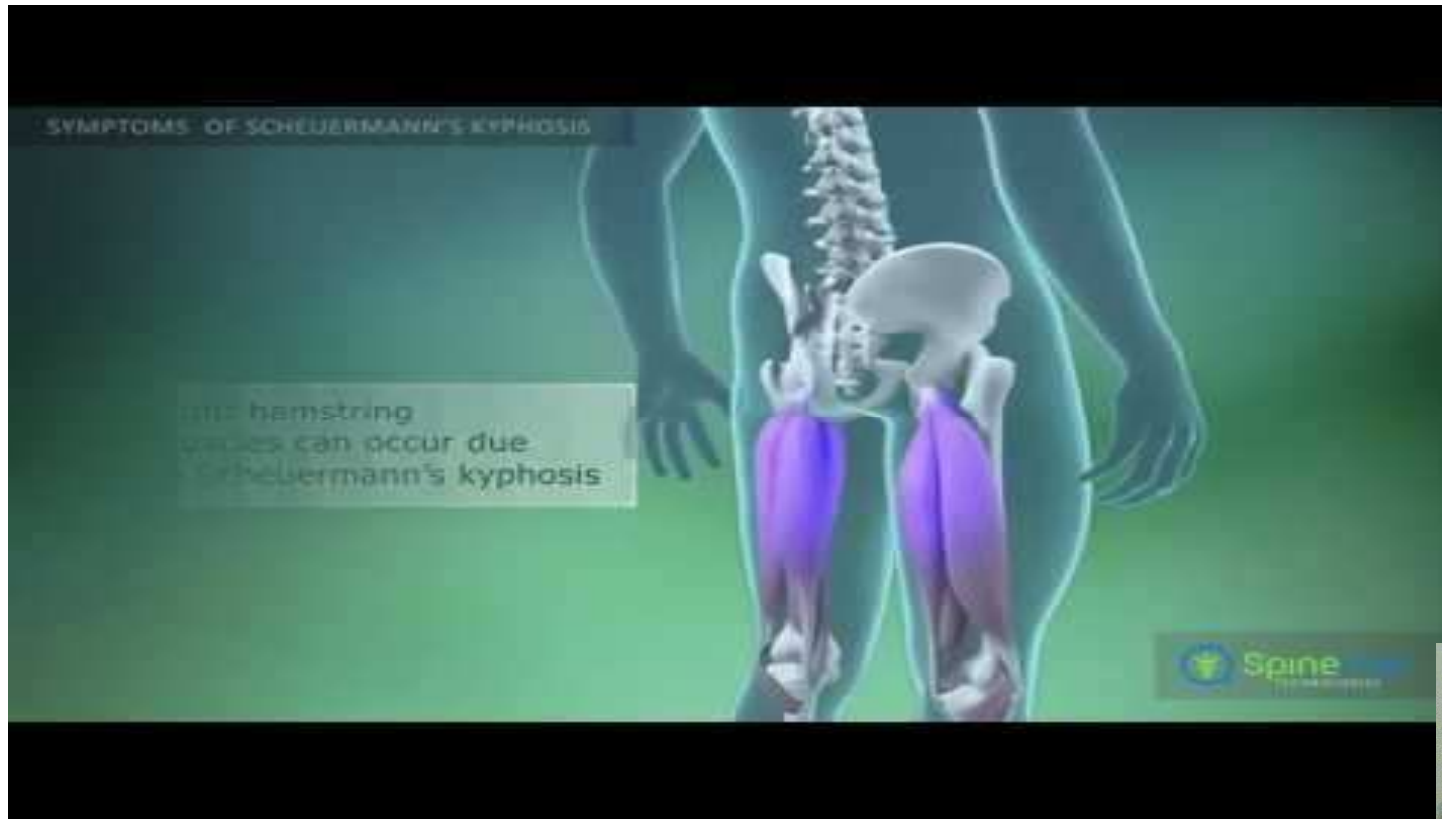

Prosthetics - Faculty of Medicine Masaryk University



Epidemiologie a etiologie

Morbus Scheuermann youtube



Prosthetics - Faculty of Medicine Masaryk University



Epidemiology and Etiology

Morbus Scheuermann in literature

„...autosomal genetic component of high penetrance and variable expressivity, with 74% heredity...“

Damborg F, Engell V, Andersen M, Kyvik KO, Thomsen K. Prevalence, concordance, and heritability of Scheuermann kyphosis based on a study of twins. J Bone Joint Surg Am. 2006;88(10):2133–2136

„...Its origin has been associated with avascular necrosis of the epiphyseal rings....“

Scheuermann HW. Kyphosis dorsalis juvenilis. Orthop Chir. 1921;41:305–317

„...juvenile osteoporosis...“

Gilsanz V, Gibbens DT, Carlson M, King J. Vertebral bone density in Scheuermann disease. J Bone Joint Surg Am. 1989;71(6):894–897

Lopez RA, Burke SW, Levine DB, Schneider R. Osteoporosis in Scheuermann's disease. Spine. 1988;13(10):1099–1103


„...shortening of the ischiotibial musculature...“

Lopez RA, Burke SW, Levine DB, Schneider R. Osteoporosis in Scheuermann's disease. Spine. 1988;13(10):1099–1103

„...mechanical factors that would trigger secondary remodelling responses, such as reduction of sternal size...“

Sorensen KH. Scheuermann's Juvenile Kyphosis: clinical appearances, radiography, aetiology and prognosis. Munksgaard. 1977;1:1–10

Ferguson AB., Jr The etiology of preadolescent kyphosis. J Bone Joint Surg Am. 1956;38(1):149–157

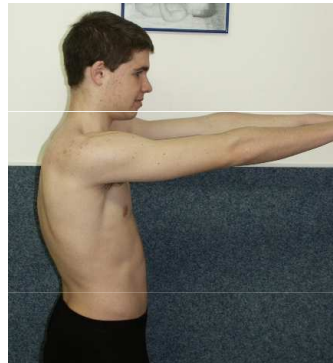


Clinical examination

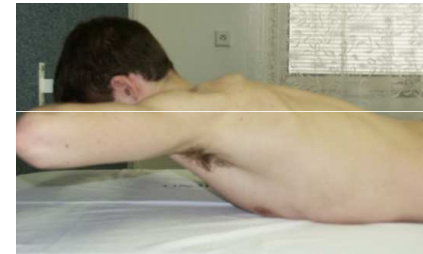- Round back at the bottom t8-9 (48%)
- Thoracic or lumbar spine pain (28%)
- Rigidity of deformity
- Scoliosis in 49%
- Muscle dysbalance "texas attitude"
- Reflective changes in soft tissues
- Positive tests (Matthias, Frank, hyperextion)



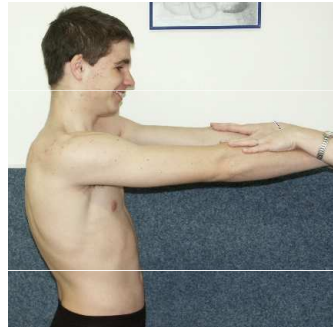Clinical examination



Matthias




hyperextension



Franke




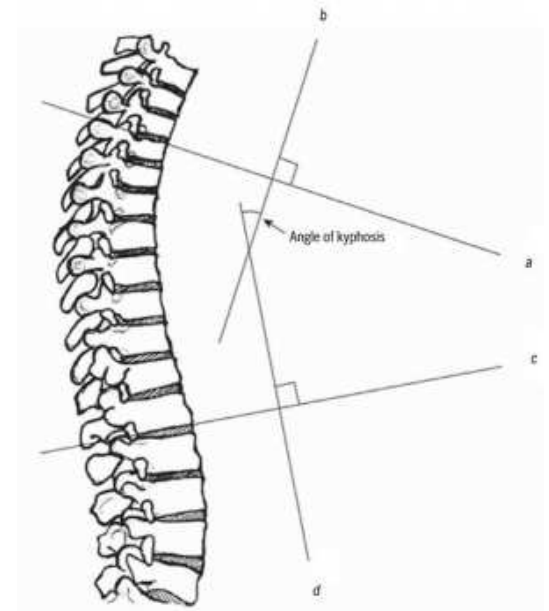
Clinical examination



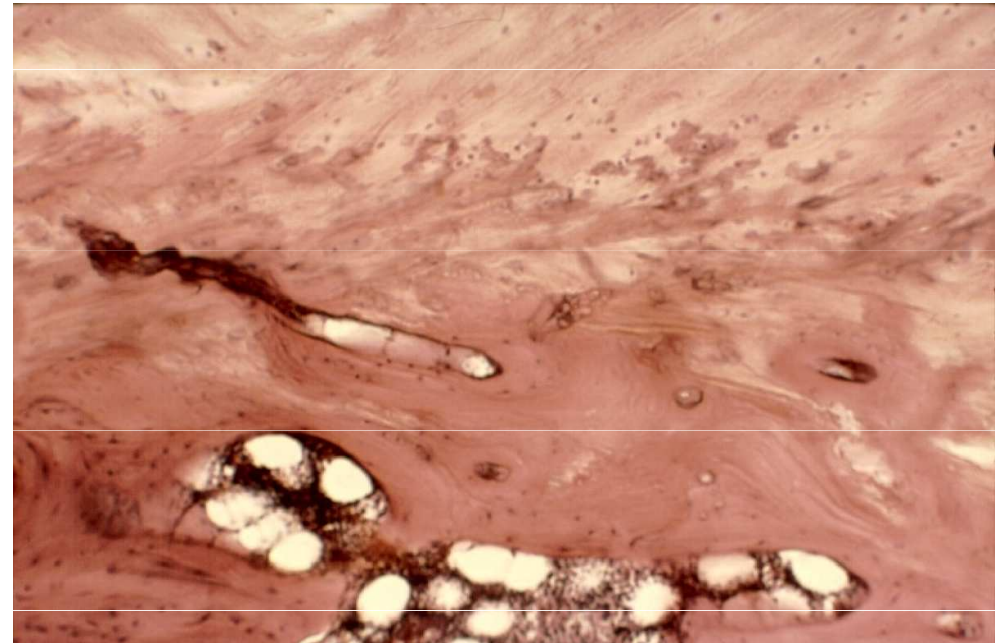

Morphology

- Histology, X-ray, CT, MRI
- C lordosis, Th kyphosis, L lordosis
- Th kyphosis: $20^{\circ} - 40^{\circ}$ ($< 20^{\circ}$ hypo; $> 45^{\circ}$ hyper)
- Radiological criteria according to Bradford 1985:
- Chest kyphosis above 40° according to Cobb
- Vertebral wedges above 5° (43% in 3 vertebrae)
- Unevenness of covering surfaces and disc narrowing
- Stretching of vertebral bodies
- Schmorl nodes (up to 42%)
-

Prosthetics - Faculty of Medicine Masaryk University



Histology



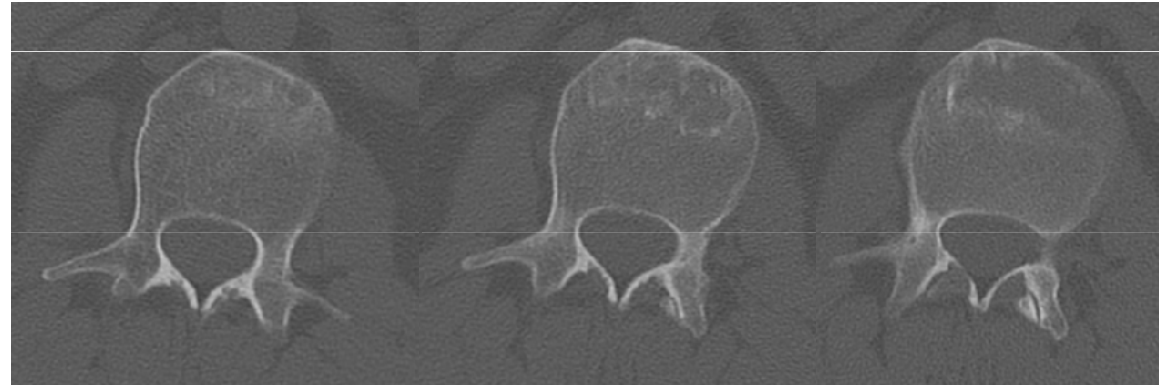Xrays

- AP + side long formats
- re-evaluation
- We measure:
 - Cobb angle T3/4 – T12
 - reclinacion
 - SVA
 - PT, PI, SS



CT

- CT - bone window
- fresh Schmorl knot:
 - character of osteolysis
 - around the edge break
 - In addition, STIR MRI
- Differential diagnosis!



MRI

old Schmorl's knot:

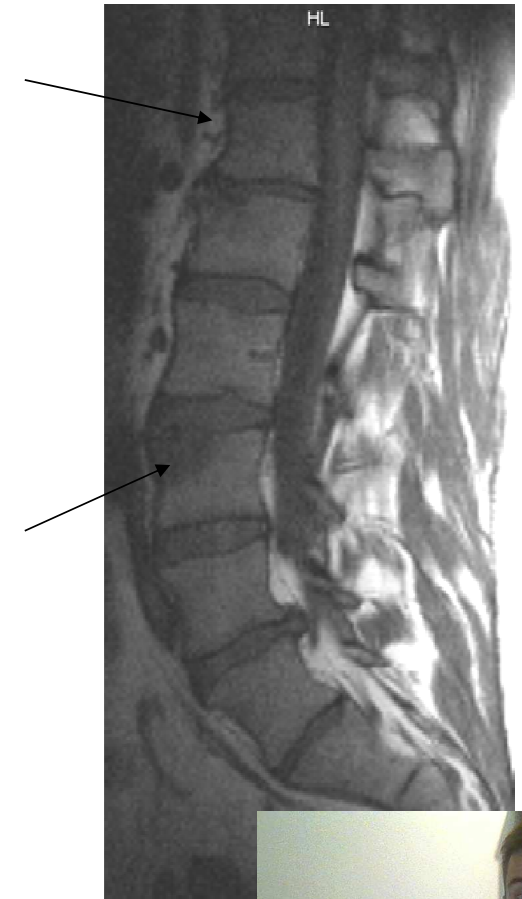
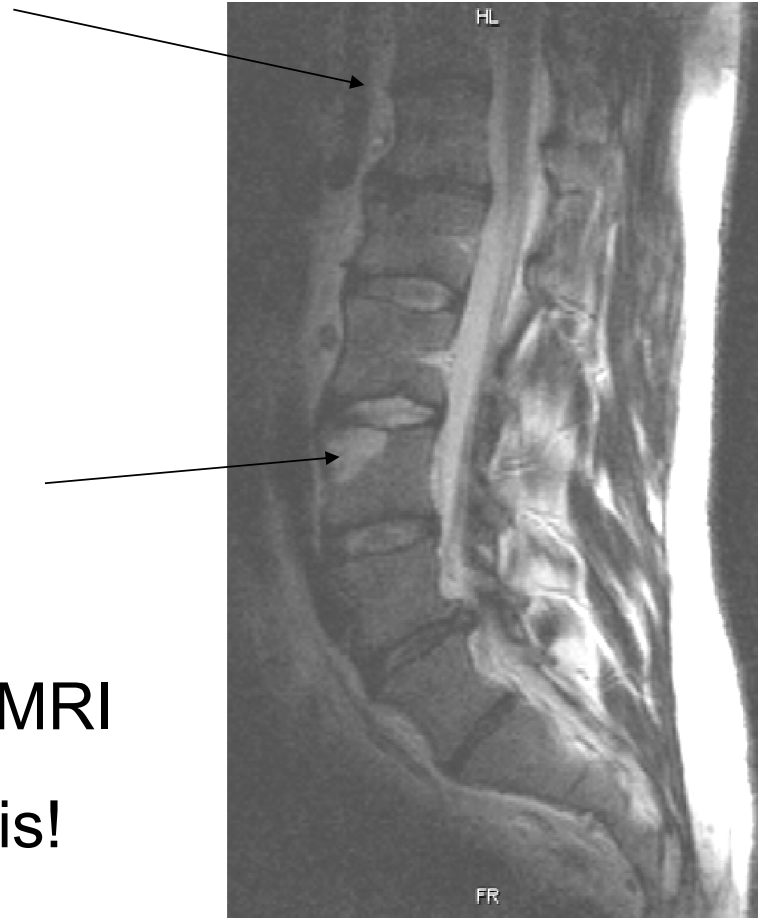- Consolidated
- Inactive

fresh Schmorl knot:

- Character of osteolysis
- around the edge break

on T2, better STIR MRI

Differential diagnosis!



T2



Forms Morbus Scheuermann

Typical and atypical

Typical:

- Type I: Th spine only: upper type
- Type II: Th – L Gradient: Lower Type
- Affects the transition of Th and L of the spine
- "Lumbar type" Morbus Scheuermann
- fresh Schmorl's knot

Atypical:

- I. form (vertebrae changes without hyperkyphosis)
- II. form (typical clinic, no significant serious X-ray changes)
- III. form (lumbar localization)



Stages Morbus Scheuermann

early – deformities - consequences

Stage I early on set

9-12 years, round loose back with pain, muscle changes

Stage II deformities

13-16 years, stiffness, x-ray changes

Stage III of the consequences

chronic back pain



Degrees Morbus Scheuermann

Montgomery 1981

- Grade I – up to 45° kyphosis
- Grade II - up to 55° kyphosis
- Grade III - up to 65° kyphosis
- Grade IV - 75° and up
-



Therapy

Conservative

- Exercising
- orthosis and exercises
- antigravity plaster corset
followed by orthosis and LTV
- "Lyon method" De Mauroy and Stagnar's 1978

Surgical

- Indications:
 - Absolute:
neurological deficiency (extremely rare)
 - Relative:
Rigid deformity above 70°
Pain
Cosmetics
Posterior spondylodesis
SPO/PSO



Conservative practices



Prosthetics - Faculty of Medicine Masaryk University



Conservative practices

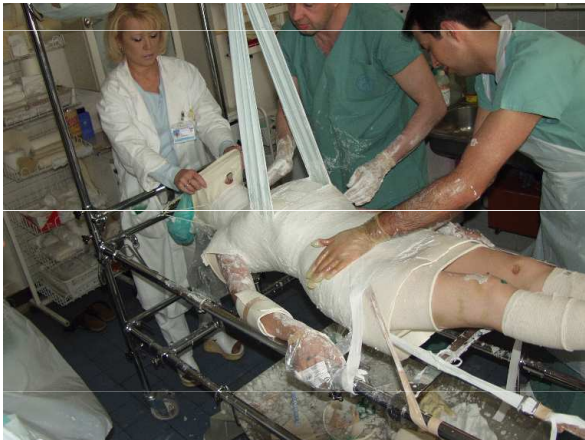
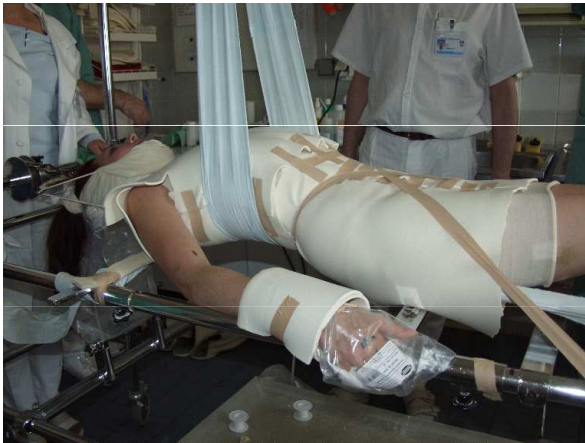- Exercise + corztotherapy
- Physical treatment
- Stop: competitive sport
- Stop: heavy loads
- NSAIDs, analgesics?
- Myorelaxantia?
-



Modified Milwaukee Orthosis (Hudeček- Wernio – Nobility 2004)



Antigravity – plaster - corset



Prosthetics - Faculty of Medicine Masaryk University



Rehabilitation and prosthetics

23h/16h night mode, „NO“ night mode, intense, daily exercise

- Exercising
- Physical treatment
- Prohibition of competitive sport
- Prohibition of heavy loads
- NSAIDs, analgesics
- Muscle relaxants
- Anti-gravity brace
-



Rehabilitation and prosthetics

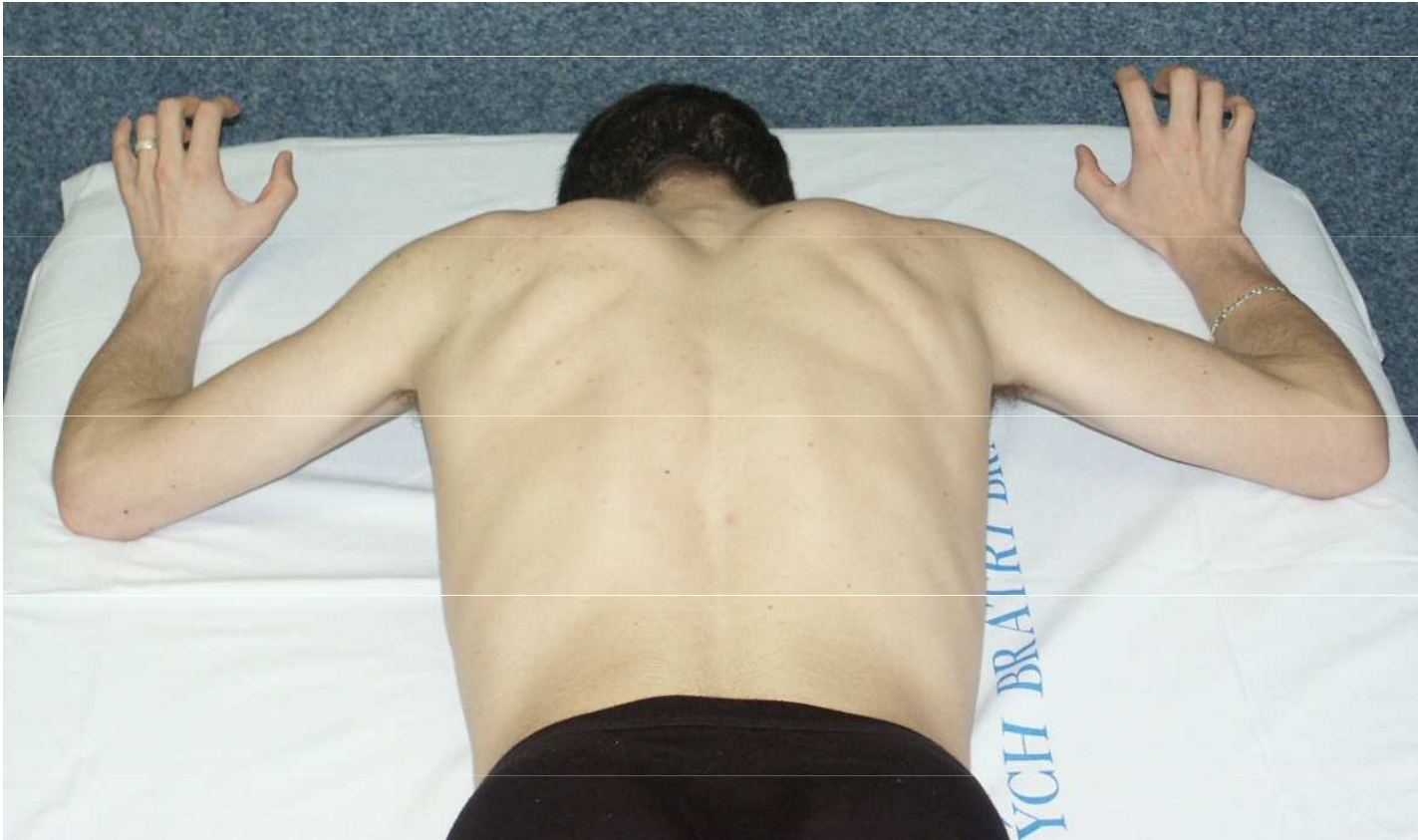23h/16h night mode, „NO“ night mode, intense, daily exercise

- Individual LTV + instruction
- Individual + special techniques (Brunkow, Brügger, Klapp and others)
- Group and Motivational (swimming, hippotherapy, dancing)
-



Rehabilitation and prosthetics

Brunkow





Prosthetics - Faculty of Medicine Masaryk University



Rehabilitation and prosthetics

Brügger





Prosthetics - Faculty of Medicine Masaryk University



Rehabilitation and prosthetics

Brügger

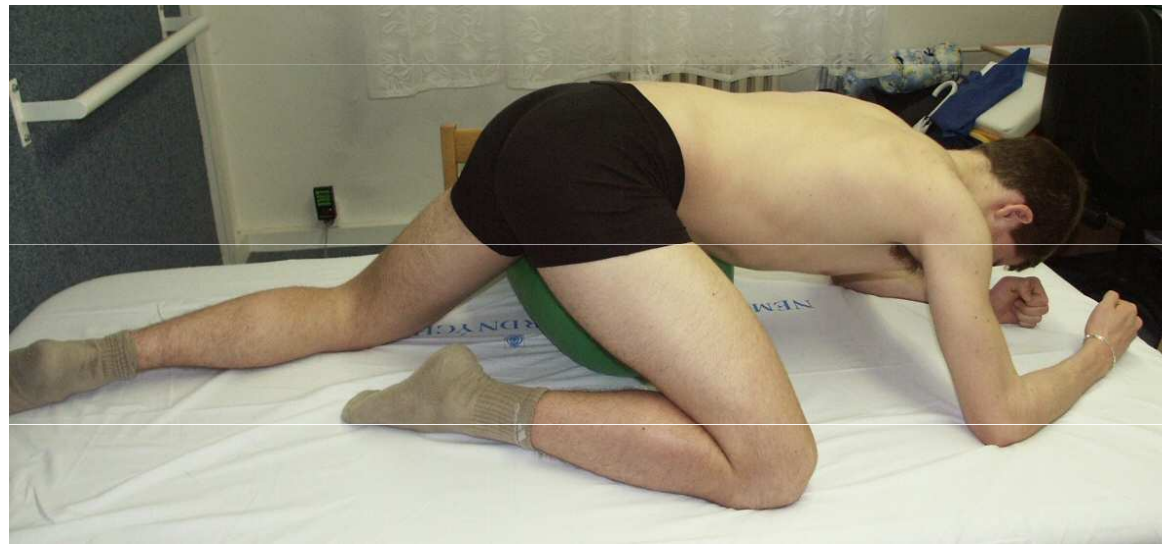

Prosthetics - Faculty of Medicine Masaryk University



Rehabilitation and prosthetics

Klapp



Complications of conservative therapy

Patient and parents

- CAST SYNDROME!!!**
- Care for antigravity corset (exanthema, decubitus)
- Long-term treatment
- Small cooperation in puberty
- Little motivation
- Lifestyle
- Assessment problems:
 - improved with the abolition of compulsory military service
 - the most common cause of the "blue book"

Prosthetics - Faculty of Medicine Masaryk University



Complications

CAST SYNDROME = ACUTE CONDITION = THERAPY IMMEDIATELY

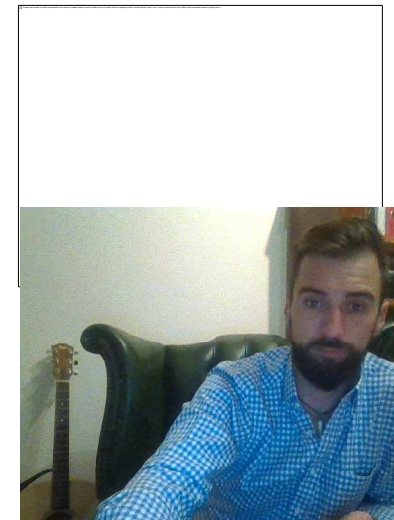






- SMAS= superior mesenteric artery syndrome (mesenteric artery syndrome)
- dilation of the stomach with partial or complete obstruction of the duodenum
- Conservative therapy: castings, plaster corsets, corsets:
- in all patients with mesenteric artery syndrome
- NSG (nasogastric decompression), pharmacological treatment: Metoclopramid i.v.
- Positioning: left, knee-to-chest position or Goldthwaite maneuver
- Enteral nutrition using a double lumen tube, soyurally guided distal to obstruction under fluororoscopic assistance
- Surgical therapy:
- Failure of conservative treatment = surgical intervention:
- duodenojejunostomy or gastrojejunostomy to bypass obstruction or duodenal derotation altimeter
- mobilization of duodenum by laparotomy or laparoscopy
- duodenojejunostomiestomy rarely
- Pathophysiology:
- compression of the duodenum between the upper mesenteric artery forward and the aortic and spine at the back.
- obstruction may occur within a few hours to days after surgery or casting or plaster corset or may not develop for s



Surgical treatment

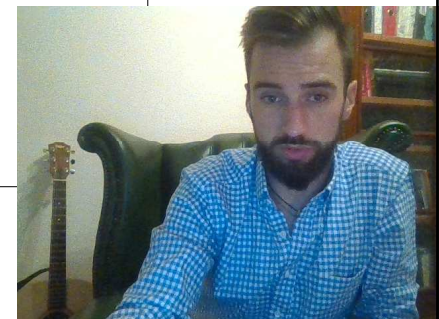



Late, severe diagnosis

- Posterior spondylodesis
- Osteotomy: SPO/PSO
- + treatment in TLSO
-






Surgical therapy

Smith-Petersen osteotomies



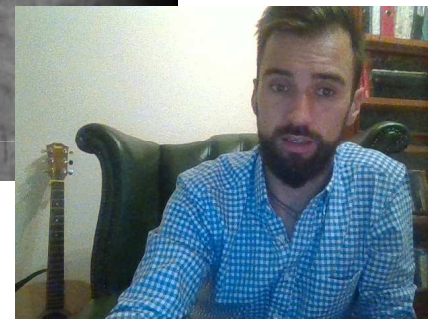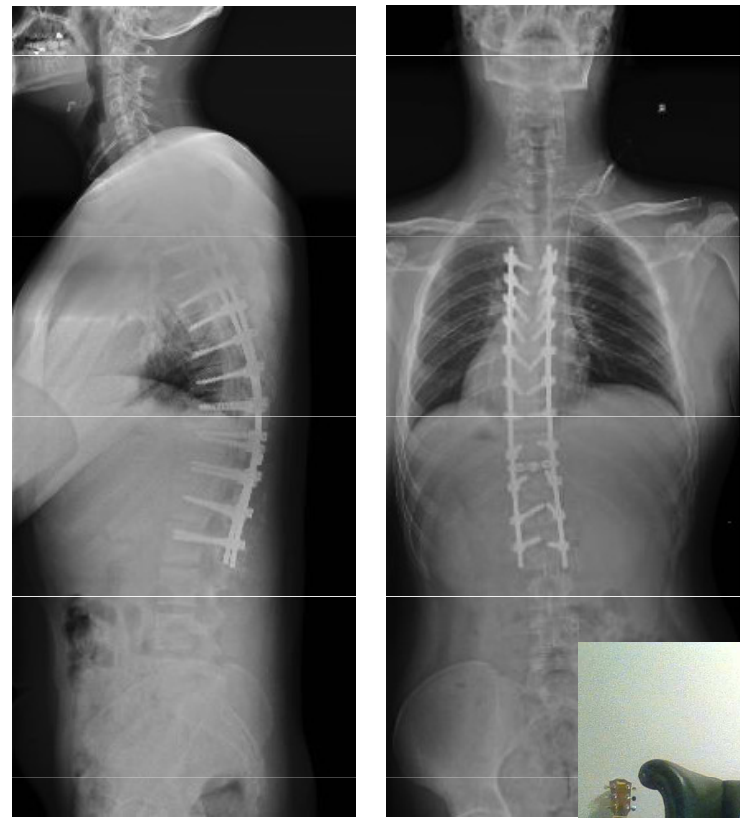
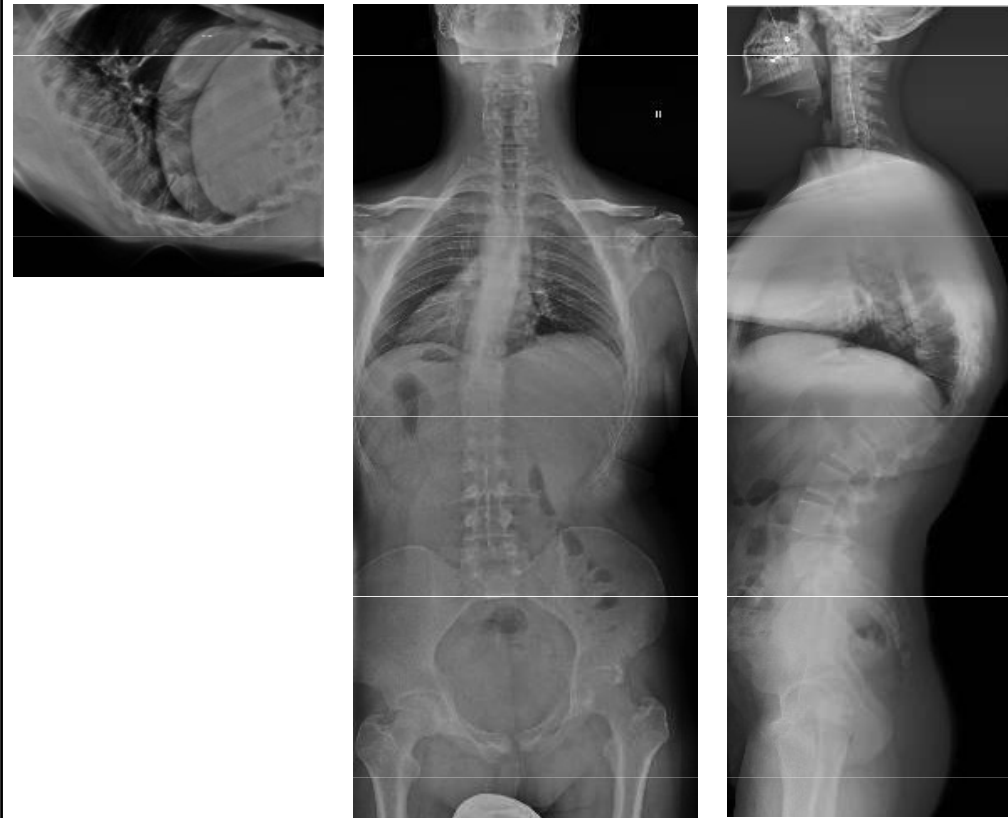
Surgical therapy

Cantilever maneuver



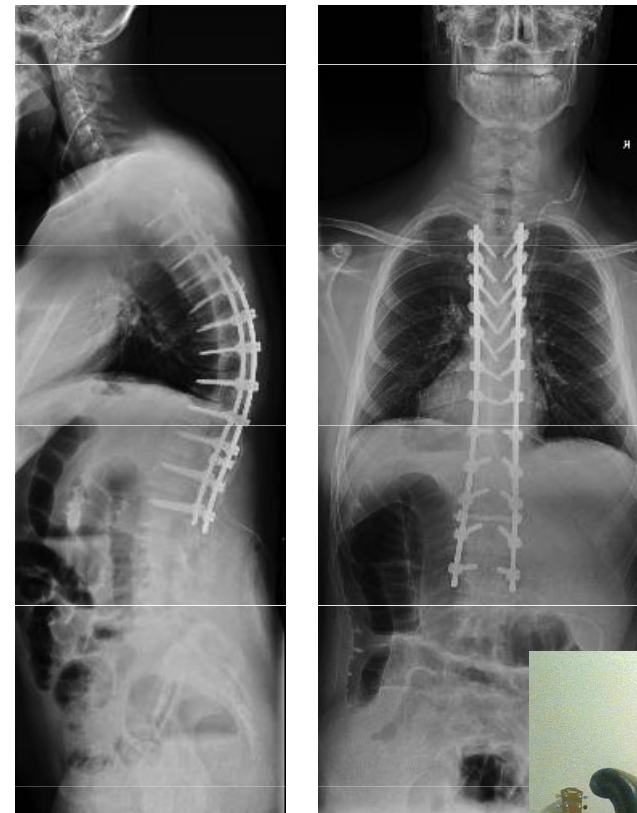
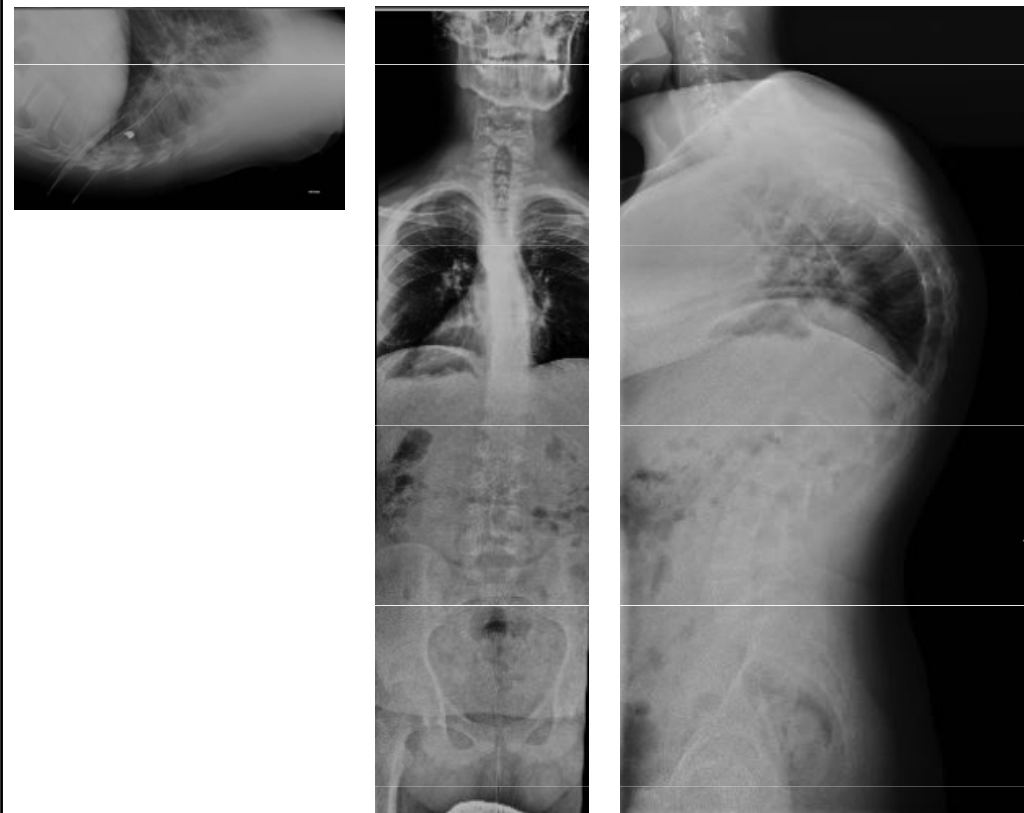
Surgical therapy

Xrays Follow ups (16y + 2m)



Surgical therapy

XR FU (17y + 3m)



Faulty posture

Most common

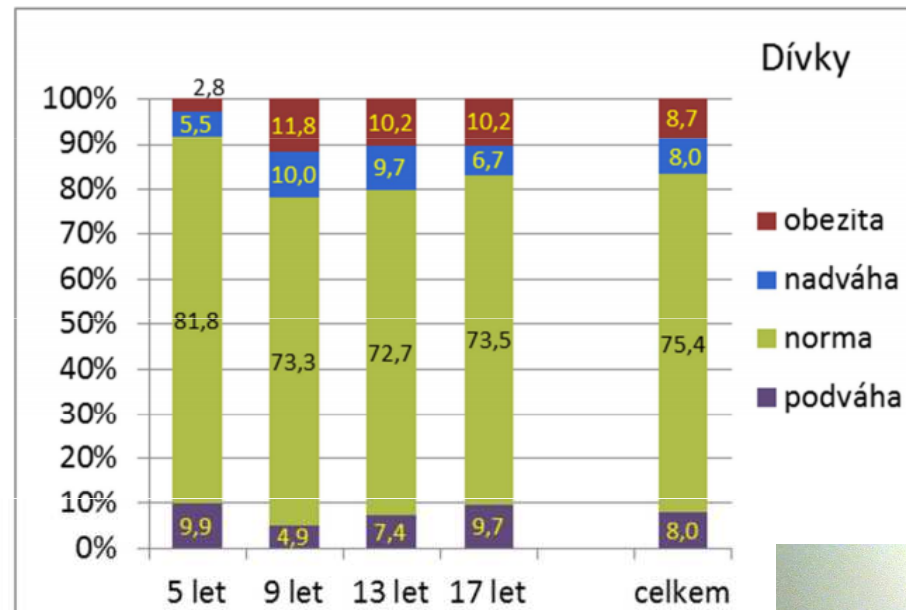
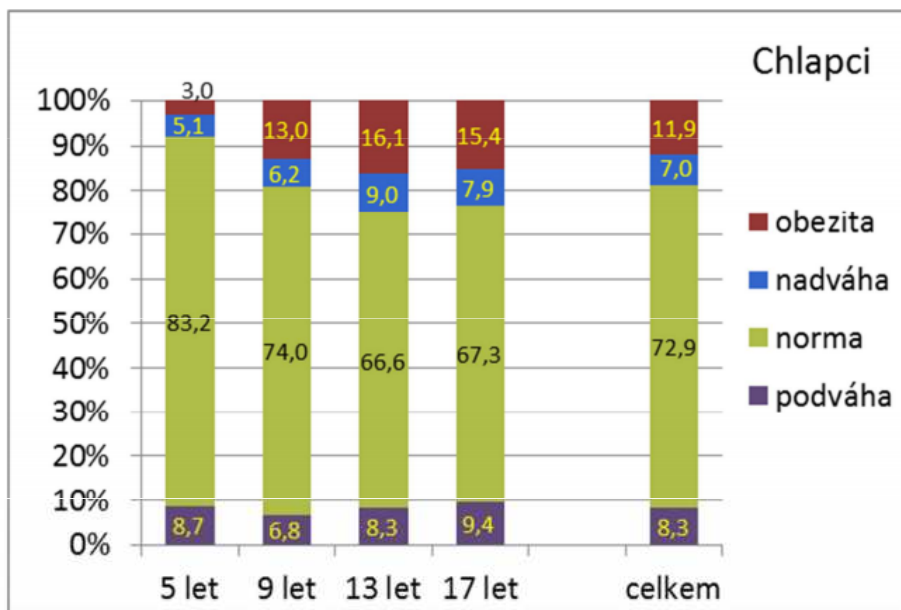
- It arises with muscle imbalance, lack of exercise and „sitting“ lifestyle.
- Poor musculature of the back and abdominal.
- Increased lumbar lordosis and thoracic kyphosis
- Treatment:
 - "Good lifestyle"
 - Regular exercises of back and abdominal muscles
 - Endurance
 - Physiotherapist



Faulty posture

BMI a „bad posture“?

Graf č. 14 a 15. Hodnoty BMI u chlapců a dívek podle věku



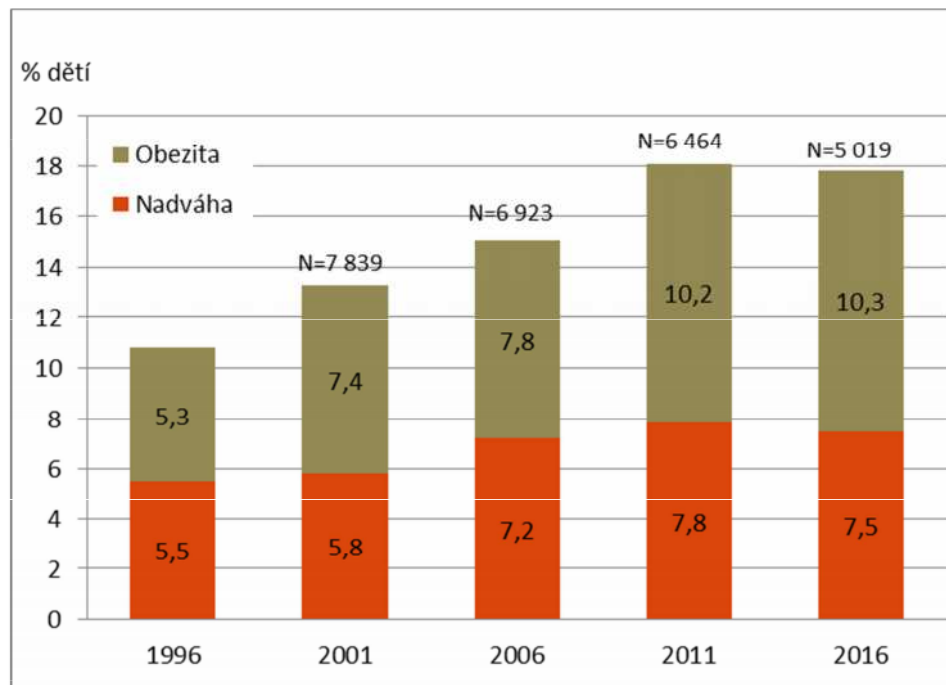
Prosthetics - Faculty of Medicine Masaryk University

Zdroj: http://www.szu.cz/uploads/documents/chzp/odborne_zpravy/OZ_16/OZ_BMI_VDT.pdf
Výsledky studie „Zdraví dětí 2016“ Tělesná hmotnost a vadné držení těla



Faulty posture

Graf č. 16. Vývoj prevalence nadváhy a obezity u dětí (věkové skupiny 5, 9, 13 a 17 let) mezi lety 1996 až 2016



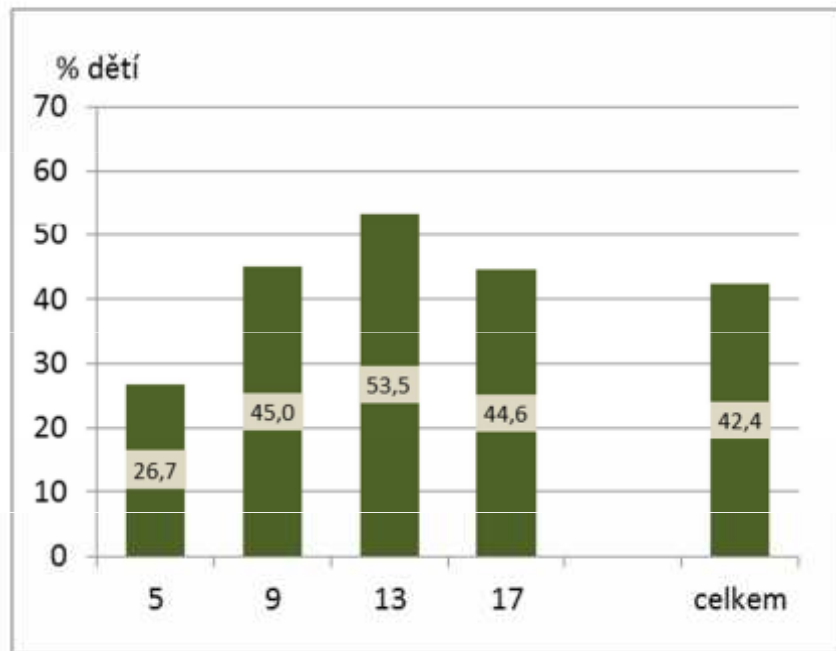
Prosthetics - Faculty of Medicine Masaryk University

Zdroj: http://www.szu.cz/uploads/documents/chzp/odborne_zpravy/OZ_16/OZ_BMI_VDT.pdf
Výsledky studie „Zdraví dětí 2016“ Tělesná hmotnost a vadné držení těla

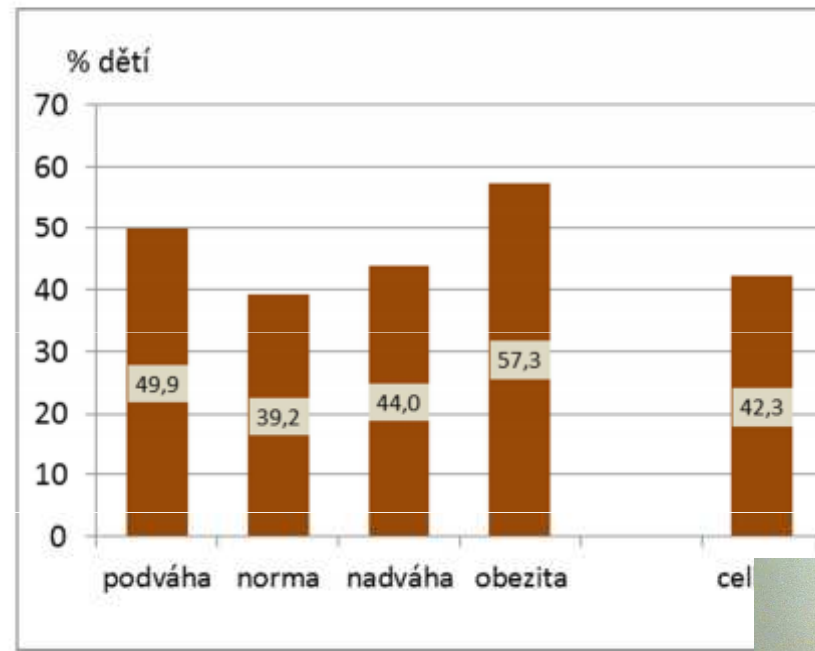


Faulty posture

Graf č 17. Prevalence VDT dle věku



Graf č. 18. Prevalence VDT dle BMI



Nejčastější zjištěnou vadou v držení těla byl předsun hlavy (25,5% dětí), kulatá záda / zvýšená hrudní kýfóza (14 %) a skoliotické držení (13 %). Předsun hlavy a kulatá záda byly častější u chlapců, ve výskytu skoliotického držení se chlapci a dívky nelišili. Všechny tyto tři vady byly nejčastější u třináctiletých dětí.

Nejzávažnější z posuzovaných vad je skolióza. Jedná se o již fixovanou poruchu zakřivení páteře, kterou není možné zvýšeným svalovým napětím vyrovnat a která ovlivňuje celou funkci páteře a ve svých důsledcích může vést k snížení funkce plic. Skoliózu mělo celkem 79 dětí (1,5 % souboru), nejčastěji byla diagnostikována u 17letých (45 dětí, 4 % všech 17letých).

Součástí rodičovského dotazníku byly otázky zjišťující, jestli děti trpí bolestmi hlavy a páteře.

Bolestmi hlavy trpělo 21,2 % dětí, významně častěji dívky (23,1 % dívek, 19,4 % chlapců; $p=0,001$). Podíl dětí s bolestí hlavy narůstal s věkem (graf č. 19), nejčastěji ji trpěli sedmnáctiletí (34,8 %; více jak pětina z nich pociťovala bolest hlavy nejméně jedenkrát za týden). Častěji bolestmi hlavy trpěli děti s vadným držením těla (24,7 %) v porovnání s držením fyziologickým (18,0 %). Bolesti krční i bederní páteře uváděli rodiče shodně u 7 %



Evaluation morbus scheuermann

- adolescent damage to the spine with lifelong consequences
- requires 100% cooperation between patients and families
- Conservative therapy: in combination treatment with orthosis and rehabilitation
- Surgical therapy: Dpt of Orthopaedic Surgery UniHospital Brno



Evaluation morbus scheuermann

- Exercise: affecting up to 5%
- TLSO braces: up to 30% influence
- Operation: today over 70%
-



Case report – JH 1997



Case report – JH 1997

06/2011

06/2011

04/2012

10/2012

03/2013


Prosthetics - Faculty of Medicine Masaryk University





Case report – JH 1997

05/2013

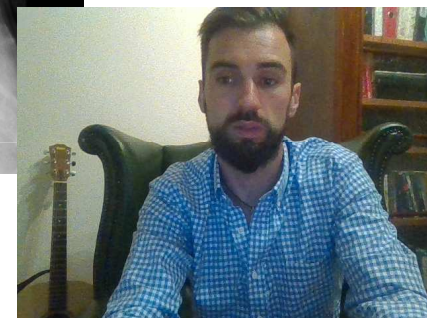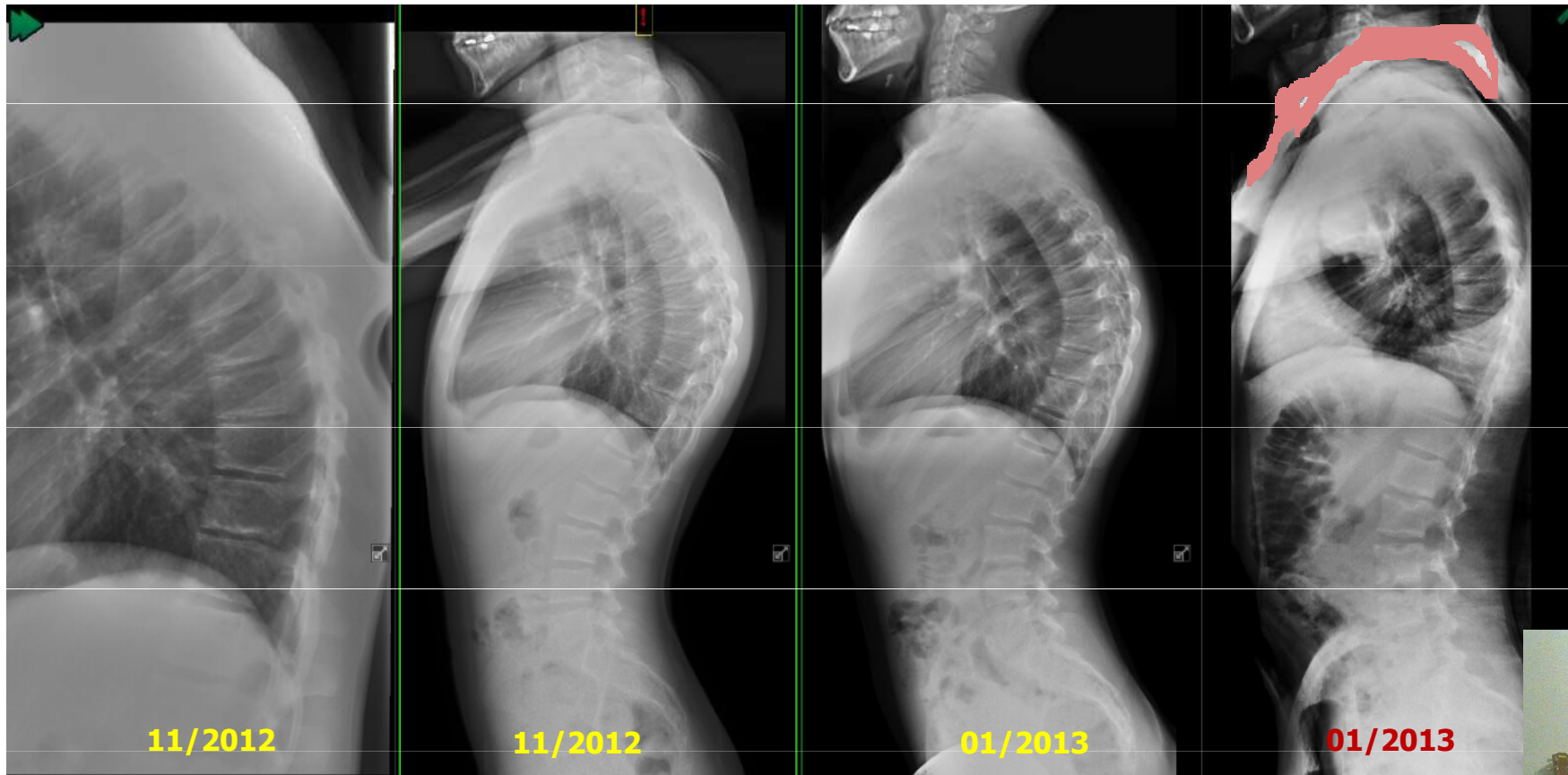10/2013



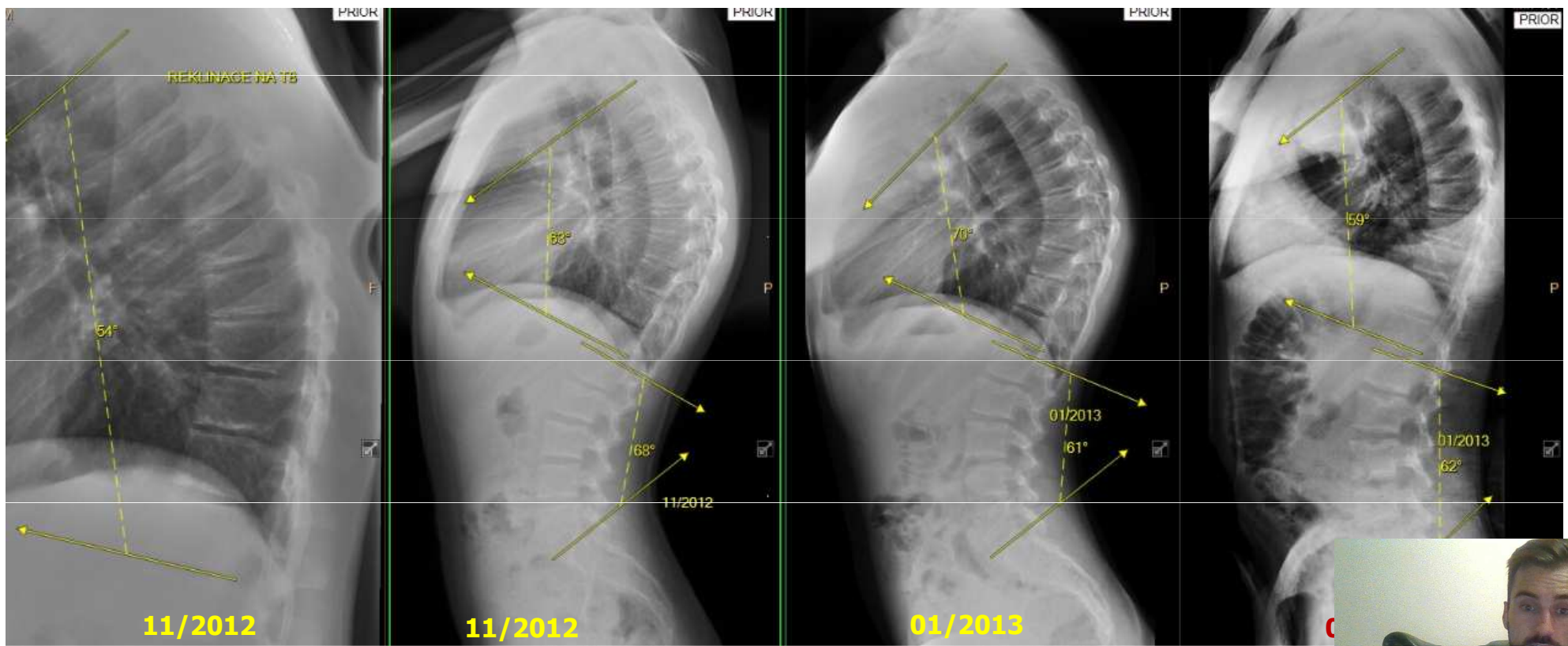Case report – AF 1999



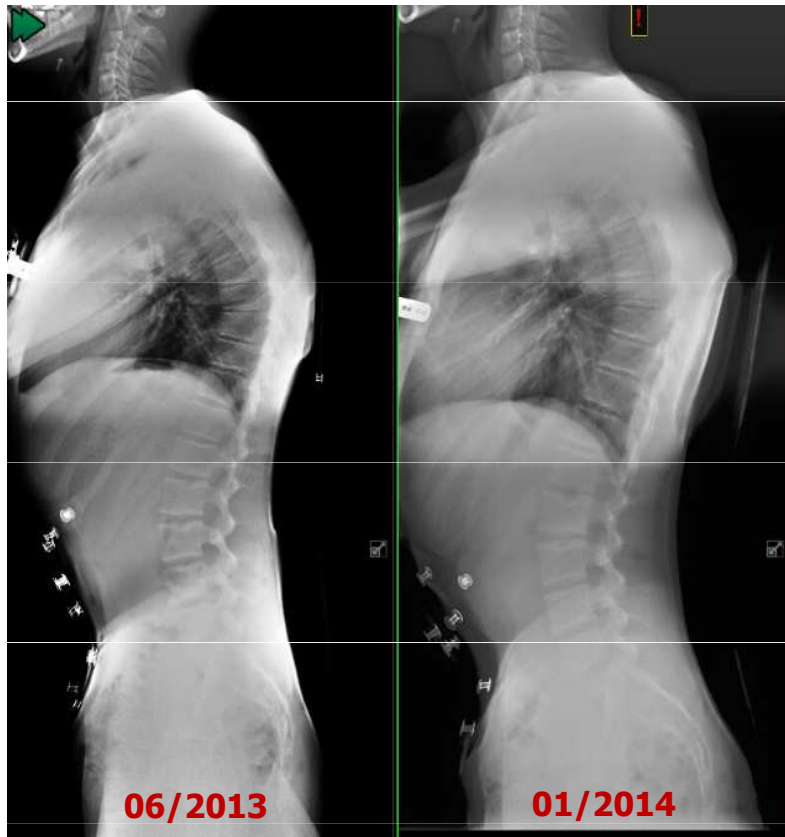Case report– AF 1999



Case report – AF 1999



CR – AF 1999





Prosthetics - Faculty of Medicine Masaryk University



CR – RS 1999



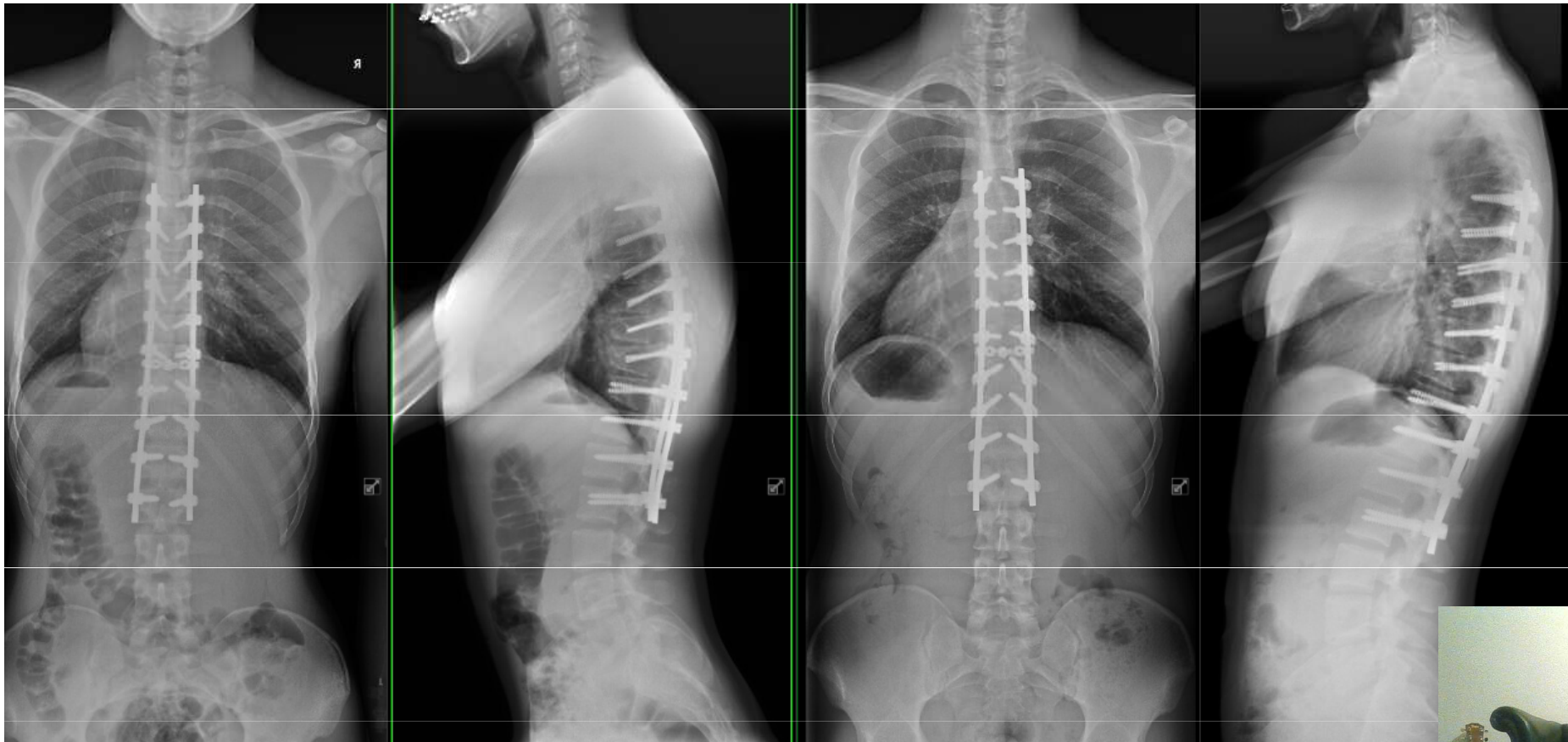CR – RS 1999



CR – RS 1999



CR – RS 1999





Prosthetics - Faculty of Medicine Masaryk University



Epithetics

doctrine on cosmetic cover of the body part



Replacement of lost, undeveloped or atrophied body parts



Epithetics

3D



- In the abode of paired organs, parts (ears, fingers, amputation of the foot)
- Skenner: sensing – CAD - positives
- Maxillacafacial epithesis (Bibb et al.)
- Design Covers - SLS (Selective Laser Sintering)
-



Calceotics

orthopedic shoe doctrine

- Specially adapted shoes



Calceotics

orthopedic shoe doctrine


- Features of orthopedic shoes:
- 1. Relief
- 2. Correction of defective position
- 3. Immobilization
-



Calceotics

orthopedic shoe doctrine

- Types of orthopedic footwear:
- Medical shoes
- Customized ready-made shoes
- Orthopedic shoes
- Diabetic shoes
-



Calceotics

orthopedic shoe doctrine

Part:



Calceotics

doctrine on orthopedic shoes

- To make a copy:
 - 1. Sew the upper according to the hoof
 - 2. Drawing of the tensioning insole
 - 3. Tensioning the upper through the insole
 - 4. Sticking the upper to the insole
 - 5. Making a frame circling the entire insole
 - 6. Knob workmanship – reinforcement
 - 7. Soiling
 - 8. Sticking soles and heel: A-measures, B-sides, C-tuna, K-hoof



Prosthetics - Faculty of Medicine Masaryk University



Calceotics

Shoe shapes


- A- high boots
- B-shoe
- C- ankle shoe
- D-half-shoe
- E- „perka“
- F- boots
-



Calceotics

Principles of children's shoes

- 1. The correct size. Front of the tip of at least 1 cm of free space
- 2. Shoes with wider forefoot
- 3. Flexible in the centre of the foot
- 4. A solid abbot that holds the heel well
- 5, Barefoot....
-



Calceotics

vložky

- 1. Insoles
- 2. Three-quarter
- 3. Heel heels
- 4. Hearts

- 1. Stiff
- 2. Soft

- 1. Active
- 2. Passive


Prosthetics - Faculty of Medicine Masaryk University



Calceotics

Inserts

- Shell inserts
- Helfet heel insert
-



Calceotics

3D





Prosthetics - Faculty of Medicine Masaryk University



Calceotics

Concealers, heel-heels

- heels
- concealers
-



Adjuvatics - aids

teaching on operator aids

- Disabled persons and daily tasks
- locomotive, hygiene and self-sufficiency, safety
- practical and graphomotor activities
- Sports
-



Adjuvatics

teaching of operator aids

- Immobile patients, wheelchair users, seniors
- Long-term bed treatment
- After demanding orthopedic – surgical procedures
-



Adjuvatics

teaching of operator aids



- positioning and fixing
- for locomotion, its training and compensation
- Hygiene
- facilitating the performance of practical activities
- for the implementation of leisure, work activities
-



Adjuvatics

positioning and fixing

- position optimisation, verticalization of persons with impaired momentum
- equipped with a controller to adjust the necessary height and slopes



Adjuvatics

positioning and fixing

Positioning wedges, tubes:



- Fixation lying on the back, side, abdomen
- Rotation of positions and 30min, prevention of dekubitus

Brace:

- Stabilization of posture, spine, chest and joints

Seats:




- Specially adapted, adjustable
- Safe seat, headrest



Adjuvatics

positioning and fixing



- Positioning, verticalizing stands:
- Fixation in the areas of the feet, calves, knees and thighs, pelvis, hips and hare
- + working stations
- Sliding plate:
- Makes it easy to move from trolley to bed or car
-



Adjuvatics





For locusming, practicing and compensating

- Medical strollers:
 - For children of early age
 - Combination with duct wedges, backrests, tables ap
- Rehabilitation carts:
 - according to the drive - mechanical x electric
 - according to the environment - interior x exterior
 - by age - for children, young people and adults
 - according to construction - fixed x folding
 - according to the purpose - standard x special (sports, hygienic, transport).







Adjuvatics

Rehabilitation trucks – mechanical: activating, mechanical, multi-blow, for hemiparetics, amelia, dysmels






Adjuvatics

Special sports carts: basketball, rugby, tennis, bencykl



Adjuvatics




For sports: handbike, monocross, monoski



Adjuvatics

Limb movement trainers, e.g. after operations





- Motopeds:
- Motoding:
- Upper limbs
- Lower limbs:
- Knee and hip joint
- Ankle joint



Adjuvatics

Limb movement trainers, e.g. after operations


- Climbers: nana for children with cerebral palsy - diparetic form
- Walkers: walking practice:
 - Four-point immobile/mobile
 - Two-wheeled: mobile
 - Three-wheeled....



Adjuvatics

Crutches: support function





- four-point, French, children's elbow crutches,
- armpit, walking sticks
- height adjustable, folding outing sticks
-



Adjuvatics

Overcoming barriers

- Stair platforms: oblique, vertical
- „stairclimbers“
- ramps
-





Adjuvatics

For hygiene

increase the user's potential in self-service and independence from the assistance of the other person

Jacks, bath/shower seats, toilet trolleys




Attachments, backrests, toilet handles



Adjuvatics

Usnadňující výkon praktických činností

- fixing boards, plates
- Cutlery, handles
- Special knives
- Feeders
-




Adjuvatics

IT



Trackball, mouse

Keyboard




Adjuvatics

IT



Adjuvatics

Smart NAV a 14 Control




Adjuvatics

Strollers, trolleys



- Medical strollers:
 - For children of early age
 - Combination with abduction wedges, armrests, tables ap
- Rehabilitation carts:
 - according to drive - mechanical x electric
 - according to the environment - interior x exterior
 - by age - for children, young people and adults
 - according to the design - fixed x folding
 - according to purpose - standard x special (sports, hygienic, transport).





Conclusion




Conclusion








Prosthetics - Faculty of Medicine Masaryk University



Conclusion

21st century



Source

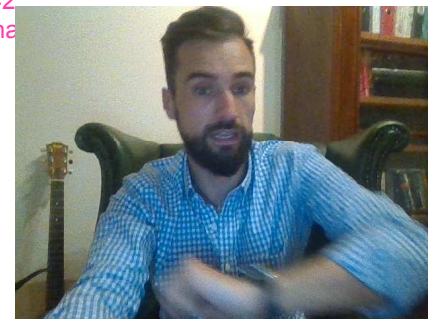publikace LF MU, doc. Ivan Müller, CSc., doc. Z. Rozkydal, Internet

- BENDO VÁ, P., JEŘÁBKOVÁ, K., RŮŽIČKOVÁ, V. *Kompenzační pomůcky pro osoby se specifickými potřebami*. Olomouc, 2006. ISBN 80-244-1436-8.
- JONÁŠKOVÁ, V. *Protetické pomůcky osob s poruchou mobility*. In Renotiérová M., Ludíková, L. a kol. Speciální pedagogika. Olomouc: UP, 2006. ISBN 80-244-1475-9.
- TŘASOŇOVÁ, Miroslava, LF MU 2005 PPT
- <http://www.oajl.cz>, <http://www.ms-protetik.cz>, <http://www.ergon.czm>, <http://www.altech-uh.cz>, <http://www.ortoservis.cz>, <http://www.zdravotniprodejna.cz>
- <http://www.medicco.cz>, <http://www.meyra.cz>, <http://www.dmapraha.cz>, <http://www.petit-os.cz>
- Janíček, P.: Ortopedie. Lékařská fakulta MU v Brně, 2001 Spoluautoři: Dufek, P., Chaloupka, R., Krbec, M., Poul, J., Procházka, P., Rozkydal, Z.
- Näder, E.M., Näder, H.G., Blomke, F: Otto- Bock Prothesen- Kompendium Prothesen für die untere Extremität. 2. Auflage, Schiele and Schön, 1993.
- Otto Bock: Technische Information, 2.3.5. ISNY – Island- Schweden, New York, 1990.
- Sosna, A., Vavřík, P., Krbec, M., Pokorný, D.: Základy ortopedie. Triton, 2001.
- Fotografie z LAOS (soukromá databáze Jan Kocanda)



Source

1. Scheuermann HW. Kyphosis dorsalis juvenilis. *Orthop Chir.* 1921;41:305–317.
2. Sorensen KH. Scheuermann's Juvenile Kyphosis: clinical appearances, radiography, aetiology and prognosis. Munksgaard; Copenhagen: 1964.
3. Stoddard A, Osborn JF. Scheuermann's disease or spinal osteochondrosis: its frequency and relationship with spondylosis. *J Bone Joint Surg Br.* 1979;61(1):56–58.
4. Taylor TC, Wenger DR, Stephen J, Gillespie R, Bobechko WP. Surgical management of thoracic kyphosis in adolescents. *J Bone Joint Surg Am.* 1979;61(4):496–503.
5. Ali RM, Green DW, Patel TC. Scheuermann's kyphosis. *Curr Opin Pediatr.* 1999;11(1):70–75.
6. Bradford DS. Juvenile kyphosis. In: Lonstein JE, Bradford DS, Winter RB, Ogilvie J, editors. *Moe's textbook of scoliosis and other spinal deformities.* 3rd ed. Saunders; Philadelphia: 1995. pp. 349–367.
7. Damborg F, Engell V, Andersen M, Kyvik KO, Thomsen K. Prevalence, concordance, and heritability of Scheuermann kyphosis based on a study of twins. *J Bone Joint Surg Am.* 2006;88(10):2133–2136.
8. Gilsanz V, Gibbens DT, Carlson M, King J. Vertebral bone density in Scheuermann disease. *J Bone Joint Surg Am.* 1989;71(6):894–897
9. Lopez RA, Burke SW, Levine DB, Schneider R. Osteoporosis in Scheuermann's disease. *Spine.* 1988;13(10):1099–1103.
10. Lowe TG. Scheuermann disease. *J Bone Joint Surg Am.* 1990;72(6):940–945
11. Aufdermaur M. Juvenile kyphosis (Scheuermann's disease): radiography, histology, and pathogenesis. *Clin Orthop Relat Res.* 1981;(154):166–174.
12. Ferguson AB., Jr The etiology of preadolescent kyphosis. *J Bone Joint Surg Am.* 1956;38(1):149–157
13. Scoles PV, Latimer BM, Digiovanni BF, Vargo E, Bauza S, Jellema LM. Vertebral alterations in Scheuermann's kyphosis. *Spine.* 1991;16(5):509–515
14. Bradford DS, Moe JH, Montalvo FJ, Winter RB. Scheuermann's kyphosis. Results of surgical treatment by posterior spine arthrodesis in twenty-two patients. *J Bone Joint Surg Am.* 1975;57(4):439–448.
15. Murray PM, Weinstein SL, Spratt KF. The natural history and long-term follow-up of Scheuermann kyphosis. *J Bone Joint Surg Am.* 1993;75(2):236–248.
16. Tribus CB. Scheuermann's kyphosis in adolescents and adults: diagnosis and management. *J Am Acad Orthop Surg.* 1998;6(1):36–43.
17. Gill JB, Levin A, Burd T, Longley M. Corrective osteotomies in spine surgery. *J Bone Joint Surg Am.* 2008;90(11):2509–2520
18. Berven SH, Deviren V, Smith JA, Hu SA, Bradford DS. Management of fixed sagittal plane deformity: outcome of combined anterior and posterior surgery. *Spine (Phila Pa 1976)* 2003;28:1710–1716.
19. Bridwell KH. Decision making regarding Smith-Petersen vs. pedicle subtraction osteotomy vs. vertebral column resection for spinal deformity. *Spine (Phila Pa 1976)* 2006;31(19 Suppl):S171–S178
20. Lee SS, Lenke LG, Kuklo TR, Valenté L, Bridwell KH, Sides B, Blanke KM. Comparison of Scheuermann kyphosis correction by posterior-only thoracic pedicle screw fixation versus combined anterior/posterior fusion. *Spine (Phila Pa 1976)* 2006;31(20):2316–2321
21. Macedo RD, Fontes BPC, Cunha FM, Werlang PM. Sistema de parafusos pediculares no tratamento de deformidades vertebrais: *Rev Bras Ortop.* 2006;41(10):417–424.
22. Suk SI, Kim WJ, Lee SM, Kim JH, Chung ER. Thoracic pedicle screw fixation in spinal deformities: are they really safe? *Spine (Phila Pa 1976)* 2001;26(18):2049–2057.
23. Kim YJ, Lenke LG, Bridwell KH, Cho YS, Riew KD. Free hand pedicle screw placement in the thoracic spine: is it safe? *Spine (Phila Pa 1976)* 2004;29(3):333–342
24. Bradford DS, Ahmed KB, Moe JH, Winter RB, Lonstein JE. The surgical management of patients with Scheuermann's disease: a review of twenty-four cases managed with posterior spine fusion. *J Bone Joint Surg Am.* 1980;62(5):705–712



Thank you for your attention.

E: kocanda@med.muni.cz

T: 00420 5 3223 3118

M: 00420 774 536 287

UČO: 31182

 **FAKULTNÍ
NEMOCNICE
BRNO**

