

19. Acute back pain

A diagnostic algorithm is derived based on whether acute back pain is traumatic or non-traumatic. Diseases of organs other than the spine, which may present with back pain, should also be considered in the context of differential diagnosis.

Trauma of the spine

The basic diagnostic modality for the detection of traumatic changes in the spine remains **X-ray** of the spine performed in two standard projections (anteroposterior and lateral), mainly due to the possibility of examination of long sections of the spina (eventually the whole spine) and a relatively low radiation dose. The sensitivity of X-ray examination is undoubtedly lower compared to CT, which, however, when examining large sections of the spine (e.g. thoracic and lumbar) burdens the patient with a much higher radiation dose compared to X-ray, so this indication is not justified as a method of first choice. An exception is whole-body CT performed in polytraumatized patients, which provides a detailed assessment of the skeleton of the entire spine. The indication of this examination is given by the assumption of the presence of other life-threatening injuries (chest, parenchymal organs), which justifies the application of a higher radiation dose.

If trauma on X-ray is suspected or in case of unclear findings (eventually in case of insufficient clarity of some sections of the spine), the **CT** examination is indicated specifically for selected levels of the spine. CT makes it possible to detect skeletal fracture lines with very high sensitivity, to classify the type of fracture (*Fig. 1*) and to assess the possible prominence of bone fragments into the spinal canal. A general limitation of CT is the relatively low contrast of soft tissues, so this method is not suitable for the detection of discoligamentous injury.

The last of the available methods is **MR** examination, which does not burden the patient with radiation and allows examination of long segments of the spine in an acceptable time. Indications of MR is reserved for traumatic conditions in which the patient have a significant neurological deficit that is not explained by the finding on CT. In such a case, we look for signs of discoligamentous trauma, such as traumatic disc herniation with compression of the spinal cord or nerve roots (*Fig. 2*). Fresh traumatic changes in the skeletal spine, especially the compression of vertebral bodies, are characterized in the MR image by an increased T2 signal of the bone marrow corresponding to edema, which can also be used to estimate the age of the fracture. A certain limitation of MR can sometimes be difficulties in detection of skeletal fractures, which are generally better visible on CT.

Non-traumatic conditions

Back pain, especially in the lumbar region, is a very common clinical problem, which is one of the most common reasons for visiting a doctor. In most cases, non-traumatic back pain has no obvious cause and usually resolves spontaneously within a few weeks, sometimes referred to as non-specific back pain. In this case, the international guidelines generally oppose the routine use of imaging methods, which do not provide any essential information necessary for the treatment, which usually consists of symptomatic analgesic therapy. However, it is not a mistake to take an X-ray of the spine.

In patients with back pain, however, it is necessary to take into account so-called "**red flags**", i.e. significant clinical circumstances that may indicate a more serious structural pathology of the spine as a cause of back pain. These include, in particular, **known** or suspected **oncological diseases** (weight loss, etc.), long-term **use of corticosteroids** or other conditions leading to **osteoporosis, signs of infectious disease or immunodeficiency**, etc. In such cases, **X-ray** examination of the spine especially compression of vertebral bodies. If the problem persists or if there is a serious clinical suspicion of structural pathology of the spine, **MR** is the method of choice, which, in addition to assessing the severity of degenerative changes, allows to detect pathological changes of the bone marrow of the spine with

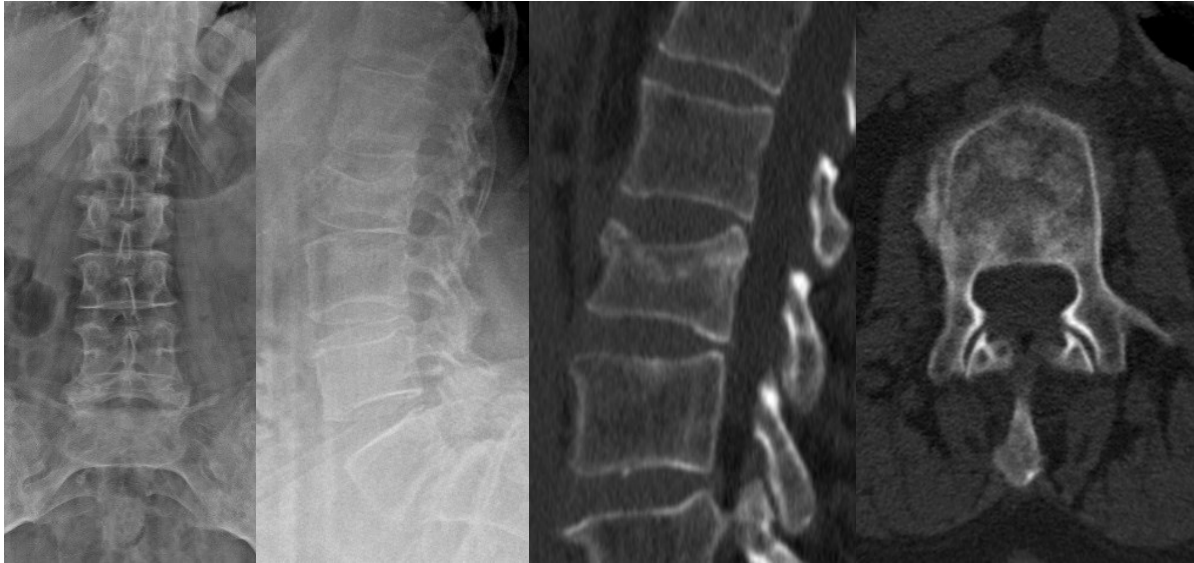sensitivity exceeding not only X-ray but also CT examination. CT, unlike MR, rather than bone marrow involvement, detects the destruction of the mineralized component of bone, which in many cases occurs in the later stages of the disease; therefore, the indication for CT examination of the spine is currently reserved almost exclusively for traumatic conditions. On MR, we can detect, for example, metastatic or inflammatory involvement of the spine in patients with back pain. In the case of metastases or other tumorous process of the skeletal spine, MR enables sensitive detection of skeletal infiltration (*Fig. 3*), eventually the spread of the soft tissue component of the tumor paravertebrally or into the spinal canal.

The most common inflammatory diseases of the spine include spondylodiscitis, which is an infectious process affecting the intervertebral disc and adjacent parts of the vertebral bodies. The optimal imaging method for the detection of spondylodiscitis is MR, which allows to detect inflammatory changes from the early stage of inflammation in the form of edema or pathological enhancement of the intervertebral disc and adjacent parts of vertebral bodies (*Fig. 4*). In these cases, where skeletal destruction is not yet present, X-ray and CT examination are not very sensitive. Methods of nuclear medicine (bone scintigraphy, PET) also have a high sensitivity for the detection of spinal inflammation, although the findings, especially in the case of bone scintigraphy, are less specific compared to MR.

In patients with back pain, in addition to the anamnesis and basic physical examination, it is also appropriate to perform a neurological examination to detect radiculopathy or other neurological symptoms. In such cases, MR examination is indicated. MR enables precise visualisation of possible disc herniations and their relationship to nerve structures (*Fig. 5*).

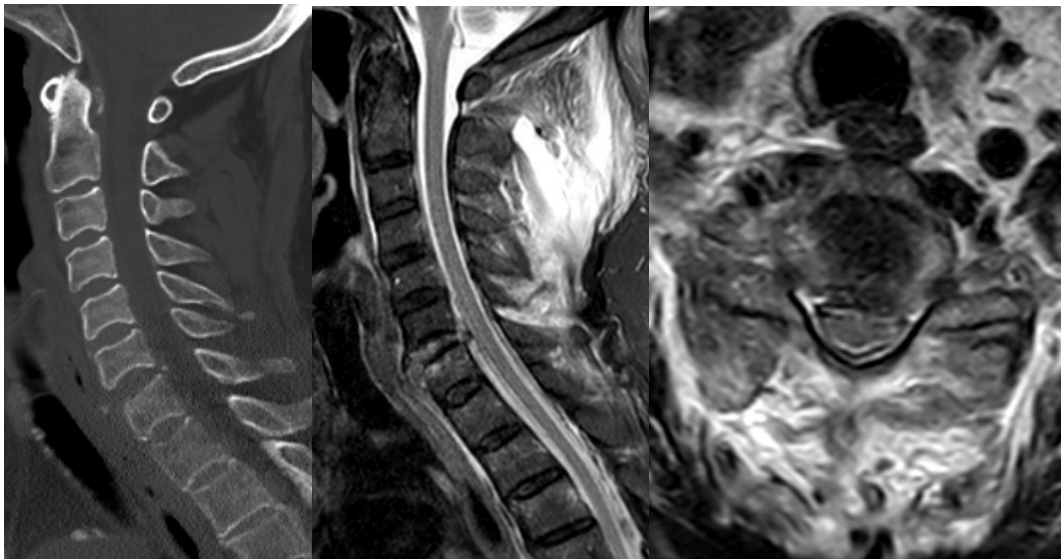
Other causes of back pain

There are a number of diseases whose clinical picture is characterized by back pain and which can therefore mimic vertebrogenic problems. These conditions include, for example, renal colic, acute pancreatitis, and aortic dissection. Therefore, in the context of differential diagnosis, it is necessary to look for clinical and laboratory signs that may raise suspicion of these diseases. In such a case, there are indicated appropriate imaging methods targeted at specific anatomical areas, most often ultrasound or CT.



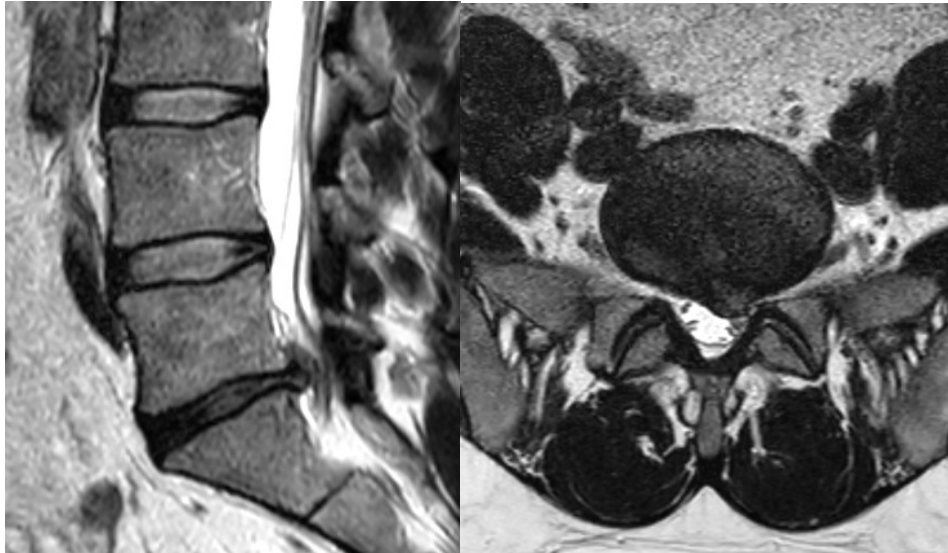
Compression fracture of L2, type A3 according to AO classification

Already displayed on **X-ray** (left) then on **CT** (right). X-rays allow the detection of a fracture, but CT is necessary for a more accurate classification, which in many cases determines further treatment. Here, the interference of the fracture lines into the posterior edge of the vertebral body is evident, without significant dislocation of the fragments into the spinal canal.



Discoligamentous injury at the level C6/7.

The suspicion was already expressed on a CT examination of the cervical spine (**left**), where a slight enlargement of the C6 / 7 intervertebral space is evident on the sagittal reconstruction. This finding was confirmed by MR examination, where the pathological signal of the torn disc and its prolapse in the ventral and dorsal direction into the spinal canal are visible in the STIR image (**middle**). In the axial plane (**right**) there is a noticeable restriction of the ventral arachnoid space and a slight impression of the spinal cord. In the paravertebral soft tissues, a large bleeding zone with increased signal intensity is seen dorsally.



*Left paramedial **hernia of the disc L5/S1** impressing the nerve root S1 on the left on MR. Left T2 in sagittal plane, right T2 in coronal plane.*