

TREATMENT OF SPINAL TRAUMA


MUDr. D. Matejička, MUDr. J. Sklenský, MUDr. M. Prýmek

Department of Orthopaedic Surgery

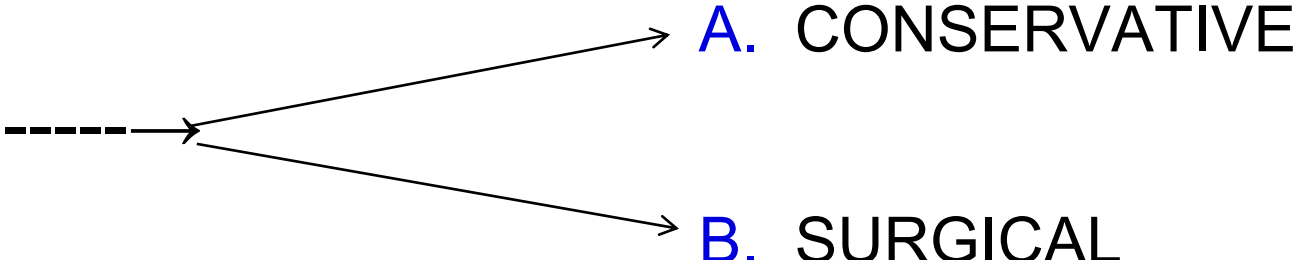
at

**Faculty of Medicine, Masaryk University and
University Hospital Brno**

Head : prof. MUDr. Martin Repko, Ph.D.

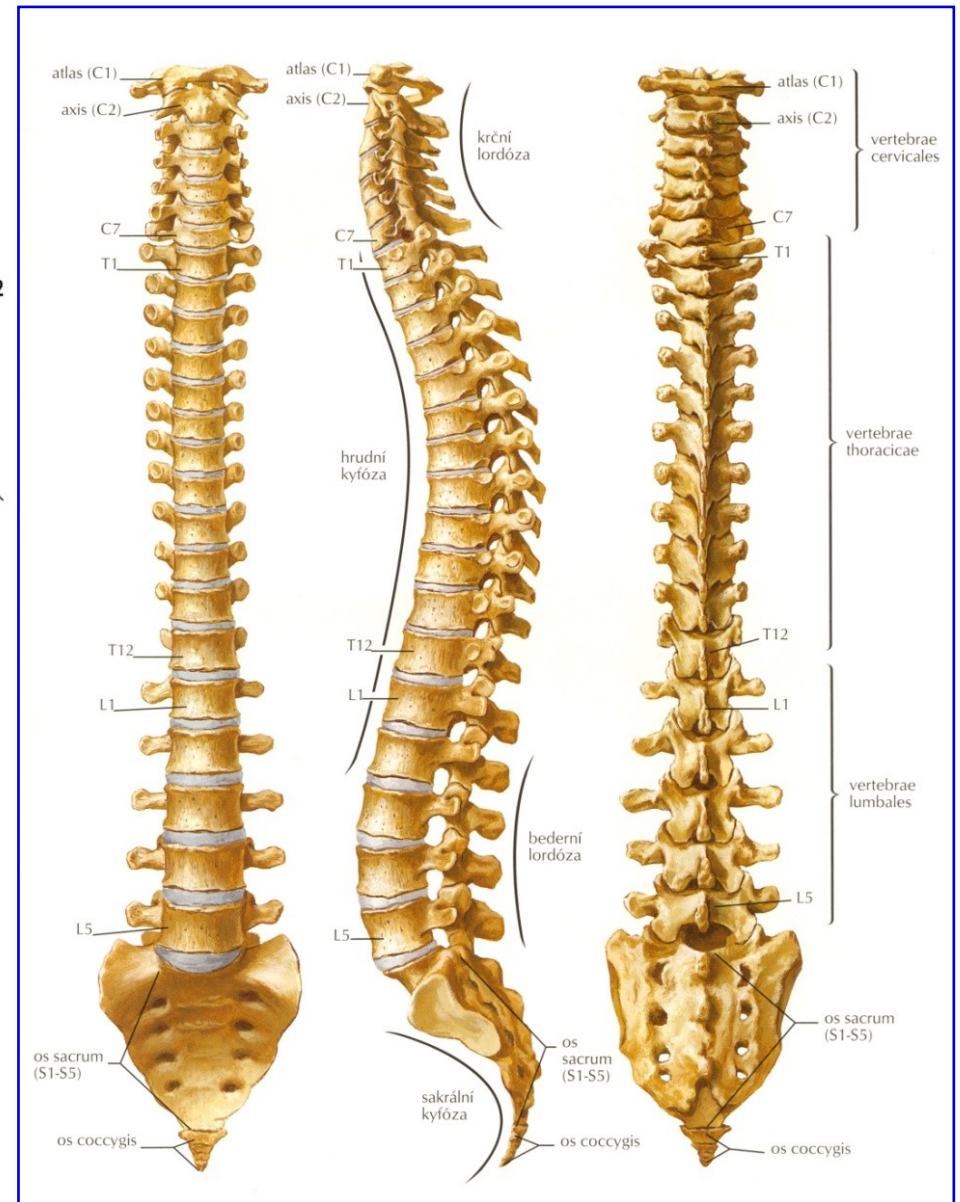
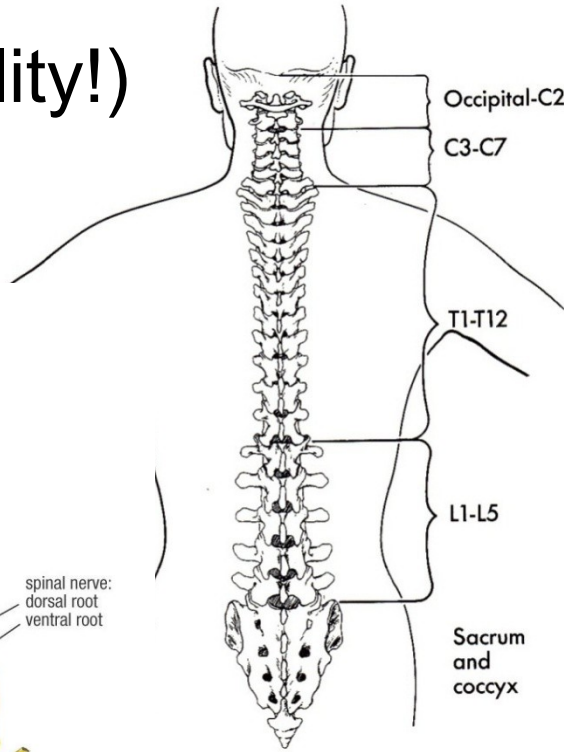
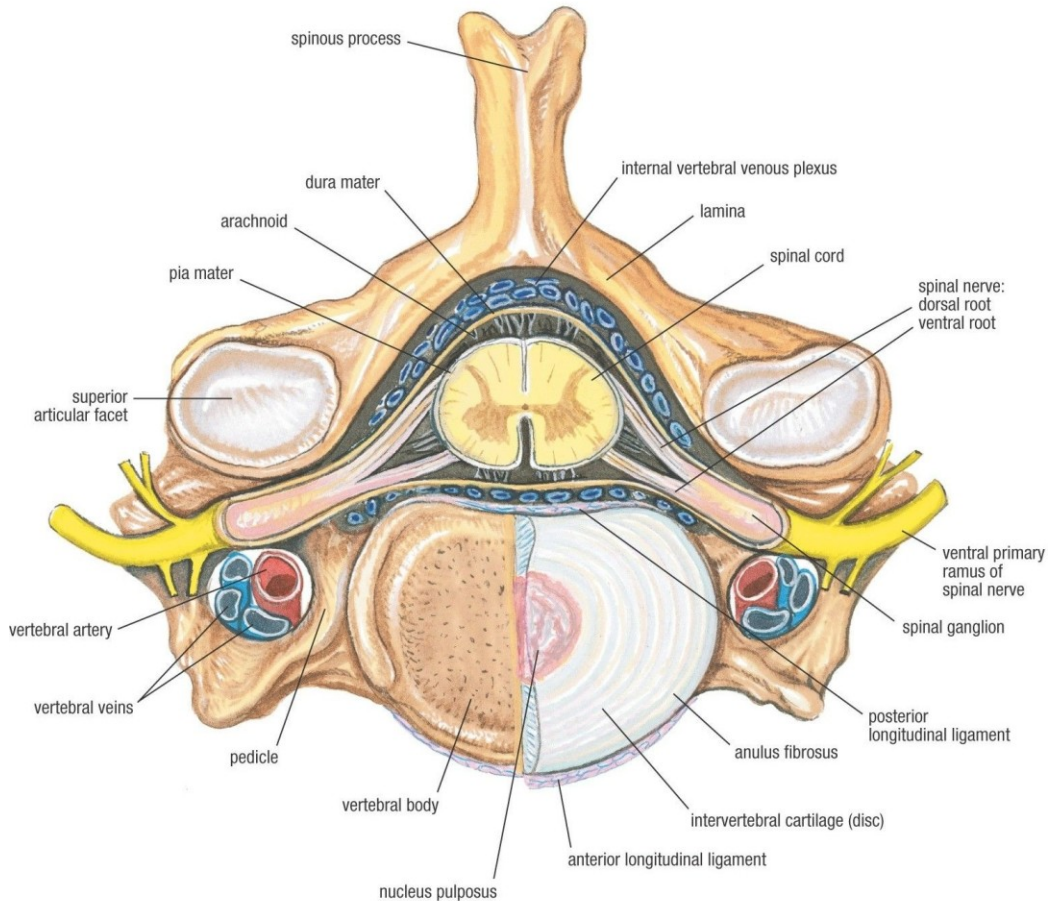


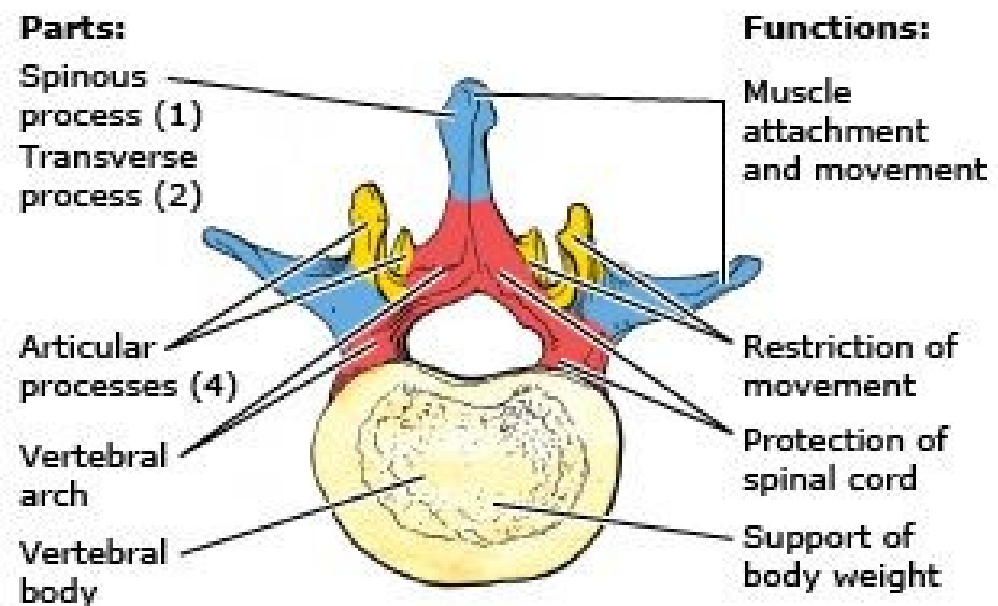
CONTENT:

- I. Revision of Anatomy
- II. Biomechanics of spine
Mechanisms of trauma,
- III. AO classification
- IV. Spinal cord injury + examination
- V. Treatment 
 - A. CONSERVATIVE
 - B. SURGICAL
- VI. Instrumentation of the spine
 - trauma vs. degenerative goals & treatment

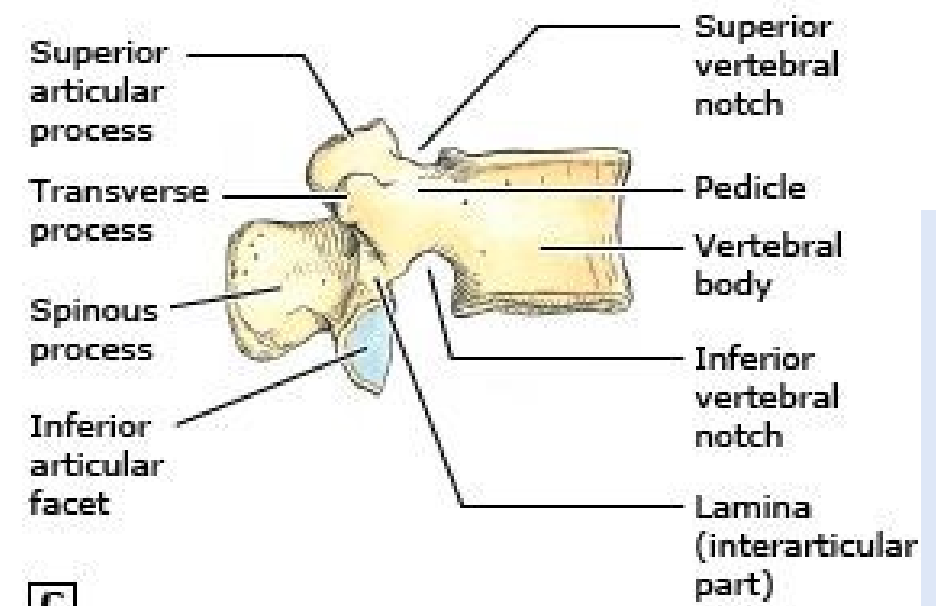
I. Revision of Anatomy - SPINE

- count of vertebrae (variability!)
- spine curvatures
- neuro-vascular structures!

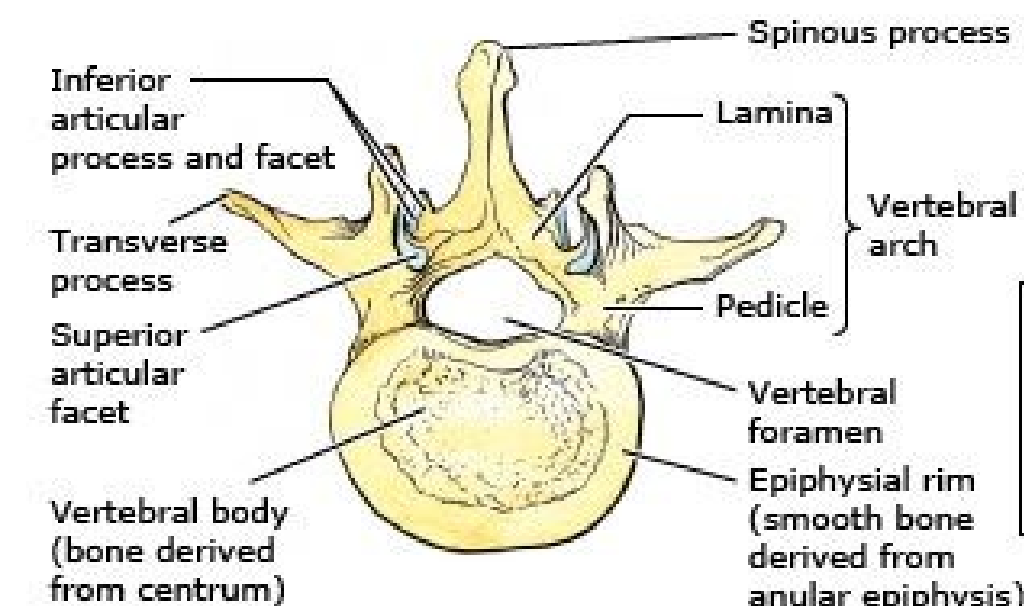




A

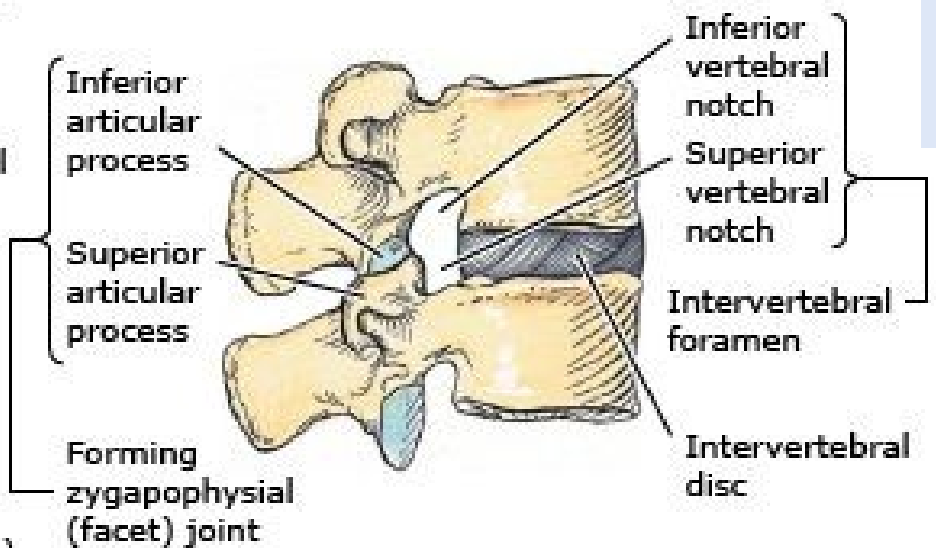


C



Superior views

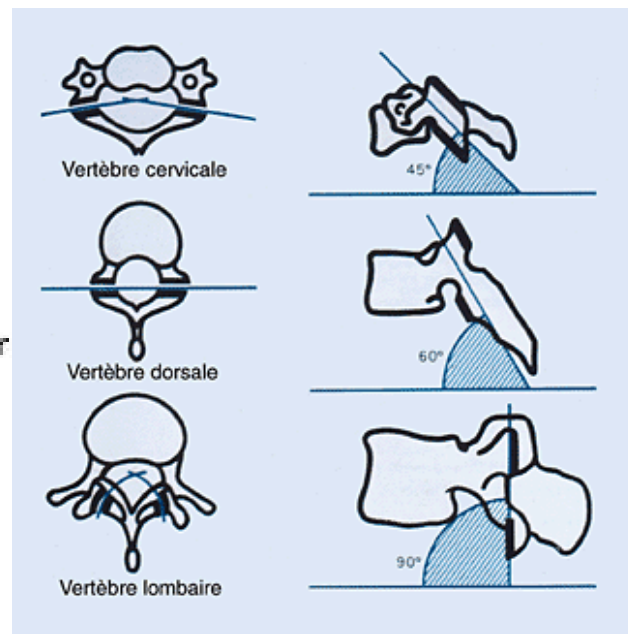
B



Lateral views

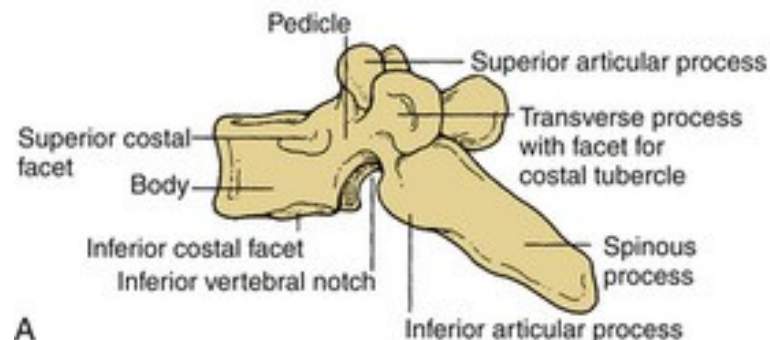
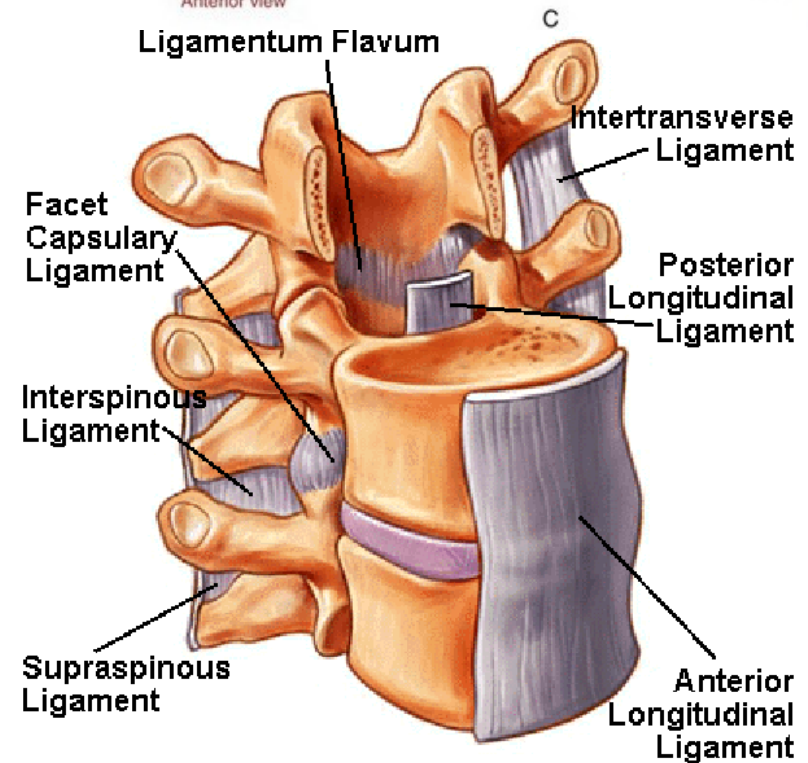
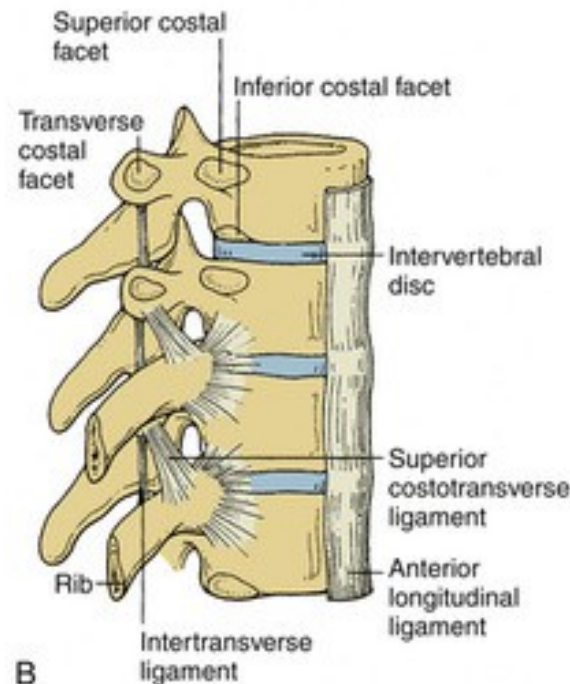
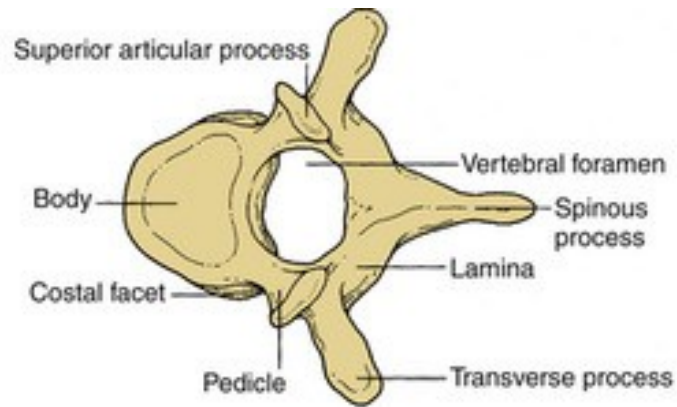
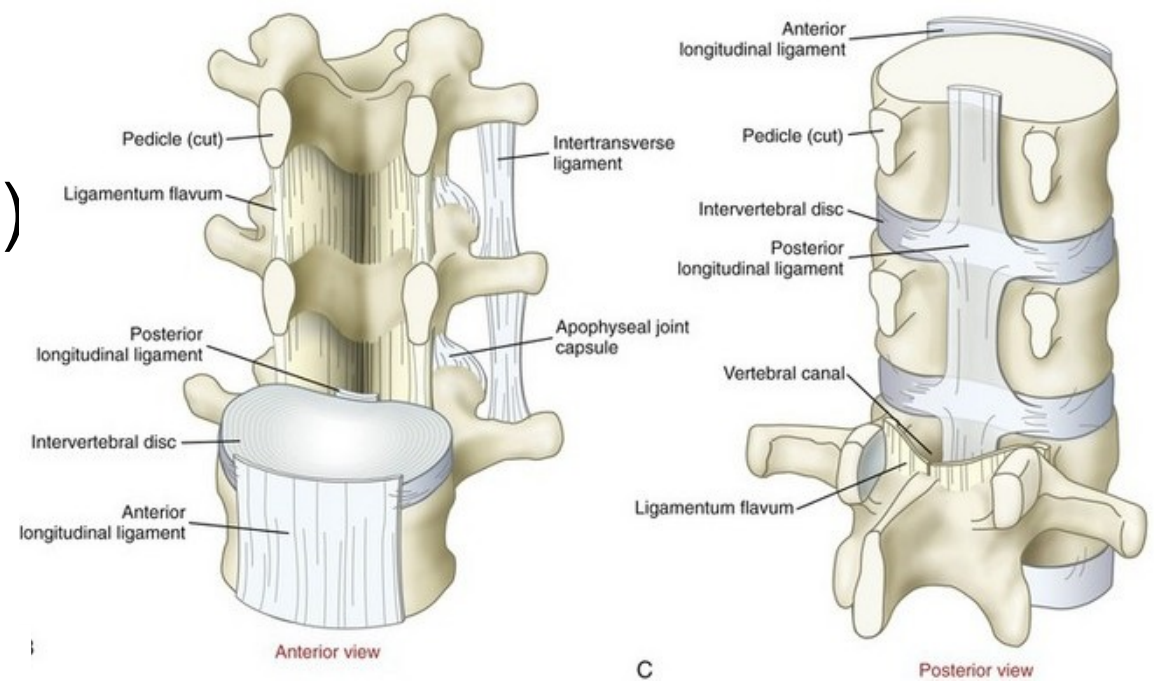
D

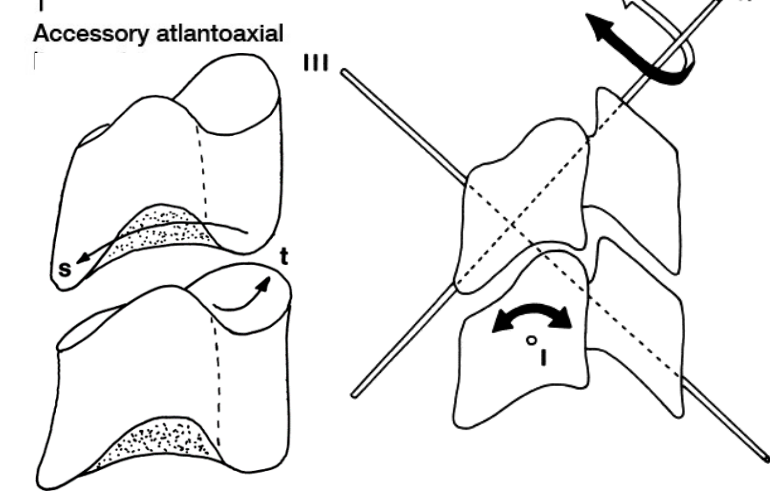
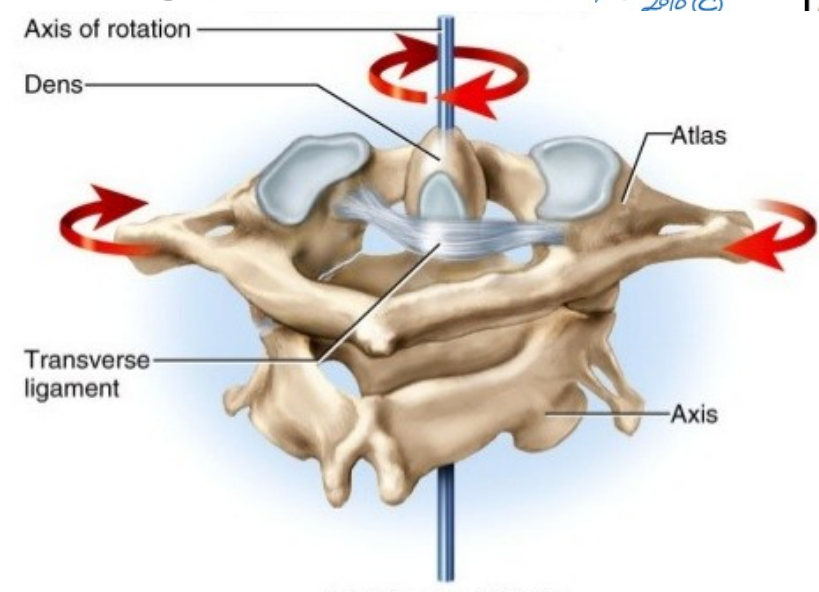
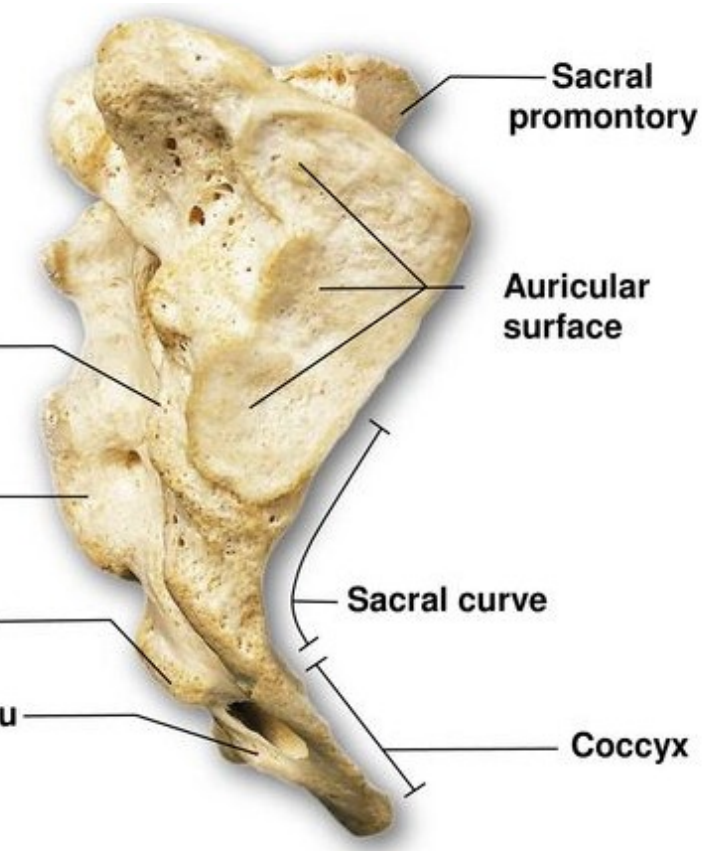
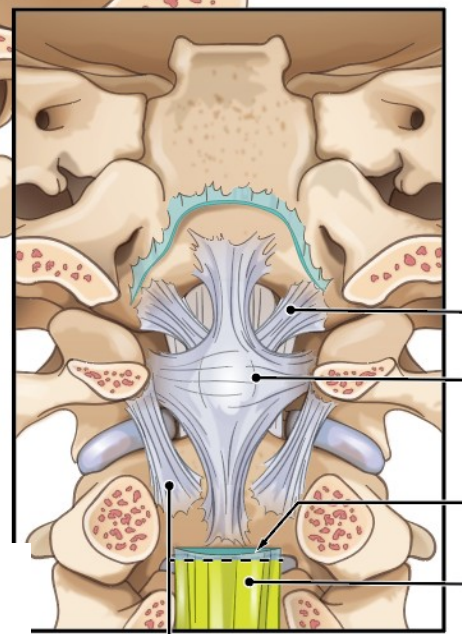
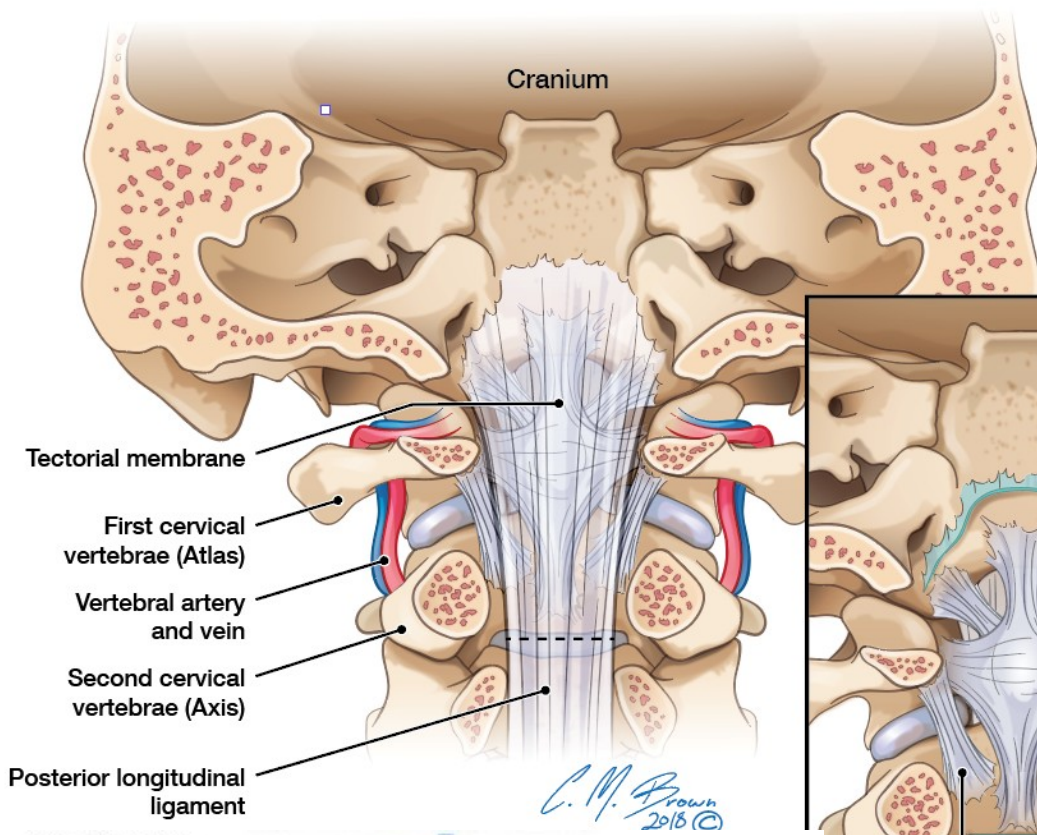
Facet joints angle



-Synarthrosis „joints“
 (connection by cartilage/ligament/bone)

-Diarthrosis (synovial) joints
 (articular surfaces, joint capsule, cavity, synovial fluid ...)





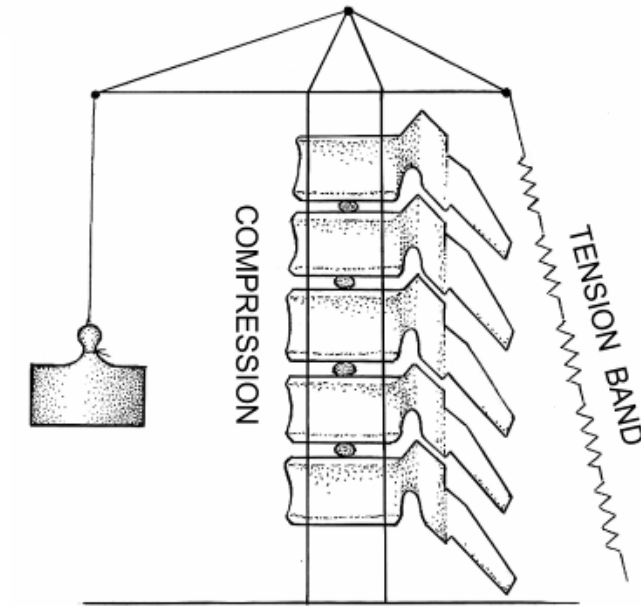
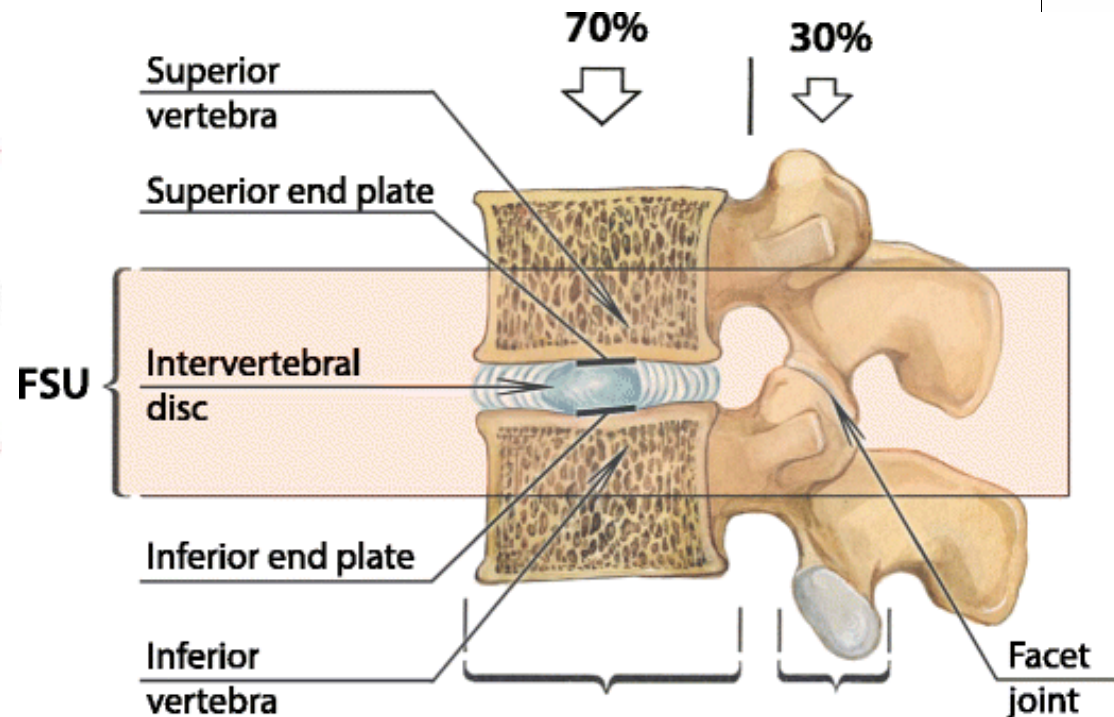
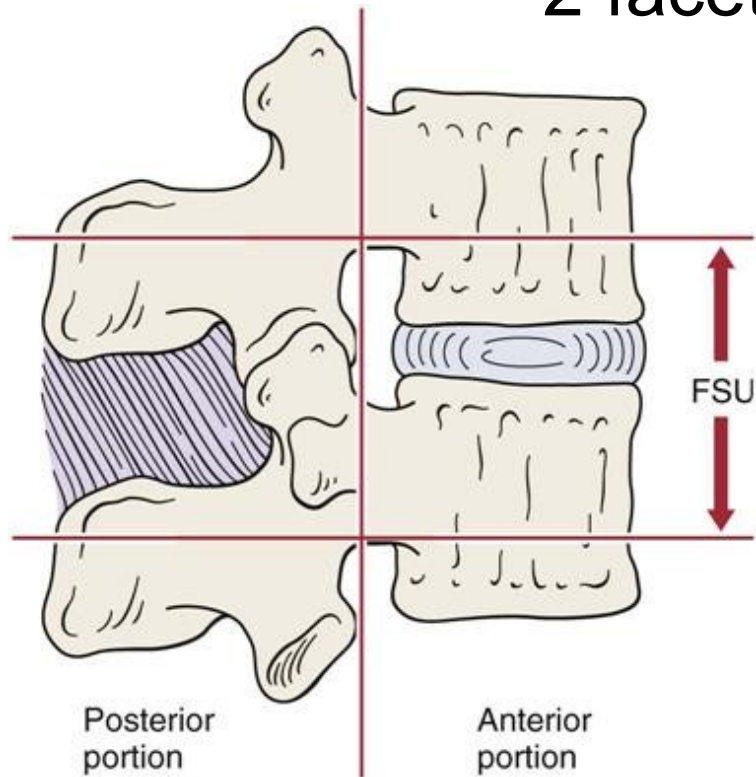
b A lateral view from the right side

II. Biomechanics - Functional Spinal Unit (FSU)

= smallest mobile segment of the spine

- Composed of: 2 adjacent vertebrae, intervertebral disc, ligaments

2 facet joints and capsules, surrounding soft tissues



II. Incidence of spinal trauma

- 3-6 % of all injuries
- 70 % thoracic and lumbar
- 30 % cervical
- 20 % presence of neurological deficit

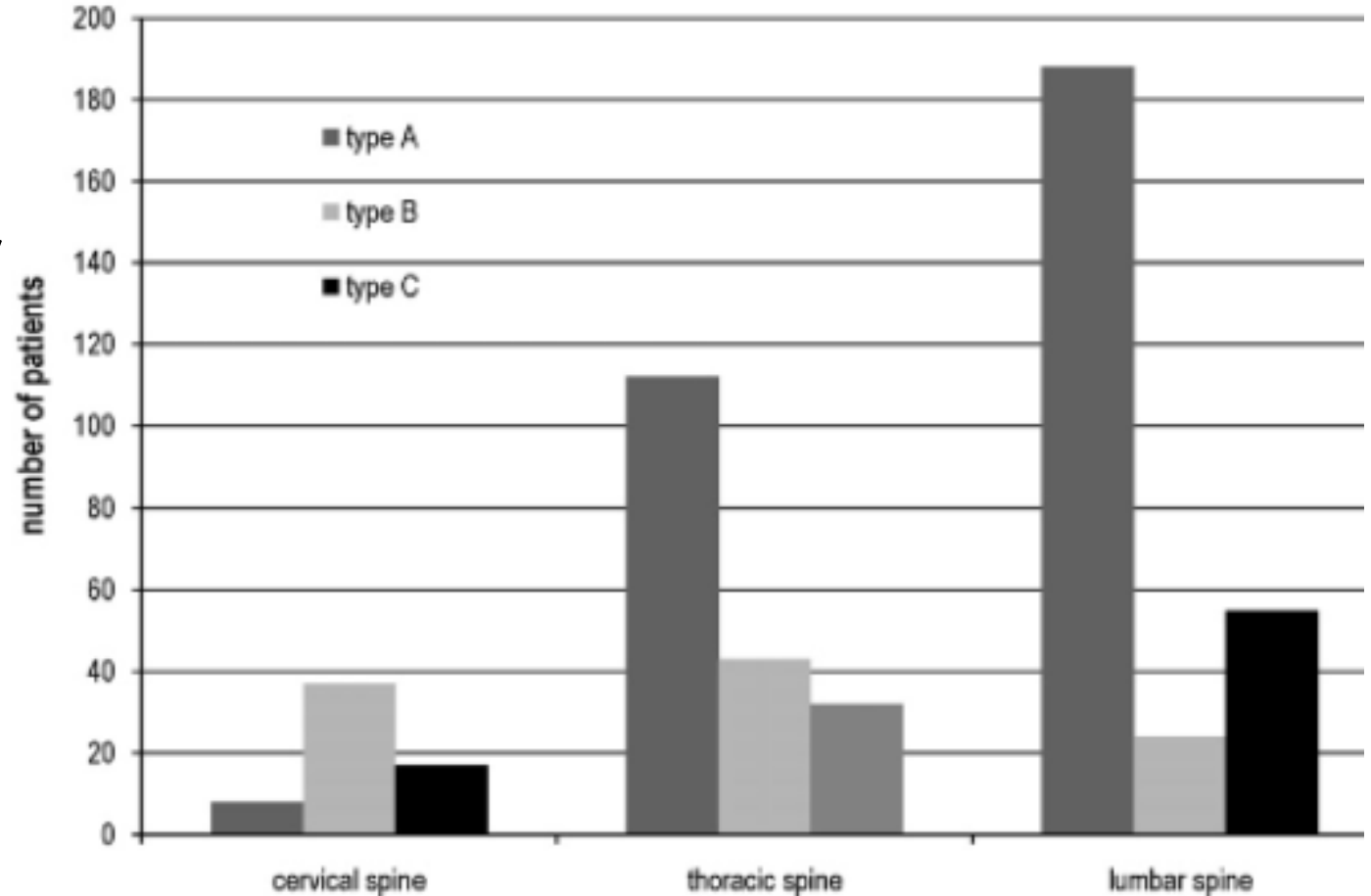


Fig. 5. Incidence of fracture mechanism in each spinal level.

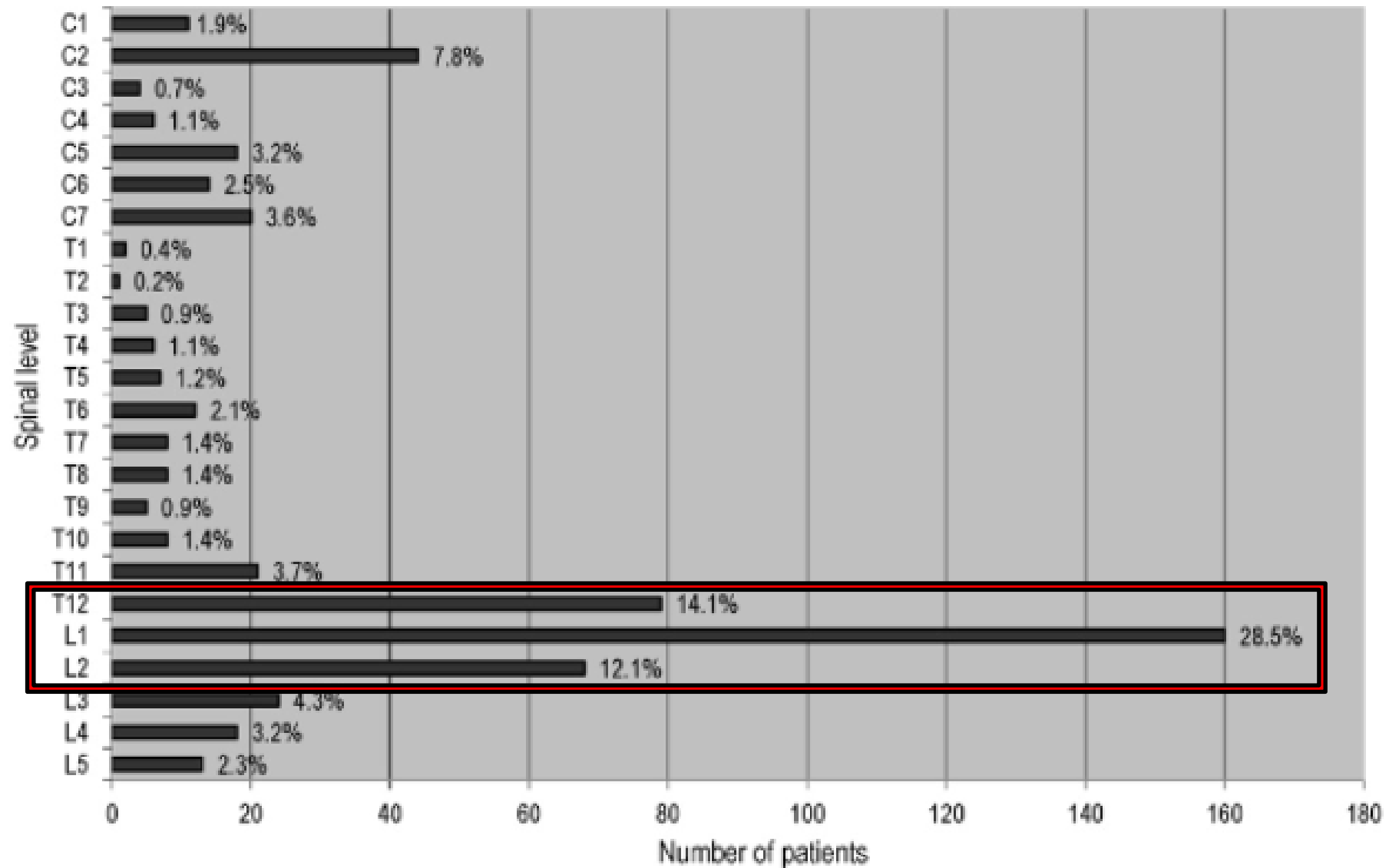


Fig. 4. Distribution of spine fractures for each vertebra.

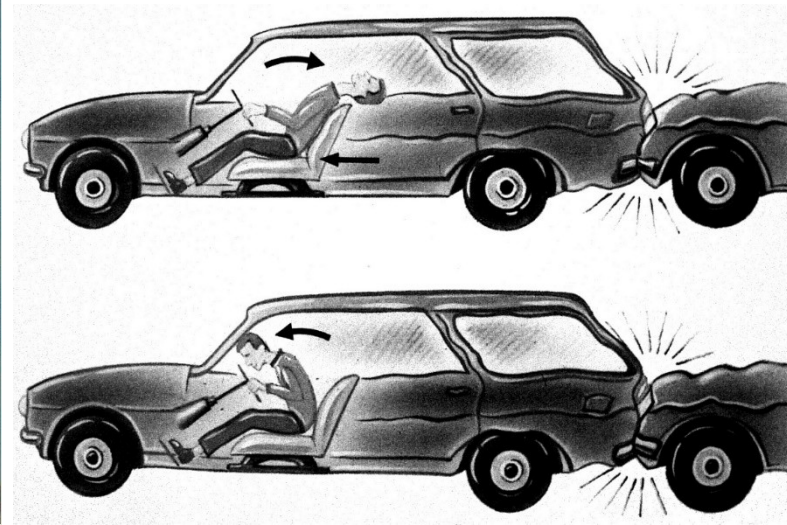
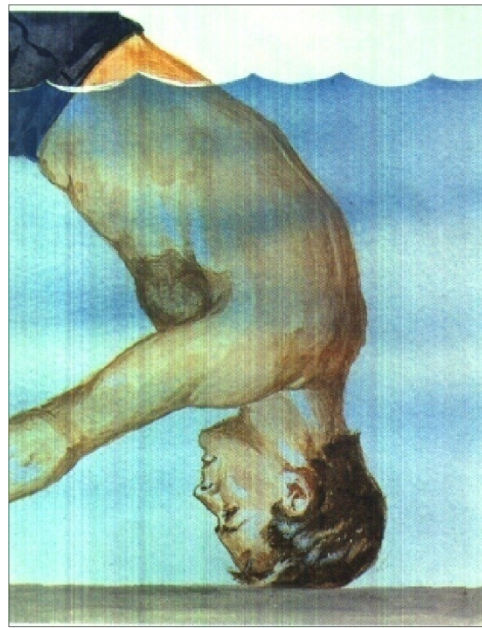Etiology of spinal trauma

- High energy trauma – youth
- Low energy trauma – over 60 yo (osteoporotic fx.)
- Falls
- Traffic accidents
- **whiplash** injury
- Sport
- Combinations

Table 3

Relationship between cause of accident and fracture localisation.

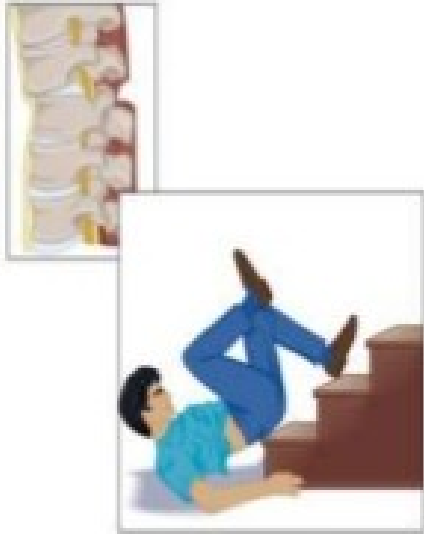
Cause of accident	Fracture localisation				
	C1-2	C3-7	T1-10	T11-L2	L3-5
High-energy fall	18 (8.2%)	14 (6.4%)	15 (6.8%)	150 (68.5%)	22 (10%)
Simple fall	11 (9.6%)	9 (7.9%)	5 (4.4%)	75 (65.8%)	14 (12.3%)
Traffic	21 (14.1%)	26 (17.4%)	30 (20.1%)	58 (38.9%)	14 (9.4%)
Sports	3 (10.3%)	9 (31%)	4 (13.8%)	12 (41.4%)	1 (3.4%)
Miscellaneous	2 (3.9%)	4 (7.8%)	8 (15.7%)	33 (64.7%)	4 (7.8%)
Total	55 (9.8%)	62 (11%)	62 (11%)	328 (58.4%)	55 (9.8%)



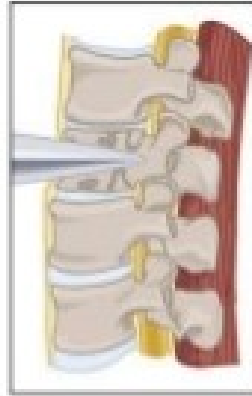
Leucht et al. 2009

Spinal trauma- mechanisms

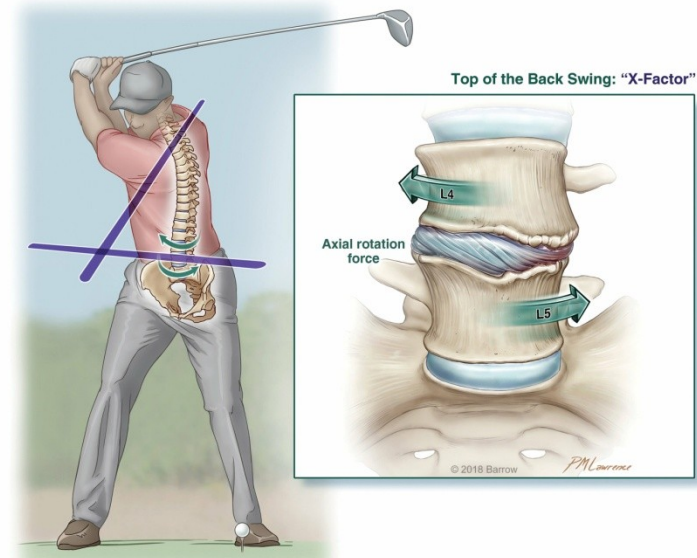
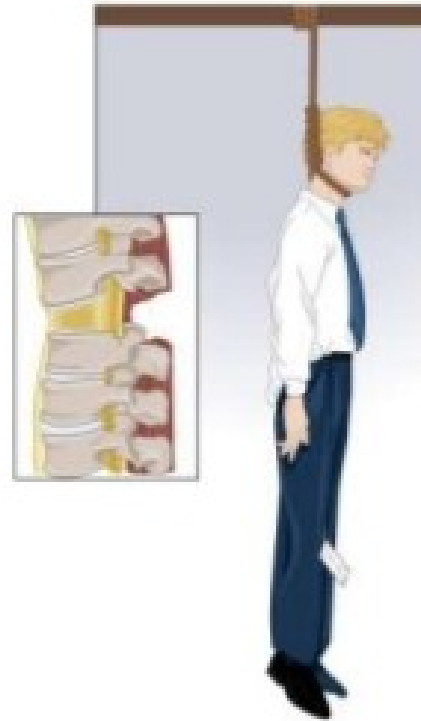FLEXION INJURY



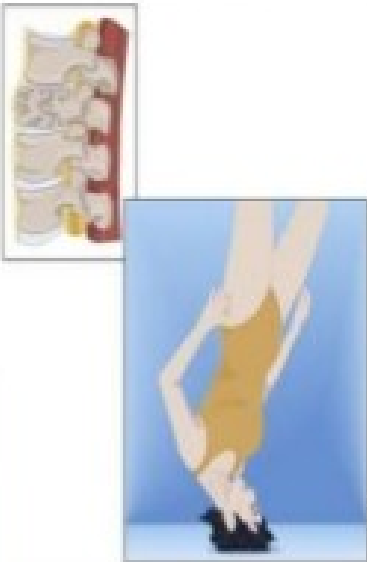PENETRATION INJURY



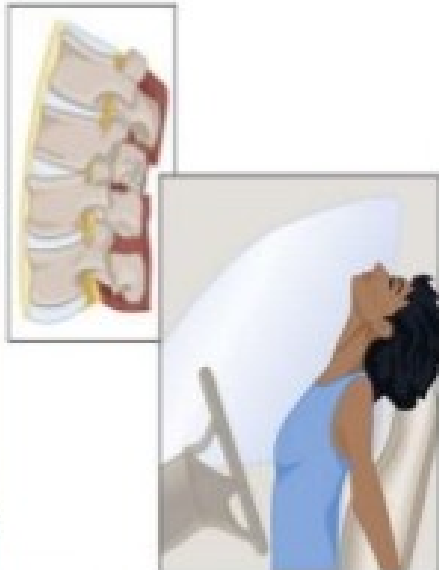DISTRACTION INJURY



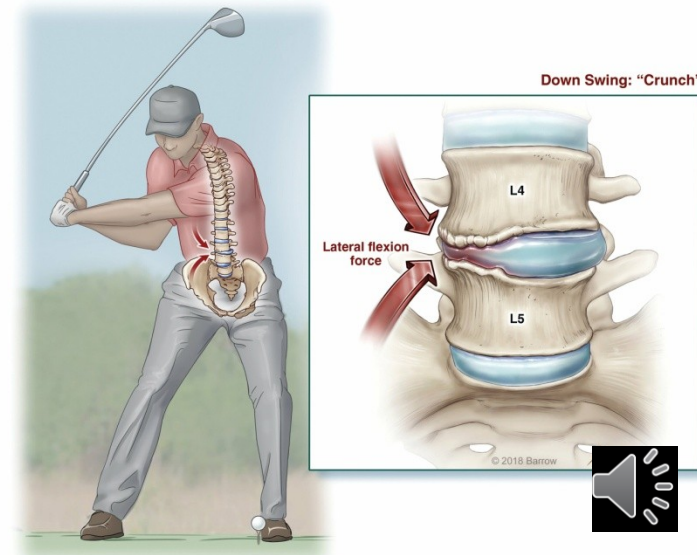
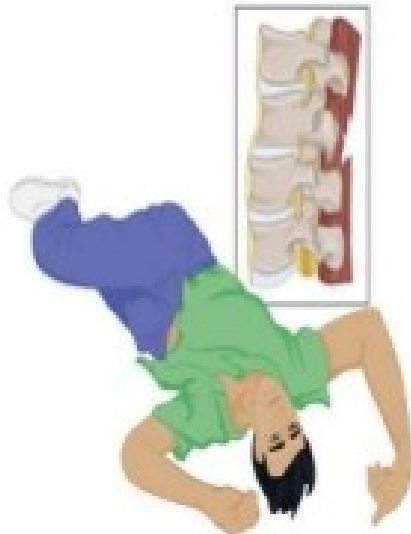COMPRESSION INJURY



HYPEREXTENSION INJURY

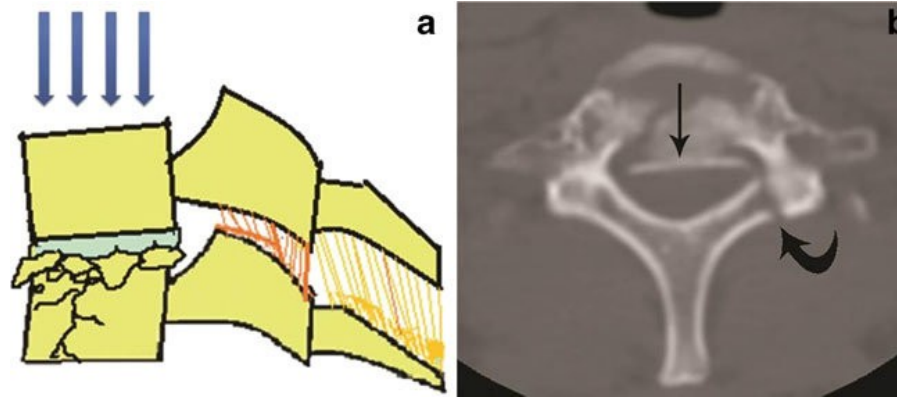
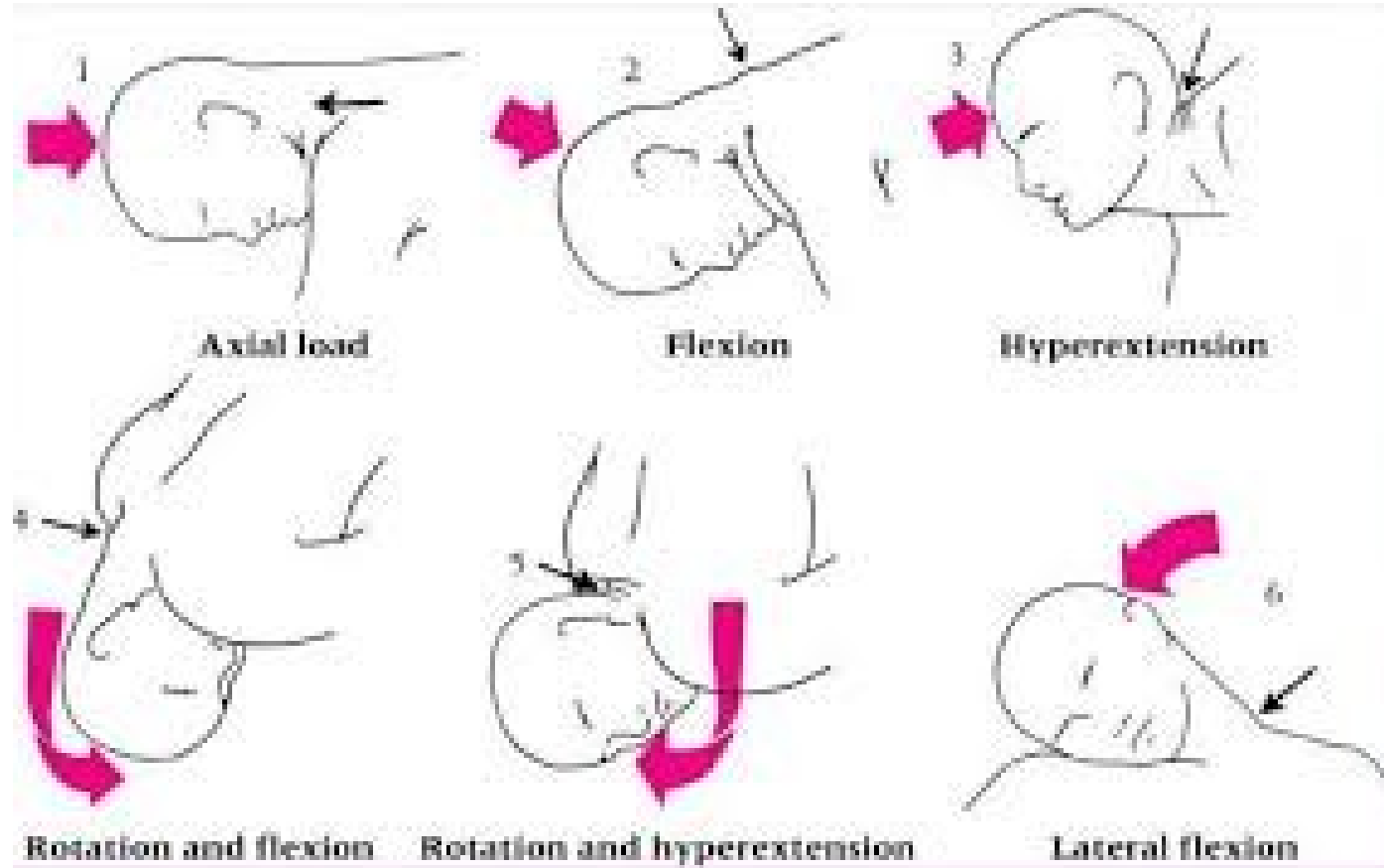
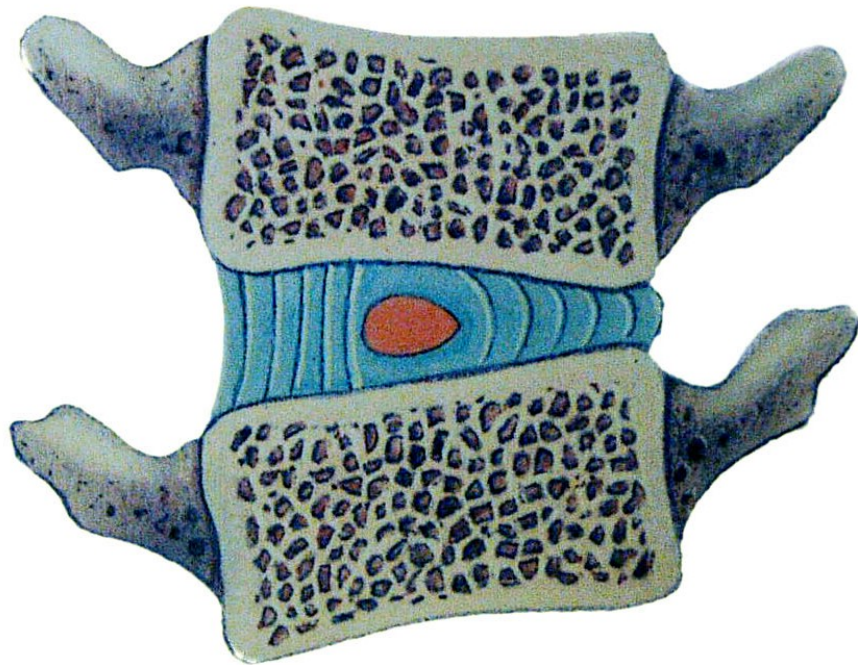


FLEXION-ROTATION INJURY



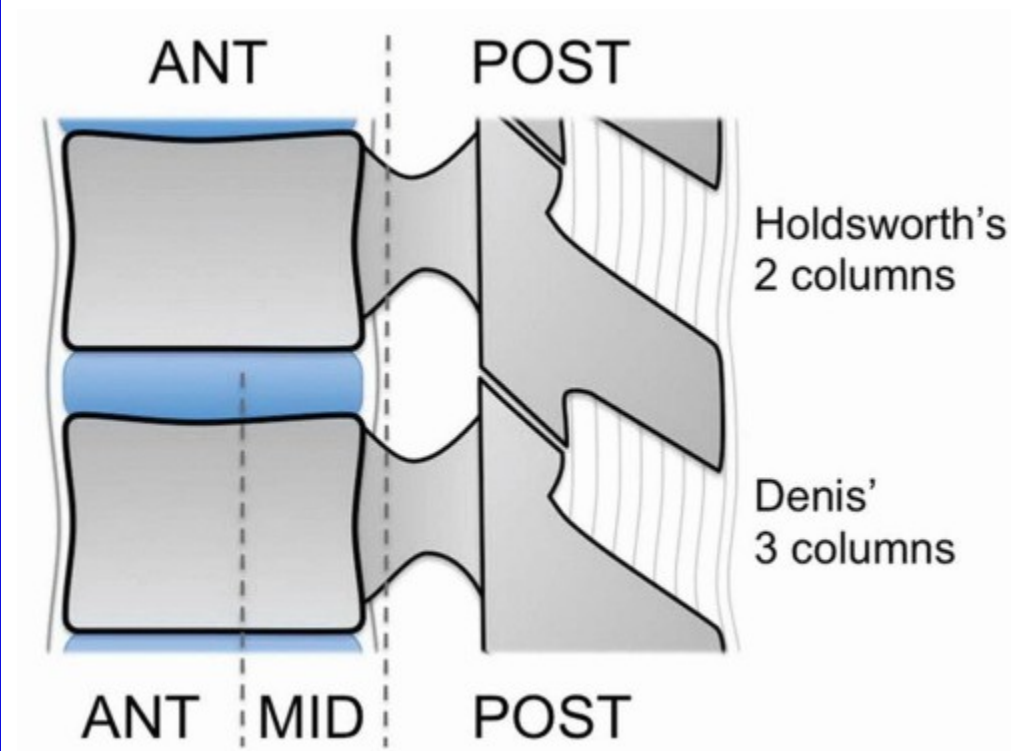
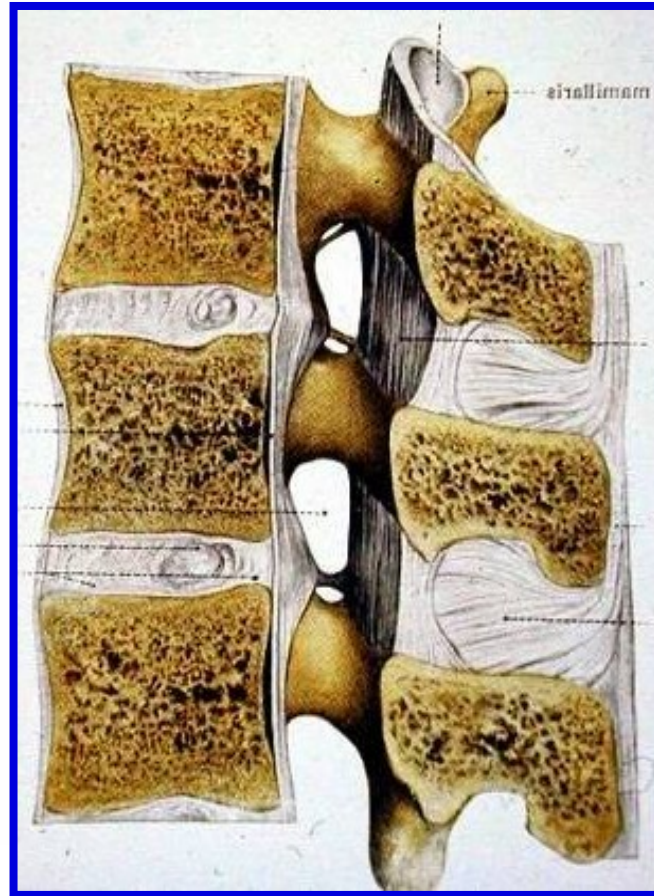
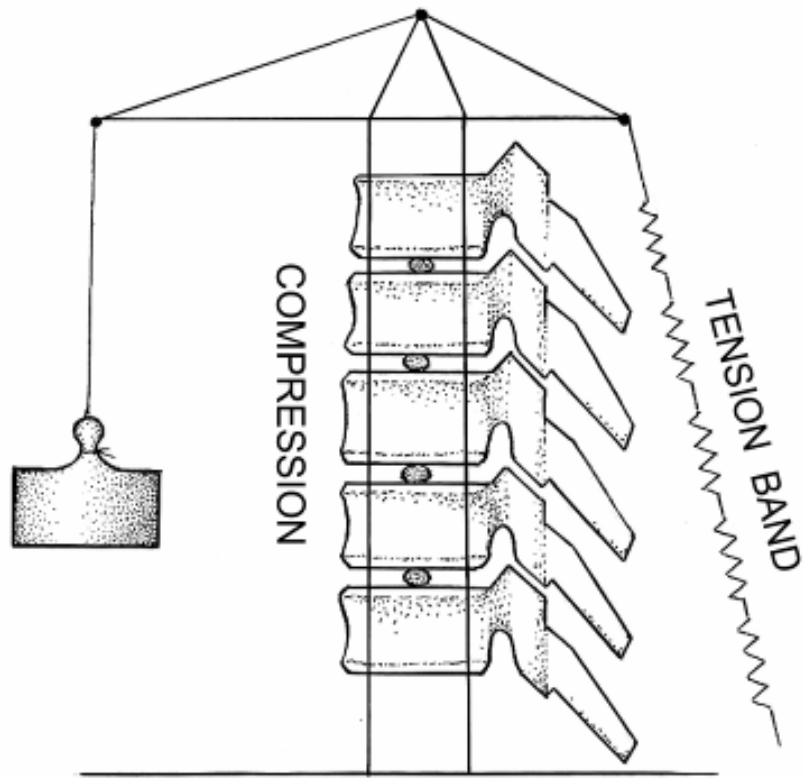
Types of injuries

- Axial load forces
- Flexion-Extension forces
- Rotation forces
- Combination



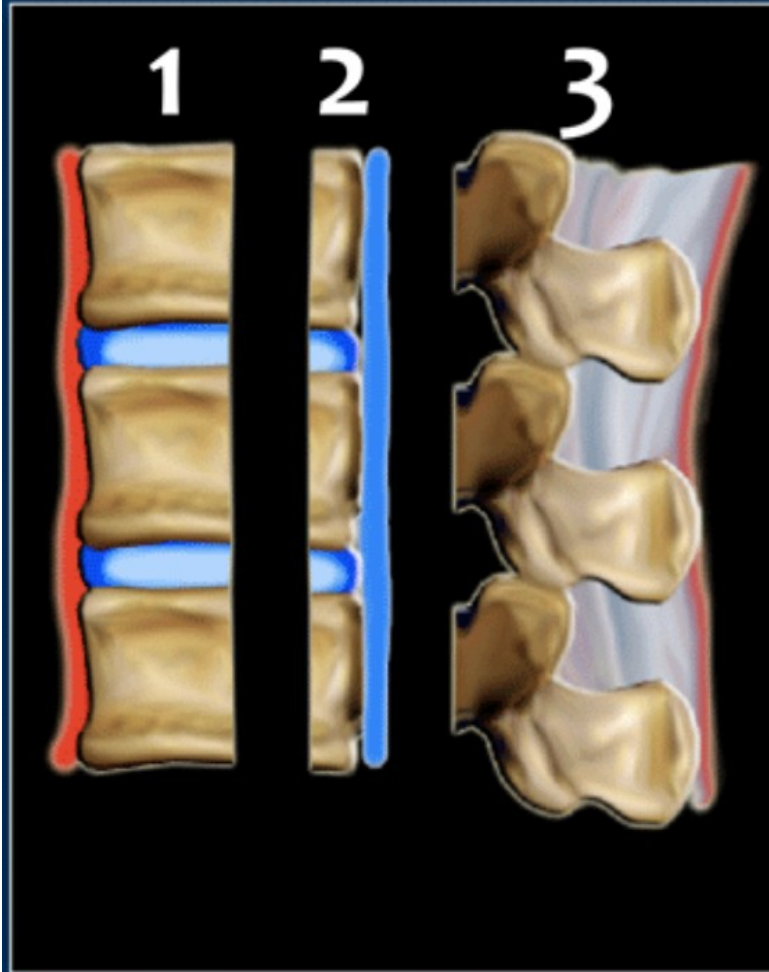
III. SPINE TRAUMA CLASSIFICATION

2 column theory (Holdsworth) vs. ~~3 column theory (Denis)~~



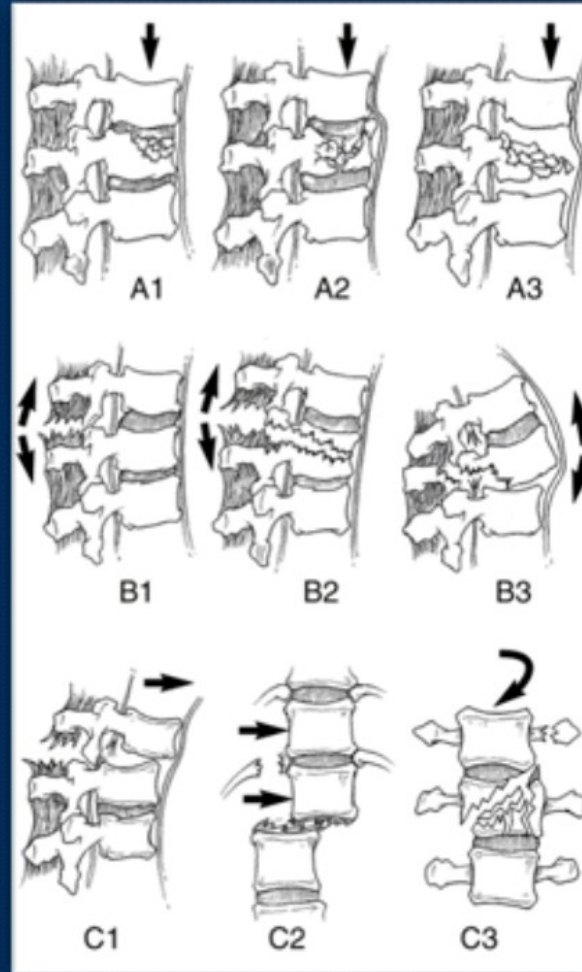
Denis

3-column classification



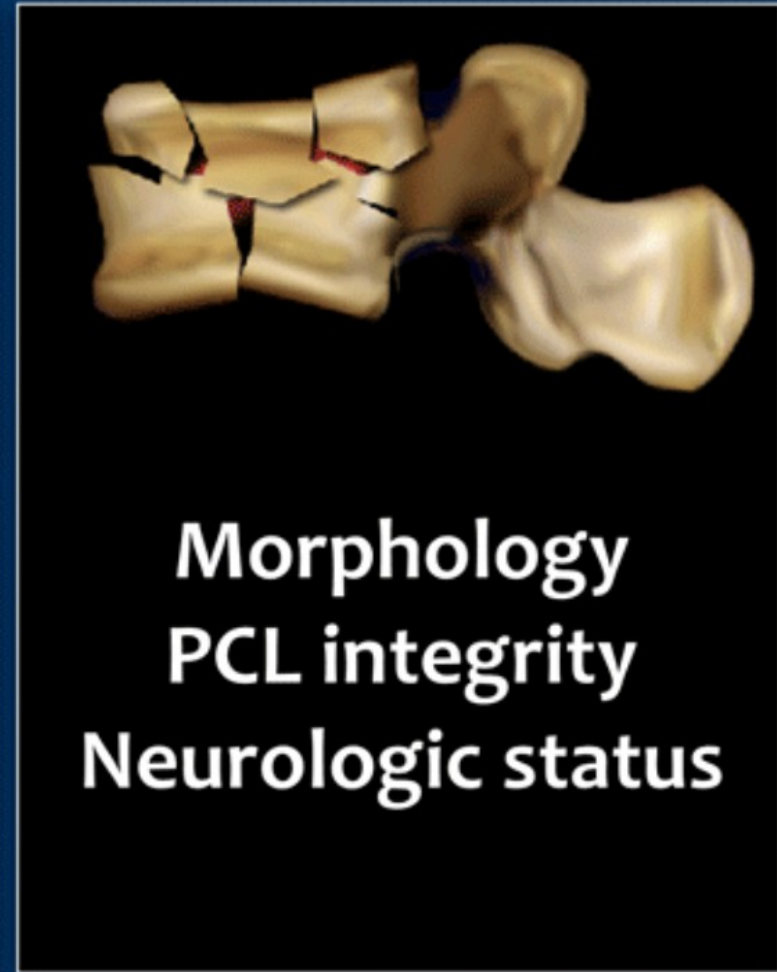
AO

classification



TLICS

classification



AO classification (Magerl 1994)

AO Surgery Reference Authors

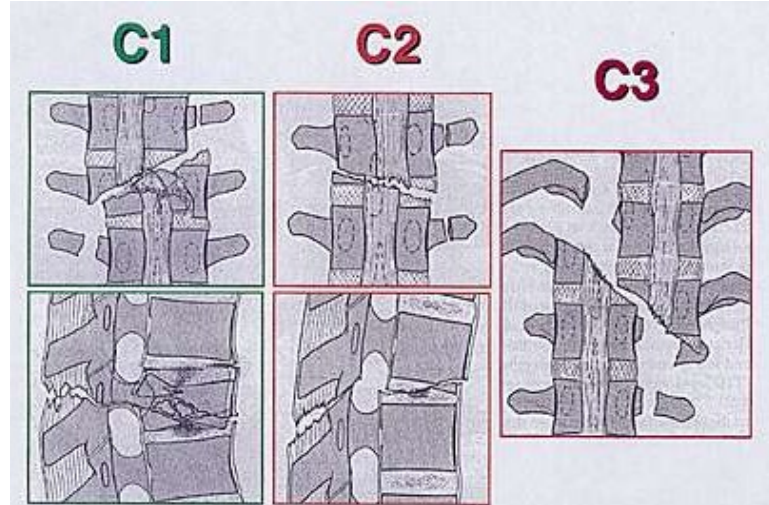
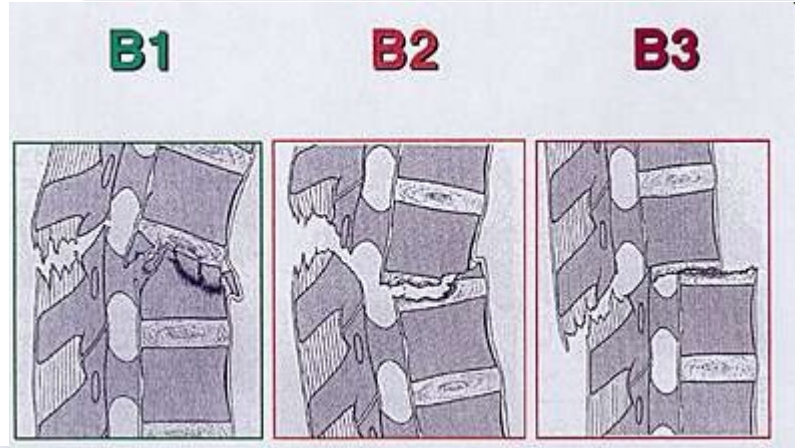
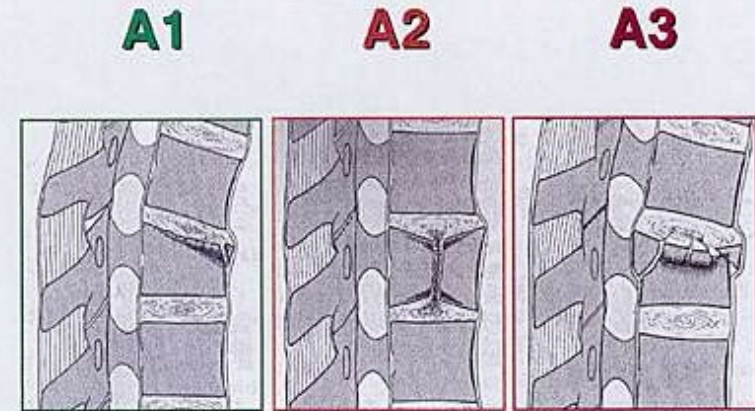
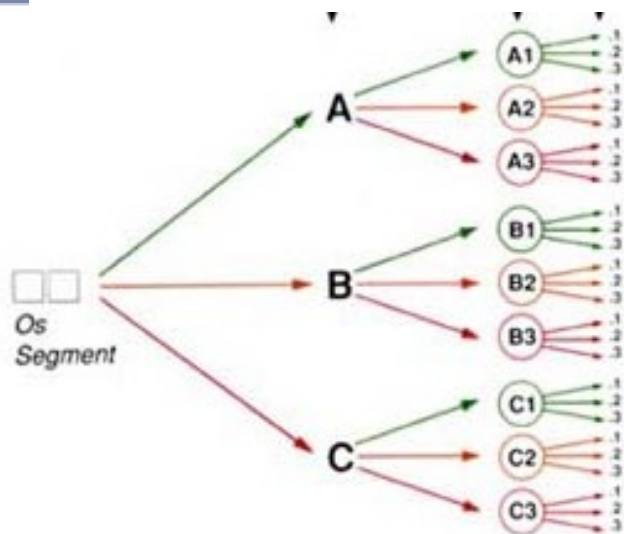
Please select an anatomical area

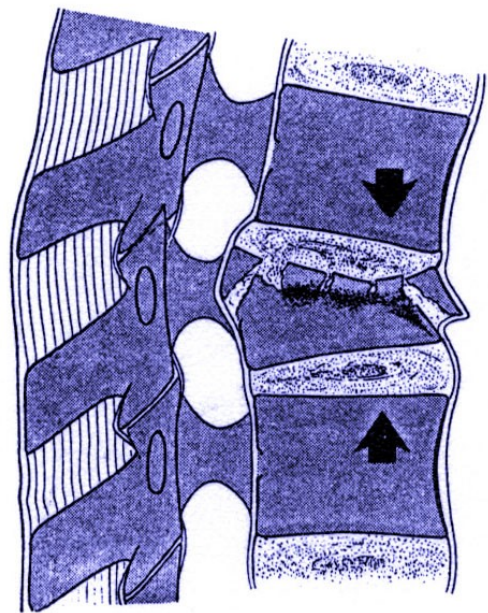


CMF

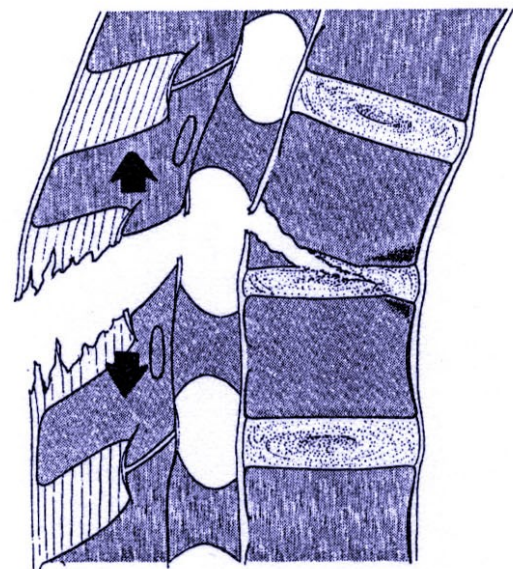
Clavicle	Proximal humerus
Scapula	Humeral shaft
Spine	Distal humerus
	Proximal forearm
Pelvic ring	Forearm shaft
Acetabulum	Distal forearm
Proximal femur	Hand
Femoral shaft	
Distal femur	
Patella	
Proximal tibia	
Tibial shaft	
Distal tibia	
Malleoli	
Foot	

Pediatric

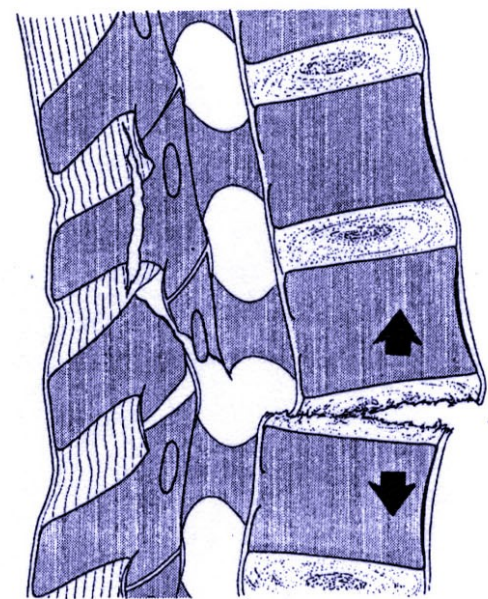




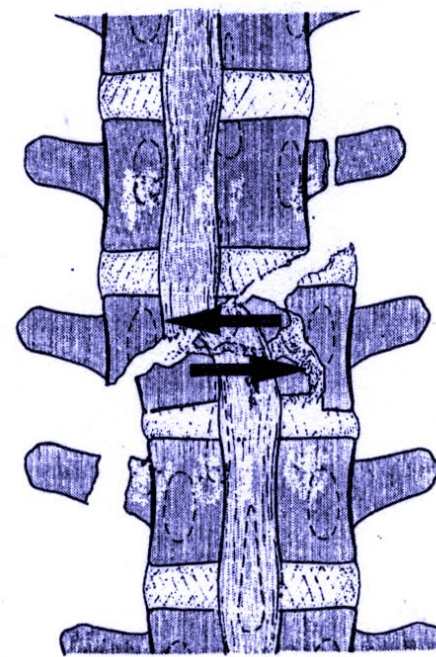
A
COMPRESSION



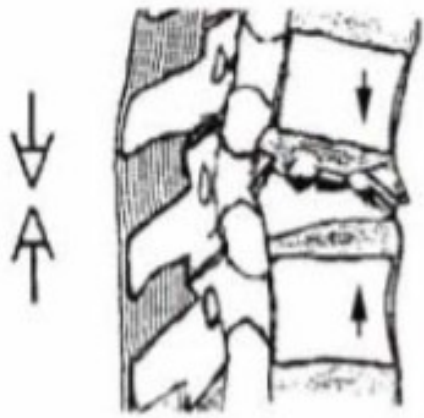
B
FLECTION+
DISTRACTION



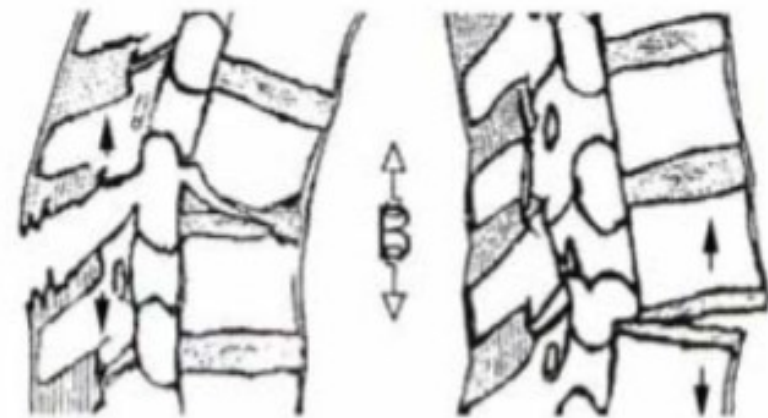
C
EXTENSION



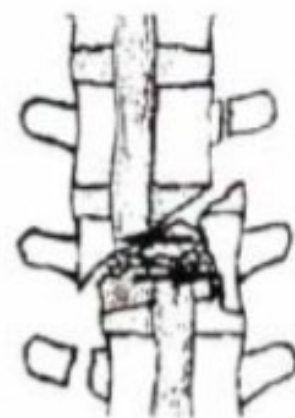
D
ROTATION/
TRANSLATION



A



B



C

Vertebral body injury
with compression

Anterior and posterior elements injury
with distraction ----- *with rotation*



impaction
fx

split fx

burst fx

posterior injury

anterior
injury

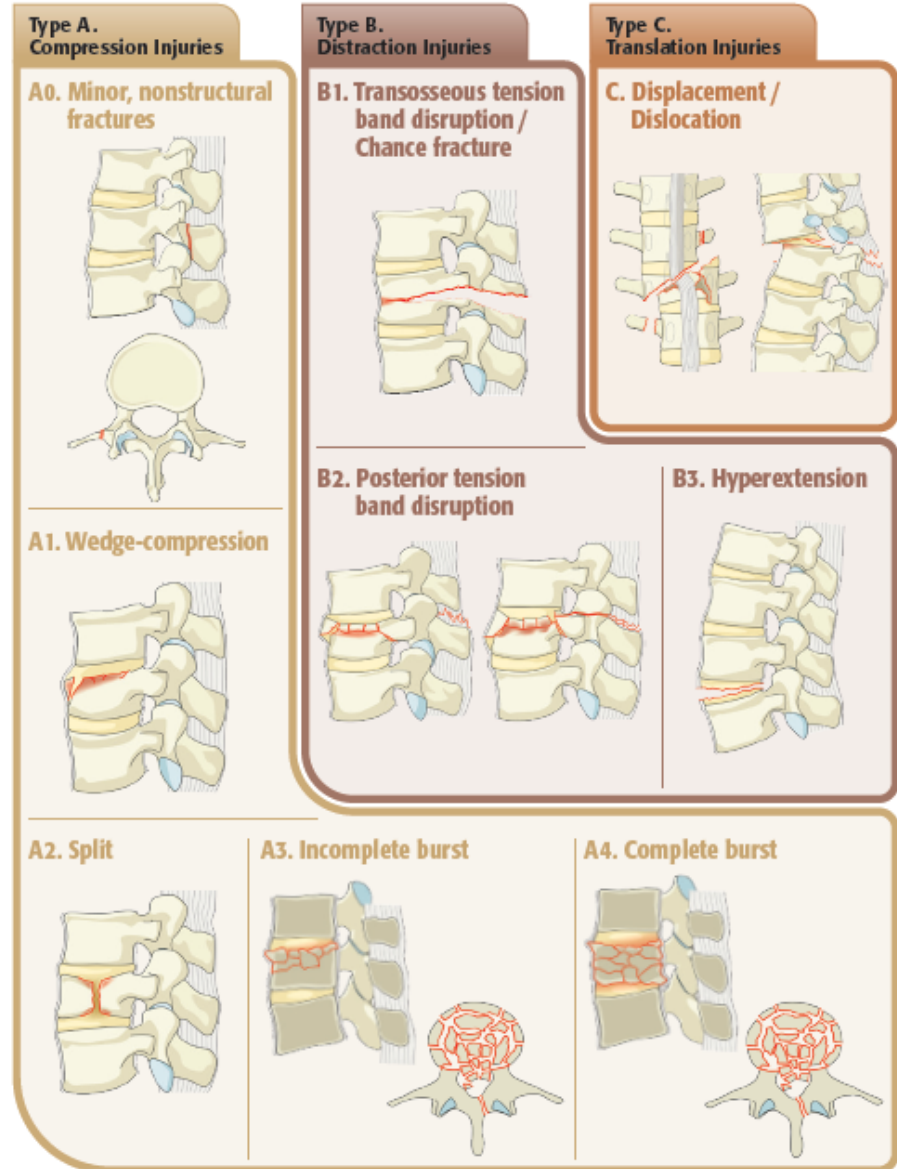
rotational
shear



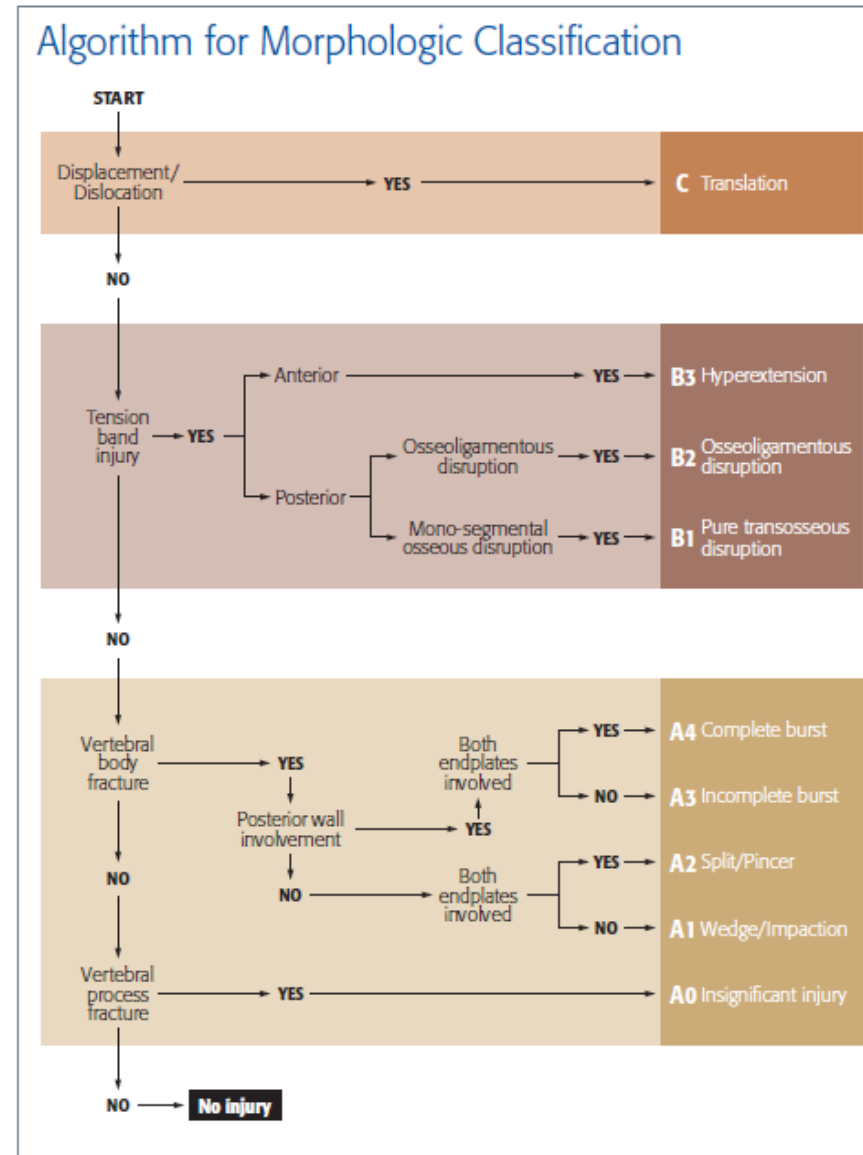
↓ predominantly ↓
ligamentous  s
through the disc

Type A Type B

AOSpine Thoracolumbar Classification System



AOSpine Thoracolumbar Classification System




AOSpine Upper Cervical Classification System


AOSpine Subaxial Classification System

I. Occipital Condyle and Craniocervical junction


Type A. Isolated bony injury (condyle)



Type B. Non-displaced ligamentous injury (craniocervical)

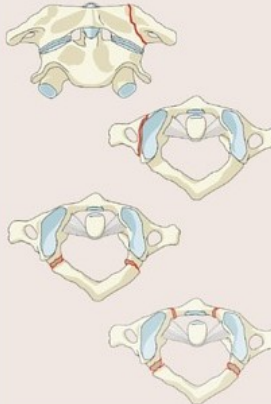


Type C. Any injury with displacement on spinal imaging

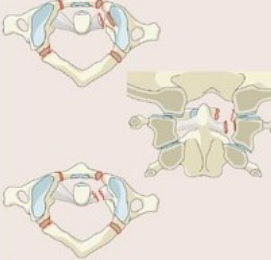


II. C1 Ring and C1-2 Joint

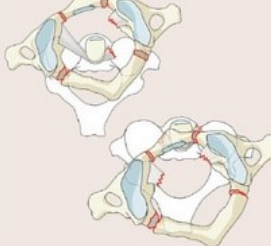
Type A. Isolated bony only (arch)



Type B. Ligamentous injury (transverse atlantal ligament)

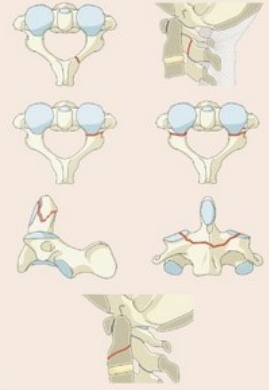


Type C. Atlantoaxial instability / Translation in any plane

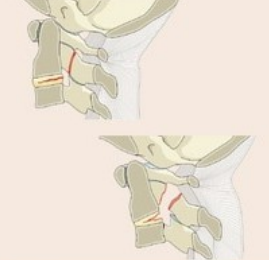


III. C2 and C2-3 Joint


Type A. Bony injury only without ligamentous, tension band, discal injury



Type B. Tension band / Ligamentous injury with or without bony injury



Type C. Any injury that leads to vertebral body translation in any directional plane



Type A. Compression Injuries

A0. Minor, nonstructural fractures



A1. Wedge-compression



A2. Split



A3. Incomplete burst

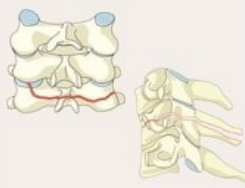


A4. Complete burst

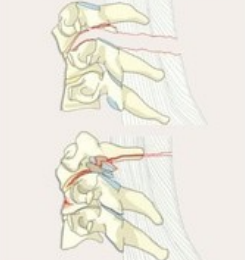


Type B. Distraction Injuries


B1. Posterior tension band injury (bony)



B2. Posterior tension band injury (bony capsulo-ligamentous, ligamentous)



B3. Anterior tension band injury



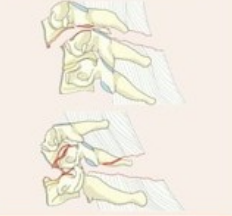
BL. Bilateral Injuries

BL. Bilateral injury




Type C. Translation Injuries

C. Translational injury in any axis-displacement or translation of one vertebral body relative to another in any direction




Type F. Facet Injuries


F1. Nondisplaced facet fracture




F2. Facet fracture with potential for instability



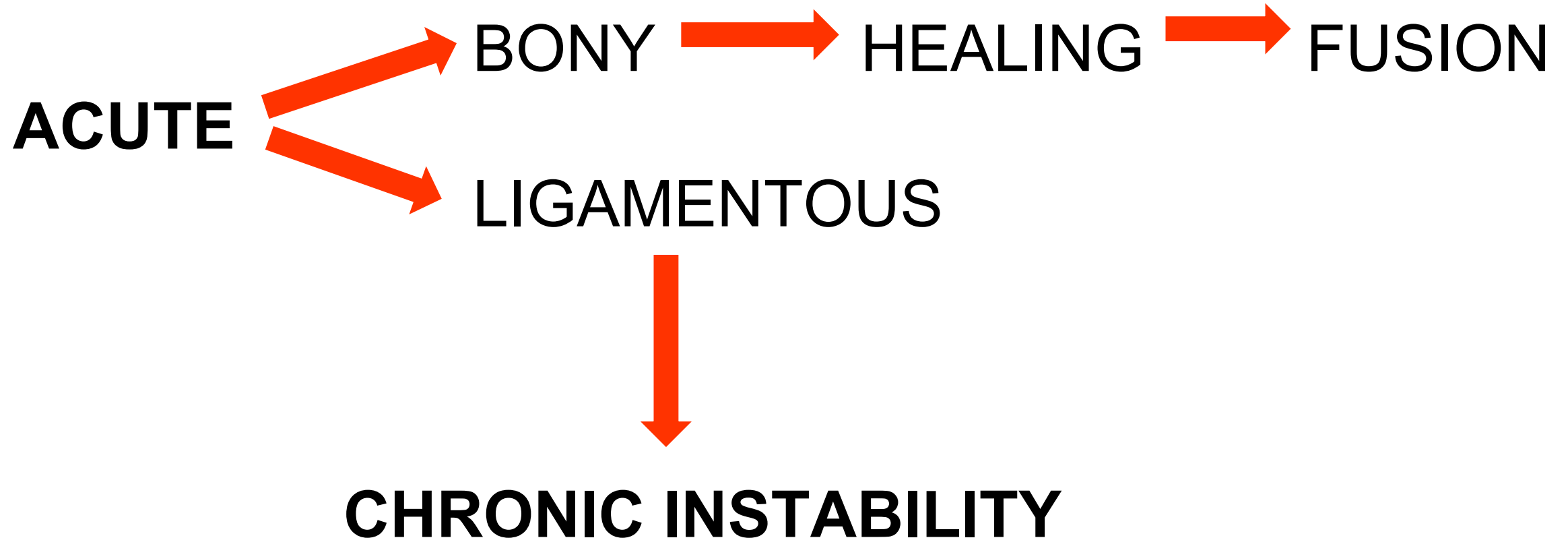
F3. Floating lateral mass



F4. Pathologic subluxation or perched/dislocated facet

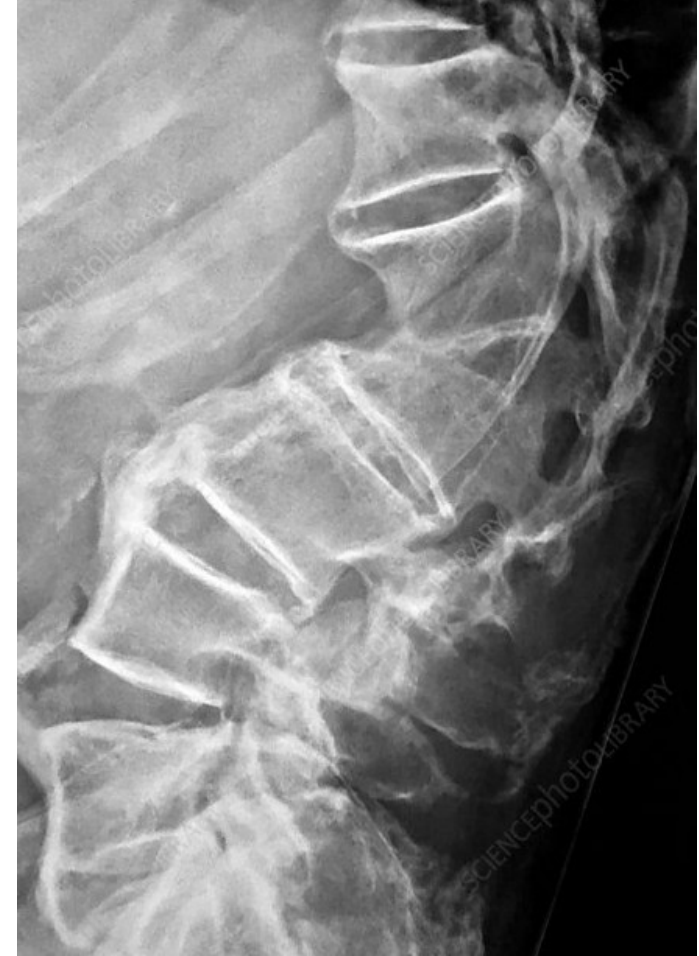

Spine INSTABILITY



LIGAMENTOUS INSTABILITY

- conservative treatment cannot lead to healing
- result is chronic progressive instability
- pseudoarthrosis or kyphotic deformity may occur
- can only be repaired by **fusion of affected segment**



IV. Spinal Cord Injuries (SCI)

Spinal cord impairment causing temporary or permanent changes in motor, sensory, or autonomous spinal cord functions.

- 1) type : **A) primary** **B) secondary**
- 2) degree: **A) complete** **B) incomplete**

1A) Primary SCI

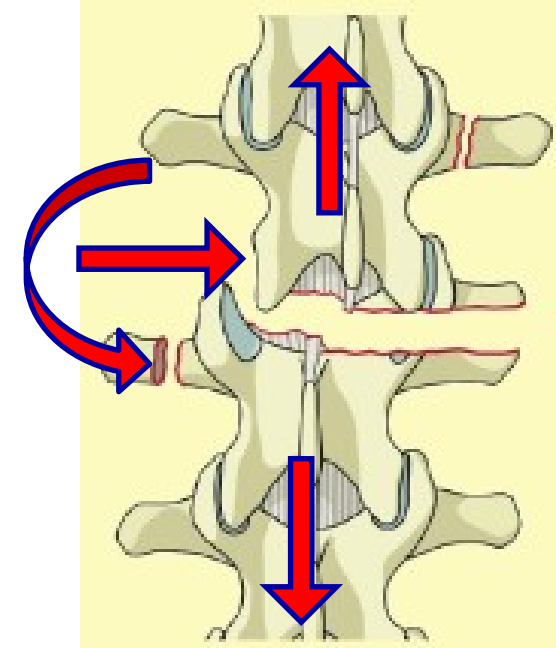
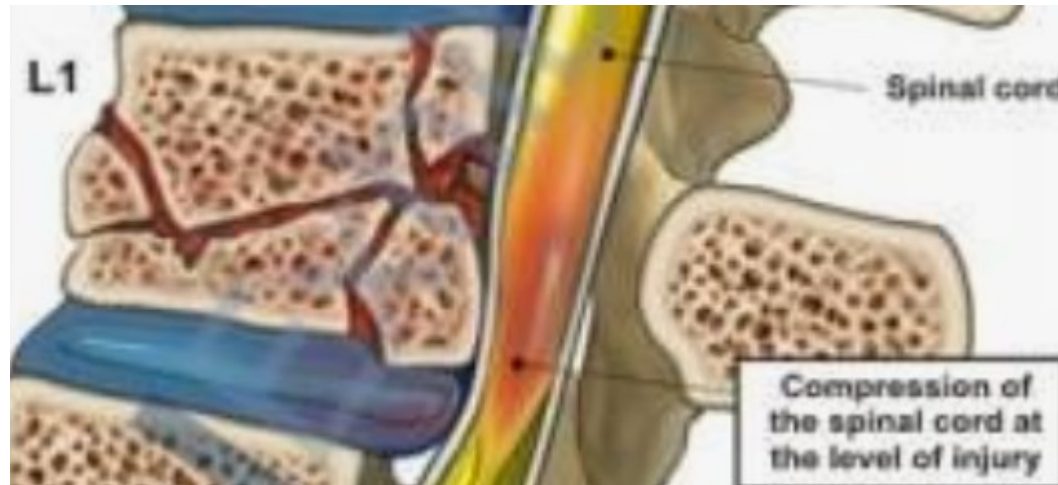


Spinal cord compression by bone fragments, hematoma, herniated intervertebral disc.

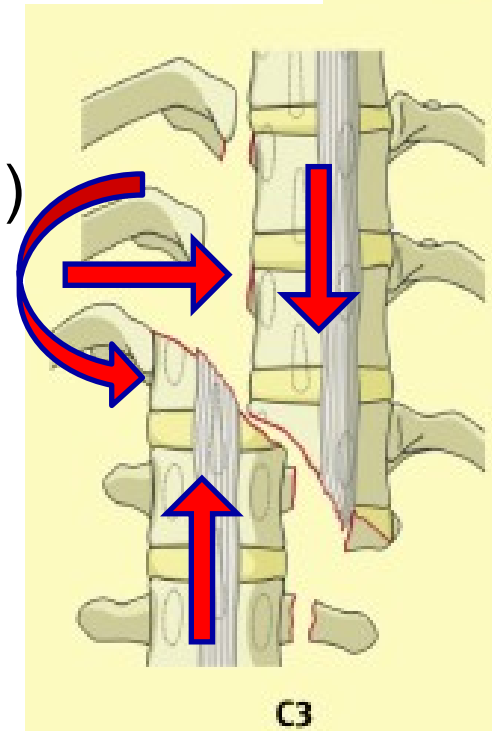
Torsion, distraction, (shear forces = unfavorable prognosis)

Ischemia

Penetrating injury

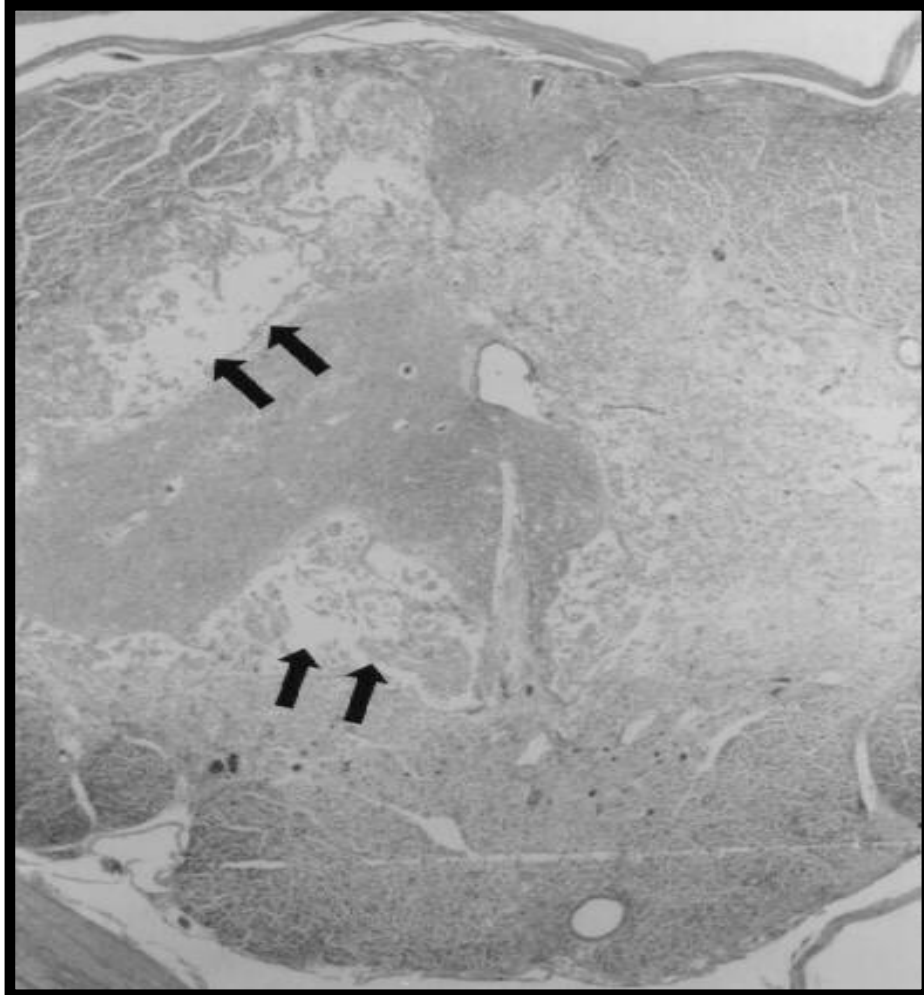


C2



C3

1B) Secondary SCI



- Vascular changes :
 - reduced flow
 - thrombosis
 - vasospasm
 - hemorrhagia
- electrolyte changes
- free O₂ radicals
- Inflammatory reaction

=> the result is neuronal necrosis !!

1B) Secondary SCI

Possibilities of its influence :

- oxygenation, optimal BP
- pharmacotherapy (anti-oedematous treatment -corticoids ?)
- **surgical treatment** (decompression of neural structures + instrumentation of the spine for its stabilization)



2) Degrees of SCI

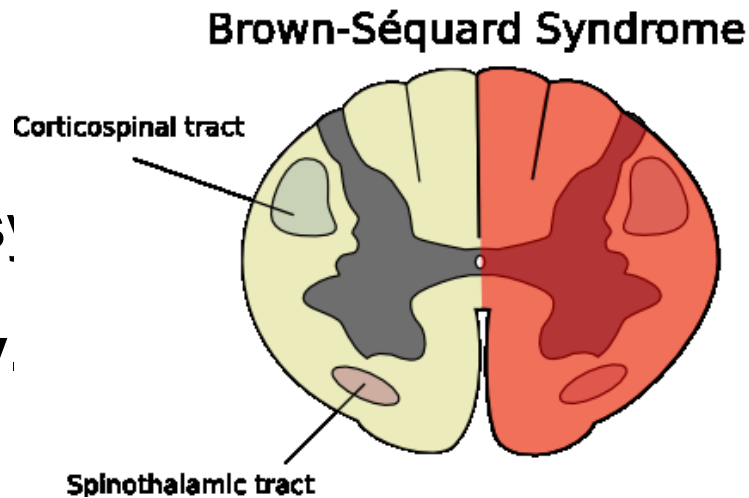
complete lesion /according to the height of the injury/

cervical quadriplegia
thoracic paraplegia

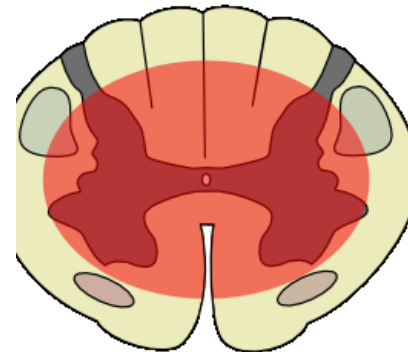incomplete lesion /specific syndromes

anterior cord sy.
central cord sy.
posterior cord sy.
Brown-Sequard sy.

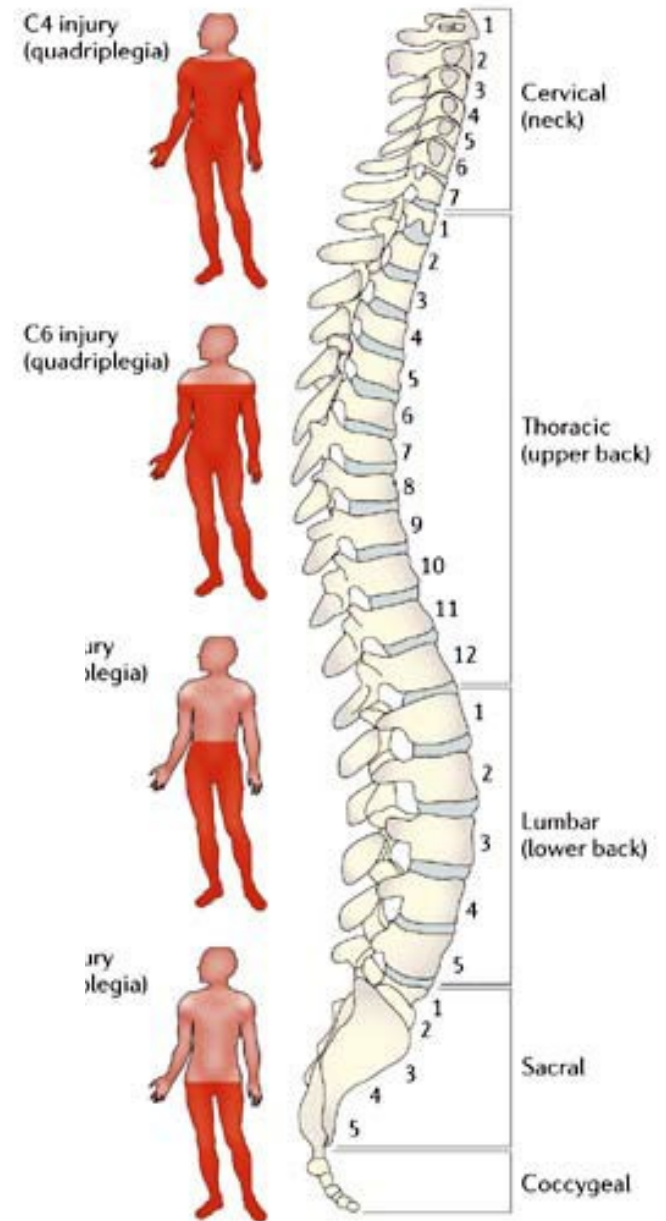
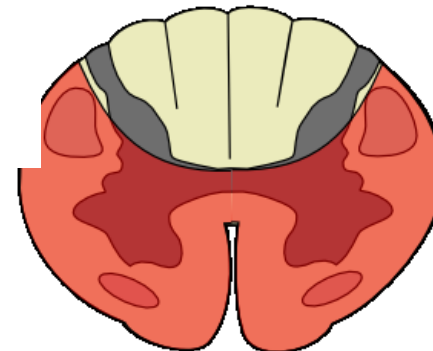
cauda equina sy.



Central Cord Syndrome



Anterior Cord Syndrome



SPINENE

Saddle Anaesthesia

Loss of feelings around the buttocks, anus and genitals?

Pain

Severe nerve pain in back and/or down one or both legs?

Incontinence

Bladder incontinence or inability/difficulty urinating and/or bowel incontinence/constipation

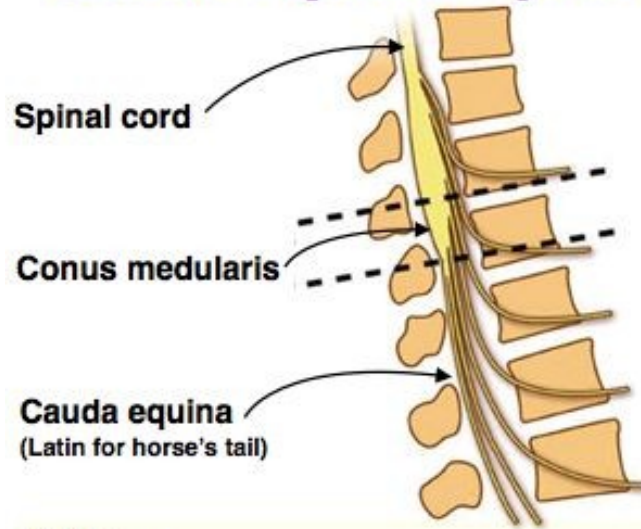
Numbness

Lack of sensation and/or weakness in the legs

Emergency

Any of the above symptom could be a sign of Cauda Equina Syndrome – please contact your GP or A & E department immediately – without urgent treatment the damage can become permanent.

Cauda Equina Syndrome



Etiology

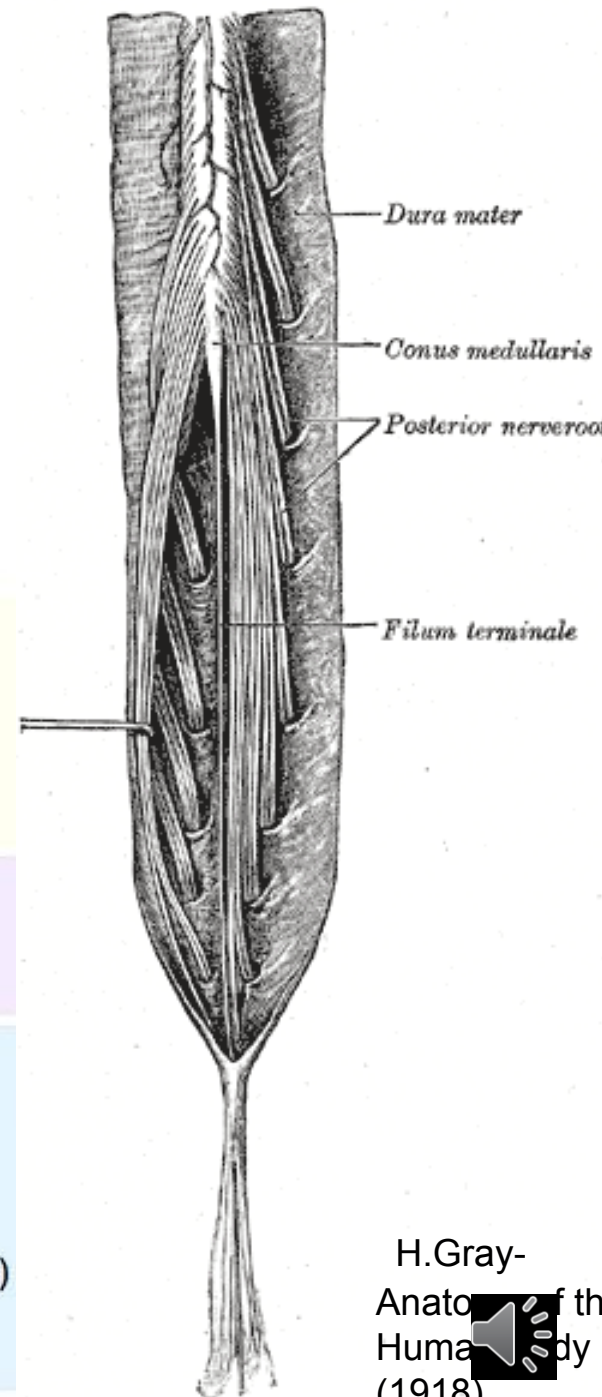
- Compression of cauda equina by:
- Herniated disk
- Tumor
- Abscess

Diagnosis

- Clinical suspicion
- MRI or CT myelogram

Clinical

- **Urinary retention** (most sensitive) followed by incontinence
- Post-void residual urine vol > 100 mL
- Bowel retention
- Saddle anesthesia
- Flaccidity of lower extremities (lower motor neuron symptoms)
- Loss of deep tendon reflexes (DTRs)
- Loss of rectal tone



Evaluation of spinal cord injury

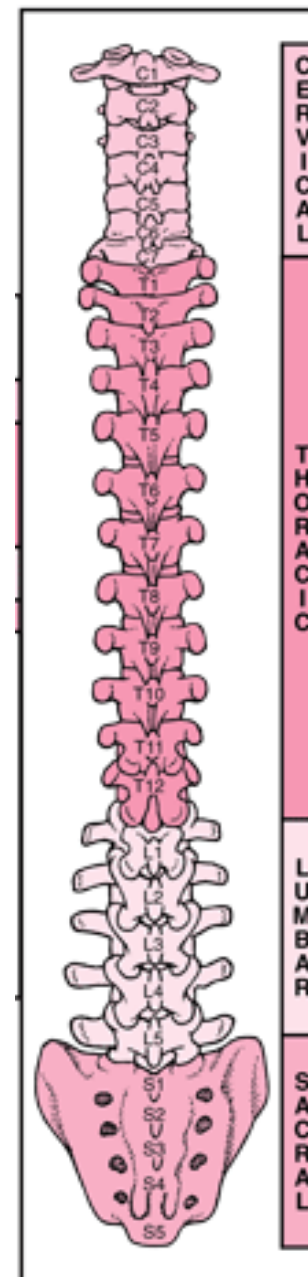
3 functions:

- motoric
- sensoric
- spinal reflexes

The purpose of the evaluation is to **determine the height and type of lesion.**

Nerve root	Test
C5	Elbow flexion
C6	Wrist extension
C7	Wrist flexion, finger extension
C8	Finger flexion
T1	Finger abduction
L1,2	Hip abduction
L3,4	Knee extension
L5,S1	Knee flexion
L5	Great toe extension
S1	Great toe flexion

Effects of Spinal Injury



Level of Injury	Effect*
CERVICAL Between C1 and C5	Paralysis of some or all muscles used for breathing and all arm and leg muscles Typically, fatal unless a ventilator is used
Between C5 and C6	Paralysis of the legs, trunk, hand, and wrist Weakness of the muscles that move the shoulder and elbow
Between C6 and C7	Paralysis of the legs, trunk, and part of the wrists and hands Normal movement of the shoulders and elbows
Between C7 and C8	Paralysis of the legs, trunk, and hands
THORACIC C8 to T1	Paralysis of the legs and trunk Weakness of the muscles that move fingers and hands Horner's syndrome (with a drooping eyelid, a constricted pupil, and reduced sweating on one side of the face) Possibly normal movement of the shoulders and elbows
T2 to T4	Paralysis of the legs and trunk Loss of sensation below the nipples Normal movement of the shoulders and elbows
T5 to T8	Paralysis of the legs and lower trunk Loss of sensation below the rib cage
LUMBAR T9 to T11	Paralysis of the legs Loss of sensation below the navel
T11 to L1	Paralysis of and loss of sensation in the hips and legs
SACRAL L2 to S2	Various patterns of leg weakness and numbness, depending on the precise level of injury
S3 to S5	Numbness in the perineum

* At any level of the spinal cord, severe injury cause loss of bladder and bowel control.



Evaluation of spinal cord injury

Classification of Neurological Function

Frankel Classification Grading System

	Sensory	Motor
A	Absent	Absent
B	Present	Absent
C	Present	Active but not useful (grade 2-3)
D	Present	Active and useful (grade 4)
E	Normal	Normal

Patient Name _____

Examiner Name _____ Date/Time of Exam _____



STANDARD NEUROLOGICAL CLASSIFICATION OF SPINAL CORD INJURY



MOTOR

KEY MUSCLES
(scoring on reverse side)

	R	L	
C5	<input type="checkbox"/>	<input type="checkbox"/>	Elbow flexors
C6	<input type="checkbox"/>	<input type="checkbox"/>	Wrist extensors
C7	<input type="checkbox"/>	<input type="checkbox"/>	Elbow extensors
C8	<input type="checkbox"/>	<input type="checkbox"/>	Finger flexors (distal phalanx of middle finger)
T1	<input type="checkbox"/>	<input type="checkbox"/>	Finger abductors (little finger)

UPPER LIMB TOTAL (MAXIMUM) + =
(25) (25) (50)

Comments:

L2	<input type="checkbox"/>	<input type="checkbox"/>	Hip flexors
L3	<input type="checkbox"/>	<input type="checkbox"/>	Knee extensors
L4	<input type="checkbox"/>	<input type="checkbox"/>	Ankle dorsiflexors
L5	<input type="checkbox"/>	<input type="checkbox"/>	Long toe extensors
S1	<input type="checkbox"/>	<input type="checkbox"/>	Ankle plantar flexors

Voluntary anal contraction (Yes/No)

LOWER LIMB TOTAL (MAXIMUM) + =
(25) (25) (50)

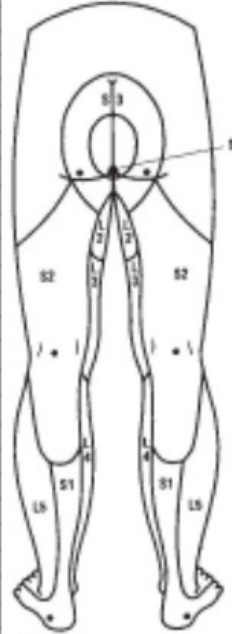
	LIGHT TOUCH		PIN PRICK	
	R	L	R	L
C2				
C3				
C4				
C5				
C6				
C7				
C8				
T1				
T2				
T3				
T4				
T5				
T6				
T7				
T8				
T9				
T10				
T11				
T12				
L1				
L2				
L3				
L4				
L5				
S1				
S2				
S3				
S4-5				

TOTALS { + = } (MAXIMUM) (50) (50) (50) (50)

PIN PRICK SCORE (max: 112)

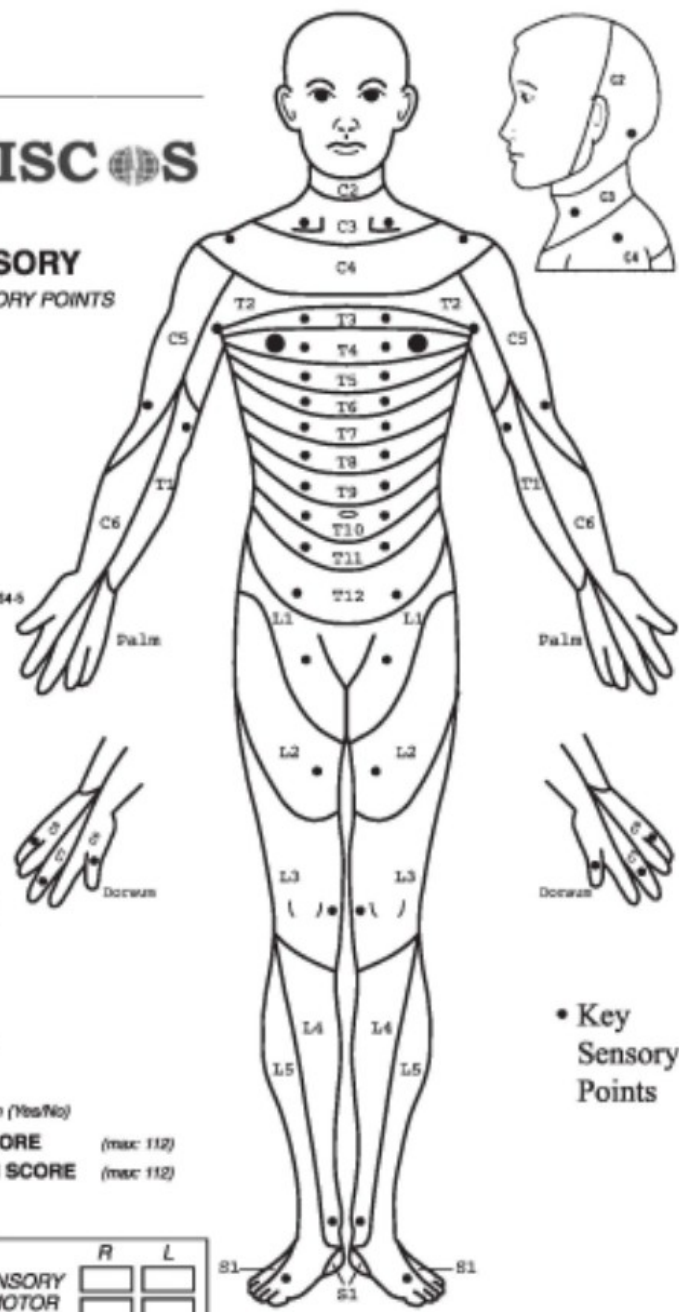
LIGHT TOUCH SCORE (max: 112)

0 = absent
1 = impaired
2 = normal
NT = not testable



SENSORY

KEY SENSORY POINTS



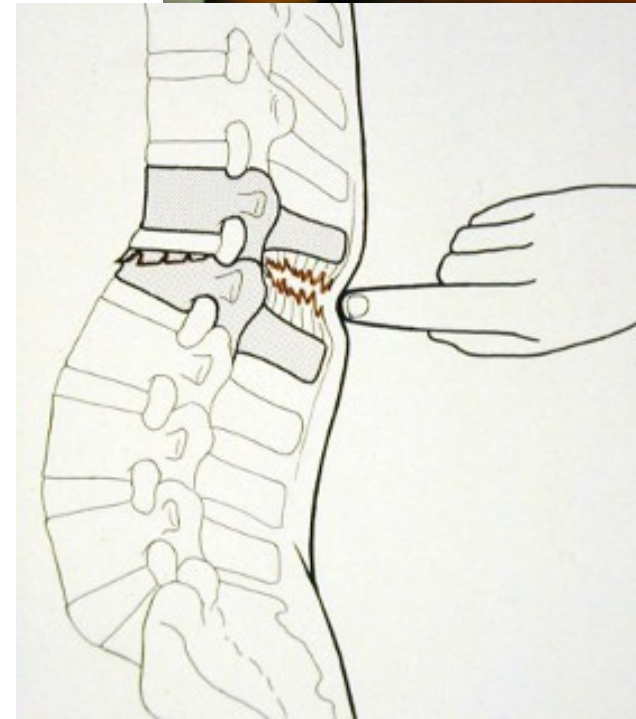
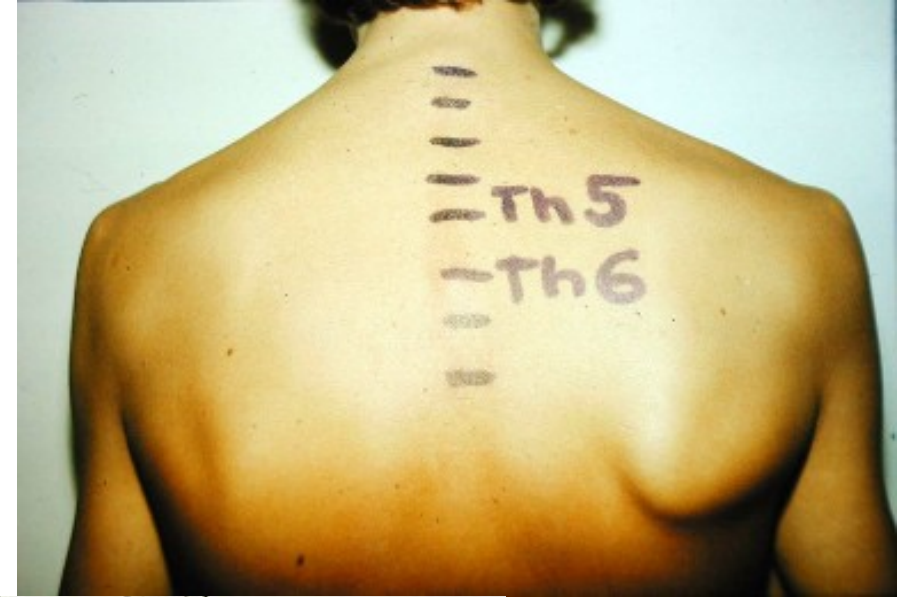• Key Sensory Points

NEUROLOGICAL LEVEL The most caudal segment with normal function	SENSORY	R	L	COMPLETE OR INCOMPLETE? Incomplete = Any sensory or motor function in S4-S5	ZONE OF PARTIAL PRESERVATION Caudal extent of partially innervated segments	SENSORY	R	L
	MOTOR	<input type="checkbox"/>	<input type="checkbox"/>			MOTOR	<input type="checkbox"/>	<input type="checkbox"/>
ASIA IMPAIRMENT SCALE								



CLINICAL EXAMINATION

- **Aspection** (defiguration, hematoma ...)
- **Palpation** (rate and spreading of pain)
- **Basic neurological assessment**
(Frankel scale, **ASIA score**)



EXAMINATION - imaging methods

Anamnesis

Clinical examination

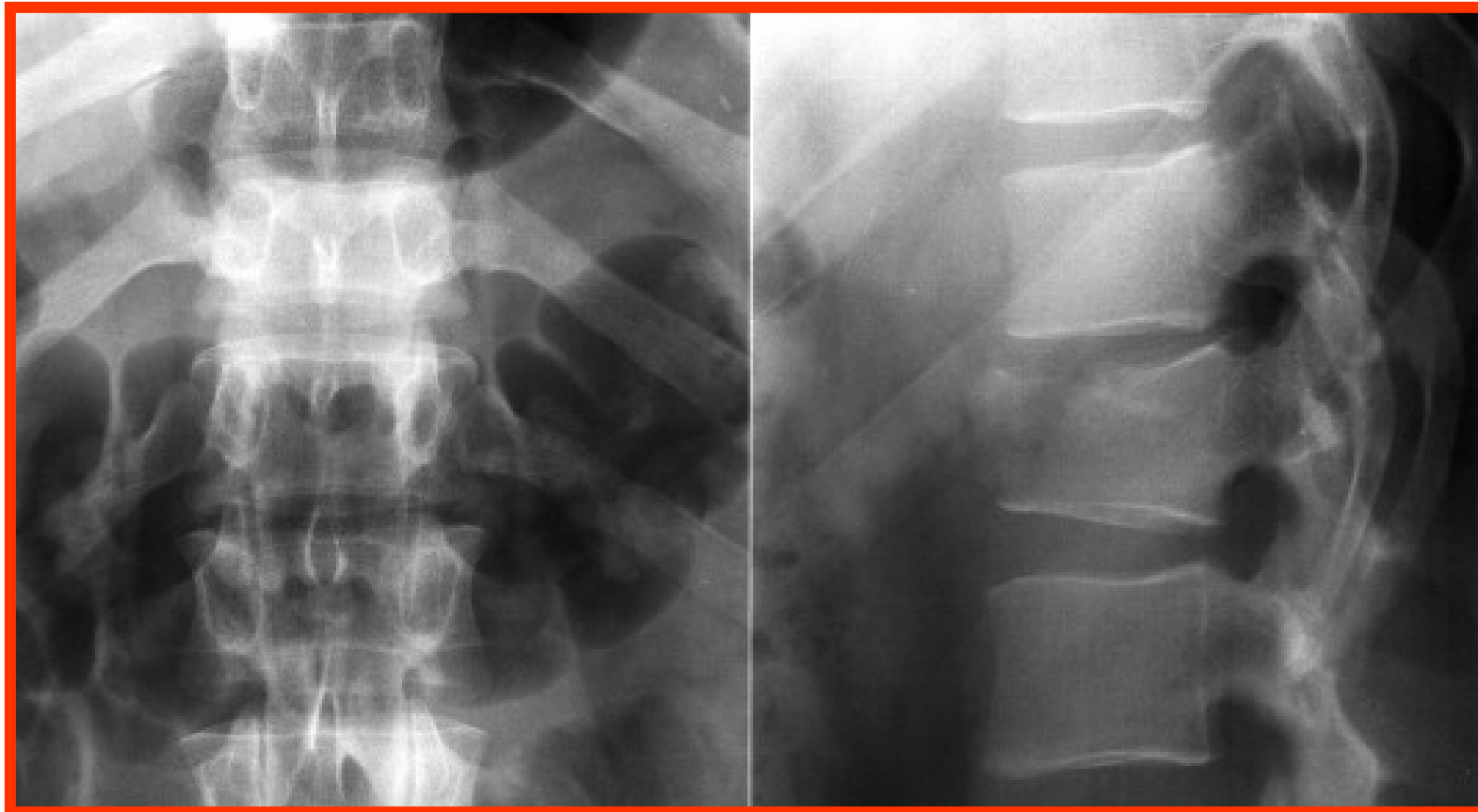
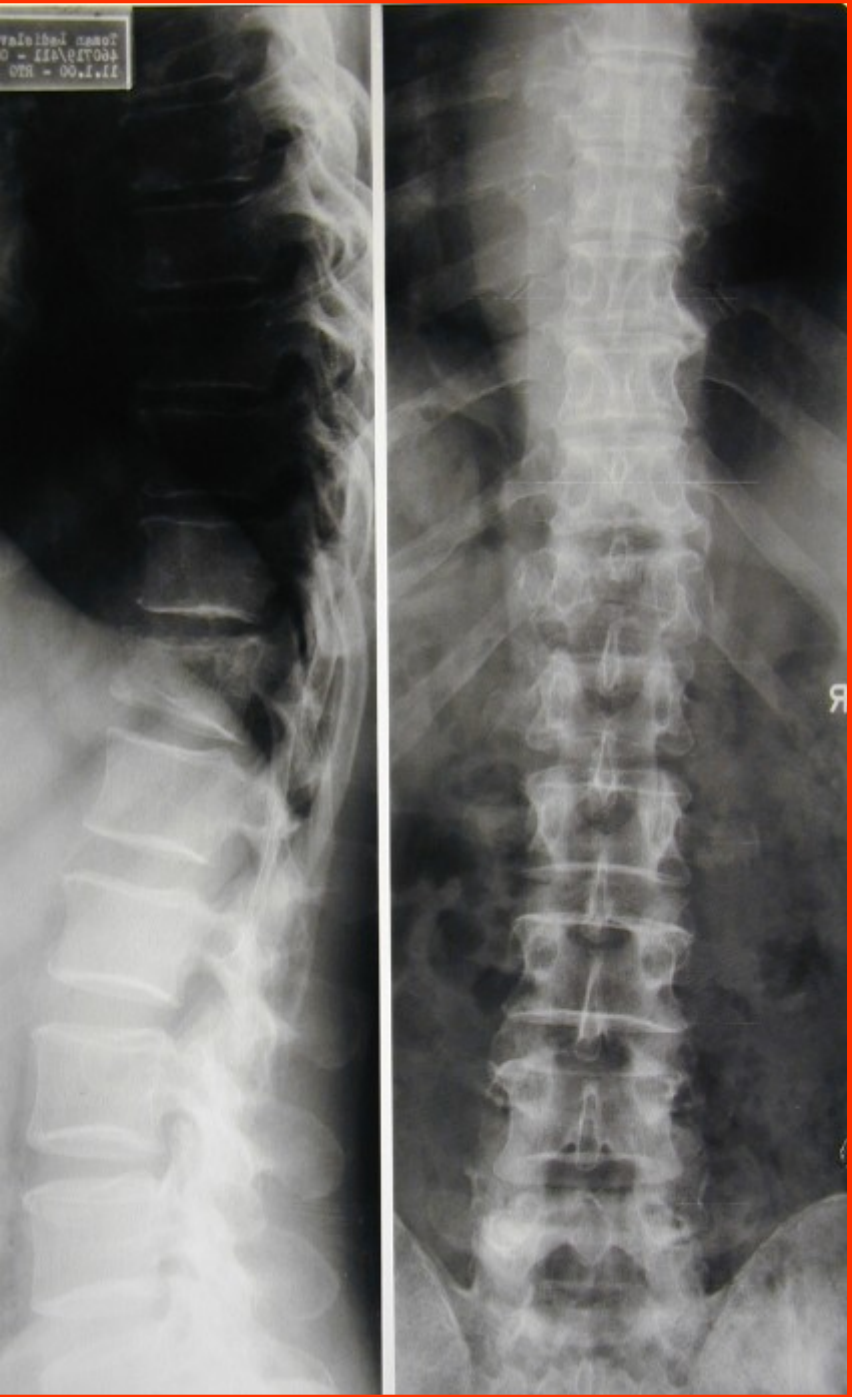
Neurological status

X-ray

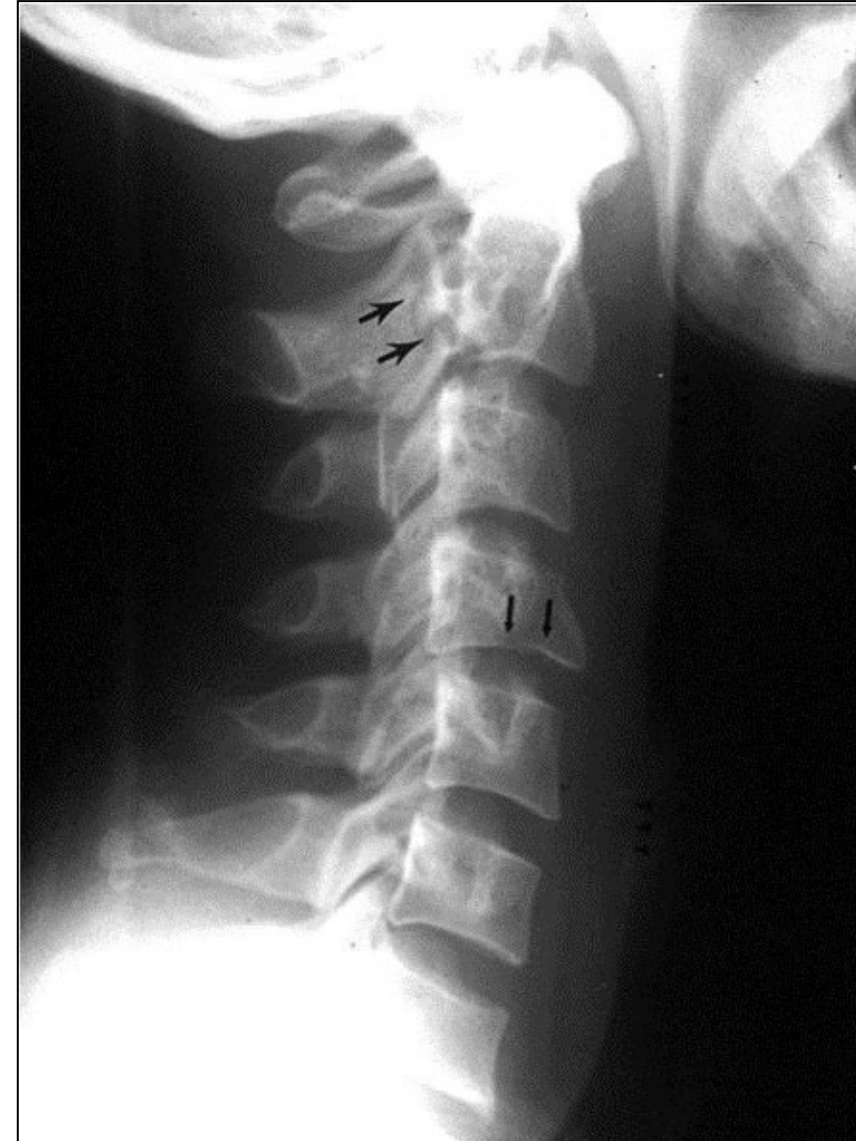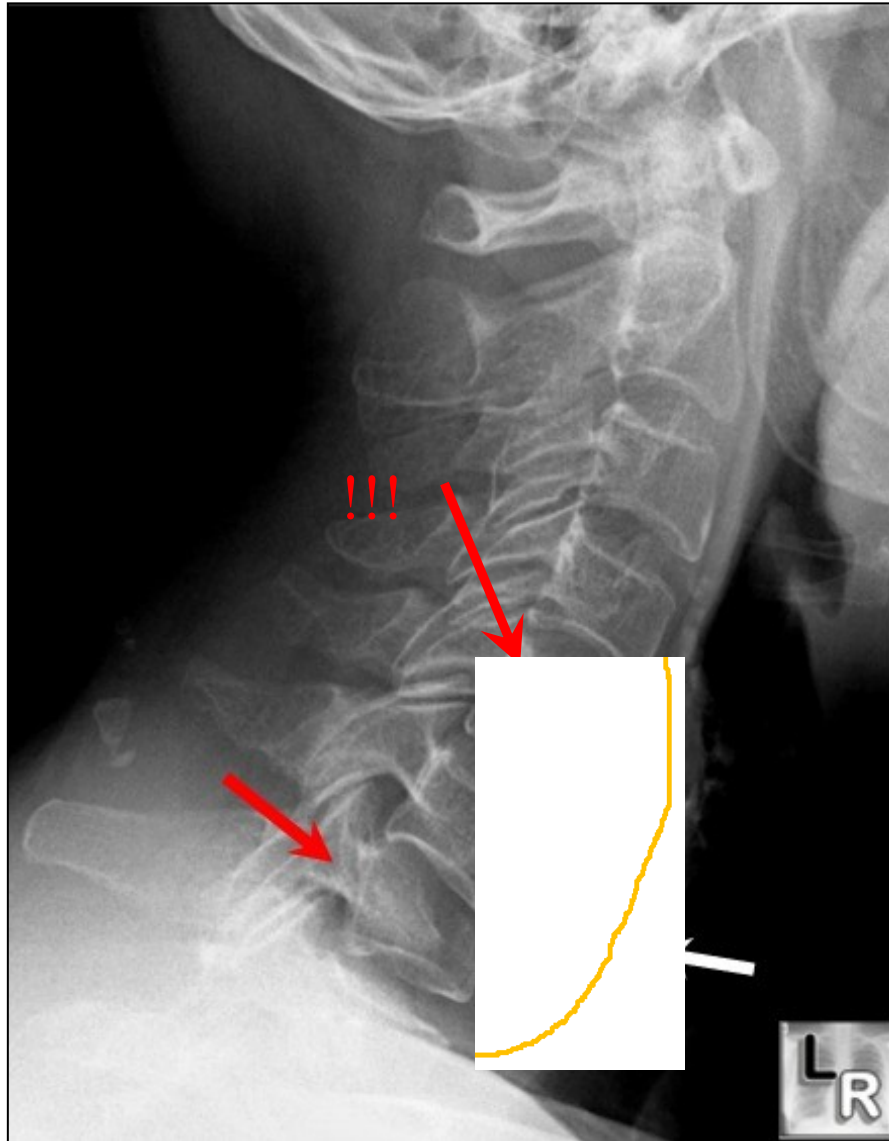
CT

MRI

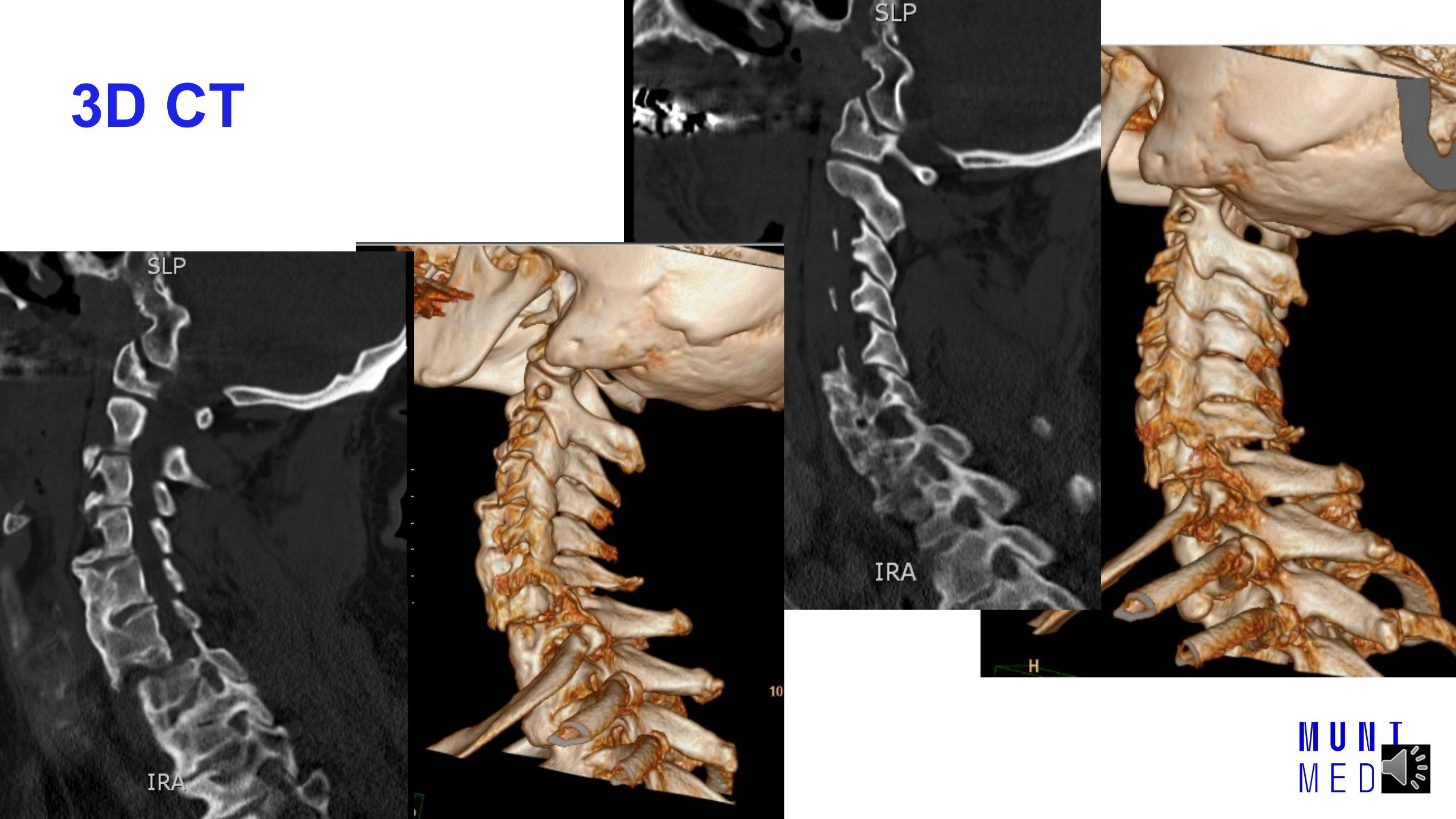X-ray



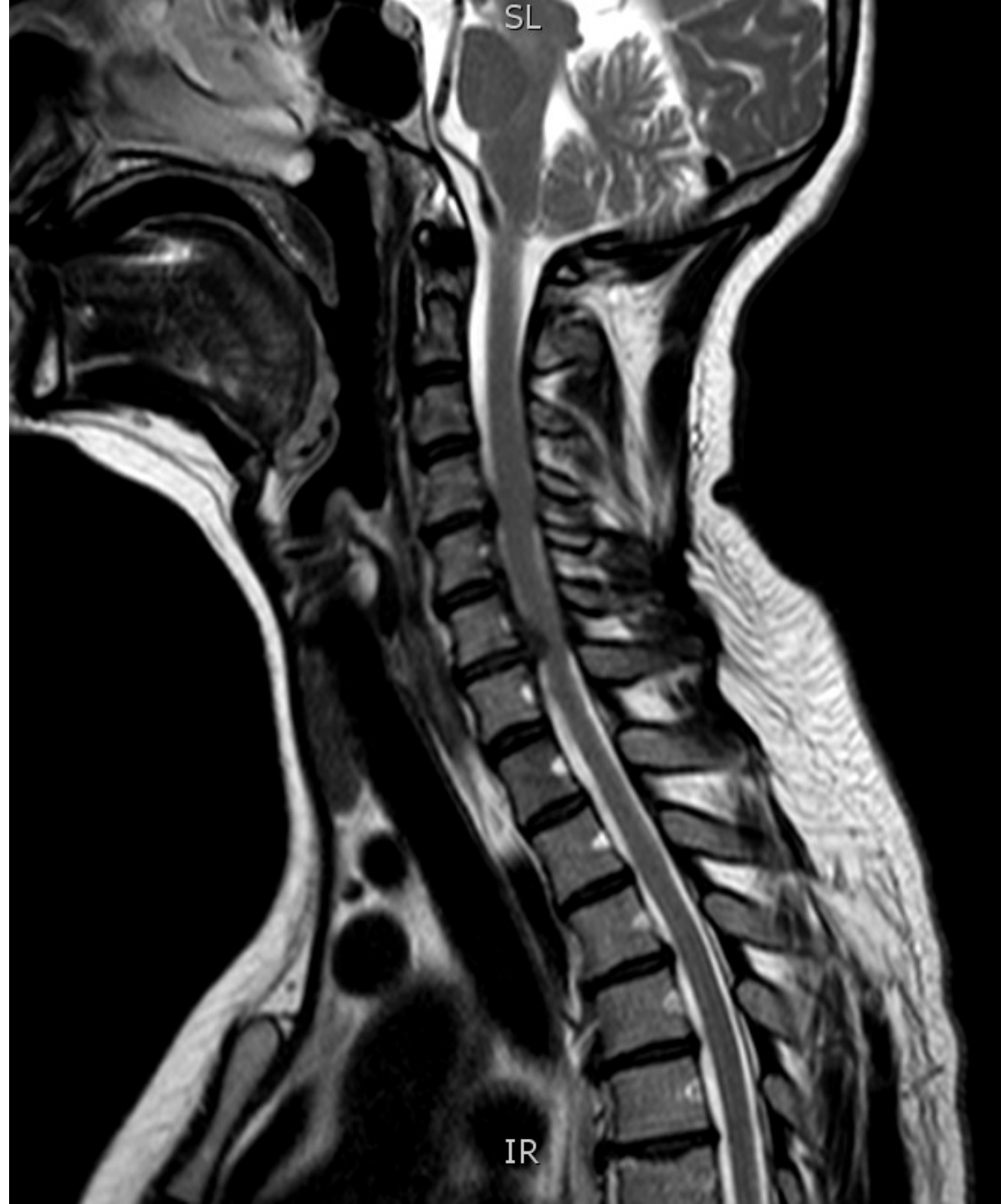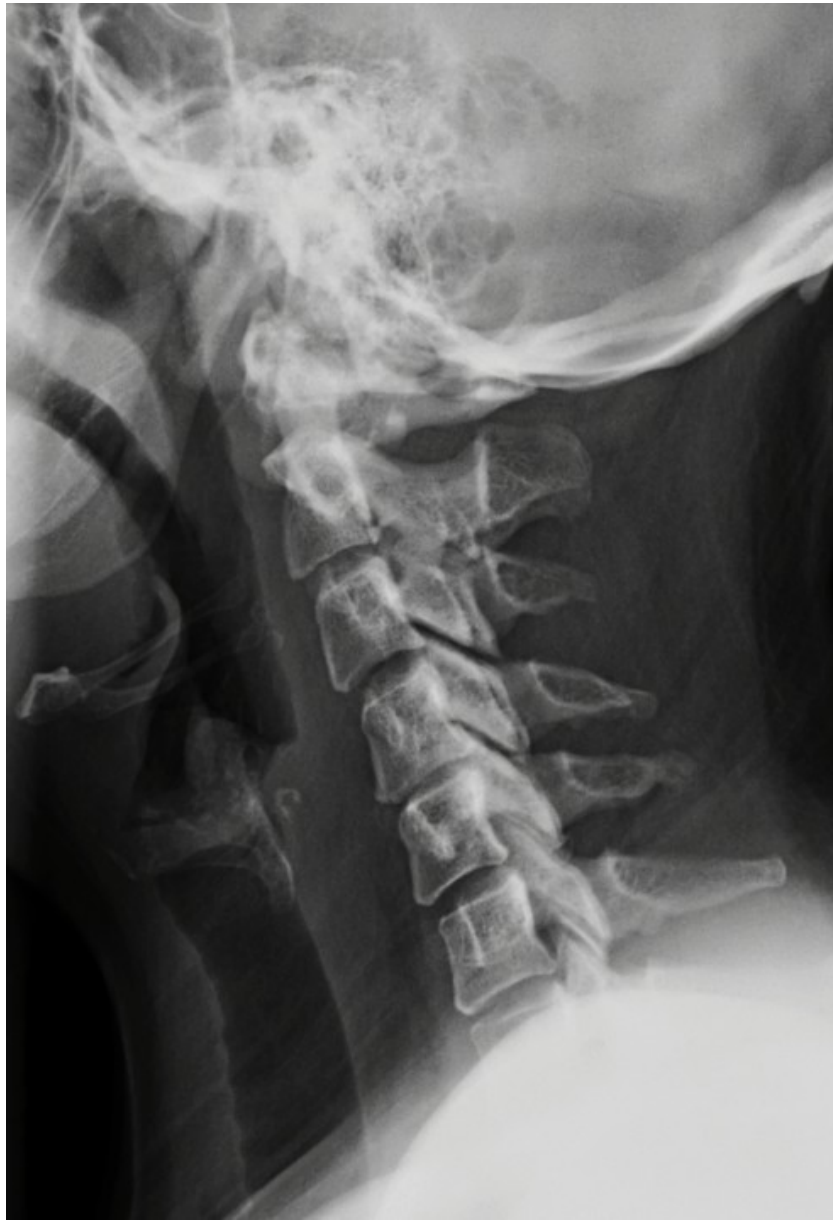Fracture of the body and preventrtebral **hematoma** !



3D CT



MRI



OBJECTIVES OF THERAPY

PAINLESSNESS

FUNCTIONALITY (movement)

STABILITY

V. THERAPY

A) conservative

orthoses, corsets

bed rest

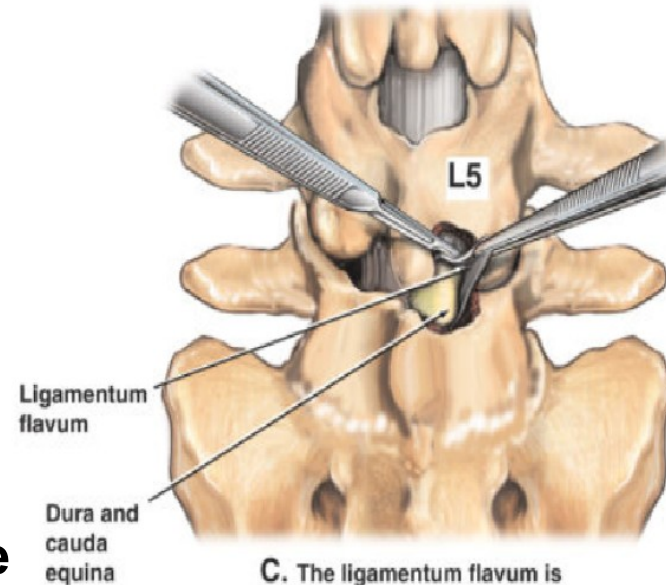
B) surgical

Decompression of spinal cord and nerve structures + **stabilization of the fracture** by specific instrumentation

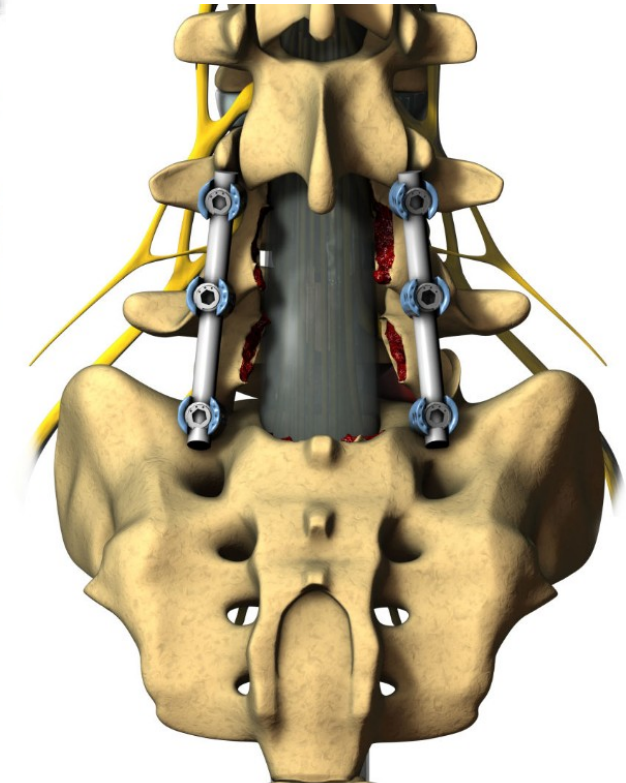
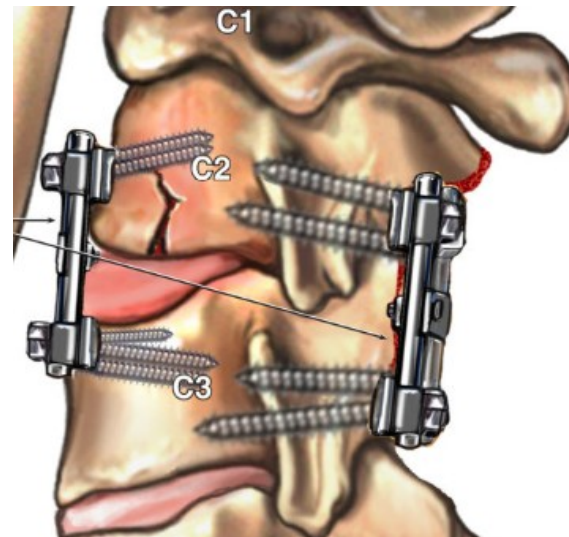
Dorsal procedure

Ventral procedure

Combined



C. The ligamentum flavum is removed exposing the neural elements.



Nucleus Medical Media (2020). *Posterior spinal fusion* [Digital image]. Retrieved from <https://ebSCO.smartimagebase.com/posterior-spinal-fusion/view-item?ItemID=68987>

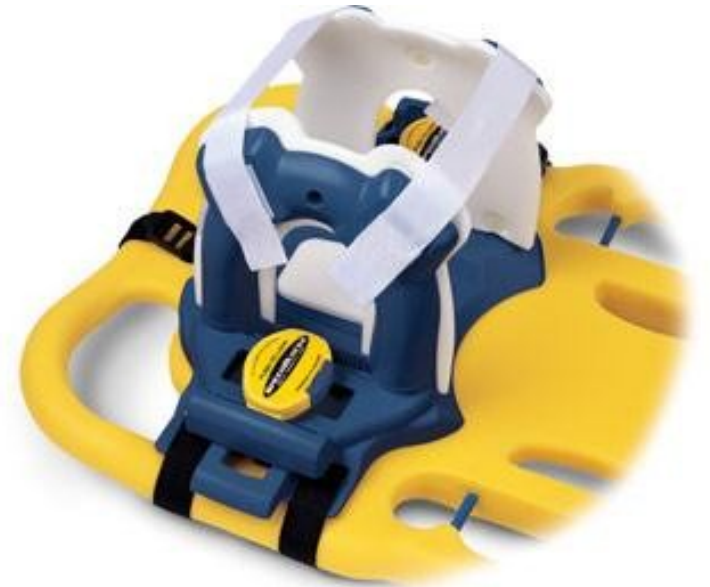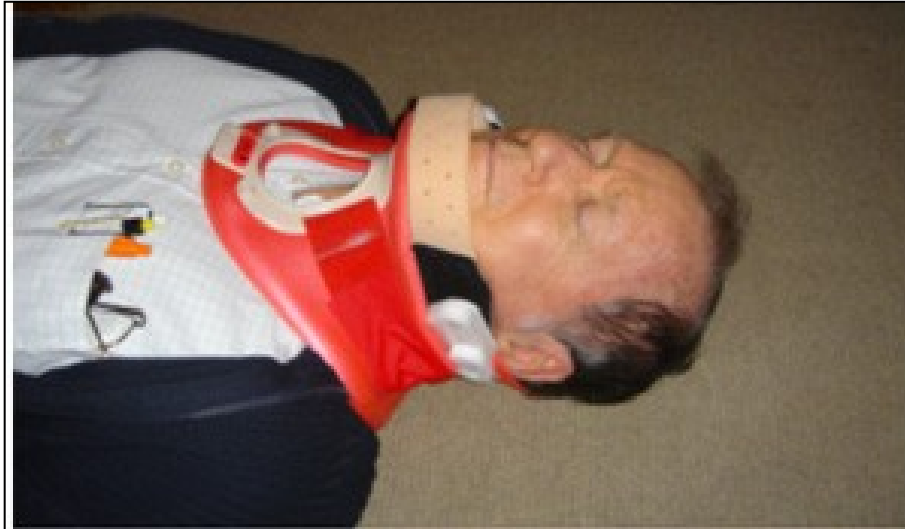FIRST AID

1)FIXATION OF THE CERVICAL SPINE

2)EXCLUDE MOVEMENT OF T & L SPINE DURING MANIPULATION

3)TRANSPORT TO SPINAL CARE DEPARTMENT

1) Fixation of C-spine



2) Immobilization of T & L spine during transport

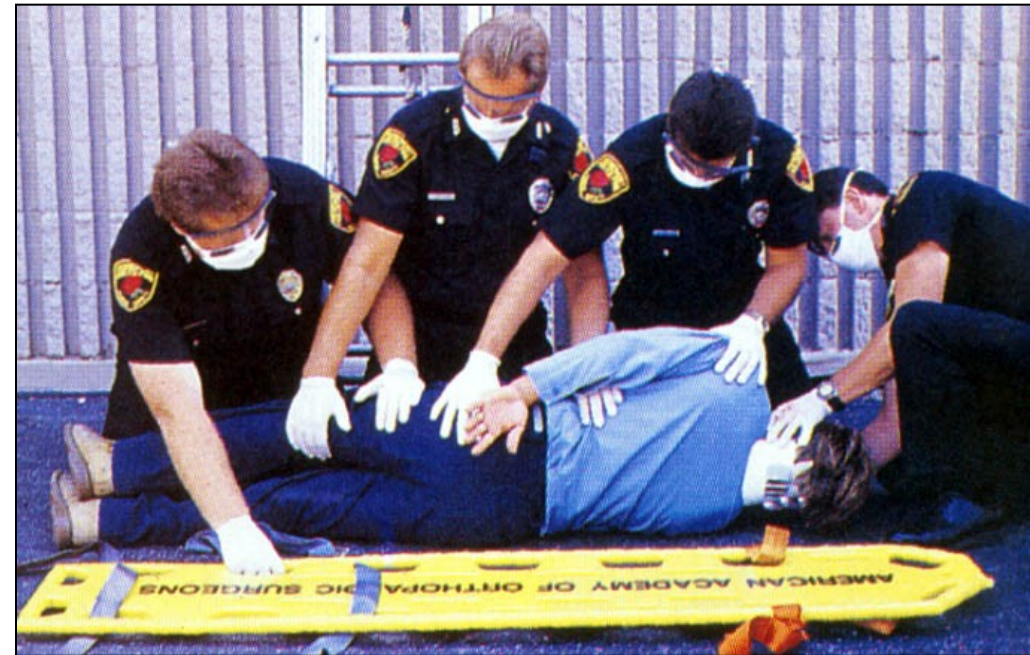„in line position“ – minimize patient handling !

Head fixation

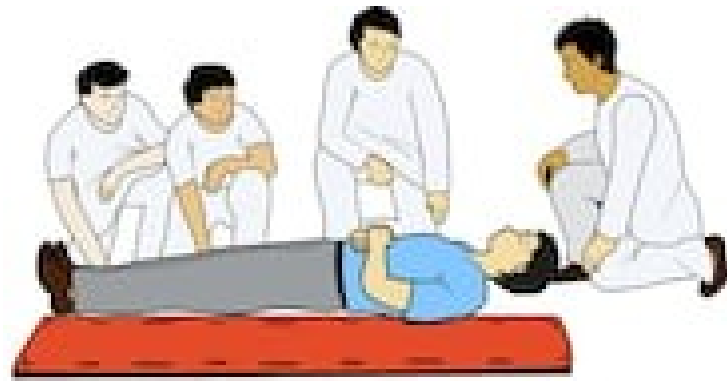
Body and limbs fixation

Surface for transport

- „**back board**“ risk of pressure ulcers
- **vacuum mattresses** - suitable for longer transport

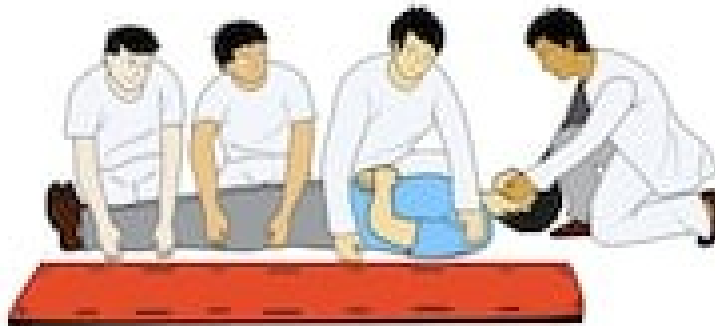

2) „Log-roll“ manuever

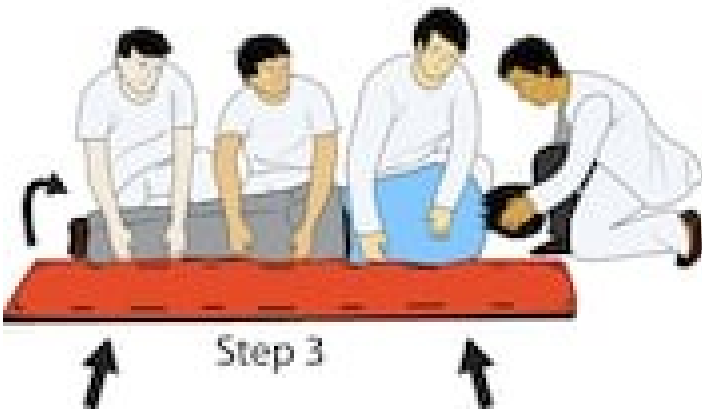


Step 1

Logroll method



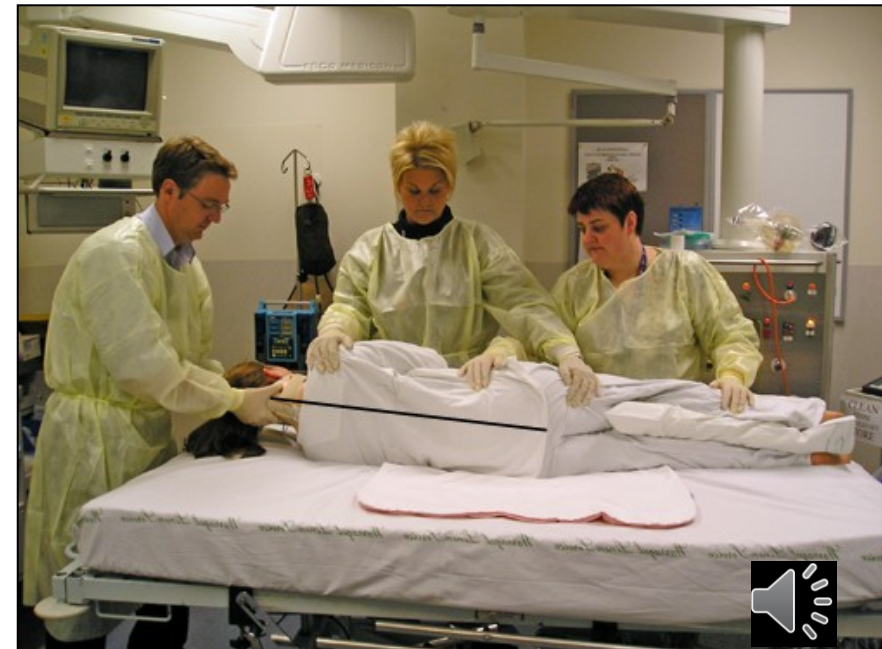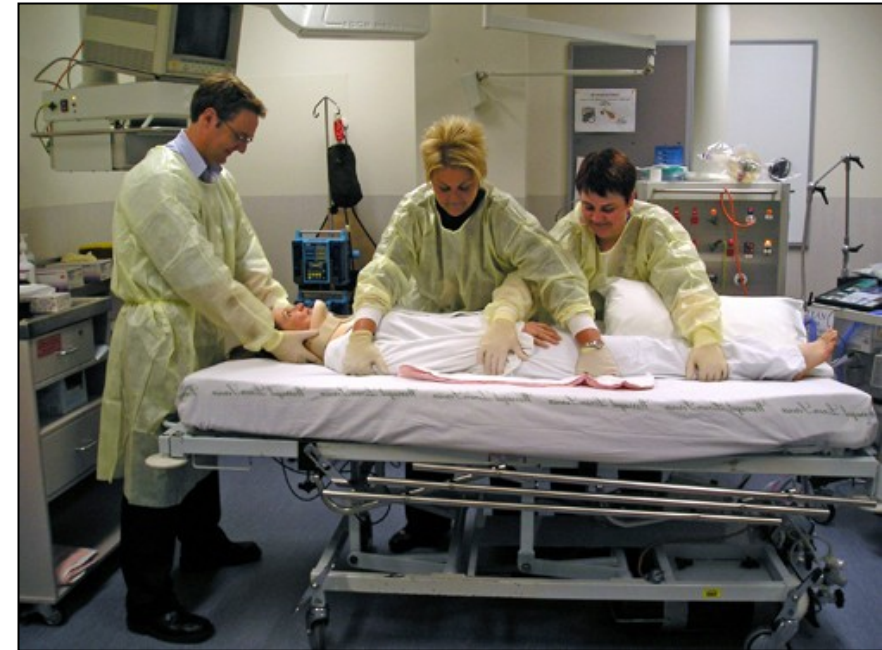Step 2



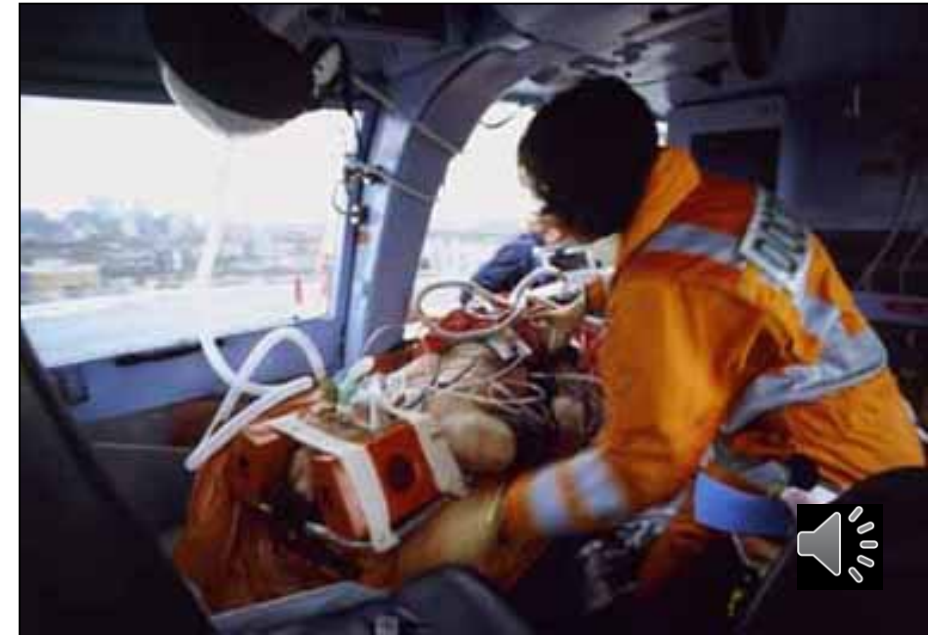Step 3



Step 4



3) Transport



THERAPY

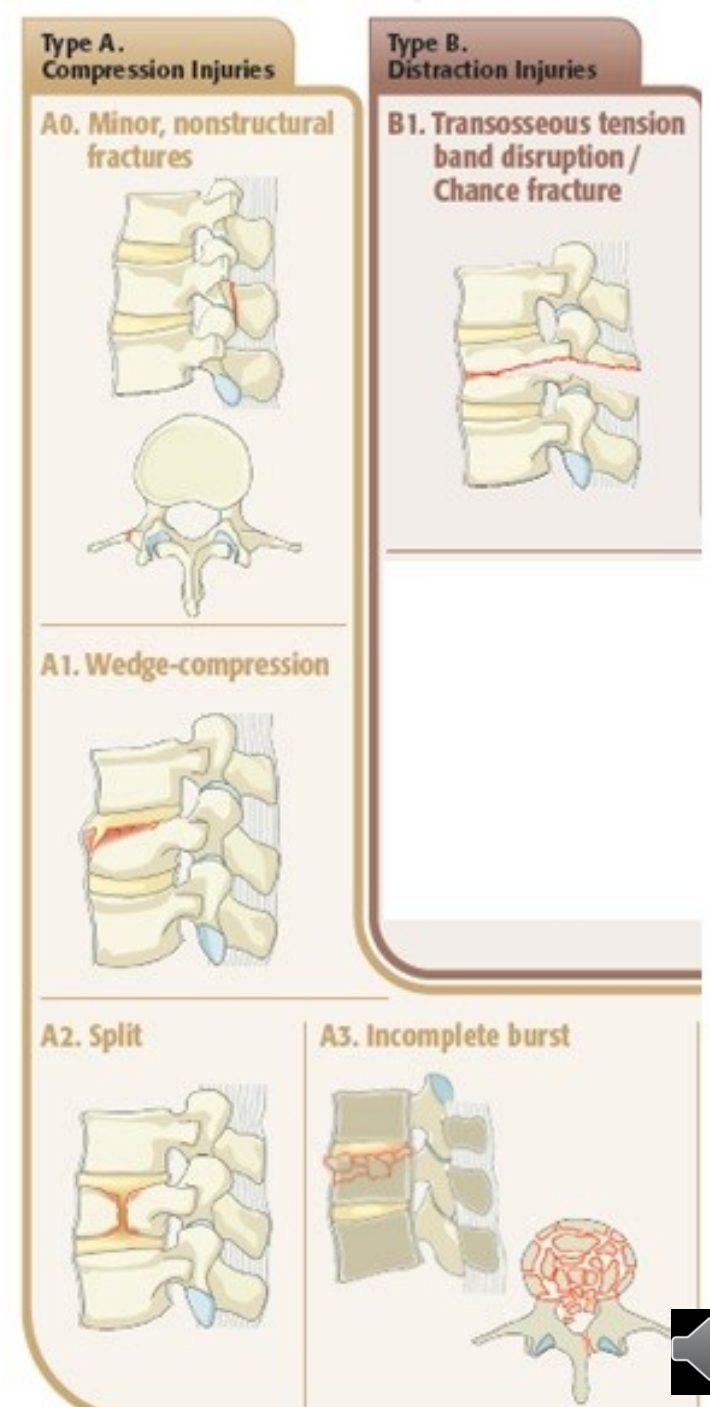
conservative vs. surgical

- ❖ TYPE of fracture
- ❖ grade of INSTABILITY
- ❖ NEUROLOGICAL find

V.A) CONSERVATIVE TREATMENT

INDICATIONS:

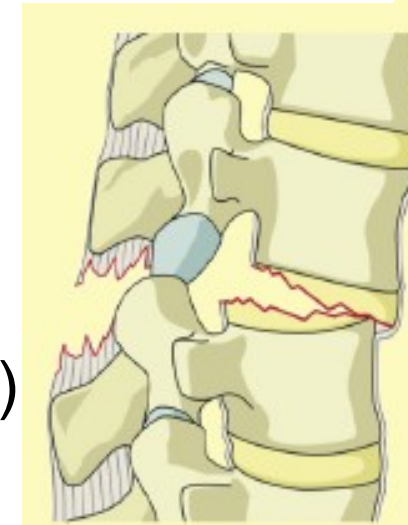
- ✓ flexion-compression fr. **w/o instability** (A0, A1, rarely A2)
- ✓ no injuries to important ligaments or discs (stable "burst" fr. - A3, **w/o kyfotisation**)
- ✓ only instability in the bone part (Chance's fr.- B1)
- ✓ Others (contraindications of surgery)



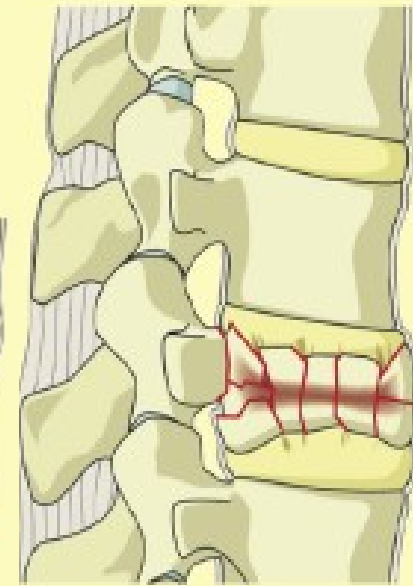
V.A) CONSERVATIVE TREATMENT

CONTRAINDICATIONS:

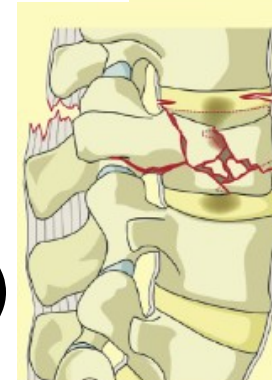- ! unstable "burst" fr. (A3 + A4)
- ! flexion-distraction fr. (B- group according to AO)
- ! translation injury (C- group according to AO)
- ! **NEUROLOGICAL** deficit
(Surgery is **necessary within 6 hours** !!)



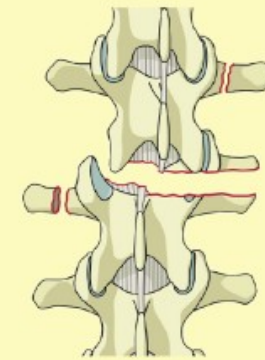
B1



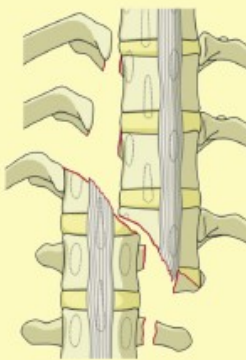A3



C1



C2



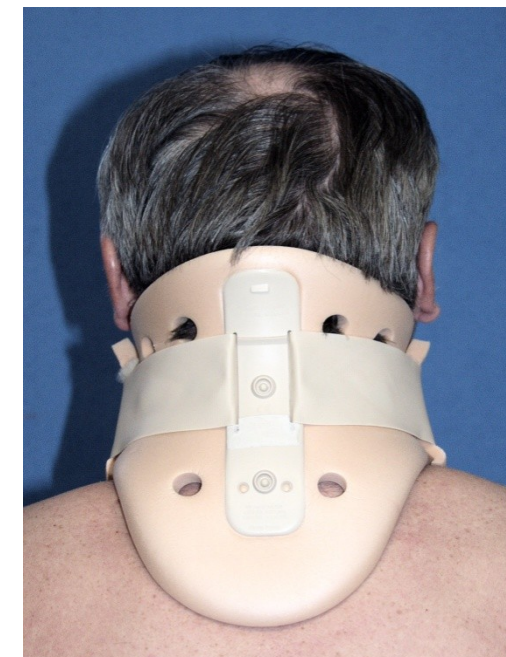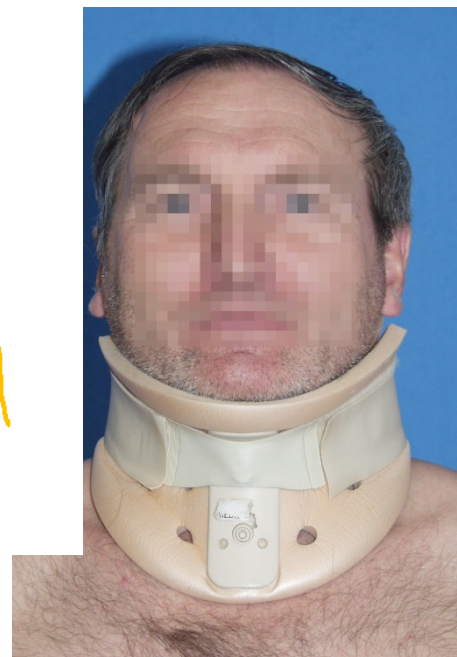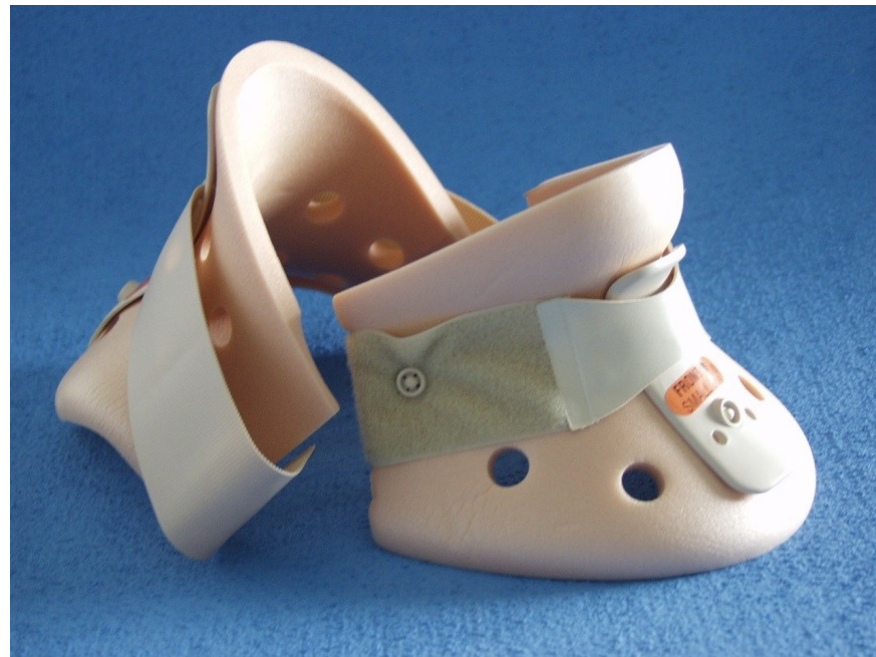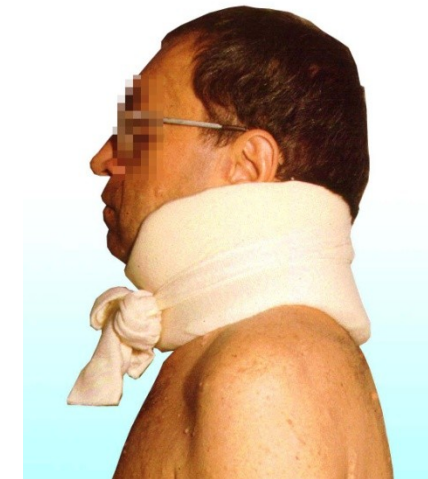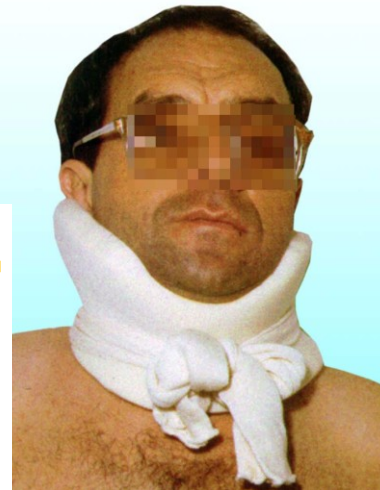C3

=> **SURGICAL TREATMENT !!**

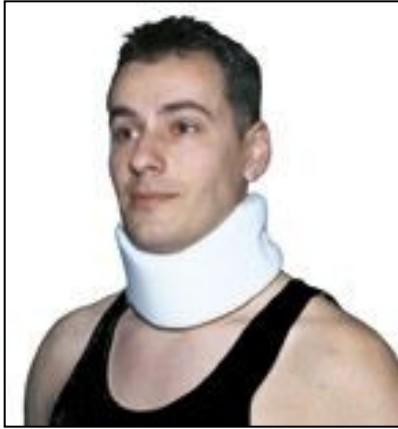V.A) CONSERVATIVE TREATMENT

Rest regime

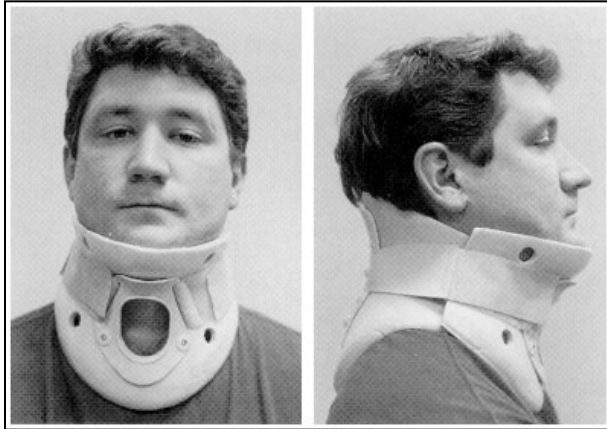
- Collars
- foam
 - Philadelphia



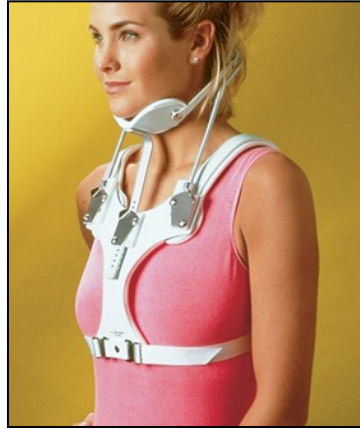Mobility of C-spine



100 %



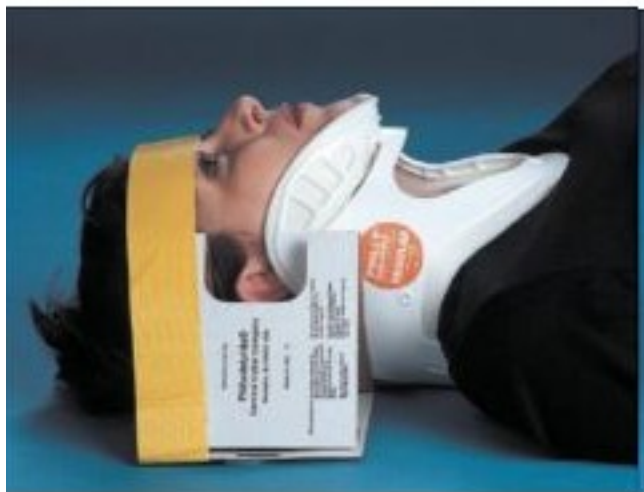40-45 %



30-35 %



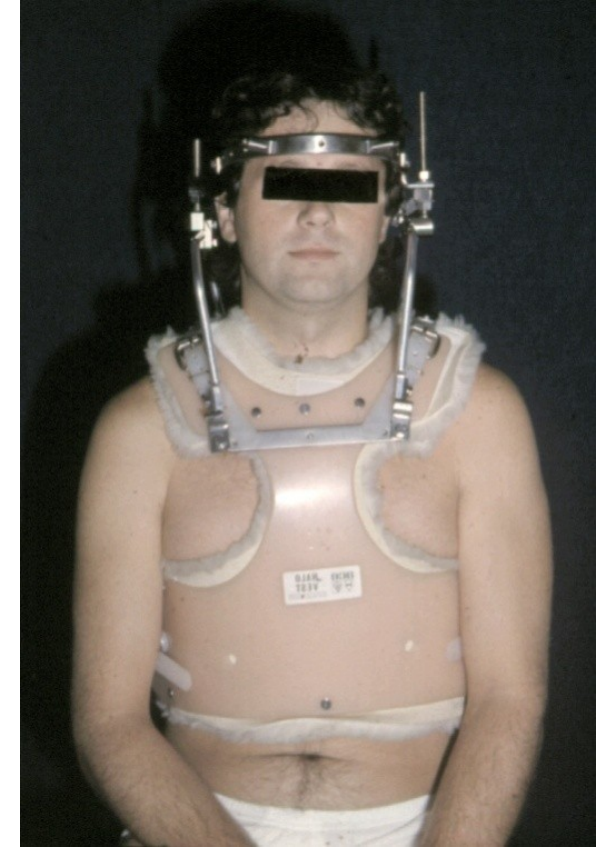
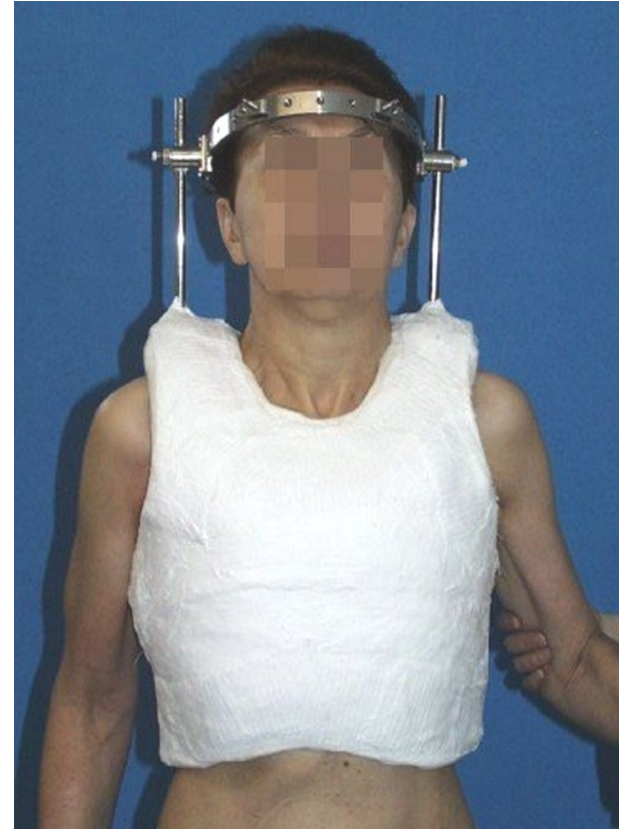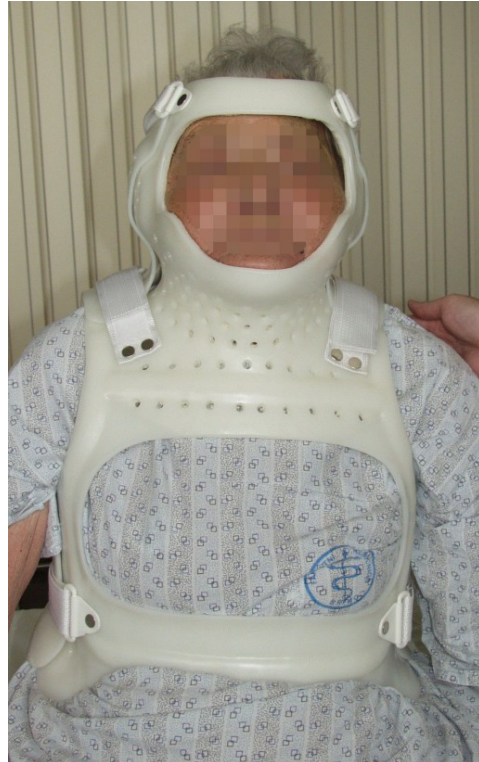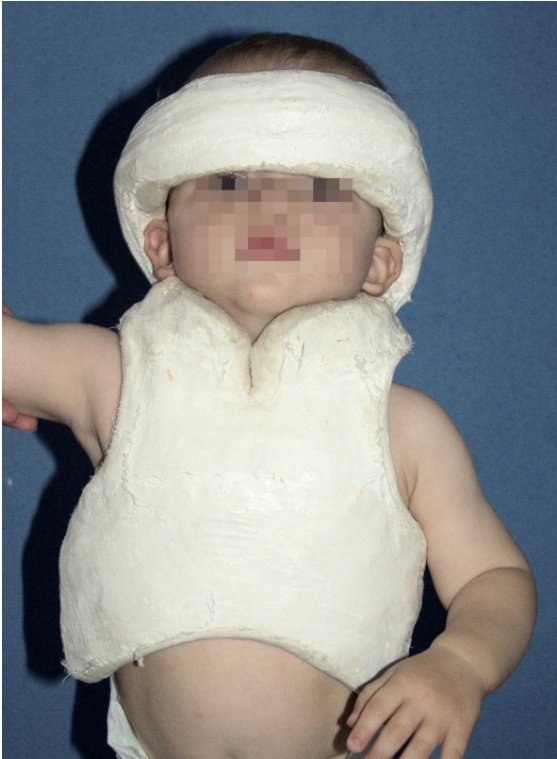5-10 %

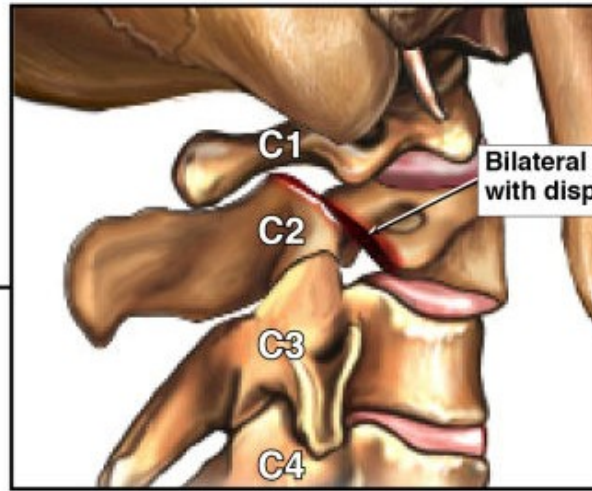
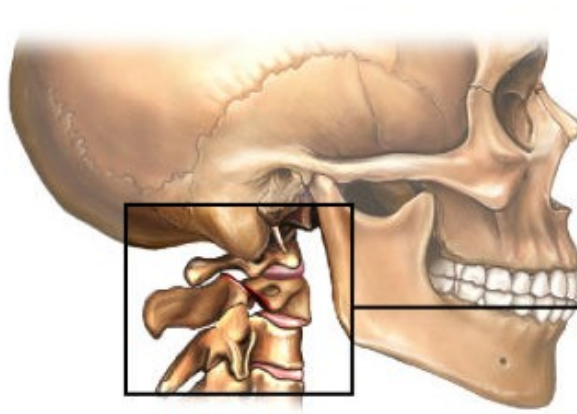


V.A) CONSERVATIVE TREATMENT

CERVICAL spine

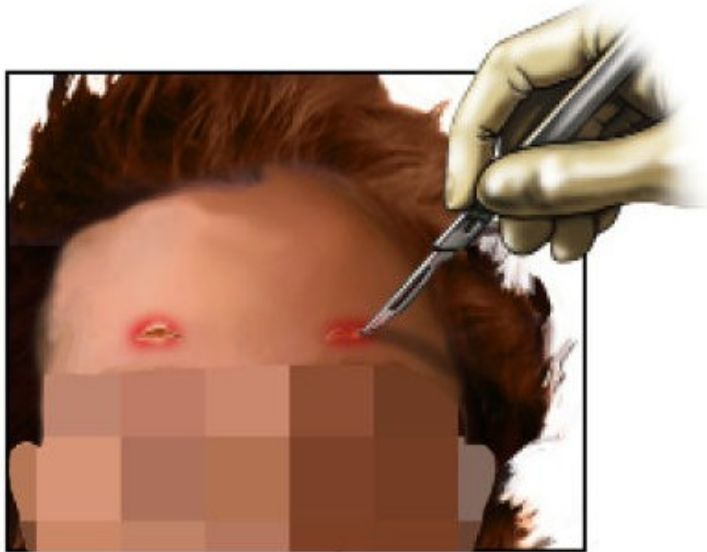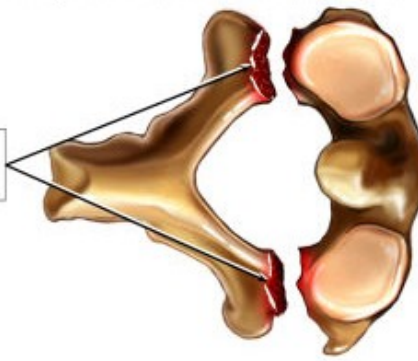
- halo-cast, halo-vest
- Minerva



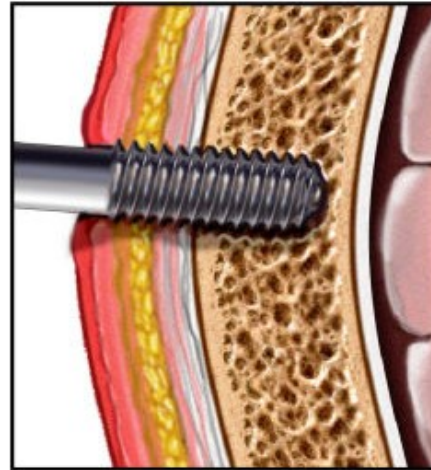


Lateral view of upper cervical spine

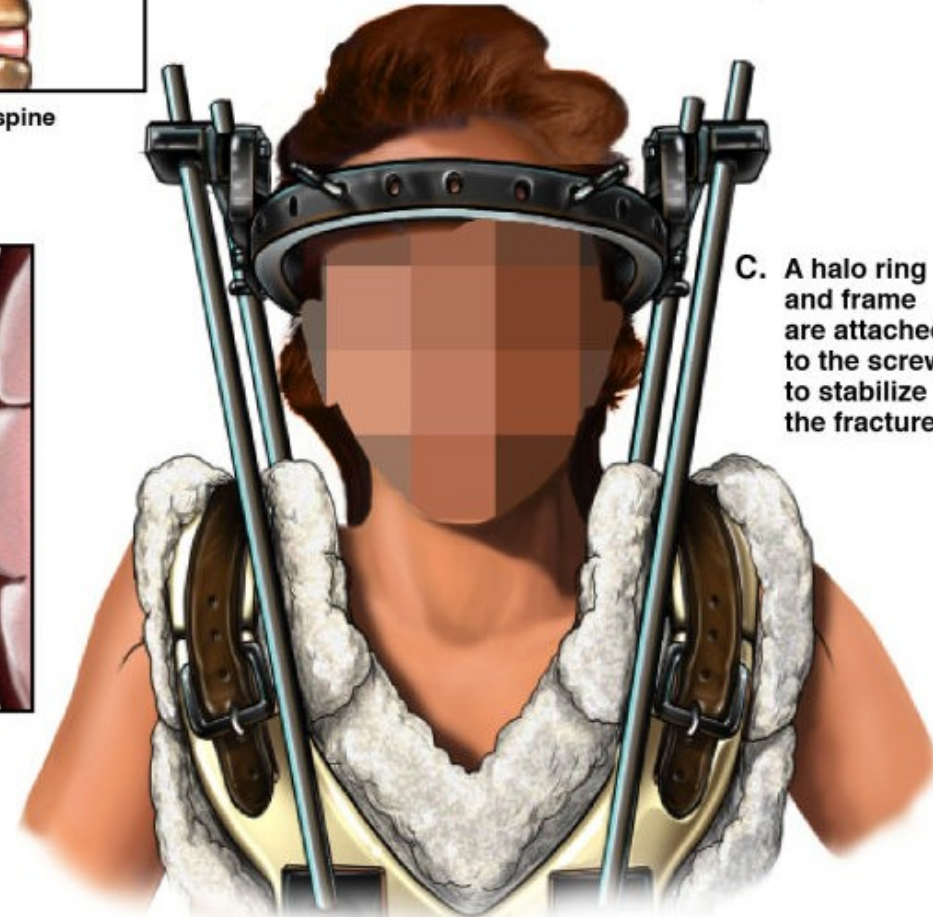
Superior view of second cervical vertebra



A. Incisions are made to expose the skull.



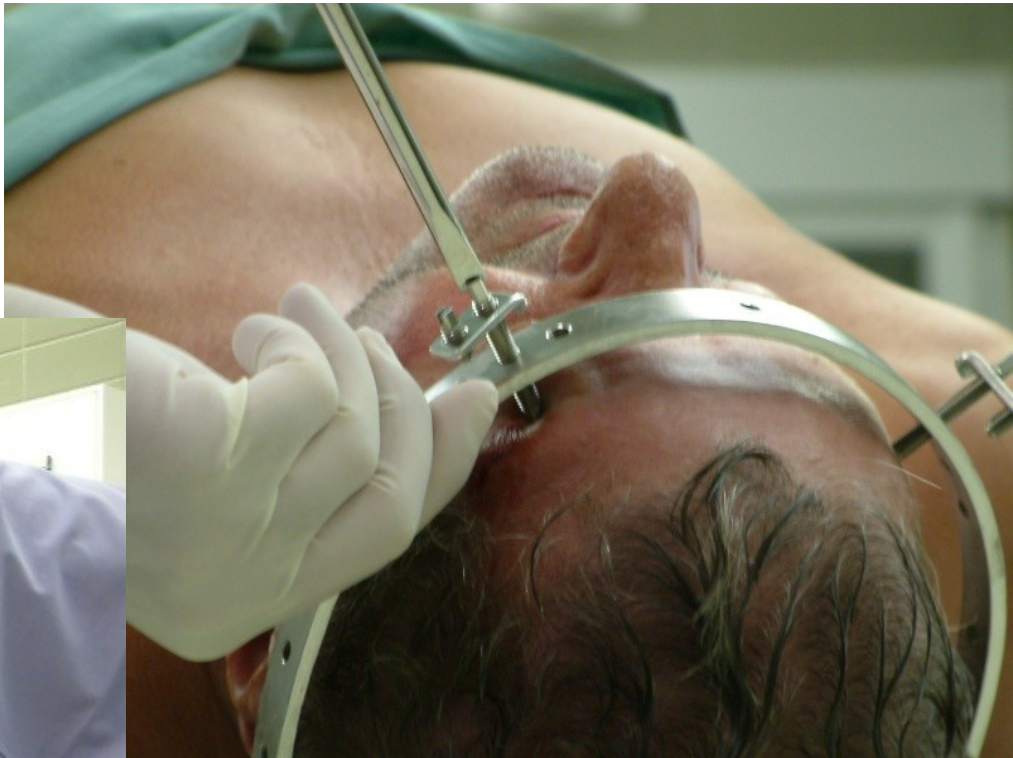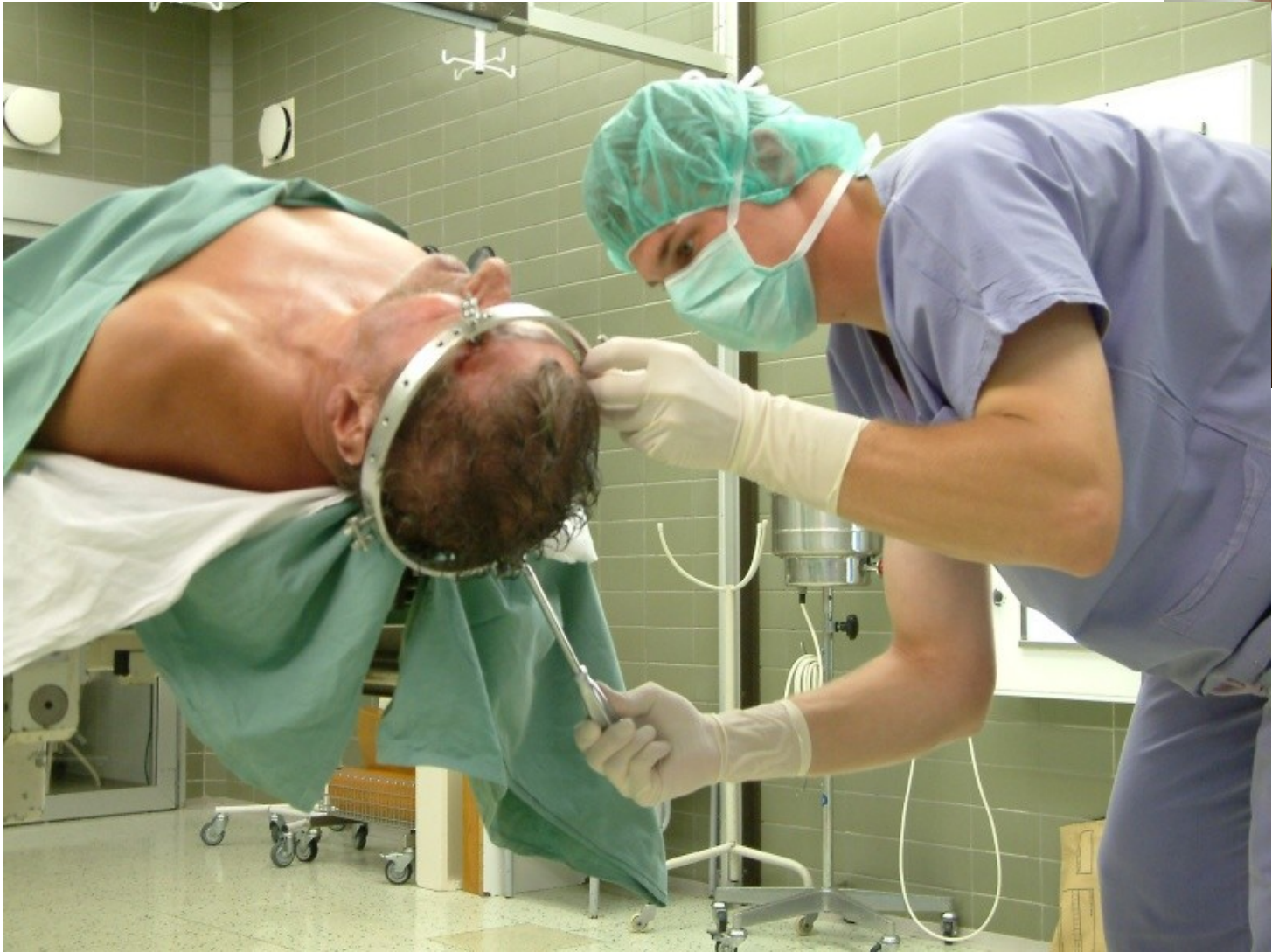B. Screws are placed into the skull.



C. A halo ring and frame are attached to the screws to stabilize the fracture.

Nucleus Medical Media (2020). *Cervical spine fracture with application of halo ring stabilization* [Digital image]. Retrieved from <https://ebSCO.smartimagebase.com/cervical-spine-fracture-with-application-of-halo-ring-stabilization/view-item?ItemID=73352>

Fitting the HALO traction



CONSERVATIVE TREATMENT



THORACO – LUMBAR spine

- **Jewett** (hyperextension) **brace**
 - featuring 3 support points: suprapubic, dorsolumbar and sternal
 - it consists of mass-produced parts, but MUST BE individually adapted to the patient's needs and dimensions!

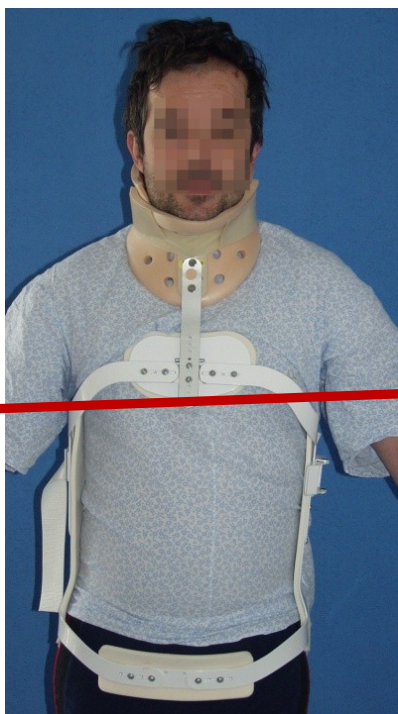
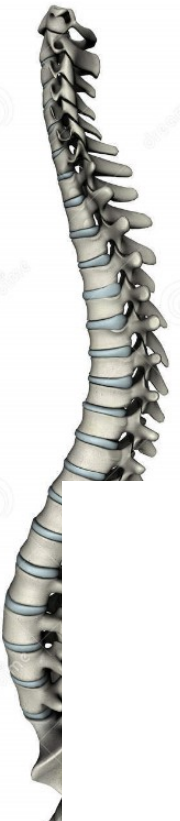

CONSERVATIVE TREATMENT

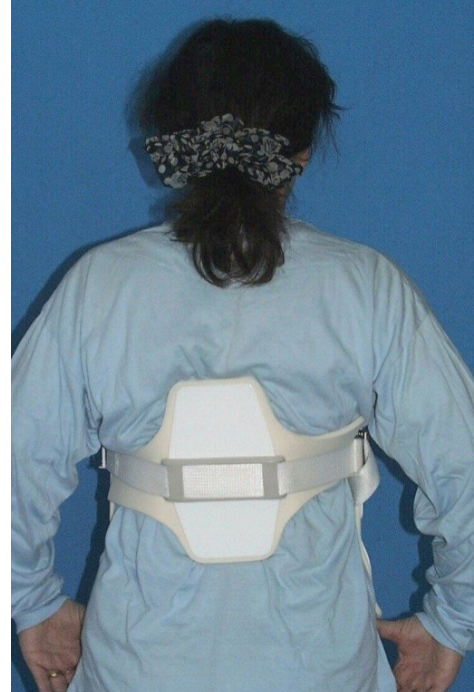Modifications of THORACO – LUMBAR fixation

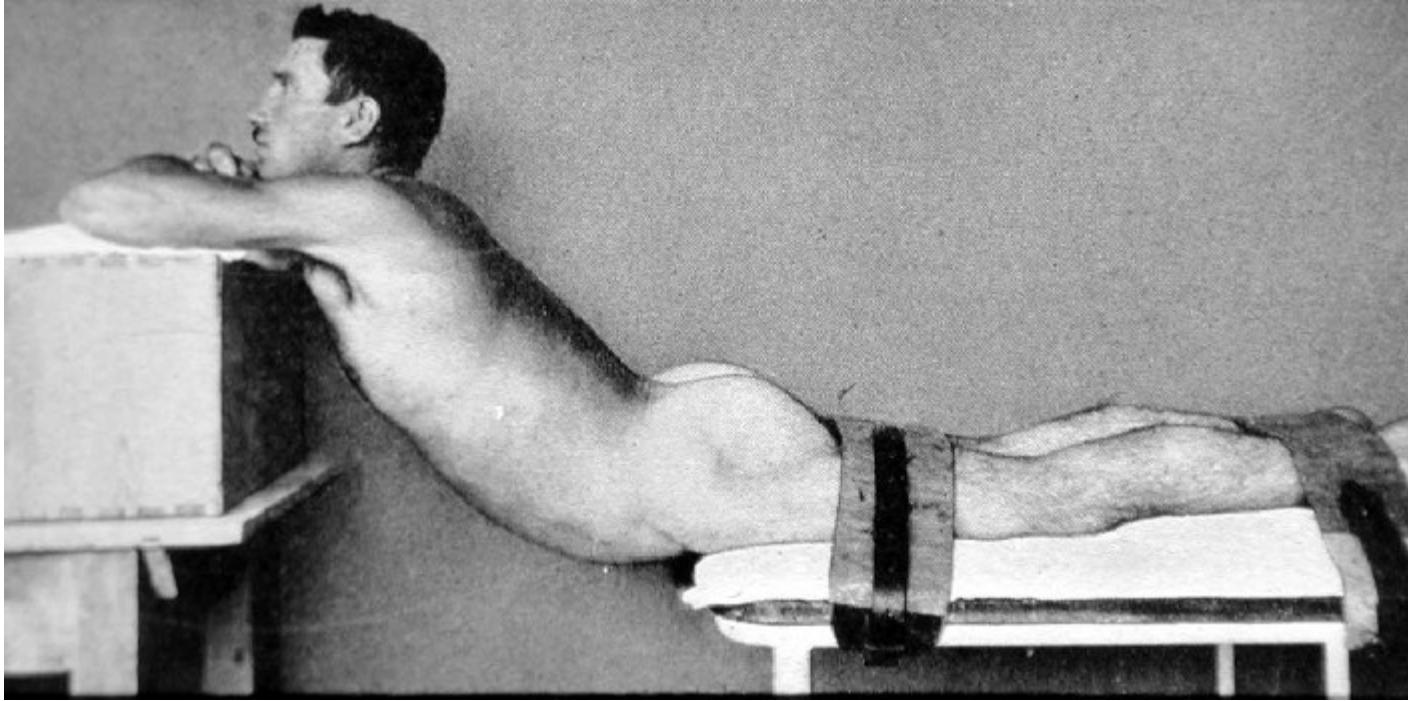
– according to the **height of the injury** :

- From **Th 6 ABOVE**
- **Th6 – L3**

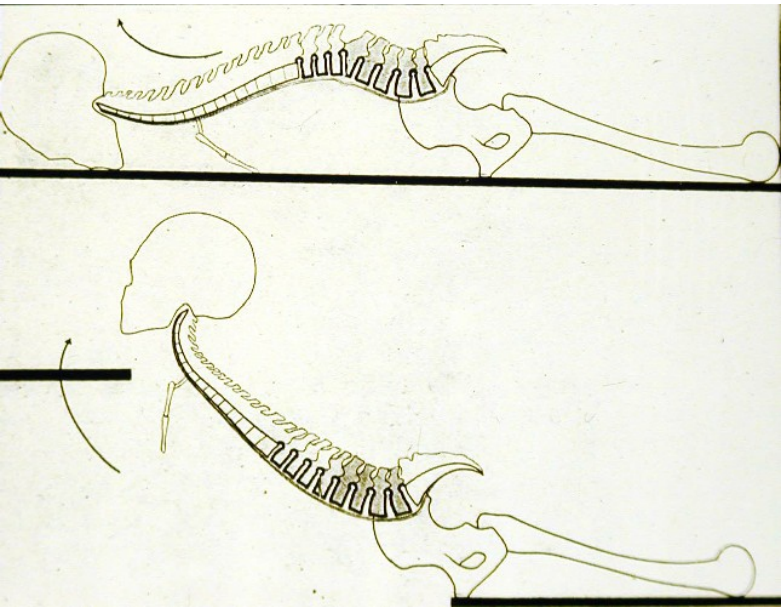


Jewett brace with **cervical extension**





Böhler's method
of corection in
hyperextension

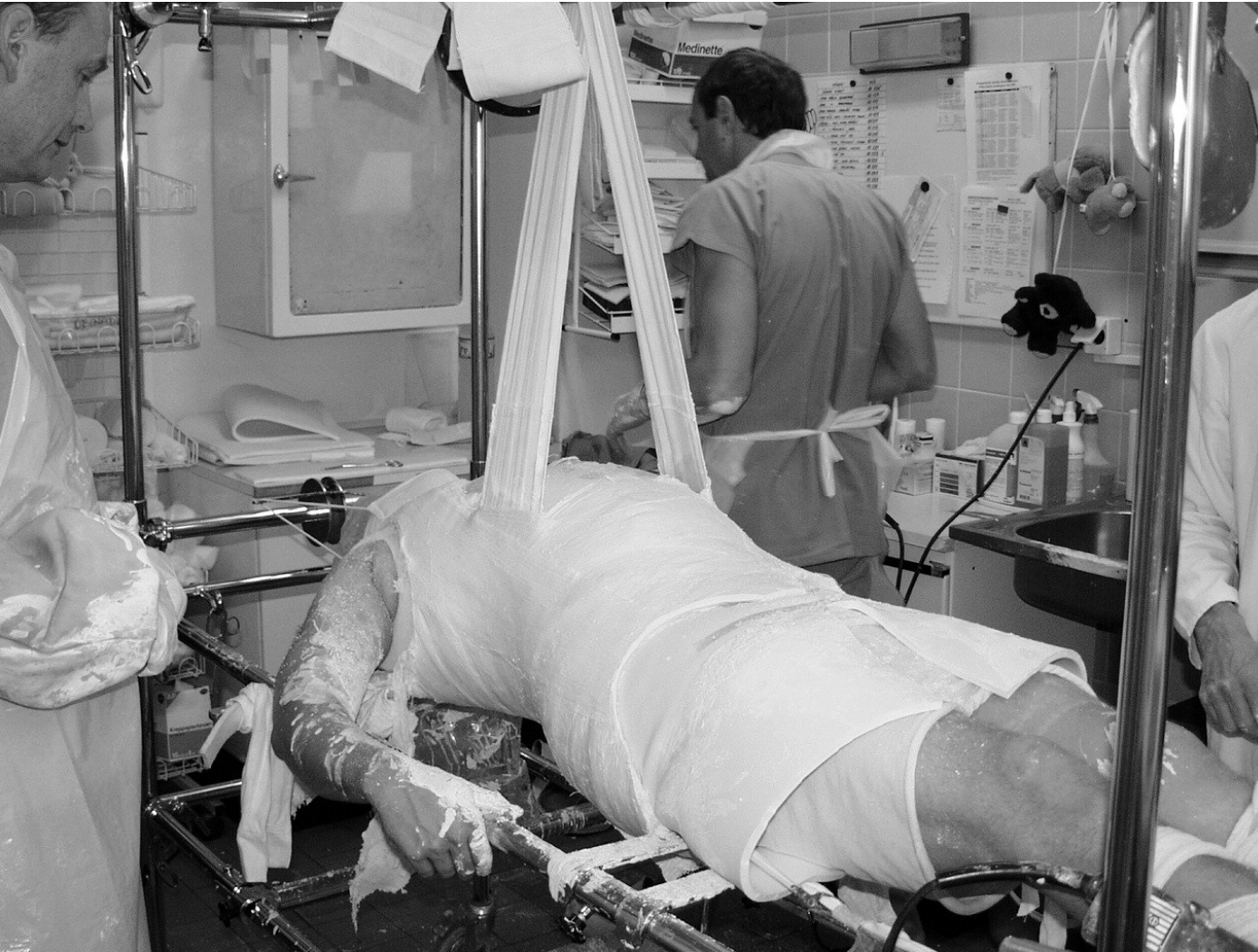


Cotrel's EDF frame

(Elongation, Derotatin, Flection)



CONSERVATIVE TREATMENT – history: plaster corsets

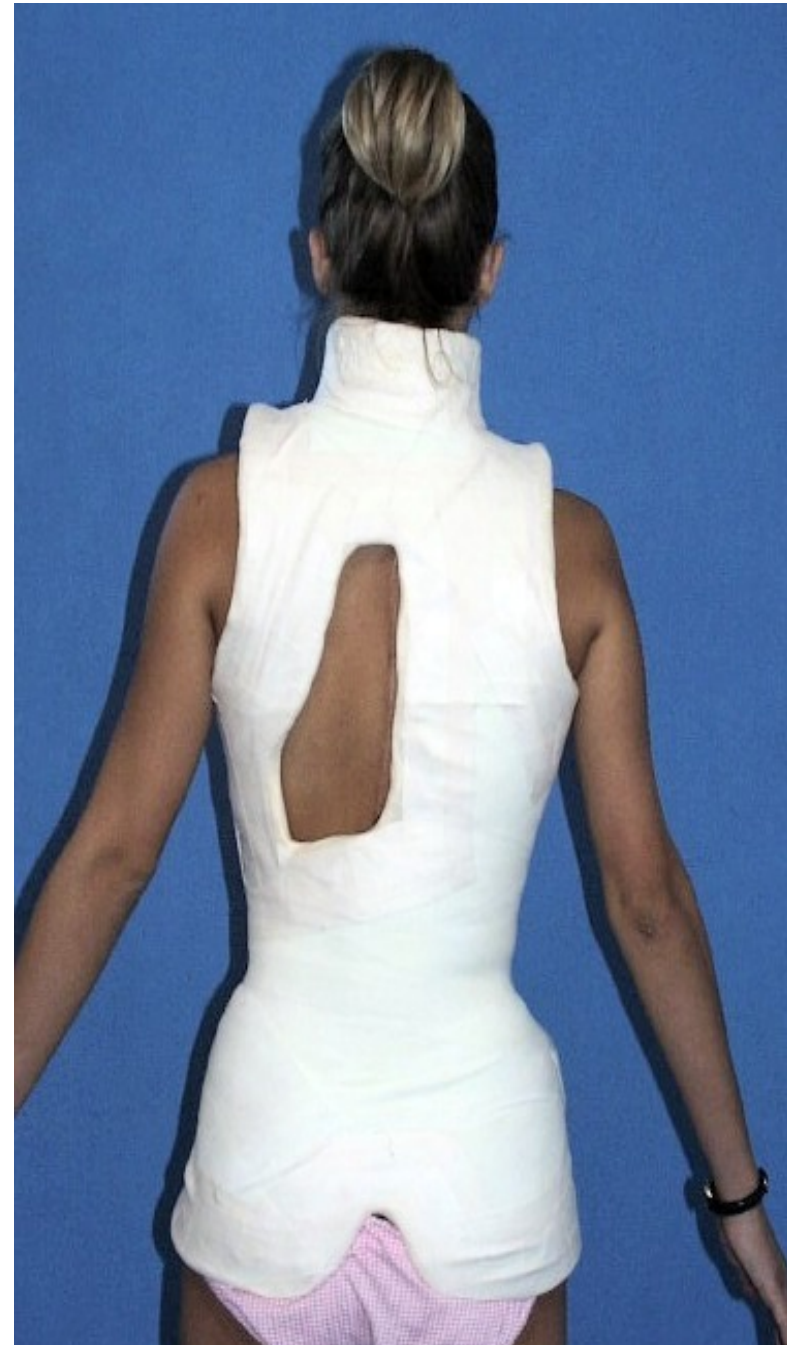
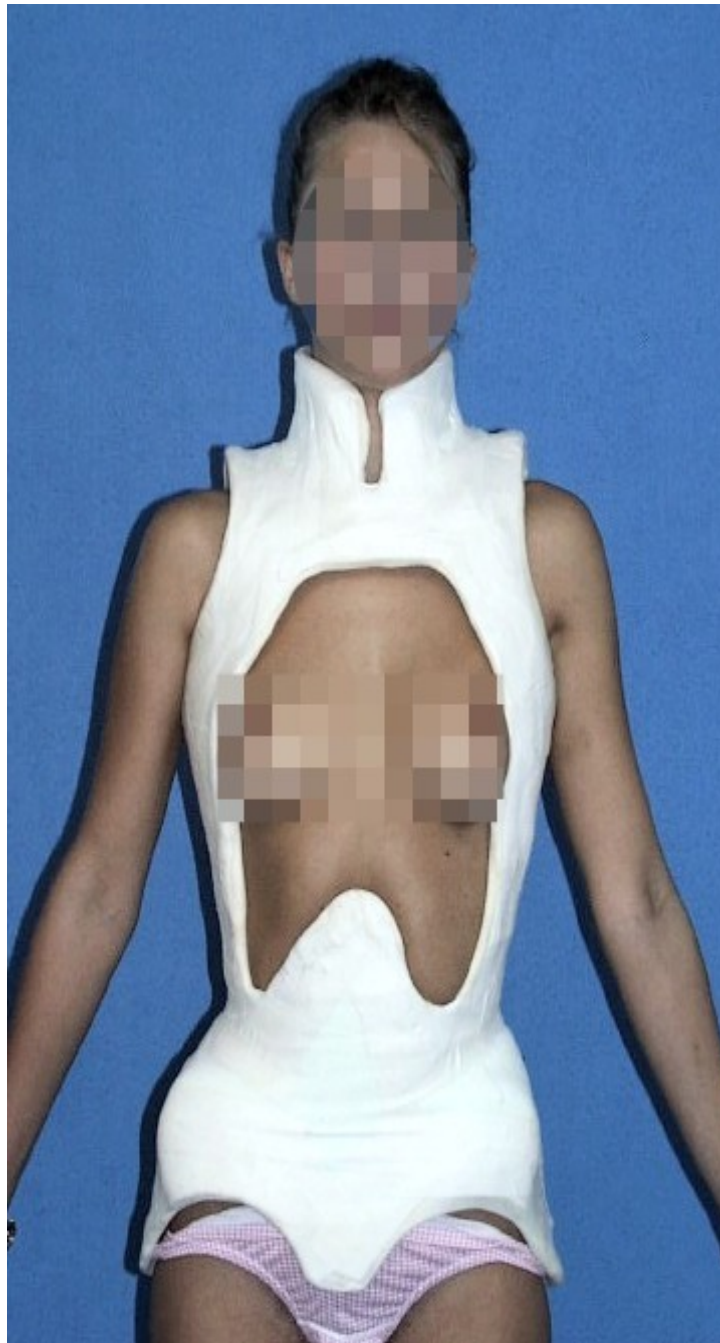
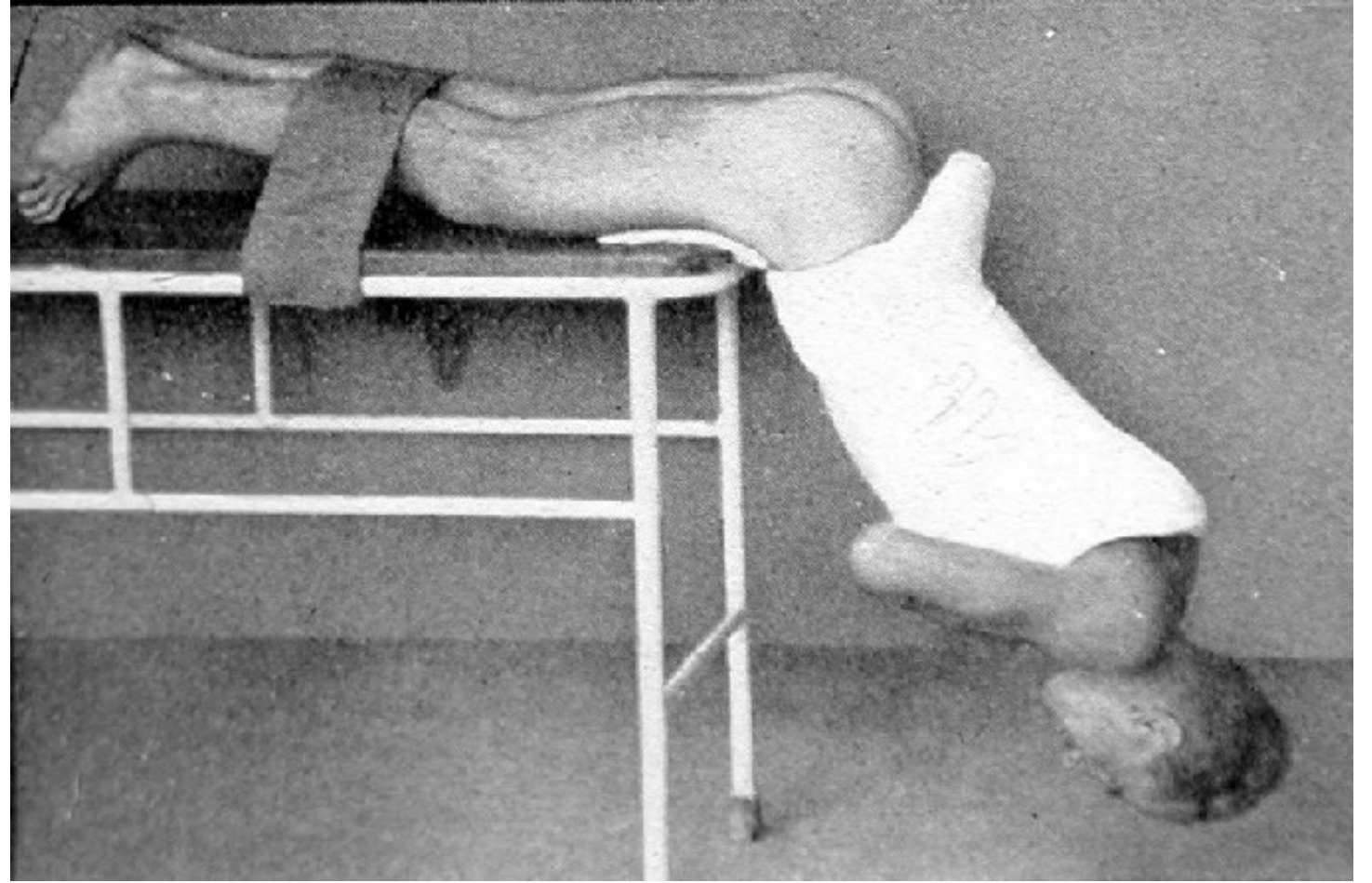

Indications of corsets (except traumatic):

- m. Scheurmann
- Scoliosis (infantile e.g.)

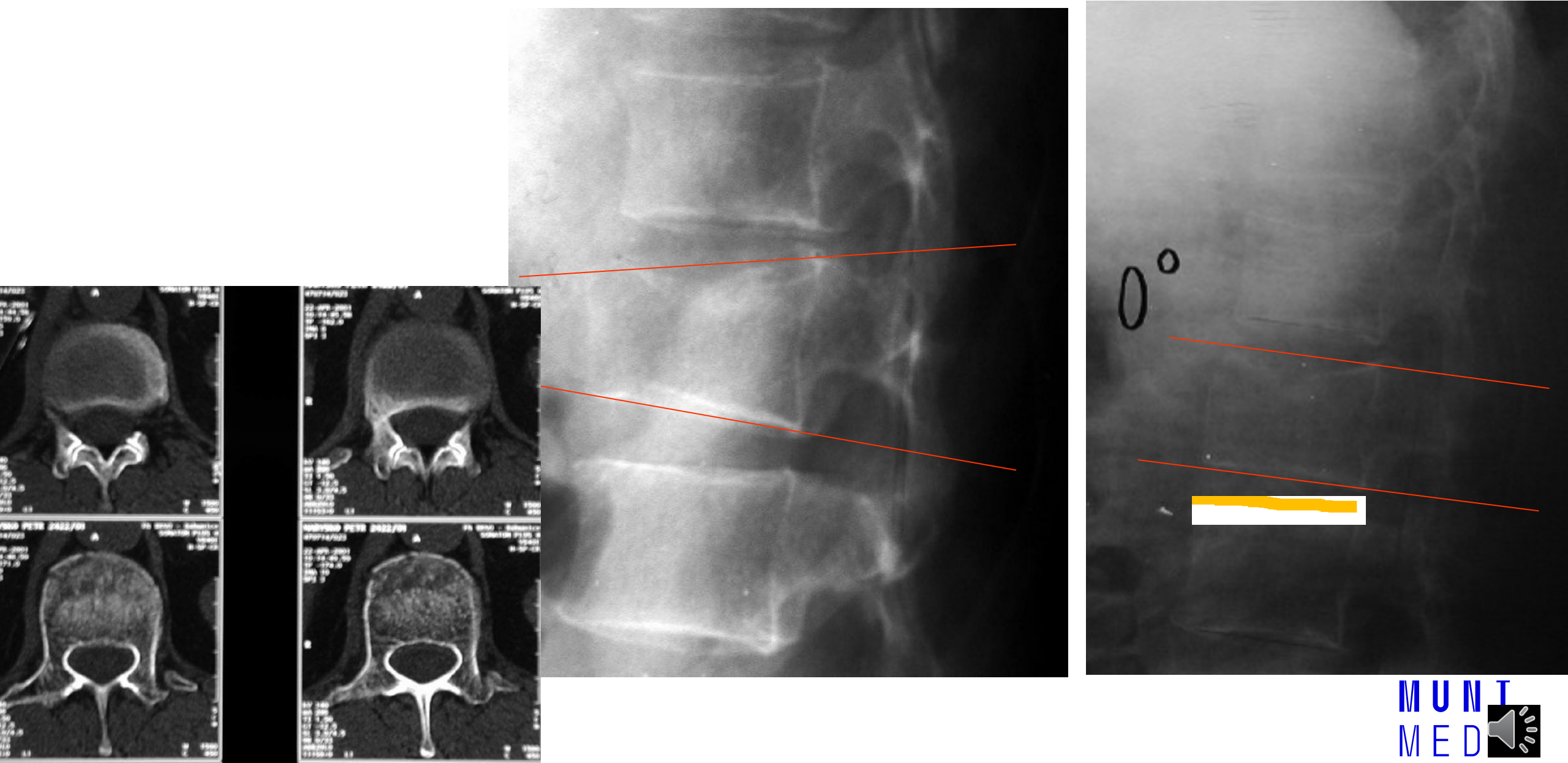
Others:

- incomppliance of pts (luxation of THA e.g.)



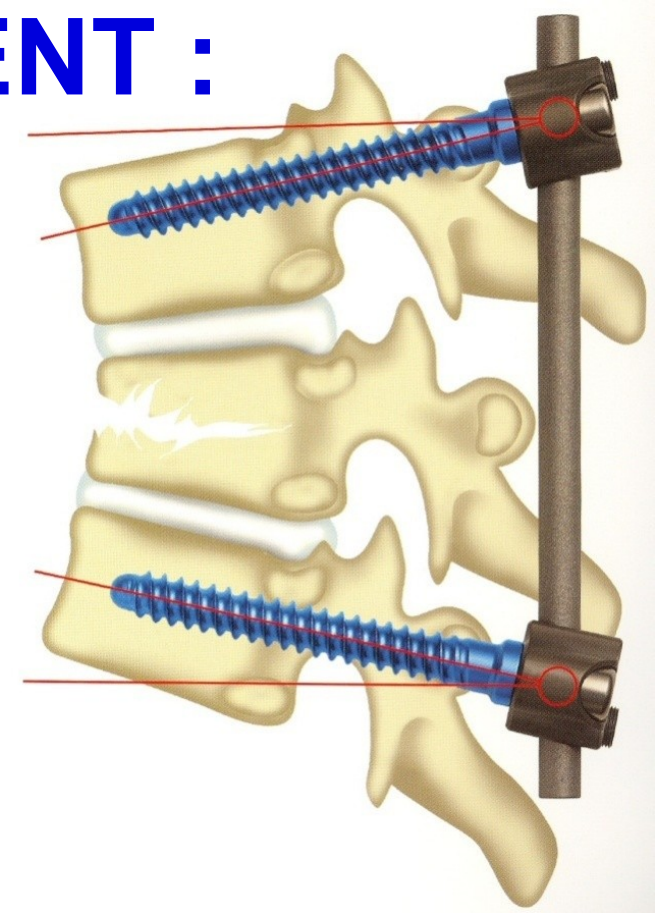


V.A) CONSERVATIVE TREATMENT – results:



V.B) goals of SURGICAL TREATMENT :

- **CORRECTION OF DEFORMITY**
 - restore sagittal balance of segment
- **STABILIZATION**
 - anatomical shape of vertebra
 - anterior support if it's necessary
- **INTERVERTEBRAL FUSION**
 - if it's necessary
- **DECOMPRESSION OF NEURAL STRUCTURES**
 - direct or indirect (ligamentotaxis)



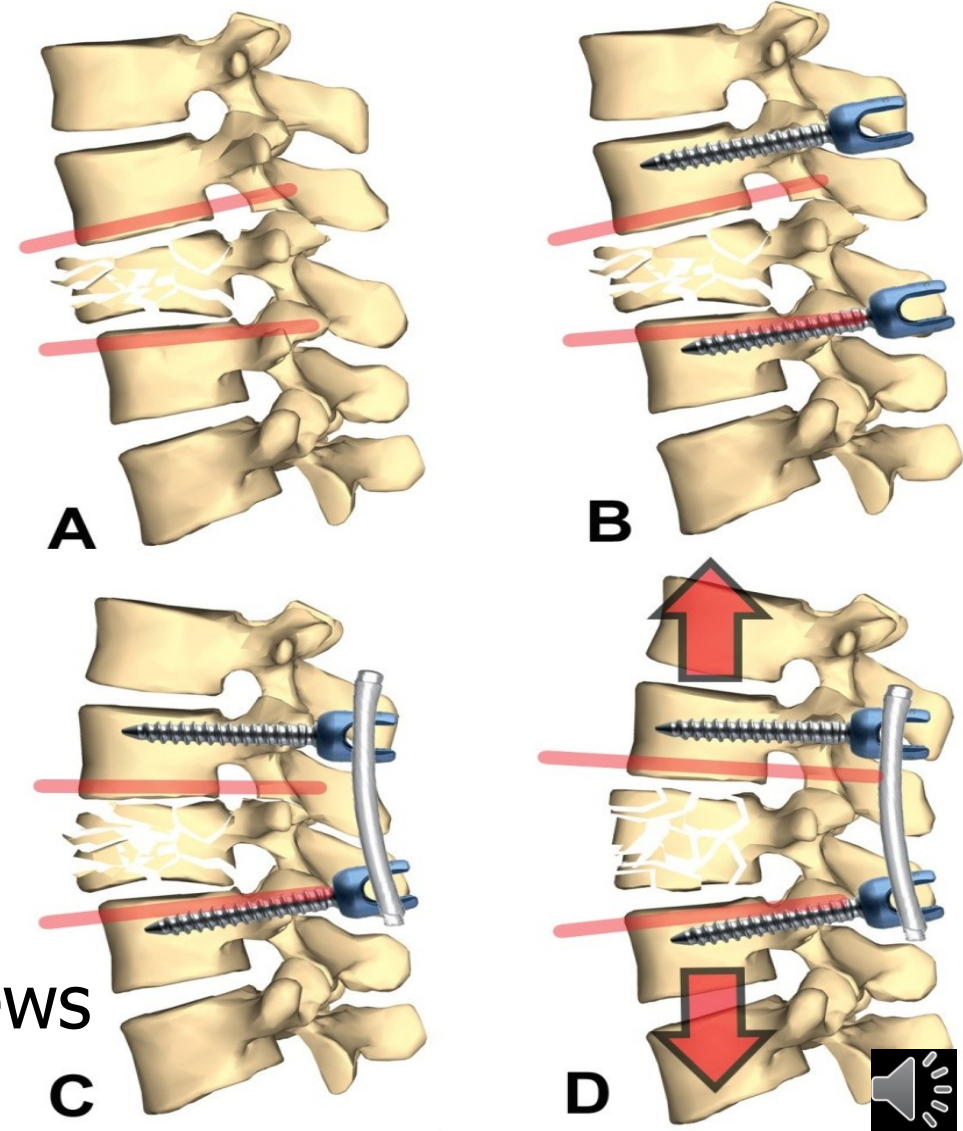
V. SURGICAL TREATMENT – posterior approach – principles of REPOSITION:

1) Dorsal (trans-pedicular) fixation (B)

2) Lordotisation (C)

3) Distraction (D)

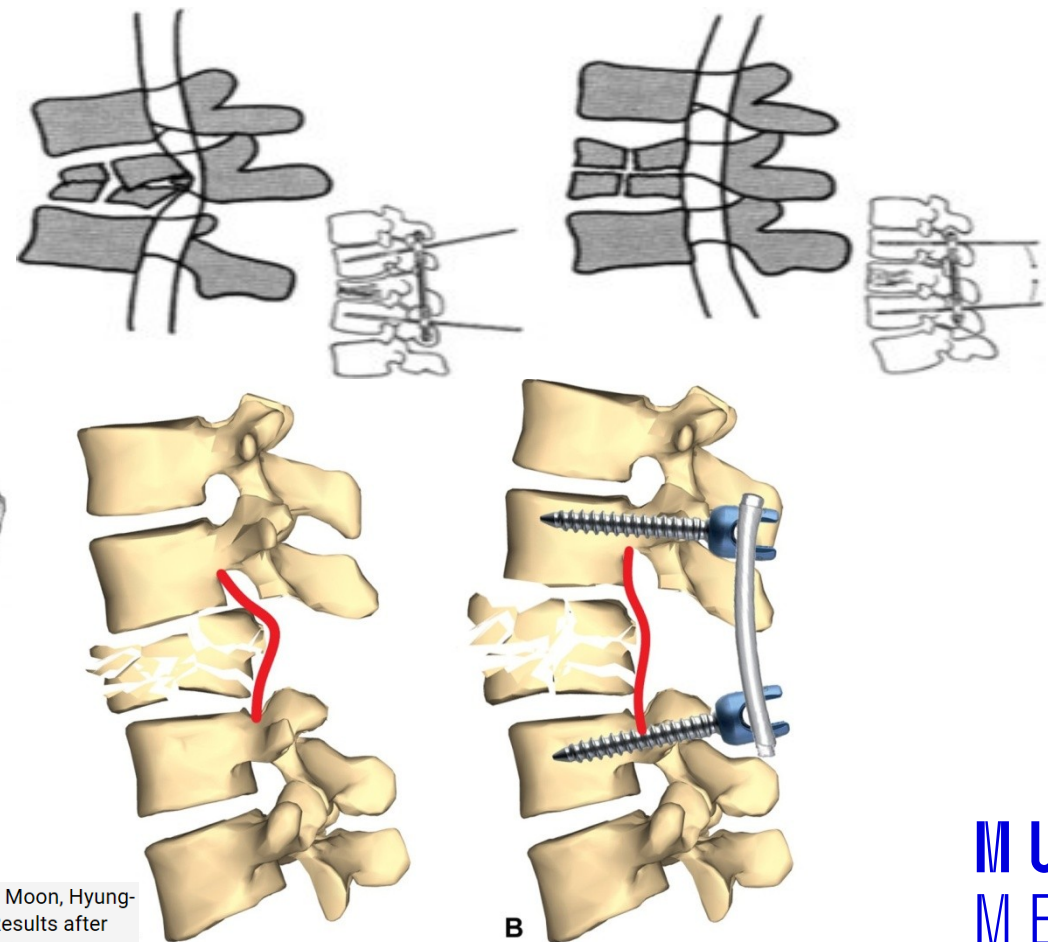
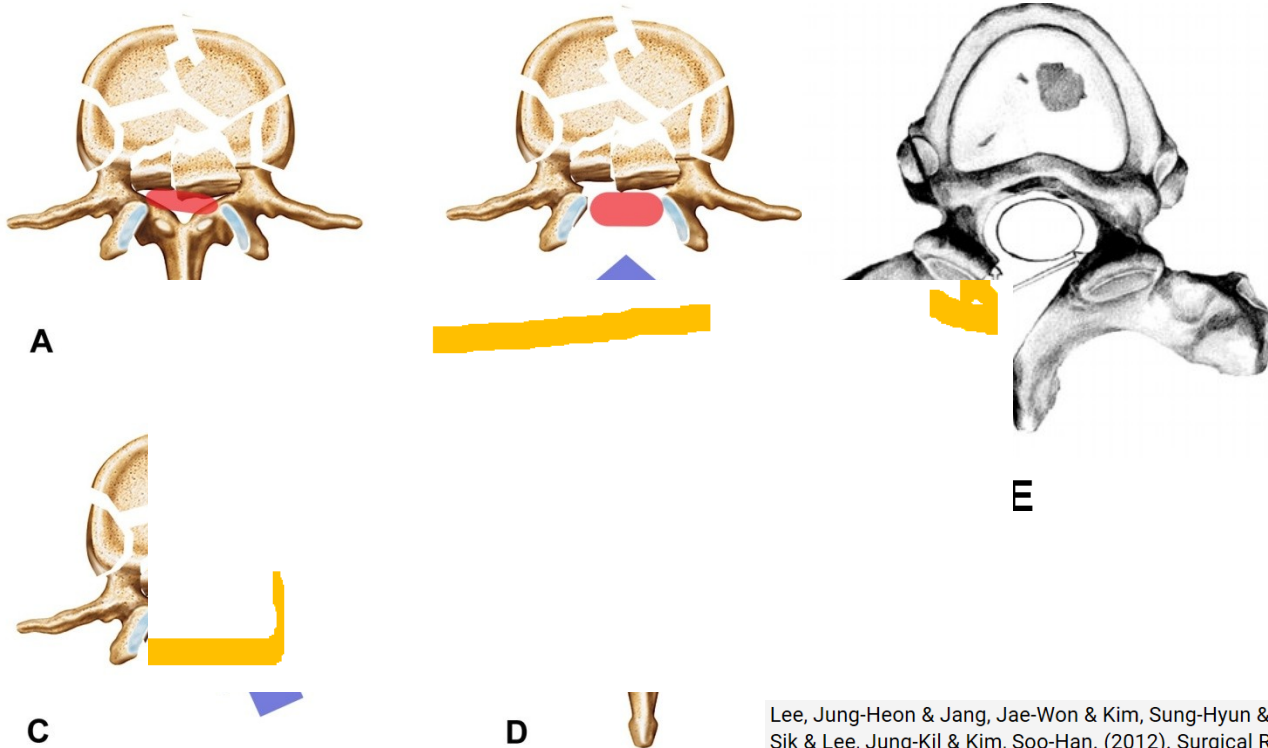
4) Stabilization - tightening the heads of screws



V. SURGICAL TREATMENT – posterior approach – principles of DECOMPRESSION of spinal canal:

DIRECT = LAMINECTOMY (B)
HEMI-LAMINECTOMY with (C)
or without facetectomy (E)
ANTERIOR DECOMPRESSION (D)

INDIRECT = LIGAMENTOTAXIS

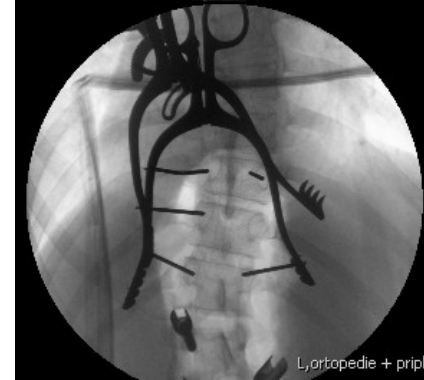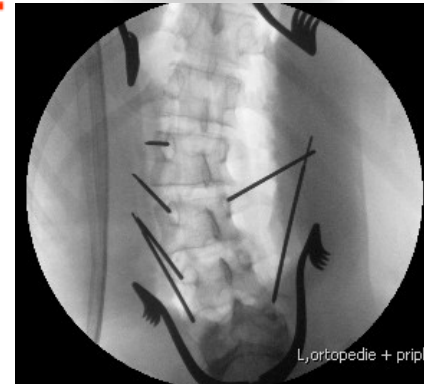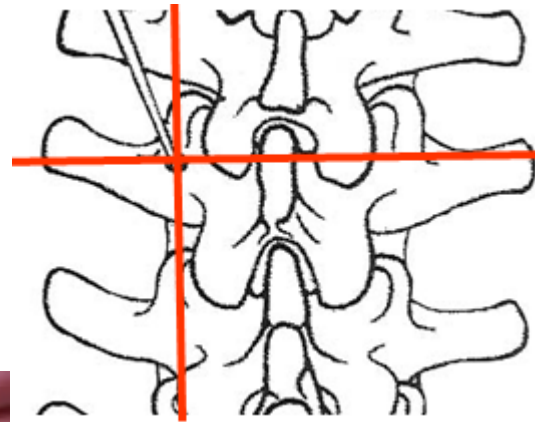


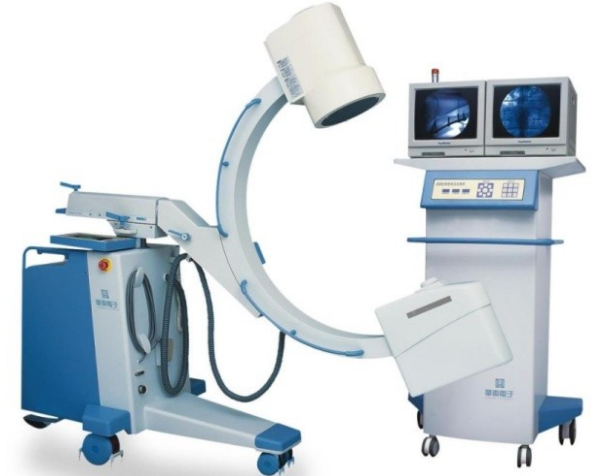Lee, Jung-Heon & Jang, Jae-Won & Kim, Sung-Hyun & Moon, Hyung-Sik & Lee, Jung-Kil & Kim, Soo-Han. (2012). Surgical Results after Unilateral Laminectomy for the Removal of Spinal Cord Tumors. Korean Journal of Spine. 9. 232. 10.14245/kjs.2012.9.3.232.

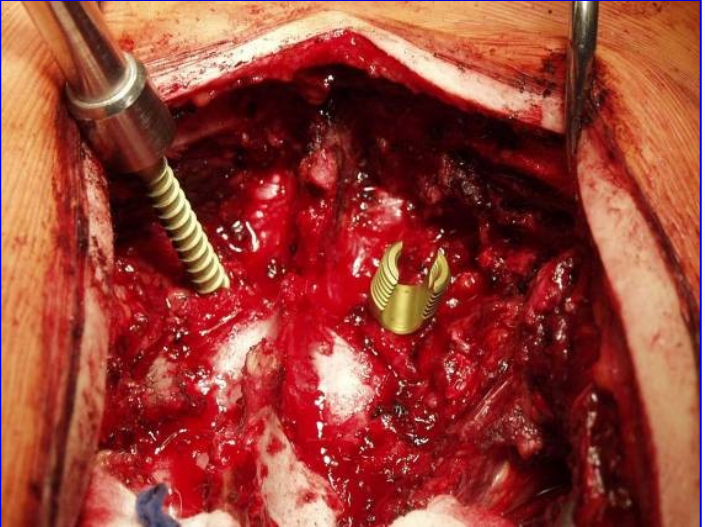
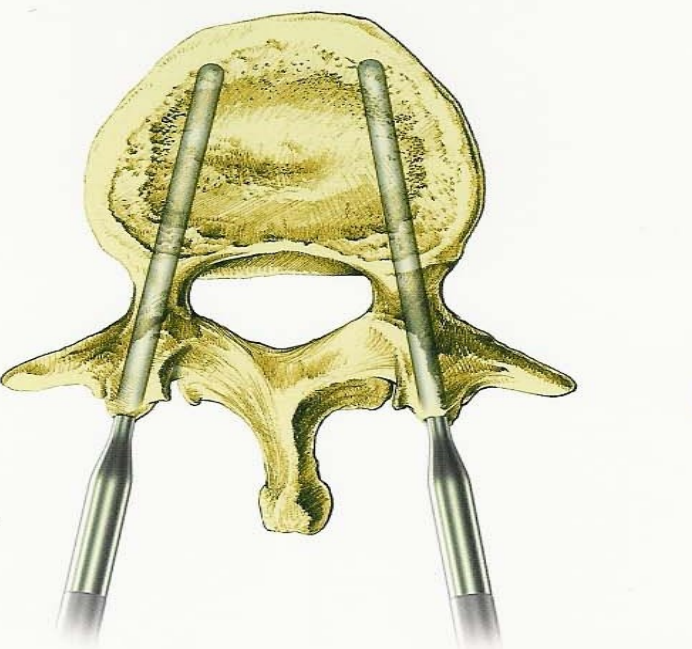
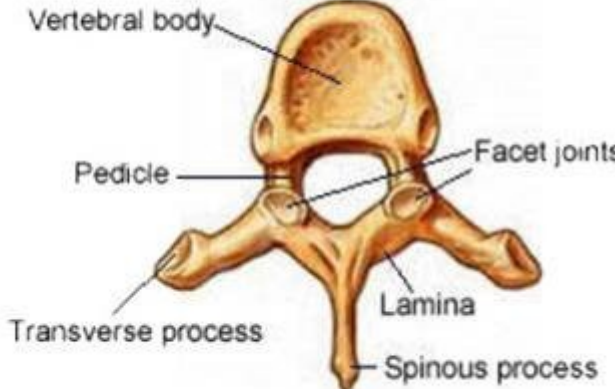
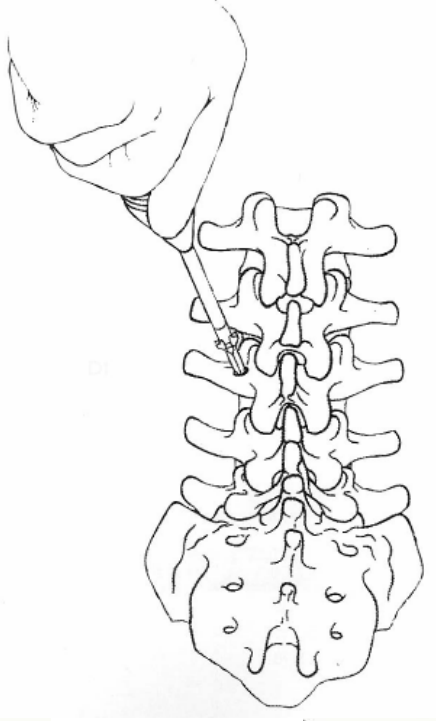
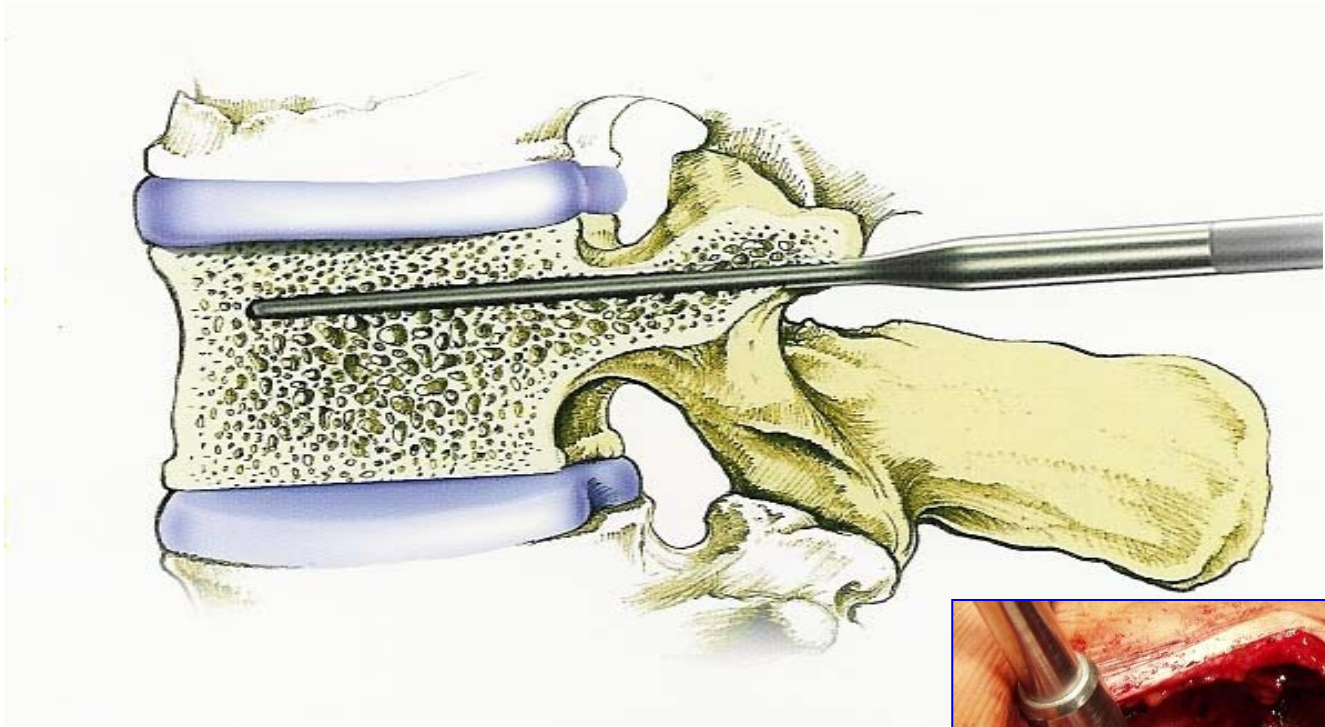
V. SURGICAL TREATMENT – posterior approach

– principles of TRANSPEDICULAR fixation:

- Transpedicular screws → targeting the screws
- Rods
- Cross-link connector

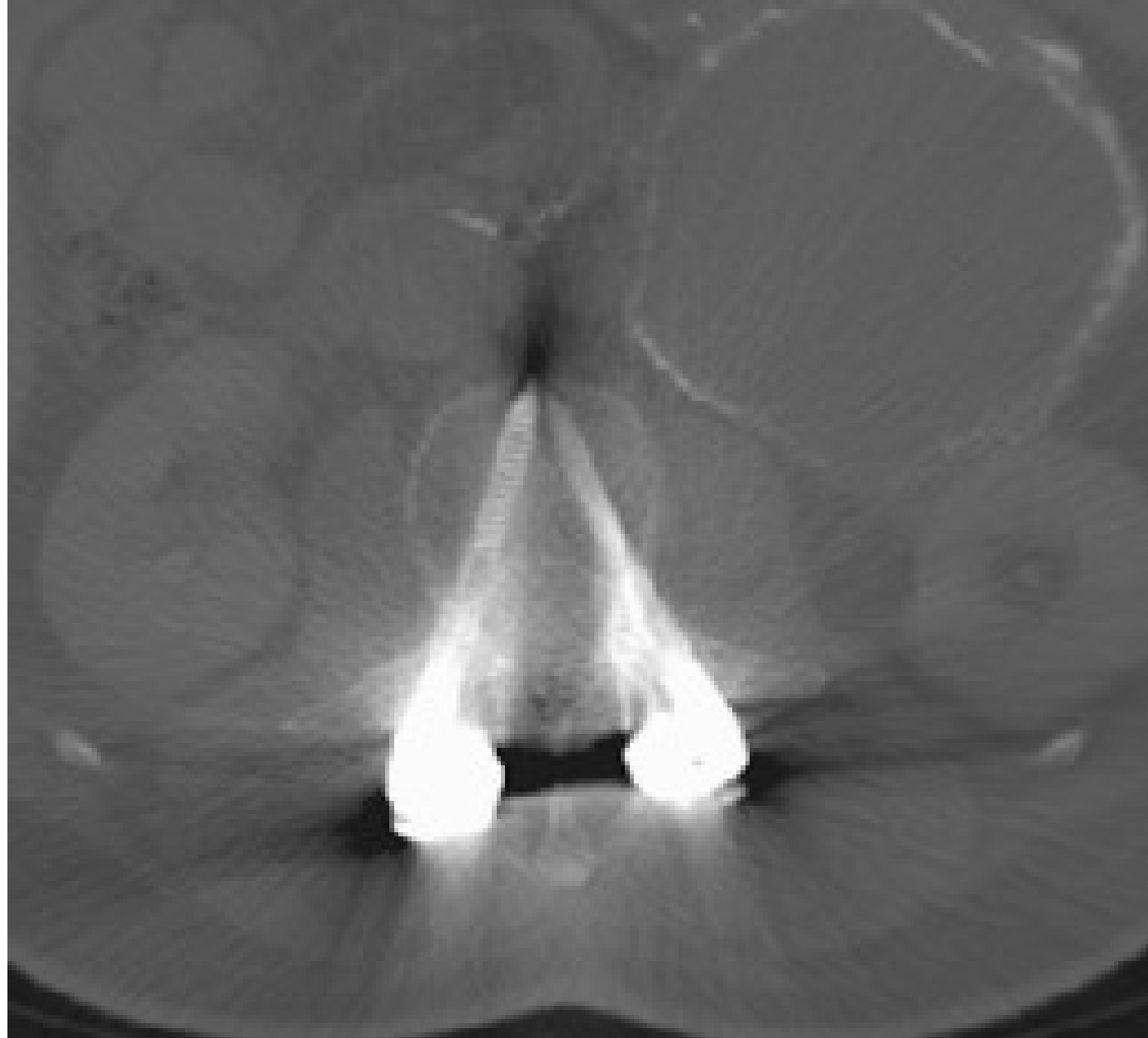

Inserting the TP screws



TRANSPEDICULAR SCREWS:

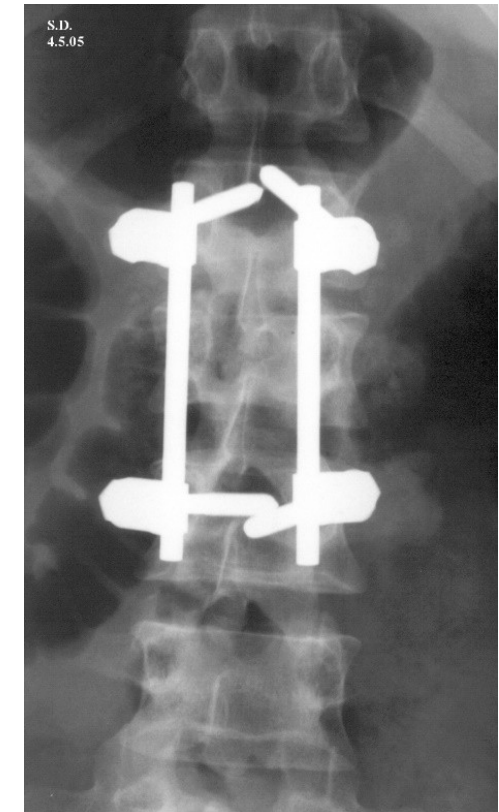
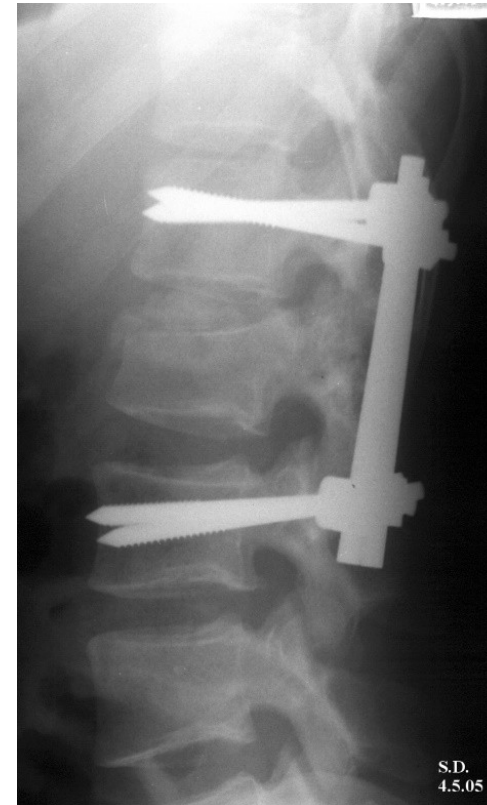
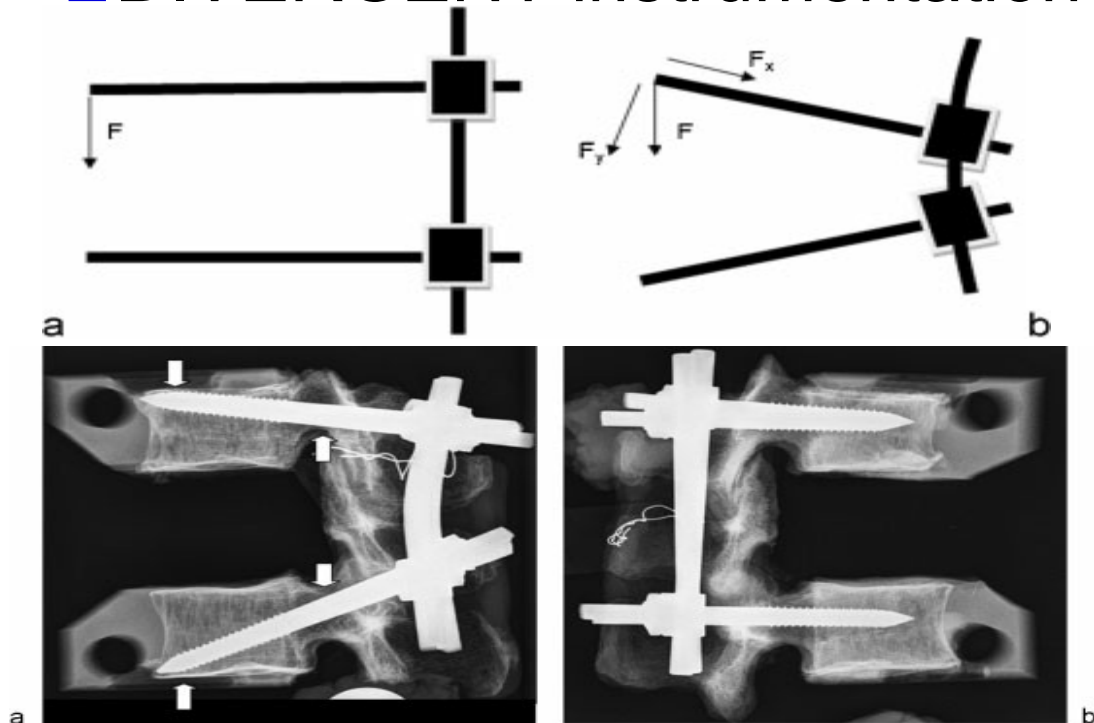
CT scan of correctly inserted screws *in situ*.



V. SURGICAL TREATMENT – posterior approach

– principles of TRANSPEDICULAR fixation:

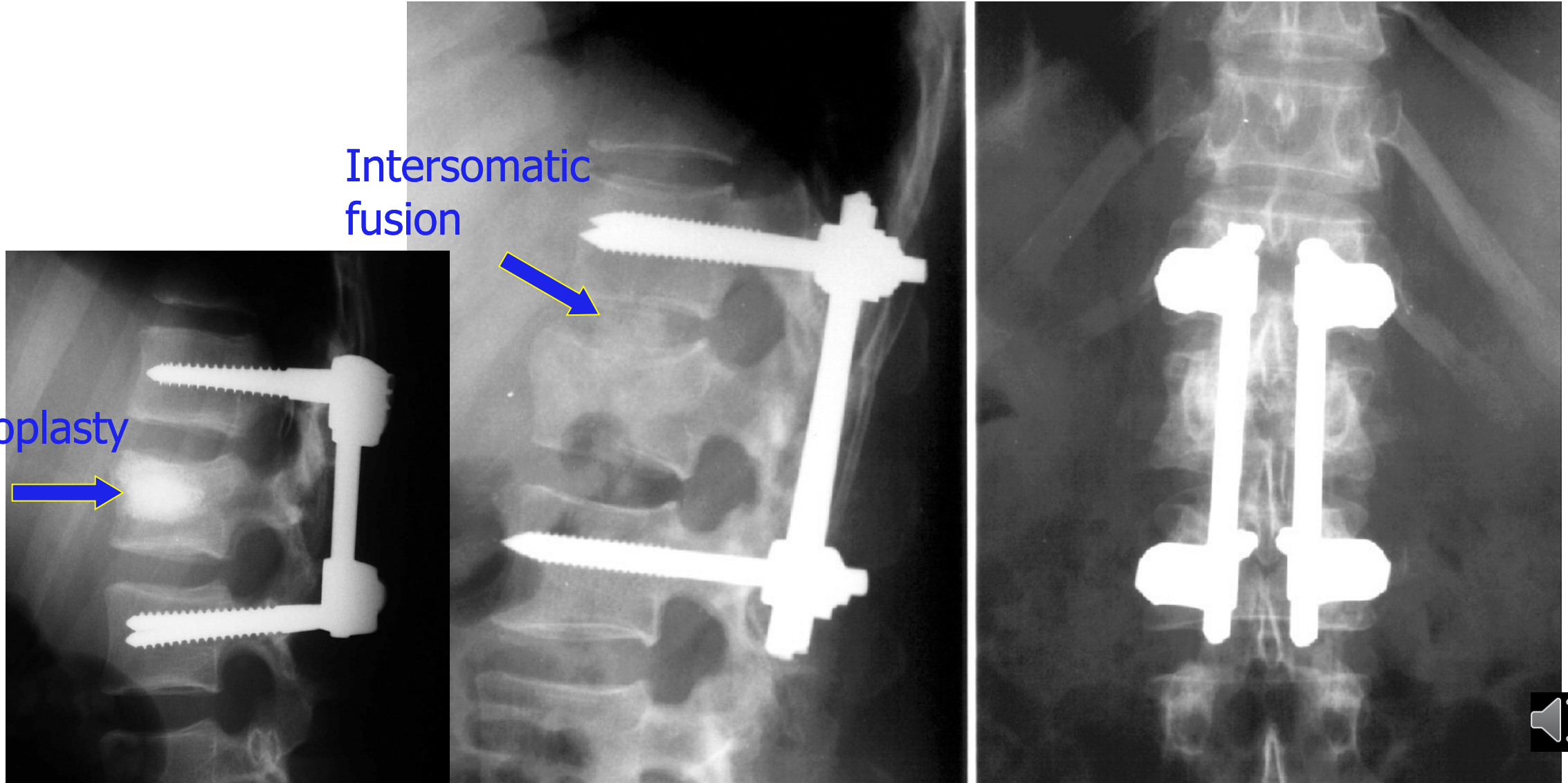
□ DIVERGENT instrumentation



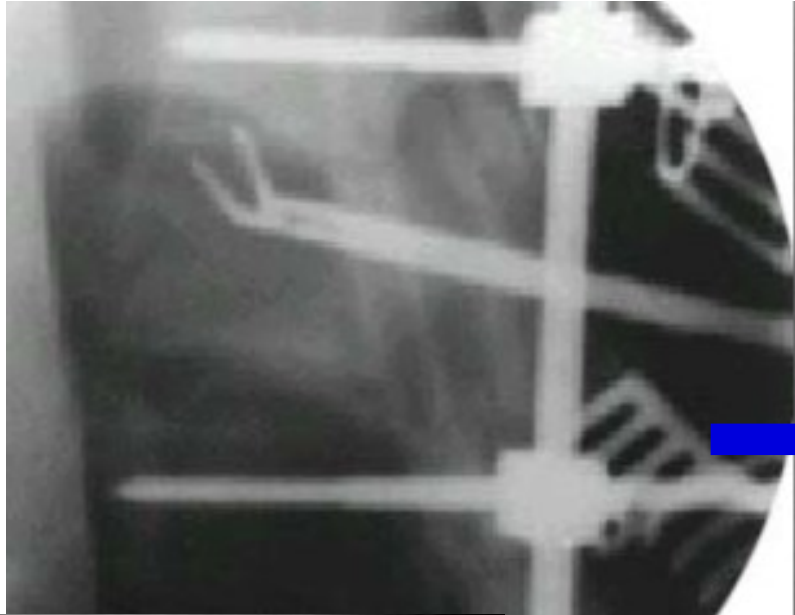
Divergent instrumentation is up to 30% stronger than parallel !

V. SURGICAL TREATMENT T-L SPINE – posterior approach

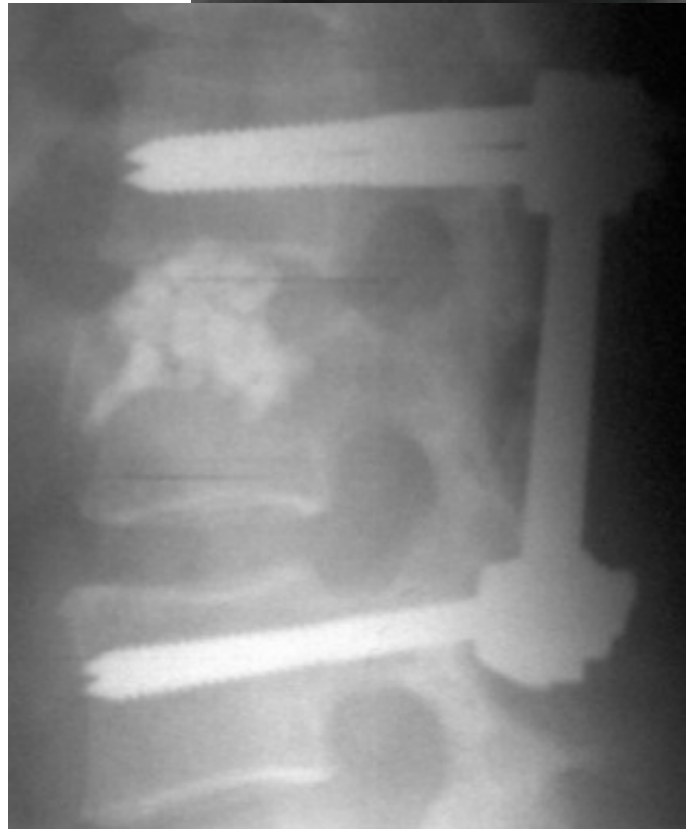– dorsal instrumentation + spondylolplasty:



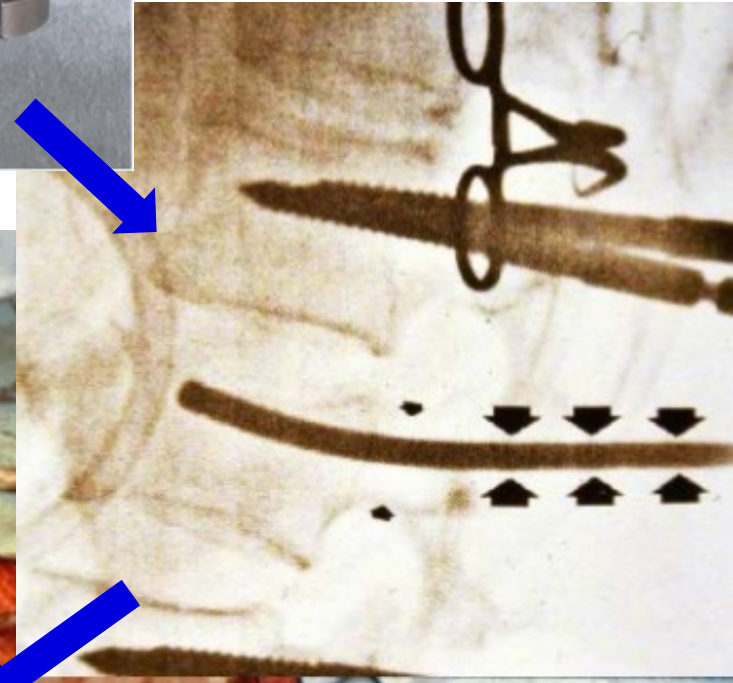
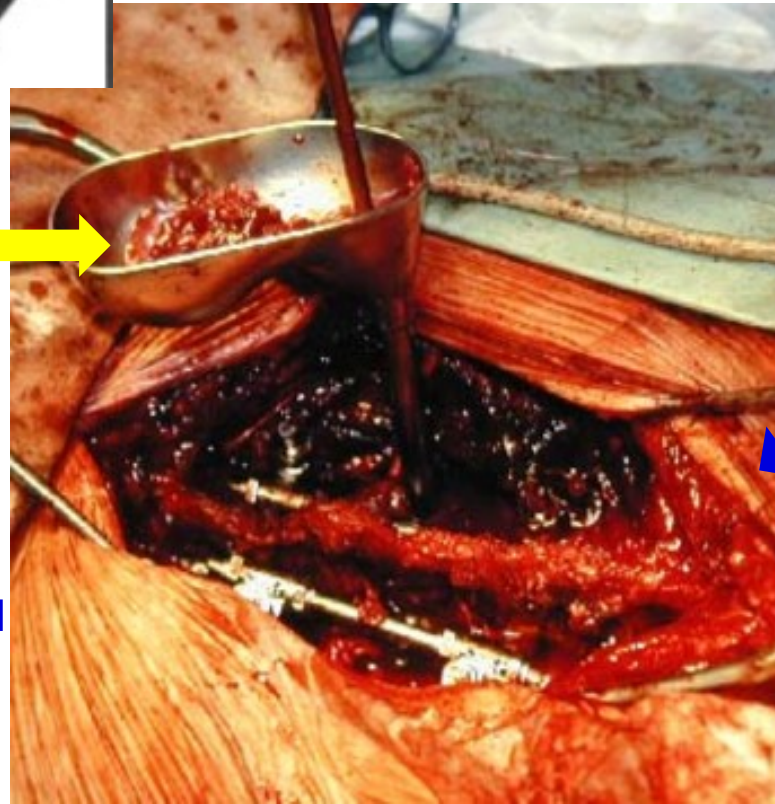
SPONGIO plasty (Daniaux technic)



Kanno H, Aizawa T, Hashimoto K, Itoi E. Enhancing percutaneous pedicle screw fixation with hydroxyapatite granules: A biomechanical study using an osteoporotic bone model. PLoS One. 2019 Sep 26;14(9):e0223106. doi: 10.1371/journal.pone.0223106. eCollection 2019. PubMed PMID: 31557234



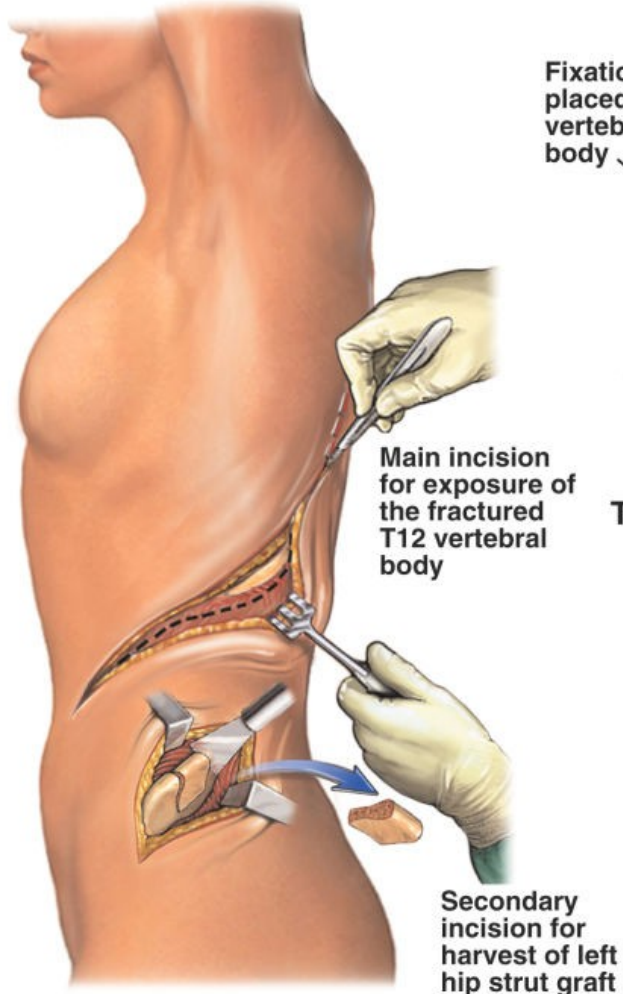
Milled
bone-
graft



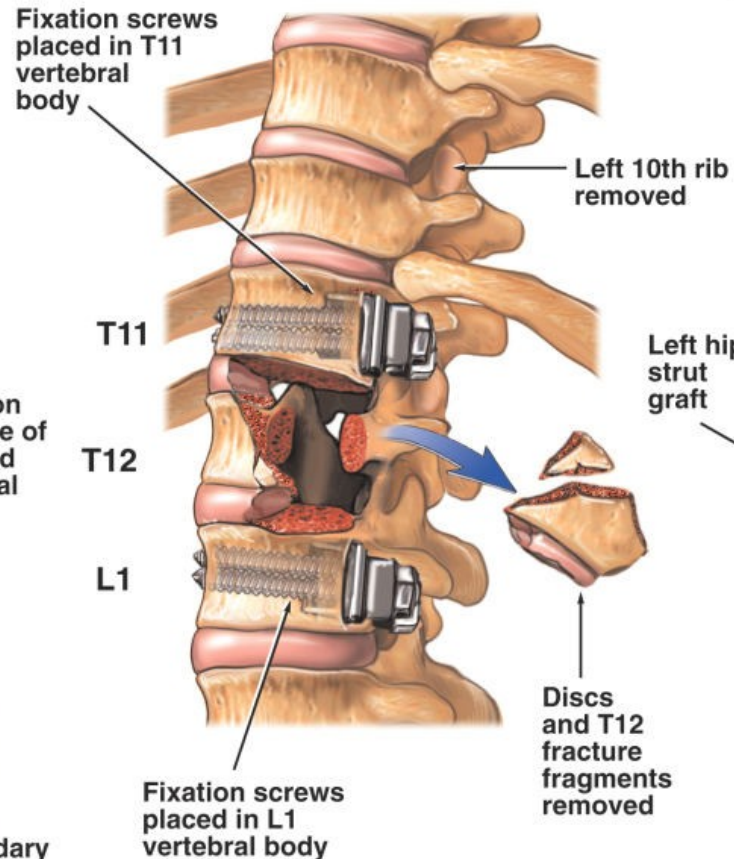
V. SURGICAL TREATMENT T-L SPINE – combined approach

– dorsal instrumentation + ventral spondylectomy with bone strutgraft:

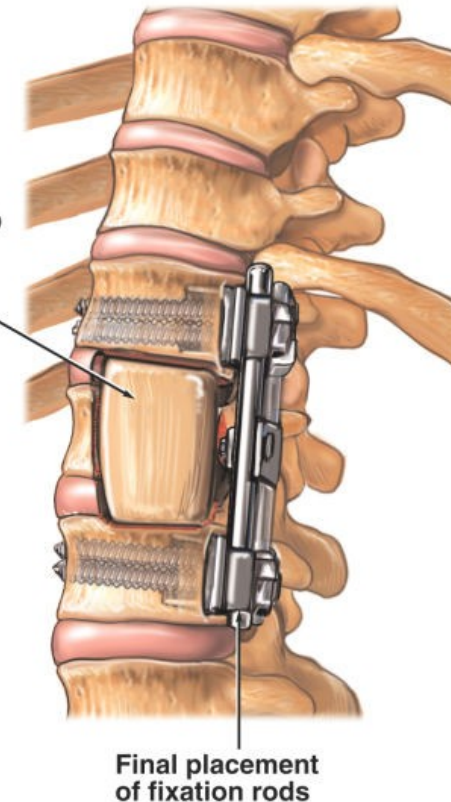
A. Incisions are made to expose the T12 vertebral burst fracture and left hip strut graft harvest site.



B. T11-L1 are exposed for placement of fixation screws, excision of disc material and removal of T12 bone fragments.



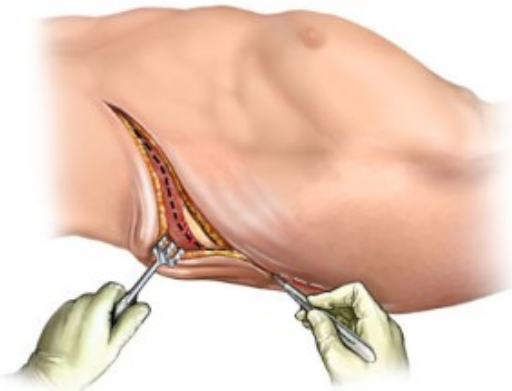
C. The spine is fused utilizing a left hip strut graft and fixation hardware.



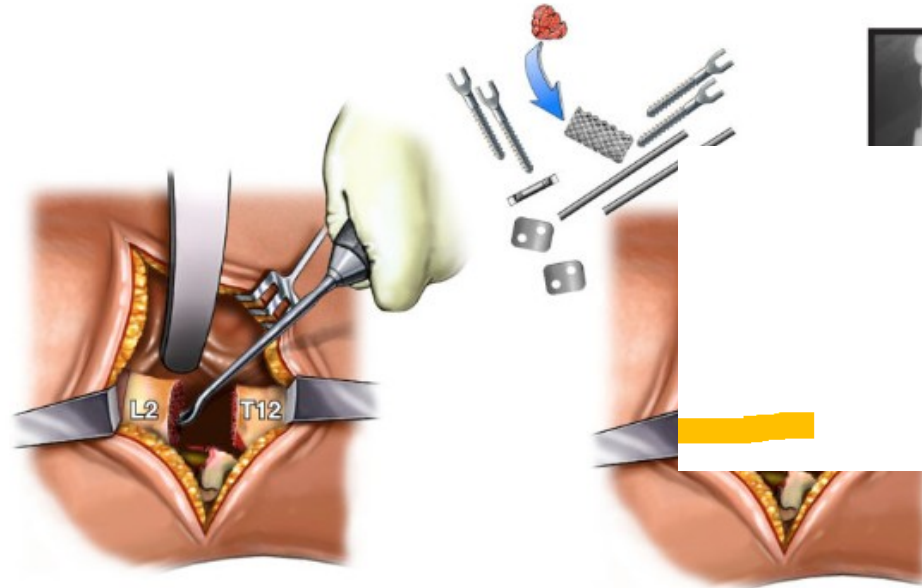
Nucleus Medical Media (2020). *Surgical decompression and stabilization of the spine* [Digital image]. Retrieved from <https://ebSCO.smartimagebase.com/surgical-decompression-and-stabilization-of-the-spine/view-item?ItemID=76291>

V. SURGICAL TREATMENT T-L SPINE – anterior approach

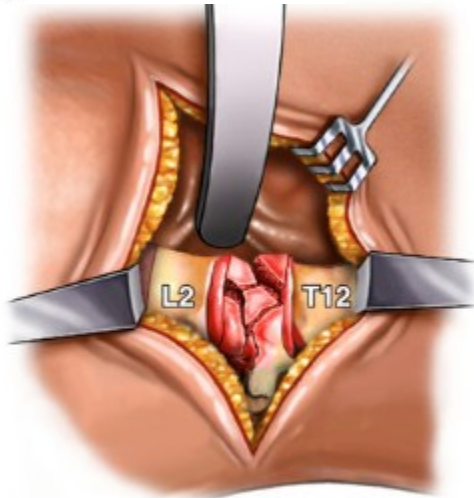
– ventral instrumentation + augmentation of ventral column (Harm's cage vs. Implant):



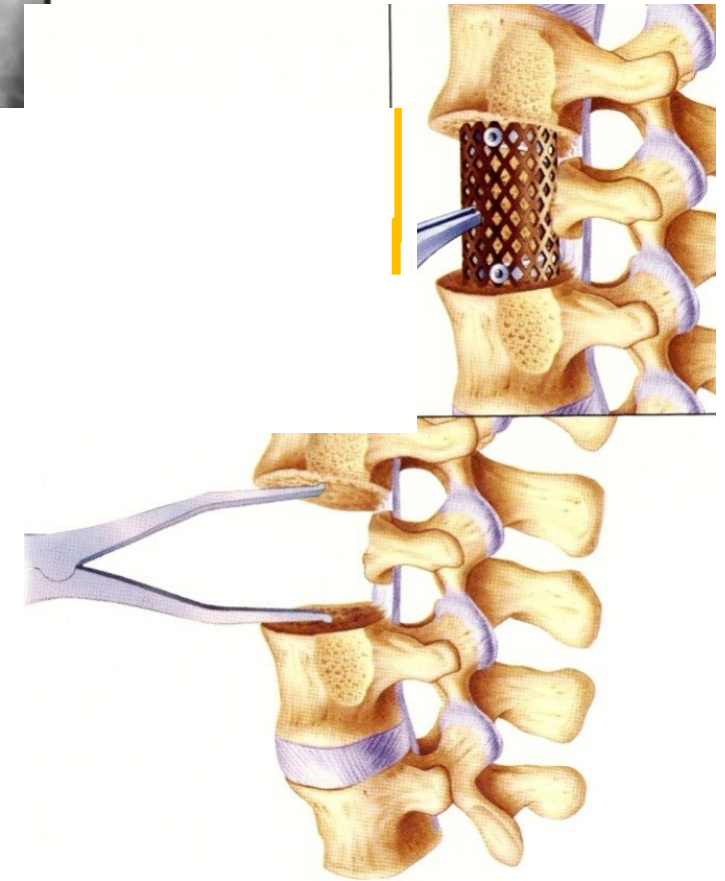
A. An incision is made over the eleventh rib on the left side of the body.



C. The fractured vertebral body of the first lumbar vertebra is removed. The endplates of the adjacent vertebrae are scraped with a curette.



B. The rib is resected and the first lumbar vertebra is exposed.

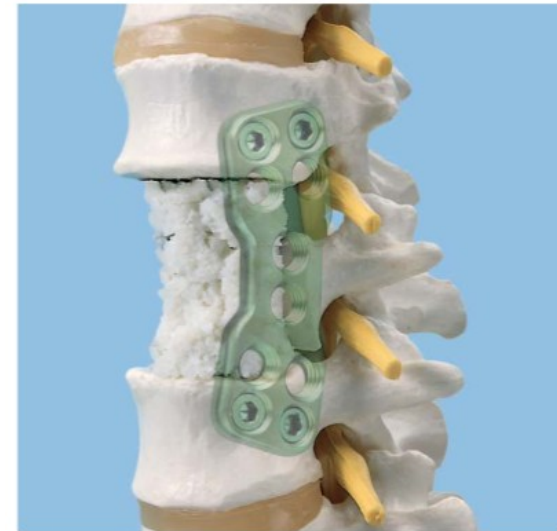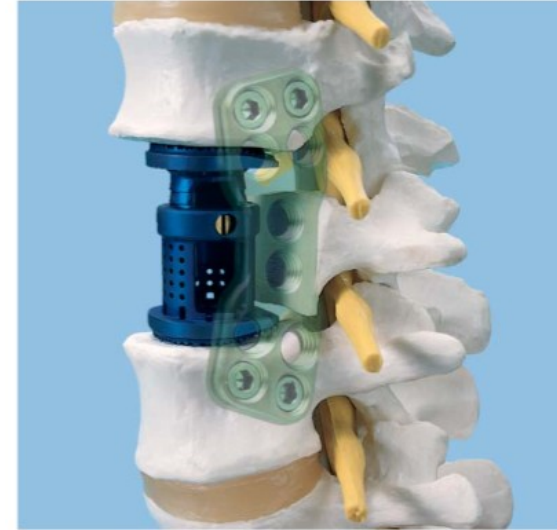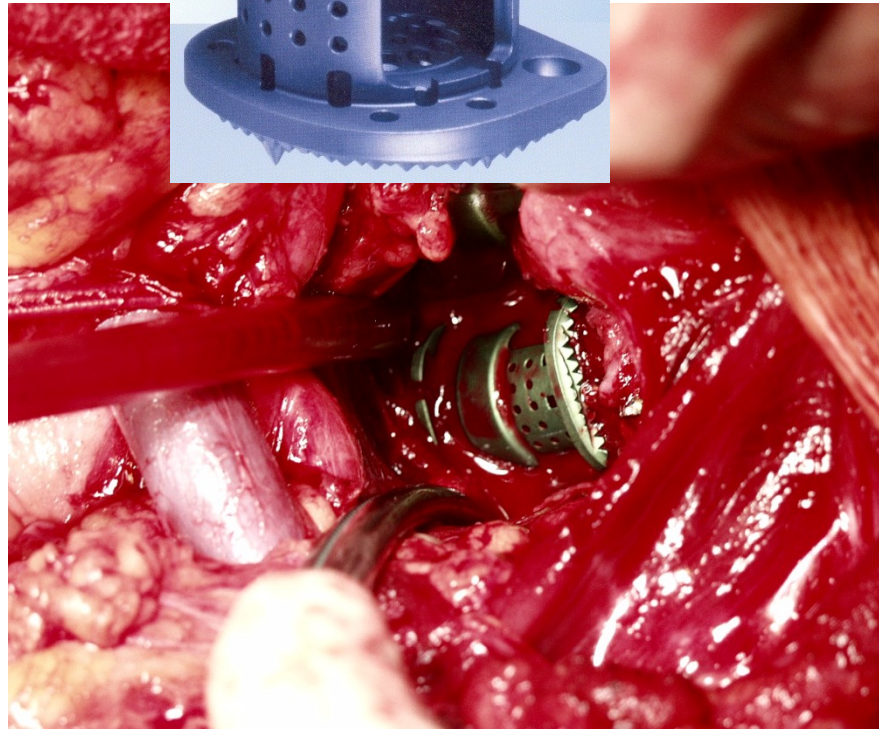


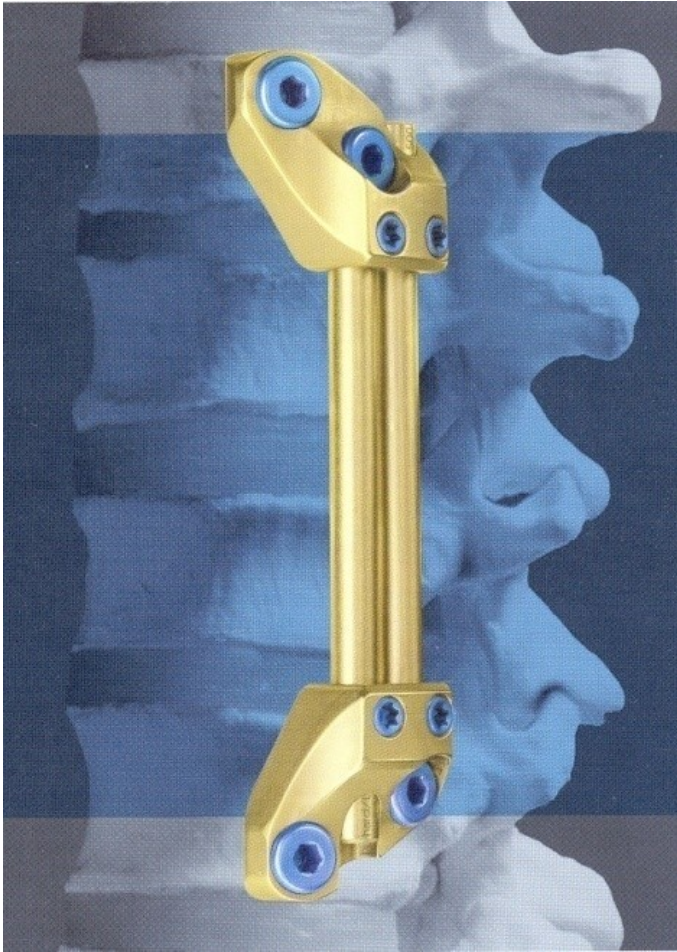D. A cage is filled with bone graft. The cage is inserted into the L1 disc space. Plates, rods and screws are then inserted to connect the L2 vertebra to the T12 vertebra.

Nucleus Medical Media (2020). *Lumbar spine fracture with surgical repair* [Digital image]. Retrieved from <https://ebSCO.smartimagebase.com/lumbar-spine-fracture-with-surgical-repair/view-item?ItemID=11652>

V. SURGICAL TREATMENT T-L SPINE – anterior approach

– ventral instrumentation + augmentation of ventral column (Harm's cage vs. Implant):



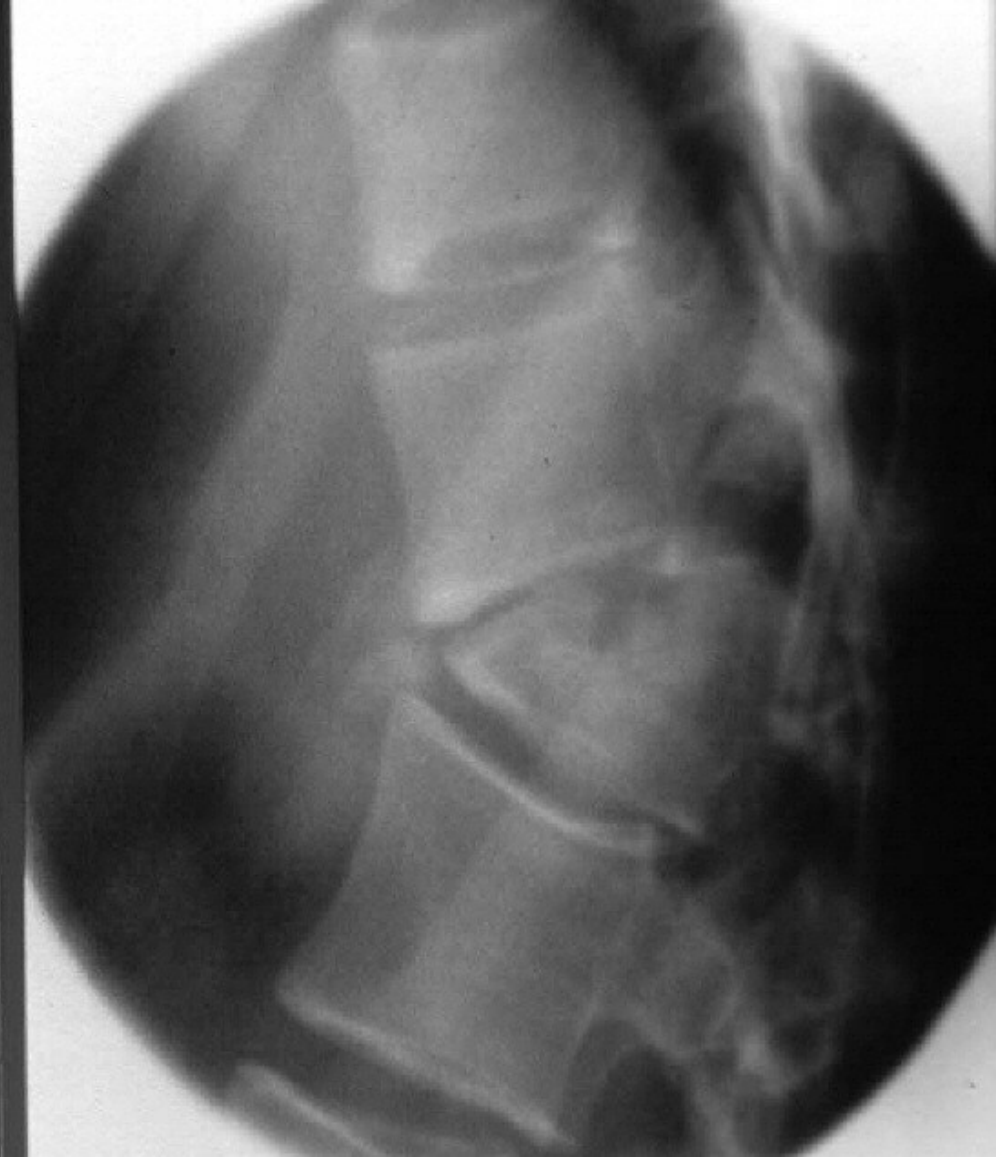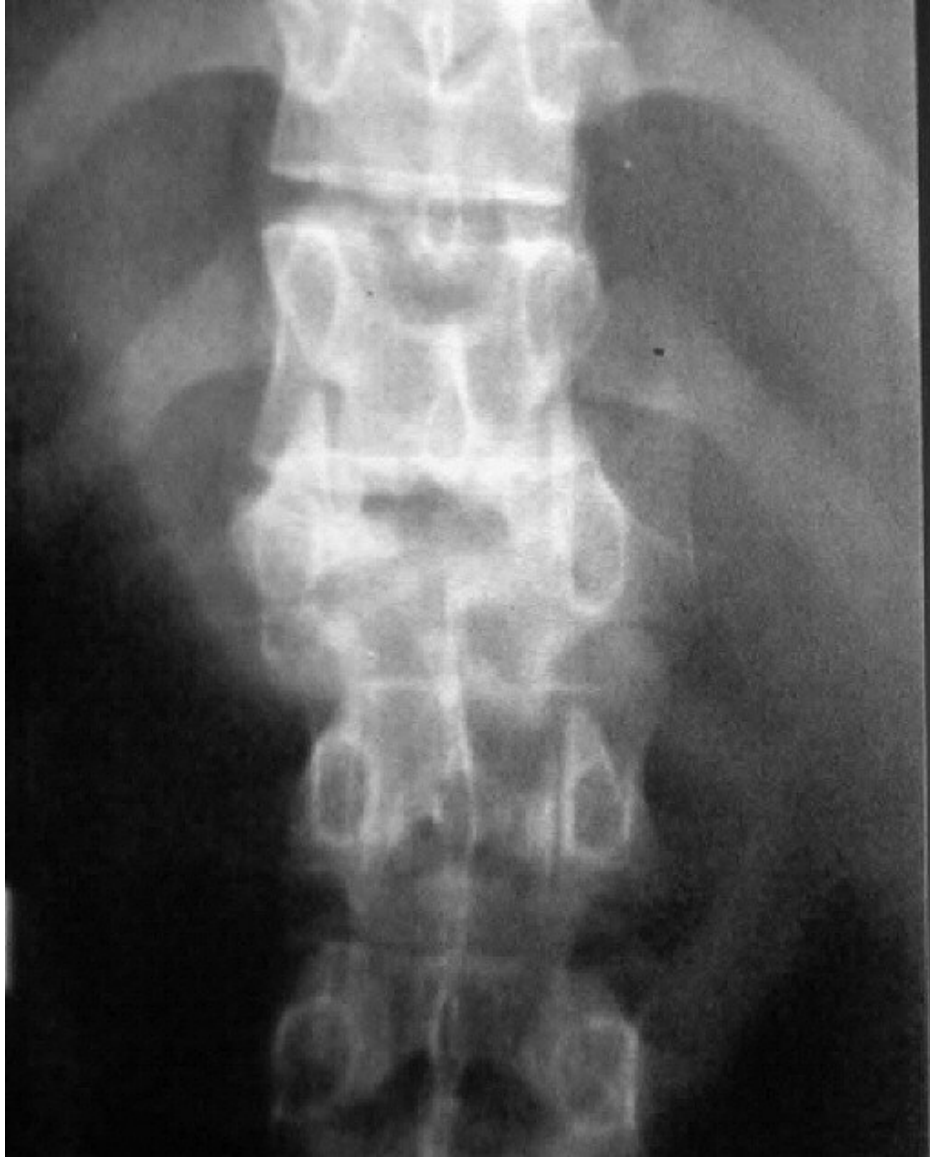Instruments and implants
approved by the AO Foundation

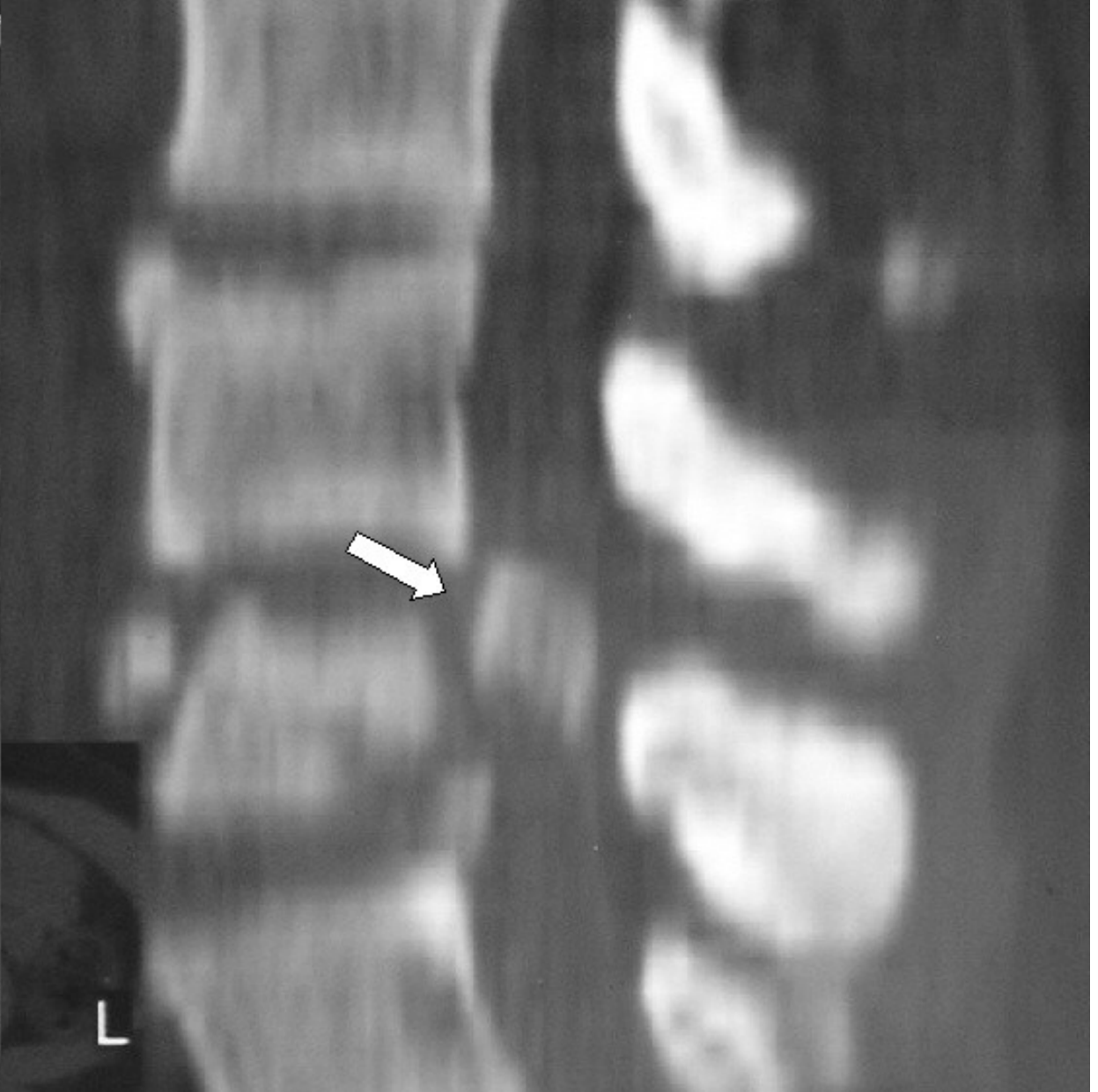
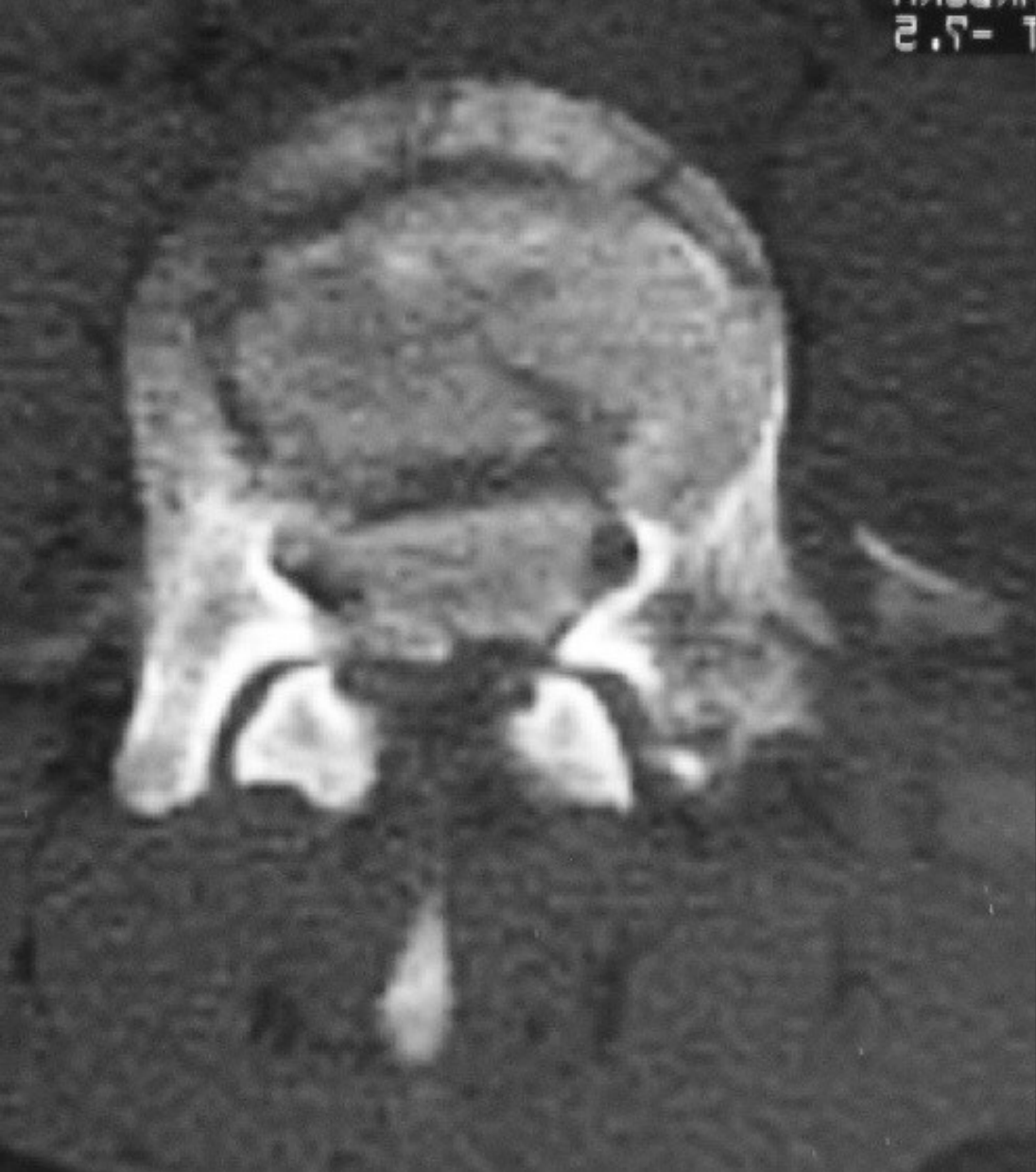SYNTHES
Spine

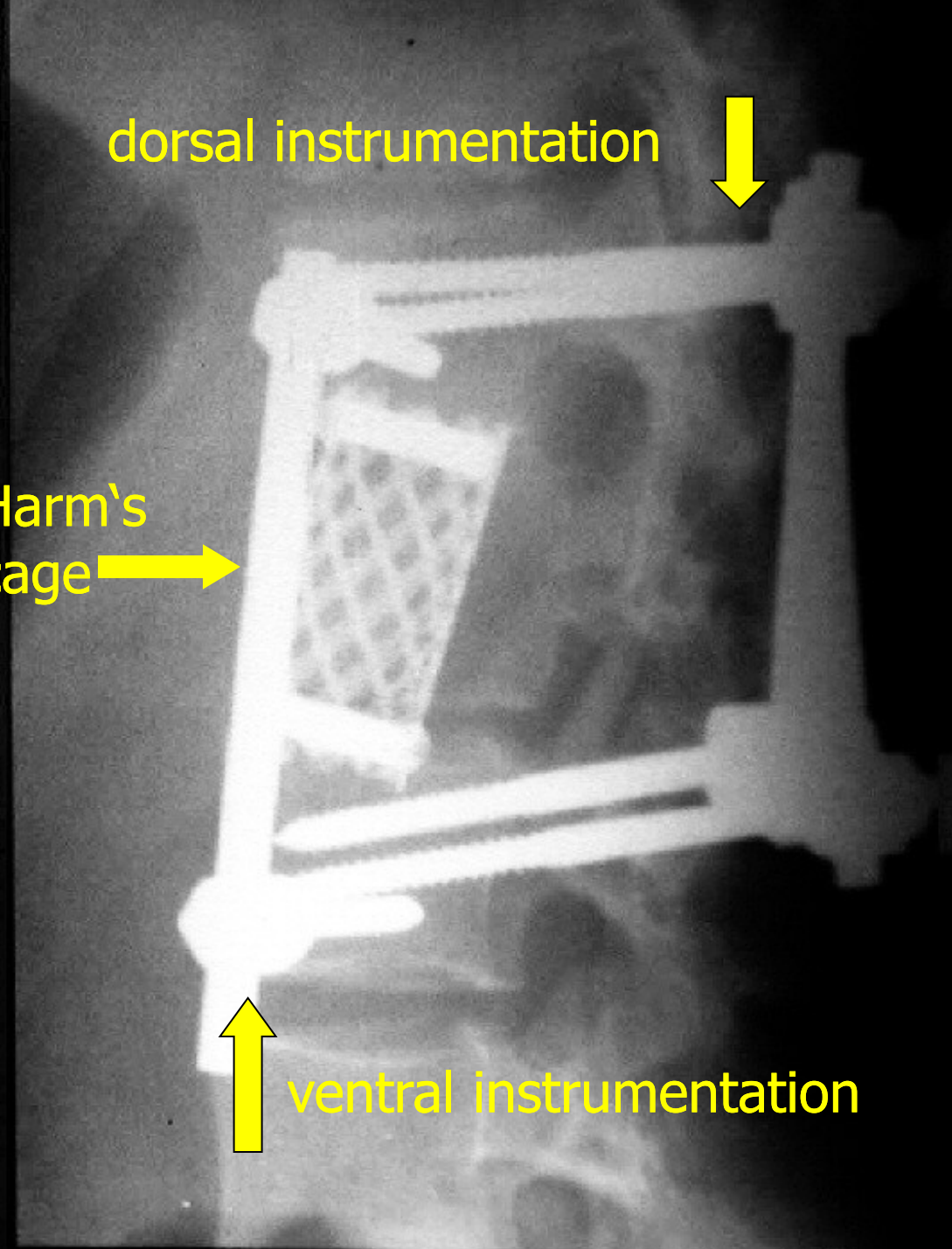
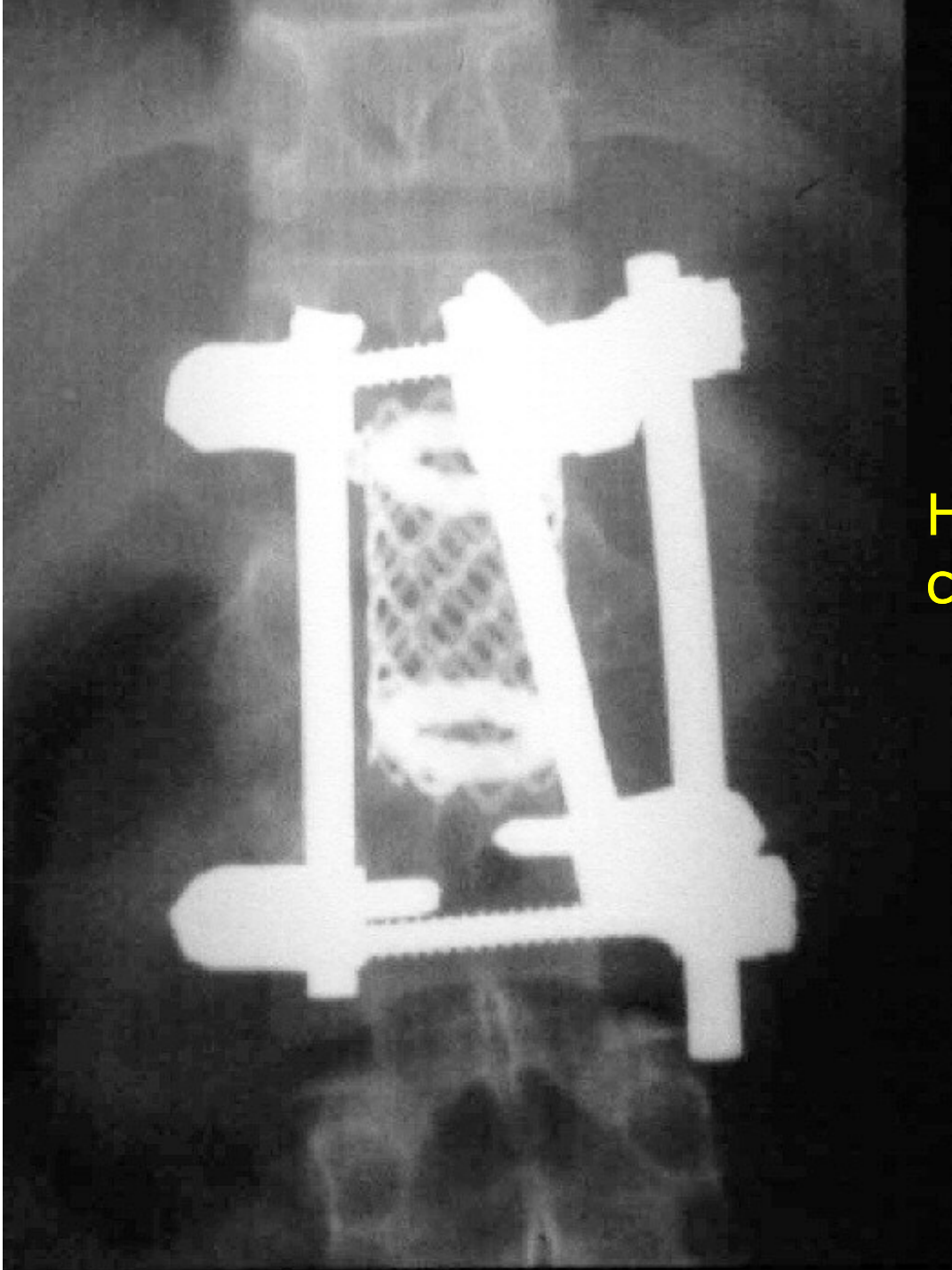
MUNT
MED 

V. SURGICAL TREATMENT T-L SPINE – combined approach

– dorsal + ventral instrumentation + ventral column augmentation:







dorsal instrumentation



Harm's cage

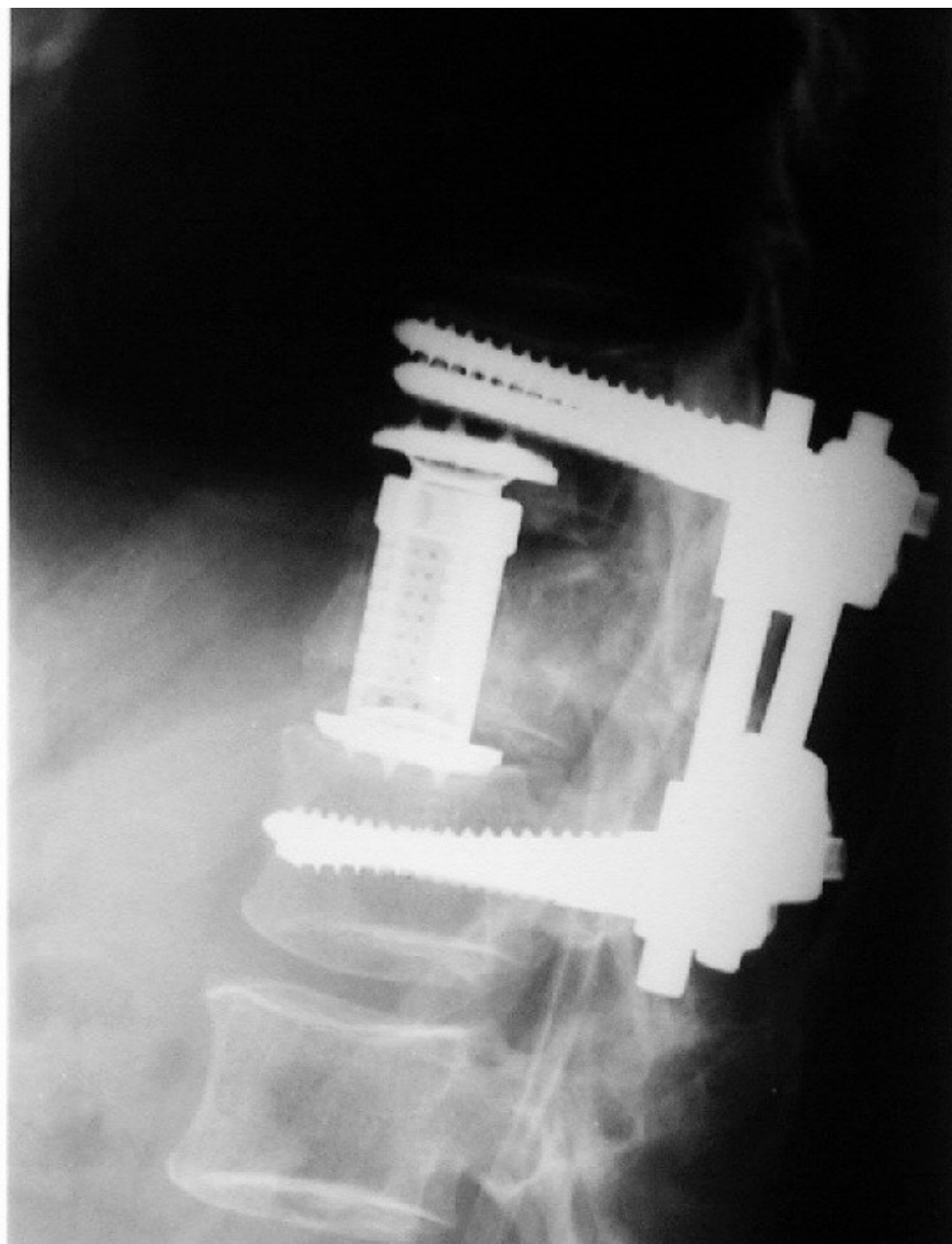
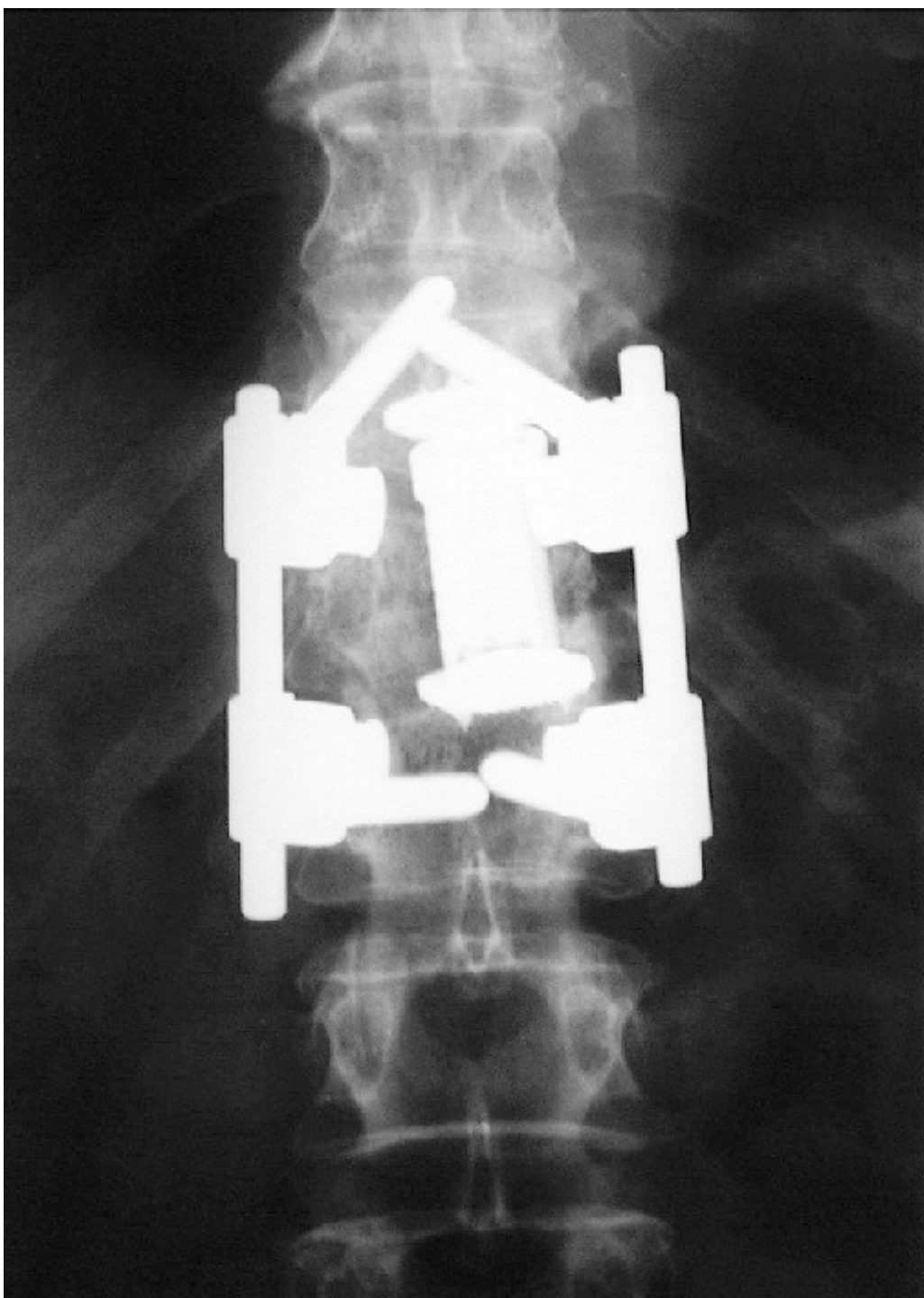


ventral instrumentation



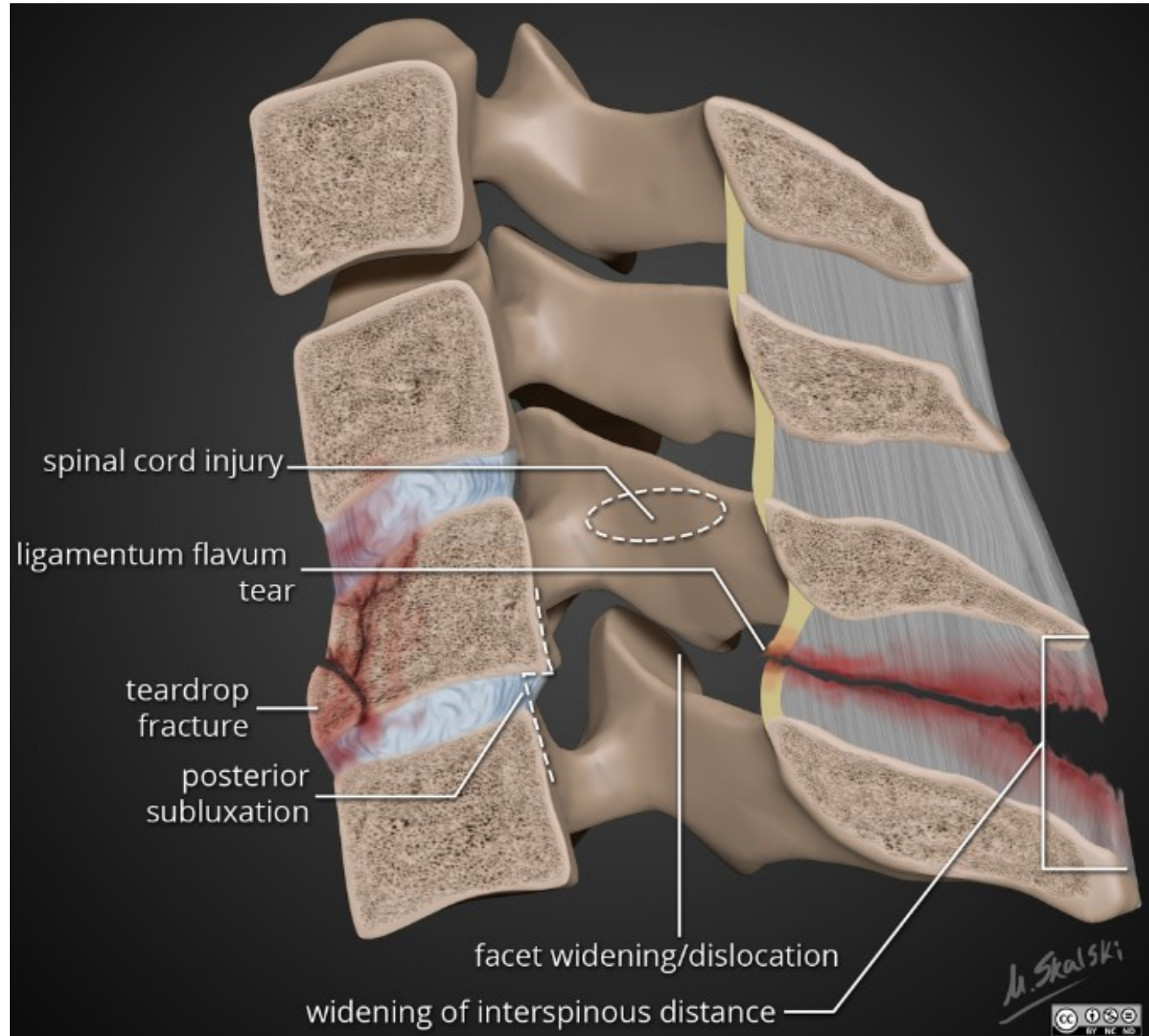
Synex -
expandable
implant





CERVICAL SPINE INJURY

- Comminutive fr. of the body
- discoligamentous lesions
disks and ligament
- Combined - tear drop



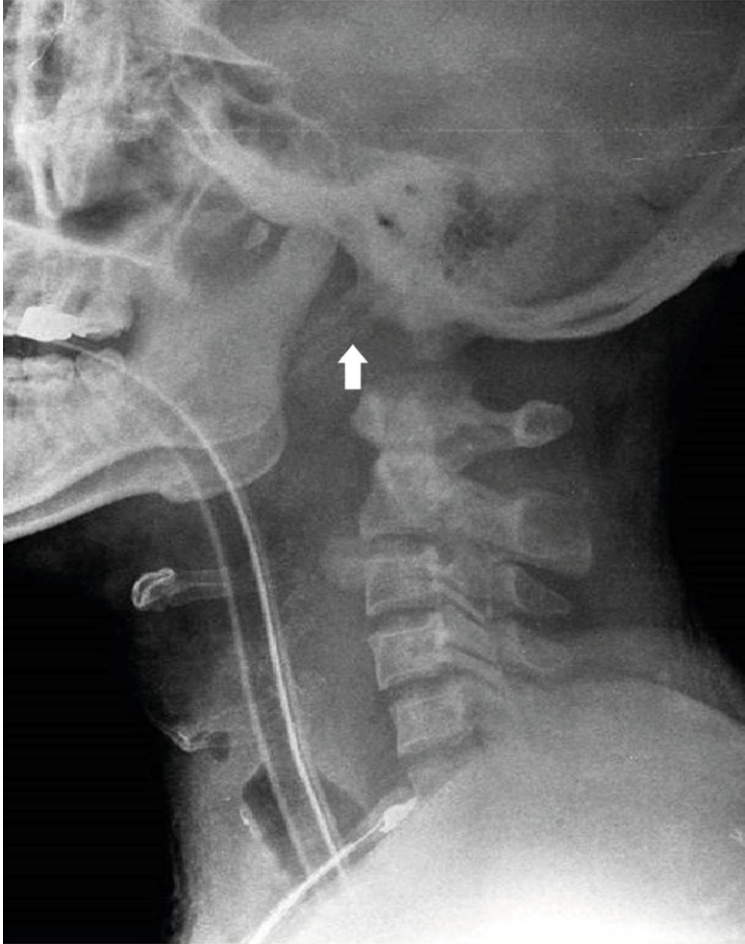
radiopaedia.org/cases/flexion-teardrop-fracture-illustration?lang=us

INJURY OF THE UPPER C-SPINE

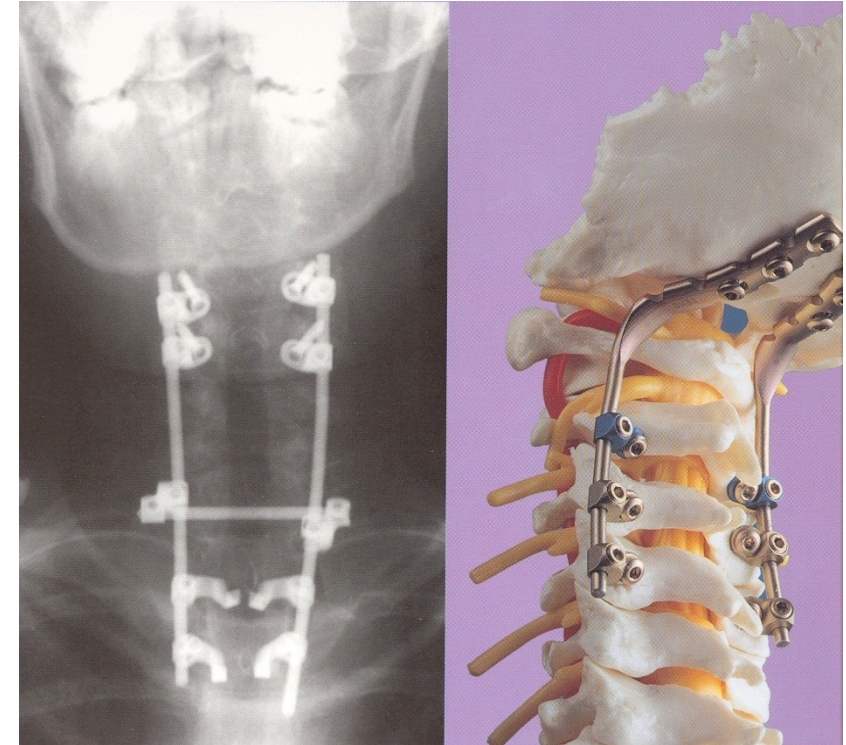
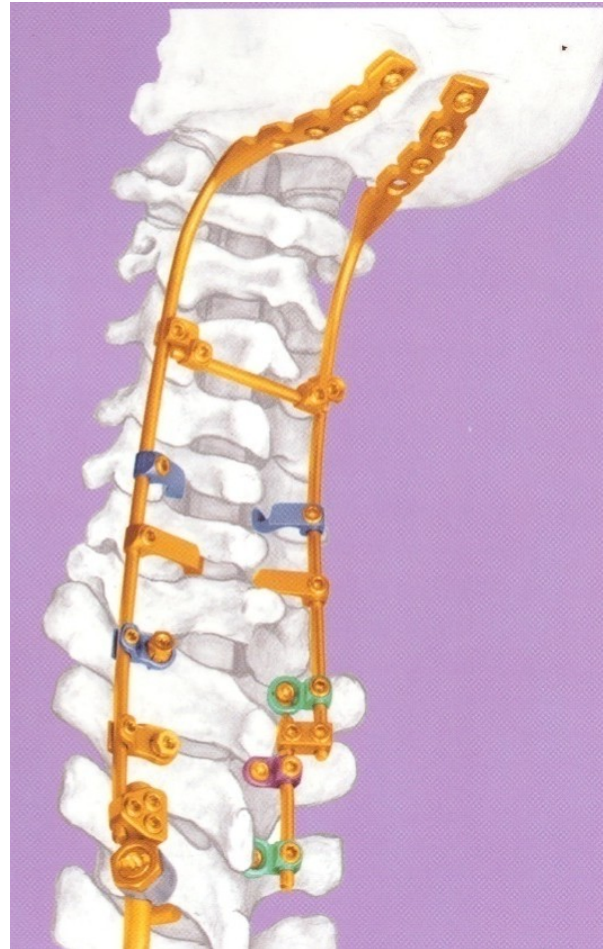- fractures of condyles of occipital bone (C0)
- atlantooccipital dislocations (C0-C1)
- atlas fractures (C1)
- atlantoaxial dislocations (C1-C2)
- fractures of the epistropheum (C2)

V. SURGICAL TREATMENT – UPPER C- SPINE

– atlantooccipital dislocation : Dorsal O-C fusion



Korean J Neurotrauma. 2019 Apr;15(1):55-60.
<https://doi.org/10.13004/kjnt.2019.15.e3>

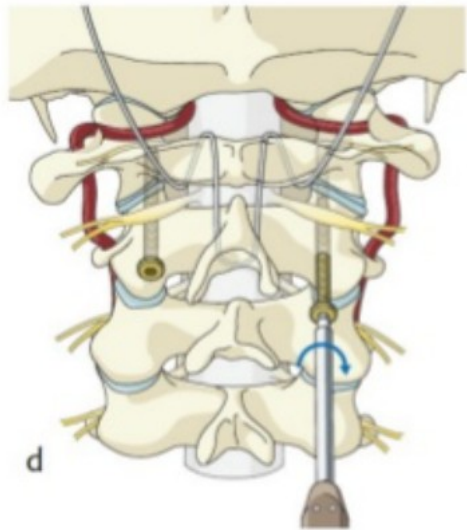


Synthes
CerviFix

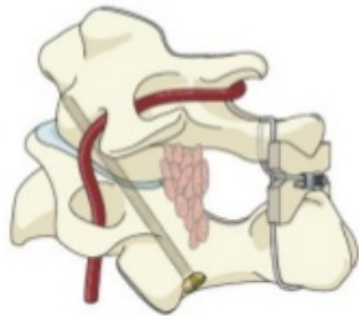
V. SURGICAL TREATMENT UPPER C- SPINE:

– atlas fractures (disruption of transvers ligamnet):

atlantoaxial screw fixation and fusion (Magerl C1 and C2 transfacet screw technique)

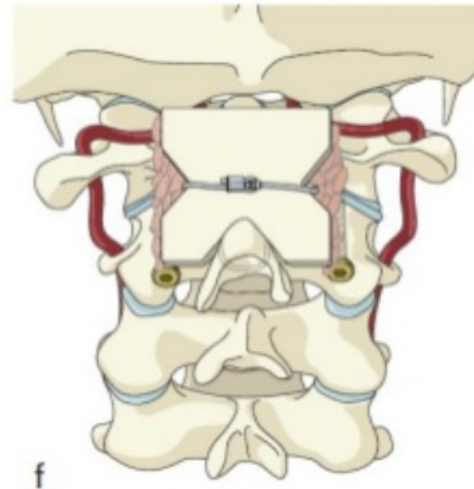


Screwing



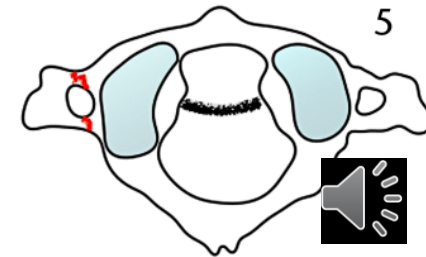
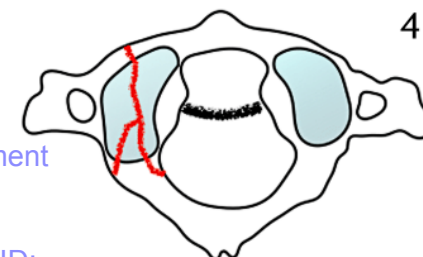
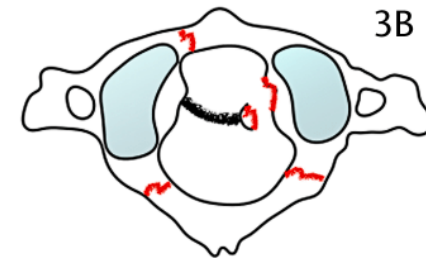
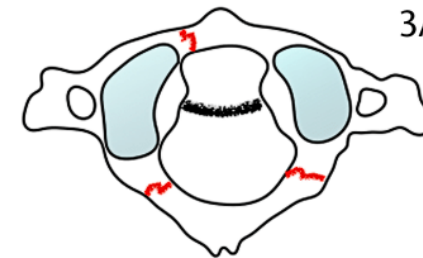
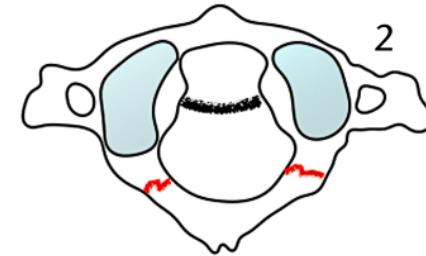
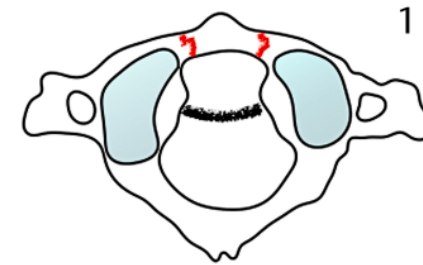Sagittal plane

Posterior 3rd of C1/2 joint
(50° cephalad)



Iliac bone graft

Gehweiler classification (1980)



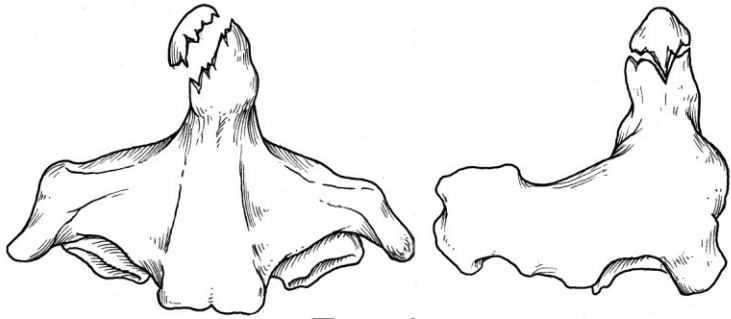
Jefferson's fr. = **type 3A** (stable), **3B** (unstable) !!

Types 1,2,4,5 – non-operatively

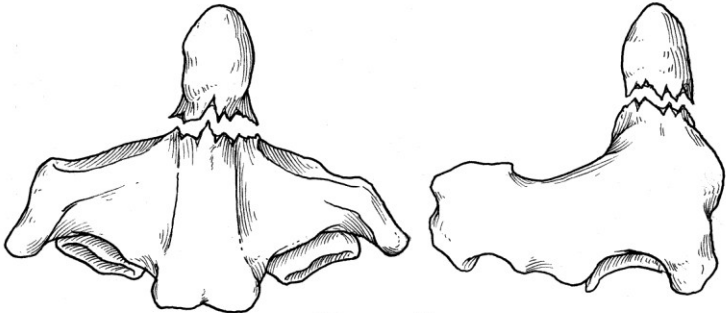
Schleicher P, Pingel A, Kandziara F. Safe management of acute cervical spine injuries. EFORT Open Rev. 2018 May 21;3(5):347-357. doi: 10.1302/2058-5241.3.170076. eCollection 2018 May. PubMed PMID: 30054074



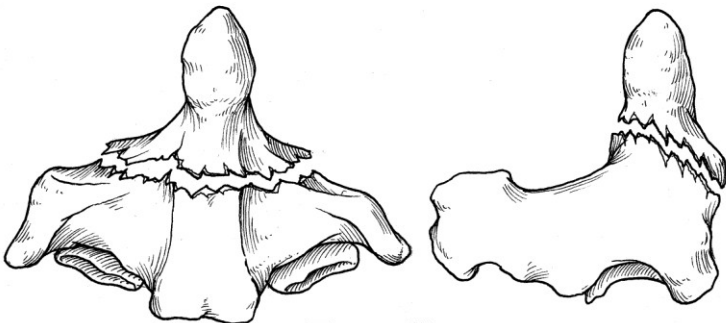
ODONTOID FRACTURES OF C2



Type I



Type II



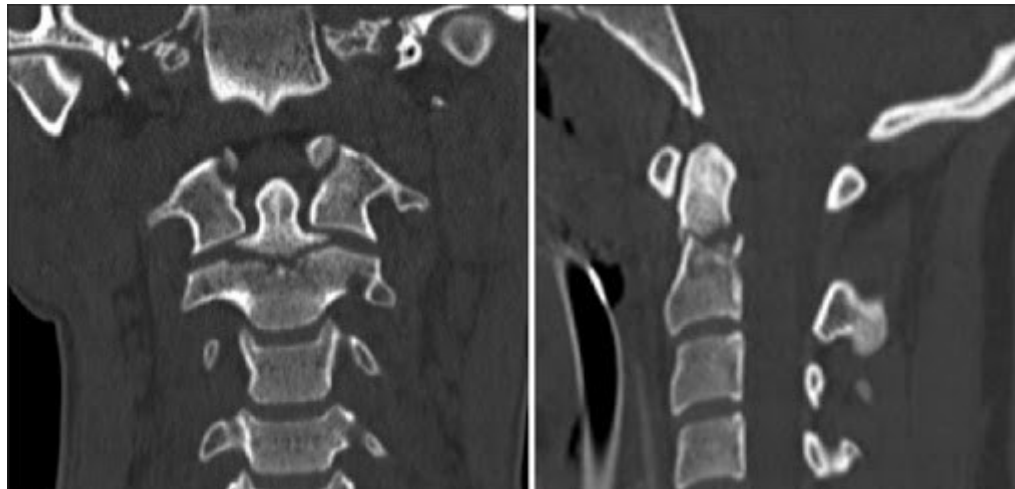
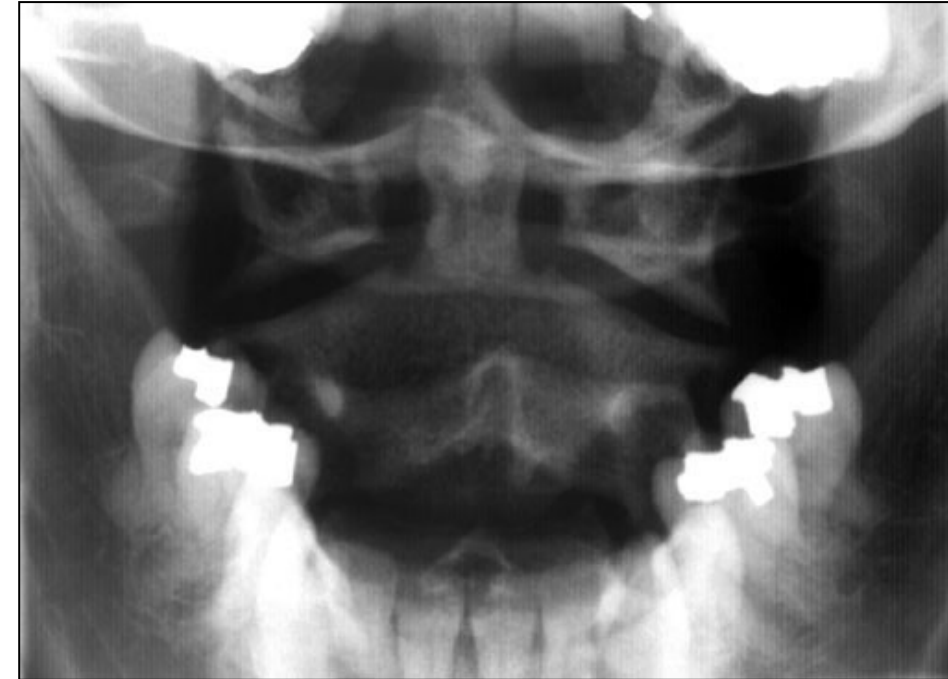
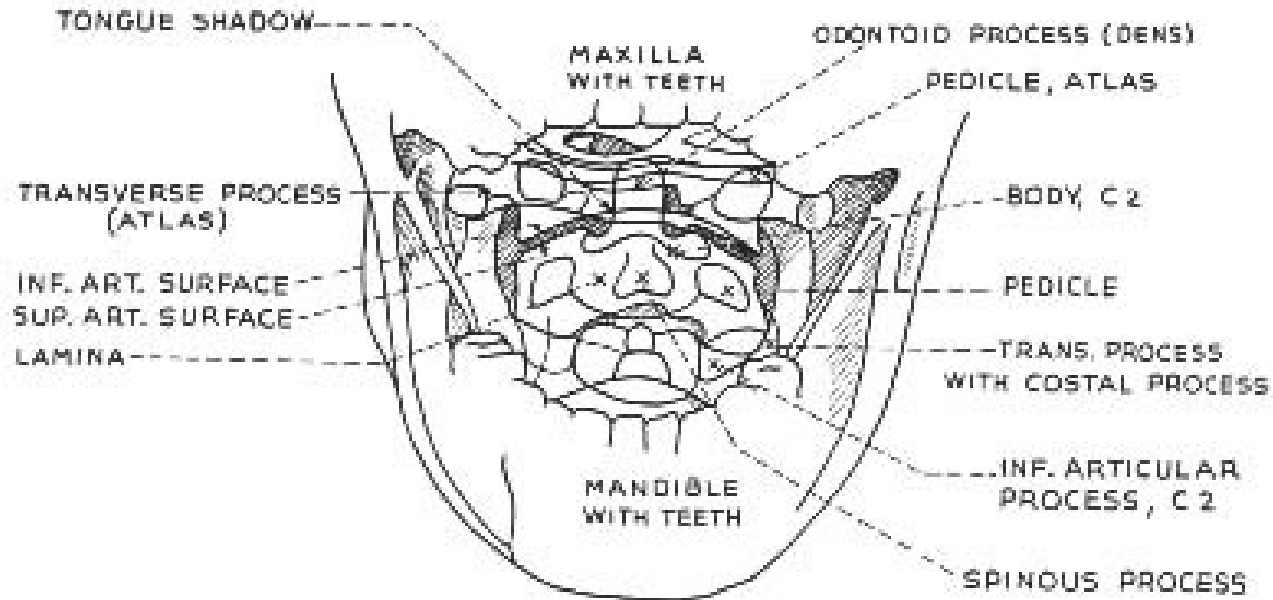
Type III

Anderson and D'Alonzo Classification of Odontoid Fractures

Type II = NECESSITY OF SURGERY especially:

- In pts age > 50 (high risk of non-union)
- Fracture displacement \geq 5mm
- Neurological deficit
- Comminution

Transoral (Sandberg) projection

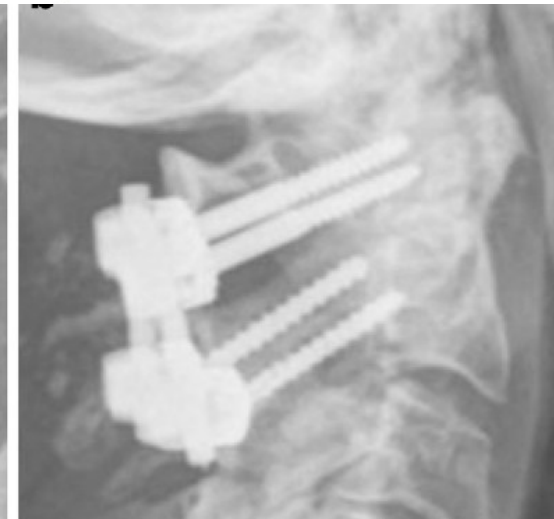
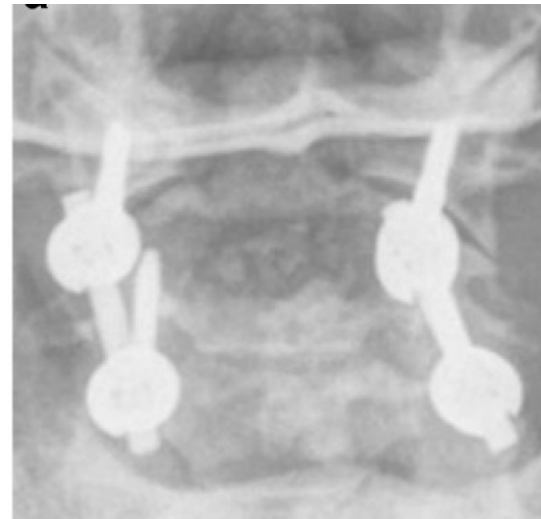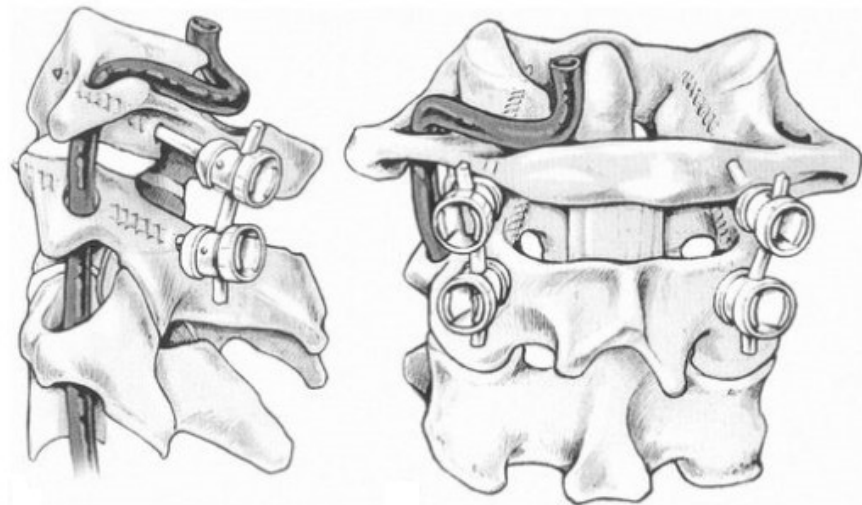
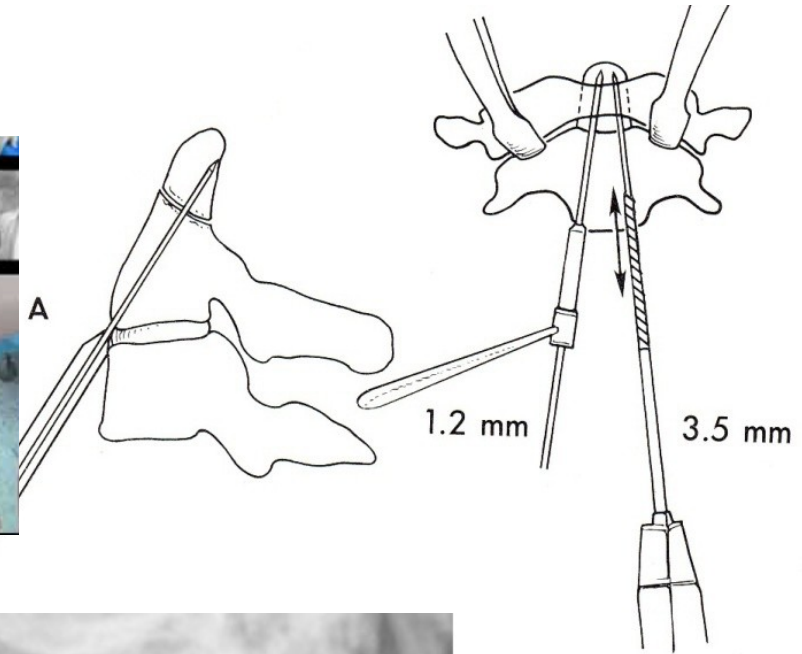
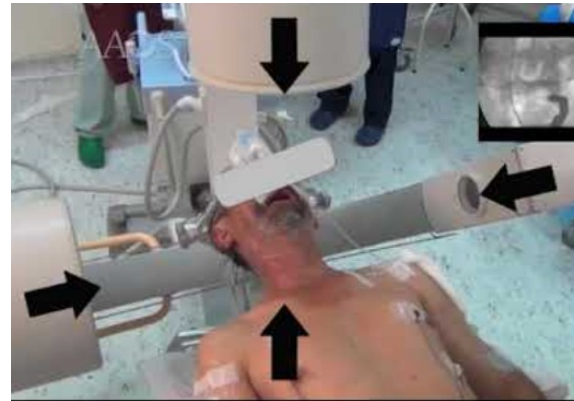
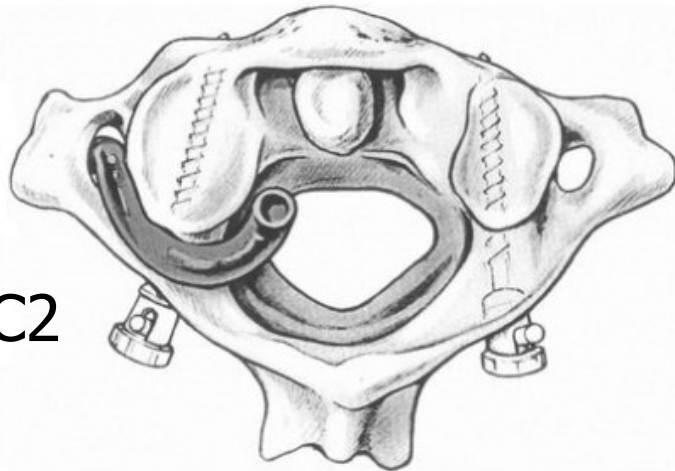


V. SURGICAL TREATMENT UPPER C- SPINE

– fractures of the epistropheum : dorsal / ventral approach

ODONTOID FRACTURES OF C2

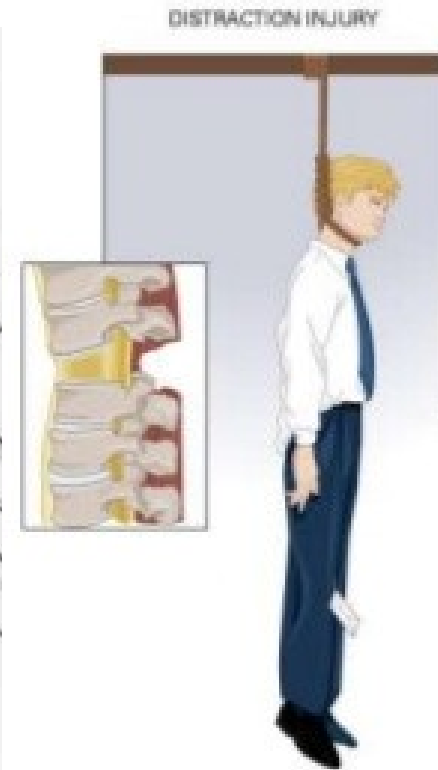
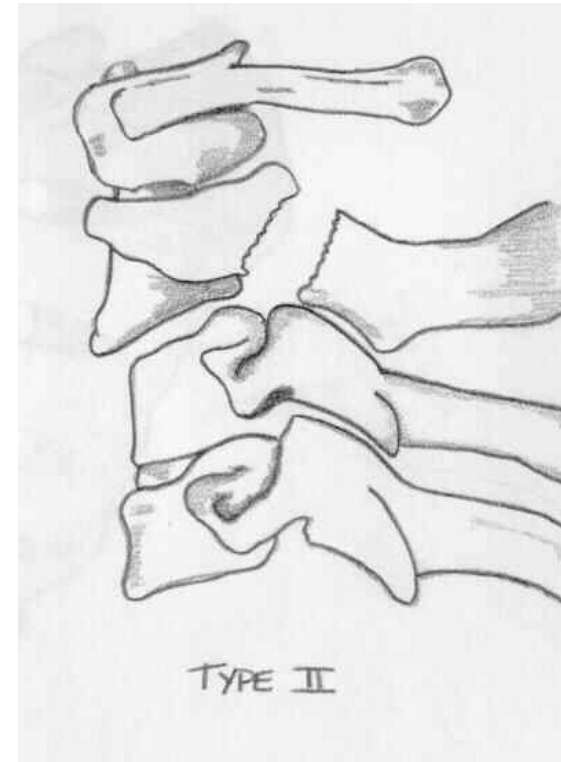
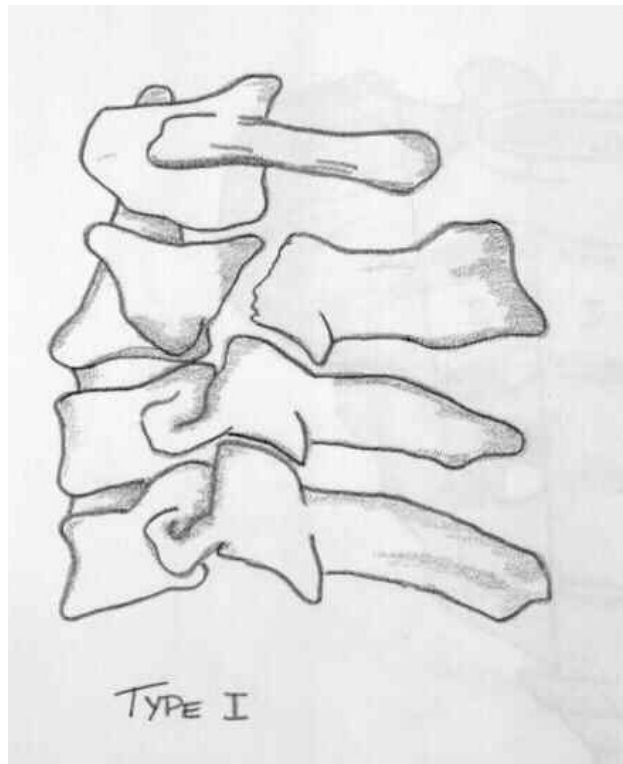
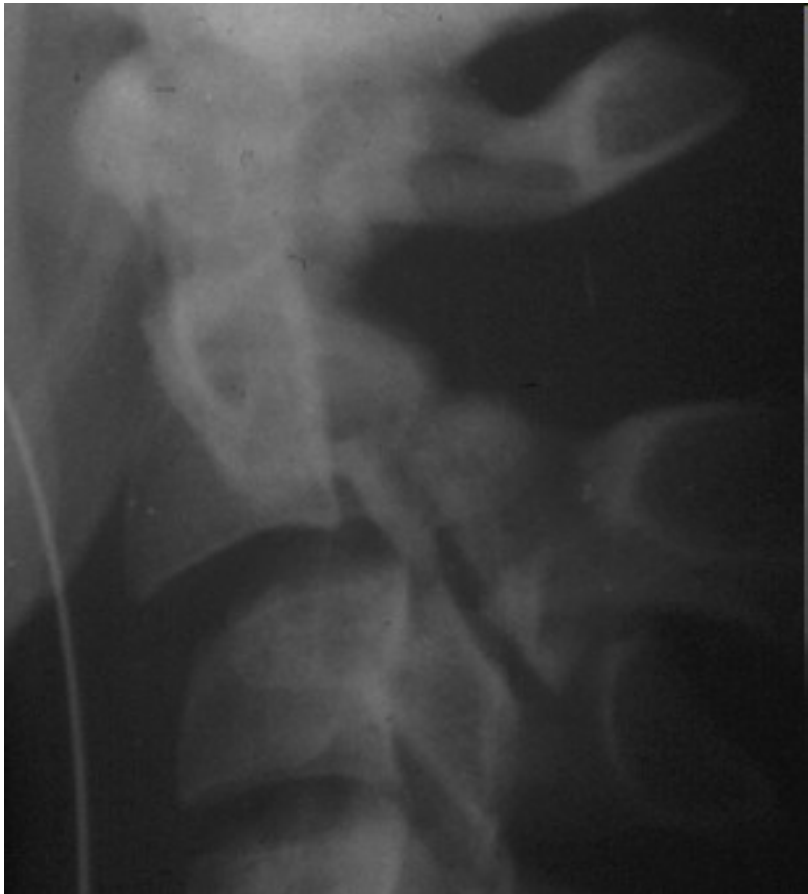Harm's C1-C2
construct

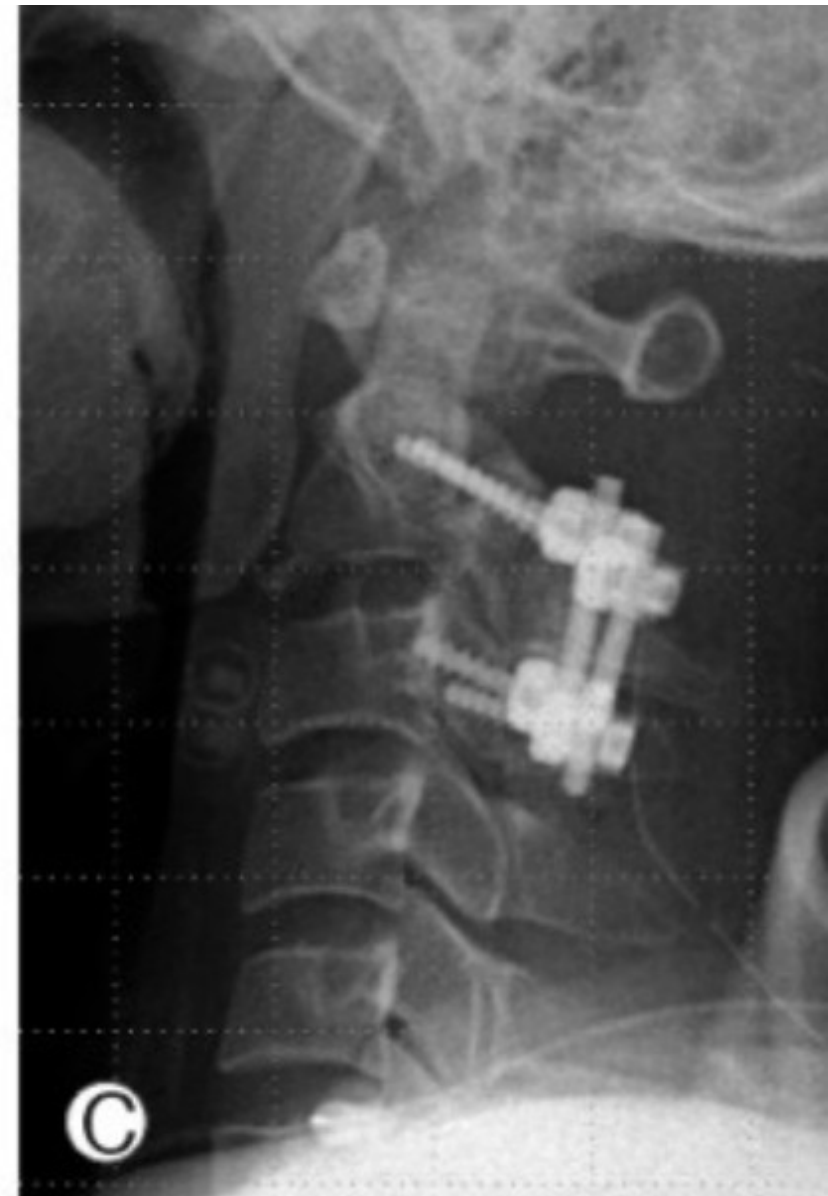
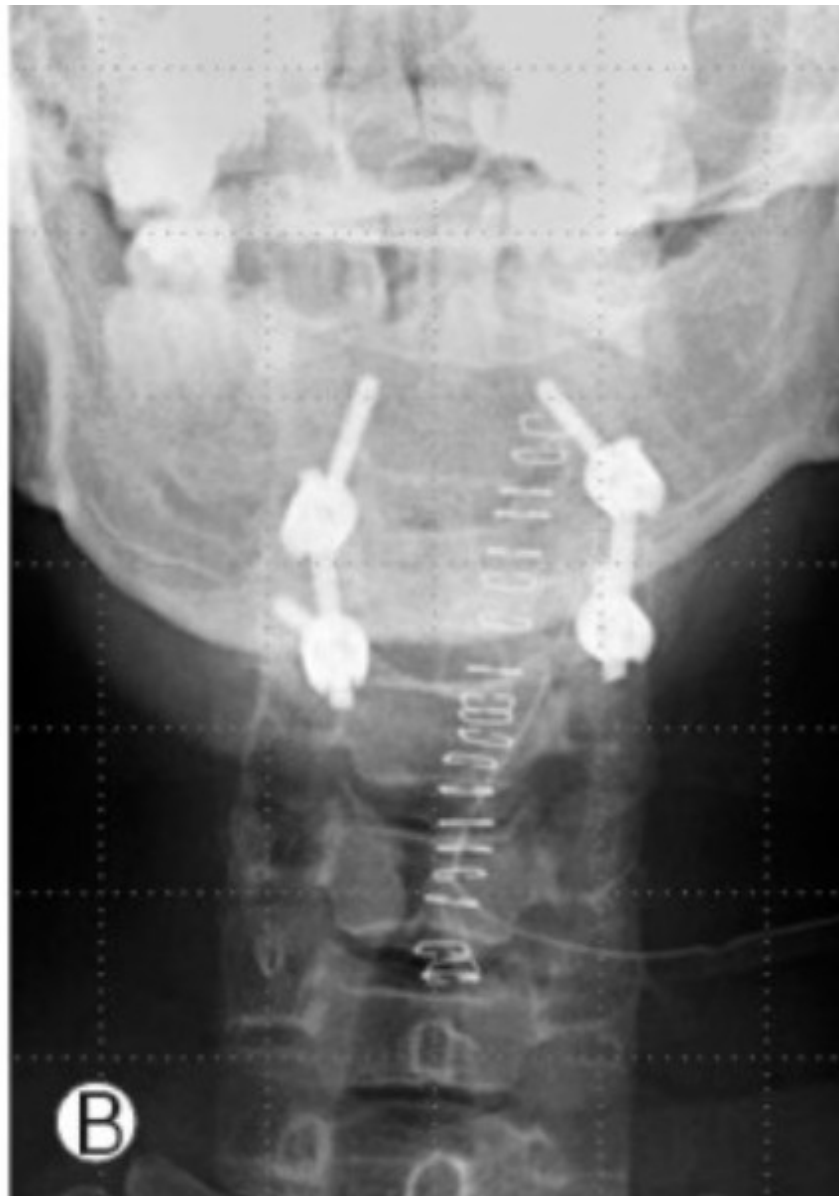
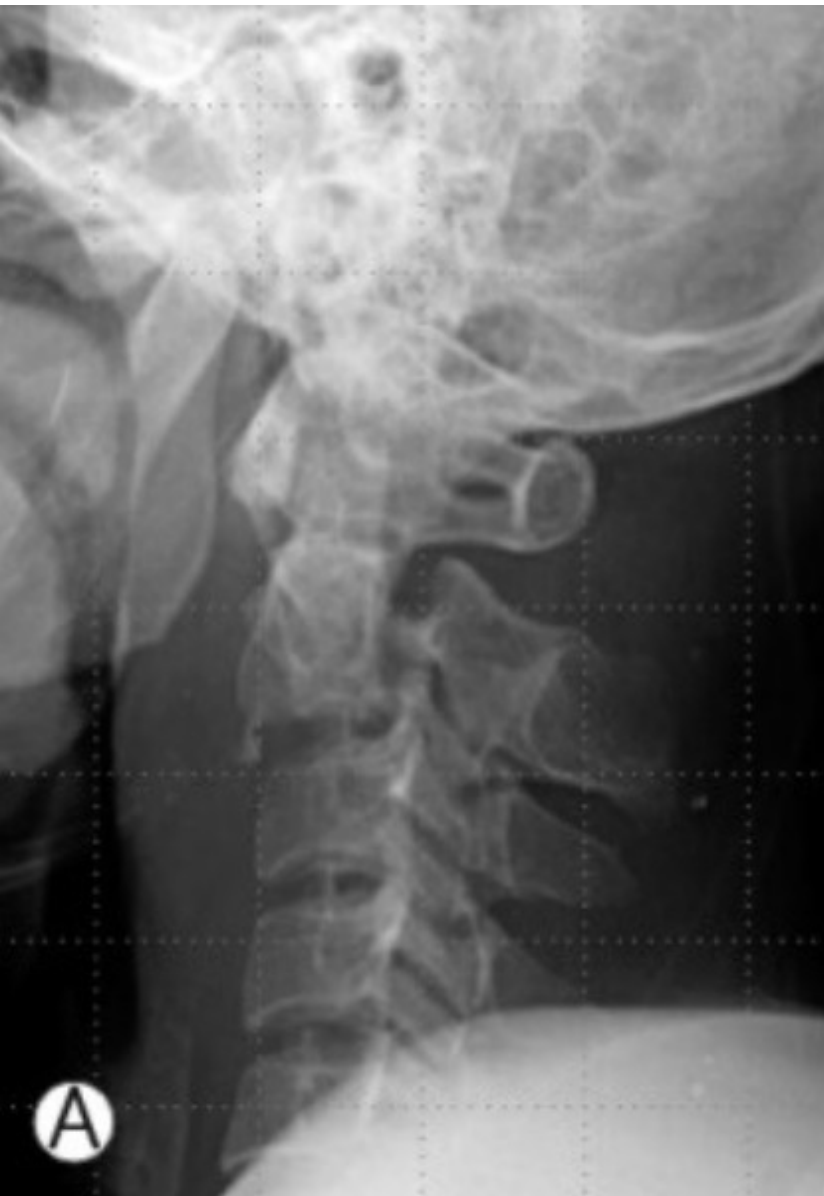V. SURGICAL TREATMENT UPPER C- SPINE

– fractures of the epistropheum : **dorsal / ventral approach**

HANGMAN FRACTURE – traumatic olisthesis C2





Dorsal – TP fixation

Jeong DH, You NK, Lee CK, Cho KH, Kim SH. Posterior C2-C3 Fixation for Unstable Hangman's Fracture. Korean J Spine. 2013 Sep;10(3):165-9. doi: 10.14245/kjs.2013.10.3.165. Epub 2013 Sep 30. PubMed PMID: 24757480

V. SURGICAL TREATMENT LOWER C- SPINE

– ventral / dorsal approach

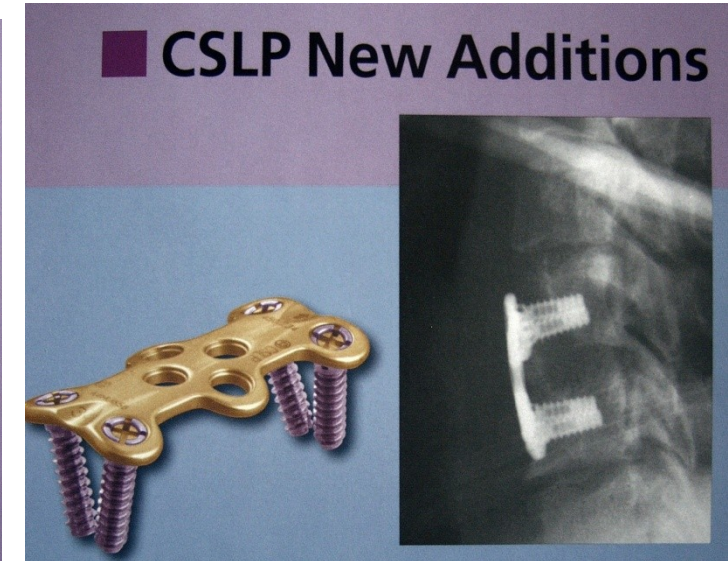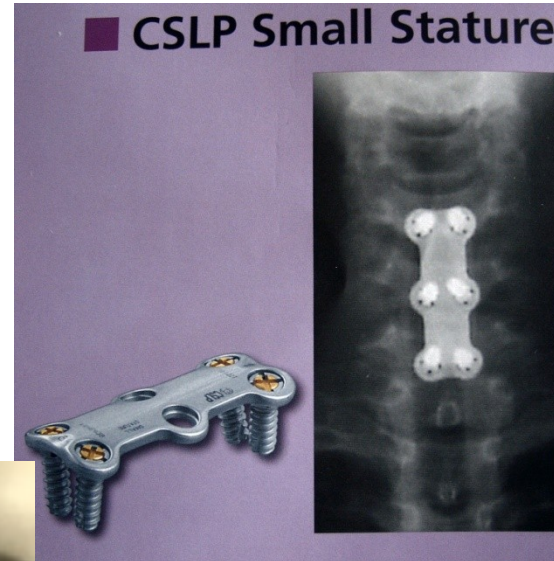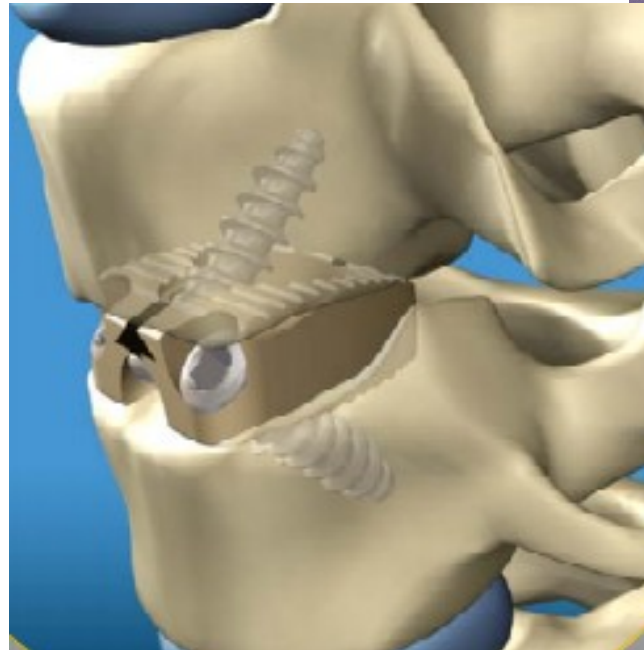
Ventral procedures

- Plating
- Discs / vertebral bodies replacement

Dorsal procedures

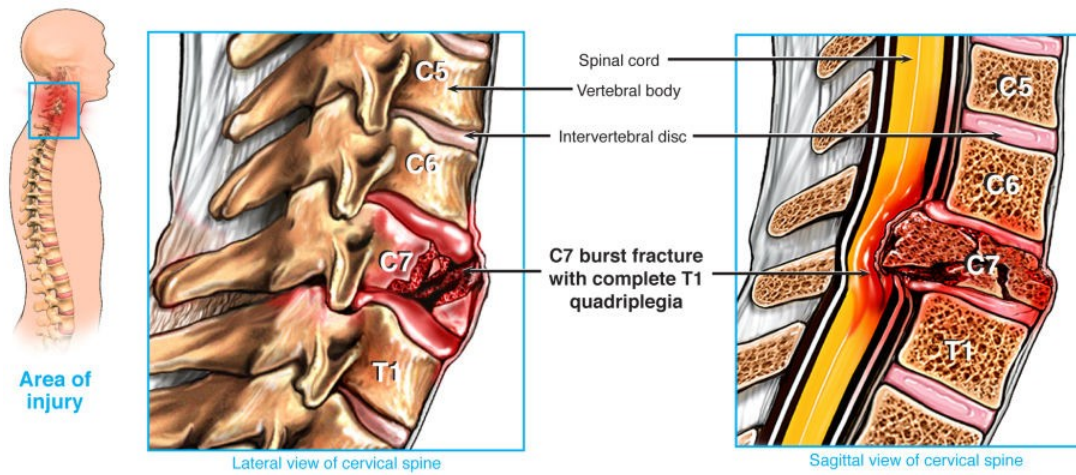
- TP stabilizations

Combinations

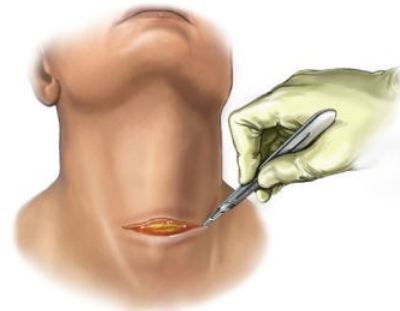


www.bbraun.com/content/dam/bbraun/global/website/products-and-therapies/degenerative-spinal-disorders/O85002_Aesculap_XP.pdf.bb-95195616/O85002_Aesculap_XP.pdf

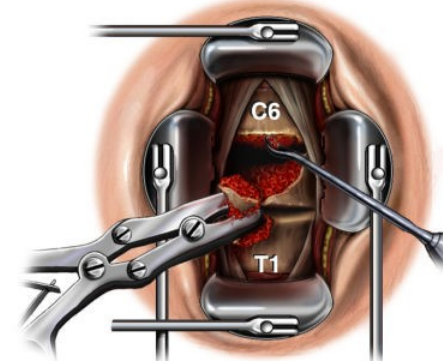
ACDF = Anterior Cervical Decompression and Fusion



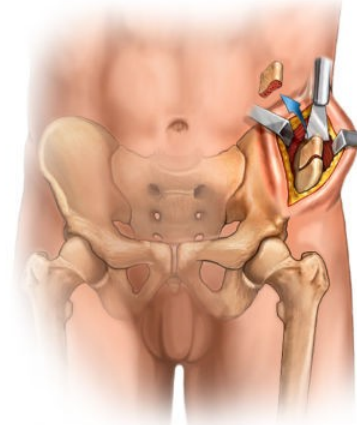
A. A transverse incision is made in the region of the C7 vertebral body.



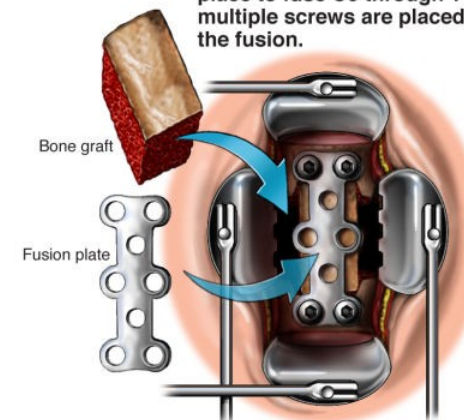
B. The C7 vertebral body along with the C6-7 and C7-T1 discs are removed.



C. A separate incision is made over the left iliac crest to harvest bone graft.

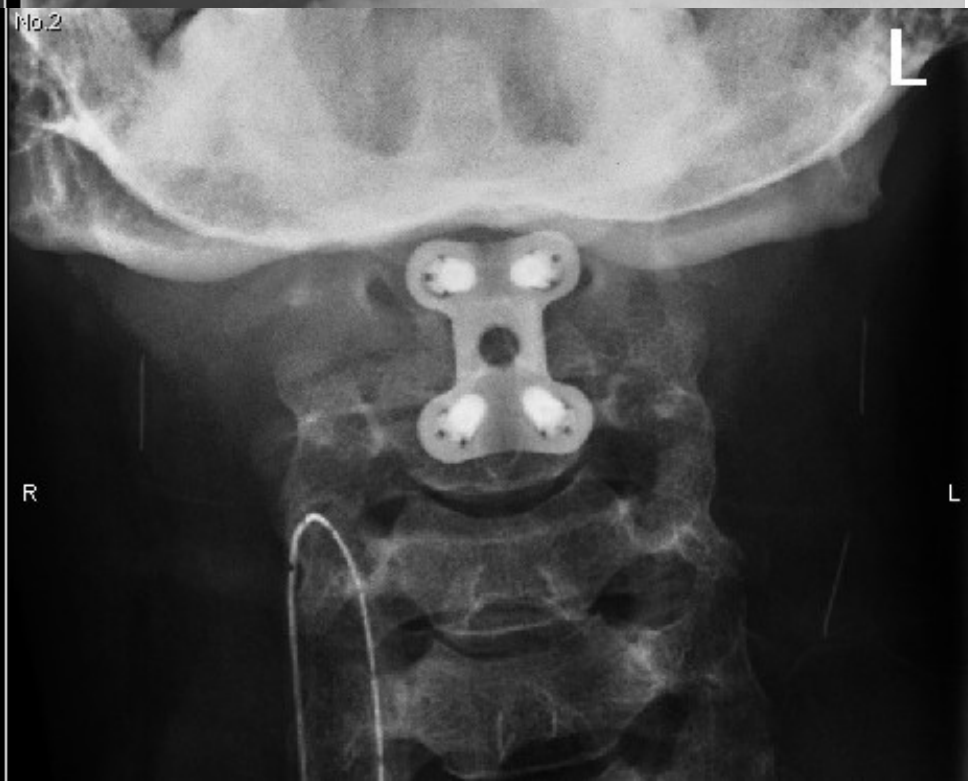
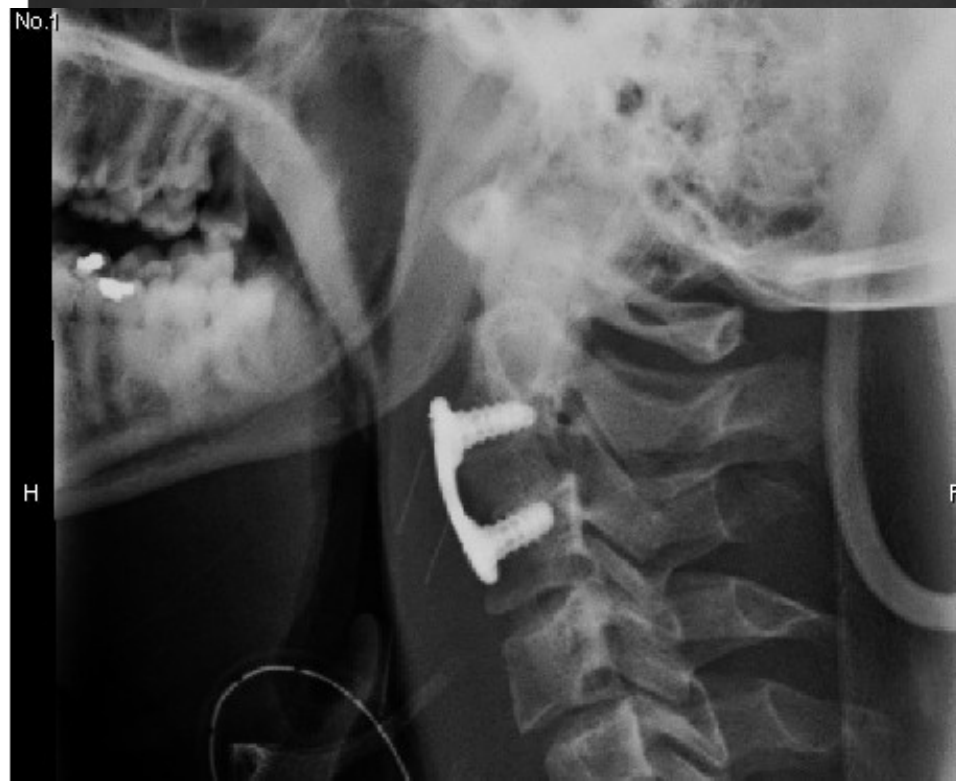
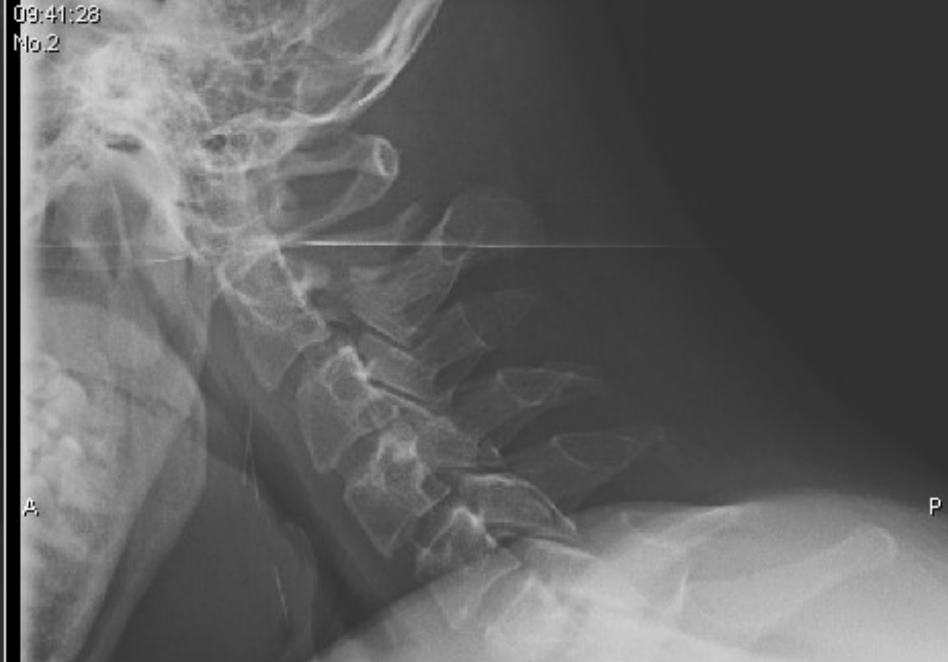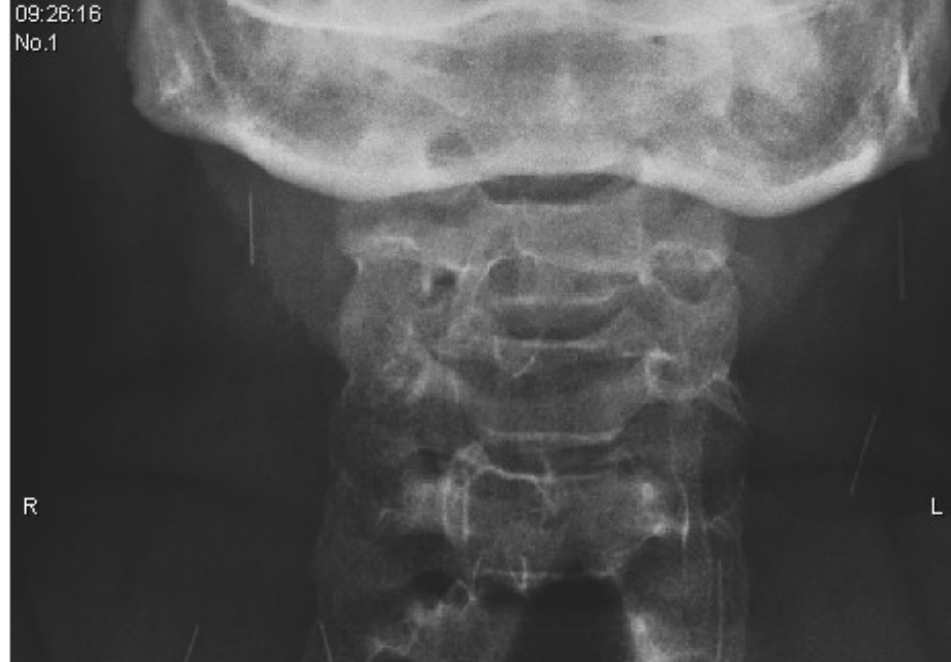D. Bone graft is cut to size and tapped into place to fuse C6 through T1. A plate and multiple screws are placed to complete the fusion.

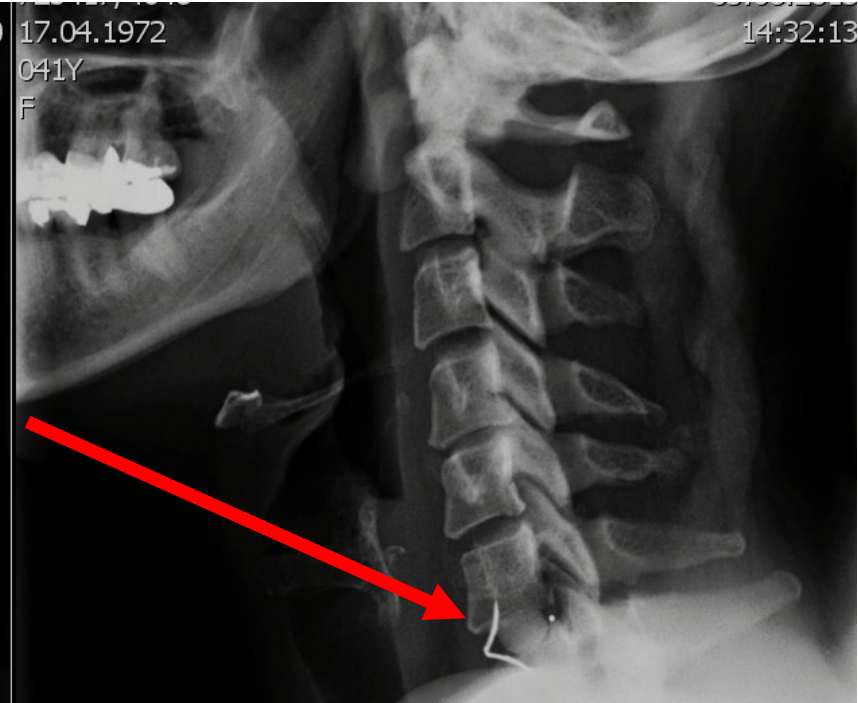
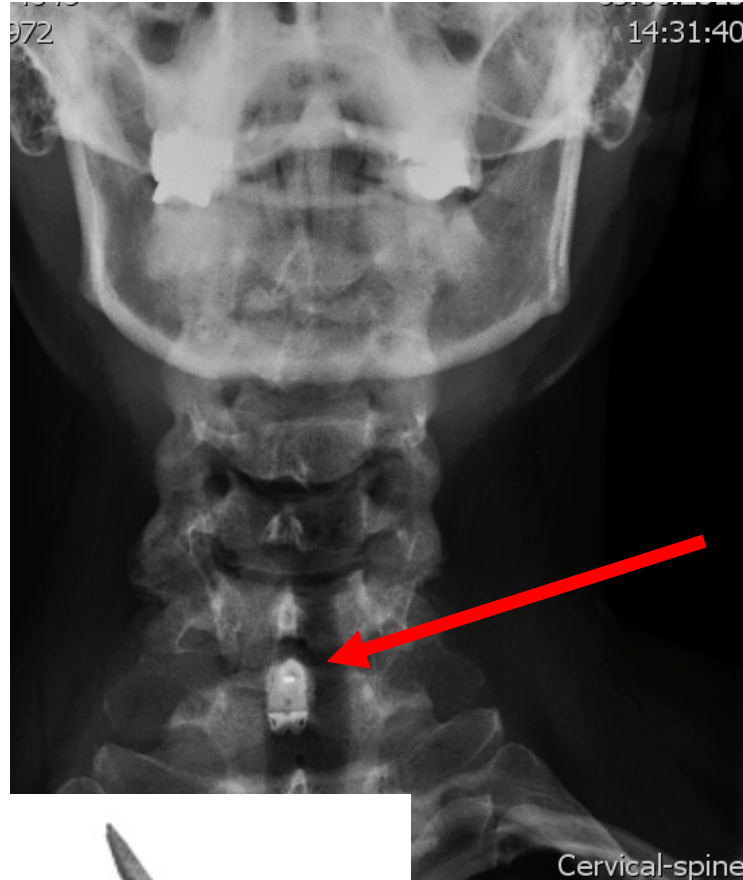
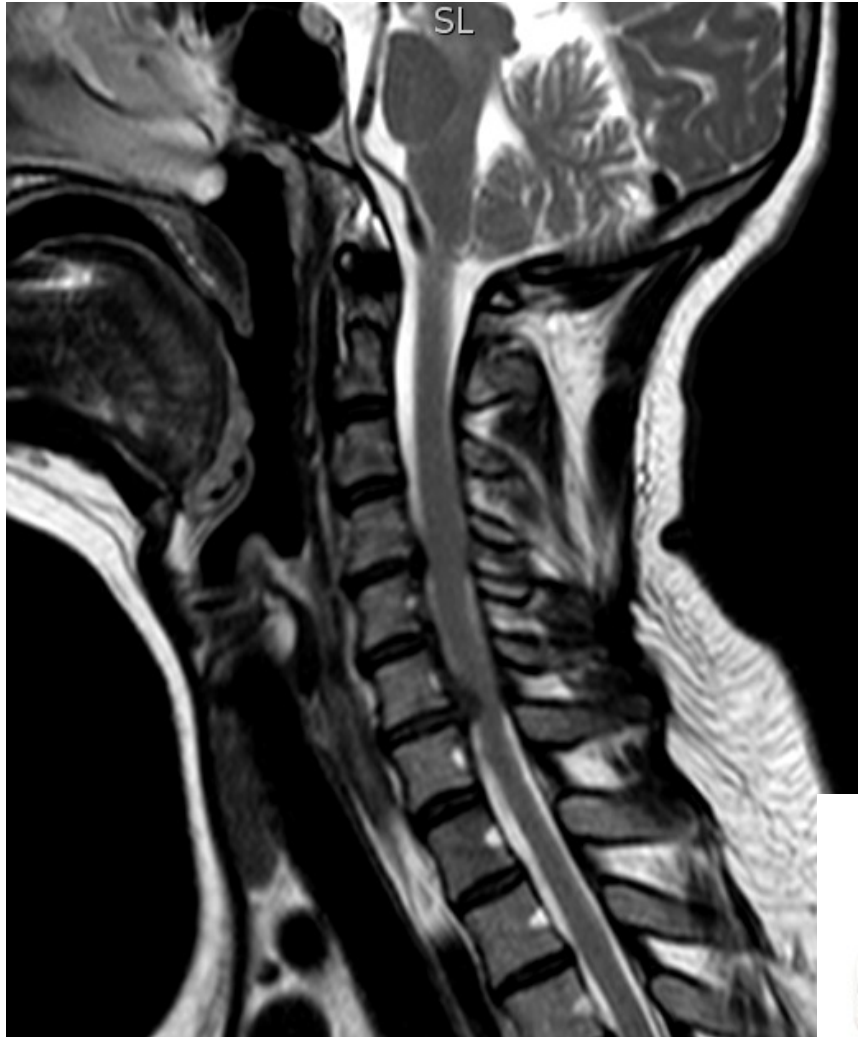
Nucleus Medical Media (2020). *Surgical decompression and stabilization of the spine* [Digital image]. Retrieved from <https://ebSCO.smartimagebase.com/surgical-decompression-and-stabilization-of-the-spine/view-item?ItemID=76291>

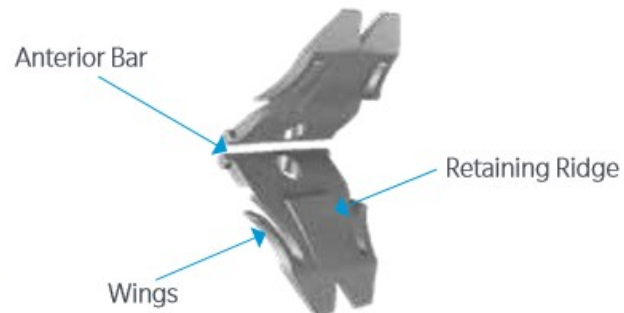
Ventral - ACDF



INTERSOMATIC FUSION C6/7

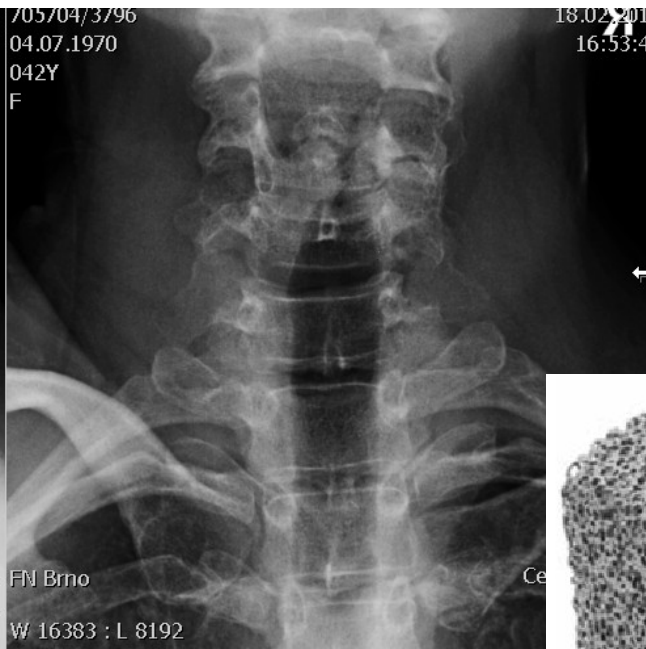
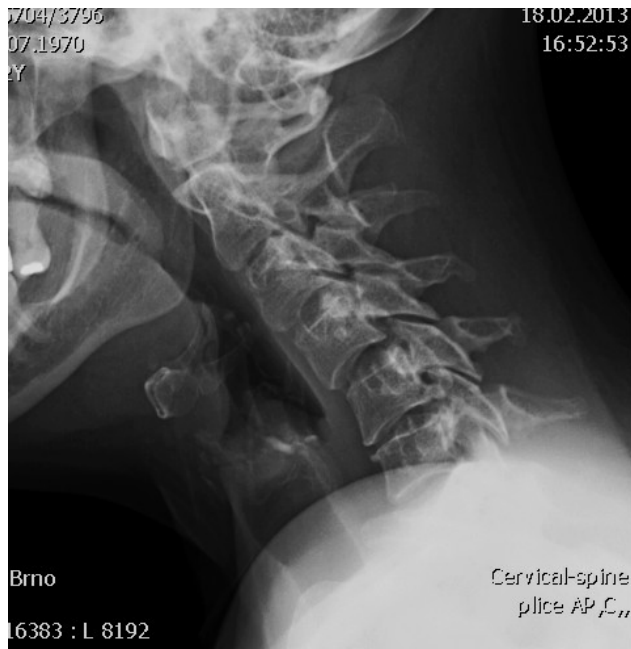

1mm from center of Tantalum marker to the posterior edge.

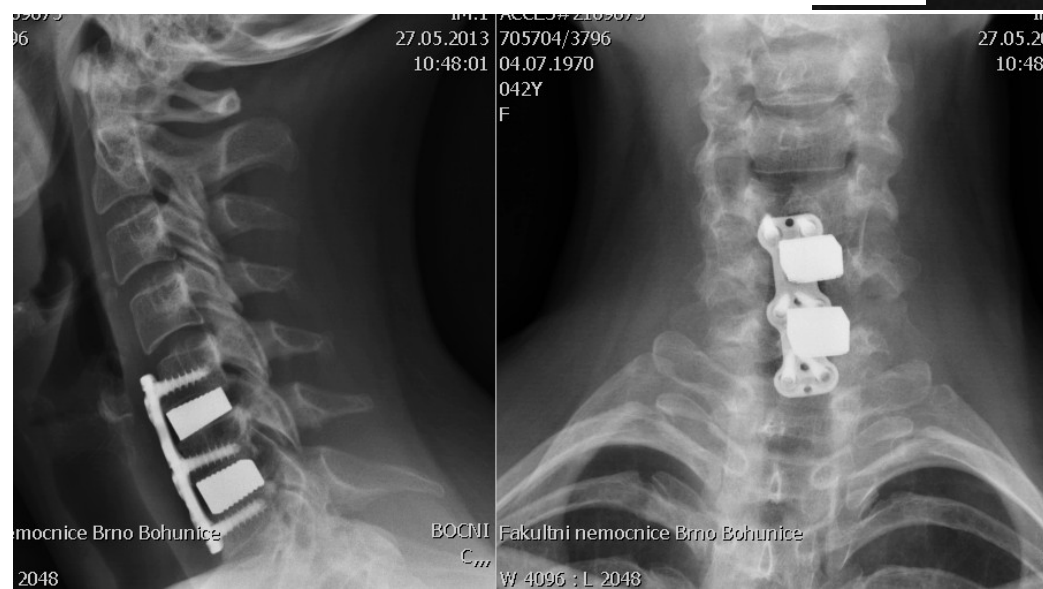
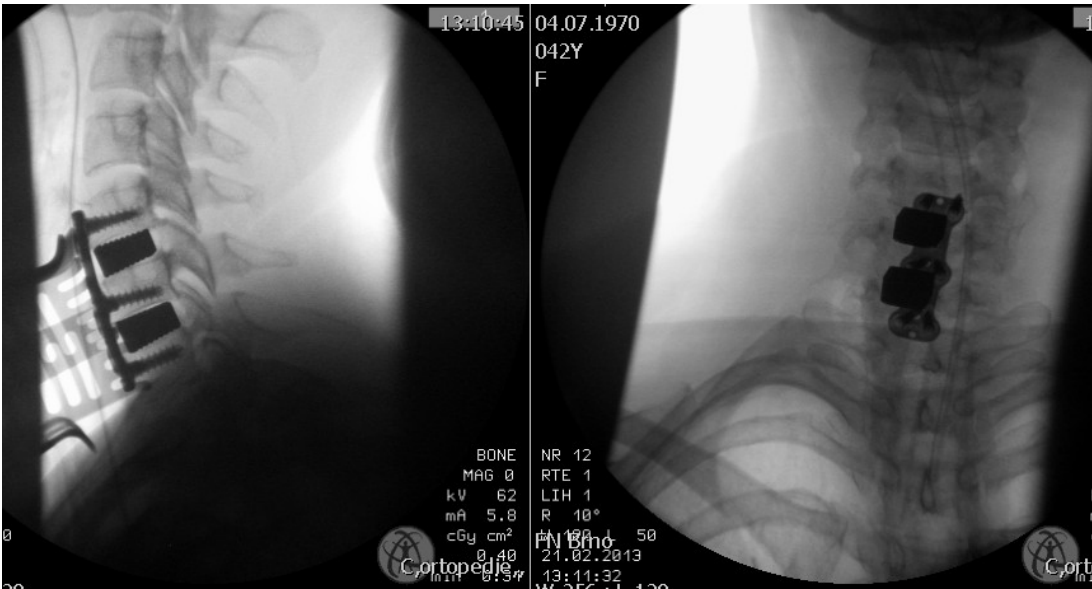
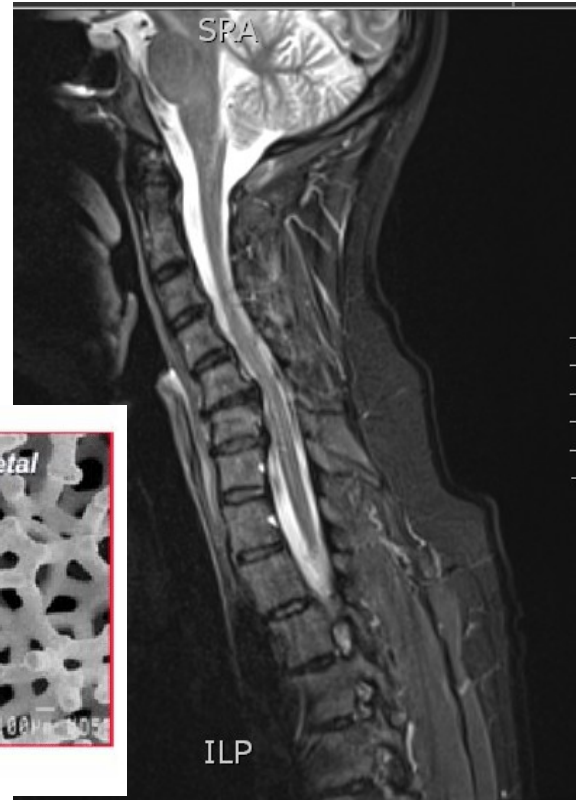


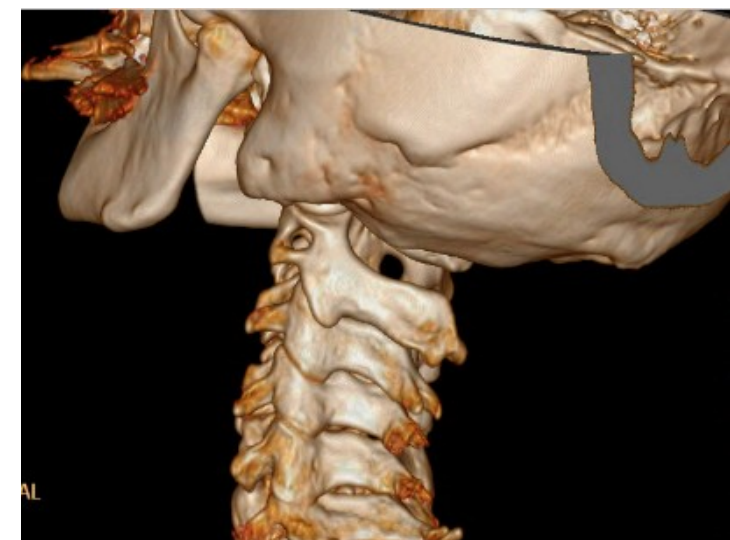<https://www.zimmerbiomet.com/content/dam/zimmer-biomet/medical-professionals/spine/roi-c-cervical-cage/ROI-C%20Product%20Brochure.pdf>



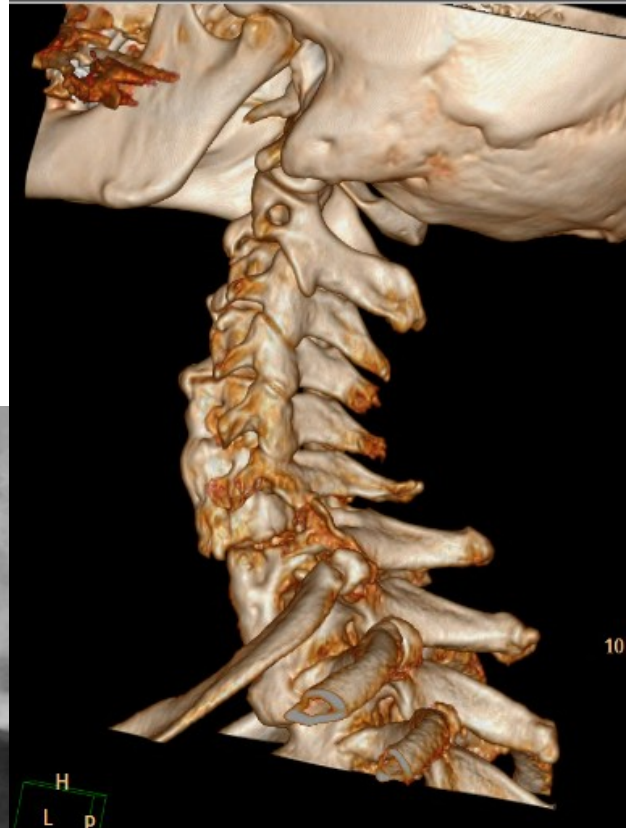


TRABECULAR METAL





SE:8128 SIPKA,LUBOMIR,
IM:1 ACCES#1965301
24.10.2012 511220/100



Dorsal

8192

C_{III}

W 16383 : L 8192

Cervica

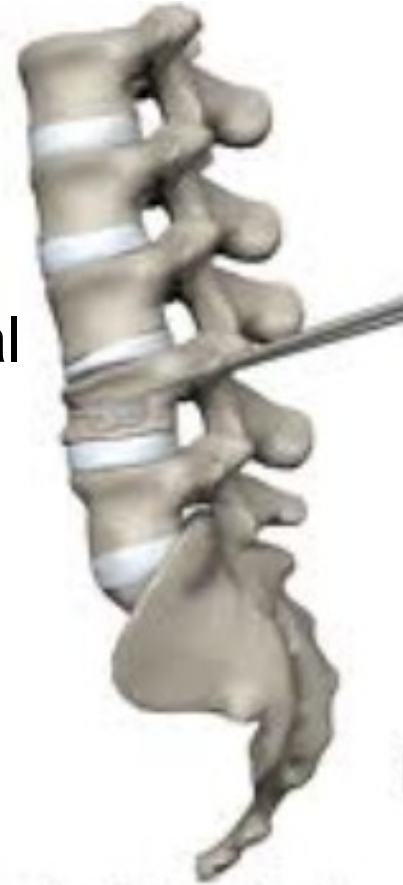

MISS (Mini Invasive Spine Surgery)

VERTEBROPLASTY

- pain reduction 70-90%
- fracture stabilization
- does NOT adjust vertebral height
- HIGH pressure cement application !
- HIGH risk of **leaking cement** (65%) !!

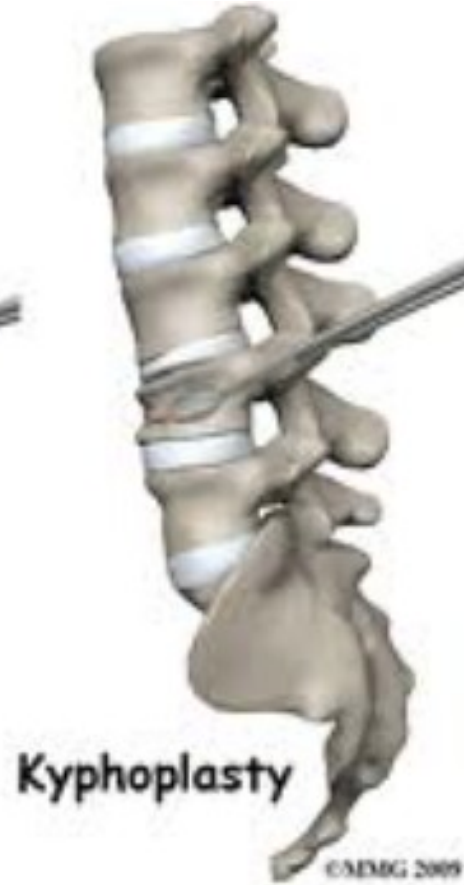could be outpatient



Vertebroplasty

KYPHOPLASTY

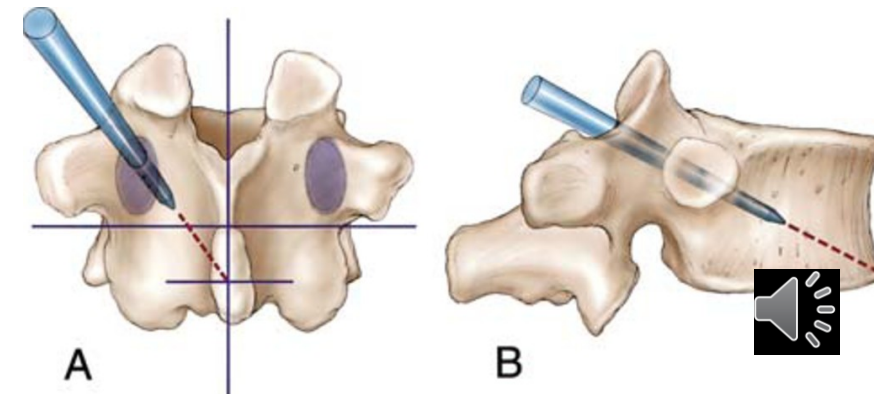
- pain reduction 90%
- fracture stabilization
- **adjustment** of vertebral height especially in **acute** fractures
- creation of cavity **reduces the risk** of leakage (10%)
- **general anaesthesia**



Kyphoplasty

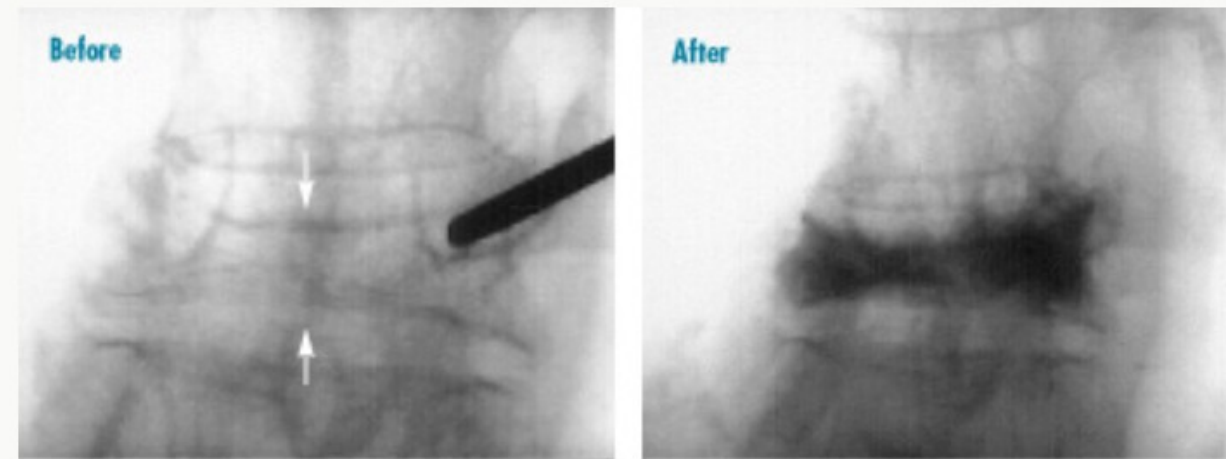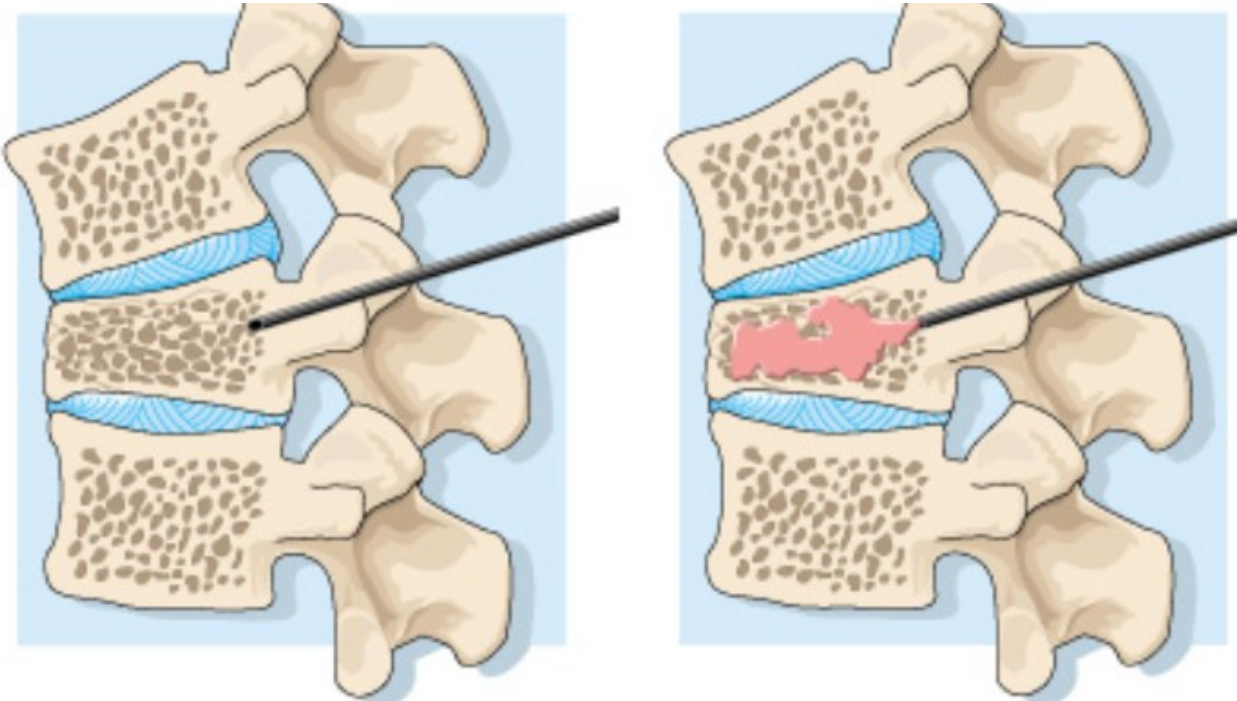
©SEMG 2009

Fourney DR, Schomer DF, Nader R, Chlan-Fourney J, Suki D, Ahrar K, Rhines LD, Gokaslan ZL. Percutaneous vertebroplasty and kyphoplasty for painful vertebral body fractures in cancer patients. J Neurosurg. 2003 Jan;98(1 Supl):21-30.



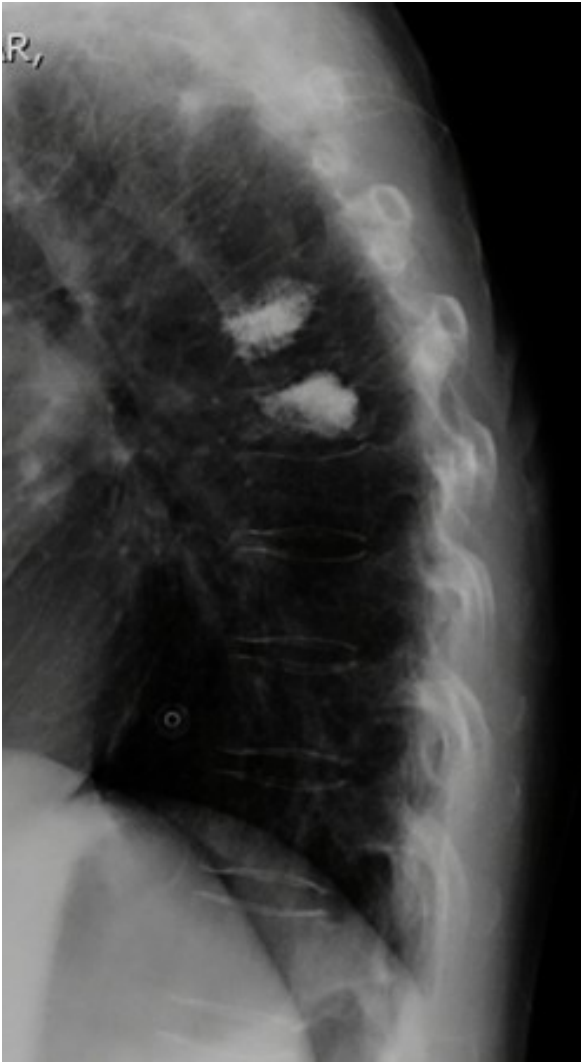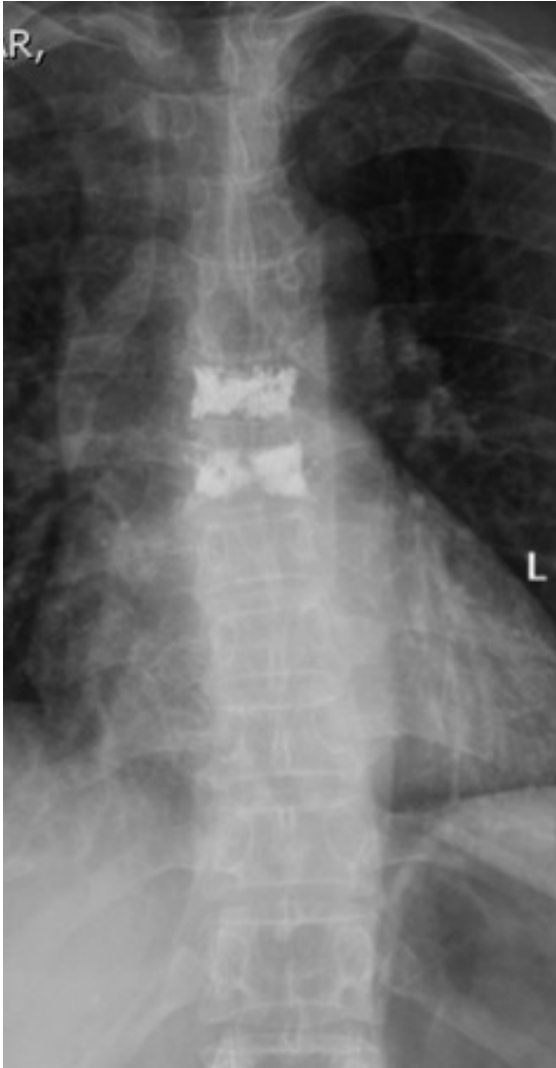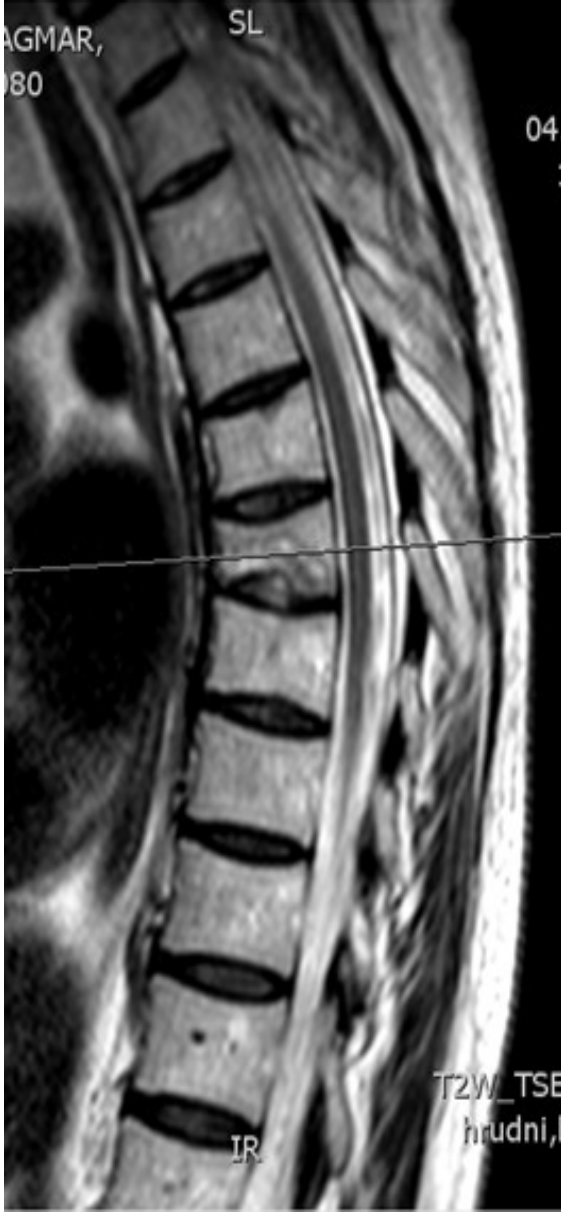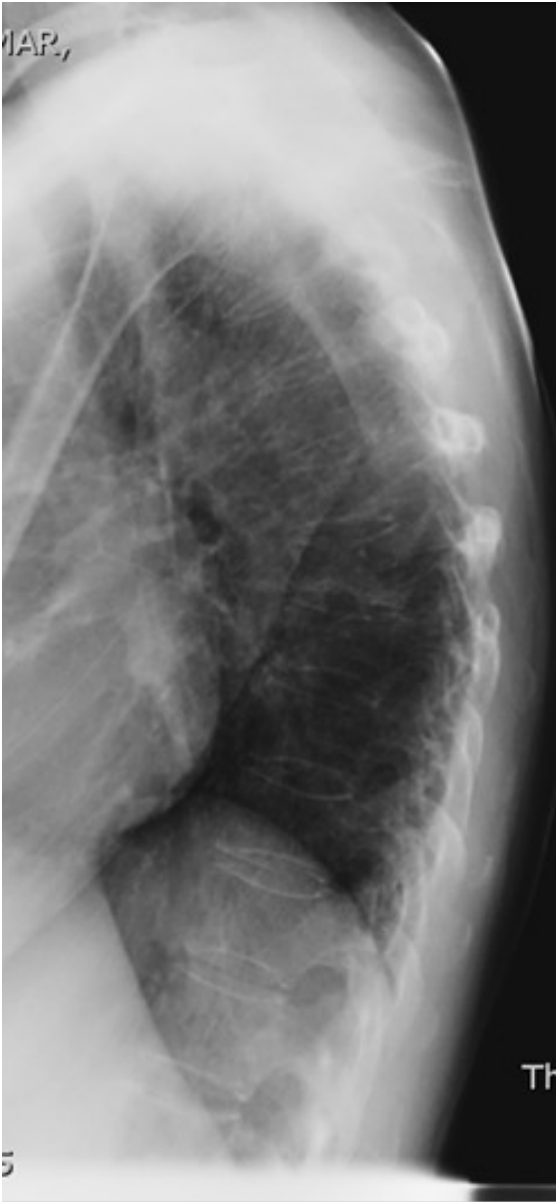
VERTEBROPLASTY – potential risks

- Allergic reactions to medications
- Infection (occurs in less than 1 per 15,000 injections)
- Post-injection flare (nerve root irritation with pain several hours after treatment, which may last days or weeks)
- Depigmentation (a whitening of the skin)
- Local fat atrophy (thinning of the skin)
- Destruction of a motor or sensory nerve in the path of the needle
- Bleeding, nerve injury, organ injury and death are rare but possible
- **Cement leakage is possible.** The cement used in vertebroplasty is in a liquid form and is squeezed into the fractured vertebra under high pressure. Some of the cement commonly leaks out of the vertebra, but this usually doesn't cause any problems. Only rarely does a cement leak cause pressure on the spinal cord or nearby nerves. In these cases, surgery may be required to remove the pressure.

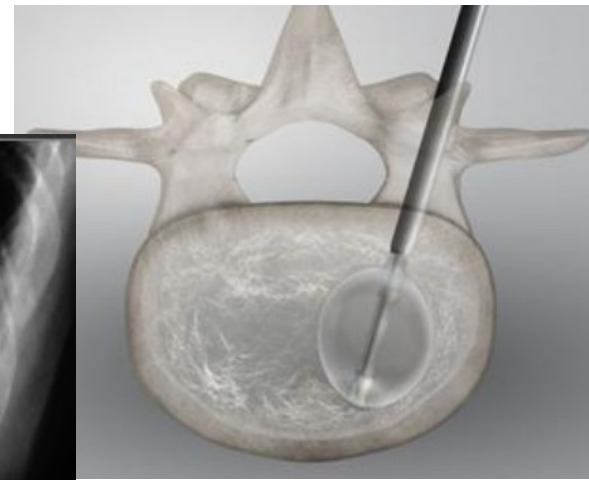
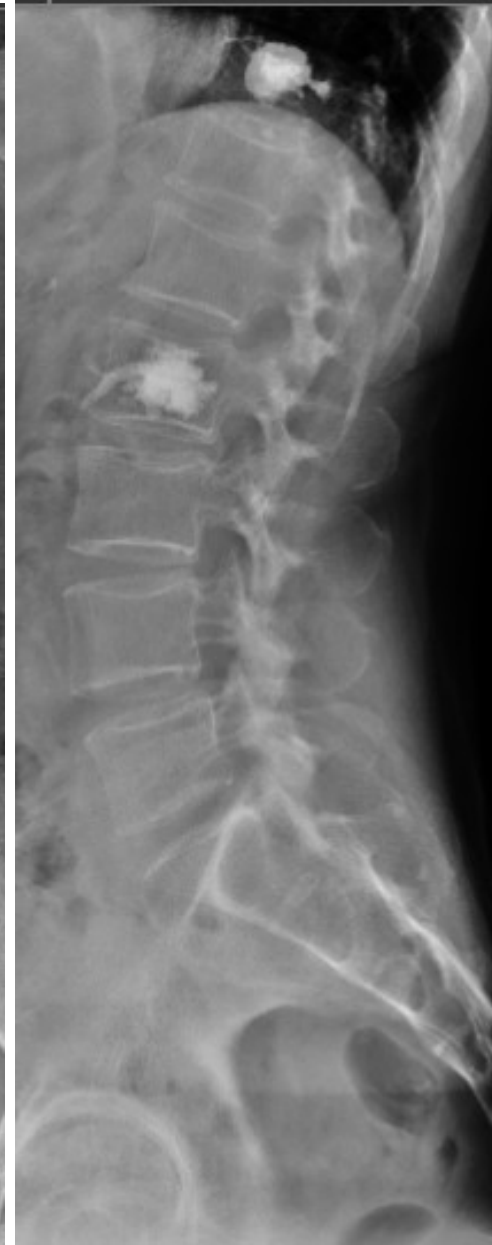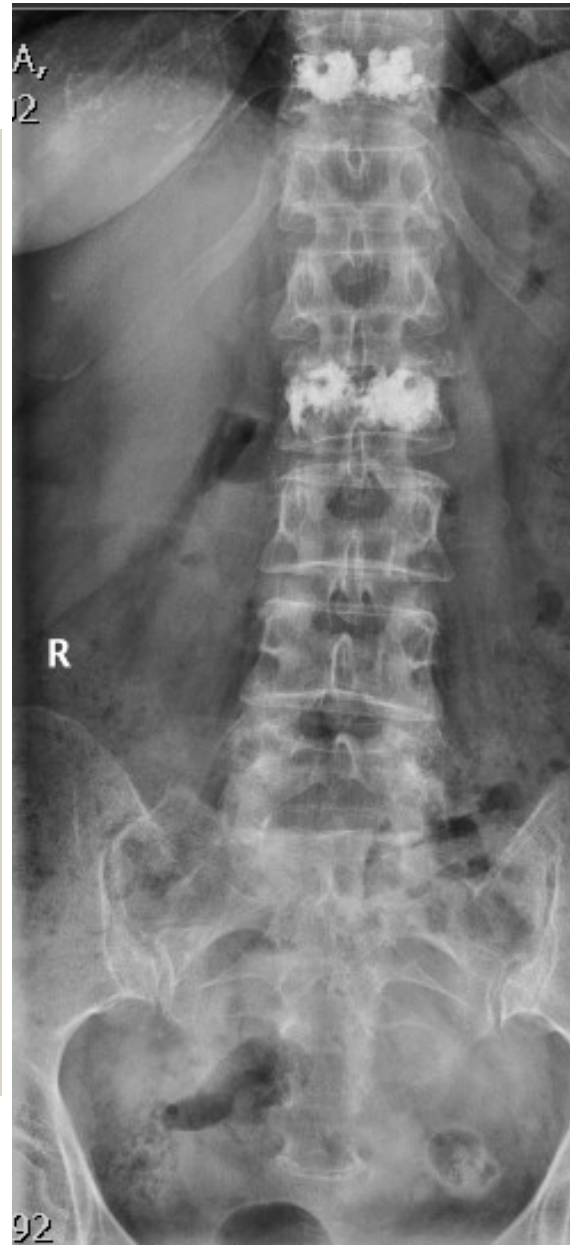
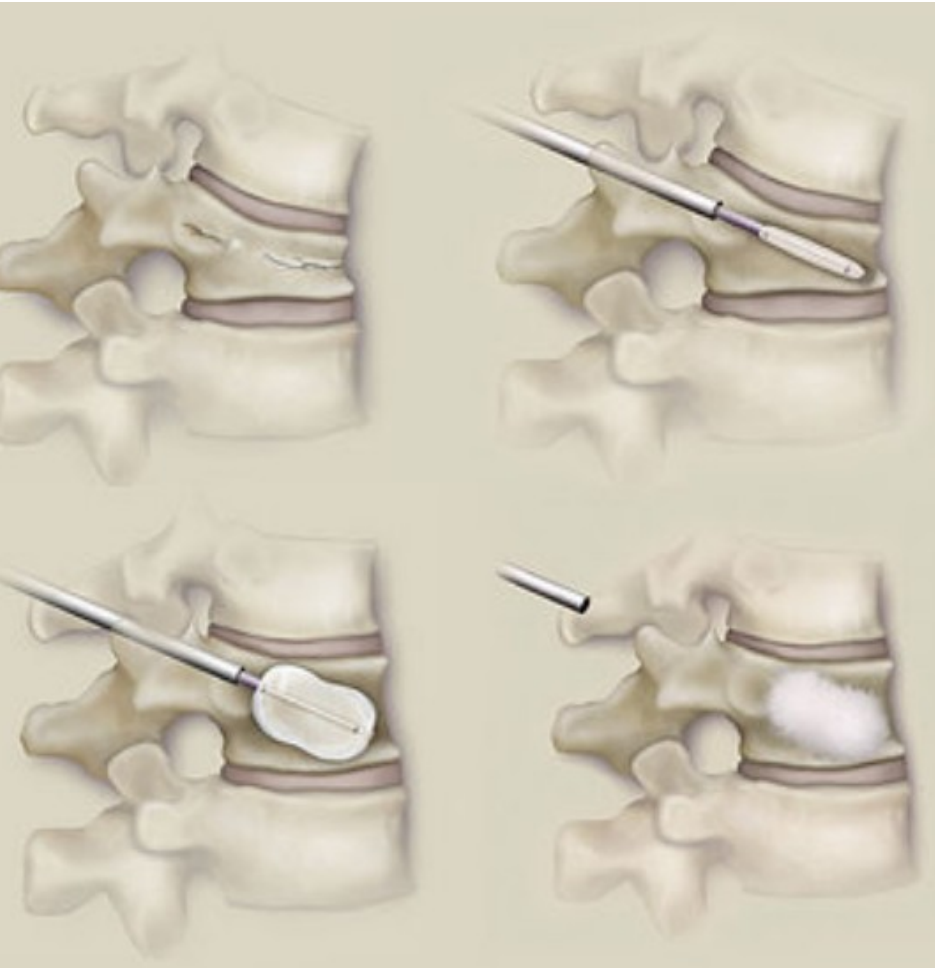


<http://www.painmanagementexperts.com/vertebroplasty-for-compression-fractures/>

VERTEBROPLASTY

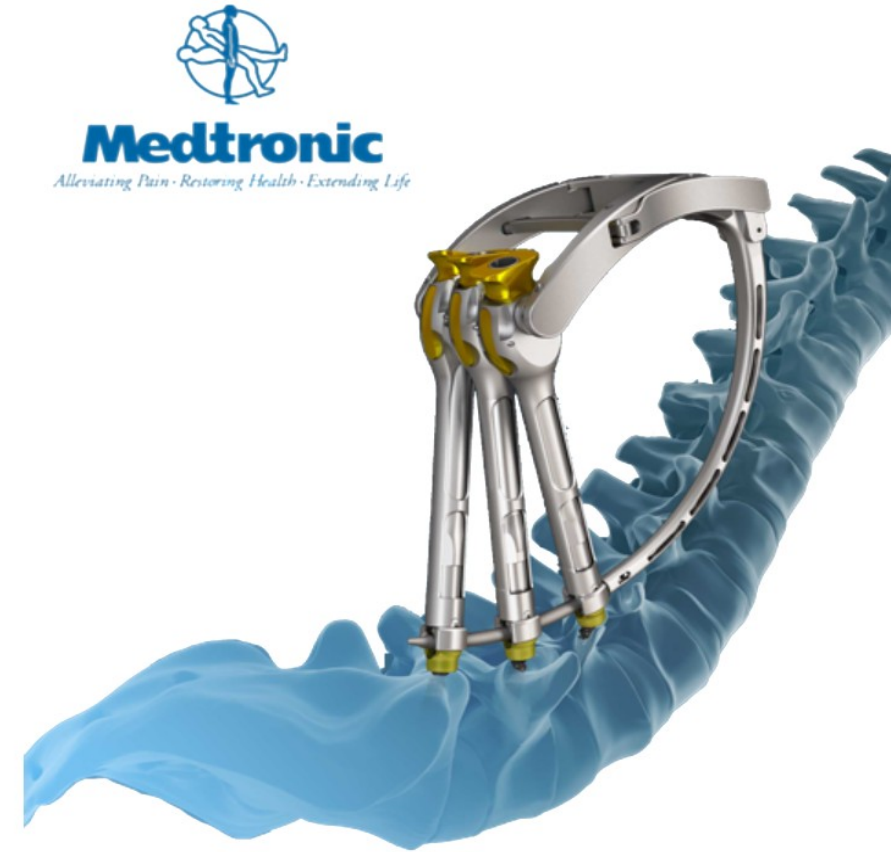
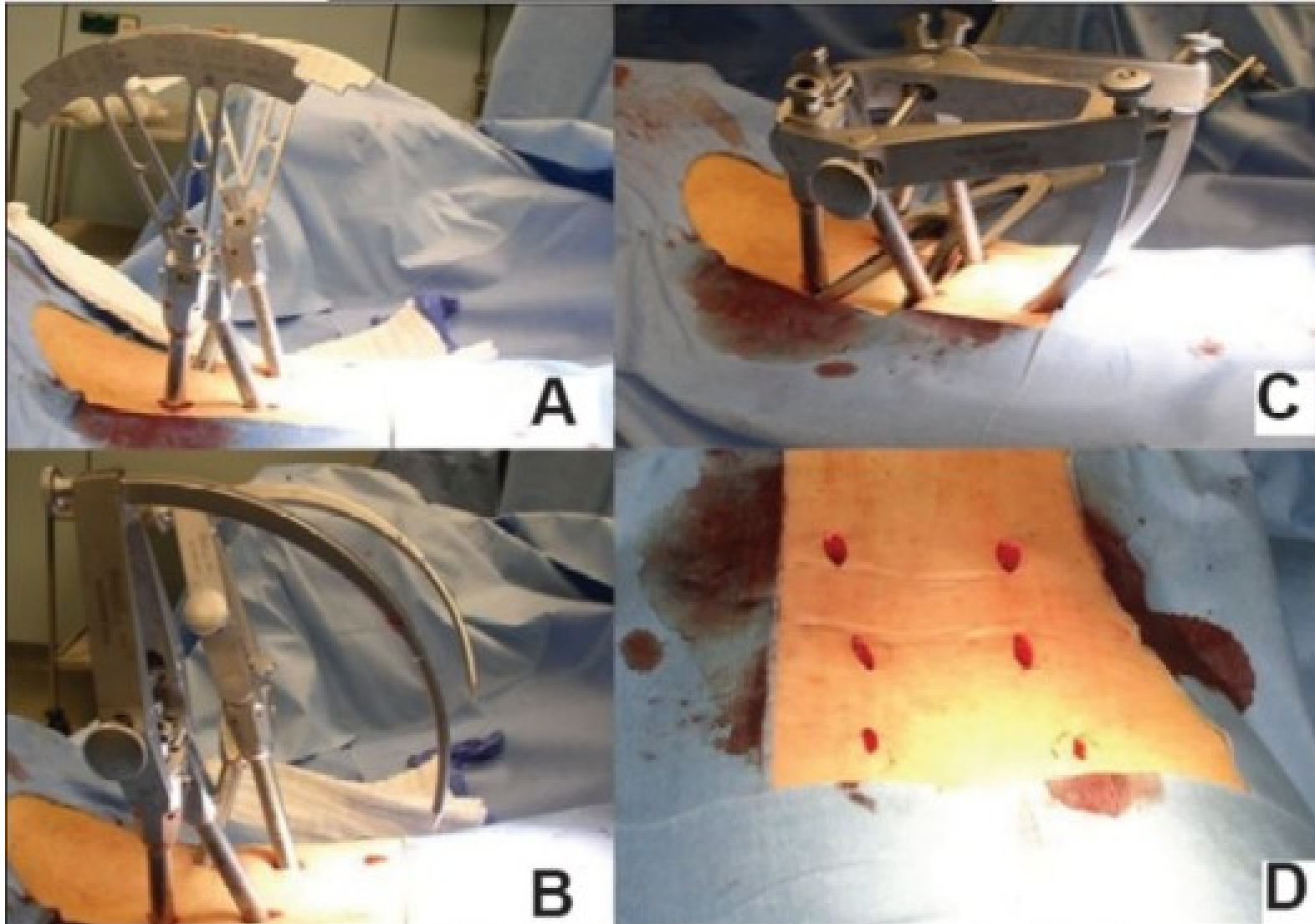


KYPHOPLASTY



MISS (Mini Invasive Spine Surgery)

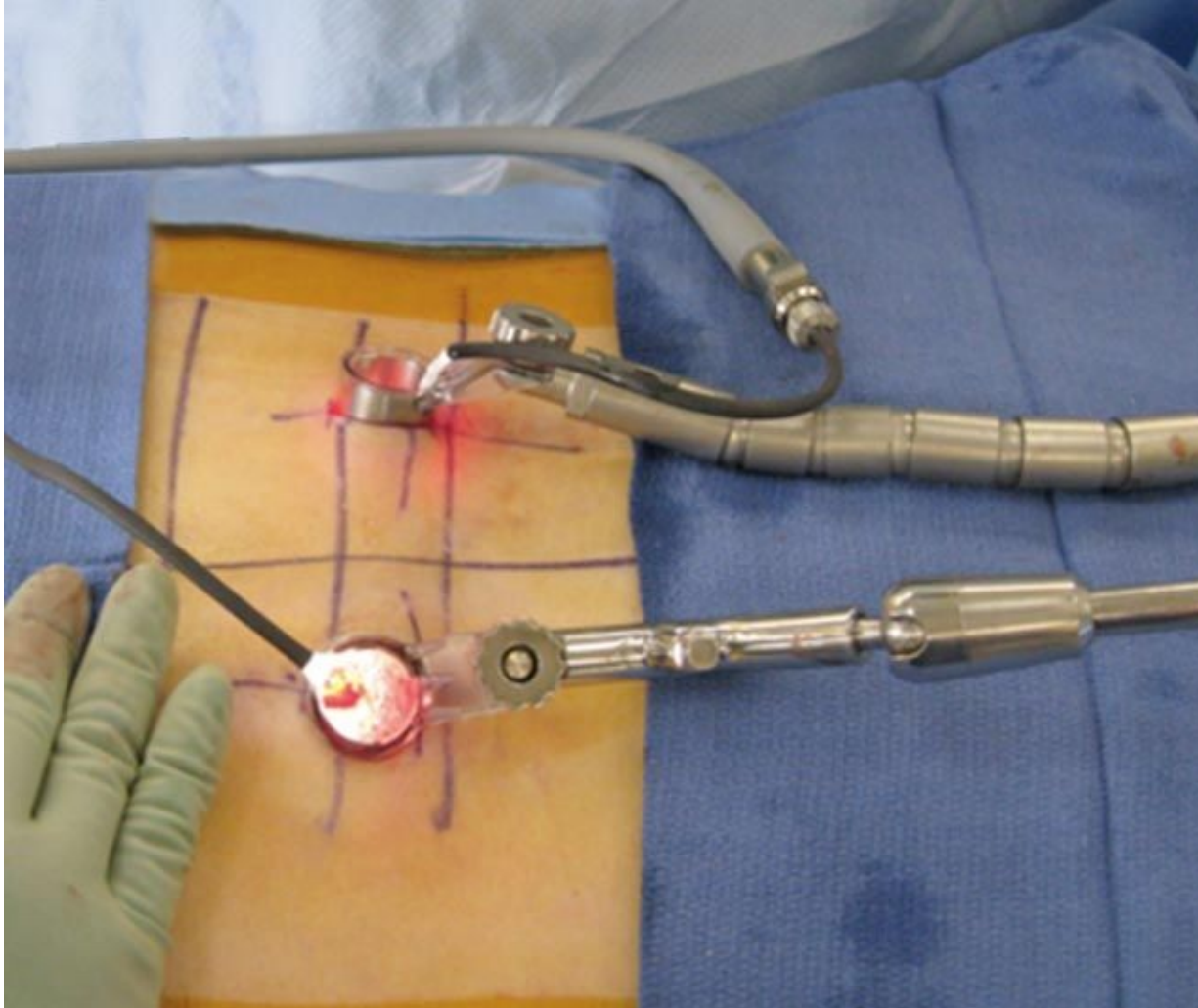
PERCUTANE FIXATION & DECOMPRESSION



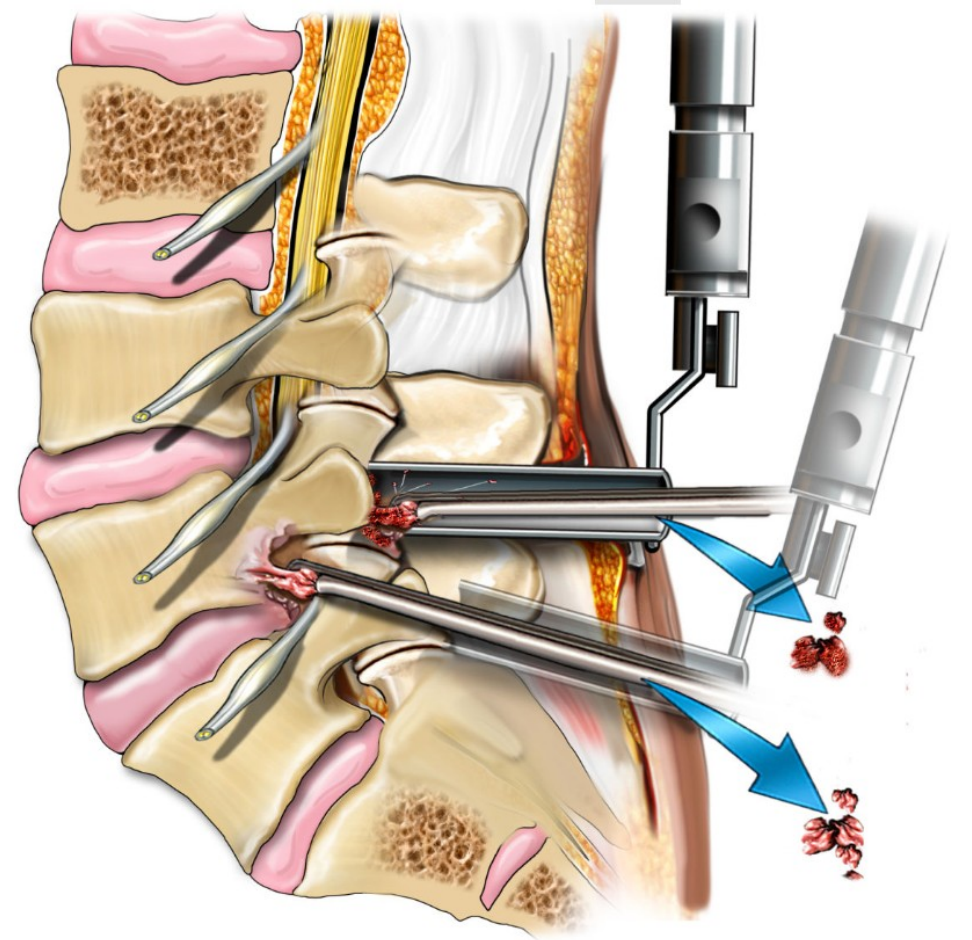
Schmidt OI, Strasser S, Kaufmann V, Strasser E, Gahr RH. Role of early minimal-invasive spine fixation in acute thoracic and lumbar spine trauma. *Indian J Orthop.* 2007 Oct;41(4):374-80. doi: 10.4103/0019-5413.37003.

MISS (Mini Invasive Spine Surgery)

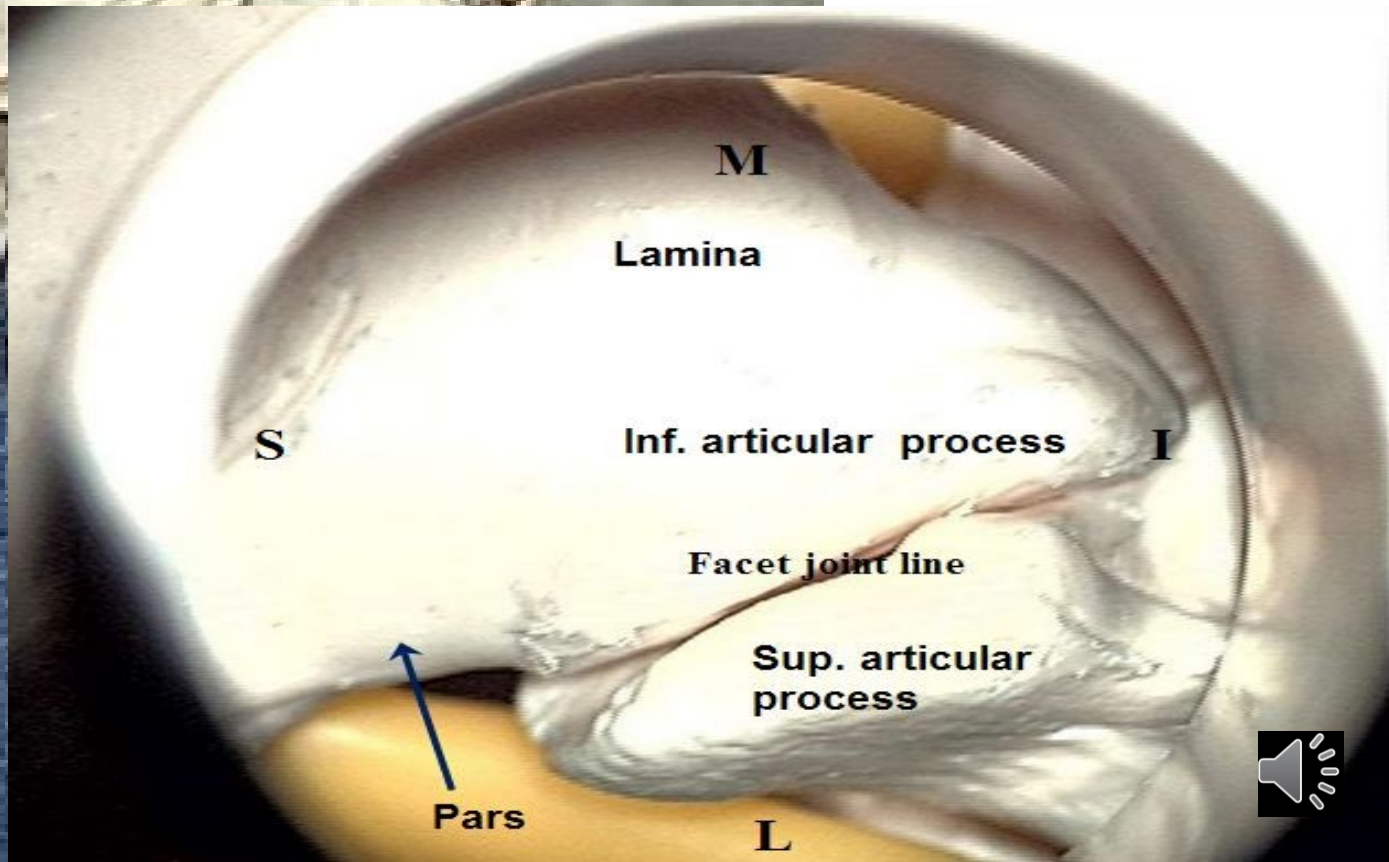
PERCUTANE FIXATION & DECOMPRESSION

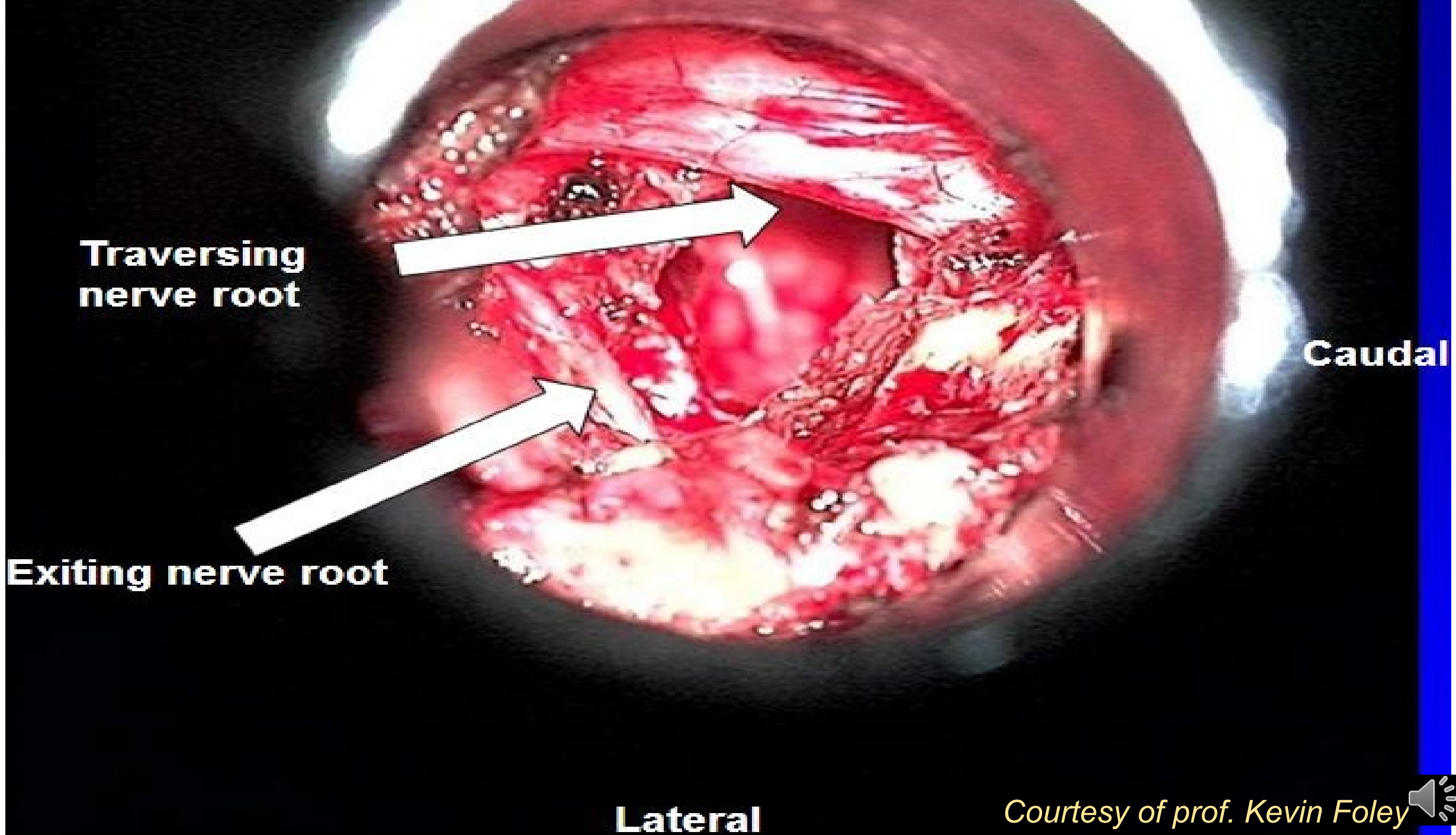


Kim C, Siemionow K, Anderson D, Phillips F: The current state of minimally invasive spine surgery, in Egol K, Tornetta III P, eds: Instr Course Lect, 60. Rosemont, IL, American Academy of Orthopaedic Surgeons, 2011, 353-370.



Nucleus Medical Media (2020). *Minimally invasive disc removal* [Digital image]. Retrieved from <https://ebSCO.smartimagebase.com/minimally-invasive-disc-removal/view-item?ItemID=22128>





**Traversing
nerve root**

Caudal

Exiting nerve root

Lateral

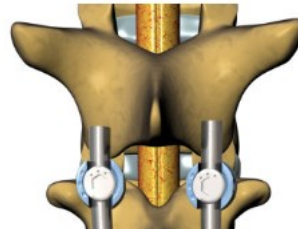
Courtesy of prof. Kevin Foley



VI. INSTRUMENTATION OF THE SPINE

TRAUMATIC

Instrumentation should to



The instrumentation is usually **removed** after fractures have healed

Nucleus Medical Media (2020). *Posterior spinal fusion* [Digital image]. Retrieved from <https://ebSCO.smartimagebase.com/posterior-spinal-fusion/view-item?ItemID=69744>

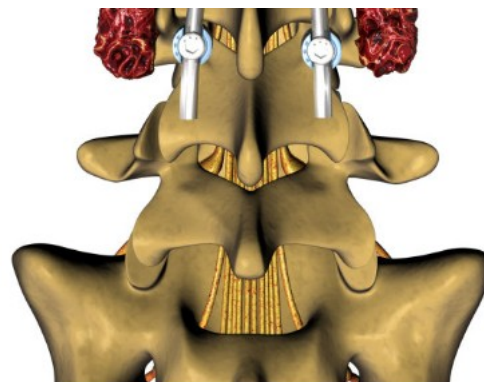
DEGENERATIVE & DEFORMITY

The instrumentation helps to create

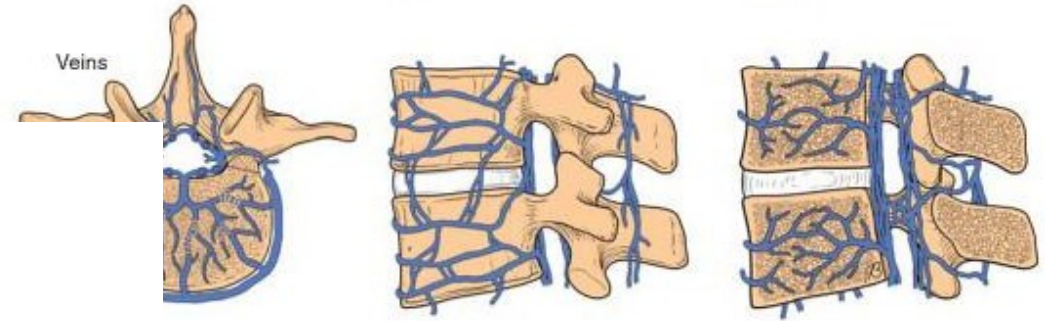
I
slip
c

(= **immobilization of operated extent!**)

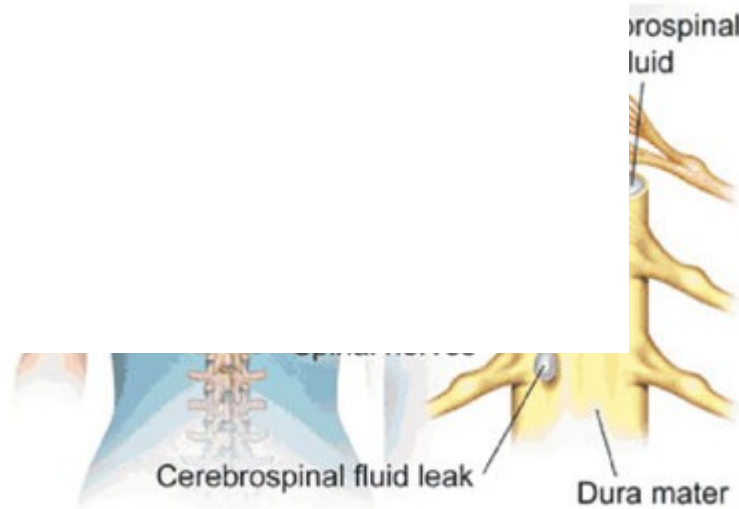
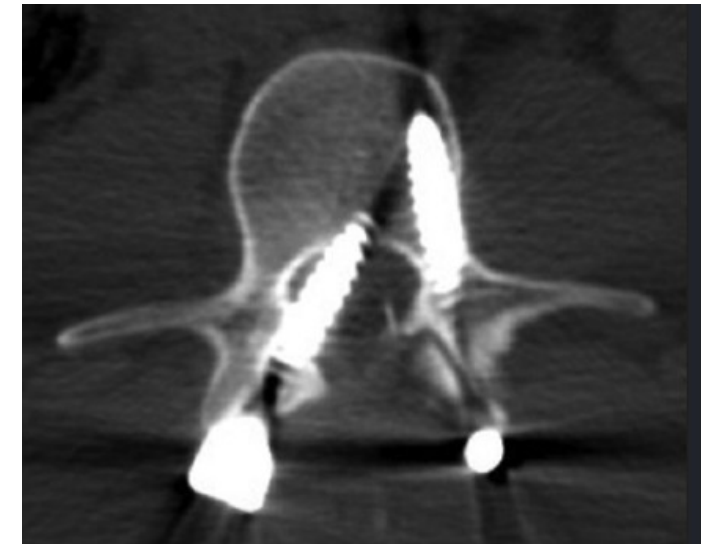
Instrumentarium **stays** in the body for **rest of life**



Complications of surgical treatment

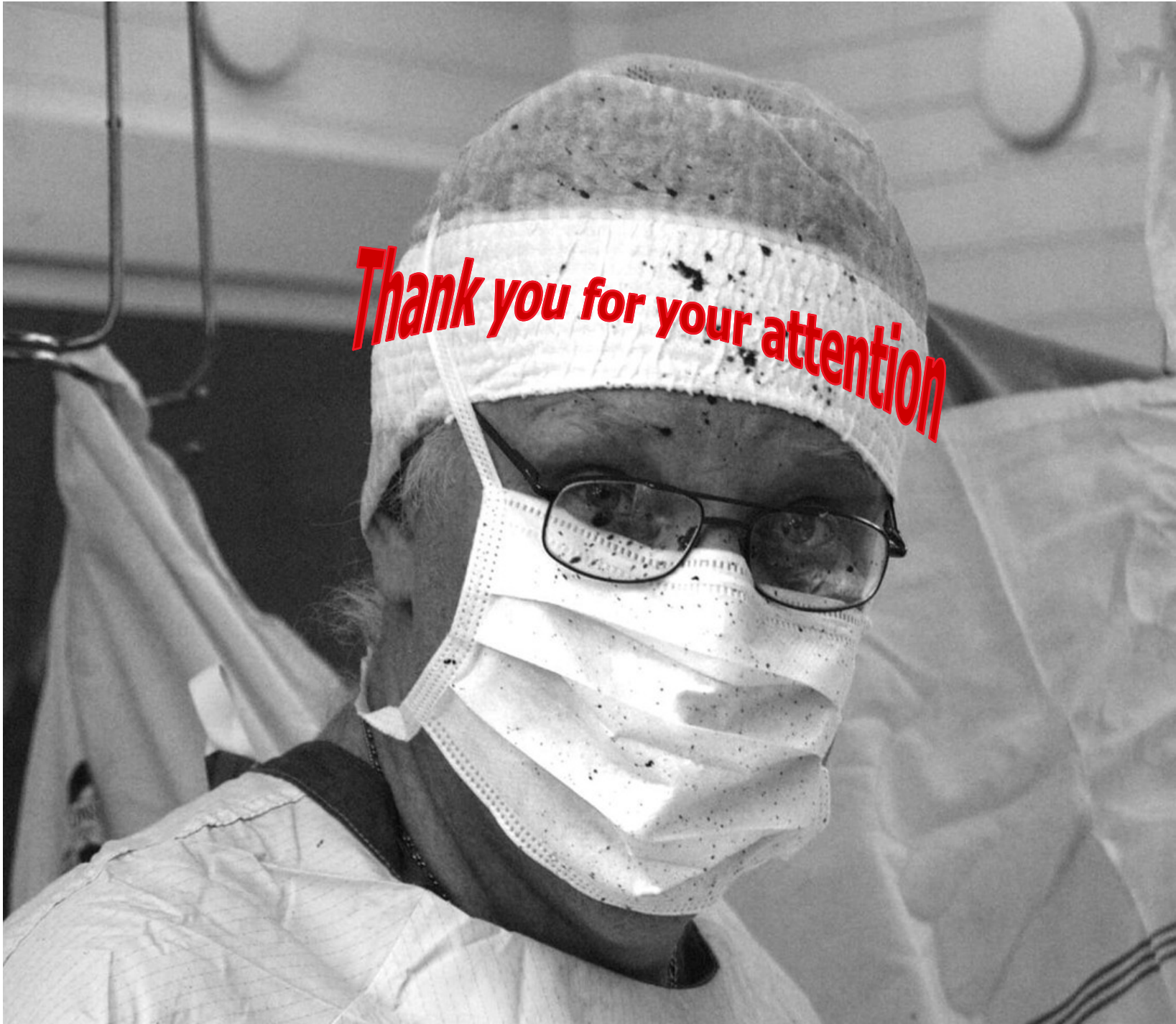

n)



- early, late

www.pauljeffordsmd.com/understanding-the-risks-of-spine-surgery



Thank you for your attention