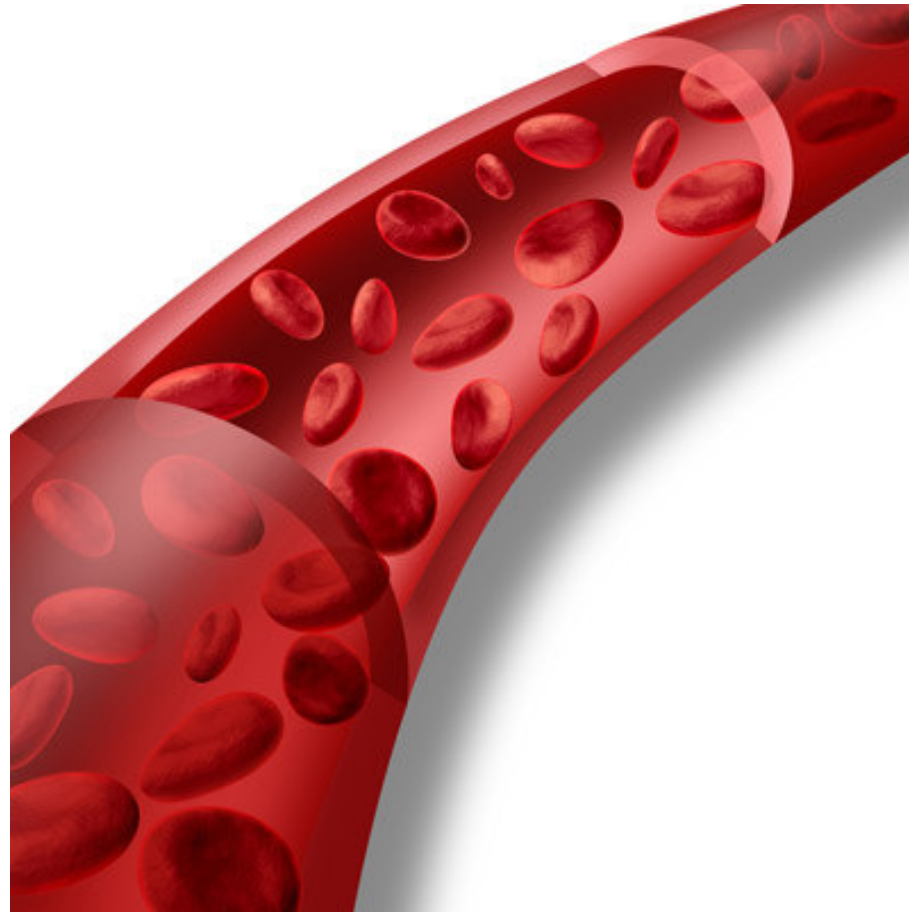


# Cévy - tepny, vlásečnice

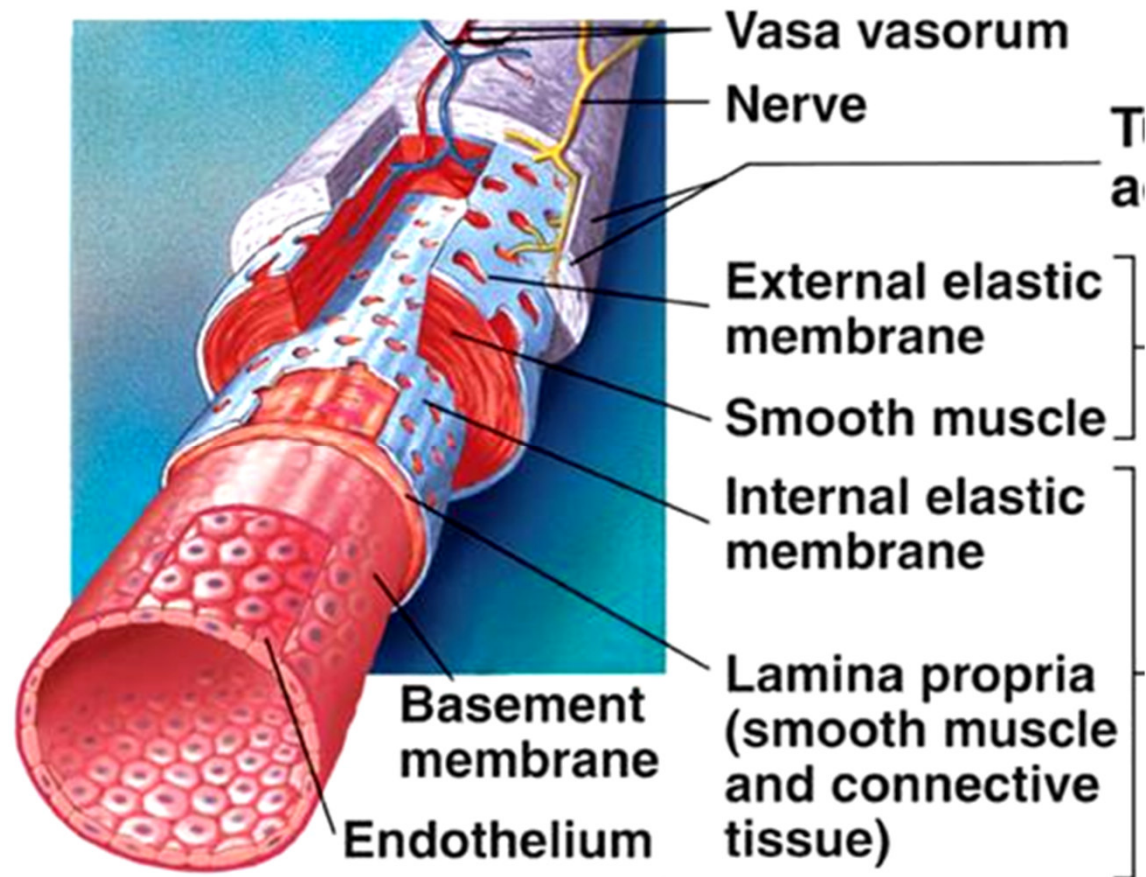


# Arterie: stavba stěny

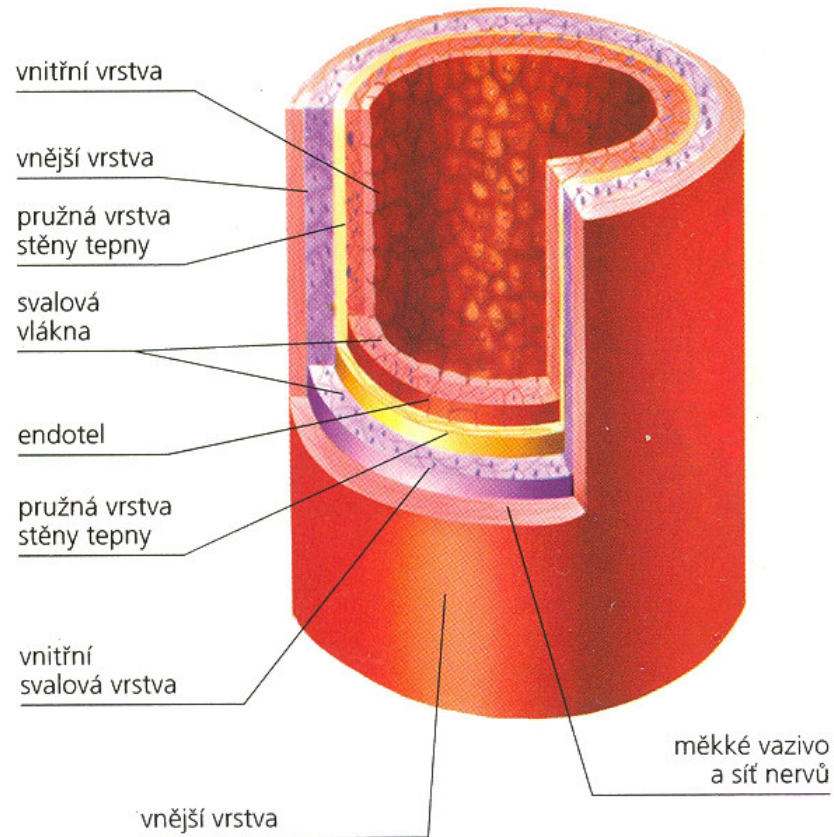
Tunica intima

Tunica media

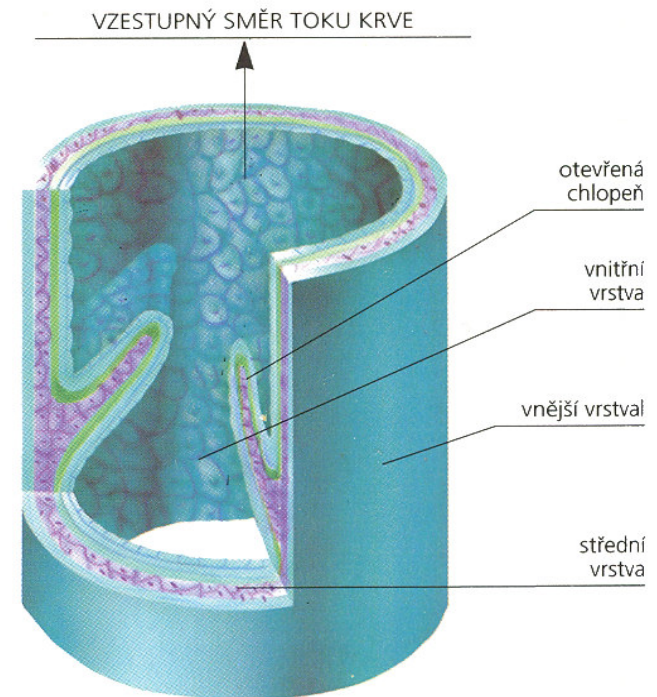
Tunica externa



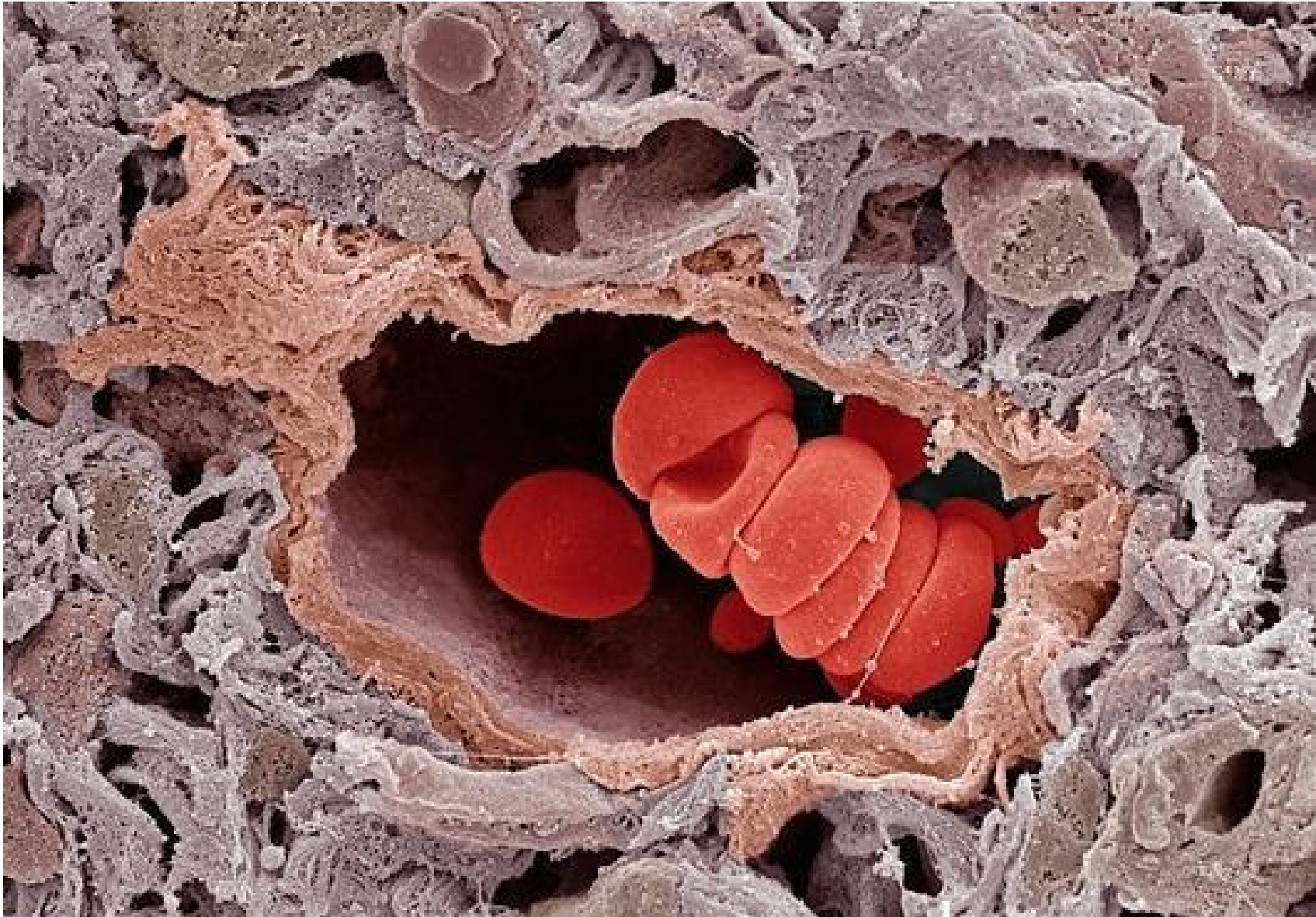
# Tepna



# Žíla



• chlopně

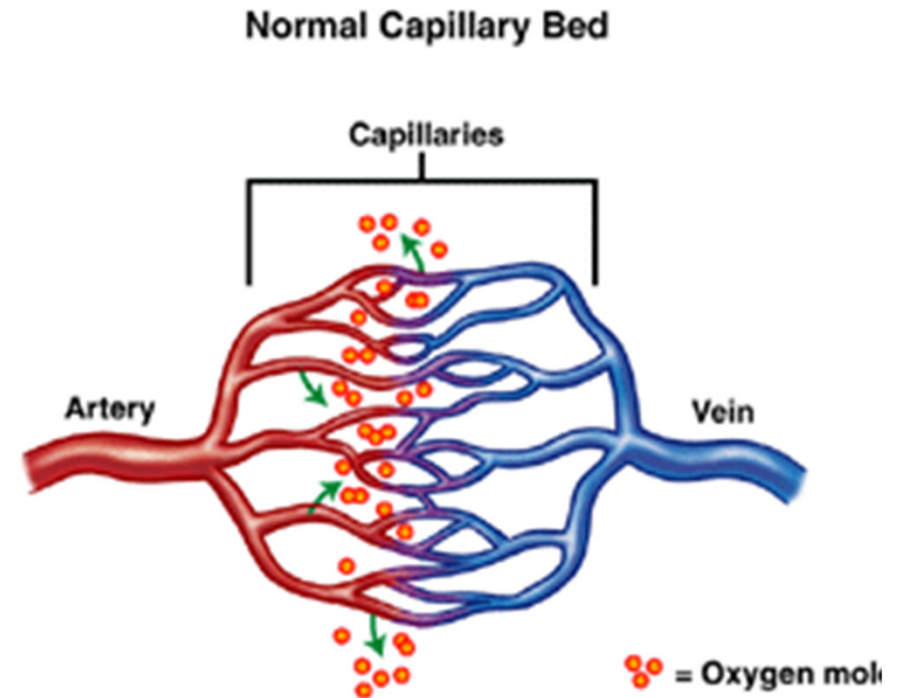
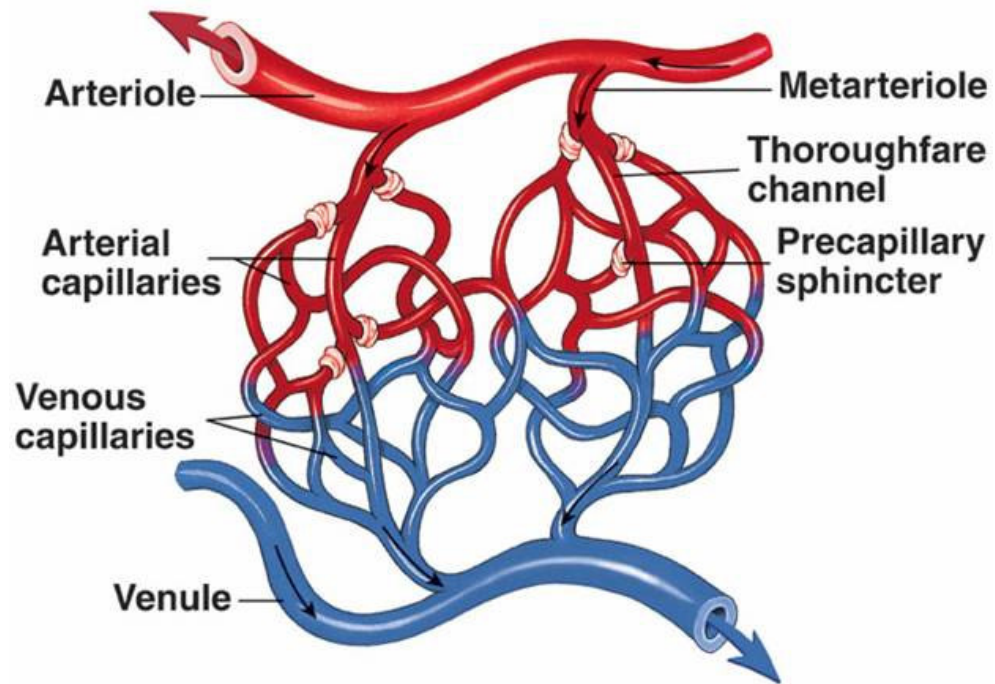


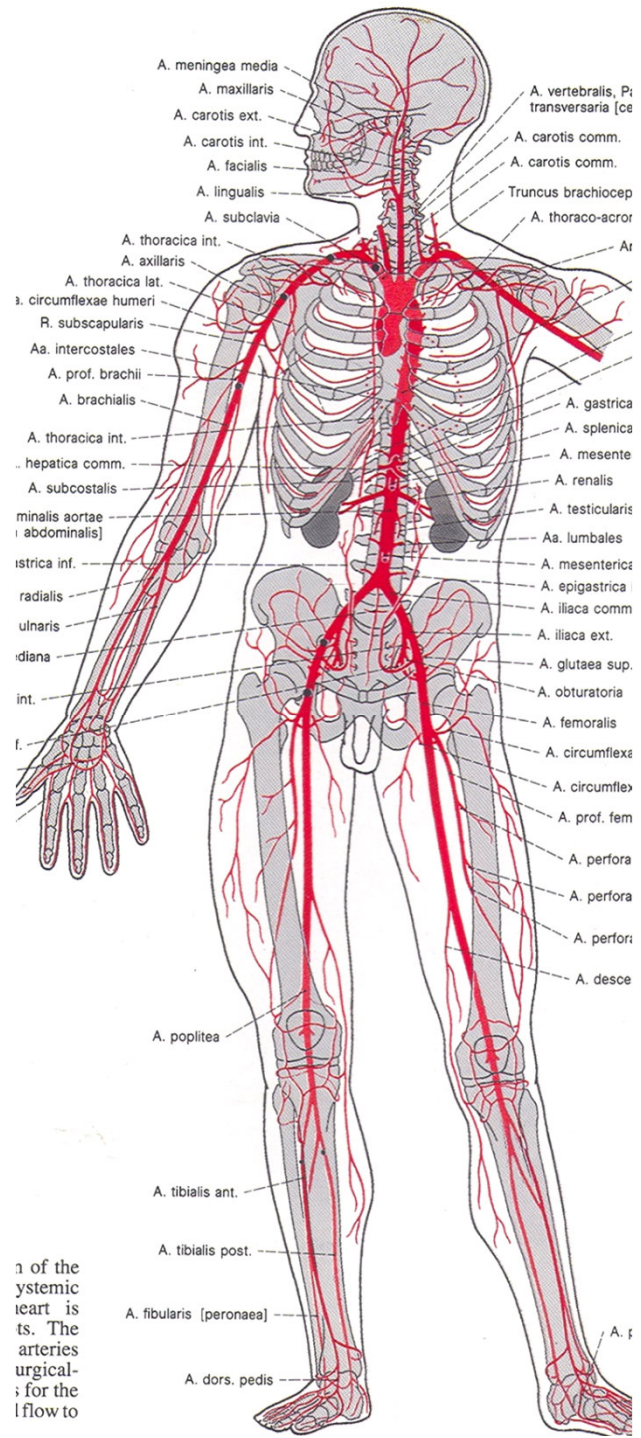


## Vlásečnice (kapiláry)

- spojení mezi tepnami a žilami, výměna látek mezi krví a tkáněmi

Copyright © The McGraw-Hill Companies, Inc. Permission required for reproduction or display.



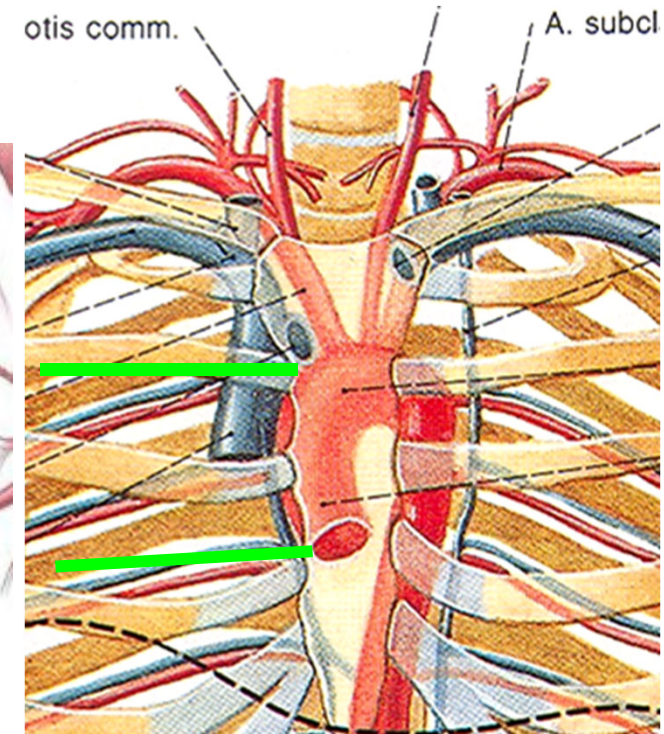
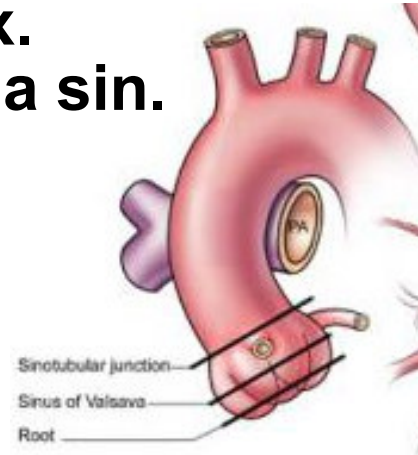

1 of the  
 systemic  
 heart is  
 ts. The  
 arteries  
 urgical-  
 ; for the  
 lflow to

# Aorta

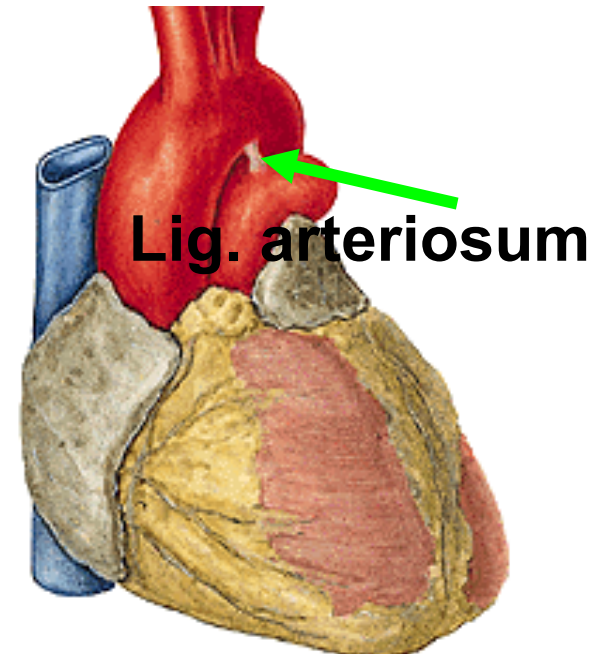
Aorta ascendens: ventriculus sin. -

- 2. art. sternocostalis dx.
- a. coronaria cordis dx. a sin.



Arcus aortae: 2. art. sternocostalis dx. - levou stranu Th<sub>3</sub>

- truncus brachiocephalicus (a. carotis communis dx. a a. subclavia dx.)
- a. carotis communis sin.
- a. subclavia sin.

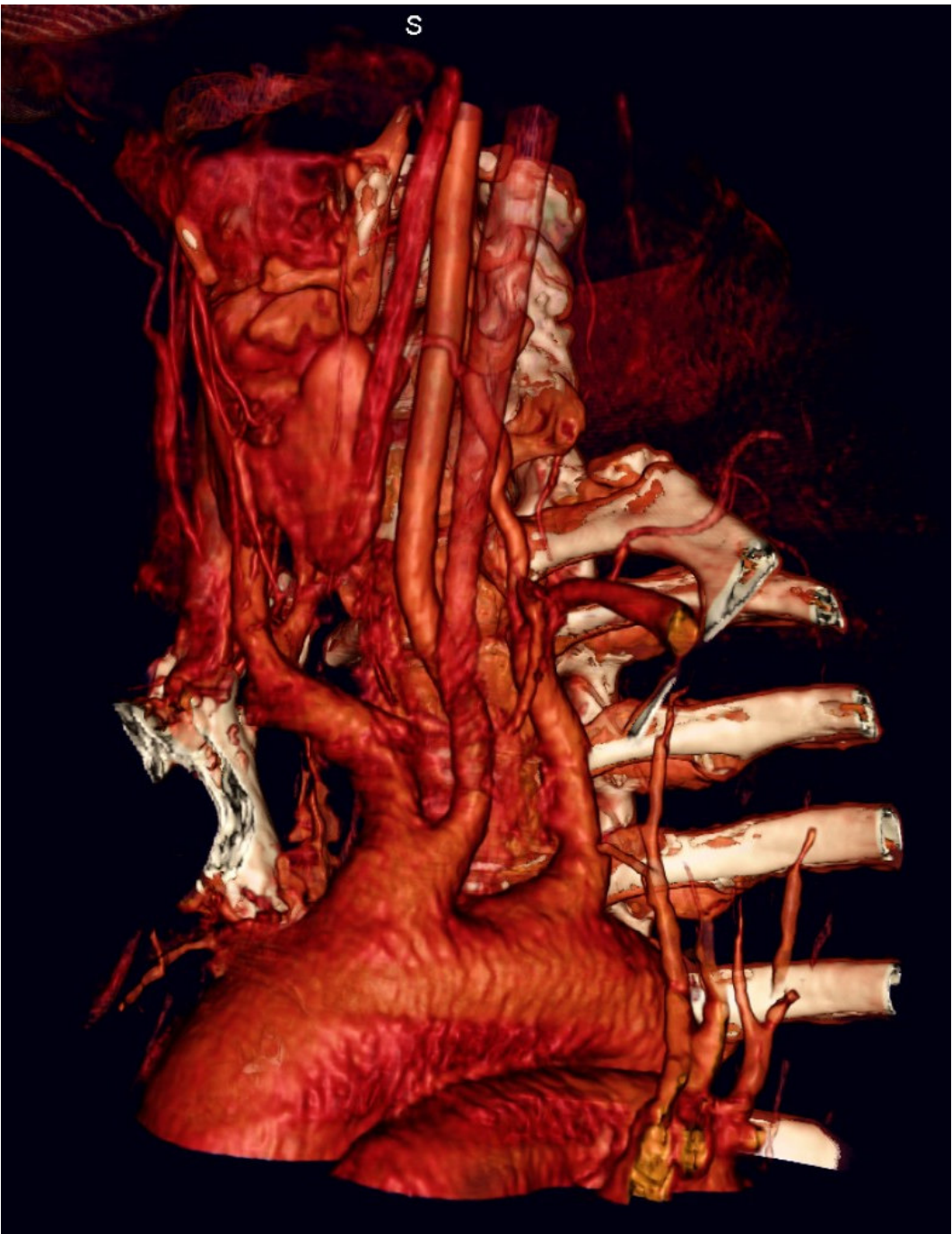

Aorta descendens: od Th3 – L4

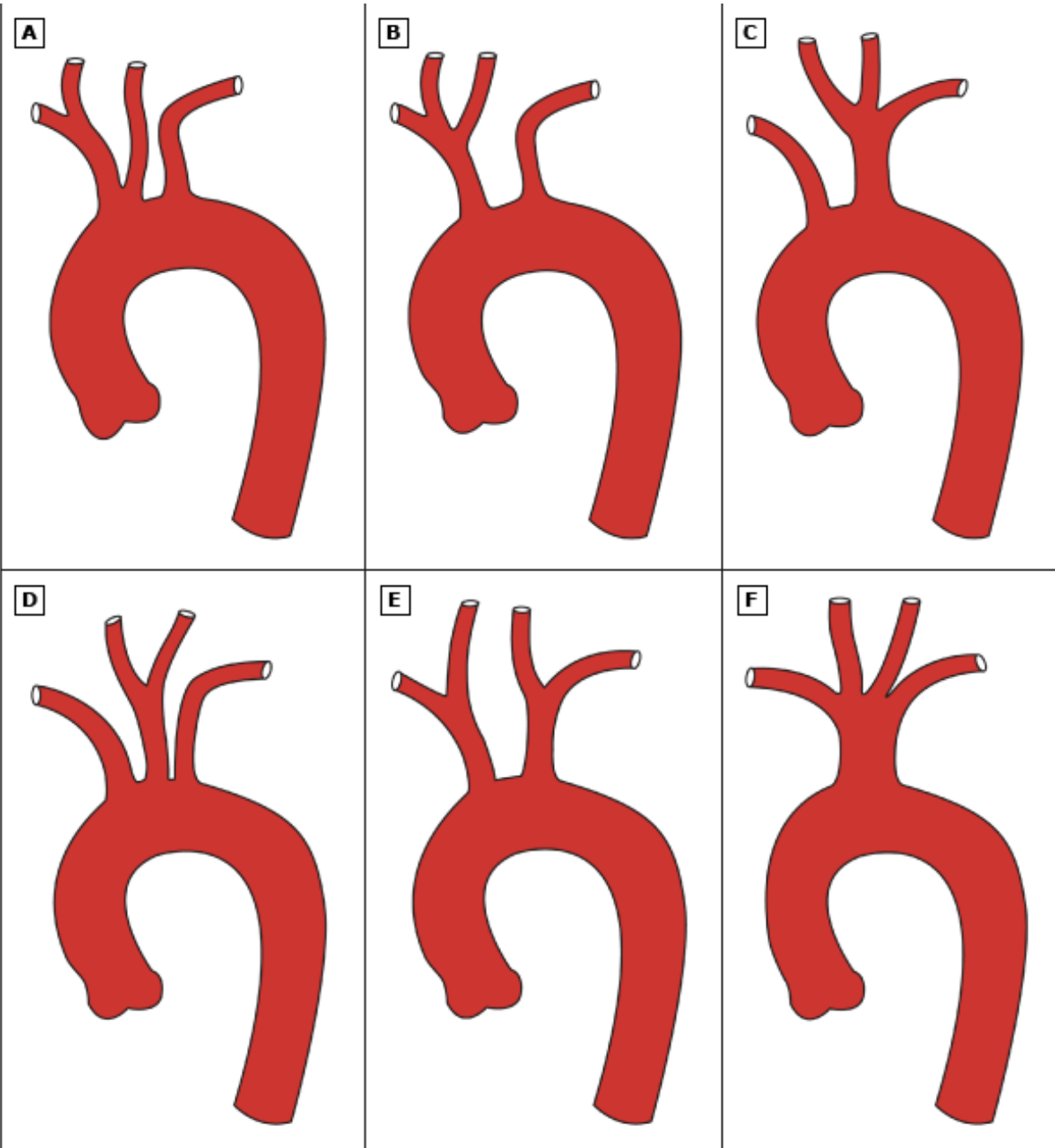
Aorta thoracica

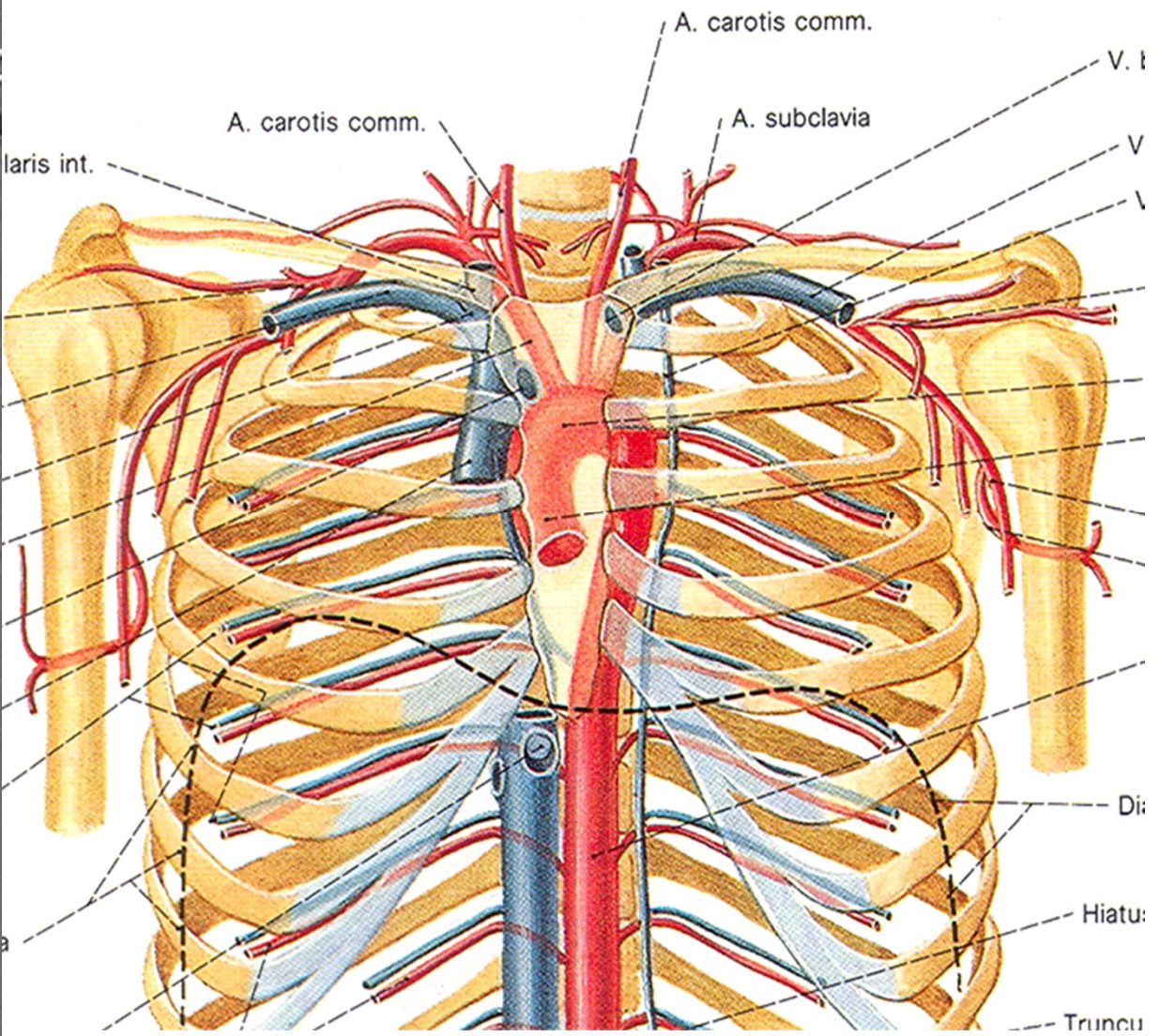
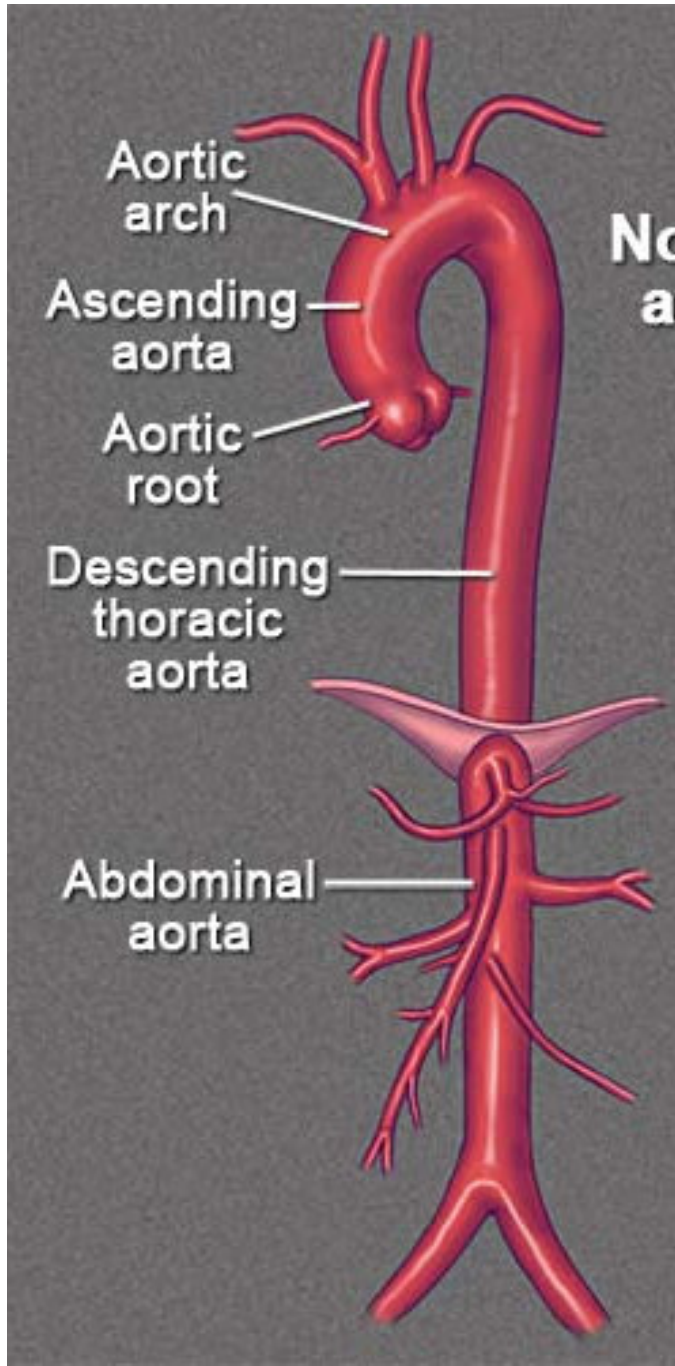
Aorta abdominalis (odděleny bránicí)





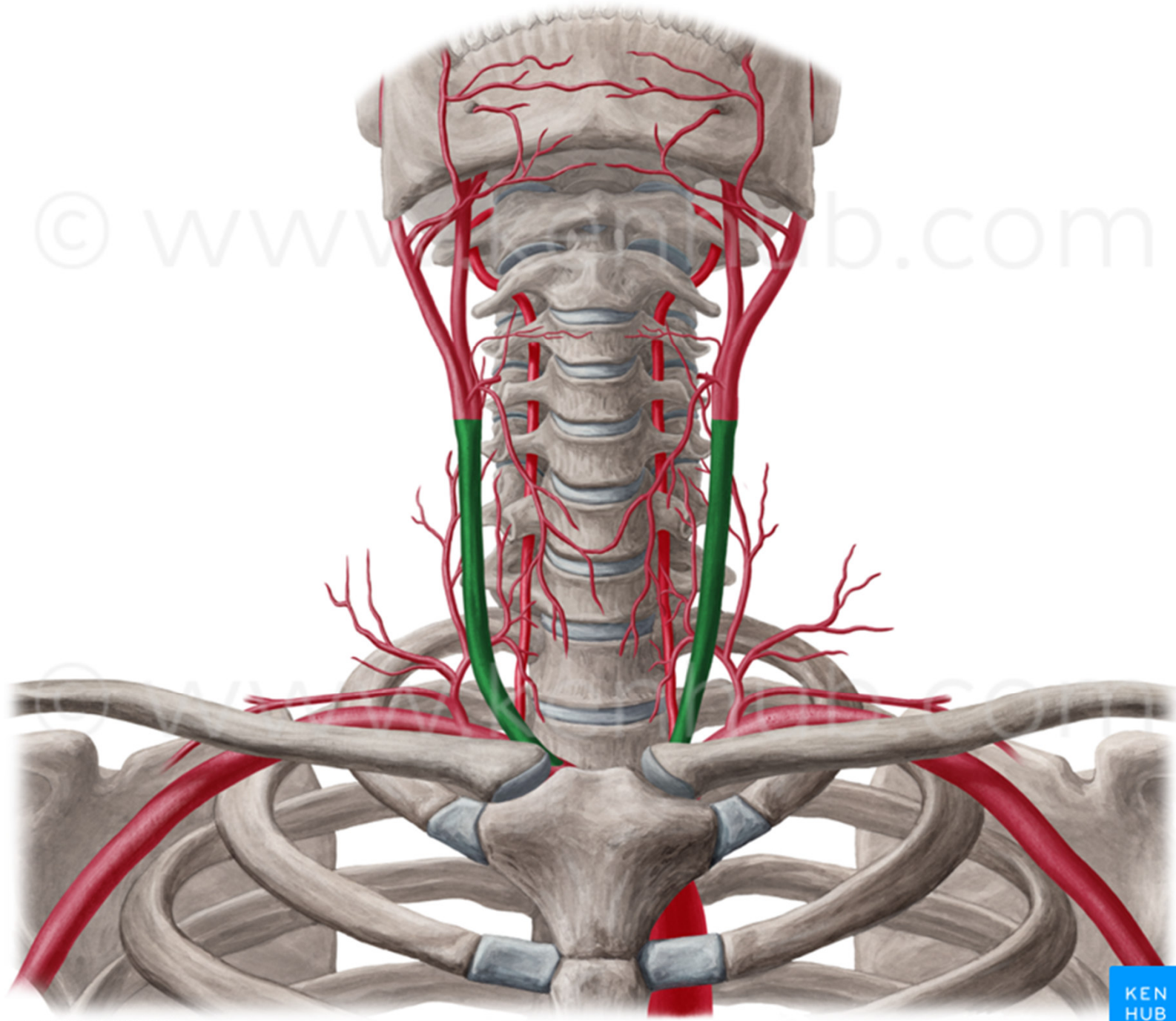




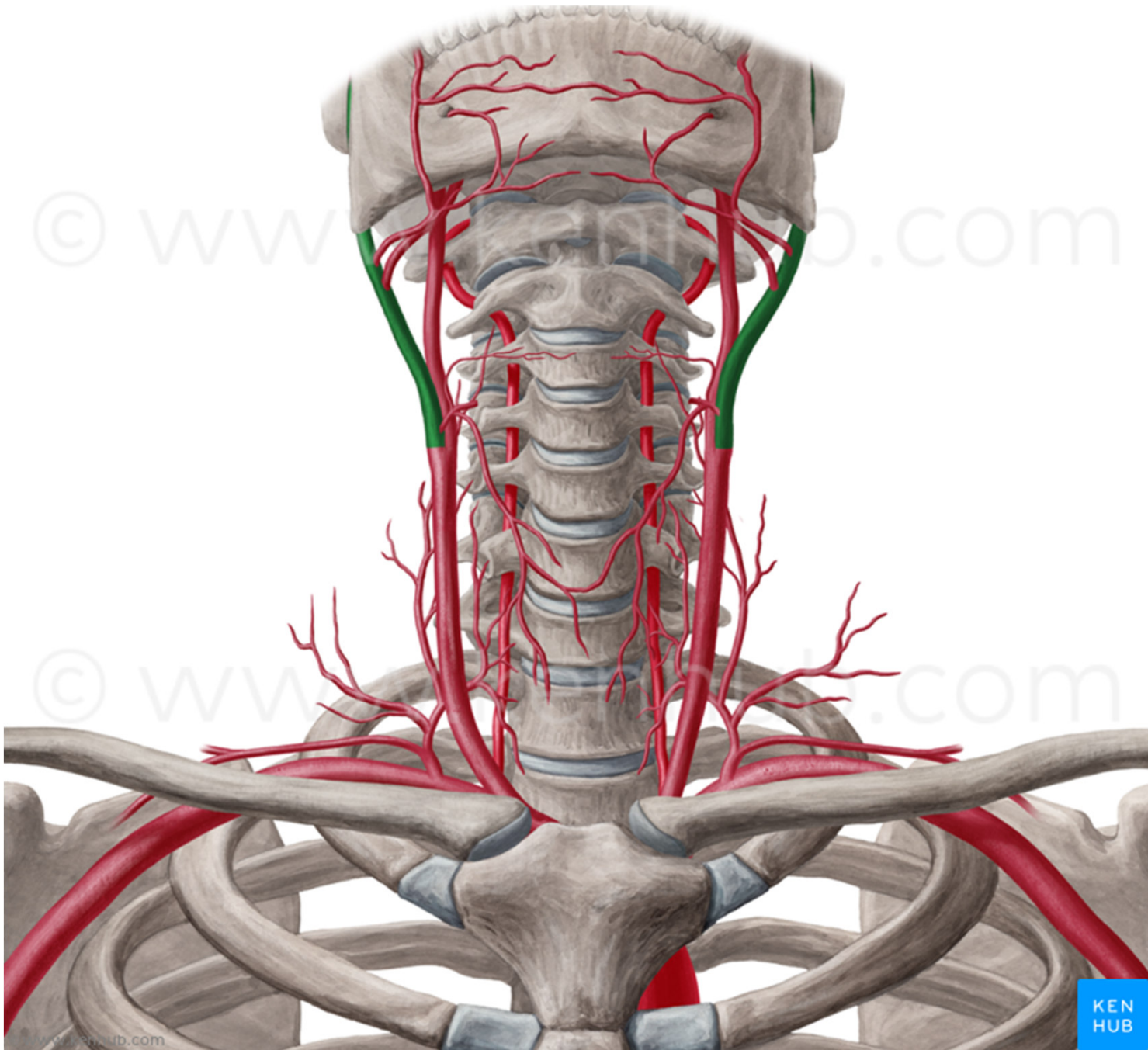


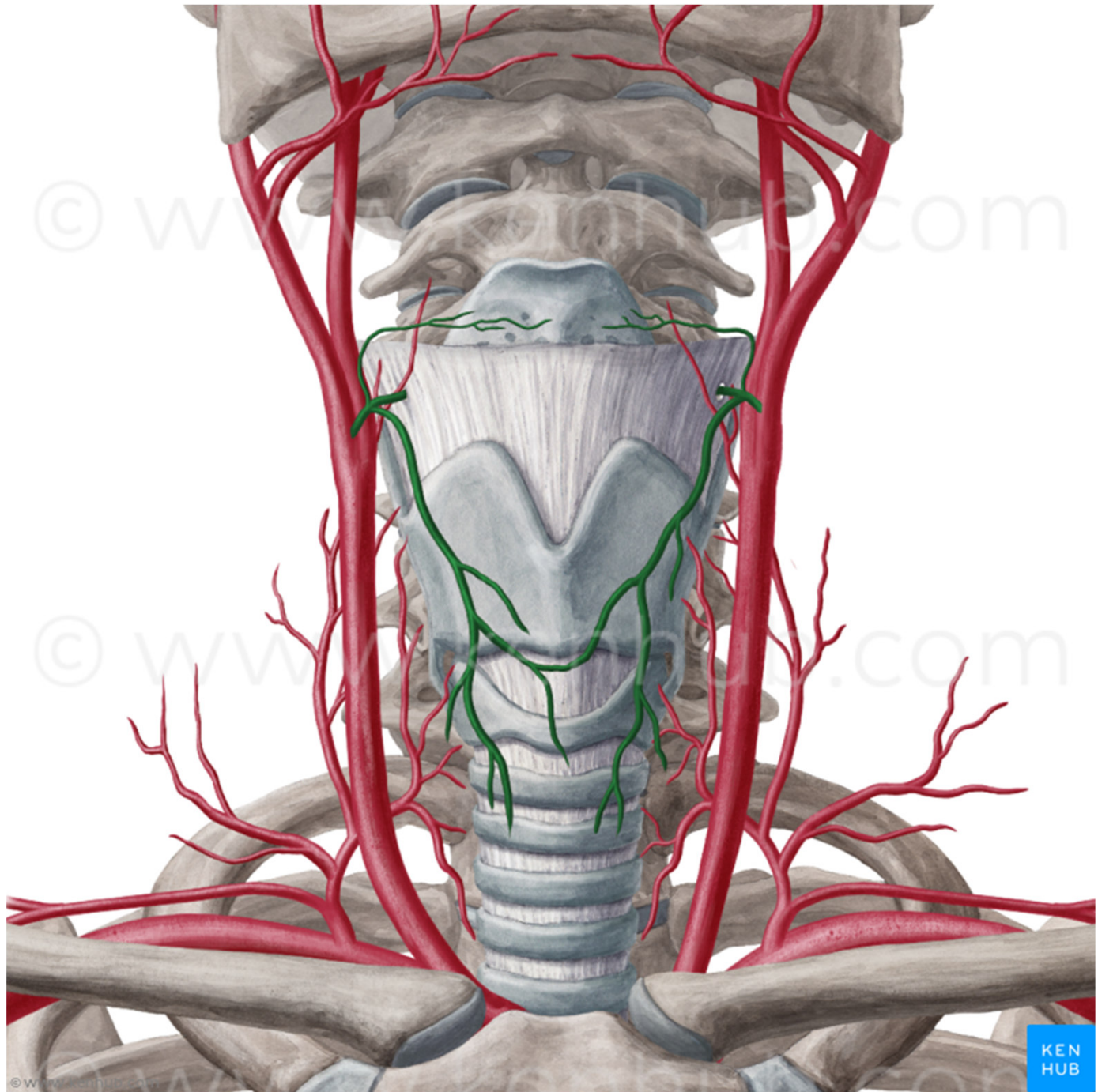




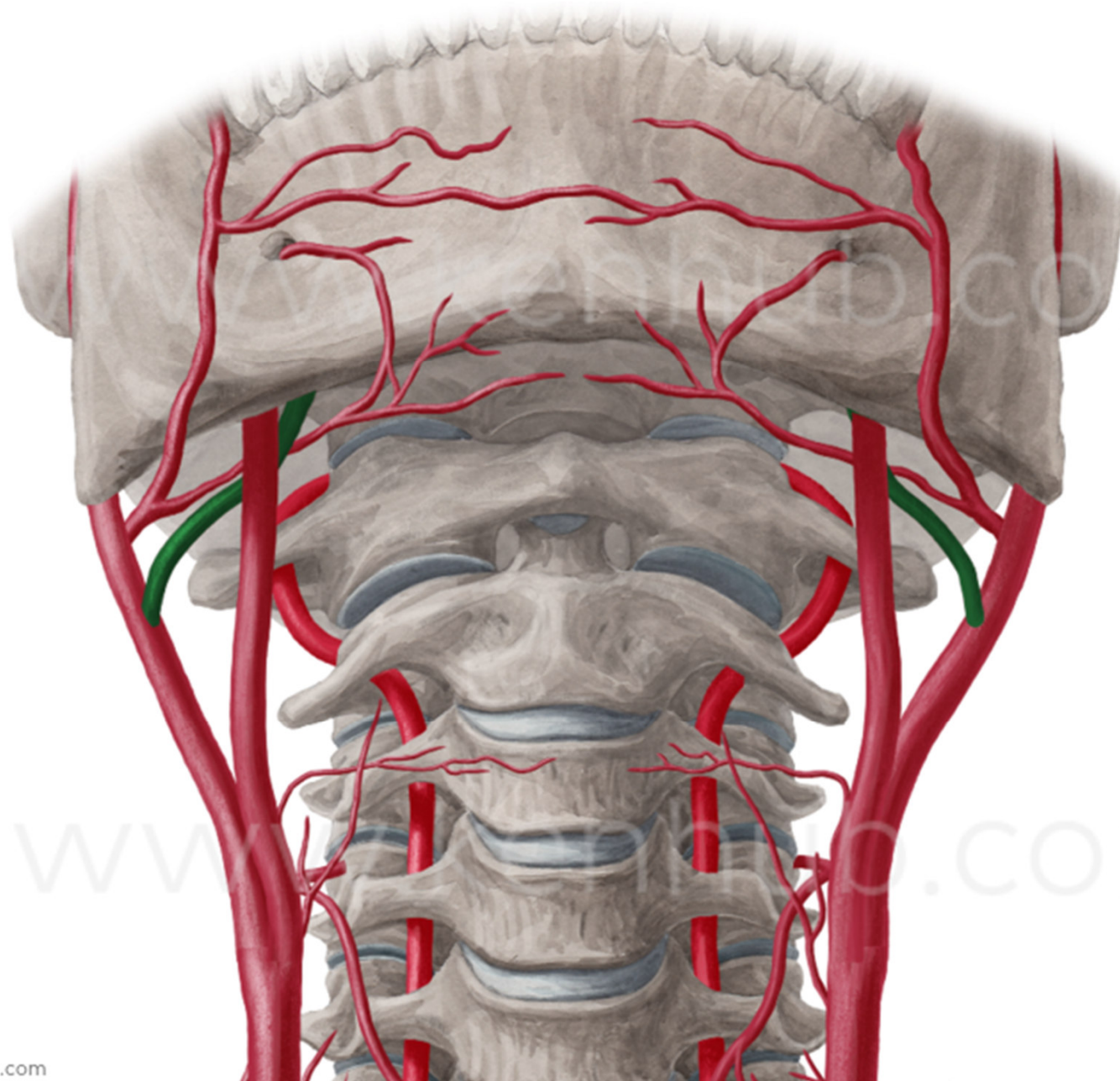


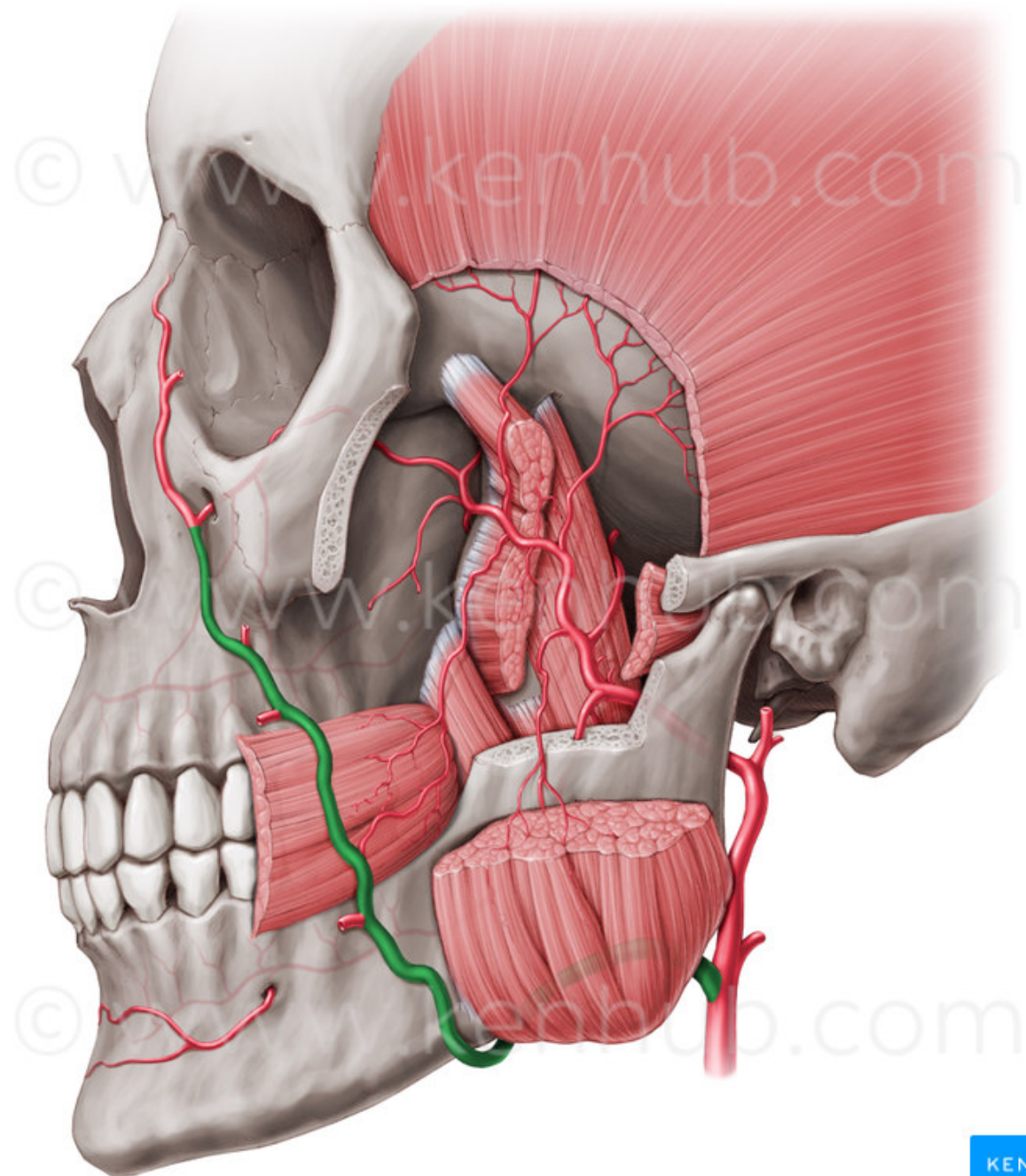




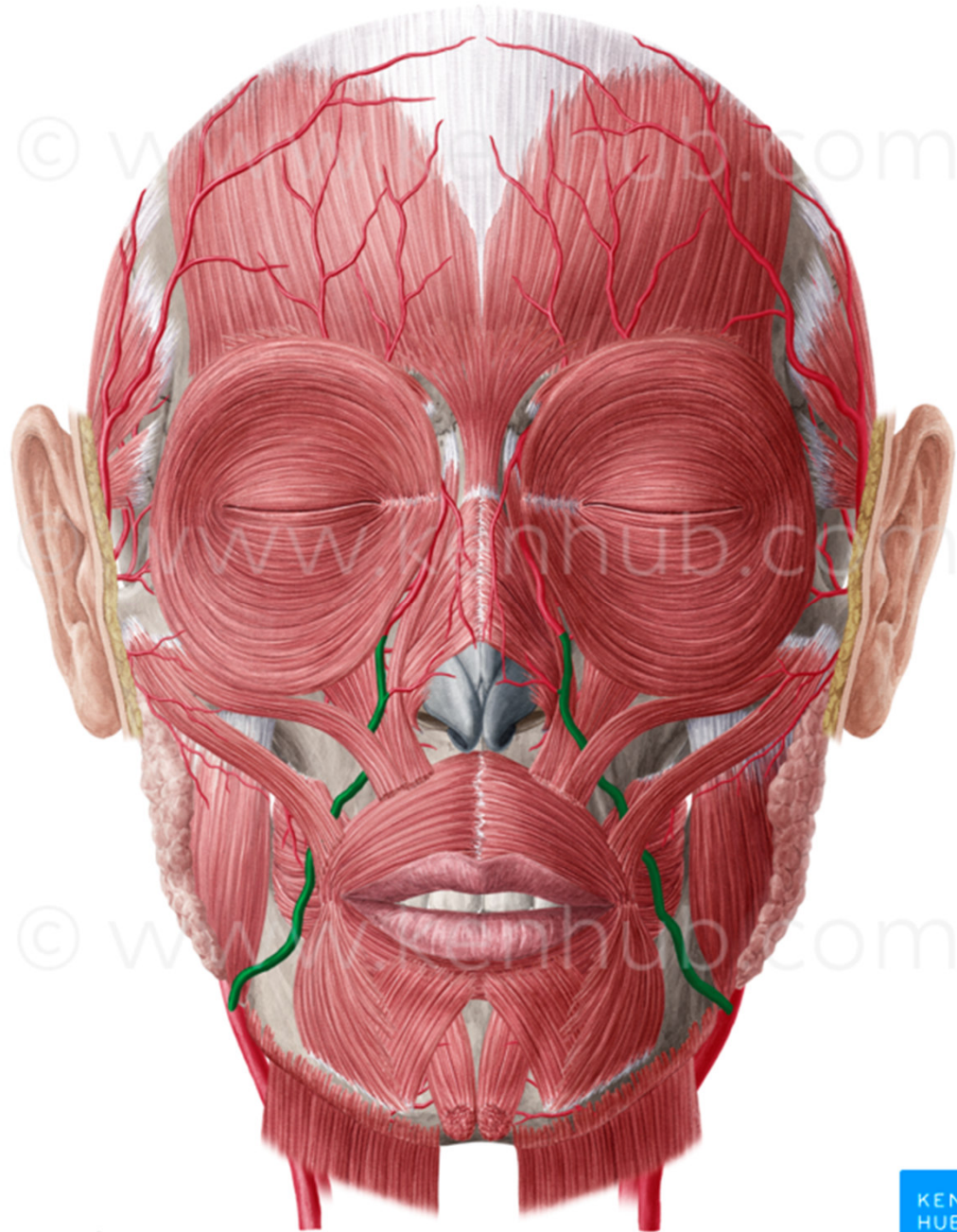


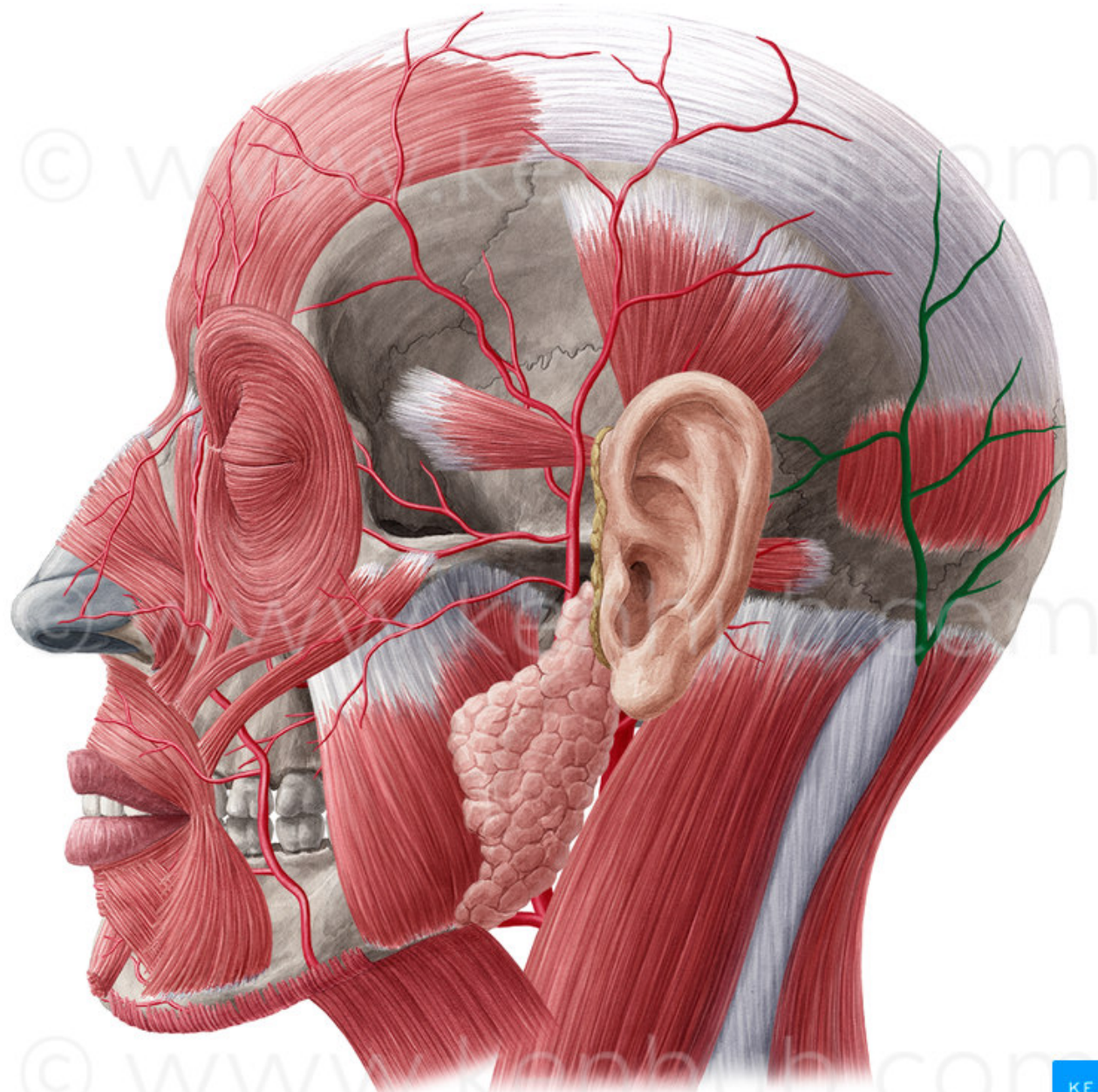




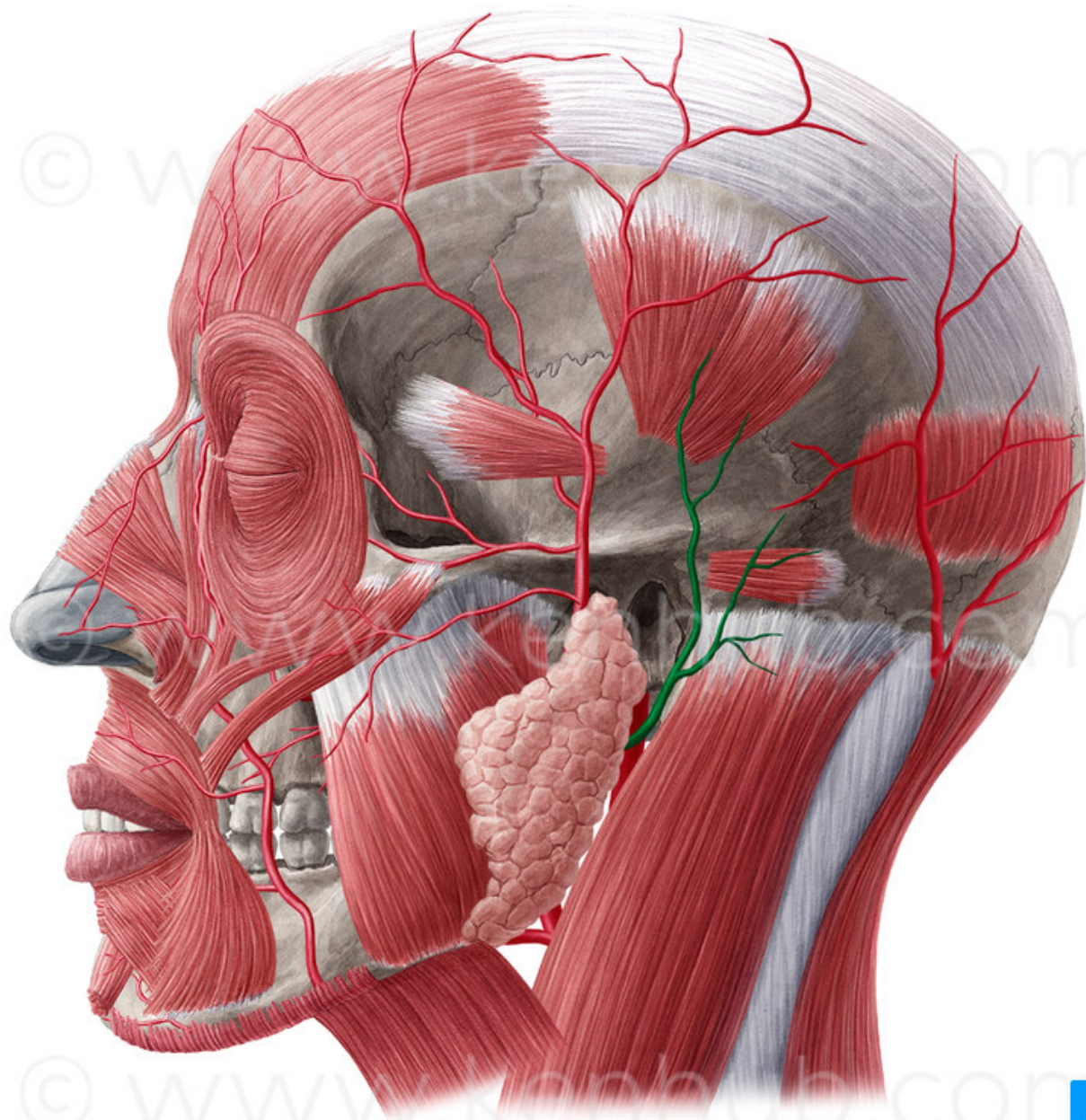


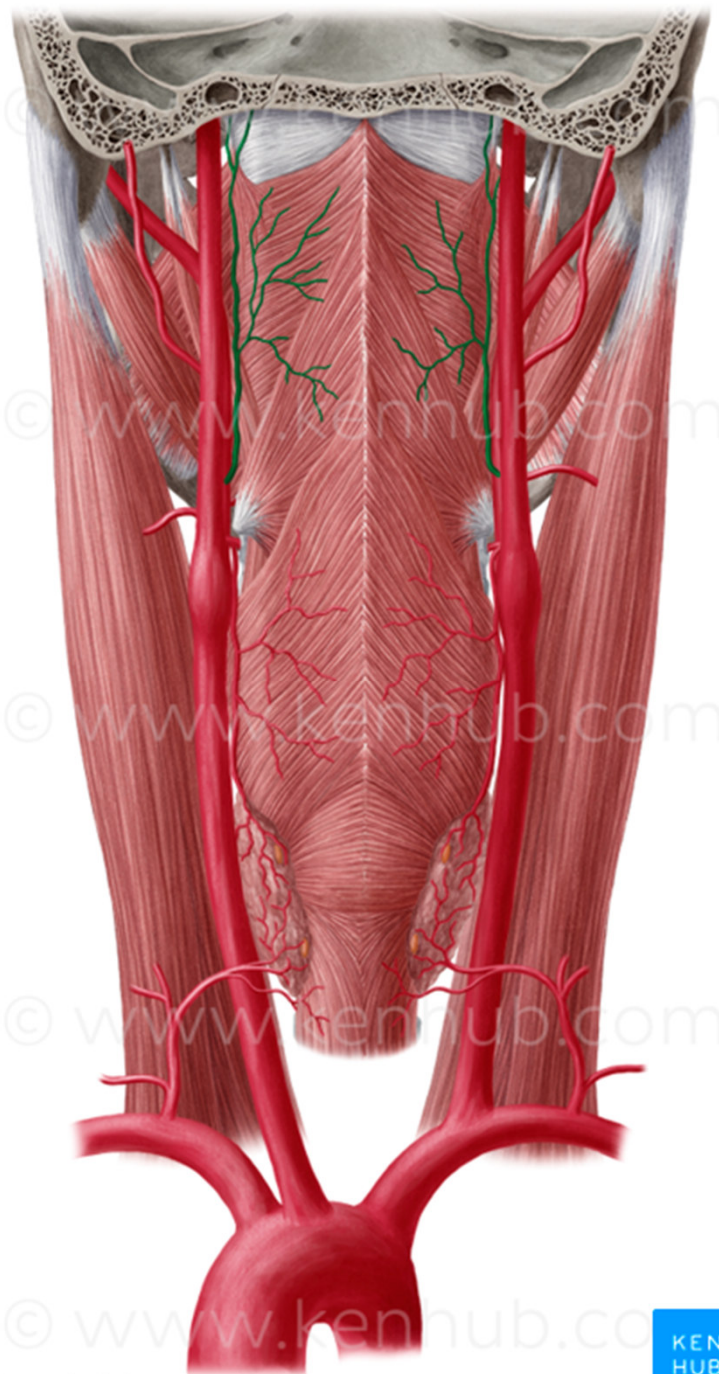












© www.kenhub.com

© www.kenhub.com

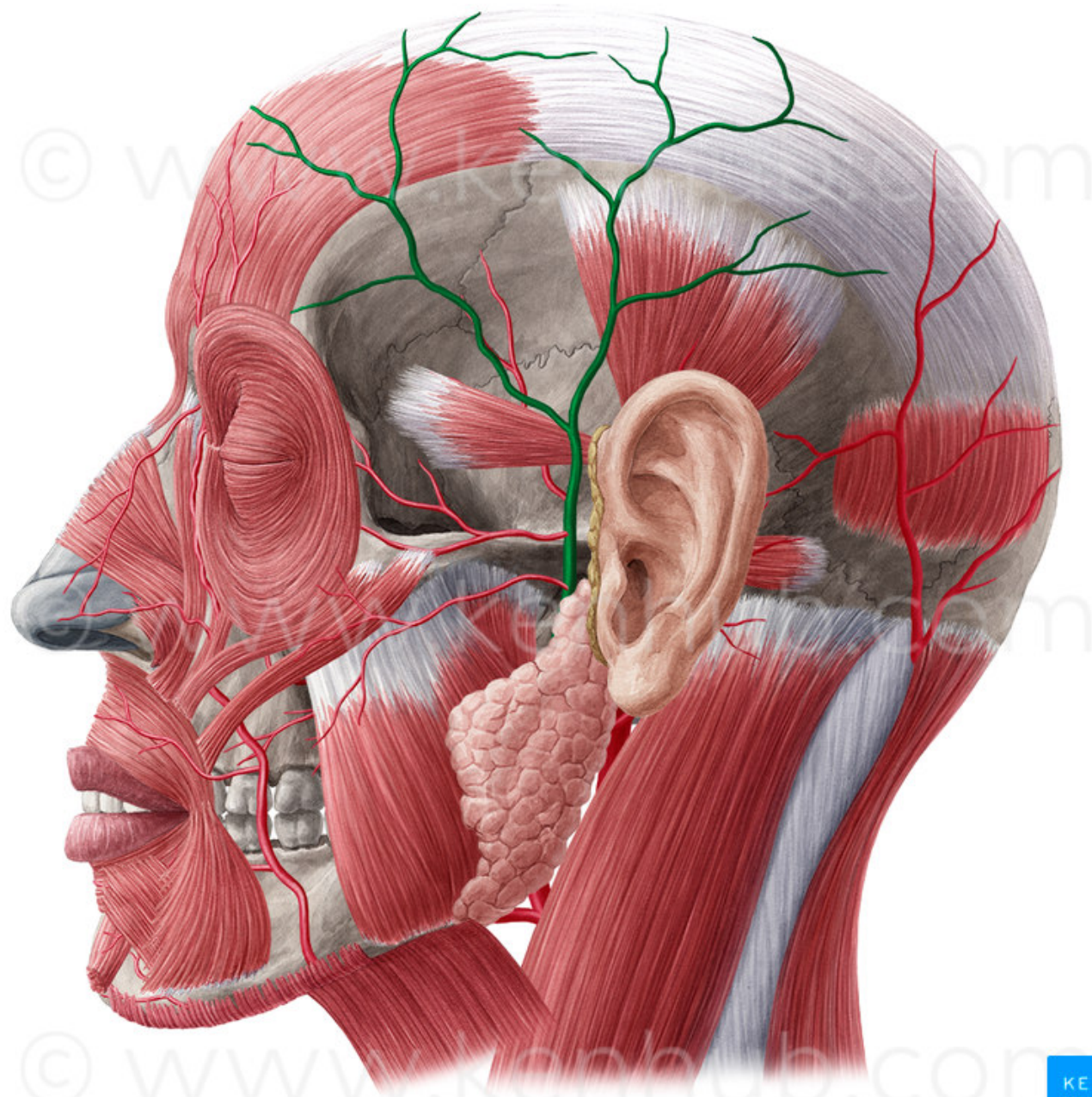
© www.kenhub.com

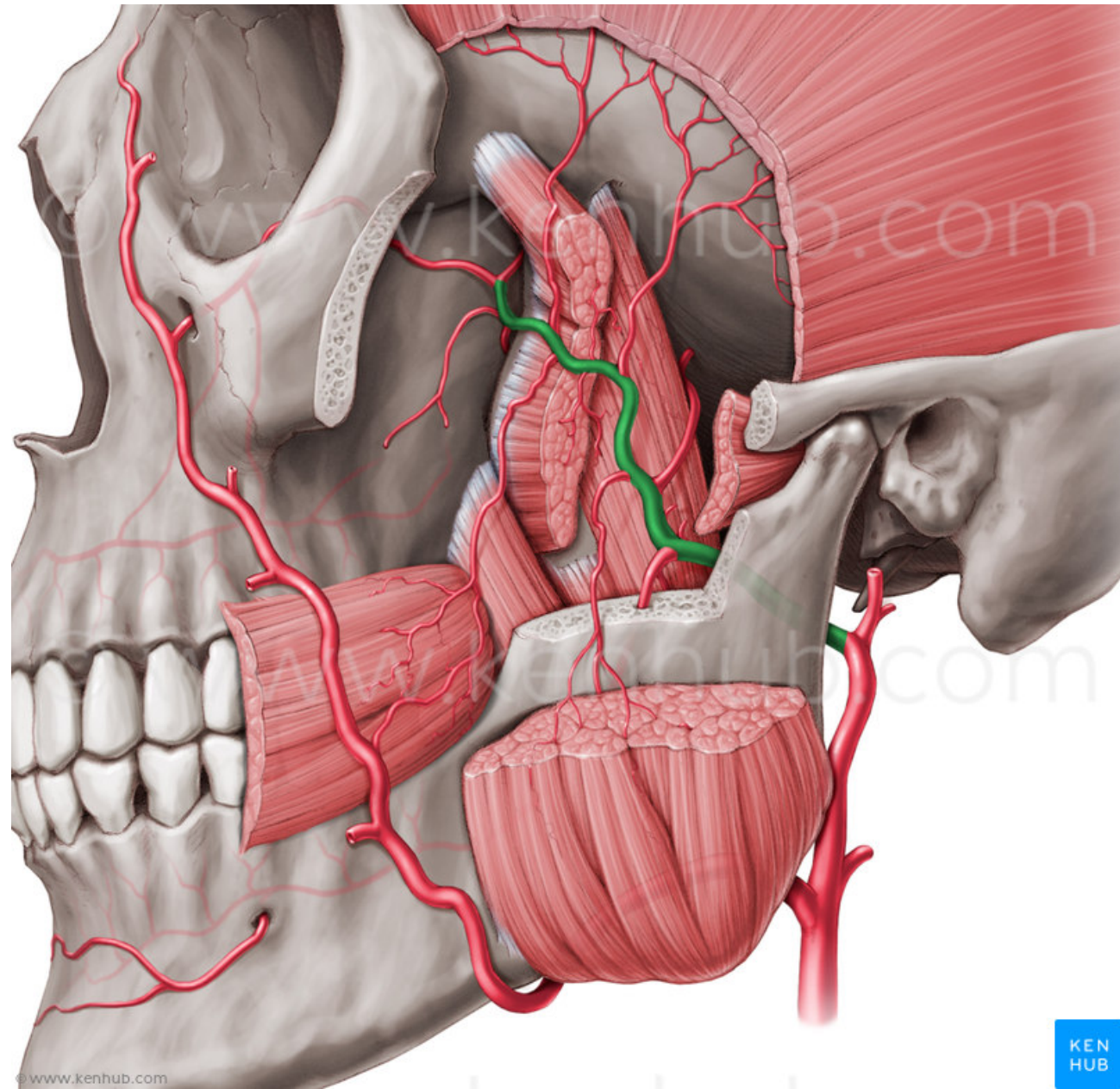
© www.kenhub.com

© www.kenhub.com

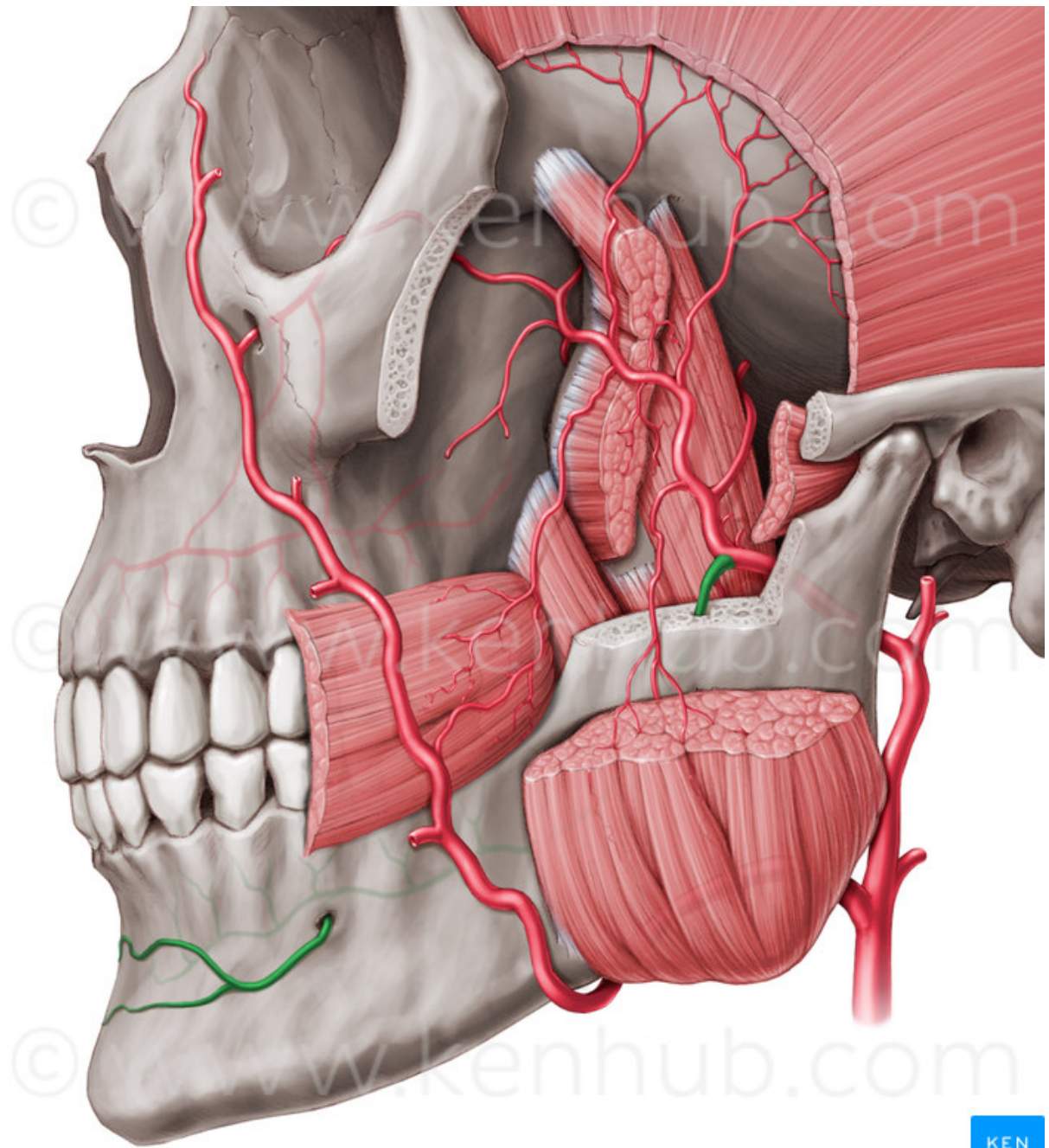




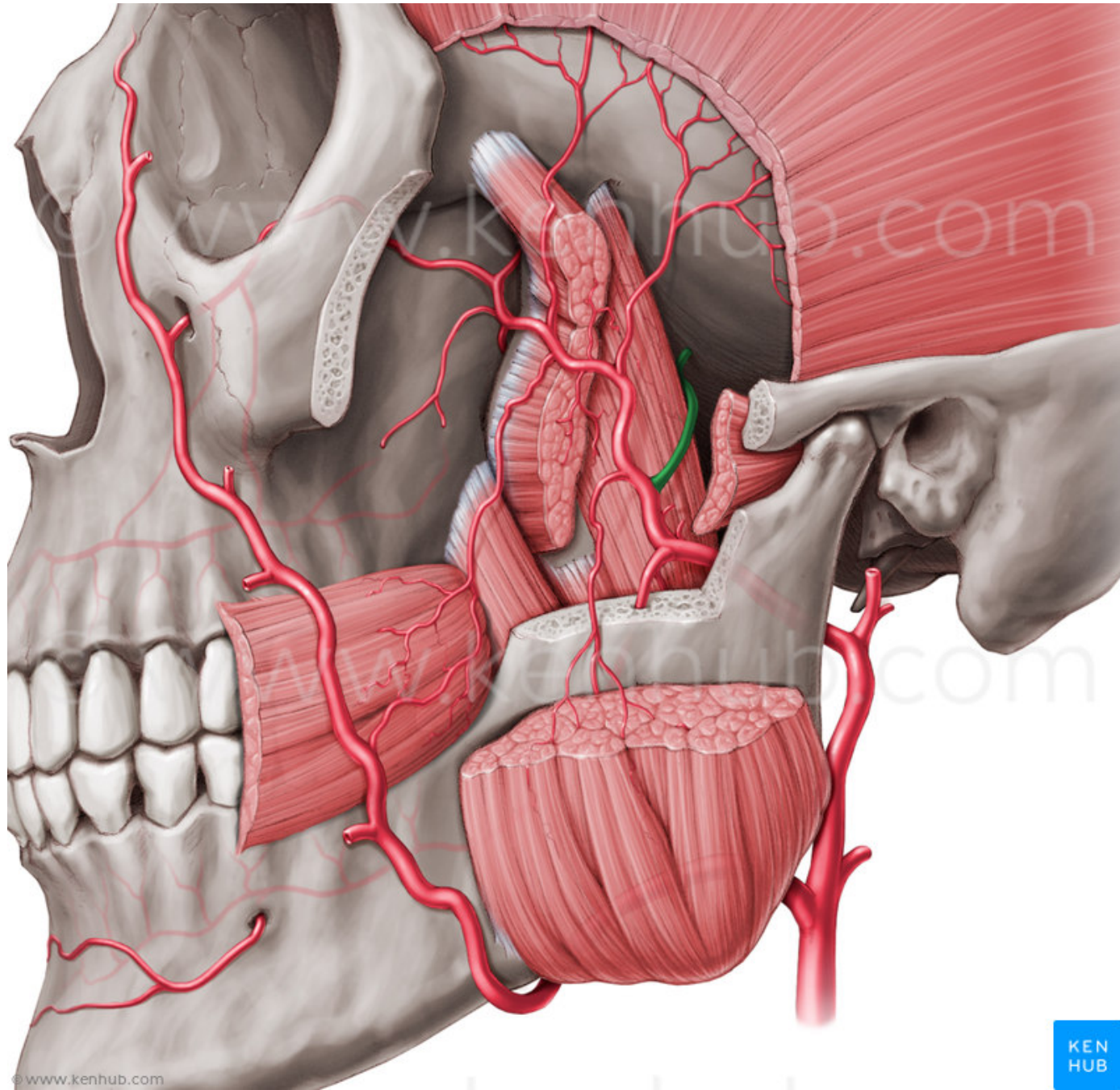








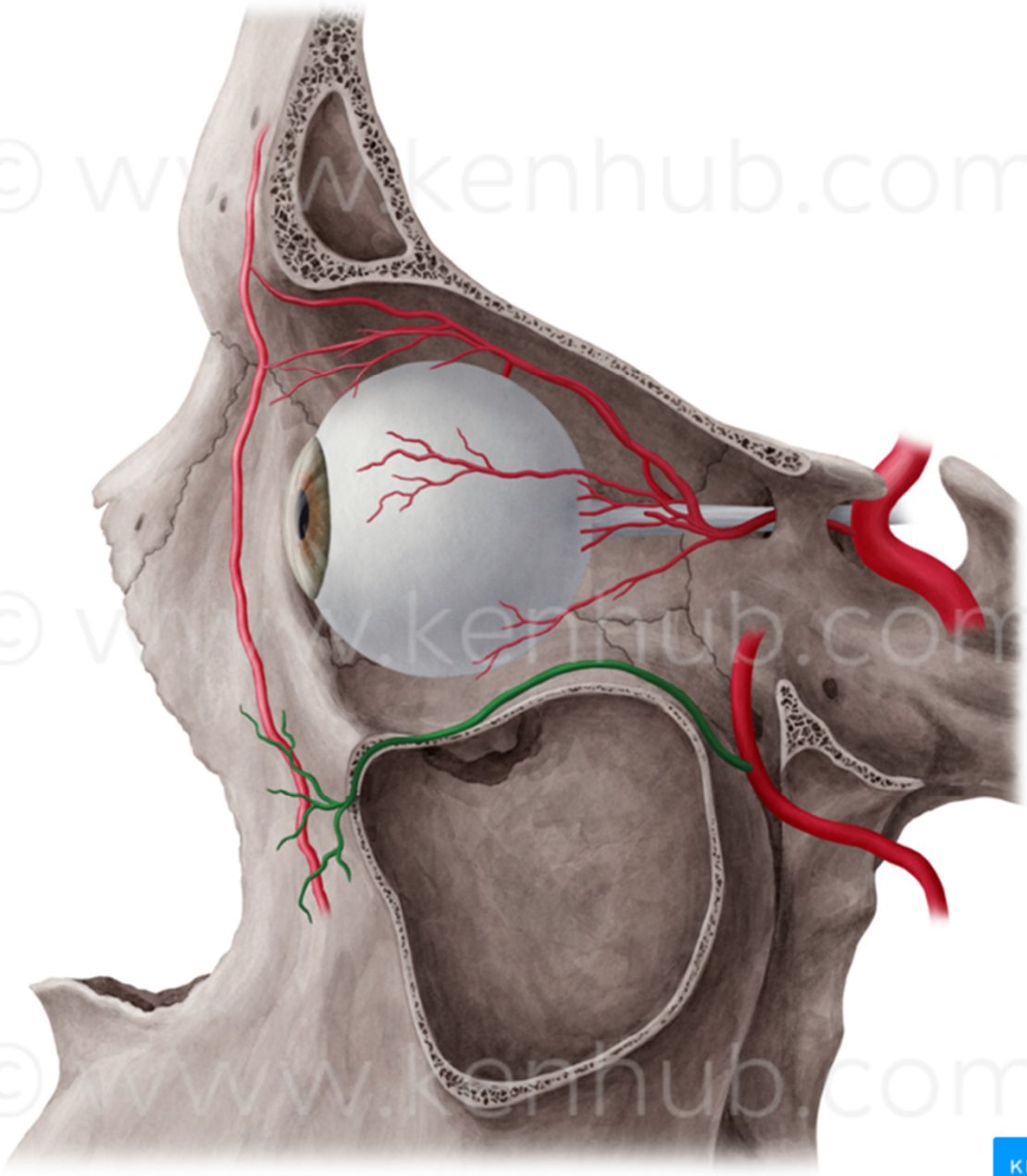




© www.kenhub.com

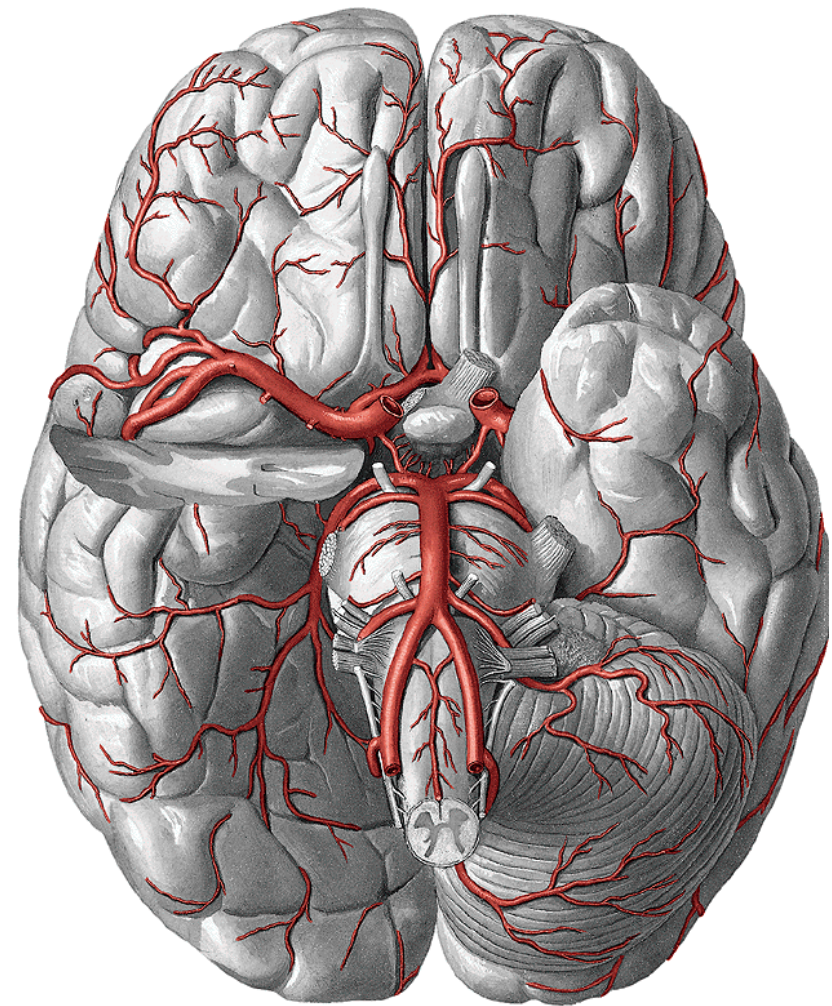
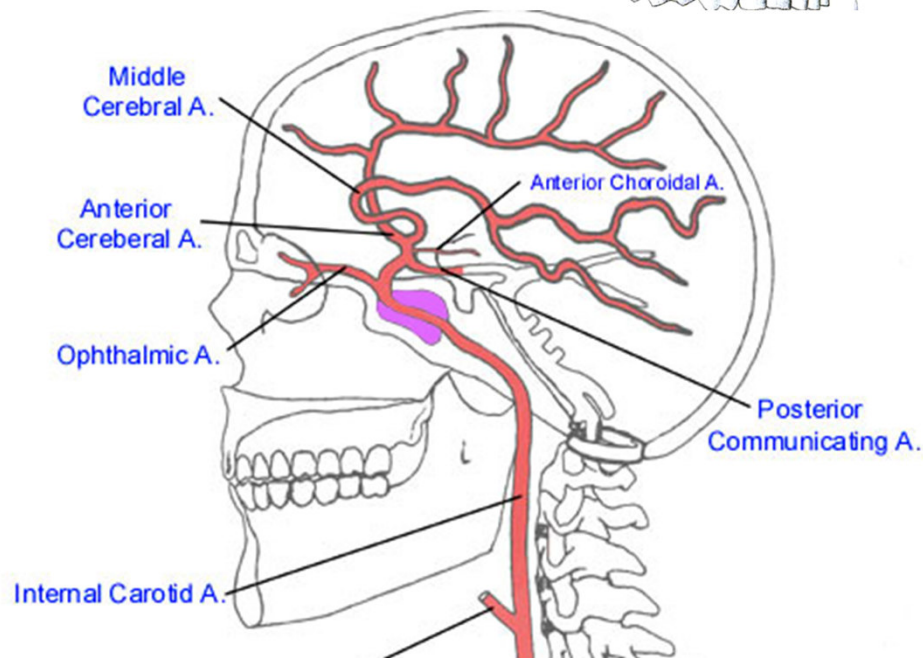
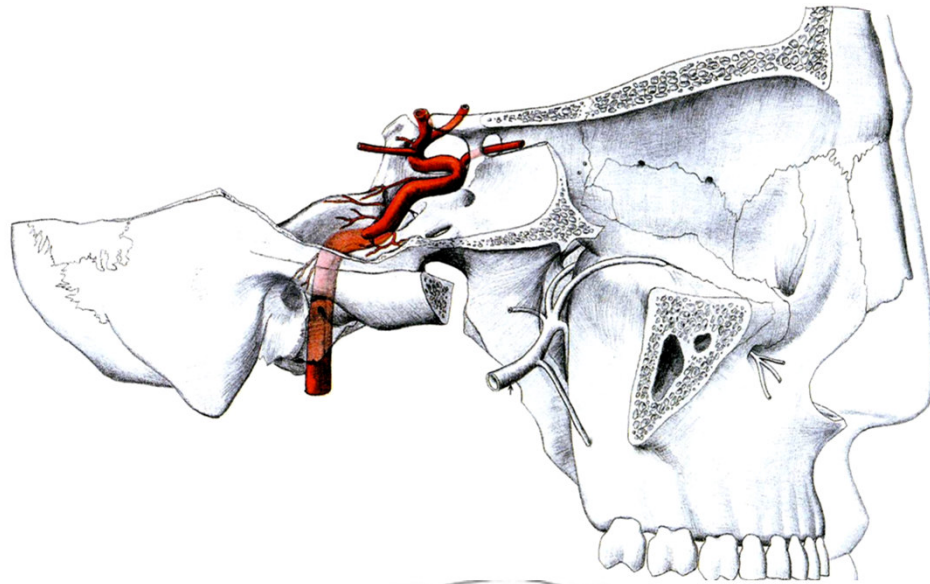
© www.kenhub.com

© www.kenhub.com

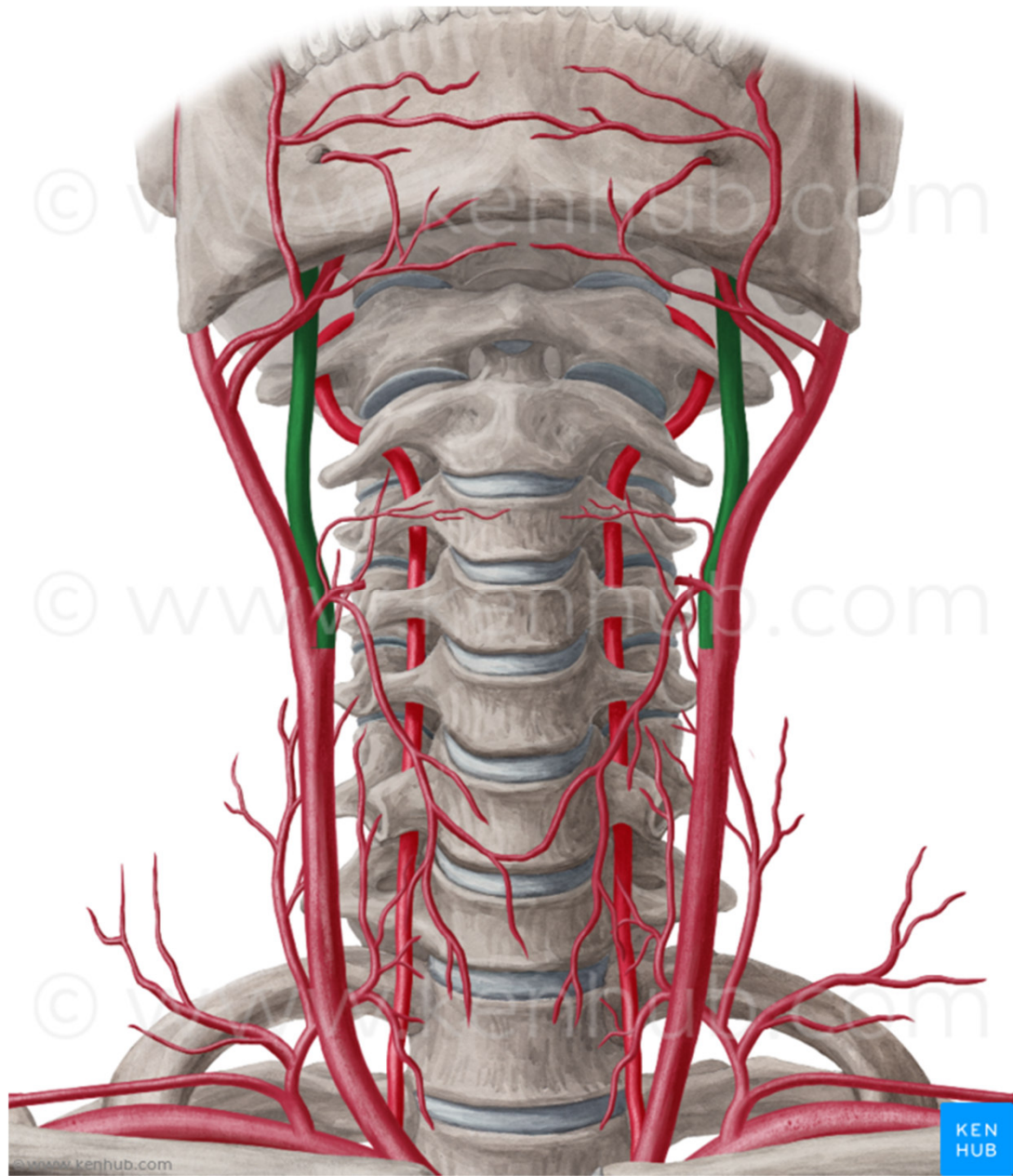


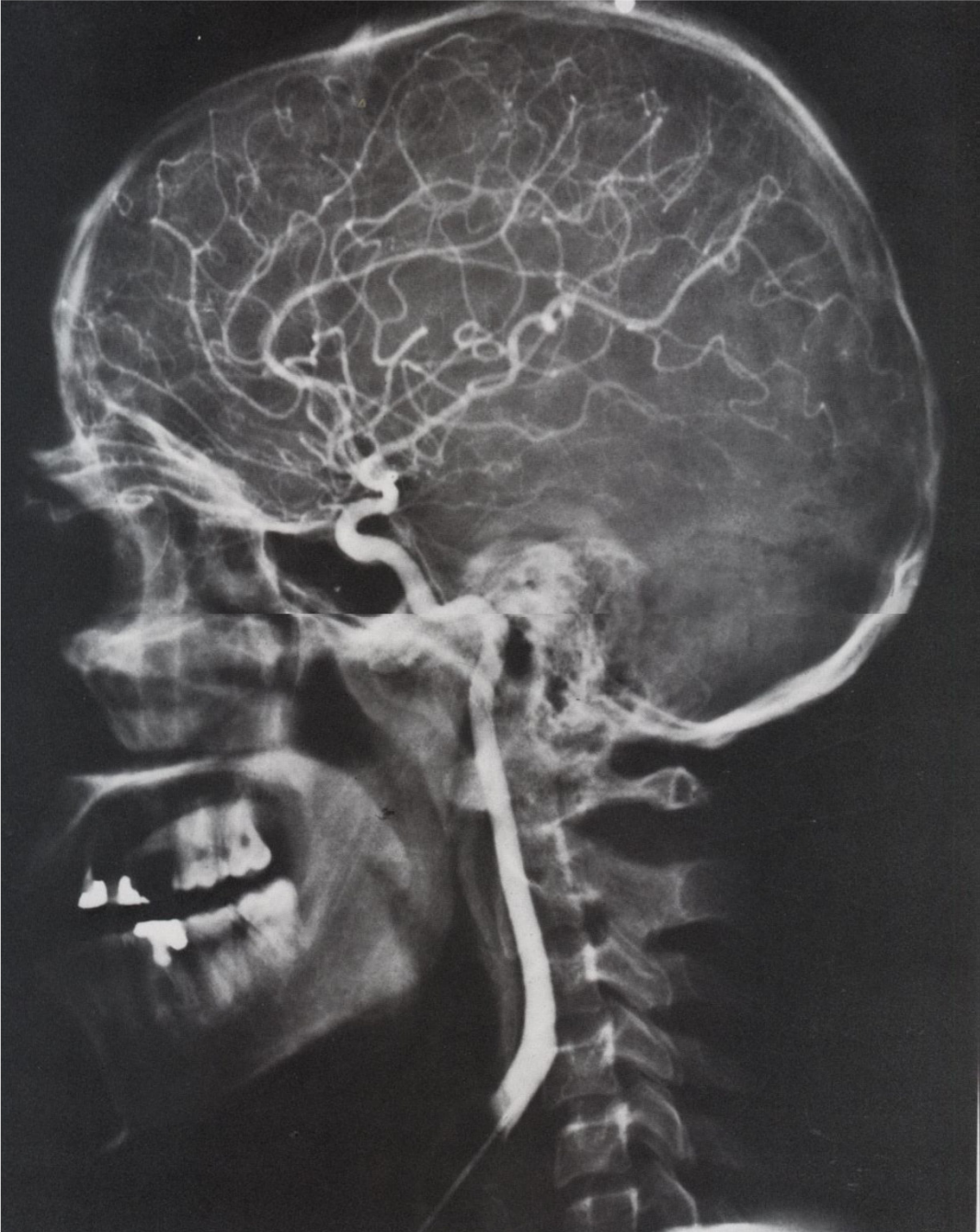

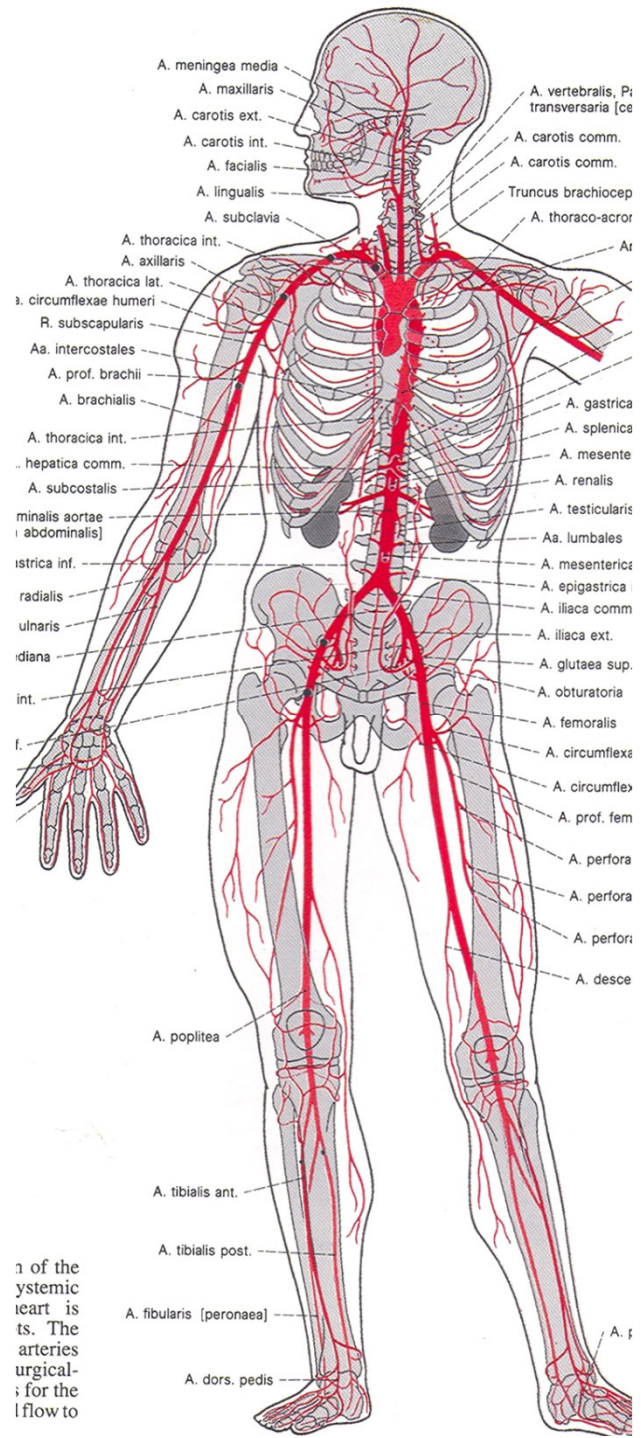
2) a. carotis interna – přes apertura externa canalis carotici do střední jámy lební, zásobuje přední část hemisfér a očníci







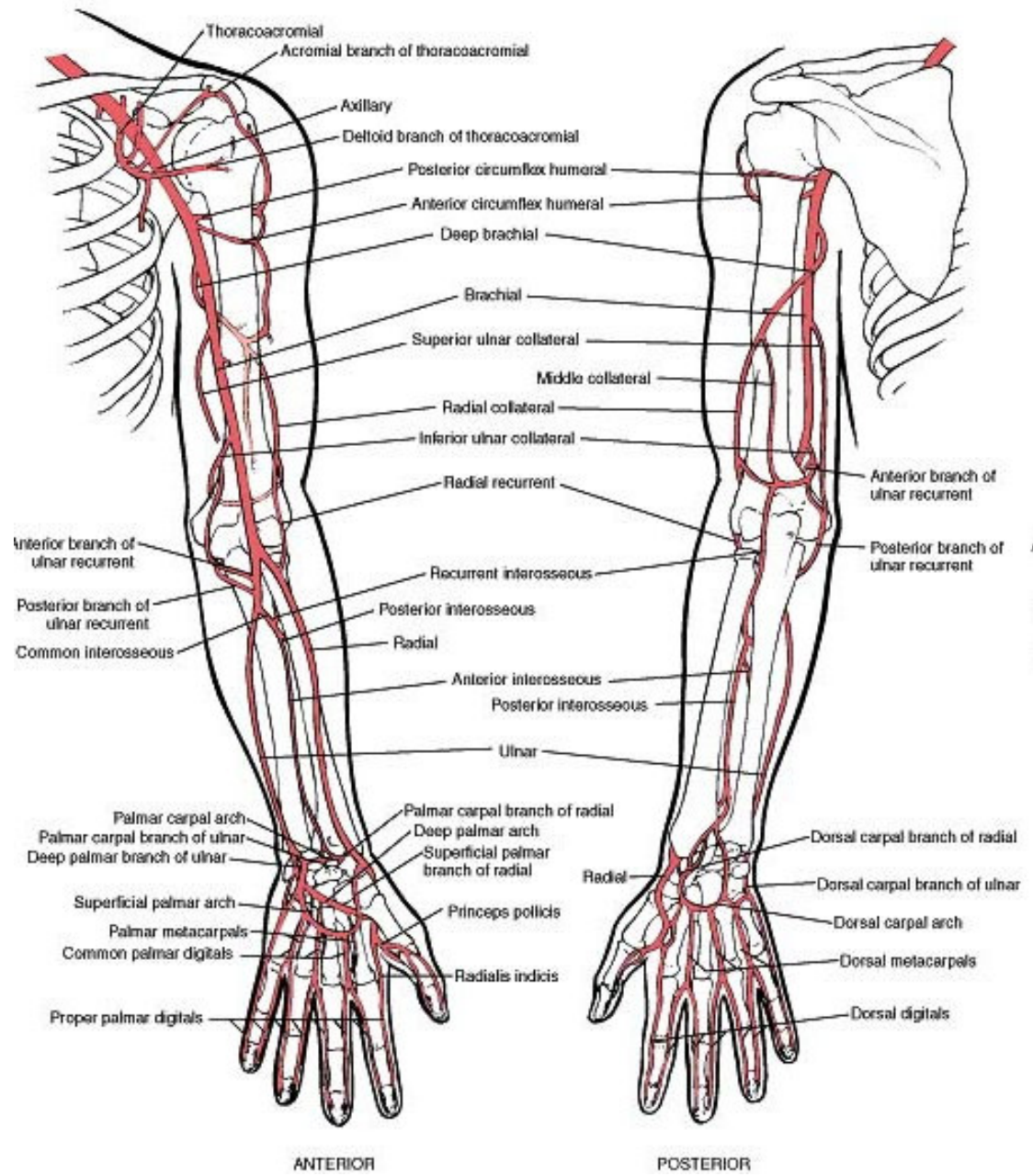




1 of the  
 systemic  
 heart is  
 ts. The  
 arteries  
 urgical-  
 ; for the  
 lflow to

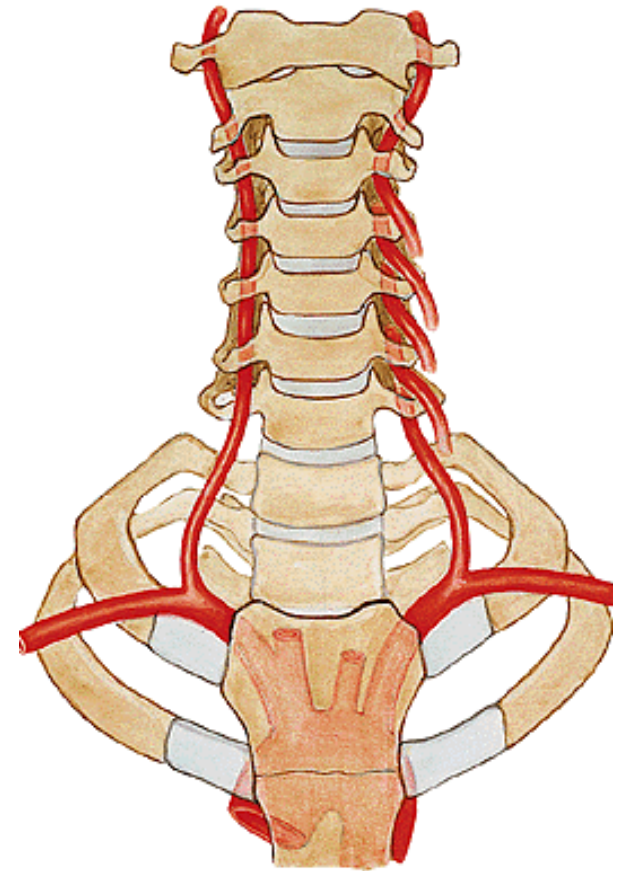
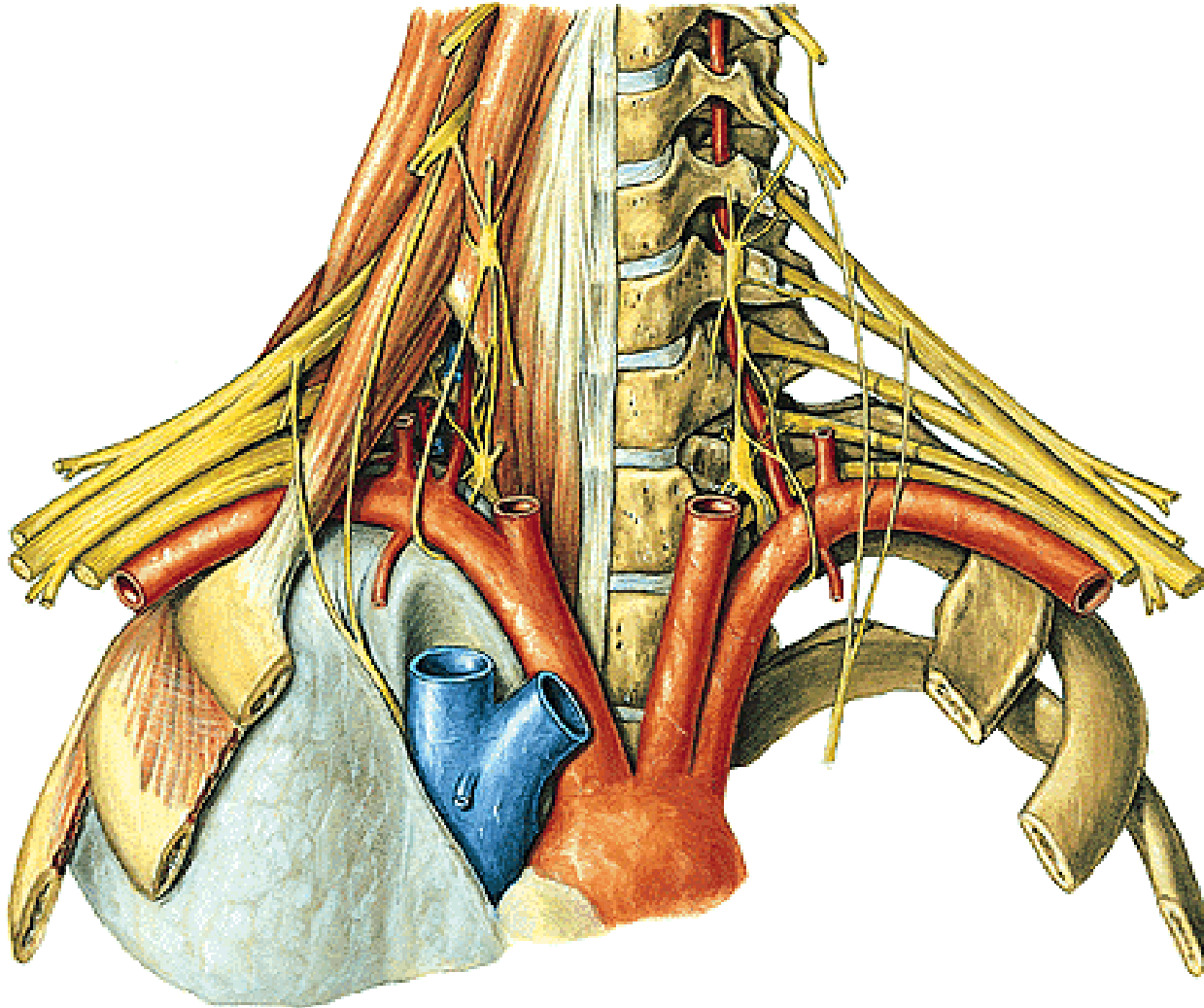


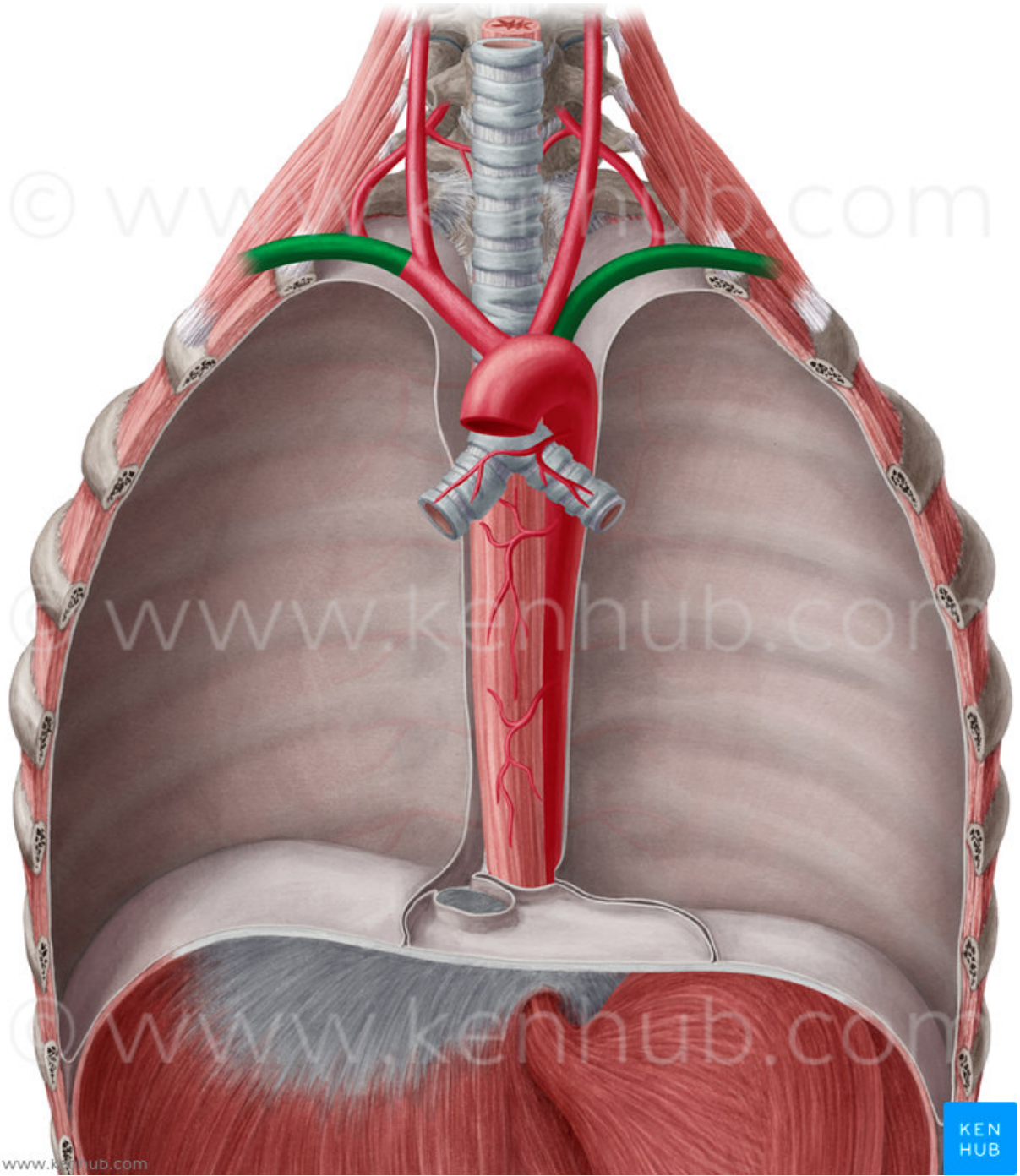
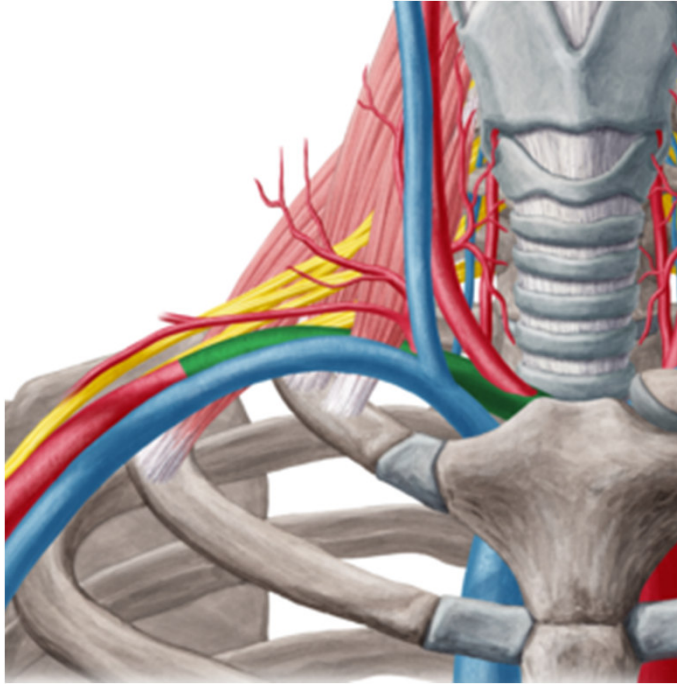
# Aa. membri superioris



## A. subclavia

- prochází přes cupula pleurae, fissura scalenorum, vytváří sulcus a. subclaviae na 1. žebře – od zevního okraje 1. žebra mění jméno na a. axillaris

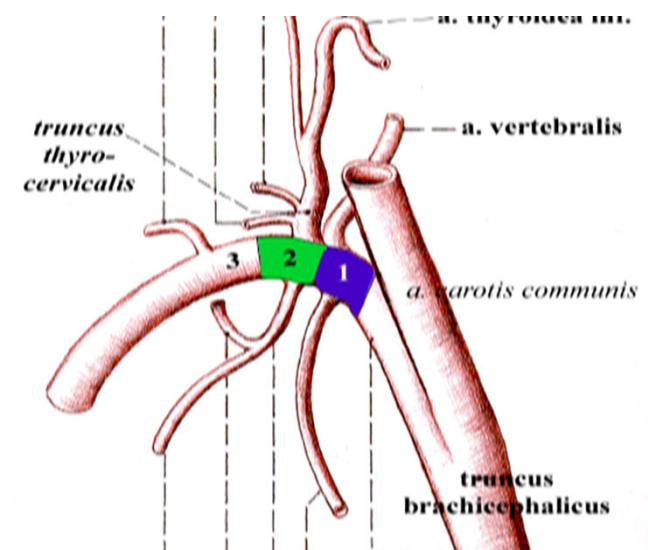
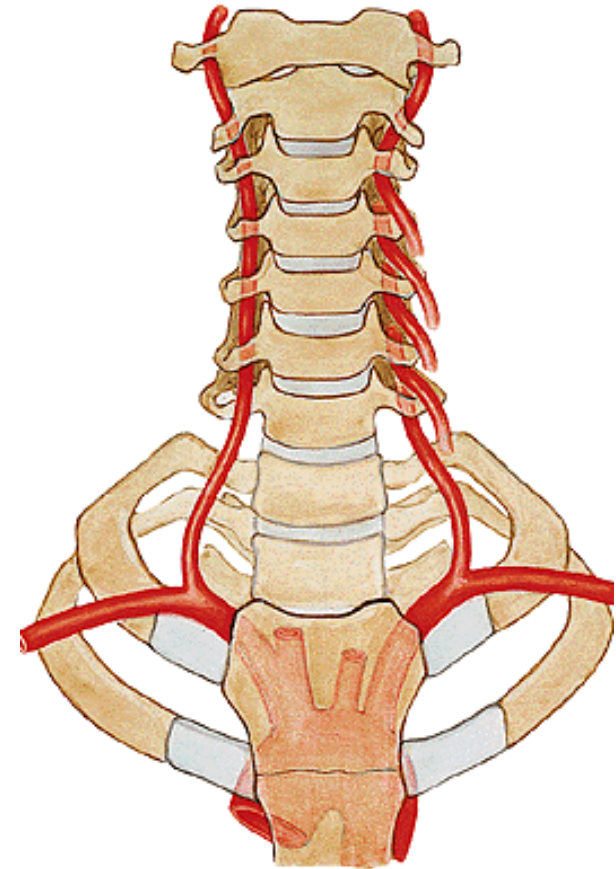


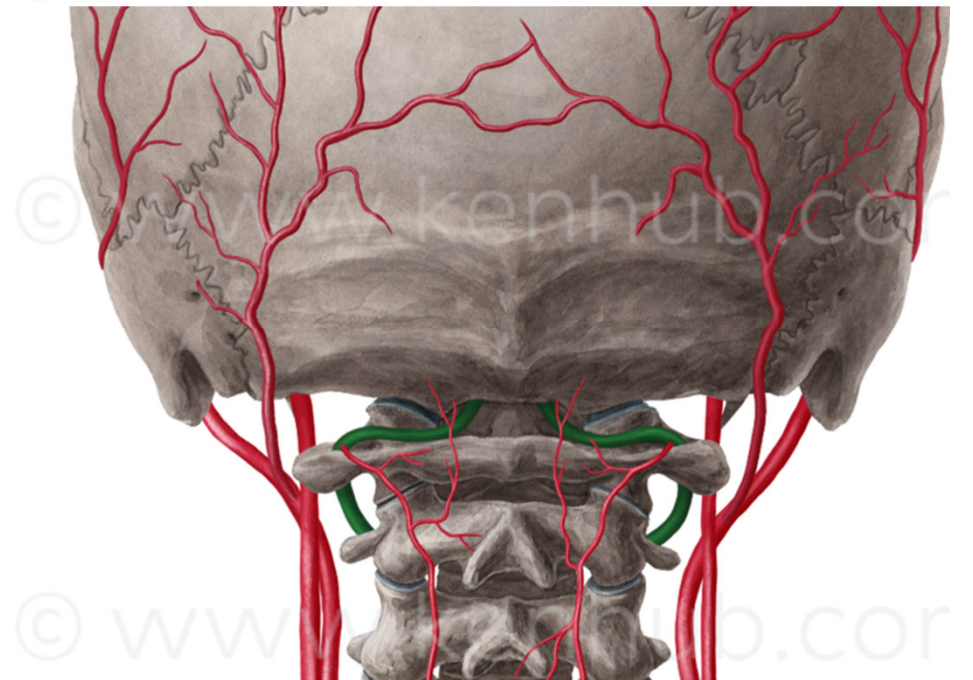
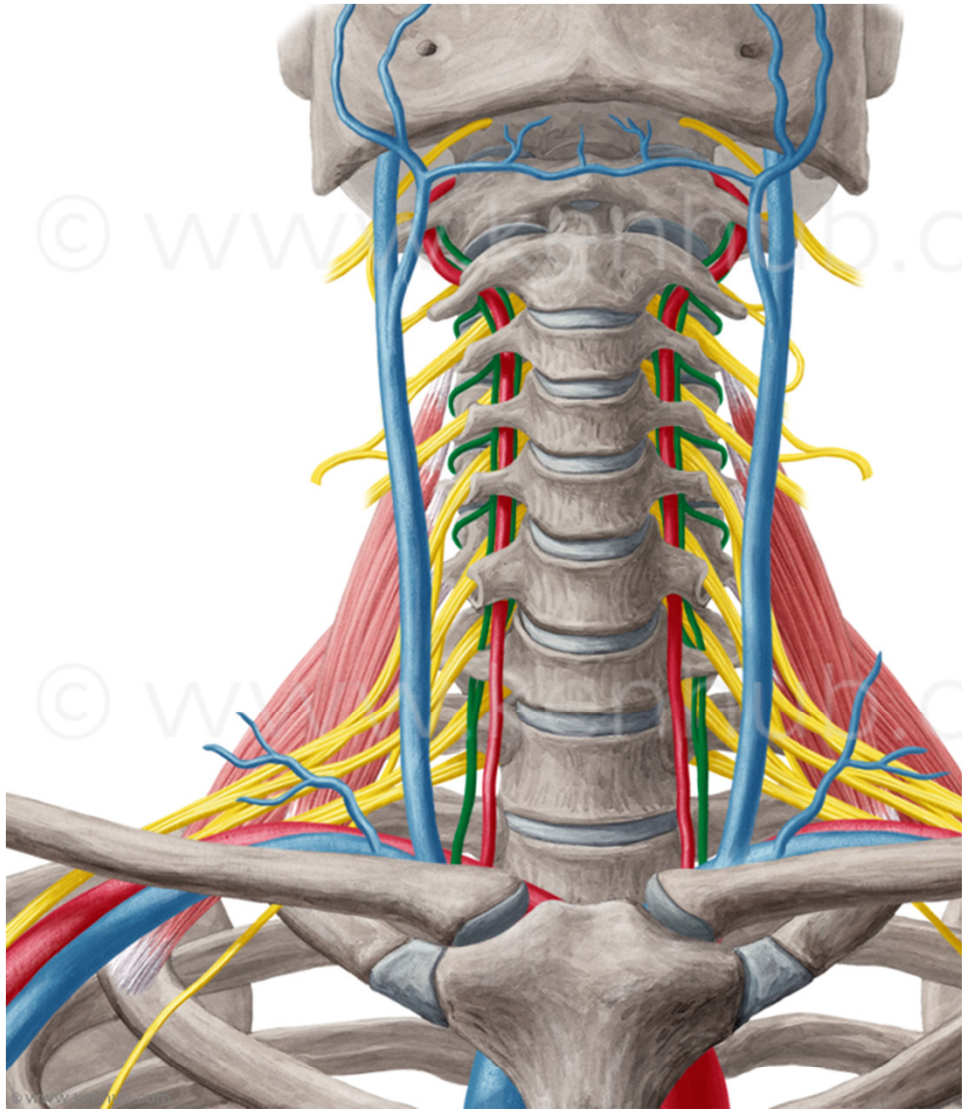




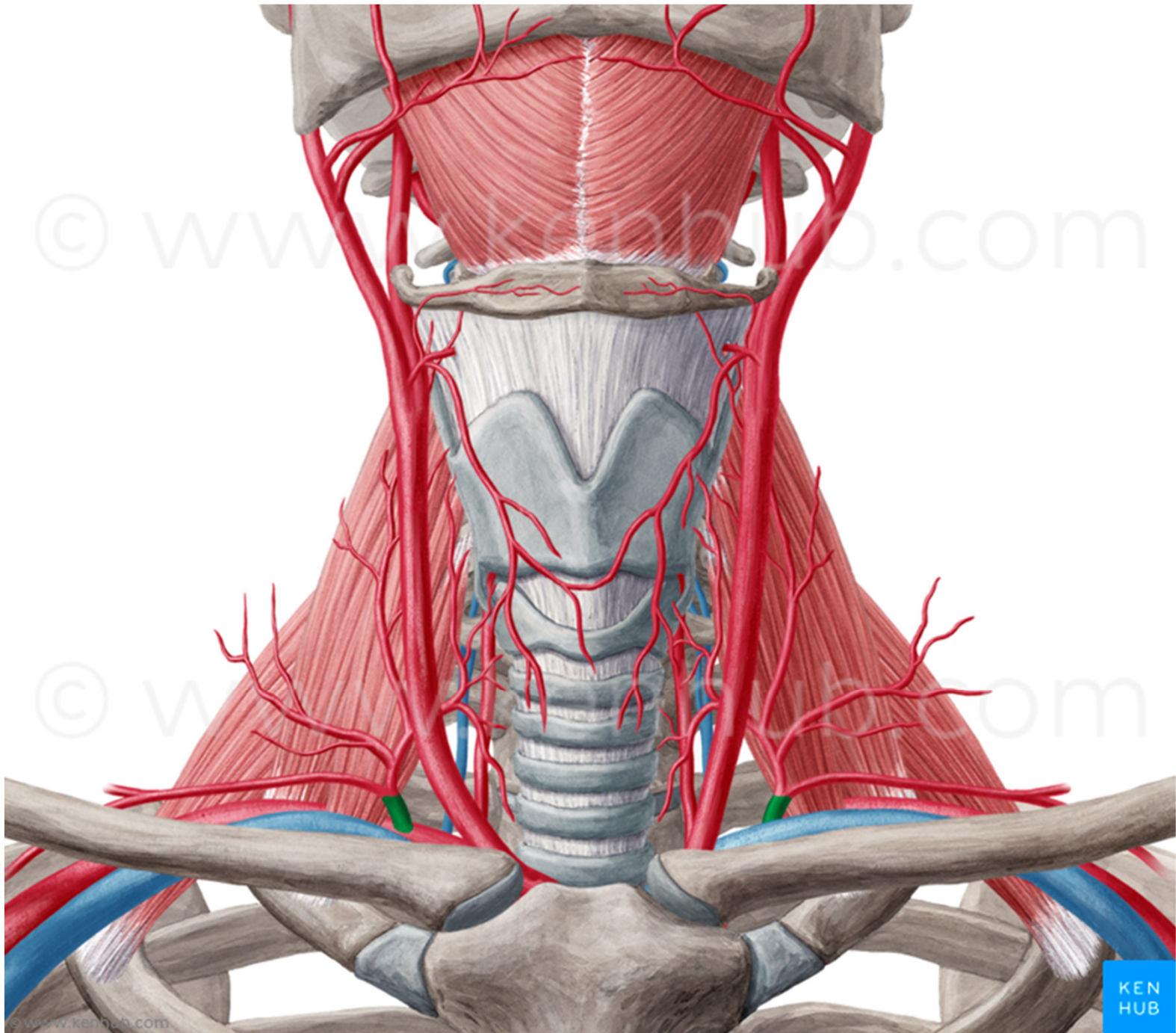
## Větve:

- 1) **a. vertebralis** (mozek)
- 2) **truncus thyreocervicalis** (ke štítné žláze (a. thyroidea inferior), pro svaly lopatky (a. suprascapularis) a krku (a. cervicalis ascendens, a. cervicalis superficialis))
- 3) **truncus costocervicalis** pro hluboké šíjové svaly (a. cervicalis profunda) a první dvě mezižebří (a. intercostalis suprema)
- 4) **a. thoracica interna** pro m. rectus abdominis (a. epigastrica superior) a pro bránici (a. musculophrenica)
- 5) **a. transversa colli** (šíjové svaly, svaly pletence HK, m. trapezius)





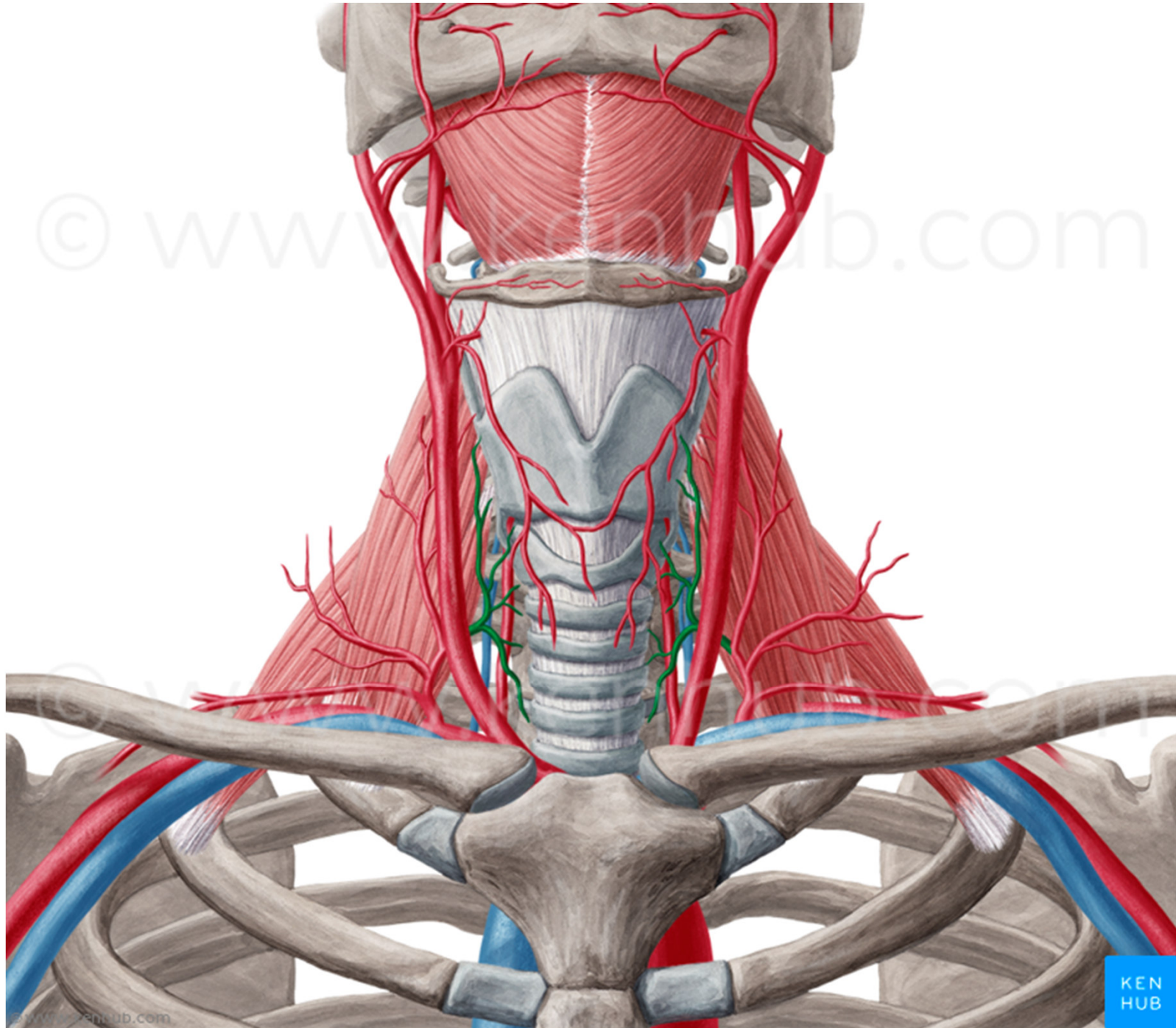


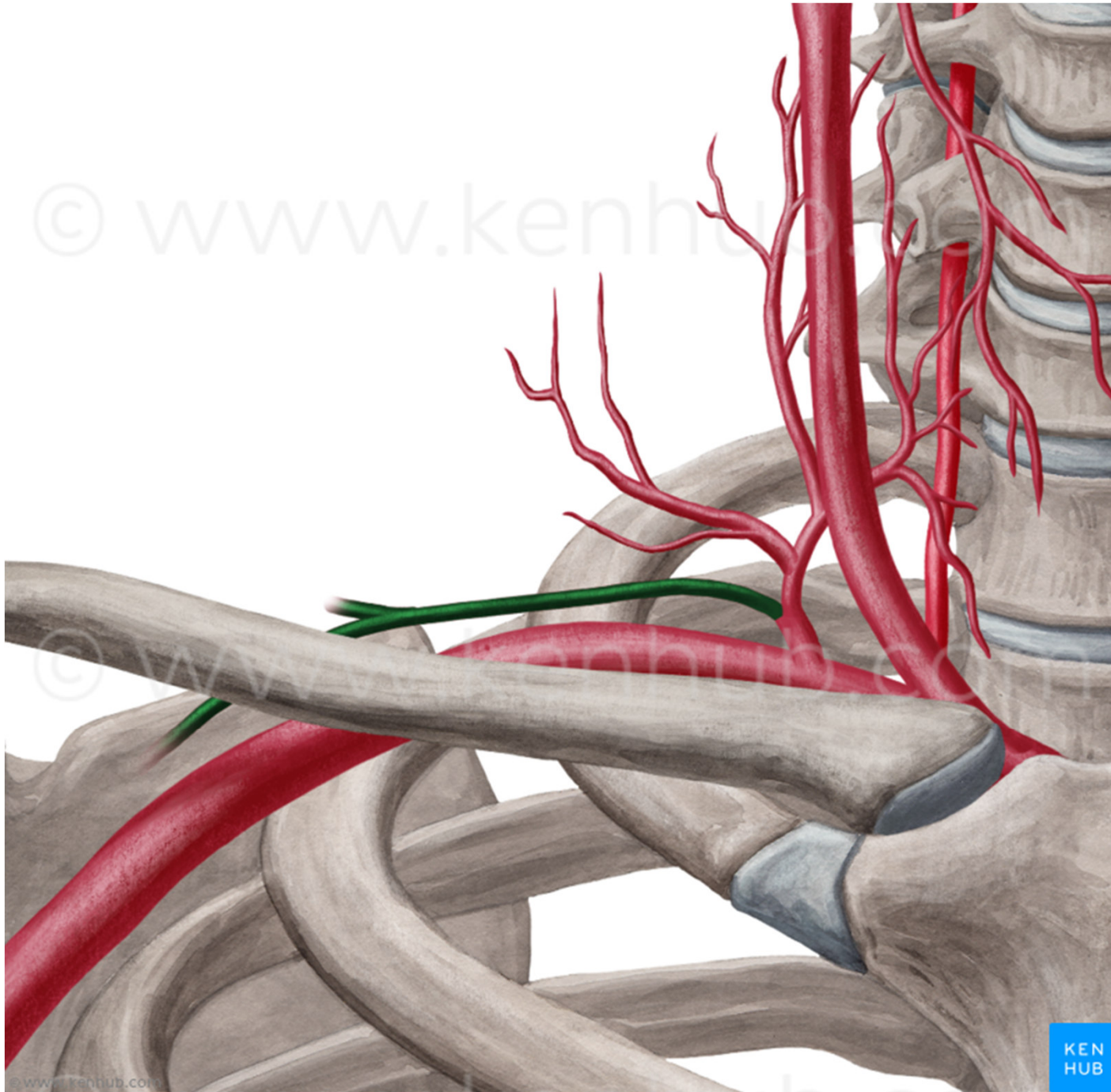


© www.kenhub.com

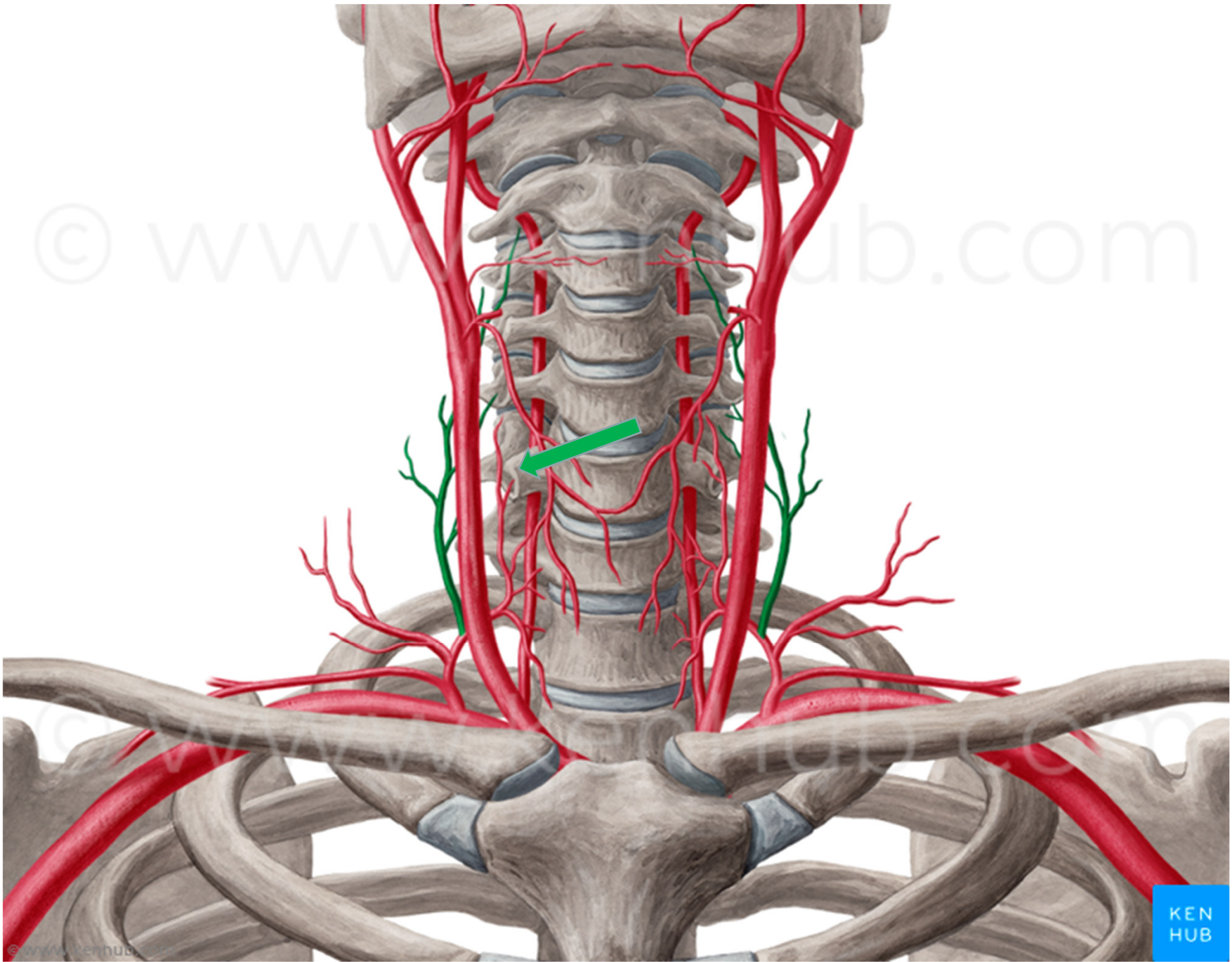
© www.kenhub.com

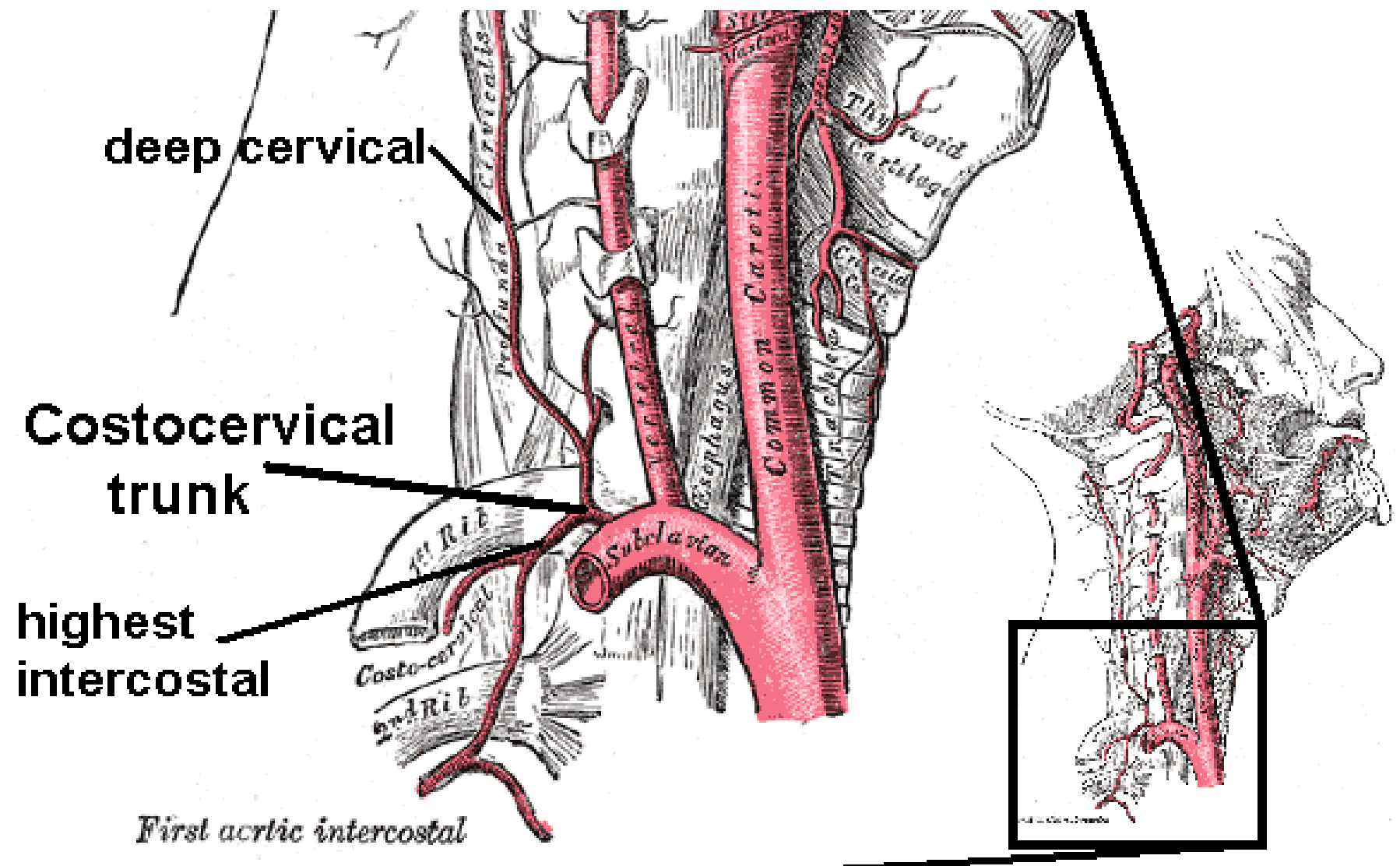






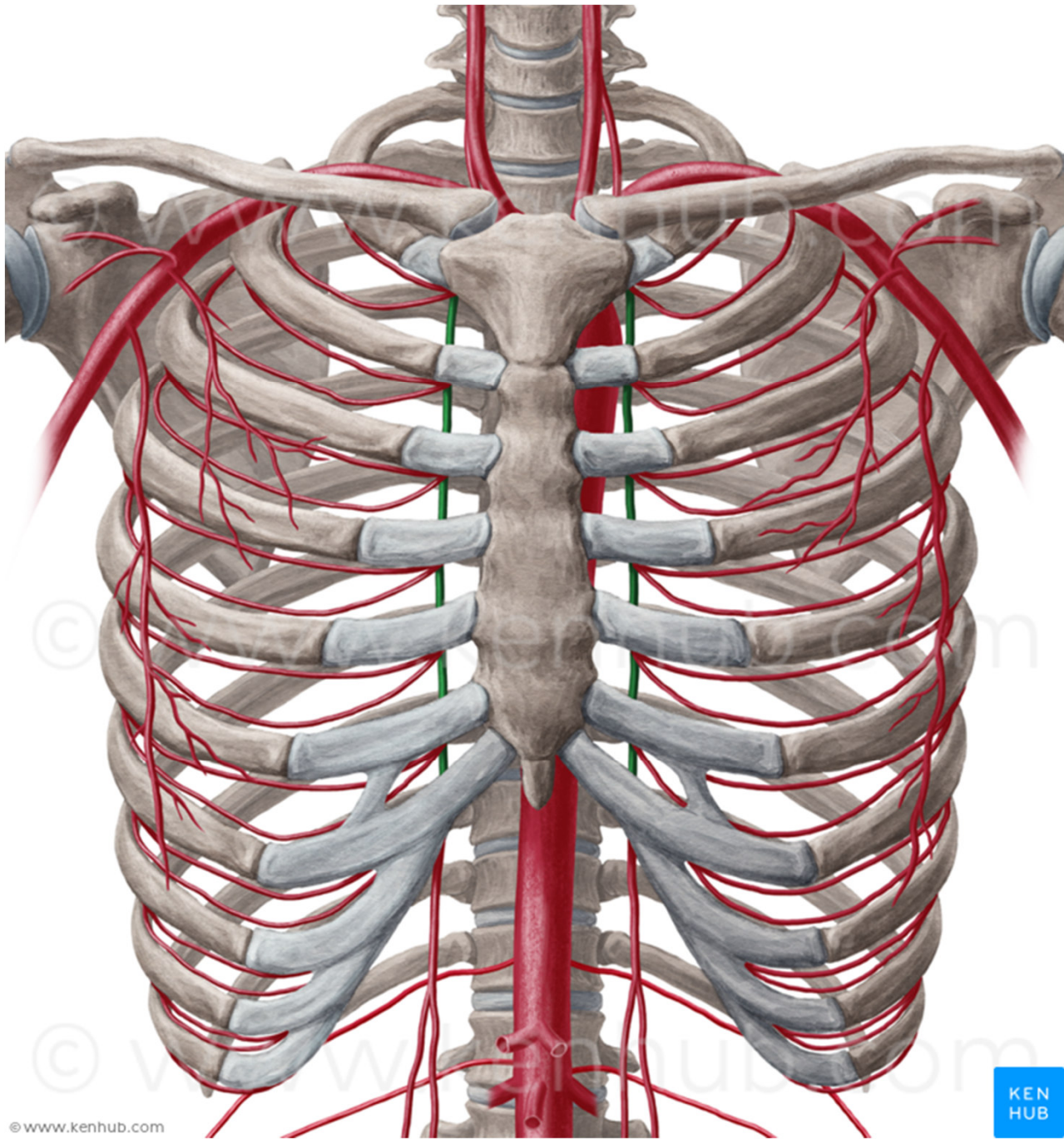


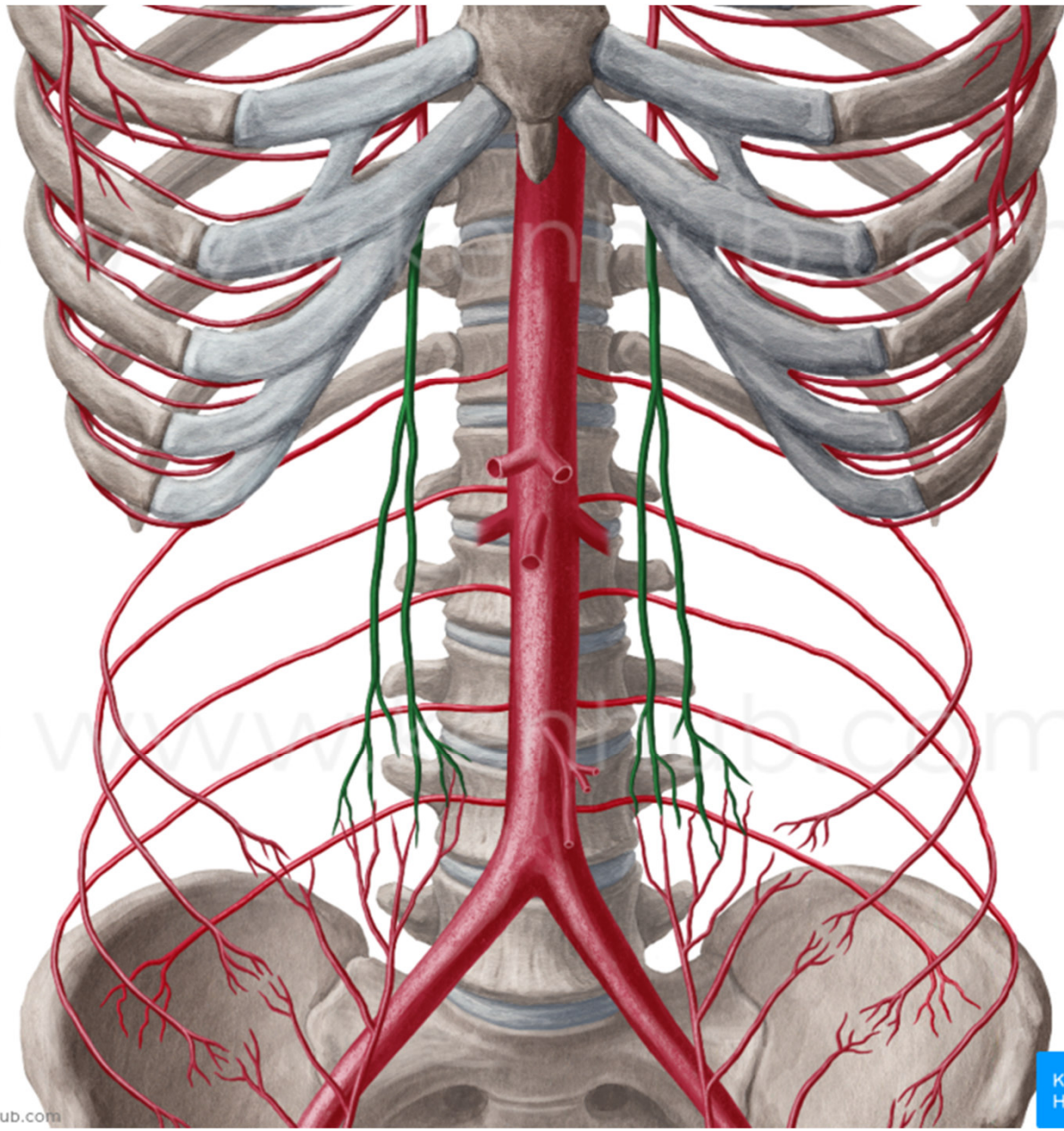




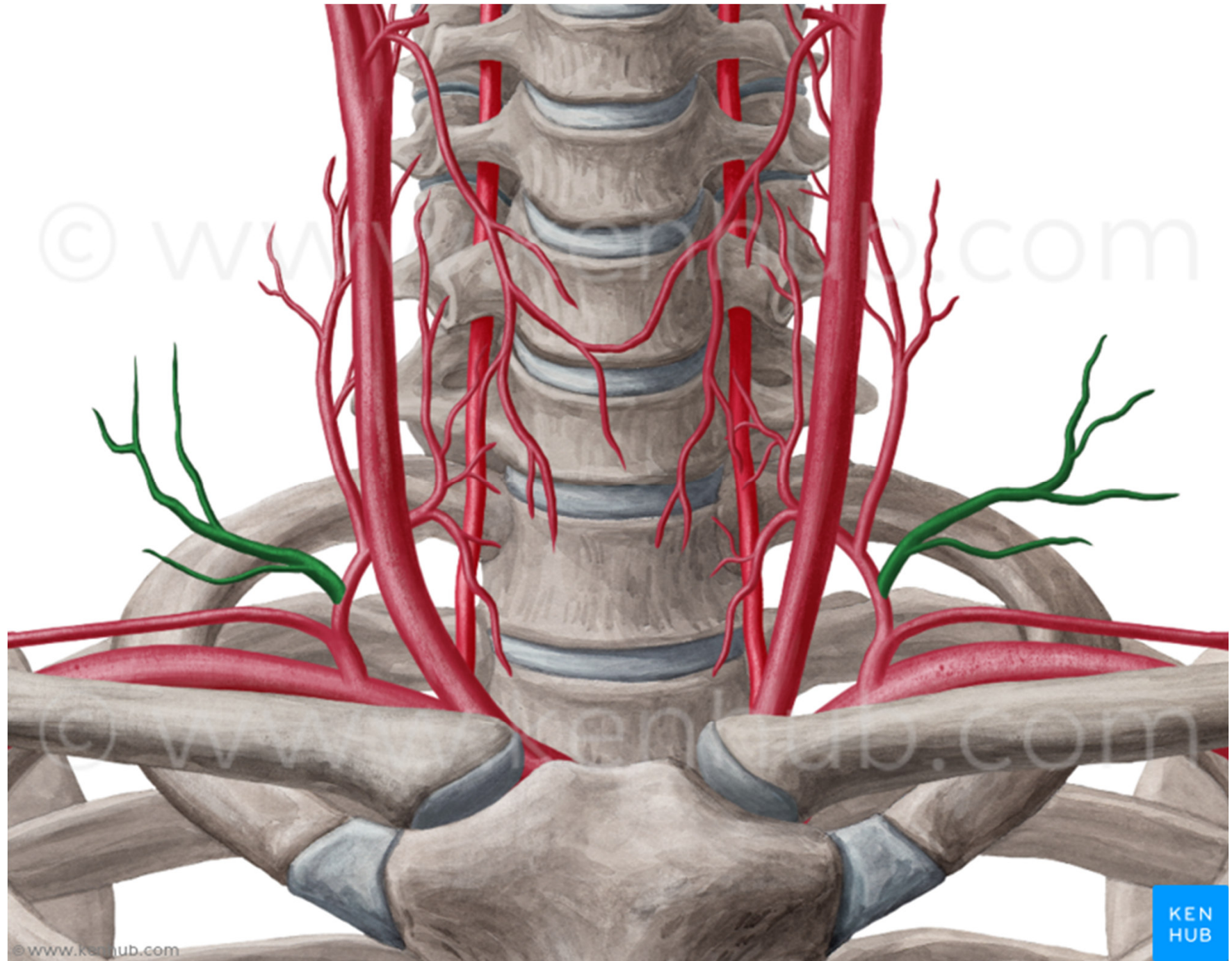
*First aortic intercostal*

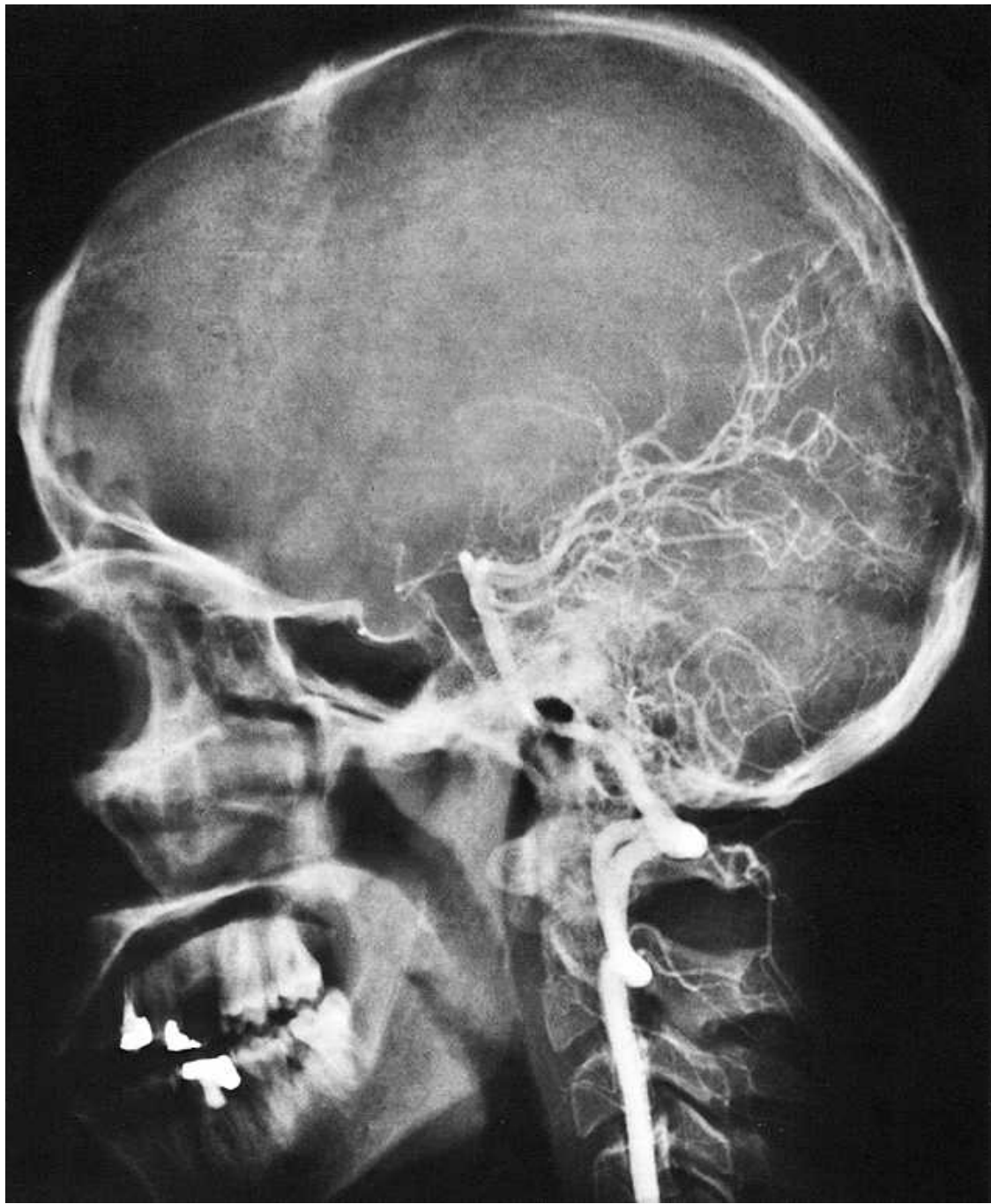








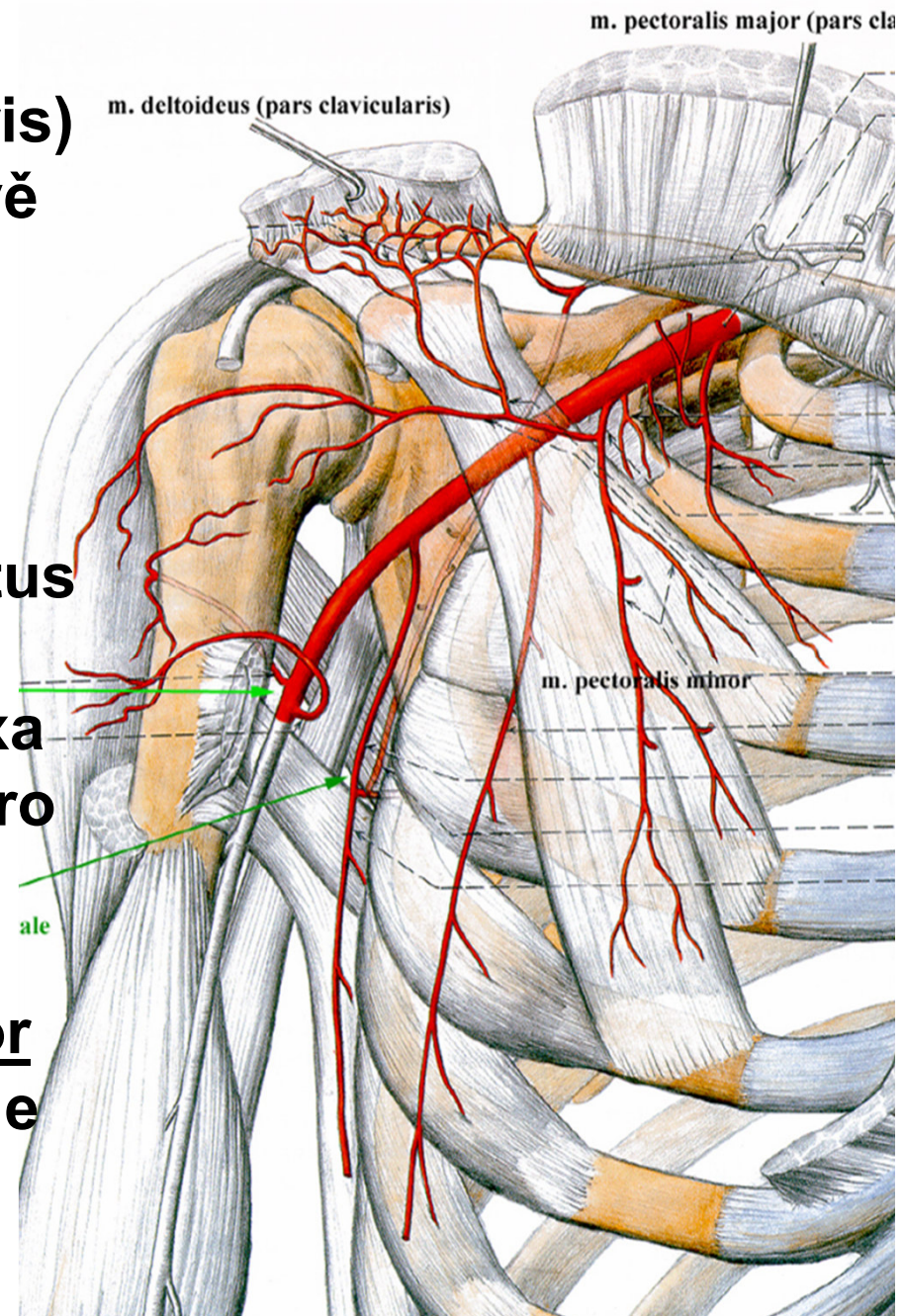


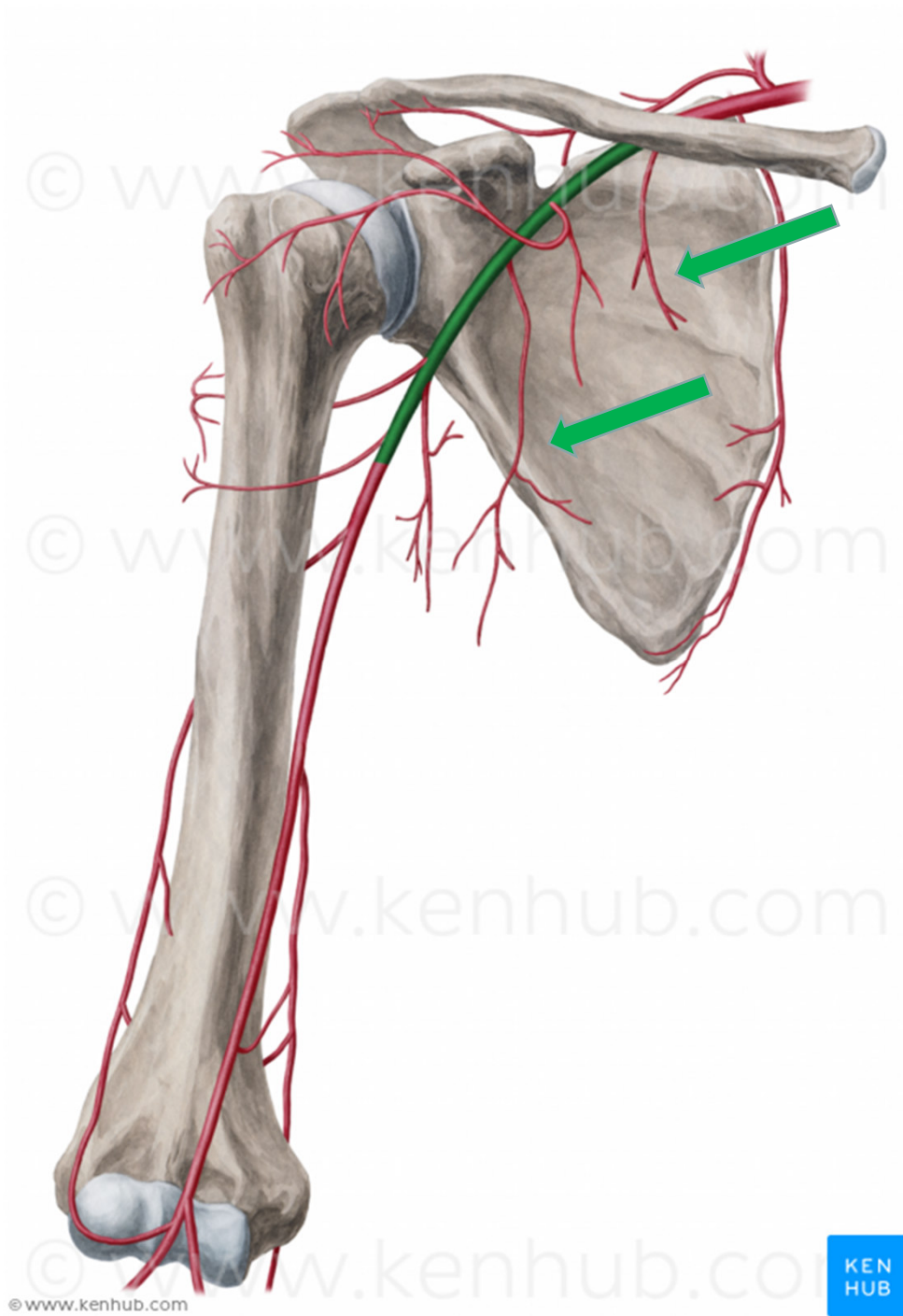




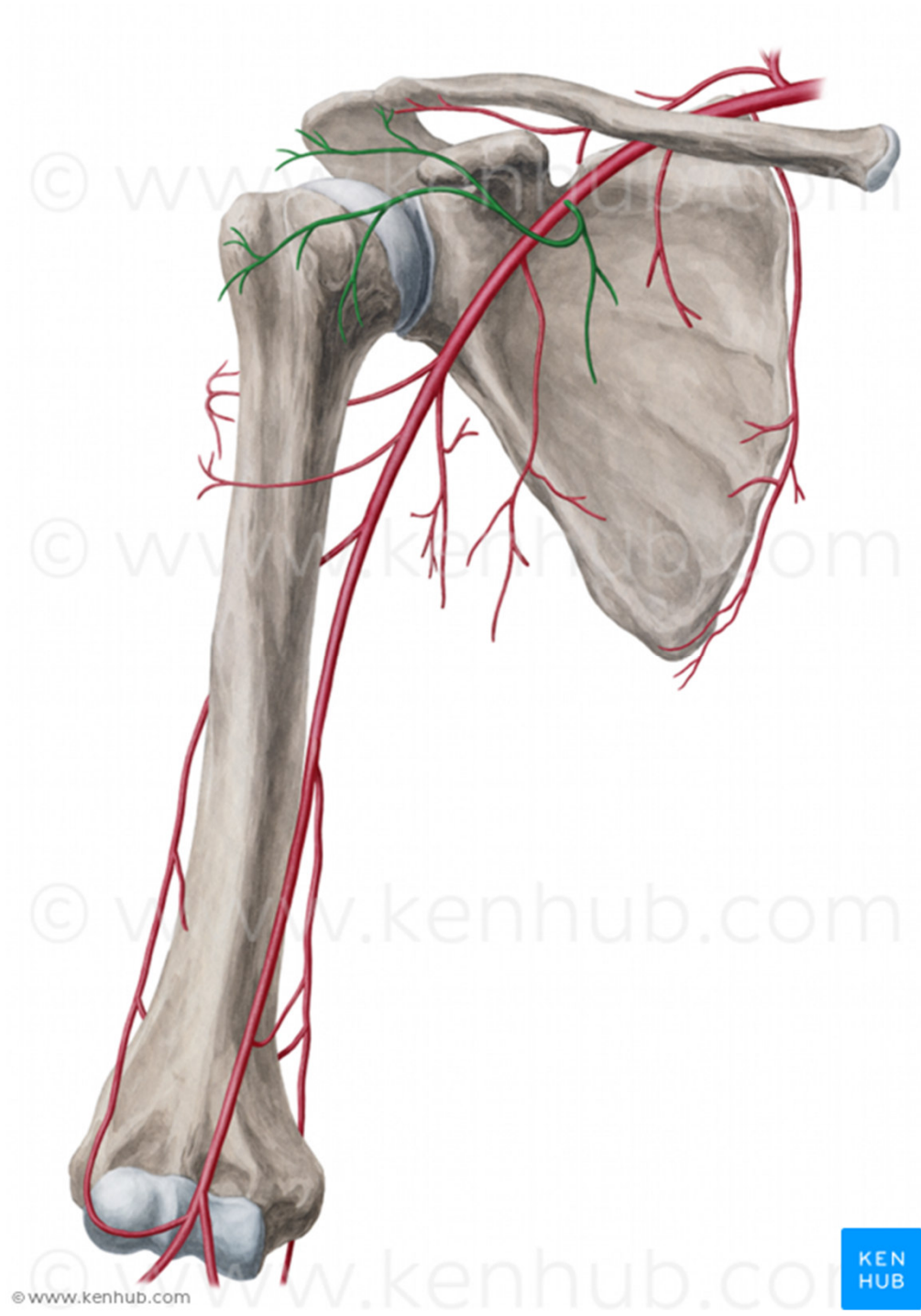
**A. axillaris – od 1. žebra po distální okraj šlachy  
m. pectoralis major**

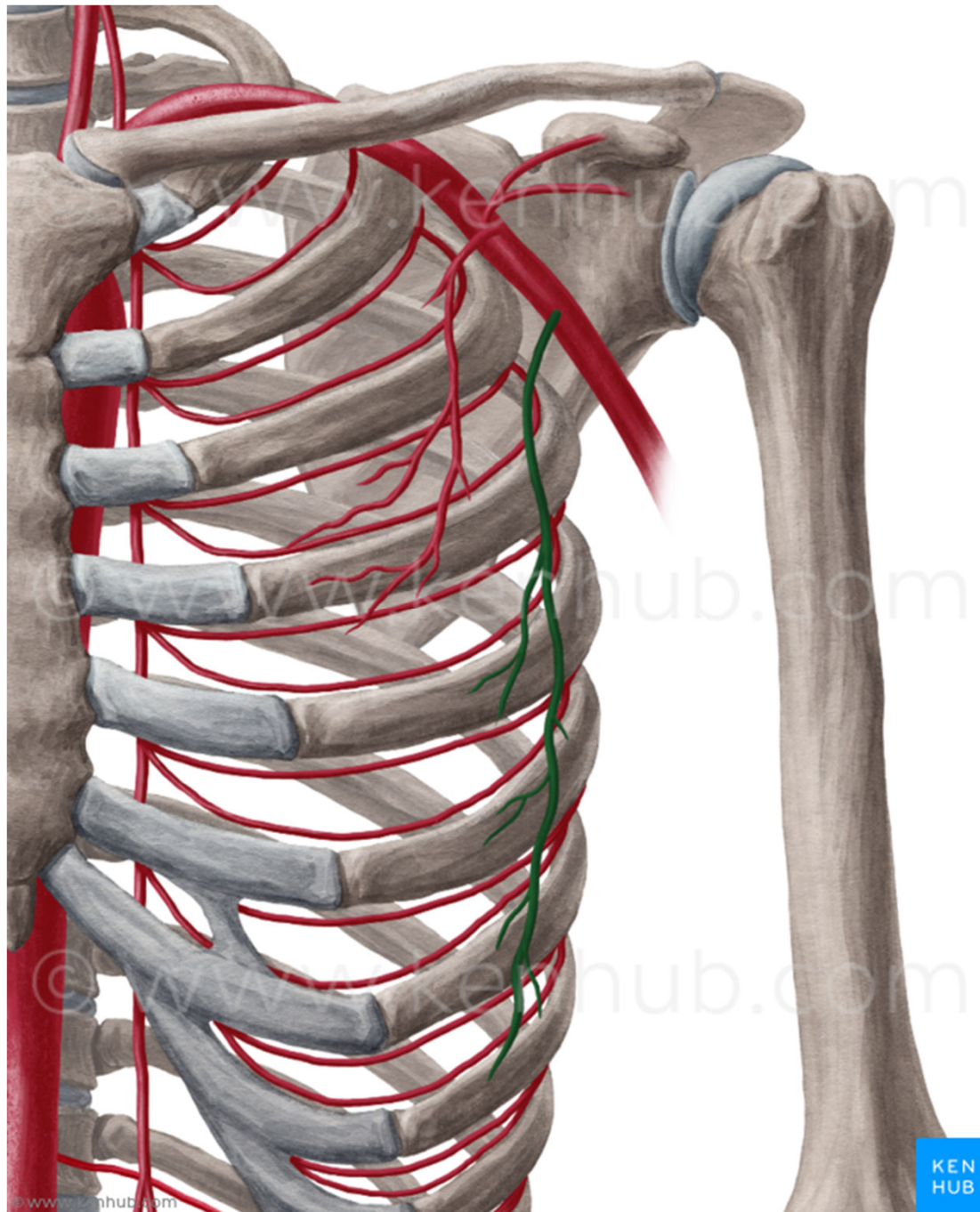
- 1) **svalové větve** (m. subscapularis)
- 2) **a. thoracica suprema** (první dvě mezižebří)
- 3) **a. thoracoacromialis** (ramenní kloub, m. deltoideus, mm. pectorales)
- 4) **a. thoracica lateralis** (m. serratus anterior)
- 5) **a. subscapularis** (a. circumflexa scapulae, a. thoracodorsalis pro m. latissimus dorsi)
- 6) **a. circumflexa humeri anterior**
- 7) **a. circumflexa humeri posterior** (přes foramen humerotricipitale do m. deltoideus)



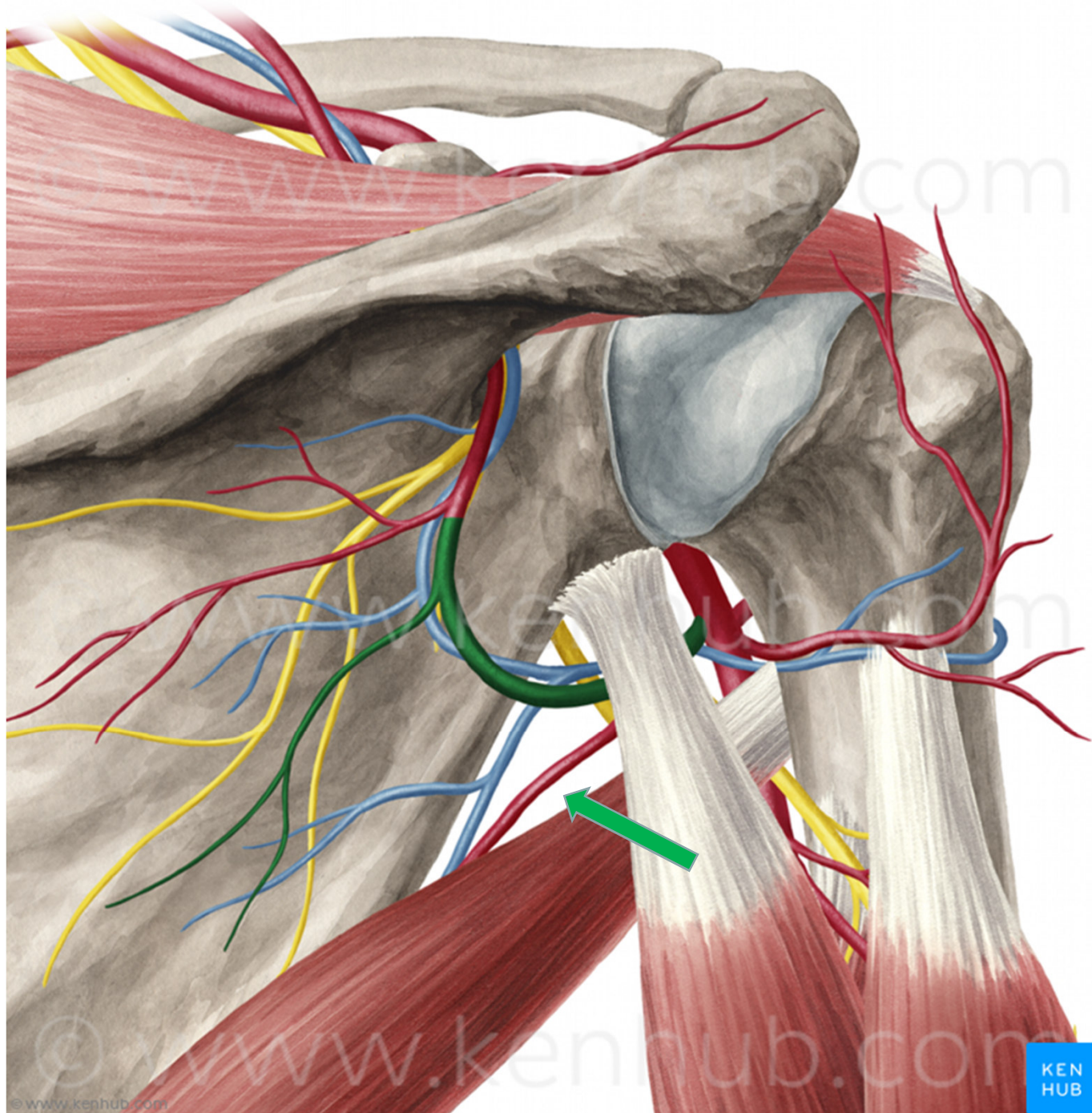






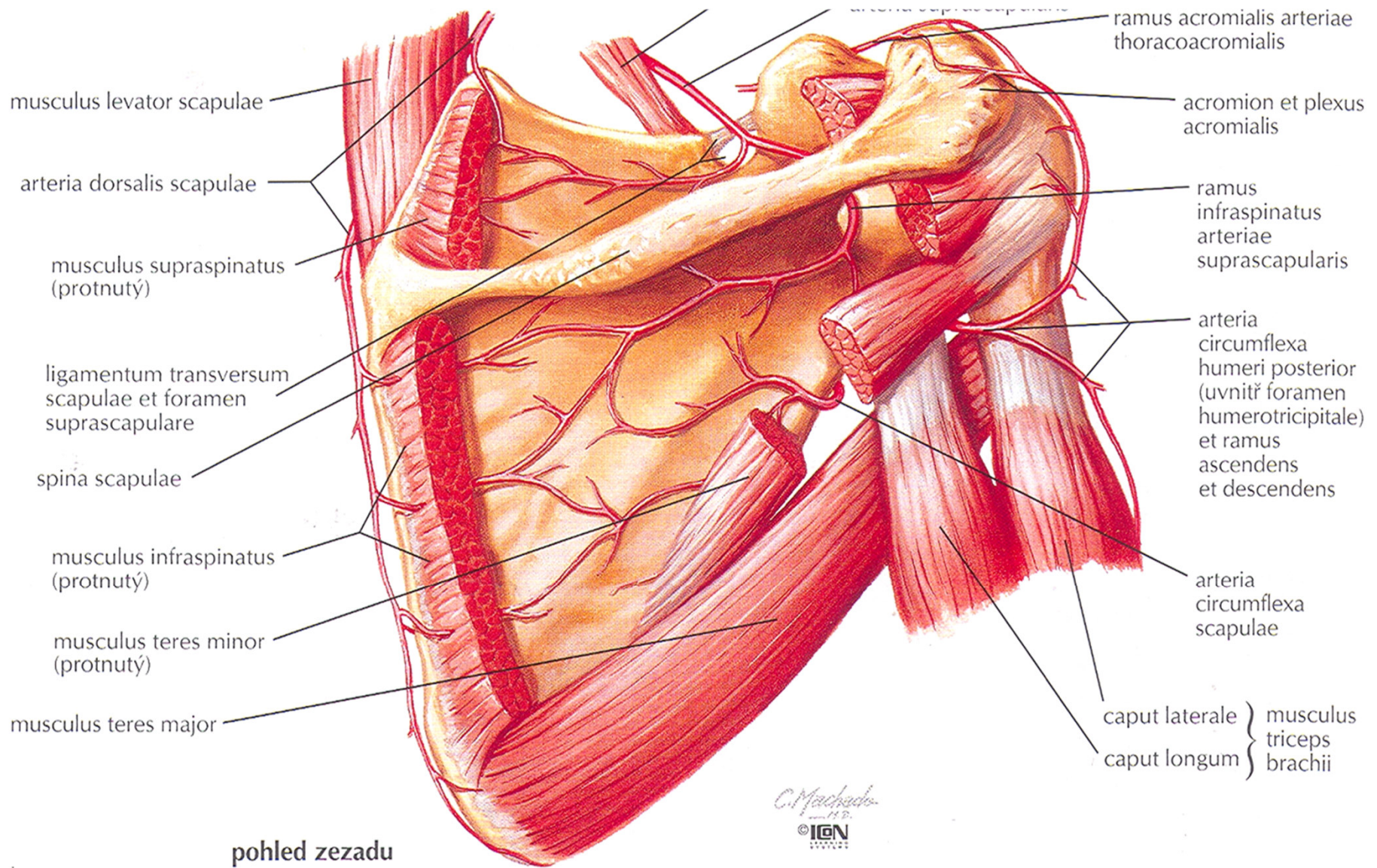




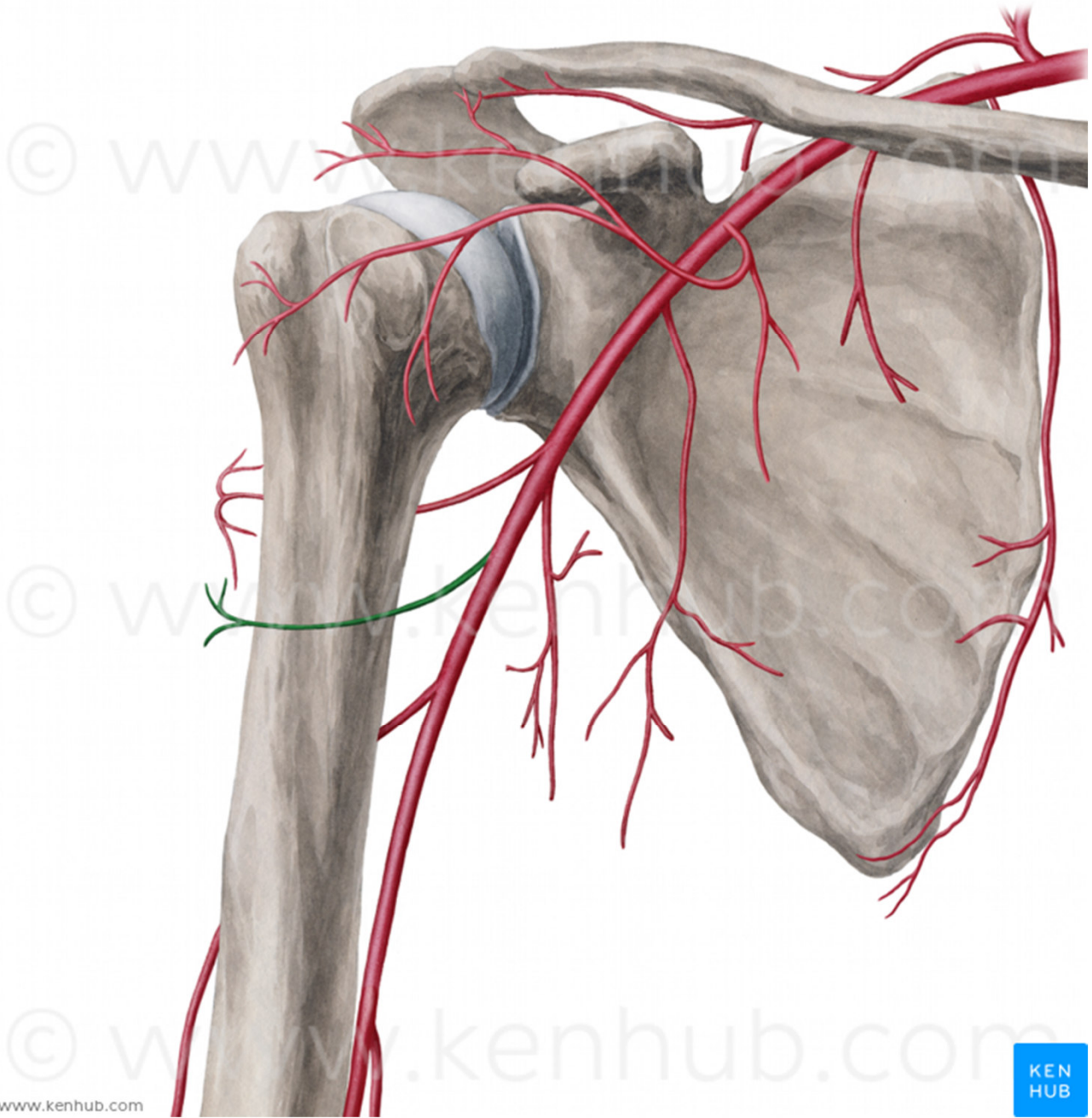


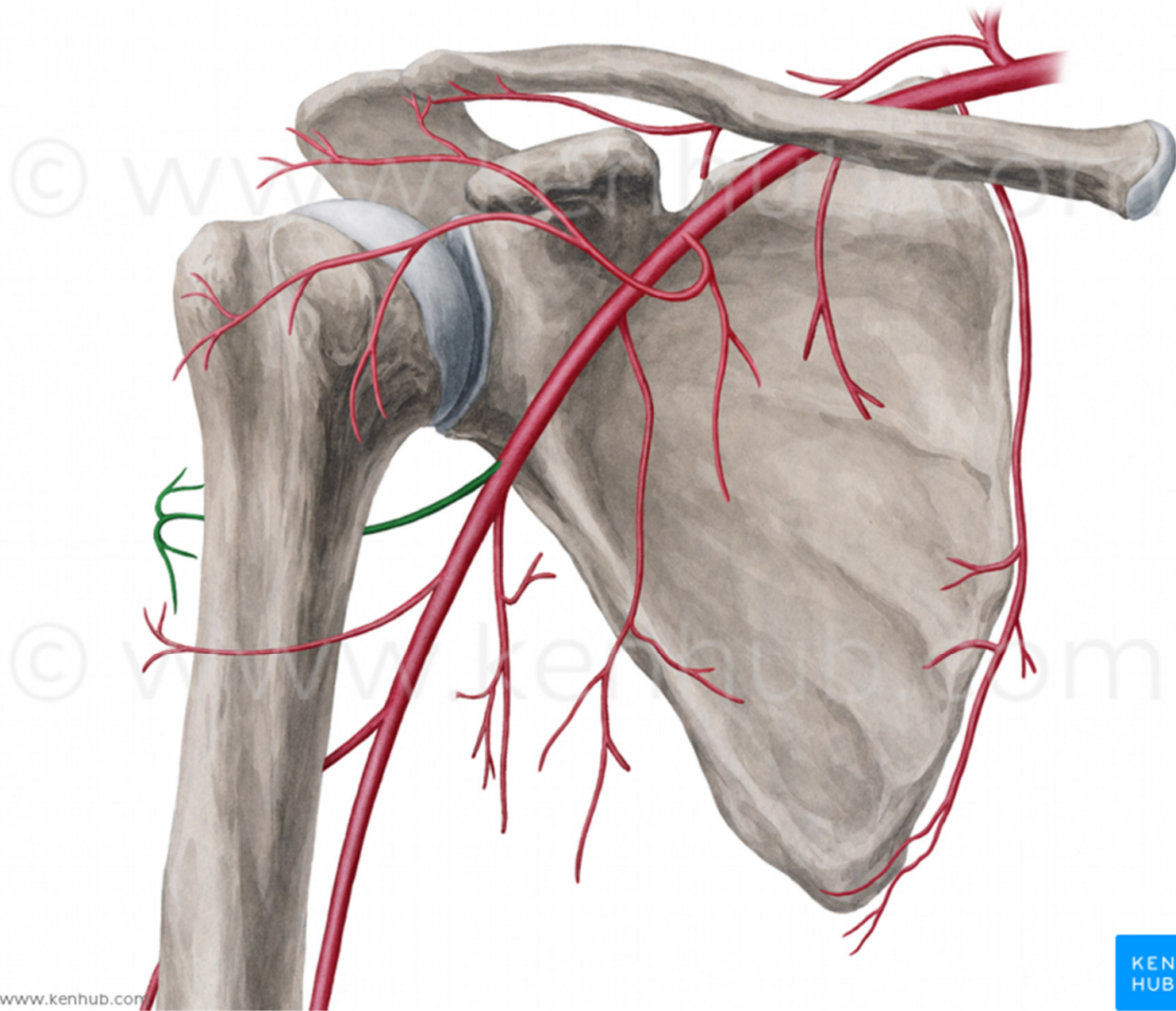


# Anastomóza a. suprascapularis a a. circumflexa scapulae





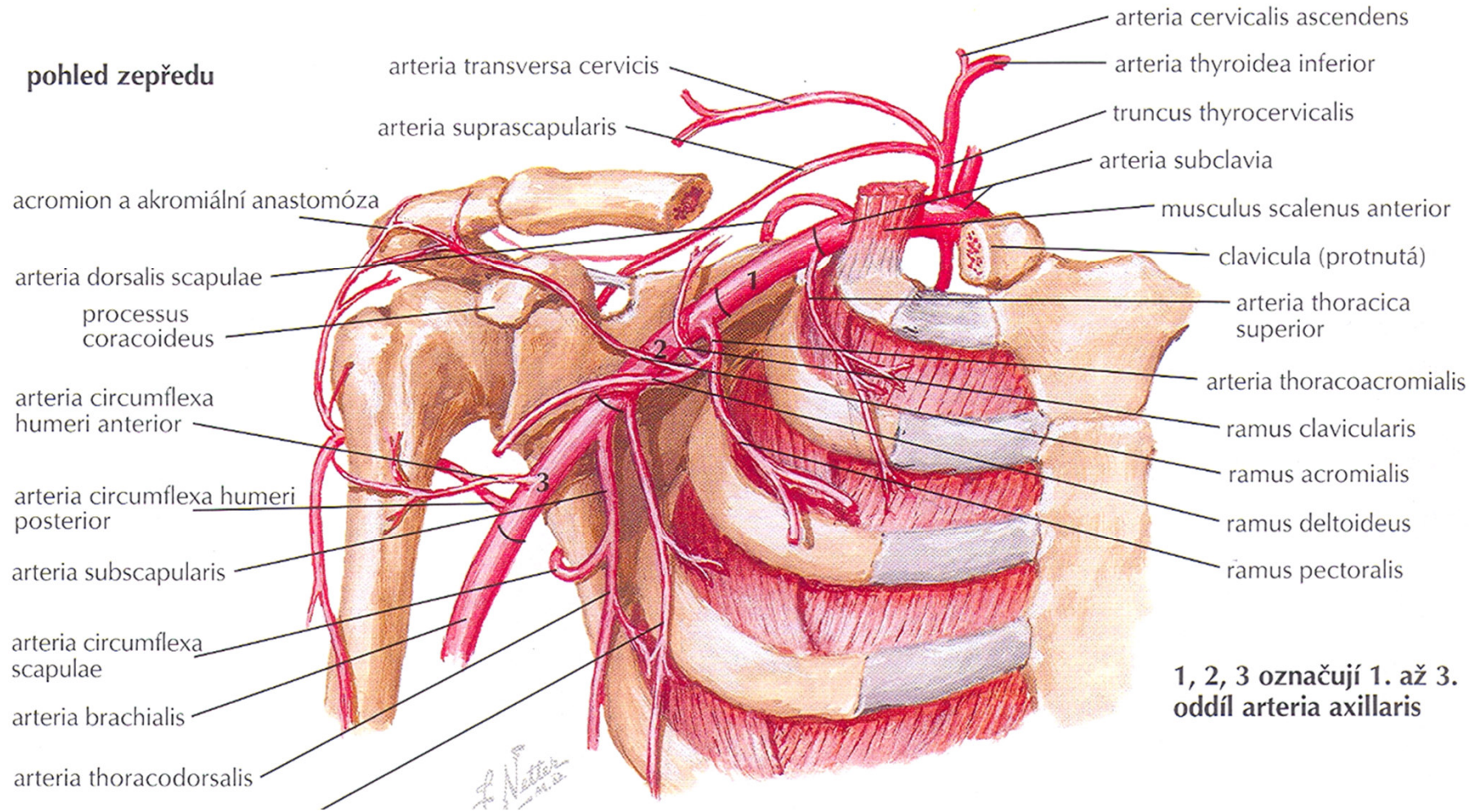






# Anastomóza a. circumflexa humeri anterior et posterior

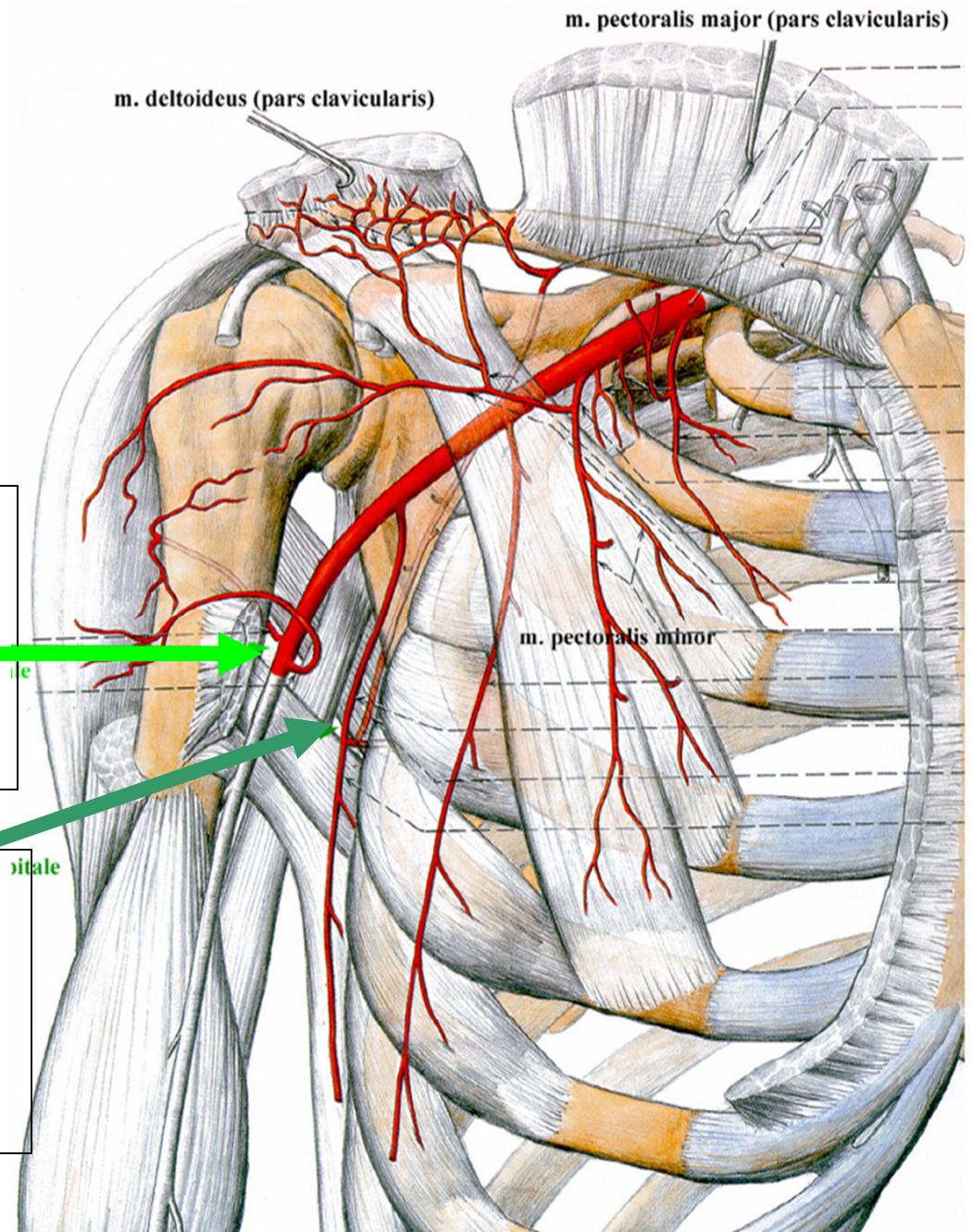
**pohled zepředu**





**Foramen humerotricipitale:**  
**n. axillaris,**  
**a. circumflexa**  
**humeri posterior**

**Foramen omotricipitale:**  
**a. circumflexa scapulae -**  
**anastomosa s a.**  
**suprascapularis**





## A. brachialis

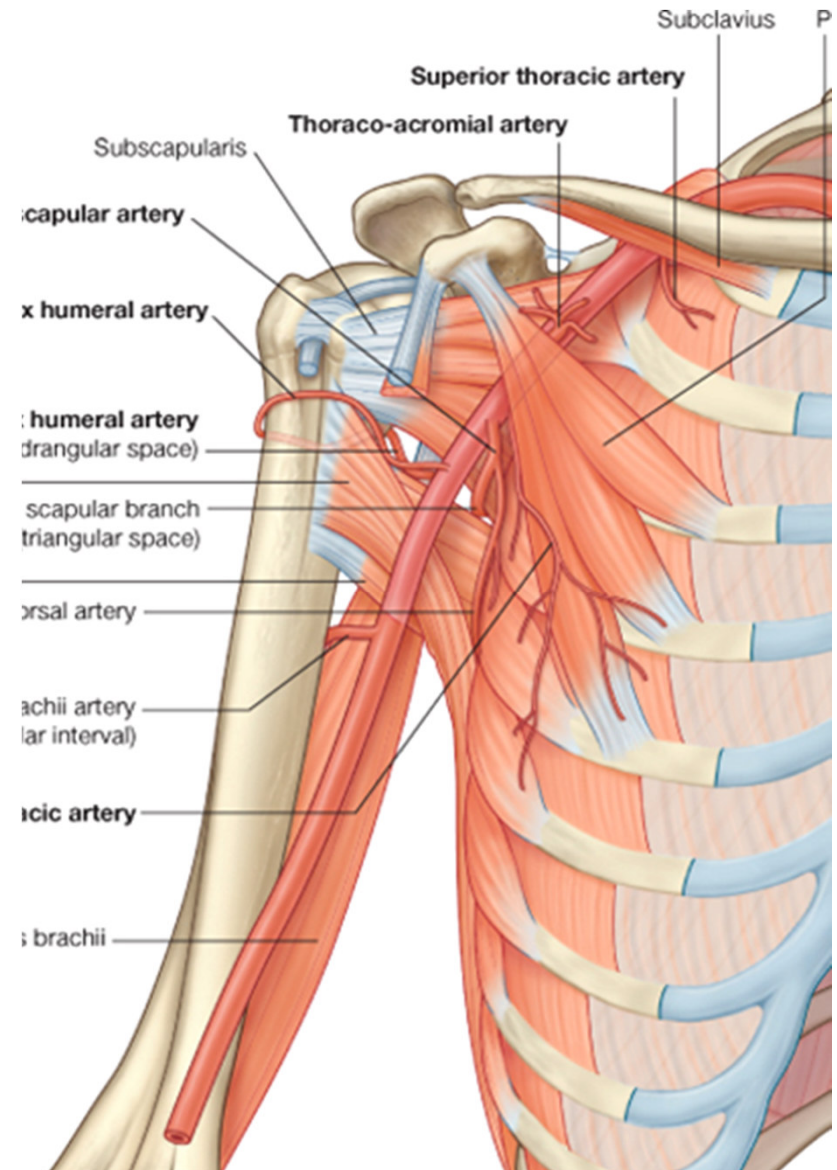
- od okraje m. pectoralis major, v sulcus bicipitalis medialis, ve fossa cubiti se štěpí na: a. radialis a a. ulnaris

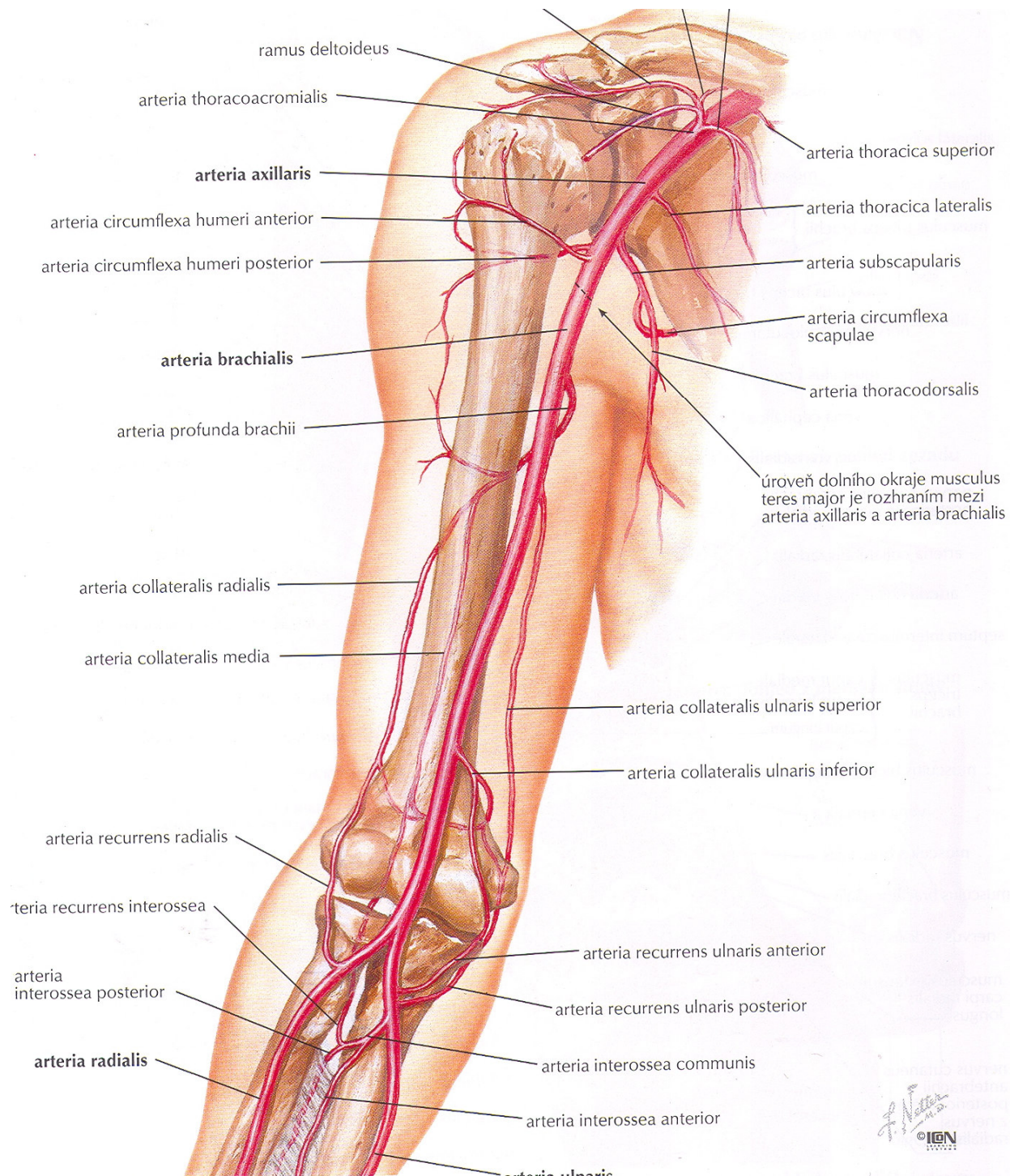
větve:

- 1) a. profunda brachii (v sulcus n. radialis)
- 2) a. collateralis ulnaris superior (za med. epikondylem, do tepenné sítě kolem loketního kloubu)
- 3) a. collateralis ulnaris inferior (do tepenné sítě kolem loketního kloubu)

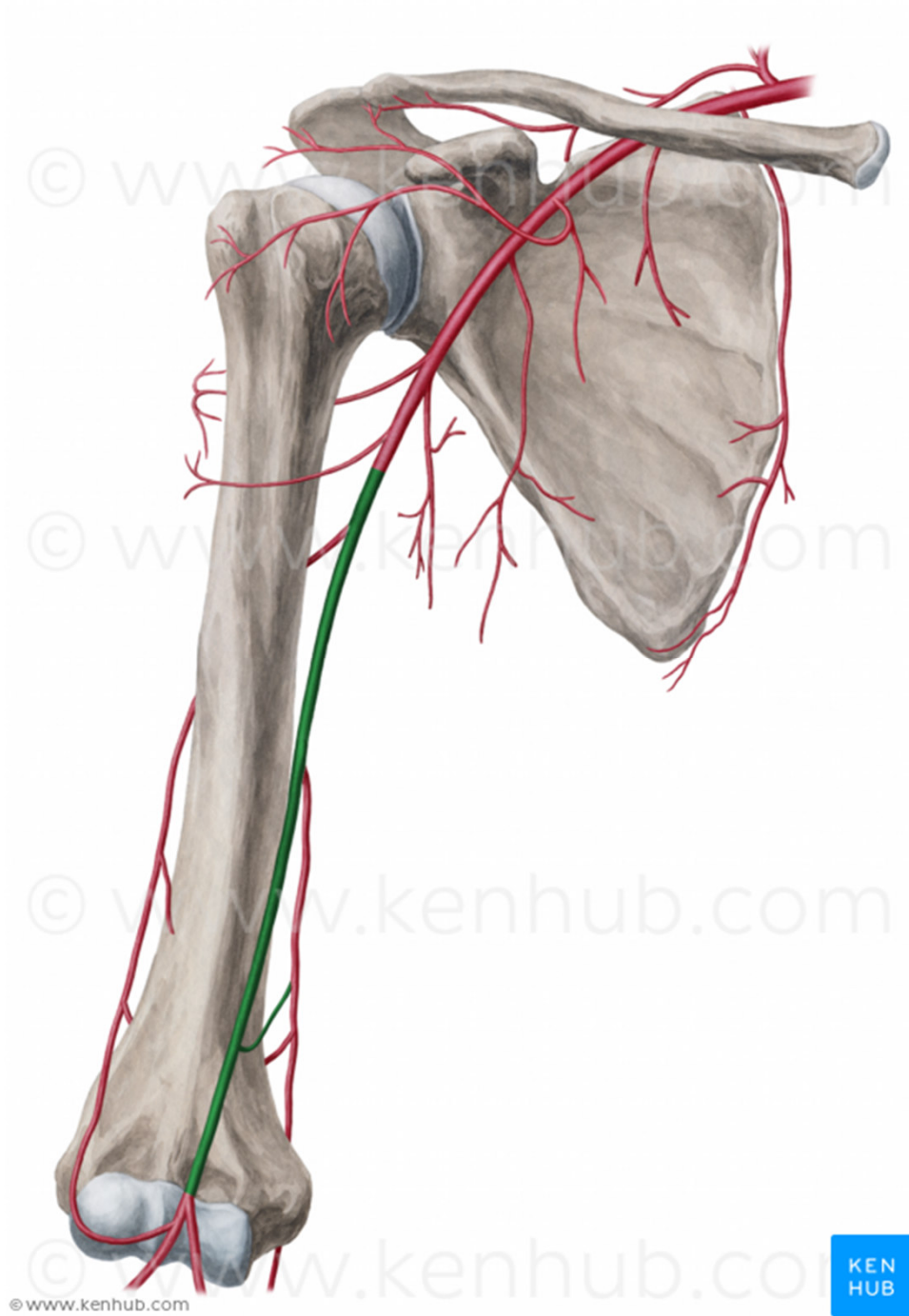
konečné větve:

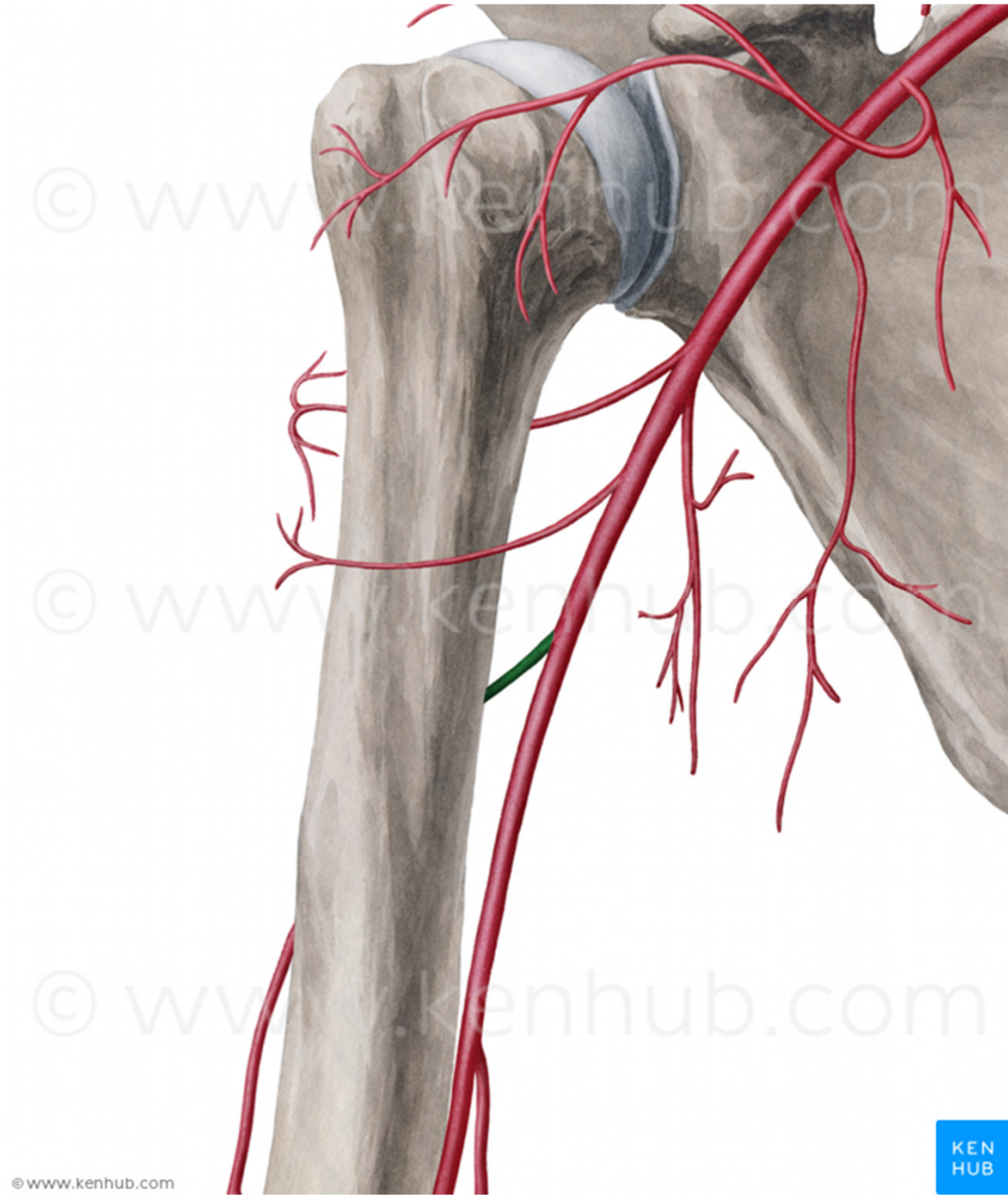
- 4) a. radialis a a. ulnaris



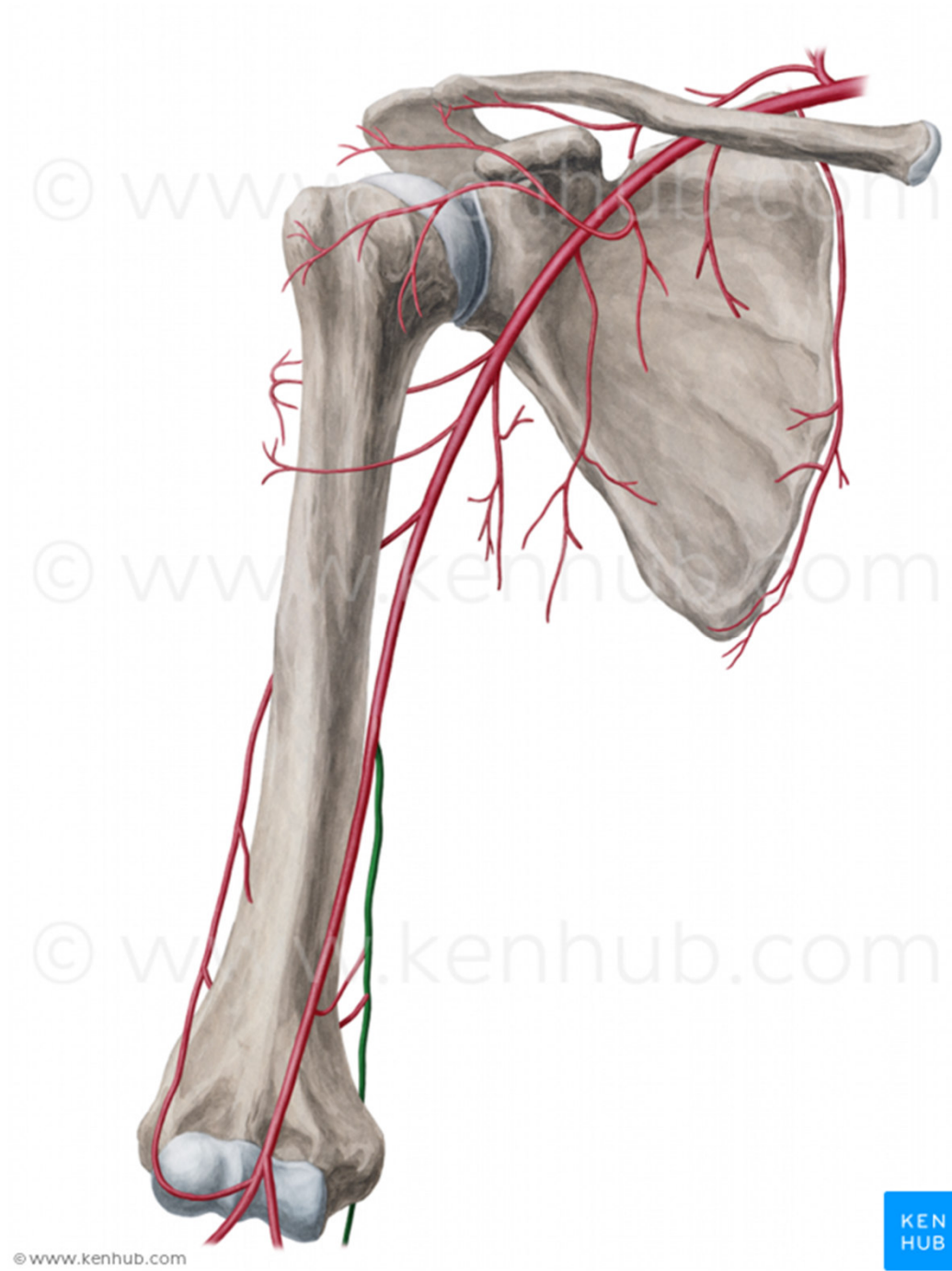






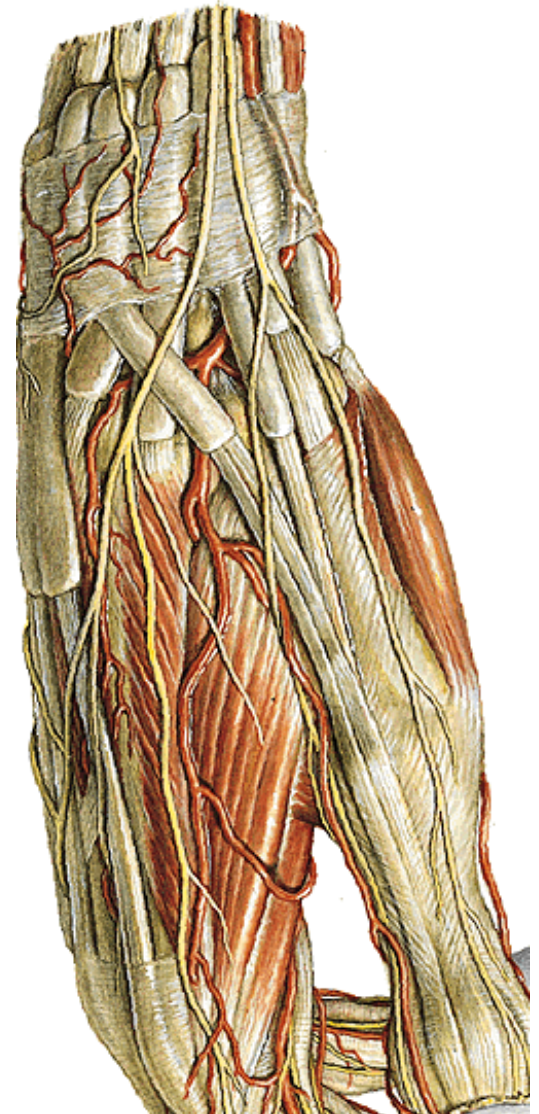
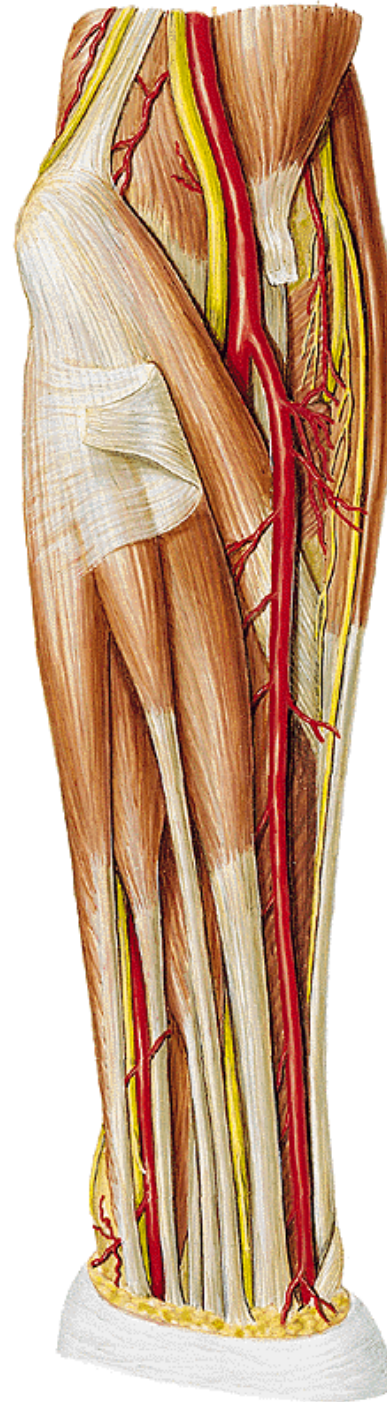
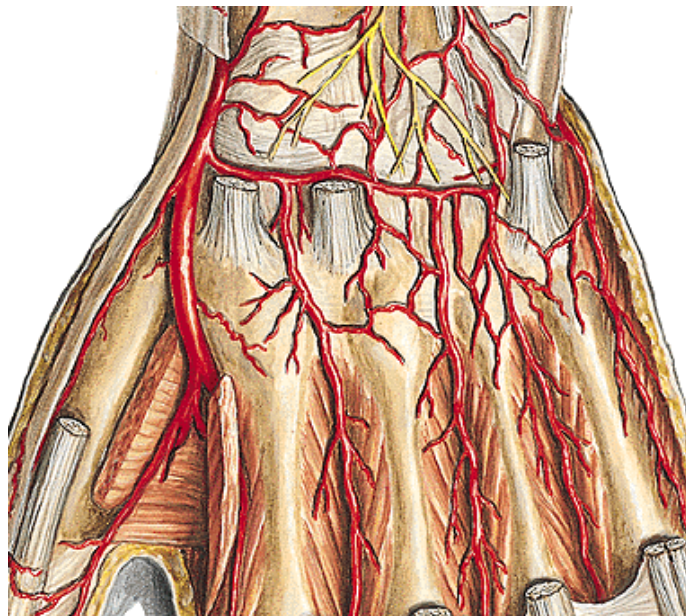






## A. radialis

- pod m. brachioradialis, do foveola radialis, pod šlachou m. extensor pollicis longus (**foveola radialis** mezi dlouhým a krátkým extensorem) jde na hřbet ruky, prostoupí m. interosseus dorsalis I. a na dlani vydá konečné větve: **arcus palmaris profundus** a. **princeps pollicis**





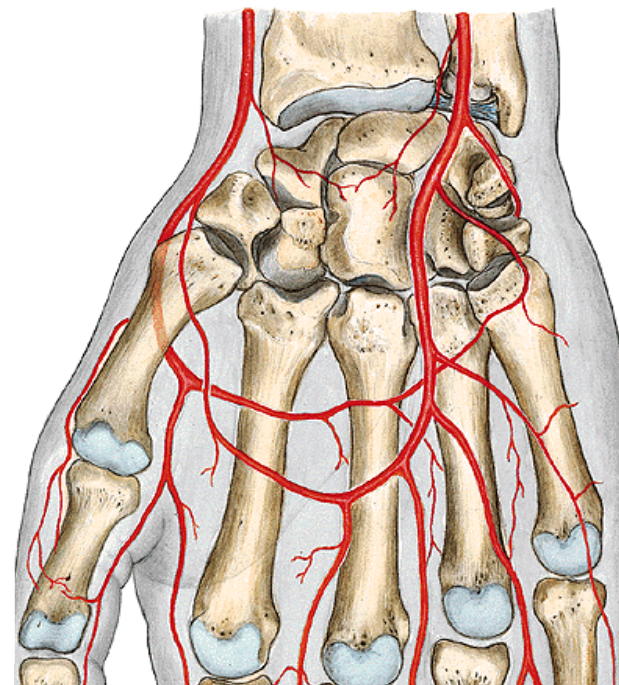
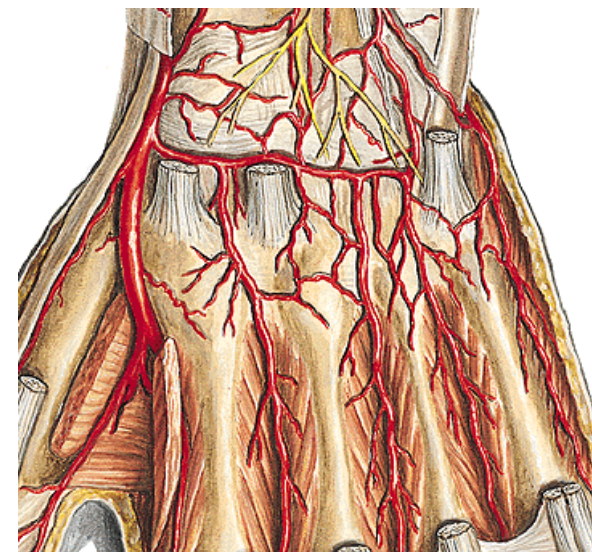
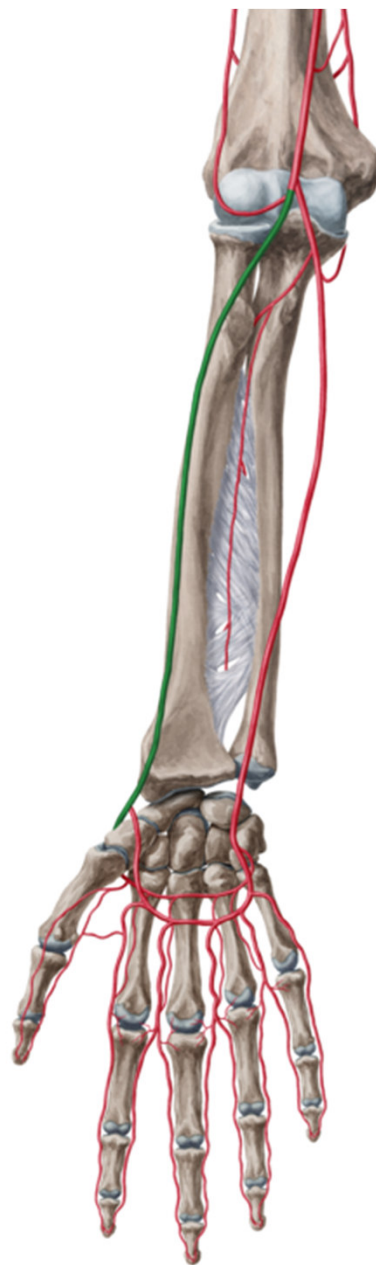
**Větve :**

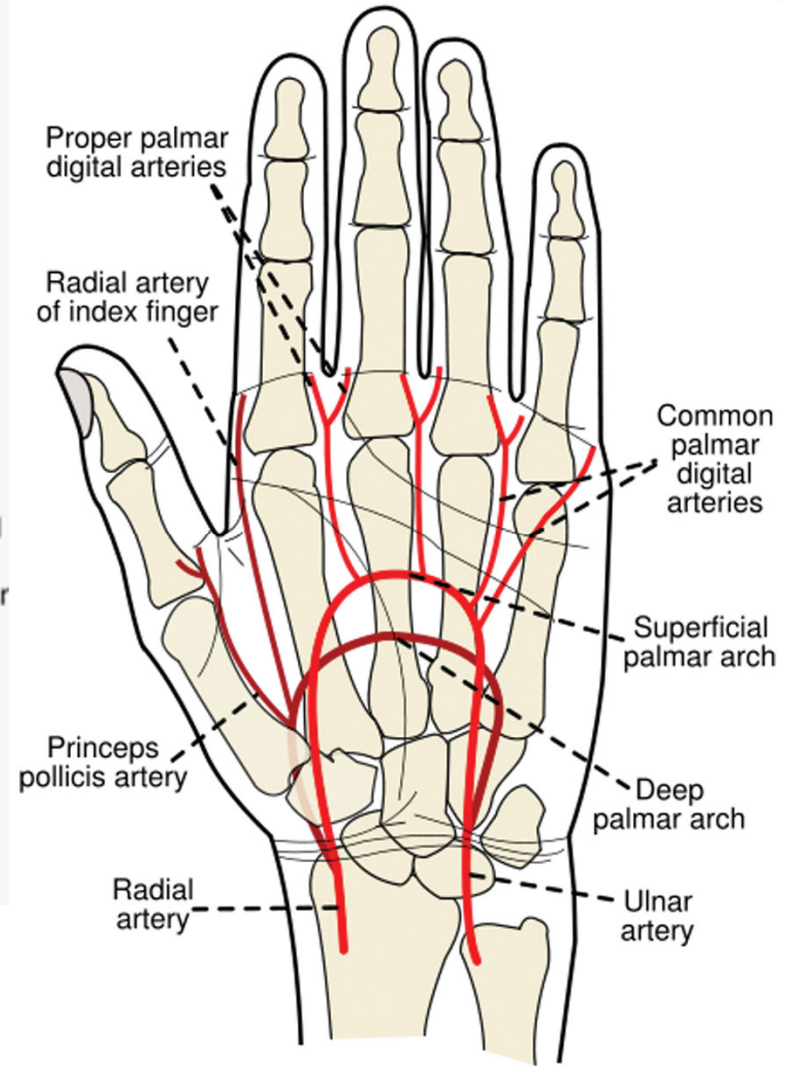
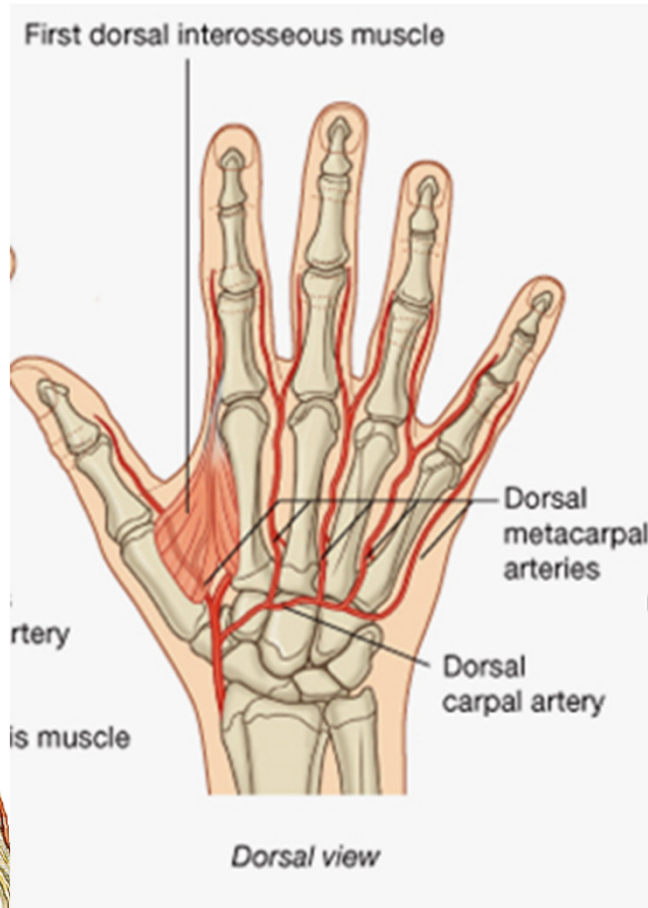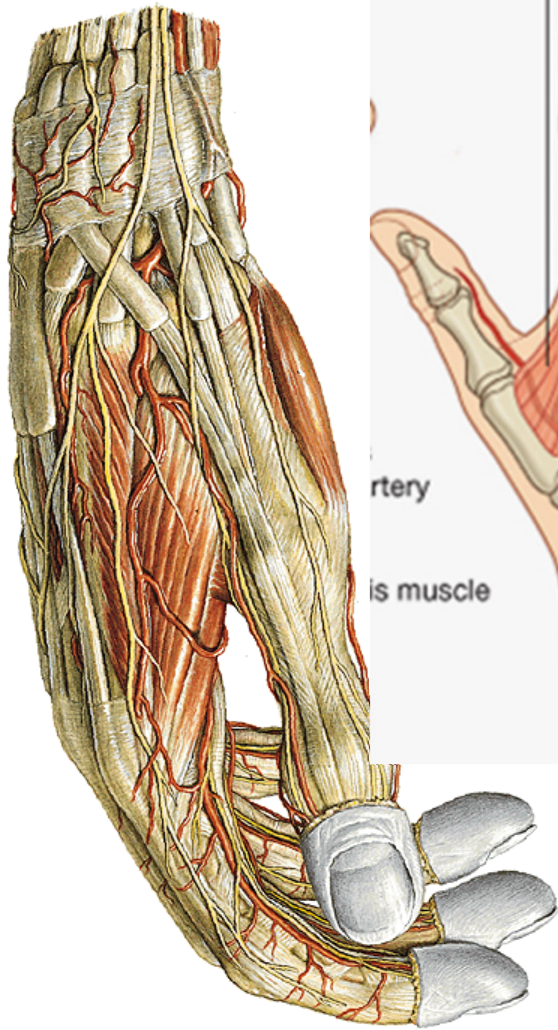
**a) větve k loketnímu kloubu**

**b) svalové větve (radiální a palmární skupina)**

**c) r. palmaris superficialis et profundus - spoluvytváří arcus palmaris superficialis et profundus**

**d) a. princeps pollicis- pro palec a lat. okraj ukazováku**







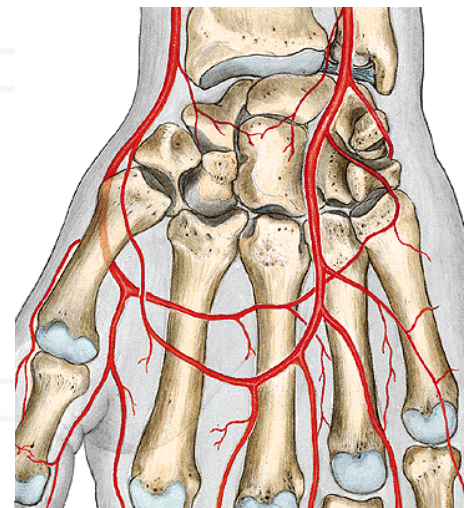
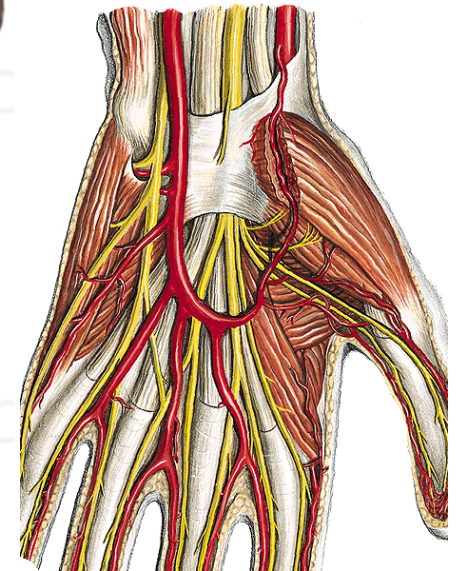
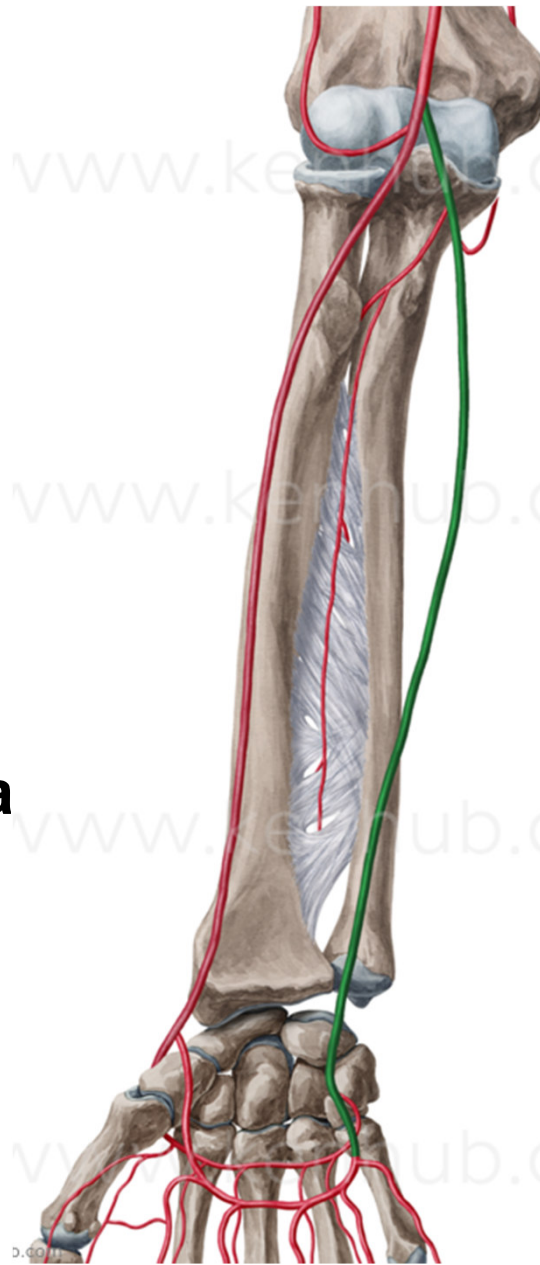
**A. ulnaris**  
**mezi m. flexor digitorum**  
**profundus a superficialis**

**distálně mezi m. flexor carpi**  
**ulnaris a m. flexor digitorum**  
**superficialis**

**Do dlaně po povrchu**  
**retinaculum flexorum po**  
**radiální straně os pisiforme a**  
**dělí se na konečné větve:**

**r. palmaris superficialis**

**r. palmaris profundus**



větve:

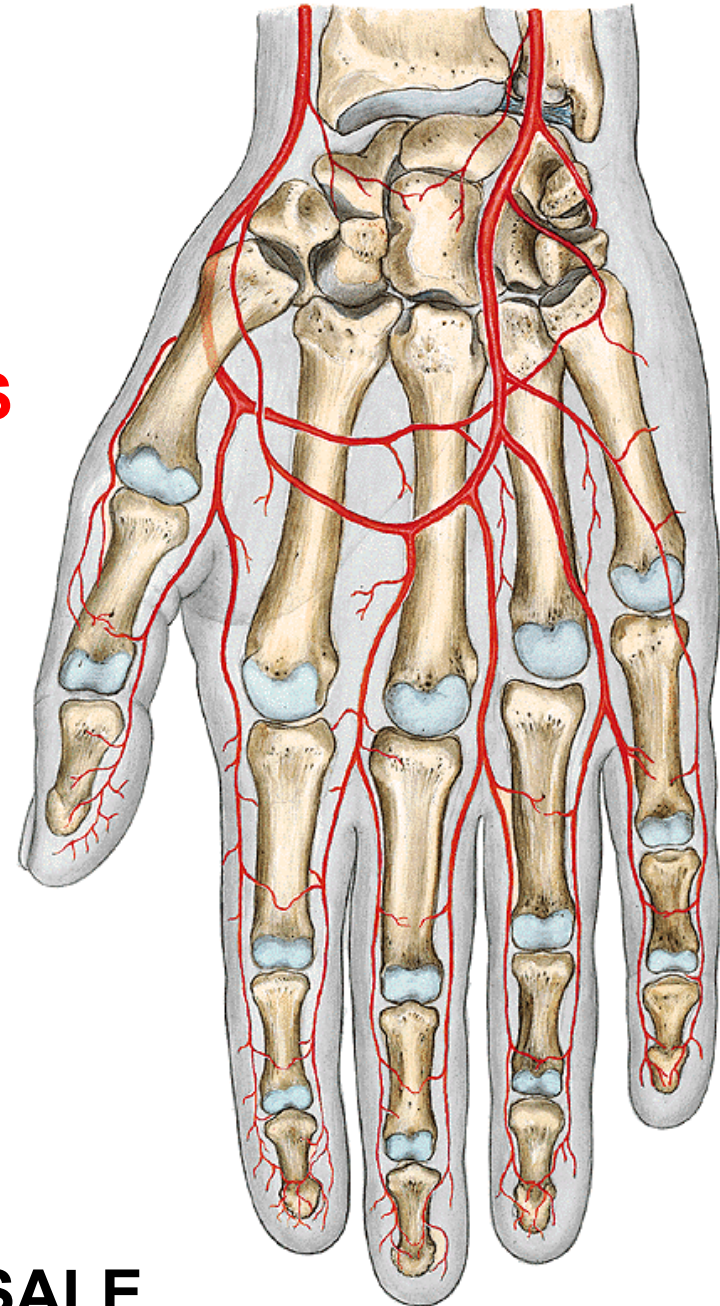
- a) svalové větve
- b) a. interossea communis
- c) k radiokarpálnímu kloubu
- d) r. palmaris superficialis
- e) r. palmaris profundus

### **ARCUS PALMARIS SUPERFICIALIS**

-aa. digitales palmares  
communes → aa. digitales  
palmares propriae

### **ARCUS PALMARIS PROFUNDUS**

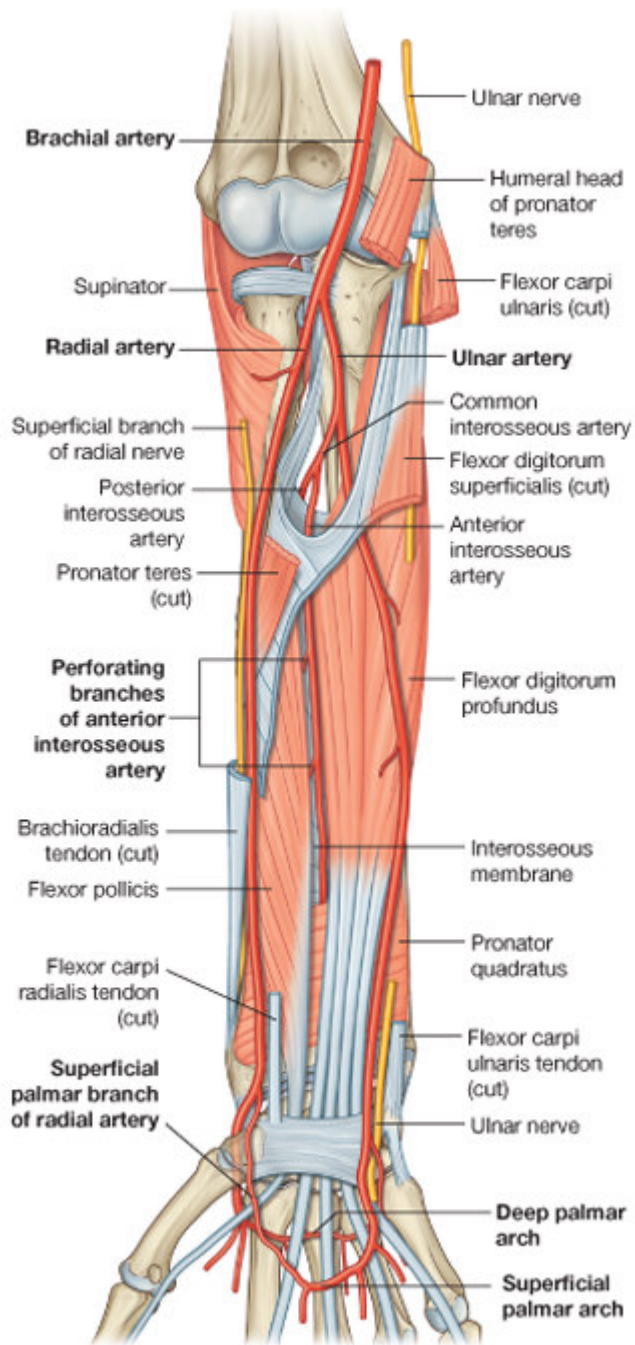
-aa. metacarpae palmares – spojují  
se s aa. digitales communes



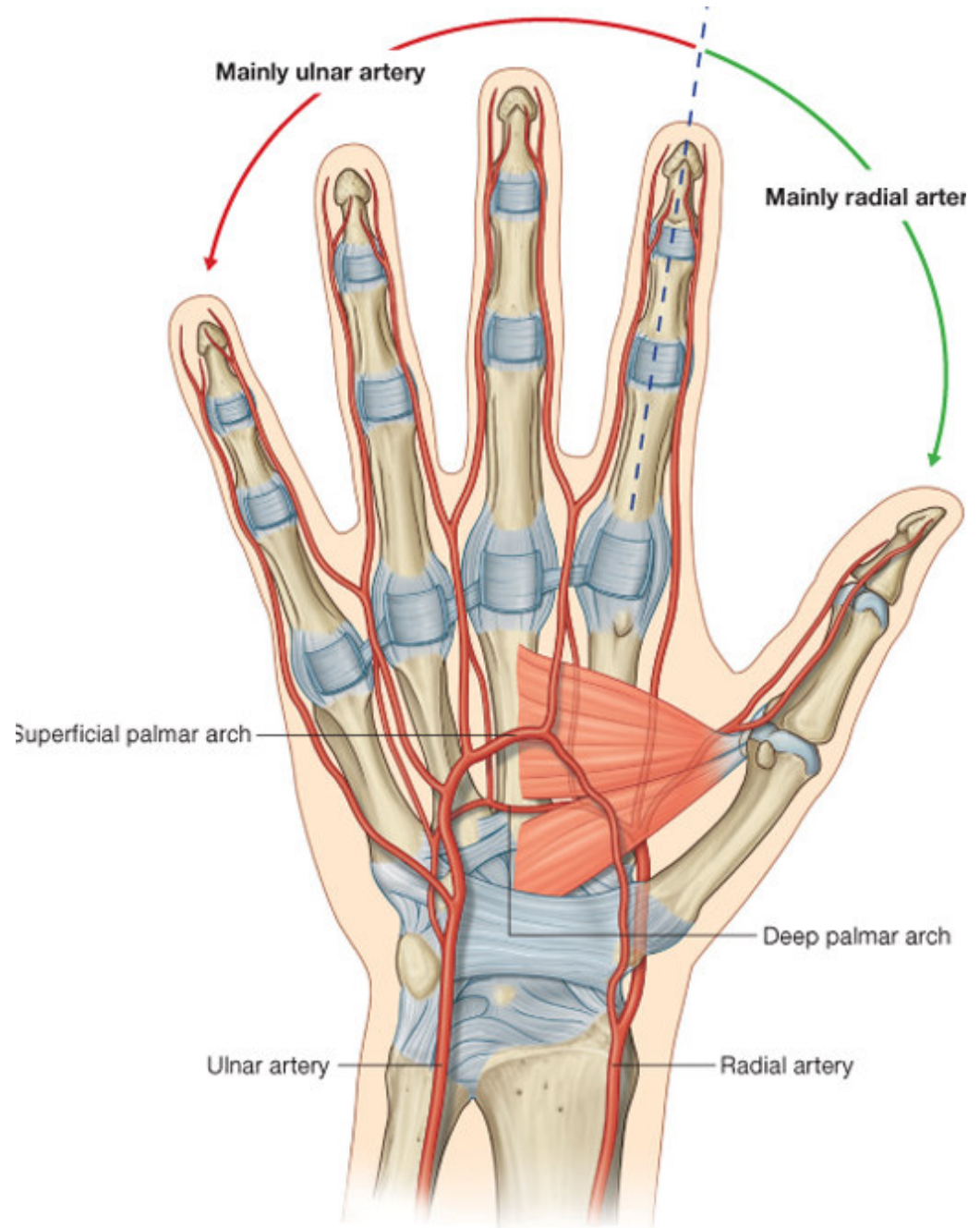
**RETE ARTICULARE CUBITI**

**RETE CARPI PALMARE ET DORSALE**

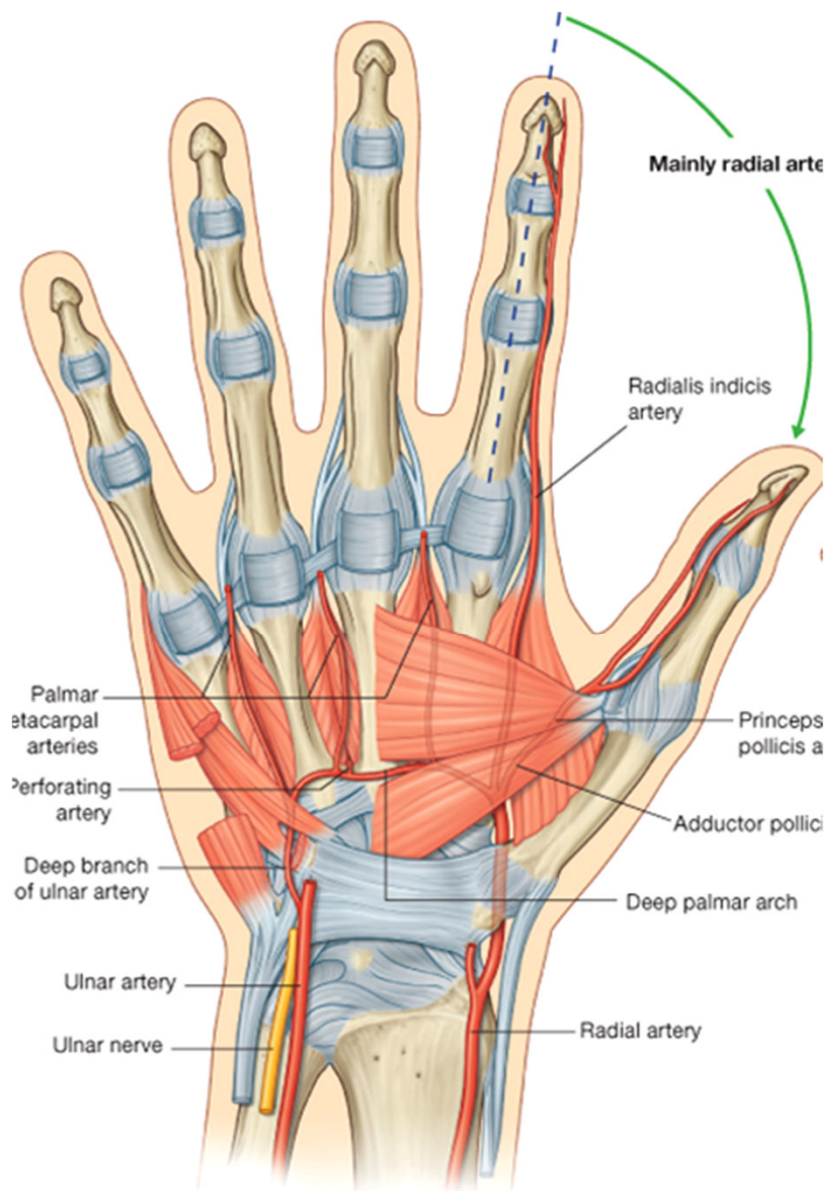




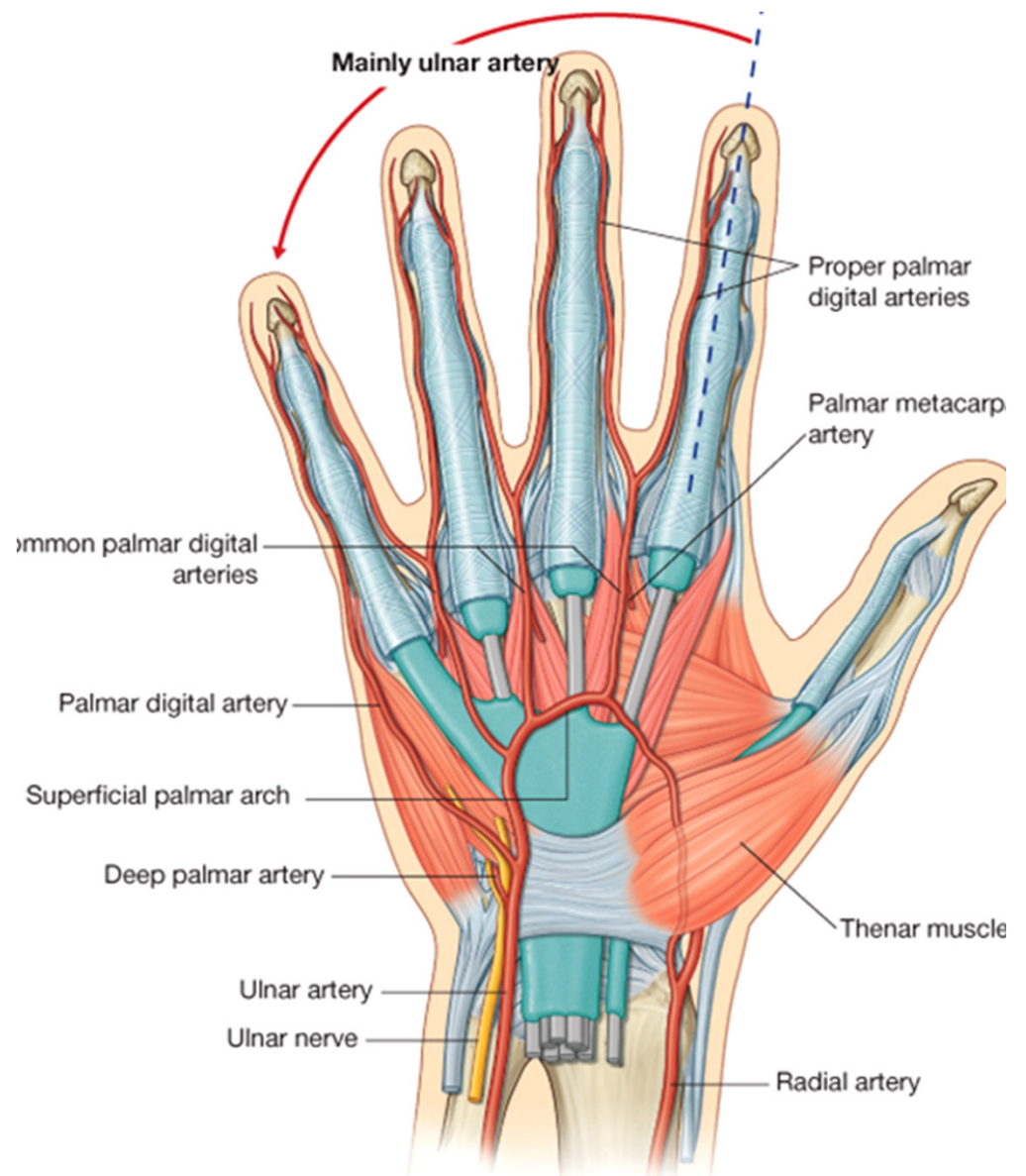
Drake: Gray's Anatomy for Students, 2nd Edition.  
 Copyright © 2009 by Churchill Livingstone, an imprint of Elsevier, Inc. All rights reserved.



Drake: Gray's Anatomy for Students, 2nd Edition.  
 Copyright © 2009 by Churchill Livingstone, an imprint of Elsevier, Inc. All rights reserved.



Drake: Gray's Anatomy for Students, 2nd Edition.  
 Copyright © 2009 by Churchill Livingstone, an imprint of Elsevier, Inc. All rights reserved.



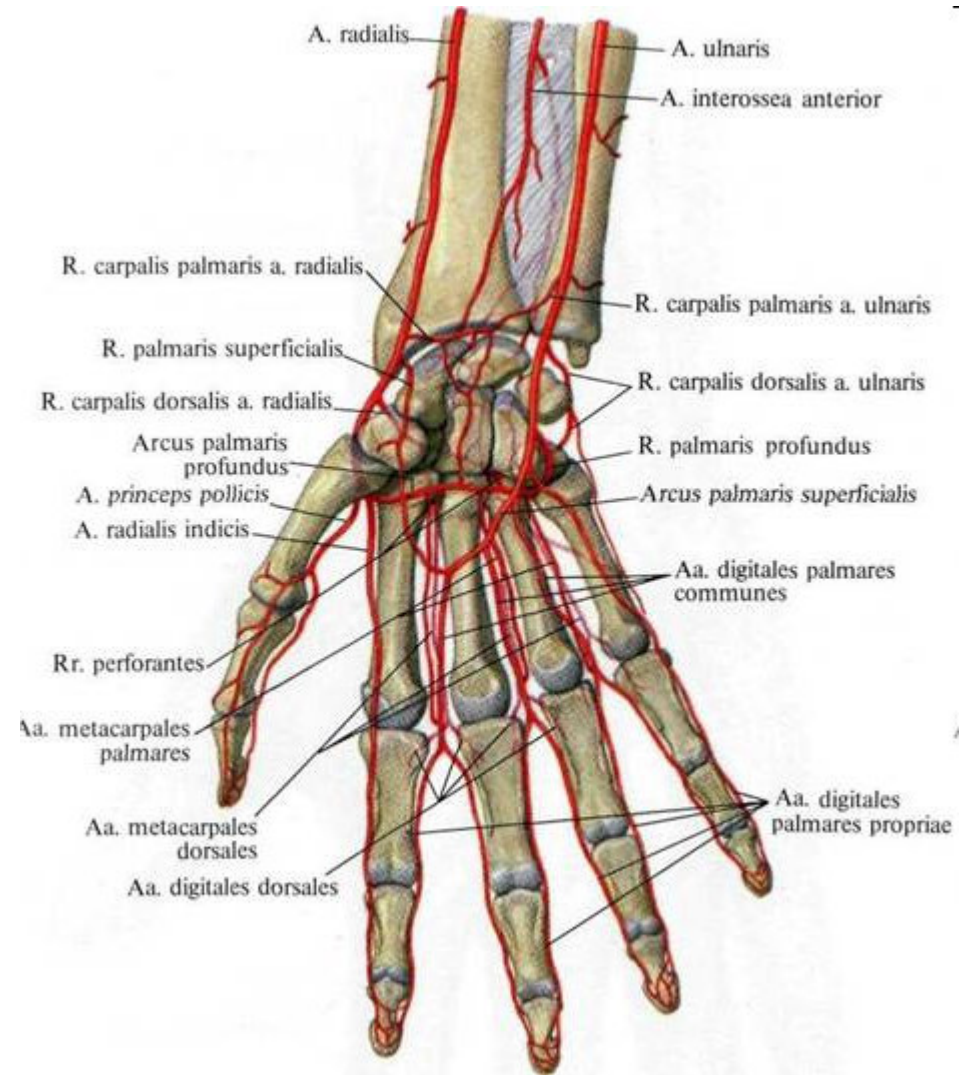
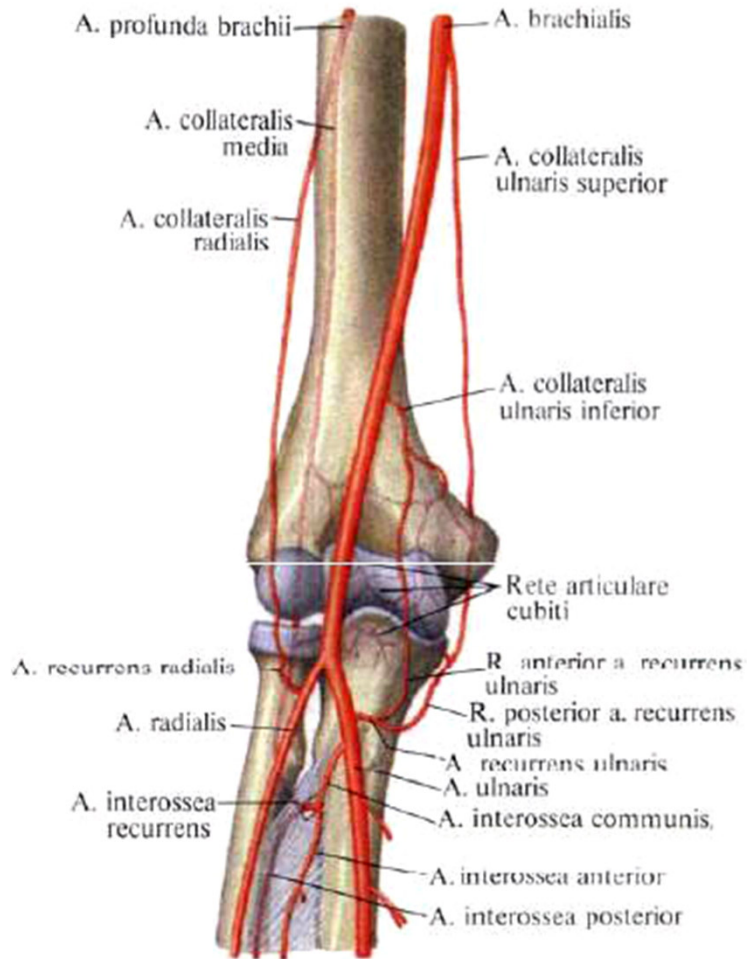
Drake: Gray's Anatomy for Students, 2nd Edition.  
 Copyright © 2009 by Churchill Livingstone, an imprint of Elsevier, Inc. All rights reserved.

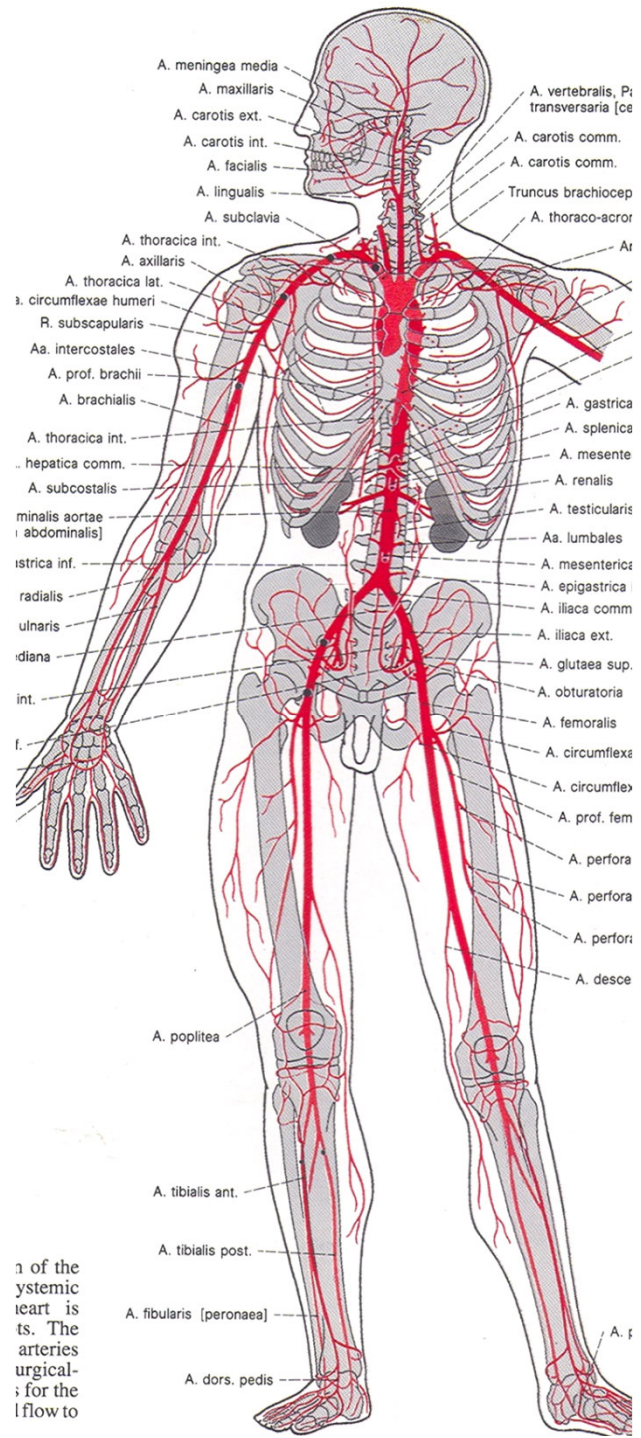


# RETE ARTICULARE CUBITI

## RETE CARPI PALMARE

## RETE CARPI DORSALE



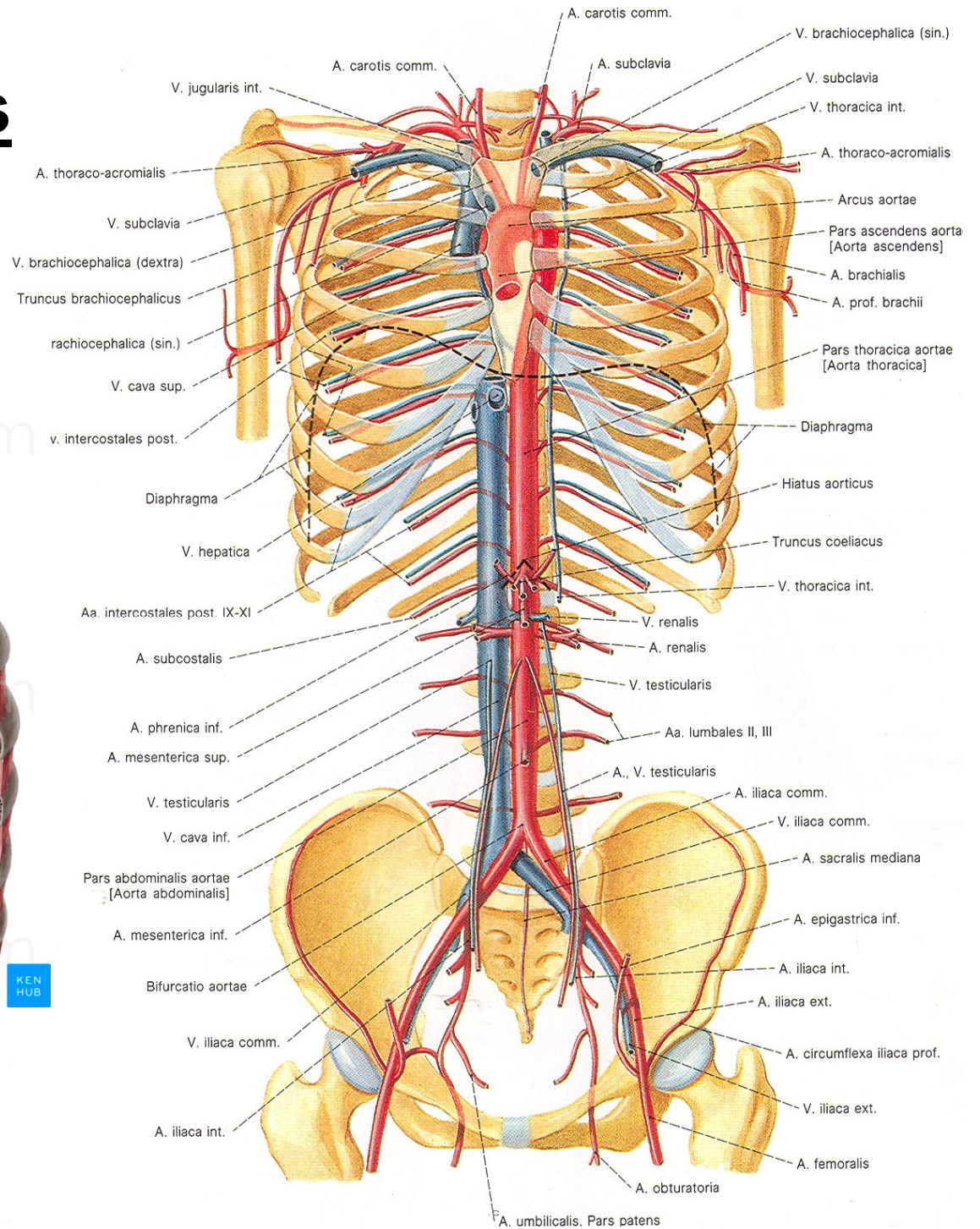
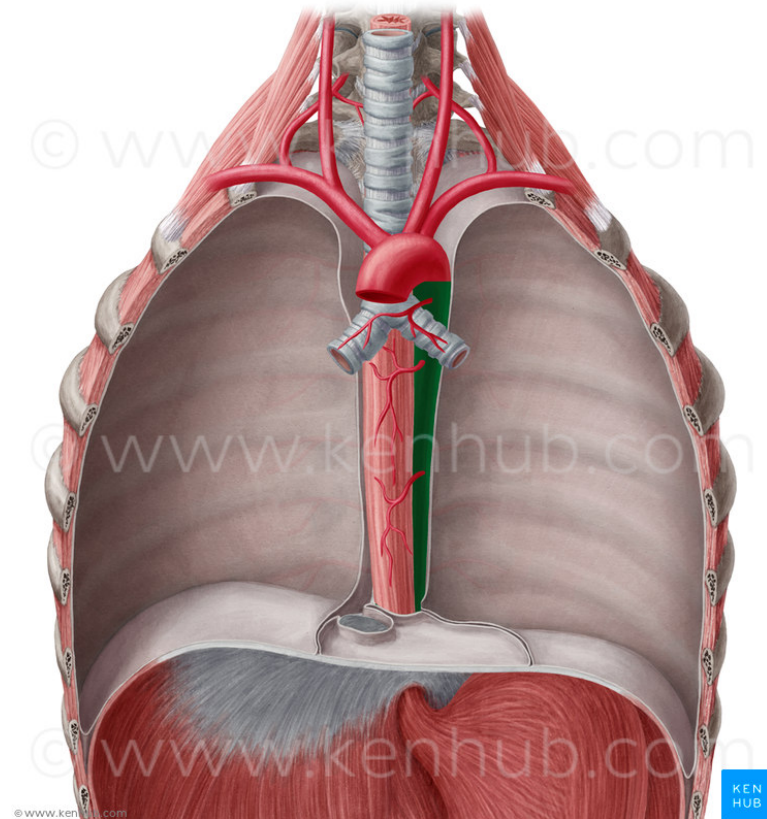


1 of the  
 systemic  
 heart is  
 ts. The  
 arteries  
 urgical-  
 ; for the  
 lflow to



# Aorta descendens

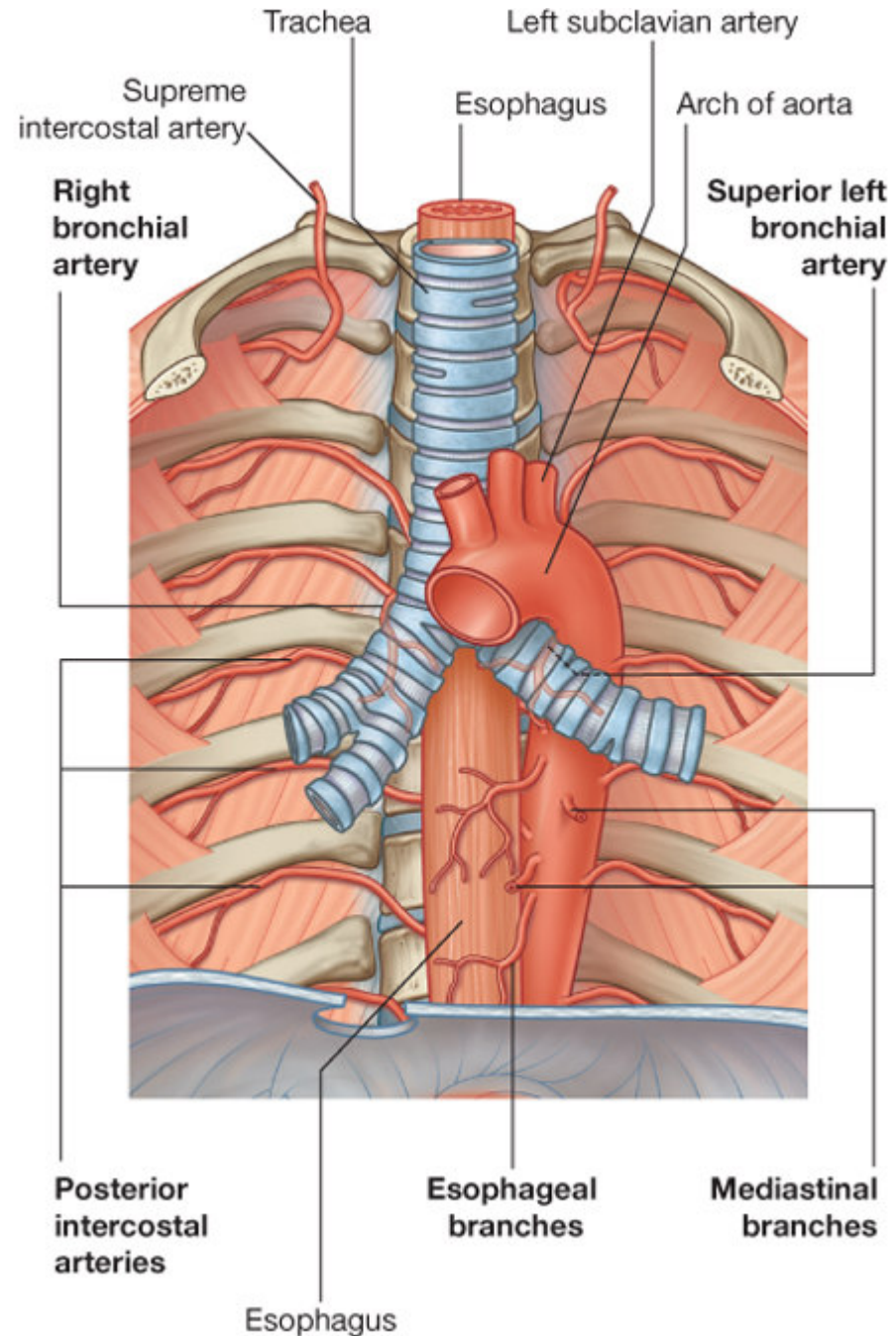
## - Th3- L4



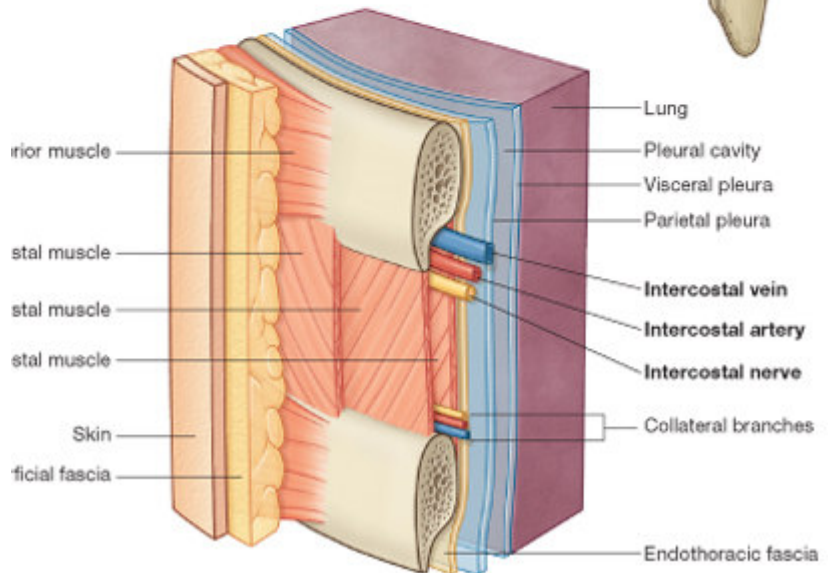
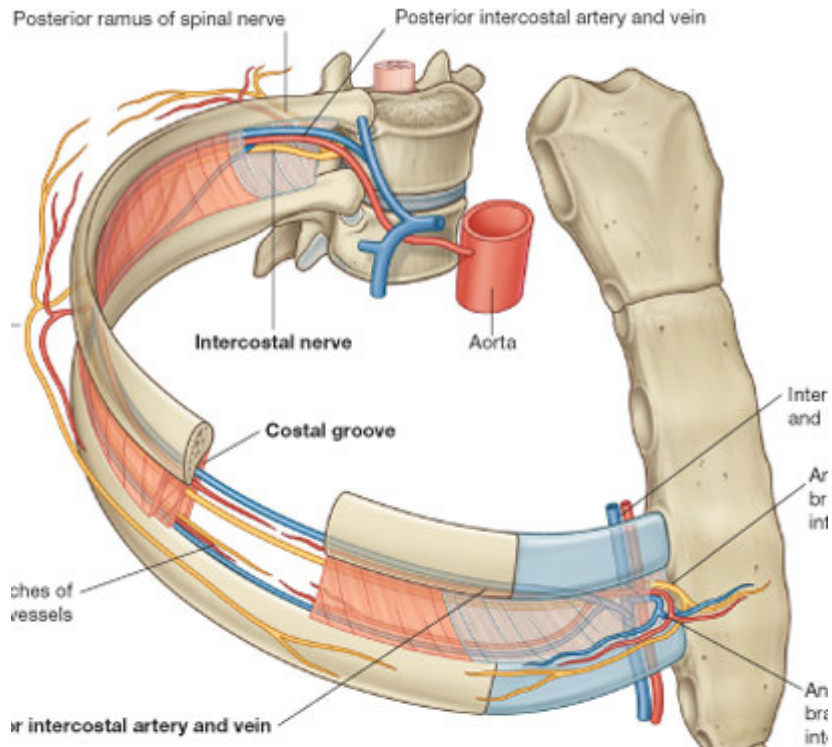
**AORTA THORACICA** –  
od Th<sub>3</sub> k bránici  
(zadní mediastinum)

**Parietální větve:**  
aa. intercostales  
posteriores (mezižebří)  
aa. phrenicae superiores  
(bránice)

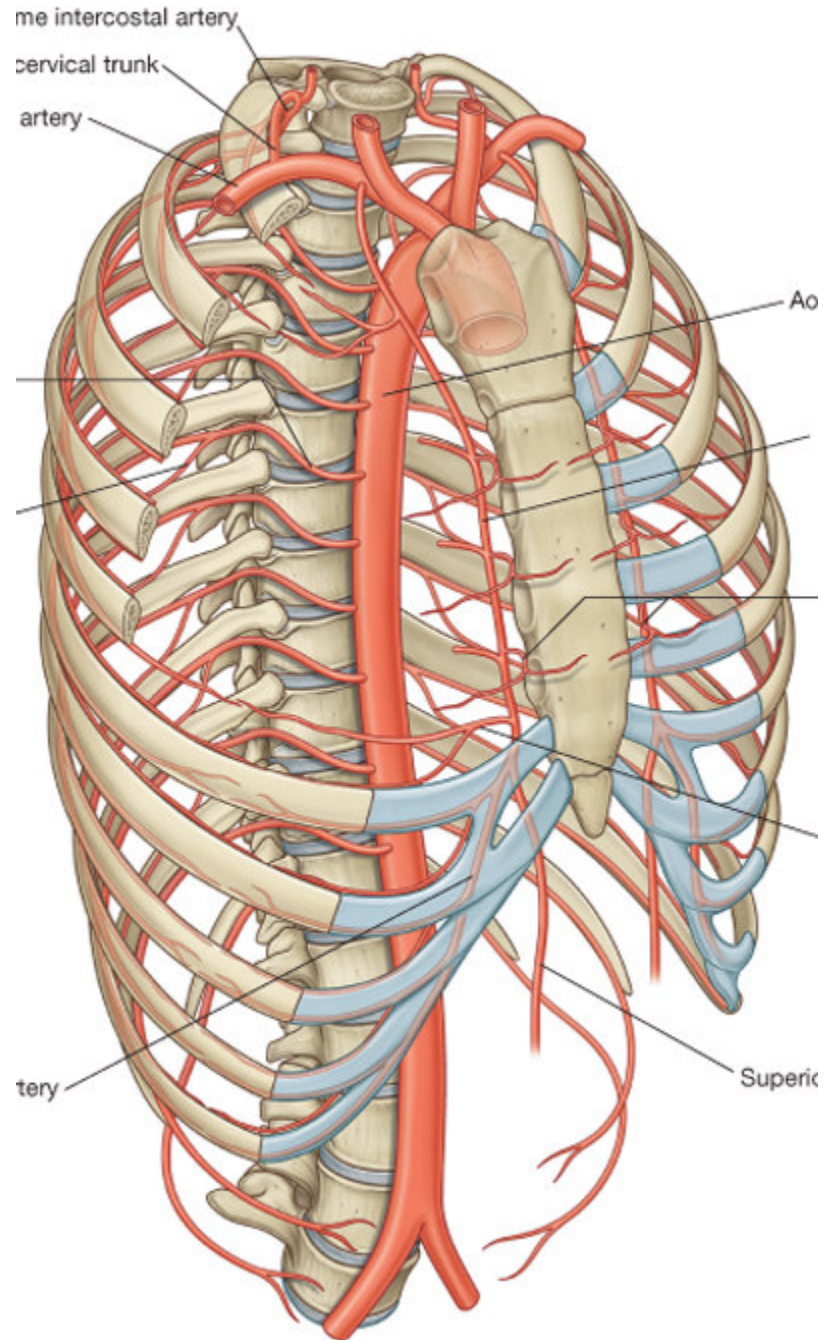
**Viscerální větve:**  
rr. bronchiales  
rr. oesophagei  
rr. pericardiaci  
rr. mediastinales



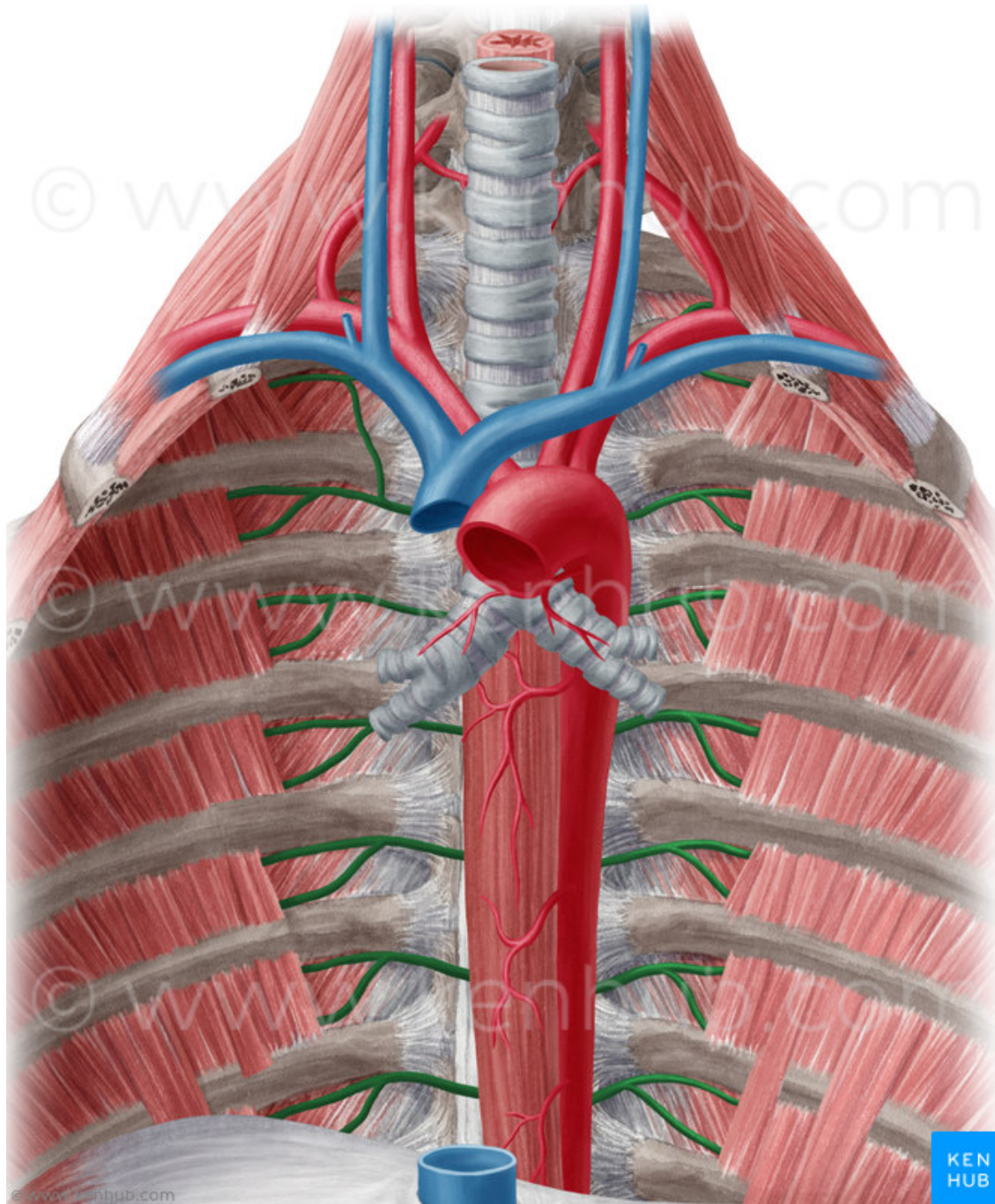




Moore's Anatomy for Students, 2nd Edition.  
 © 2009 by Churchill Livingstone, an imprint of Elsevier, Inc. All rights reserved.



Moore's Anatomy for Students, 2nd Edition.  
 © 2009 by Churchill Livingstone, an imprint of Elsevier, Inc. All rights reserved.





# AORTA ABDOMINALIS – bránice - L4

- retroperitoneálně
- L4 bifurcatio aortae

## Větve parietální:

- ke stěně břišní dutiny, k bránici (aa. phrenicae inferiores, aa. lumbales)

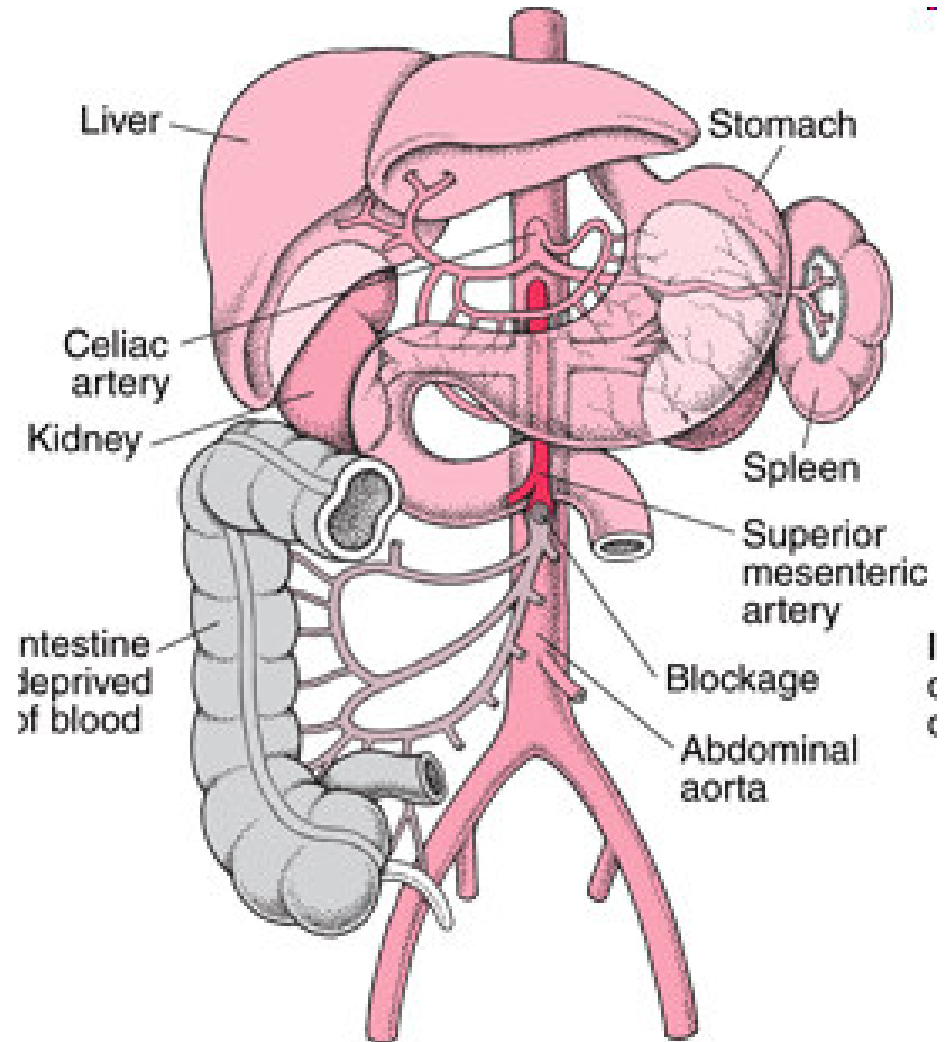
## Větve viscerální:

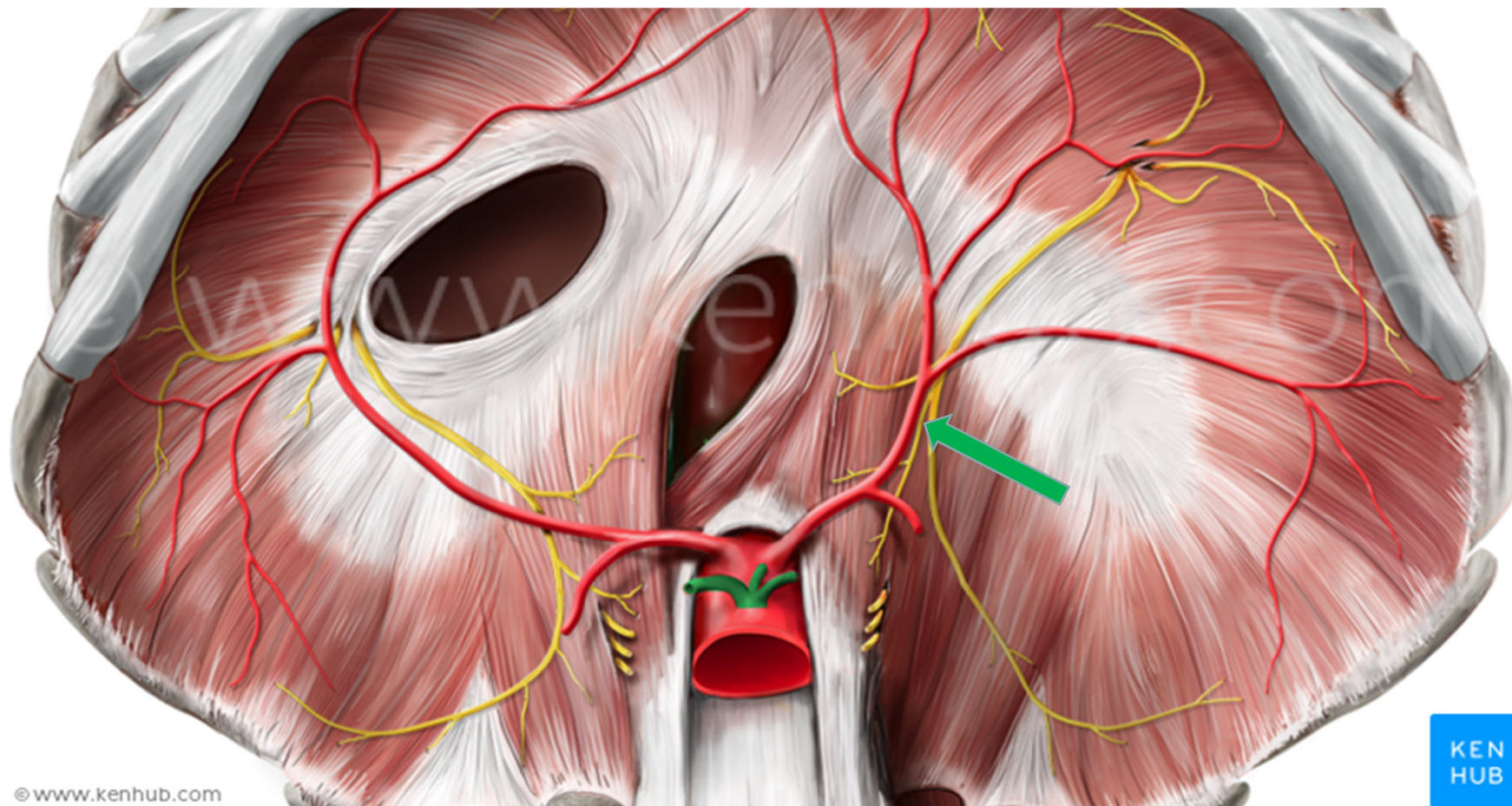
- **nepárové**

1) truncus coeliacus (Th<sub>12</sub>-L<sub>1</sub>) - (k žaludku, k játrům, ke slezině)

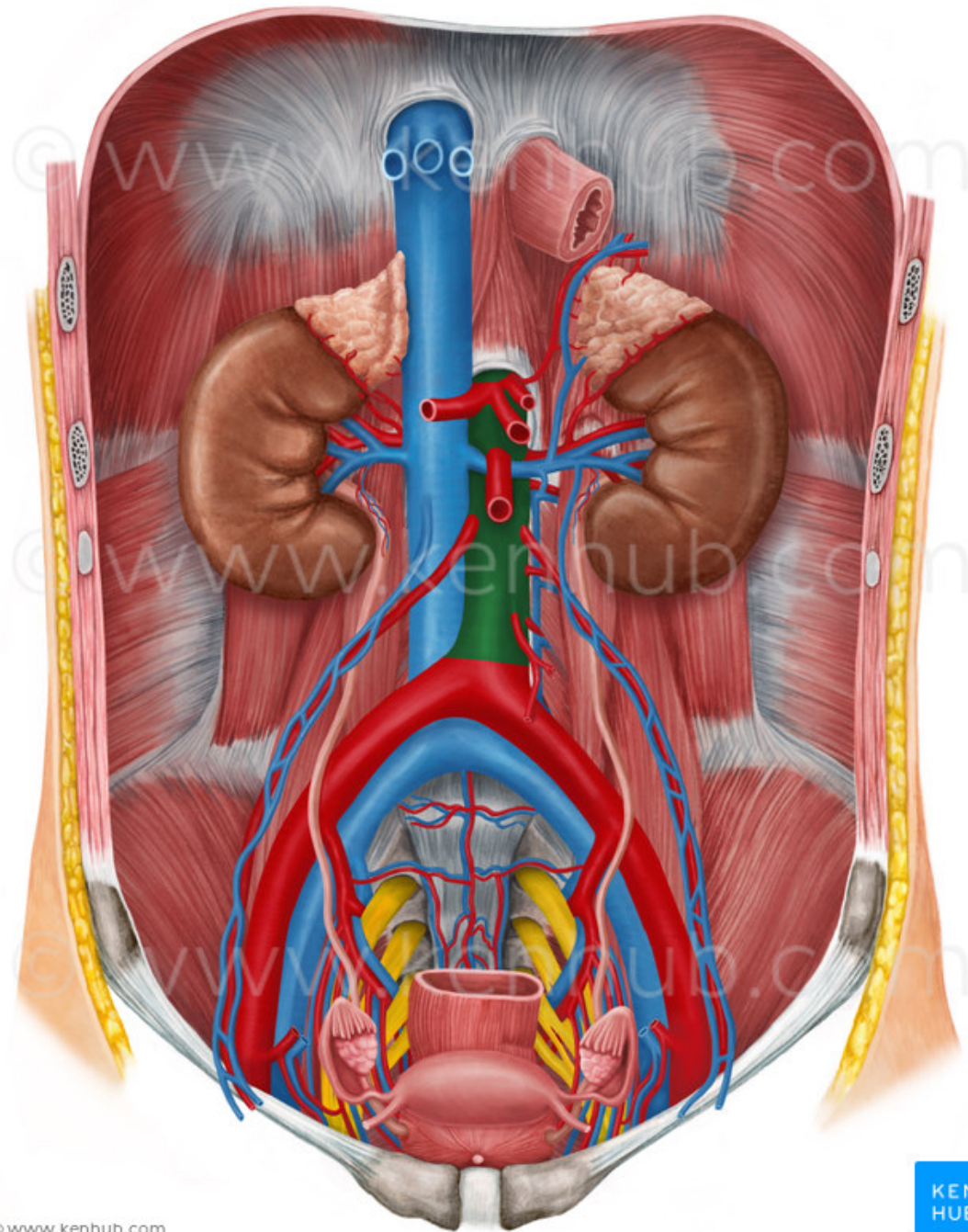
2) a. mesenterica superior (L<sub>1</sub>) (pro celé tenké a část tlustého střeva)

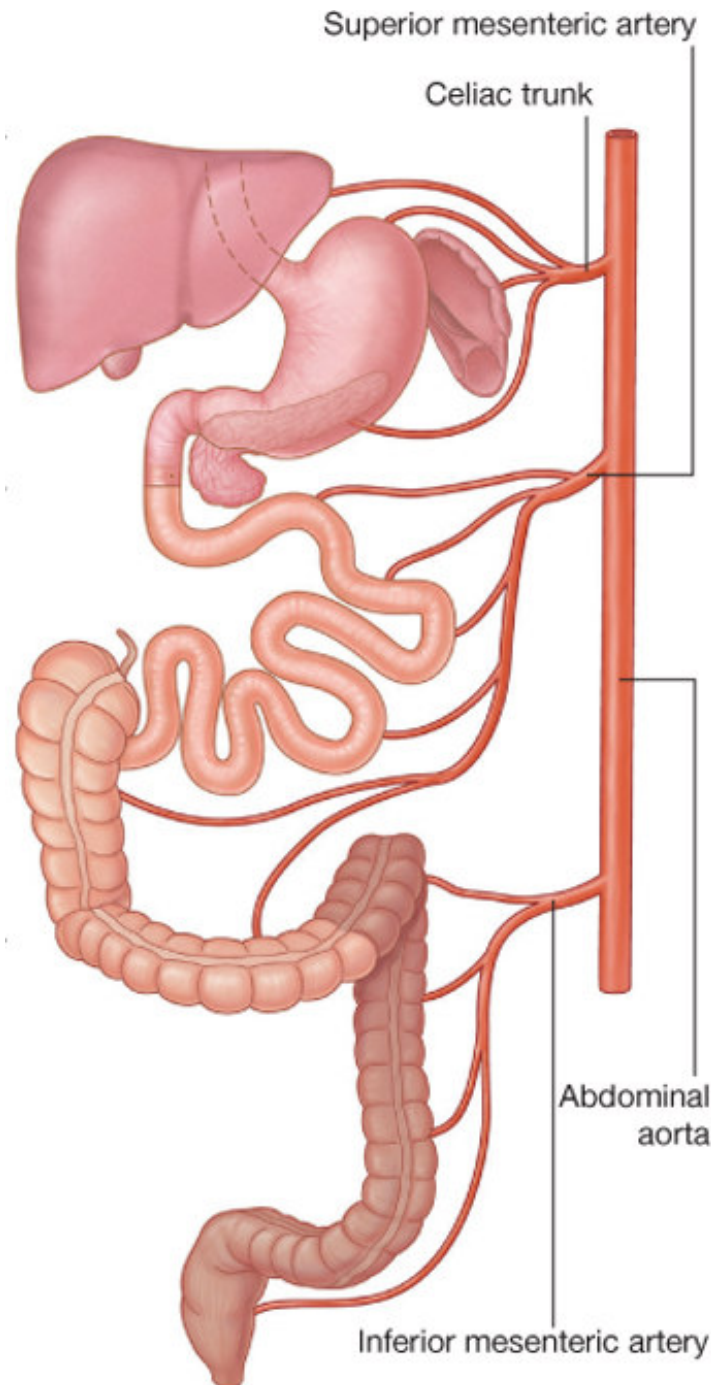
3) a. mesenterica inferior (L<sub>3</sub>) (od flexura coli sin. kaudálně až po kraniální část konečníku)











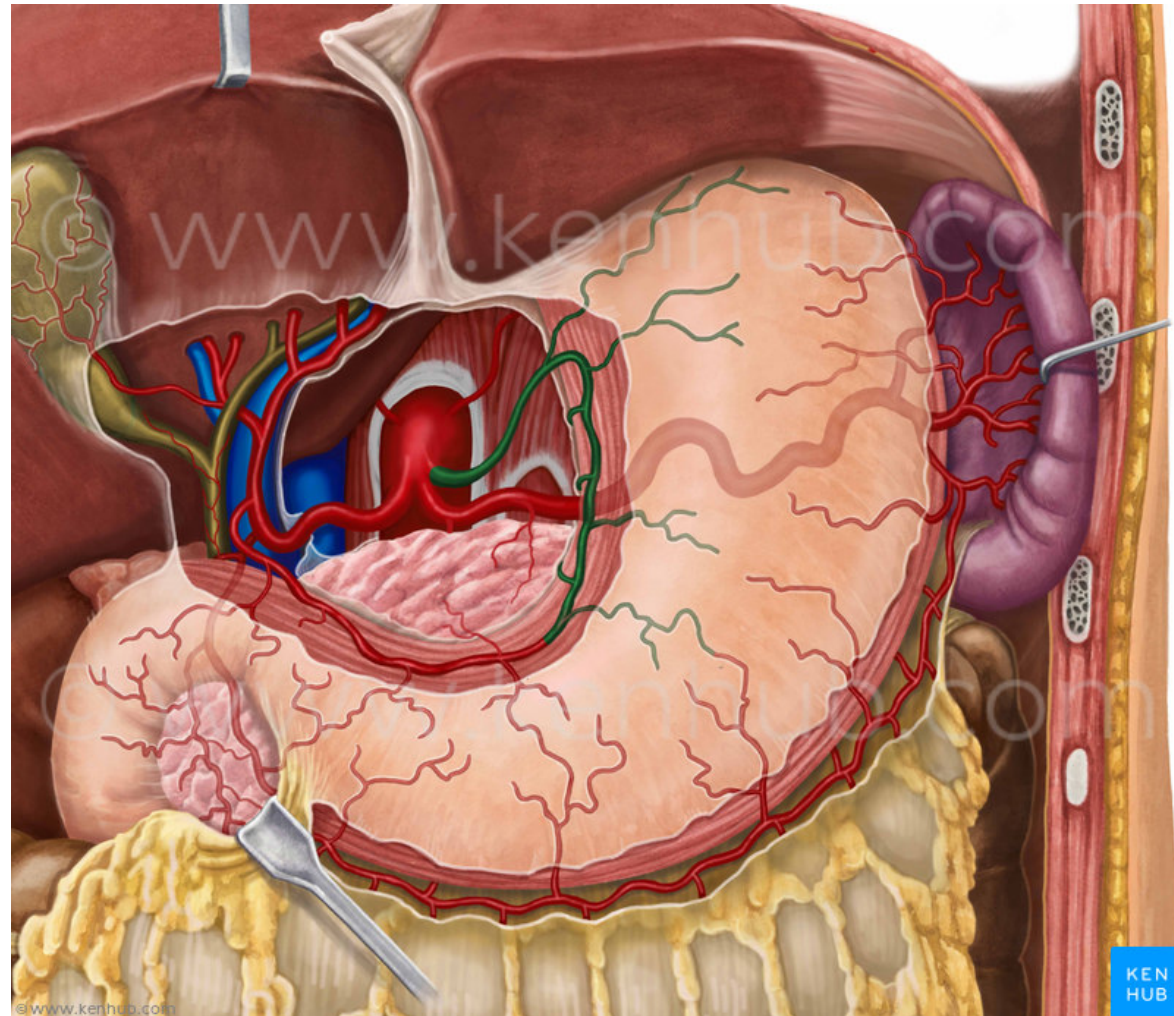
**truncus coeliacus**

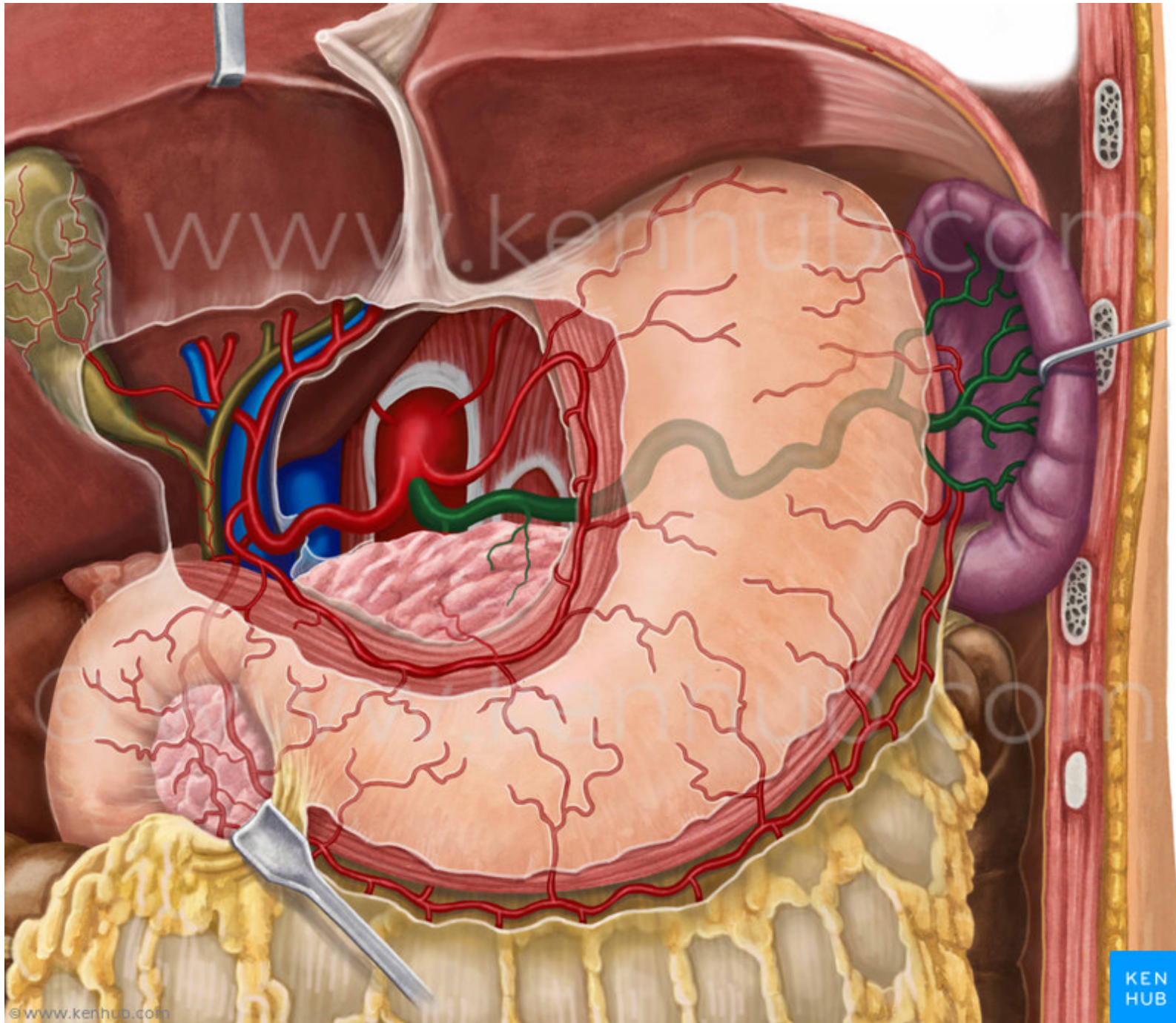
**a. mesenterica superior**

**a. mesenterica inferior**

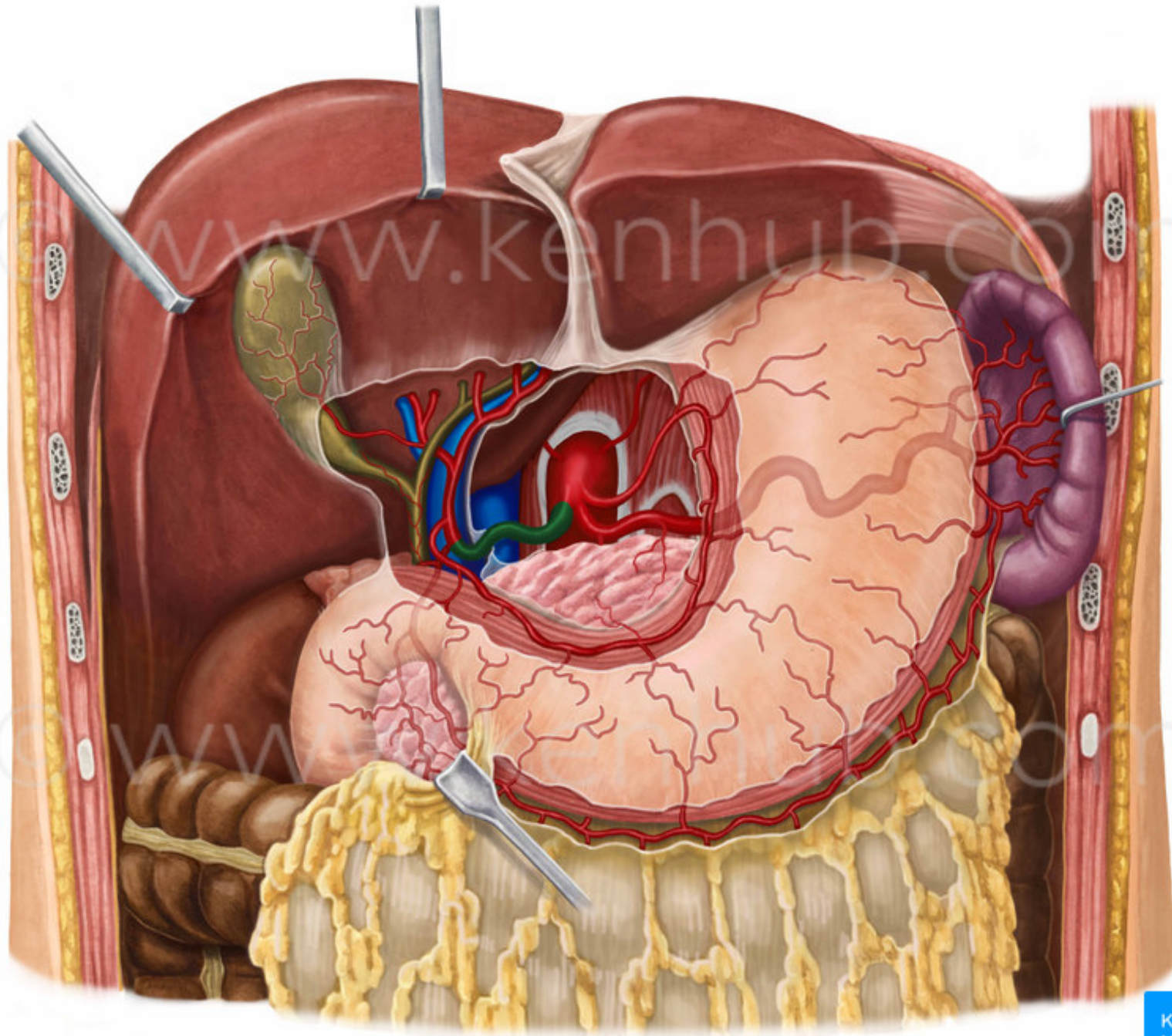


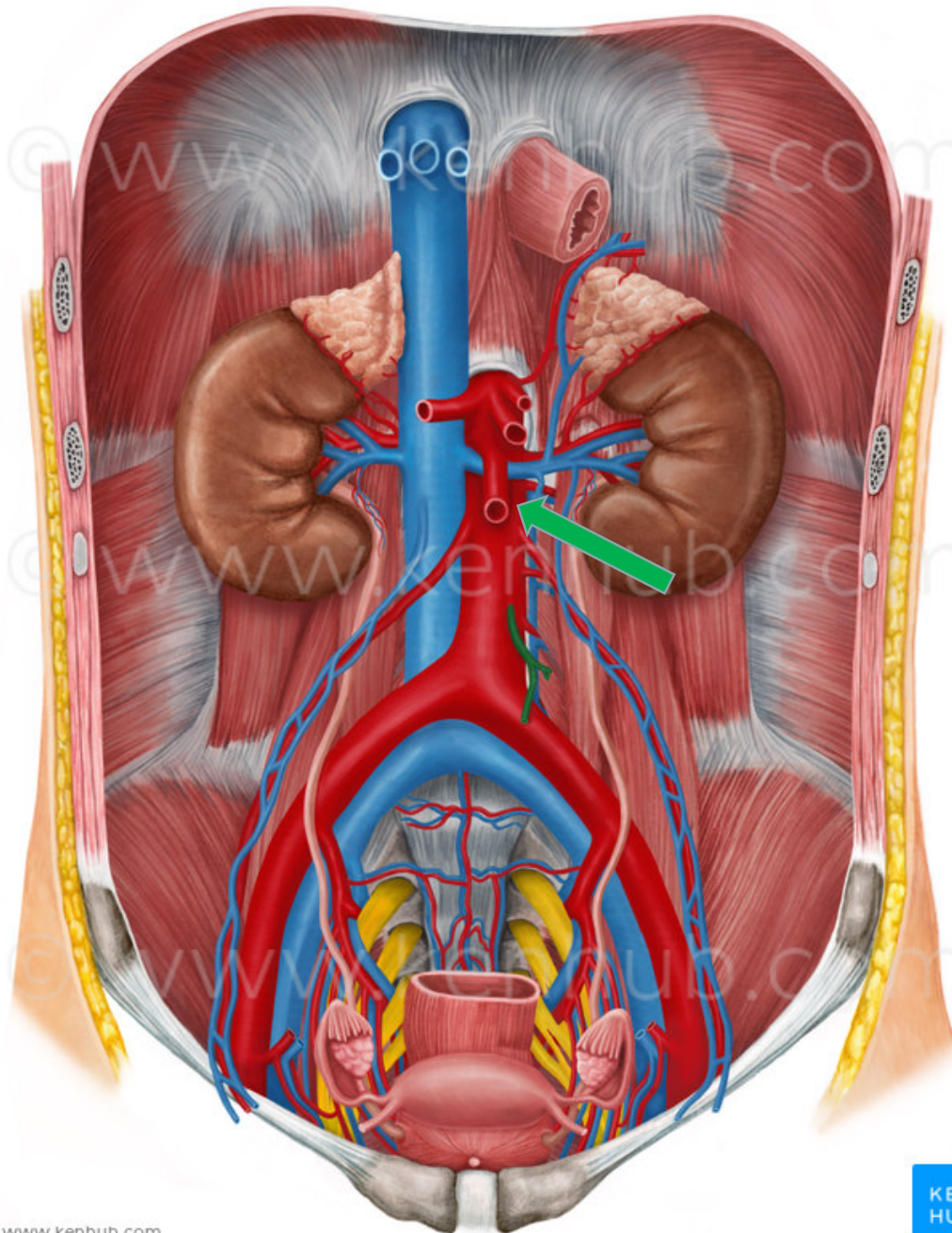
- Truncus coeliacus:
- A. gastrica sinistra
- A. hepatica communis
- A. lienalis





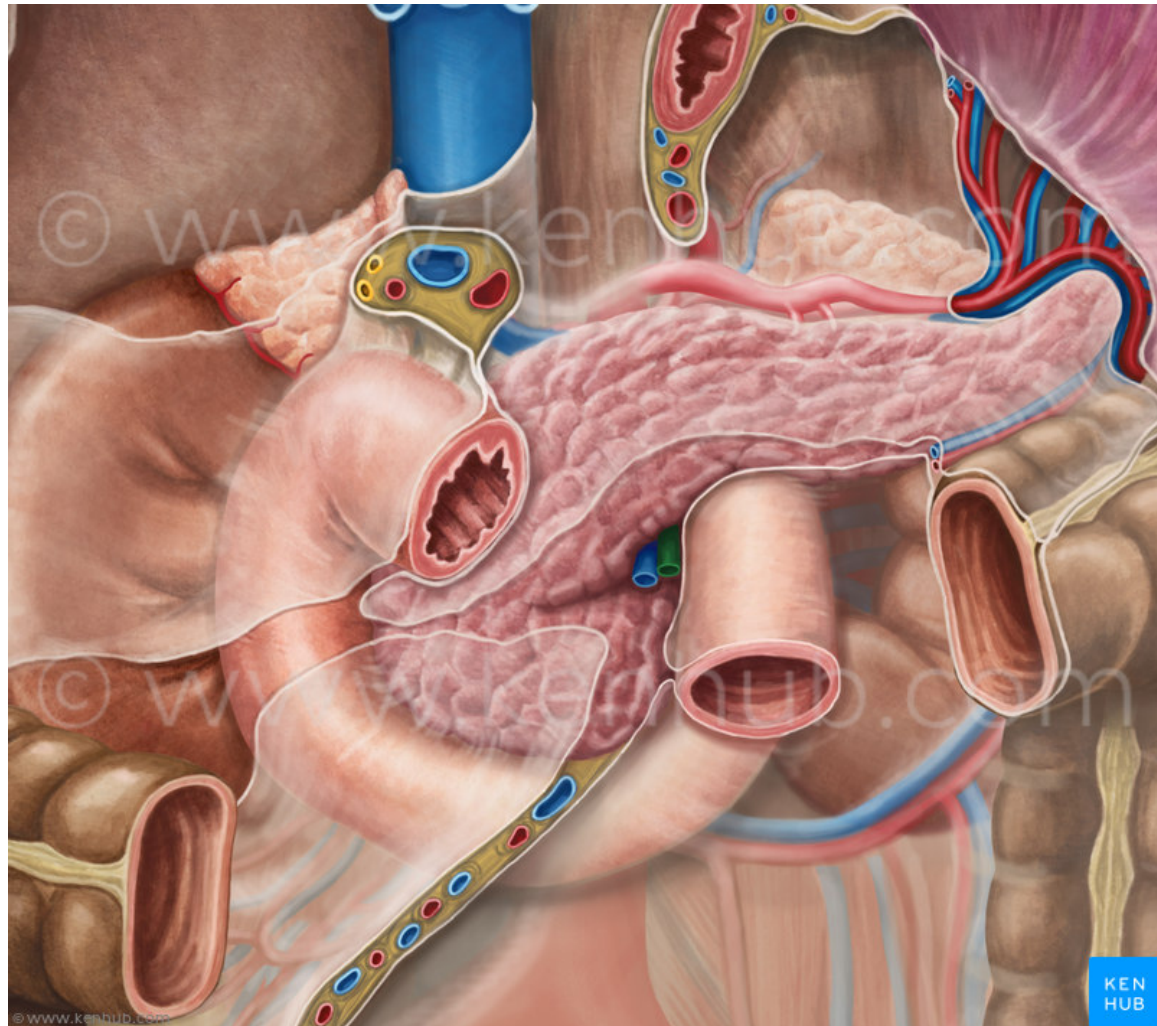


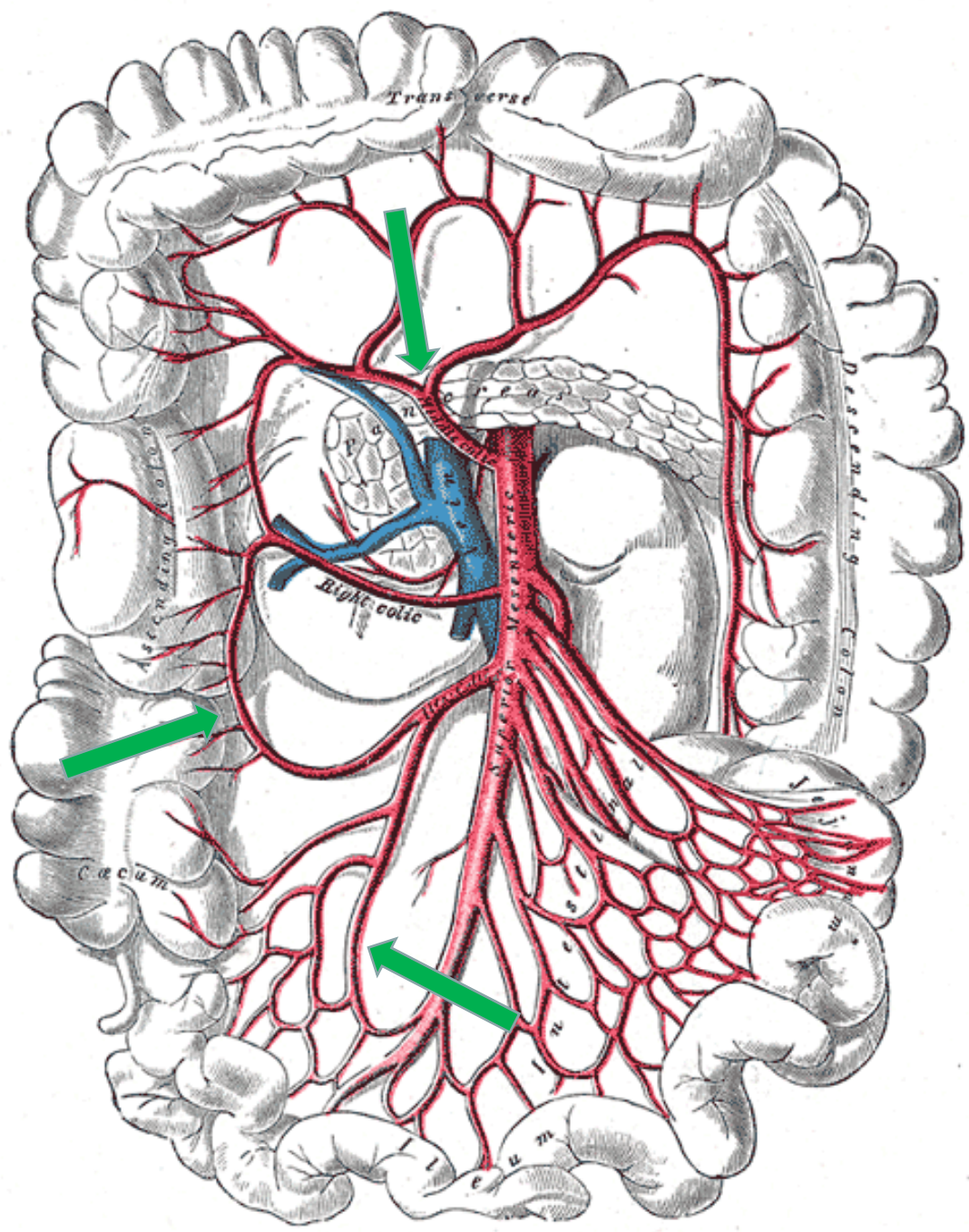






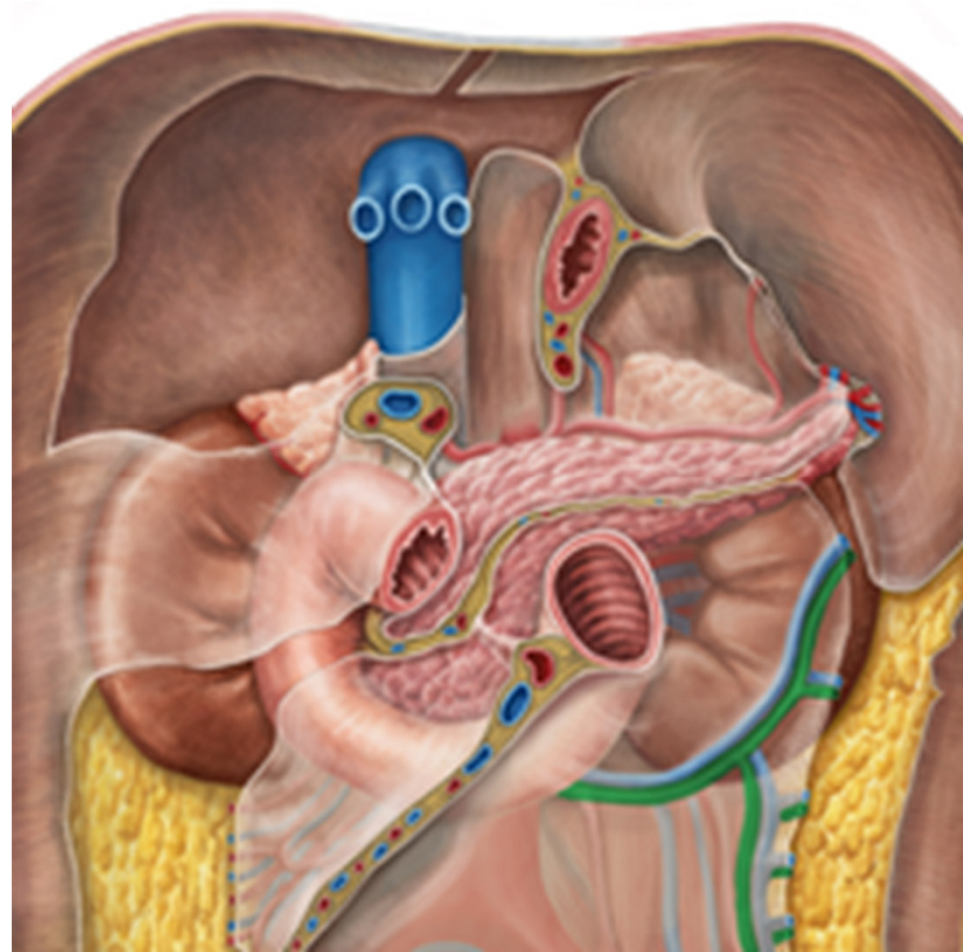
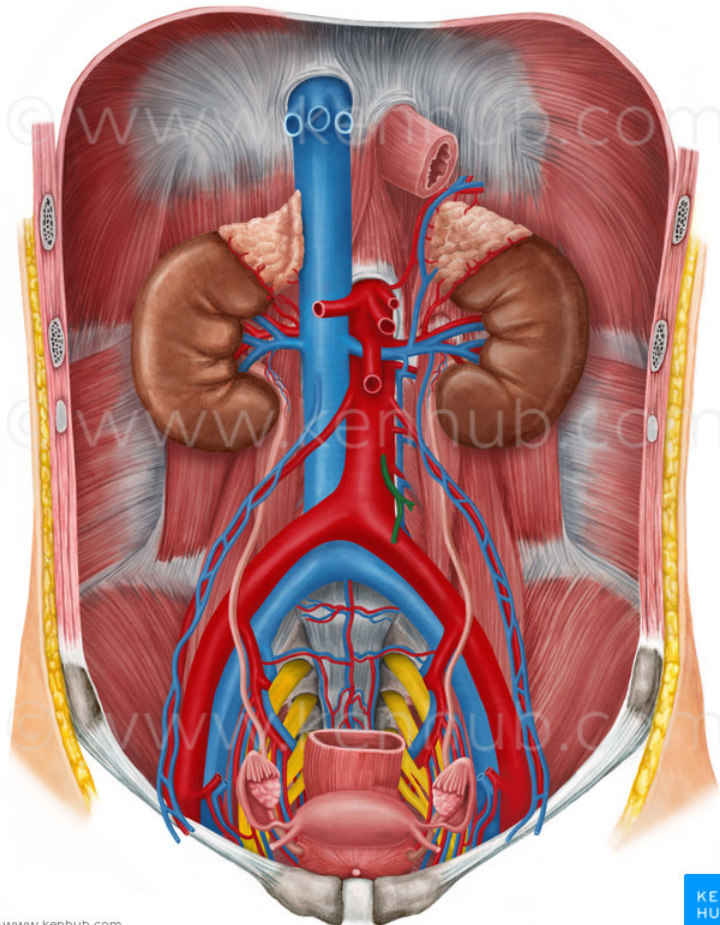
- A. mesenterica superior:
- A. pancreaticoduodenalis
- Aa. jejunales et ilei
- A. ileocolica
- A. colica dextra
- A. colica media

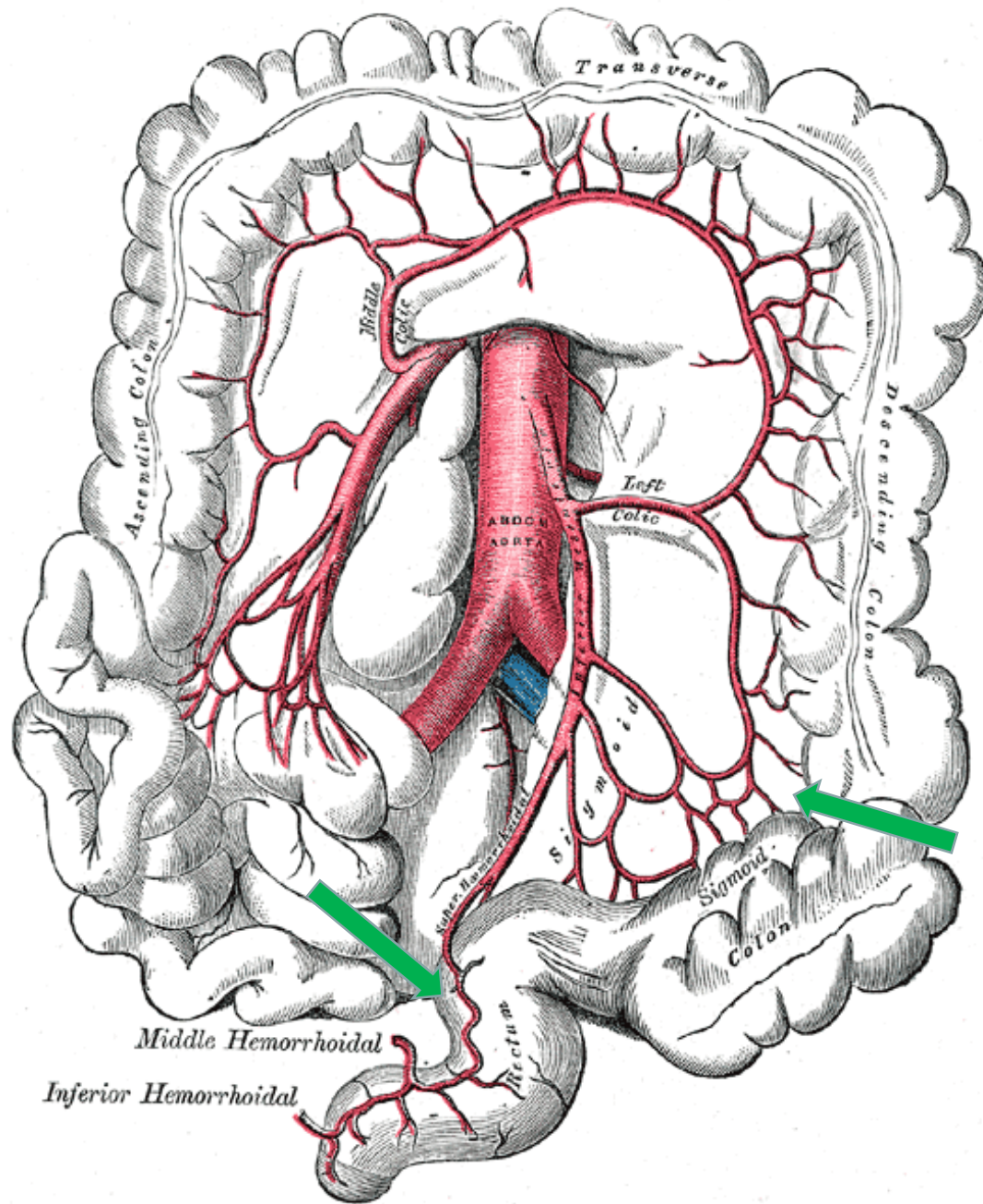






- A. mesenterica inferior:
- A. colica sinistra
- Aa. sigmoideae
- A. rectalis superior







- **párové:**

- 1) k nadledvinám

- aa. suprarenales mediae

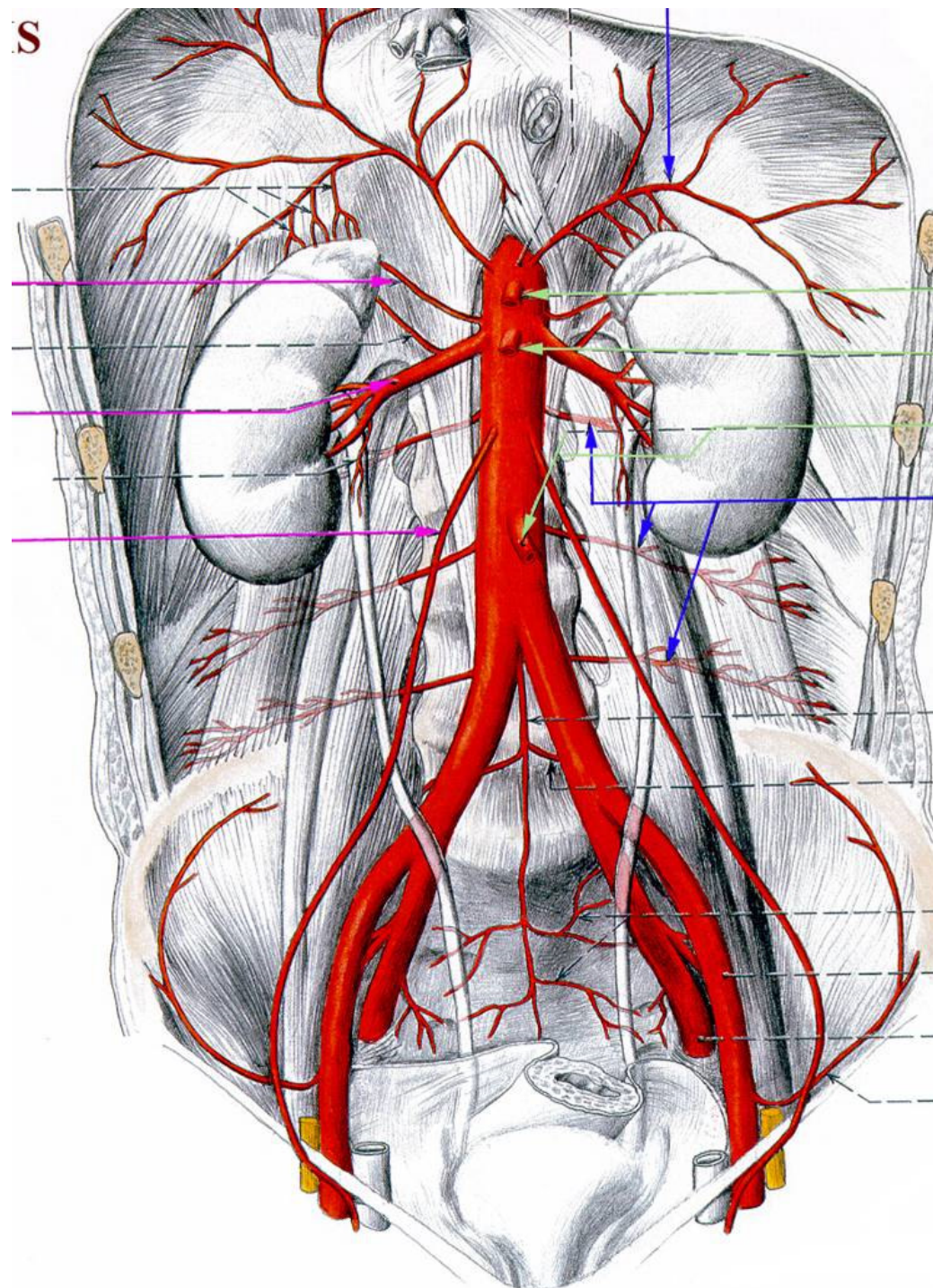
- 2) k ledvinám

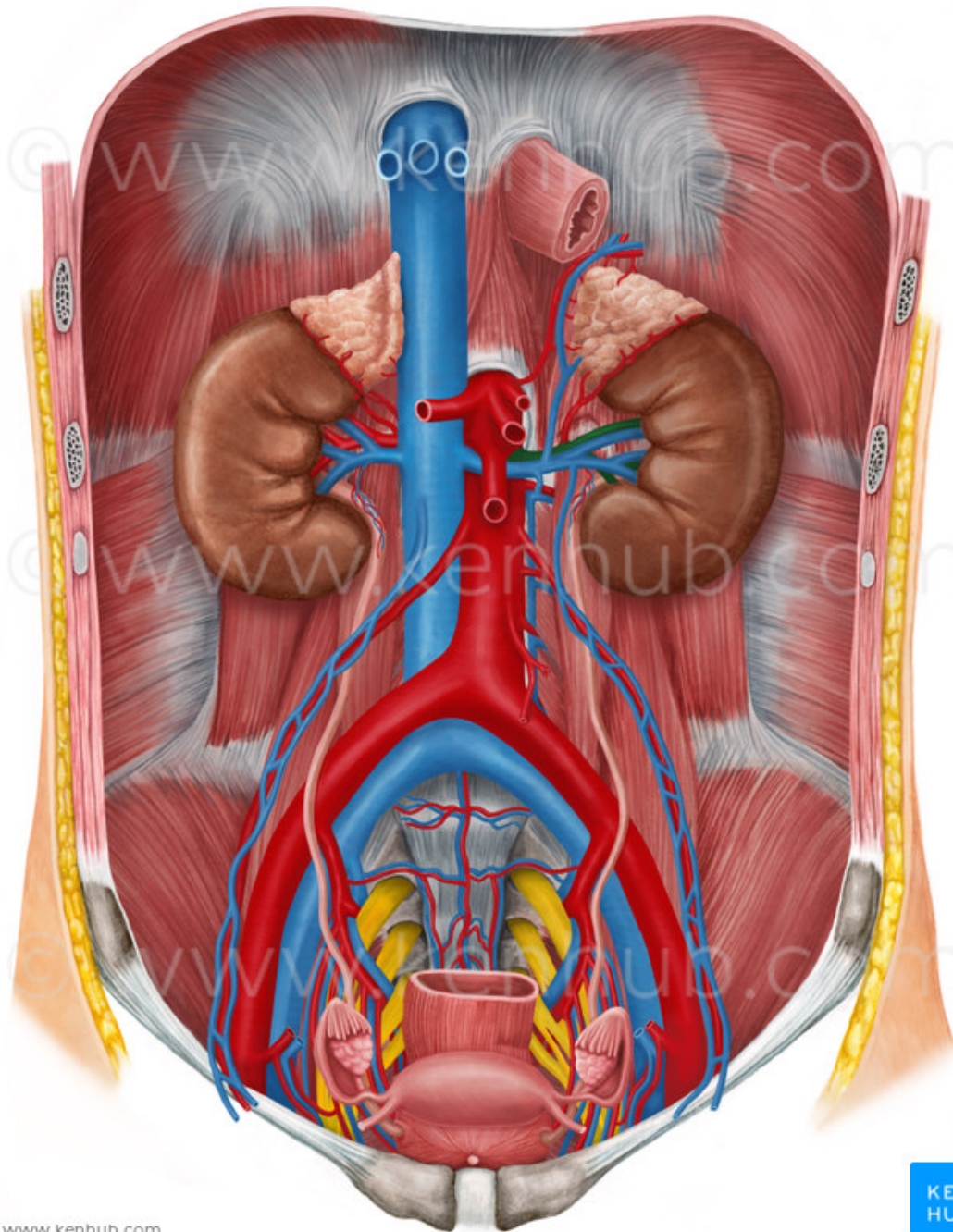
- aa. renales

- 3) k vaječníkům (varlata)

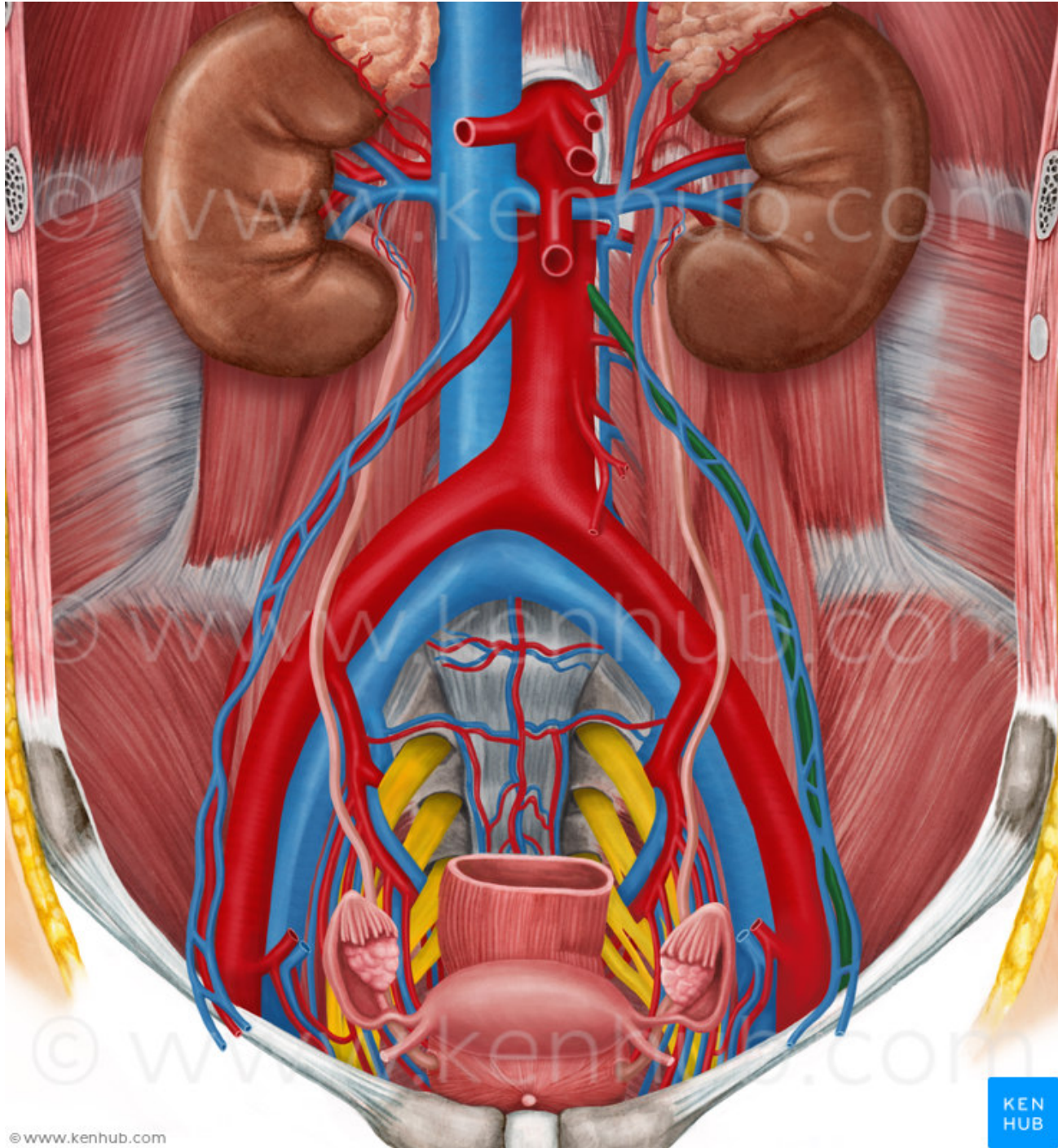
- aa. testiculares

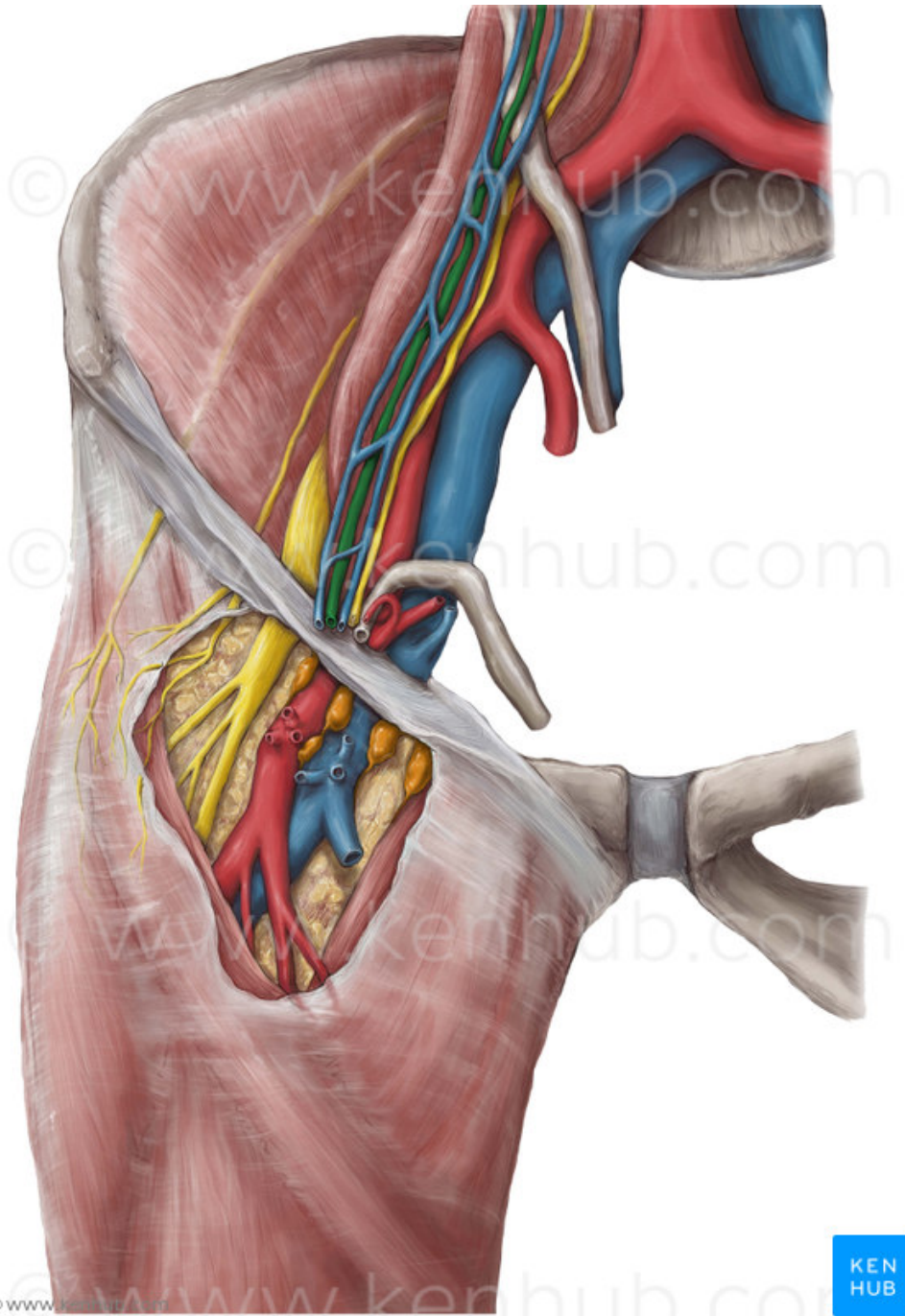
- aa. ovaricae









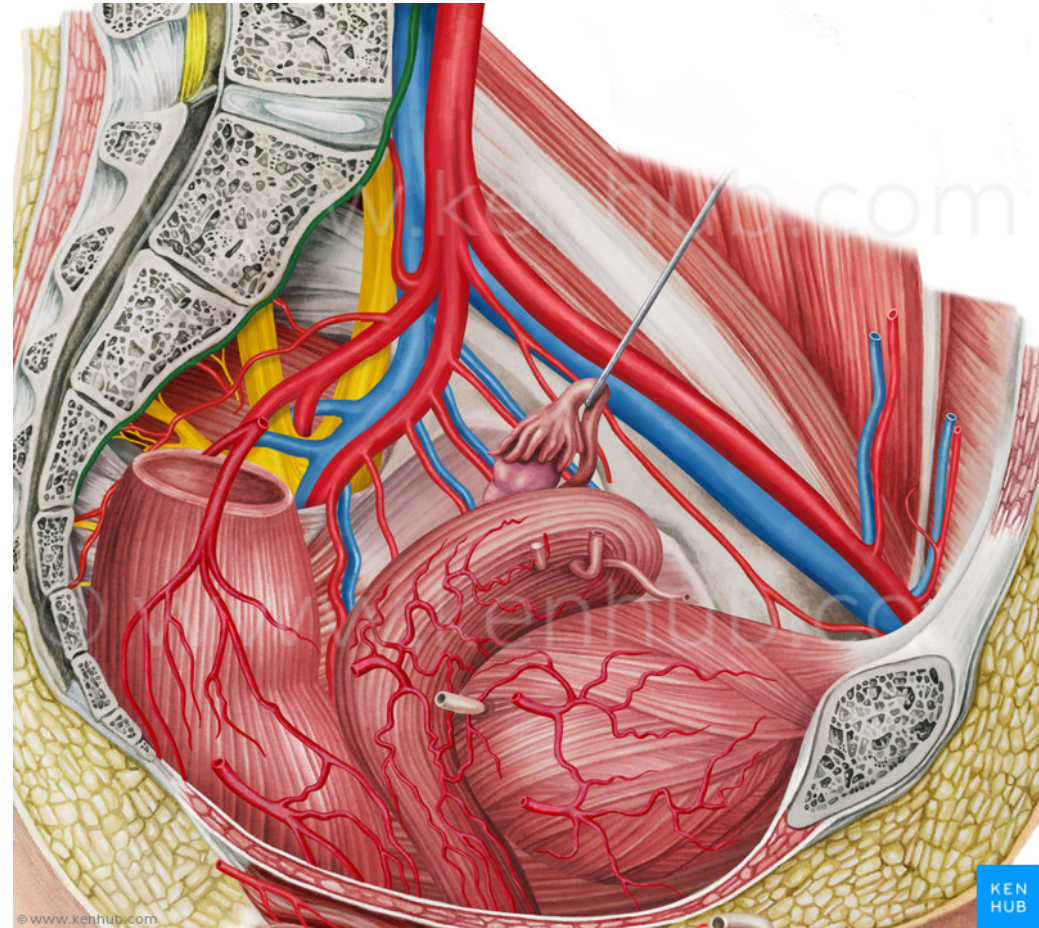
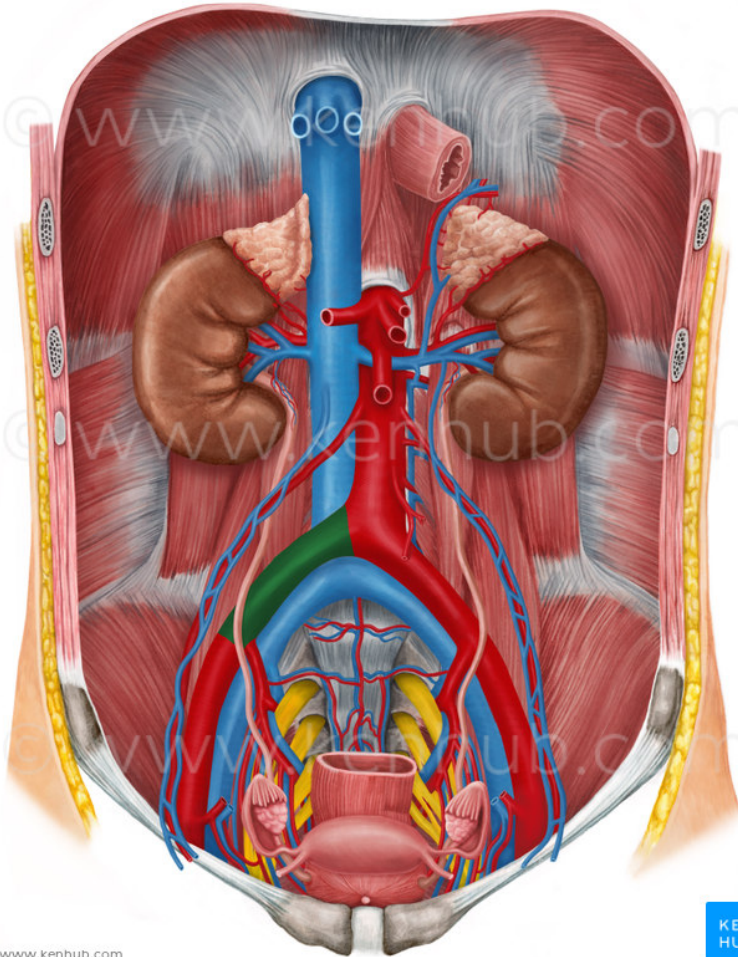


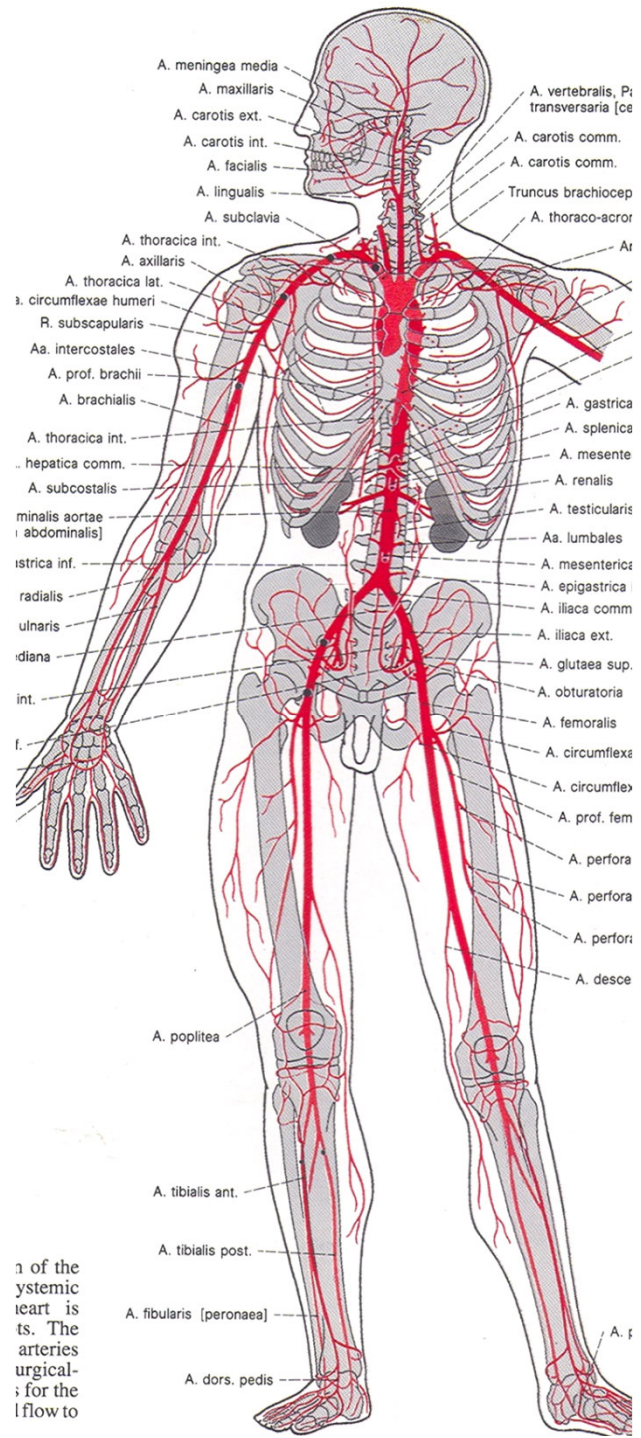


- **konečné:**

- **a. sacralis mediana**

- **aa. iliacae communes**





1 of the  
 systemic  
 heart is  
 ts. The  
 arteries  
 urgical-  
 ; for the  
 l flow to



## Aa. iliacae communes

- L<sub>4</sub> bifurcatio aortae
- art. iliaca communis (dělí se na a. iliaca int. a ext. )

### A. iliaca interna

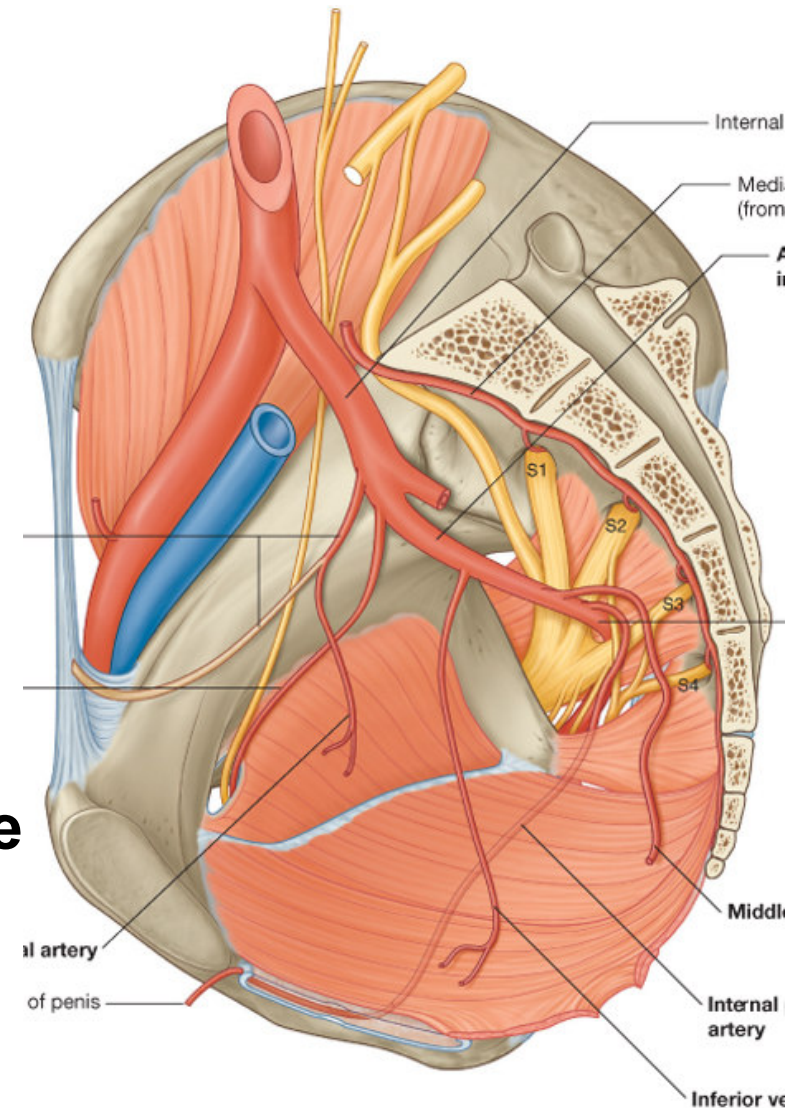
– zásobuje orgány a stěnu malé pánve

#### Větve parietální:

- svalové větve pro hýžd'ové svalstvo (a. glutea superior et inferior), stěna malé pánve (a. iliolumbalis, a. sacralis lateralis), pro adduktory stehna (a. obturatoria), pohl. orgány (a. pudenda interna)

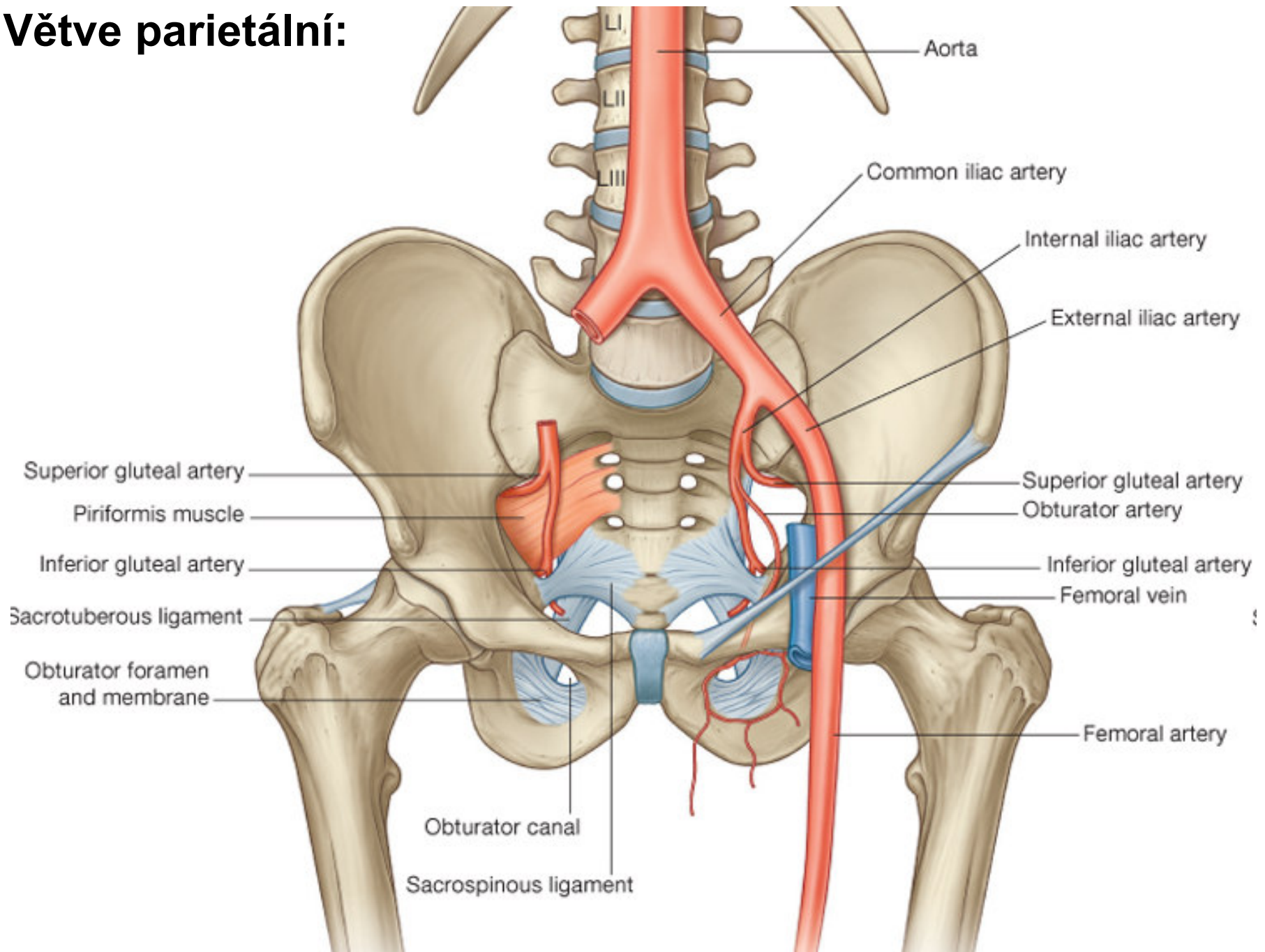
#### Větve viscerální:

- a. umbilicalis (obliteruje a mění se v lig. umbilicale lat.)
- k močovému měchýři (a. vesicalis inf.)
- k ductus deferens (resp. k děloze) – a. ductus deferentis, a. uterina
- ke konečníku (a. rectalis media)

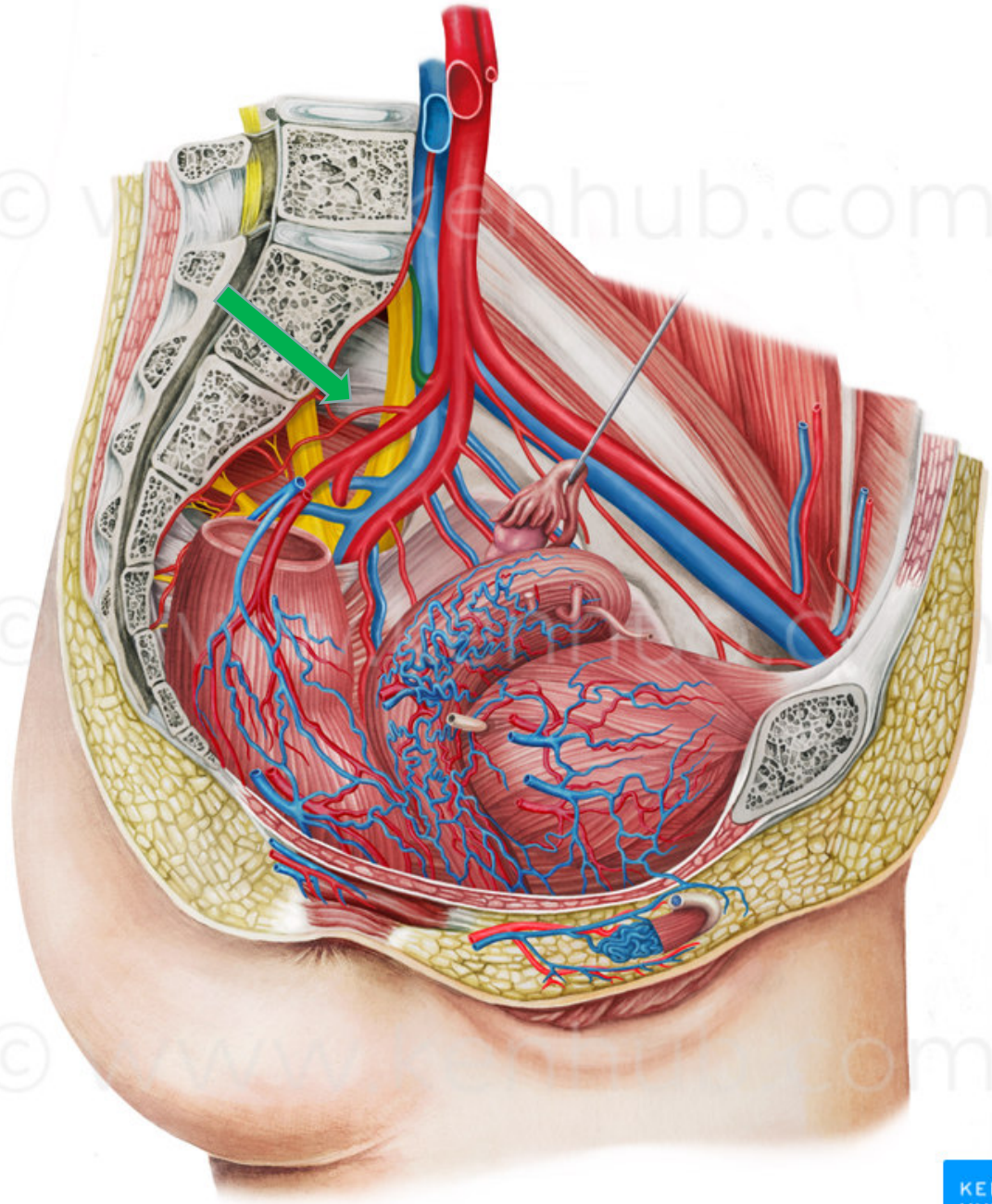


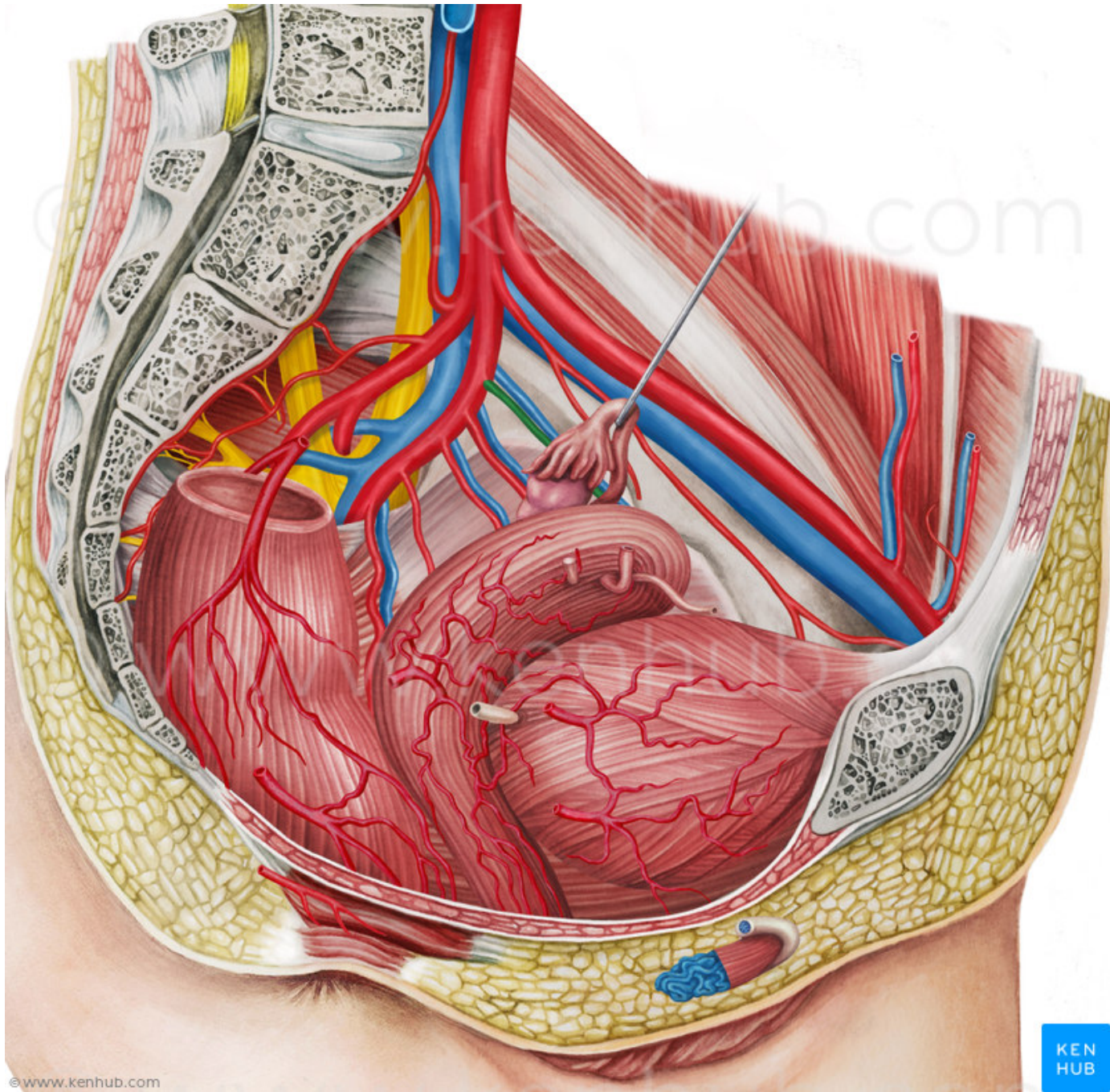
Drake: Gray's Anatomy for Students, 2nd Edition.  
Copyright © 2009 by Churchill Livingstone, an imprint of Elsevier, Inc. All rights reserved.

# Větve parietální:

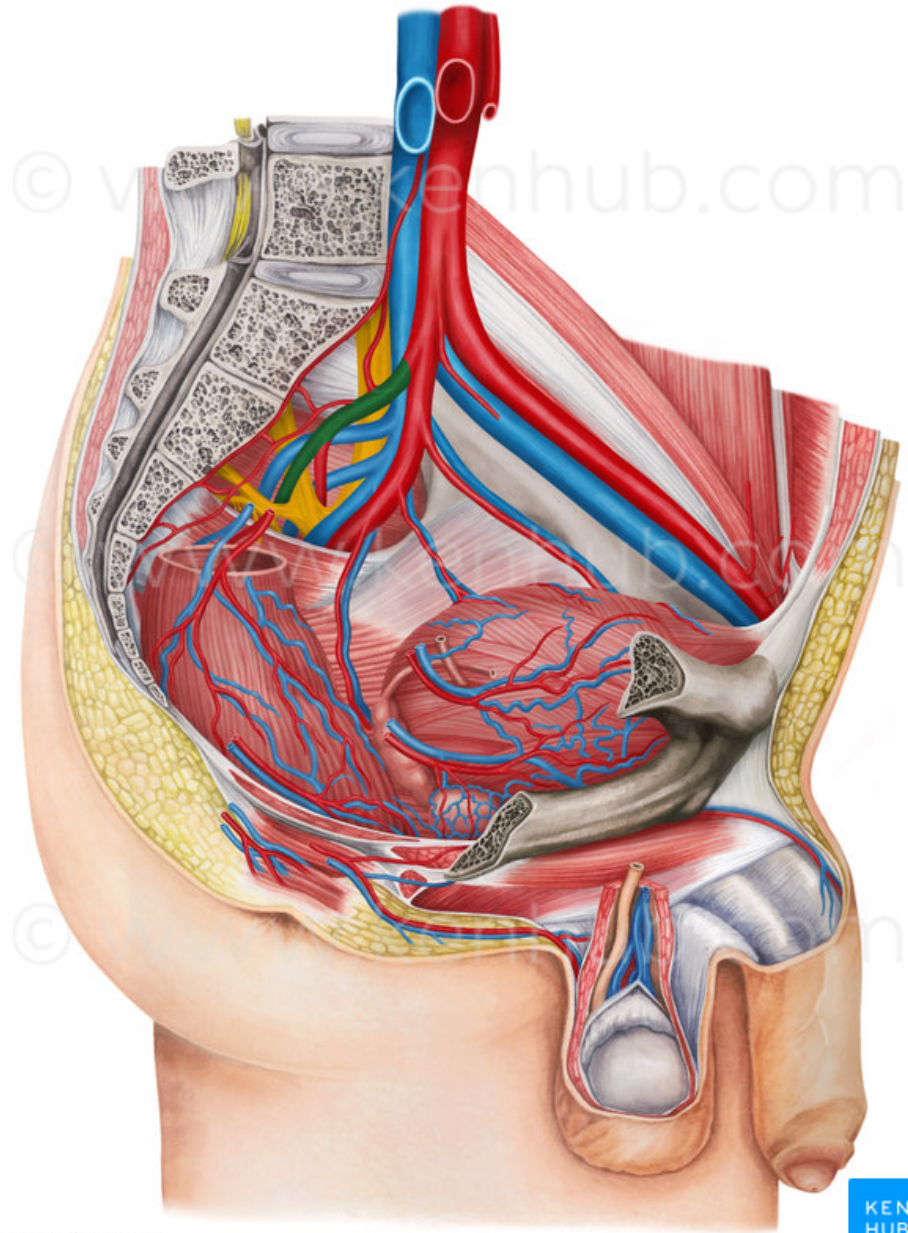






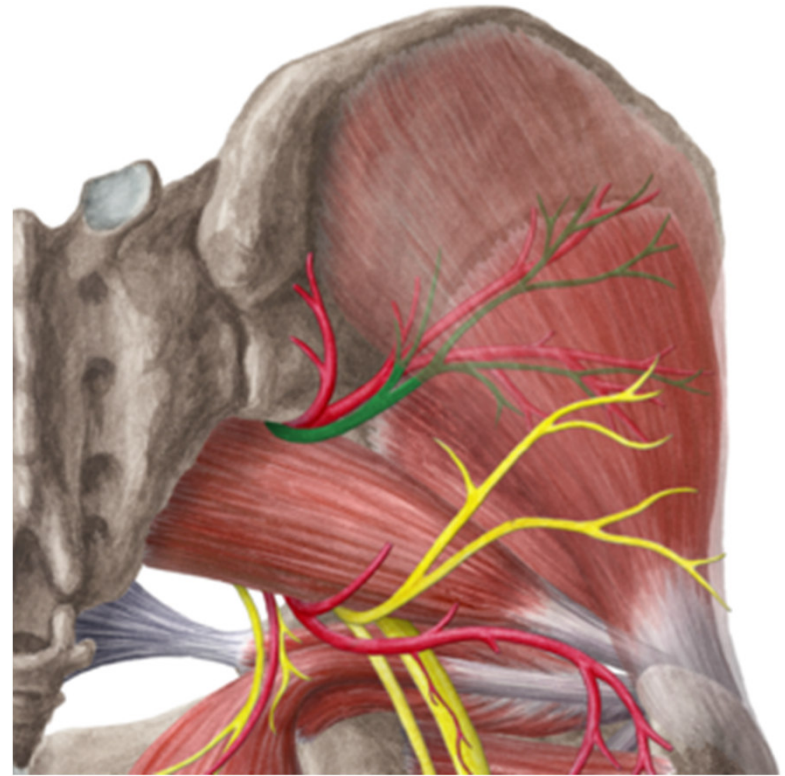


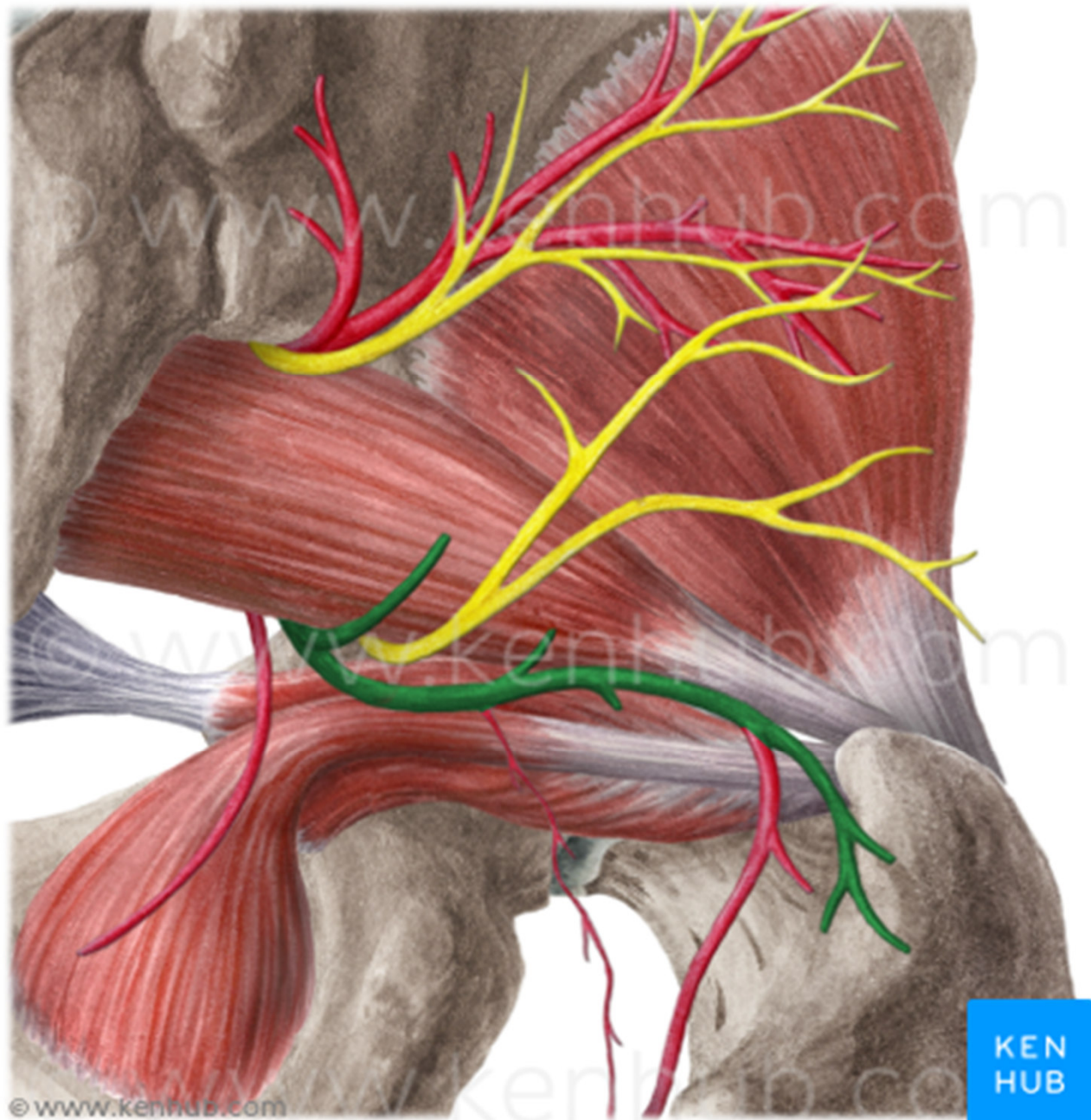




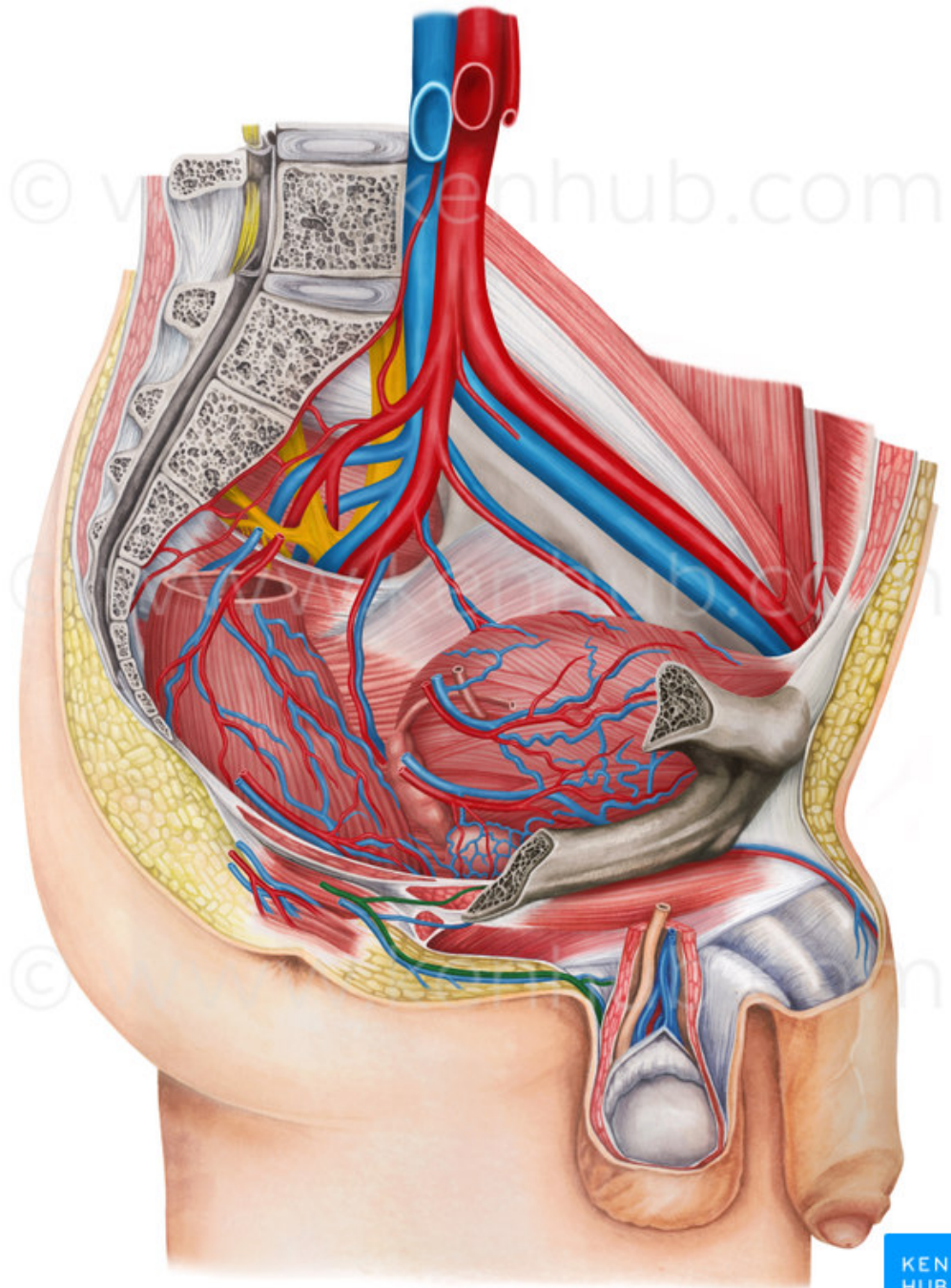
© www.kenhub.com

KEN  
HUB

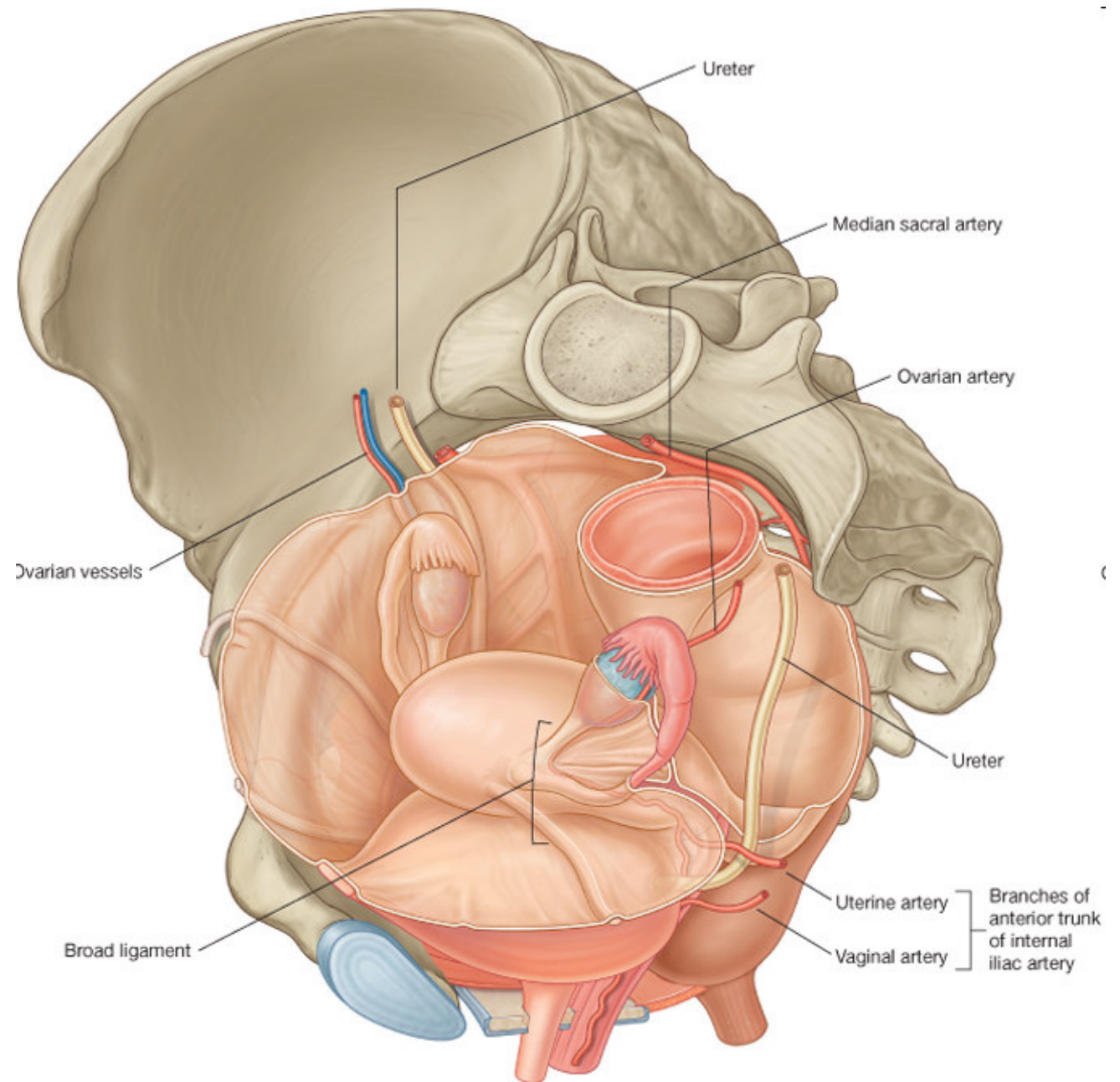




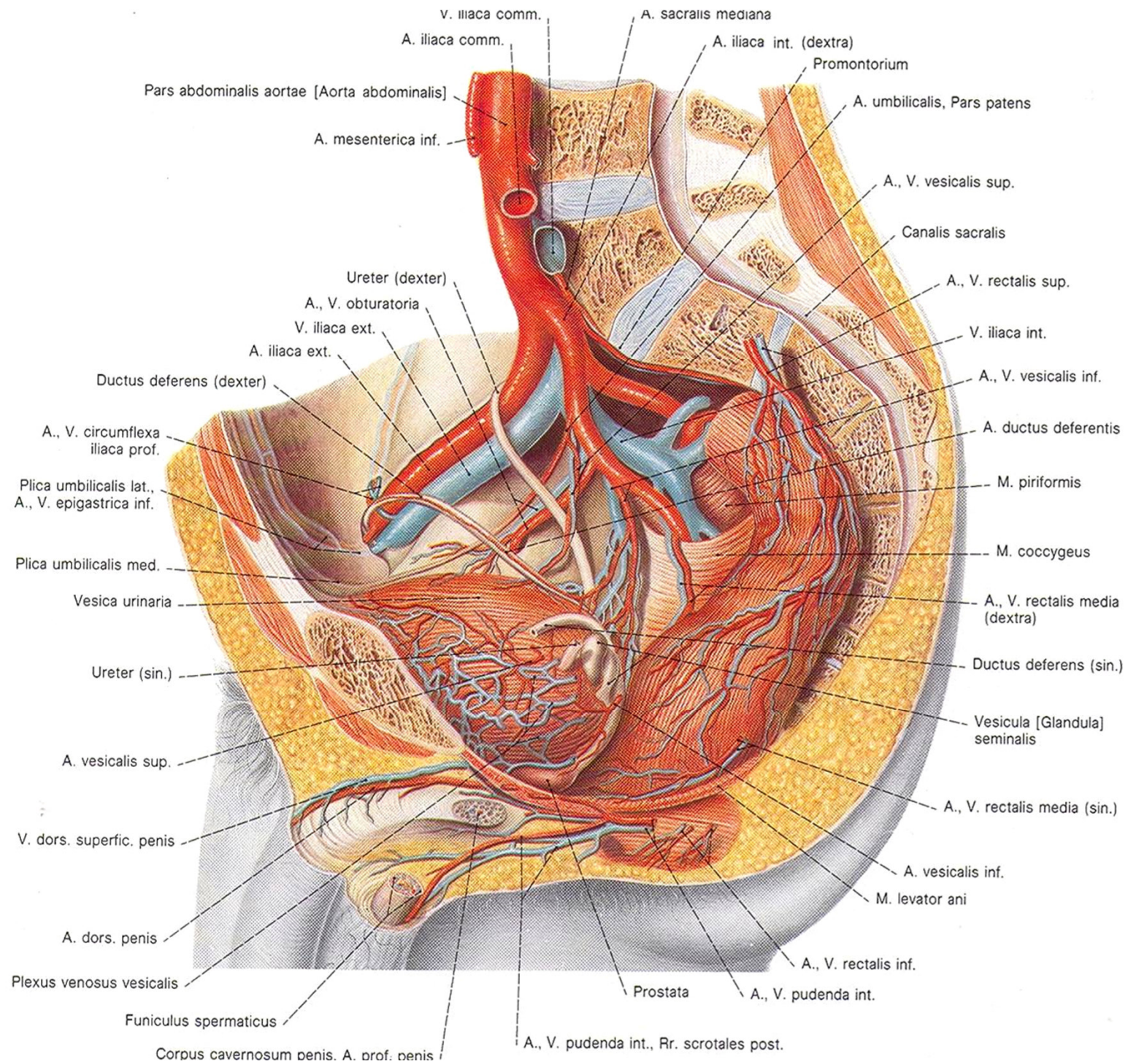




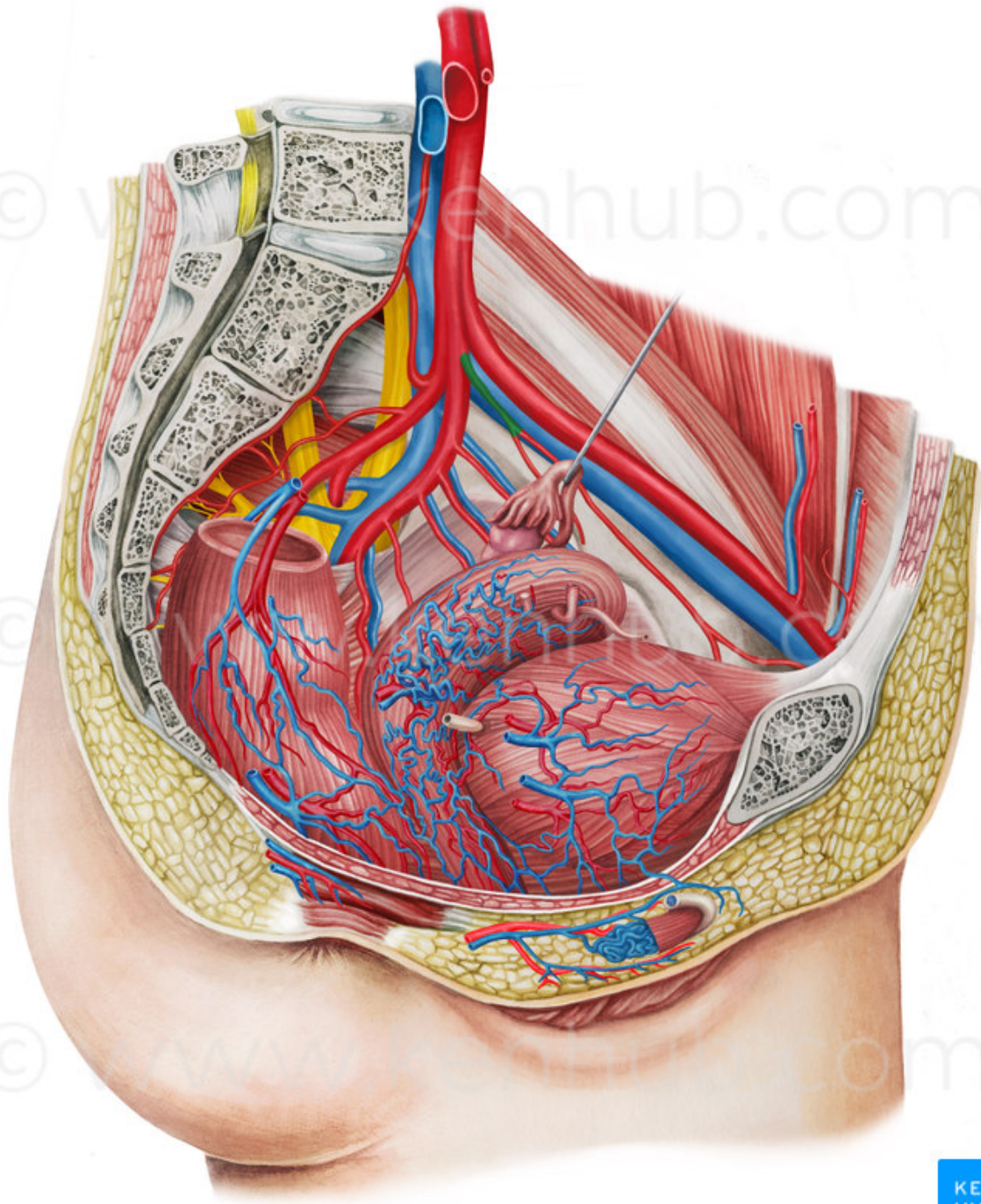
# Větve viscerální:





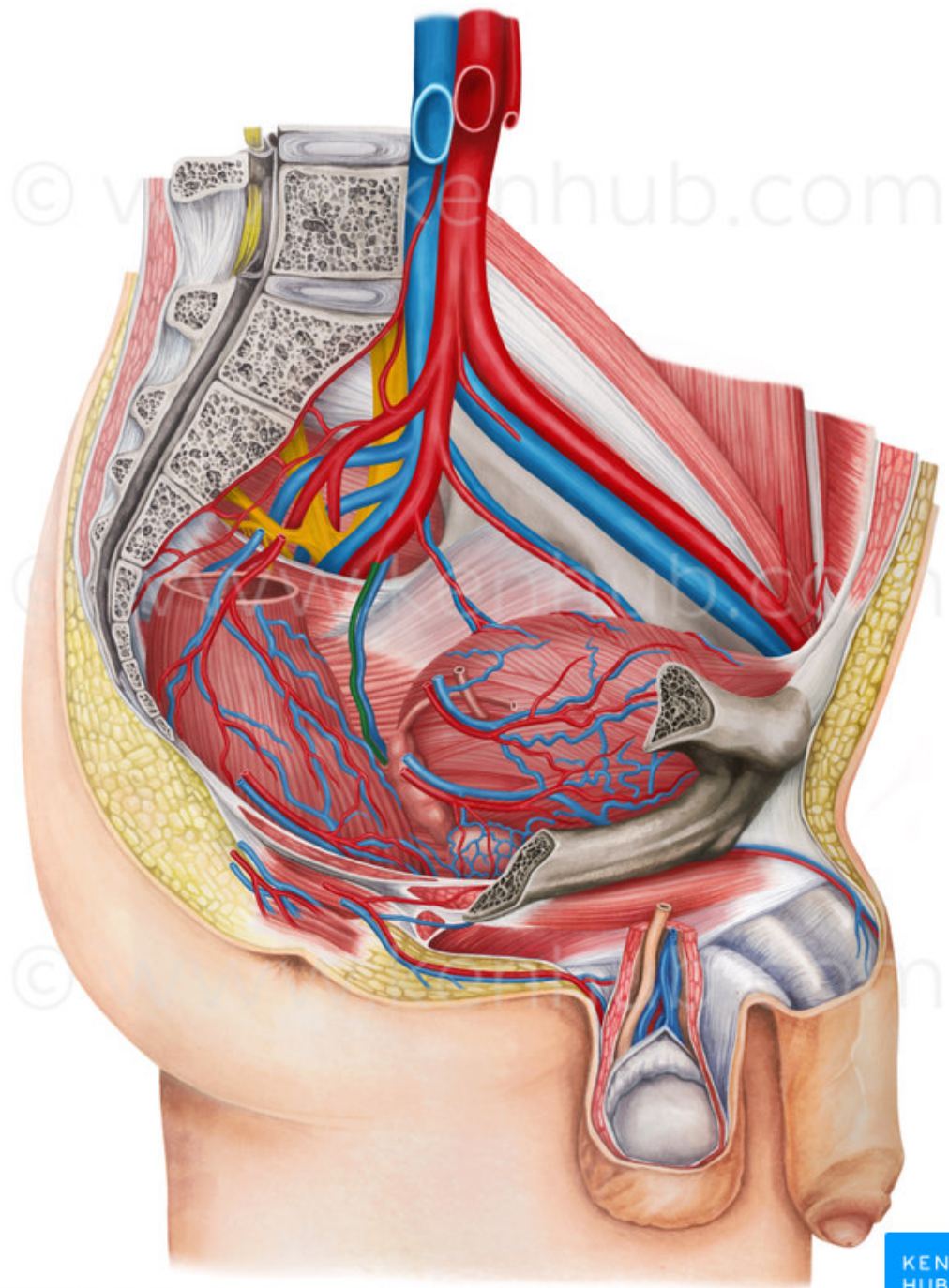








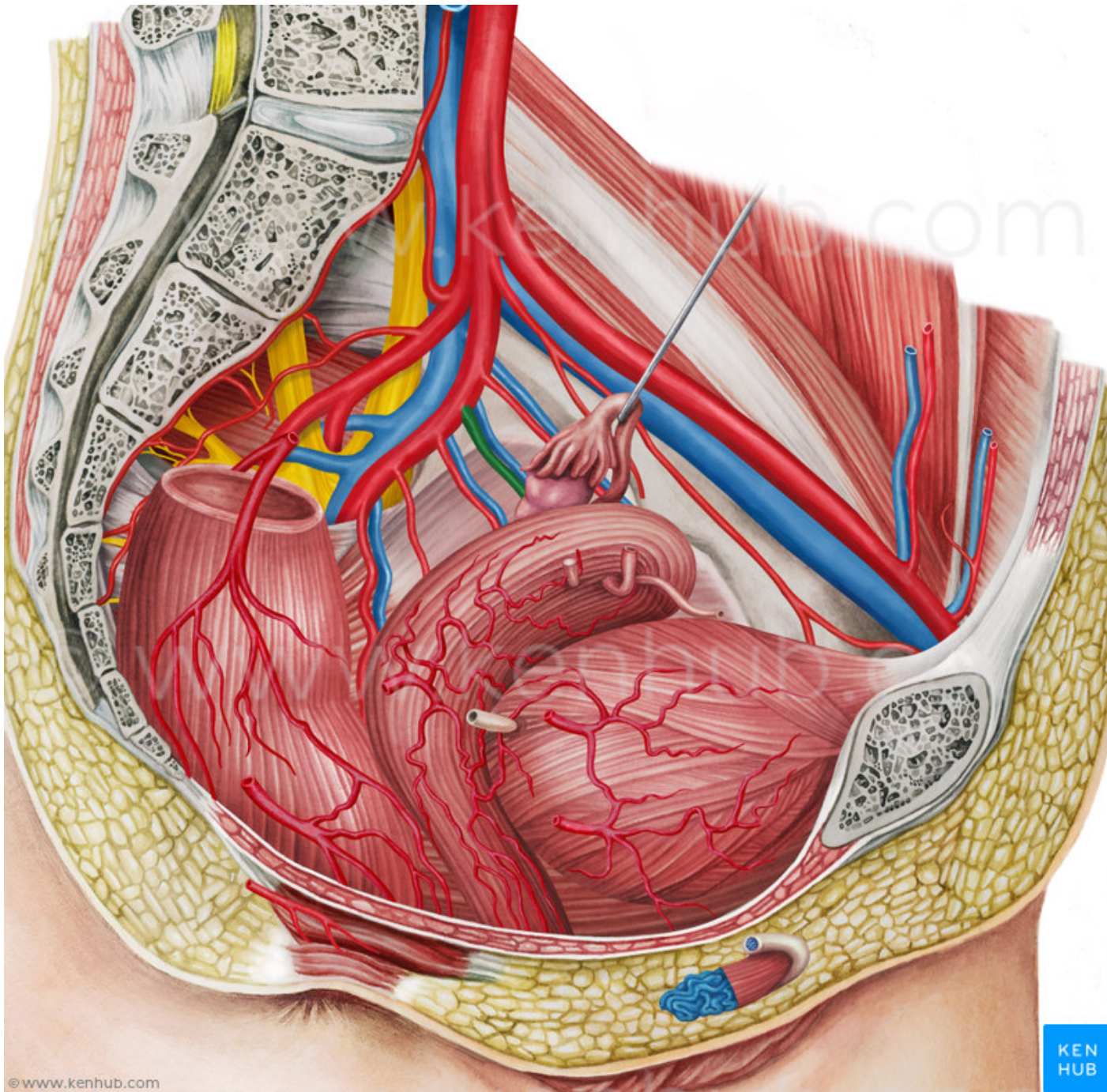




© www.kenhub.com

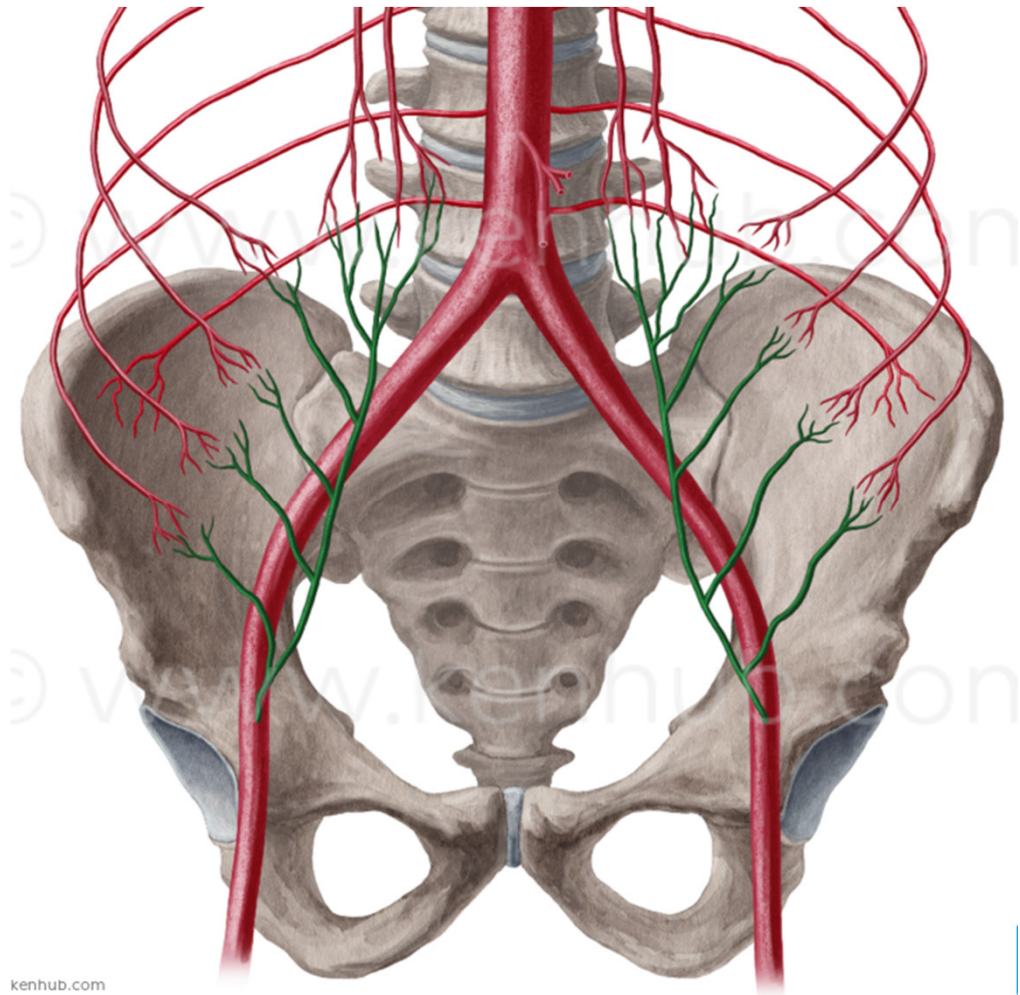
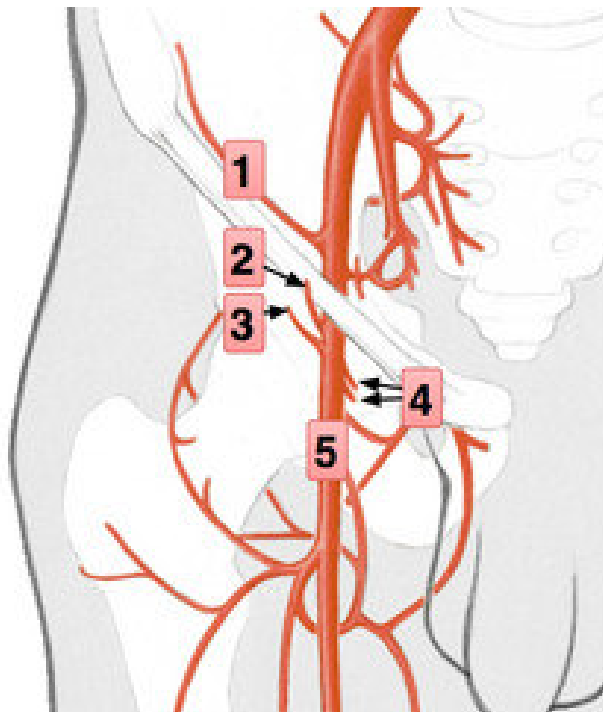
© www.kenhub.com



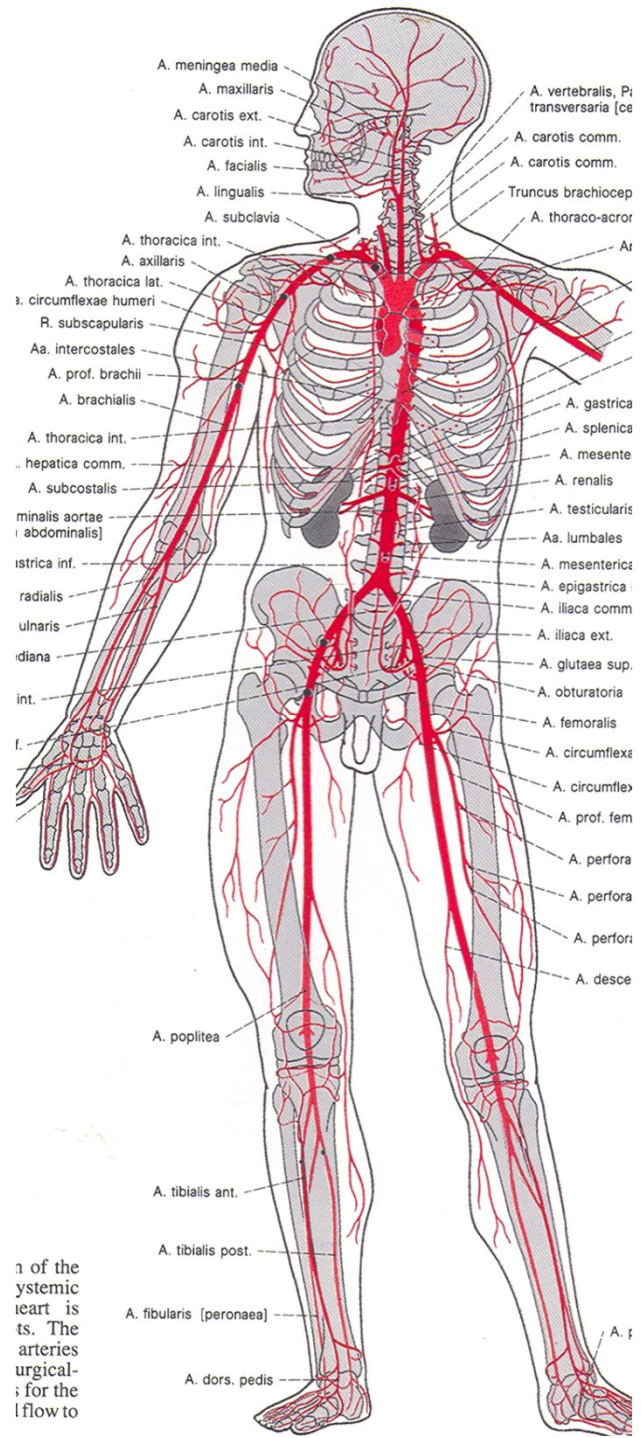


# A. iliaca externa

- silnější
- a. epigastrica inferior (svaly břišní stěny, stěna velké pánve)
- a. circumflexa ilium profunda

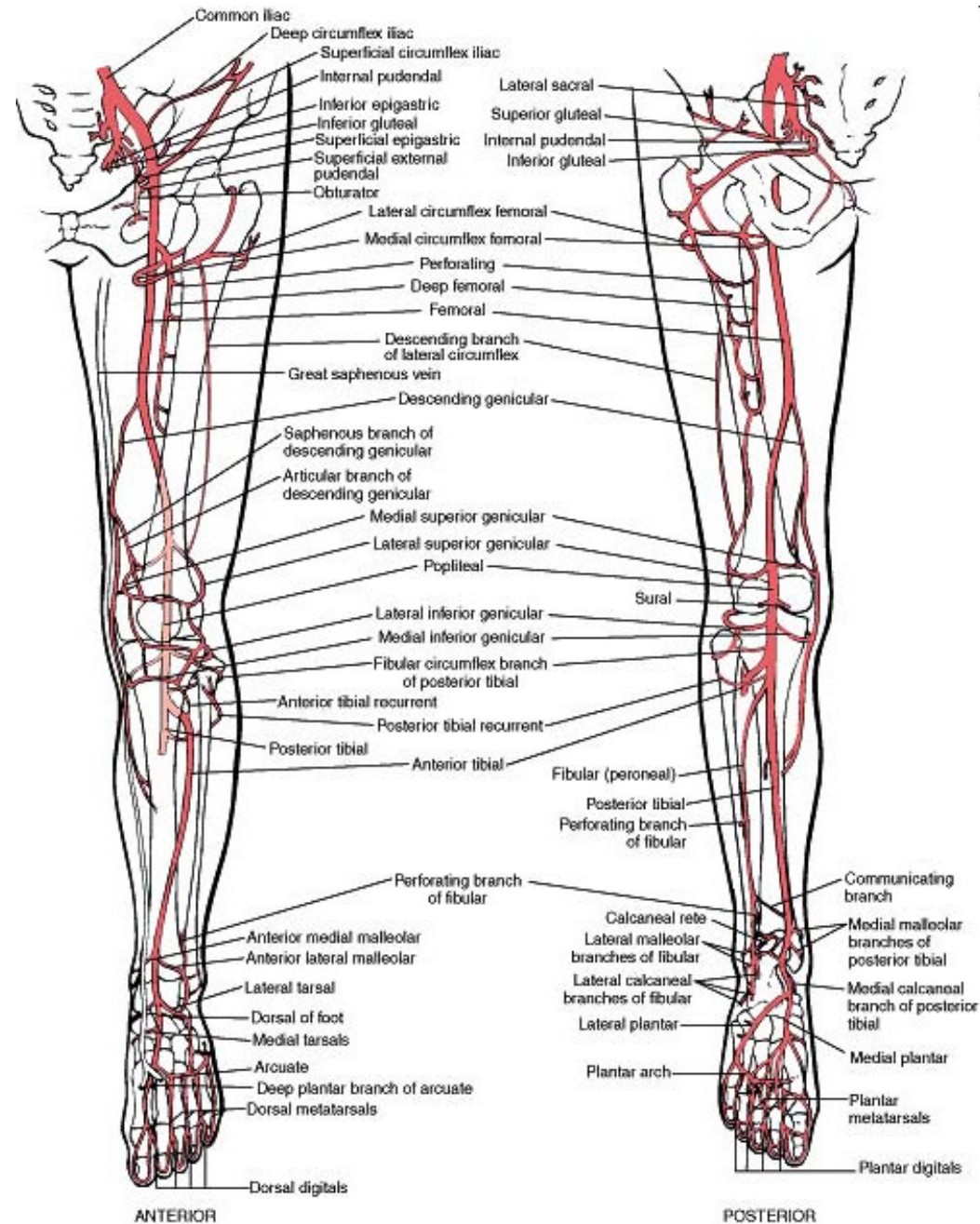






1 of the  
 systemic  
 heart is  
 ts. The  
 arteries  
 urgical-  
 ; for the  
 lflow to

# Aa. membri inferioris



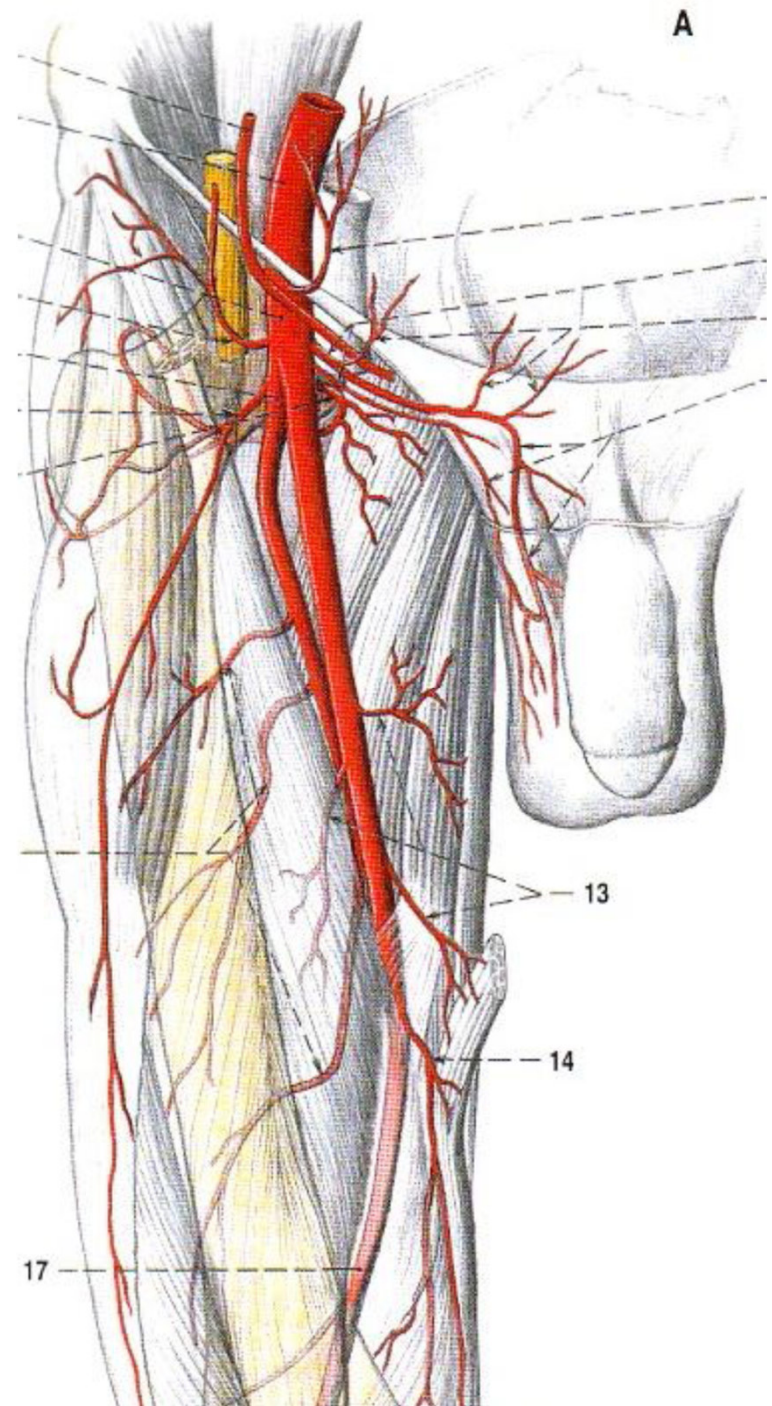


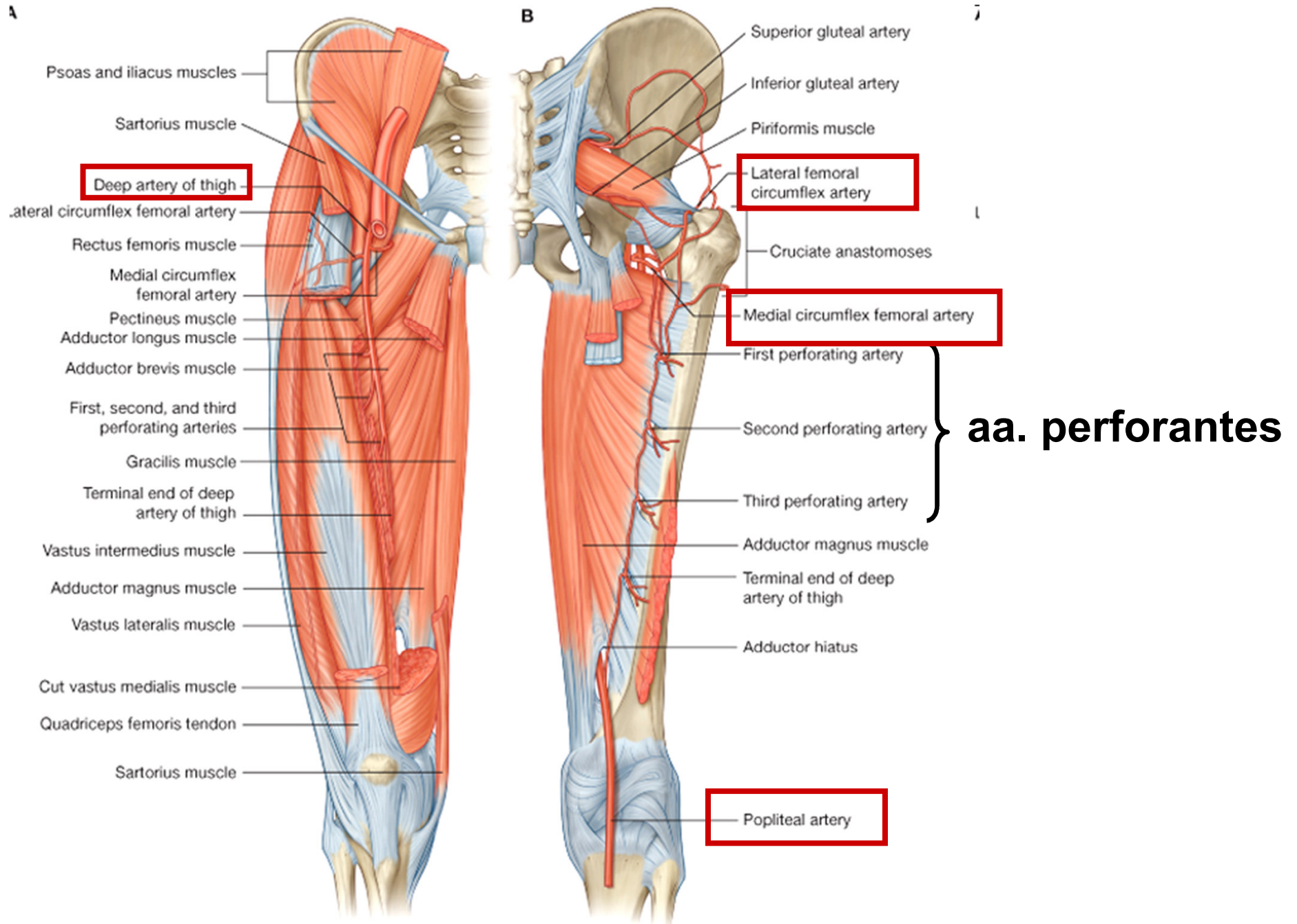
## A. femoralis

- od lacuna vasorum po fossa poplitea, přes fossa iliopectinea a canalis adductorius

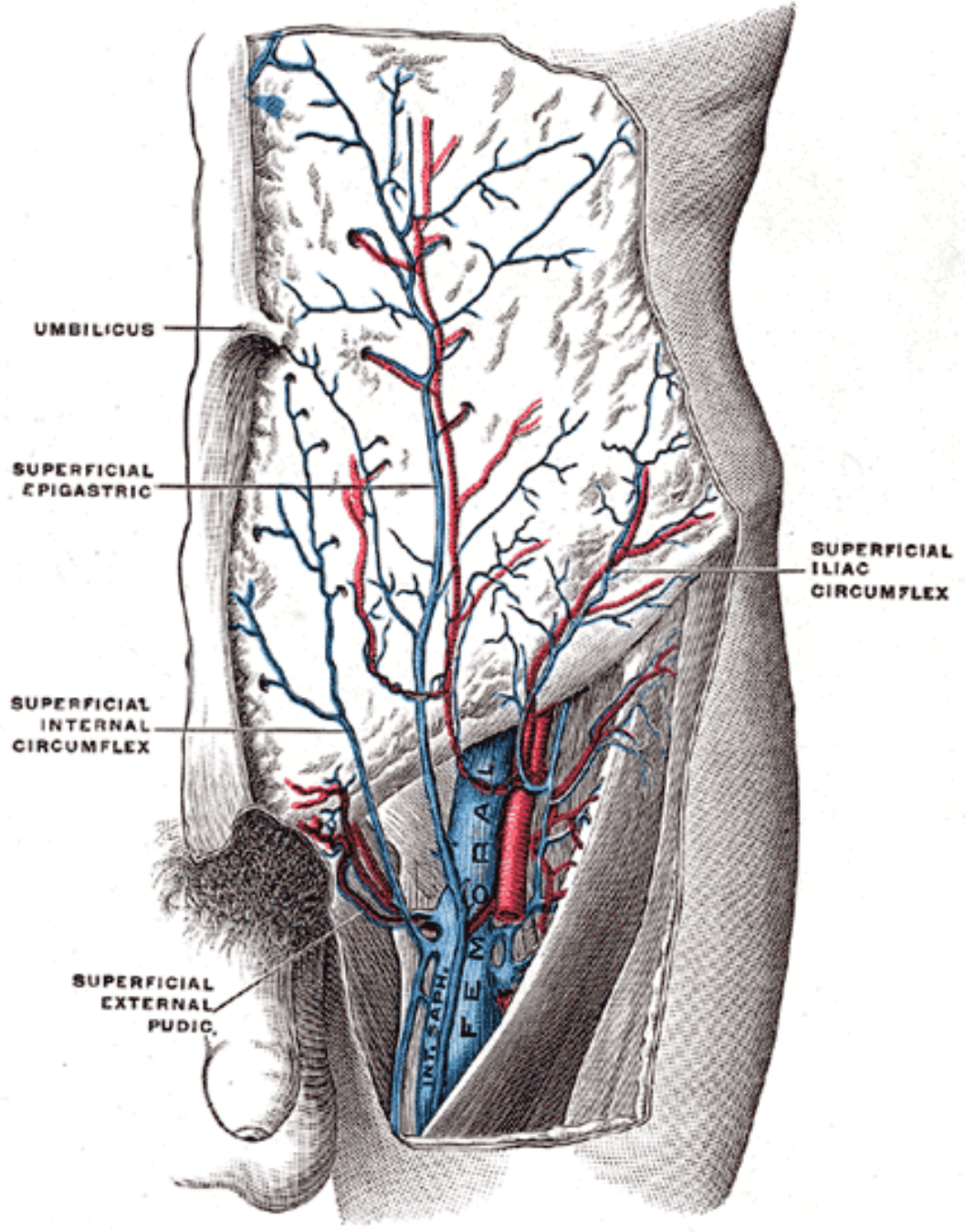
větve:

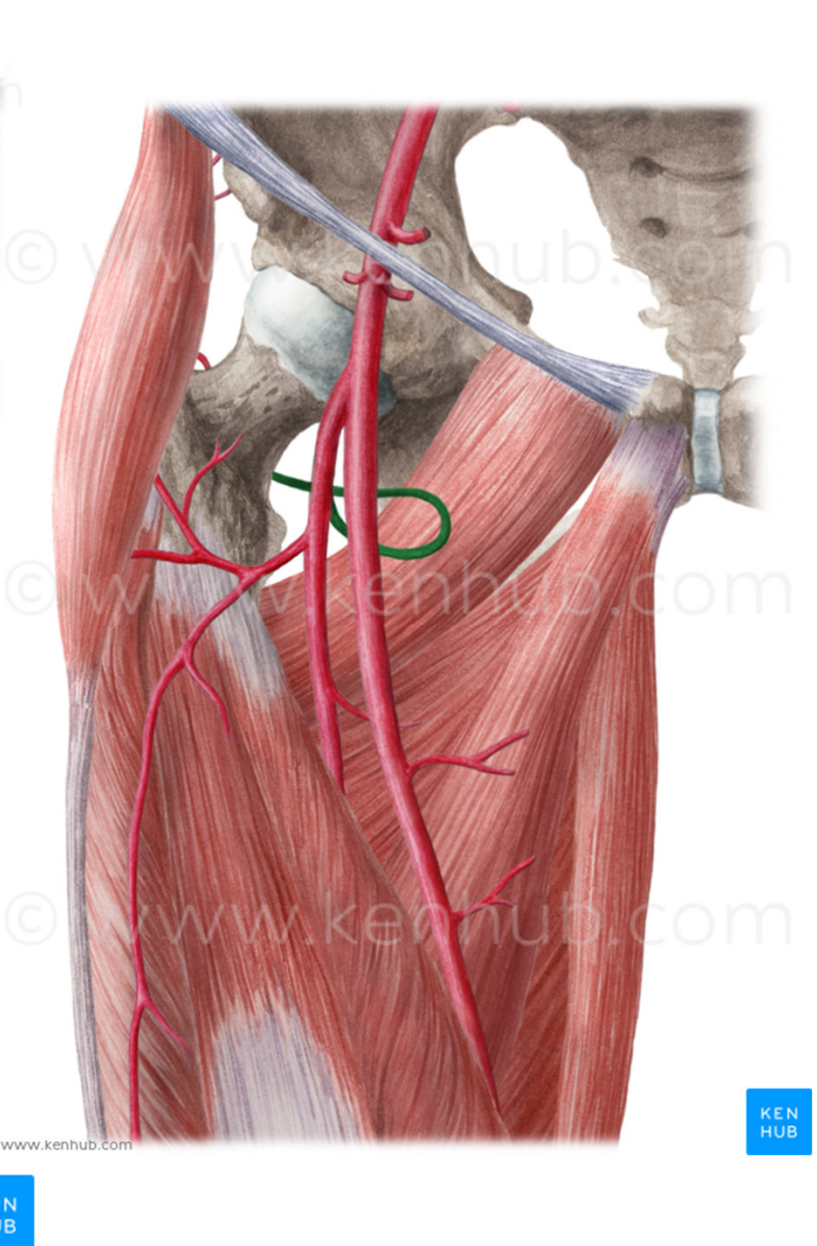
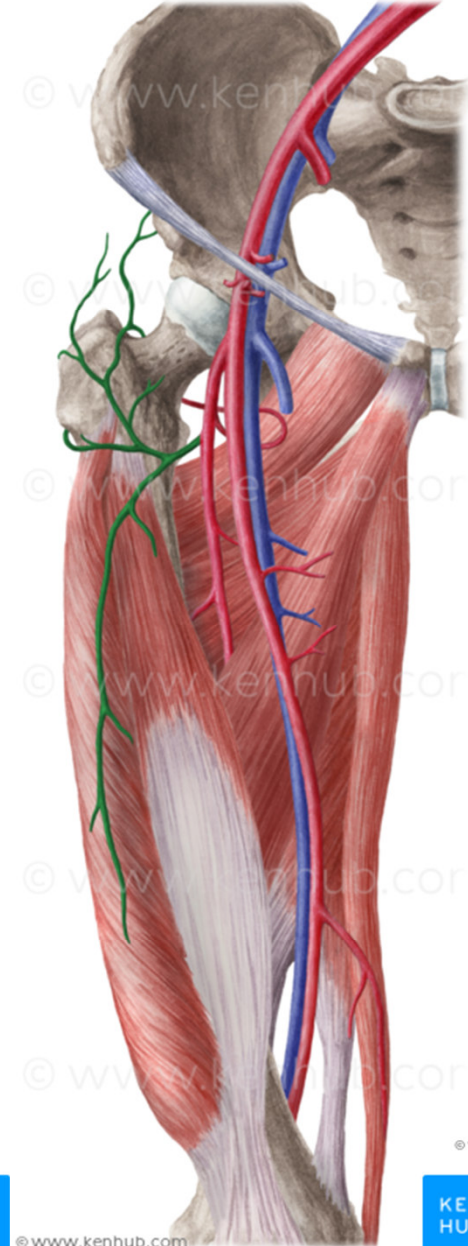
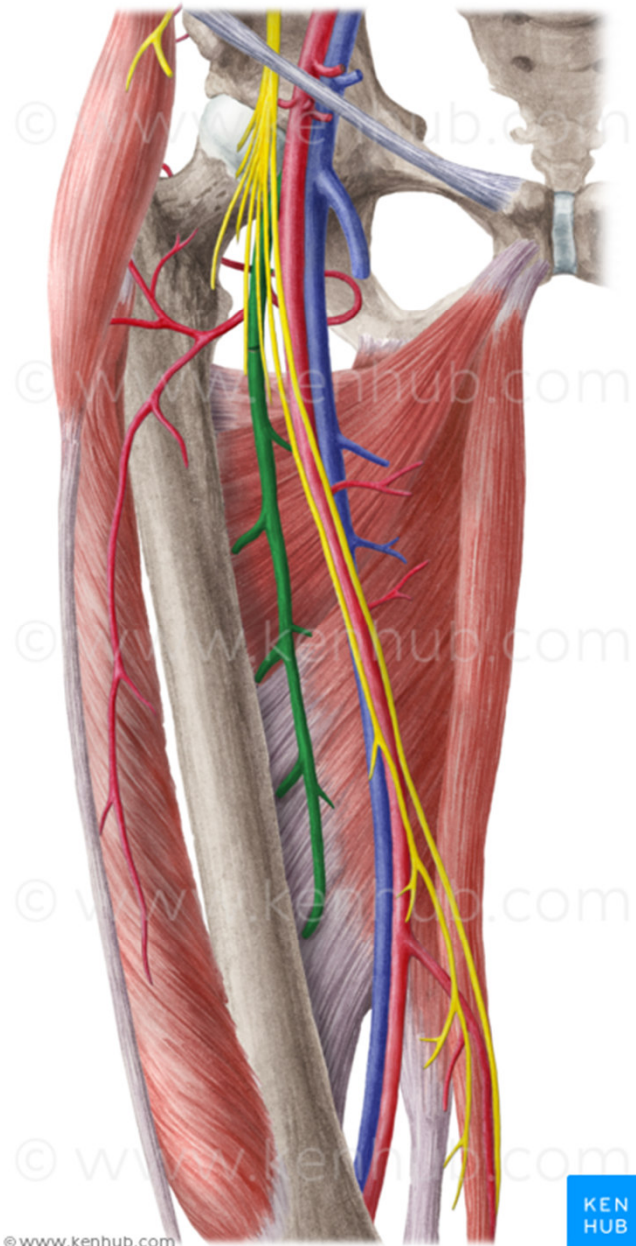
- 1) k zevním pohlavním orgánům a břišní stěně: a. epigastrica superficialis, a. circumflexa ilium superficialis, aa. pudendae externae
- 2) **a. profunda femoris**: hlavní tepna pro svaly stehna (a. circumflexa femoris med. a lat., aa. perforantes)
- 3) svalové větve (svaly stehna)
- 4) **a. genus descendens**: do rete articulare genus (r. saphenus)



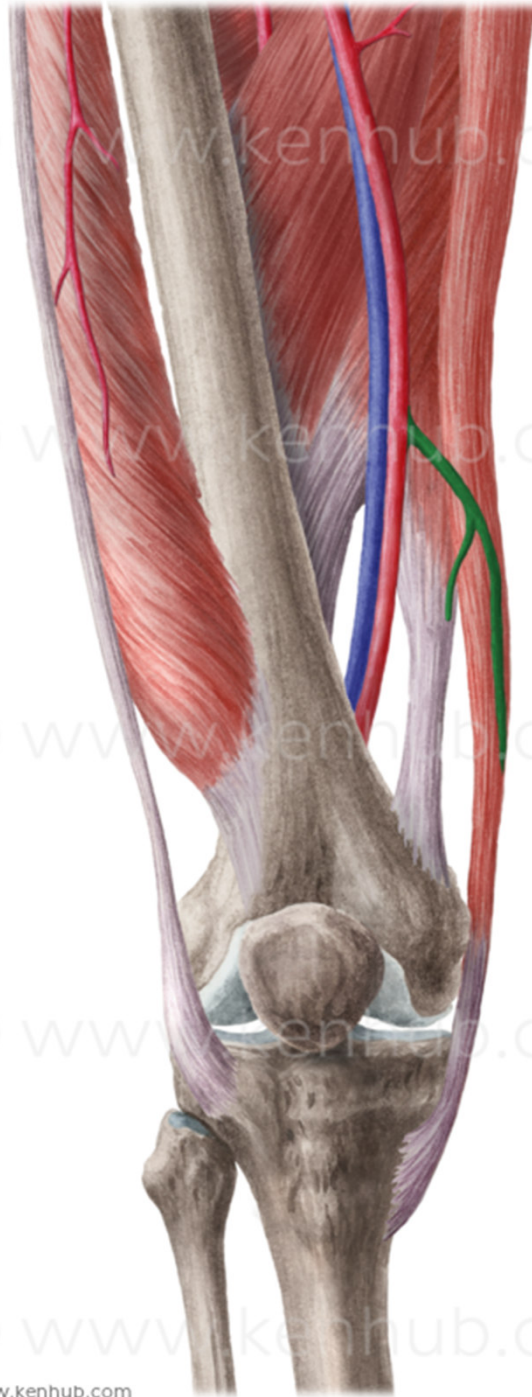












© www.kenhub.com

© www.kenhub.com

© www.kenhub.com

© www.kenhub.com

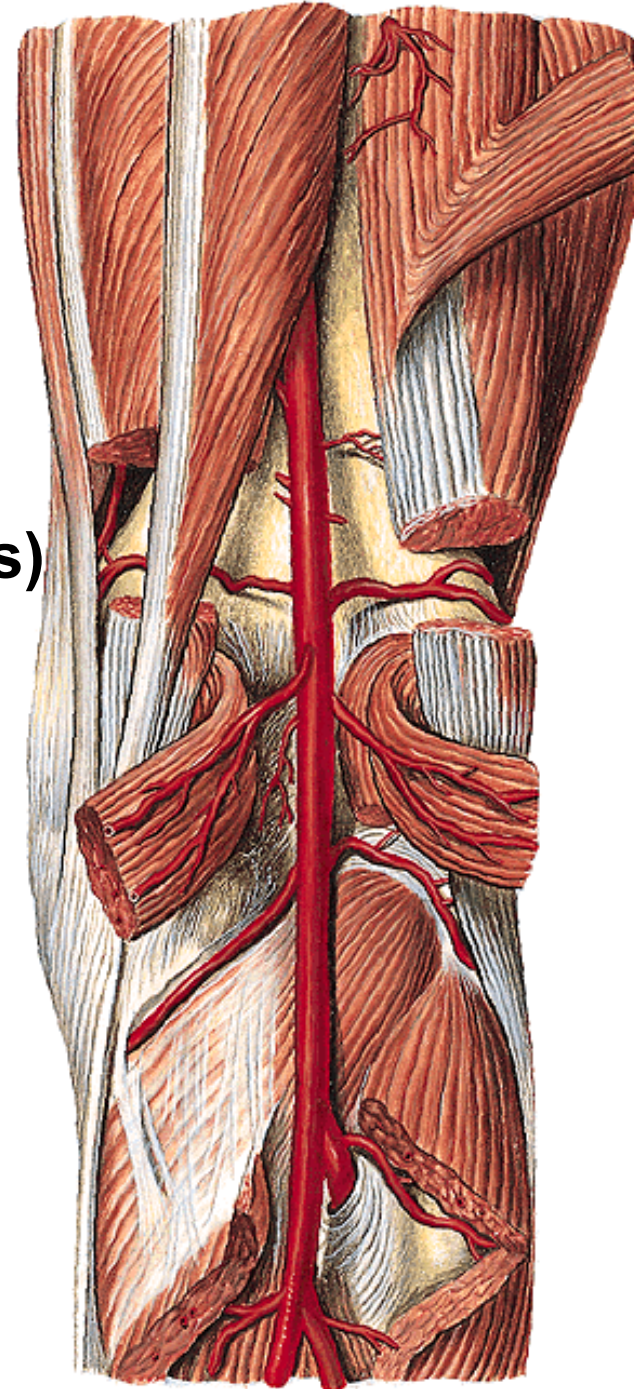
© www.kenhub.com

## A. poplitea

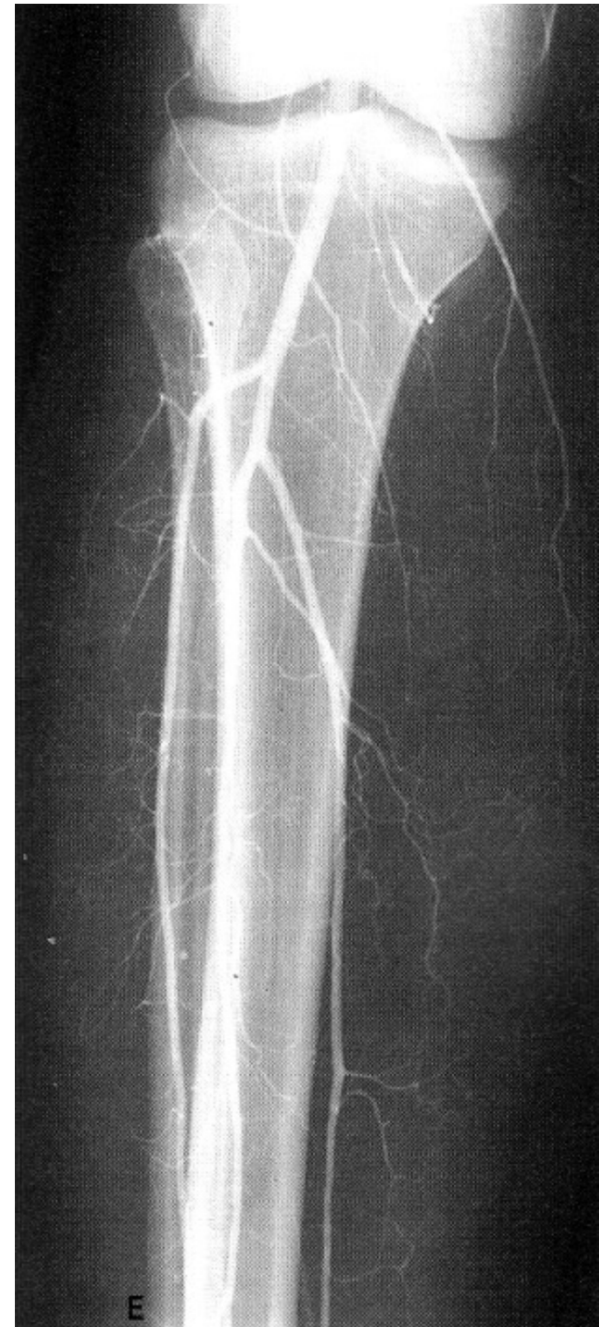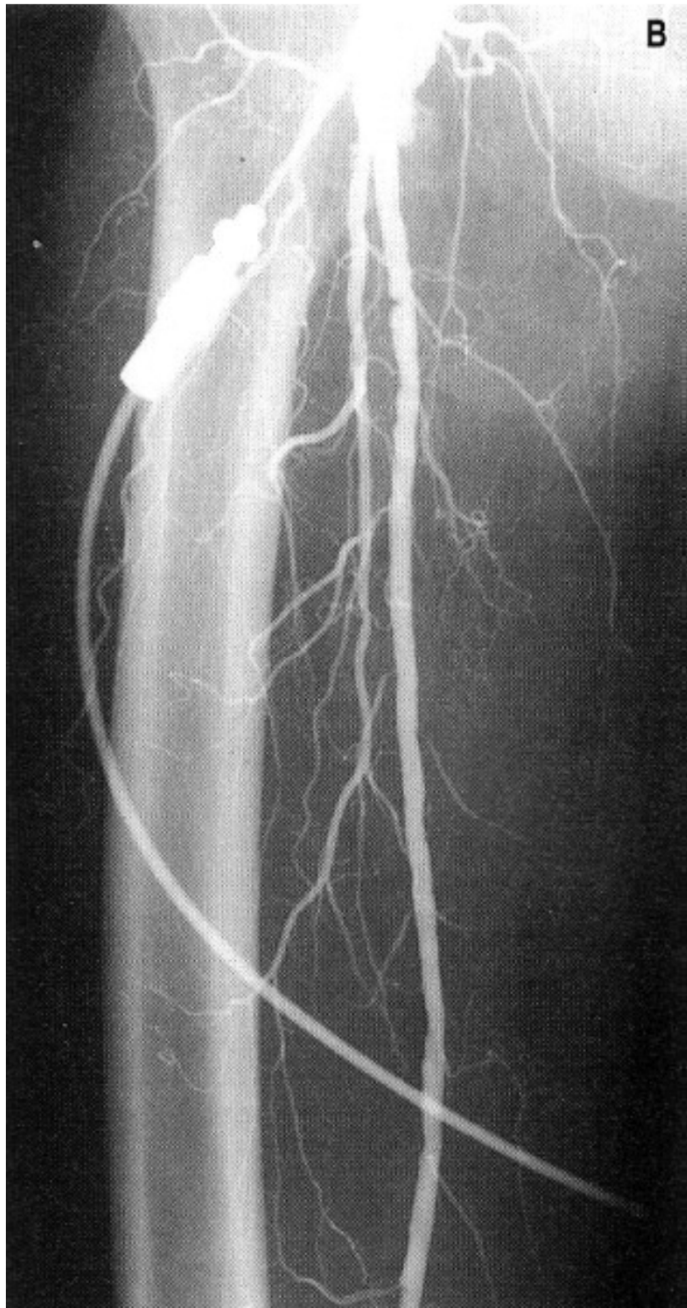
- od hiatus tendineus k distálnímu okraji m. popliteus
- svaly zákolenní jamky a kolenní kloub

### Větve:

- 1) aa. surales (pro hlavy m. gastrocnemius)
- 2) aa. genus - do tepenné sítě kolem kolenního kloubu
- 3) konečné větve:
  - a. tibialis anterior
  - a. tibialis posterior

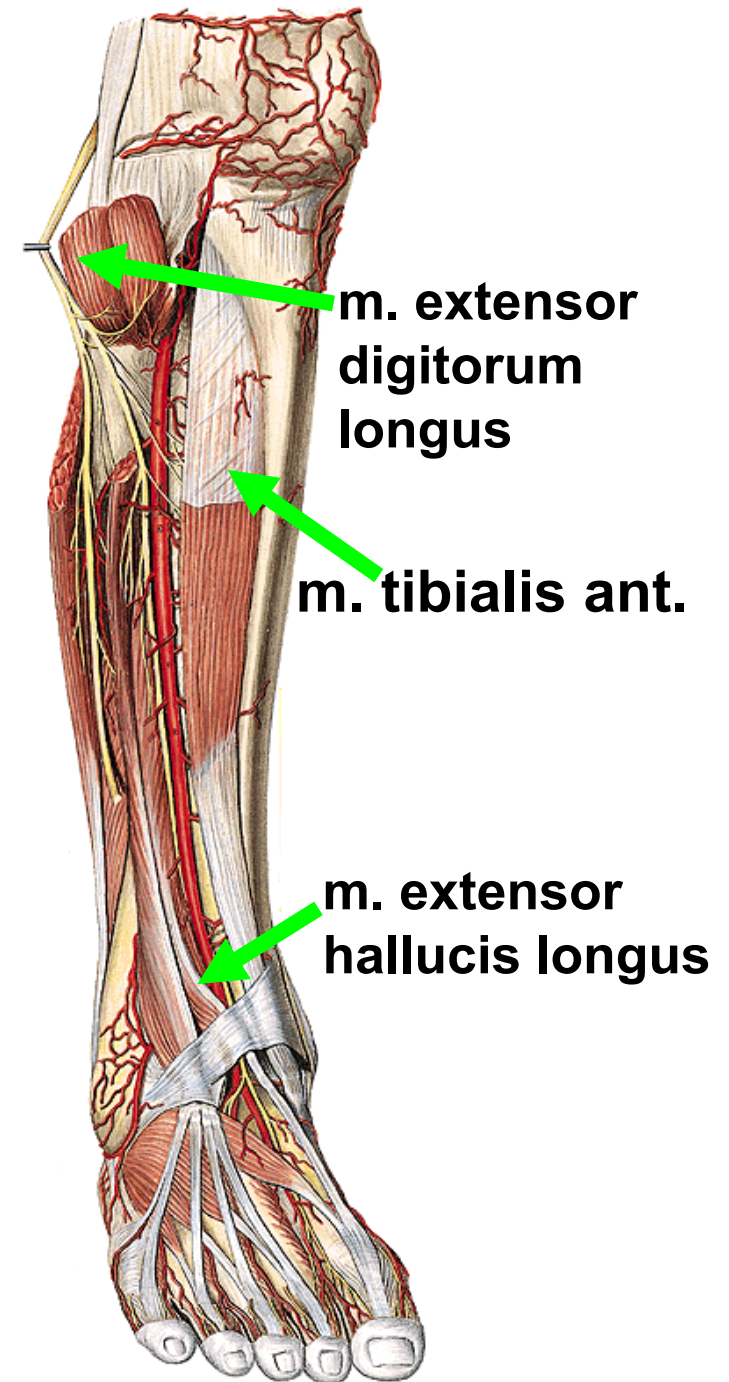




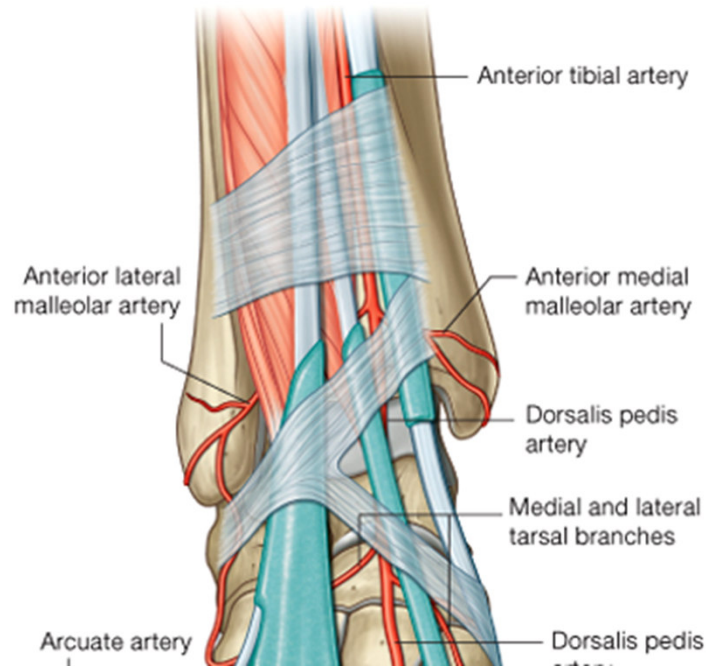


## A. tibialis anterior

- nad membrana interossea cruris (nebo proráží skrz)
- proximálně mezi m. tibialis ant. a m. extensor digitorum longus
- distálně mezi m. tibialis ant. a m. extensor hallucis longus – pod retinaculum extensorum
- od prostupu pod retinaculum extensorum – **a. dorsalis pedis**



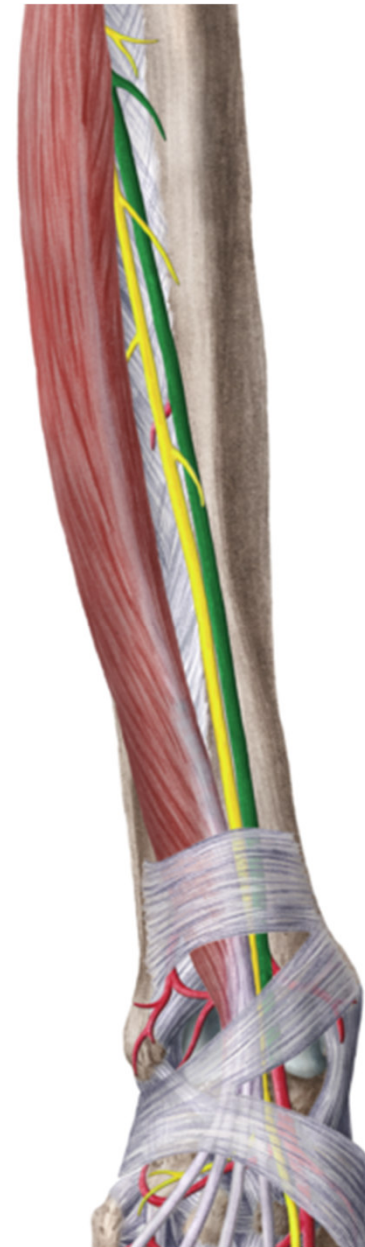




- zásobuje kolenní kloub, přední stranu bérce, hřbet nohy a prstů

větve:

- 1) do tepenné sítě kolenního kloubu
- 2) svalové
- 3) do tepenné sítě kolem obou kotníků
- 4) a. dorsalis pedis



**Větve z a. dorsalis pedis:**

**a. tarsalis lateralis**

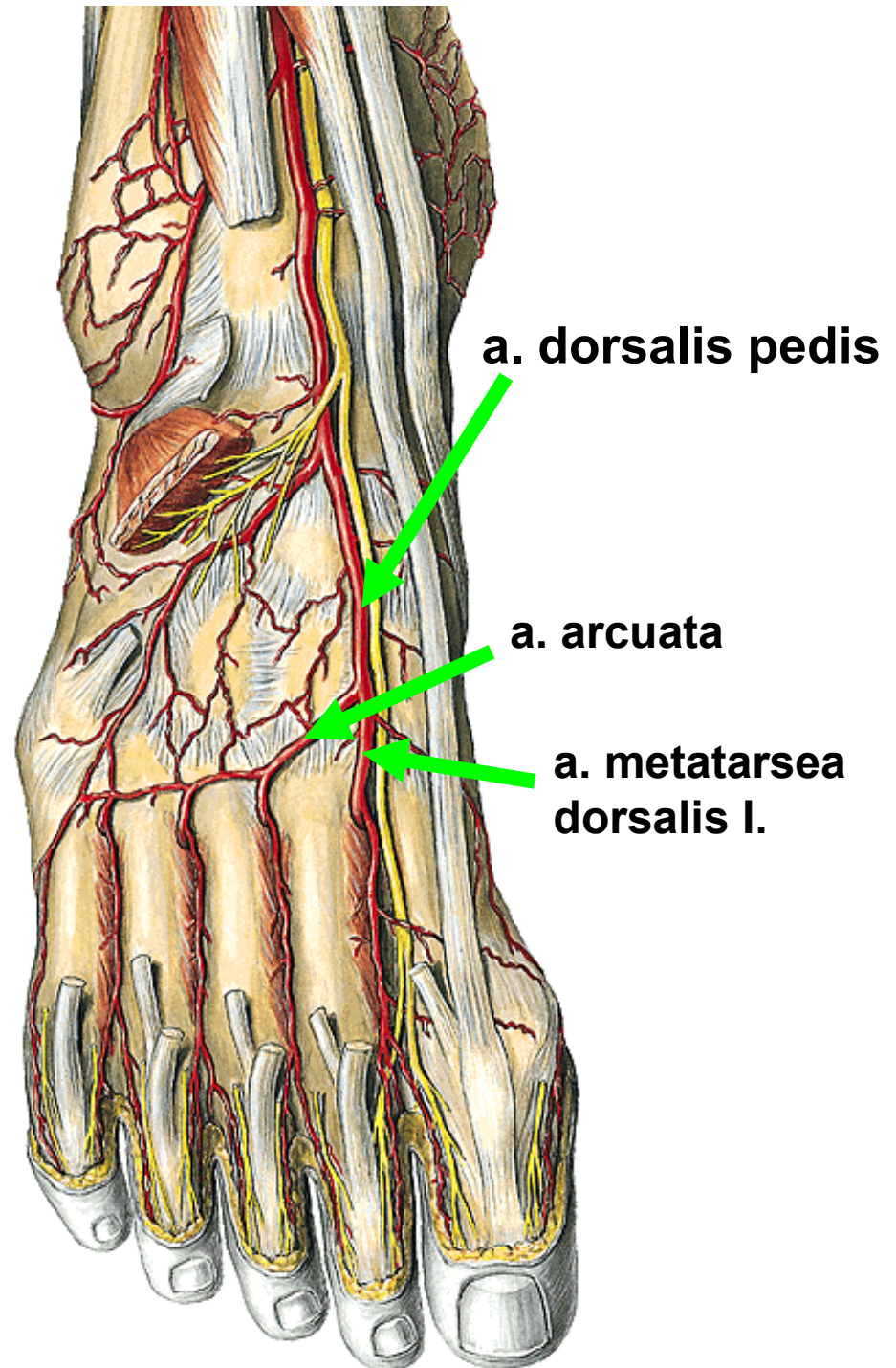
**aa. tarsales mediales**

**a. arcuata**

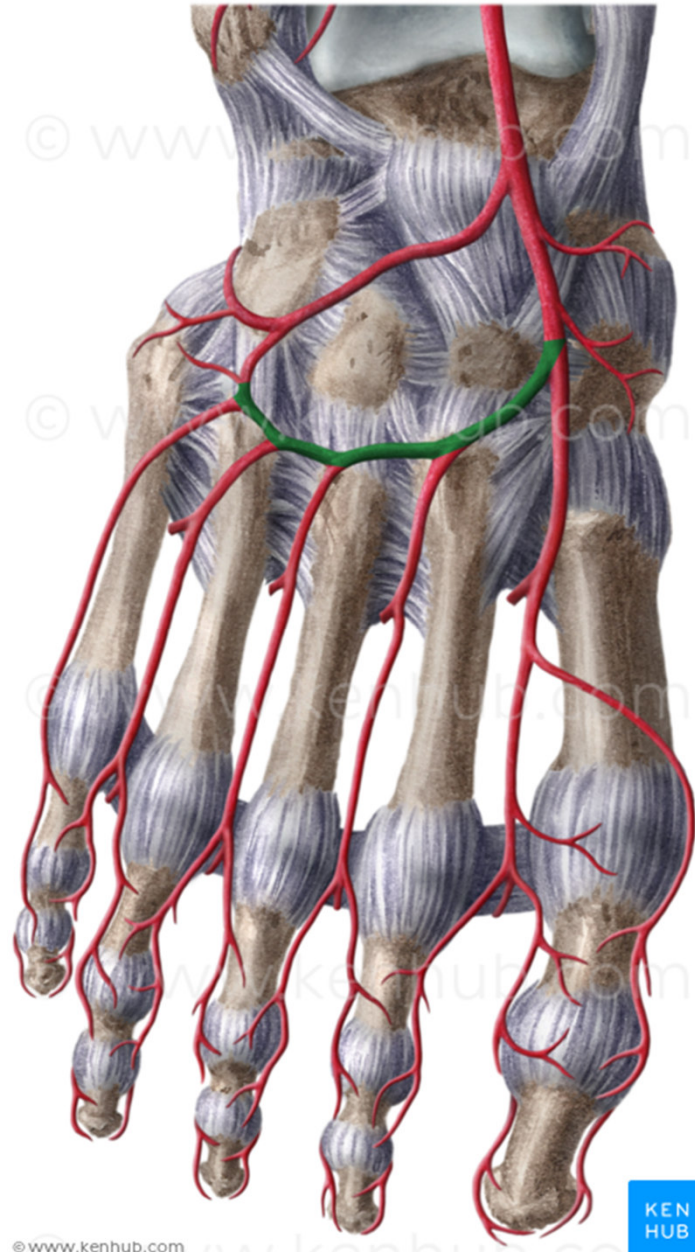
- aa. metatarsae dorsales
- aa. digitales dorsales

**a. metatarsa dorsalis I.**

**r. plantaris profundus** (do  
planta pedis-arcus plantaris)

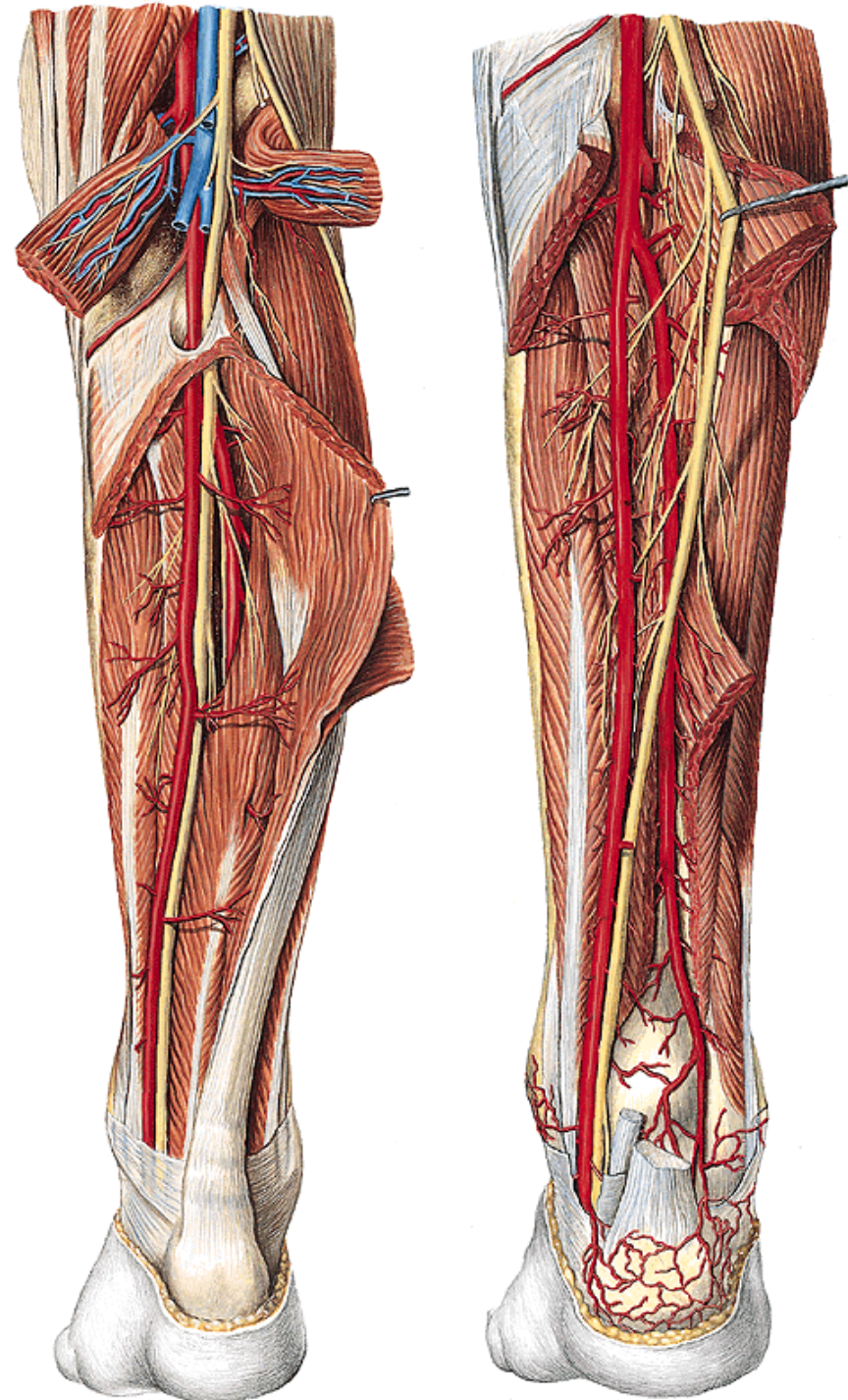






## A. tibialis posterior

- pod arcus tendineus m. solei, leží na hlubokých flexorech bérce, za mediálním kotníkem jde do planta pedis
- **canalis malleolaris** (útvary za mediálním kotníkem)
  - m. tibialis posterior
  - m. flexor digitorum longus
  - a. et vv. tibiales posteriores
  - n. tibialis
  - m. flexor hallucis longus



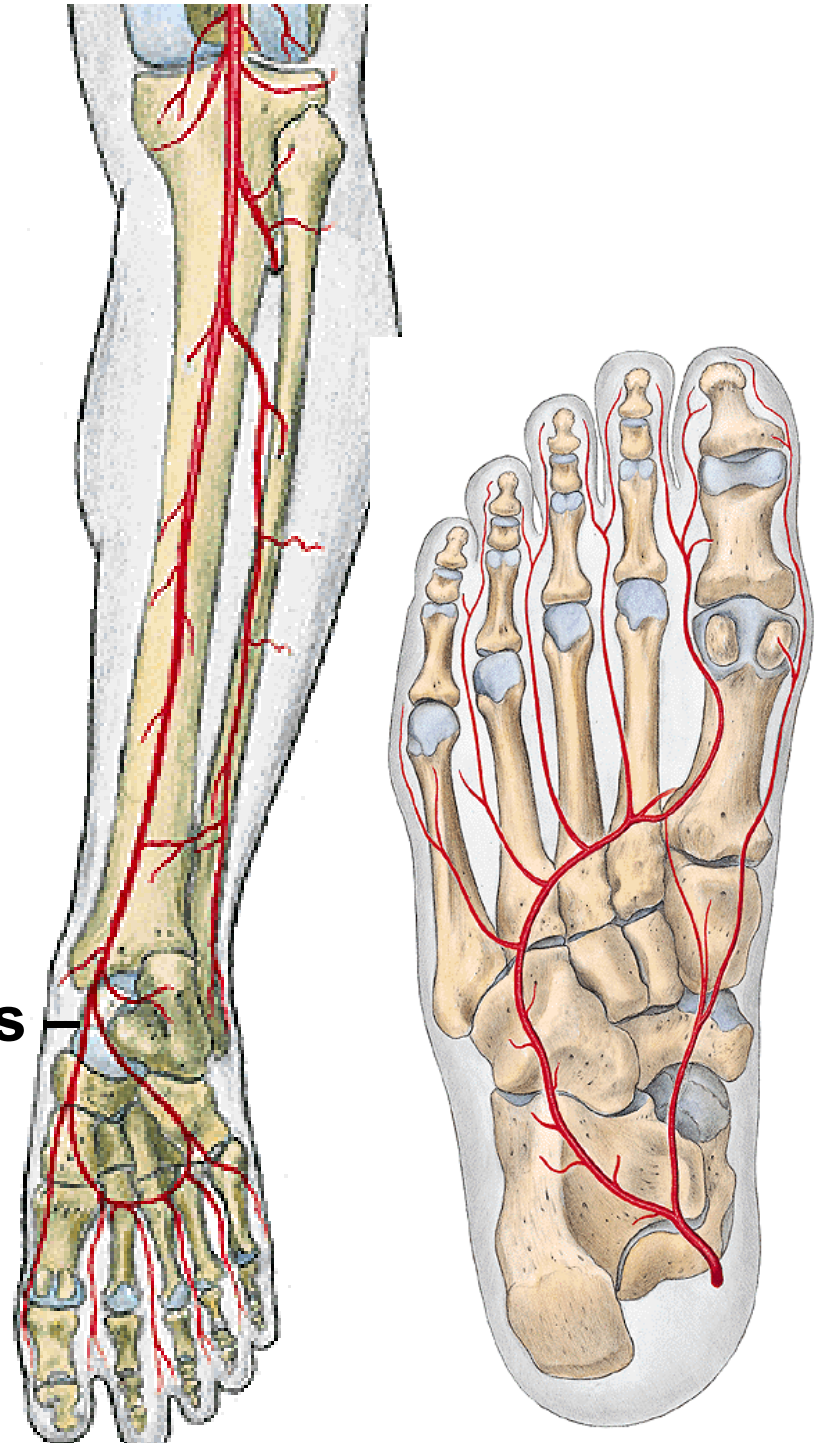


**větve:**

- 1) do tepenné sítě kolenního kloubu**
- 2) a. peronea (fibularis)-  
vyživuje fibulu a okolní svaly**
- 4) do tepenné sítě mediálního kotníku**
- 5) do tepenné sítě kolem paty**

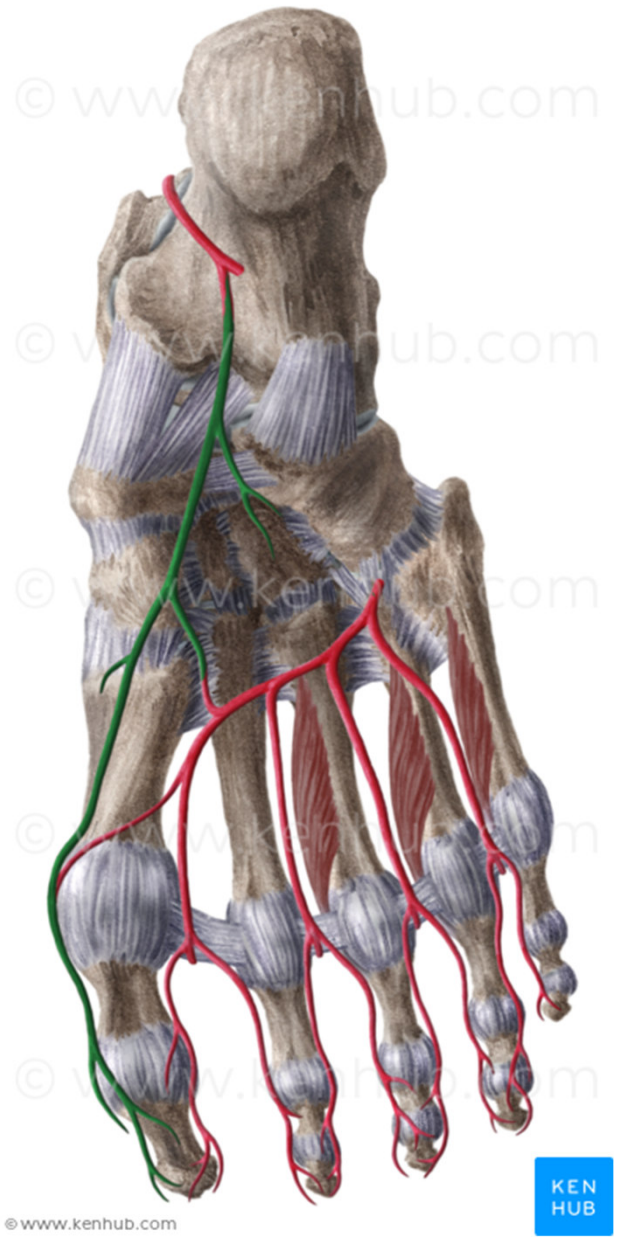
**konečné větve:**

- a. plantaris medialis**
- a. plantaris lateralis (arcus plantaris –  
aa. metatarsae plantares  
aa. digitales plantares)**

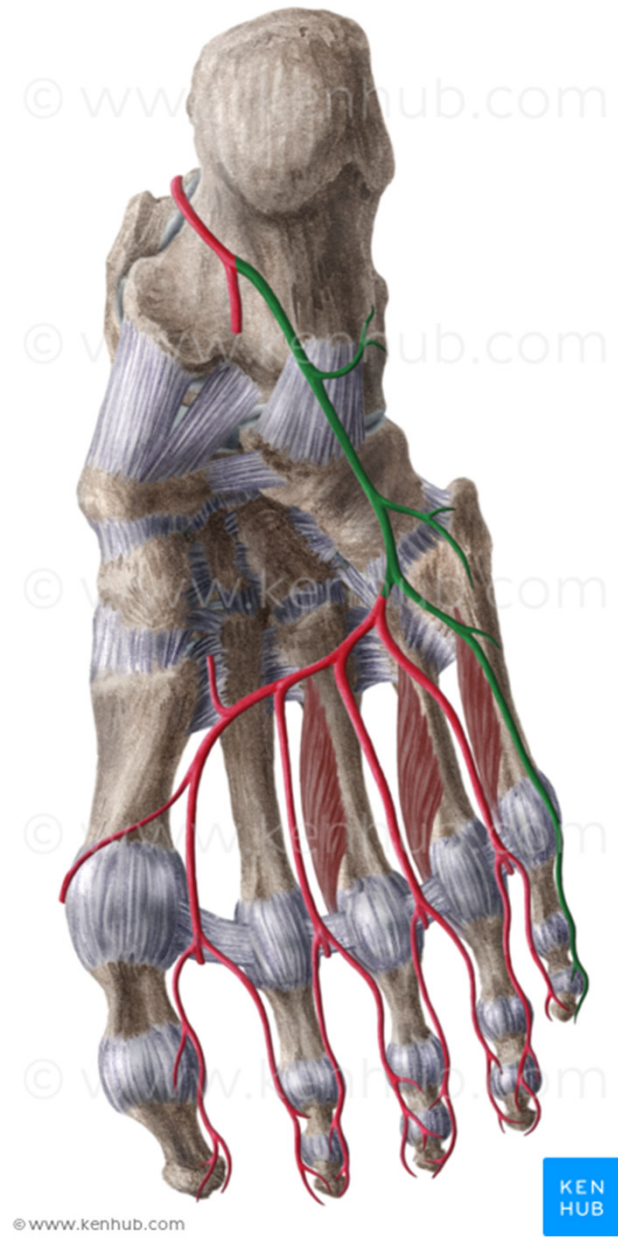








© www.kenhub.com



© www.kenhub.com



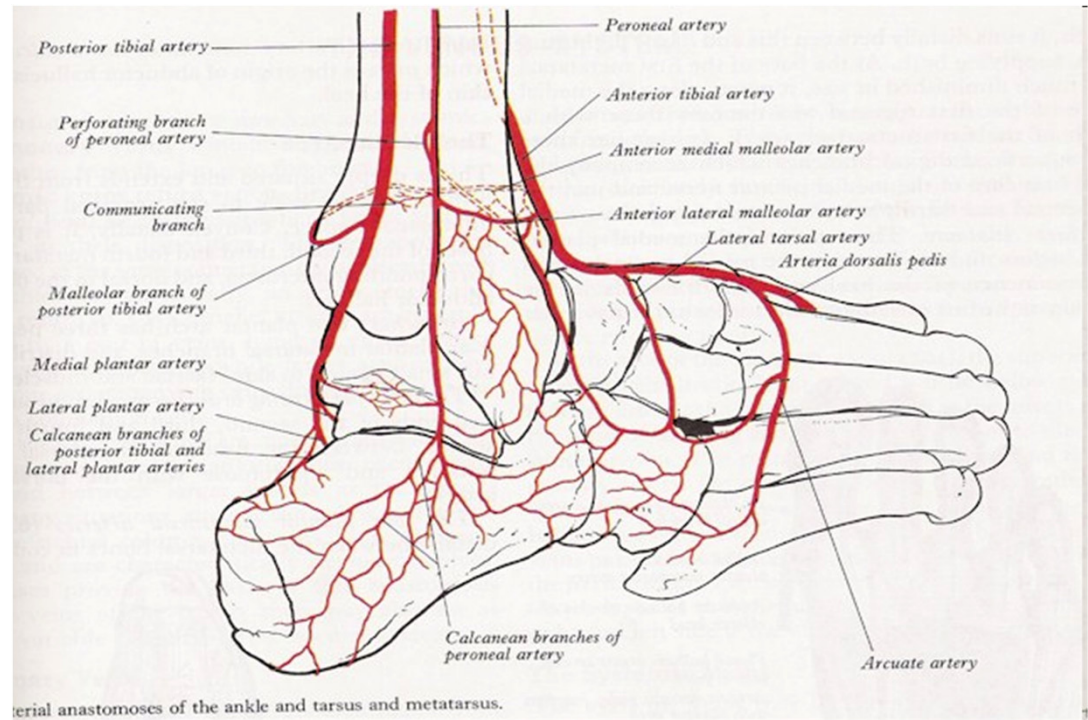
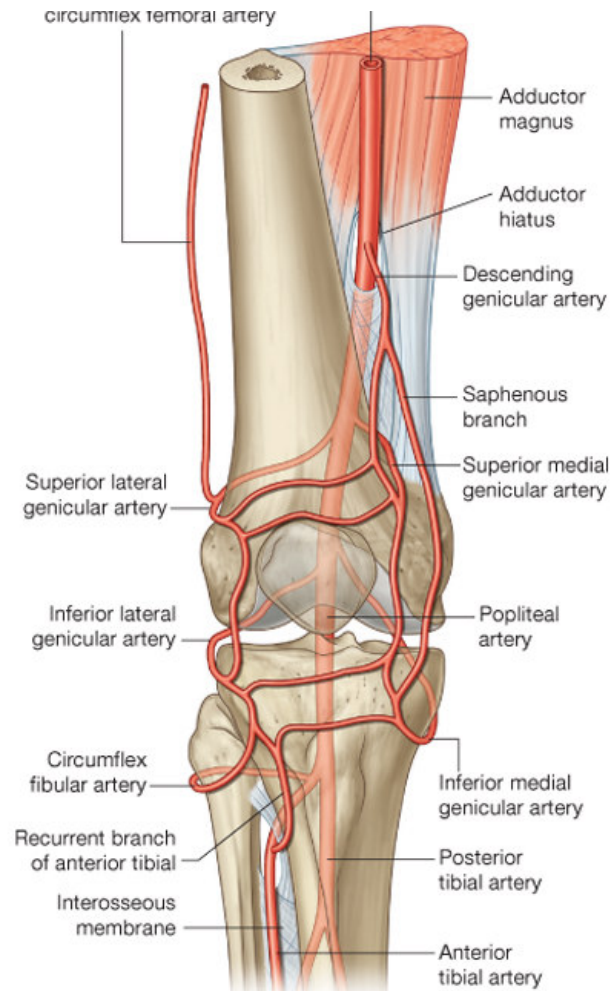
# RETE ARTICULARE GENUS (rete patellae)

## RETE MALLEOLARE MEDIALE

## RETE MALLEOLARE LATERALE

## RETE CALCANEUM

## RETE DORSALE PEDIS





- **Obrázky:**
- **Atlas der Anatomie des Menschen/Sobotta. Putz,R., und Pabst,R. 20. Auflage. München:Urban & Schwarzenberg, 1993**
- **Netter: Interactive Atlas of Human Anatomy.**
- **Naňka, Elišková: Přehled anatomie. Galén, Praha 2009.**
- **Čihák: Anatomie I, II, III.**
- **Drake et al.: Gray's Anatomy for Students. 2010**