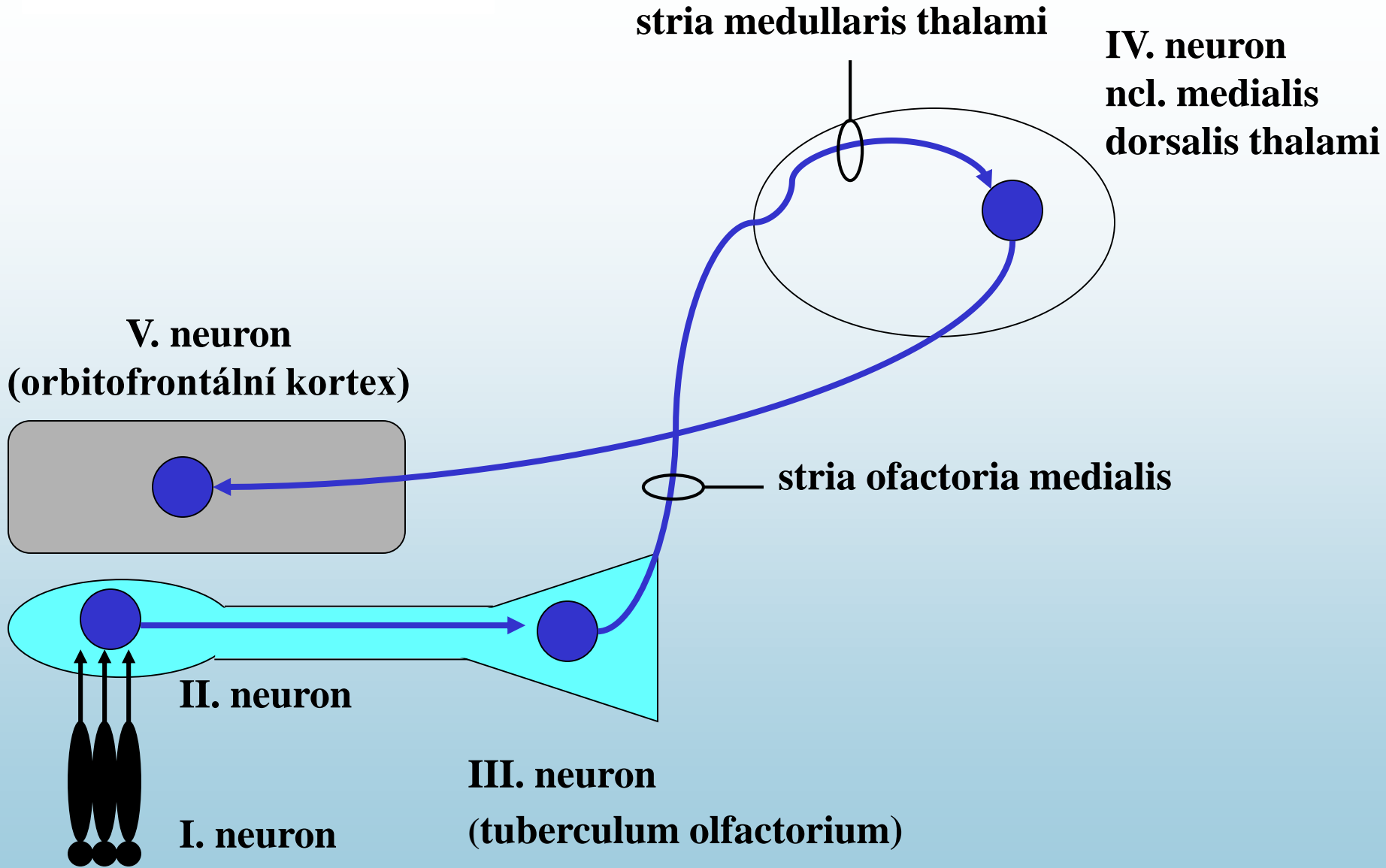
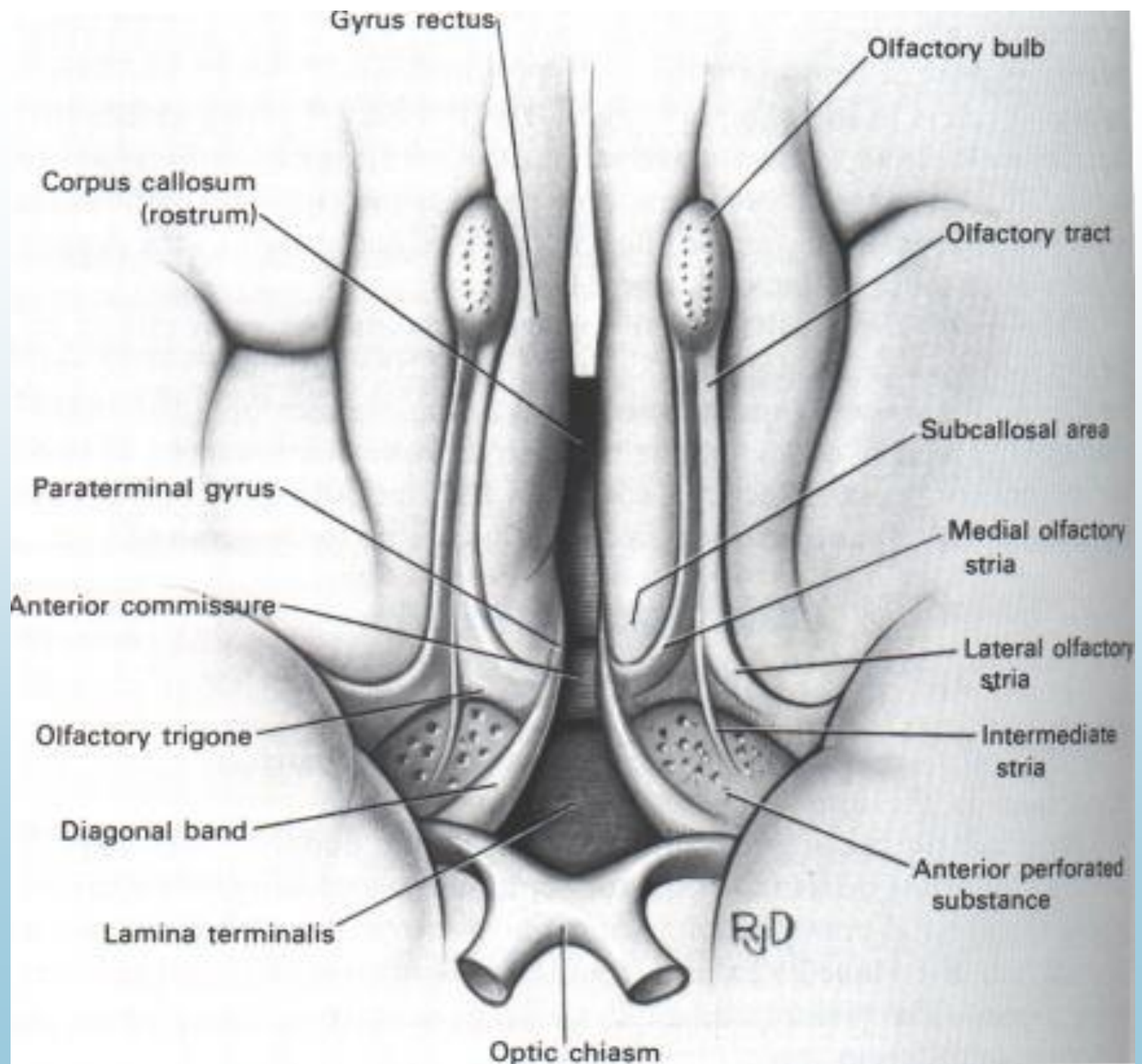
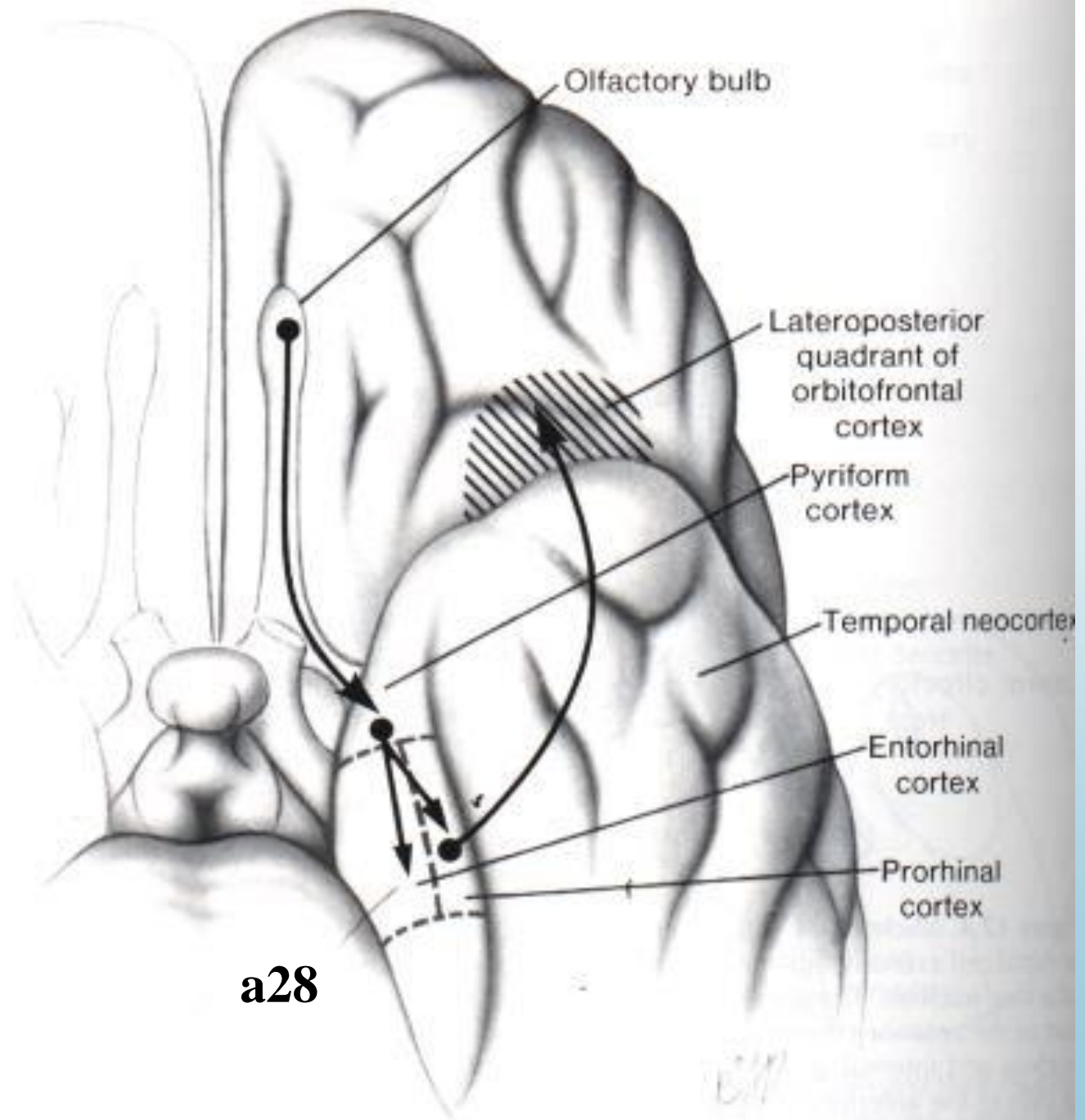


ČIHOVÁ DRÁHA







PET po čichové stimulaci pacienta

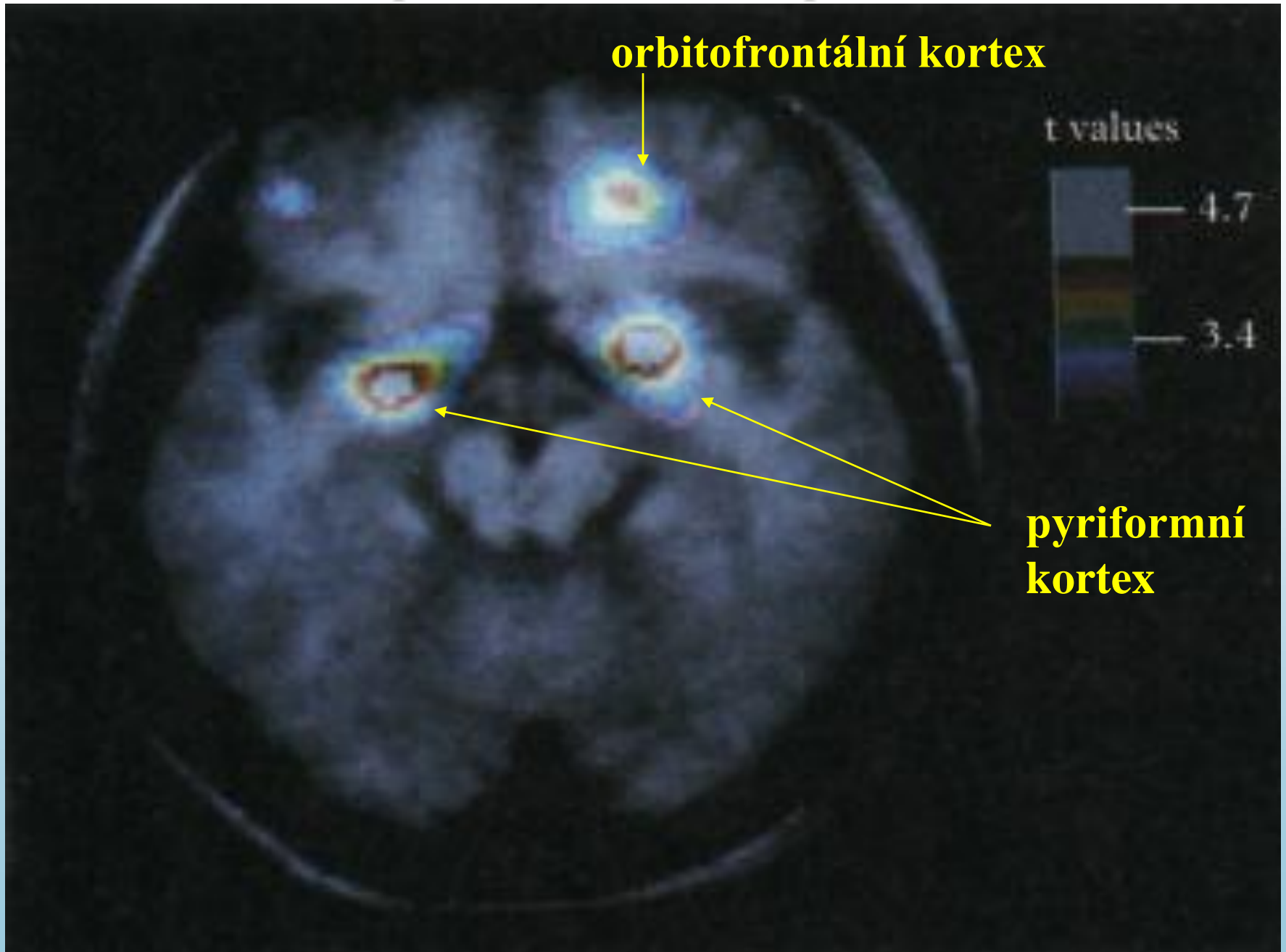
orbitofrontální kortex

t values

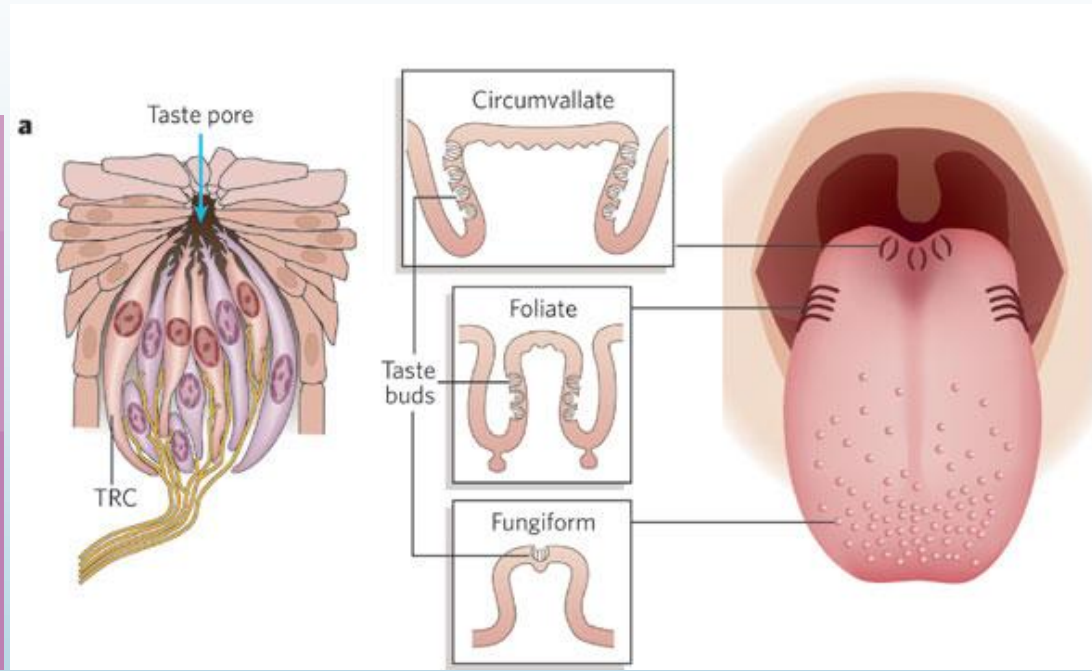
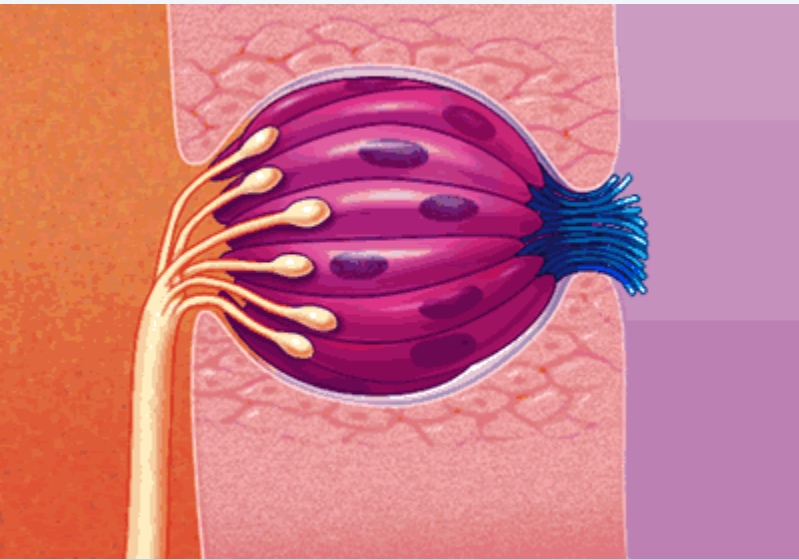
— 4.7

— 3.4

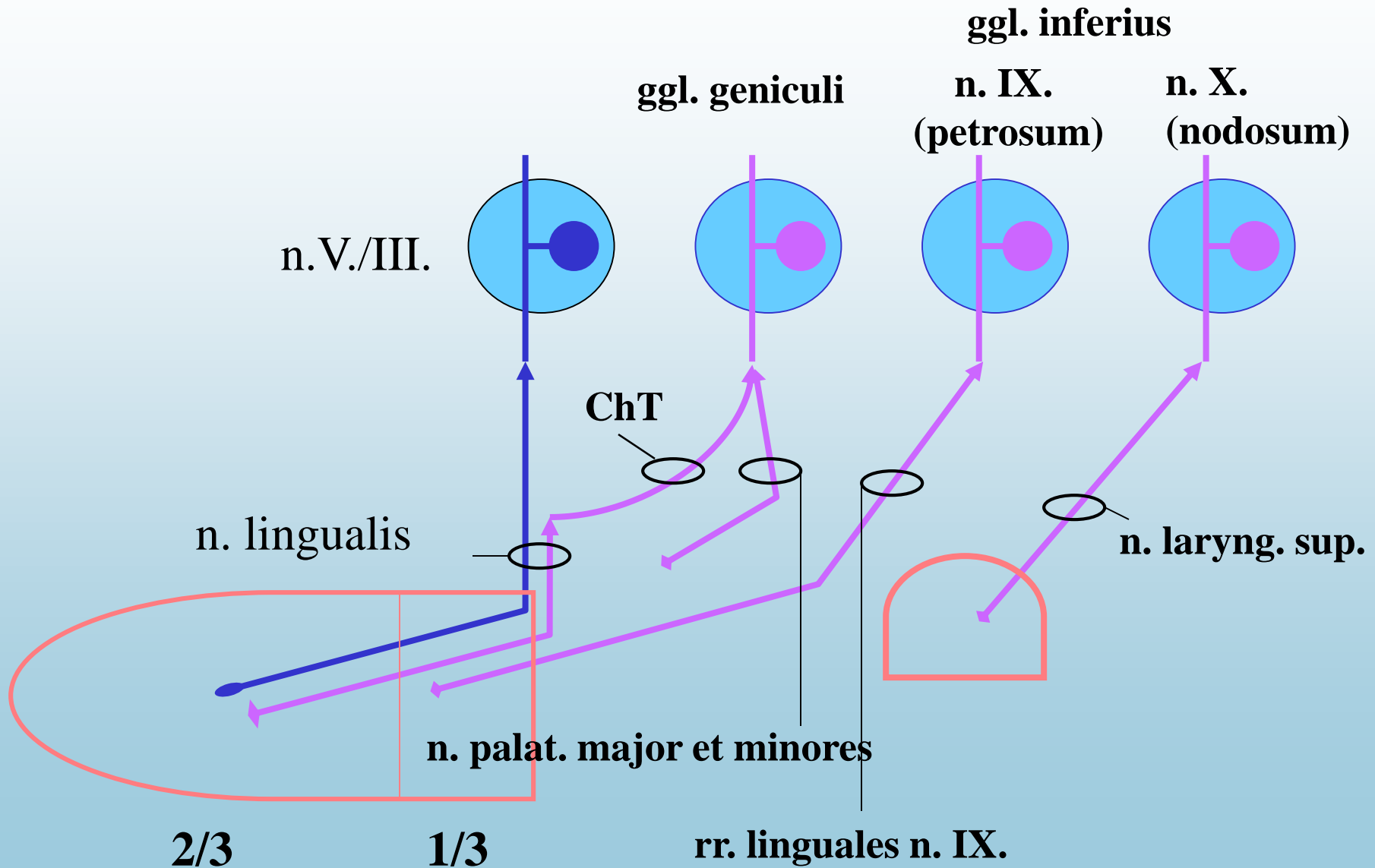
piriformní kortex



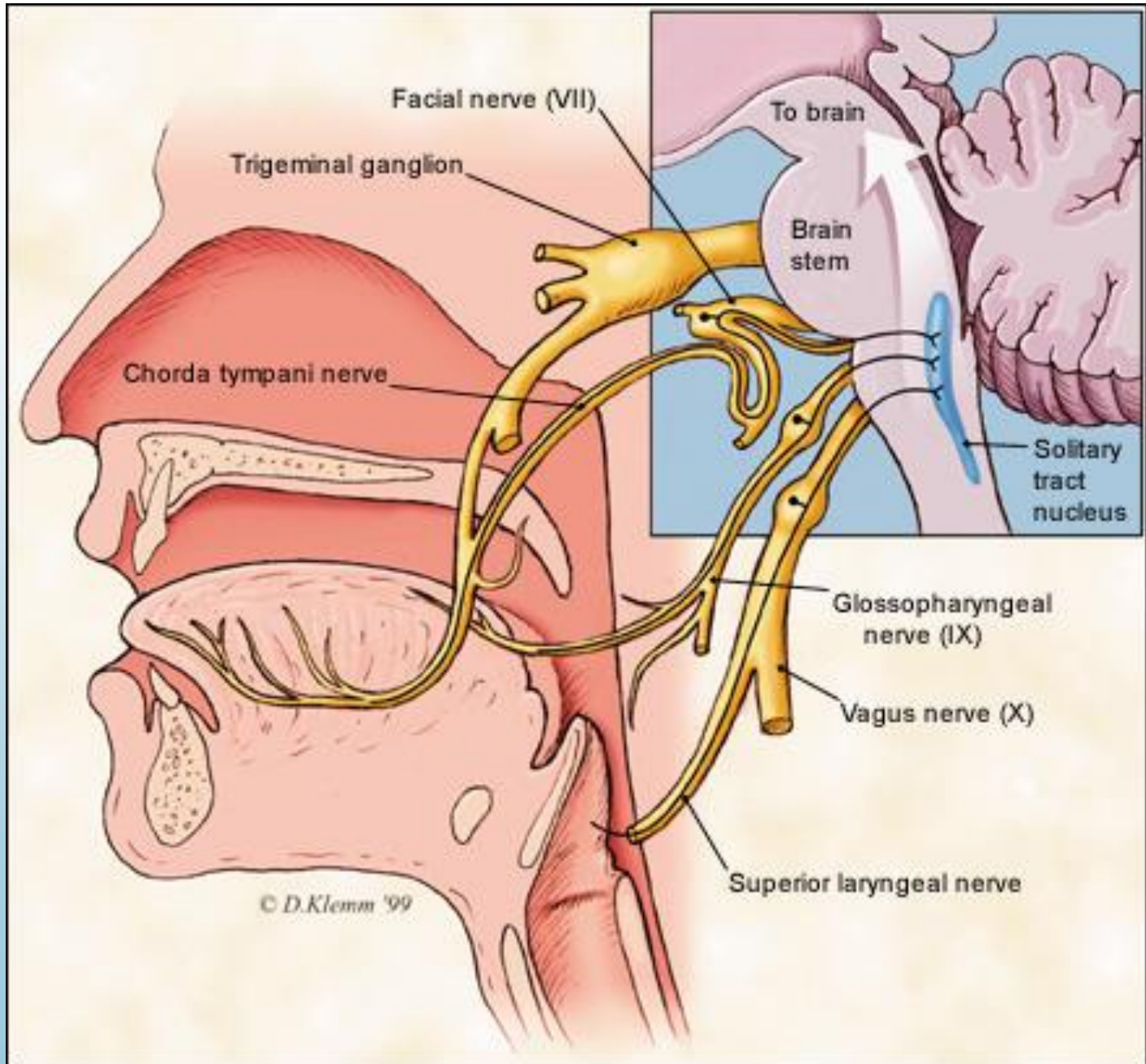
CHUŤOVÁ DRÁHA - chuťové papily



CHUŤOVÁ DRÁHA - inervace chuťových papil I. neurony



CHUŤOVÁ DRÁHA



CHUŤOVÁ DRÁHA

gyrus postcentralis, area 43

ncl. ventr. postero-medialis
(parvocelulární část)

ncl. parabrachialis

tr. solitarius

insula
(alkohol?)

IV. neuron

III. neuron

II. neuron
ncl. gustatorius

I. neuron

