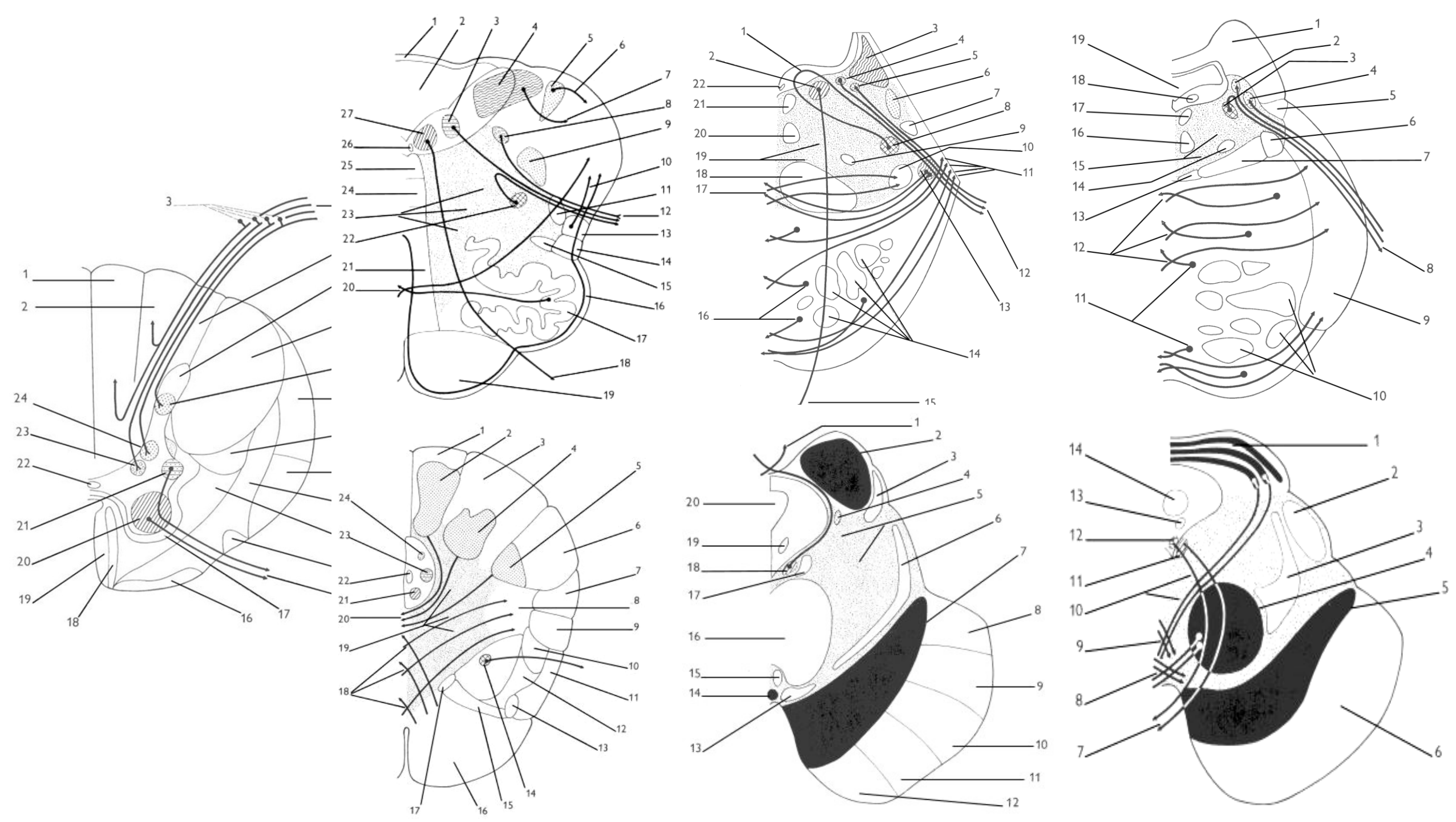
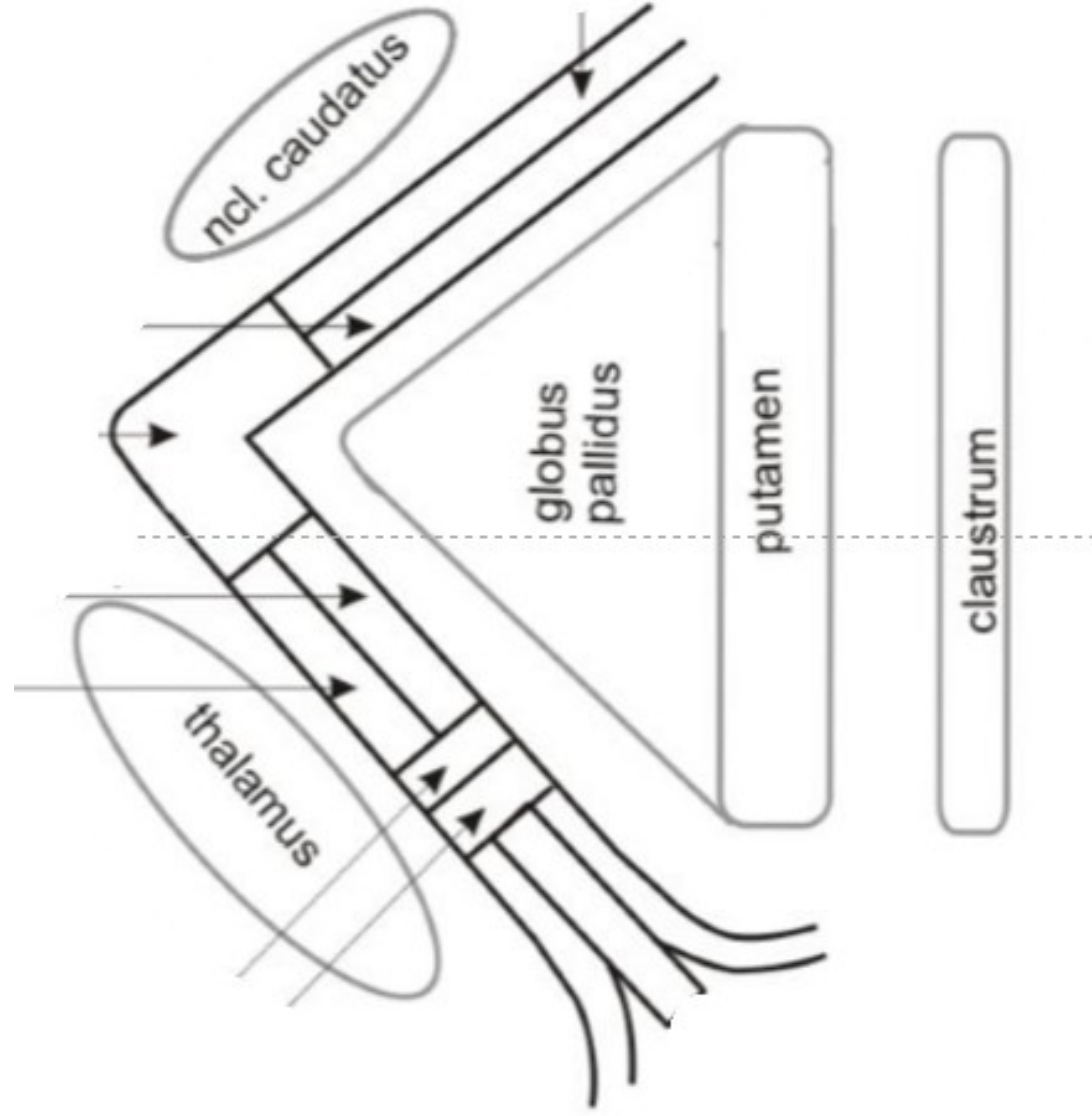
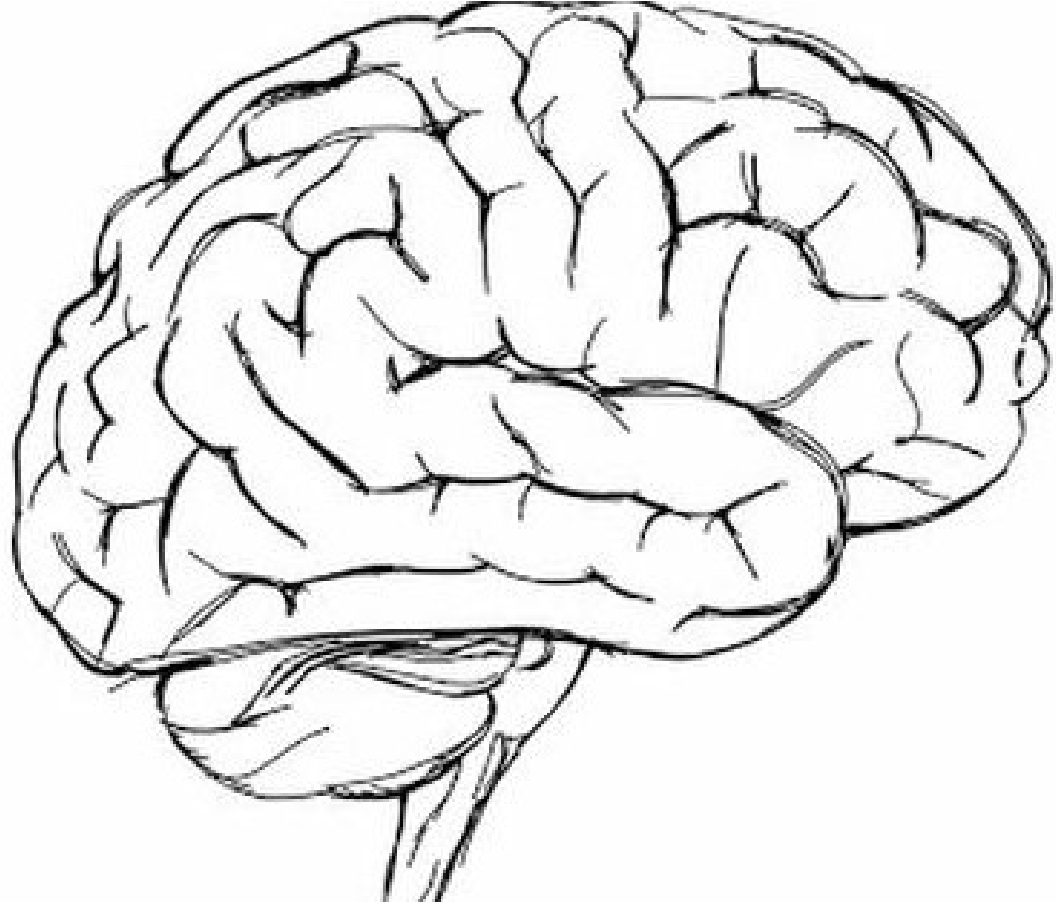


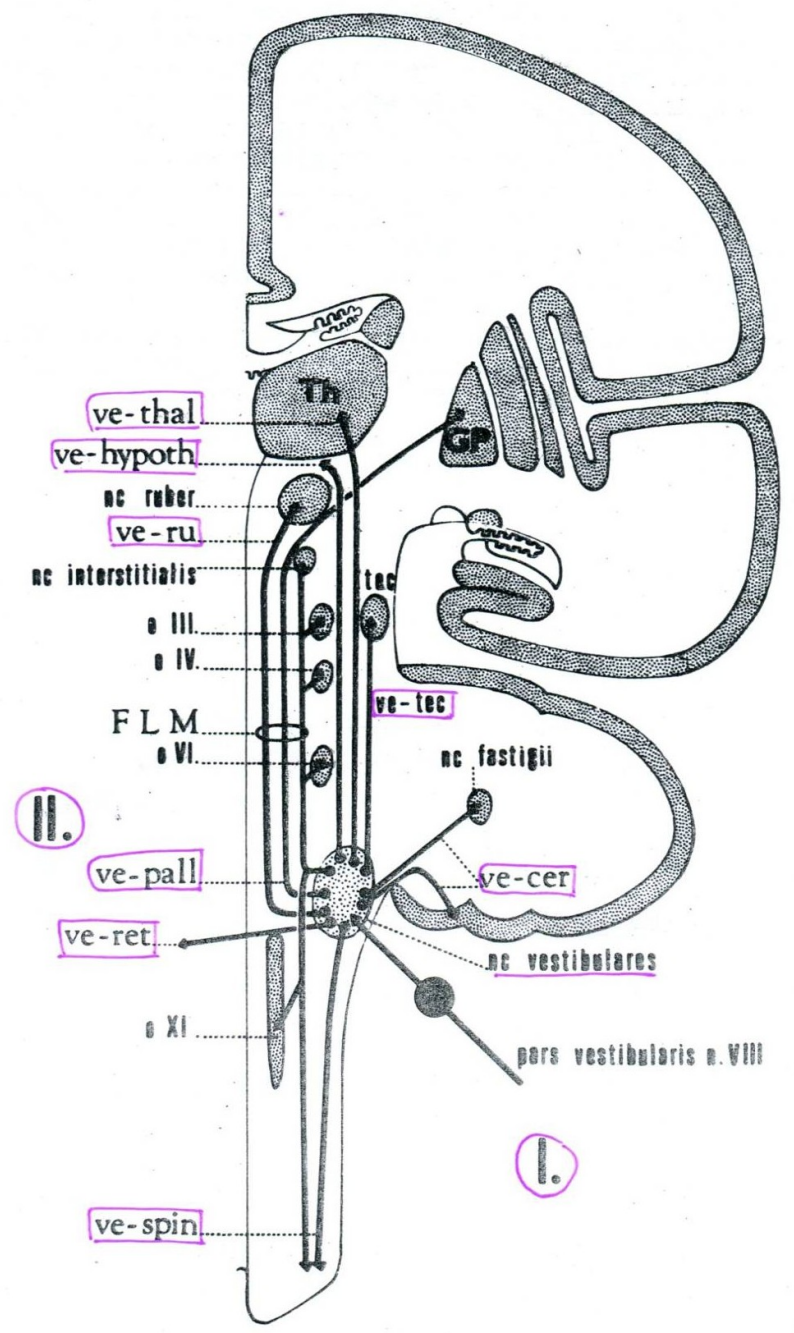
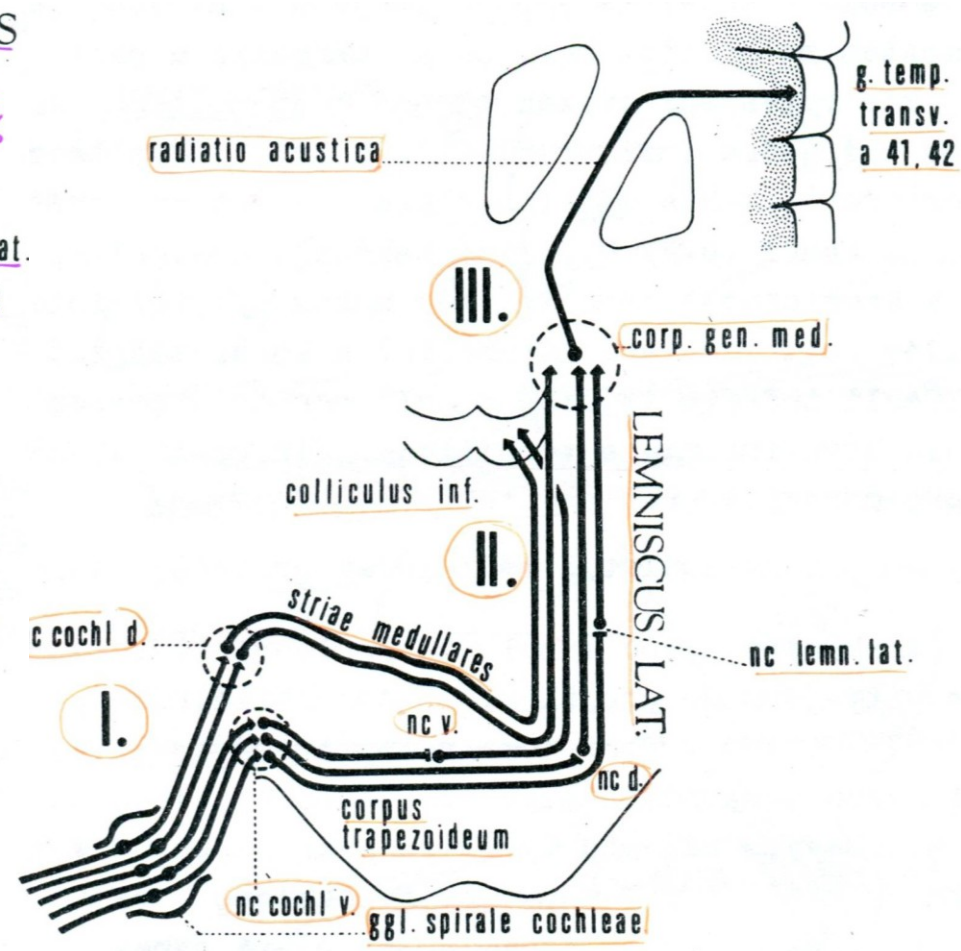
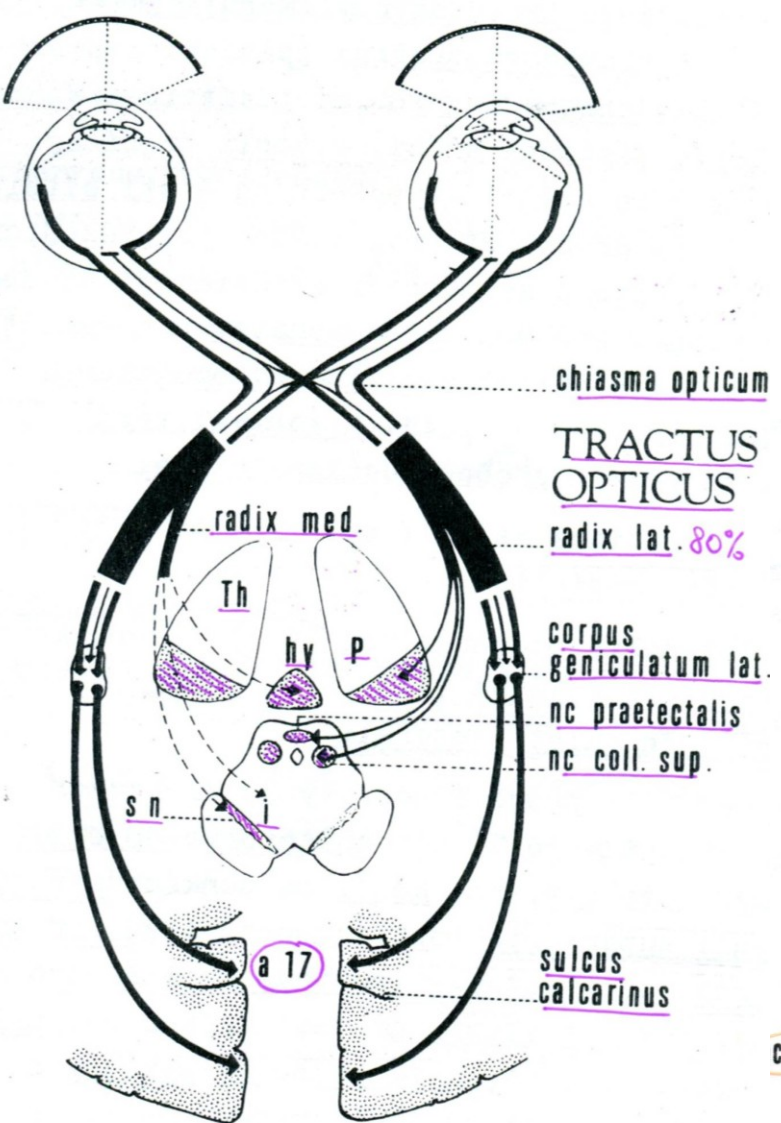
Neuronal pathways

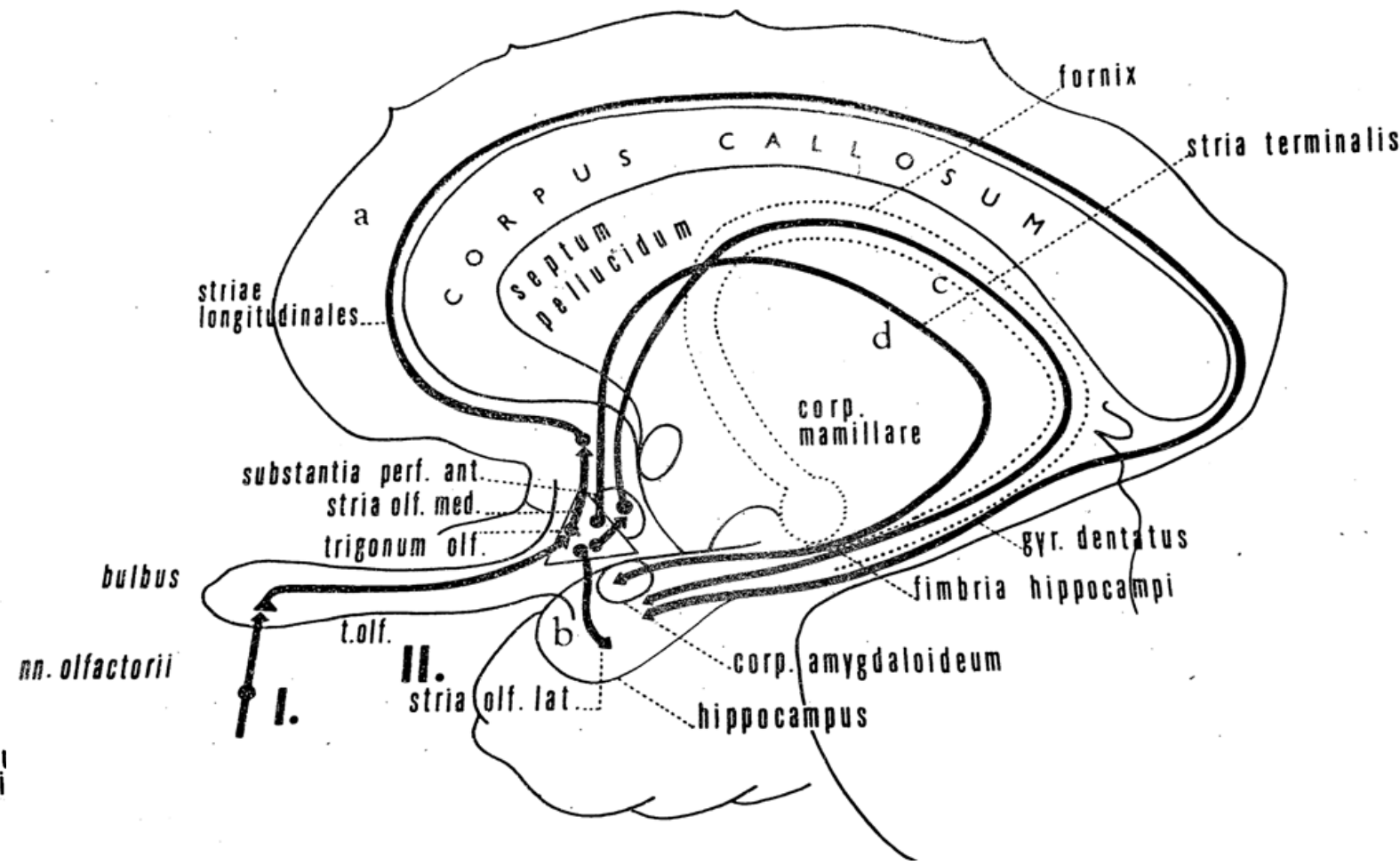
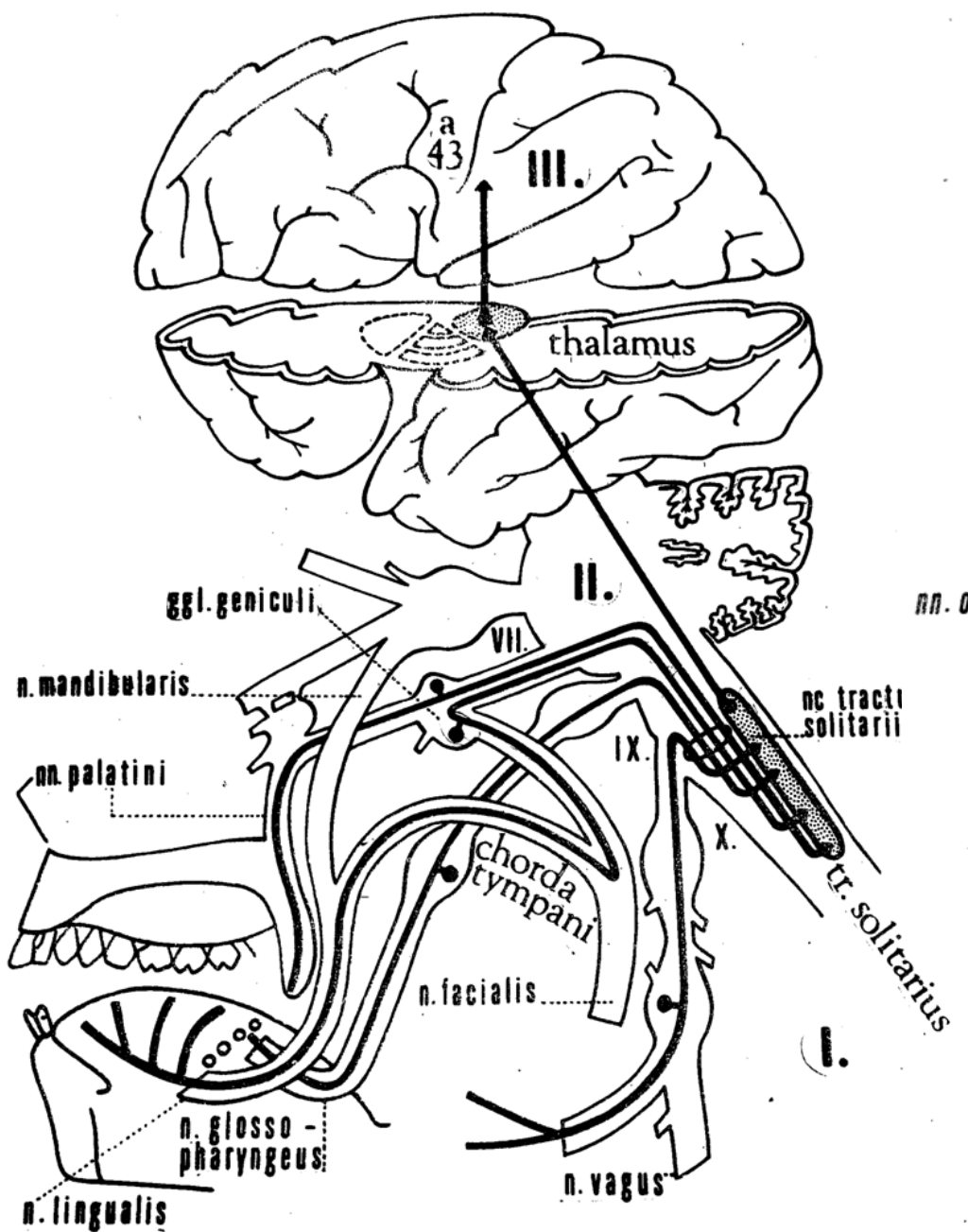
Topo head and neck

Overview 😊

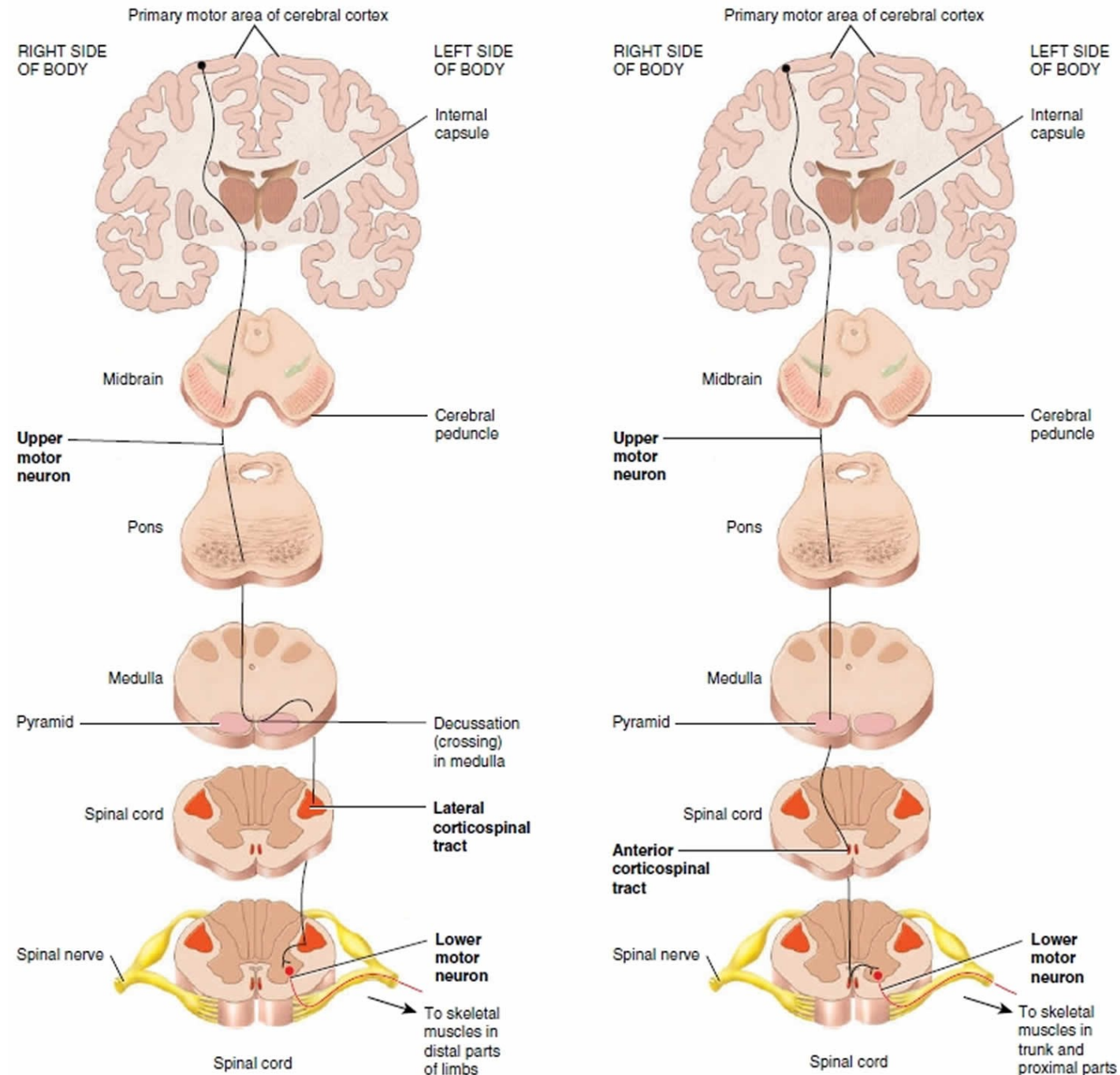








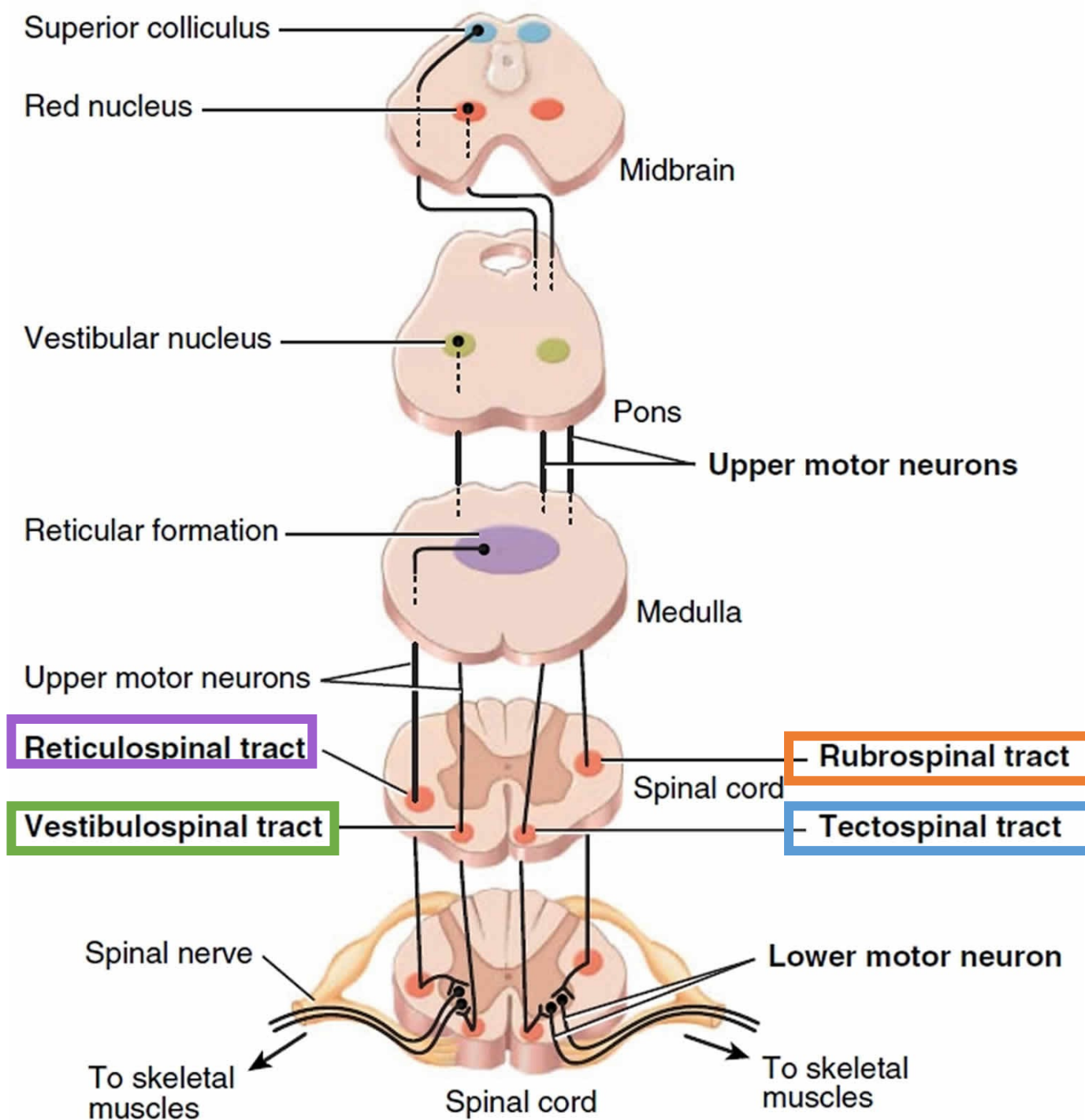
**MOTOR (DESCENDING)
PYRAMIDAL (DIRECT)**



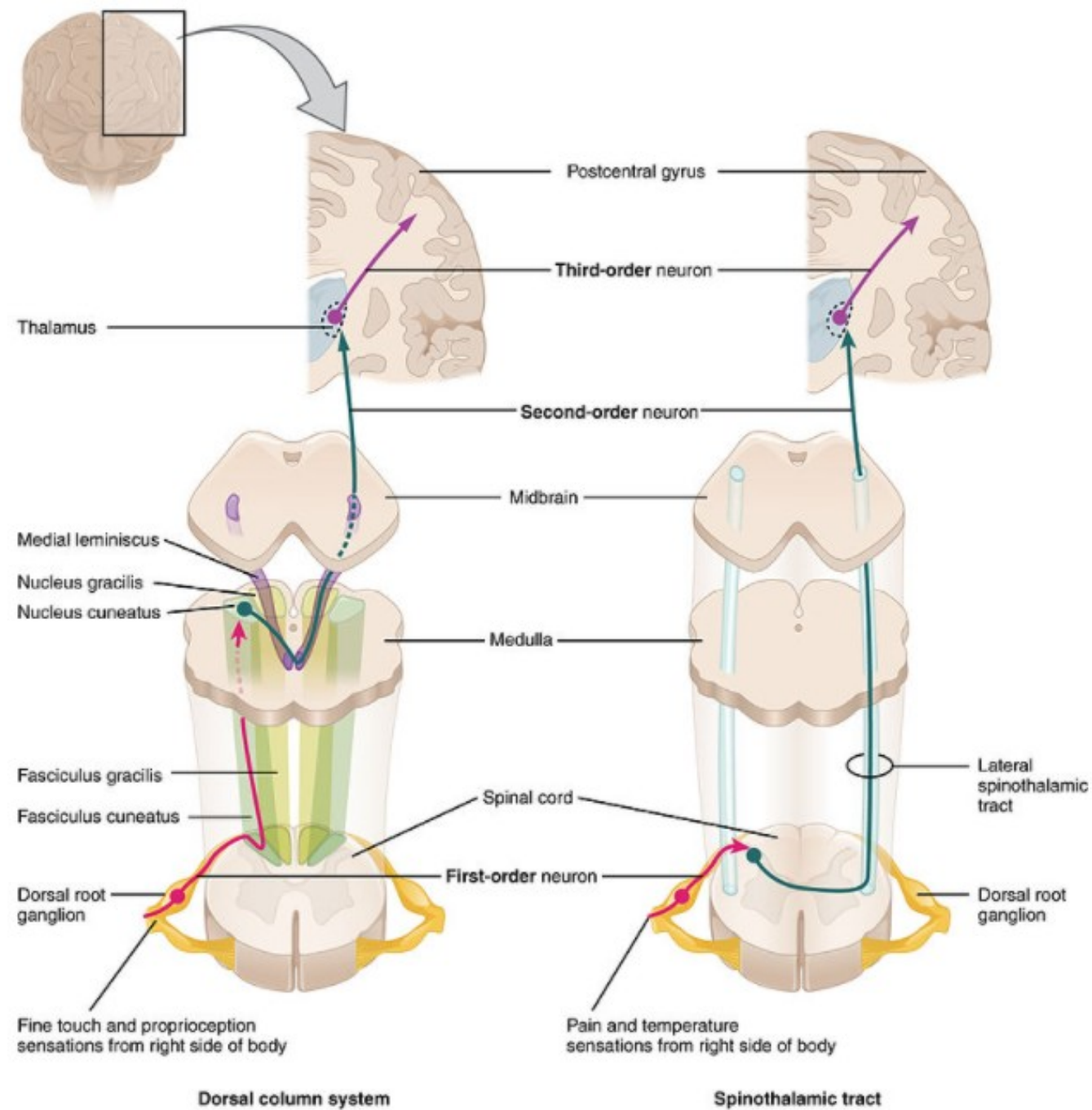
(a) The lateral corticospinal pathway

(b) The anterior corticospinal pathway

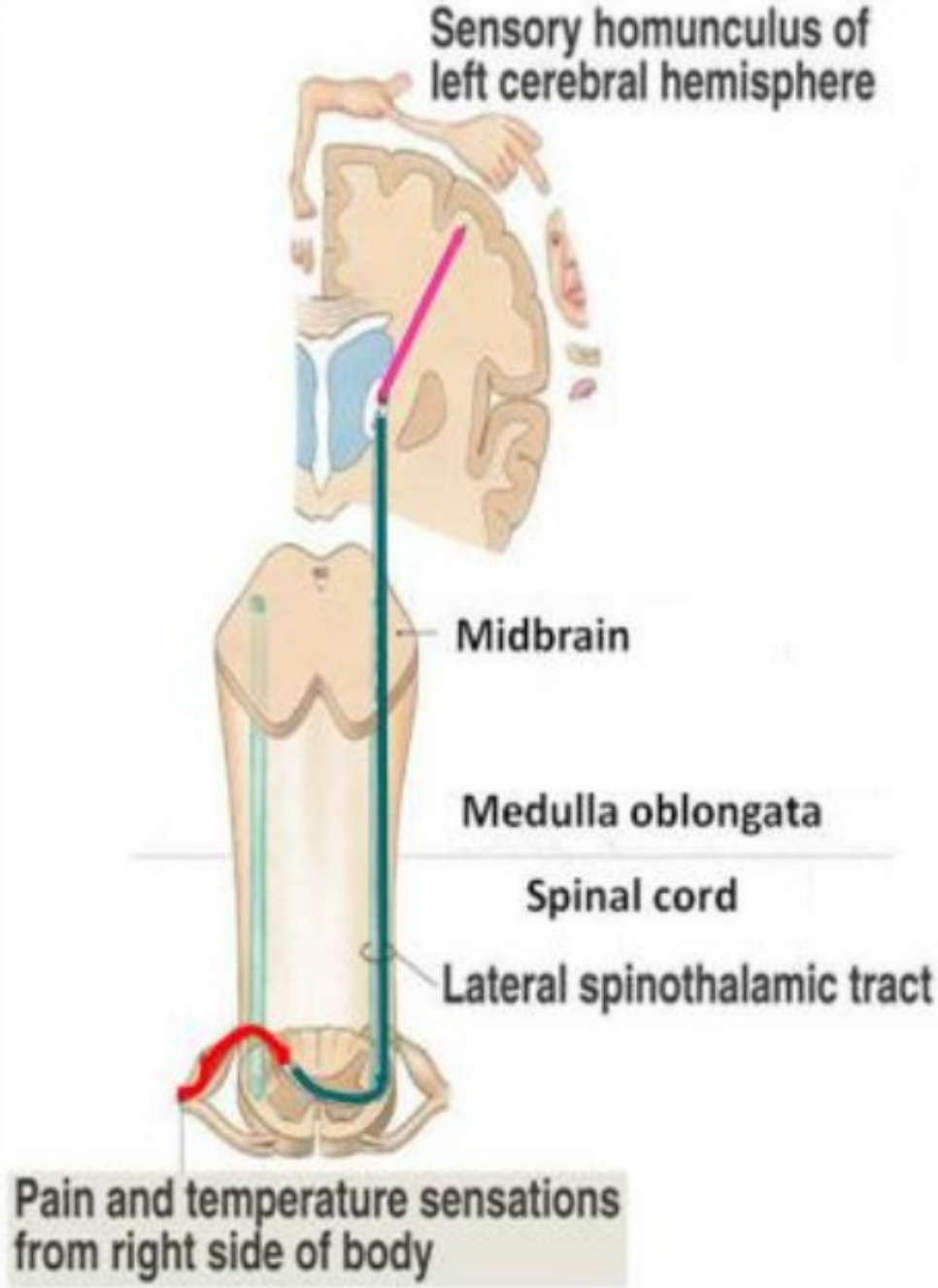
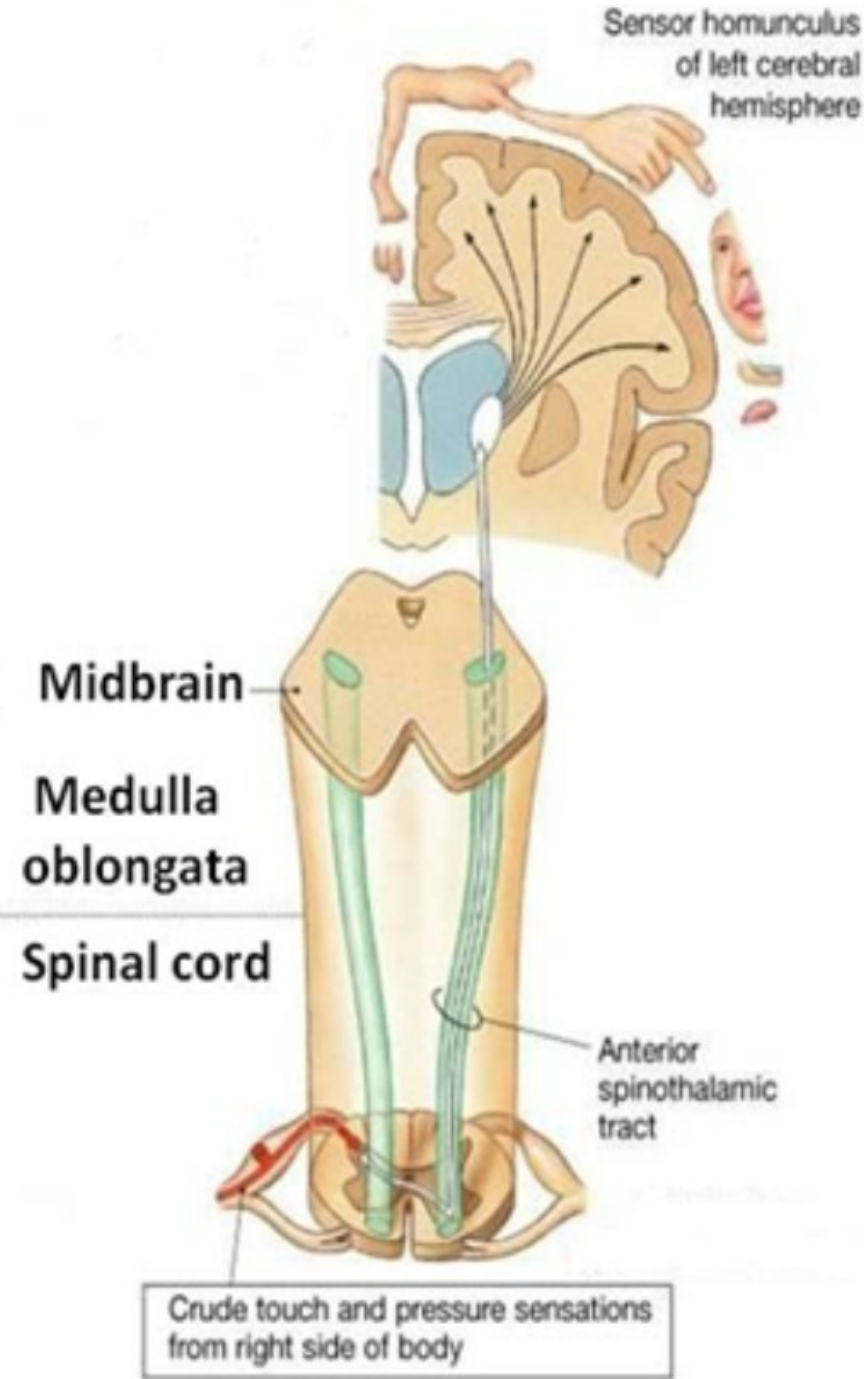
MOTOR (DESCENDING)
EXTRAPYRAMIDAL (INDIRECT)

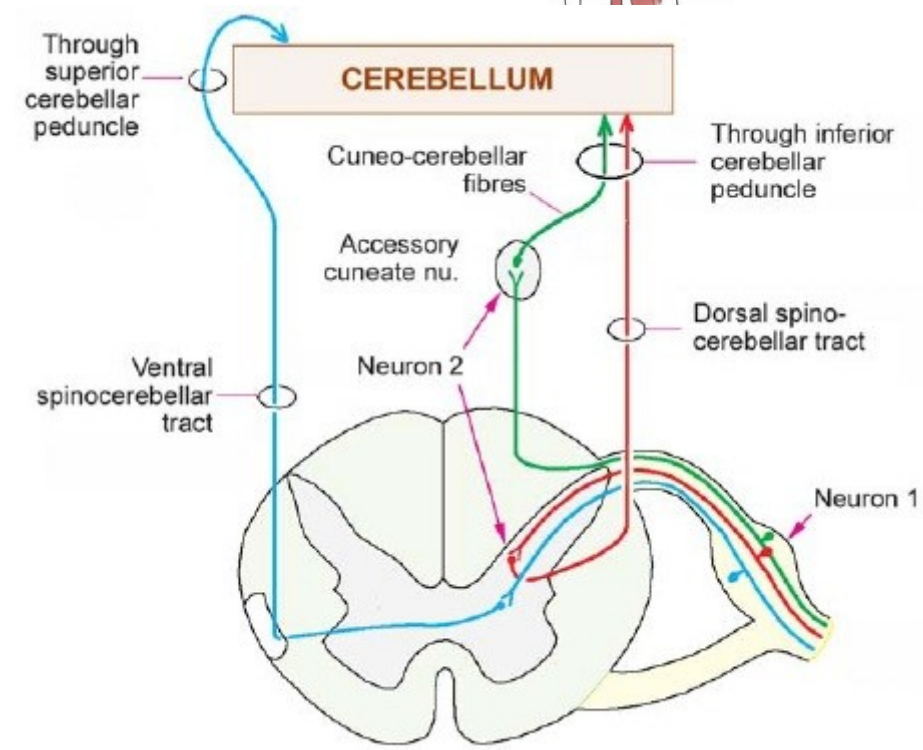
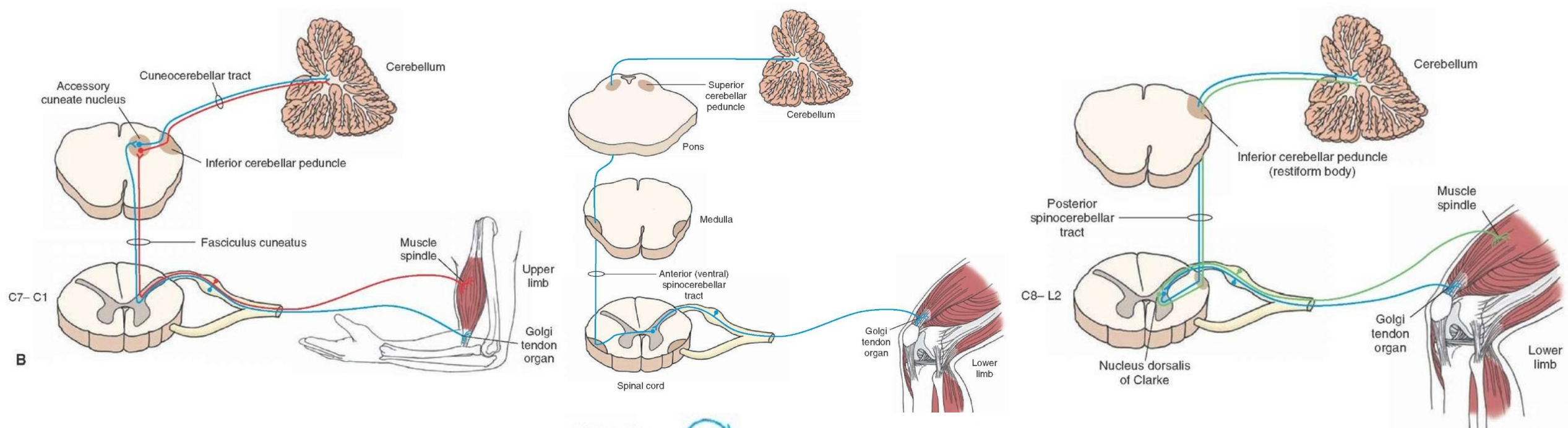


SENSORIC (ASCENDING)
EPICRITIC AND PROTOPATIC SENSATION



SENSORIC (ASCENDING)
PROTOPATIC SENSATION



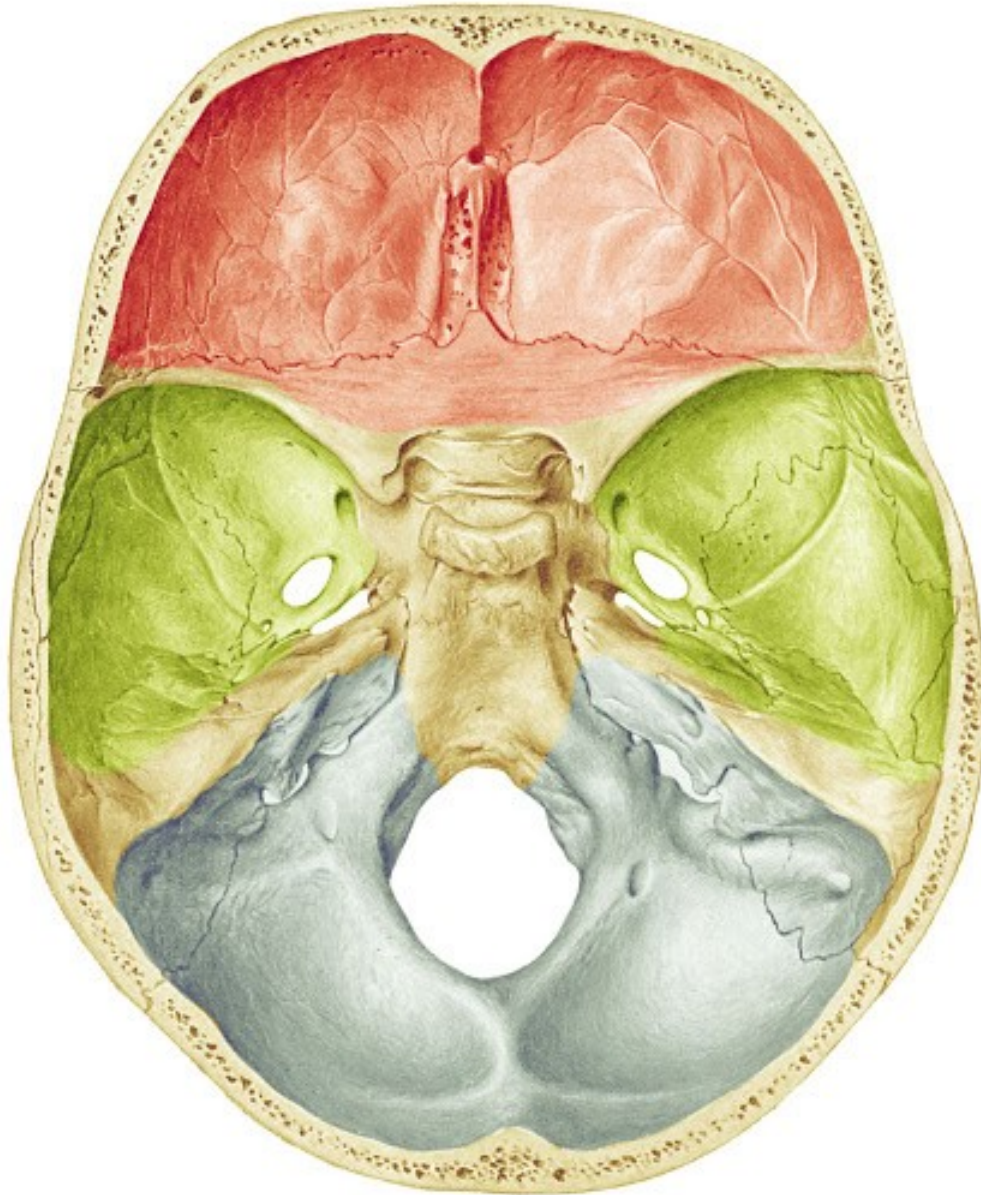


SENSORIC (ASCENDING)
PROPRIOCEPTION

TOPOGRAPHY

Head and neck

BASIS CRANII INTERNA

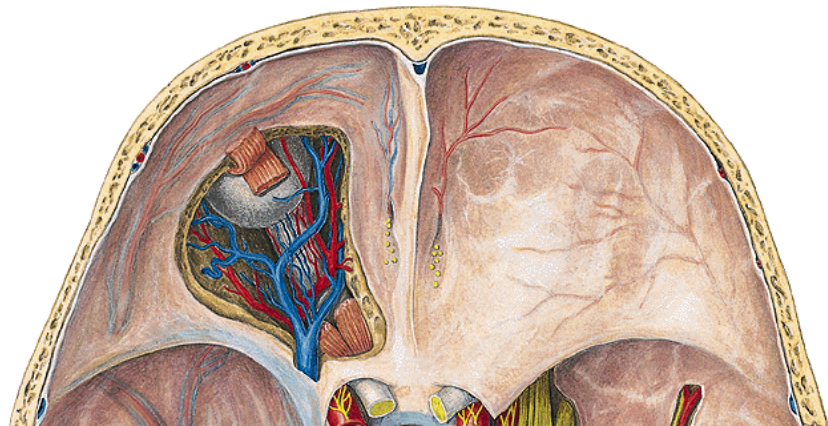
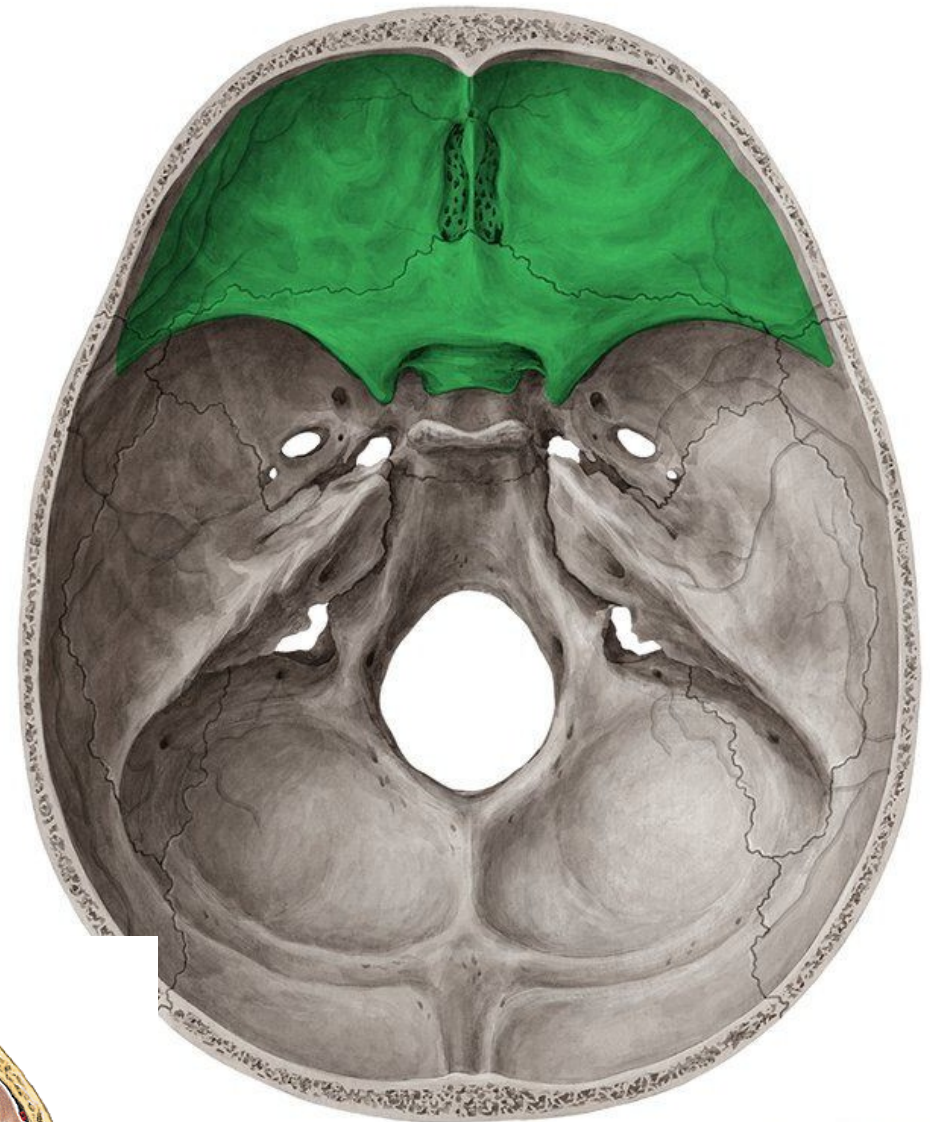
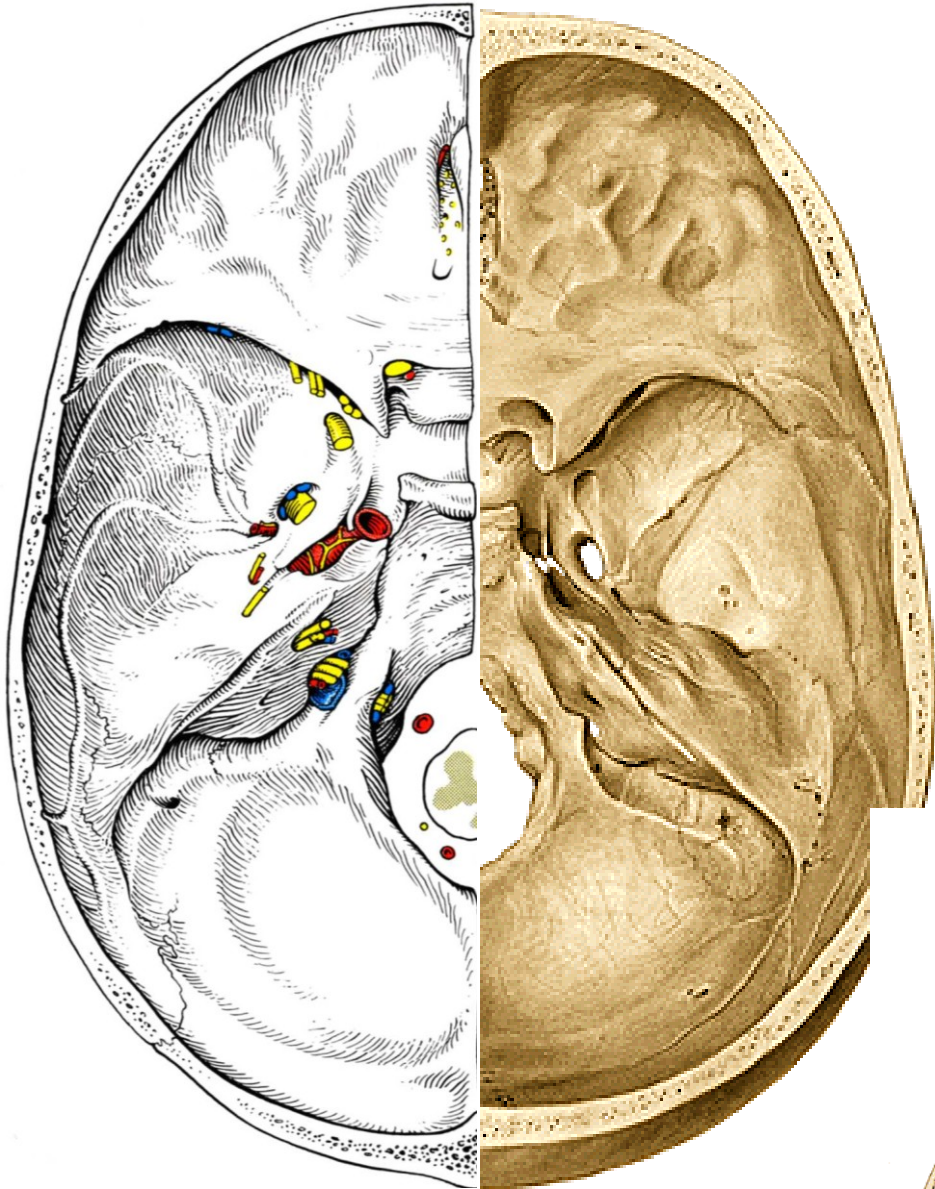


Fossa cranii anterior

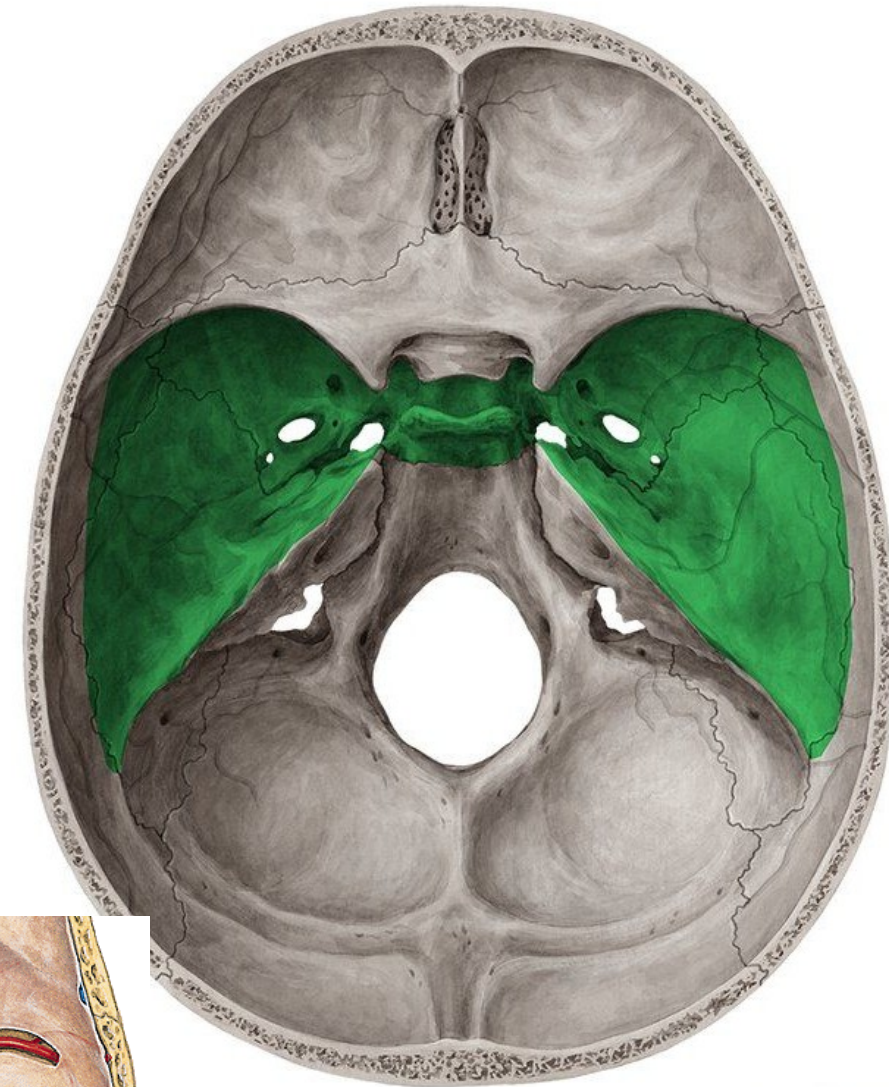
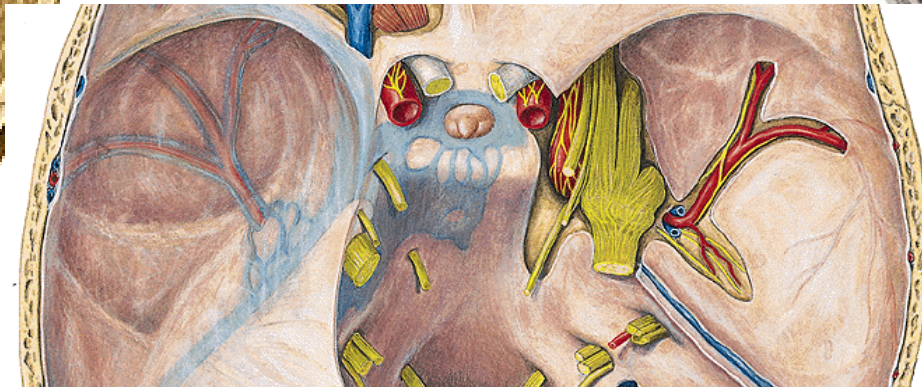
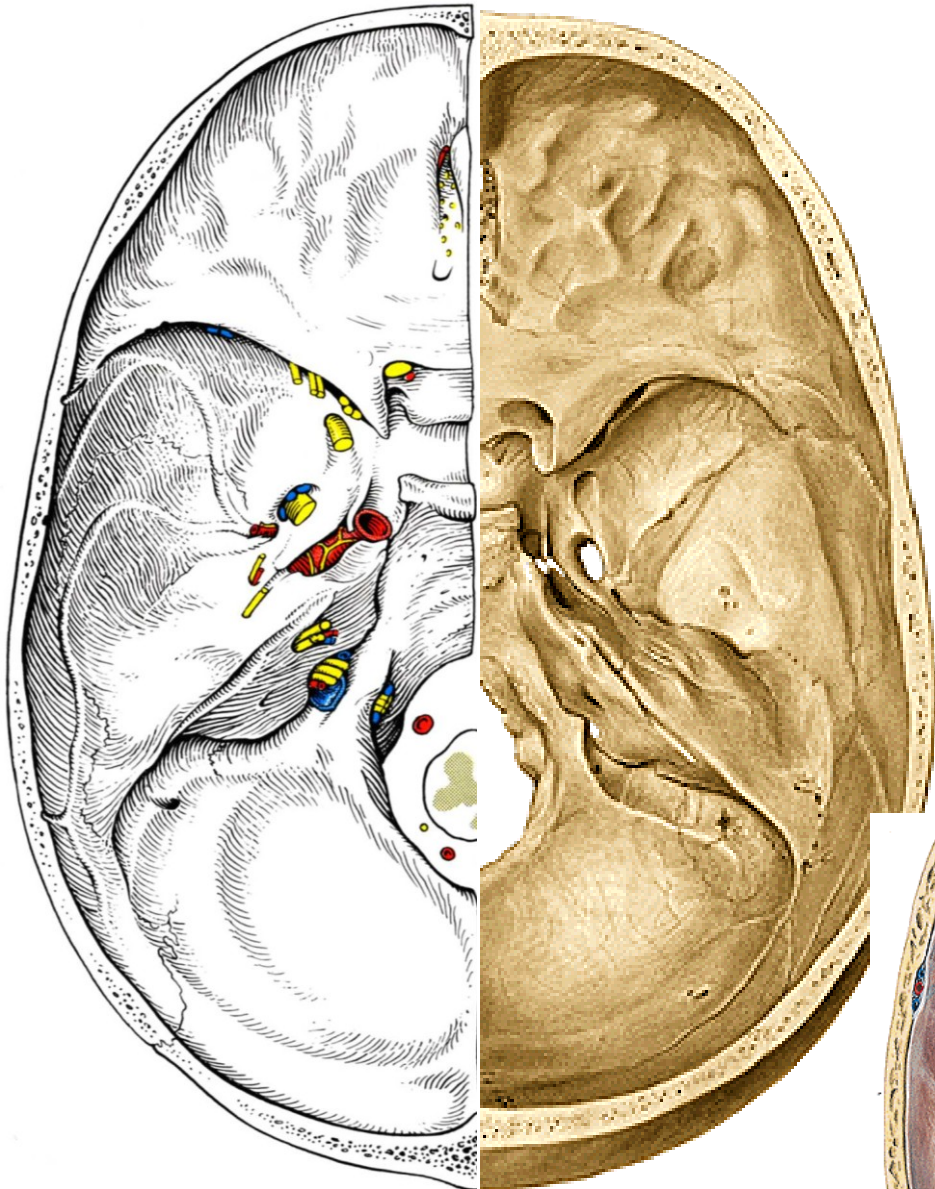
Fossa cranii media

Fossa cranii posterior

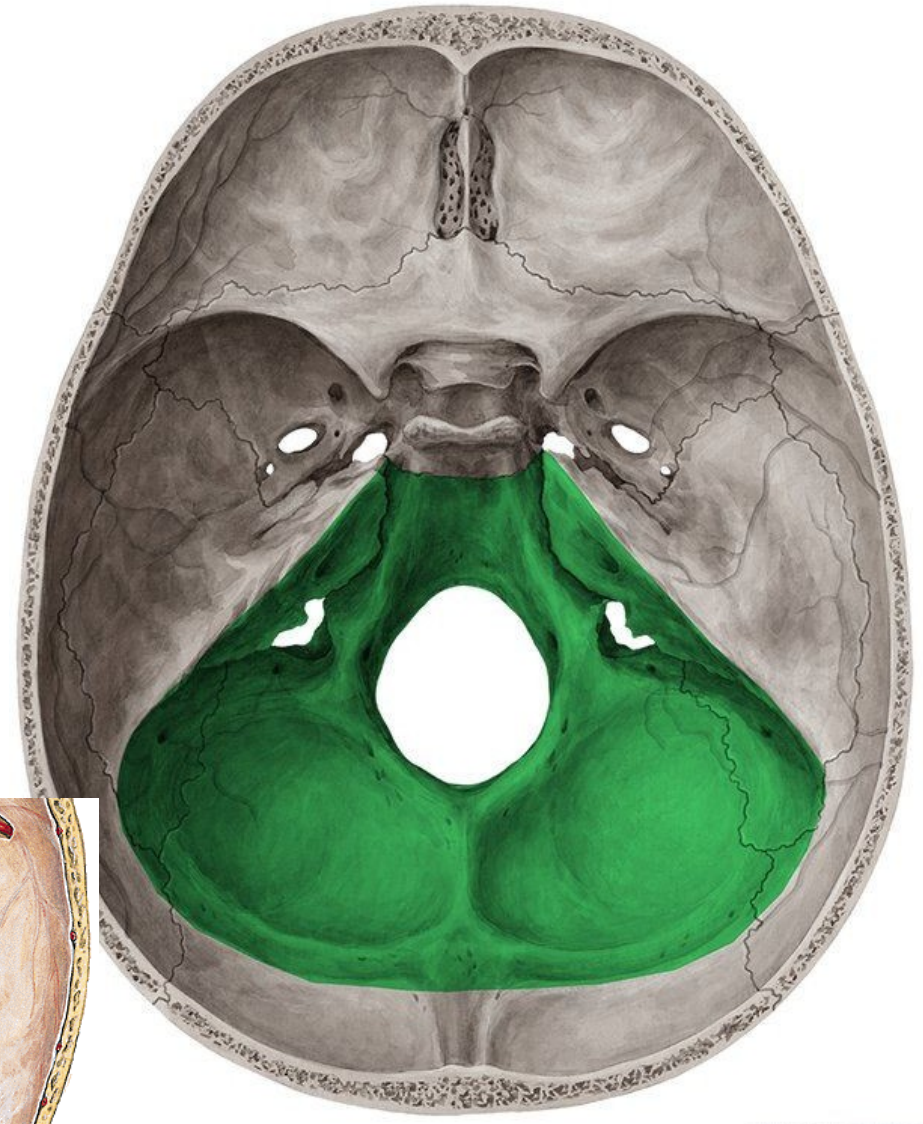
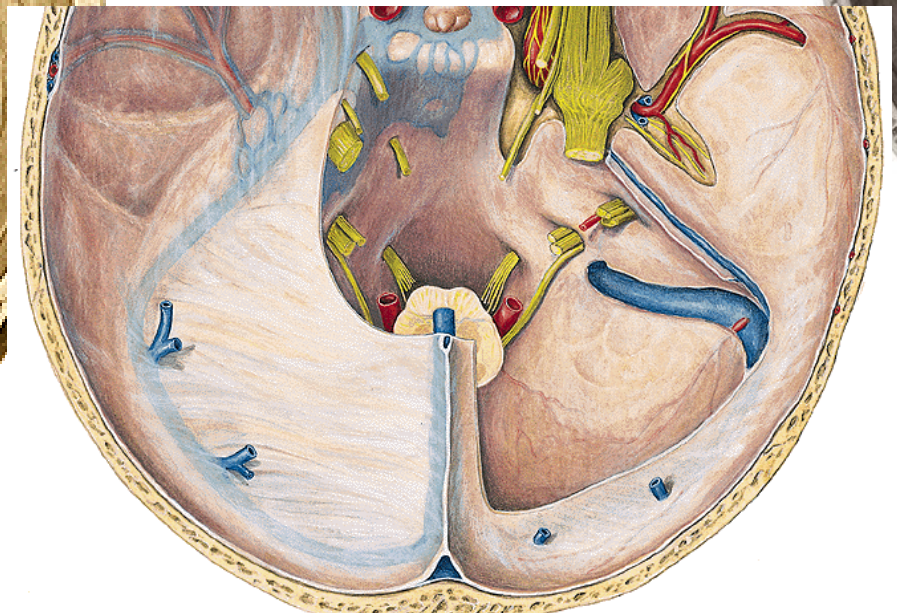
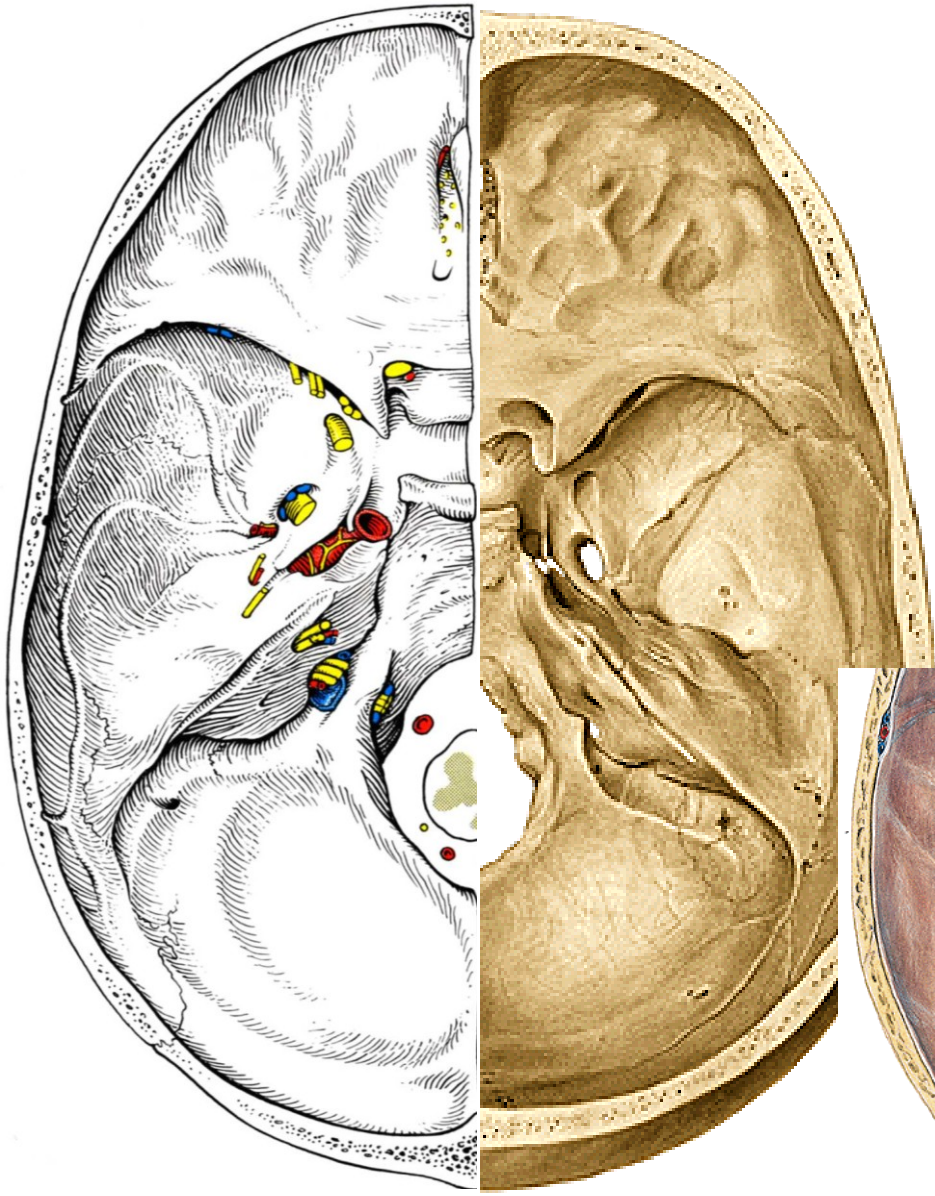
BASIS CRANII INTERNA – Fossa cranii anterior



BASIS CRANII INTERNA – Fossa cranii media



BASIS CRANII INTERNA – Fossa cranii posterior

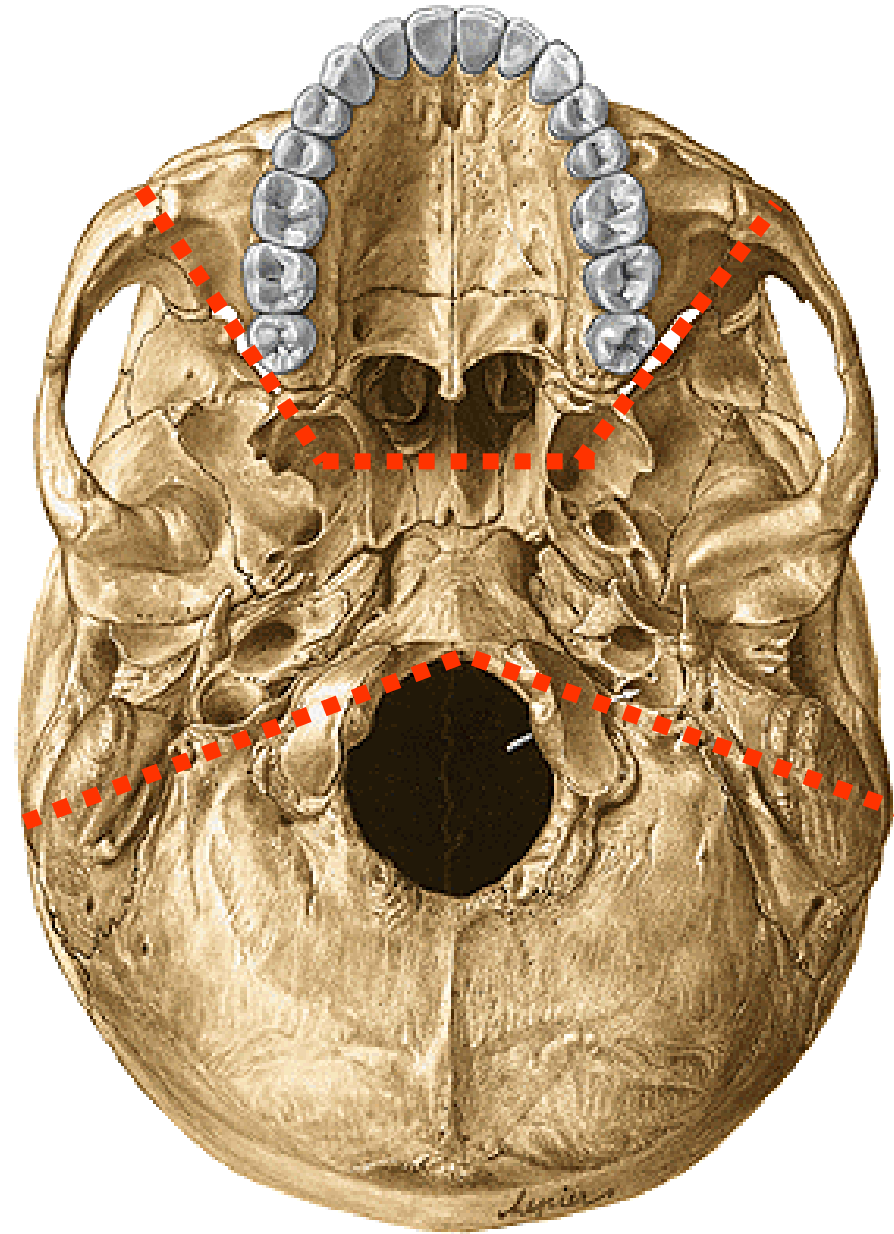


BASIS CRANII EXTERNA

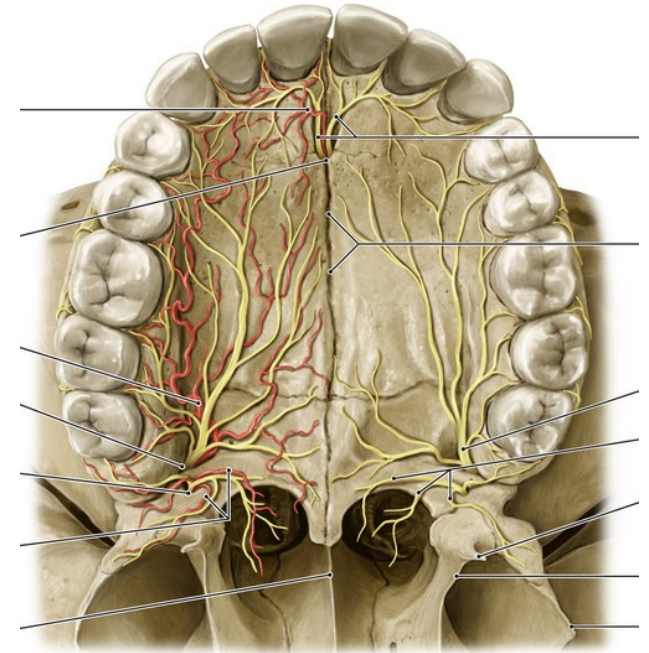
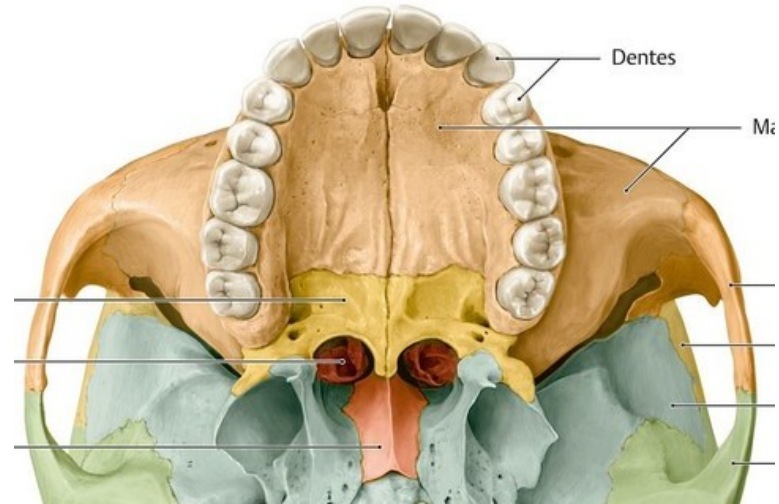
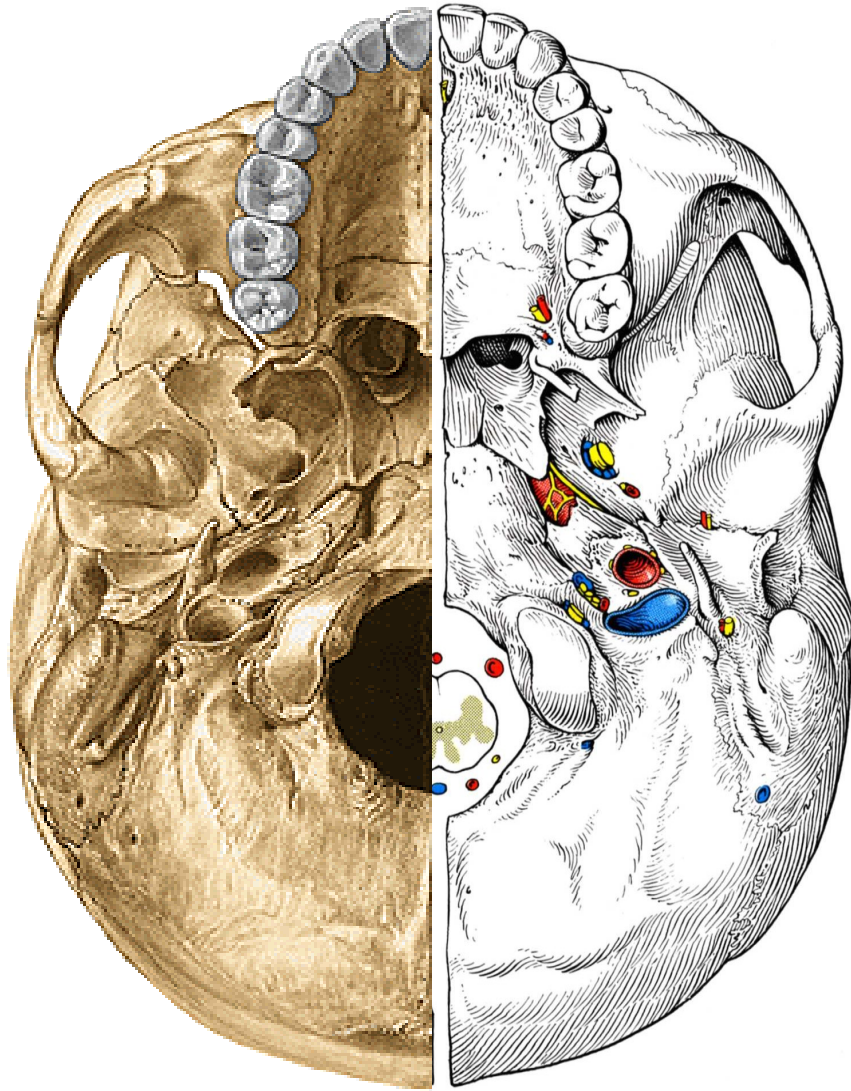
Fossa cranii anterior

Fossa cranii media

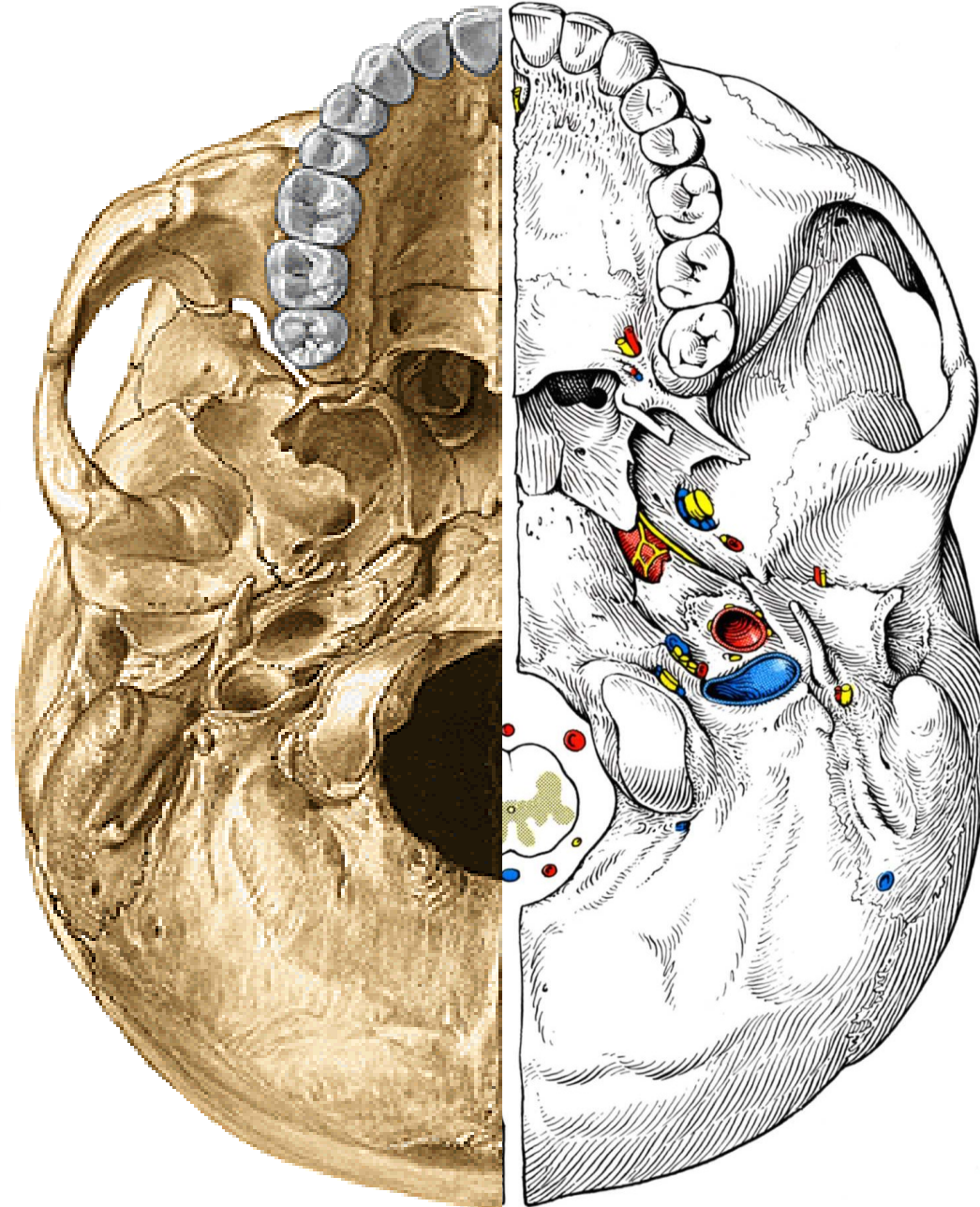
Fossa cranii posterior



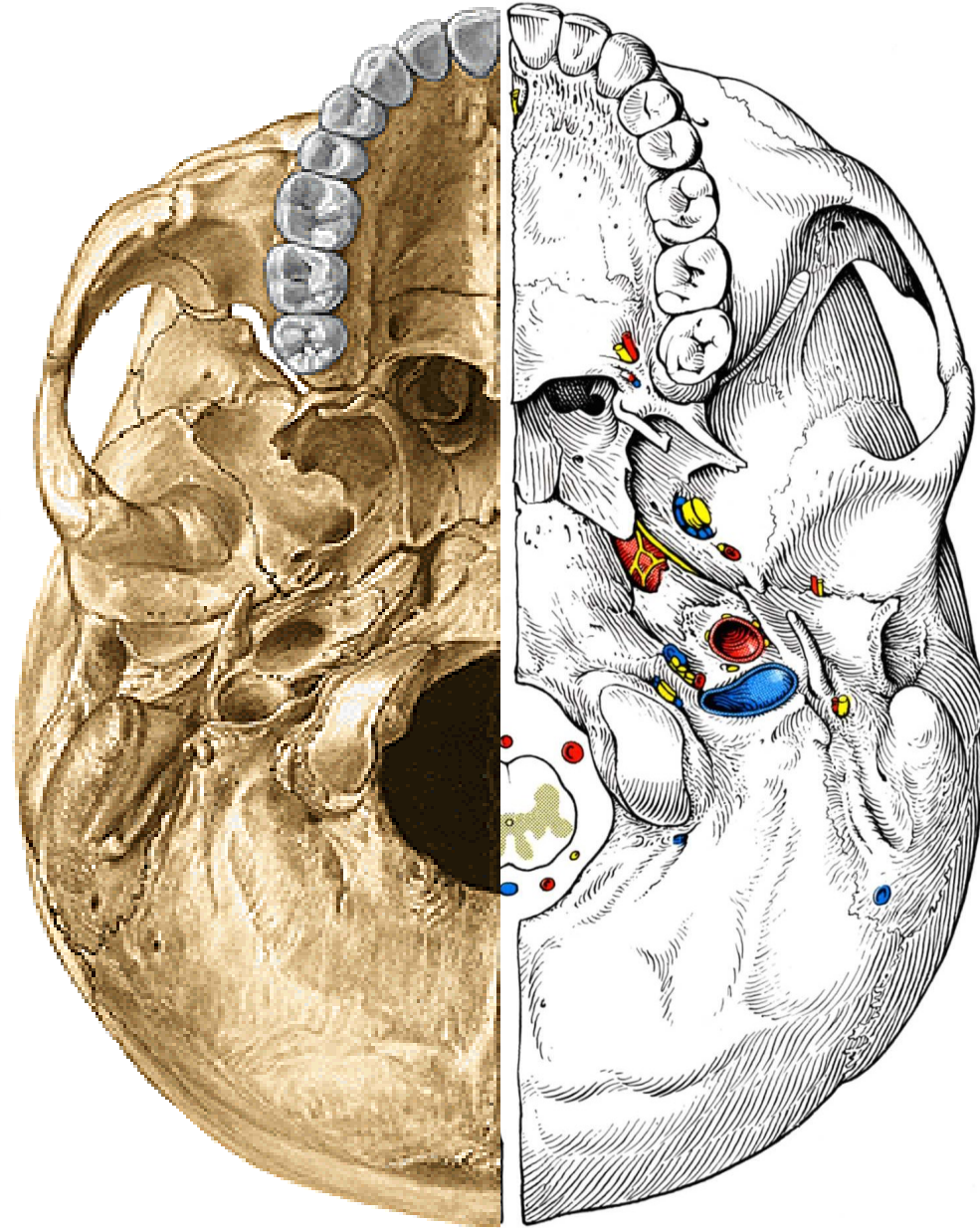
BASIS CRANII EXTERNA – fossa cranii anterior



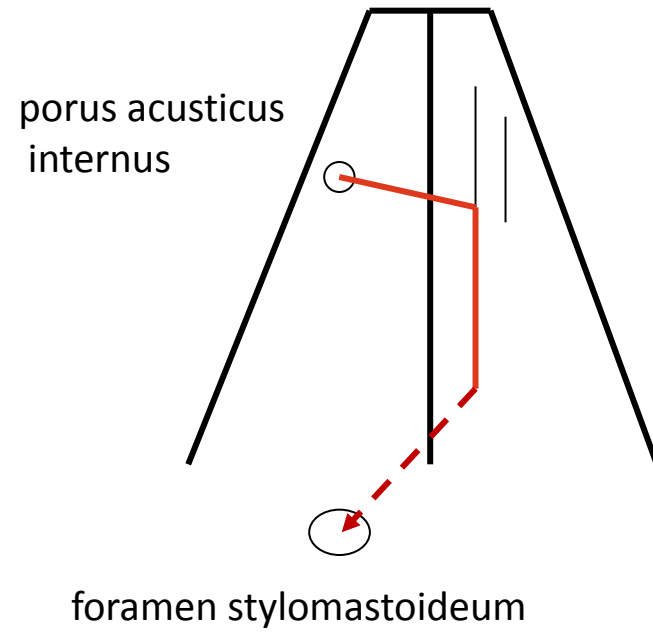
BASIS CRANII EXTERNA – fossa cranii media



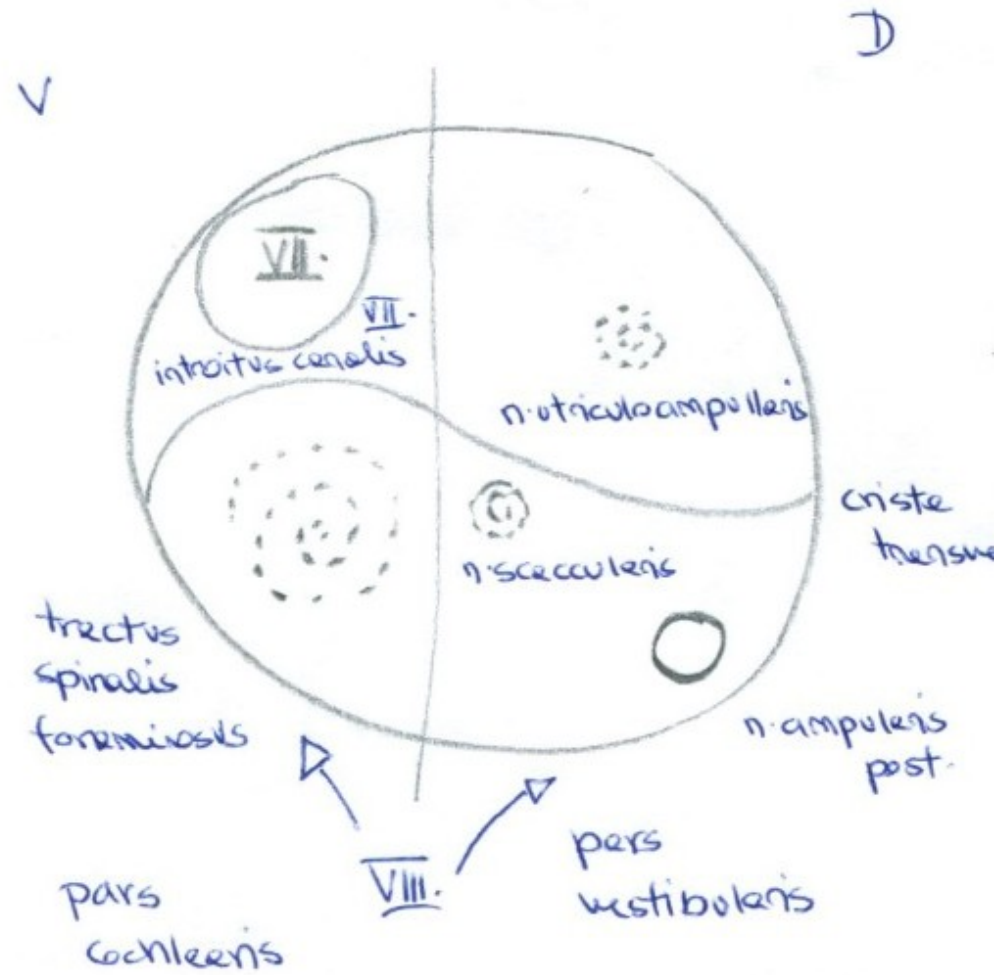
BASIS CRANII EXTERNA – fossa cranii posterior (os occipitale)



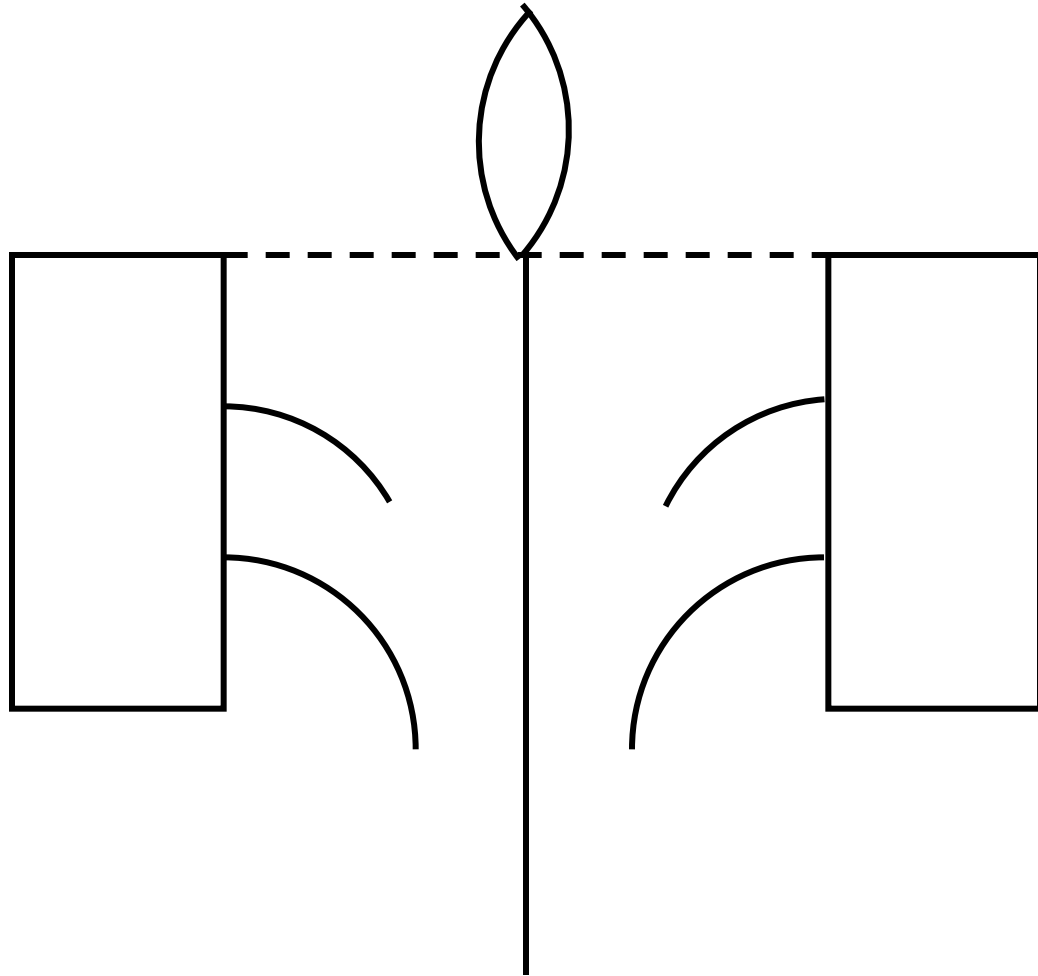
Canalis n. facialis



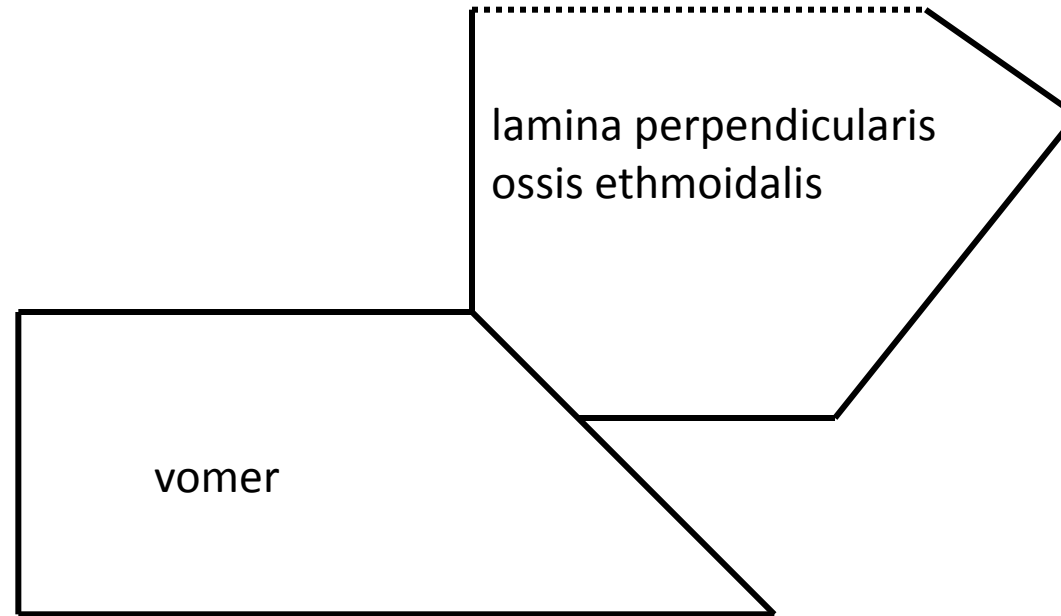
Porus acousticus internus



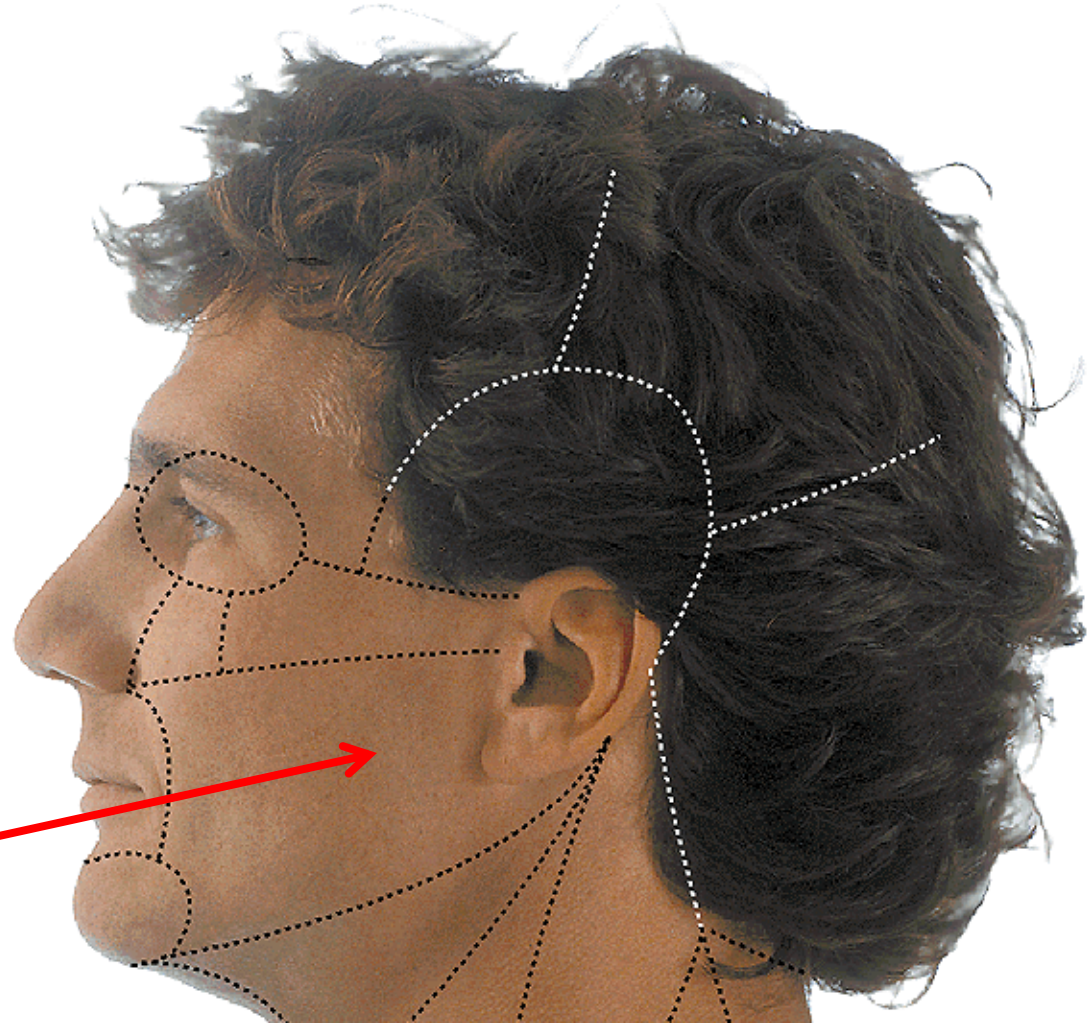
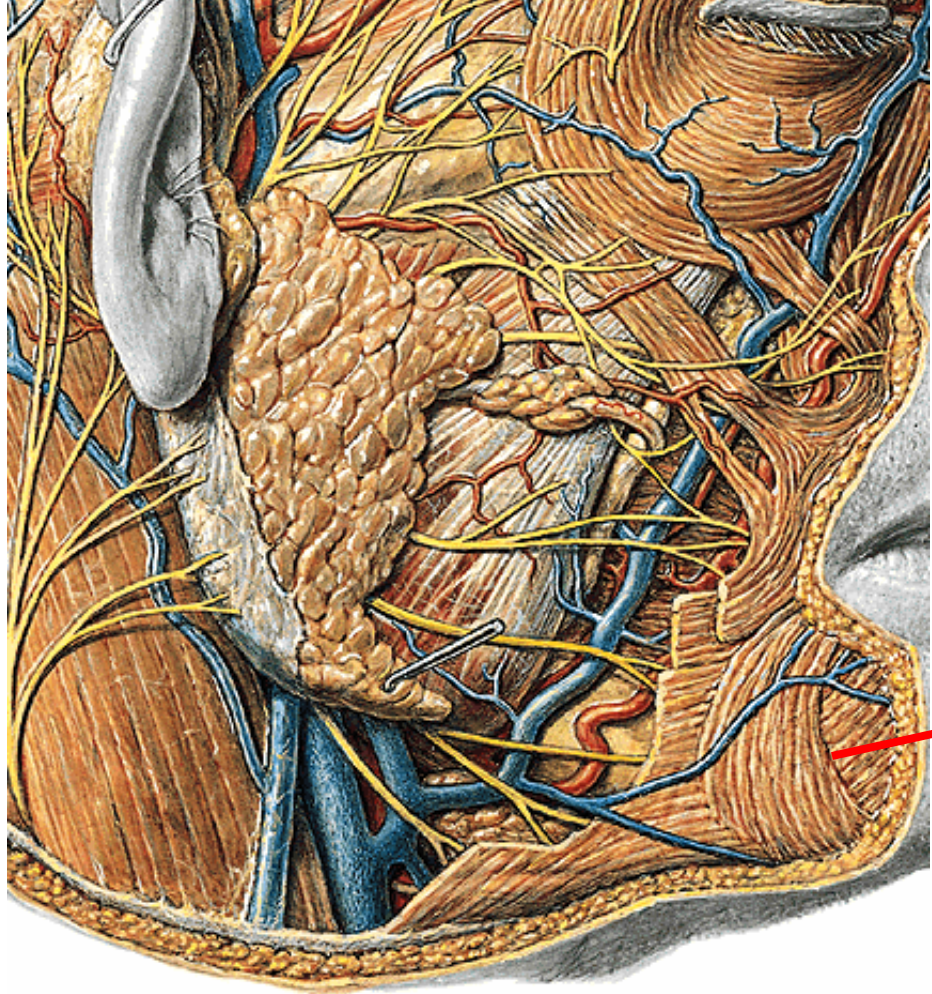
Os ethmoidale



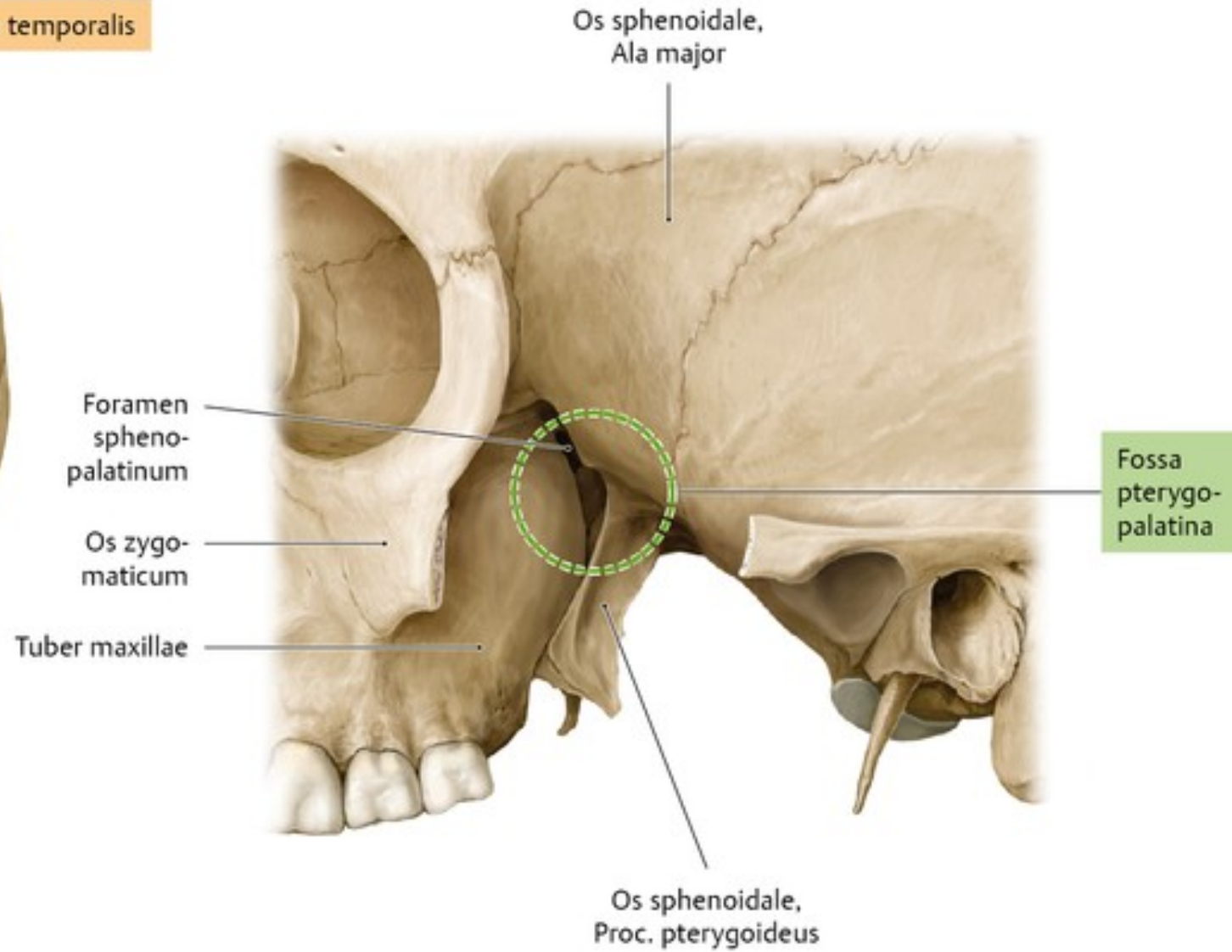
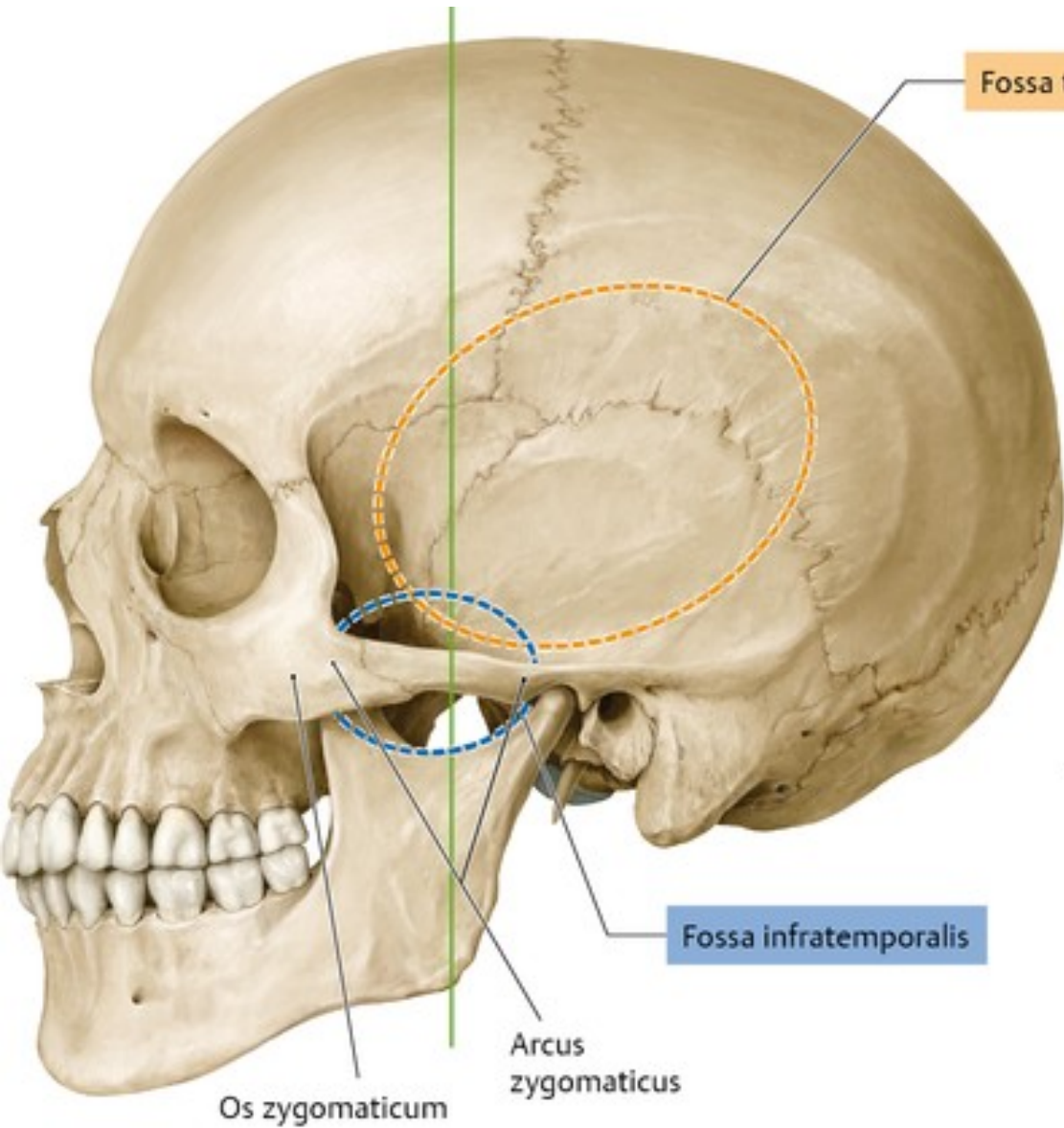
SEPTUM NASI OSSEUM

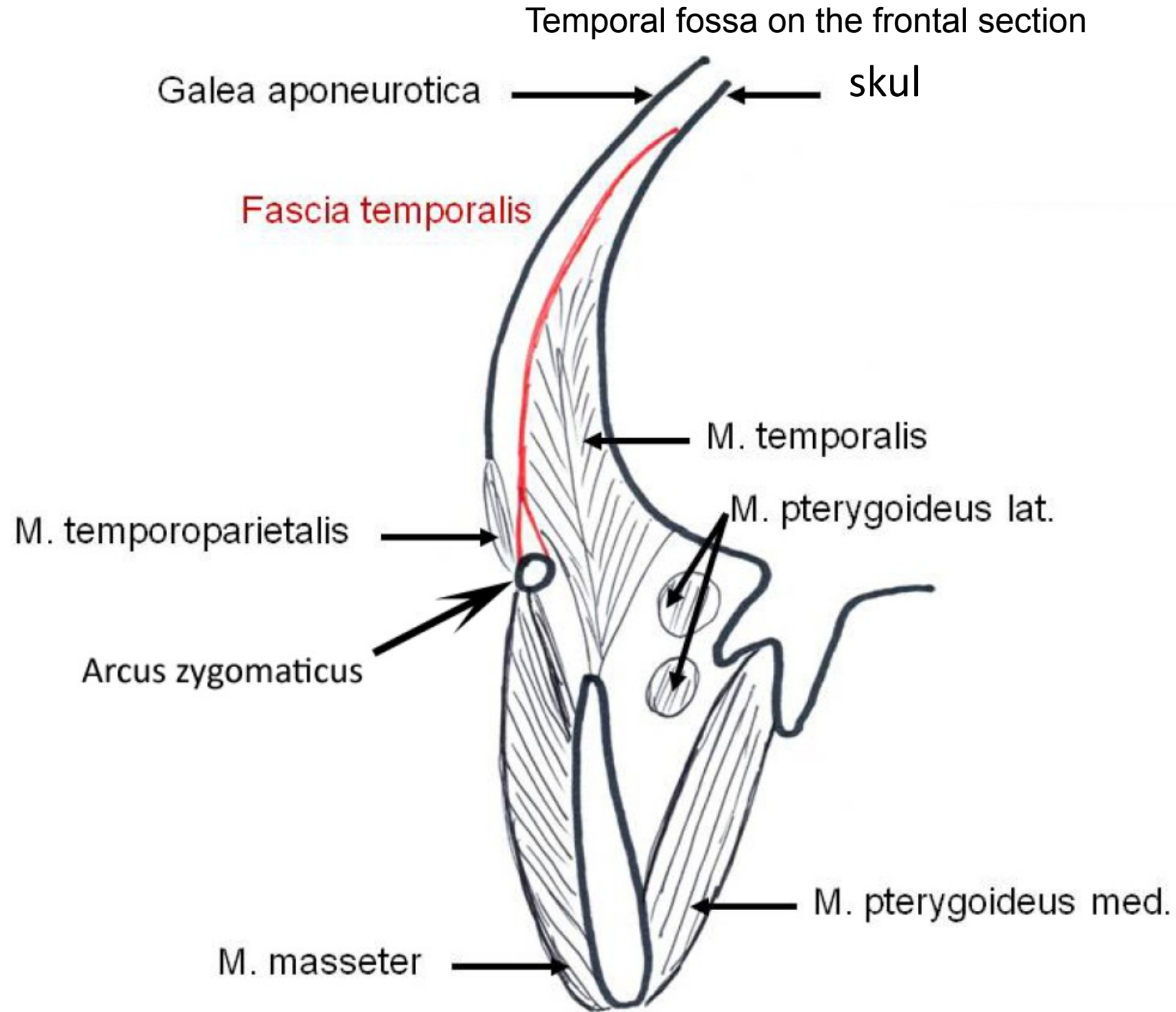


Regio parotideomasseterica

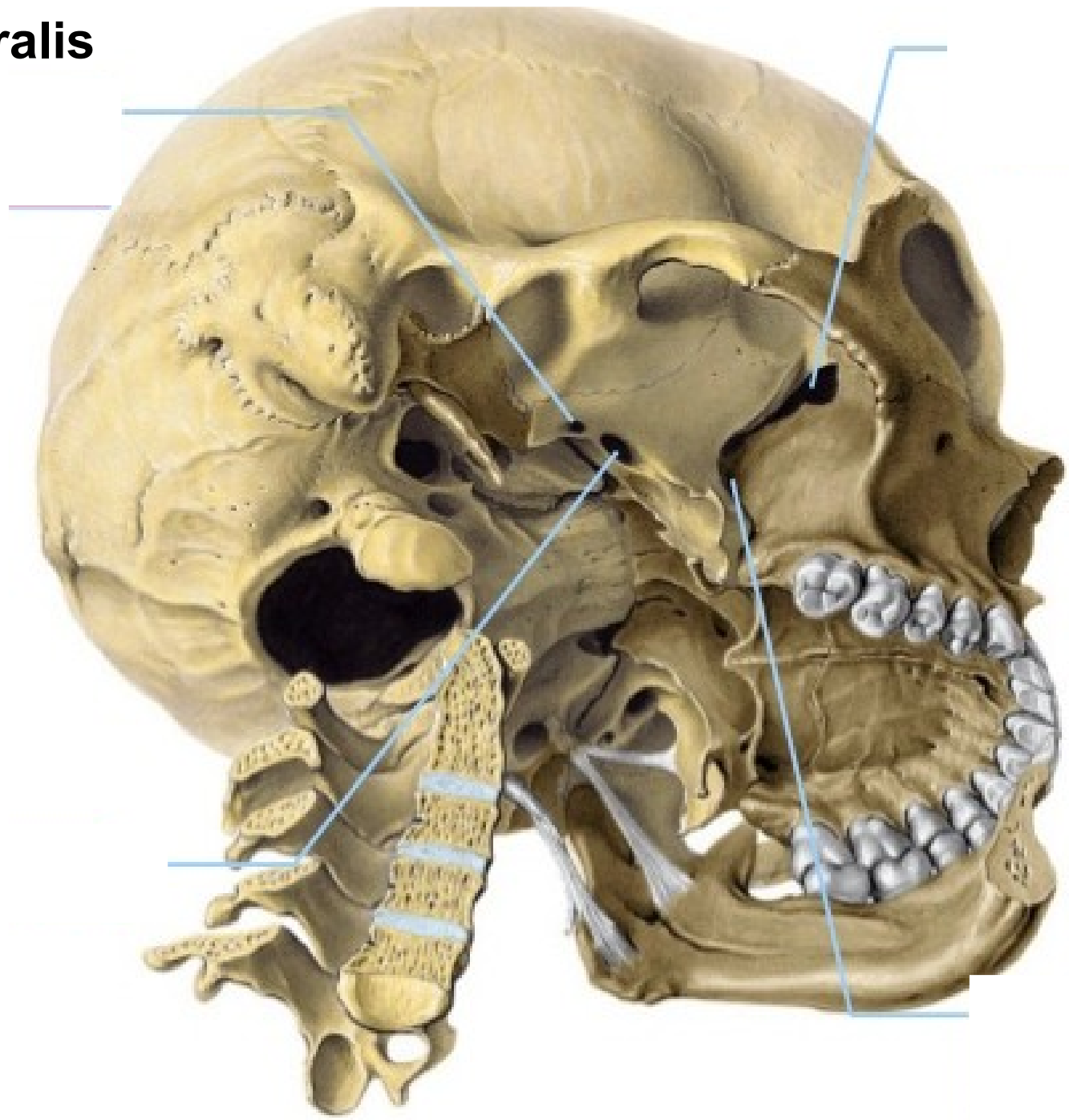


Fossa temporalis



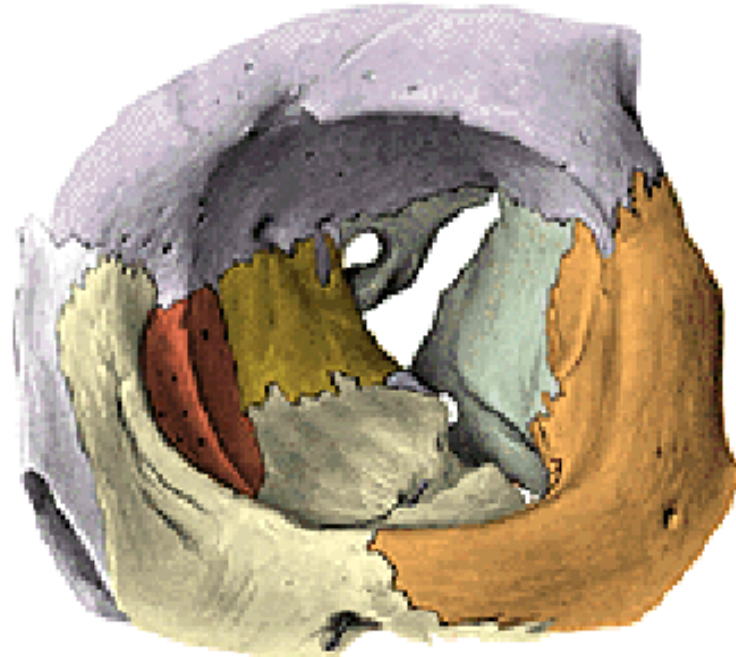
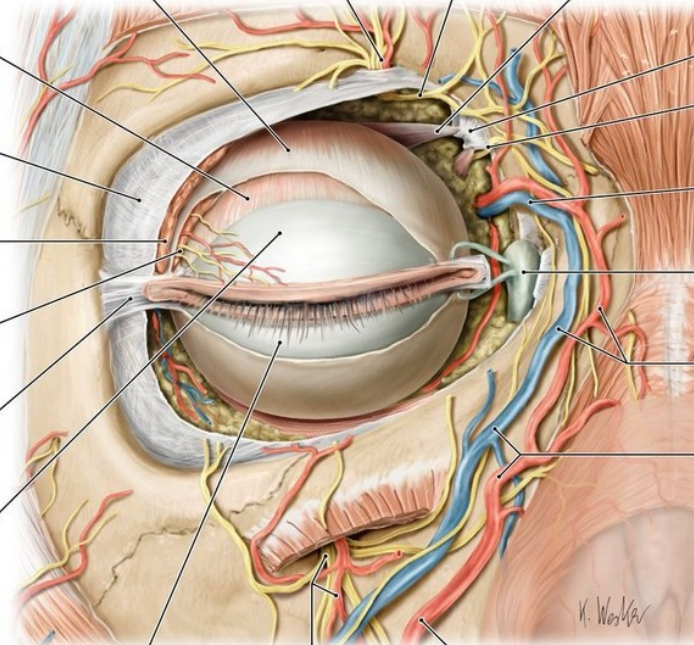
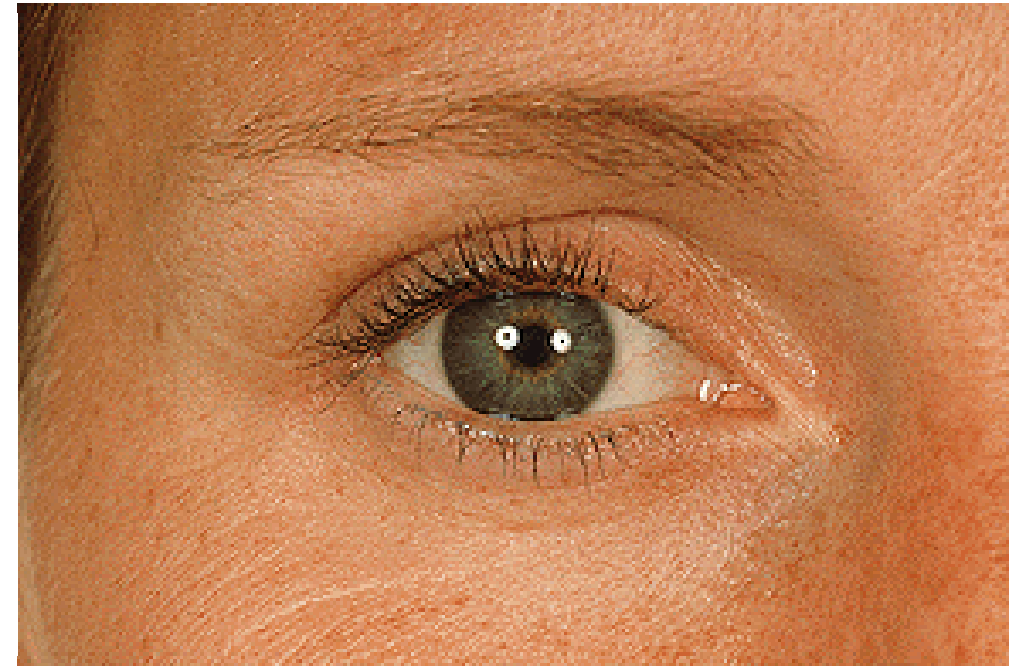
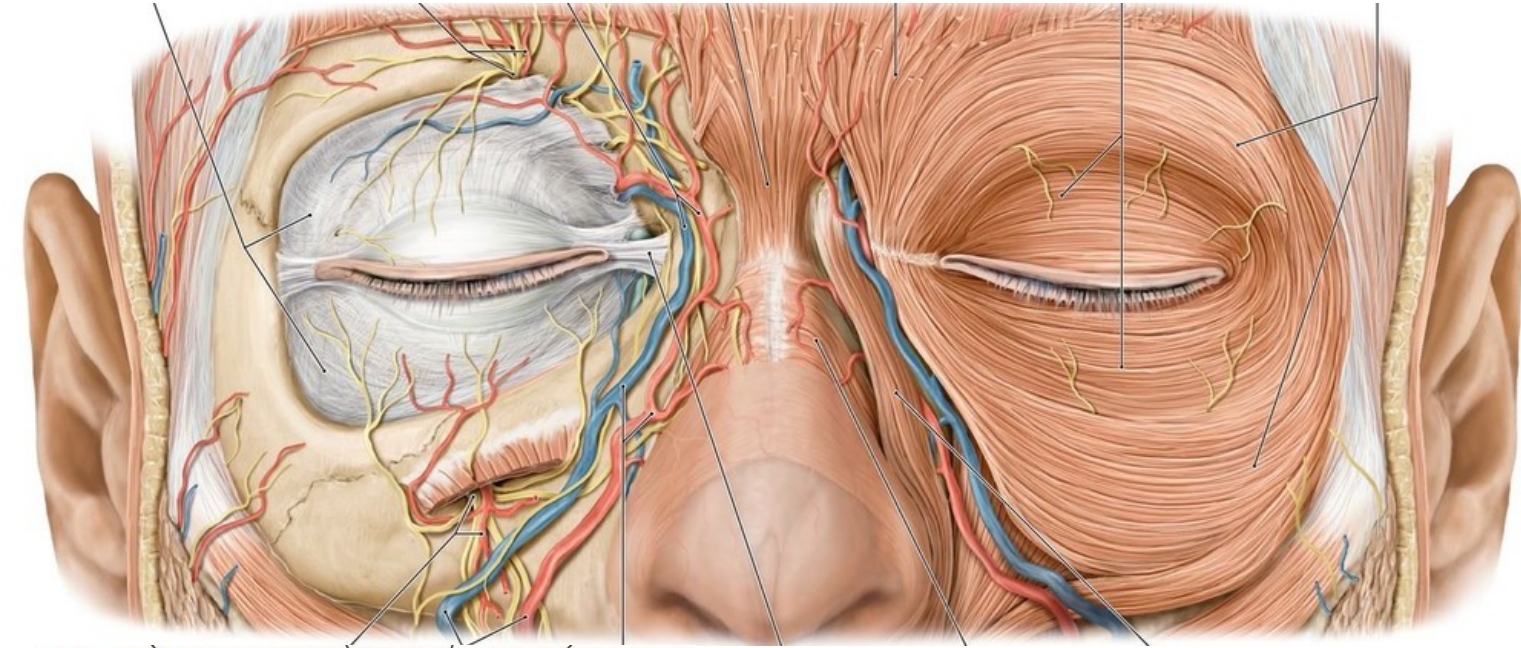


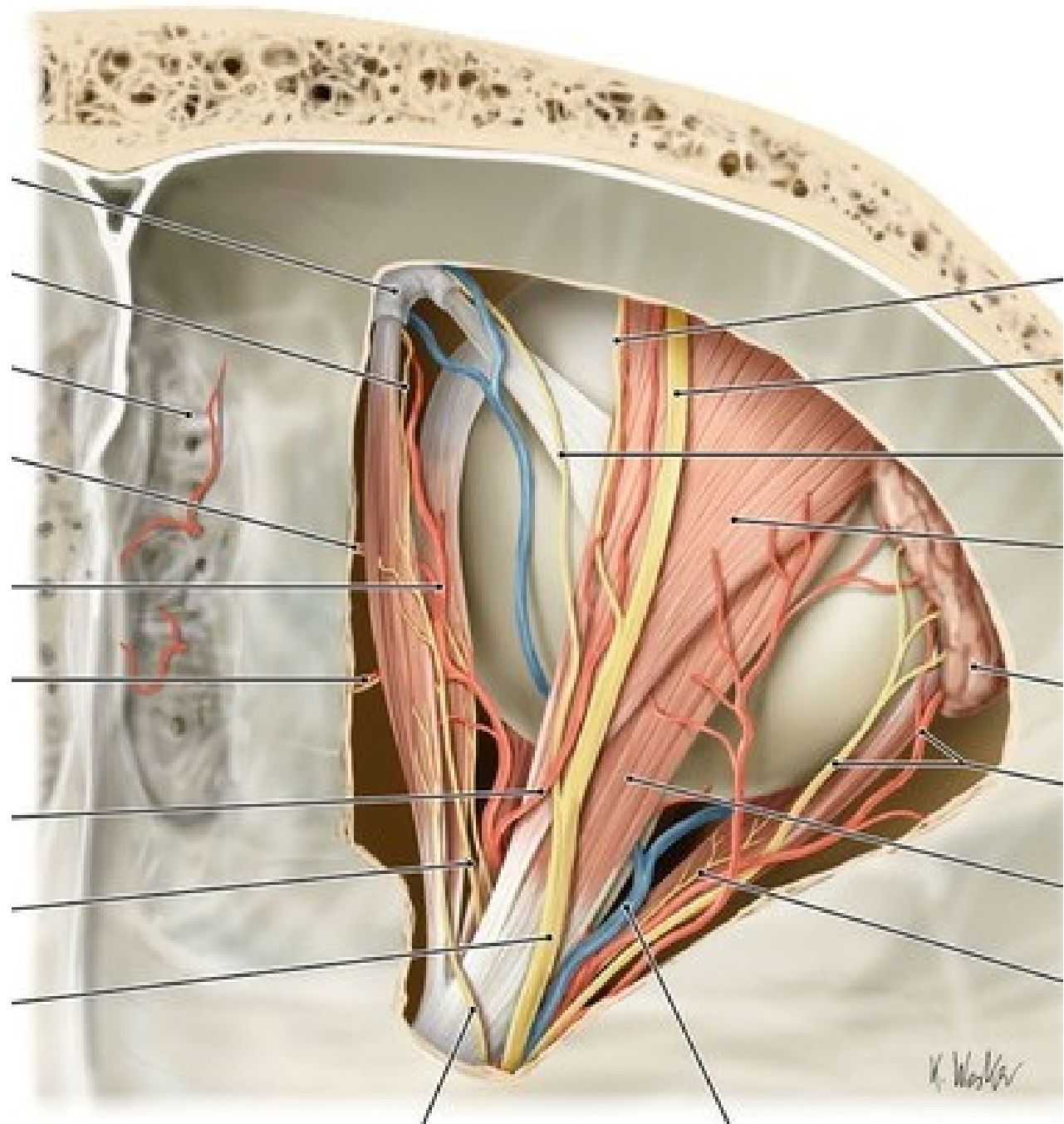
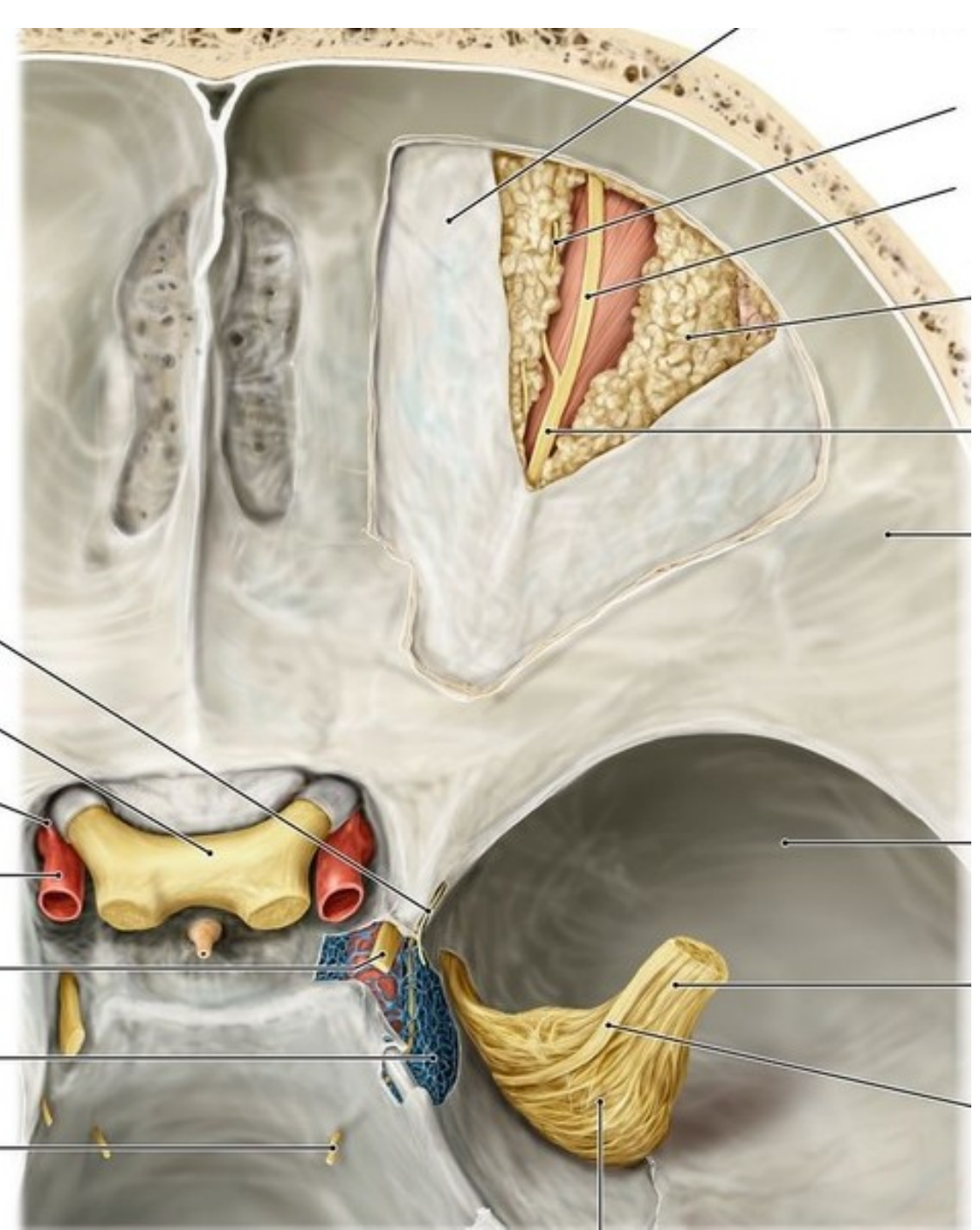
Fossa infratemporalis

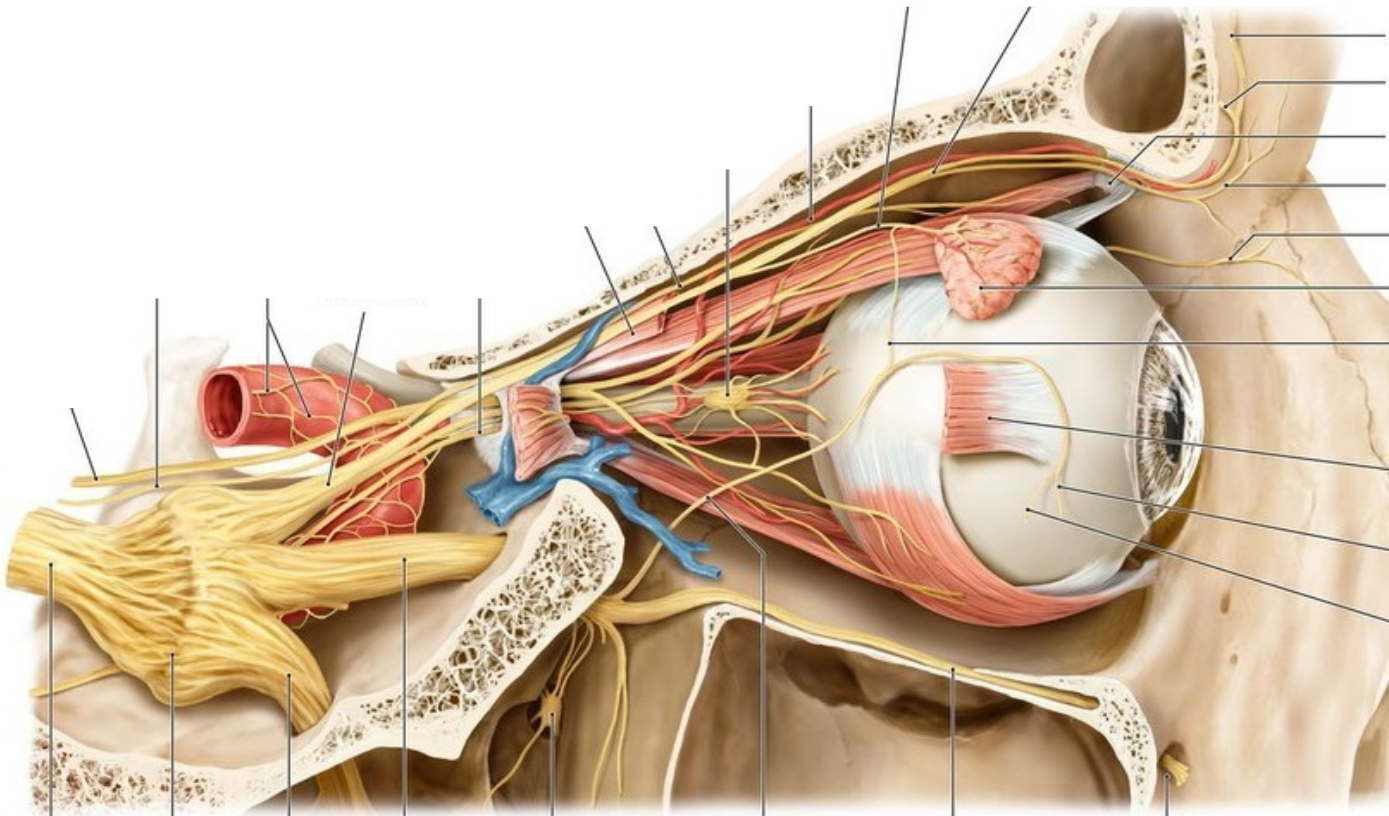
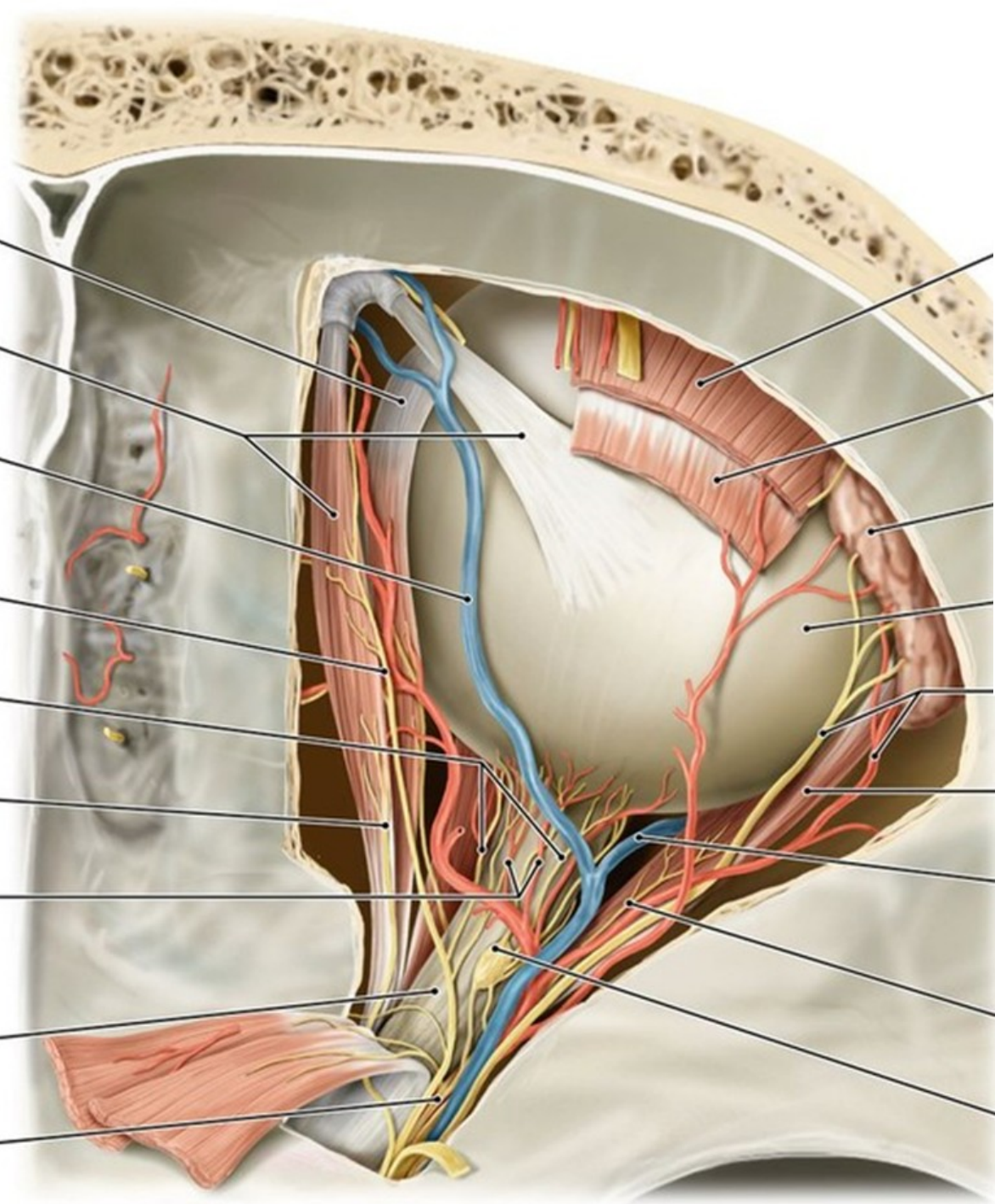


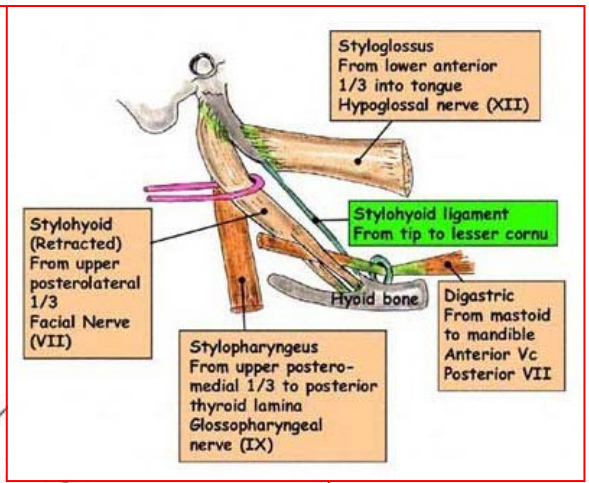
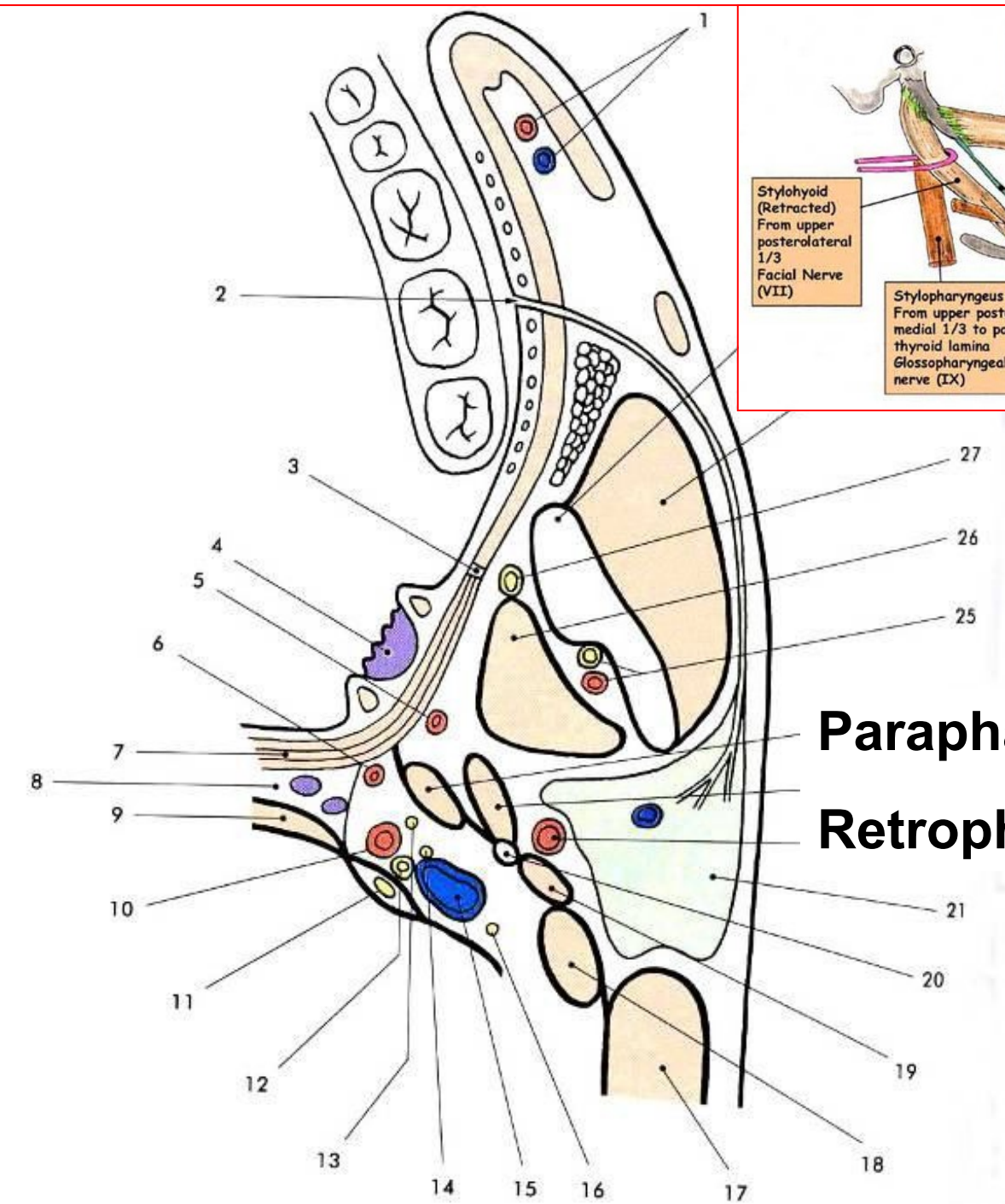
Fossa pterygopalatina

Regio orbitalis



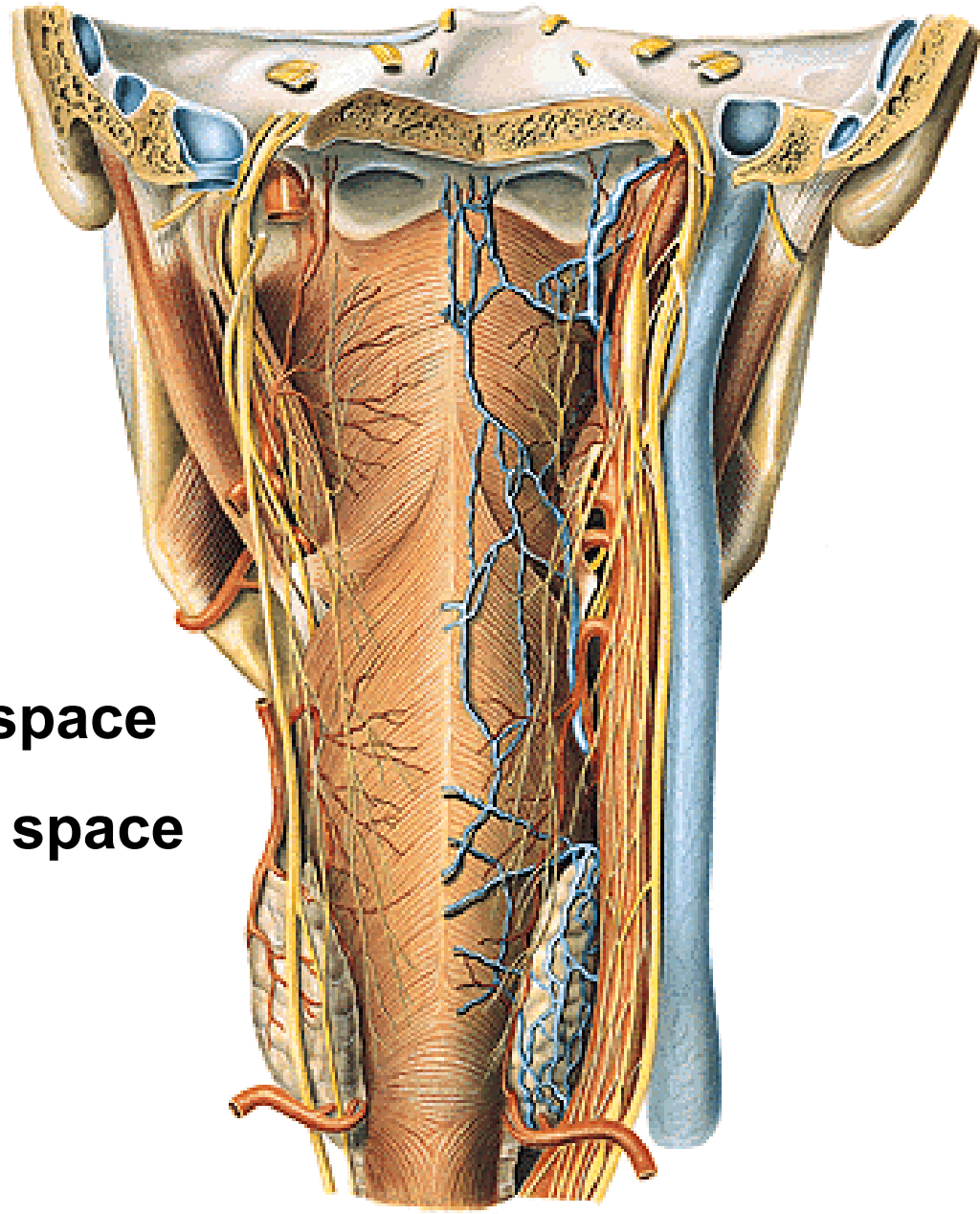




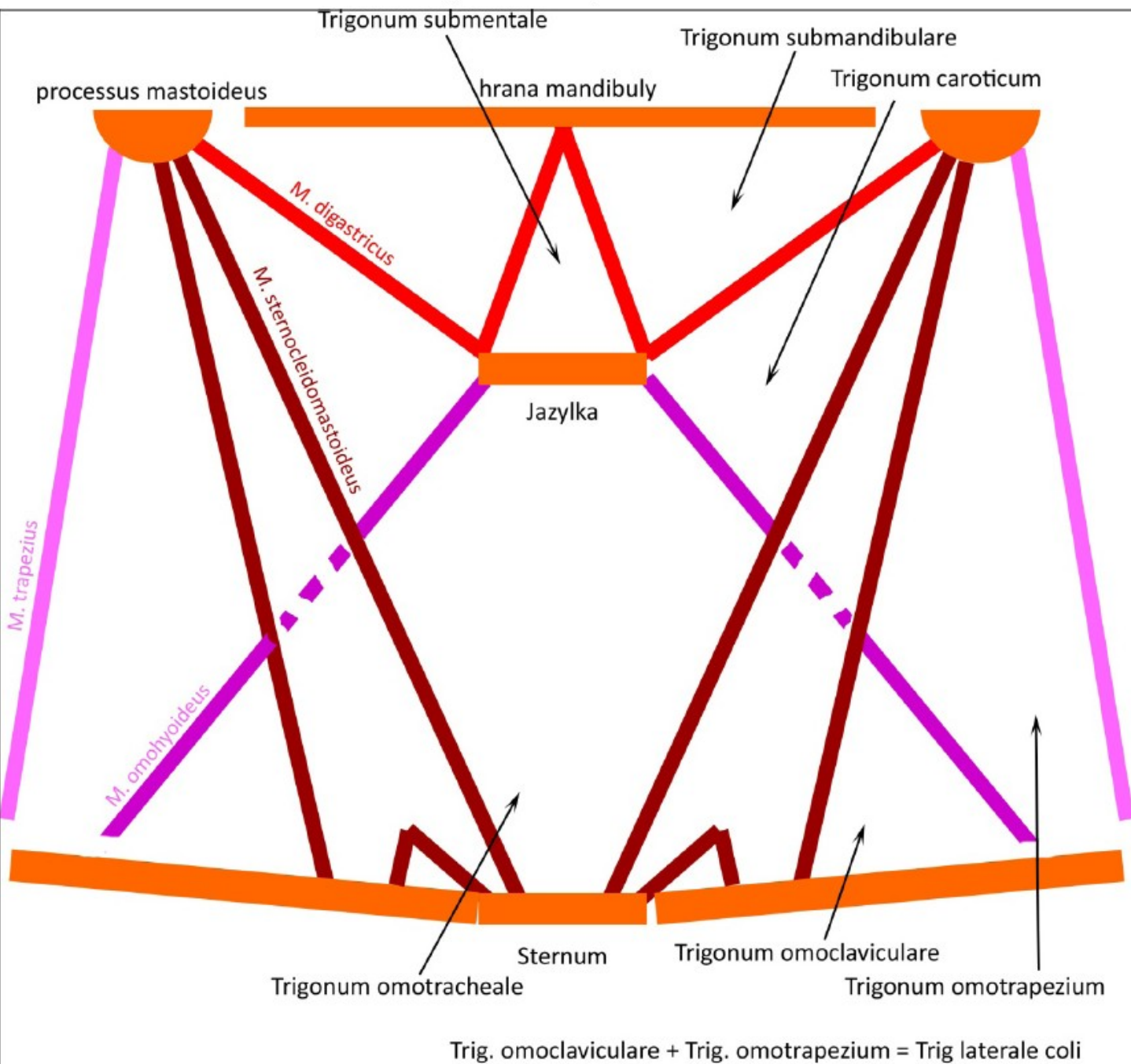


Parapharyngeal space
Retropharyngeal space

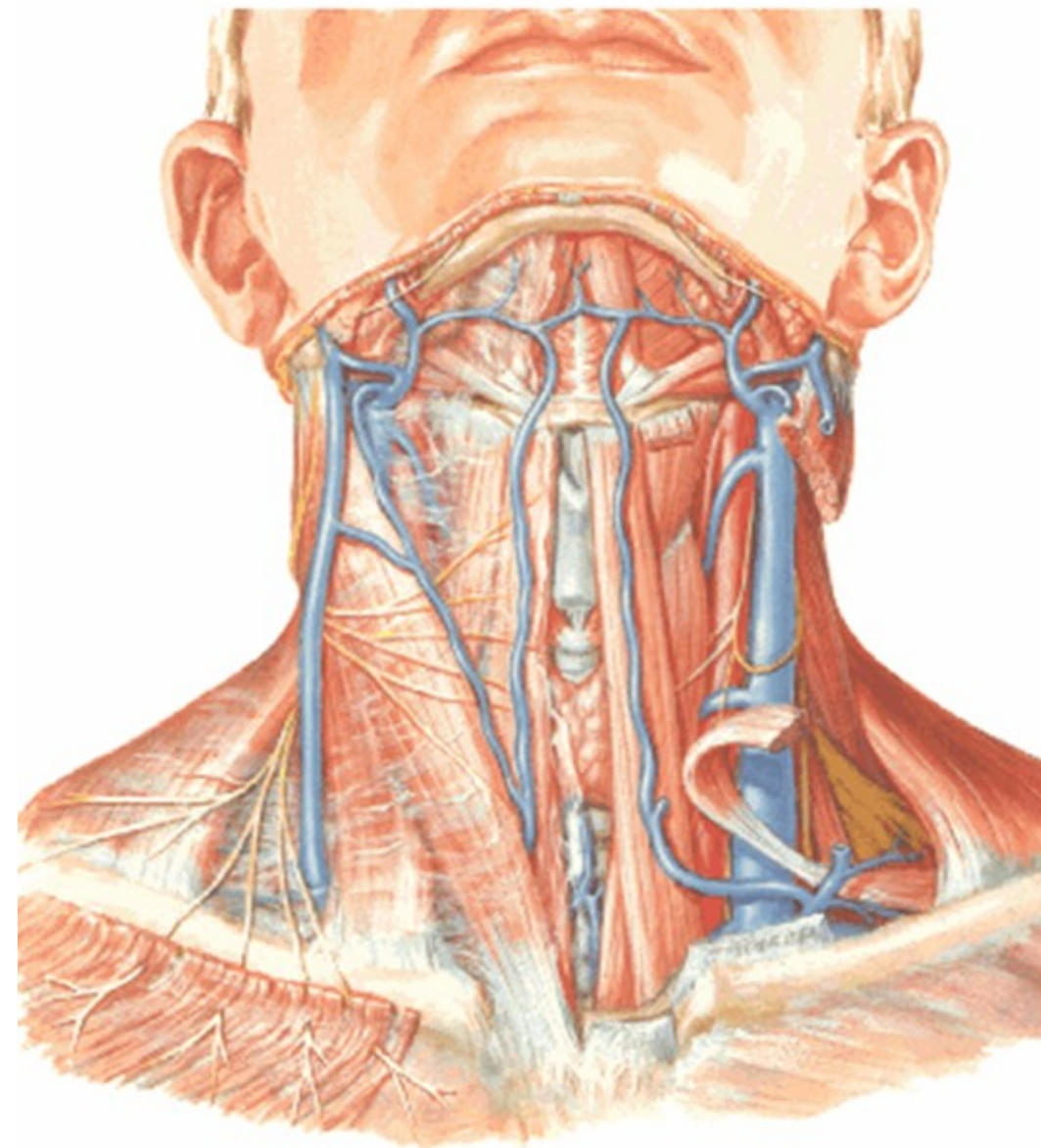
Styloid septum

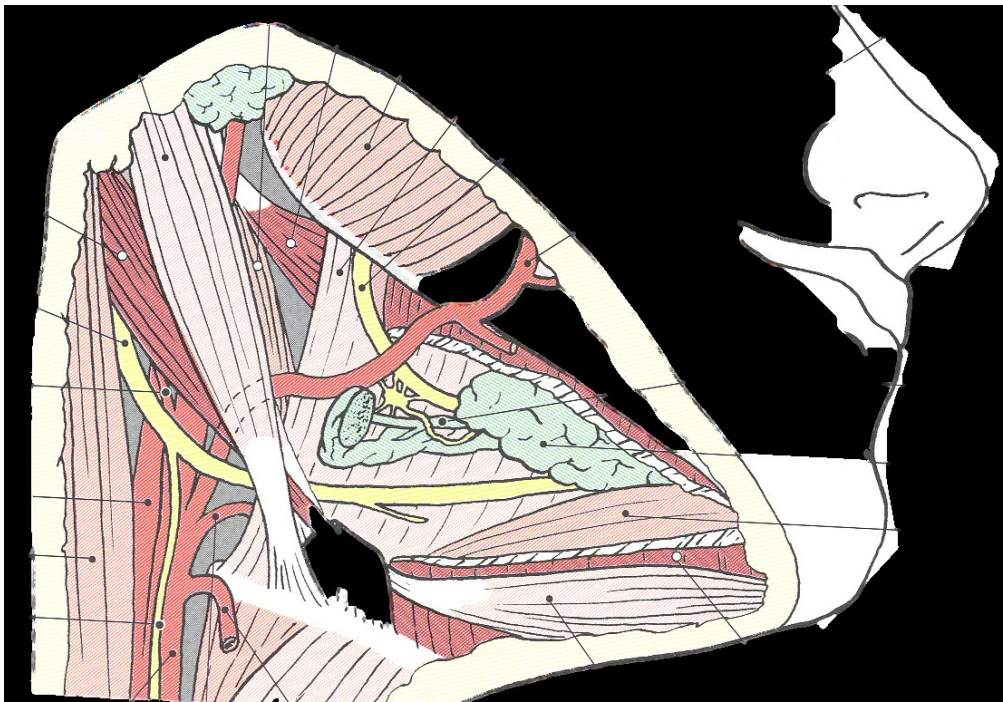


Trojúhelníky na krku

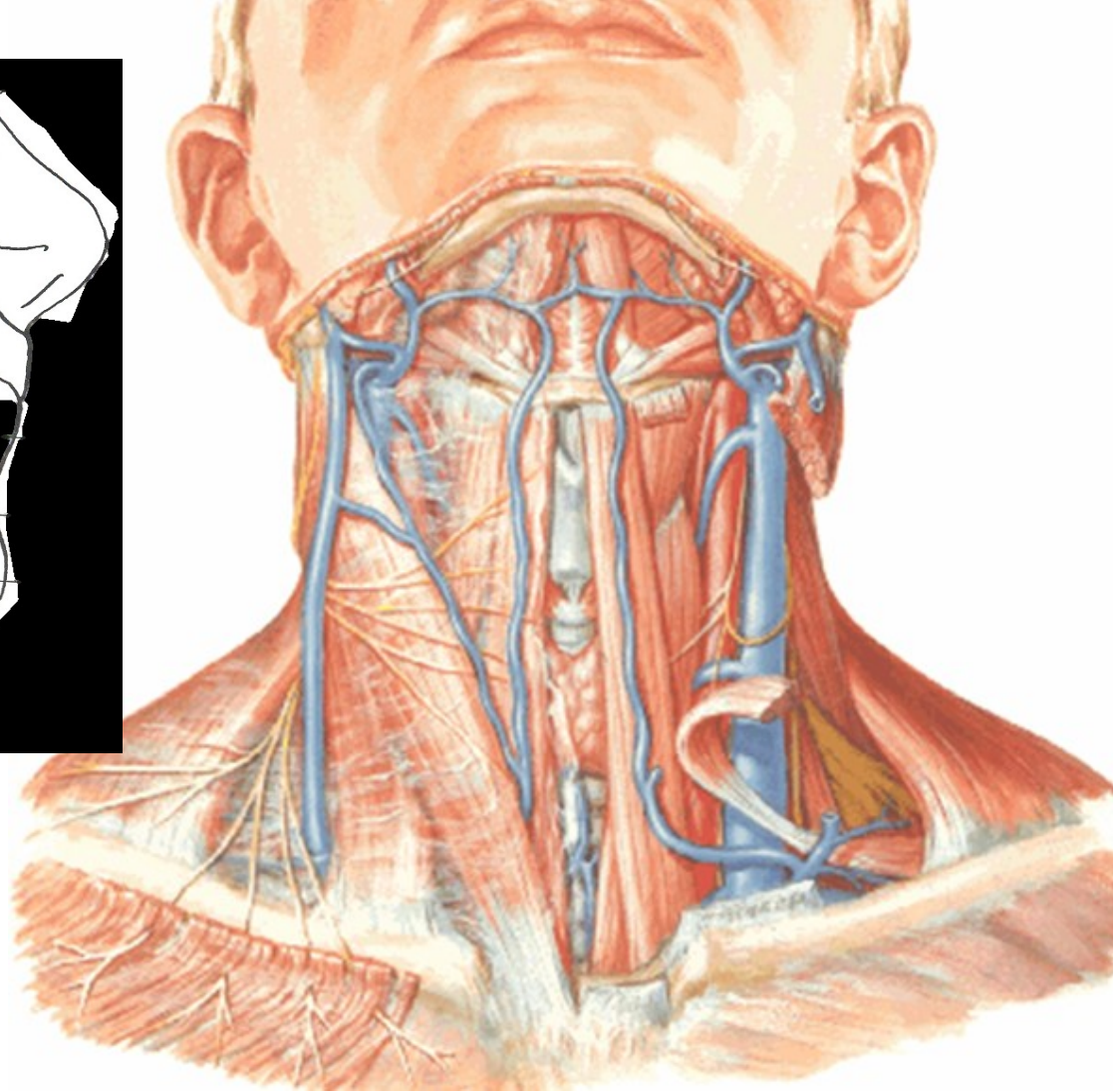


Neck regiones

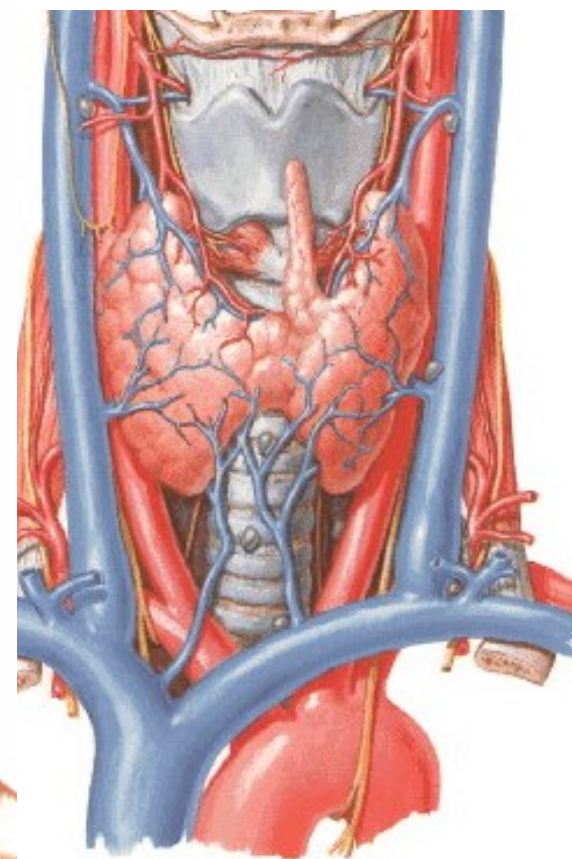


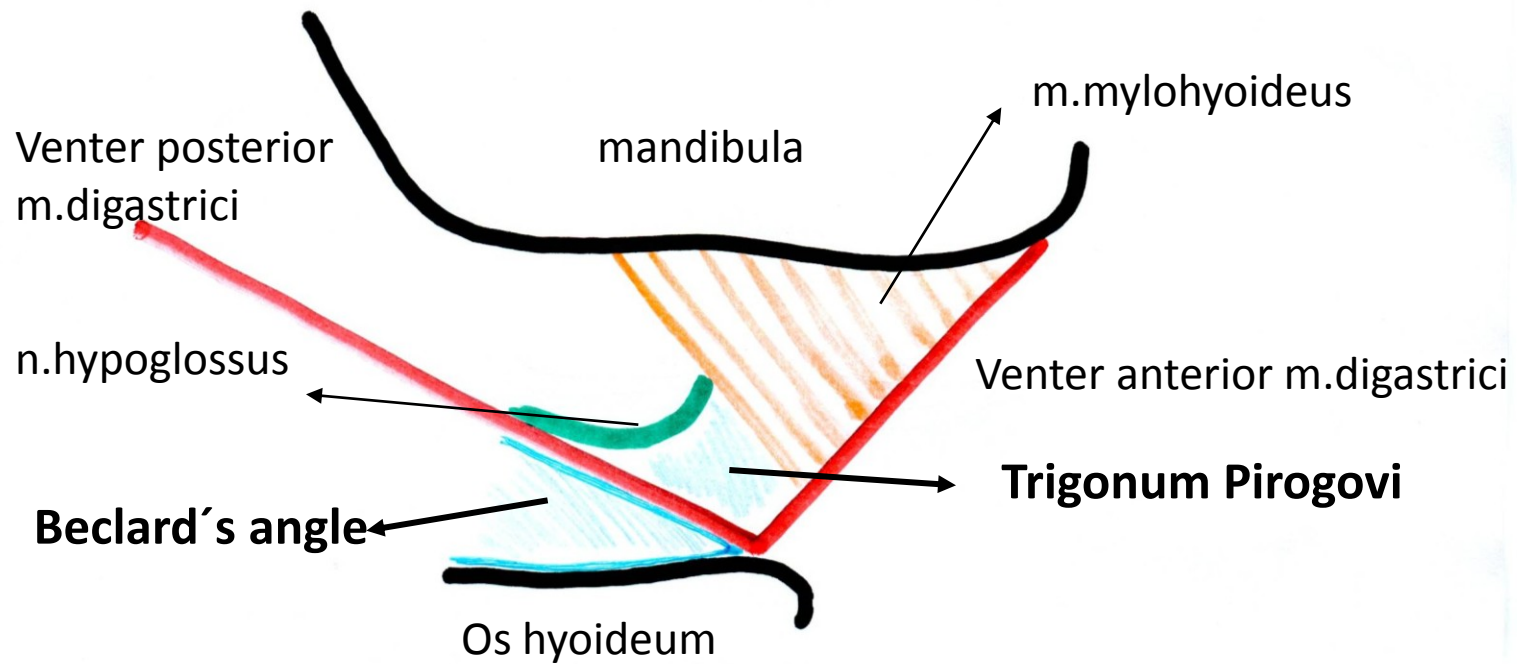
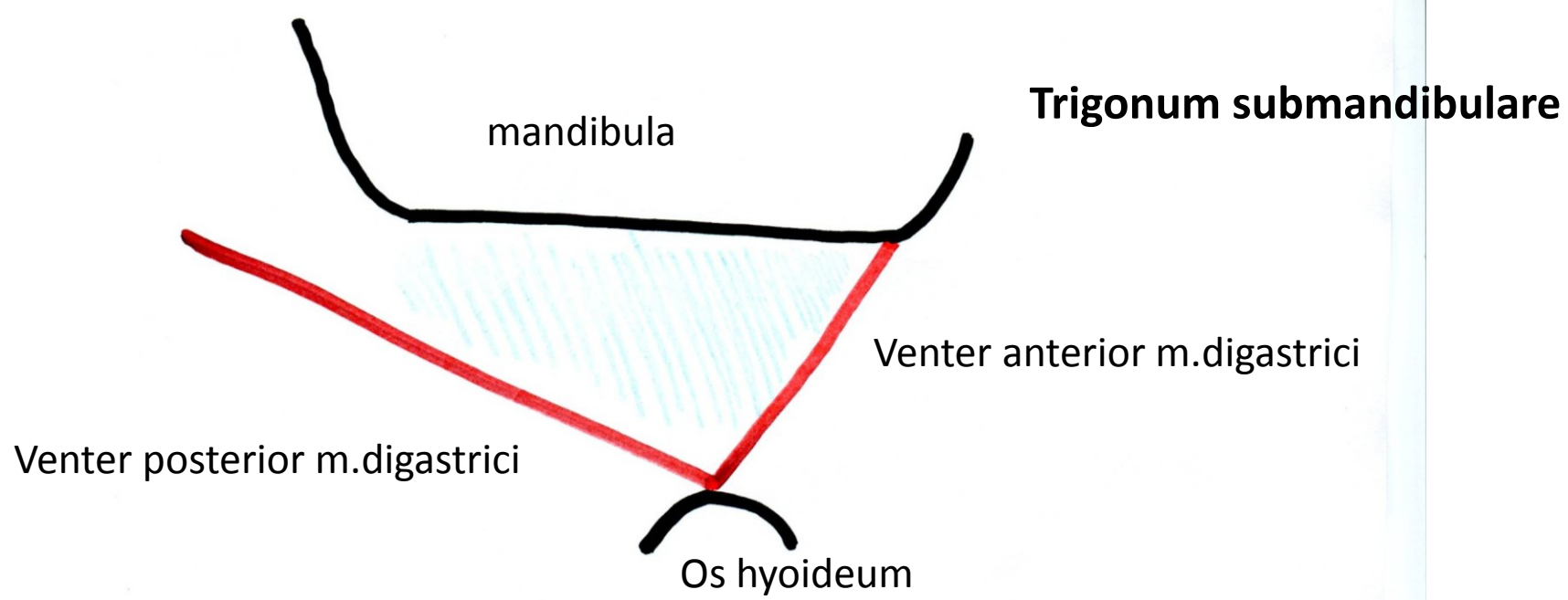


Trigonum submandibulare

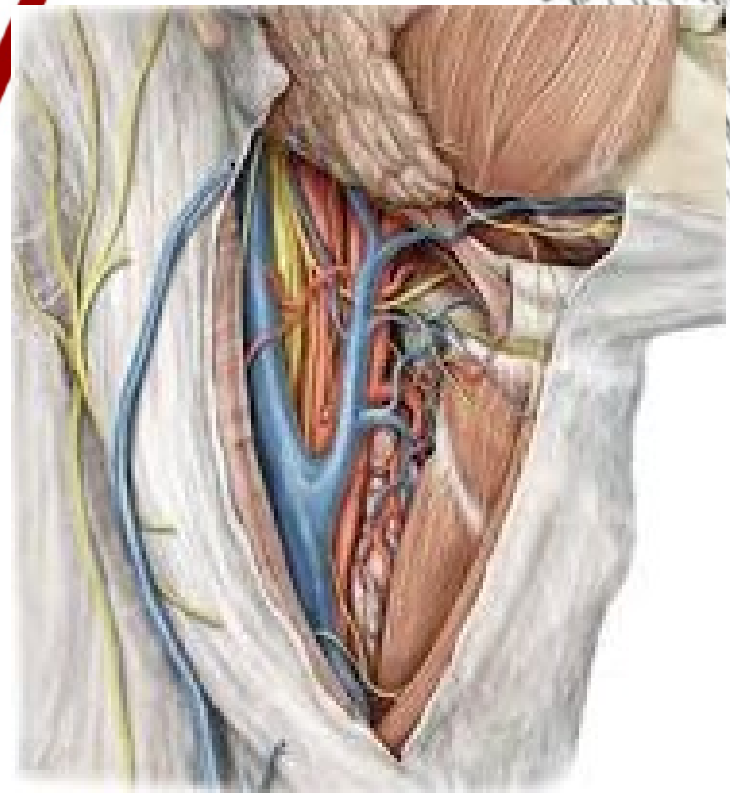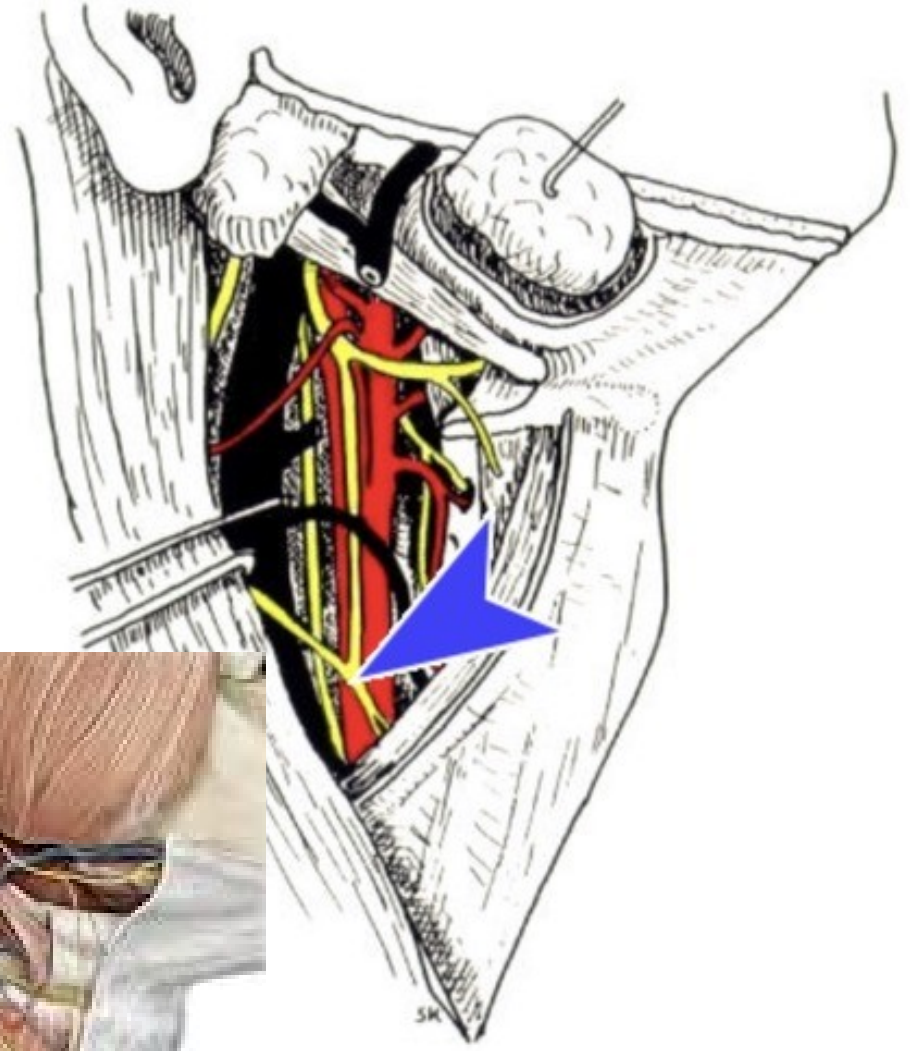
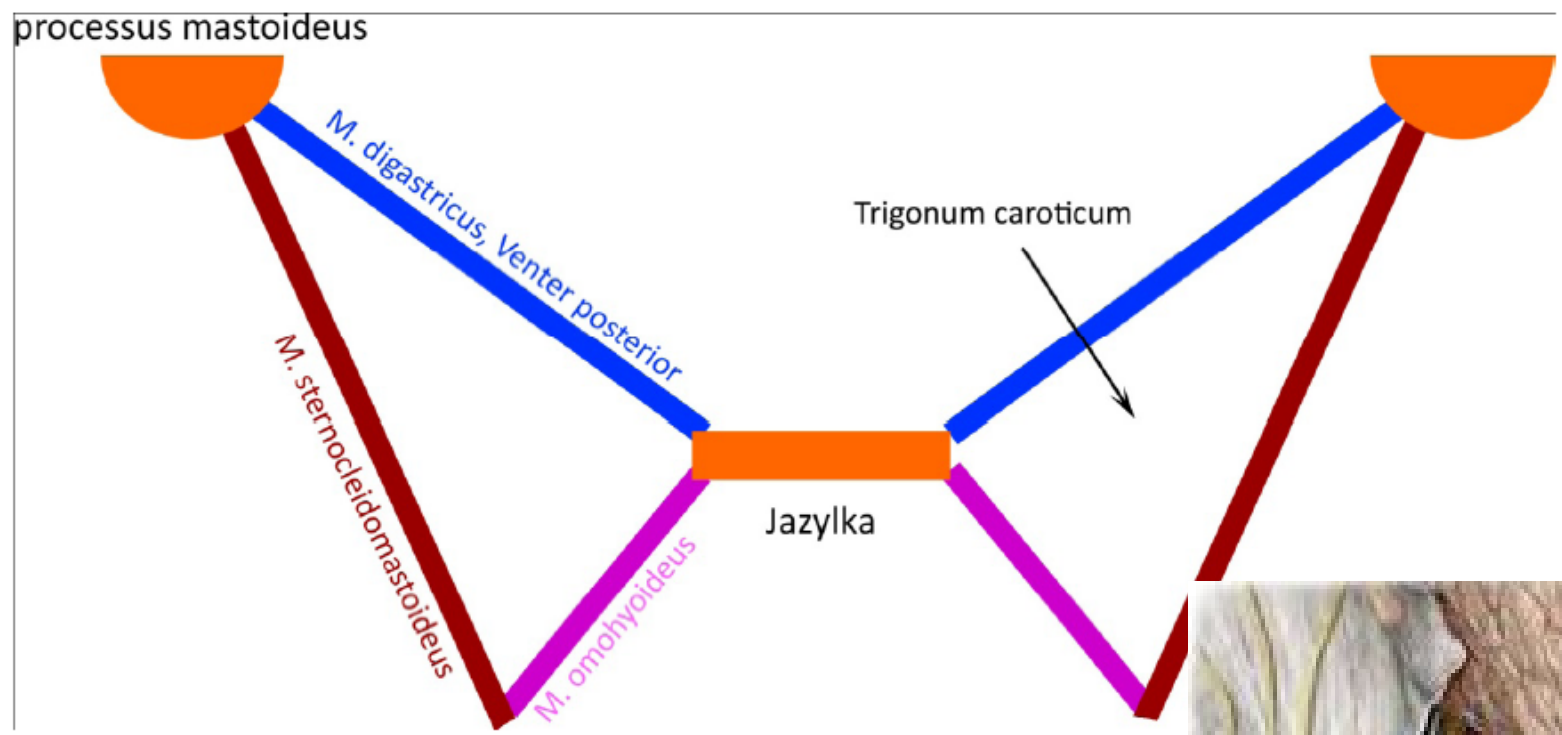


Trigonum submentale, omotracheale

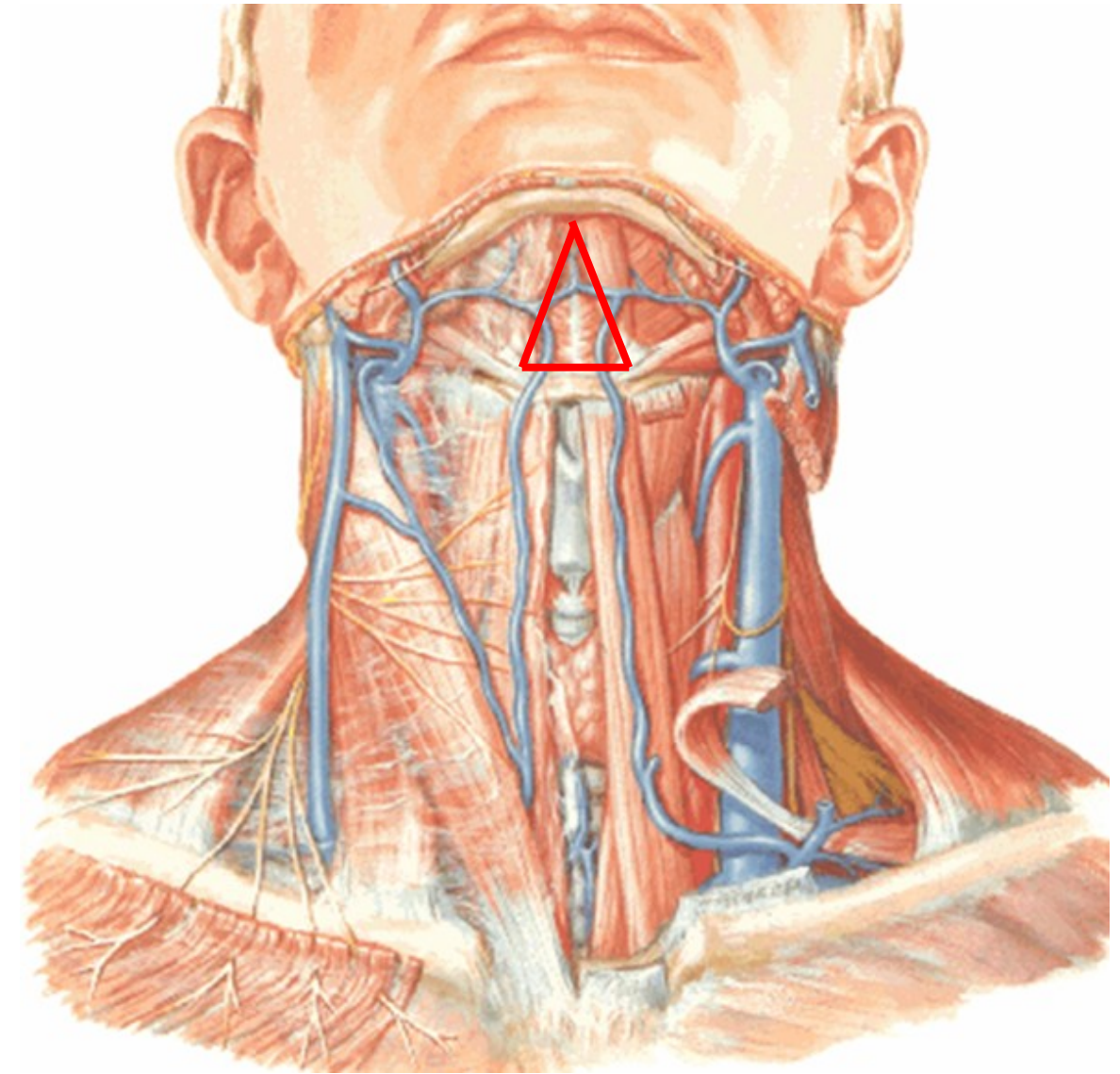
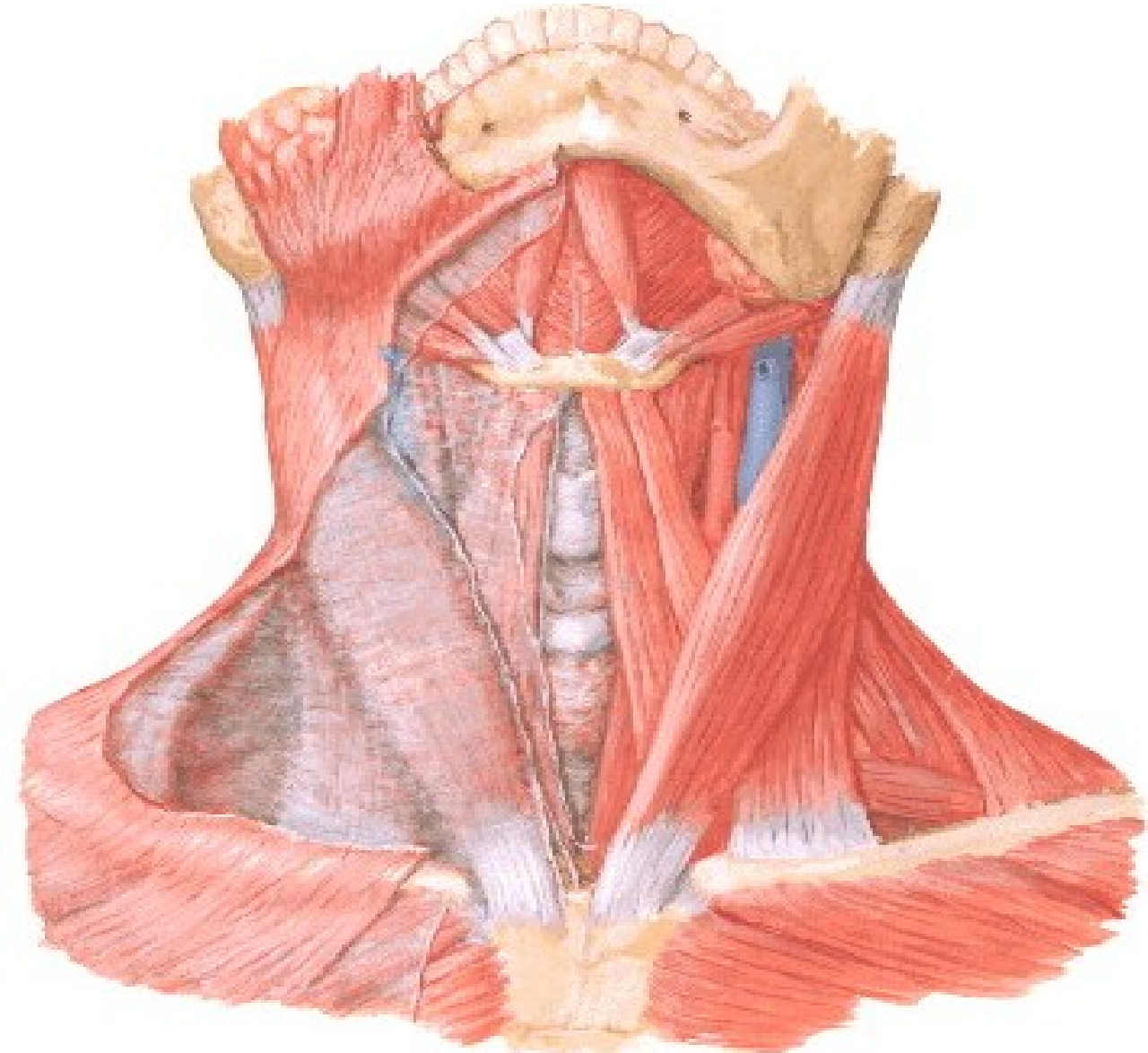




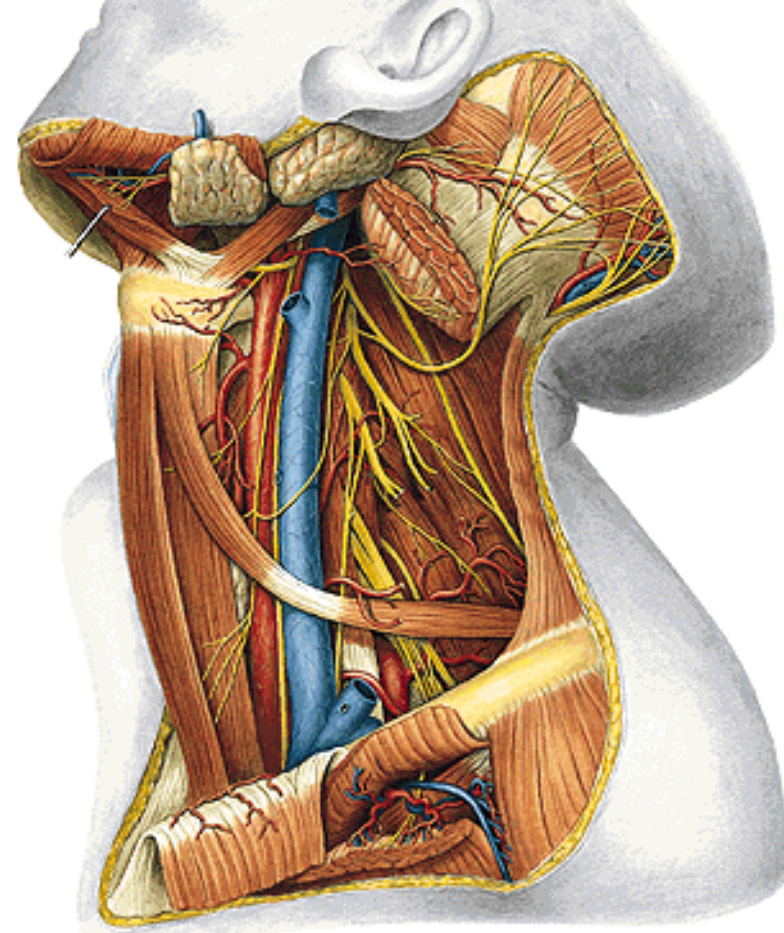
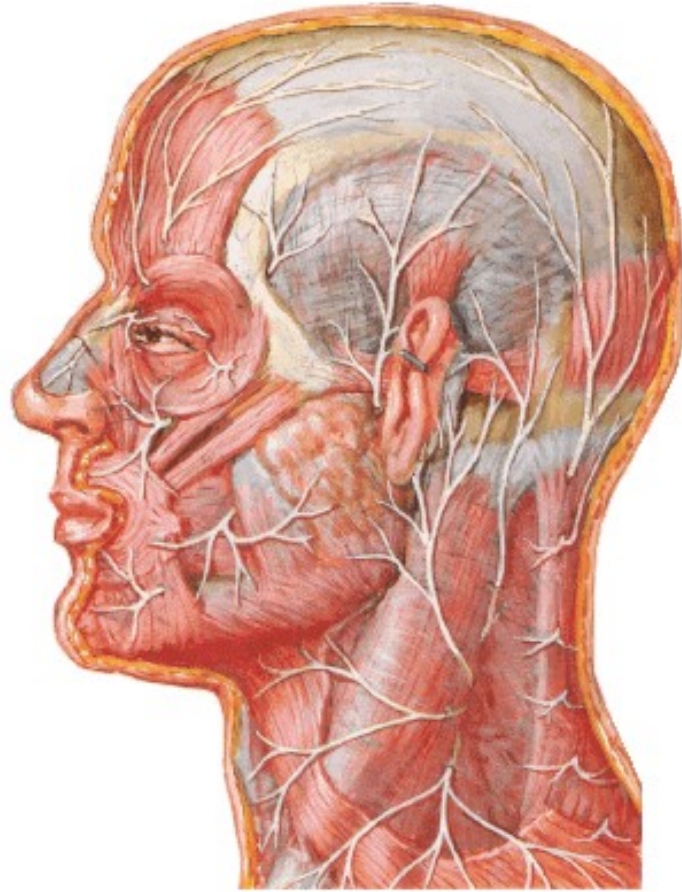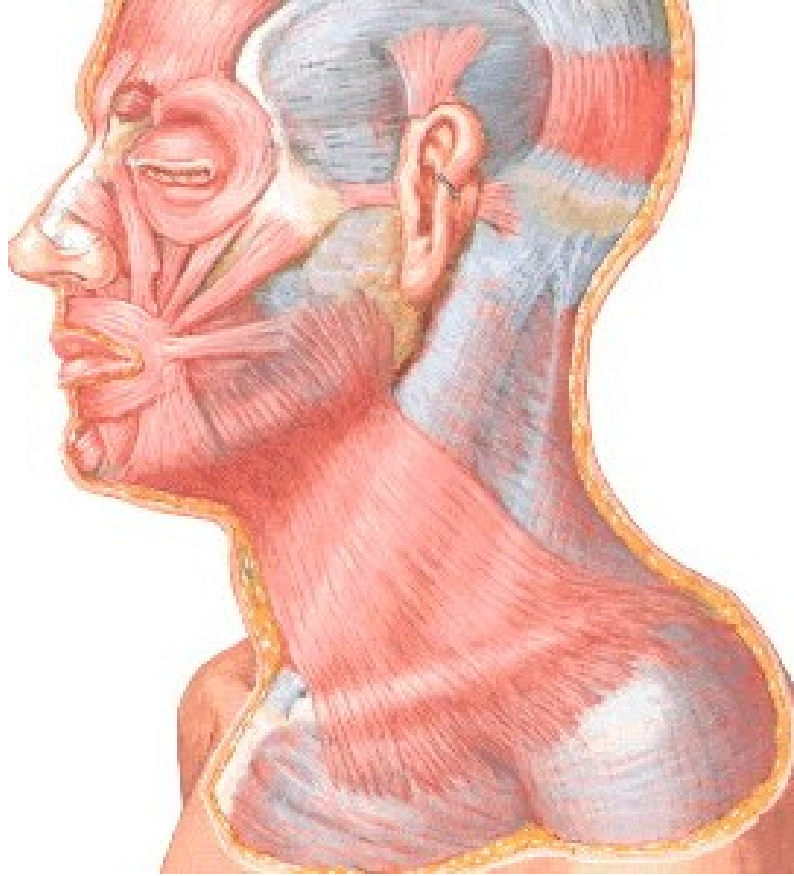
Trigonum caroticum



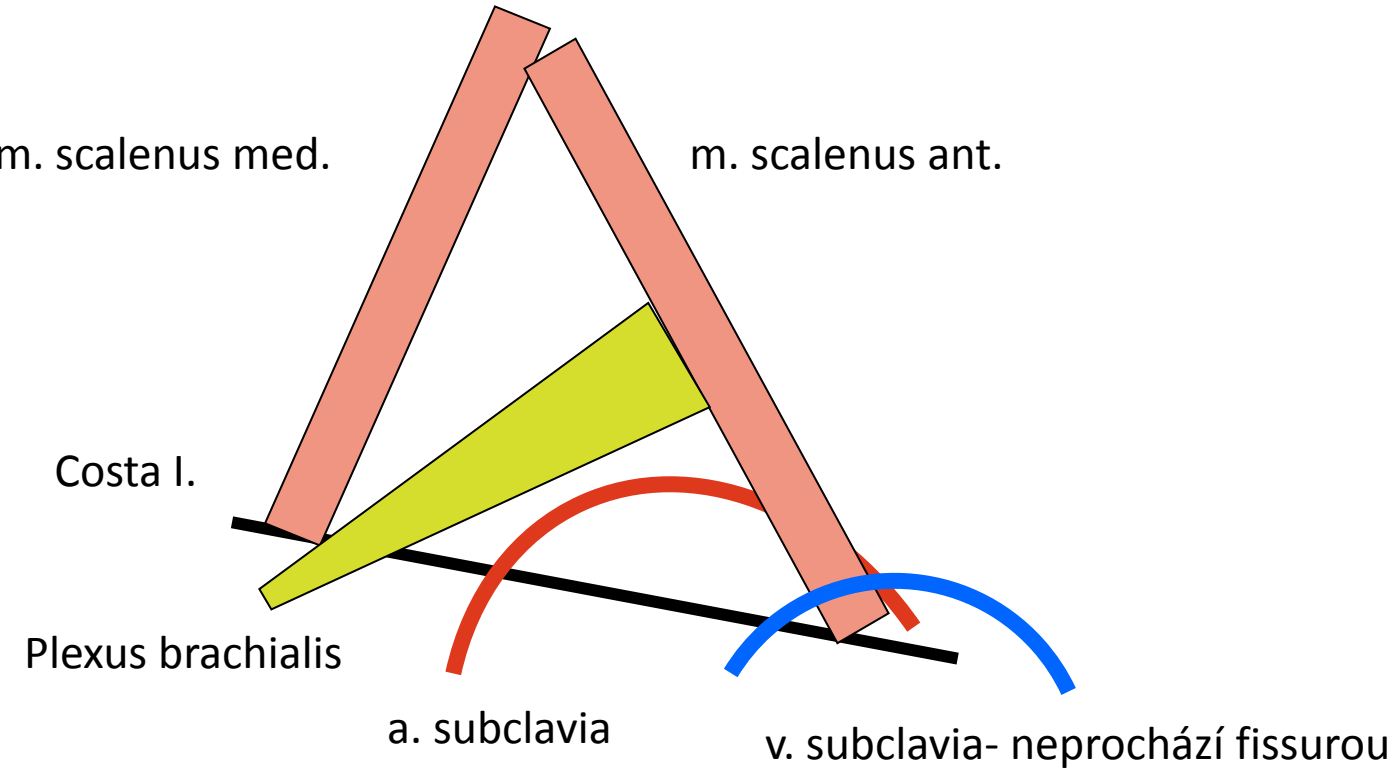
Regio sternocleidomastoidea



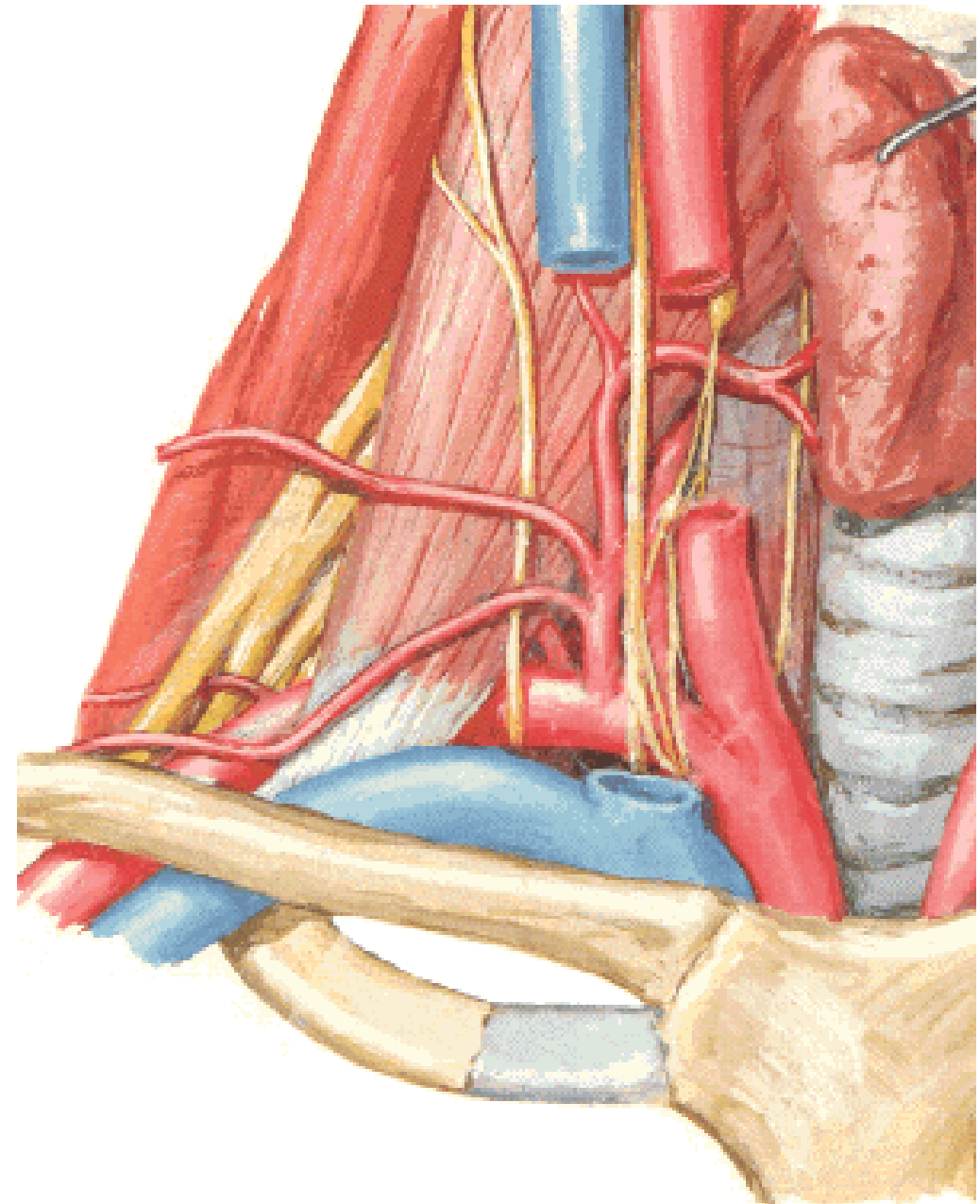
Regio colli laterale



Fissura scalenorum

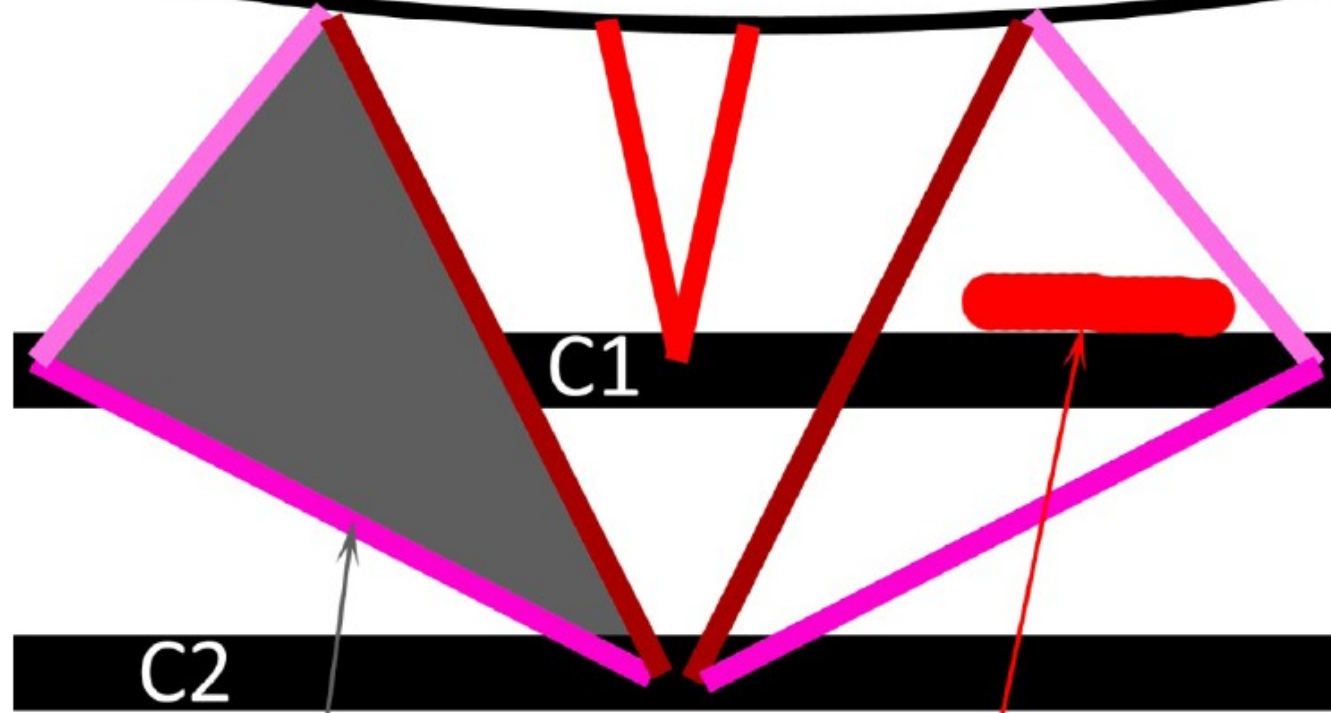


Trigonum scalenoverterale



Trigonum suboccipitale

Linea nuchae inferior



Trigonum suboccipitale

Arteria vertebralis

