

MUNI MED

Chrupavka

Chrupavka hyalinní, elastická, vazivová

Chondrocyty

Mezibuněčná hmota

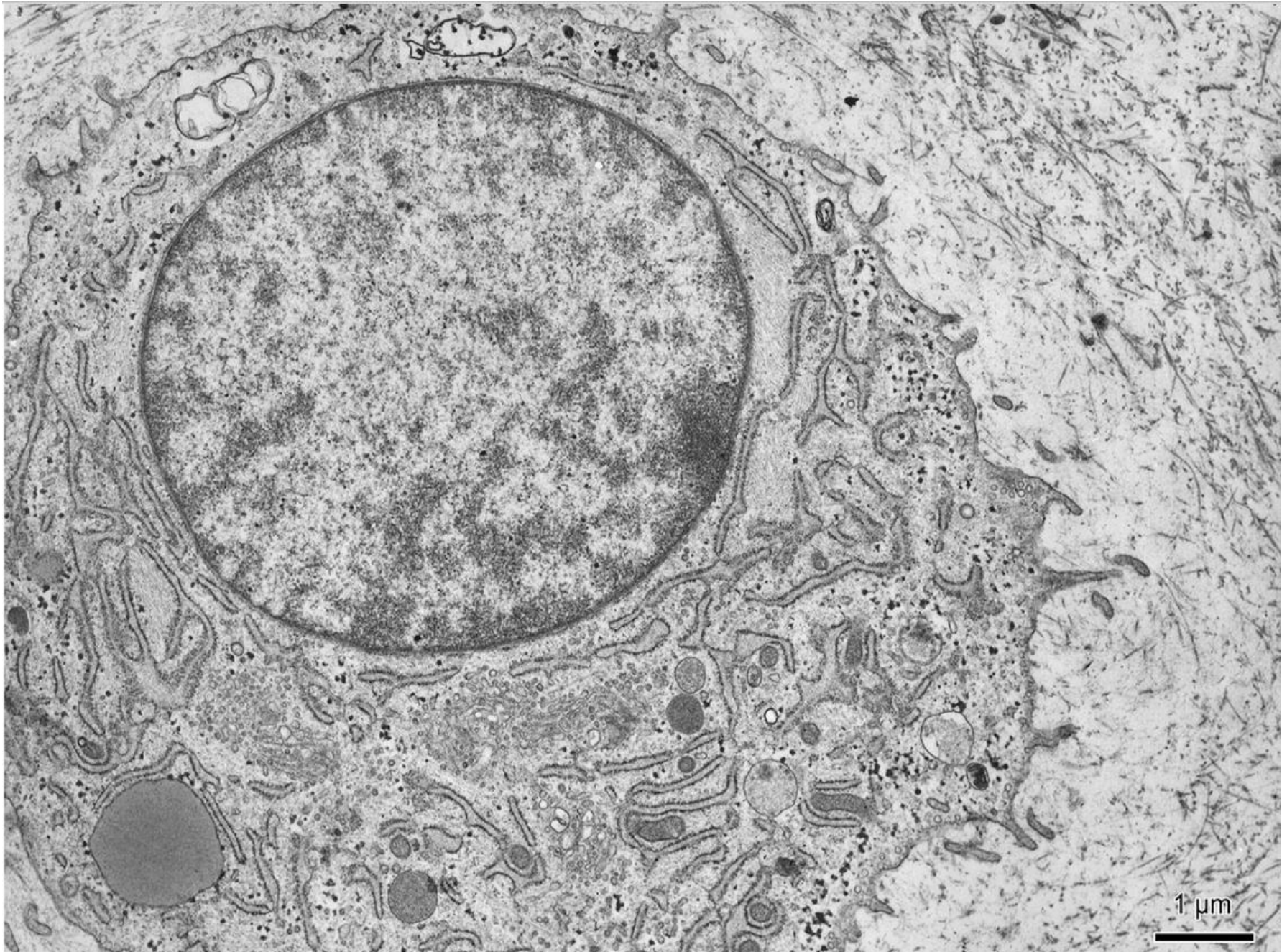
Kost

Kost vláknitá, lamelózní (kompaktní, spongiózní)

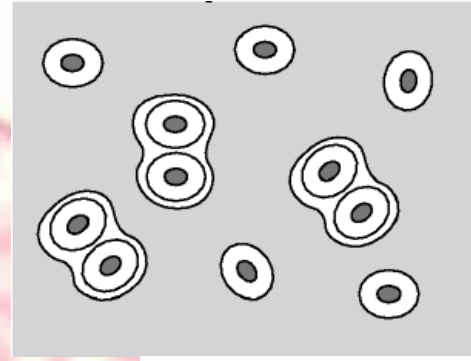
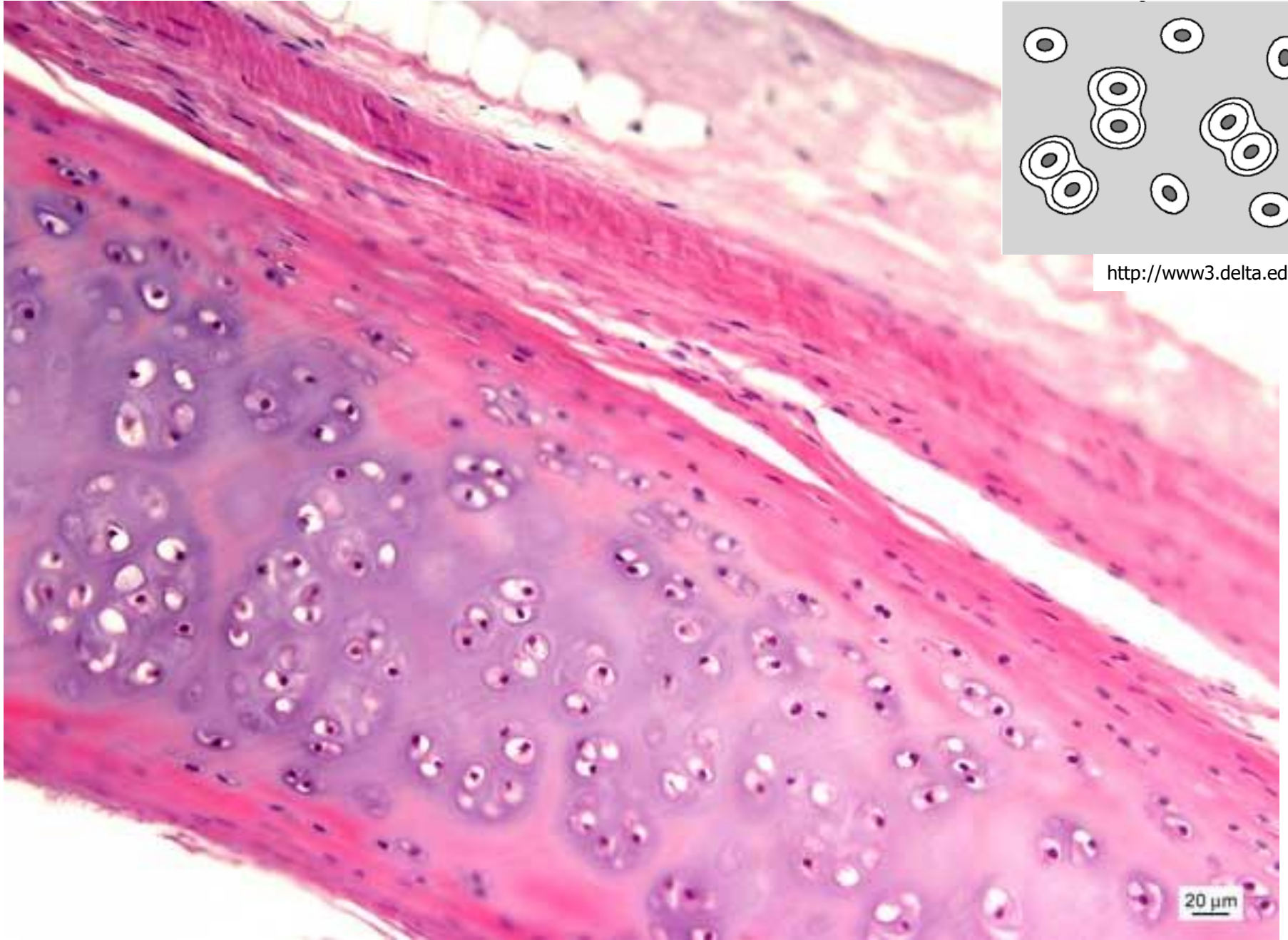
Osteocyty, osteoblasty, osteoklasty, osteoprogenitory

Mezibuněčná hmota (mineralizace)

Chondrocyt



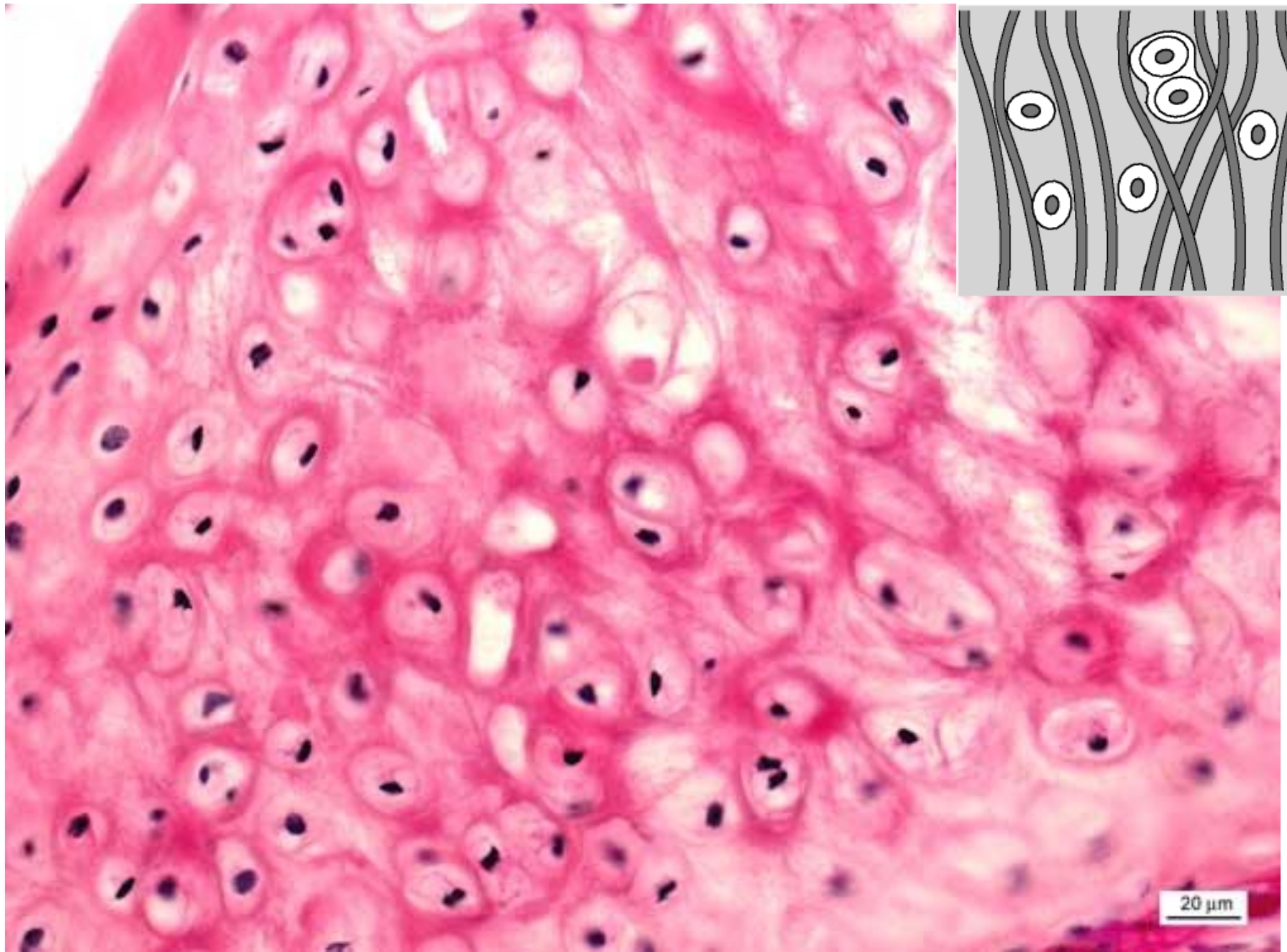
Hyalinní chrupavka - trachea (HE)



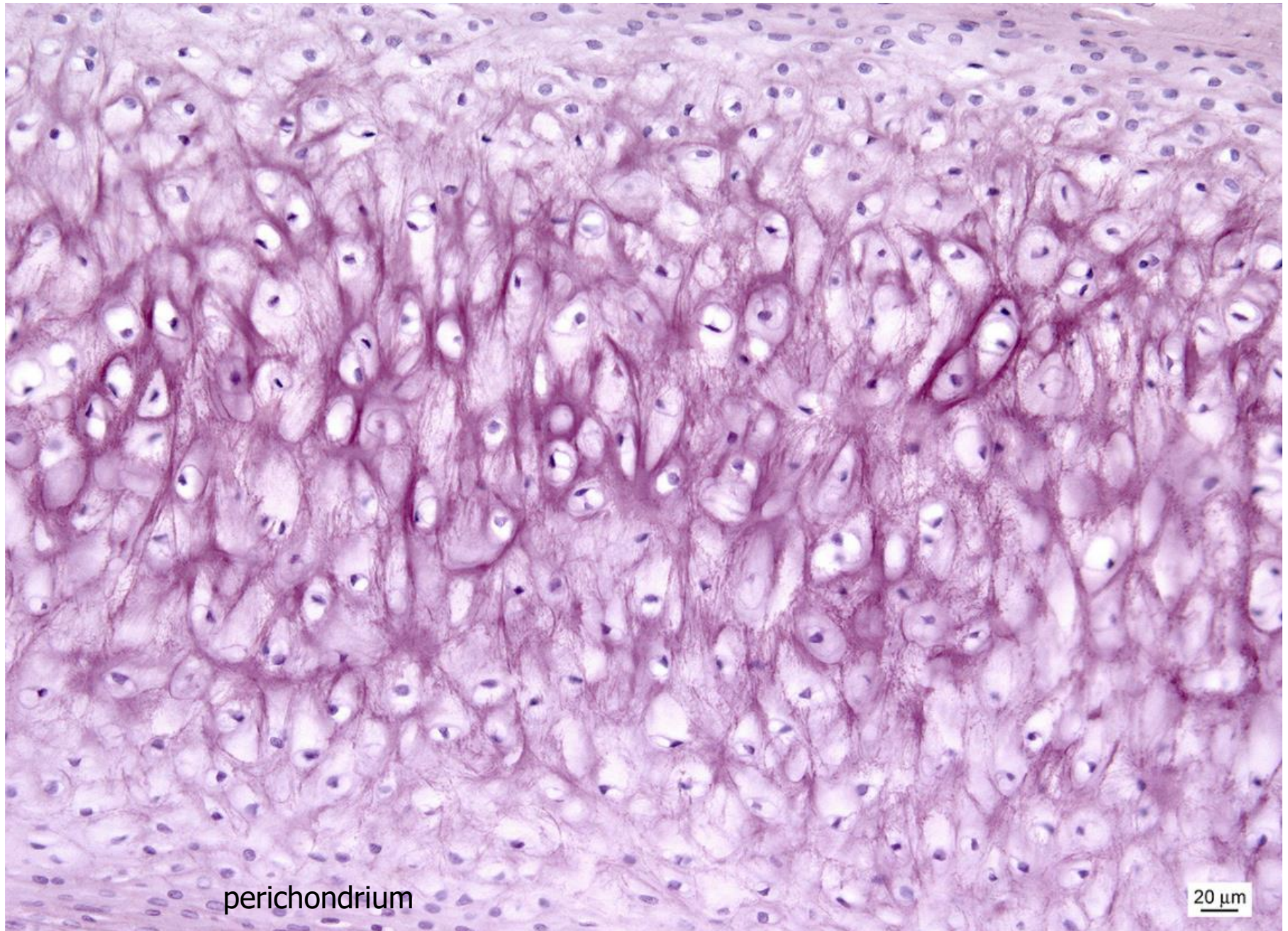
<http://www3.delta.edu/>

20 μm

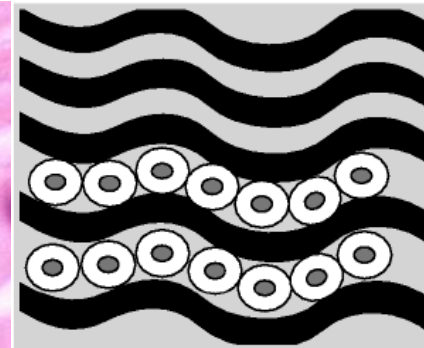
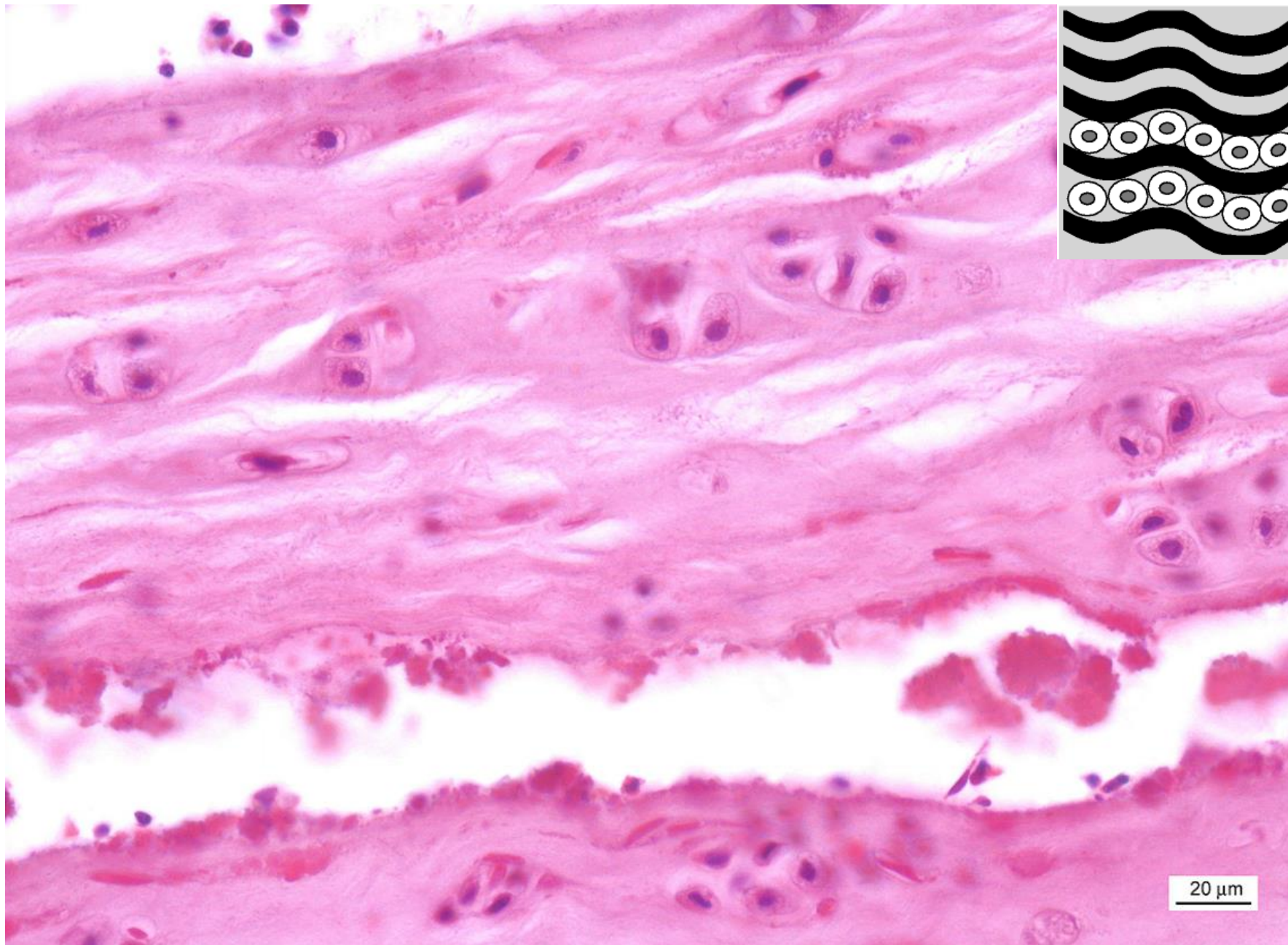
Elastická chrupavka – aurikula (HE)



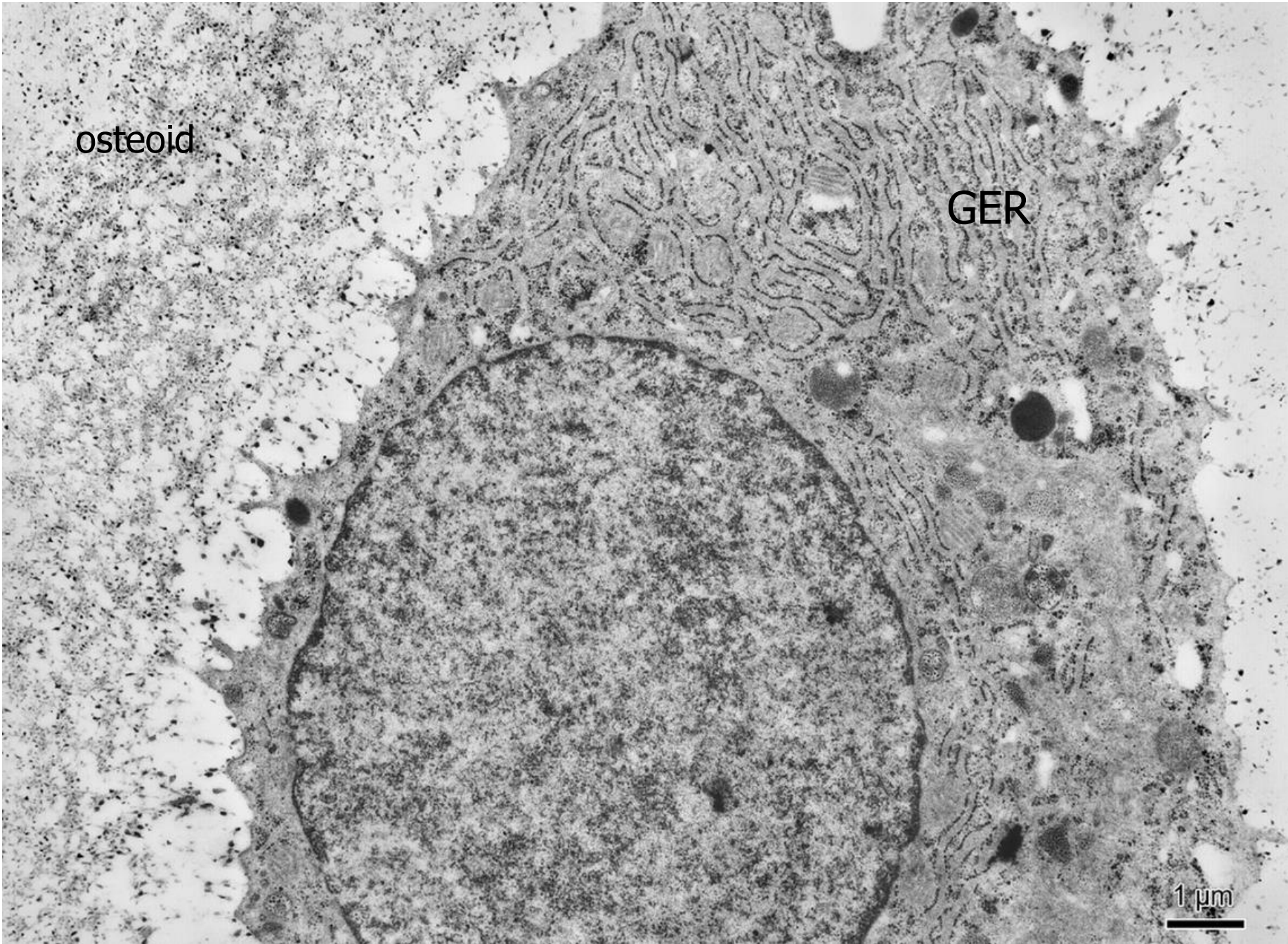
Elastická chrupavka – průkaz elastických vláken (aldehydový fuchsin)



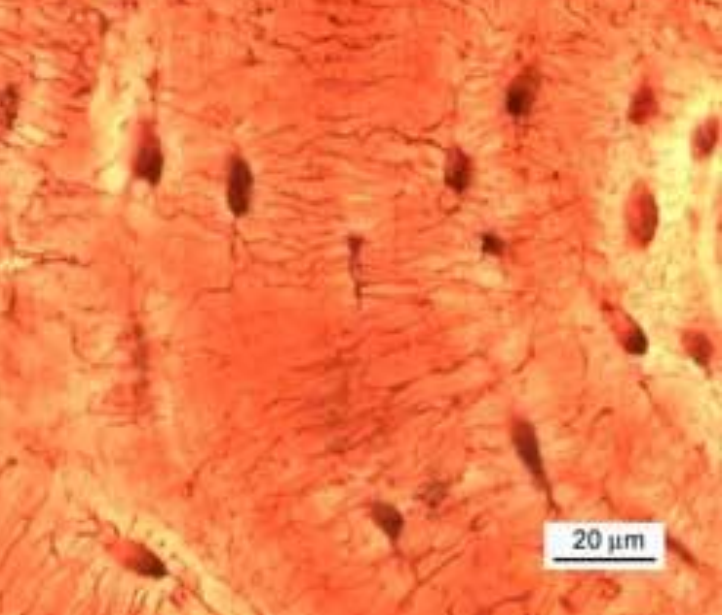
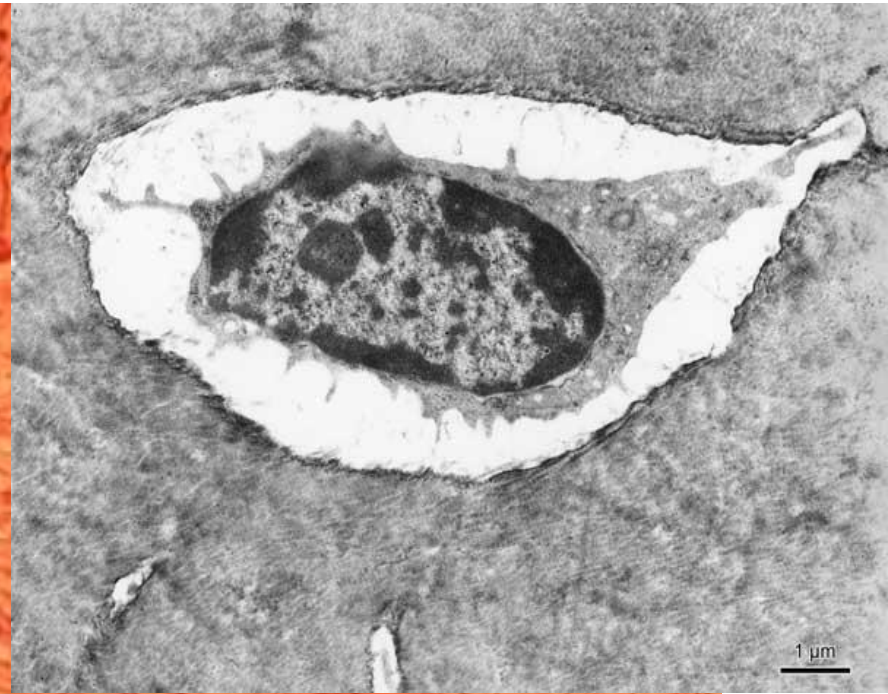
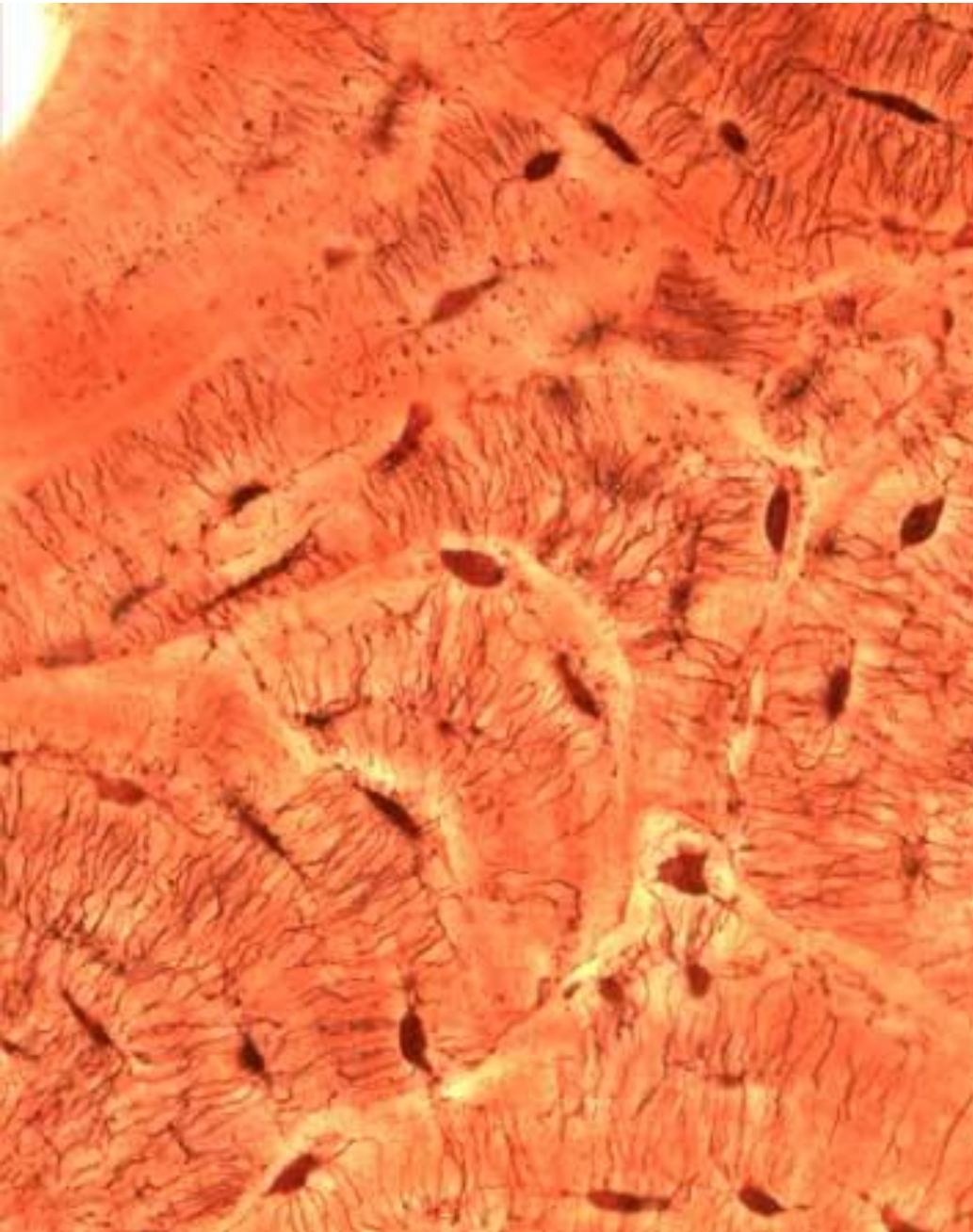
Vazivová chrupavka – meziobratlová ploténka (HE)



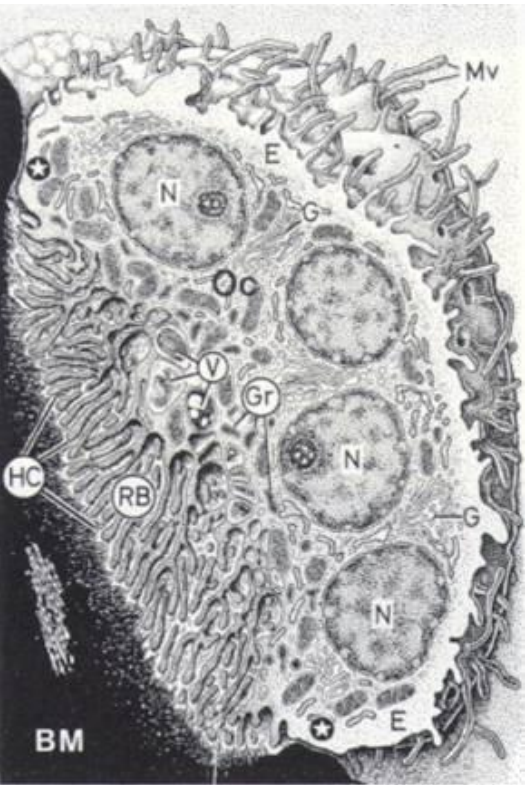
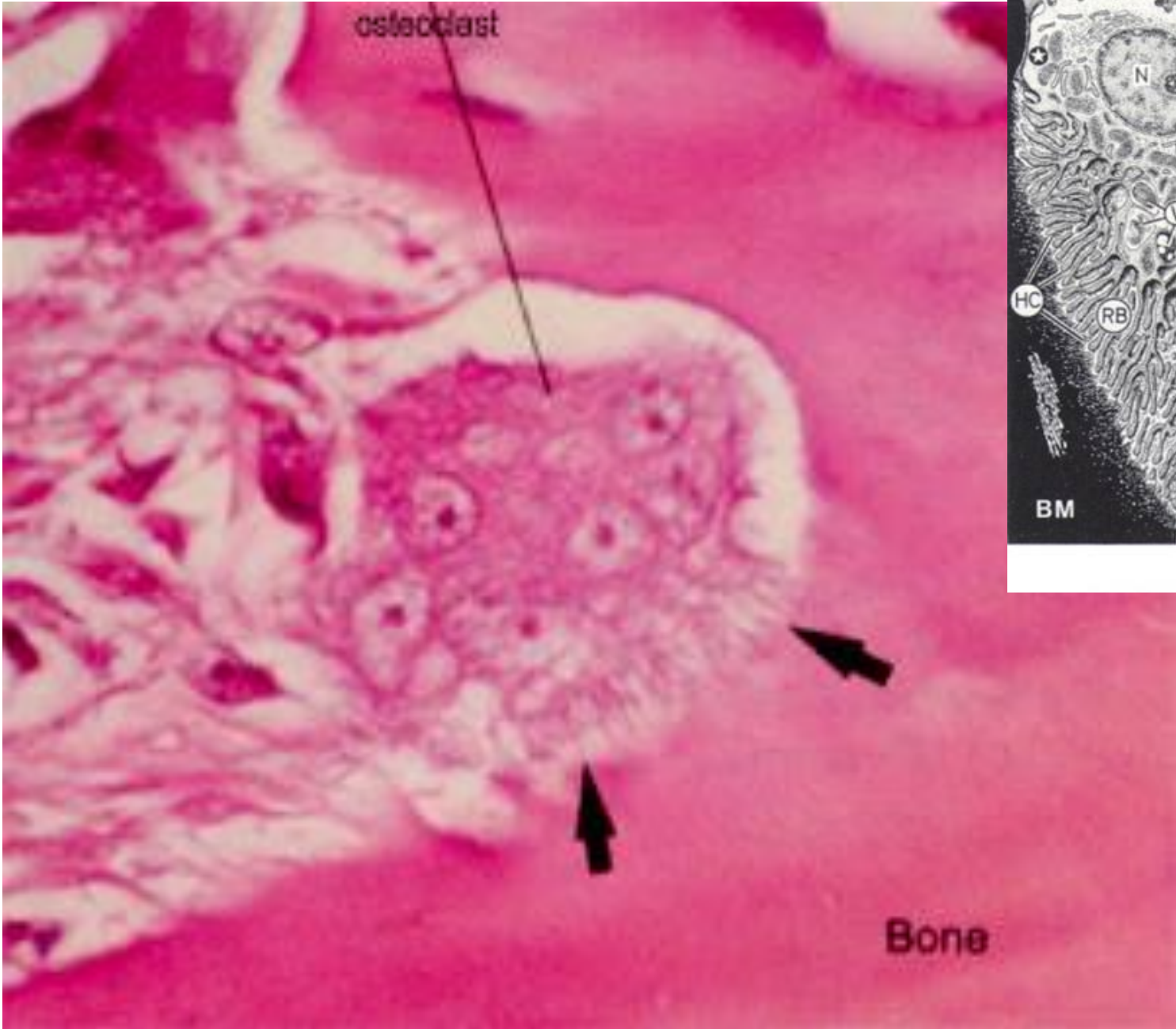
Osteoblast



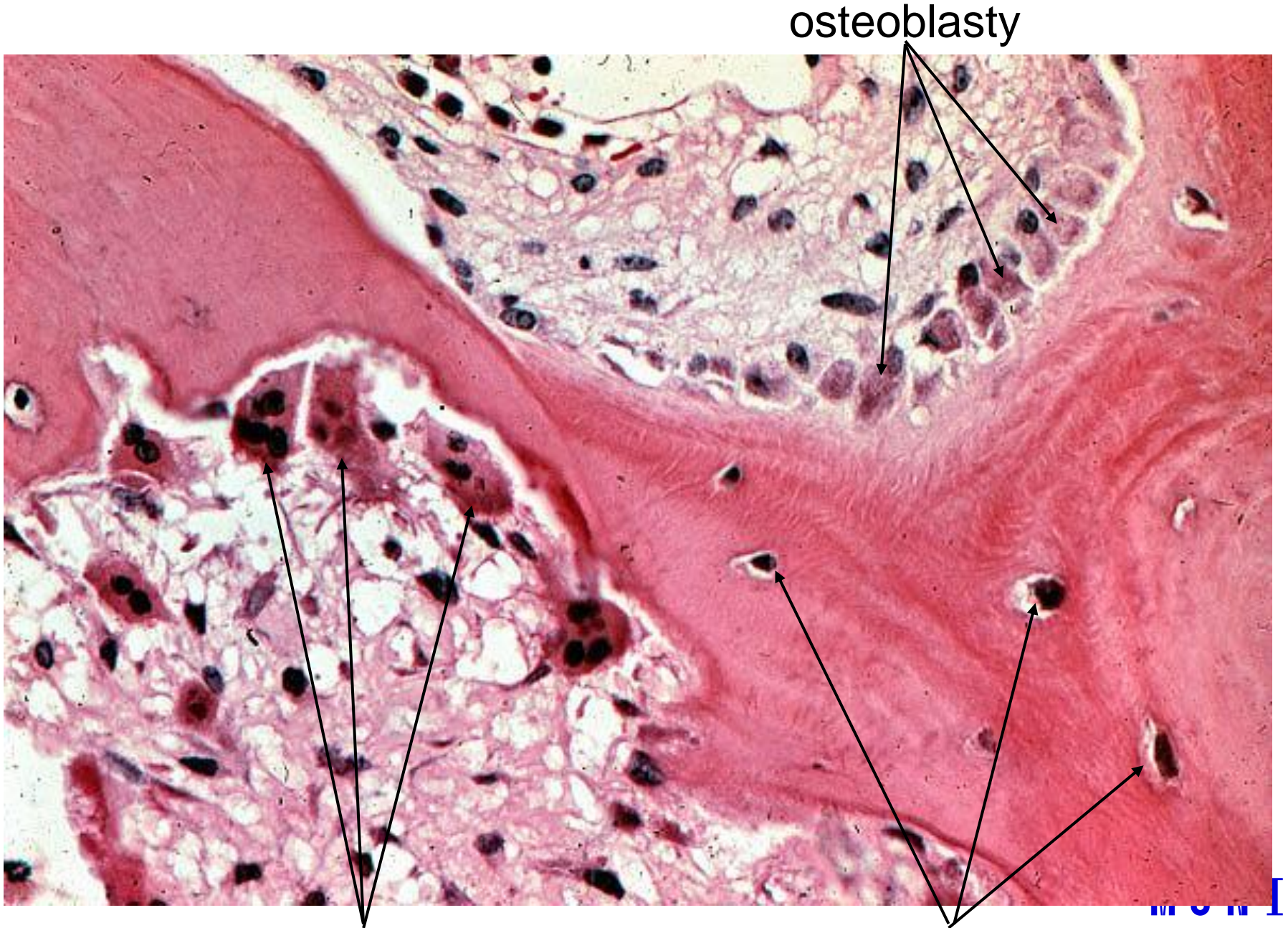
Osteocyt



Osteoklast



www.studyblue.com



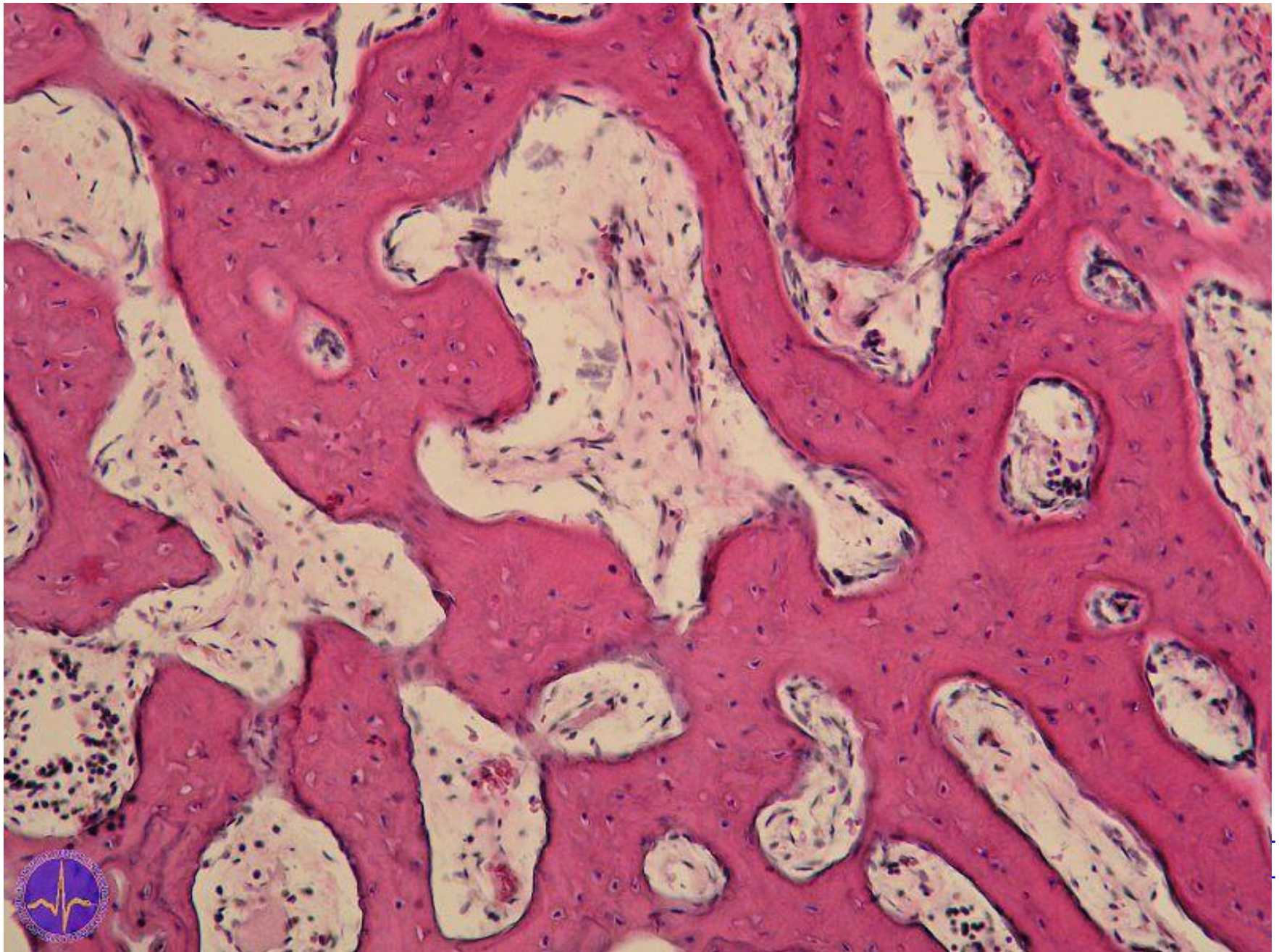
osteoblasty

osteoklasty

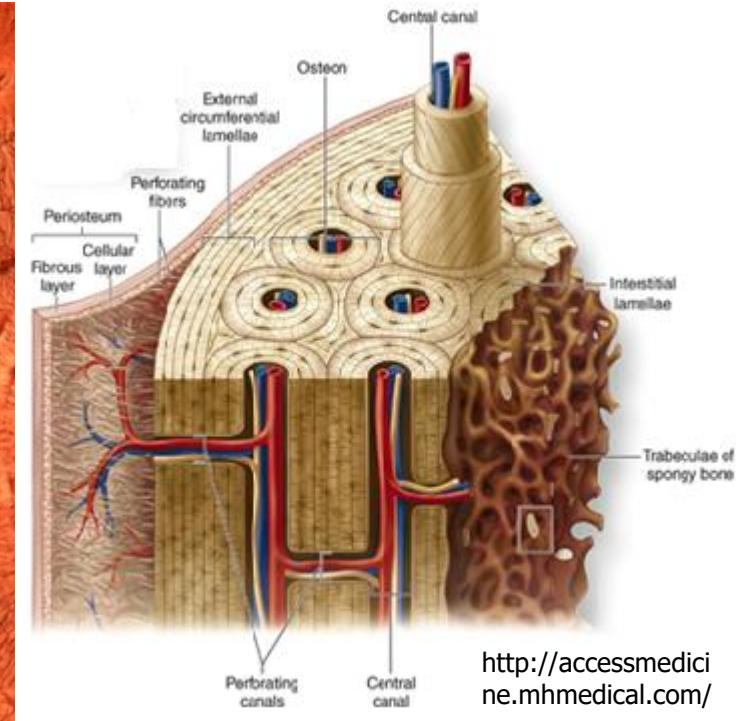
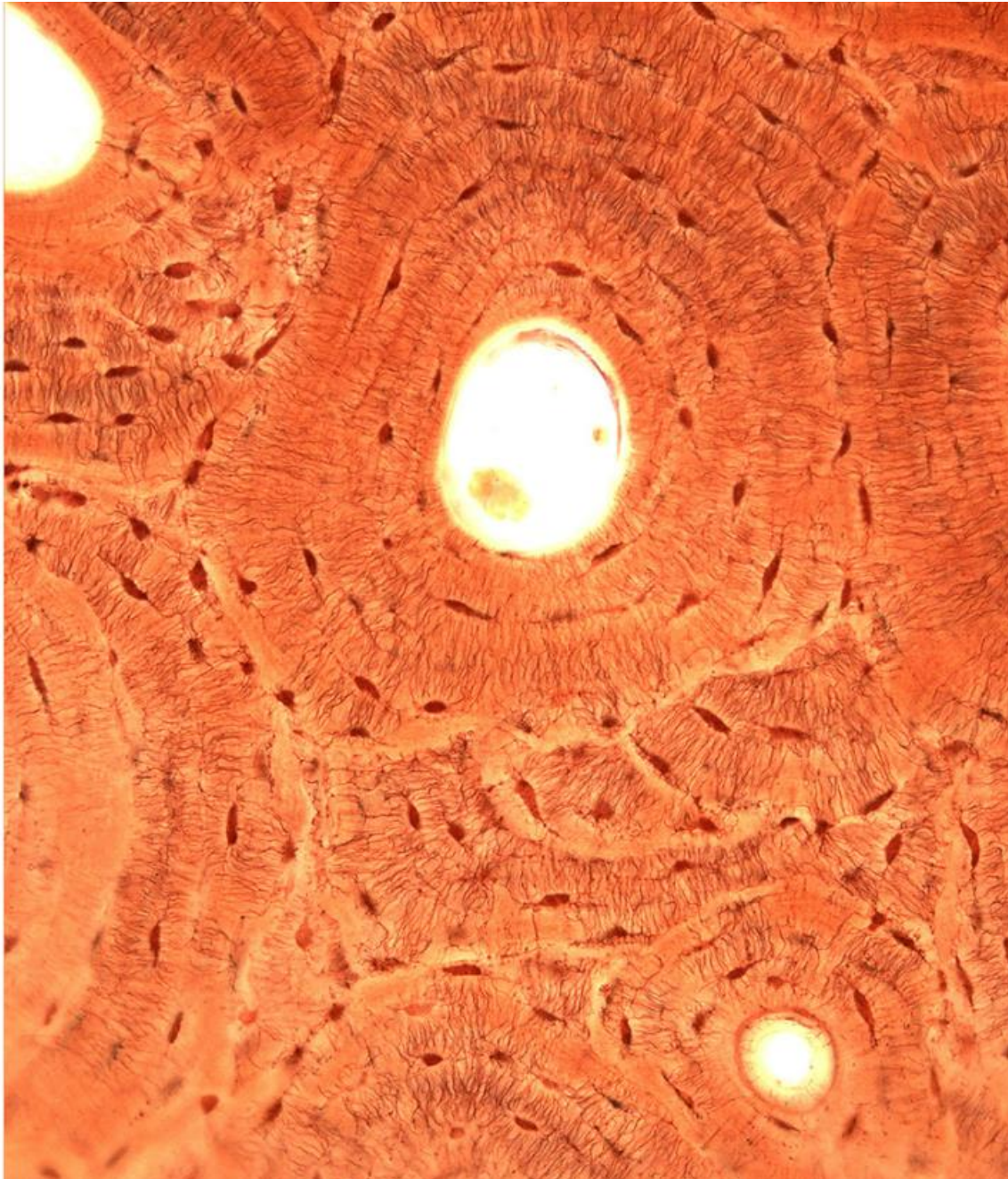
osteocyty

UNIVERSITY
OF MEDICINE

Vláknitá kostní tkáň

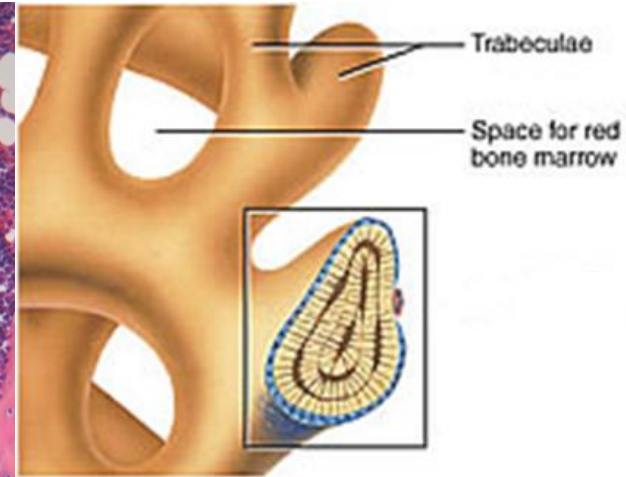
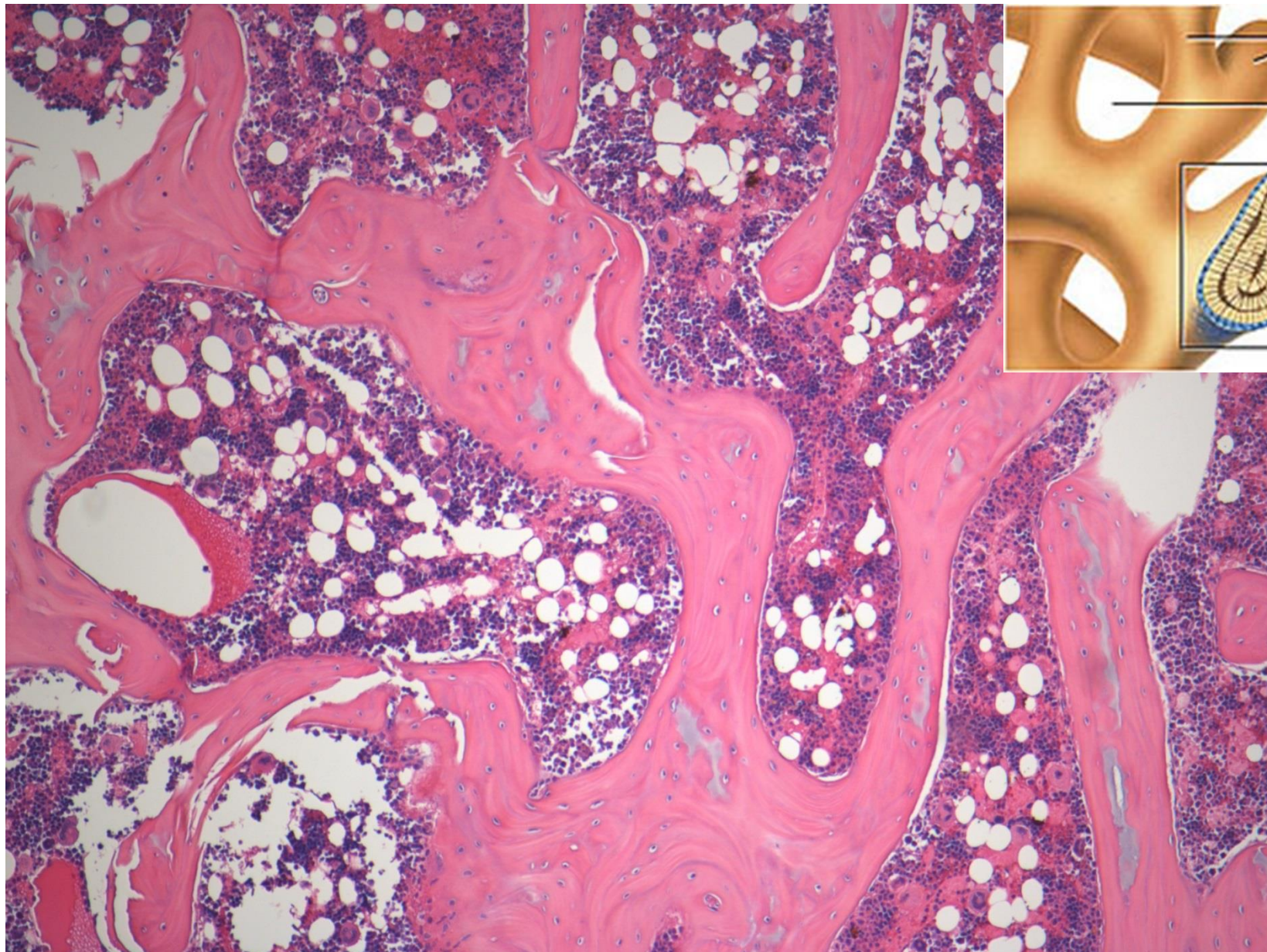


Lamelózní kost kompaktní (Schmorl)



20 μ m

Lamelózní kost spongiózní (HE)

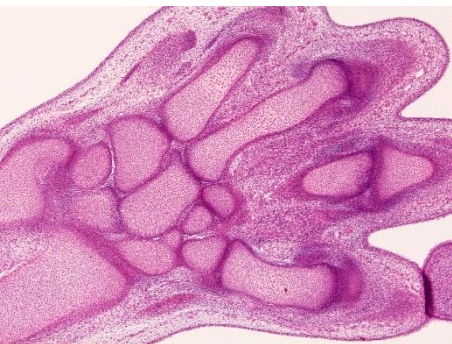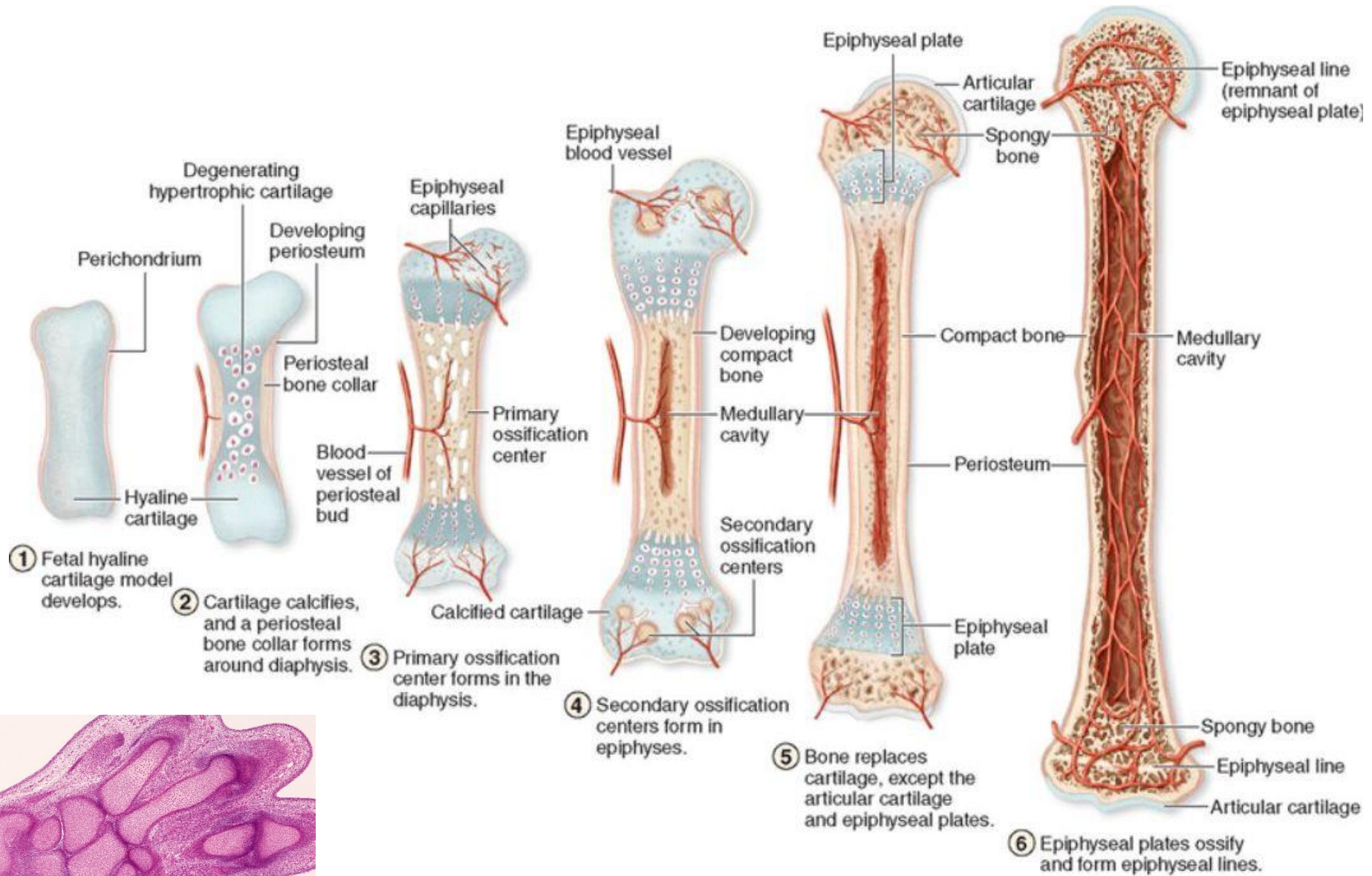


studydroid.com

MUNI
MED

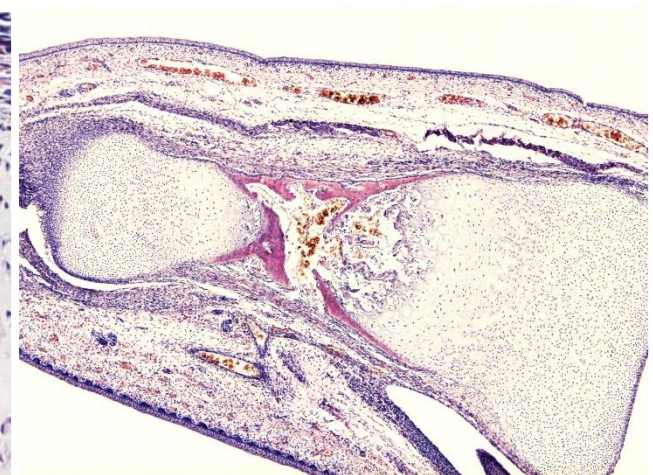
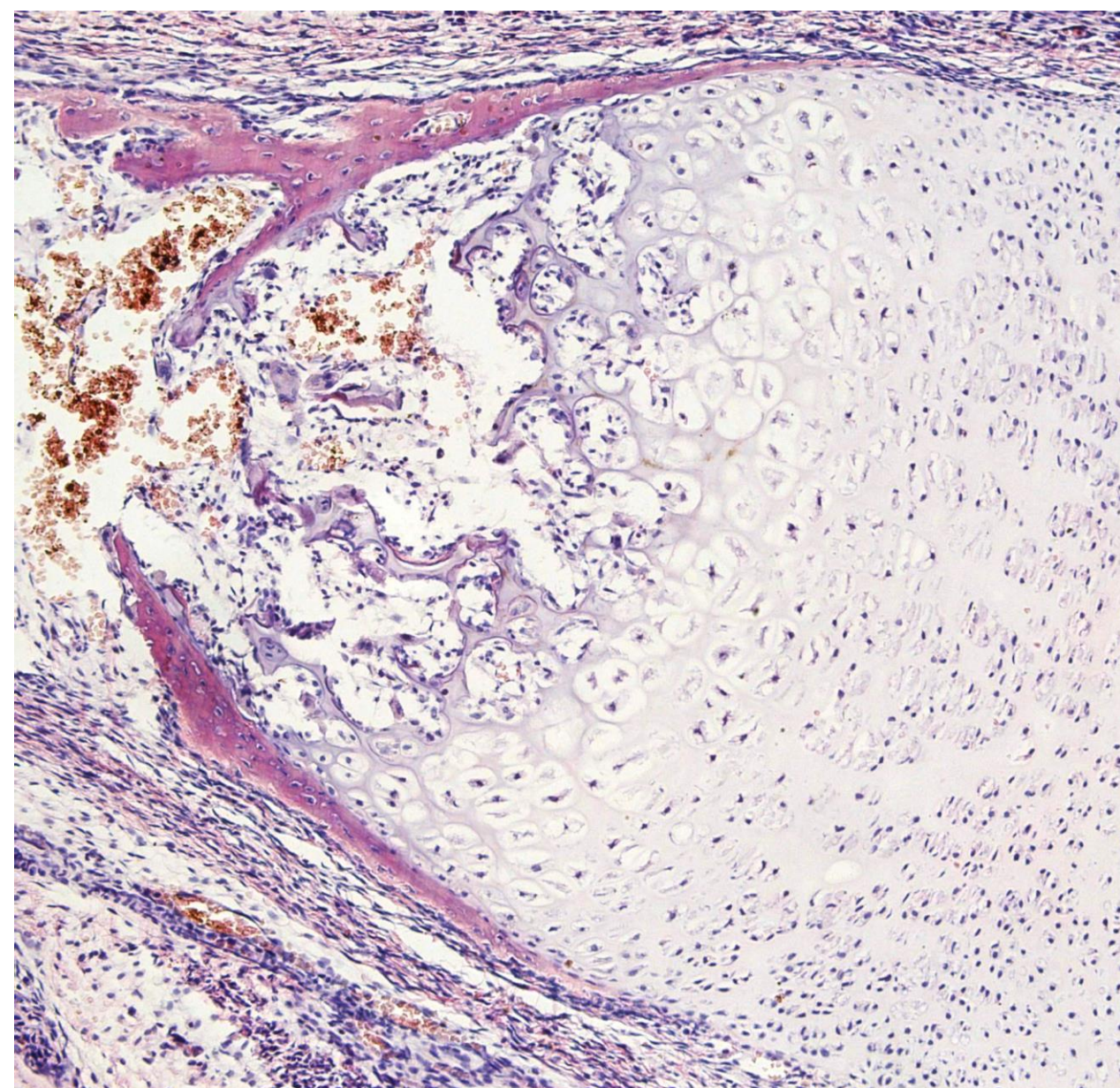
imgkid.com

Chondrogenní osifikace

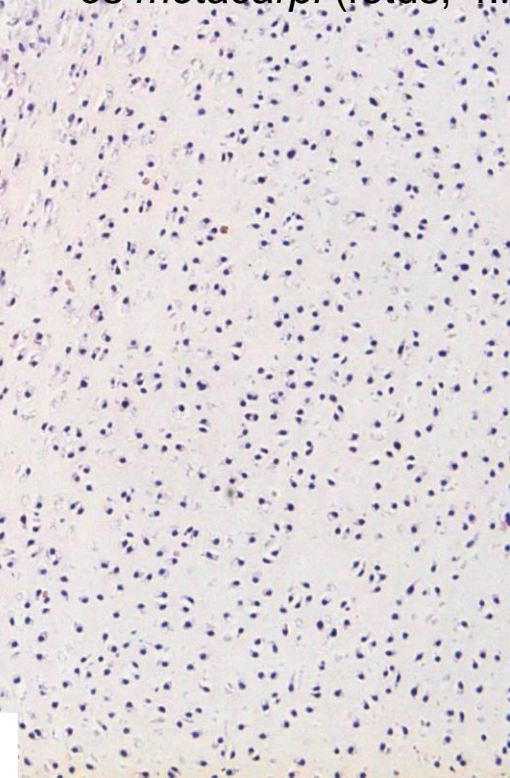


ruka, fetus, 8. týden, model hyalinní chrupavky (HE)

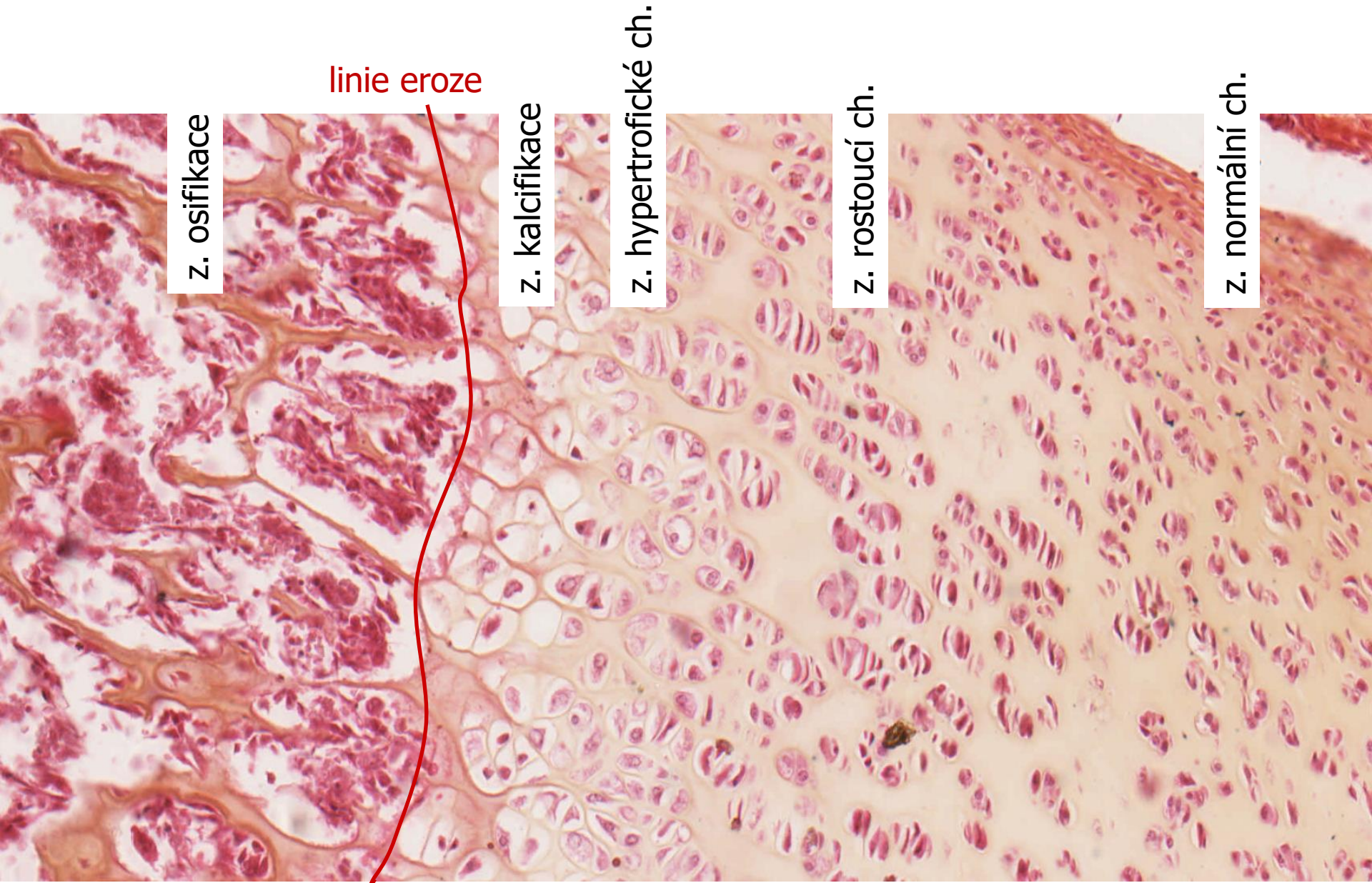
Chondrogenní osifikace (HE)



os metacarpi (fetus, 4.m.)



Chondrogenní osifikace (HEŠ)



POJIVOVÉ TKÁNĚ II – chrupavka a kost:

Preparáty:

Hyalinní chrupavka (27. Trachea)

Elastická chrupavka (94. Auricula, 28. Elastická chrupavka - orcein)

Lamelózní kost (95. Kost – HE nebo Schmorl)

Chondrogenní osifikace (96.)

Atlas EM:

strany 38 - 41